

WOOD (J.A.)

POTT'S DISEASE;

OR,

ANGULAR CURVATURE OF THE SPINE.


CASES SUCCESSFULLY TREATED

BY

J. A. WOOD, M.D.,
OF BOSTON, MASS.

AND REPORTED IN THE NEW YORK JOURNAL OF MEDICINE,

November, 1857.



New York:

THOMAS HOLMAN, STEAM BOOK AND JOB PRINTER,
CORNER OF CENTRE AND WHITE STS.

1859.



POTT'S DISEASE ;

OR,

ANGULAR CURVATURE OF THE SPINE.

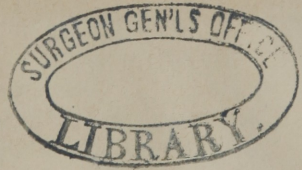
CASES SUCCESSFULLY TREATED

BY

J. A. WOOD, M.D.,
OF BOSTON, MASS.

AND REPORTED IN THE NEW YORK JOURNAL OF MEDICINE;

November, 1857.



New York:

THOMAS HOLMAN, STEAM BOOK AND JOB PRINTER,
CORNER OF CENTRE AND WHITE STS.

1859.

JACOB A. WOOD, M.D.,

GIVES SPECIAL ATTENTION TO THE TREATMENT OF

CURVATURES OF THE SPINE AND SPINAL DISEASES,

And may be consulted at his Office, No. 31, Cooper Institute, New York, from 9 A. M. to 2 P. M., and from 3 to 5 P. M.; also, at his Office, No. 215 Washington Street, Boston, Mass., one week, alternately, in each place.

CHARLES H. SPRING, M.D.,

Is associated with Dr. Wood, in the treatment of Spinal Diseases, and may be found in constant attendance, at the office in Boston.

POTT'S DISEASE;

OR,

ANGULAR CURVATURE OF THE SPINE.

Having devoted my time and attention to the treatment of spinal diseases, as a specialty, for the last three years or more, examining closely the results that have followed, I now propose to show, by the report of cases which have been under my charge, that a cure in Pott's Disease of the Spine may not, perhaps, in all cases, "necessarily consist of curvature," as is generally maintained; that the further progress of the curvature may generally be arrested from the time treatment is commenced, and, in cases of recent character, a cure effected with the curvature nearly, if not completely removed, by appropriate mechanical appliances principally, to the entire exclusion of setons, issues, or any other counter irritant, or even restricting the patient to the recumbent position.

Case 1.

Master —, æt. 9 years, son of Dr. Lyman Bartlett, of New Bedford, Mass., was placed under my care for the treatment of angular curvature of the spine, December 14, 1855.

The early history of this patient, as related to me, bore upon its face an unfavorable cast—three uncles, on the mother's side, having died in childhood of consumption, which they inherited from their mother, another victim of that treacherous disease. The patient, himself, exhibited early and repeated indications of premature decay, and, in the Autumn of 1854, began to complain occasionally of pain in the left hip.

In January, 1855, had an attack of croup, followed with severe paroxysms of cough, which continued about three weeks, when an attack of measles supervened, of extreme severity.

For three months following the attack of croup, little or no respiratory murmur was perceptible in the left lung.

While recovering from the measles, the patient having occasion to get up in the night, it was ascertained that he could not stand upright, but was obliged to support himself by placing his hands upon his knees. This led to the discovery of a curvature of the spine, with a small knuckle, which was distinctly marked.

The pain in the back and legs was severe, extending to the knees and ankles, and affecting other parts of the system; the pain occurring at intervals, and the curvature continuing to increase from this up to the time I first saw the patient—some ten months after. The history, thus far, I obtained from the Doctor himself, who is scrupulously exact in noting observations, and in the statement of facts. The disease had now existed more than a year, affecting, particularly, the three lower dorsal vertebræ, producing a bold, angular projection of the spine backwards, a pending and prominent abdomen, with a flattened chest. The lower extremities were contracted and drawn up, the left about an inch shorter than the right, and any effort to extend them was painful to the patient.

The pain was severe, the lower extremities nearly powerless, and but faint hopes had been entertained of a final recovery. He was now utterly unable to stand, and had not been dressed for nearly six months, wearied and worn, as this class of patients usually are, from pain, and suffering, and continued confinement.

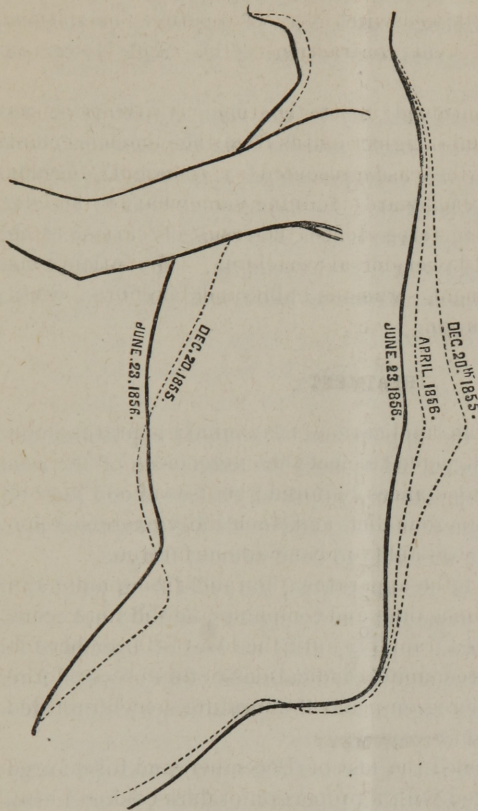
TREATMENT.

This consisted in the application of a spinal apparatus of recent invention, constructed and applied upon a *new* principle, nicely adjusted, and readjusted from time to time as the necessity of the case demanded.

This afforded efficient and comfortable support to the spinal column, enabling the patient to resume, at once, the erect position and move about, cautiously at first, upon his feet, which he was permitted to do daily, as his strength and other circumstances would allow. Galvanism was applied by friction with the hand to the back and limbs once or twice a day, and continued for some length of time, with the use of a free and generous diet.

On the application of the apparatus the relief from pain was *immediate* and *complete*, and in a few weeks the lower extremities

were of equal length, and could be fully straightened without the least difficulty.



The patient quickly recovered, has grown rapidly, and has since fully regained his vigor, strength, and powers of locomotion, in either of which he would not now appear deficient in comparison with others of his age. The accompanying outlines of the case were taken by the Doctor at his own suggestion, a gentleman of high professional reputation, who very kindly offered them to me, unsolicited, recommending their publication as a matter of medical interest. The anterior and posterior dotted lines represent the *precise* form of the patient as exhibited

December 20, 1855. The two shaded, or dark lines represent *correctly* the form of the patient, June 23, 1856 (six months after), with the curvature nearly obliterated, the abdomen less prominent, with a full and capacious chest. *It should be here observed, that the curvature, since the last outline was taken, has gradually diminished, till every appearance of it has become extinct.*

Case 2.

Miss R., æt. 13 years, only daughter of Lineas Wood, Esq., of New Bedford, Mass., was placed under my care for the treatment of Pott's Disease of the Spine, May 31, 1856.

The disease commenced in October, 1855, with severe pain in the right hip, extending down the thigh, and occurring in paroxysm. This took place more frequently at night, often depriving the patient of rest, followed with loss of appetite, emaciation, general debility, and great contraction of the right lower extremity.

These symptoms continued up to the time my attention was first called to the patient—eight months from the commencement of the disease—when the case presented a prominent, angular curvature of the spine backward, inclining somewhat to the left, shortening the right leg three inches, the result of caries of the two upper lumbar and lower dorsal vertebræ. The patient was of a nervous temperament, strumous habit, and lax fibre, with a weak and frail constitution.

TREATMENT.

This consisted in the application of a spinal apparatus upon the *new* principle, constructed to meet the exigencies of the case, and readjusted as circumstances required, the use of cod liver oil, three times a day, a generous diet, and such daily exercise upon the feet as the patient was able to bear without fatigue.

On the adjustment of the apparatus, the relief from pain, as in the former case, was immediate and complete, and did not recur.

The patient improved rapidly, until the last of December following, when there were manifest indications of an abscess, forming in the right lumbar region near the curvature, which retarded somewhat the process of recovery.

The abscess was opened the last of December, and discharged three pints of pus, mixed with a proportion of dark-colored blood.

The discharge continued abundant for several weeks, and at a subsequent period, numerous pieces of bone, varying from one-quarter to half an inch in length, passed with the discharge of matter.

October 1, 1857.—The abscess is now healed, the curvature completely reduced, the lower extremities of equal length, original form fully restored, and the patient, whose weight at the time I first saw her (sixteen months since) was only sixty-five pounds, has now attained to one hundred and fourteen pounds, and, in all respects, has a healthy and robust appearance.

LETTER FROM DR. BARTLETT.

NEW BEDFORD, Nov. 10, 1857.

Dr. J. A. Wood, *Boston*.

DEAR SIR:—I have just read, in the proof of the forthcoming number of the *N. Y. Journal of Medicine*, your report of two cases of Pott's Disease of the Spine. The cases are correctly reported, but more facts of interest connected with them might have been given.

The case of the Irish girl, on Sixth Street, at Mrs. Dunbar's, which you have *not* reported, is quite as remarkable in all respects as either of the above. Your treatment of her case was commenced early in 1855. She has been perfectly well for more than a year.

I cannot urge upon you too strongly the importance of taking outline drawings of all cases where much deformity exists. They would have been equally as striking in the last two as in the first of the above cases, if they had been taken.

The other cases treated by you in New Bedford, although *not* less successful or important than the above outlines, are of less consequence, because less deformity existed.

Very respectfully yours,

LYMAN BARTLETT.

Case 3.

Son of Mr. Otis Gay, of West Roxbury, Mass., aged 2 years and 1 month, of light complexion and scrofulous diathesis, came under treatment for Pott's Disease of the Spine, June 15, 1855.

The deformity in this case consisted both of a lateral and angular projection of the spine, each well defined and strongly marked, as seen in fig. 1.

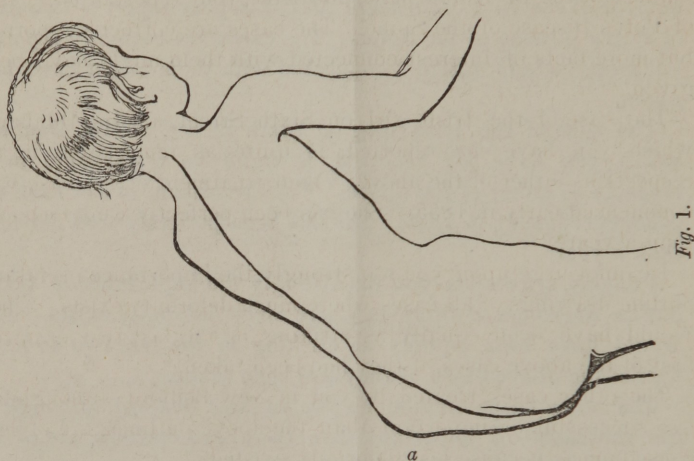The former consisted of a bold reflection of the spine to the left, extending from the cervix to the sacrum, and the latter of an angular projection of the eighth, ninth, and tenth dorsal vertebræ.

To avoid tedious detail, I give only a few of the leading facts in the history of this case, as related by the mother.

She informed me that the child had always evinced a peculiar weakness of the back from its birth, a few months after which, an irregularity in the course of the spine was discovered.

There was a tardy development of strength, and a manifest want of the ordinary physical force and energy in the child up to

the age of 16 months, when it was suddenly attacked with apparent paralysis, and remained *perfectly* helpless for many weeks, with slight, *occasional* febrile excitement, extreme paleness, and ultimate emaciation.



The recovery from this attack was protracted and imperfect, during which the deformity continued with a more rapid increase than at any previous period of the disease, and, overpowered by all the contingencies in the case, the child had never been able to walk, up to the commencement of the treatment.

The body was thrown into such a position, by this distortion of the spine, that the abdominal viscera were pressed with great force into the left iliac region, presenting there the appearance of a large tumor, as seen at (a) in the above cut.

The early history of this case, and its subsequent developments, suggest the following inquiry. Is Pott's Disease of the Spine *ever* congenital?

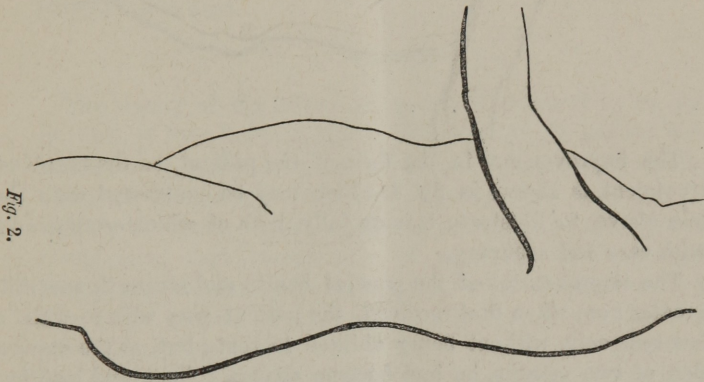
The treatment applied in this case, was simply mechanical, spring-like in its action, and comfortable to the patient, a generous diet and exercise in the open air.

Four days from the first application of the apparatus, the patient walked across the room, and four weeks from that time, he walked a third of a mile without any apparent fatigue.

By keeping the apparatus well adjusted, and supporting properly every part embraced by it, the general health and strength

improved rapidly, the deformity gradually diminished until nearly removed, when the process was somewhat interrupted by inattention of those having charge of the child to the instructions given. Consequently, there yet remains a *very slight* lateral variation of the spine, from a normal position, yet susceptible of removal, not exhibited in fig. 2, as the objects of these reports is to illustrate more particularly, the result of treatment in angular curvature of the spine.

With this exception, fig. 2 illustrates correctly the result of treatment in the case.



The patient has grown rapidly, and for more than two years has been vigorous, robust, *fat*, and healthy.

Case 4.

Son of Mr. Horace Hopkins, of Chicago, Ill., aged 8 years, of light complexion, strumous habit, pale, emaciated, and sickly in appearance, weight 36 lbs. (precisely what it was four years previous), came under treatment for Pott's Disease of the Spine, March 3, 1857.

The disease had existed more than three years, and involved the 5th, 6th, and 7th dorsal vertebræ, producing at that point a formidable posterior projection of the spinal column, with its consequent results to the contour of the whole system, as seen in fig. 3.

Anchylolysis seemed nearly, or quite complete, and no encouragement was given as to the result of treatment, beyond an improvement of the general health, and, perhaps, to some slight degree,

the general form and figure of the patient, as circumstances would seem to forbid the accomplishment of more than that.

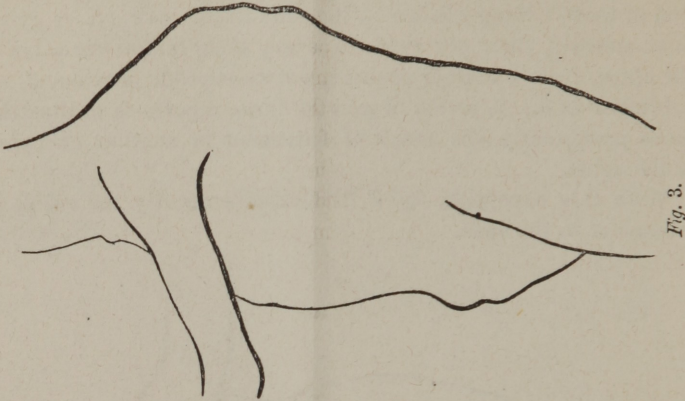


Fig. 3.

The improvement in the form of the patient, as the result of treatment, is shown in fig. 4, which may be contrasted with the one above to illustrate it more fully, both of which were drawn with care and accuracy.

The improvement of the general health and strength was still greater ; as, when first received, the patient was able to walk a few rods *only*, without being obliged to rest ; but, at the expiration of two months, he had become strong, robust, and healthy, exercising vigorously upon his feet through the day, without any apparent fatigue.

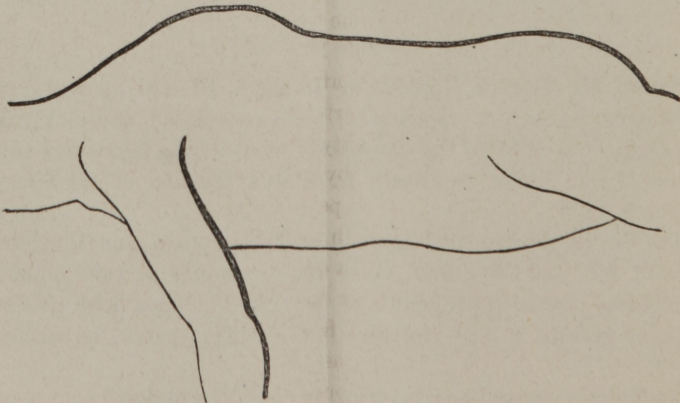


Fig. 4.

The parents were then permitted to take the patient home. In May, after the lapse of one year, he returned again greatly im-

proved, but not as much as he might have been had more particular attention been given to his case during the last six months, as the apparatus had not been kept properly adjusted, being somewhat out of repair.

This case is reported more particularly to show the advantage of well-adjusted, appropriate, mechanical support to patients embarrassed and overpowered by the *burden of position* often enforced upon them by the destruction of some portion of the spinal column.

The treatment consisted in the adjustment and readjustment of an apparatus, briefly described in a former number of the *N. Y. Journal of Medicine*, galvanism, free diet, and what exercise the patient could bear.

Case 5.

The history of the following case was furnished by Dr. Lyman Bartlett, of New Bedford, Mass., who attended the patient through the fever to which allusion is made, the patient still continuing under his charge up to the time I first saw her.

Miss Elizabeth Potter, aged 16, bluish-gray eyes, light florid complexion, dark brown hair, of scrofulous and consumptive family, was attacked with *typhoid fever* about September 12, 1857. The fever became of unusual severity, insomuch that, from the 30th September to the 3rd October, her life was despaired of. She began, and continued slowly to convalesce from about the 20th October. From the 1st to the 9th December, she was able to sit up in a chair for several hours daily.

About the 6th December, she began to complain of pain in the back on sitting up. On the 10th December, after sitting up longer than usual, she was attacked with severe pain in the region of the first lumbar vertebræ. This continued for two or three weeks with such severity, that she could not be turned in bed; and was only relieved by presence of the hand, constantly applied day and night for the period of nearly a week.

On examination (made with great difficulty on account of the pain caused by moving her), a curvature of the spine was discovered, of the length of about four vertebræ, having its centre between the last dorsal and first lumbar vertebræ, and to the degree represented in fig. 5, as nearly as could be judged; her condition rendering an exact outline drawing impracticable.

She had severe bed-sores over both trochanters, then of some

six weeks' standing, and which were not entirely healed until the February following.

Her emaciation was extreme, greater than ever before witnessed by the writer in any case, from any cause.

On raising her out of the hollow in the bed into which she had settled, and making extension and counter-extension from the ankles and head, the curvation was somewhat reduced and the pain in the spine diminished. This partial relief was continued by the firm application of a broad swathe around the loins.

Her condition did not materially improve, however, until after the 12th January, 1858, at which time Dr. J. A. Wood applied his apparatus for disease of the spine.

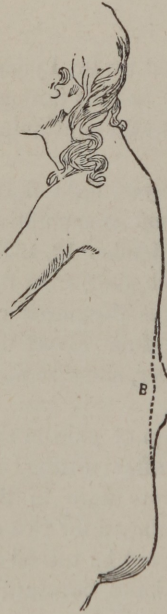

Fig. 5.

Her *great emaciation* rendered it difficult to fit the apparatus, so as not to give her annoyance, for several days. So *scraggy* was she, that it seemed like an attempt to fit stays to a *gun-lock*. By means of much padding, however, Dr. Wood succeeded, and, in the course of three or four days, relief was complete whilst the apparatus was applied; but pain returned for several months afterwards whenever the apparatus was removed.

Now (July 24, 1858), she has been able to sit up three or four hours a day for several weeks past without suffering, and can turn in bed as well as ever she could.

Her flesh and strength are now very fair, and steadily improving. She may be considered nearly cured.

In the appended cut, A represents the character and degree of deformity, as described by Dr. Bartlett, that existed previous to an attempt at its reduction and relief of the patient. B represents the position of the spinal column at the point of curvation, eight months after the commencement of treatment, the general health and strength of the patient at the same time rapidly improving.

Case 6.

Son of Mr. Charles T. Stevens, No. 8 New Prince Street, Boston, Mass., aged 5 years, of light, rather florid complexion and scrofu-

lous diathesis, was placed under my charge for treatment of Pott's Disease of the Spine, March 30, 1857.

The case then presented an angular curvature of the spine, projecting, posteriorly, nearly one and a quarter inch, involving the three lower, and having for its centre the eleventh dorsal vertebræ. The body inclined considerably to one side, and the left hip was elevated one and a half inch above the right.

Respiration was hurried and laborious, and partial paralysis of one leg, with other impediments, rendered locomotion somewhat difficult.

From the mother I obtained the following history of the case, from its commencement to the time that it was placed under my care.

In March, 1854, at the age of two years, the patient was attacked with lung fever ; whooping-cough supervening, the sickness was protracted and severe, characterized with great prostration, copious sweating, and ultimately extreme emaciation.

In the Autumn succeeding the attack, the cough still continuing from the first, hæmorrhage from the lungs ensued, of which there were several attacks, and at one time, in the space of twenty-four hours, there were, by estimation, from three to four ounces of blood thrown up in the act of coughing ; the patient becoming more prostrate and pallid, little or no hopes were entertained of his recovery.

In April, 1855, at the expiration of one year from the commencement of this sickness, the patient had, however, nearly recovered, when he was attacked with severe pain in the bowels and partial paralysis of the lower extremities accompanying ; he was deprived of the power of locomotion, which did not return again in any degree until the expiration of eight or ten months. Difficult respiration and a tumid state of the abdomen then existed to a marked degree. In the Spring of 1856, a small knuckle was discovered projecting from that portion of the spinal column already referred to, which continued to increase, with a recurrence of the pain in the bowels, at intervals, with all the general symptoms, more or less aggravated, that usually attend such cases.

March 30, 1857.—The progress of the disease has continued unabated up to the present time, and resisted all attempts to arrest it by mechanical or other means employed for that purpose,

which, as remarked by the mother, were resorted to soon after the trouble was first discovered.

My treatment of *this* case was entirely mechanical, accompanied with such instructions in reference to the general health of the patient, as should usually be observed in a normal or healthy state of the system.

An apparatus was constructed to meet all the indications in the case as well as possible, by giving that support to the spinal column which would, in the most efficient manner, relieve the affected part from all undue pressure from the weight of the superior portion of the body, as well as to prevent the evil consequences of the various motions of the body at that point.

The apparatus was adjusted and readjusted as often as the circumstances in the case required, with a *direct* bearing upon the transverse processes of the projecting vertebræ.

By this arrangement, the bowels are elevated and retained in their proper position by gentle support, thus relieving the superior portion of the body from a dragging weight that serves not only to enhance the original trouble, but greatly to embarrass respiration.

Convalescence commenced at once, and continued without interruption.

The curvature is completely reduced, the patient has grown well, and is now straight, robust, and healthy.

Case 7.

Mrs. R., of Woburn, Massachusetts, aged thirty-six years, tall in stature, of fair complexion, and of somewhat scrofulous diathesis, came under treatment for Pott's Disease of the Spine, July, 1858.

The following is a brief history of the case from its commencement to the time I first saw it, as related by the patient.

Eight years ago she was attacked with pulmonary disease, unprovoked by a cold, characterized at first with a dry, hacking cough, which, at a subsequent period, became urgent, attended with copious expectoration, occasionally tinged with blood, emaciation, and extreme prostration, with hectic and night sweats.

This sickness continued a little more than six months, and for many weeks during that period, the attending physician and friends of the patient entertained little or no hope of her ultimate recovery.

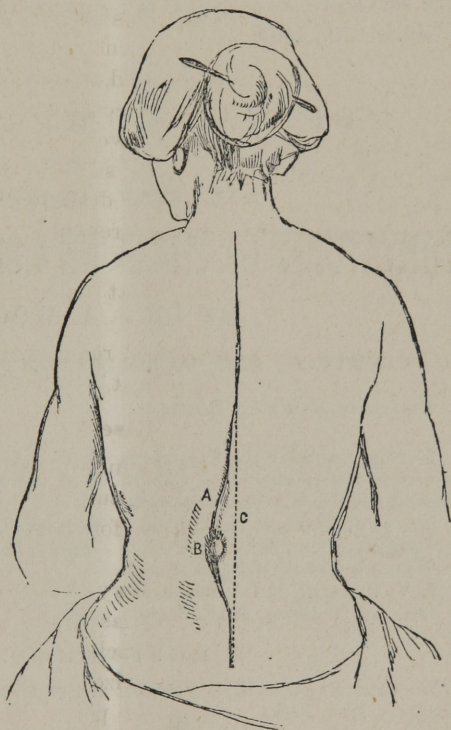
While in this situation, she first began to experience pain in the vicinity of the second and third lumbar vertebræ, with some degree of tenderness on pressure, which did not subside on her recovery from this severe sickness, but both continued with greater or less severity at times, soon accompanied with curvature of the spine, which was quite apparent, even when the patient was standing or walking about.

In April, 1857, the case assumed a more formidable character.

At that time, from some violent exertion on the part of the patient, in consequence of sudden fright, the pain was greatly increased and the curvature more rapidly developed than at any former period of the disease.

The difficulty progressed, and on examining the case in July, 1858, when my attention was first directed to it, I found the second and third lumbar vertebræ projecting posteriorly, as seen at B, in the accompanying cut, about half an inch, forcing those directly above and below, more or less, from their normal position.

In connection with this posterior projection, there was, also, a lateral reflection of the spinal column, to the left, embracing the lumbar, and several of the lower dorsal vertebræ, as seen at A, in the accompanying figure, which represents, *correctly*, the extent and degree of this lateral inclination of the spinal column.



The pain was severe in the back, hip, and left lower extremity, with a partial loss of power in that limb. The muscles were contracted, drawing the body to one side, rendering exercise difficult and painful.

The treatment was simply mechanical, and consisted in the application of a Spinal Apparatus, such as has been described in a former number of the *New York Journal of Medicine*, appropriately adjusted and readjusted at such times and manner as the nature of the case demanded.

The usual instructions in regard to regimen in those cases were given, with the recommendation only of *moderate* exercise.

The patient has fully recovered, with a *complete* reduction of the curvature, as seen at C in the preceding cut.

June 16th, 1859.

SPINAL COMPLAINTS.

A NEW METHOD OF TREATING

CURVATURES OF THE SPINE & SPINAL WEAKNESS.

BY DR. J. A. WOOD.

OFFICE, 215 WASHINGTON STREET,

RESIDENCE, MARLBORO' HOTEL,

BOSTON, MASS.

Having examined the SERPENTINE SPRING APPARATUS used by Dr. J. A. WOOD, in the treatment of Curvatures of the Spine, we recommend it as efficient and comfortable to the patient.

HENRY J. BIGELOW, M.D., Prof. of Surgery, Harvard University.

GEO. HAYWARD, M.D., Ex-Prof. of Surgery, Harvard University.

WINSLOW LEWIS, M.D., Boston, Mass.

J. V. C. SMITH, M.D., Boston, Mass.

JOHN W. WARREN, M.D., Boston, Mass.

REFERENCE.

WILLARD PARKER, M.D., Professor of Surgery, College of Physicians and Surgeons, New York.

JOHN T. METCALFE, M.D., Professor of Institutes and Practice of Medicine, University of New York.

STEPHEN SMITH, M.D., Surgeon to Bellevue Hospital, New York.

GEORGE MARVIN, M.D., Brooklyn, N. Y.

H. I. BOWDITCH, M.D., Boston, Mass., Prof. of Clinical Med.

SAM'L W. THAYER, JR., M.D., Prof. of Anatomy in the University of Vt.

JAS. H. CROMBIE, M.D., Derry, N. H.

