

WP
S769i
1894

THE SPRINGSTEEN MEDICINE CO.'S
DESCRIPTIVE STUDY
OF
DISEASES OF WOMEN.

NATIONAL LIBRARY OF MEDICINE




NLM 00580103 9

SURGEON GENERAL'S OFFICE
LIBRARY

Section


Form 113c No.
W. D., S. G. O.

GOVERNMENT PRINTING OFFICE



Springsteen's Mountain Rose.

TRADE MARK



The *W. Springsteen*
Springsteen Medicine Co.
SOLE MANUFACTURERS,
(CLEVELAND, O. U. S. A.)

ILLUSTRATED
GYNECOLOGICAL STUDY

OF THE

Diseases of Women,

WITH FULL DIAGNOSIS OF THE MOST PREVALENT AILMENTS
AFFECTING THE ORGANS OF THE FEMALE PELVIS.

BY

WALLACE S. SPRINGSTEEN, M. D.,

EX-U. S. SURGEON NEVADA INDIAN AGENCY; MEMBER OF THE NATIONAL
MEDICAL ASSOCIATION (ECLECTIC); FORMERLY SURGEON-IN-CHIEF OF
NEVADA CENTRAL R. R., AND PHYSICIAN IN CHARGE OF BRANCH
HOSPITAL, LANDER COUNTY, NEVADA; EX-U. S. PENSION EXAM-
INING SURGEON FOR NORTHERN DISTRICT OF MICHIGAN;
MEMBER OF OHIO AND CALIFORNIA STATE MEDICAL
ASSOCIATIONS; HONORARY MEMBER OF MICHIGAN
STATE MEDICAL & SURGICAL SOCIETY;
EX-PRESIDENT OF THE COUNTY MEDICAL AND SURGICAL SOCIETY OF
ALAMEDA Co., CALIFORNIA;
DISCOVERER OF THE


Mountain Rose Treatment for Female Diseases,

AND

MEDICAL DIRECTOR OF

THE SPRINGSTEEN MEDICINE Co.,

CLEVELAND, OHIO.





11614 22

WP
5769i
1894



Entered, according to Act of Congress, in the year 1894,
By THE SPRINGSTEEN MEDICINE CO.,
in the Office of the Librarian of Congress, at Washington, D. C., U. S. A.



G22J056

PREFACE.

IN preparing this work great pains have been taken to make it plain and comprehensive, that those who desire to become enlightened on this most important subject may, by the aid of the various Illustrations, get a clear, concise and comprehensive idea of the origin, progress and termination of the dreaded diseases usually attacking the organs of the Female Pelvis. We trust also, by this work to *prevent* much disease and suffering, and have great assurances our efforts are appreciated by the student of Gynecology as well.

THE AUTHOR.

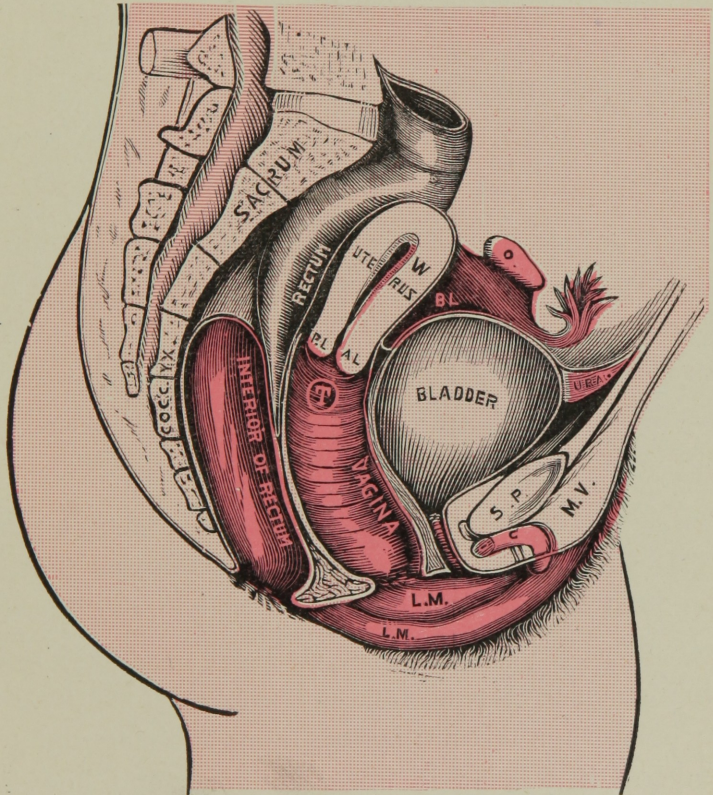
PLATE I.

SECTION OF FEMALE PELVIS,

Showing Position of Viscera, with different organs in natural position.

B. L. is Broad Ligament; **O.** is Ovary; **URA.** is Urachus; **U.** is Urethra; **L. M.** is Labia Majora and Labia Minora; **M. V.** is Mons Veneris; **T.** is Mountain Rose Tablet, in through vagina next to mouth of womb, where it should be from use of Placer.

PLATE I.



SECTION OF FEMALE PELVIS.

(For explanation see opposite page.)

PLATE II.

RETROVERSION OF WOMB.

(TIPPING BACKWARD.)

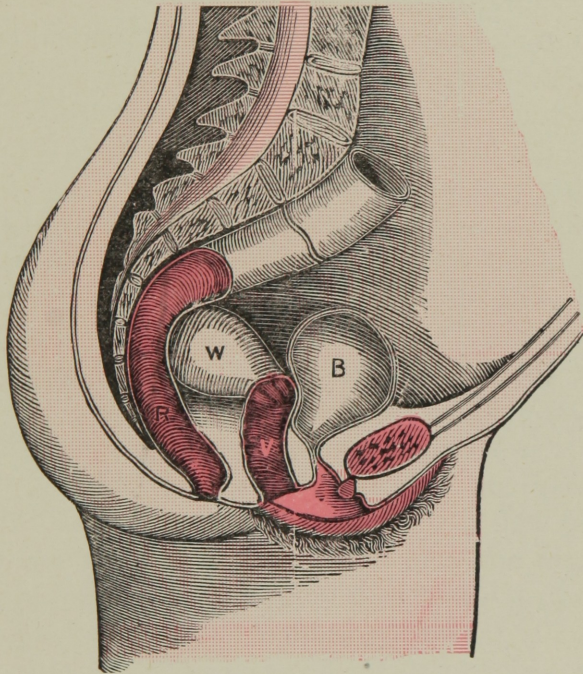
This form of displacement is not so common as Prolapsus, but is frequent, however, and consists in a displacement as shown in Plate (II), the upper body of womb being thrown against the rectum with mouth turned forward, and pressing the bladder.

CAUSES are from a relaxed and weakened condition of the supports and posterior walls of Vagina; too frequent child-bearing; miscarriages; chronic inflammation; enlargements; congestion; hypertrophy; fibroid growths; sudden shock, as falling, coughing, running up stairs, etc., etc., all tends to push womb back in hollow cavity of sacrum.

SYMPTOMS:—Great functional and sympathetic derangement; distressing irritations; nervous depressions and dyspepsia; local neuralgia; pain in chest and in the breasts at time of menstrual period; pain in back; feeling as though womb was enlarged; aching and dragging, bearing-down pains; pressure in rectum; constipation; straining and pressing pain as if drawing in lower abdomen and bowels on moving of same; sterility, etc.

TREATMENT:—Mountain Rose should be fully relied upon; its tonic and astringent effects are marvelous, and the Tonic Tablets as a constitutional building agent are without a successful rival.

PLATE II.



RETROVERSION OF WOMB.

This form of Displacement is well represented in above cut, womb laying against rectum.

W. Womb; **R.** Rectum; **B.** Bladder; **V.** Vagina.

PLATE III.

ANTEVERSION OF WOMB.

(TIPPING FORWARD.)

This malposition of the Uterus consists of the upper body of womb being carried forward toward the symphysis pubis and pressing the bladder, while the mouth or cervix is thrown backward against the rectum.

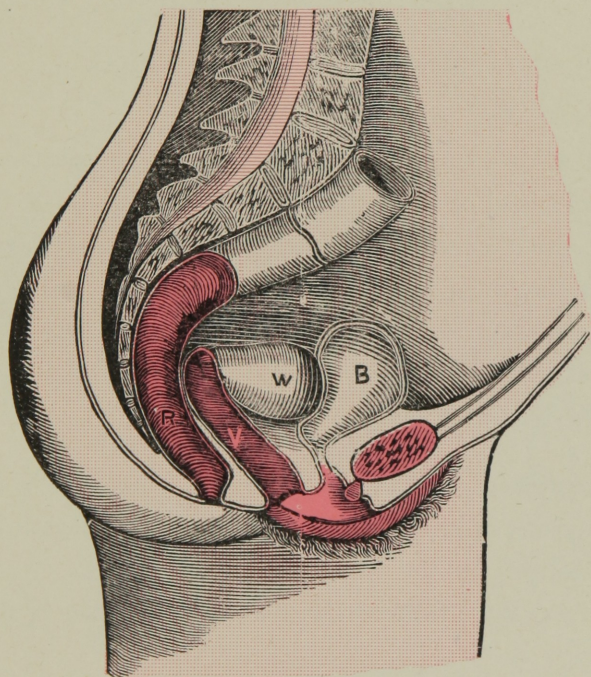
It is not so frequent as many other abnormal positions in this displacement, we have two varieties or degrees, viz: *anteversion* and *anteflection*. In the latter degree the organ is bent at the junction of the cervix or neck of uterus, the body being bent wholly forward.

CAUSES:—Long continued inflammation, which weakens the walls of the vagina, causing them to become relaxed, and the body of uterus becoming enlarged and somewhat unnaturally heavy. Then by sudden fright, over-joy, outward pressure, sudden fall, running up or down stairs, etc., etc., may be assigned as sufficient cause.

SYMPTOMS.—Similar to those in Retroversion, though not so fully marked. Patient feels a sense of fullness and weight in pelvis, with a tendency to bearing down behind pubis, with weight and pain in peritoneum and rectum. Frequent desire to pass water, with great difficulty in doing so. If displacement is caused by sudden fall, or coughing, or severe straining, which bring the accident very suddenly, the symptoms will be very marked. The pressure of the womb against urethra producing in many cases almost complete retention of urine.

TREATMENT.—It will be seen that, as the trouble appears to exist only by some degree of relaxation of ligaments of womb and walls of vagina—what seems the most rational to repair, the only thing to do is to remove the cause. To do this, MOUNTAIN ROSE is to be wholly relied upon, it will supply strength, tone up the parts, contract the supports and walls, and nature will perform the complete cure.

PLATE III.



ANTEVERSION OF WOMB.

B. Bladder; **W.** Womb; **R.** Rectum; **V.** Vagina.

PLATE IV.

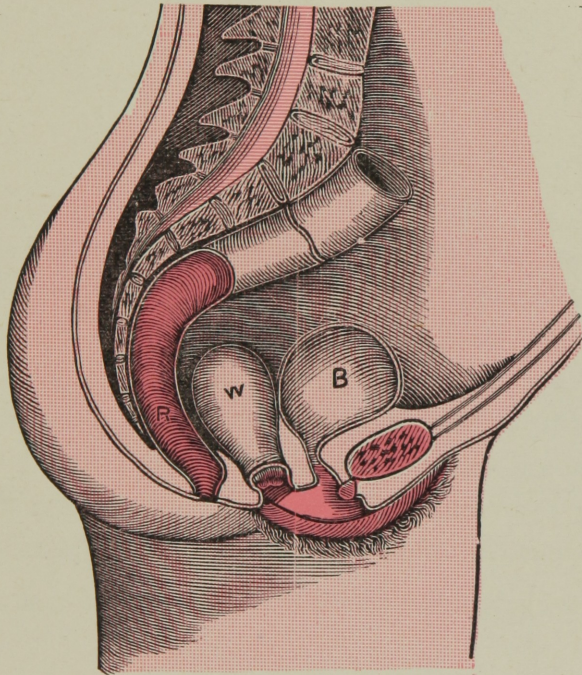
PROLAPSUS OF WOMB.

SYMPOMS:—Dragging down pain in lower portion of back; tenderness over abdomen, seeming to be a fullness in vagina; much irritation of bladder, and trouble and pain on bowels being evacuated; increasing pain on walking; painful, sometimes profuse menstruation; sometimes a total protrusion of the womb—a relaxation of some of the ligaments allows this to exist.

TREATMENT:—The use of the Tablets, which being absorbed by the ligaments, removes the relaxed condition, and adds tonicity.

A perfect cure follows the use of **MOUNTAIN ROSE.**

PLATE IV.



PROLAPSUS OF WOMB.

The above cut is a good representation of a severe degree of Prolapsus (falling) of Womb.

W. Womb; **B.** Bladder; **R.** Rectum.

PLATE V.

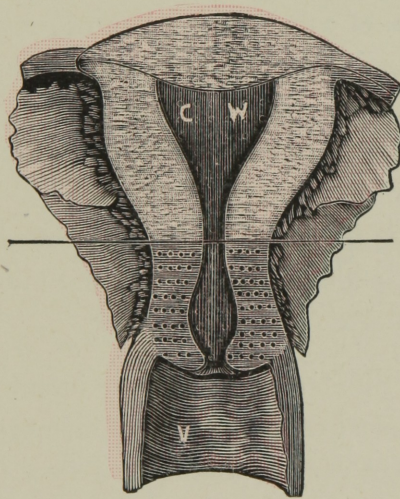
CERVICAL HYPERPLASIA.

This is no more nor less than a result of inflammation of the substance of the neck of the womb; very common.

SYMPTOMS:—Backache; headache; hot flashes; pelvic pains; dragging sensation about loins; bearing down pains; leucorrhœa; menstrual disorders; excessive flow; throbbing sensation about uterus; general despondency; irritable feeling of bladder and rectum; general lassitude; nausea and vomiting; nervous disturbance; sterility or barrenness, etc.

The dots below horizontal line show the seat of disease.

PLATE V.



CERVICAL HYPERPLASIA.

C. W. is Cavity of Womb; **V.** Vagina.

PLATE VI.

CHRONIC CORPOREAL ENDOMETRITIS.

(INFLAMMATION AND CONGESTION.)

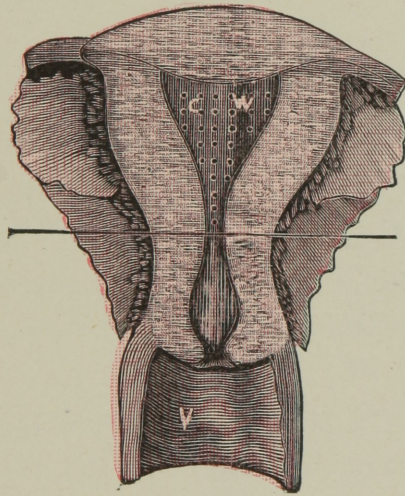
Like the cervix of womb, as spoken of previously, we have the exact condition of disease, only in a different part of the uterus. There may be seen the little dots above the horizontal line, which represent the seat of inflammation and congestion in cavity of body of womb.

This condition is known and spoken of as *catarrh*, *leucorrhœa* or whites, endometritis or internal metritis, or inflammation of the womb.

SYMPTOMS:— Similar to preceding inflammation of neck of womb. This seat of inflammation is more rare than that preceding, but yet very common, and is a fruitful cause to great functional and constitutional trouble, and should never be neglected for a moment.

MOUNTAIN ROSE is the most natural remedy known to-day as a certain and speedy cure.

PLATE VI.



CHRONIC CORPOREAL ENDOMETRITIS.

C. W. is Cavity of body of Womb; the little dots above line show seat of inflammation, **V.** Vagina.

PLATE VII.

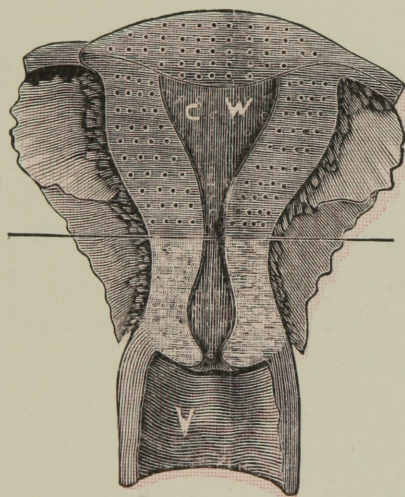
CORPOREAL HYPERPLASIA.

(INFLAMMATION.)

SYMP TOMS as in preceding diagnosis, as: Pain in back and loins; pressure on bladder and rectum; disordered menstruation; difficulty of locomotion; nervous disorders; pain in womb and all pelvic regions; pain in mamma gland before menstruation, etc., etc.

TREATMENT:—In all cases **M**ountain **R**ose and **T**onic **T**ablets are warrantable. They *will and do always cure.*

PLATE VII.



CORPOREAL HYPERPLASIA.

Little dots above line represent seat of disease, to be in substance of upper womb.

C. W. Cavity of Womb; **V.** Vagina.

PLATE VIII.

CHRONIC CERVICAL ENDOMETRITIS.

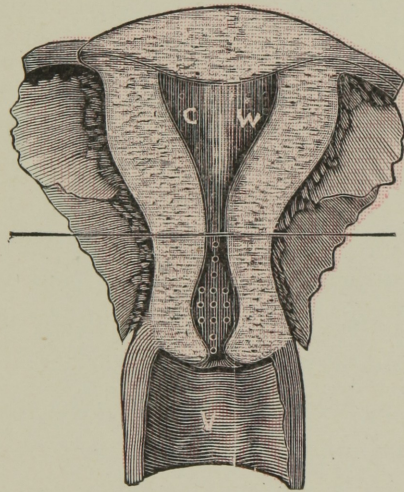
(INFLAMMATION.)

When inflammation attacks the uterus, it has a tendency to affect the whole organ, both internal cervix or neck, and body or fundis of womb.

This is a chronic inflammation of the neck of the womb, affecting especially the lining mucous membrane of the neck from the external mouth to internal. The *little dots* in the center of the neck *below* the straight line will point out the true seat of the trouble. It often is the cause of throwing off immense quantities of thick, tenacious mucus, which is loaded with little fibrous appearing particles, and sometimes streaked with blood.

The nature and seat of this inflammation is among the most common to women, and **MOUNTAIN ROSE** will be found a positive remedy, and but a short time is required for a cure. This treatment never fails.

PLATE VIII.



CHRONIC CERVICAL ENDOMETRITIS,

Little dots below line show the seat of inflammation to be in neck of womb.

C. W. Cavity of Womb; **V.** Vagina.

PLATE IX.

FOLLICULAR VULVITIS.

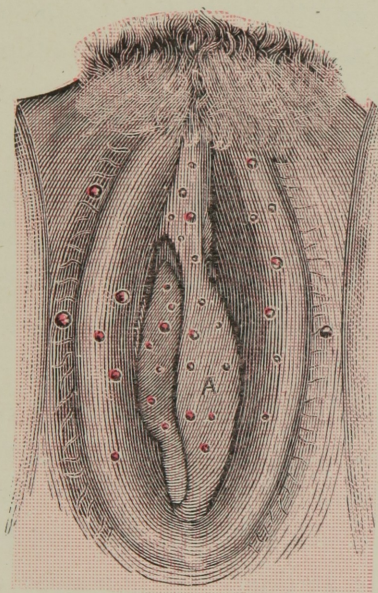
FOLLICULAR VULVITIS is a disease commonly found to exist chiefly with women above twenty years of age, and is of that nature of disease which attacks only the external genitals; we may say, however, to explain more fully, the mucous membrane lining the vulva, more especially in that covering the *labia majora*, *labia minora* and vestibule numerous follicles exist, and are no more nor less than little solitary glands, in common purulent vulvitis. These, as component parts of the diseased membrane, are implicated in the morbid action.

SYMPTOMS:—Burning, itching and heat in the vulva or vagina, with secretion soon appearing, and which increases as the disease advances. As a usual thing the secretion is very offensive and irritating in character, excoriating and scalding. The urethra becomes inflamed at its vulvar extremity or external metis, or water passage.

On the mucous membrane of labia and vagina will be found numerous intensely red spots or patches, being slightly elevated, however most commonly found on edges of vaginal rugæ, the nymphæ, etc. It extends and implicates all surrounding mucous membrane, as the labia majora and minora and the whole external lips of the genitals.

These morbid conditions succumb at once to the curative qualities of MOUNTAIN ROSE, and we may say, it never has been known to fail. By a glance at cut (IX) may be seen a correct representation of this common and distressing complaint.

PLATE IX.



The above Plate represents a severe case of FOLLICULAR VULVITIS. **A.** shows an abscess, forming a common trouble and much to be dreaded.

PLATE X.

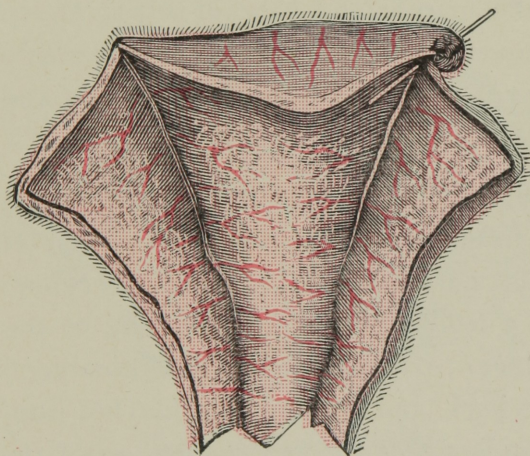
DYSMENORRHŒAL MEMBRANE.

Membranous Dysmenorrhœa is a variety which consists in the formation of organized material in the uterine cavity, and which affords relief when expelled, which many times is done in tack and seemingly unbroken. It is no doubt an abnormal formation of the muscular membrane lining the cavity of the womb, and is most certainly a source of a great amount of trouble.

SYMPTOMS:—At the outset of the appearance of menstrual period coming there are congestive pains, and they increase until they are violent and expulsive-like, resembling abortive pains. A patient is so distressed that she cannot find words to express her pain and feelings of suffering. She has an anxious look, a glacy eye, extremities become cold and countenance anxious and pallid, and cramps fairly doubles her up; she has an inclination to draw her knees toward the chin, and actually at times lies in a state of stupor. It is certainly a frightful, troublesome affliction.

MOUNTAIN ROSE has never been known to fail in this disease, and at all times and under all conditions its application is warrantable. During the month between Periods, if Mountain Rose treatment is used, the cure will be forthcoming. The Tonic Tablets serve a grand purpose in the above disease.

PLATE X.



The above illustration is a true representation of a DYS-
MENORRHŒAL MEMBRANE as expelled by use of Mountain
Rose.

PLATE XI.

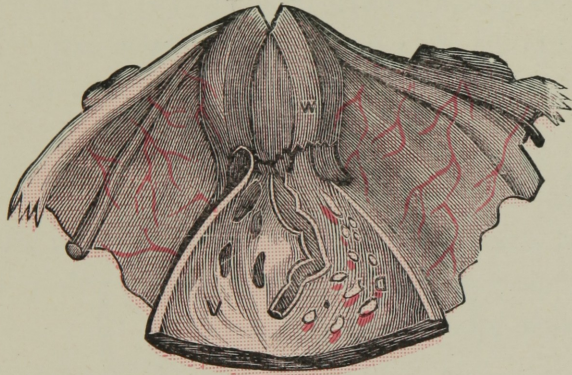
Represents a CORRODING ULCER attacking the Anterior Lip, having almost totally destroyed it and involving the Posterior Lip, and spreading upwards, involving Cervex, and making its inroads toward the body of that organ.

This ulcer is of an irregular, sinuous, jagged nature, the tissues at the margin and base of which are thickened or hardened in consequence of a sluggish inflammatory process, and discharges a brownish-green, glutinous and poisonous or watery secretion.

SYMPTOMS:—Pains in pelvis; a profuse watery discharge takes place from the vagina, usually offensive, varies from a light straw to a dark brown color, with weakness and pain in back and a feeling of weight extending to the loins and around abdomen; pains described as lancinating, like a knife running into back, and burning pain like hot iron. The constitution soon becomes affected, patient emaciated, appetite deranged, bowels irregular, skin dry and sallow and becomes flabby, quick pulse, frequent flushes of fever, gradual declining, and green evacuation of bowels with much pain. Unlike cancer this disease is local.

Mountain Rose is richly worthy of a trial in this awful affliction, and women should embrace the opportunity to use it as soon as possible. Past experience with this treatment warrants the greatest hope.

PLATE XI.



Section of Womb, showing
CORRODING ULCER.

W. (Womb), showing plainly the deep-seated Ulcer eating away the Anterior Lip of Uterus.

*PLATE XII.—Figures 1, 2, and 3.*ELEVATIONS, THE RESULT OF PROLONGED
INFLAMMATION.

In some cases of long continued uterine inflammation a condition appears, which in many ways is extremely annoying. It is the appearance of numerous little elevations of the size and somewhat of the appearance of little red currants.

[Fig. 1 shows the result of sub-acute inflammation of cervix; uterus drops low in pelvis and is soft and flabby and somewhat enlarged. The elevations are of a deep red color and no pedicle attachment.

Fig. 2 shows inflammation of *cervex uteri*. Monthly flow excessive, considerable tumefaction of uterus, cervix of a livid appearance and bleeds at the slightest pressure.

Fig. 3 illustrates a bad condition and interrupts very materially the monthly flow; it being abundant and very frequent. In this condition we find the uterus extremely low down on floor of pelvis, and very painful.

PLATE XII.

Fig. 1.

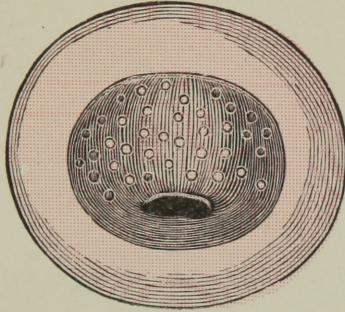


Fig. 2.

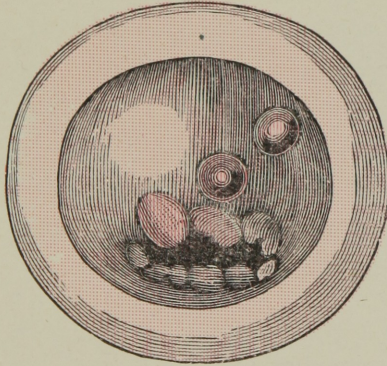


Fig. 3.

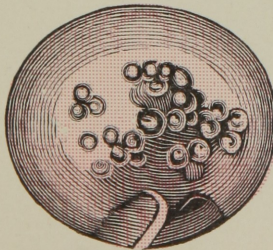
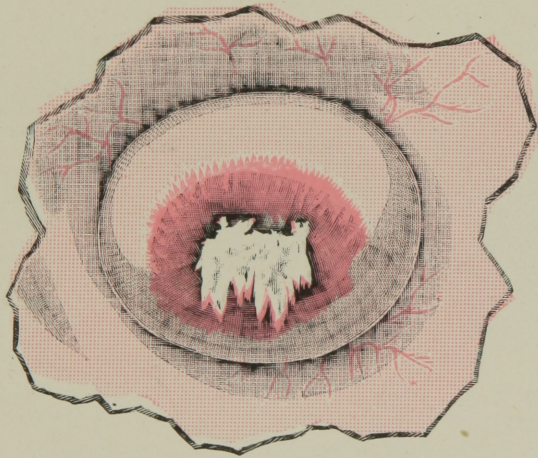


PLATE XIII.

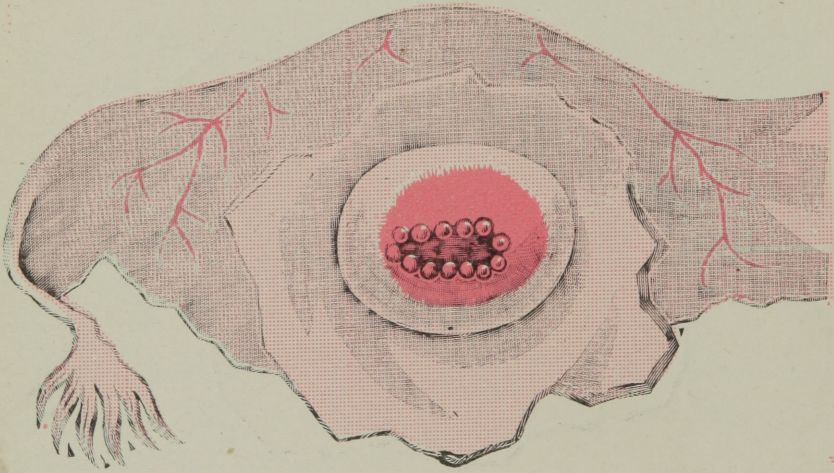
Shows the mouth of womb very much enlarged and transverse, dividing the cervix on neck of womb in two lips. The granular elevations plainly seen to be extensive, keeping the mouth of womb open, making it very sensitive and tender. By cut (XIII) may be seen several of the elevations to have run in together and extended to such a degree as to develop in a long ulcer.

The application of *Mountain Rose*, when used persistently and according to instructions, is a *boon* to be appreciated by any sufferer.

PLATE XIII.



Above cut represents a severe case where the elevated tumors had extended and spread in one fearful ulcer.

PLATE XIV.

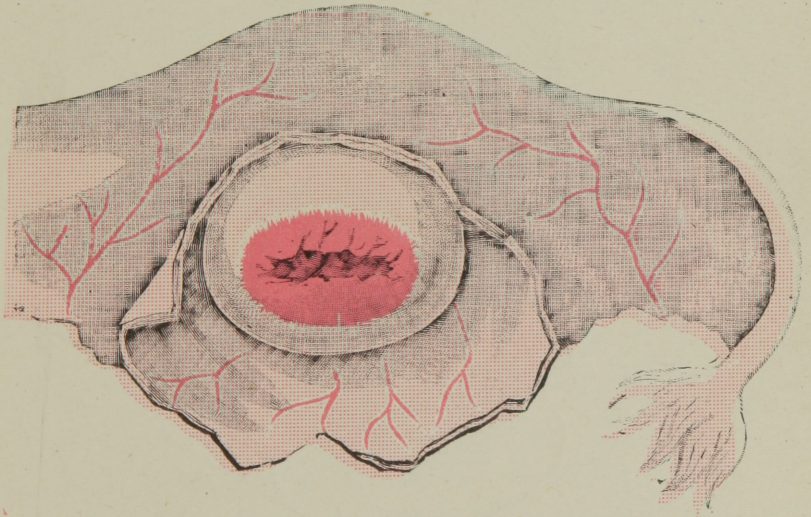
True representation of a condition sometimes called

RED CHERRY DISEASE ;

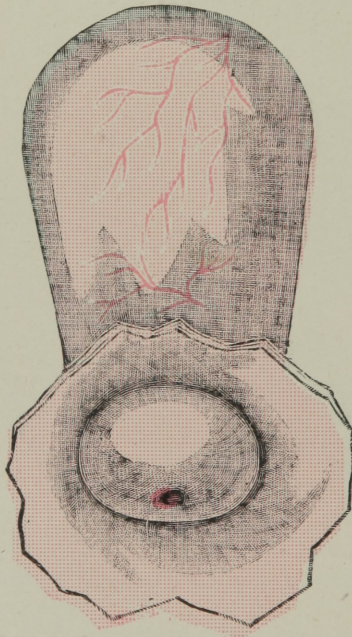
little elevated tumors resembling little red cherries.

Causes much trouble at times.

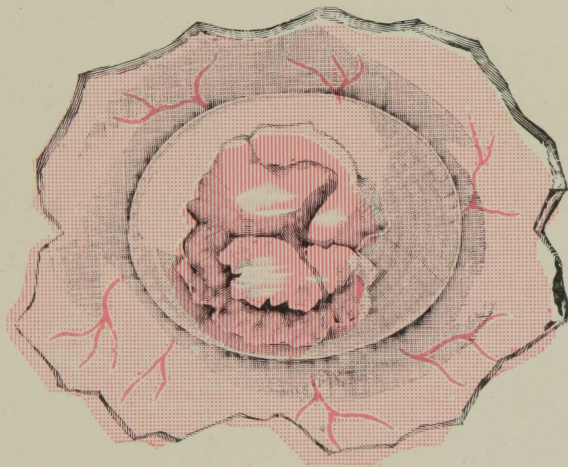
PLATE XV.



Above cut represents the Womb in a high state of inflammation, the little red cherry disease abating tumors, as seen in Plate XIV, all disappeared, and mouth gradually closing to normal condition from use of Mountain Rose.

PLATE XVI.**HEALTHY UTERUS,**

As it appears after recovery from elevated excrescences or little tumors, as represented in previous Plates, XII, XIV, XV.

PLATE XVII.

This cut gives a good idea of the result of long undisturbed inflammation. It has reached such an aggravated point as to produce extensive ulceration, involving both Anterior and Posterior Lips. The mouth of womb is greatly swollen and enlarged.

PLATE XVIII.

FIBROUS TUMOR in the cavity of the womb. (1) is Rectum; (2) Cavity of the Womb; (3) Cavity of the Bladder; (4) Cavity of Vagina; (5) Fibrous Tumor attached to inside walls of womb.

PLATE XIX.

A SECTION OF THE CAVITY OF THE ABDOMEN AND PELVIS, illustrating a large MONILECULAR TUMOR (5) attached to the Womb (2). The Bladder (3) much reduced from size of Tumor pressing against it. This species of Tumor must be removed by surgical means.

The difference in the two cases will readily be seen—the former is inside of womb, while the latter, as shown in cut, is situated outside of womb, but attached to it.

PLATE XVIII.

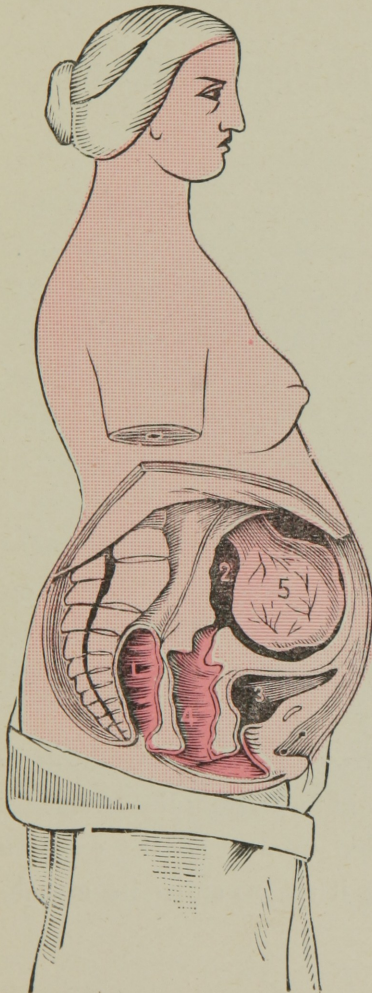
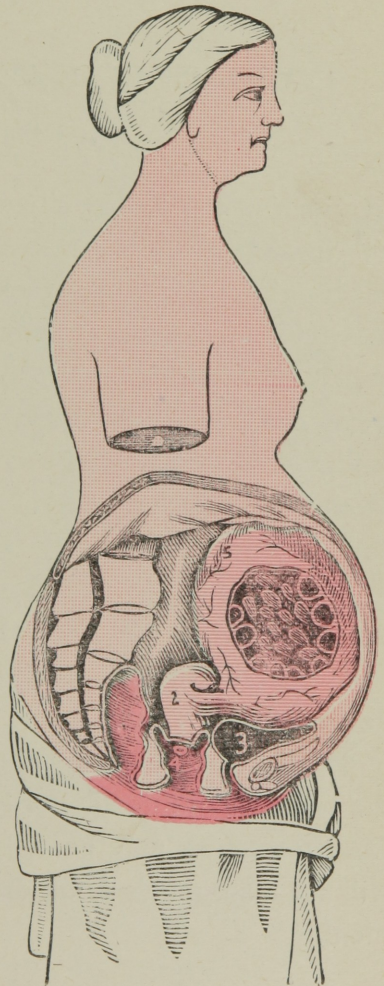


PLATE XIX.

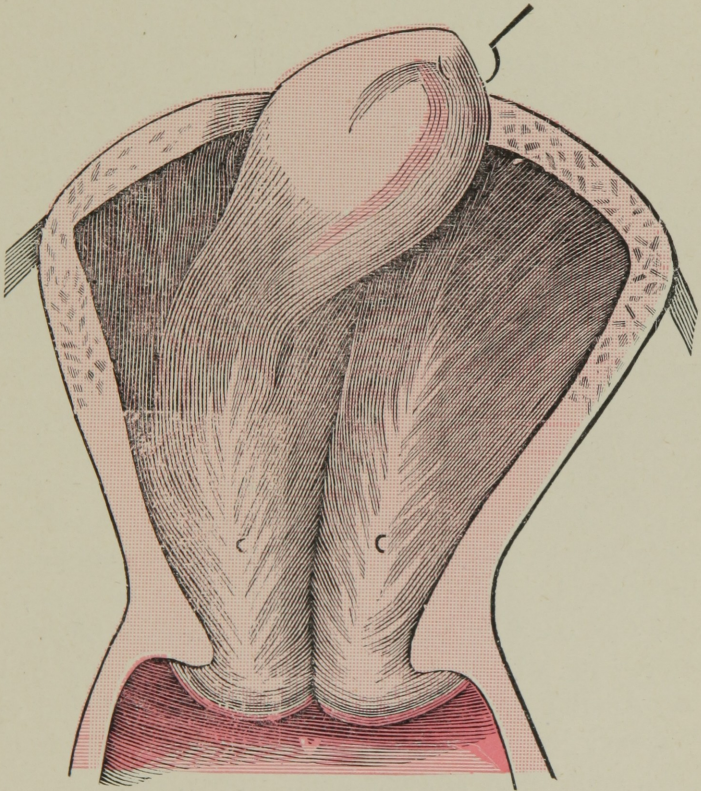


*PLATE XX.*INTRO-UTERINE PEDICULATED FIBROID
TUMOR.

A Species of Polypus, situated on inside of cavity of womb, has its attachments to the parieties of that organ. It adheres by a thin layer of whitish or reddish somewhat vascular cellular tissue. It then will be seen it may be detached quite easily, and its removal by the use of **Mountain Rose** treatment is no doubt made possible by contraction of upper fundus or large body of womb after continued treatment of MOUNTAIN ROSE, the action of which has had a direct tendency to shrink and render the sensitive vascular attachment to become weakened and atrophied, as it were, dispelling the blood from the substance of tumor, while toning and stimulating the womb, causing it to contract and hence expel its unwelcome visitor.

In all cases where the above condition exists, resulting in the presence of this kind of Polypoid formation, the *Mountain Rose* treatment may be fully relied upon. By the cut you will see a surgeon's hook drawing it up, to show its attachment.

PLATE XX.



INTRO-UTERINE PEDICULATED FIBROID TUMOR.

C. C. Cavity of Womb. **V.** Vagina.

CAULIFLOWER EXCRESCENCE OF MOUTH OF WOMB.

Cauliflower Excrecence is doubtless a morbid growth and is situated at the mouth of womb, and consists of minute ramifications of arteries connected by flocculent tissue and covered with a secreting membrane. Its surface has a somewhat granulated feel, it bleeds with the slightest handling and pours forth a watery discharge. It varies in size, is painless or nearly so. When removed by surgical means with knife it shows its malignancy by returning. By some authorities it is claimed to be a species of cancer. For ourselves, we believe it to be non-cancerous and simply a sort of morbid warty or papillary growth. The illustrations (Fig. 1 and 2 on opposite page) are good representations of this growth.

SYMPTOMS:—Patient first notices a clear, watery discharge, inodorous, but quite constant. It keeps up discharging for weeks and months, increasing to such an extent as to compel the patient to wear napkins for protection to surface of limbs, over which the exudation may pass. After a long time little streaks of blood and something resembling fibre may be noticed. It is in its advanced stage so tender and sensitive that even by a movement of bowels it bleeds quite profusely. Its attachment is from the *os externum* or lip of womb. As the disease advances the constitutional symptoms appear: Derangements of stomach, loss of flesh, creeping chills, pallid skin, anxious look, dropsy, etc.

In cancer the discharge is fetid, in this disease it is not. Hence the distinction.

MOUNTAIN ROSE cures this disease, its *astringent*, *escharotic* and *discutient* properties act with great certainty on the granulations and morbid flocculent tissue, sapping, as it were, its very life. Many specimens, preserved in alcohol, have been sent by grateful patients to the home office.

PLATE XXI.

Fig. 1.

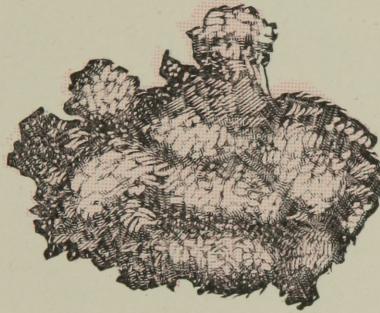
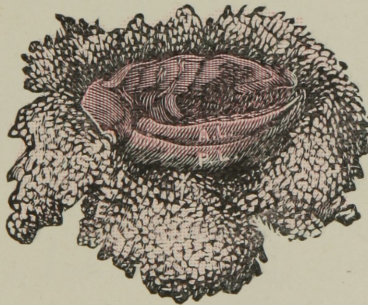


Fig. 2.



CAULIFLOWER EXCRESCENCES OF MOUTH OF WOMB.

A. L. Anterior Lip. P. L. Posterior Lip.

PLATE XXII.

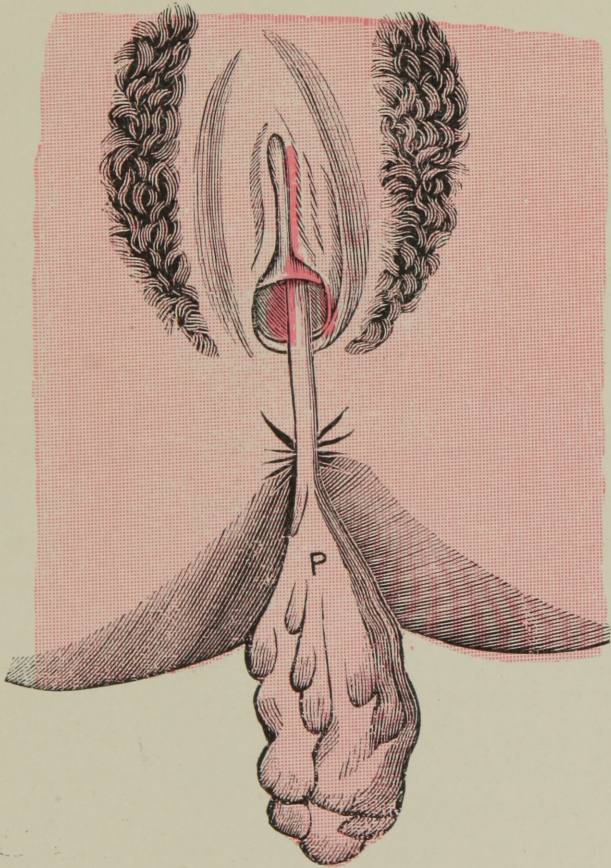
PEDICULATED POLYPUS.

On opposite page (Plate xxii) will be seen a splendid representation of a large Pediculated Polypus of the Uterus, as it has crowded through the cervix and suspends from the mouth, coming through vaginal canal.

SYMPTOMS:—This species of tumor causes great loss of blood, necessarily by keeping the womb open and causing so much irritation. The flow keeps up for a long time, producing a pallid appearance, a blanched countenance, appetite deranged, bowels relaxed, limbs swell, nausea and vomiting, a terrible dragging down pain, dropsical conditions, leucorrhœa, and wasting of physical strength, sometimes mental derangements, and many other prominent symptoms, until at last a general breaking down of the whole system.

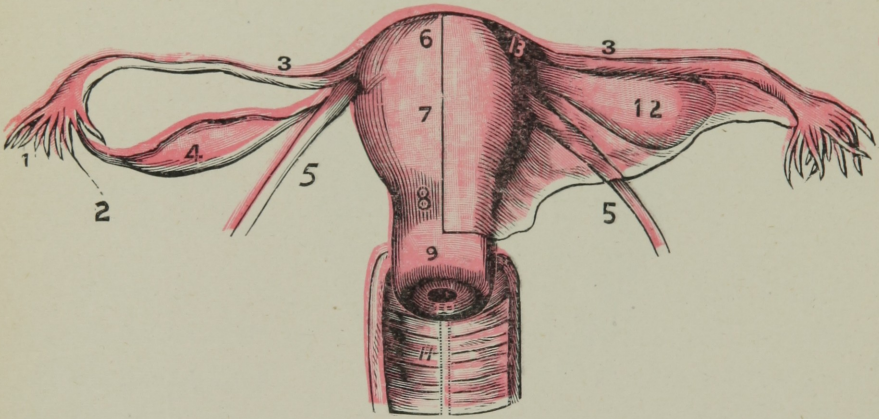
TREATMENT:—Surgical means are usually resorted to, but not always successful. **Mountain Rose** has proven an invaluable remedy in the above disease. It being absorbed seems to stimulate the blood. It is then distributed more equal, soon the Pedicle of Tumor begins to present an atrophied condition and soon the whole tumor succumbs and drops away, after which small pieces come, until a cure is effected.

PLATE XXII.



PEDICULATED POLYPUS OF THE UTERUS.

P. Polypus.

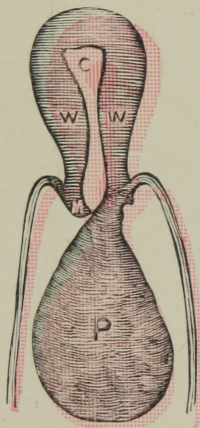
PLATE XXIII.**THE WOMB AND ITS APPENDAGES.**

1. Fimbriated Extremity of Fallopian Tube.
2. A Bristle passing through.
3. Fallopian Tubes.
4. Ovary.
5. Round Ligaments.
6. Fundus, or Upper Body of the Womb.
7. Body of the Womb.
8. Cervex, or Neck of Womb.
9. Part of Neck, enclosed by Vagina.
10. External Os, or Mouth of Womb.
11. A section of Vagina, lined with a pale, pink-colored mucous membrane, showing Follicles, or gathered into numerous folds like a ruffle, termed Follicles of Vagina.
12. Broad Ligament.
13. Entrance of Fallopian Tube into Womb.

PLATE XXIV.

POLYPUS.

Fig. 1.



The above cut represents plainly a Polypus with its attachment on the anterior lip of womb.

W. W. Womb; **M.** Mouth of Womb; **C.** Cavity; **P.** Polypus as it falls and suspends in vaginal canal.

Fig. 2.

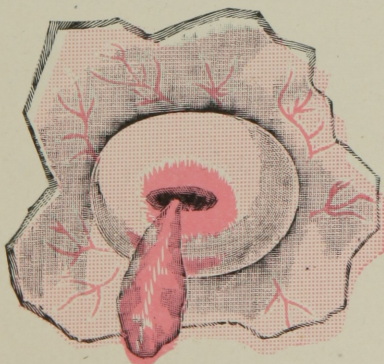


Fig. 2 shows a Polypus with its attachment from inside the Cervix or neck of womb.

PLATE XXV.

BLOOD SUPPLY OF UTERUS.

By observing the Plate (XXV) one may see plainly the circulation of blood, as it is supplied to the Uterus.

Nature certainly has been generous in its mysterious supply of blood vessels. Its arteries are derived from two sources. The principal, called Uterine Arteries, arise from the hypogastric; the other set, called the Spermatic, arise from the aorta, descending with tortuous inflexions. They supply the ovaries, then passing along the broad ligaments they distribute their terminal branches to the Uterus. The veins follow the course of the arteries. The spermatic veins ascending with the spermatic arteries terminate the same as in the male, the right in the ascending "*vena cava*", the left in the renal veins.

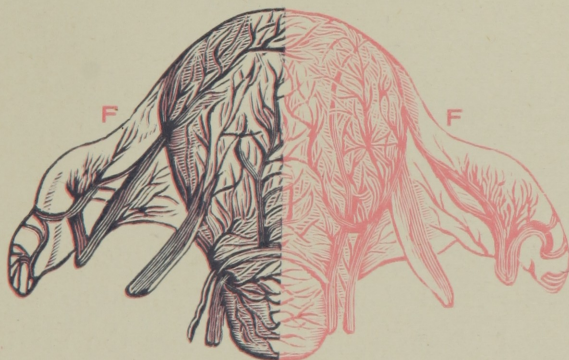
The uterine veins empty themselves into the internal Iliacs. It must be apparent then to the observer, and patient as well, that when from cold or other causes, viz., intemperance or excesses in any manner, the dangers of abnormal conditions arise, such as congestion, causing inflammation, etc., etc. Do not, therefore, tempt nature too much during the menstrual period, for if you do, you may plainly see the danger signal of being liable to pay the penalty.

FALLOPIAN TUBES.

In Plate XXV are also represented the Fallopian Tubes, which are two ducts, situated on each side of the uterus and extending from it to the ovaries. They arise from the upper angles of the uterus and pass transversely outward in the folds of the broad ligament for some distance, then bend backward and inward, in order to approach the outer end of the ovarian ligament. The Fallopian Tubes are four or five

inches in length, straight in the inner half of their course, but describe several curves toward their outer extremity. They consist of three coats—an external or peritoneal coat, a middle or muscular coat, and an internal lining or mucous membrane.

PLATE XXV.



An excellent representation, showing distribution of Blood through Uterus, with view of Fallopian Tubes.

F. F. Fallopian Tubes.

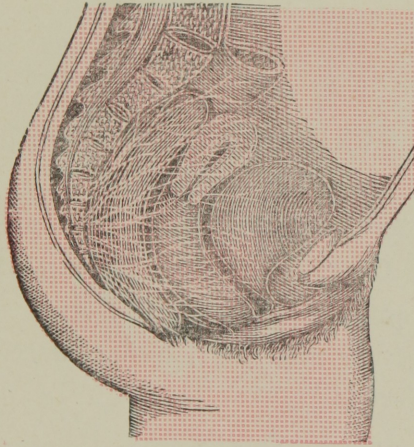
PLATE XXVI.

SHOWING THE NERVES OF THE WOMB.

DESCRPTION:—The uterine nerves, derived from the hypogastric plexuses, are divided into the Ascending and Descending branches. The Ascending branches run upward along the lateral borders of the uterus and terminate in its substance. The Descending branches furnish numerous branches which pass to the lower portion of the uterus; they then run along the sides of the vagina and terminate in it.

It will be noticed then, that as the hypogastric plexuses, from which the uterus derives its principal nerves, are formed not only from the filaments of the lymphatic nerves, but also from numerous small filaments of the spinal nerves, derived from the sacral plexuses, it follows that the uterus is connected both with the ganglionic and cerebro-spinal system, which accounts for the fact of the great sympathy and influence existing between the uterus and other parts of the body, a cause direct then, which accounts for headache, back-ache, stomach and heart troubles, when womb is affected.

PLATE XXVI.



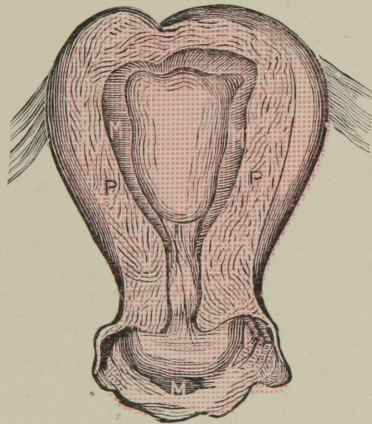
The above cut shows a good representation of Nerve Structure supplying the Womb.

PLATE XXVII.

STRUCTURE OF WOMB.

The constituent parts of the Womb are: An External Peritoneal Coat; an Internal Lining of Mucous Membrane, and the proper Tissue of the Uterus situated between these two, together with the Uterine Arteries, Veins, Lymphatics and Nerves.

PLATE XXVII.



This cut is a fine representation of **Tissues of Uterus.**

P. P. The Muscular Tissues;

M. M. The Internal Lining or Mucous Membrane;

M. Mouth showing Internal Lining as it enters cervix.

PLATE XXVIII.

HEMORRHOIDS OR PILES.

Figure 1 of the illustrations on opposite page represents a bad case of INTERNAL PILES in an advanced stage of ulceration.

CAUSES:—Usually from a fullness of the abdominal vessels from some cause, which may impede the return of blood from the rectum, as luxuriant living, sedentary habits of life, excessive use of tobacco with some constitutions is a cause, and with others constipation and straining, intemperance, etc.

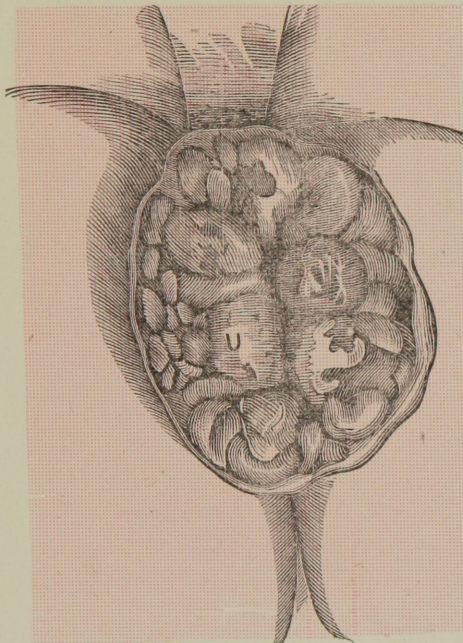
SYMPTOMS:—Great sense of weight and bearing down in rectum; bleeding from small tumors which appear about the verge of the anus, sometimes extending upwards near a finger's length; extreme pain on going to stool, followed by pain and pressing down weight, with annoying itching and bleeding at times, as to produce temporary weakness.

TREATMENT:—The Pastile being placed above the sphincter muscle beyond the seat of disease by means of our Placer, you can readily see the advantage of our celebrated Pile Cure above all other remedies. It is a universal Cure.

Fig. 2 illustrates External Pile Tumors grasped by sphincter muscle, and is a source of much annoyance.

PLATE XXVIII.

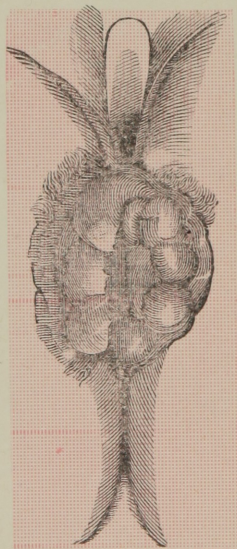
Fig. 1.




INTERNAL HEMORRHOIDS OR PILES
IN HIGH STAGE OF ULCERATION.

U is Ulcers.

Fig. 2.



EXTERNAL
PILE TUMORS.



NATIONAL LIBRARY OF MEDICINE



NLM 00580103 9