

WIC
L527r
1848

NATIONAL LIBRARY OF MEDICINE
Washington



Founded 1836

U. S. Department of Health, Education, and Welfare
Public Health Service

WIC
L527r
1848

Prof. J. Wyman
with the profound resp
of the author

RESEARCHES
INTO THE
COMPARATIVE STRUCTURE OF THE LIVER.

BY JOSEPH LEIDY, M. D.

WITH THREE PLATES.

[Extracted from the American Journal of the Medical Sciences for January, 1848.]

The following observations* on the comparative structure of the liver were made solely for my own satisfaction, but I have been induced to make them public from the impression that some of the facts presented may be new, or that, at least, the anatomy of the liver being presented in a somewhat new aspect, may be better understood than by former methods of description.

It will be remarked that as respects the anatomy of the liver of vertebrated animals, the facts observed by me corroborate the very carefully made researches and accurate descriptions of the anatomy of the human liver by Mr. Kiernan. (*Philosophical Transactions*, London, 1833.)

The constant presence of the liver throughout the whole of the vertebrate series of animal life and the higher orders of the invertebrate series, is sufficient proof of the importance of the organ, in connection with the digestive apparatus. It is an extensive secreting surface collected into a small bulk, and in the vertebrata it is arranged in such a complex manner, that before the researches of Mr. Kiernan, anatomists entirely failed in obtaining any satisfactory knowledge relative to its arrangement.

Before entering upon the details of the anatomy of the liver, it may be well to examine in a very general manner the nature of secretion and the organs which possess this function. It is rather difficult to give a good general definition of the term secretion, for there are many organic pro-

* These observations were made with an excellent microscope manufactured by Oberhaeuser, of Paris, and belonging to Dr. Wm. Schmoele, of this city, to whose liberality I am indebted for its use during a long period.

cesses which closely resemble it; such are respiration,* the renewal of epithelial surfaces, growth of hair, &c.; but to restrict it in some degree, it may be considered to be that process in an organic being by which certain organic cells, forming part of its composition, separate or form from the nutritive fluid, in contact with them upon one side through the intervention of a basement membrane, certain peculiar substances, which they give up upon the other side, to be appropriated to some other purpose in the organism, or to be cast off as useless, or which would be hurtful if retained.

Particular organs devoted to this function are denominated glands, and the simplest form of a glandular body is a single organic cell resting upon a basement membrane, and having the function just spoken of. Such are probably the cells which secrete the irritating fluid in the *Medusæ*, certain cellules in the *Polygastric animalculæ*, &c. An increase of such cells upon a plane surface is a little advance on the former state, and appears almost as simple;—of this character are the glandular patches found in the alimentary canal of insects, &c. The surface upon which the secreting cells are placed, being depressed below the general level, adds a little more to the complexity of the structure, and in this way the simple mucous follicles are formed,—the follicles of the proventriculus of birds, follicles of Lieberkuhn, &c. Should these depressions, which if deep are tubular, be divided towards the extremity, it increases the amount of secreting surface, and renders it more complex,—as in the compound follicles of the stomach, the sebaceous follicles of the skin, &c. If the divisions be subdivided, glands like the salivary, lachrymal, &c., are formed. If, instead of subdivision, the primitive divisions are much elongated, and convoluted to economize space, we have a gland of which the testicle of the higher vertebrata is an example. If the tube be divided and subdivided to a great extent, and each ultimate division forms a reticulated mass of tubular structure, the most complex form of a gland is produced, as in the fully developed liver of most vertebrated animals. The relation of the channels which convey the nutritive fluid to and from glandular organs, of course adds considerably to their complexity. From the foregoing we perceive the complexity of a gland depends upon the extent and mode of arrangement of its secreting surface and the relation of the blood-vessels to it.

The quantity of secreted matter depends upon the number and activity of the organic cells forming a secreting surface, and the quality appears not to depend upon the complexity of the gland, but upon the power of the individual cells; for the same secretion produced in glands of the most intricate arrangement in higher animals, is produced in very simple structures in the lower animals, as instanced in the liver of the higher vertebrata, and that of *Amphioxus lanceolatus*, the testicle of man and that of *Julus*, &c.

* In respiration there is not only a substance derived from the blood and given off externally, but also one derived from the exterior and given up to the blood, so that there is an interchange of substances which is not the case in secretion.

In the lowest forms of vertebrated animal life, where no distinct digestive apparatus exists, we find no trace of biliary structure. When we rise a little in the scale, and arrive at animals with an internal digestive cavity, as the *Polypi*, it is probable that certain of the cells forming part of the parietes of the cavity, may possess the power of secreting a fluid analogous to bile. Certain cellules, also, of the *Polygastrica* may be devoted to this purpose. The few short cœca of the digestive cavity of many *Medusæ* may also be biliary in their nature.

In the *Tænoidea* and *Trematoda*, animals which have a ramiform digestive apparatus, the cœcal appendages have been considered as a rudimentary form of the organ. They, however, do not differ in structure, which is granular, from the main portion of the cavity, and, like the latter, receive part of the alimentary matter. The cœcal appendages of the digestive cavity of the *Echinodermata* are reported as representing the biliary structure, a question, as in several of the former instances, which I have not yet examined. In many *Annelida* there are cœca appended to the sides of the alimentary canal, which are lined by organic cells of small size, and probably secrete a biliary fluid, as in *Hirulo*, *Arenicola*, &c. In the *Myriapoda*, emptying into the intestine, there are several long and delicate tubes of basement membrane lined by secreting cellules, in the *Julidæ* averaging $\cdot 0125$ millimetre in diameter, which are no doubt of this nature; but as they do not differ in structure from corresponding tubes of insects, a more particular description of the latter will answer for the former.

Insects.—In insects the liver consists of a number of distinct, white, yellow or brown, filiform, tortuous tubes placed in close apposition with the sides of the alimentary canal and opening into it, generally by separate orifices, frequently after joining each other to form short trunks, as in *Musca*, *Tabanus*, &c., in the vicinity of the pyloric extremity of the stomach. The smallest number, which is four, occurs in the flies (*Diptera*); in the *Lepidoptera* there are six; and in the *Orthoptera* and *Hymenoptera* they are numerous. When few in number, they are very long, sometimes three or four times the length of the intestinal canal; when numerous, they are proportionately short, and more delicate. In some insects they terminate in blind extremities, as in many *Diptera*; in others they unite in pairs, at their farthest extremity, so as to form loops, as in the bugs, (*Hemiptera*.)

When more intimately examined, these tubes (Plate I. Figs. 2, 3, 4, 5, 6) are found to consist of a delicate tube of clear, transparent, amorphous basement membrane, the inner surface of which is covered with secreting cells. From the thinness of the tube, the cells often project so as to give it a granulated appearance when viewed by the naked eye, as in the flesh fly, (*Musca carnaria*.) (Pl. I. Fig. 1;) and generally towards the free extremity, the sides of the tubes are so irregular that they appear as if merely folded upon the secreting cells to keep them together.

The secreting cells (Pl. I. Figs. 4, 5, 7) are round, oval, or nearly

cylindrical from elongation. Their average measurement is about $\cdot 09$ millimetre. The contents are white, yellowish, or brownish, and consist of a finely granular matter, numerous fine oil-globules, a granular nucleus, and a transparent nucleolus.

The cells in the extremity of the tubes are not more than half the size of those, a little farther on, or nearer the termination, and contain less granular matter, and no oil-globules, so that they are more distinct, and the nucleus more apparent. Upon advancing a very little, the cells are found to be of an increased size and full of granular matter, so as considerably to obscure the nucleus from view. A little farther, we find the addition of fine oil globules readily distinguishable by their thick black outline, when viewed in a certain focus. Sometimes the cells become so filled with oil as to be distended with it, rendering the granular matter and nucleus so transparent, as totally to destroy all appearance of the former, and the latter only is to be perceived in faint outline. Such a state I have frequently observed in *Dermestes*, *Ateuchus*, &c.

The nucleus (Pl. I. Fig. 7) is generally central, globular, and pretty uniform in size in the same species, averaging in measurement about $\cdot 025$ millimetre. Sometimes, as in *Cicada*, &c., where the cells are elongated, the nucleus is also irregularly so. (Pl. I. Fig. 5.)

The nucleolus is always transparent, and measures about $\cdot 006$ of a millimetre.

The central passage of the tubes, or separation of the cells in the middle line, is usually found filled with fine granules and a great amount of oil globules. (Pl. I. Figs. 4, 5.)

The biliary tubes of insects are bathed in blood or the nutritive fluid, and the respiratory trachææ are distributed to them with extreme minuteness, but are separated from the secreting cells through the intervention of the basement membrane. (Pl. I. Figs. 2, 3.)

Crustacea —The liver in the common cray-fish (*Astacus affinis*) of our rivulets, consists of two large lobes, one on each side of the intestine, united by an isthmus anterior to the middle. Each lobe consists of numerous long conical cæca, aggregated together. (Pl. I. Fig. 8.) From each cæcum passes off a narrow duct, to join a common trunk which opens into the intestinal canal, in the vicinity of the pylorus. In structure the cæca (Pl. II. Fig. 9) resemble the tubes of insects, being composed of a sac of basement membrane, within which, originating from the inner surface, are numerous secreting cells. The cells are more or less polygonal in form from mutual pressure. In the bottom of the cæca, the cells (Pl. II. Fig. 10) are small, with an average diameter of $\cdot 02$ millimetre, and contain a finely granular matter of a yellowish hue, with a granular nucleus, and a transparent nucleolus. As we proceed from the bottom onwards, the cells (Pl. II. Figs. 11, 12, 13) are found to increase in size, and to obtain a gradual addition of oil globules, until beyond the middle of the tube where

they are found filled with oil, so as to have the appearance of ordinary fat cells, and have a diameter averaging $\cdot 06$ millimetre. From this arrangement of the cells, when a cœcum is viewed beneath the microscope, (Pl. II. Fig. 8,) its lower half appears filled with a finely granular matter intermingled with nucleolated nucleated bodies, and the anterior half, with a mass of fat cells, the nucleus hardly visible, from the property of oil rendering organic tissues more or less transparent. The central cavity of the cœca is filled with fat globules, and a finely granular matter corresponding to that in the interior of the cells.

Mollusca.—The liver of the slug (*Limax*) and snail (*Helix*) consists of five lobes which are subdivided into lobules, (Pl. I. Fig. 16,) and each lobule is composed of numerous bulbiform cœca, polygonal from mutual pressure. From each of these passes off a duct, which by union form two trunks opening into the duodenum.

When one of the bulbiform cœca (Pl. I. Fig. 16) is examined beneath the microscope, it is found to have a structure differing in no important particulars from that of the cray-fish. The cells (Pl. II. Fig. 17) at the bottom of the sac average $\cdot 02$ millimetre in diameter; those towards the other extremity about $\cdot 04$ millimetre. Some of the fully ripe cells (Fig. 18) are filled with innumerable minute globules of oil hardly distinguishable from the granular matter; others (Fig. 19, *a, b, c*) with globules of a larger size; some (Fig. 21) are found with from one to ten, or more, large, deep yellow oil globules in the centre; a few (Fig. 22) with a hard, or crystallized mass of fat in the centre; and many (Fig. 20) are distended with oil. By pressing the cells (Fig. 23) between two plates of glass, the contents will be squeezed out, and the structure will be seen as follows:—The vesicular, transparent, amorphous cell wall, finely granular matter, fat globules, and a granular nucleus, measuring about $\cdot 01$ millimetre, and containing a hard, transparent nucleolus. A few of the cells contain two nuclei.

The blood-vessels, consisting of arteries and veins, form a rete around the bulbiform cœca, but do not appear to come in immediate contact with the secreting cells. Along the course of these vessels, and attached to them, numerous nucleated fat cells exist, and the white opaque colour, which often renders these vessels so conspicuous, as they ramify in the brown-coloured liver, I find arises from innumerable minute oil globules attached to every part of their parietes.

Vertebrata.—In vertebrated animals the liver is of large size and of no general regular form. It is usually divided by deep fissures into several portions or lobes, which are invested by the peritoneum. In colour it passes through all the shades of light pink or nearly white, yellow, red, brownish purple, and brown. When the surface is closely examined beneath the transparent peritoneum, it will be found to have somewhat the appearance of a mosaic structure, a dark ground inlaid with small portions of a lighter

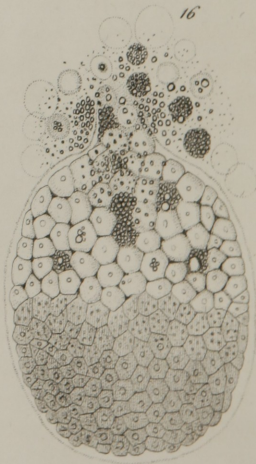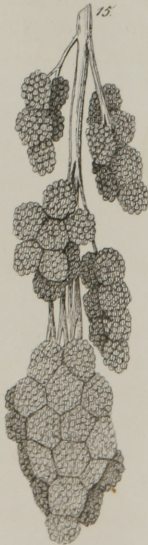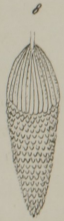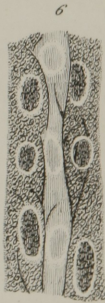
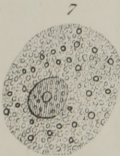
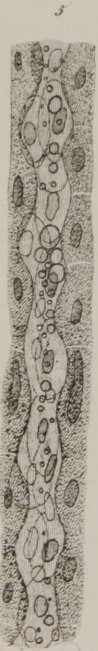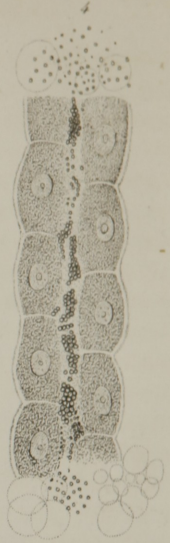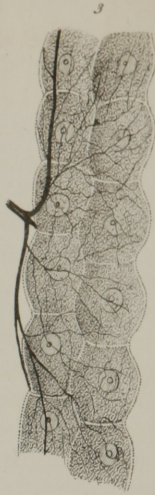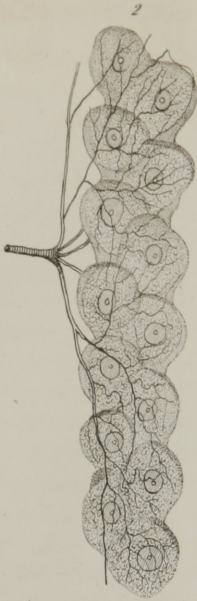
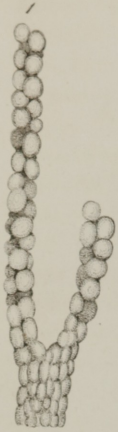
colour. In intimate structure it consists of numerous, small, irregular bodies, or lobules (lobules of Kiernan), corresponding to the lighter portions just mentioned, which are lobulated themselves and closely connected together by means of white and yellow fibrous tissue and the blood-vessels belonging to the organ, which correspond to the dark ground lines separating the lighter-coloured masses. The lobules are not regularly arranged side by side throughout the liver, but lie in all directions, principally, however, with their long diameters at right angles to the surfaces. When the vessels of a liver have been injected, and the organ then hardened in alcohol so that it may be rendered more consistent and its difference of structure more perceptible, and a section made at right angles to the surfaces of the organ, a view like Fig. 31, Pl. III., will be obtained. In such a section lobules will be observed to be cut in all directions; longitudinally, when they have a foliated appearance; obliquely or transversely when they have a more or less polygonal form depending upon the amount of mutual pressure at any part of the liver, being greatest in the interior, least near the surface. In their interior, sections of blood-vessels are seen, which belong to the hepatic veins; and the vessels occupying the interspaces between them are branches of the hepatic artery and vena portarum. The lobules are composed of an intertexture of biliary tubes, (*pori biliari*.) (Pl. III. Fig. 32,) and in the areolæ or interspaces of the network the blood-vessels ramify and form amongst themselves an intricate anastomosis, the whole being intimately connected together by a combination of the white fibrous and yellow elastic tissue.

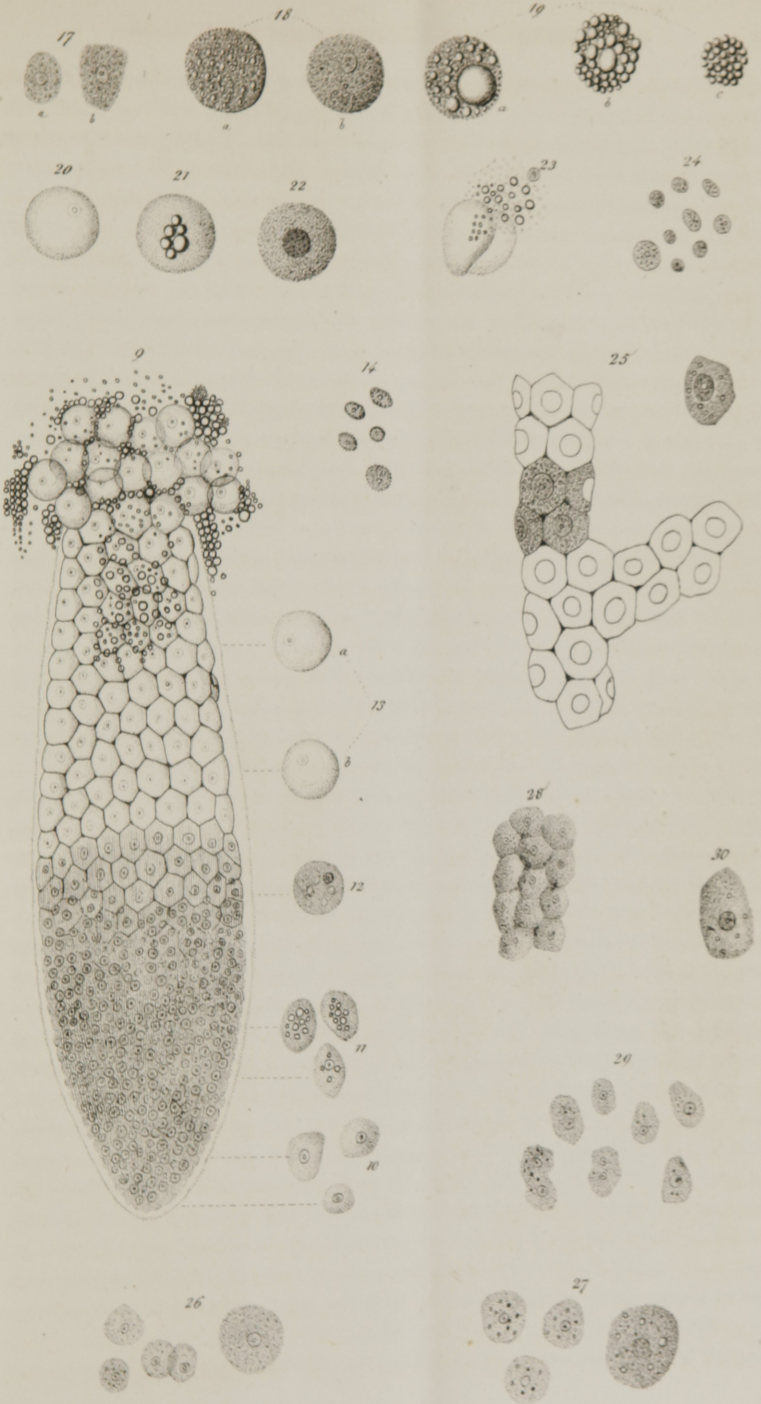In structure the biliary tubes (Pl. II. Figs. 25, 28; Pl. III. Figs. 33, 34), correspond with those of the invertebrata, consisting of cylinders of basement membrane containing numerous secreting cells, and the only difference exists in the arrangement; the free tubes of the lower animals in the vertebrata becoming anastomosed or forming an intertexture. The tubuli vary in size in an unimportant degree in different animals, and also in the same animal, being generally from two to two and a half times the diameter of the secreting cells. The tubes of one lobule are distinct from those of the neighbouring lobuli, or only communicate indirectly by means of the trunks or hepatic ducts originating from the tubes and lying in the interspaces of the lobuli. The secreting cells (Pl. II. Figs. 25, 26, 27, 29, 30; Pl. III. Figs. 35, 36, 37) are irregularly angular, or polygonal in form from mutual pressure, and line the interior surface of the tubes. They vary in size in a moderate degree in different animals and also in the same animal, appearing to depend upon certain conditions of the animal and liver. The colour is light yellowish, or brownish when in mass, the other and darker colours of the liver appearing to depend upon the blood in the organ. They contain a finely granular matter, oil globules, a granular nucleus, and a transparent nucleolus.

The finely granular matter is the portion from which the colour of the

[The text in this section is extremely faint and illegible. It appears to be a multi-paragraph document, possibly a letter or a report, but the specific content cannot be discerned.]







cell is derived; it appears to be made up of innumerable exceedingly minute spheriform granules, which, when under a low power of the microscope and well defined, look like so many minute black points. This substance, from its quantity and minute state of division, often obscures the nucleus so that it cannot be distinguished until acetic acid is applied to it, when it is rendered more translucent without affecting the nucleus. The oil globules vary in quantity in different conditions of the liver, and in different cells. It exists in the form of exceedingly minute globules, looking like so many intensely black points, and hardly perceptible from the granular contents of the cells, up to larger and distinct globules, sometimes one-fourth the diameter of the cell. From this gradual advance from the state in which it is hardly distinguishable from the granular matter up to a large size, and in the invertebrata even to a distended state of the cell, a gentleman, to whom I presented the observation, supposed that the liver only secreted fatty matter, while the gall-bladder secreted cholesterine, the latter fact being presented to his observation in several pathological cases, in which the cystic duct was obstructed and the bladder filled with white concretions (biliary calculi), which consisted of pure cholesterine. This, which appears plausible at first view, falls at once to the ground when it is recollected that some animals have no gall-bladder, as the horse, sloth, &c., and yet secrete a bile constituted like that of animals possessing a gall-bladder. The giraffe, it is also well known, in the three or four cases in which the animal has been dissected, in two cases had no gall-bladder, and in a third instance possessed one of large size. I have mentioned that the quantity of oil globules varies in different conditions of the animal or organ. If the animal be very fat, or be well fed, especially on substances containing much starch, it will be found in greater abundance than usual; as may be readily seen in the difference between poultry which run about and those which are penned up for fattening; and I have no doubt that in the preparation of the liver of geese, in which it becomes enormously enlarged, for making the "*paté de foie gras de Strasbourg*," there is not the addition of a single secreting cell, but merely an accumulation of fat globules, within the secreting cellules, derived indirectly from the starchy matters of the food, which ordinarily are consumed in the process of respiration. In phthisis, in which more or less of the respiratory surface is destroyed, the liver appears to take upon itself part of the office of the lungs, but rids the blood of the excess of carbon in another way, that is by converting it, with the elements of water, into fat, which is deposited within the cells, producing what is called "fat liver." The same condition of the liver is produced in drunkards, probably from the stimulation to nutrition and the conversion of the alcoholic constituents into fat. It is also produced in some other ways not well understood, as was presented to me lately in a case of Prof. S. Jackson's, in which the patient had laboured for a long time under disease of the liver and dyspepsia, and died of hemor-

rhage from the bowels consequent on extensive ulceration of the mucous membrane.

The nucleus is generally central, frequently lateral, globular, and pretty uniform in size in the same animal. It is granular in structure and never contains oil globules; generally, it is but indistinctly seen, excepting in fishes and reptiles, and frequently not at all, from the granular contents of the cell obscuring it, but is readily brought into view by the influence of acetic acid upon the latter. Sometimes there are two nuclei instead of one.

The nucleolus measures about $\cdot 001$ millimetre, is round in form, consistent, and transparent, and is situated in the centre of the nucleus.

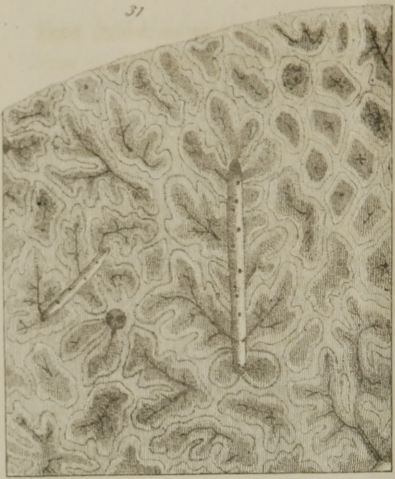The interlobular trunks or commencement of the hepatic ducts, as they originate from the biliary tubes or pores, run in varied directions in regard to the lobules, and freely anastomose with each other, and by their convergence form trunks which take a general course at right angles to the surfaces of the liver, and finally appear by several trunks externally beneath the liver.

The blood-vessels (Pl. III. Figs. 38, 39) of the liver consist of two sets, the hepatic artery and vena portarum, which convey the blood to it, and a third set, the hepatic veins, which conducts the effete blood from it into the general circulation again.

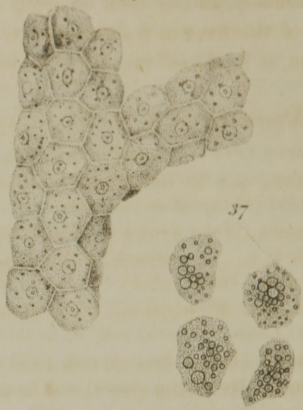The hepatic artery, much smaller than the vena portarum, appears to be appropriated to the nutrition and supply of oxygen to the tissues entering into the composition of the liver; while the vena portarum is probably devoted to the conveyance of blood to the secreting cells, which appropriate the peculiar fluid of the liver, or bile from it. These two vessels enter the liver at the place of exit of the hepatic ducts, and follow the same course inwards that the latter did in coming out. The artery in its passage supplies the ducts with branches and the vena portarum with vasa vasorum. In the intervals of the lobules they comport themselves very much in the manner of the interlobular ducts, and form an intricate network around the lobules, but whether the two sets of vessels anastomose I could not satisfactorily determine. They both send off numerous branches which enter the lobules at right angles to the length of the latter, and form an intricate plexus by turning through the interspaces of the biliary tubes. The vessels within the lobules freely communicate with each other and converge towards their interior, where they terminate in trunks, which run in the length of the lobules, and are the commencement of the hepatic veins. This free intercommunication of the three sets of vessels within the lobules has been fairly proved to me by a minute injection of a young liver, by Prof. Wm. E. Horner, of the University. All three of the vessels have been injected with red size, and it has penetrated beautifully, and a fine section from almost any part of it, beneath the microscope, has the appearance represented in Fig. 39.

The commencing branches of the hepatic veins issue from the base of

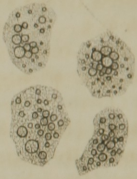31



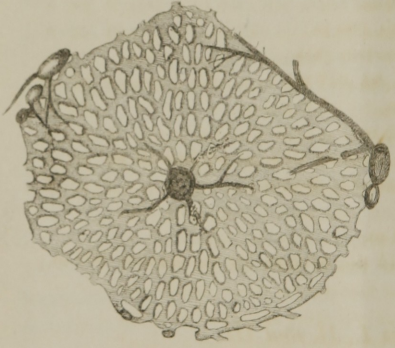
34



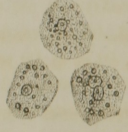
37



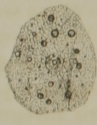32



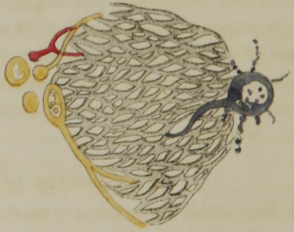
33



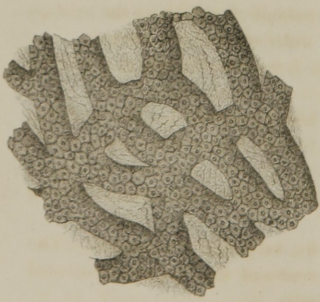
36



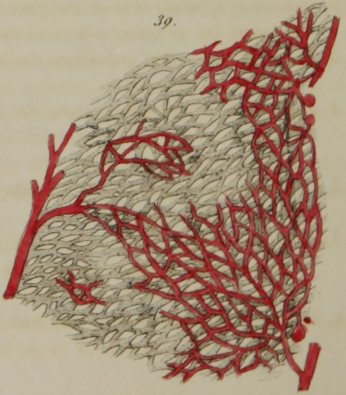
38



33



39



the lobules, and by their convergence, form several large trunks, which pass out of the liver at right angles to the other two sets and parallel to its surfaces, at its dorsal margin close to the spinal column.

Measurement of the Secreting Cells of the Liver of some Animals.

- Centiped (*Julus impressus*) cell, .0125.
 Tumble bug (*Ateuchus volvens*) cell, longest diameter .0225 m.; shortest, .0125 m.
 Katydid (*Platyphyllum concavum*) cell, .13 m. in length; nucleus .0225 m.
 House-fly (*Musca domestica*) cells, .09 by .06 m.; nucleus .0225 m.
 Flesh-fly (" *carnaria*) cell, .09 m.; nucleus .0275 m.; nucleolus .006 m.
 Cray-fish (*Astacus affinis*) cell, .02 to .06 m.; nucleus .015 m.
 Snail (*Helix albolabris*) cell, .02 to .04 m.
 Slug (*Limax variegatis*) cell, .03 to .06 m.
 Rock fish (*Labrax lineatus*) cell, .0275 m.
 Minnow (*Hydrargira ornata*) cell, length .02 m.; breadth .015 m.
 Cat-fish (*Pimelodus catus*) cell, .0275 m.
 Lizard (*Triton niger*) cell, .03 m.; nucleus .0125 m.
 Frog (*Rana halcina*) cell, length .03 m.; breadth .02 m.; nucleus .005 to .01 m.
 Terrapin (*Emys terrapin*) cell, .03 m.
 Snake (*Tropidonotus sirtalis*) cell, .02 to .0275 m.
 Boa (*Eoa constrictor*) cell, .03 m.; nucleus, .0150 m.
 Duck (*Anas acuta*) cell, .0175 to .02 m.; nucleus .006 m.
 Owl (*Strix brachyotos*) cell, average .015 m.; nucleus .005.
 Chicken (*Gallus domesticus*), lean, cell .016 m.; fat, .017 m.
 Ground Squirrel (*Sciurus striatus*) cell, .0175 m.
 Gray " (*Sciurus Carolinensis*) cell, .015 m.
 Rabbit (*Lepus Americanus*) cell, largest .03 m.; smallest .015 m.; nucleus .01 m.
 Sloth (*Bradypus tridactylus*) cell, .0133 m., remarkably distinct.
 Leopard (*Felis leopardis*) cell, .0125 to .015 m.
 Monkey (*Simia* ———?) (*American*) cell, .015 m.
 Man—cell, largest .03 by .02 m.; smallest .015 m.; average .02 m.; nucleus .009 m.; nucleolus .001 m.

Explanation of Plates I., II. and III.

- Fig. 1 Represents a portion of a trunk and two branches of one of the biliary tubes of the flesh fly (*Musca carnaria*), viewed by reflected light, and magnified 8 diameters.
- " 2, Portion of a biliary tube of the flesh fly, highly magnified, exhibiting the arrangement of the secreting cells, and the mode of distribution of the tracheæ.
- " 3, From the house fly; exhibiting the same as fig. 2, with the exception of a different form of the cells.
- " 4, Portion of a biliary tube from the house fly, highly magnified. The secreting cells are seen ranged upon each side with a passage between the rows, which is filled with oil globules.
- " 5, 6, Portions of a biliary tube from the katydid (*Platyphyllum concavum*), exhibiting the elongated cells and nuclei.
- " 7, A secreting cell from the liver of the flesh fly, very highly magnified. The nucleus with its nucleolus is seen near the centre of the cell, and distributed through the latter are seen numerous oil globules.
- " 8, Portion of the liver of the cray fish (*Astacus affinis*), magnified 3 diameters, and exhibiting the structure of cæcal tubes.

- Fig. 9, A cœcum or biliary tube of the cray fish (from an individual which was one inch in length and had been well fed for some time), highly magnified. At the bottom is seen a confused mass of cells with their nuclei and nucleoli, but at the upper part of the sac they are seen distinct, and polygonal from pressure, and filled with oil which renders them transparent. At the mouth or open extremity numerous detached cells and oil globules are perceived, which have been squeezed out by the pressure of a thin plate of glass.
- Figs. 10, 11, 12, 13, a, b, Exhibit the progressive change of the cells as they advance from the bottom of the tube.
- Fig. 14, Nuclei, from the secreting cells of the liver of the cray fish, highly magnified.
- " 15, Portion of the liver of the snail (*Helix albolabris*), moderately magnified, exhibiting the arrangement of the lobules.
- " 16, A biliary cœcum from the liver of the snail, highly magnified. It shows the same structure as fig. 9.
- " 17, a, b, Two cells, from the bottom of a biliary cœcum of the snail, highly magnified.
- " 18, a, b, Two cells, more advanced, containing numerous very minute oil globules.
- " 19, a, b, c, Three cells, containing larger oil globules.
- " 20, A cell distended with oil.
- " 21, A cell containing nothing but six deep yellow consistent oil globules.
- " 22, A cell containing a hard yellow mass of fat.
- " 23, A cell ruptured and its contents escaping.
- " 24, Nuclei, from the cells of the liver of the snail, highly magnified.
- " 25, Portion of a biliary tube and secreting cells, from the liver of a lizard (*Triton niger*), highly magnified.
- " 26, Secreting cells, from the liver of an owl (*Strix brachyotos*), highly magnified.
- " 27, " " from a duck (*Anas acuta*).
- " 28, Portion of a biliary tube of the rabbit (*Lepus Americanus*), highly magnified.
- " 29, 30, Secreting cells from the liver of the rabbit.
- " 31, Longitudinal section of human liver from the posterior part near the upper surface, magnified 3 diameters, from a preparation made by Prof. W. E. Horner of the University of Pennsylvania. The three sets of blood-vessels were injected with colouring matter and the preparation then preserved in alcohol. The blood-vessels represented in the drawing belong to the hepatic veins, and are seen at various parts coming from the interior of the lobules. The spaces between the lobules, which are filled with branches of the hepatic artery and vena portarum and hepatic ducts, have been purposely left white so as not to obscure the view of the lobules.
- " 32, Transverse section of a lobule of the human liver, taken from the same preparation as fig. 31, highly magnified, and presenting to view the reticulated structure of the biliary tubes. In the centre of the figure is seen the hepatic vein cut across and several small branches terminating in it. Where the injecting matter did not run freely, it is seen standing in dots along the course of the vessels. At the periphery are seen branches of the hepatic artery, vena portarum and hepatic duct.
- " 33, A small portion of fig. 33 more highly magnified. The secreting cells are seen within the tubes, and in the interspaces of the latter the fibrous tissue is represented.
- " 34, Portion of a biliary tube, from a fresh human liver, very highly magnified. The secreting cells may be noticed to be polygonal from mutual pressure.
- " 35, Three secreting cells detached.
- " 36, A secreting cell much more highly magnified, representing plainly the internal

structure. The granular nucleus is central, and the small bodies with thick black outlines represent oil globules.

- Fig. 37, Four secreting cells, from a human liver, in a diseased condition called "fatty degeneration" or "fat liver." The great increase of oil globules is observable.
- " 38, Transverse section of a lobule, from the same preparation as 31 and 32, but not so highly magnified as 32, representing the relation of the three sets of blood-vessels with each other and with the biliary tubes. The artery is coloured red, the vein blue, and the vena portarum yellow.
- " 39 Represents a longitudinal section, highly magnified, of a portion of a lobule, from an injected preparation, made by Dr. Horner, of the liver of a child about 6 years of age. It will be perceived there is a free anastomosis of the three sets of vessels, which have all been successfully injected with red colouring matter. Spaces are also observable through which the injection failed to pass.

structure. The granular portion is coarse, and the small bodies with thick

black outlines represent oil globules.

27. For a section with free air, in a closed condition called "dry

depression," see "the liver." The great number of oil globules is characteristic

of the granular portion of a liver, from the same preparation as 21 and 22, but not

as highly magnified as 22, representing the colour of the first set of blood

vessels in each colour and with the brown stain. The artery is coloured red

the vein blue and the vein parietal yellow.

28. Represents a longitudinal section highly prepared, by a portion of a whole liver

an injected preparation made by Dr. Huxley, of the liver of a child about 2

years of age. It will be perceived that in a few instances in the three

arterial vessels, but all have necessarily injected with red staining

matter. There are also elements through which the injection holds in

passage.

Dr. Wyman,
with the author's respects.

Observations on the existence of the Intermaxillary Bone in the Embryo of the human subject.

By JOSEPH LEIDY, M. D.

The immortal Goethe, I believe, was the first to point out the existence of the os intermaxillare in the human subject, but it has only been observed in an abnormal condition, or where there has been an arrest of development in connection with some cases of hare-lip; and the period of life in which it is found as a distinct piece, and its exact limits, have not yet been accurately determined. The universality of the presence of the os intermaxillare in all animals below man, its presence as a distinct piece in an abnormal condition in man, always defined by a lateral fissure which characterizes it as the incisive bone, and the uniform existence of a transverse fissure behind the incisive alveoli of the os maxillare superius of the human foetus at birth, have led many anatomists to suspect its normal and independent existence in the embryotic condition of man at an earlier period than it has been sought for.

As the negro in his anatomical characters is not so far removed from the embryological condition as the white, it is to be presumed that the intermaxillary bone would remain longer distinct; and under such an impression I have several times desired medical students, from our Southern States, whose opportunities of investigating the anatomy of the negro are frequent, to make this a subject of inquiry. Such an opinion cannot be considered unworthy of attention, when it is recollected that Tschudi mentions the existence of a true os interparietale, as a constant condition, in certain branches of the aboriginal inhabitants of Peru, the Chinchas, Aymaras and Huanacas.

Recently having had an opportunity of examining several human embryos, in one of them I was fortunate enough to detect the intermaxillary bone as a distinct and independent piece. This embryo measured one inch and eleven lines from heel to vertex, and I presumed it to be about nine or ten weeks old. In it ossification had already advanced in the superior maxillary and intermaxillary bones sufficiently to give them a determinate form, and their appearance, when magnified, is represented in the figures 1 and 2, which were taken from the specimens through the aid of the camera lucida.

Fig. 1.

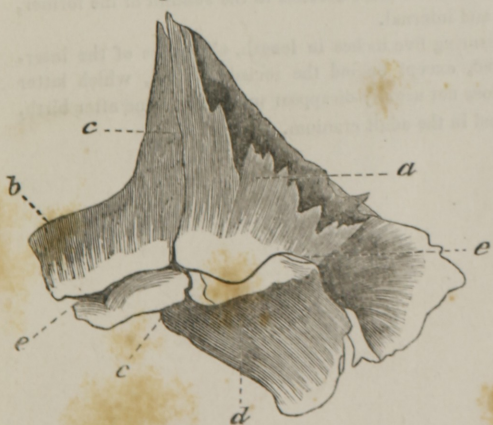

Fig. 2.

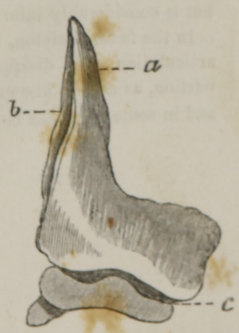

Fig. 1 represents the superior maxillary and intermaxillary bones, much magnified, of a human embryo. The drawing was taken from the right side through the aid of the camera lucida, which reverses its position. *a.* superior maxillary bone; *b.* intermaxillary bone; *c.* line of articulation between the two bones; *d.* palatine process; *e.* alveolar groove.

Fig. 2 represents the antero-inferior surface of the separated intermaxillary bone, much magnified. (From the left side, but reversed by the camera.) *a.* ascending or nasal process; *b.* articulating surface for the superior maxillary bone; *c.* incisor alveoli.

The greatest breadth of the two bones in apposition is one line and two-thirds, the greatest height, being at the ascending or nasal process, is one line. The two pieces present a facial portion, consisting of the ascending or nasal process and part of the body of the bones; an alveolar ridge and groove and a palatine process projecting backward from the superior maxillary bone. They are easily separable at this period, and the articulation passes through the alveolar ridge, at a point corresponding to the separation between the incisor alveoli and the canine alveolus, and extends transversely inwards behind the incisor alveoli, and vertically upwards, dividing the nasal process into two nearly equal portions. On the posterior surface of the nasal process the articulation is at the bottom of a comparatively deep and wide groove, which, however, does not appear to be part of the lachrymal canal, as the latter appears afterwards and external to the former groove. The preparations exhibiting these interesting points which prove the existence of the same law, throughout the animal kingdom, governing the formation of the upper maxillary bones, I present for the inspection of the members of the Academy.

In an embryonic skeleton in the Wistar Museum, measuring three and one-eighth inches in length, and purporting to be about nine weeks old, which, however, I think too young, the maxillo-intermaxillary articulation is still evident at the ascending process, but it does not divide the latter so equally, being more internal and inferior, apparently from a more rapid development of the nasal process of the true maxillary bone. Just above the alveolar ridge they are already ankylosed together.

In another embryo, in the same museum, measuring three and one-fourth inches in length, the two bones have become firmly united, excepting behind the incisor alveoli, but the line of original separation is readily traced out, from a greater degree of thinness and transparency along its course. The nasal process of the true maxillary bone has so much increased beyond the nasal process of the intermaxillary bone, that the latter no more ascends to the summit of the former, but is considerably inferior and internal.

In the fetal skeleton, measuring five inches in length, all traces of the inter-articulation have disappeared, except behind the incisor alveoli, which latter portion, as is well known, does not usually disappear until some time after birth, and in some instances is found in the adult cranium.

NATIONAL LIBRARY OF MEDICINE



NLM 04139040 6

ARMY
MEDICAL LIBRARY