

PRACTICAL
NORMAL HISTOLOGY

QSA P971m 1887

61220260R



NLM 05045782 4

NATIONAL LIBRARY OF MEDICINE

Turner
ney
Hospital

DR. M. L. TURNER
Berwyn, Md.

SURGEON GENERAL'S OFFICE
LIBRARY.

Section

3-513

RETURN TO
NATIONAL LIBRARY OF MEDICINE
BEFORE LAST DATE SHOWN

JAN 21 1986

Stall
Whitbeck

10 - 20



M Turner

302-51-

N.Y.C.

A MANUAL
OF
PRACTICAL NORMAL
HISTOLOGY

DR. M. L. TURNER
Berwyn, Md.
Box 33

BY

T. MITCHELL PRUDDEN, M.D.

DIRECTOR OF THE PHYSIOLOGICAL AND PATHOLOGICAL LABORATORY OF THE ALUMNI
ASSOCIATION OF THE COLLEGE OF PHYSICIANS AND SURGEONS, N. Y. ;
LECTURER ON NORMAL HISTOLOGY IN YALE COLLEGE ; PATHOLOGIST
TO THE MANHATTAN EYE AND EAR HOSPITAL.

SECOND EDITION.
Revised, with an Appendix.

NEW YORK & LONDON
G. P. PUTNAM'S SONS
The Knickerbocker Press
1887

QSA

P971m

1887

COPYRIGHT

G. P. PUTNAM'S SONS

1881.

Film 7414. Item 1

Press of

G. P. PUTNAM'S SONS

New York

PREFACE TO THE SECOND EDITION.

The advances in Normal Histology since the first edition of this book was written have been largely in the direction of improved technical procedures. These improvements have been embodied in this edition, for the most part in an appendix, to which references are made in the text by foot-notes.

T. M. P.

NEW YORK, *July*, 1884.

LETTERS TO THE BOUNTY KITION

The amount of General Bland's share in the
Bounty was \$100,000. It was paid to him in
1817. He died in 1820. His estate was
valued at \$1,000,000. He left a large
family. His share of the Bounty was
paid to his heirs.

T. H. B.

PREFACE.

This book has been prepared for the use of those students and practitioners of medicine, who with a limited amount of time at their disposal, wish to acquaint themselves in a practical way with Normal Histology. It is especially designed for those who study the science in classes, with an instructor in a laboratory; but the technical procedures are described with sufficient fulness for the needs of those who are obliged to pursue the study by themselves.

The method adopted is to give a brief description of the tissues and organs in appropriate sequence, following each description with an account of the way in which the structures described may be demonstrated. The descriptions were written for the most part at the microscope table, with the preparations made by the methods recommended, under the eye of the writer, so that it is believed that the student will have no difficulty in verifying them.

Too much stress cannot be laid upon the necessity of each student making outline sketches of all

but the more complicated structures examined, and for this provision has been made in the book. It is not to be expected that epitomized descriptions of structures as elaborate as are many of those with which we have to deal in Human Histology, will be in all cases perfectly clear and intelligible without the aid of plates; but the specimens which the student prepares, and the sketches from them which he makes, will make good, it is hoped, the lack of illustration in the text. Indeed, the more critical examination which accurate sketching requires, as well as the facility which this exercise cultivates, will enlarge the achievements of such a course of study beyond the acquirement of a knowledge of this theme alone, so as to embrace a valuable training of the eye and hand.

This book is not designed to take the place of more elaborate treatises on this subject; nor is it written with the design of fostering the deplorably wide-spread tendency among medical students, to be content with the barest smattering of those branches which are not in the most evident manner "practical." On the contrary, where time permits, collateral reading and additional practical work are most urgently recommended. But the necessity for improvement in medical education, which is expressing itself in the medical colleges of this country, especially in the establishment of laboratories and practical courses of instruction, is, unfortunately,

not yet sufficiently deeply felt as to have led to the general lengthening of the period of undergraduate study; so that very little time is usually at the disposal of medical students for collateral reading, or for the pursuit of elaborate practical investigations. It is desirable, moreover, since the laboratory time itself is usually limited, to occupy as little of it as may be, in oral descriptions of tissues and methods.

It is these considerations which seem to justify the addition of another to the long list of elementary text-books.

There are many points in this, as in every developing science, which are still unsettled—opinion in regard to them changing or being modified as new facts and investigations are recorded. These have been treated, for the most part, very briefly in the text, it being left for the supplementary oral instruction to enlarge upon and explain them, as the light thrown upon each by new researches may seem to require.

In the simpler form of "Notes on the Practical Course in Normal Histology" the substance of this book has been in use for two years in the laboratory of the Alumni Association of the College of Physicians and Surgeons, and it has been found that with some preliminary preparation of tissues by the instructor, the subject essentially as presented here, can be embraced in a course of forty lessons of about two hours each.

The writer wishes, in conclusion, to express his sincere thanks to Prof. Francis Delafield, to whose wise counsel and unwearied assistance in many matters requiring a wider experience than his own, he is greatly indebted.

T. M. P.

LABORATORY OF THE ALUMNI ASSOCIATION
OF THE COLLEGE OF PHYSICIANS
AND SURGEONS.

NEW YORK, *May*, 1881.

CONTENTS.

	PAGE
INTRODUCTION	I
I—THE CELL IN GENERAL	17
II—CONNECTIVE TISSUE	27
III—EMBRYONAL AND MUCOUS TISSUE—FAT TISSUE—RETICULAR CONNECTIVE TISSUE	48
IV—CARTILAGE—BONE—TEETH	56
V—BLOOD AND LYMPH	80
VI—MUSCULAR TISSUE	91
VII—NERVE-TISSUE	103
VIII—BLOOD-VESSELS—LYMPHATIC VESSELS	119
IX—LYMPH-NODES—SPLEEN	129
X—THE GASTRO-INTESTINAL CANAL	143
XI—SUBMAXILLARY GLAND—LIVER	155
XII—SUPRA-RENAL CAPSULES—THYROID GLAND	164
XIII—THE RESPIRATORY APPARATUS	168
XIV—THE KIDNEY	178
XV—THE GENERATIVE ORGANS	188
XVI—THE CENTRAL NERVOUS SYSTEM	211
XVII—THE SKIN AND ITS ADNEXA	220
XVIII—THE EYE	232
APPENDIX	251

INTRODUCTION.

GENERAL METHODS FOR PRESERVING TISSUES AND PREPARING THEM FOR STUDY.

Animal tissues must conform to certain physical conditions before they can be subjected to a satisfactory microscopical examination. Portions of them subjected to study must be sufficiently thin to allow the light to pass readily through them, and transparent enough to permit the determination of the form, character, and relations of their structural elements. At the same time the refractive power of the different elements should not be too nearly alike, since upon differences in this respect, the form and characters which microscopical objects present to the eye are largely dependent; or, in case they are so, the different elements must be rendered visible by staining them with coloring agents.

Certain tissues naturally undergo rapid changes of structure after death; these are to be prevented by the use of preservative agents. Some are too soft to permit the preparation of thin sections, and must be hardened; others are too hard and must be softened. In some specimens one, in others another,

structural feature is to be brought into prominence. All of these indications in the histological technique are to be met in such a way as to leave the structures under investigation in as natural a form as possible. Finally, specimens suitably prepared for examination, are in many cases, to be rendered permanent for future reference and study.

We will now consider briefly some of the methods by which these indications may be fulfilled. Most histological specimens are laid in some enclosing fluid medium, on a glass plate and covered with a thin slip of glass, before being brought upon the microscope. One of the simplest methods of studying tissues is to place them, when quite fresh and after they are reduced to a condition of suitable tenuity, on a slide with some fluid which alters their physical condition but little or not at all, or at least very slowly, and examine them at once. Such a fluid is called an *indifferent fluid*, and for most purposes a dilute solution of common salt, one-half to three-quarters per cent., answers very well.

The examination of fresh tissues is very important, not only because it enables us to study the vital phenomena in certain elements, but because we are thus enabled by comparison to determine the amount of change which tissues undergo when prepared by more elaborate methods. Still it is in many respects unsatisfactory. In the first place, it is not always easy to procure fresh tissues for every

observation, and even in an indifferent fluid, tissues sooner or later undergo considerable alterations, so that they cannot be permanently preserved. A still more important deficiency in this method is the lack of distinctness in structural details which it involves. Most of the fresh animal tissues are nearly transparent in thin pieces, and their structural elements have so nearly the same refractive power, that we see through them, but do not see them; or, if we do see them, it is not with that definiteness which our purposes demand. Now these difficulties are usually met by the use of agents which harden and preserve the tissues and at the same time render the details of their structure visible, by changing the refractive power of one or other of their elements; or, we employ certain coloring agents, which, being taken up with different degrees of avidity by different parts, assist in the recognition of details by differences in color; or, such agents are used as both harden and stain at once; or, finally which is the most common method, we employ two or more of the different classes of agents, one after the other. We shall consider here only some of the most common and useful of these agents.

HARDENING AND PRESERVATIVE AGENTS.

Alcohol is one of the most valuable of these. It causes a considerable shrinkage of most tissues, partly by the withdrawal of water from them, and,

like many of these fluids, precipitates certain of their albuminoid constituents, thus diminishing their transparency. It is in general to be used at first diluted with one-third water, and after the tissues have lain for 24 hours in this, they are transferred to strong alcohol in which they may be preserved indefinitely. Bits of tissue to be preserved in alcohol, as in other hardening agents, should be quite small, not larger, as a rule, than 1 or 2 cms. on a side, and the quantity of fluid should be abundant. Certain structures are best preserved by plunging them at once into strong alcohol.

Aqueous solutions of *chromic acid* and of *potassium* and *ammonium bichromate* and of the neutral *chromate of ammonium* are much used to preserve and harden tissues, and many structures are more perfectly preserved in these fluids than in alcohol. The hardening proceeds more slowly than in alcohol, and the structures do not shrink as much. It is a common practice to commence the hardening with one of the chromic fluids and complete it with alcohol, the former being thoroughly washed out before immersion in the latter. Specimens should not remain too long in chromic fluids since they are apt to become brittle. An immersion of from 2-3 weeks usually suffices, especially if alcohol is to be used afterward.* Chromic acid may be used in solutions of from $\frac{1}{6}$ to $\frac{1}{2}$ per cent., potassium and ammonium bichromate in 2 per cent., and the neutral ammonium chromate in 5-per-cent. solution.

* See Appendix, p. 2

A very useful preservative solution is *Müller's Fluid*, consisting of

Sodium sulphate,	1
Potassium bichromate,	2
Water,	100

Chromic acid renders the lime salts in bone soluble, and is often used to soften them in preparation for section-cutting.

Picric Acid.—This agent while hardening, preserves the structure of many tissues very perfectly, and at the same time stains them yellow. It is usually necessary to complete the hardening with alcohol. For the decalcification of bone it is one of the best of agents, although it acts very slowly. It is used in saturated aqueous solution.

Osmic Acid.—This substance has the power of fixing and hardening the tissue elements in a nearly normal form, and is one of the most valuable of this class of agents. It gives tissues a gray or brown appearance, and stains fat and certain allied substances deep black. It is used in one-per-cent. aqueous solution. The tissue should be quite fresh when immersed in it, and, as a rule, should remain for twenty-four hours. Specimens hardened in osmic acid commonly become quite granular and dark after a time.

Preservative fluids are sometimes brought into more direct contact with the tissues, by injecting

them into the blood-vessels of the part before cutting it in pieces; or they may be driven directly into the interstices of the tissue, by means of a small syringe with a sharp-pointed canula; this is called *interstitial injection*.

Indications as to which of these agents are best adapted for the preservation of different tissues, and the more exact details of the methods of employing them, will be given as we proceed with our practical study.

STAINING AGENTS.

Hæmatoxylin is one of the most generally useful of the staining agents. It has the power of coloring certain parts, as the nuclei of cells, deeply, while other parts are stained much less, or not at all. The following is Prof. Delafield's method of preparing the solution: To make six hundred c. c. of the solution, take four hundred c. c. of saturated solution of ammonia alum, with an excess of the alum crystals, and add to this four grms. of hæmatoxylin (Merck's is preferable, the crude extract will not answer), dissolved in twenty-five c. c. strong commercial alcohol. This, at first, produces a light violet, or sometimes a dirty-red color, but on exposure to the light, in an unstoppered bottle, the color deepens; after standing for three or four days exposed to the air and light, the solution is filtered, and one hundred c. c. each, of glycerin and Hast-

ings' wood naphtha (pyroxylic spirit) are added. The solution is now allowed to stand for a day or two, and is then filtered again, and this filtration is repeated, after standing, until a dark sediment is no longer formed. The color is now usually very deep, and the solution should be kept in a tightly-stoppered bottle.

Such a solution is usually to be diluted with water before using, the exact degree of dilution depending upon the rapidity with which we wish the specimen to be stained. As a rule, slow staining with a dilute solution gives the best result, and is less likely to cause shrinkage of the specimen. In staining, bits of tissue are placed in a small dish of the solution, so that they are bathed on all sides by it, and allowed to remain until sufficiently colored. The time required will depend on the strength of the solution, and also, to a considerable degree, upon the character and previous preparation of the tissue. The excess of coloring fluid is to be thoroughly washed out of the specimen by water before further manipulation.

Carmine.—This is a red stain, and is employed in the same manner as hæmatoxylin, and is useful where we do not wish as great body of color in the specimen as the hæmatoxylin imparts. It may be prepared by dissolving two grms. of commercial carmine in a few drops of strong ammonia, and adding one hundred c. c. of water. It should be

allowed to stand in an open vessel until the excess of ammonia evaporates. As a rule, old carmine solutions stain better than those recently prepared.

Picro-carminate of Ammonia, or Picro-carmine.—With this substance we can obtain at once a yellow color from the picric acid in certain elements, while others are stained red by the carmine. It is prepared by adding to a saturated solution of picric acid, a strong, ammoniacal solution of carmine to saturation; evaporating the mixture to one-fifth its bulk; allowing to cool; filtering from the deposit, and evaporating the filtrate to dryness over a water bath. The picro-carmine is left in the form of an ochre-red powder, which, for use, may be dissolved in water in the proportion of one to one hundred.

Eosin.—This substance stains tissues more uniformly than many other dyes, and is especially valuable when used in connection with other coloring agents, such as hæmatoxylin, which stains the cell nuclei more deeply, since by this method of double staining we have certain elements exhibiting one color, others another. Eosin may be conveniently used either in aqueous or alcoholic solutions of one to one hundred.

METHODS OF PREPARING SPECIMENS FOR STUDY.

Certain fluid tissues, such as blood, lymph, etc., are fitted for study, either fresh, or after suitable preservation, when a drop is placed on a slide, and

covered. Certain tissues occur in the form of membranes, of sufficient thinness to admit of study without other manipulation than spreading them out smoothly on a slide. In other cases we have recourse to the dissociation of tissues by needles, called *teasing*.

Section Cutting.—In many cases we wish to study the structural elements of a tissue in their normal relations to one another, and in parts which are too thick to permit a direct observation. In such cases we have recourse to thin sections, cut from the tissue by a sharp knife or razor, the tissue, if not sufficiently hard naturally, being hardened by one or other of the above-described methods. The razor employed for this purpose should have a thin blade, perfectly flat on the lower side, and somewhat concave on the upper side, so that a small quantity of fluid will lie upon it. A flat, shallow dish is partly filled with alcohol, with which the surface of the specimen to be cut, as well as the razor blade, should be constantly covered, the blade being dipped into the alcohol, and as much taken up as will lie upon it. The bit of tissue being held firmly in one hand, and the razor firmly but lightly in the other, the sections are made by long, slow, diagonal sweeps of the razor, the blade being drawn from heel to tip along the tissue, and not crowded directly forward. Much practice is required for making large, thin, and even sections, and the endeavor

at first should be to get thin and even sections, no matter how small they may be. The razor should never be allowed to get dull, its edge being frequently freshened by a few light passes along a leathern strop.*

INJECTIONS.

It is often desirable in studying the distribution of the blood- or lymph-vessels to fill them by injection with some colored substance by means of which their ramifications may be readily recognized. One of the most commonly employed injecting materials is a solution of gelatin colored with Prussian blue. This may be prepared as follows: Dissolve 4 grms. of gelatin in 60 c. c. of water on a water bath; divide the solution into two portions; to one portion add 4 c. c. of a saturated solution of sulphate of iron (green vitriol), stirring constantly; † to the other add first 8 c. c. saturated sol. of ferrocyanide of potassium, and then 8 c. c. saturated sol. of oxalic acid; these two portions are now to be slowly mixed with constant stirring, and then heated up to about the boiling point of water. The solution is now filtered hot through flannel, and is ready for use. An animal or organ injected with this mixture should be kept warm during the injection, as should all the utensils employed, so

* See Appendix, p. 251.

† Should the iron cause a pasty precipitate in the gelatin, this portion should be allowed to cool, when on warming again, with stirring, it will dissolve.

that the gelatin may not harden prematurely and stop the vessels. The injection may be made with a syringe, or better with some form of apparatus furnishing a constant pressure of variable degree.

EMBEDDING.

It often occurs that a bit of tissue from which we wish to prepare a section is too small or delicate to be held in the fingers; in such cases the object may be placed between two bits of hardened tissue, such as liver, tied round with a thread, and thus held while the sections are made. Or, such a specimen may be embedded in a mixture of equal parts of white wax and paraffin melted together, with addition of a sufficient quantity of olive oil to give the mass the proper consistence for cutting when cold.

Certain tissues are very friable, so that thin sections fall apart as soon as they are made; or they may contain cavities so that they do not afford sufficient resistance to the razor. In such cases the interstices may be filled with some fluid material which can afterward be rendered solid and resistant, so that the whole forms a firm mass; after the sections are cut the impregnating material may be dissolved out, so as not to interfere with study. The details of such impregnating processes will be found on p. 115.*

* See also the *celloidin method*, Appendix, p. 252.

MOUNTING.

Sections, bits of dissociated tissue, membranes, etc., having been duly prepared, they are to be mounted on a slide for study. The choice of a fluid for this purpose will depend upon the nature of the specimen, the mode of preparation to which it has been subjected, and the structural features which we wish especially to demonstrate. One of the fluids most frequently employed for this purpose is *glycerin*. Many of the hardening agents, such as alcohol, precipitates, as above remarked, certain albuminoid substances in the tissues, in the form of minute strongly refractive particles, thus rendering them more or less opaque, or at least translucent. Now glycerin has the power of penetrating many such tissues; and since, as a rule, its index of refraction is much more nearly like that of the albuminous particles, than is the refractive index of the substance lying between them, when the tissue becomes soaked with glycerin the light passes more directly through, and the tissue is more transparent. Many specimens, furthermore, preserve their structural features very perfectly for a long time in glycerin.

The stained specimens are either soaked until they become transparent in a small dish of glycerin, and then transferred to a slide and mounted in the same; or they may be mounted at once, with-

out the preliminary soaking. Eosin is soluble in glycerin, so that if a tissue stained in it is mounted in pure glycerin it gradually fades. To prevent this the glycerin used for mounting should be slightly tinged beforehand with eosin.

The strong refractive power of glycerin, although of value in rendering tissues transparent, is, however, in some cases prejudicial to our aims, because it makes them too transparent; its refractive power being so nearly like that of the tissue elements themselves that their more minute structure is concealed. For we find, within certain limits, that the greater the difference between the refractive power of an object and that of the fluid in which it lies, the more distinct will be the outlines of the object.

We have then in using glycerin as a mounting medium which renders tissues transparent, to guard against its too excessive action; and this may be done by mixing with it, in varying proportions, some less refractive substance, such as water. For permanent preservation, however, most tissues are to be put into pure or nearly pure glycerin.

Canada balsam is for many tissues a most excellent mounting medium. It possesses to a still greater degree than glycerin the power of rendering them transparent, obscuring proportionately, in the manner above described, certain of their minute structural features. This difficulty can, however, be to a considerable extent obviated with bal-

sam as with glycerin, by the judicious use of coloring agents. Thus, for example, suppose we have an object containing cells, the exact outlines of which we wish to bring clearly into view; if we stain with hæmatoxylin alone, and then mount the object in balsam, the nuclei will be distinctly seen, because they have a violet color; but the cell body will in many cases be well nigh invisible, because it has almost the same refractive power as the balsam which surrounds it. If, however, before mounting in balsam we stain with eosin, which colors the cell body, this will be distinctly visible under any circumstances. We shall stain most specimens which are to be mounted in balsam first with hæmatoxylin and then with eosin, and throughout this manual, when the direction is given to "stain a specimen double," this use of hæmatoxylin and eosin is to be understood.

The most convenient way of using Canada balsam is in solution in chloroform. The commercial balsam is thinned with chloroform until it drops readily from the end of a glass rod. The mode of procedure in Canada balsam mounting is the following: The specimen having been suitably prepared and stained, it is freed as completely as possible from water by touching its edges with a bit of filter paper, and then placed in a small wide-mouthed bottle containing a few cubic centimetres of *common strong alcohol*; after from ten to fifteen minutes it is

transferred to *absolute alcohol*, where it remains fifteen minutes. It is then taken out, the superfluous alcohol removed by filter paper, and laid in *oil of cloves*. As soon as it becomes transparent, when it usually sinks to the bottom of the dish, it is spread on a slide, the excess of oil removed, a drop of balsam put upon it, and covered by thin glass. This process, which seems at first somewhat complicated, is readily understood, if we remember that neither the water in which the specimen usually lies when the staining is completed, nor the alcohol, which, being hygroscopic, removes the water, are miscible with balsam; and further, that alcohol is miscible with oil of cloves, and oil of cloves with balsam. Care must be taken in these manipulations not to breathe on the specimen, nor to allow any moisture to come in contact with it, since even a small amount of moisture produces a precipitate in the balsam which greatly diminishes the clearness of the preparation. Canada balsam is, as a rule, best adapted for mounting those specimens in which we wish to study the general structure of a tissue rather than its more minute characters. Preparations in which the blood or lymph vessels are injected with some colored material, usually show best when mounted in balsam.

To make the double staining with hæmatoxylin and eosin, as mentioned above, we may first stain in the usual way with an aqueous solution of hæma-

toxylin, and then accomplish the eosin staining by adding a few drops of a saturated solution of eosin in absolute alcohol to the absolute alcohol used for the final dehydration of the specimen, before laying it in oil of cloves. We thus complete the dehydration and stain with eosin at one operation.

Acetic acid is sometimes used to render tissues transparent. This it does by causing the albuminoid materials and particles within them to swell and become actually more transparent, differing in this from glycerin and balsam. It produces, however, very considerable changes in the form and character of many tissue elements, so that although very valuable for special purposes, as will presently be seen, it is now much less frequently employed than formerly.

The chemical agents which the histologist uses, and the manipulative devices to which he has recourse in the study of the tissues, are very numerous, and we have considered here only a few of the more important and typical. The preparation of each tissue presents to the worker in histology a separate problem, and in few departments of science is careful attention to technical minutiae of more importance than in that which is now to engage us.

CHAPTER I.

THE CELL IN GENERAL.

IN all animal bodies are found certain tiny structural elements called *cells*. These are parts which at one time or another are alive ; and all the varied activities of the body are the result of the single or combined activities of the cells which are within it. It is very desirable, owing to their great significance, that before commencing the systematic study of the tissues we should acquire a definite conception of the nature of these elementary organisms. We may consider cells from a morphological and from a physiological standpoint, asking first, what is their structure ? and second, what do they do ?

First, then, what is the structure of cells ? We find in this a great diversity, some being extremely simple, others quite complex. The most common, and usually the most prominent structural feature of the cell, that portion which gives to it form and consistence, is called the *cell-body*. This usually consists of an albuminoid material, sometimes transparent and apparently structureless, sometimes finely or coarsely granular, and not infrequently present-

ing, at least after death, a reticulated appearance; this material is called *protoplasm* in its typical active form, and may be then very soft and viscid, like thin jelly, or it may become so modified as to be hard and even horny like the nail. The cell-body presents a great variety of forms; it may be spherical, cuboidal, cylindrical, fusiform, ovoid, pear-shaped, discoidal, or scale-like; it often sends off processes like branches or wings, and sometimes assumes the most irregular bizarre forms. We not infrequently find imbedded in the cell-body, pigment granules, droplets of fat, and various kinds of crystals. The form of the cell-body seems usually to depend largely upon the pressure to which it is or has been subjected by adjacent structures.

Within the cell-body and making up a part of the protoplasm, we usually find one or more spherical, ovoidal, or irregular-shaped bodies, called *nuclei* (singular, *nucleus*). The nucleus usually presents a sharply defined contour, is frequently coarsely granular, and sometimes a coarse or filiform network is seen suspended within or stretching from side to side. The nucleus may be very small in proportion to the size of the cell-body, or may make up nearly the entire bulk of the cell. In the processes of degeneration and decomposition, and under the action of certain chemical agents, the nucleus is more resistant than the cell-body, and on treatment of the cell with certain coloring agents, such as hæmatoxy-

lin, the nucleus is more deeply stained than the cell-body. Within the nucleus, again, we frequently find one or more small spherical or irregular-shaped bodies, looking like vesicles or shining granules, which are called *nucleoli*. They would seem, in some cases at least, to be connected with the above-mentioned intra-nuclear network. Of the exact nature and significance of the nucleus and nucleolus, we have at present little definite knowledge, but the nucleus, at least, seems to be a very important part of the cell.

Finally, a small proportion of animal cells are enclosed by an envelope—the *cell-membrane*, which may be thick or thin, now presenting well-defined structural peculiarities, and again quite homogeneous and structureless. In many cases the cell-membrane would seem to be simply a peripheral hardened layer of the cell-body.

It will thus be seen that we may have, in an animal cell, four distinct structural elements: the *body*, the *nucleus*, the *nucleolus*, and the *membrane*. It is only in a few varieties of cells, however, that all of these elements are present. The cell-membrane is the least commonly present of all, and there are certain cells which consist of a cell-body alone.

Regarding cells now from a physiological point of view, we find the expression of their vitality in four distinct ways: they nourish themselves; they grow; they perform certain functions for their own good and

for the benefit of the organism of which they form a part; and, finally, under certain circumstances, they are capable of reproducing their like. Or, in more concise language, we say the cell expresses its vitality in *nutrition, growth, function, and reproduction*. Not all of these expressions of vitality, however, can be subjected to direct microscopical observation. Nutrition, being as we believe, essentially a chemical process, cannot, with our present facilities, become to any considerable extent the object of direct microscopical study. The growth of cells, too, is for the most part so gradual, that we cannot directly follow it, but are obliged to study it in different phases of its progress.

The functional activity of cells can be indirectly subjected to microscopical investigation when it is associated with demonstrable changes in the morphological characters of the cell, or directly observed when it expresses itself in motion; thus, we can readily detect the difference between a condition of functional activity and rest in the peptic cells of the stomach, and the observation of ciliary and amœboid movements in certain cells is among the most fascinating of histological studies.

Finally, regarding the reproduction of cells, in a few instances the act has been directly observed under the microscope, but in the majority of cases our knowledge is derived from the study of a succession of consecutive stages in the process. Every

new cell which appears in the animal body, during and subsequently to its development, is derived from a pre-existing cell, and all the cells are derivatives of a single original cell, the ovum. New cells are produced by a process of division in older cells. Cell-division *seems* to occur in a variety of ways, usually commencing in the nucleus. Of the details of the process we have at present but little satisfactory classified knowledge, and although interesting and valuable facts are rapidly accumulating, we cannot tarry long upon the subject here.

In one of the apparently simplest modes of cell-division, one or more constrictions appear around the cell-body, after certain changes in the nucleus* have led to its partial or entire division; these constrictions grow deeper and deeper, until finally the parts separate and become individual cells, each furnished with a nucleus. This form of cell-division is called reproduction by *fission*. Or, the cell-body may send off from some part a bud-like process, which, becoming nucleated, is, by a constriction of its pedicle, at length set free as an independent cell; this is called cell-reproduction by *budding* or

* These preliminary changes in the nuclei of proliferating cells, which consist in a readjustment and perhaps new formation of fibres of the intra-nuclear network, and the development of bizarre and often symmetrical figures within the nucleus, are at present engaging the attention of many eminent histologists. The results of their researches, while now affording much, and promising far deeper, insight into the nature of cell-life, are not yet sufficiently classified, and are far too intricate to come within the scope of this manual.

gemmation. A mode of division, called *endogenous* cell-reproduction, is described, in which the division is said to occur entirely within the membrane of a cell, called the parent cell, so that the new organisms—the daughter cells—are not at once set free. This mode of cell-division is, however, doubtful, or at least extremely infrequent. These modes of cell-reproduction seem to be different, and yet there is much reason for believing that they are really only modifications of one process; but in the present condition of our knowledge on the subject, all general statements should be very cautiously made; and such classifications as the above are to be regarded merely as for convenience of study, and not as expressing any absolute and fully established truth.

Cells are variously classified according to their nature and relations to adjacent parts: thus we have *epithelial cells*, which cover the skin and mucous membranes, and occur in certain parts of the glandular organs; *connective-tissue cells*, which lie scattered throughout the substance of the structures, presently to be described as connective tissue, and in certain parts undergoing modification of form and relation to neighboring parts, and called *endothelial cells*; *gland cells* are those which, possessing peculiar functional or morphological characters, make up the parenchyma of certain glands and organs. The special characters of these classes of

cells, together with those of other classes not here mentioned, will be considered in our systematic study of the tissues.

PRACTICAL STUDY.

Many of the above-described general characters of cells may be seen by studying the epithelial cells of the bladder, the pigmented cells of the retina, and the living ciliated cells from the mucous membrane of the frog's mouth.

✓ *Epithelial Cells from the Rabbit's Bladder.*—A small piece, including the mucous membrane, is cut from the wall of the bladder of a recently-killed rabbit and immersed for 24 hours in a 5-per-cent. solution of neutral chromate of ammonium. It is then soaked for an hour in water to remove the chromate solution, and the now loosened cells are scraped from the surface of the mucous membrane and placed in a few cubic centimetres of the picro-carmin solution, where they remain until they have acquired a distinct red color. A small fragment of the cell mass is now transferred to a slide, covered with a drop of glycerin, teased apart with needles, and carefully covered with thin glass so as to exclude all bubbles of air. The cover-glass should be allowed to close down upon the specimen by its own weight alone, since much pressure upon these delicate cells distorts and breaks them. This, like nearly all specimens, should be examined first with a low and then with a high power. The cells will be found to have a great variety of forms, some of them evidently determined by the pressure of adjacent cells. They have

a finely granular body, with more coarsely granular nuclei, and nucleoli. In many cases, instead of appearing coarsely granular, the nucleus is seen to contain a distinct reticulum (*intra-nuclear net-work*) of strongly refractive material, the thickened nodal points of which may be regarded as nucleoli. To preserve this, and all specimens mounted in glycerin, a narrow rim of asphalt varnish is painted around the cover-glass, lapping over the edges of the latter and extending for a short distance on to the slide.

Pigmented Cells of the Retina.—An eye from the ox or sheep, which has lain for a few days in Müller's fluid, is opened by an equatorial section, and the vitreous body and the retina removed from the posterior half. If the remaining portion, including the sclera, choroid, and a portion of the pigmented epithelium of the retina, be put under water in a shallow dish, and brushed gently over the surface with a fine camel's-hair pencil, delicate pigmented flakes will float off in the water. These are the desired cells. One or two bits should be put into a drop of glycerin on a slide. Another bit is put on to another slide with a large drop of hæmatoxylin solution, and after about ten minutes the coloring fluid carefully washed off with water, and the stained fragments placed with the other in the glycerin on the other slide. They are now covered and examined.

These cells appear hexagonal* and are joined together

* These cells have really a very complicated structure, see page 241, but it is not necessary to study this in detail here, since they are only studied now for the purpose of demonstrating the occurrence of pigment in the bodies of certain cells.

edge to edge, giving a paved appearance to the fragments. Most of the cell bodies are closely crowded with elongated brown or black pigment granules. Sometimes such are seen as have but few granules within them, and occasionally they are entirely free. When the cell bodies are crowded with pigment the nucleus appear as a rounded, indefinitely outlined structure, containing no pigment and looking like a hole in the cell. When the pigment is present in small quantity or entirely absent, the nucleus is much less sharply outlined. In the cells which have been stained with hæmatoxylin, however, the nuclei all present well-defined outlines, and are stained of a violet color.

Ciliary Movement in Living Ciliated Cells from the Frog's Mouth.—The mucous membrane of the roof of the mouth of a living frog is gently scraped with a scalpel, and the slimy mass thus procured is transferred to a large drop of one-half-per-cent. salt solution on a slide, and thoroughly teased apart. The specimen is now covered, a bit of hair being placed beforehand beside it to prevent pressure from the cover-glass. The cells are mostly spheroidal, and will be seen isolated or in clusters the cilia, in the form of rows of delicate hair-like processes, springing from one side of the cells. A considerable number of non-ciliated cells will also be observed. The form of the cilia will be most readily seen in cells in which the movement is becoming languid, which occurs gradually in all, and finally ceases altogether. The movement, when vigorous, often causes cells and masses of cells to revolve and move about in the fluid, and frequently produces

currents in the latter, into which floating particles are drawn and then driven onward with considerable velocity.

If it be desired to preserve specimens of ciliated cells, a fragment of the palate of the frog, or, better, of the trachea of the rabbit—since the cells here are much more like those in the air-passages of man,—should be excised and treated in the manner above described for the preparation of the epithelial cells of the bladder.

CHAPTER II.

CONNECTIVE TISSUE.

OUR knowledge of the animal tissues is not yet extensive and exact enough to enable us to make a satisfactory classification of them, but for convenience of study we may regard the body as composed of simple tissues and of organs. As examples of the first we have connective tissue, muscular tissue, nerve-tissue, etc.; of the second, the liver, the lungs, the skin, mucous membranes, etc.

Among the simple tissues there is a large and important group, called *connective tissues*, the members of which, though presenting many marked differences, yet seem so closely allied, both in structure and life history, as to justify their grouping under the above common name. The members of this group of tissues may be tabulated as follows:*

1. Fibrillar connective tissue.

* In addition to these varieties, we find in certain parts of the body membranous layers or sheaths—sometimes structureless, sometimes having well-marked structural features—which differ in many respects from the above-mentioned varieties of connective tissue, but which cannot be separately described here. They will be briefly considered as we meet with them in our systematic study of the parts of the body in which they occur.

2. Embryonal and mucous tissue.
3. Fat tissue.
4. Reticular connective tissue.
5. Cartilage.
6. Bone and teeth.

Aside from many striking points of similarity in their structure, which we can better appreciate after having made a practical study of the group, three considerations may be briefly noticed here as of weight in determining this classification. At an early period of embryonic life, when the animal is composed almost exclusively of cells, it is found that one of the first definite arrangements or groupings of these cells consists in the formation of three distinct layers: an outer, a middle, and an inner layer. Now it is found that the cells in these different layers have an entirely distinct capacity in their power of producing the tissues which are found in the adult animal. From the cells in the outer layer are produced the skin with its adnexa, certain organs of sense, and the central nervous system; from the inner layer are formed the intestinal epithelium and glands, and certain of the large organs of the body; while from the middle layer are developed the muscles, the vascular systems, and, which especially concerns us here, the tissues tabulated above as members of the connective-tissue group. Besides the relationship given to them by this common origin, these tissues show their close

alliance by the fact that during the process of development one is sometimes formed from another. Finally, certain frequently observed pathological conditions seem to consist chiefly in the transformation of one of these forms of tissue into another of the same group.

With *fibrillar connective tissue* or *connective tissue proper*, or simply *connective tissue*, as it is often called, we commence our systematic study. This tissue is most widely distributed in the human body, occurring in the greatest diversity of forms, and an exact knowledge of its structure and arrangement is absolutely essential to a correct understanding of most other tissues and the organs, since it occurs in one form or another in nearly all of them. Fibrillar connective tissue, under the name of tendons and ligaments, forms bands and cords which bind the muscles to the bones, and bind the bones together. It is spread out in thin layers in the fasciæ and aponeuroses; it surrounds the bones and cartilage as periosteum and perichondrium. It divides and encloses muscular bundles and the nerves; it supports the blood and lymphatic vessels, and forms the limiting membrane of the serous cavities. It forms an encasing membrane for many organs, and, extending into their interior, serves, under the name of interstitial tissue, to support their parenchyma.

Fibrillar connective tissue is composed of two dis-

tinct classes of structures: *a. cells*, and *b. a substance* lying between the cells, the *intercellular* or *basement substance*. We shall consider the latter, first.

b.—INTERCELLULAR SUBSTANCE.

The intercellular substance consists chiefly of two distinct kinds of fibres: *fibrillated fibres* and *elastic fibres*.

The *fibrillated fibres* are tiny, grayish, translucent cords, which, sometimes singly, sometimes in straight or wavy bundles, lie nearly parallel to one another, and again cross each other at all conceivable angles, forming complicated net-works. When examined fresh, with high-magnifying powers, the individual fibres are seen to be moderately refractive; they have a delicate longitudinal striation—this striation being, as we shall presently see, the expression of the fact that each fibre is made up of a number of still finer fibrillæ.

On boiling for a considerable time in water they are converted into gelatin, and when treated with acetic acid or dilute alkalis, they swell up, lose their longitudinal striations, become very transparent, and finally almost invisible.

The second variety of fibres which occurs in connective tissue—the *elastic fibres*—are much more strongly refractive than the first, hence presenting more sharply-marked contours; they are not longitudinally striated, and often branch and form anas-

tomoses with one another, sometimes joining at frequent intervals to form a narrow-meshed net, and again stretching away for long distances to form a broadly-spaced reticulum. Sometimes the fibres are broad and band-like, sometimes extremely fine ; on being boiled in water they are not converted into gelatin, and they are unchanged by acetic acid and dilute alkalis. These fibres, as their name indicates, possess elasticity, and as a consequence of this property we often find, when the fibres have been severed by teasing or other modes of preparation, that the free ends curl over in the act of retraction, forming very characteristic curves or spirals. The elastic substance sometimes occurs in the form of granules instead of fibres, or as nearly homogeneous membranes.

The relative number of the fibrillar and elastic fibres in connective tissue varies greatly in different parts of the body ; in some we find but few elastic fibres, others contain little else. The interstices of the interlacing fibres—both fibrillated and elastic—are filled with the nutritive fluids of the body ; or in some cases, a small amount of a more consistent homogeneous material cements them together. The marked difference in general appearance which is seen in different parts composed of connective tissue, is largely due to differences in the arrangement of the fibres and bundles, and in the relative proportion of the fibrillated and elastic fibres.

a.—CELLS.

We consider next the cellular elements of fibrillar connective tissue. These are of two distinct classes. First, those which are essential components of it, preserving a fixed and definite relation to the basement substance, and which are quite constant in the different varieties of tissue, in form, size, and number; these are called *fixed connective-tissue cells*. Second, small spheroidal cells, the white blood-cells, which, escaping in varying number from the blood-vessels, move about through the interstices of the tissues, and are called *wandering cells*. These will be studied with the blood.

Among the fixed connective-tissue cells, by far the greater proportion are more or less flattened, presenting to the eye, when seen from the edge or in cross-section, the appearance of slender spindles. The cell-bodies are for the most part quite transparent, often very thin and scale-like, frequently so delicate as to be difficult of recognition, and sometimes the protoplasm in the vicinity of the nucleus is distinctly granular. These fixed connective-tissue cells present a great variety of forms, being round, ovoid, oblong, fusiform, or irregularly rectangular, often sending off branches which seem to be connected with the branches of neighboring cells. Sometimes the thin cell-body sends off one or more delicate wing-like processes at varying angles. These cells may have one or more nuclei;

they lie in the interstices of the fibres, which they often enwrap with their delicate bodies. The form which they assume in the different varieties of connective tissue would seem to be largely dependent upon the varying conditions of pressure to which they are subjected by the adjacent fibres. These flattened connective-tissue cells in many parts of the body may, and in certain parts constantly do, contain pigment granules.

In certain parts of the body the connective tissue presents free surfaces, lining more or less well-defined closed spaces or cavities, or free surfaces which are movable over one another, as in the great serous cavities, in the blood- and lymph-channels, tendon-sheaths, etc. In these cases the flat connective-tissue cells usually undergo some modification in their form, character, and relations to one another, and are called *endothelial cells* or *endothelium*.

Finally, in certain parts of the body, usually in the vicinity of blood-vessels, are found irregular-shaped granular cells, not usually flat, and of varying size and form, called *plasma cells*, which resemble in many respects cells found in the embryo.

PRACTICAL STUDY.

b.—INTERCELLULAR SUBSTANCE.

Fibres of Subcutaneous Connective Tissue.—To study these, the skin should be reflected back from the abdomi-

nal wall of a recently killed animal (mammal), and choosing a part which is free from fat, a bit of the loose, so-called *areolar tissue* is seized with the forceps and snipped off with scissors. The bit of tissue, which will contract to a little lump around the point of the forceps, is to be spread out very thin on a slide and covered with a $\frac{1}{2}$ -per-cent. salt solution. The specimen will be seen to consist largely of fibrillated fibres crossing one another in all directions, with a few delicate elastic fibres. After studying in salt solution, a drop of 2-per-cent. sol. of acetic acid should be allowed to run under one edge of the cover-glass, the salt solution being drawn off by a bit of filter paper placed at the opposite edge, and the effect carefully observed. This preparation is not to be preserved.

Fibrillæ in Tail Tendon of Mouse.—It is not easy in studying fresh tissues to convince one's self that the longitudinal striations on the fibres are really the expression of their fibrillar structure, since any attempt to pick the fibres apart with needles is of little avail, because the fibrillæ are bound together by a small amount of cement substance. If, however, the tissue be placed for a few hours in some fluid which dissolves this cement substance, as osmic acid, the ultimate elements, the fibrillæ, may be readily separated. A bit of the tail tendon of a mouse, or a small tendon from any mammal, should be soaked for a few days in a 1-per-cent. sol. of osmic acid, washed and teased apart on a slide and mounted in glycerin.

Elastic Fibres from the Ligamentum Nuchæ.—A small fragment of this structure—conveniently obtained from the ox—is preserved in strong alcohol. A tiny bit is

teased thoroughly and mounted in glycerin. It will be seen to consist of a dense net-work of broad, closely-anastomosing elastic fibres which curl over at the free ends.

a.—CELLS.

Cells in the Subcutaneous Connective Tissue.—The fixed connective-tissue cells, which occur in this form of tissue, may be studied in any mammal. They vary somewhat in size, shape, and number in different animals, but those in the rabbit are sufficiently typical. In the study of these cells, whose bodies are, for the most part, so thin and transparent as to be almost invisible when fresh, and very liable to shrink and become distorted by contact with the usual hardening agents, we have to fulfil two important indications in our technical procedure; we must treat the tissue with some agent which will render the cells visible, and, at the same time, not greatly alter the form of the delicate cell-body.

These ends are best attained by the method suggested by Dr. W. H. Welch. The skin being reflected back from the abdominal wall of a freshly-killed rabbit, with a hypodermic syringe, inject beneath the loose adherent tissue a few cubic centimetres of a solution of aniline red (Fuchsine), prepared by adding one part of saturated alcoholic sol. of the powder to forty parts of water. After the red fluid has remained for two or three hours in contact with the tissues, a small fragment is snipped off from the colored œdematous portion, spread very thin on a slide, covered with the same fluid, and enclosed at once with

asphalt varnish. The cells in this tissue are, for the most part, extremely thin, and of various, often quite irregular forms, sometimes sending off narrow branching processes, by which they join neighboring cells, and sometimes furnished with wing-like projections. In addition to these cells, and the intercellular fibres, nerves and capillary blood-vessels are sometimes seen in the specimens, and, occasionally, in the vicinity of the vessels are found the above-mentioned plasma cells. The cells prepared by this method preserve their form for a considerable time, but finally shrink, and lose their color.

Pigmented Connective-tissue Cells of the Choroid.—These may be taken from the eye of any mammal (except albinos) which has been hardened in Müller's fluid and alcohol. A shred of the outer layers of the choroid should be torn off, stained with hæmatoxylin, and mounted in glycerin. Irregular-shaped, often branched and flattened cells are seen lying embedded in a membranous nucleated basement substance, containing delicate elastic fibrils, the cells being more or less crowded, except in the part occupied by the nucleus, with a multitude of minute brown or black granules.

Cells in Teased Tendon.—Tendons are composed essentially of parallel bundles of fibrillated connective-tissue fibres, with thin irregular-shaped cells between them. The complicated forms which tendon cells present can be most easily understood when they are studied in their natural relation to the fibres.

Owing to their extreme tenuity, and the consequent possibility of studying them with but little manipulation,

the tail tendons of the mouse or rat are well suited for this purpose. If the skin of the tail of a recently-killed mouse or rat be torn across transversely, by slight twisting, or pressure with the edge of the nail, and gentle traction be exerted at both sides of the rupture, the caudal vertebræ will readily separate, and, as the traction continues, a multitude of extremely fine tendon-bundles will be seen stretching across the break. When the tendons, by this natural and simple dissection, have been freed for one or two centimetres of their length, they are laid, still under slight tension, on a bit of glass, of suitable size, the ends cemented to the glass with a bit of soft wax or paraffin, and the remainder of the tail cut off. The fastening of the ends is to prevent the tendon from shrinking when immersed in the preservative fluid. The bit of glass, with its tendon-bundles, is now immersed for twenty-four hours in a one-per-cent. solution of osmic acid, then washed in water.

One or two of the tiny bundles is now to be partially teased apart, lightly stained with hæmatoxylin, and then with picro-carminé; then still further very finely teased on a slide, and mounted in glycerin. The individual fibrillated fibres will now be readily seen, and arranged in rows along them, edge to edge, with more or less irregular contours, the flattened tendon cells will be seen to lie. Their nuclei, stained violet by the hæmatoxylin, when seen from the side appear oval or rectangular, and are often arranged in couples along the fibres; when seen edgewise they look like short, thick lines. The cell-bodies, when seen sidewise, look like faintly-colored, often indefinitely-outlined, very thin plates, stretching

out from the nuclei, and partially enwrapping the tendon-fibres. When the cell-body is placed with its edge toward the observer and in close apposition with the fibre, it is not to be distinguished, owing to its extreme thinness, from the line which marks the border of the fibre; if, however, it has been separated, in part or entirely, from the fibre by the previous manipulations, it will appear as a faint line, at some part of which is seen the elongated nucleus. Examining the specimen still further, one sees in the side view of the cells, sometimes along a single cell, sometimes along a row of them, one or more fine lines or striæ, and on looking carefully at the cells placed edgewise, he can convince himself that thin, narrow wings are given off from the cell-body, and that it is the edges of these wings which cause the striæ in the cells seen on the flat. In teased specimens of tendon one occasionally finds irregular-shaped branching cells.

We have then in tendon parallel bundles of fibrillated fibres, arranged along and in the interstices between which lie flattened cells whose thin bodies partially enwrap certain fibres, and send off between other and neighboring fibres branches and thin narrow wings. The interstices between the bundles, in which the tendon-cells lie, are lymph-channels.

Cells in Transverse Sections of Tendon.—A very clear view of the relations between the cells and fibres of tendon, as well as the relation of the wings to the cell-bodies, may be obtained by making a transverse section of a hardened and stained tendon. Any small tendon from a recently killed animal will answer the purpose. It should be freed from surrounding tissues, and imme-

diately immersed in a small quantity of a half per cent. solution of gold chloride. Here it remains for half an hour, when it is removed, washed with pure water, and put into a few cubic centimetre of the following mixture, known as the *reducing fluid* :

Amyl Alcohol,	I
Formic Acid,	I
Water,	100

After remaining for twenty-four hours in the reducing fluid, the specimen will probably have assumed a rich violet color ; if not, it should be kept for twenty-four hours longer in a fresh portion of the fluid. When the requisite color has been obtained, the specimen is hardened for a day in alcohol, embedded in hardened liver or wax, and thin cross-sections made from it. The sections are now stained lightly with hæmatoxylin, and mounted in glycerin. They should be kept as much as possible from the light, which, after a time, destroys gold preparations. This method of staining with gold is known as *Pritchard's method*.*

* The older method of gold staining, known as *Conheim's method*, differs from that just given, in that, after soaking in the gold solution, the specimen is exposed to the light until it has assumed the violet color. It is then mounted and preserved as before. This method is less certain in its results than Pritchard's, being less apt to give clear pictures. In both methods the staining action consists in the precipitation of the gold in metallic form in a state of extreme comminution in the tissue. In one case this precipitation is effected by the acid mixture, in the other by the light. This deposition of gold in the tissues occurs, for the most part, in the protoplasm of the cells, bringing them into sharp contrast with surrounding parts, and fixing their form. There is one source of error, however, in the interpretation of gold specimens, which should never be forgotten. The gold is apparently sometimes deposited, and the characteristic

Transverse Sections of the Cornea.—Cells seen from the edge.—We shall employ for our study here the cornea of the frog, because of the ease with which it can be obtained, and, because, on account of its thinness, it is well suited to the various manipulations to which we shall subject it. A frog's eye should be enucleated directly after death, and placed entire in Müller's fluid, where it should remain for ten days. It is then washed, and put, for a few hours, into dilute alcohol (alcohol one, water two), then transferred to, and left, for forty-eight hours, in strong alcohol. The cornea is now excised, just within the sclero-corneal junction, and, two or three short radial incisions having been made at the edge, so that it will lie flat, it is embedded between two bits of hardened liver,* and thin transverse sections cut from it. These are stained double, and mounted in glycerin, slightly tinged red with eosin.

If the sections are made so as to include the entire thickness of the cornea, both the anterior and posterior edges of the section will be seen to be covered with epithelial cells. Between these two layers of cells lies the connective tissue substance of the cornea, which alone concerns us here. This consists of delicate fibrillated fibres, closely bound together by a small amount of cementing substance, and arranged in lamellæ. Between these lamellæ are seen the corneal cells, which, in this

color produced, *outside of the cell protoplasm*, and especially in spaces in the tissues which are filled with albuminoid materials, so that the utmost caution is required in determining whether a given area of gold deposit and staining really indicates the presence of cell protoplasm. And, in fact, it is in some cases impossible, at present, to decide this question.

* Better in celloidin. See Appendix, p. 252.

view, seem to have the form of slender elongated spindles, part of them being closely surrounded by the inter-cellular substance, part lying in small elongated cavities.

✓ *Laminæ of Cornea.—the Cells seen on the Flat.*—In order to determine the exact shape of the cells, which in the former preparation are seen only from the edge, it is necessary to look at the cornea from the side. For this purpose a fresh cornea should be very carefully excised, all pulling or stretching of the part being avoided, since this distorts the cells. It is now stained with gold chloride by Pritchard's method, and then laid on a slide in glycerin. The epithelium on both the anterior and posterior surfaces is now scraped off, and with a little care the part may be divided into several thin layers by means of fine forceps. These layers are lightly stained with hæmatoxylin and mounted in glycerin.

In a specimen thus prepared, the basement substance looks homogeneous or delicately striated; fine nerve-fibres are seen stretching across the specimen in various directions. The corneal cells, which are the most prominent objects in the specimen, are seen thickly scattered over the field, stained of a reddish violet color. They have flat, irregular-shaped bodies which send off a variable number of longer and shorter processes; the nuclei are large, ovoidal, or irregular-shaped, and usually contain nucleoli. Fine irregular-branching, almost linear structures are seen in good preparations thickly scattered over the specimen, and very frequently lying nearly at right angles to one another. A part at least of these are continuous with the cell-bodies whose processes they are;

whether or not they are all cell processes is not yet definitely known.

It will be seen from the above studies, that the connective-tissue cells of the cornea are flattened and branched cells, and that certain of them, at least, lie in spaces between the fibres of the intercellular substance. We have now to study more carefully the nature of these spaces and their relation to the cells.

Cornea treated with Silver.—*Relation of the Cells to the Basement Substance.*—Strong solutions of nitrate of silver have the power of staining the intercellular substance of connective tissue light brown, while the cells are left uncolored. In order to stain the cornea of the frog with silver, the following process should be employed: the spinal cord of the animal having been broken up with a needle, a finger is introduced into the mouth so as to press the eyeball forward and bring the cornea into prominence; the membrana nictitans is drawn away with the thumb or a pair of fine forceps, so as to leave the anterior surface of the cornea quite free. The eye is now held for an instant over a jet of steam, when the epithelium will become white or milky in appearance, and can be readily scraped off by passing the blade of a scalpel lightly over the surface. It is necessary to remove the epithelium in order that the silver solution may have ready access to the connective-tissue substance of the cornea; and the advantage of steaming is, that it can be scraped off without the use of much force, which would disturb the relations of the parts beneath. The epithelium being thus removed, a five-per-cent. solution of silver nitrate is allowed to flow over the cornea and re-

main for two or three minutes in contact with it. By this treatment the whole cornea becomes opaque and stiff. The silver is now neutralized and its further action prevented, by washing the cornea with a one-per-cent. salt solution. It is now carefully excised and placed in a dish containing a mixture of alcohol and water, one to two, and exposed to direct sunlight, or bright daylight, for from a few minutes to half an hour, depending upon the intensity of the light. When it has become brown it is to be laid in glycerin and stripped into thin layers, as directed above, for the gold cornea; the layers are mounted in glycerin.

If the preparation is successful, clear, branching, communicating spaces are seen on a yellowish or brown ground. These spaces, although larger, evidently correspond in position and in a general way, in shape, to the cells in the cornea, as seen after treatment with chloride of gold; and if a specimen thus prepared be stained with hæmatoxylin, the corneal cells will be seen lying within them.

It is difficult to determine with certainty whether or not the cells send processes into all of the channels which radiate from the spaces in which they lie; it is probable that some of the narrow branching bodies or lines noticed above in the gold cornea are nothing more than these branching and communicating spaces in which an albuminous fluid accumulates, which is stained by the gold very much as cell protoplasm itself is.

We thus see that the cornea is permeated by numerous branching and intercommunicating spaces, and that in these spaces the flat, branching connective-tissue cells lie.

These spaces are called *lymph-spaces*, and what we have been able to demonstrate in regard to the relation of cells to the lymph-spaces in the cornea, by these various modes of preparation, seems to be true, with certain modifications, of the cells in most of the varieties of connective tissue. These cells lie in spaces, sometimes completely, sometimes only partially filling them. These spaces communicate with one another, and communicate also, on the one hand, with the blood-vessels, and, on the other, with the lymphatics. Through them lymph-currents pass, bathing the cells and supplying them with nutritive material.

It is extremely probable that it is through these lymph spaces exclusively that the white blood-cells travel, in their perigrinations through the tissues. We study them in the cornea alone, because the scope of this manual is too limited to admit of such a detailed study of all varieties of connective tissue, and because here the relation of the cells to the spaces is clearly defined.

Endothelium of the Serous Membranes.—The serous membranes are formed by layers of fibrillar connective tissue fibres mingled with a varying number of elastic fibres, and containing ordinary flattened connective-tissue cells. They are more or less abundantly furnished with blood and lymphatic vessels. On the free surface of these membranes rests a continuous layer of flattened cells, differing in many respects from the ordinary connective-tissue cells, and called *endothelial cells* or *endothelium*. These cells are usually transparent, irregularly polygonal in form, and frequently much elongated; they possess one or more ovoidal nuclei, which often project

above the general level of the free surface of the cell-body ; they are placed edge to edge, like the stones in a mosaic, and seem to be joined together by a minimal amount of an albuminoid cement substance.*

✓ *Endothelium covering the Mesentery.*—In order to bring the outlines of the cells clearly into view, the membrane should be first treated with a solution of nitrate of silver. This substance in dilute solutions forms with the cement substance between the endothelium an albuminate of silver, which, on exposure to light, becomes brown or black, thus clearly defining the outline of the cells.

The mode of proceeding is as follows : A portion of the mesentery of the recently killed dog or rabbit should be carefully removed and laid over the rim of a shallow dish so that it rests loosely over the opening. All stretching and pulling of the membrane should be avoided, because this would destroy the natural relations of the cells to one another. The membrane must be allowed to sag a little into the dish, so that it may be bathed on both sides by the silver solution. It is now to be carefully washed with water to remove any albuminous substance or blood—which would cause a granular precipitate of silver albuminate on the surface—and the dish then filled with an aqueous solution of nitrate of silver, 1 to 500. The dish should be gently shaken at frequent intervals, so as to bring fresh portions of the solution into contact with the membrane, and after from twenty minutes

* There is reason for believing that the cement substance between the endothelium, as well as between many kinds of epithelial cells is permeable to fluids, and, under certain conditions, to solid particles also, and thus forms an avenue of communication between adjacent but separated cavities or lymph spaces.

to half an hour the tissue will be seen to have become cloudy or milky.

The silver is now poured off, and the membrane carefully washed with water. The cells will have been fixed by the silver, so that the membrane may be removed without further danger of disturbing the relation of the cells, and laid in a dish containing water to which one-third its bulk of alcohol has been added. It is now exposed to the sunlight, and after from a few minutes to half an hour—sometimes longer, depending upon the intensity of the light—the tissue will be seen to have assumed a brown color.

A small piece from the thinner portion should now be lightly stained with hæmatoxylin and mounted in glycerin.

These portions of the mesentery consist of a thin membrane of fibrillar connective tissue containing a delicate network of elastic fibres and a few small blood-vessels; the whole being covered on both sides by the delicate mosaic of endothelial cells. The outlines of these cells on both sides, may be brought successively into view by careful focussing.

↓ *Endothelium of the Omentum.*—A portion of the omentum of the dog should be treated with silver in the way just directed for the mesentery, and also stained with hæmatoxylin and mounted in glycerin. The omentum of the dog, as of man, consists of an irregular meshed net, whose trabeculæ are made up of fascicles of fibrillar connective tissue of varying thickness, the broader containing blood- and lymph-vessels and fat-cells, the narrower consisting of single bundles of fibrillæ—all being

alike covered with a single layer of endothelium. In many parts the endothelial cells are seen in profile, when their nuclei appear lenticular in form, usually projecting above the general level of the cell-body, which is itself in most cases thicker in the vicinity of the nucleus than at the points of junction with adjoining cells. The specimens of both omentum and mesentery may be preserved in the usual way ; but silver preparations, like the gold, do not preserve their first clearness very long, unless carefully kept from the light.

CHAPTER III.

EMBRYONAL AND MUCOUS TISSUE.—FAT TISSUE.— RETICULAR CONNECTIVE TISSUE.

EMBRYONAL AND MUCOUS TISSUE.

AT a certain period of embryonic life, those parts of the body which are destined finally to become fibrillar connective tissue, consist almost entirely of small spheroidal cells—the intercellular substance being absent, or consisting only of a very small quantity of fluid lying between and bathing the cells. As the process of development goes on, some of the cells retain their original spheroidal form, while others change their character, becoming elongated and fusiform, often terminating at their extremities in delicate single or branching processes; others become flattened and assume irregular shapes, sending off branching processes by which they are joined to one another. Hand in hand with this change in the cells there occurs an accumulation of intercellular material, which is at first fluid, and later presents the appearance of a homogeneous gelatinoid substance. Then within the gelatinoid intercellular substance appear fine fibrillæ, which become more and more abundant, arranging themselves now in bundles, and again to form irregu-

lar networks. The cells approach more and more closely to the type of the adult connective-tissue cells, as development goes on ; the intercellular substance loses its soft gelatinoid character, and is finally replaced by the fibrillated and elastic fibres with which we are already familiar.

The process of development is a very gradual one, and although the younger forms of embryonal connective tissue and the adult connective tissue are distinct enough, we are yet unable to separate them sharply, since they merge so gradually into one another. In general, however, simply as a matter of convenience, we call connective tissue which is almost entirely made up of spheroidal, spindle-shaped, or flattened cells, in which little accumulation and little differentiation of the intercellular substance has occurred, *embryonal tissue*; while to that older form, which consists of variously shaped, spheroidal, flat, branching and anastomosing cells, with a gelatinoid, homogeneous, or partially fibrillated intercellular substance, the term *mucous tissue* is usually applied. The name mucous tissue was given to this form of young tissue, because the soft gelatinoid intercellular substance was found to contain a certain amount of *mucin*, which may be thrown down in the form of a whitish, often stringy precipitate, by the addition of acetic acid. At present, however, tissues presenting the above mentioned morphological characters are usually

called mucous tissues, whether the intercellular substance contains mucin or not. Mucous tissue is not found in the healthy human adult, but frequently occurs under pathological conditions.

PRACTICAL STUDY.

Subcutaneous Tissue of Embryo.—Embryonal connective tissue may be studied in any young mammalian embryo, preserved in Müller's fluid and alcohol. Bits of the subcutaneous tissue are torn off from the abdominal wall, stained double, finely teased, and mounted in glycerin.

Mucous Tissue from the Umbilical Cord.—In the umbilical cord of a nearly mature foetus we find typical mucous tissue. A bit of the cord of any mammalian foetus, as the pig, is hardened in Müller's fluid and alcohol, then embedded in liver and transverse sections made. These are stained double and mounted in glycerin or balsam. The surface of the cord is seen to be covered with laminated epithelium, and the three large blood-vessels are seen to be cut across. The amount of fibrillation present in the intercellular substance depends upon the age of the foetus.

FAT TISSUE.

Fat-tissue is a modified form of connective tissue, in which the intercellular substance is present in proportionally small amount, and a large part of the protoplasm of the cells is replaced by fat, which crowds the remaining part, together with the nucleus, to the side of the cell, nearly or entirely con-

cealing both. The fat-cells thus formed are arranged in clusters or lobules, enclosed by fibrillar connective tissue, which sends into the lobules and between the cells broader and narrower bundles, which serve to support the cells and carry the blood and lymphatic vessels, etc. Owing to the pressure to which the fat-cells are subjected, they usually assume, in the adult animal, a polyhedral form.

Sometimes the fat appears within the cell in the form of clusters of radiating needle-like crystals.

In order to understand clearly the nature of adult fat-tissue, it is necessary to study it during the process of development. At an early period of life, those parts of the body which are finally to become fat-tissue, possess the character of mucous tissue with a more or less fibrillated intercellular substance. The first change which we notice in the cells as the transformation into fat-tissue commences, is the appearance in the cell-body of small shining particles. These particles, of which there may be many, become gradually larger, until they present the form and character of distinct droplets of fat. As these droplets increase in size, they coalesce, forming one or more drops, which presently become large enough to crowd the nucleus to one side. The growing drops finally unite into one large drop, which at length becomes so large as to occupy nearly the whole of the cell, leaving only a thin crescent of protoplasm and a squeezed and distorted nucleus

crowded up against the cell-membrane. At last we can no longer see, without special modes of preparation, any trace of cell protoplasm—although a small amount of this really persists as a thin shell within the membrane—and only the deformed remnant of the nucleus. This process is called *fatty infiltration*.

In those parts of the body where the fat is invariably found, this change in the cells occurs in the vicinity of little tufts of capillary blood-vessels, so that at one period, the forming fat is seen lying in scattered clusters in the meshes of distinct groups of blood-capillaries. It is these clusters of fat-cells, with their accompanying blood-vessels, which determine, when the fat is fully formed, the lobular character of this tissue.

In many parts of the body and under varying conditions—sometimes physiological, sometimes pathological—there is an accumulation of fat in the protoplasm of cells; but it is, under normal conditions for the most part, temporary, and the fat-cells have no definite grouping in lobules and about the blood-vessels in the way above described for the permanent fat.

PRACTICAL STUDY.

Fresh Fat, teased.—A bit of fresh subcutaneous fat should be teased and covered in salt solution, without staining. In such a specimen little else is seen than a

congeries of more or less globular or polyhedral masses of fat-cells, with larger and smaller free fat droplets. The fat is characterized by its great refractive power ; by the dark contour of its globules by transmitted, and their yellowish silvery lustre by reflected, light ; by its solubility in alcohol and ether, and by the deep black color which it acquires on treatment with osmic acid. The connective tissue which encloses the lobules is seen in broken masses and shreds, scattered through the preparation.

Section of Adult Fat Tissue.—A small piece of subcutaneous fat from man should be hardened in alcohol, by which the fat will be for the most part dissolved out of the cells. Thin sections are made, stained double, and mounted in balsam. This preparation shows the relation of the cells to one another, and the lobular structure of the tissue. If the blood-vessels of the part from which the tissue is taken have been previously injected with the blue gelatin mixture, the relations of the vessels to the lobules and cells will be well shown.

Developing Fat from Young Animals.—To study this in its early stages, some of the fresh mucous tissue from the axilla or groin of a foetal animal, such as a pig, 5 inches long, should be immersed for 24 hours in 1-per-cent. osmic acid ; then washed and teased, and mounted in glycerin slightly tinged with eosin. The larger and smaller fat droplets within the cells will be black, and numerous cells will be seen in which the fatty infiltration has not commenced.

To study the fat cells at a later period of development, thin sections may be made from the subcutaneous fat of the human foetus, at from 6 to 8 months, or from any

mammal of corresponding age. These are stained double and mounted in balsam. At this period, while the fat droplet in many parts occupies the greater part of the cell, a distinct crescentic mass of protoplasm is still seen at one side, enclosing the nucleus.

RETICULAR CONNECTIVE TISSUE.

This tissue forms a large part of the supporting framework of the lymphatic glands, and is found, in somewhat modified form, in other parts of the body. It consists of delicate fibres, of varying diameter, which cross and join one another at frequent intervals, forming a fine meshed network. This network of fibres is not flattened to form a membrane, but extends in all directions, like the trabeculæ of a sponge. Irregularly scattered over the fibres are flattened nucleated cells, having the character of endothelium, which sometimes lie at the points of intersection of the fibres, sometimes along their sides, enwrapping them with their transparent bodies. When these cells are *in situ* upon the fibres, the whole presents the appearance of a mass of anastomosing, branched, or spindle-shaped cells; and, as such, the reticular connective tissue has until recently been regarded,—erroneously, however, as is shown by the fact that by appropriate manipulation the flat cells can be entirely freed from the underlying fibre-net, leaving the latter intact. The meshes of the reticular tissue are loosely filled, in the lym-

phatic glands, with small spheroidal cells—lymph cells—which, however, seem to have no direct connection with the tissue we are studying, and may be easily removed.

PRACTICAL STUDY.

Section of the Lymphatic Gland of Dog, Treated with Osmic Acid.—One of the mesenteric or cervical glands is removed from a recently-killed dog, and a hypodermic syringe being partially filled with 1-per-cent. solution of osmic acid, the canula is thrust well into the gland, and the acid slowly injected until the organ becomes quite tense; the canula is then withdrawn, and the gland placed in strong alcohol. After a few days it will be hard enough to make sections from.* The sections, which must be very thin, should be carefully shaken in a test-tube, one-third filled with water, to remove the lymph cells which lie in the meshes of the reticular tissue and conceal it. As these cells are shaken out, the sections look thinner, and when the operation is completed they are stained with hæmatoxylin and mounted in glycerin.

* It should be embedded in celloidin.

CHAPTER IV.

CARTILAGE—BONE—TEETH.

CARTILAGE.

CARTILAGE consists, like other members of the connective-tissue group, of cells and intercellular substance. There is nothing characteristic, however, in the form of the cartilage-cells. It is in the peculiar nature of the intercellular substance and the relations which the cells bear to it, that we find the distinctive features of this form of connective tissue. The cartilage-cells are spheroidal, flattened, or angular in form; the cell-body is finely granular and often contains tiny droplets of fat, and sometimes pigment-granules. The cells have one, or sometimes two, sharply defined nuclei, which are coarsely granular and often contain an irregular network of a more strongly refractive substance. Around each cartilage-cell, in the adult animal, and closely enclosing it, is a homogeneous envelope called the *capsule*. The substance forming this capsule is identical with the intercellular substance of hyaline cartilage, presently to be described.

The cartilage-cells very readily lose their normal form and relation to the capsule by the application

of a great variety of substances, and even by slight exposure to the air. The most common change which is noticed in them is a rapid shrinkage, such as occurs when cartilage is exposed to the air or treated with strong salt solutions, or any substance which extracts water from the tissues. Under these circumstances the cell becomes more coarsely granular, it shrinks away from the capsule at certain points, giving the edge of the cell a festooned appearance; sometimes large, clear spheroidal spaces, called vacuoles, appear in the cell-body, and finally the cell shrinks to a shapeless mass in the centre or at one side of the cavity, or retains its connection with the capsule by one or more narrow irregular projections from the shrunken mass.

The basement or intercellular substance is not the same in all cartilages, and, according to the differences in its nature, cartilage is divided into *hyaline cartilage*, *fibro-cartilage*, *fibro-elastic cartilage*.

In hyaline cartilage the intercellular substance is homogeneous and transparent in thin layers, somewhat opalescent in thicker masses; it is of firm consistence, and contains at tolerably regular intervals variously shaped cavities in which the cells lie, exactly filling them. The layer of basement substance which immediately surrounds the cells possesses slightly different refractive power, and it is this layer which constitutes the capsule above mentioned.

The cell-spaces or cavities in hyaline cartilage do not by the ordinary modes of preparation appear to be connected by lymph-channels, as are the cell-spaces in other varieties of connective tissue, yet the rapid passage of fluids through the tissue under certain circumstances, together with some recent microscopical observations, renders it extremely probable that such communications do exist, though we are not at present able to demonstrate them with certainty. Although by the ordinary modes of preparation the basement substance of hyaline cartilage appears quite homogeneous, certain changes which it undergoes under pathological conditions, or by the use of certain macerating or digesting fluids, lead us to believe that it really contains a groundwork of delicate fibrillæ.

The basement substance of hyaline cartilage differs chemically from the basement substance of other members of the connective-tissue group, yet recent researches have thrown serious doubt upon the view formerly held, *i. e.*, that cartilage gave, on boiling, a peculiar and characteristic substance called *chondrin*, it having been shown that the so-called chondrin is not a pure chemical substance, but a mixture of gelatin, mucin, and certain salts.

Hyaline cartilage is found, in the adult, covering the ends of the bones in the joints; and most of the laryngeal and the tracheal, bronchial, costal and nasal cartilages are of this variety.

Fibro-cartilage differs from hyaline cartilage in having a distinctly fibrillated intercellular substance. This form of cartilage is found in the intervertebral cartilages, in the meniscuses of certain joints, and at certain points where the ligaments are inserted into the cartilaginous extremities of bones.

In certain other cartilages—such as the epiglottis, some of the small cartilages of the larynx, and the cartilage of the pinna of the ear—the intercellular substance contains, in addition to a few fibrillated fibres, elastic tissue, either in the form of fibres or in fine granules. Such cartilage is called *fibro-elastic cartilage*. In both fibro- and fibro-elastic cartilage the cells are identical in character with those of hyaline cartilage.

Except at the free surfaces, which it presents in the joints, cartilage is surrounded by a layer of fibrillated connective tissue of varying thickness, called the *perichondrium*, in which are found the blood-vessels which supply nutritive material to the non-vascular cartilage within. At the surface of many cartilaginous masses the cells are very much crowded together, and flattened in a plane parallel to the surface.

PRACTICAL STUDY.

Hyaline Cartilage from Femur of Frog.—The head of a femur of a recently killed animal being exposed, a thin slice of cartilage is shaved off with a razor so as to leave

a flat surface from which a thin section should be cut, and immersed in a drop of saturated solution of picric acid on a slide, and covered and surrounded at once by a rim of asphalt varnish, before the acid solution commences to evaporate.

In such thin sections, cavities are seen here and there from which the cells have fallen out ; these may be filled with the preservative fluid, or with bubbles of air. Picric acid is one of the best agents for preserving the normal characters of cartilage cells, but even in this they shrink somewhat, and after a time become coarsely granular.

Shrinkage of Cartilage Cells by Strong Salt Solution.— Since in most of the specimens containing cartilage, which we shall study later, the cells will have been considerably shrunken by the preservative fluids, it is desirable for us to acquaint ourselves here with the process of shrinkage, so that we may understand the various distorted forms which such cells present. To do this, we have simply to prepare a thin section of hyaline cartilage, as above, and mount it at once in half-per-cent. salt solution. When a good field for observation has been selected, a drop of ten-per-cent. salt solution (alcohol will do as well) is run in at one edge of the cover glass, the agent being drawn through by filter paper at the other. In this way the process of shrinkage and formation of vacuoles may be readily observed.

✓ *Fibro-cartilage* may be studied in thin sections from the intervertebral cartilages of man or any of the domestic animals ; or from the head of the femur, through the insertion of the ligamentum teres, parallel with the course of its fibres. The tissues should be laid for a few days in

alcohol before cutting. The sections are stained with picro-carmin, and mounted in glycerin.

Fibro-elastic Cartilage.—This is best studied in the epiglottis of man or the lower animals, which has been preserved in alcohol. Thin sections are stained with picro-carmin, which colors the cells red, and the elastic granules and fibres yellow. They are mounted and preserved in glycerin. The cells in both fibro- and fibro-elastic cartilage are, by the above modes of preparation, more or less shrunken and deformed.

BONE.

In studying bone we have to consider: 1, the hard substance, or *bone-tissue proper*; 2, the connective tissue envelope which surrounds the bone—the *periosteum*; and, 3, the *marrow* contained in the central cavities or spaces within.

1. The most striking feature of bone-tissue proper is its firmness and hardness, which is due to the presence of certain inorganic salts of lime. Various acids dissolve these lime salts, and when they are removed a substance is left behind which retains, for the most part, both in general form and minute structure, all the essential features of the original bone. There is a basement substance, presenting many of the optical characters of hyaline cartilage; and lying in tiny, branching spaces, in the basement substance, are flat, nucleated cells. The lime salts are deposited in the intercellular substance in such

an extremely minute state of division as to be invisible, even with high powers of the microscope. The elongated and flattened cell-spaces of bone are frequently called *lacunæ*, and the numerous fine, branching, intercommunicating channels which pass off from them in all directions, and open into the marrow cavities, or into the passages for the blood-vessels, are called *canaliculi*.

The *bone-cells*, or bone-corporcules, as they were formerly called, are, in adults, thin, flat cells, with spheroidal or oval projecting nuclei. It was formerly believed that they sent fine branching processes off into the ramifications of the canaliculi. Recent investigations, however, have thrown great doubt upon the existence of at least such numerous processes as were formerly believed to exist—it having been shown that some, at least, if not all, of the supposed processes are really portions of the intercellular substance lining the *lacunæ* and *canaliculi*. In young bone the cells are not flat, but spherical or ovoidal.

We distinguish two kinds of bone-tissue, *spongy* and *compact*.

In *spongy bone-tissue*, which is found in abundance in the epiphyses of the long bones, the hard substance, or bone proper, is arranged in the form of thin plates, which are grouped together so as to enclose tiny, irregular-shaped cavities, filled with marrow-tissue. In these thin plates of spongy

bone the cells lie irregularly scattered through the intercellular substance, which is homogeneous.

In *compact bone*, such as is found in the diaphyses of the long bones, the intercellular substance is arranged in layers, or lamellæ, in and between which lie the cells. The lamellar arrangement is best seen in transverse sections from the diaphyses of the long bones. If we look at a thin cross-section of such a bone with a low magnifying power, we notice numerous round or ovoid, or irregular-shaped openings, of varying size, and around these are grouped several thin concentric layers of basement substance, in and between which lie the cells, flattened in the plane of the lamellæ.

These sets of concentric lamellæ are called *special* or *Haversian systems of lamellæ*. Sometimes these Haversian systems of lamellæ lie closely crowded together, and again they lie at varying distances from one another. In the latter case the intervening space is filled up by other and irregular sets of lamellæ which do not correspond with the Haversian lamellæ, but pass off obliquely in various directions. These are called, from their position relative to the Haversian system, *intermediate lamellæ*. Finally, at the surface of the bone beneath the periosteum, and sometimes at the inner surface adjacent to the medullary cavity, are seen a series of lamellæ which lie parallel to the surfaces of the bone, and are called *general* or *circumferential lamellæ*. If we make a

longitudinal section of a long bone, we find that it is traversed by a number of more or less longitudinally arranged, branching and communicating canals, of varying size, in which lie the blood- and lymph-vessels. It is around these canals, called *Haversian canals*, that the Haversian lamellæ are grouped, and the variously shaped openings which are seen in the transverse sections, are transverse sections of these vascular or Haversian canals. Within the Haversian canals, when they are not entirely filled with the blood-vessels, we find the latter enclosed in a tissue identical with that filling the medullary cavity, and presently to be described as marrow. In the flat and irregular-shaped bones essentially the same structural features are present, but the lamellar arrangement is much less regular.

Although, for the most part, the intercellular substance of bone is, by the ordinary modes of preparation, apparently quite destitute of structure beyond that indicated by its lamellation, we yet find in certain portions a well-defined system of fibres. If, in a decalcified bone, some of the external lamellæ are torn off, numerous fine, fibrillated, spicula-like projections are seen hanging on to the inner surface of the separated fragments. These are the so-called *Sharpey's fibres*, which, passing inward from the periosteum, pierce the bone either obliquely or at right angles. As we shall see when studying the development of bone, these Sharpey's fibres are the

remains of fibrillated connective-tissue bundles, which originally occupied the situation now filled by bone. Recent investigations, moreover, have led to the belief that in bone, as in hyaline cartilage, the basement substance is everywhere delicately fibrillated, but we have not space in this manual to consider the methods by which this may be demonstrated.

2. *Periosteum*.—The periosteum consists chiefly of fibrillated connective tissue, with a few elastic fibres, and we recognize in it two layers: an outer layer, composed chiefly of firm, dense connective tissue, which is continuous with the muscular aponeuroses surrounding the bone; and an inner layer, which is looser in texture, more vascular, and abundantly furnished with variously shaped cells. The periosteum is attached to the bone by connective-tissue fibres, which pass from the former into the substance of the latter, the attachment being firmer at some points than at others, as, for example, near the extremities of the long bones and at the points of insertion of the tendons and ligaments. Blood-vessels pass also from the periosteum into the bone.

3. *Marrow*.—Marrow-tissue is found in the central or medullary cavity of bones, in the tiny chambers of spongy bone, and in the Haversian canals. Sometimes it has a yellowish color and is fatty, sometimes it presents itself in the form of a red-

dish pulp. Red marrow is found in embryos and in young animals, and in adults in certain small bones and in vertebræ. In certain animals, such as the rabbit and guinea-pig, red marrow is found in most of the bones, even in adult life. In adult man, under normal conditions, the marrow—except in the vertebræ, ribs, and certain small bones—is yellow. Yellow marrow differs from the red in that it contains a large amount of fat, sometimes consisting almost exclusively of fat-cells.

We find in red marrow, which is best adapted for study, blood-vessels and spindle-shaped or branching cells, which constitute the supporting framework of the tissue. In the interstices of the latter lie several distinct kinds of cells: 1. Fat-cells; 2. smaller and larger spheroidal cells, having essentially the same structure and character as the lymph-cells, and called, par excellence, *marrow-cells*; 3. cells somewhat larger than the last mentioned, with, usually, a single very irregular-shaped and sharply defined nucleus; 4. very large granular cells, which usually have several nuclei scattered through the cell-body, or grouped on one side, the so-called *myeloplaxes* or *giant cells*. It is not improbable that the two last varieties are only modified forms of the same kind of cells. In the marrow of developing bone are seen spheroidal, or irregularly cuboidal, large granular cells, with commonly oval nuclei, usually situated at one side of the cell-body. These are the so-called

osteoblasts, with which we shall become better acquainted when we study the process of bone-development.

In addition to the above cell-forms, red blood-cells, escaped from the blood-vessels, are usually seen in abundance. Not infrequently, when fresh marrow is studied, cells are seen which in many respects are like the true marrow-cells, but which, with a distinct nucleus, have a homogeneous cell-body resembling in its color the red blood-cells. These cells are the so-called *nucleated red blood-cells*, and are believed by some observers to be destined to lose their nuclei, and assume the character of the ordinary red blood-cells. Those who advocate this view regard the marrow of bones as one of the blood-producing tissues of the body. The transformation of these cells into red blood-cells has never been directly observed, and as the peculiar appearance which they present can be accounted for on other grounds, the formation of red blood-cells in the marrow, while not improbable, cannot yet be regarded as definitely demonstrated.

PRACTICAL STUDY.

Decalcified Bone.—To obtain a general view of the structure of bone, we have recourse to transverse and longitudinal sections of one of the long bones (from man or the lower animals, such as the rabbit or dog), which has been freed from its lime salts by soaking in dilute acids, and rendered so soft as to be readily cut with a razor.

Although various acids, such as nitric and hydrochloric, effect the decalcification of bone, solutions of chromic or picric acids are preferable, because, while very perfectly removing the lime salts, they harden and preserve the soft structures in a most satisfactory manner. As the salts of lime, as they exist in bone, do not undergo rapid solution in these acids, the bits of bone which are to be decalcified should be small, or the process will be a very protracted one. They should not, at most, be larger than a cubic centimetre. The quantity of fluid should also be quite large (two hundred to three hundred cubic centimetres to a bit of bone of the above size). Picric acid, although slow in its action, is, on the whole, to be preferred, because the chromic acid often leaves the tissues in a granular or cloudy condition, which interferes with subsequent study. If chromic acid be employed, the bit of bone is put first into a weak aqueous solution of one in six hundred; in a couple of days it is transferred to a fresh solution of one in four hundred, and again in a couple of days to another solution of one in two hundred. A stronger solution than this should not be used, but this should be renewed every few days, and the bottle frequently shaken. In two or three weeks the process will probably be completed; this can be ascertained by passing a fine needle into the preparation. If it be desirable to hasten the process, after a week or ten days' soaking in chromic acid, as directed, a little nitric acid may be added to the solution (one c.c. to one hundred c.c.). The previous action of the chromic acid will prevent the swelling and partial destruction of the soft parts, which nitric acid alone causes. If picric acid be

employed, a saturated aqueous solution should be used, the preparation frequently shaken, and additional crystals of the acid occasionally added.

When the bone has become sufficiently soft by either of these methods, it is allowed to soak for a day in water to remove the excess of acid, and then hardened and preserved in alcohol. Longitudinal and transverse sections should be made, and, if decalcified by chromic acid, are best stained double with hæmatoxylin and eosin; if by picric acid, the structure shows very well after staining with picro-carmin. Both may be mounted in glycerin. If the periosteum has not been removed, its structure and relation to the bone are well shown.

Sections of Hard Bone.—In such preparations as the above, which are mounted in fluids, the canaliculi are for the most part invisible, because the fluids which fill them possess very nearly the same refractive power as the basement substance. The cell-spaces and canaliculi are best studied in thin sections of hard bone, which have been macerated for some time, so as to remove the medullary fat and other soft parts, and then dried. Transverse or longitudinal sections may be made, the latter being most easily prepared, because sections in this direction are less brittle.

A small piece, as thin as possible, should be sawn from the bone (the diaphysis of a human long bone answers very well) in the proper direction; this is ground down very thin on a whetstone or grindstone, or on a plate of glass with emery powder, the section being held down with the ball of the finger or a bit of soft cork. When it

has become quite thin, so as to be almost transparent, it is polished on a dry oil-stone free from grease, and then carefully washed and brushed under water with a fine pencil to remove particles of dirt. It is now allowed to dry, and is mounted in balsam. For this purpose the semi-fluid Canada balsam, such as is used for ordinary mounting, should not be employed, because it would run into the lacunæ and canaliculi, and render them invisible. A bit of quite hard and solid balsam should be placed on a slide and heated until it melts; just as it begins to fairly cool, but before it gets at all hard, the slip of bone is quickly immersed in the drop and covered. If the proper moment has been chosen, when the balsam is neither too hot nor too cold, the lacunæ and canaliculi are clearly defined by reason of the air with which they are filled. Usually, however, in the most successful preparations, in the very thin parts or at the edges, part of the canaliculi have become filled with the balsam and rendered invisible.

✓ *Marrow*.—A long bone, from a rabbit or from a child, should be broken across and a little of the red marrow scooped out and laid for twenty-four hours in a mixture of alcohol and water (one to two). Fragments are then teased on a slide in glycerin which has been colored with eosin, and mounted in the same. By this process the red blood-cells are destroyed, and the characters of the so-called nucleated red blood-cells changed. For the study of the latter, fresh marrow should be teased on a slide in the indifferent salt solution.

DEVELOPMENT OF BONE.

At a certain period of embryonic life no bone-tissue is found in the body, the parts where it is finally to be, being occupied either by cartilage or fibrillar connective tissue. Out of these tissues the bone is developed by a process which, though presenting considerable differences in detail in various parts of the body, is yet, in its essential nature, the same in all. We recognize three ways in which bone is developed: 1. In the substance of preëxisting cartilage—*intra-cartilaginous*; 2. beneath the periosteum—*sub-periosteal*; 3. in the substance of preëxisting fibrillar connective-tissue membranes—*intra-membranous*. In all of these modes of bone-formation the new bone seems to be deposited under the influence of certain large, granular, usually spheroidal or cuboidal cells, called *osteoblasts*.

1. When bone is formed from cartilage, the latter bears a general resemblance in shape to the finished bone. The first change which we notice in such a cartilage which is about to undergo ossification, is that at a certain point—if it be a long bone, at about the middle of the diaphysis—the cartilage-cells begin to enlarge, the basement substance between them becoming partially absorbed, and what remains of the latter becoming infiltrated with fine granules of lime salts. Around this calcified portion we find the blood-vessels of the perichondrium

accompanied by marrow-tissue and the above-mentioned osteoblasts, growing into the calcified cartilage, absorbing the latter as they go, and forming irregular channels or cavities called medullary spaces. These channels are first separated from one another by narrow, irregular septa of the cartilage basement substance which remains unabsorbed, and are lined by layers of osteoblasts, by whose agency the septa become covered with new bone, in a manner presently to be described.

The region in which this new bone is first deposited is called the *ossification zone*. As the blood-vessels, accompanied by the osteoblasts and marrow-tissue, proceed further and further into the cartilage, channelling out the medullary spaces as they go, we always find—just in advance of the ends of the blood-vessels and the extremity of the spaces in which they lie—a zone of calcified cartilage; and beyond this, cartilage-tissue which apparently prepares the way for the advancing marrow-spaces and newly forming bone, by very characteristic modifications, chiefly in the form and arrangement of its cells.

If we examine the cartilage at a considerable distance from the line of ossification, we find the ordinary appearance of hyaline cartilage with more or less flattened cells. Approaching now the zone of ossification, we find that the cells are larger, are arranged in rows or groups of frequently four, eight,

or sixteen, etc., the intercellular substance being less in amount, corresponding to the increase in size and number of the cells. Further inward, we find the cells still more plainly arranged in rows, very large, sometimes globular or flattened against one another, and the basement substance reduced to quite thin septa, enclosing spaces in which the rows of large cartilage-cells lie. Then comes a narrow zone, in which the septa of the basement substance are filled with fine granules of lime salts—*calcification zone*. Here the cartilage-cells have assumed a peculiar granular character. Finally, still nearer we find that the lime salts have disappeared from the septa, and that the spaces which contained the large granular cartilage-cells have become continuous with the advancing vascular, bone-walled marrow-cavities, above described. It is to be distinctly understood that the calcification zone is not bone, but only calcified cartilage; the true bone being first formed after this lime has disappeared, on the surface of the septa in which it was temporarily deposited—for what purpose we do not know.

Turning our attention now to the exact way in which the bone is formed under the influence of the osteoblasts, we find that just beneath these cells, as they lie along the walls of the new-formed medullary spaces, the basement substance of true bone begins to be deposited, at first in the form of a narrow shell beneath each osteoblast. These deposits,

which on cross-sections have a crescentic shape, become thicker and thicker, rising up around the cell, which they finally enclose—the enclosed osteoblast becoming, as it would seem, a bone-cell. This process going on around each osteoblast, the walls of the medullary cavities soon become covered with a layer of bone containing bone-cells. New osteoblasts appear on the walls, and in turn become enclosed in a layer of bone, and thus the lamellar arrangement of bone-tissue is produced. The remains of cartilage basement substance between the medullary space thus covered by bone finally disappear in a manner unknown to us.

2. Hand in hand with the formation of bone within the cartilage, new bone is formed on its surface beneath the perichondrium, which thus becomes periosteum. The process of sub-periosteal ossification, by which the bone increases in thickness, is dependent also upon the presence of osteoblasts. We find these arranging themselves along the blood-vessels which enter the bone, and along the inner layer of connective-tissue fibres of the periosteum, and bone is formed around them in the manner above described. New bone thus formed at the surface appears at first by no means in the form of smooth, continuous layers, for as the blood-vessels and connective-tissue bundles, along which the osteoblasts lie, are arranged at varying angles with the surface of the bone and with each other, the effect

is to produce irregular-branching cavities, upon whose walls the new layers of bone are deposited. When these branching cavities become filled, with the exception of the space occupied by the blood-vessels and marrow-tissue, by successive lamellæ of bone, they constitute the structures with which we are already familiar under the name of Haversian canals and Haversian lamellæ. Where the formation of bone has taken place along the bundles of connective tissue, these bundles sometimes persist for a long time, in a modified form, among the lamellæ, and constitute the above-mentioned *Sharpey's fibres*.

Thus, by the transformation of cartilage and apposition at the surface, the long bones are formed. In these bones the ossification progresses toward the epiphyses, where independent centres of ossification are established. The lines of ossification approach each other, and finally, when the process of growth in the bone is complete, the band of cartilage which separated them disappears, and epiphysis and diaphysis join to form a single bone. As the bone grows by apposition beneath the periosteum, the osseous tissue which was first formed in the diaphysis is absorbed, and the medullary cavity is formed in the place which it originally occupied.

3. When bone is formed in membranes of fibrillar connective tissue, as in the skull-cap, we notice, first, that some of the interlacing bundles which occupy

the place of the future bone become infiltrated with lime salts; along these calcareous bundles cells become very abundant, osteoblasts appear and arrange themselves, and bone forms around them just as in the other varieties of bone-formation. Blood-vessels and marrow-tissue lie between the new-formed layers of bone, so that at a certain period of embryonic life the bones of the skull-cap consist of a series of bony lamellæ, arranged so as to enclose branching and communicating cavities, which are occupied by blood-vessels and marrow-tissue, and whose walls are lined with osteoblasts. A well-defined periosteum is finally formed, beneath which successive layers of new osseous tissue are deposited, and thus the bone increases in thickness and acquires its smooth surfaces.

The mode of origin of the osteoblasts is still very obscure. Many investigators believe that in the intra-cartilaginous ossification they are the large cartilage-cells which we see at the calcification line, which in contact with the blood-vessels become so modified in form and function as to assume the rôle of bone-formers. Others assert that the large cartilage-cells disintegrate and disappear, and that the osteoblasts are produced from cells which accompany the blood-vessels. Still others regard them as white blood-cells, modified and endowed with new functional powers. In the intra-membranous and sub-periosteal ossification, many suppose that they

are formed from connective-tissue cells. So little is absolutely known, however, as to their genesis, that while recognizing their importance in bone-formation, we can regard none of these various theories as to their origin as definitely established.

PRACTICAL STUDY.

Intra-cartilaginous and Sub-periosteal Ossification.—A long bone, from a nearly mature foetus or a young animal, should be carefully removed without injuring the periosteum, and decalcified.* Thin longitudinal sections are made with a razor through the ossification zone, embracing the tissue for a considerable distance on either side of it. The sections are stained double and mounted in balsam.

✓ *Intra-membranous Ossification.*—To study the early stages of this process, a young embryo (if from the sheep or pig, four to six cms. long) should be soaked for a few days in Müller's fluid, and a bit corresponding to the portion of one of the parietal bones cut out, and the skin, muscles, and dura mater torn away with forceps under water. The membrane in which ossification is occurring is now to be carefully brushed with a stiff pencil until it is thin enough to be examined with tolerably high powers. It is stained double and mounted in balsam.

The irregular chambers, lined with osteoblasts and filled with blood-vessels and marrow, which are formed in the bones of the skull-cap at a later period, are well shown by transverse sections through the decalcified skull-bones of an older foetus (human, at about six or

* Embed in celloidin.

seven months, or from the beef or sheep, sixteen to twenty cms. long). These should be stained and mounted as above.

TEETH.

The teeth have many structural features in common with bone. The chief bulk of the tooth is made up of homogeneous, brittle basement substance much harder than bone, called *dentine*. The dentine contains lime salts, and is permeated by a multitude of fine branching channels which radiate from a central cavity, called the *pulp cavity*, which the dentine encloses. These delicate channels in the dentine are analogous with the canaliculi of bone.

The pulp cavity is filled with a soft vascular tissue, called *pulp*, containing irregular-shaped, often branching cells, and nerves. Along the sides of the pulp cavity lie spheroidal or ovoid cells, which send off branches into the pulp and also into the above-mentioned delicate channels in the dentine. These cells are called *odontoblasts* or *dentine cells*, and are usually considered to be the analogues of the bone-cells. The pulp cavity is open at the root of the tooth for the admission of vessels and nerves. Surrounding the root of the tooth is a thin layer of bone called *cement*. At the crown of the tooth the dentine is completely covered by a layer, of varying thickness, of an extremely hard substance called

enamel. The enamel consists of a series of closely packed, small, wavy or undulating prisms, placed edgewise upon the surface of the dentine, and covered, over the free surface of the tooth, by a hard, tough, structureless membrane, called the *enamel cuticle*.

PRACTICAL STUDY.

Hard Teeth.—To study the hard parts of teeth, thin sections of a macerated and dried tooth should be ground down by the method described when we were studying hard bone, and mounted, with the same precautions, in hard Canada balsam.

Decalcified Teeth.—The soft parts of teeth may be studied in sections from teeth which have been decalcified with picric acid. The tooth should be broken across, so as to expose the pulp cavity and hasten the action of the solvent. Sections are stained with hæmatoxylin and eosin, and mounted in glycerin.

CHAPTER V.

BLOOD AND LYMPH.

BLOOD.

ALTHOUGH strikingly different in physical character from most animal tissues, we must yet regard blood and lymph as true tissues—tissues with a fluid intercellular substance. Let us first consider the blood.

In normal human blood we find suspended in a colorless fluid, the *plasma*, three distinct kinds of formed elements: 1. *Colorless blood-cells*; 2. *red blood-cells*; 3. variously shaped *free granules*.*

1. *Colorless or White Blood-cells or Leucocytes*.—These are small, usually spheroidal nucleated cells, without a membrane, the cell-body being finely, or sometimes coarsely, granular. The nuclei, of which there may be one or more, are not usually visible in the living cells on account of the granular character of the body which conceals them, and are of varying form,—sometimes spheroidal or dumb-bell-shaped, sometimes having the form of a bent or twisted cylinder, and again entirely irregular.

These cells possess the power, under favorable conditions, of spontaneous movement. They change

* See Appendix, p. 253.

their form and place. While, when in a state of rest, they assume in general the spheroidal form, as above stated, we find that when they become active they send out variously shaped processes, some fine and delicate, others broad and of very irregular shape. We often see, after a process has been thrown out, that it becomes gradually larger and larger, the cell-body becoming correspondingly smaller, until finally the whole cell seems to have passed over into the process, thus moving forward. Sometimes processes are thrown out and again withdrawn, and not infrequently the whole cell flattens out into an irregular-shaped mass, so thin as to be almost invisible. Not infrequently clear rounded spaces, called vacuoles, suddenly appear in the cell-body during its movements, and either remain for some time, or soon disappear as suddenly as they came.

These movements are called *amœboid movements*; they are always very slow, and are greatly influenced by the temperature, density, and oxygen-content of the fluid in which they lie. By virtue of this locomotive power the white blood-cells perform certain evolutions within the vessels; they escape through their walls, and sometimes singly, sometimes in vast numbers, move through the tissues in the larger and smaller lymph-spaces. This *emigration* of white blood-cells occurs apparently, to a slight extent, under normal conditions; but it is under pathological conditions that it is most active.

The nuclei of these cells become visible on the application of a variety of agents which determine the death of the cells, such as acetic acid, dilute alcohol, and certain coloring agents. The cells vary greatly in size, but on the average are, in man, larger than the red cells.

2. *Red Blood-cells*.—These cells, having in man the form of bi-concave discs, consist apparently, simply of a cell-body without membrane or nucleus. Although when crowded together in great numbers they give the blood a distinct red color, when seen singly they have a greenish-yellow tint. The cell-body is very soft and pliable, jelly-like, changing its shape on the slightest pressure. It is more deeply colored at the periphery, when seen from the side, because of its greater thickness at that part. Owing to the peculiar shape of the cell, it acts as a lens upon the light passing through it, and its central portion is either light or dark, depending upon whether the objective is approached to or withdrawn from it. When examined fresh in the plasma, many of the cells arrange themselves closely together side by side, in longer and shorter rows.

If water is mixed with blood, the red cells soon begin to swell and lose their color. Sometimes one side swells faster than the other and the cells become cup-shaped; finally they become globular, are considerably larger than at first, and colorless.

On being drawn from the vessels, if the plasma

be allowed to evaporate, or if certain fluids—such as strong solutions of common salt or bichromate of potassium—be added, a part of the red blood-cells lose their regular shape, their edges become crenulate and jagged, and they sometimes seem to become smaller; finally, they assume the form of irregular globular masses, beset with short, blunt spines. Various other irregular forms are produced under the same circumstances which it is not necessary to describe here. The addition of water causes the spines to disappear, and the cells swell up and assume a globular form. These changes in form, produced by chemical agents and by change in the density of the fluid in which the cells lie, should not be mistaken for an expression of vitality, or regarded as analogous with the amœboid movements of the white blood-cells.

The red blood-cells are much more abundant than the white, there being in normal human blood about 350 to 500 of the former to one of the latter. It is estimated that in man there are between four and five million red blood-cells in one cubic millimetre of blood. The diameter of the average cell is about $\frac{1}{126}$ th of a millimetre, or about 7.9μ .¹ Not infrequently in normal blood—very often under pathological conditions—red blood-cells are seen which

¹ The Greek letter μ is frequently employed to represent the micro-millimetre, or the one-thousandth part of a millimetre, this having been widely adopted as the unit for microscopic measurement. In English measurement the average red blood-cell has a diameter of about $\frac{1}{8200}$ th of an inch.

are much smaller than the above-described forms, and are often spheroidal in shape.

The red blood-cells owe their color, as well as their capacity for performing certain important physiological functions, to the presence in them of a crystallizable substance called *hæmoglobin*. The exact relation existing between the hæmoglobin and the substance of the cell is but little understood. They are but loosely combined, for the hæmoglobin is readily dissolved out by water, which itself becomes colored, while the colorless and swollen cell or *stroma* is left behind. The shape of hæmoglobin crystals obtained from the blood of different animals is not always the same; those from human blood have, in general, the form of rhombic prisms.

3. *Free Granules*.—These are always found in greater or less number in human blood when drawn from the vessels. They are chiefly of two kinds; either small spherical bodies, somewhat resembling fat-droplets, or variously shaped, often angular masses, looking not unlike fragments of white blood-cells. They are sometimes seen singly, sometimes in clusters. Their nature is still undetermined.

The above general description of the blood-cells of man applies, with few exceptions, to other mammalia. The differences in size, however, which exist between the red blood-cells of man and those of certain of the mammalia, are so considerable that they can be distinguished with certainty from one

another by microscopic measurements. It should, on the other hand, never be forgotten that the red blood-cells of certain other mammalia, *e. g.*, the dog, have so nearly the same average diameter as those of man that they cannot be distinguished with absolute certainty by measurements. In other vertebrates the form and character of the red blood-cells differ greatly from those above described; being for the most part oval, and having a distinct nucleus.

The intercellular substance or plasma of freshly drawn blood is perfectly homogeneous; but if we allow it to coagulate, we find, on subjecting it to microscopical examination, that in addition to the above-described elements, a multitude of delicate filaments lie among the cells, stretching in all directions, and joining each other at frequent intervals, forming an irregular-meshed net. We find, moreover, if we examine a clot from which the red cells have been carefully removed or rendered invisible, that in many places the filaments are grouped around irregular-shaped granules, looking like those above described in normal blood; and if the process of coagulation be carefully observed, they may be seen to actually shoot out from these granules, which thus seem to form starting-points for their formation. The substance which thus separates from the plasma is called *fibrin*.

LYMPH.

In lymph, in addition to the plasma from which fibrin is formed on separation from the body, we find spheroidal cells identical in structure with the white blood-cells; sometimes a few red blood-cells; and variously shaped granules or minute globules, composed apparently of a combination of albuminoid material, with fat. These globules, in that variety of lymph called chyle, are so abundant as to give the fluid a milky appearance.

Origin of Blood-cells—Direct observation has shown that, in some animals at least, the white blood-cells can multiply by division. Whether the cells which supply the place of those which seem to be used up in the process of growth and reparation are produced in this way, and if so, whether the division occurs in the blood- or lymph-vessels, or in the cell-spaces of the connective tissue, or in certain special organs, or whether they are produced in a manner entirely unknown to us—these are questions not only of theoretical but of practical interest; but, in spite of much research, and the accumulation of many observations bearing on the matter, we are still unable to give them a definite answer. Still more obscure, if possible, is the *origin of the red blood-cells*. Although in the adult man they seem to possess no nucleus, yet in embryonic life they certainly are furnished with that structure; we

find nucleated red blood-cells. Now, it has been recently shown that in certain parts of the body, in adult life, cells occur which in many respects resemble the nucleated red blood-cells of the embryo; such cells are found, for example, in the spleen, in the red marrow of bones, etc.

The most plausible theory in regard to the matter is, that in certain parts of the body—spleen, marrow, lymph-glands, and liver—white blood-cells are produced, a part of which are changed into the red blood-cells. The so-called nucleated red blood-cells are supposed to be intermediate forms. It must be remembered, however, that this view is not established as yet, and many observers do not ascribe to the so-called nucleated red blood-cells the significance upon which the advocates of this theory insist.

PRACTICAL STUDY.

✓ *Fresh Human Blood.*—This may be obtained by tying a cord tightly around the finger to cause congestion, and then pricking it sharply at the side of the nail with a bright, clean sewing needle. A small drop is received on a slide and covered at once, care being taken not to press upon the cover-glass. The film of blood should be very thin or the crowding of the cells will interfere with the observation. As the plasma evaporates, the changes in form due to shrinkage of the red blood-cells may be observed near the edges of the preparation. Finally, a drop of water should be allowed to run under the cover-

glass and its action observed, first, in causing the disappearance of the crenulations on the shrunken cells and the swelling of all the red blood-cells, and second, in dissolving the hæmoglobin out of them.

√ *Crystals of Hæmoglobin from Rat's Blood.*—Although readily separated by water from its combination with the stroma of the red blood-cells of man, the hæmoglobin does not readily crystallize. But when separated from the red cells of certain animals, the rat for example, it commences to crystallize, under favorable conditions, almost immediately. A small drop of rat's blood is mixed on a slide with an equal quantity of water, covered and examined at once. The color begins to be discharged from the red cells very soon, and within a few moments, near the edges of the cover-glass, small crystals may be found in abundance. If the specimen is set aside and examined after a few hours, many very large and beautiful prismatic crystals may be seen. Hæmoglobin crystals do not keep long enough for permanent preservation.

Demonstration of the Nuclei of the White Blood-cells.—In order to see their outlines distinctly, the nuclei must be stained and the cell-body rendered transparent. This may be accomplished by mixing on a slide a small drop of blood from the finger with an equal quantity of the following fluid :

Saturated alcoholic solution of Aniline Red	1 part,
Alcohol	5 parts,
Water	10 parts.

After thoroughly mixing the blood with the fluid, and

covering, it will be found that while the red cells are partially decolorized and inconspicuous, the bodies of the white blood-cells have become transparent and their nuclei are stained deep red.

Amœboid Movements.—These are most conveniently studied in the blood or lymph from one of the cold-blooded animals, such as the frog, for they occur here at the ordinary temperatures of the air, while artificial heat must be resorted to if we would maintain the blood of warm-blooded animals at a proper temperature for their occurrence.

The leg and toes of a frog having been carefully cleansed, the tip of one of the toes is snipped off, and on stripping the leg downward with the thumb and finger, a drop of mixed blood and lymph will presently exude from the toe. This is received on a slide, protected from pressure by a bit of hair, and covered. To prevent evaporation of the plasma, a rim of oil is painted around the edge of the cover. On focussing now upon the specimen, white blood-cells will readily be found, and selecting one which, by its irregular shape, indicates its activity, the attention must be fixed upon this cell and sketches of its form made at short intervals—every two minutes. Although the movement is usually too slow to be actually detected by the eye, if the cell is fairly active, it will be sufficiently evident, after a few sketches, that it has changed its shape and perhaps its place also.

If the temperature of the room be low, the movements may be tardy in commencing, and they can be hastened by holding the finger or any warm object for a moment near the cover. It should be borne in mind that in the

frog's blood the red cells are oval and nucleated, and that they are also larger than the colorless cells.

Fibrin.—A small quantity of blood may be whipped and the cells washed from the clot by a stream of water, and a fragment of the remaining substance teased in water on a slide and studied ; but the objects thus obtained are not altogether satisfactory, since the relation of the fibrillæ to one another is disturbed and no light is thrown on the way in which they are formed. For the accomplishment of these ends, the following method may be employed : a medium-sized drop of blood is received on a slide and immediately covered ; after a few moments, when coagulation has occurred, the cover-glass is gently raised with the forceps, and the blood-cells washed out of the clot by allowing drops of water to fall upon the inverted cover-glass from a pipette held a few inches above the preparation. (If, in removing the cover-glass, the clot adheres to the slide, the water is, of course, to be applied here.) When no more color is seen in the clot, a drop of the above solution of *Aniline Red* is placed upon it, and it is again covered. The fibrin will be seen in the form of minute inosculating filaments which often radiate from what appear to be the above-described free granules.

CHAPTER VI.

MUSCULAR TISSUE.

CERTAIN muscles are under the control of the will, and are called voluntary muscles; and as these have, as we shall see presently, a very characteristic transverse striation of their structural elements, they are also called *striated voluntary muscles*. To this class belong, among others, the muscles of locomotion and the voluntary muscles of the trunk and head. Other muscles are not under control of the will, and are hence called *involuntary*. A certain portion of these involuntary muscles possess the same striation of their elements as the voluntary muscles, and hence are called *involuntary striated muscles*. These are found in the heart. In another kind of involuntary muscles, such as is found in the intestine and bladder, the elements do not possess the same kind of striations, and they are hence called *smooth or non-striated involuntary muscles*.

We have thus to study three kinds of muscles :

1. Involuntary muscles $\left\{ \begin{array}{l} a, \text{ smooth or non-striated,} \\ b, \text{ striated.} \end{array} \right.$
2. Voluntary muscles (striated).

I. *a.*—SMOOTH MUSCULAR TISSUE.

Smooth muscular tissue is made up of very much elongated, narrow, pointed, usually fusiform cells. These cells are commonly arranged in groups or bundles, enclosed in connective tissue and supplied with blood-vessels and nerves. The cell-body, although usually fusiform, is sometimes flattened and band-like, often divided at the ends into two pointed extremities. Owing to pressure from adjacent parts, the fusiform cell-bodies are often more or less flattened at the sides, presenting on cross-section an irregular polygonal contour. The cell-body has an indistinct longitudinal striation, and frequently in the vicinity of the nucleus a few shining granules are seen. The nucleus is usually narrow and much elongated, rod-like, and commonly encloses one or more nucleoli. It usually lies near the middle of the cell, which is often thickened or bulging at that point.

These cells lie side by side or lap over one another at the ends, and are joined together by a small amount of an albuminoid cement substance. These smooth muscle-cells are variously grouped in different parts of the body; sometimes crowded together in solid bundles, which are arranged in layers and surrounded by connective tissue, as in the intestines; sometimes arranged in narrow interlacing fascicles, as in the bladder, or scattered

singly through certain tissues ; sometimes wound in single or double layers around the blood-vessels ; and again running in various directions and associated with bands of connective tissue, they form large compact masses, as in the uterus.

The longitudinal striation—which, under favorable circumstances, is seen on the cell-body—is not a mere surface marking, but extends deep into the cell, as may be seen in transverse sections of suitably prepared cells where fine lines are observed passing inward from the periphery of the cell toward the nucleus. The blood-vessels supplying this tissue form for the most part elongated net-works throughout its substance.

PRACTICAL STUDY.

Isolated Cells.—These we obtain by teasing bits of the tissue, but as they are firmly bound together by the cementing substance, this must first be dissolved or softened. This can be conveniently accomplished by soaking a bit of the tissue—the wall of the intestine for example—for forty-eight hours in an aqueous solution of bichromate of potassium (1 to 800). Shreds of the muscular layer are torn off, slightly stained with hæmatoxylin, washed, and then carefully teased in glycerin which has been colored by eosin. To prevent the shrinkage of the cells under the action of the bichromate, it is well to enclose a short segment of the intestine, distended with the solution, between two ligatures, and immerse it in a vessel of the same solution.

The cells may be more perfectly separated by soaking a bit of the fresh tissue for a few minutes in forty-per-cent. solution of caustic potash and then teasing, but they cannot be stained or preserved.

Transverse and Longitudinal Sections of the Cells.—The intestine of the cat is well adapted for this preparation, since here the muscle-cells are unusually large. A segment having been distended as above with Müller's fluid, it should be immersed for ten days in the same, then carefully washed and put for a day or two in strong alcohol. A bit is then cut out, embedded between pieces of hardened liver,* and thin sections made in a direction exactly at right angles to the axis of the gut. The sections are stained double and mounted in balsam or glycerin. In such a preparation two layers of muscle-cells are seen: in one the cells are seen in transverse, in the other in longitudinal, section. Since the cells lap over one another, in the transverse sections the forms which they present will obviously differ, depending upon whether they have been cut across at the level of the nucleus, or at a point nearer the extremity. In such a preparation, the cementing substance between these cells may be seen in the transverse sections; and the serosa and mucous membrane are seen on opposite sides of the muscular layers.

Muscle-cells of Frog's Bladder.—Elegant pictures of very much elongated, slender muscle-cells, lying singly or arranged in narrow interlacing fascicles, may be obtained from the frog's bladder by the following method: the spinal cord of a frog being broken up, the abdominal cavity is largely opened by a crucial incision, and a

* Better in celloidin.

curved canula, attached to a small syringe filled with a saturated solution of bichromate of potassium, is passed into the cloaca and directed forward into the bladder. The fluid is now slowly injected, and when the bladder is partially distended a ligature is thrown around its base, and the injection continued till the organ is fully distended. The ligature is now drawn tight and the canula withdrawn. The bladder is cut out, still distended, and put in the same bichromate solution, where it remains for three days, when it is washed and transferred to alcohol. After twenty-four hours it may be opened, and a bit cut out, the epithelium carefully brushed from the inner surface, and stained double and mounted in glycerin. In addition to the muscle-cells, the nuclei of the endothelial cells covering the peritoneal surface will be seen, as well as connective-tissue cells and fibres in the wall of the bladder.

2.—STRIATED VOLUNTARY MUSCULAR TISSUE.

As the involuntary striated or heart muscle occupies, in structure, an intermediate position between the smooth and the voluntary striated muscle, we shall find it advantageous to postpone its study until we have considered the other varieties.

Voluntary striated muscle, to which the greater part of the muscular tissue of the body belongs, is made up of narrow, cylindrical, cord-like elements, of varying length and thickness, called *muscular fibres*. These are grouped in variously shaped bundles or fascicles, surrounded by connective-

tissue envelopes or sheaths, and abundantly supplied with blood-vessels and nerves. Let us first study the structure of the individual fibres. They consist of three distinct elements: 1, *contractile substance*, forming the centre and making up most of the bulk of the fibre; 2, *nuclei*, which in man and most warm-blooded animals lie scattered upon the surface of the contractile substance; 3, the *sarcolemma*, a thin homogeneous sheath or tube, which tightly encloses the other elements.

1. If we examine a fresh muscle-fibre, or one which has been hardened under favorable conditions, with moderately high powers, we see that the contractile substance is indistinctly longitudinally striated; and if we treat muscle with certain chemical agents, such as chromic acid or its salts, we find that by slightly teasing, the fibres break up along the longitudinal striæ into a multitude of fine fibrillæ, which are called *primitive muscle-fibrillæ*. Again, if we examine the fresh or hardened fibres still further, we find that in addition to the longitudinal striations, they are crossed by more prominent, narrow, alternating, dark and light bands or stripes, the relative width of the stripes varying according as the muscle is seen in a state of contraction or relaxation. Still further, if we soak a fresh muscle for twenty-four hours in a half-per-cent. solution of hydrochloric acid, and then tease it, we find that the fibres, instead of breaking up longi-

tudinally into fibrillæ, break across transversely into thin discs. We thus see that, by breaking up in these two directions, we may conceive of the fibre as being resolvable into a multitude of tiny prismatic structures, which are called *sarcous elements*. The central portion of each prism or sarcous element is occupied by a dark portion, while at each end is a lighter zone. The light and dark zones of the sarcous elements, when the latter are grouped together, form the alternating light and dark bands of the fibres. It is believed by many observers that the sarcous elements are definite and independent structures, in which the dark portion is the contractile element, and that they are joined together side by side and end to end by peculiar cementing substances.

In addition to these markings on the fibres, if high magnifying powers are used and the fibre is in a state of extension, a fine line is seen crossing the fibre through the centre of the light transverse band; this corresponds with the dividing line between the ends of the sarcous elements, and is called *Krause's line*. Under favorable conditions the dark band is also seen to be crossed by a line called *Hensen's line*, whose nature is as yet but imperfectly understood.

All of the above-described structural features of the muscular fibres are much more distinct after treatment with chemical agents, and after the

death of the tissue; the longitudinal striation is not visible during life, and the distinct separation of the primitive fibrillæ and discs can only be accomplished by chemical means. We can see the various markings with sufficient clearness, on the fresh or living muscle, to convince ourselves that marked optical differences, at least, exist in different parts of the fibres; but that the living fibre is made up of distinct elements, having the structure which we see in the isolated or partially isolated sarcous elements, although probable, is by no means proven, since this isolation by chemical means may signify only a tendency to break up in certain directions, and not a definite, preëxisting separate structure.

2. The nuclei, which in the mammalia lie upon the surface of the fibres, and directly beneath the sarcolemma, in the amphibia, fishes, and certain birds, also embedded within the contractile substance, are usually large, flat, and ellipsoidal in shape, contain nucleoli, and lie with their long axes coincident in direction with the axis of the fibres. They are irregularly scattered along the fibre, and a small amount of granular matter is usually seen in their immediate vicinity.

3. The sarcolemma, a delicate, structureless, membranous sheath, is so thin, and so closely encloses the contractile substance and nuclei, that we cannot usually see it, unless we separate it by artificial means from the underlying structures.

Where the muscular fibres join tendons, the sarcolemma ends in the form of a pointed or rounded blind sac, to which the tendon-fibres are attached.

The muscular fibres lie closely packed together, their ends lapping over on to adjacent fibres, and forming bundles which are enclosed in sheaths of connective tissue. Such bundles are again grouped to form larger bundles, and thus the larger and smaller muscular bellies and bands are formed. Arteries enter the muscular bundles and break up into capillaries, which run along the fibres, forming a long and narrow-meshed net. Motor nerves also pass into the muscles, divide and subdivide, and terminate, at the surface of the individual fibres, in structures called *motor end plates*.

PRACTICAL STUDY.

Fresh Muscle.—A very small bit is dissected off, with as little stretching as possible, from one of the voluntary muscles of a recently-killed mammal, and carefully teased longitudinally in salt solution. In such a preparation the transverse bands and indistinct longitudinal striations will be seen, and here and there, where the needles have pressed on the fibres, the contractile substance may be seen to have been broken across and the broken ends to have retracted within the sarcolemma, leaving the latter as a clear and sometimes folded membrane stretching across the interval. At the cut ends of the fibres the contractile substance will often be seen swelling and extruding from the sarcolemma in the form of an obscurely

striated fungiform mass. Here and there nuclei are seen ; but they may be brought much more clearly into view by allowing a drop of two-per-cent. acetic acid to flow under the cover-glass ; then the contractile substance swells and becomes transparent, the striations becoming indistinct as the somewhat shrunken nuclei become more clearly defined.

Muscular Fibres Hardened with Osmic Acid.—The above-described finer structural details of the muscle fibres are much more evident when they are in a state of extension than when contracted. We may render this condition permanent for study, by the following method : the skin is quickly removed from the leg of a freshly-killed animal (rabbit or dog), and one of the large muscles of the thigh is forcibly extended with the fingers ; the canula of a hypodermic syringe is then thrust into the muscle, and an interstitial injection is made of a mixture of equal parts of 1-per-cent. solution of osmic acid and strong alcohol. This fluid, in three or four minutes, fixes the fibres in the extended condition. A small bit of that portion which has become brown is now snipped off and carefully teased and mounted in a mixture of equal parts of glycerin and water. In such a preparation some of the fibres frequently escape extension, in which case, the marked difference may be observed between the extended and non-extended condition of the fibres.

Sections of Hardened Muscle.—The details of the structure of muscular fibres, as well as their grouping and relation to the connective tissue, may be well studied in sections from hardened muscle. For this purpose the tongue of some animal—such as the dog—is well suited,

since here we have short muscular fibres running in various directions and attached to tendons, and we see in a single transverse section of the organ, at once, longitudinal and transverse sections of the fibres. The tongue of a dog is hardened in bichromate of potassium and alcohol, and transverse sections through the anterior half of the organ are stained double and mounted in glycerin.

In muscular tissue thus hardened, the primitive fibrillæ are loosened from one another, and in some parts of the specimen are usually more or less separated. The contractile substance, moreover, usually shrinks away somewhat from the sarcolemma, which then appears in the transverse section as a delicate ring around the fibre.

Blood-vessels are seen in the above preparation, but they may be much better demonstrated in longitudinal sections of a muscle whose vessels have been injected.

I. *b.*—INVOLUNTARY STRIATED OR HEART-MUSCLE.

In mammalia, the heart-muscle differs in several important structural features from the voluntary muscle.

The contractile substance has essentially the same structure as the latter, but, instead of being arranged in the form of elongated, unbranched cylinders or fibres, without distinct cell-structure, in the heart-muscle the fibres send off at frequent intervals short, narrow processes, which join neighboring fibres, forming a narrow- and long-meshed net. Further, the fibres which, owing to the numerous anastomoses, are very irregular in form, are made up

of distinct segments or cells, each segment being cemented at the ends to its neighbors, and furnished with a flat, elongated, ovoidal, or often rectangular nucleus. In the vicinity of the nuclei we usually see a certain amount of granular material or pigment particles. The nuclei instead of lying, as in the voluntary muscles, at the surface of the contractile substance, are embedded within it. We are unable, in heart-muscle to demonstrate a sarcolemma. The fibres are grouped in bundles, which are enclosed in connective tissue and supplied with blood-vessels and nerves.

PRACTICAL STUDY.

✓ *Sections of Heart-muscle.*—A bit of the heart of man, or any mammal, should be hardened in Müller's fluid and alcohol. Longitudinal and transverse sections are stained double and mounted in glycerin.

✓ *Teased Heart-muscle.*—To demonstrate the segments or cells of which the heart-fibres are composed, a moderately thin bit of fresh heart-muscle is put for twenty-four hours into a dilute solution of chromic acid (1 to 5,000), then carefully washed with pure water and stained with picro-carmin. It is then teased on a slide and mounted in glycerin, to which a little formic acid has been added (1 to 100). The formic acid renders the tissue more transparent, and brings more clearly into view the narrow, jagged lines of strongly refractive substance which indicate the longitudinal boundaries of the muscle-cells.

CHAPTER VII.

NERVE-TISSUE.

THE primary structural element in nerve-tissue is the *nerve-cell*. Nerve-cells have the most diverse forms, and always possess one or more branching or unbranched processes. In certain cells the unbranched processes are extremely long, become associated with other tissue elements, and constitute the *nerve-fibres*. Both nerve-cells and their processes, nerve-fibres, are enclosed and supported by peculiarly arranged connective tissue, and supplied with blood and lymphatic vessels. The nerve-fibres form, for the most part, the white matter of the nerve-centres and the peripheral nerves, while the cells enter largely into the composition of the gray matter. In studying nerve-tissues, we have then to consider:

I. *Nerve-fibres*, and the supporting connective-tissue structures, with their accessories.

II. *Nerve-cells*.

I.—NERVE-FIBRES, ETC.

These are of two kinds: A, *medullated*, and B, *non-medullated*. This distinction corresponds with

the physiological and anatomical classification of nerve-tissues into those of the cerebro-spinal and the sympathetic systems; the medullated belonging to the former, the non-medullated to the latter.

A. *Medullated Nerve-fibres.*

If we disregard for the moment the structure of these nerves at their point of origin in the nerve-centres, and at their termination in the periphery, and study their structure as it is seen in the continuity of any of the larger or smaller nerves, we find that the individual fibres present three distinct structural elements: 1, the *axis cylinder*; 2, the *medullary sheath*; 3, the *neurilemma*.

1. Running through the axis of the fibre is a cylindrical, with high powers, delicately longitudinally striated structure—the *axis cylinder*. This is believed to be the essential nerve-element of the fibre—the process of the nerve-cell, from which it passes without break of continuity to the periphery; and it is probable that the longitudinal striations are the expression of its composition from still finer primitive fibrils, which, as we shall see when we study the nerve-cells, seem to be continued on into the cell-body itself, within the nerve-centres.

2. Closely surrounding the axis cylinder is a tube or sheath of varying thickness—the *medullary sheath*—composed of a white, semi-fluid, translucent, strongly refractive substance, called *myelin*, which

undergoes rapid changes after death, or on removal from the animal, and swells and assumes a multitude of bizarre forms on addition of water; it is soluble in alcohol, chloroform, and ether; and, like fat, is hardened and turned black under the action of osmic acid. The medullary sheath does not form a continuous tube, but at tolerably regular intervals is separated into segments.

3. The *neurilemma* or *sheath of Schwann* is an extremely thin, structureless, membranous tube, which tightly encloses the medullary sheath, and, like the latter, is broken up into segments. At the ends of the segments is a *constriction* around the fibre, at the expense of the medullary sheath, and the ends of the neurilemma segments are joined together by a thin layer of cement substance, which extends inward to the axis cylinder. There is reason to believe that the neurilemma extends inward and between the medullary sheath and the axis cylinder, entirely enclosing the segments of the medullary sheath.

Within each neurilemma segment, called *interannular segment*, and about midway between the constrictions, lies a flattened, elongated, elliptical nucleus. We may regard the neurilemma segments, with their nuclei, as cylindrical cells cemented together, end to end, enclosing the segments of the medullary sheath and surrounding the axis cylinder, the latter passing uninterruptedly through the axis of the seg-

ments. In addition to these structural features, we find, on examining with high powers, irregularly scattered along each interannular segment, delicate oblique lines or fissures, called the *incisures of Schmidt*, which seem to pass from the neurilemma at the surface inward to the axis cylinder, obliquely through the medullary sheath. Their significance is not, as yet, definitely determined. Medullated nerve-fibres vary greatly in diameter.

Connective Tissue of the Nerves.—The nerve-fibres are bound together by connective tissue, to form larger and smaller nerve-fascicles, which, singly or in bundles, we usually call simply nerves. If we follow the nerves outward toward their peripheral terminations, we find that they divide and subdivide, becoming, as they do so, smaller and smaller, until we finally come to nerves which consist of a single fibre. These single nerve-fibres do not lie free in the tissues, but are enclosed in a distinct sheath, called *Henle's sheath*, which is a tube formed of a single layer of endothelial cells, placed edge to edge, and cemented together. Between the sheath and the nerve-fibre is a narrow space, which, under normal conditions, is filled with lymph.

Having become acquainted with this simple structure of the single terminal nerves, let us follow them backward. We find, as we do so, that as they become larger by the junction of several fibres a small amount of fibrillar connective tissue appears be-

tween the fibres within Henle's sheath, and that the latter becomes attached to the surrounding structures by a layer of connective tissue. Finally, when we arrive at the larger nerve-trunks, we find that in each the connective tissue presents itself in three ways:

1. It forms a distinct sheath, which, although the analogue of Henle's sheath, has a much more complicated structure, and is called the *lamellar sheath*. This is composed of several concentric lamellæ, each of which is formed of a fenestrated membrane of fibrillar connective tissue containing granules of elastic-tissue substance, and covered with endothelial cells. The lamellæ are connected by oblique fibres, which pass from one to the other, binding them more or less firmly together. The whole forms a compact sheath, closely investing the fascicle of nerve-fibres.

2. Outside of the lamellar sheath, and joining it to adjacent structures—to neighboring nerve-fascicles, if the nerve-trunk is composed of several of these, as is the case in many large nerves—we find loose fibrillar connective tissue with flattened, irregular-shaped cells—like those found in the loose subcutaneous connective tissue—reinforced by elastic fibres, and often containing fat-cells. The fibrillated and elastic fibres, especially in the immediate vicinity of the lamellar sheath, usually run in a direction approximately parallel with the axis of the

nerve. This tissue is called the *peri-fascicular connective tissue*.

3. We find within the lamellar sheath and between the nerve-fibres composing the fascicle, in the first place, prolongations inward of the tissue composing the lamellar sheath; and, second, fine fibrillated fibres and flattened cells which lie in the interstices between the nerves and fibres. This tissue is called the *intra-fascicular connective tissue*. Blood-vessels penetrate the lamellar sheath of the medium-sized and larger nerves, and a very long-meshed and abundant capillary network is formed in the intrafascicular connective tissue. Lymphatic channels and spaces are also abundant within the nerves, so that the fibres are bathed in nutritive fluids.

Termination of Medullated Nerve-fibres

1. *In the Nerve-centres.*—We find in the nerve-centres, nerves which have no neurilemma, and others in which both neurilemma and medullary sheath fail—the so-called *naked axis-cylinders*; we find, further, extremely delicate filiform structures which are believed to be the primitive nerve-fibrils. The axis-cylinders of the nerves being, as above stated, processes of nerve-cells, the nerve-fibres, as we trace them back into the centres, must sooner or later join cells. Their exact mode of connection with the cells is not in all cases sufficiently well un-

derstood ; but it is believed that they either join the cells in the form of naked axis-cylinders, or, in other cases, that the axis-cylinders break up into their constituent primitive fibrils before entering the cells.

2. *In the Periphery.*—The peripheral termination of nerves is a subject which presents extreme difficulties to the histologist, and with few exceptions the exact way in which this occurs is unknown. The motor nerves, which are distributed in the voluntary striated muscles, terminate in distinct, nucleated, finely granular structures on the surface of the fibres, called *end plates* ; those which go to the smooth muscle tissue break up into fine plexuses, from which fibrils seem to pass either to the individual muscle-cells or to the surface of cell-bundles. In the case of some of the nerves of special sense, we have elaborate nerve-structures such as the retina, auditory apparatus, etc. Again, we find the nerves ending in small, complex, isolated bodies, such as the so-called *tactile corpuscles*, etc. In some cases as the nerves approach their peripheral terminations, they lose the medullary sheath and neurilemma, and the axis-cylinder breaks up into very numerous, exceedingly delicate fibrils which sometimes form intricate plexuses ; some of the fibrils appear to terminate by free extremities ; others, it is probable, end in single cells of various kinds ; but the whole subject of peripheral nerve-endings is far too intri-

cate and too little understood, to demand more than a passing mention in a course of study as elementary as that which now engages us.

b.—Non-medullated Nerve-fibres.

These are also called *fibres of Remak*. Unlike the nerve-fibres which we have just been studying, they possess no medullary sheath and no neurilemma. They are simply grayish translucent cords of varying diameter; they are indistinctly longitudinally striated, and are intimately connected with one another by frequent inosculations. The fibres seem to divide and send off oblique branches to join neighboring fibres. Flattened, elongated nuclei lie at frequent intervals upon the surface of the fibres. These fibres considerably resemble, in their general appearance, the fibrillated fibres of ordinary connective tissue, but careful examination shows them to be entirely distinct structures.

They are grouped in bundles to form nerves, sometimes alone, but very frequently in connection with medullated nerve-fibres. Thus, in the pneumogastric, we find a considerable part of the fibres to be non-medullated, and intimately bound in, by the intrafascicular connective tissue, with medullated fibres. The non-medullated fibres originate in nerve-cells of a peculiar structure, to be presently described; but of their peripheral terminations we know almost nothing.

II. NERVE-CELLS.

Nerve-cells, or *ganglion-cells*, as they are frequently called, although presenting the greatest diversity in form, have yet some quite distinctive characters in common. The cell-body is finely granular and delicately striated, often containing pigment-granules. The nucleus is large, well-defined, vesicular in appearance, and usually contains a large shining nucleolus. They all have at least one process, most of them have more; and they are hence often classified as *unipolar*, *bipolar*, *multipolar* ganglion-cells. The above-mentioned striations in the cell-body are often seen to continue out into the processes, and are apparently continuous with the striations or fibrils of the axis-cylinder of the nerves.

In many nerve-cells, especially in the spinal cord, we recognize two distinct kinds of processes: first, those which, soon after leaving the cell, divide and subdivide until they become extremely fine and delicate, and, in some cases, seem to join equally fine processes of other cells—such delicate cell-processes make up a considerable portion of the gray matter of the cord, and are called *branching processes*; second, such as pass off from the cell, and, without dividing, presently are surrounded by a sheath of myelin, and become medullated nerve-fibres; the latter are called *axis-cylinder processes*.

Nerve-cells vary greatly in size, and although the forms which they present are most diverse, we yet find that a considerable proportion of those found in different parts of the nerve-centres have certain broadly typical forms. Thus, among the cells in the gray matter of the spinal cord, we find larger and smaller fusiform or spheroidal branching cells, and, which are more characteristic, large, irregular-shaped cells, with several branching processes and a well-defined axis-cylinder process. In the cortex of the cerebrum, while we find variously shaped larger and smaller cells, we find also characteristic pyramidal cells of varying size, which give off processes from both the base and apex. In the cerebellum, we find just at the inner edge of the gray cortical matter, irregular globular or ovoidal cells, which, from the side toward the surface of the brain, send off one or two branching processes; on the opposite side we can usually demonstrate the commencement of a single delicate process, which is supposed to correspond to the axis-cylinder process, though, since it almost invariably breaks off near the cell in the attempt to isolate the latter, its nature is not yet definitely determined. These cells are called *Purkinje's cells*.

The *ganglion-cells of the sympathetic* are usually globular or ovoidal, and are peculiar in that each cell is surrounded by a distinct capsule of connective tissue, lined with flattened cells, resembling endo-

thelium. They have one or more processes which pierce the capsule and become non-medullated nerve-fibres.

PRACTICAL STUDY.

Fresh Nerve.—A bit of fresh nerve—the sciatic of the frog answers very well—should be carefully and rapidly teased apart longitudinally, in one-half-per-cent. salt solution—care being taken to pull apart the fibres from the ends, so as to break them as little as possible,—and covered; pressure from the cover-glass being avoided by placing a bit of paper or hair beside the specimen. The nerve-fibres present, if examined at once, in many parts, a sharp and regular double contour, which is their normal appearance, and along their course the constrictions and nuclei may here and there be seen. The axis-cylinder and neurilemma are for the most part invisible; the former owing to the lack of transparency in the medullary sheath, the latter because of its extreme thinness and close contact with the medullary sheath. Very soon, at once in some parts of the specimen, the contours of the fibres will be seen to become irregular, the myelin shrinking away at some parts from the neurilemma, and swelling out at others. At the severed ends of the fibres the myelin will be seen welling out from the neurilemma, and breaking off into the fluid in irregular globular or contorted masses.

After the swelling and irregular breaking up of the myelin has occurred—this may be hastened by allowing water to run under the cover-glass—the neurilemma may be seen here and there stretching across between the va-

ricosities formed by the swollen myelin, and either at the broken ends of the fibres or along their course, the axis-cylinder may occasionally be seen.

✓ *Nerve-fibres Treated with Osmic Acid.*—The most complete demonstration of the nerve-fibre may be obtained by treatment with osmic acid. This agent fixes the myelin and other constituents of the fibre nearly in their normal form, staining the myelin black. In applying this agent it is necessary to maintain the nerve in a state of gentle tension, because it is otherwise somewhat contracted and distorted. This is done by gently stretching the nerve—the sciatic of the rabbit will answer—along a bit of wood which has been whittled away at one side, so that the nerve may lie free. It is fastened by the ends to the wood by threads. The nerve thus prepared is immersed for twenty-four hours in an aqueous solution of osmic acid (1 to 100), then washed, and a small bit carefully teased apart longitudinally in glycerin. In such a preparation nearly all the structures in the fibre can be readily seen: the constrictions and nuclei, the medullary sheath stained black, the incisures of Schmidt, and where, as will almost always occur in some parts of the specimen, the medullary sheath has been broken across, or the segments pulled asunder, or the myelin has contracted at the constrictions, the neurilemma and axis-cylinder. Not infrequently, if the teasing has not been very carefully done, the segments of the medullary sheath are broken across in many places and separated, giving the fibre a beaded appearance.

Transverse Sections of Nerves Stained with Osmic Acid.
—A nerve treated as above with osmic acid is not firm.

enough to permit the making of thin sections, and should be hardened by what is known as the *gum embedding method*, as follows: a bit of the nerve, after the osmic acid treatment, is immersed for twenty-four hours in alcohol, soaked for a few moments in water, to remove the alcohol, and immersed for twenty-four hours in a syrupy solution of gum-arabic, then put again for twenty-four hours in alcohol. By this process the gum is precipitated by the alcohol in solid form in the interstices of the fibres, giving it sufficient consistence for cutting. The sections (which must be very thin), either stained with picro-carmin or unstained, are mounted in glycerin. In such a preparation the uncolored axis-cylinder is seen surrounded by a black ring, the medullary sheath, and here and there the nuclei of the neurilemma are seen at the edge of the fibres. The connective tissue surrounding the fibres has a grayish color. The nerve-fibres will be seen to have varying diameters and to present marked differences in form, some of them depending upon artificial changes, others upon the difference in level at which the fibres have been cut across.

Transverse Sections of Nerves Preserved in Chromic Acid.—Bits of the sciatic nerve from the rabbit or any other mammal should be lightly stretched along a bit of wood and placed in a solution of chromic acid (1 to 500); in two weeks it is washed and transferred to alcohol. It is now embedded in gum (see above),* and thin transverse sections made and stained double and mounted in balsam. In such preparations the general relation of connective tissue to the nerve-fibres is well seen.

Nerve-fibres Treated with Nitrate of Silver.—By this

* Better in celloidin.

method we obtain hints concerning the structure of nerves which are of no little significance from a physiological point of view. A fresh nerve is slightly teased apart on a slide, a large drop of a one-half-per-cent. solution of nitrate of silver added and allowed to remain for four minutes ; this is washed off with one-half-per-cent. salt solution, the specimen transferred to a drop of glycerin on another slide, the fibres carefully teased apart, and covered. The preparation is now exposed to sunlight or diffuse daylight until it becomes brown. If now examined, at tolerably regular intervals along the fibre, tiny brown or black crosses, called *Ranvier's crosses*, will be seen ; the transverse arm of the cross being the stained cement substance between the neurilemma segments at the constrictions ; the longitudinal arm, which coincides with the axis of the fibre, and which is longer or shorter, depending upon the length of time to which the fibre was exposed to the action of the silver, is the axis-cylinder. If the specimen be allowed to remain longer than the above time in contact with the silver, the longitudinal arm of the cross will be longer.

It is to be observed that the axis-cylinder is first stained at that part which passes through the constrictions, and not along the segments. Certain other soluble substances which stain the axis-cylinder comport themselves in the same way. We infer from this that at the constrictions certain substances in solution can pass into the fibre and come in contact with the axis-cylinder, or the nerve-element proper of the fibre. This inference is significant in connection with the nutrition of the nerves, since we are justified in assuming that nutritive substances in

solution may pass also to the axis-cylinder in the same way.

It is not improbable that the constrictions serve yet another important purpose. The myelin of the medullary sheath being a semi-fluid substance—perhaps serving either to isolate the axis-cylinder or protect it from external violence—it would inevitably tend to gravitate to the lower parts of the nerves, were it not that it is held in position by being enclosed, so to say, in cylindrical cases, *i. e.*, the neurilemma-cells, between the constrictions.

The *non-medullated nerve-fibres* may be demonstrated in connection with the sympathetic ganglion-cells; see below.

1. *Nerve-cells : a. Spinal Cord.*—Small bits of the gray matter from the spinal cord of man, or from the ox or sheep, should be put for ten days in a dilute solution of chromic acid (one to five hundred), and then carefully shaken in a test-tube with water colored lightly with carmine; when the bits have become thoroughly broken up into small particles, the tube is allowed to stand for a day or two, until the particles which have settled to the bottom are sufficiently stained. The supernatant fluid is then decanted, and with a glass tube a small drop of the disintegrated tissue is conveyed to a drop of glycerin on a slide and covered, pressure on the cells being avoided in the usual way. If the first preparation does not contain the required cells, others should be made. In this way, if the shaking be carefully done, the ganglion-cells are freed to a considerable degree from the surrounding parts, and such may be found as present numerous long branching processes, as well as the axis-cylinder process.

In addition to the cells, such specimens present fragments of connective-tissue, bits of naked axis-cylinders, and medullated nerve-fibres, myelin-droplets, etc.*

b. Brain.—In the way above described, cells should be prepared from the gray cortical portion of the cerebrum and cerebellum.

c. Sympathetic.—For the demonstration of these cells, and the fibres connected with them, the frog answers very well. The animal having been killed by breaking up the medulla, the abdominal cavity is opened, and the intestines and liver carefully removed; the aorta will then be seen lying along the vertebral column. The sympathetic ganglia and nerves lie along the walls of the aorta, and in the tissue surrounding the origin of the spinal nerves. The head and forelegs should now be cut off close behind the latter, and the hind legs severed close to the body; the trunk is then laid in a small dish, and covered with equal parts of one-per-cent. solution of osmic acid, alcohol, and water. The dish is covered and set aside for twenty-four hours, when the aorta, together with the tissue surrounding the commencement of the spinal nerves, is dissected off in a single piece, spread on a slide, and examined with a low power. Groups of sympathetic nerve-cells are seen here and there in the specimen, and are readily distinguished by the orange color of the cells: one or two of them are to be isolated and freed as much as possible from the enclosing tissue, carefully teased apart on a slide, stained lightly with hæmatoxylin and then with eosin, and mounted in glycerin. Successful preparations will show not only the nerve-cells and non-medullated nerve-fibres, but also the connection of the two within the capsule.

* Neuroglia or "spider cells" may also be seen. See Appendix, p. 254.

CHAPTER VIII.

BLOOD-VESSELS—LYMPHATIC VESSELS.

BLOOD-VESSELS.

Blood-vessels are of three kinds: *arteries*, *veins*, and *capillaries*. Although merging without sharp demarcation into one another, these vessels, in their typical forms, present distinct differences in structure. The capillaries being the simplest, it will be convenient to commence with them.

If we examine a capillary vessel, either fresh or after it has been in preservative fluids, it presents the appearance of a narrow tube, with very thin, homogeneous walls, in which, at frequent intervals, elongated nuclei are embedded, their long axes being parallel with the axis of the tube. If, however, we inject the vessels with a dilute solution of nitrate of silver, and expose them to the light, we find that the inside of the tube is divided by narrow black lines into elongated, irregular-shaped spaces; and if we then stain the specimen with hæmatoxylin, we find that a nucleus lies in each space. The walls of the capillaries are, then, not formed by a homogeneous membrane, but made up of cells having the character of endothelium. *The capillaries are*

endothelial tubes. This layer of endothelial cells, which alone forms the walls of the capillaries, is found lining all the other blood-channels, arteries and veins, as well as the heart. In the blood-vessels it is called the *intima*.

If, now, we follow the capillaries in a direction toward the arteries, we find that the connective tissue in which they lie is arranged in the form of a thin layer along their walls. This layer, which is also present in all arteries and veins, is called the *adventitia*. Almost as soon as we find the *adventitia*, we notice another layer between it and the *intima*, formed of a single row of smooth muscle-cells, or of scattered cells, wound transversely or obliquely around the vessel. This layer is called the *media* or *musculosa*, and a vessel having these three simple layers in its walls is called an *arteriole*. In these three layers, *intima*, *media*, and *adventitia*, we have the types of all the layers which occur in the walls of the largest and most complicated blood-vessels. The individual layers become, indeed, more complex in structure; but, with the exception of elastic elements, no new tissues appear.

Turning now to a larger artery—the radial, for example—and examining the various layers in its walls, we find that the *intima* is no longer formed of a simple endothelial tube, but that outside of this a new layer has appeared, composed of ill-defined fibrillated and of elastic fibres, among which

lie large, flattened branching cells. This layer is called the *intermediary layer* of the intima, and is sharply separated from the media by a fenestrated, elastic membrane, called the *membrana elastica intima*, which in contracted vessels is usually folded. The media presents here quite a thick layer of smooth muscle-cells, passing transversely around the vessel, and among these we find a few elastic fibres, which are connected with the elastic elements in the intima and adventitia. The adventitia is thicker, and consists chiefly of fibrillar connective tissue with elastic fibres.

In the larger arteries, such as the carotids, aorta, etc., we find that the individual layers are considerably less sharply defined. The three layers of the intima are much less distinct; in the media the elastic tissue is very abundant, taking the place, to a considerable extent, of the muscular elements; it is arranged in irregular lamellæ and fibres, between which lie fibrillated fibres, and connective-tissue and smooth muscle-cells, the latter no longer all lying uniformly transversely to the axis of the vessel. In the adventitia also of the large vessels the elastic elements are very numerous, being most abundant in the vicinity of the media. In the adventitia of some of the large vessels, smooth muscle-cells occur, arranged usually with their long axes parallel with the axis of the vessel.

The *walls of the veins*, like those of the arteries,

consist of three layers, and these layers have in general an analogous structure; but they are neither as distinct, nor are their structural features as constant, as those of the arteries. Moreover, we find that veins of the same calibre present, in different parts of the body, marked differences in structure, and, unlike the arteries, the thickness of their walls is not uniformly proportional to the calibre of the vessel. In general we may express the structural difference between veins and arteries by saying that in the walls of the former the elastic and muscular elements are much less, while the connective-tissue elements are more abundant, than in the walls of the latter. Now, since the muscular and elastic elements are the chief constituents of the media, and the fibrillar connective-tissue elements, of the adventitia, we find, in general, that in the veins the media is less, while the adventitia is more developed. The intermediary layer of the intima is entirely absent in small veins; in many of medium size it appears, and is again absent in the largest vessels. In some veins, such as those of the bone, central nervous system, retina, etc., the muscular elements are almost or entirely absent. In certain other veins, on the contrary, such as the v. portarum, v. renalis, the adventitia contains a great abundance of muscular elements arranged parallel with the axis of the vessel.

The walls of the larger arteries and veins contain blood and lymph-vessels, called *vasa vasorum*.

The *valves of the veins* consist of bundles of fibrillar connective tissue arranged to form a membranous projection from the walls of the vessels—the bundles being arranged, in general, in a direction parallel with the free edge of the valve. They contain also a net-work of elastic fibres, which, at that surface of the valve which is exposed to the blood-current, form a dense layer like the intermediary layer of the vein-wall itself. The whole free surface is covered with endothelium like that lining the general surface of the vessel.

ENDOCARDIUM AND VALVES OF THE HEART.

The *endocardium*, which differs somewhat in thickness and structure in different parts of the heart, consists, in general, of a membranous expansion of fibrillar connective tissue, with elastic fibres and smooth muscle-elements, which lines the cavities of the heart, and is covered on its free surface with a layer of endothelial cells.

If we examine sections made perpendicular to the surface of the endocardium, we find that just beneath the endothelium is a layer of fibrillar connective tissue, with flattened cells, reinforced by a net-work of elastic fibres, which become coarser and more abundant in that portion of the layer lying farthest from the heart-cavities. In this layer are smooth muscle-cells running in various directions. Outside of this layer, and joining it to the muscular tissue

proper of the heart, is a layer of loose fibrillar connective tissue, in which the blood, lymphatic vessels, and nerves lie embedded.

The *valves of the heart* consist of fibrillar connective tissue, arranged in membranes or fascicles, and associated with elastic tissue, the latter being most abundant at the free surfaces of the valves; and here it is present in the greatest quantity and density on the surface which is most directly exposed to the current of blood—that is, on the auricular surfaces of the tricuspid and mitral, and on the ventricular surfaces of the aortic and pulmonary valves. The elastic elements are also more abundant in the valves of the left than of the right side of the heart. The firmness and capacity for resistance of the elastic tissue being borne in mind, the significance of its distribution in the valves will be readily perceived; where they are the most exposed to the impact and pressure of the blood, there they are the most firm and dense.

LYMPHATIC VESSELS.

The larger lymphatic vessels have a structure quite similar to that of the veins, and like the latter they are supplied with valves. They approach the arterial type, however, in that the muscular fibres are quite abundant in proportion to the thickness of the walls, although the walls themselves are very thin in proportion to the size of the lumen. Fol-

lowing the larger lymphatics toward the periphery, we find that they pass over into irregular-branching and pouching channels, the walls of which consist of a single layer of endothelial cells, whose edges are very sinuous, dovetailing into one another like the pieces of a child's puzzle-map. These channels are called *lymphatic capillaries*. Between these and certain spaces or lacunæ in the tissues—those, for example, in which the connective-tissue cells lie (see page 44)—there seems to be a direct communication, by means of which fluids, and probably formed elements, such as blood-cells, pass over from the blood into the lymphatic vessels.

PRACTICAL STUDY.

Capillaries.—The general appearance of the capillaries, as well as of the smaller arteries and veins, is best seen in those parts in which the vessels are surrounded by but little tissue, as in thin membranes such as the mesentery or pia mater. A slice about an inch thick should be made from the surface of the cerebrum and laid for twenty-four hours in Müller's fluid.¹ A small fragment from that part of the pia which dips into the sulci should now be carefully separated from the brain substance, stretched on a bit of thin cork, and fastened with pins. It is then laid for twenty-fours each, in dilute and strong alcohol, and finally stained in picro-carmin and mounted in glycerin ; or stained double and mounted in balsam.

¹ The normal relations of the parts are much better preserved by a preliminary hardening in this way before the pia is removed from the brain, than if it is removed while quite fresh.

In such a preparation, although we see the elongated nuclei in the capillary wall, we cannot, as a rule, make out the outlines of the cells. To accomplish this we have recourse to the use of dilute solutions of nitrate of silver. This can be applied by immersing some thin membrane, such as the mesentery, for an hour in a solution of nitrate of silver (1-500), brushing off the endothelium from the surface, and exposing the specimen in water to the light, until it becomes brown. Or, what is better, the entire vascular system of a small animal, such as a frog, may be first rinsed out with water through a canula introduced into the aorta and attached to a syringe, and then injected with the above silver solution. Thin membranes, such as the mesentery or bladder, are removed from the animal, exposed to the light for a sufficient time, and then, either stained or unstained, mounted in glycerin.*

Arteries and Veins.—Very small vessels can be studied entire, since by careful focussing we can bring one portion after another into view, obtaining thus what are called *optical sections*.

The arterioles may be prepared by pulling out some of the arteries which enter the brain substance; at the ends of these the arterioles into which they divide are seen. Some of the finer twigs are cut off, stained double, mounted in balsam, and studied entire.

In larger vessels this simple method is no longer practicable, and we have to resort to actual sections. Small- or medium-sized arteries and veins may be prepared by stretching them, when fresh, along a bit of wood, with pins, and allowing them to dry. The dried vessels are placed between two bits of soft cork or elder-pith, and

* See Appendix, p. 254

thin sections shaved of, in any desired direction, with a hard-tempered dry razor. The sections swell out on being dropped into water; they are then stained double and mounted in balsam.

Larger vessels, such as the aorta, vena cava, etc., may be hardened in alcohol, embedded in liver, and the sections stained and mounted as before.*

Heart-valves and Endocardium.—These may be studied in thin sections made perpendicular to the surface of the valves, and the inner surface of pieces of the heart, which have been stretched on cork and hardened in alcohol.

Lymphatic Vessels.—A general view of the relation between the larger lymphatic trunks and the lymphatic capillaries, is best obtained by studying nitrate of silver preparations of some part in which the latter are abundant. Such a structure we find in the tendinous portion of the diaphragm—so called *central tendon*—of the rabbit, which is very thin, covered on both sides with endothelium, and very richly supplied with lymphatic vessels.

To prepare the central tendon, a rabbit should be killed by breaking up the medulla, and the thoracic and abdominal cavities freely opened by incisions above and below the anterior line of attachment of the diaphragm. Two ligatures are passed around the large vessels above the diaphragm, to prevent the escape of blood on to the part, the vessels cut across between them, and the heart and lungs removed from the chest. The suspensory ligament of the liver is now severed, and the diaphragm is left free, stretching across between the thoracic and abdominal cavities. Its upper surface is brushed with a soft pencil moistened with water, so as to remove the sur-

* These structures may all be embedded in celloidin.

face endothelium and allow the silver to penetrate readily into the lymphatics. The surface is now carefully washed, and a one-half-per cent. solution of nitrate of silver is allowed to run over it and remain for five minutes in contact with it. This is now washed off with water, the diaphragm carefully cut out and pinned to a cork, so as to lie flat, and exposed to the light in dilute alcohol till it becomes brown. Small pieces are then cut out from the tendinous portion and mounted in glycerin. In such a specimen the large lymphatic channels will be readily recognized, lined with elongated endothelium like that of the blood-vessels, and furnished with valves, which appear here and there as curved lines crossing the vessel. The capillaries may be recognized by their irregular shape and sinuous endothelium.

CHAPTER IX.

LYMPH-NODES—SPLEEN.

LYMPHATIC GLANDS OR LYMPH-NODES.

IF we follow the lymphatic vessels in their course from the periphery toward the thoracic duct, we find that, sooner or later, they are interrupted in their course by certain nodular masses, more abundant in some parts of the body than in others, and of variable size, commonly called *lymphatic glands*. They are not glands in the limited sense of the word, for, so far as we know, they furnish no specific secretion, they have no excretory ducts, and seem to have an entirely different structure and function from the glands proper. It would be better to call them *lymph-nodes*, for that would not be misleading, as the word gland is, in regard to their relations to other structures; but, as they are universally known as lymphatic glands, we shall at present use both terms. The lymph-nodes present a great diversity in form, being spherical, ovoid, discoidal, or irregularly prismatic; they always present at one side a hilus, at which the larger blood-vessels enter.

If we make a section through a fresh gland, at

right angles to its long axis and through the hilus, we find it more or less distinctly divided into two zones: an outer, or cortical zone—*the cortex*—which is soft and grayish or reddish in color, and divided into ovoidal or irregular-shaped masses; and an inner, or medullary zone—*the medulla*—adjacent to the hilus, which is firmer, and has a more uniform, or sometimes irregularly reticulated, grayish, or brownish-red surface.

The nodes are surrounded by a firm, dense *capsule* of connective tissue, with a few elastic fibres and smooth muscle-cells. The capsule sends inward numerous partitions or *trabeculæ*, which divide the cortex into a series of intercommunicating chambers, and the medulla into numerous irregular connecting passages. These septa are formed of the same elements as the capsule, and at the hilus are continuous with a dense mass of connective tissue, through which the blood-vessels enter the organ. If we examine the spaces left between the septa, we find that in the cortex they are incompletely filled with ovoidal or globular bodies, which are continuous with cord-like anastomosing structures lying in the narrower and irregular spaces in the medulla; the bodies in the cortex are called *lymph-follicles*, and the cord-like structures in the medulla, *lymph-cords*.

If, now, we examine more minutely the structure of the lymph-follicles, we find that they consist, in

the first place, of a framework of reticular connective tissue, whose meshes are largest in the centre of the follicle, narrower and smaller in the periphery; indeed, so closely crowded together are the trabeculæ here, that they give to the follicle a tolerably well-defined outline. In the second place, the meshes of the reticulum are closely filled with small spheroidal cells, having, in general, the characters of lymph-cells; in many of them, however, the nucleus is very large, occupying the greater part of the cell. The follicles do not entirely fill the cavities in which they lie, but are surrounded on all sides by a narrow space.

If we examine the relation of the follicles to the walls of their investing spaces, we find that, from the walls of these spaces, delicate branching trabeculæ pass inward to the surface of the follicle, where they become continuous with the reticular tissue of the latter. They are, in fact, themselves reticular connective tissue, similar to that of the follicle, except that the trabeculæ are coarser and the meshes broader. Stretching across the space surrounding the follicles, they suspend the latter so that they hang free in the cavities. The space thus formed around the follicles is called the *perifollicular space*, or, better, *lymph-sinus*, for reasons which will be presently given.

If we now turn our attention to the lymph-cords of the medulla, which, it will be remembered, are

continuous with the follicles, we find that they have an exactly similar structure, and bear the same relation to the more irregularly arranged connective-tissue septa which bound the branching spaces in which they ramify, that the follicles do to the walls of their investing spaces, *i. e.*, they are suspended in them by coarse trabeculæ of reticular connective tissue, and surrounded on all sides by lymph-sinuses. These lymph-cords, ramifying and inosculating in the medullary portion of the gland, form an intricate system of intercommunications between all the follicles of the gland. Injections of dilute solutions of nitrate of silver into the lymph-sinuses show that the surfaces of the follicles and lymph-cords, as well as the walls of their investing spaces, are covered with endothelium.

If we study the relation of the lymph-vessels to the lymph-nodes, we find that the former, on arriving at the surface of the node—*afferent vessels*—pierce the capsule and become continuous with the lymph-sinuses, into which they pour their contents; we find, further, that *efferent vessels*, still continuous with the sinuses, leave the organ at other points, frequently at the hilus. The lymph-glands, then, are structures interrupting the course of the lymphatic vessels, in which the lymph is forced to pass through a series of irregular-branching spaces or sinuses, bathing in its course certain peculiar structures—the follicles and lymph-cords—whose function

we do not yet understand. The lymph-sinuses contain not only the fluid of the lymph, but numerous lymph-cells, and usually a certain number of red blood-cells.

The principal blood-vessels enter the nodes at the hilus, and the arteries, sending off branches to the connective tissue there and to the septa, divide and subdivide, and soon enter the lymph-cords; they pass along in the axis of these, giving off a long-meshed capillary system; then entering the follicles, they break up into a loose capillary net-work, from which the blood is collected into venous radicles, and poured into veins which pass out through the lymph-cords and out of the organ in connection with the arteries. Small blood-vessels usually enter the capsule at other points than the hilus, and are largely distributed to the capsule and the connective tissue of the septa.

The number and arrangement of the follicles vary greatly in different lymphatic glands: in some there is but a single layer in the cortex; in others, several layers are superimposed and more or less crowded—thus giving to some glands a narrow, to others a broad and voluminous cortex. In many animals, as the ox, the reticular tissue of the medullary portion contains an abundance of brown pigment.

There are, in many parts of the body, small dense masses of tissue, some of them sharply circumscribed,

others diffuse and merging into adjacent tissues, which seem to be somewhat analogous to the lymph-nodes, although not, as a rule, forming well-defined organs. Thus we find in the intestines and stomach, either single or in clusters, circumscribed nodules of reticular connective tissue, whose meshes are filled with small spheroidal cells, and resembling in most respects the follicles in the cortex of the lymph-nodes. These, which will be more fully considered when we study the gastro-intestinal canal, are called the solitary follicles of the stomach and intestines, and Peyer's patches. Less well defined than these, we find scattered in various parts of the body, larger and smaller diffuse collections of small spheroidal cells, lying in a reticular stroma, and forming the so-called *lymphoid tissue*, which recent investigations have shown to be of no little importance under certain pathological conditions, although of their relations to the lymph-vessels or their physiological significance we know very little. These diffuse collections of lymphoid tissue are found in the mucous membrane of the bronchi, beneath certain serous membranes, in the liver, kidneys, and elsewhere, and may be seen in the preparations of these parts presently to be studied.

PRACTICAL STUDY.

Lymph-Sinuses Injected.—A general view of the lymph-sinuses and their relations to the follicles and cords is

best obtained from sections of nodes whose lymph-channels have been filled with a colored solution of gelatin. A gland being exposed in a recently killed animal—one of the cervical glands of the dog answers well—a hypodermic syringe is warmed and filled with the warmed blue gelatin mixture; the canula is now thrust through the capsule at any point, and the fluid injected. The node will become mottled with blue, and the mass will often be seen to flow into adjacent nodes. If it be not desired to inject more than one, a ligature should be passed around the vessels leading to the others. When a sufficient quantity of the fluid has been injected to render the gland firm and the capsule tense, the canula is withdrawn, and the node cooled by ice or cold water. When the gelatin has solidified, the gland is cut out, divided longitudinally, and put into strong alcohol. When it has become sufficiently hard, sections are made through the entire gland, stained with picro-carmin or eosin, and mounted in balsam.

Shaken Section of a Lymph-node.—The meshes of the follicles and cords, as well as the lymph-sinuses, are so closely crowded with cells, that the structure of the supporting tissue cannot be clearly made out, even in very thin sections, without removing some of the cells. This may be done by shaking in water, as in the preparation of reticular connective tissue p.55). When the operation is completed—which will be determined by the extreme thinness which the section presents when most of the loose cells are removed—it is floated, without folds, on to a slide, stained double and mounted in glycerin.

Blood-vessels.—To obtain an injection of the blood-

vessels of the lymph-nodes, either a whole animal, such as the rabbit or dog, may be injected through the aorta, with the blue gelatin mixture ; or a single gland, such as the cervical or mesenteric, may be injected through its main artery. The glands should be hardened in alcohol, and the sections stained deeply with eosin and mounted in balsam.

THE SPLEEN.

The spleen, although differing in many important and probably most essential particulars from the lymphatic glands, yet presents many striking analogies with them. Like them, it presents, on cross-section, to the naked eye, a fibrous envelope—the *capsule*,—from which septa and trabeculæ pass into the organ, enclosing irregular spaces. Here also we find the spaces between the septa filled with a soft substance presenting two distinct modes of arrangement ; we find first, irregularly scattered through the organ, small grayish globular or elongated structures, called *Malpighian bodies*, or *follicles* ; and, second, between these, filling up the remaining space between the trabeculæ, a soft red tissue called the *pulp*.

Finally, we find blood-vessels entering the organ at the hilus. We have, then, in studying the spleen, to consider the *connective-tissue capsule and trabeculæ*, the *follicles*, the *pulp*, and the *blood-vessels*.

The *capsule* of the spleen consists of a dense en-

velope of interlacing connective-tissue fibres with flattened cells, with a large number of fine elastic fibres and a few smooth muscle-cells. It is covered by a layer of endothelial cells similar to those of the general peritoneal surface. At the hilus it passes inward, forming a sheath for the large vessels, and joins a complicated system of *septa* and *trabeculæ*, which, proceeding inward from all parts of the capsule, form a multitude of irregular communicating spaces in which the follicles and splenic pulp lie. These trabeculæ and septa are made up of the same elements as the capsule, and in size and abundance vary greatly in different animals, being in man only moderately developed. The *follicles*, or *Malpighian bodies*, have essentially the same structure as the follicles of the lymph-nodes—that is, they are formed by a small mass of supporting reticular connective-tissue, whose meshes are narrowest at the periphery, and closely filled throughout with small spheroidal cells, and supplied with a net-work of capillaries; we usually find here, however, a small artery passing either through the centre or at one side of the follicle.

But in order to fully understand the follicles of the spleen, it is necessary to study their relation to the arteries, in which respect they seem entirely to differ from their analogues in the lymph-nodes. The arteries and veins as they enter the hilus of the spleen are surrounded, as above mentioned, by a

connective-tissue sheath ; after passing for a short distance inward, they separate, and the arteries, still accompanied by a certain amount of connective tissue, divide and subdivide, proceeding farther inward, until the small branches finally break up into brush-like bundles of delicate twigs. If, now, we carefully study the walls of the smaller arteries, we find that in certain parts they undergo a singular modification : at first the connective-tissue sheath and the adventitia become very loose in texture, and their meshes become filled with spheroidal cells resembling lymph-cells—this is called *lymphoid infiltration of the walls of the arteries* ; then we find that at certain points this infiltration becomes quite extensive, the intercellular substance assuming the character of reticular connective tissue ; and thus distinct spheroidal or much elongated swellings are formed either around or at one side of the arteries—these are the *splenic follicles* or *Malpighian bodies*.

In some animals this infiltration is quite extensive and continues along the arteries for a considerable distance at either side of the follicles ; in others, as in man, it is not very marked except in the follicles, but may frequently be seen along the arteries adjacent to them, in the form of narrow cellular sheaths. The capillary net-work of the follicles is connected with arterial twigs which either penetrate from without, or are given off from the follicular artery as it passes through the body.

Let us now turn to the *pulp*. This is composed, in the first place, of a multitude of irregular, frequently anastomosing cords—called *pulp-cords*—between which, and bounded closely by them, lie, in the second place, a series of branching channels—the *cavernous veins*. The pulp-cords—joined on the one hand to the follicles and infiltrated arterial sheaths, and on the other to the connective-tissue septa—consist of a framework of delicate reticular connective tissue, continuous with the sustaining tissue of the follicles, the meshes of which are incompletely filled with various kinds of cells. Among these cells we find spheroidal cells, like lymph-cells; larger colorless cells with one or more large nuclei; red blood-cells; fragments of red blood-cells; larger and smaller colorless cells containing pigment in various forms. Finally, there are sometimes found in varying number, cells which resemble the lymph- and larger colorless cells in form, but whose bodies, either homogeneous or granular, have a color similar to that of the red blood-cells. These latter cells, like certain similar cells already mentioned as occurring in the marrow of bones, are called nucleated red blood-cells, and are regarded by many observers as intermediate forms between the colorless and the red blood-cells. Although many recent observations would tend to confirm this idea, their nature is as yet by no means absolutely determined.

We have still to consider the structure of the second constituent of the pulp—the cavernous veins. Following the splenic veins inward from the hilus, we find that they gradually lose their connective-tissue sheath, and then their outer coats, and then rapidly divide and subdivide to form a multitude of intercommunicating thin-walled canals of tolerably uniform calibre, which occupy the irregular-branching spaces between the pulp-cords. These ultimate venous trunks are called *cavernous veins*, and their walls consist of little else than a few widely separated, branching, circular and oblique fibres, upon which lie, at varying intervals, elongated, curved, spindle-shaped, and flattened endothelial cells, which have their long axes parallel with the axis of the canal. These veins, whose walls, as will be seen, are not closed but fenestrated, are in direct communication with the spaces which are still left in the meshes of the pulp-cords by the cells which incompletely fill them.

Still another point remains to be considered, namely, the course of the blood after its exit from the above-described fine arterial twigs on which the Malpighian bodies are formed, until it enters the fenestrated cavernous veins of the pulp. The opinion of different observers on this point differs somewhat, owing to the extreme technical difficulties in the investigation; but it seems probable that after passing out of the fine arterial twigs, through

the intervention of the capillaries it is poured directly into the meshes of the pulp-cords, and that after circulating here around the cells, *without distinctly walled channels*, it finally finds its way through their fenestrated walls into the cavernous veins, whence it passes out of the organ through the large efferent veins at the hilus.

PRACTICAL STUDY.

Sections of Uninjected Spleen. a. Cat.—A general view of the arrangement of the different structures of the spleen may be obtained from very thin sections of a cat's spleen hardened in bichromate of potassium and alcohol. They are stained double and mounted in balsam. *b. Human.*—Structural details may be studied in a section from a human spleen hardened as above. Before mounting, the sections should be placed in a shallow, flat-bottomed dish, and just covered with water; with a fine camel's hair pencil, held perpendicularly, the section is gently tapped until it appears thinner and more transparent from the brushing out of the loose cells. It may then be stained double, and mounted in glycerin or balsam.

Section of Spleen with Injected Cavernous Veins.—A spleen is injected, under low pressure, through the vein, with the blue gelatin mixture, hardened in alcohol, stained deeply with eosin, and mounted in balsam.

Isolated Cells of the Spleen.—A bit of the fresh organ is teased on a slide in a half-per-cent. salt solution, and studied in the same. Should the red blood-cells, as is

apt to be the case, be so numerous as to conceal the other forms, a drop or two of dilute alcohol (one to two) is allowed to run under the cover-glass, and after a few moments the red blood-cells will have become so transparent as not seriously to interfere with the observation. If the nuclei are not sufficiently well defined, a drop of eosin may be added after the alcohol. In addition to the above-described cells of the pulp-cords in teased specimens, narrow, elongated, often curved cells, with projecting nuclei, are frequently seen ; these are the above-described lining cells of the cavernous veins.

CHAPTER X.

THE GASTRO-INTESTINAL CANAL.

THIS canal is a tube varying greatly in its calibre in different parts, and continuous at either end with the external surface of the body. In certain parts of its course it is intimately connected with adjacent structures; but, for the most part, it is attached only at one side by a structure—the mesentery—which serves to convey to it its blood- and lymphatic-vessels and nerves. The walls of the tube, although varying in structure in different sections, consist in general of a *muscular layer*, a *mucous layer* lining the tube, and, in those parts where it is suspended in the abdominal cavity, a *serous layer* covering it.

Confining our attention to the stomach and intestines, we find that these layers are not simple, but have each a composite structure; thus, we find in the serosa, a layer consisting chiefly of dense fibrillar connective tissue, *subserosa*, covered with a layer of *endothelium*. The muscular tunic, or *musculosa*, consists of two layers of smooth muscular tissue: an *external*, in which the cells lie longitudi-

nally, and an *internal* in which they lie transversely to the axis of the canal. In certain parts of the stomach an indistinct third layer is found, in which the cells have an oblique course. Inside of the muscularis and joining it to the mucosa, is a layer of loose fibrillar connective tissue, called the *submucosa*, in which the blood and lymphatic vessels ramify. In the mucosa, finally, we have a delicate supporting framework of connective tissue, varying somewhat in its structure and abundance in different parts of the canal; this is covered by epithelial cells and contains the glandular apparatus, while at the base of the glands and adjacent to the submucosa is a thin layer of smooth muscle-cells, lying in both transverse and oblique directions, called the *muscularis mucosæ*, from which usually a few muscle-cells pass up between the glands.

The chief differences in minute structure between the stomach and intestines are in the mucous membrane, and since in this the glands are very important factors, a word should be said here about the structure of *glands in general*.

Although the term gland is popularly applied to structures having the greatest diversity of form and function, and little in common but their name, we mean by it here, those organs whose physiological activity expresses itself, in part at least, by the elaboration of certain specific fluids, secretions, or excretions. All such glands have a somewhat analo-

gous structure, and present two distinct kinds of structural elements: 1. epithelial or gland-cells; 2. a connective-tissue framework, with blood- and lymphatic-vessels and nerves. The epithelial cells, usually large, differ in form in different and even in the same glands: in the latter case especially, when the gland is divided into a secreting and excretory portion. They will be described when we study the glands in detail. The connective tissue, varying greatly in amount in different glands, is sometimes arranged in sheets and bundles so as to form variously shaped cavities which are lined with the gland-epithelium; sometimes, in the form of simple or superimposed lamellæ covered with flat cells like endothelium, it forms thin-walled tubes or chambers on whose sides the cells are placed; in this form it is called the *membrana propria* of the gland cavities. The cavities and tubes thus formed and lined with gland-epithelium are variously arranged in different glands, but their different modes of arrangement may be reduced to three types:

1. *Tubular glands*, which have the form of simple or occasionally branching, straight, curved, or variously contorted tubes, terminating in blind extremities. Such are the glands of the stomach.

2. *Racemose glands*, in which the secreting portion in the form of vesicular or irregular-shaped cavities—*alveoli*—are grouped around simple or branching excretory ducts, into which they open; the whole

structure has been not inaptly compared to a bunch of grapes, in which the fruit would correspond to the alveoli, the stem to the excretory ducts; the analogy failing at this point, however, for in the gland the alveoli and ducts are bound together by connective tissue lying between them—called *interstitial tissue*—in which the vessels and nerves ramify. The alveoli which open into the same excretory duct are usually joined more closely to one another than to those opening into different ducts, and these clusters of alveoli are called the *lobules* or *acini* of the gland. Such are the mammary glands and certain mucous glands of the bronchi.

3. *Vesicular Glands*.—These consist of simple, spheroidal, or irregular-shaped closed alveoli, surrounded by a *membrana propria*, and lined with epithelium, the separate alveoli being embedded in interstitial connective tissue. Such glands are the thyroid and ovary.

THE STOMACH.

The muscularis of the stomach differs from that of the intestines, in that a certain number of the cells, especially in the cardiac extremity, do not have the typical transverse or longitudinal arrangement, but lie in an oblique direction. In the vicinity of the pylorus again, the inner circular layers are much thickened, forming the *sphincter pylori*. The mucosa is entirely made up of glands supported

and held together by a small amount of delicate connective tissue, in which the blood and lymphatic vessels ramify. The glands are tubular, sometimes simple, sometimes divided, and often tortuous at the base. They have a *membrana propria*, and, depending upon differences in the epithelium which line them, they are classified as: 1. *mucous glands*; 2. *peptic glands*.

The general surface of the stomach is covered with cylindrical epithelium. In the pyloric region, and here and there in other parts, the glands, or *follicles*, as they are often called, are lined throughout with cylindrical epithelium; these are the *mucous glands*.

The greater proportion of the glands, however, are lined only at their orifices with cylindrical epithelium; deeper down in the gland we find usually two kinds of cells: *a*, spheroidal or polyhedral cells, with transparent or very finely granular bodies; and *b*, larger spheroidal, or somewhat flattened, very granular cells, which usually lie outside the others, between them and the *membrana propria*. These are the so-called *peptic cells*, and these glands are called *peptic glands*. The relative number of these different kinds of peptic cells varies, depending upon the degree of functional activity of the glands. When they are secreting rapidly, the granular cells are abundant; when at rest they are few in number, the smaller transparent cells preponderating.

The arteries pass obliquely through the serosa and musculosa, divide and subdivide in the loose tissue of the submucosa, from whence branches are sent in between the glands; here, before reaching the surface, they break up into a close capillary net surrounding the follicles, and the blood is finally collected into narrow venous trunks directly beneath the surface epithelium; from these it passes back into larger veins in the submucosa, where it collects in the efferent veins. The lymphatic vessels lie between the glands, form anastomosing channels in the submucosa, and pass out through the musculosa, receiving larger and smaller trunks from the latter.

The nerve-trunks from the sympathetic and pneumogastric form a plexus, associated with minute ganglia, called *Auerbach's plexus*, between the layers of the musculosa; from this branches pass into the submucosa and form another similar plexus, called *Meissner's plexus*.

Nodules of lymphoid tissue, varying greatly in size and number, are found in the mucosa of the stomach, at the base of the follicles, and sometimes extending up between them. These are sometimes visible to the naked eye as small grayish prominences on the surface of the mucous membrane, and have been called the *lenticular glands* or *follicles* of the stomach.

THE SMALL INTESTINE.

The supporting connective-tissue framework of the mucosa in the small intestine is more abundant than in the stomach, and is richly infiltrated with small spheroidal and variously shaped cells. In it lie embedded tubular glands, not unlike the mucous glands of the stomach, but not crowded so closely together. These glands are often called the *follicles of Lieberkühn*, and are lined with cylindrical epithelium. Rising from the general surface of the mucous membrane, between the orifices of the glands, are very numerous short cylindrical or conical projections called *villi*. These are formed by projections inward of the mucosa; they are covered by cylindrical epithelium, and contain an abundant vascular net-work, and the radicles of the lymph- or chyle-vessels.

The cylindrical epithelial cells are joined together, side by side, by cement substance, and possess a marked peculiarity in the structure of the free border, which is considerably thickened, and is crossed, in a direction corresponding with the long axis of the cell, by fine parallel, closely-set lines, which are usually interpreted as tiny pores or canals passing through the border. It was formerly taught that through these pores the chyle passed to enter the epithelium on its way to the lymph-vessels. More recently, however, the view has been ad-

vanced that substances absorbed into the lymph-vessels from the intestines pass, not through the epithelial cells, but through the cement substance between them.

Scattered here and there between the cylindrical epithelium, sometimes abundant, sometimes not, are transparent more or less ovoidal cells with a nucleus and a small amount of protoplasm in the vicinity of the narrow base; they look as if the free border of the cell had fallen off and most of the cell-contents had disappeared. Not infrequently a translucent structureless substance is seen protruding from the open end of the cell, as if in the act of passing out of it. These cells are called, from their form, *goblet-cells*. Their significance is not yet definitely determined in all cases: by some, they are regarded as cylindrical cells changed by artificial means; but most observers believe them to be normal structures, and suppose that under certain circumstances the cell-contents undergo a mucous metamorphosis, swell up, burst out of the cell, leaving little but the membrane and nucleus behind, and that thus, under normal conditions, a certain amount of the mucus furnished by mucous membranes is produced.

In addition to the tubular glands which are found throughout the whole extent of the small intestine—in the duodenum, especially in its upper portions—racemose, probably mucous glands, are

found, called *Brunner's glands*. They lie in the submucosa, and consist of variously shaped, but usually elongated alveoli, surrounded by a membrana propria and lined with cylindrical epithelium. The excretory ducts are also lined with cylindrical epithelium, and open on the surface of the mucous membrane.

Smooth muscle-cells pass up from the muscularis mucosæ into the villi. The central portion of the villi is occupied by one or more usually blind canals—the chyle-vessels—which pass outward to the bases of the villi, where they usually unite to form a net-work around the orifices of the tubular glands of Lieberkühn and the lymph-follicles presently to be described; they then pass into the submucosa, where they form larger anastomosing channels; from thence trunks pass through the musciosa, receiving vessels from its two layers, and from a well-developed net-work between them. The distribution of the nerves is essentially similar to that in the stomach.

Closely connected with the lymphatic vessels, and apparently forming a part of the lymphatic apparatus of the intestines, are found certain structures called lymphatic follicles, and of these it is customary to distinguish two kinds: 1. *Solitary follicles*; and 2. *Agminated follicles*, or *Peyer's patches*.

1. *Solitary Follicles*.—These are irregularly scattered through the mucous membrane of both small

and large intestines, in the form of small grayish nodules. They lie chiefly in the mucosa, *often piercing the muscularis mucosæ and descending into the submucosa*; they are usually spheroidal or pear-shaped, and frequently project somewhat into the intestinal cavity. Where they lie, the tubular glands are crowded to one side, and the villi are absent over their surfaces. They may lie so near the surface as to be covered only by a single layer of cylindrical epithelium, or they may be more deeply placed, and covered, in addition, by a thin layer of the connective tissue of the mucosa. They consist of a nodule of reticular connective tissue, whose meshes are somewhat narrower at the periphery, where it becomes continuous with adjacent parts. The meshes are closely filled with small spheroidal cells, having the characters of lymph-cells. In their periphery the lymph-vessels of the mucous membrane form a closely anastomosing net-work. The blood-vessels also interlace in their periphery, and send an abundance of anastomosing capillary loops into their interior.

2. *Peyer's Patches*.—These are found chiefly in the small intestine, and here are most abundant in the lower portion of the jejunum and in the ileum; they are round, or more frequently elongated usually slightly elevated structures, and are always situated at the side opposite the mesenteric attachment, with their long axes parallel with the axis of

the gut. They consist, essentially, of an aggregation of a variable number of structures, having the characters of the solitary follicles; these are placed closely together, side by side, and supplied in essentially the same way as the solitary follicles with blood- and lymphatic-vessels.

THE LARGE INTESTINE.

The mucosa of the large intestine is thickly set with tubular glands similar to Lieberkühn's glands in the small intestine, but is destitute of villi. Solitary lymphatic nodules are abundant, and are, as a rule, somewhat larger than those of the small intestine. The distribution of blood- and lymphatic-vessels resembles in most respects that described in the stomach and small intestine.

PRACTICAL STUDY.

Sections of Stomach.—Bits of perfectly fresh rabbit's or dog's stomach, from the fundus and the pyloric region, should be stretched on a bit of cork to prevent shrinkage, and immersed in absolute alcohol. After twenty-four hours the fluid should be changed, and in three or four days the specimen will probably be hard enough to cut. After embedding in wax,* sections from both regions are made perpendicular to the surface, stained double and mounted in balsam. The nuclei of all the cells are stained violet by the hæmatoxylin; in the peptic glands the bodies of the granular peptic cells are stained a deep rose-red, while the others are but slightly

* Better in celloidin.

colored, or not at all. Sections perpendicular to the surface of a stomach, whose blood-vessels are filled with the mixture of Prussian-blue and gelatin, and stained with carmine, are very instructive.

Sections of Intestine.—Bits of intestine from the upper portion of the duodenum, from the ileum, including one of Peyer's patches, and from the large intestine, should be stretched on cork and immersed in a mixture of equal parts of half-per-cent. chromic acid sol. and alcohol; after four days they are transferred to alcohol, in which, in a day or two, they will become hard enough to cut. Perpendicular sections from the various parts should be stained and mounted in the same way as the stomach. Sections from intestines, whose blood-vessels are injected with blue, are stained with eosin and mounted in balsam.

CHAPTER XI

SUBMAXILLARY GLAND—LIVER.

SUBMAXILLARY GLAND.

CONNECTED with the digestive tract are several racemose glands, which, although differing in important particulars, both in structure and function, yet have many features in common. These glands are the *submaxillaris*, the *sublingual*, the *parotid*, and the *pancreas*. Their details of structure are still insufficiently known, and within the limits of this manual we cannot consider at length even what is well understood. We will simply look at some of the more important features of one of the best known, the *submaxillaris*, considering this, in a general way only, as typical of the others.

The *submaxillary gland* differs in structure in different animals, its structure in the dog being perhaps best known, and quite closely resembling that in man. In the dog it consists, like other racemose glands, of alveoli and excretory ducts. The elongated alveoli are surrounded by a *membrana propria*, and grouped into lobules by more or less interstitial connective tissue, which is furnished with blood- and lymph-vessels and nerves. The alveoli, depending

upon the gland-epithelium which lines them, present two distinct forms: in one form, the smaller of the two, we find the cavity of the alveoli nearly filled by cuboidal or polyhedral cells, whose bodies are cloudy or granular, and which have spheroidal or ellipsoidal nuclei. In the other form of alveoli—the larger—we find in the first place, surrounding the cavity of the alveoli, large, irregular-shaped, transparent cells, having a gelatinoid appearance, with an often flattened nucleus lying at the peripheral side; these cells are not readily stained by eosin, and are called *mucous cells*. In the second place, in the periphery of the alveoli, between the cells just described and the *membrana propria*, lie large, in cross-section, crescentic, strongly granular masses, usually containing several nuclei; these are called the *crescents of Gianuzzi*. They are believed to be formed by a number of small angular cells closely crowded together; they are readily stained with eosin, and are apparently analogues of the granular peptic cells of the stomach. Like the latter, they are most abundant when the gland is in a condition of functional activity, and are believed to be destined to replace the inner layer of transparent cells as these are destroyed or changed in furnishing the specific secretion of the gland.

The excretory ducts differ in structure and in the diameter of the lumen, in different parts of the gland; the difference depending chiefly upon differ-

ences in the structure of the epithelial layer which lines them; this, in the larger ducts, is columnar, and in the smaller, flattened.

PRACTICAL STUDY.

Section of Gland of Dog.—Small pieces of a perfectly fresh gland are hardened in absolute alcohol. Very thin sections are to be stained with hæmatoxylin and eosin, and mounted in glycerin or balsam. One frequently finds in a gland taken from a dog shortly after eating, certain groups of alveoli with the cells in an active, others with the cells in a resting, condition.

THE LIVER.

The liver presents three distinct elements of structure: 1. The cellular elements, which in form, function, and arrangement, characterize the organ—the *liver-cells* or *parenchyma*. 2. The connective-tissue framework—the *interstitial tissue*, which surrounds the organ as a capsule, and in its interior supports the parenchyma and carries the larger vessels. 3. The *blood-, lymph-,* and *gall-vessels*.

The liver-cells are large, have the form of irregular, often somewhat elongated polyhedra; they have a granular body which frequently encloses granules of pigment and larger or smaller droplets of fat; they have one or more vesicular nuclei and nucleoli. When living, they are very soft, and the isolated cells often show depressions on their sides caused by the pressure from adjacent blood-vessels.

If we look at the cut surface of a fresh liver with the naked eye, we find that it presents, more or less distinctly, small polygonal or irregular-shaped figures, which are sections of certain groups of liver-cells, called *acini* or *lobules*. These lobules have, in general, the form of oblong polyhedra, and the difference in shape presented by the sections is due to the fact that they lie crowded together, with their long axes lying in various directions. In order to understand the structure of these lobules, it is necessary to study them in connection with the blood-vessels of the liver, to which they bear a very constant and characteristic relation.

The liver receives its blood from the portal vein and the hepatic artery; it is conveyed away by the hepatic vein. If we follow the ramifications of the *hepatic vein*, we find that it divides and subdivides until it finally breaks up into short terminal radicles, around which as a centre the oblong liver-lobules are grouped. From its smaller branches also, before it breaks up into terminal radicles, small, short branchlets are given off, which form the *centres* of lobules. Veins bearing this relation to the lobules are called *central veins*, or *venæ intralobulares*.

If now we follow the ramifications of the *portal vein*, on the other hand, we find that, dividing and subdividing, it, too, gives off small branchlets which, with the terminal branchlets into which it finally breaks up, pass to the *surface* of the lobules; there

they pour their blood into a rich capillary net-work within the lobules, whence it passes directly into the radicles of the hepatic vein at the centre. The capillaries of the lobules radiate from the central vein, for the most part nearly at right angles to its axis, and take more or less direct, slightly divergent courses to the periphery, being connected with each other by frequent branches. A net-work is thus formed, in whose narrow and elongated meshes the liver-cells lie, sometimes in a single row, sometimes in several rows, depending upon the breadth of the intercapillary spaces. The central vein does not usually extend quite to the extremity of the lobules, and here the capillaries are given off, brush-like, obliquely from its end. *A liver-lobule, then, is a circumscribed portion of liver-tissue, having for its centre a branchlet of the hepatic vein—vena intralobularis,—and at its periphery the terminal branchlets of the portal vein—venæ interlobulares,—while between these two sets of vessels, and joining them, is a rich capillary net-work, in whose elongated meshes lie rows of liver-cells.*

In certain animals, such as the pig, the lobules are very distinct, being surrounded by connective tissue which is directly continuous with the connective tissue surrounding the larger trunks of the portal vein, hepatic artery, etc., and called *Glisson's capsule*. In this connective tissue between the lobules are found, in addition to the branchlets of the portal

vein, certain of the terminal branchlets of the hepatic artery and the capillaries connected with them, and the smaller gall-ducts. In the human liver, on the contrary, there is very little connective tissue between the lobules, only here and there small masses are seen surrounding the branches of the portal vein and its accompanying vessels, the lobules merging, for the most part, insensibly into one another. The hepatic artery sends its blood into capillaries which are distributed largely to the walls of the vessels and the connective tissue, and it finally passes, directly or indirectly, into the intralobular capillaries.

We have finally to consider the *gall-passages*. The larger gall-ducts, lined with a well-developed mucous membrane, supplied with tubular and racemose mucous glands, and covered with cylindrical epithelium, enter the liver with the other large vessels, and, dividing and subdividing, accompany them in the capsule of Glisson. As they pass inward they become smaller and smaller, the mucous membrane loses its glands and becomes simpler in structure—the small ducts consisting of little more than a simple tube lined with low cylindrical or cuboidal cells. Finally, as the ducts arrive at the periphery of the lobules—*interlobular gall-ducts*—they are lined with flat, polygonal cells; here they become continuous with the intralobular gall-passages or gall-capillaries. The gall-capillaries are extremely

narrow, and form a delicate net-work around the individual liver-cells; being arranged in such a way, however, that they never come into contact with the blood-capillaries, always being separated by at least a part of the diameter of a liver-cell from the latter. They do not seem to possess a distinct wall, but are rather, simple channels grooved in the walls of contiguous liver-cells.

The connective tissue of the human liver is chiefly found in the capsule which surrounds the organ, and in the capsule of Glisson, which accompanies the larger vessels; but, in addition to this, we find it *in very small quantity*, not only in the vicinity of the hepatic vein, but also between the cells and along the capillaries within the lobules; in the latter situation it occurs in the form of delicate fibres or membranes, with here and there fusiform or stellate cells.

The lymphatic vessels of the liver form an abundant net-work in the capsule, and also accompany the larger vascular trunks in Glisson's capsule and between the lobules, and are connected with minute intralobular lymph-spaces. Here and there in the interstitial tissue of the liver are found small irregular nodules of lymphoid tissue, see page 134.

PRACTICAL STUDY.

Liver-cells.—A small fragment of fresh liver is teased in salt solution and studied in the same. It need not be

preserved, as hardened cells will be seen in the following preparations.

Sections of Pig's Liver.—A small piece of pig's liver should be hardened in Müller's fluid and alcohol, and very thin sections made near the surface, both parallel and at right angles to it, so as to cut the lobules, which are quite regularly arranged at the surface, in different directions. The sections are stained double and mounted in balsam. The lobules being here surrounded by tolerably distinct layers of connective tissue, in which the interlobular vessels run, the lobular structure is quite evident, and the pictures obtained by sections in different directions are easy of interpretation.

Sections of Human Liver.—Sections are made from a bit of human liver hardened as above, stained double and mounted in balsam. Here the lobular structure is very ill-defined, because of the small amount of connective tissue between the lobules, and for the recognition of the different parts of the latter we are largely dependent upon the determination of the different kinds of blood-vessels, since these always bear a definite relation to the lobules. It is to be remembered that the branches of the portal vein lie only in the periphery of the lobules, that they are usually accompanied by other vessels besides capillaries, and are in most cases surrounded by a greater or less amount of connective tissue. The central vein, on the other hand, is usually unassociated with other dissimilar vessels, except capillaries, and surrounded only by a scarcely appreciable amount of connective tissue.

Injected Liver.—The general arrangement of the blood-

vessels is best studied in sections from a human or rabbit's liver, which has been injected through the portal vein with the blue gelatin mixture. The sections are stained with eosin and mounted in balsam.

Injected Gall-capillaries.—By a careful injection of the blue gelatin mixture into the hepatic duct, the gall-capillaries may be partially filled. Sections are stained with eosin and mounted in balsam.

To show the relation between the blood- and gall-capillaries, both may be simultaneously injected with gelatin of different colors, one forced into the hepatic duct, the other into the portal vein.

Don't spend much time

CHAPTER XII.

SUPRA-RENAL CAPSULES—THYROID GLAND.

SUPRA-RENAL CAPSULES.

IN sections of the supra-renal capsules, through their thickest part, and at right angles to the long axis of the organ, we see with the naked eye two distinct layers; a tolerably firm, yellowish, striated cortical layer of considerable thickness—the *cortex*,—and a narrower central, yellow or reddish portion—the *medulla*. Between the two, or rather at the inner side of the cortical portion, a more or less distinct brown zone is seen.

If we examine thin sections microscopically, we find that the organ is enclosed in a firm connective-tissue capsule, in which are numerous elastic fibres and smooth muscle-cells. From this capsule, delicate converging connective-tissue bands or septa, similar in structure to the capsule, pass inward, and being joined together by delicate transverse bands or trabeculæ, divide the cortex into a multitude of variously shaped chambers. In the periphery, just beneath the capsule, the chambers are small and irregular in shape; then comes a broader zone, whose chambers are long and narrow; and again, at

the inner border of the cortex, they are small and irregular. In the medulla the supporting framework has the form of a delicate reticulum with small irregular meshes. The spaces thus formed are filled with cells—*parenchyma cells*,—which differ in character in the different parts; in the cortex they are, for the most part, large, polyhedral, and granular; less abundant are smaller cuboidal or cylindrical forms. Those in the elongated chambers are usually crowded with fat-droplets, and those lying in the inner zone usually contain an abundance of brown pigment, forming the above-mentioned brown zone. The meshes of the medulla are filled with large globular or angular or branched, finely granular cells, which, in marked contrast to the cortical cells, are stained intensely brown by solutions of chromic acid or its salts.

The blood-vessels are very abundant; many of them have very thin walls and lie in close contact with the cells of the parenchyma. The organ is abundantly supplied with nerves which, passing along the converging trabeculæ, form a dense plexus in the medulla, in which, as well as in the capsule, considerable numbers of ganglion-cells are found. Lymphatic vessels and sinuses are also abundant.

PRACTICAL STUDY.

Sections.—A human supra-renal capsule, as fresh as possible—or, if this cannot be obtained, that of the

guinea-pig or ox,—is cut transversely into two or three pieces and hardened in bichromate of potassium and alcohol. Transverse sections are stained double and mounted in glycerin or balsam.

THE THYROID GLAND.

The thyroid gland is composed of a congeries of larger and smaller spheroidal or irregular-shaped alveoli, enclosed in connective tissue and grouped together to form lobules. The alveoli are entirely separate from one another, and they have no excretory ducts. Each alveolus has a delicate *membrana propria*, and is lined with a single layer of cylindrical or cuboidal cells. The connective tissue between the alveoli contains numerous blood- and lymphatic-vessels.

The entire gland, which consists of two lateral lobes, united at their lower extremities by a transverse commissure, is enclosed in a dense connective-tissue envelope. The alveoli are filled with a clear, homogeneous albuminous fluid, which in adult life is frequently transformed *into* or replaced by a translucent material, called *colloid*. Owing to the pressure which the accumulating colloid substance exerts on the epithelium lining the alveoli, they are often very much flattened, and not infrequently almost entirely disappear. The colloid material seems to be formed, in part at least, by a transformation of the contents of the epithelial cells, and its

formation under pathological conditions gives rise to one of the forms of goitre.

PRACTICAL STUDY.

The thyroid of a child or adult—better the former—is cut into small pieces and hardened in alcohol. Sections are stained double and mounted in glycerin or balsam.

CHAPTER XIII.

THE RESPIRATORY APPARATUS.

THE respiratory apparatus consists of a multitude of small cavities or chambers, on whose walls the blood is brought into close contact with the air, and of a system of branching tubes through which the air is conducted to and from them. The conducting tubes are the larynx, the trachea, and the bronchi. We shall limit our study of the tubes to the two last.

The walls of the trachea consist of several layers: commencing at the outside, we have first, a layer of firm connective tissue—the *fibrous layer*—in which lie embedded, incomplete cartilaginous rings, the space between whose free ends, at the posterior portion of the tube, is bridged over by transverse bands of smooth muscular tissue, which bind the ends together. The cartilaginous rings are of the hyaline variety, and their perichondrium is continuous with the looser connective tissue of the layer in which they lie. This layer merges into the next, the *submucosa*, which consists of loose, fibrillar connective tissue with elastic fibres, the latter running chiefly in a longitudinal direction.

Still farther inward, and not distinctly separated from the submucosa, lies the *mucosa*, composed of fibrillar connective tissue containing an abundance of variously shaped cells, and, for the most part, longitudinally arranged elastic fibres. In some parts of the mucosa the tissue resembles diffuse lymphoid tissue. The connective tissue of the mucosa, in some parts of the trachea, does not form an uniform layer, but is arranged in more or less well-defined longitudinal bundles, giving the surface a wavy or folded appearance.

Internally, the mucosa is bordered by a thin, homogeneous membrane, the *basal membrane*, upon which the epithelial cells lining the trachea rest. The epithelial cells are usually arranged in about three layers. Lying upon the basal membrane are irregularly spheroidal, often somewhat elongated cells; upon these lie fusiform or pear-shaped cells, while the surface is formed by a layer of pyramidal or cylindrical ciliated cells. In the submucosa, and sometimes extending outward along and between the cartilaginous rings, lie racemose mucous glands, whose excretory ducts, lined with cylindrical epithelium, pass obliquely inward and terminate on the surface in expanded orifices. The alveoli of the glands are lined with a single layer of slightly granular, polyhedral cells. When the glands are in a condition of functional activity, however, the cells become larger, the outlines indistinct, their nuclei

are crowded to one side, and their contents are apparently transformed into a homogeneous mucous mass. Scattered here and there among the glands and between the cartilaginous rings, lie larger and smaller clusters of fat-cells.

The blood-vessels, passing through the outer layers, furnish an abundant capillary network to the mucous glands, and spread out in a rich capillary plexus beneath the basal membrane.

Although the larger and medium-sized bronchi have the same general structure as the trachea, still we find, aside from a decrease in the thickness of the walls, certain noteworthy structural modifications which chiefly concern the cartilaginous and muscular elements. The cartilage occurs in the form of regular, incomplete rings, only in the upper portion of the larger bronchi. As the tubes become smaller the cartilage occurs in the form of scattered, irregular-shaped, often angular plates, which become gradually smaller and thinner. Furthermore, a distinct layer of smooth muscular tissue, in the form of transverse rings, connected with each other by interlacing cells, appears between the mucosa and the submucosa. We find, also, that the longitudinal bundles of fibrillar and elastic connective tissue in the mucosa are more strongly developed as the bronchi become smaller, so as to throw the mucous membrane into pronounced longitudinal folds.

Following the bronchi now down toward their

finer ramifications, we find that the outer connective-tissue layer becomes thinner, the cartilaginous plates become smaller and more infrequent, and finally altogether disappear; the mucous glands, too, after becoming smaller and simpler in structure, disappear with the cartilages. The muscular rings assume, gradually, the form of an uniform thin layer of transversely arranged muscle-cells, intermingled with elastic fibres, and are finally represented only by a few scattered transverse cells. The mucosa in the smaller tubes becomes gradually thinner, and finally merges into the fibrous layer, with the intervention only of a few scattered muscle-cells; the lower layers of epithelium gradually disappear, leaving a single row of ciliated cells upon the basal membrane. Finally, we have, in the smallest tubes, very thin connective-tissue walls, containing a few muscle-cells and elastic fibres, and lined with cuboidal, ciliated, and at last with flattened, non-ciliated cells.

We are thus led to the respiratory cavities of the lungs—the air-chambers. If we look at the surface of a lung, we see that it is more or less distinctly divided, by narrow branching lines, into irregular polygonal spaces, each one of which corresponds to a *pulmonary lobule*. These lobules have, on the surface of the lung, where they are more uniform in shape than within, a pyramidal form, and are separated by narrow connective-tissue septa, and each lobule is, in fact, a group of air-vesicles, which are

in communication with a single small bronchus and its terminal twigs. As the small bronchus enters the lobule, it divides into several terminal twigs; these open at the peripheral extremity into irregular tubular passages, called *alveolar passages*; on the sides of these alveolar passages still other irregular, sometimes branched elongated cavities, called *infundibula*, open out, and their walls, as well as the walls of the alveolar passages, are beset with tiny, irregular-shaped vesicles, called *air vesicles* or *alveoli*, which communicate with the cavities of the infundibula and alveolar passages by wide, irregular openings. All of these cavities are closely crowded together, and their walls intimately joined. It is in the walls of the air-vesicles that that interchange of material between air and blood occurs, which is the essential factor in respiration.

We have now to consider the structure of the walls of the alveolar passages, infundibula, and air-vesicles. The gradual thinning which we have observed in the walls of the bronchi as they approach their termination, is still more marked as we pass over into the alveolar passages and infundibula. Here, the walls consist of little else than a thin, delicately striated, membranous basement substance, in which numerous elastic fibres ramify, and a few connective-tissue and smooth muscle-cells are embedded, the whole being lined with flattened epithelium. At the opening of the infundibula and air-

vesicles the elastic fibres are grouped to form projecting rings, which bound the opening. From these rings of elastic fibres which surround the openings into the alveoli, other elastic fibres are given off, which, dividing and subdividing, stretch over the walls of the air-vessels in the form of a wide-meshed net, the spaces between the fibres being occupied by an extremely thin, structureless membrane, in which lies an occasional oval nucleus.

The alveoli, in the adult, are lined with a single layer of flattened, polygonal, epithelial cells. These are of two kinds: first, small granular, nucleated cells; and, second, cells which are larger, more irregular in form, very thin and transparent, and usually without nuclei. The relative proportion of these two kinds of cells is variable, and their outlines, especially those of the larger cells, it is difficult to see distinctly without resorting to silver-staining.*

In the foetus the air-vesicles are lined at first with a distinct layer of cylindrical or cuboidal epithelial cells, which become gradually flattened, and when respiration is established assume the form of a layer of very thin polygonal cells; these change their character as the animal matures, until in adult life we have the forms above described.

Just beneath the epithelial cells, and separated by them alone from the air within the vesicles, lies the rich blood-capillary net-work, which, in bulk as in importance, is the most essential element in the

* See Appendix, p. 254.

walls of the vesicles. The lungs are supplied with blood through the pulmonary and the bronchial arteries. The blood from the latter is chiefly distributed to the walls of the bronchi and larger blood-vessels, and to the connective tissue of the lungs. A large part of the blood from the bronchial arteries, after passing through various sets of capillaries, returns through the bronchial veins; but a certain portion of it finds its way into the pulmonary veins; indeed, the two sets of vessels seem to be in communication in various parts of the lungs.

The pulmonary artery, following the course of the bronchi, divides and subdivides, until on reaching the lobules the small trunks break up into smaller branchlets, which pass along the alveolar passages and in the interlobular connective tissue to the air-vesicles, where they break up into the rich capillary net-work which is spread over their walls. The capillaries wind over the free edges of the alveolar walls, the vessels often projecting somewhat into their cavities. The net-work on the alveolar walls is quite dense, and the vessels are very broad, leaving only small oval or rounded spaces between them. A single net-work frequently supplies the walls of adjacent vesicles, which in such cases are merged into one. The blood passes from the vesicles into the pulmonary veins in the interlobular connective tissue, and then into larger trunks which, passing inward, follow the course of the other large vessels.

The surface of the lungs is invested with a thin layer of connective tissue,—the *pulmonary pleura*,—which contains numerous blood- and lymph-vessels, and is covered with endothelium. Here and there, beneath the pleura, as well as elsewhere in the lungs, between the lobules and around the alveolar passages and small bronchi, are small irregular nodules of lymphoid tissue.

The epithelial cells of the alveoli often contain brown or black pigment, and pigment deposits are of the most frequent occurrence, in the adult lung, in the interlobular connective tissue, and in the connective tissue and lymph nodes at the base of the lungs, as well as in the above-mentioned lymphoid nodules. The greater part of this pigment is probably taken up from the respired air, and transported through the cells or lymph-channels to the parts in which it is found.

PRACTICAL STUDY.

Trachea.—A portion of the human trachea is placed for ten days in $\frac{1}{6}$ -per-cent. solution of chromic acid, and the hardening completed with alcohol. A small bit is embedded in wax or hardened liver,* care being taken not to rub off the ciliated cells in the manipulation, and the longitudinal and transverse sections are stained double and mounted in balsam.

Uninjected Lung.—The lungs from the human subject, or any small animal, such as the dog, rabbit, or cat, having been carefully removed, a canula is tied into the

* Much better in celloidin.

trachea (or one of the large bronchi, if one lung only is to be prepared), and the organ is distended by pouring a one-sixth-per-cent. solution of chromic acid into the canula, which, for this purpose, may be connected by a short rubber tube with a funnel. When the lung is filled and its surface tense, the trachea or bronchus is tied, and the entire organ immersed in the same fluid with which its alveoli are filled. After a couple of days the organ may be cut in pieces and put into a stronger solution of the chromic acid, one-fifth to one-fourth per cent. In three or four days they are washed and transferred at first to dilute, and then to strong, alcohol. Sections* may be stained double and mounted in glycerin.

To demonstrate the elastic fibres in the walls of the air-vesicles, thin sections of an unstained human lung are mounted in glycerin to which strong acetic acid has been added in the proportion of 1-100.

Epithelium of the Air-vesicles.—The lung of a freshly-killed animal (a young cat is best) is filled with a solution of silver nitrate 1-500, in the manner just described, and after remaining for half an hour, the tube between the funnel and the lungs should be lengthened to about six or eight inches, so as to increase the pressure, and the funnel filled with a mixture of equal parts of alcohol and water. Under this increased pressure, the silver solution will be partially driven out through the pleura and replaced by the dilute alcohol. When this replacement is partially accomplished, the lung is placed entire in alcohol of the same strength and exposed to the light. After a few hours it may be cut into pieces and preserved in strong alcohol. Sections are made* from the surfaces

* After embedding in celloidin.

which have become brown, and mounted in glycerin tinged with eosin.

Injected Lung.—From bits of human lung whose blood-vessels have been injected with the blue gelatin mixture through the pulmonary artery, sections, which need not be very thin, are made, stained with eosin and mounted in balsam.

CHAPTER XIV.

THE KIDNEY.

IF a longitudinal section be made through the middle of a rabbit's kidney, the cut surface will present a well-marked separation into an outer *cortical* and an inner *medullary* substance; between these two are seen sections of large blood-vessels. The medullary portion, called *medullary pyramid* or *medulla*, and occupying the central part of the organ, terminates in the pelvis in a single short, rounded prolongation, called the *papilla*, at the end of which, with a low magnifying power, several tiny openings may be seen. The cut surface of the papilla presents an uniform grayish appearance, while the segment of the medulla adjacent to the cortex presents distinct bands or *striæ*, radiating from the papilla and extending, in the form of narrow, isolated tapering rays, into the cortex, almost to the surface of the organ; these cortical rays are called *medullary rays*.

The cortex, surrounding the medulla like a thick shell, and covered by a firm, dense layer of connective tissue—the *capsule*—consists, besides the medul-

lary rays, of a grayish substance lying in the form of elongated truncated pyramids between the rays, and in a thin irregular layer of the same appearance directly beneath the capsule. The grayish, pyramidal portions of the cortex are called *cortical pyramids*, and the entire substance of the cortex, exclusive of the medullary rays, is sometimes called the *labyrinth*. If the blood-vessels of the kidney have been injected with some colored substance, or if the vessels are well filled with blood, tiny vessels can be seen passing off from the large trunks which lie between the cortex and medulla; and extending radially toward the surface of the organ through the centre of the cortical pyramids, and at each side of these vessels, may be seen a row of minute globular structures, which are the *Malpighian bodies* or *glomeruli*.

The human kidney differs from that which we have just described, in that it consists of a number of just such structures crowded together to form a single organ. In embryonic life its composite nature is evident, because each *renculus*—as each portion corresponding to the rabbit's kidney is called—is separated from its neighbors by a certain amount of connective tissue, giving the surface of the organ a lobulated appearance. As the individual matures, the *rencoli* usually become merged into one another, so that we no longer see on the surface any trace of its composite character. This is betrayed, however,

by the fact that the medullary pyramids of the primitive renculi persist as separate structures, and we thus have in the adult human kidney just as many medullary pyramids and papillæ as there were original renculi. We find also, which is a striking feature in the adult human kidney, that the cortical substance is not confined to the cortex, but extends into the pelvis between the papillæ, often as far as, and sometimes farther than the papillæ themselves. Not very infrequently the divisions between the primitive renculi are not entirely obliterated in the process of development, and the surface of the kidney, even in the adult, is distinctly lobulated.

Having thus acquainted ourselves with the general structure of the kidney, we have now to study the elements of which it is composed, and the way in which they are grouped to form the different parts above described. The kidney is a tubular gland; the innumerable tubes of which it is mainly composed are lined with epithelial cells, and run a very tortuous course from their origin in the cortex to their termination in the tiny openings, above mentioned, at the apex of the papillæ. They constitute, with the cells lining the walls of the glomeruli, in which they originate, the *parenchyma* of the kidney. In addition to the parenchyma we have, then, to study the connective tissue or *interstitial tissue* of the organ and the *blood-vessels*.

The tubes of the kidney, called in general *urin-*

iferous tubules, consist of an apparently homogeneous *membrana propria* lined throughout with a single layer of epithelial cells, which differ greatly in character and form in different parts of the tubules; the tubules have received special names in different parts of their course.

Each tubule commences within a cortical pyramid, in a dilatation called the *glomerulus*, with whose capsule, presently to be described, its *membrana propria* is continuous; it is narrow as it leaves the glomerulus, but broadens out at once into a wide, convoluted canal—*convoluted tubule*—which winds about in the pyramid, finally approaching a medullary ray; this it enters, and, suddenly becoming very narrow, descends more or less deeply into the medulla; here, widening somewhat, it turns sharply on itself and ascends into a medullary ray again. This portion of the tube, from the point at which it becomes narrow and begins to descend in the medullary ray, is called *Henle's loop*, and the arms of the loop are called, following the course which the description has taken, the *descending* or *narrow*, and the *ascending* or *broad* arms of Henle's loop. The ascending arm of Henle's loop, on arriving in the cortex, widens and enters a cortical pyramid, forming what is known as the *intercalated tubule*; this resembles the convoluted tubules, among which it winds in and out, and then passes over, entering a medullary ray, into a *straight uriniferous tubule*.

This is again narrower than the convoluted tubules, and passes directly downward through the medulla, joining other similar tubules dichotomously and becoming larger as it does so, until at length it opens at the apex of a papilla. The uriniferous tubules run an entirely independent course until, as straight tubules, they join one another by twos, to form the outlet ducts.

We have now to consider the epithelium which lines the tubules. Commencing at the straight tubules in the papillæ, we find that in their lower portion they are lined by cylindrical cells with large nuclei and transparent bodies; further up the cells become more nearly cuboidal, and are often flattened in the medullary rays. The epithelium of the convoluted and intercalated tubules is similar in character, and consists of large granular striated cells, whose outlines are not well defined, and which nearly fill the lumen of the tube. The ascending arm of Henle's loop is lined with pyramidal or low cylindrical, granular cells; while the very narrow descending arm is lined with flat, transparent cells, whose nuclei usually project into the lumen of the tube.

The glomeruli consist, in the first place, of a membranous, apparently structureless capsule, similar to and continuous with the membrana propria of the tubules. The epithelium of the convoluted tubules, as the latter join the glomeruli, becomes flattened

and continuous with a layer of very thin transparent cells, which completely line the capsule. At one side of the glomerulus, usually opposite to the attachment of the tubule, a small artery—the *vas afferens*—pierces the capsule and immediately divides into a number of capillary loops, which wind about one another, forming a complicated vascular tuft; the blood from this tuft is collected into a vein—*vas efferens*—which is, as a rule, somewhat smaller than the afferent artery, and leaves the glomerulus near the point where the latter enters. The capillary tuft within the glomerulus is covered also with a layer of flat cells like those lining the capsule.

Let us now review the positions of the different parts of the tubules in the kidney. In the papillæ are the termini of the straight tubules; in the medulla lie the straight tubules and portions of Henle's loops; in the medullary rays are the upper portions of the straight tubules, and of both arms of Henle's loops; in the labyrinth, including the cortical pyramids, are the convoluted tubules, intercalated tubes, and the glomeruli.

The distribution of the blood in the kidney yet remains to be considered. The larger branches of the renal arteries, accompanied by the veins, enter the organ at the bases of the medullary pyramids, and divide into large arching trunks which pass, in various directions, with their convexity toward the

cortex, along the irregular boundary line between the cortex and medulla. From the convex side of the arterial trunks spring numerous small branches, each of which enters at once the apex of a cortical pyramid, and proceeds directly toward the surface of the organ; these arteries are called *interlobular arteries*.¹ From these interlobular arteries lateral twigs are given off at frequent intervals, which, after passing a short distance, enter the glomeruli as the arteriæ afferentes. On leaving the glomerulus, the efferent vein—which still carries arterial blood—breaks up into a capillary net-work, which lies among the adjacent convoluted tubules and in the neighboring medullary rays, the meshes in the former region being rounded, in the latter, elongated, corresponding to the character of the tubules among which they lie. From these the blood is collected into small veins, which in turn pour it into interlobular veins, and these, following the course of the interlobular arteries, finally pour it into the large arched trunks between the cortex and medulla. In the superficial portions of the cortex there are no glomeruli, and here small venous trunks centre in

¹ If we consider a circumscribed portion of the cortex of the kidney, having for its centre a medullary ray, and extending on every side as far as to the nearest interlobular vessels, we see that in this limited area we have all of the essential structural elements of the cortex—a medullary ray surrounded by convoluted tubules and glomeruli. Such groups of elements, although they have by no means a separate existence, and can be but indefinitely bounded, have been called lobuli; and, hence, the vessels passing between them are termed interlobular vessels.

the commencement of an interlobular vein, forming the well-known *stellulæ Verheyenii*.

The medulla receives its blood in part from the vasa efferentes of the glomeruli, which lie near the boundary, between cortex and medulla; in greater quantity from the large arterial arches. Vessels from the latter sources descend in spreading tufts, called *vasa recta*, between the tubules, and break up into a long-meshed capillary net, the blood from which is collected in part into a round-meshed venous net-work in the papillæ, and returned in straight veins along the tubules to the venous arches, and in part passes directly back to the arches without going down to the papillæ. The capsule of the kidney receives its blood in part from the terminal twiglets of the interlobular arteries, in part from terminal branches of the phrenic, lumbar, and supra-renal arteries, and it passes into the stellate veins.

The connective tissue of the kidney, aside from that which forms the capsule, lines the pelvis, and is distributed along the walls of the larger blood-vessels and around the glomeruli, is very small in amount. It may, however, be demonstrated here and there, and is most abundant in the vicinity of the papilla.

PRACTICAL STUDY.

Rabbit's Kidney—General View.—A rabbit's kidney is cut transversely across the middle and hardened in two-

per-cent. solution of bichromate of potassium and alcohol. Thin sections are made across the entire organ, including cortex, medulla, and papilla, stained double and mounted in balsam.

Isolated Tubules.—A small fragment of fresh kidney, including both cortical and medullary portions, is placed in a mixture of equal parts of alcohol and strong hydrochloric acid; the acid partially dissolves the intertubular tissue, so that after a time the tubules can easily be pulled apart. This is usually effected in about twelve hours; but the specimen should be examined from time to time after it has been in the acid for eight hours, and removed as soon as the object is accomplished. It is allowed to soak for a few hours in water to remove the acid, and then small bits are torn off, including cortical and medullary substance, and the tubules carefully separated on a slide. They are extremely brittle, and great care must be used in their isolation; this may be done by needles, or better by allowing small drops of water to fall upon the specimen on a slide, from a pipette. When the dissociation is partially effected, the excess of water should be removed with filter paper, and a mixture of equal parts of saturated solution of picric acid and glycerin added, in which it is mounted and preserved.

Sections of Uninjected Human Kidney.—A perfectly fresh human kidney is cut into small pieces and hardened in strong alcohol. Sections are made in a plane vertical to the surface of the organ, including both cortical and medullary portions, and also parallel to the surface, through the cortex. They are stained double and mounted in glycerin.

Sections of Injected Kidney.—The kidney is injected, through both the renal artery and vein, with the blue gelatin mixture, and sections in different directions are stained with eosin and mounted in balsam.

CHAPTER XV.

THE GENERATIVE ORGANS.

MALE GENERATIVE ORGANS.

WE shall confine our study of these organs to the *testicle, prostate gland, and parts of the penis.*

THE TESTICLE—SPERMATOOZA.

This is a tubular gland, whose chief specific secretion is the spermatozoa; it is enclosed by a firm, dense connective-tissue capsule, called the *albuginea*, which sends inward several incomplete septa, which divide the organ into a number of communicating cavities, and unite at its posterior superior part in a dense, wedge-shaped mass of connective tissue, called the *corpus Highmori*. The more or less conical cavities between the septa contain winding, anastomosing, and looped tubules, called *semiferous tubules*, which constitute the secreting portion of the organ. As the tubules approach the corpus Highmori, they become narrower and straighter—*tubuli recti*—and are lined with cylindrical epithelium, and, on entering that body, form a net-like series of intercommunicating channels lined

with flattened cells, called the *rete testis*. The channels of the rete testis are continuous with several tubules, which, passing upward and backward, become very much convoluted, and form a number of conical masses—*coni vasculosi*—which largely constitute the head of the epididymis. The tubules of the *coni vasculosi* gradually unite as they descend to form a single canal, which, with numerous windings and contortions, constitutes the body and tail of the epididymis, and finally becomes continuous with a straight, thick-walled ascending tube—the *vas deferens*.

The seminiferous tubules, which chiefly concern us here, lie embedded in loose, delicate, lamellated connective tissue, which is abundantly supplied with blood-vessels, and contains many cells; among the ordinary connective-tissue cells of various forms, large granular, often pigmented cells are not infrequently seen lying singly or in groups, and sometimes in rows along the blood-vessels; their nature and significance are still doubtful. The tubules have a distinct *membrana propria*, and are lined with several layers of cells piled irregularly over one another, which differ in form under different circumstances, and sometimes in different parts of the same gland.

In a tubule which is not producing spermatozoa, the outer row of cells—those lying upon the *membrana propria*—are large, granular, well-defined, nu-

cleated cells; and upon these lie two or three irregular layers of smaller nucleated cells with ill-defined cell-bodies. Between the cells of the inner layers a peculiar, irregular-branching net-work is seen, which, by some recent observers, is believed to be formed, for the most part, by branches of the outer row of cells; and it is supposed that it serves as a loose framework in which the inner cells are supported. Others believe it to be only intercellular cement-substance. The lumen of these tubules may be filled with granular material or may contain spermatozoa.

In tubules which are in full functional activity, the cavity is usually filled with more or less granular material and mature and immature spermatozoa, and on every side a multitude of clusters or bundles of developing spermatozoa are seen, with the heads embedded among the cells of the inner layers, which are similar to the lining cells above described, and the tails stretching brush-like into the cavity of the tube.

According to some observers, the spermatozoa are formed from certain of the cells of the inner layers, which are called *spermatoblasts*. The process of development, according to this view, commences in the nuclei of the spermatoblasts, which become converted into the head, while the tail is an outgrowth from the nucleus, or is produced by a transformation of a portion of the cell-protoplasm. Others believe

that the spermatozoa are formed by the growth inward, from the large outer cells, or from cells lying among these, of a long-stemmed bud-like process, whose dilated end divides into a number of longitudinal segments, each of which finally becomes a spermatozoön. That the latter is the mode of development in certain animals, *e. g.* the rat, would seem to be unquestionable.

The mature spermatozoa differ in form in different animals; in man they consist of a flattened, pear-shaped portion, called the *head*, the small end of which is directed forward; and a delicate, tapering, almost filiform portion, called the *tail*; while between the head and tail is a short, narrow segment, called the *middle piece*. When living, and under favorable conditions, the spermatozoa are capable of performing rapid movements, the whole organism being driven hither and thither by wavy vibrations of the tail.

PRACTICAL STUDY.

Spermatozoa.—These may be obtained from the seminal vessels of man, or from the sediment of urine in which they occur either normally, or under pathological conditions. They are well preserved by a mixture of equal parts of saturated sol. of picric acid, glycerin, and water, in which they may be mounted.

Spermatozoa for comparative study may be readily obtained by making an incision into the head of the epididymis of a dog, rabbit, or guinea-pig, and receiving the milky fluid which exudes in the above picric acid fluid.

The movements of the living spermatozoa may be studied by mixing some of the milky fluid from the epididymis of a freshly killed animal, on a warm slide, with $\frac{1}{2}$ -per-cent. salt solution, and protecting from pressure by a hair.

The temperature of the slide should be kept at about the same elevation as that of the animal from which they are taken. The movement may be stopped by the addition of water.

Sections of Testicle.—Small pieces of the human testicle, obtained as soon as possible after death, or, if this cannot be obtained, of the testicle of the cat, rabbit, dog, or rat, are hardened in 2-per-cent. sol. of potassium bichromate and alcohol. Sections from the different parts are stained double, and mounted in glycerin or balsam. The differences between the structure of the testicle in the lower animals and man cannot be described here.

THE PROSTATE GLAND.

The prostate is a racemose gland, in which the alveoli, instead of being more or less spheroidal, as is usually the case in racemose glands, are often very much elongated and irregular in shape, and very frequently present high, narrow, irregular folds in their walls. The alveoli are lined for the most part with a single layer of cylindrical epithelium. The excretory ducts are lined, within the gland, with cylindrical, which pass over into flattened cells, as they approach the urethral orifice. The alveoli and ducts lie embedded in a dense mass of interlacing

bundles of smooth muscular tissue, intermingled with elastic fibres and a small amount of fibrillar connective tissue. In the periphery of the gland the muscular tissue forms a sort of capsule of varying thickness, which, in turn, is enclosed in a fibrous tunic.

PRACTICAL STUDY.

Section of Gland.—A bit of that portion of the prostate gland of man which lies behind the urethra, is hardened in potassium bichromate and alcohol, and the sections are stained double and mounted in balsam.

URETHRA AND CORPUS SPONGIOSUM.

The tissues which form the penis are so various, and present such essential differences in their arrangement in different parts of the organ, that a detailed study of its structure does not lie within the scope of this manual. Inasmuch, however, as the urethra is so frequently the seat of surgical operations, and as the corpus spongiosum, which surrounds a portion of it, presents an example of a variety of tissue which we shall have no opportunity to study elsewhere, it is desirable to briefly consider their structure here.

The urethra, divided into three portions—a *prostatic*, a *membranous*, and a *spongy*,—consists of a mucous membrane which is surrounded by a muscular sheath. The considerable differences in structure which its different parts present are due chiefly

to variations in the form of the epithelium and the character and arrangement of the muscular tissue. The mucosa is composed, in all parts alike, of fibrillar connective tissue containing numerous elastic fibres and richly furnished with cells; upon the free surface of this rests the epithelium, which, at the meatus and in the fossa navicularis, is of the flat, laminated variety; this passes over into a single row of cylindrical cells which line the spongy portion; and this in turn merges into the spheroidal, pear-shaped, prismatic, and flattened cells of the prostatic portion, which, lying in several layers, are quite similar in form and arrangement to the epithelium of the bladder.

Outside of the mucosa, and but indistinctly separated from it, is the submucosa, which consists of connective tissue with elastic fibres, and is especially characterized by a dense network of veins which receive their blood from the rich capillary system lying in the mucosa beneath the epithelium. This venous network is so dense and the vessels so large as to lend to the submucosa, especially in the prostatic and membranous portions, the character of erectile tissue (see below).

Here and there, in the spongy portion, larger and smaller irregular depressions, called *lacunæ Morgagni*, are seen in the surface of the mucous membrane. Racemose glands, called *Littre's glands*, lie embedded in the mucous membrane, sometimes extending

into the muscular tunic; their excretory ducts, sometimes short, sometimes long and tortuous, open on the surface of the mucous membrane. In the prostatic portion, the prostatic and ejaculatory ducts pierce the mucous membrane, as do the ducts of Cowper's glands that of the posterior segment of the spongy portion.

The muscular tunic of the urethra consists, in general, of an inner longitudinal and an outer circular layer of smooth muscle-cells, but varies greatly in structure in the different portions. The outer layers of the posterior portion of the canal are formed, in part, of striated muscle. The musculosa of the spongy portion consists entirely of smooth muscle-cells, and forms a complete circular layer in the posterior region alone, while anteriorly only scattered, transversely and obliquely placed cells are found.

When the urethra is closed the mucous membrane is thrown into irregular longitudinal folds.

The urethra is enclosed through a part of its length in the corpus spongiosum, which is largely composed of a kind of tissue called *erectile tissue*; and before describing this body it will be well to consider for a moment the nature of this kind of tissue.

Erectile tissue, in certain cases, consists simply of a somewhat circumscribed collection of larger and smaller veins, which under, certain circumstances,

may become distended with blood, thus causing the part in which they lie to expand; in other cases it consists of numerous larger and smaller irregular-communicating cavities, separated from one another by broad or narrow interlacing bundles of connective tissue and smooth muscular tissue, and in communication with arterial trunks or capillary blood-vessels; the cavities are lined with endothelium, and, while usually containing but a small amount of blood, and in this condition appearing simply as slits or narrow irregular spaces in the tissue, they may, under certain conditions, become distended with blood, when they assume the character of spheroidal, or broad elongated cavities, and thus cause a considerable increase in volume of the part in which they are situated. The corpus spongiosum is composed largely of erectile tissue of the character last described.

The *corpus spongiosum* is enclosed in a dense connective-tissue sheath which contains elastic fibres and a few smooth muscle-cells. From this a multitude of narrow trabeculæ or septa, composed largely of smooth muscle-tissue, pass inward in various directions, and dividing and subdividing, form an intricate series of spaces, which are the above-mentioned blood-cavities. This system of trabeculæ and septa is continuous, within, with the submucosa of the urethra.

The erectile tissue is most abundant below the

urethra; above, the blood is collected into venous trunks, which, joining similar trunks from the corpora cavernosa above, convey the blood away from the part. The corpora cavernosa are similar in structure to the corpus spongiosum.

PRACTICAL STUDY.

Transverse Sections.—The corpus spongiosum and the posterior portions of the urethra are dissected from the remainder of the penis and hardened in potassium bichromate and alcohol. Transverse sections from the different regions are stained double and mounted in balsam.

FEMALE GENERATIVE ORGANS.

THE OVARY.

The ovary is a gland whose vesicular alveoli have no excretory ducts, but discharge their contents by periodic rupture at the surface of the organ. These alveoli are called *Graafian follicles*, and the ovum may be regarded as their specific secretion. They lie embedded in a peculiar connective-tissue stroma, the *interstitial tissue*, and in the adult are confined to the peripheral zone. We have, then, in studying the ovary to consider the *interstitial tissue*, with its blood-vessels; and the *glandular tissue* or Graafian follicles.

On looking at a thin transverse section of the ovary, we see that it presents two indistinctly separated zones; an inner or central zone, including

the ramifications of the larger blood-vessels, and called the *medullary portion*; and an outer, denser *cortical zone*, in which the follicles lie. The interstitial tissue consists, throughout the entire organ, of connective-tissue bundles, which in the medullary portion are somewhat loosely interwoven and associated with elastic fibres and smooth muscle-cells. In the cortical zone the muscular elements fail, the connective-tissue bundles are finer, and cross and interlace in all directions, surrounding the follicles, in whose vicinity they are modified so as to form a kind of capsule. Near the surface of the organ the connective-tissue fibres arrange themselves in crossing layers, to form a dense but not distinct sheath, called the *albuginea*.

The connective tissue of the ovary, especially in the cortical zone, contains a great number, and indeed in some parts seems almost entirely to consist of spindle-shaped, flattened, and irregular branching cells, among which are not infrequently larger and smaller pigmented cells and polyhedral cells resembling epithelium.

The surface of the organ is covered by a single layer of cylindrical epithelium, whose extreme significance we shall recognize when we study the development of the Graafian follicles. The ovary has no serous covering, the peritoneum being replaced by the epithelial cells.

The interstitial tissue of the ovary is very vascu-

lar; the large arterial trunks, entering from the broad ligament, divide and subdivide in the medullary portion, and pass off in larger and smaller twigs into the cortex, from which an abundant capillary net-work is formed around the follicles. The arteries frequently run a very tortuous course, twisting and turning upon themselves, and are characterized, moreover, by the great abundance of smooth muscle-cells in their walls. Lymphatic vessels are abundant. Concerning the distribution of nerves, our knowledge is still very meagre.

We have now to consider the structure of the Graafian follicles, to which the parts just described are subservient. The Graafian follicles in the ovary of the adult female, at the child-bearing age, present by no means the same appearance; some are large and readily visible to the naked eye; others very minute, and presenting under the microscope an entirely different structure. These differences in structure are accounted for by the fact that certain of the follicles are mature or approaching maturity, while others are still undergoing development.

We will first consider the structure of those which are mature, or nearly so. The interstitial tissue of the ovary arranges itself, in the immediate vicinity of the follicle, in the form of a tolerably well-defined wall, called the *theca folliculi*, consisting of an external denser layer and an internal layer very richly supplied with cells, and containing an abundant

capillary net-work. Within the theca folliculi is a layer, usually several cells deep, of larger and smaller spheroidal, or, in the periphery, cuboidal epithelium, called *follicular* epithelium, and constituting the so-called *membrana granulosa*. At one or other side the follicular epithelium is heaped up into a larger or smaller mass, which projects into the cavity of the follicle and contains the ovum; this accumulation of cells is called *cumulus proligerus* or *germ-hill*. The remainder of the follicular cavity is filled with a colorless fluid, in which not infrequently fine granules are suspended. This fluid increases in quantity as the follicle approaches maturity, and the pressure occasioned by its accumulation probably conduces in no slight degree to the final rupture of the follicle. The follicular epithelium immediately surrounding the ovum is cylindrical and arranged radially about it.

In the ovum itself, which is a cell of the most highly developed type, we recognize four structural elements: 1, a thick hyaline membrane, presenting, with high powers, a delicate radial striation, and called the *zona pellucida*; 2, within the *zona pellucida* is the cell-body, consisting of coarsely and finely granular protoplasm, and usually called the *vitellus*; 3, the *vitellus* encloses a comparatively large vesicular, transparent, and sharply-outlined nucleus, the *germinal vesicle*; 4, the *germinal vesicle*, which is usually somewhat eccentrically placed, con-

tains, in addition to a nearly transparent fluid, a small dark, often almost opaque nucleolus, the *germinative spot*.

As the Graafian follicles mature, they approach the surface of the ovary, often projecting above it; the walls become thinner and less vascular at the projecting side, and finally burst at a menstrual period. The ovum, with the fluid and a portion of the follicular epithelium, is discharged, and through the hemorrhage which occurs from the capillaries in the follicular wall, the cavity becomes filled with blood.

Changes now occur in the walls and cavity of the follicle, which result sooner or later in cicatrization and obliteration of the cavity. These changes vary considerably, depending upon whether or not the ovum is impregnated and develops; and the difference expresses itself chiefly in a difference in size and persistence of the mass of tissue called the *corpus luteum*, which is produced by a growth of certain of the cells which remain after the rupture of the follicle. These differences cannot be considered here. The process of formation and disappearance of the corpus luteum, under all circumstances, is essentially the following: The blood which is poured out into the cavity passes through the same retrogressive metamorphosis which extravasated blood in any part of the body may undergo: it coagulates, the serum is absorbed, the red cells disintegrate, and the coloring matter is in part taken up by surround-

ing tissues, in part transformed into yellowish or red hematoidin (bilirubin) crystals, which in turn may change into a dark brown or black pigment, and be taken up by surrounding tissues, or remain for a long time unchanged. Hand in hand with these changes in the extravasated blood, go important changes in the follicular epithelium which is left behind, and in the cells of the theca folliculi. These cells proliferate and form a soft, yellowish, very vascular tissue, resembling mucous tissue, which presently undergoes fatty degeneration. This yellow mass, surrounding and enclosing the remains of the extravasated blood, constitutes the corpus luteum; and, as it disappears, its place is occupied by firm, dense connective tissue, which usually persists for a long time in the form of an irregular cicatrix, whose cells not infrequently still contain yellow or brown or black pigment.

In order to understand all the forms which the immature Graafian follicles present, it will be necessary to study the way in which these structures originate. They are produced from the cylindrical epithelium which covers the ovary and is called *germ-epithelium*. At an early period of life the connective-tissue stroma of the ovary grows rapidly, and partially encloses groups of the germinal epithelial cells, which themselves proliferate, and dip down into the stroma of the organ in the form of elongated, solid or tubular masses. Presently these

groups of cells become separated from the germinal epithelium at the surface, and appear then as irregular masses of polyhedral or spheroidal cells, enclosed on all sides by connective tissue. A still further growth of the stroma separates these masses of cells into smaller groups, which gradually sink farther from the surface of the organ and become more widely separated from one another, while new masses of germ-epithelium are being enclosed at the surface. The cells which now lie in these separated cavities may at first all look alike, but later we usually find that one of them is larger than the others, is spheroidal, and occupies the centre of the cavity, while the rest are more or less cuboidal and arranged in a single layer around the wall, closely enclosing the central cell. This is the young Graafian follicle, and the central cell is the ovum; but it presents as yet no zona pellucida. Gradually the follicular epithelium increases in quantity, forming several layers, and the ovum becomes eccentrically placed. There is still no cavity, but this soon appears, at first as a slit between the cells, and then grows wider and wider as fluid accumulates within it. Changes in the interstitial tissue lead to the formation of the theca folliculi, the epithelium directly about the ovum assumes a radial arrangement, the zona pellucida is formed, and we thus have the structure of the maturing follicle, with which we are already acquainted.

PRACTICAL STUDY.

Section of Adult Ovary.—The human ovary, or that of a recently killed dog or cat, should be divided transversely, great care being taken not to rub the surface, since the germ-epithelium easily comes off, and placed in a mixture of equal parts of one-quarter-per-cent. chromic acid solution and alcohol. After a week it is to be transferred to alcohol, in which in a few days it will become sufficiently hard. A half is embedded in wax,* the sections stained double and mounted in balsam.

Section of Developing Ovary.—The ovary of a foetal or new-born animal is hardened and prepared as above.

THE UTERUS.

The walls of the uterus consist of crossing and interlacing bundles of smooth muscle-cells, with a small amount of connective tissue enclosing them and binding them together. The muscular tissue is arranged in three ill-defined layers, of which the middle is the thicker. It may be said, in general, that the bundles of the inner layer run transversely around the organ, those of the middle layer are longitudinal, while those of the outer layer are quite irregular; still in all the layers there is great lack of uniformity in the direction of the cells. A part of the external surface of the uterus is covered by the peritoneum, while its inner surface is lined with a mucous membrane. The latter consists of a framework formed of a delicate net-work of fibres, between

* Better in celloidin.

which lie a great number of spheroidal, fusiform, and branched cells, and is covered on the free surface by cylindrical ciliated cells. In the mucosa the simple or branched tubular uterine glands are embedded; they are often tortuous, and, like the surface of the mucous membrane, are lined with cylindrical ciliated epithelium.

The surface of the mucous membrane of the body of the uterus is smooth, but in the cervix it presents regular folds, the so-called *plicæ palmatæ*; the connective-tissue framework of the cervical mucous membrane is, moreover, firmer in texture, contains fewer glands, and these, for the most part, are more or less globular and lined with short cylindrical or cuboidal epithelium. The ciliated epithelium of the body extends over on to the mucous membrane of the cervix, where it becomes continuous with the laminated epithelium covering the lower portion of the canal and the portio vaginalis. The uterus is a very vascular organ; the mucous membrane is supplied with a rich capillary plexus, which passes inward close beneath the surface-epithelium.

During menstruation the mucous membrane becomes thickened—partly owing to the engorgement of its blood-vessels, and partly to the accumulation of fluid and lymph-cells in its interstices. The uterine glands are enlarged, and their epithelium, as well as that of the general surface of the cavity, is swollen. To what extent the blood, which, mixed

with mucus and separated epithelium, is present in the cavity at the menstrual period, is due to the rupture of the engorged capillaries, and to what extent to diapedesis, is not yet definitely determined.

PRACTICAL STUDY.

Section of Human Uterus.—The uterus is cut into several pieces, and hardened in potassium bichromate and alcohol. The organ should be procured as soon as possible after death, since the cilia of the lining epithelium are easily destroyed by the decomposition which commences very early in the uterine cavity. Sections perpendicular to the surface of the mucous membrane are made from the cervix, and, in the body, from the lower portions or from the vicinity of the entrance of the Fallopian tubes, since here the uterine glands are more uniformly arranged at right angles to the surface. They are stained double and mounted in balsam.

THE VAGINA.

In the walls of the vagina we recognize three layers: an *outer fibrous layer*, a *middle muscular layer*, and a *lining mucous membrane*.

The *fibrous layer*, by means of which the vagina is connected with adjacent parts, consists of connective tissue with elastic fibres, and in texture is looser in its outer, denser in its inner, portions. The *muscular layer* consists of bundles of smooth muscle-cells, which present an indistinct grouping into an

outer portion, formed of longitudinally arranged cells, and an inner, in which they have, in general, a transverse arrangement.

The *mucous membrane* consists of delicate connective tissue, loose in texture and containing coarser and finer elastic fibres; it presents numerous transverse folds and elevations, and is covered by laminated epithelium, the cells in the lower layers being more or less spheroidal, but flat and scale-like at the surface. Numerous papillæ project into the epithelium. Venous plexuses are formed within the deeper portions of the mucous membrane, which give to some parts of that structure the character of erectile tissue.

PRACTICAL STUDY.

Transverse Sections.—A bit of the vaginal wall should be stretched on cork and placed in a mixture of equal parts of one-fourth-per-cent. solution of chromic acid and alcohol, and after five days transferred to alcohol, in which the hardening is completed. Sections at right angles to the surface are stained double and mounted in glycerin.

Isolated Surface-cells.—From a bit of vagina hardened as above, or simply in alcohol, the cells from the surface of the mucous membrane are scraped with a scalpel, stained on a slide with hæmatoxylin, and mounted in glycerin. Familiarity with the appearance of these surface cells is of practical importance, since they are often found in urine.

MAMMARY GLAND.

The mammary gland is a racemose, and when fully developed a lobulated, gland, whose spheroidal and elongated alveoli are formed by a membrana propria composed of flattened cells, and lined with cuboidal epithelium. The excretory ducts, which in each gland are fifteen to twenty in number, and open at the surface of the nipple, are lined with cylindrical epithelium. Fibrillar connective tissue with elastic fibres lies between the alveoli and lobules, and is abundantly furnished with blood-vessels.

The gland presents, both macroscopically and microscopically, quite marked differences in appearance at different times, depending upon age, sex, and, in the adult female, upon whether or not the individual is pregnant, and upon the period of pregnancy and the occurrence of lactation.

In children, as in the adult male, the gland presents, in general, a system of ramifying ducts, terminating in blind or in more or less pouched or dilated extremities; these lie embedded in connective tissue, which makes up the greater part of the bulk of the gland. At puberty the gland of the female undergoes considerable development; well-defined alveoli are found in the periphery of the gland connected with the excretory ducts, but the interstitial tissue is still more abundant than the

gland-tissue proper. Essentially in this condition the gland usually remains until the climacteric period, if pregnancy does not occur.

If, however, the individual becomes pregnant, the number and size of the alveoli rapidly increase; the ducts, which in the virgin terminate only in dilated extremities, become connected with extensive groups of newly formed alveoli; the gland assumes a lobulated character, the connective tissue between the alveoli is very much less abundant in proportion to the gland-tissue, is looser in texture, and contains a great number of larger and smaller cells, and frequently fat-cells. During lactation the alveoli are very large, their epithelium contains fat-droplets in considerable number, and fat is found in greater or less quantity in the dilated cavities of the alveoli, and in the excretory ducts. When the secretory activity of the gland ceases, it undergoes involution, the alveoli become smaller, fat ceases to be produced by the cells, and the interstitial connective tissue becomes proportionally more abundant.

With the decline of the reproductive power the mammary gland undergoes a marked and permanent involution: the terminal alveoli disappear, the smaller ducts are obliterated, and finally little is left of the organ excepting the deformed and collapsed larger ducts and a mass of connective tissue.

PRACTICAL STUDY.

Sections of Hardened Gland.—Portions of the gland from the human subject or from some of the lower mammalia—if possible, both in a condition of rest and of functional activity—should be hardened in potassium bichromate and alcohol, and the sections stained double and mounted in glycerin or balsam.

CHAPTER XVI.

THE CENTRAL NERVOUS SYSTEM.

THE SPINAL CORD.

THE spinal cord contains *nerve-cells* and *nerve-fibres*; the former confined to the central, the latter most abundant in the peripheral, portions. These nerve-elements lie in the meshes of peculiarly arranged connective tissue in which blood-vessels ramify, and the whole is surrounded by a vascular connective-tissue membrane—the *pia mater spinalis*. On its anterior and posterior surfaces, narrow fissures, reaching nearly to the centre, divide the cord into lateral halves; into these fissures, called the *anterior* and *posterior longitudinal fissures*, the *pia mater* sends membranous prolongations. The anterior fissure is complete, the *pia* being found on both of its sides, which can be easily separated; while in the posterior fissure the sides are bound together by the *pia*.

In transverse sections of the cord a central gray portion is seen which is surrounded by an irregular white zone. The form which the gray matter assumes differs considerably in different parts of the cord, but has, in general, the form of an unsymmet-

rical H ; the cross-arm of the H is formed, in great part, by the nerve-substance which connects the lateral halves of the cord, and is called the *gray commissure* ; the uprights of the H lie completely embedded within the white matter of the lateral halves ; the anterior and broader ends being called the *anterior cornua*, the posterior and narrow ends the *posterior cornua*. Within the gray commissure, and separating it into an anterior and a posterior portion, a narrow canal, called the *central canal*, runs the entire length of the cord ; it is lined, in early life at least, with cylindrical ciliated cells, and is surrounded by delicate connective tissue. From the anterior and posterior cornua the spinal nerves pass off, dividing the white matter into three tolerably distinct portions called the *anterior*, *lateral*, and *posterior columns*.

In the white substance of the cord we find nerve-fibres, connective tissue, and blood- and lymph-vessels. The fibres are for the most part medullated, but have not, so far as we can determine with the technical facilities at present at our disposal, any neurilemma. They vary greatly in diameter, and although a large majority of them run longitudinally for the greater part of their course, we find in each transverse section a considerable number which run in an oblique or horizontal direction. Thus, we find in front of the anterior gray commissure, at the bottom of the anterior fissure, a band

of horizontally arranged fibres running from one side to the other, called the *white commissure*. The fibres which pass out of the gray matter to form the roots of the spinal nerves, take also longitudinal and oblique courses.

The connective tissue of the white substance is intimately connected at the periphery with the pia mater. The inner layers of the latter, consisting of delicate fibrillated and a few elastic fibres, send into the cord numerous branching septa, which divide the space occupied by the nerve-substance into smaller irregular spaces, in which the nerve-fibres run, these being surrounded by a delicate net-work of fibrillæ, among which, here and there, variously shaped, for the most part flattened, sometimes branching, connective-tissue cells are found.* This delicate supporting connective tissue is called *neuroglia*. In addition to the fibrillar and cellular elements above described, there seems to be a greater or less amount of soft homogeneous or finely granular material lying in the interstices of nerve- and connective-tissue fibres. The amount of connective tissue in the white substance of the cord, relative to the nerve-fibres, varies considerably in the different columns.

In the gray matter of the cord, we have also nerve- and connective-tissue elements and blood- and lymph-vessels; the first consisting of ganglion-cells and nerve-fibres. The nerve-fibres are in part

* Neuroglia cells. See Appendix, p. 254.

medullated, in part naked axis cylinders; and besides these, a multitude of extremely delicate gray nerve-fibrils occur, which seem partly to come from the breaking up of axis cylinders, and partly to be the delicate branching processes of ganglion-cells. The nerve-cells of the gray matter are, for the most part, multipolar, and vary greatly in size, the largest being found, as a rule, in the anterior cornua. They are arranged in irregular groups in different parts of the cord.

The connective-tissue elements of the gray matter consist of a delicate neuroglia framework, similar, in most respects, to that supporting the nerve-fibres between the coarser septa of the white substance. In the hinder portions of the posterior cornua there is a circumscribed area, which, in the fresh cord, has a peculiar gelatinous appearance, and is called the *substantia gelatinosa of Rolando*; in this we find comparatively few nerve-elements and much connective tissue. The limitations of this manual will not permit us to consider more in detail what is known of the course of the nerve-fibres through the cord, and the more exact relations to the ganglion-cells.

The blood-vessels enter the cord from the pia, along the septa which the latter sends into the organ, and ramify in its substance, the capillary plexuses being denser in the gray than in the white matter.

THE BRAIN.

In this organ also we have gray and white matter; but they are arranged in a much more complicated manner than in the spinal cord, the grouping being far too intricate for consideration here. The collections of gray matter are variously associated with one another by means of the nerve-fibres of the white substance.

The white substance of both cerebrum and cerebellum consists of coarser and finer, but all very small, nerve-fibres, running in various directions, and supported by a delicate connective-tissue framework, similar to the neuroglia of the cord. The gray matter consists here, as in the cord, of ganglion-cells, and fine gray fibres supported by connective tissue. In parts of the gray as of the white substance, certain cellular and fibrous elements occur, of which it is at present impossible to say whether they are connective or nerve-tissue. Indeed, it is the difficulty of determining the nature of certain structures in the brain, together with their extreme delicacy, and the difficulty of isolating them, which renders the histology of the brain so difficult a theme, and explains the unsatisfactory state of our knowledge concerning it.

We cannot do more in these lessons than to study briefly the structure of two of the best known and, at present, perhaps most interesting parts of the

brain—namely, the cortical portions of the cerebrum and cerebellum.

a. Cortex of the Cerebrum.—The structure of this part of the brain differs somewhat in different regions, but that of one of the frontal lobes is sufficiently typical for our purpose. Here, in a section perpendicular to the surface, and extending through the entire depth of the gray matter, five zones or layers may be recognized, which, however, merge into one another.

In the most superficial layer, the connective-tissue elements preponderate, and among them, delicate nerve-fibrils interlace, and a few small, scattered globular and elongated branching nerve-cells are found; the second layer is characterized by a great number of small more or less pyramidal cells; the third and broadest layer contains a proportionately smaller number of ganglion-cells than the second, but they are larger, and, for the most part, pyramidal, or broad spindle-shaped, and multipolar, with their long axes perpendicular to the surface of the cortex; in the fourth layer, which is much narrower than the last, are large numbers of small globular and irregular-shaped and branching cells; the fifth layer, finally, contains medium-sized spindle-shaped cells, with long tapering processes, together with a certain number of smaller irregular-shaped cells. In the third layer, certain of the delicate nerve-fibres begin to take a more regular course toward the

white matter; and in the fourth and fifth layers, they are readily seen in distinct bundles passing inward between the ganglion-cells.

b. Cortex of the Cerebellum.—In sections through the cortex of the cerebellum perpendicular to the surface, three distinct layers are recognizable: the outer, sometimes called the *molecular layer*, consists, like the outer layer of the cerebral cortex, of a delicate connective-tissue framework, which supports fine nerve-fibres and small spindle-shaped and branching nerve-cells; the middle, *cellular layer*, is formed by an irregular row of large ganglion cells, *Purkinje's cells*, whose branching processes extend into and ramify in the outer layer, while the axis-cylinder process passes inward through the inner layer; the inner, *granular layer*, contains a great number of small spheroidal cells whose nature is undetermined. The granular layer merges gradually into the white substance and is thickest at the summit of the convolutions, where also Purkinje's cells are most abundant.

The blood-vessels penetrate the cortex of both cerebrum and cerebellum, in the form of small arterial twigs from the pia, and form an abundant network in the gray substance, being somewhat differently distributed in different parts of the organ, and less abundant in the white than in the gray matter.

The *Dura Mater* of the brain is a dense connective-tissue membrane containing numerous elastic fibres and lined within by endothelial cells. Where it is

attached to the bones of the skull, to whose inner surface it acts as periosteum, the tissue on the attached surface is looser in texture and abundantly supplied with blood-vessels. It contains the ordinary flattened connective-tissue cells, and usually a certain number of "plasma" cells. The dura mater of the cord does not form the periosteum of the bones forming the spinal canal, and hence in it the looser vascular layer is for the most part wanting.

The *Pia Mater* of the brain is a thin connective-tissue membrane, covered on its outer surface with endothelium, and containing an exceedingly abundant net-work of blood- and lymph-vessels. Over the surface of the convolutions it forms a single membrane containing numerous small lymph-sinuses; but as it approaches the sulci it is partially separated into two indistinct layers, the outer bridging over the sulci, while the inner and more vascular layer dips down to the bottom of them. The space within the sulci, between the two layers, is occupied by numerous larger and smaller lymph-sinuses, which under normal conditions are little more than slits in the connective tissue, lined with endothelium; but they are capable of considerable dilatation when, for any reason, fluid accumulates in the meshes of the pia. These spaces are called *sub-arachnoidal lymph-spaces*; the outer layer of the pia having been formerly regarded as a distinct membrane, and called the *arachnoid*. These sub-arachnoidal lymph spaces, as well as the other numerous lymph-channels of the

pia, are in communication with lymph-channels, called *perivascular lymph-channels*, which ensheath certain of the blood-vessels as they enter the brain-substance.

PRACTICAL STUDY.

Transverse Sections of Spinal Cord.—A perfectly fresh human cord should be freed from its dura mater, and short segments from different portions of it hardened in Müller's fluid and alcohol.* Thin transverse sections are made through the entire cord in different portions, and may be stained first lightly with hæmatoxylin and then deeply with eosin and mounted in balsam. A very excellent hardening agent for the nerve-centres is the bichromate of ammonium, 2-per-cent. solution, in which small fragments should lie for a week, and then, after careful washing, the hardening completed with dilute and strong alcohol. They may be stained and mounted as above.†

Sections of Cortex of Cerebrum and Cerebellum.—These should be prepared in the same way as the spinal cord, pieces from the cortex of the frontal lobes being taken, and from the cortex of the cerebellum at any convenient part; they should not be larger than a cubic centimetre, and the chromic fluid well washed out before immersion in alcohol.

Dura Mater.—A bit of this membrane should be stretched on a piece of cork with pins, hardened in alcohol, embedded in hardened liver, and thin transverse sections made, stained double and mounted in glycerin or balsam.

Pia Mater.—This may be prepared by the method given on page 125.

* Embed in celloidin.

† See new staining method, Appendix, p. 254.

CHAPTER XVII.

THE SKIN AND ITS ADNEXA.

THE SKIN.

WE recognize in the skin three layers of tissue: 1, an outer, epithelial layer, the *epidermis*; beneath this, 2, a layer of quite firm and dense connective tissue, the *corium*—true skin, *cutis vera*, or *derma*; 3, a layer of looser connective tissue, the *subcutaneous tissue*, which, merging into the *corium*, serves to bind it to the underlying parts. The skin is variously modified in structure in different parts of the body, corresponding to the different conditions of exposure and wear to which it is subjected, and to form certain supplementary structures, such as the hair, nails, etc.; and contains various sensory and secretory structures.

In the epidermis we recognize two tolerably distinct layers of cells: 1, an outer or *horny layer*, consisting of very thin, transparent, tough, scale-like cells, which present, for the most part, no nuclei, and are packed closely together; 2, an inner layer, the so-called *mucous* or *Malpighian* layer, consisting of larger and smaller nucleated cells of varying shape and character: in the deeper portion, ad-

joining the corium, the cells are more or less cylindrical; above this they are spheroidal or polyhedral or elongated; still nearer the surface they become flattened, and finally merge into the thin cells of the horny layer. In the middle zone the cells present a peculiar jagged outline, looking as if they were bordered by short delicate spines, by which the cells appear dove-tailed together. These spined cells—called *prickle cells*—are very characteristic of this part of the epidermis, and are also found in certain other parts of the body where stratified epithelium occurs, as in the vagina, mucous membrane of the mouth, etc.

The relative thickness of the horny and Malpighian layers of the epidermis differs greatly in different parts of the body; in some parts of the palms of the hands and soles of the feet the horny layer is very thick, and here we often find that the cells which lie between the horny and Malpighian layers form a distinct narrow, transparent zone, called the *stratum lucidum*. The deeper cells of the Malpighian layer contain, uniformly in the negro, and occasionally in circumscribed regions in white men, more or less brown or black pigment.

The epidermis forms in but few regions of the body a layer of uniform thickness, since the corium sends up into it, at varying intervals, simple or branching, variously shaped *papillæ*, the valleys between which, as well as their summits, being cov-

ered by the cells of the Malpighian layer. If we imagine a section made through the skin, parallel with its surface, and just deep enough to cut off the tops of the papillæ, the cells of the Malpighian layer which lie between the latter, would appear, on looking at the cut surface, to be arranged in the form of a net-work, whose meshes are filled by the papillæ of the corium. Hence it is that these collections of cells have received the name *rete Malpighi*.

The corium is formed of interlacing bundles of connective tissue, which are coarser in the deeper, finer in the more superficial portions, where they extend into the epidermis, forming the papillæ. Embedded in the papillæ are capillary blood-vessels, nerves, and special terminal nerve-apparatuses. Elastic fibres are present in considerable number, and in the interstices of the fibres lie flattened, spindle-shaped, branching, and small spheroidal cells. In addition to these elements we sometimes find muscular tissue in the corium; thus striated muscular fibres occur in certain parts of the skin of the face; and smooth muscular tissue, aside from that belonging to the hair-follicle, is found about the sweat-glands, in the skin of the scrotum and penis, and in the nipple and its areola.

The subcutaneous connective tissue we have already studied when considering the connective tissue in detail. In some parts of the skin its texture is

so loose that the corium and epidermis can be readily moved to and fro upon the underlying parts or pinched up in folds; in others its fibres are short and tense, and bind the corium closely to the parts beneath. In the subcutaneous tissue of most parts of the body, greater or smaller deposits of fat occur, forming the *panniculus adiposus*; but in the subcutaneous tissue of the scrotum, penis, eyelids, and the pinna of the ear, fat is not formed.

Blood-vessels.—The arteries of the skin, which enter through the subcutaneous tissue, give off, in general, three sets of branches, through which the blood is distributed to three principal sets of capillaries: first, to those which supply the fat-tissue; second, to those which ramify in the sweat-glands; third, to those which supply the hair-follicles, sebaceous glands, and the papillæ of the corium. Each papilla is furnished with a capillary loop, except when it contains a tactile corpuscle, when the former may be absent.

THE NAIL.

We recognize in the hard substance of the nail, which corresponds to the horny layer of the epidermis, a *body* and a *root*; the former lies upon a portion of the somewhat modified corium, called the *nail-bed*, while the root is embedded in a shallow pocket of skin, the corium of which constitutes the *matrix* of the nail. The corium of the nail does

not differ essentially from that of the skin in general; it is intimately connected with the periosteum of the phalanx, and presents longitudinal ridges, low in the matrix, higher in the nail-bed, which are covered with papillæ. The latter are bent obliquely forward, and are more abundant in the nail-bed than in the matrix. Upon and between the papillæ several layers of variously shaped cells lie, corresponding to the Malpighian layer of the skin. In the body these cells pass quite abruptly into the flat, horny, nucleated cells of the hard substance of the nail; in the matrix, however, the transition is very gradual, and it is here that the growth of the nail occurs. The *lunula* is a portion of the nail in which the Malpighian layer is very thick, as it is in all parts of the root, and being evenly distributed over the surface of the papillæ, does not permit the color of the blood in the capillaries of the papillæ to be seen, as it is in the rest of the nail-bed, where the longitudinal ridges are higher, and covered by fewer cells.

THE HAIR.

We distinguish in the hair: the *shaft*, which projects above the surface of the skin; the *root*, which is embedded in an oblique tubular depression, called the *follicle*; and the *bulb*, a dilated portion at the bottom of the follicle in which the hair ends. The follicle sometimes extends into the subcutaneous

tissue, sometimes only into the corium, and its walls are formed in the first place by a sheath of connective tissue continuous with the corium, in which numerous blood-vessels ramify; this sheath is lined by a thin transparent membrane, called the *vitreous membrane*. Within this follicular wall lies the *root-sheath*, which consists of two layers: an outer thicker layer, formed by the dipping down into the follicle of the cells of the rete Malpighi, and hence consisting of cylindrical, spheroidal; and somewhat flattened cells; and an inner layer made up in turn of an external layer, called *Henle's sheath*, in which the cells resemble those of the horny layer of the epidermis, and are closely packed together to form a transparent mass; and an internal layer, called *Huxley's sheath*, whose cells, belonging more properly to the hair itself, are irregularly polygonal, somewhat flattened, and contain an elongated nucleus.

Both at the opening of the follicle, and at its base, the layers of the root-sheath become indistinct, merging on the one hand into the cells of the epidermis, and on the other into those of the hair-bulb. At the bottom of the follicle is a projection from the connective tissue forming the wall of the follicle, in the form of a papilla, which corresponds to the papillæ of the skin, and upon which the hair-bulb rests, surrounding it at the top and sides. The hair is produced by the growth of cells about

the papillæ; directly covering the latter are cylindrical and cuboidal cells, corresponding to those of the rete Malpighi, which gradually become changed in shape, and more or less horny, and form the substance of the hair-shaft.

In the shaft we recognize three portions: 1. A central or *medullary portion*, composed of cuboidal or more or less flattened cells, not infrequently enclosing between them tiny bubbles of air, which give the centre of the hair a dark appearance by transmitted light. Outside of this is 2, the *cortical portion*, making up the larger part of the bulk of the shaft, and composed of tough, horny, elongated, flattened cells closely packed together, and having within and between them, except in colorless hairs, granules of variously colored pigment. In that portion of the hair which lies within the follicle, and between the bulb and the free shaft, we find, while the hair is growing, that the cells of the cortical layer are larger, less flattened and horny, and, as above mentioned, merge into the large cylindrical and spheroidal cells of the bulb. Finally, the shaft is covered, 3, by the so-called *cuticula*, consisting of thin rectangular, non-nucleated, scale-like cells, which lap over one another, so that the lower cells, *i. e.*, those nearest the root of the hair, cover a portion of the cells beyond, and these free edges often project slightly from the surface of the hair, giving it a finely serrated appearance.

SEBACEOUS GLANDS.

These are racemose glands, whose excretory ducts are lined with polyhedral and somewhat flattened cells. The alveoli, bounded by a membrana propria, are lined with granular polygonal epithelium, and the cavity is more or less filled with larger polyhedral cells, crowded with fat-droplets. The sebaceous glands, as a rule, either open into a hair-follicle near the surface of the skin, or their excretory ducts are pierced near the surface by the shaft of a hair.

The hair-follicle, as above mentioned, is placed obliquely in the skin, and at the side at which it forms an oblique angle with the surface, a bundle of smooth muscle-cells is placed. This is attached to the connective-tissue sheath of the follicle in its lower third, and, passing obliquely upward, is inserted into the upper portion of the corium at some distance from the opening of the follicle. A contraction of the muscle thus placed will, of course, draw the hair-follicle, and with it the shaft, into a position more nearly perpendicular to the surface of the skin, and hence it is called the *erector pilæ*. As a rule, the sebaceous follicle lies above the erector muscle in the angle which it forms with the upper portion of the hair-follicle, and is moved with the hair when the muscle contracts, and may even be pressed upon by it, when, as is frequently the case, it runs closely over the surface of the gland.

This relation of the erector pilæ muscle to the sebaceous gland is probably not without significance in connection with the discharge of the secretion of the latter.

SWEAT-GLANDS.

The sweat-glands, which are found in the skin of almost all parts of the body, although much more abundant in some than in others, are tubular glands, the tube consisting of a membrana propria, lined throughout with polyhedral and cuboidal epithelium. Its lower extremity, coiled into a ball, and held together by loose connective tissue, lies sometimes in the corium, sometimes in the subcutaneous tissue. The upper portion of the tube, which serves as the excretory duct, passes to the surface of the skin, often taking a wavy course through the corium. It pierces the epidermis between two papillæ, and here the walls of the duct cease, and it is bordered by epidermis-cells alone. If the epidermis-layer is thick, as in the palm, etc., the course of the duct through it is a remarkably winding one. An abundant capillary net-work lies in the loose connective tissue of the gland-coil.

NERVES.

The nerves of the skin ramify in the subcutaneous tissue, and a certain number of them terminate here in the so-called *Pacinian bodies*; others pass into

the corium, where they form plexuses, varying in character in different parts of the body. From these, certain medullated nerves pass into the papillæ and terminate in the tactile corpuscles (called Meissner's corpuscles); others pass to the hair-follicles and sebaceous glands; still other, non-medullated nerves enter the papillæ or pass between the cells of the rete Malpighi, but their mode of termination is not yet definitely ascertained. The structure of the Pacinian bodies and Meissner's corpuscles is too intricate, and the methods required for their complete demonstration too elaborate, to justify their further consideration here.

PRACTICAL STUDY.

Sections of Injected Skin.—A piece of skin is removed from an injected leg or arm, care being taken to include the subcutaneous tissue to a considerable depth; it is stretched flat on a bit of cork, and placed in a mixture of equal parts of one-half-per-cent. chromic acid solution and alcohol; after ten days it is transferred to strong alcohol. When sufficiently hard it is embedded in wax or liver,* and sections made perpendicular to the surface; these are stained lightly with hæmatoxylin, then with eosin, and mounted in balsam.

Sections of Skin of Negro.—The skin is hardened in the chromic acid and alcohol mixture, the sections stained with picro-carmin, and mounted in glycerin.

Sections of the Nail.—A nail should be separated from a finger which has been hardened in alcohol, together

* Better in celloidin.

with as much as possible of the connective tissue which binds it to the bone. In order to render the soft parts more consistent and more nearly like the body of the nail, so that uniformly thin sections can be made, the whole should be hardened by the gum method; see page 115. Longitudinal and transverse sections are made through the entire nail, and stained double and mounted in balsam.

Sections of Hairs from Skin of Scalp.—A piece of skin from the scalp of an adult is stretched on cork and hardened in the above chromic acid mixture. Sections* are made as nearly as possible in the direction of the hair-follicles, so as to include the entire root and bulb, and also at right angles to them. They may be stained double and mounted in balsam; or instead of first staining with hæmatoxylin they may be laid for twenty-four hours in a strong aqueous solution of analin green and then dehydrated in the usual way in the eosin alcohol. By the latter method a very brilliant differentiation in color in the layers of the inner root-sheath may be obtained.

Cells of the Cuticula of the Hair.—These are readily seen by placing a hair on a slide in a drop of strong sulphuric acid, and covering; in a short time the cells will have become so much loosened that if the cover be lightly tapped upon, a certain number of them will float off into the acid, or may be seen bristling out from all sides of the shaft.

Section of Skin from the Finger-tips.—This is prepared like the injected skin, and will show the thick layer of epidermis-cells with the stratum lucidum, the tortuous course of the sweat-gland ducts through the epidermis.

* After embedding in celloidin.

In this preparation the ovoidal tactile corpuscles may be seen lying in some of the papillæ, and if the subcutaneous tissue has been included in the section to a considerable depth, transverse or longitudinal sections of a Pacinian body may be found.

CHAPTER XVIII.

THE EYE.

THE organ of sight is composed of the eyeball and various accessory structures, such as the eyelids, lachrymal gland, muscles, etc. The eyeball is composed, in the first place, of a dense, firm, spheroidal connective-tissue envelope, whose anterior transparent portion, the *cornea*, is more convex than the posterior opaque segment, the *sclerotic*, and differs somewhat from it in structure; the sclerotic is pierced posteriorly by the optic nerve. Within the sclerotic lies a vascular tunic, the *choroid*, formed of several layers of tissue, and thrown anteriorly, just behind the sclero-corneal junction, into numerous longitudinal folds, called the *ciliary processes*. An extension from the ciliary processes passes forward, constituting the *iris*, which is a perforated vascular connective-tissue and muscular curtain, suspended behind the cornea, and connected peripherally, near the sclero-corneal junction, with a connective-tissue structure called the *ligamentum pectinatum*.

Passing backward from the ligamentum pectina-

tum, between the ciliary processes and the sclera, and attached posteriorly to the choroid, is a muscle having the form of a flattened ring, thickest in front, called the *ciliary muscle*. The direction of the muscle-cells in the ciliary muscle, which are of the smooth variety, is in part meridional or oblique, in part circular. The ciliary processes and muscle form together the greater part of a structure known as the *ciliary body*. The *retina*, the innermost of the layers forming the wall of the eyeball, spreads out from the point of entrance of the optic nerve over the inner surface of the choroid. At about a third of the distance back from the front of the eye, the nerve-elements of the retina cease in a wavy line, called the *ora serrata*; certain cellular elements continue, however, over the ciliary processes, under the name of *pars ciliaris retinae*.

The crystalline lens is suspended close behind the iris by a firm, delicate, fibrillated membrane, called the *suspensory ligament*, which is attached, on the one hand, to a membrane covering the ciliary processes, and on the other to the capsule of the lens.

The cavity of the eyeball is divided by the lens and its suspensory ligament into two chambers,* the anterior and smaller of which is filled with a homogeneous fluid the *aqueous fluid*; the posterior,

* By the *anterior* and *posterior chambers* of the eye, ophthalmologists at present mean the cavities in front of the lens, separated by the iris, and formerly regarded as constituting the anterior chamber alone, while that containing the vitreous was called the posterior.

with a gelatinous substance, the *vitreous body*, which presents an ill-defined lamellar structure, and sometimes contains a variable number of ill-defined more or less granular cells. The vitreous is surrounded by a delicate membrane, called the *hyaloid membrane*, which is closely connected posteriorly with the lining membrane of the retina, and is hardly to be differentiated from it. The hyaloid membrane is thickened and fibrillated over the ciliary processes, where it is called the *zonula ciliaris*, and a prolongation forward from this constitutes the suspensory ligament of the lens.

Having thus briefly described the general structure of the eye, it remains for us to consider some of its parts somewhat more in detail; the scope of this manual will not permit us, however, to make an extended study of all or even any of the structures in the eye; we shall be obliged to confine ourselves to the more marked structural features of the *cornea* and *sclera*, the posterior portions of the *choroid* and *retina*, the *iris* and *crystalline lens*.

THE SCLERA.

The sclera is composed of very closely interwoven connective-tissue fibres, with fine elastic fibres, the latter most abundant near the inner surface. Between the fibres, which have little regularity in their arrangement, lie flat connective-tissue cells, a certain number of which frequently contain pigment-gran-

ules. On the external surface the sclera sends off delicate fibres anteriorly into the subconjunctival tissue, while posteriorly, behind the muscle tendons, they join to form the wall of a lymph-sac, called the *capsule of Tenon*. On the inner surface certain fibres pass directly over into the choroid; others form the outer wall of a lymph-sac between the sclera and choroid, and called, on account of its yellow color, the *lamina fusca*; it resembles in structure the outer layers of the choroid, presently to be described as the *membrana supra-choroidea*, of which it is indeed a part. In man and many animals, the opening in the posterior segment of the sclera, through which the optic nerve passes, is crossed by a net-work of connective-tissue fibres; these pass in from the sclera on all sides, and surround the delicate bundles of nerve-fibres of the opticus, forming the *lamina cribrosa*.

THE CORNEA.

The cornea is directly continuous at its periphery with the sclera, but differs from it in structure in many particulars, among the more prominent of which are, the more regular lamellar arrangement of its connective-tissue basement-substance, the greater transparency of the latter, the peculiar form of its cellular elements, and the free surfaces covered with cells.

In a thin section of the cornea, perpendicular to

its surface, we recognize, passing from before backward, five layers: 1. A stratified layer of epithelial cells—the *anterior corneal epithelium*—consisting of cells resembling in general form and arrangement those of the epidermis; that is, we have in the deepest layer, cylindrical cells, passing over into polyhedral, and these into flattened cells at the surface; 2. The anterior epithelium rests on a dense transparent membrane, called the *anterior basal membrane*, or *lamina elastica anterior*, which is composed of closely packed fibrillæ; 3. The body of the cornea—*substantia propria corneæ*—is composed of connective tissue whose characteristics we have already studied; 4. Lying closely upon the posterior surface of the last layer, is a thin, apparently structureless membrane—the *membrane of Descemet* or *lamina elastica posterior*—upon which lies: 5. A single layer of flattened polyhedral cells, called the *endothelium of Descemet*.

Except at its extreme periphery, the cornea contains no blood-vessels. Nerves, on the other hand, are very abundant. These, in larger and smaller trunks, enter the cornea at the periphery, and dividing and subdividing, break up into bundles of extremely delicate fibrils, some of which are distributed to the superficial, others to the deep, layers of the cornea. These fibrils form extraordinarily delicate and intricate plexuses, and are finally resolved into the ultimate nerve-fibrils

which, often finely beaded, pass off to their terminations. The exact mode of termination of the nerve-fibrils in the cornea is not yet sufficiently definitely known; certain of them, however, seem to pass between the anterior epithelial cells, and are believed by some investigators to end in free extremities at the surface.

THE CHOROID.

In the posterior portion of the eye, the choroid presents four layers, which, although intimately connected, and presenting no sharp line of division, may yet be more or less completely separated by a careful dissection. Directly beneath the lamina fusca of the sclera, and forming the inner wall of the above-mentioned lymph-sac, is the outermost layer, called the *lamina supra-choroidea*; it is composed of a series of superimposed connective-tissue membranes containing delicate elastic fibres and numerous flattened, irregular-shaped, often branching pigmented cells. The layers are covered with endothelium, and the spaces between them are lymph-spaces or sinuses.

Within the lamina suprachoroidea lies a layer, containing the larger arteries and veins of the choroid, called the *external vascular layer*, or the *layer of Haller*. This layer is composed of a groundwork similar to the suprachoroidea, in which the vessels are embedded, the arteries being often

closely surrounded by dense masses of pigmented cells.

The inner vascular layer, called the *chorio-capillaris*, follows next, and consists almost entirely of a very dense net-work of broad capillary blood-vessels. Finally, the choroid is limited within, by an extremely delicate, finely striated membrane, called the *lamina vitrea*, or *membrane of Bruch*.

THE IRIS.

The iris is a thin connective-tissue membrane, pierced near the centre by an opening, the *pupil*, and joined at the periphery to the ligamentum pectinatum and the ciliary body. The bulk of the iris, the *substantia propria*, consists of delicate inter-lacing connective-tissue fibres, among which are numerous variously shaped, often branching pigmented and unpigmented cells.

It contains numerous blood-vessels which are characterized by an extraordinary thickness of the walls. Near the pupillary margin lies a circular band of smooth muscle-cells—*sphincter pupillæ*—while radiating bands of similar cells passing from the periphery toward the pupil—*dilator pupillæ*—are found in certain animals, but not in man. The anterior surface is covered by a layer of endothelial cells, while the posterior surface is covered by an irregular thicker layer of polyhedral cells, which are densely crowded with pigment, and constitute the so-called *uvea*

THE RETINA.

Of all the animal structures the retina is one of the most delicate, complicated, and difficult of study, and we can do little more here than indicate briefly the general grouping of its elements. It consists of a connective-tissue framework by which the nerve-elements are supported, and with which they are most intimately associated; and in some cases it is as yet impossible to say to which variety of tissue a given element belongs. We distinguish, in typical parts, ten layers; commencing from within, they may be enumerated as follows:

1. *Membrana limitans interna.*
2. Layer of nerve-fibres.
3. Layer of ganglion-cells.
4. Internal molecular layer.
5. Internal nuclear layer,
6. External molecular layer.
7. External nuclear layer.
8. *Membrana limitans externa.*
9. Layer of rods and cones.
10. Pigment layer.

The limiting membranes, the outer of which is perforated by numerous openings, are very delicate and homogeneous, and belong to the connective-tissue framework. In the layer of nerve-fibres, which is thickest around the entrance of the optic nerve,—thus forming the papilla,—the fibres spread

out, intricately interlacing, into a thin sheet, and then pass outward into the next layer to join the ganglion-cells. These, which have the general characters of branching nerve-cells, send numerous processes into the internal molecular layer, where they break up into an extremely delicate fibrillar net-work associated with the connective-tissue framework. Most of the nuclei in the internal nuclear layer are believed to belong to small nerve-cells, while the larger ones belong to the connective-tissue framework. In the external molecular layer, again, we have a delicate net-work of nerve-fibrils intermingled with connective tissue. The nuclei of the external nuclear layer seem to belong exclusively to nerve-elements, and are directly connected, by processes which pass through the openings in the external limiting membrane, with the rods and cones.

Of the rods and cones, which within the limits of this book cannot even in a general way be adequately described, the rods are the longer, are usually somewhat pointed at the inner extremity where they join the nerve-elements of the outer nuclear layer; the cones are shorter, are connected also with nerve-elements within, and terminate externally in pointed or rounded extremities.

The connective-tissue elements of the retina consist, in certain layers, of broad, irregular radial fibres forming frequent inosculations, and, in the molecu-

lar layers, of a delicate reticulum, within which the nerve fibrils ramify.

The pigmented epithelium of the retina consists of large polyhedral cells set together side by side, and forming a continuous layer over the distal ends of the rods. As seen from the side, as we have already studied them, p. 24, they appear like flat pentagonal or hexagonal plates, but when seen in profile while *in situ*, it is evident that they send down long, slender pigmented processes between the rods.

The outer portion of these cells, that next to the choroid, usually contains the nucleus and but little pigment, while the amount of pigment in the processes seems to depend upon whether the eye had been exposed to light or not immediately before death. For it has been recently shown that in some animals the pigment particles under the influence of light can move within the narrow cell-processes so as to be now collected within the inner portion of the cell-body, and again grouped in larger and smaller masses between the rods. In this movement the pigment particles are themselves passive, the change in position being due to active movements in the protoplasm, induced by light.

The larger arteries and veins ramify beneath the internal limiting membrane in the layer of nerve-fibres, and from these blood is distributed outward to all the layers, as far as to the external nuclear layer, beyond which no blood-vessels are found.

THE LENS.

The lens is a transparent double convex body, of sufficient firmness to maintain its form when removed from the eye, and is enclosed in a homogeneous elastic capsule which is thicker on the anterior than on the posterior surface. To the peripheral zone of the capsule, on both anterior and posterior surfaces, the suspensory ligament is firmly attached. The body of the lens, although perfectly transparent, is by no means structureless. Behind the anterior wall of the capsule lies a single layer of flattened polygonal cells, which at the equator gradually lengthen out to form very much elongated, band-like nucleated cells, or *lens-fibres*, which running meridionally, and joined by interfibrillar cement-substance make up the greater part of the body of the lens. The lens-fibres are slightly ridged upon the surface, and have, on transverse section, a flattened hexagonal form; they are so intimately joined to one another at their sides by the cement-substance, that under certain circumstances they may be peeled off in layers.

The course of the fibres in the lens is somewhat complicated, but it may be said in general that they run meridionally from one-half of the lens, in broad sweeps, over into the other; inasmuch, however, as the individual fibres are not long enough to reach the entire distance from one pole of the lens around

to the other, they commence along certain definite lines at varying distances from the poles; and the farther from one pole one end of the fibre is, the nearer to the other will its other end lie. In the young human lens, the lines from which the fibres start may be seen on the anterior and posterior surfaces, under certain circumstances, in the form of a three-rayed star; in the adult, the rays usually part at the ends, giving rise to secondary rays.

THE EYELIDS.

These are formed in general by a plate of connective tissue, which toward the free border is very dense and firm, and called the *tarsal cartilage, or tarsus*; they are covered on the outside by skin, on the inside by the conjunctival mucous membrane; between the tarsus and the skin lie the bundles of the *musculus orbicularis*. The tarsus, which is, in no sense, cartilage, is a plate of very dense and firm fibrillar connective tissue, containing ordinary flattened connective-tissue cells, and is closely connected within with the palpebral conjunctiva. Embedded within the tarsus lie the *Meibomian glands*, thirty to forty in number in each lid. They consist of numerous vesicular alveoli, lined with short cylindrical cells, arranged along and opening into long excretory ducts, which are lined with laminated epithelium, and open on the inner border of the edge of the lids. They are some-

what modified sebaceous glands, but, unlike most sebaceous glands are not connected with hair-follicles.

The skin of the eyelids is somewhat thinner than that of the face, is beset with delicate hairs, and supplied with sweat-glands and sebaceous follicles. It passes over on to the edge of the lids, at the inner border of which it becomes continuous with the mucous membrane. The eyelashes are inserted obliquely into the edge of the lid, in from two to four rows; and the follicles, which are quite deep, are furnished with sebaceous glands.

The conjunctival mucous membrane of the lids consists of a basis substance of loose fibrillar connective tissue containing a few elastic fibres and numerous small spheroidal and branching cells. The epithelium is laminated, consisting of a deep layer of polyhedral cells, then more superficially of more or less columnar cells.

The epithelium of the bulbar conjunctiva approaches more and more closely in structure that of the cornea, as we pass from the lid over toward the sclero-corneal junction.

Small racemose glands, called *accessory tear-glands*, are often seen opening on the surface of the mucous membrane. In addition to the striated muscular bundles of the orbicularis, smooth muscle-cells, forming a membranous layer, occur beneath the conjunctiva on the orbital portion of the lids.

PRACTICAL STUDY.

General Dissection of the Eye.—For this purpose a large eye, like that of the sheep or ox, is preferable ; it should be opened by a short incision through the sclerotic, so that the fluid can readily come into contact with the parts within, and placed in Müller's fluid ; after two weeks it is carefully washed and placed in alcohol for a week, when the dissection may be made.

The eye should be divided with a sharp razor into lateral halves, the section passing through the optic nerve. The cut surface shows clearly the general relations of the parts ; *cornea, iris, lens, ciliary body, vitreous, retina, choroid, and sclera* are seen in approximately normal relations to one another.

If the vitreous be now removed from one of the halves, the retina and ciliary body come more fully into view. As the zonula ciliaris approaches the edge of the lens, it divides into two layers, which pass, one to the anterior, the other to the posterior surface of the body, forming the suspensory ligament ; the slit-like opening between the layers is called the *canal of Petit*, which may be seen by pulling the lens slightly backward, when the layers will separate.

Now seizing the half of the lens with forceps and carefully drawing it downward and backward away from the iris, the zonula ciliaris, in the form of a folded fringe-like membrane, will be separated from the surface of the ciliary body. A portion of this, in connection with a fragment of the lens-capsule, is detached from the lens, stained deeply in eosin, and mounted in glycerin. After

the removal of the lens, the form and attachment of the iris are readily seen.

In the same half of the eye, the layers of the choroid may be demonstrated. For this purpose the retina is pulled off, and the pigmented cells, which are apt to adhere to the inner surface of the choroid, are brushed or scraped off. The eye is now firmly pinned with the flat side down to a flat bit of cork which has been attached to a piece of sheet-lead and sunk in a dish of water deep enough to cover the eye. A window about a centimetre square is now cut through the sclera, including the sclero-corneal junction, and the bit of sclera having been removed, care being taken not to disturb the ciliary body, the membrana suprachoroidea will be seen as a brown loose tissue floating at the surface of the choroid. Bits of this are pulled off with the forceps, stained with hæmatoxylin, floated smoothly on to a slide immersed in water, and mounted in glycerin. The floating shreds of the suprachoroidea which remain after suitable specimens have been obtained, should now be pulled from the eye, when the vascular layer of Haller will come into view.

The separation of the three remaining layers is not easy under the most favorable conditions, and is especially difficult in the eye of the ox and sheep, where the layers are rendered more complicated and difficult of separation by the presence of a mass of interlacing fibres. Haller's layer, however, and the membrana chorio-capillaris may be, with care, stripped off in pieces sufficiently thin for demonstration; sometimes a fragment will be obtained, which, especially at the edges,

will show both of the vascular layers at once. They are stained double and mounted in glycerin or balsam.

Cornea and Sclera.—A fresh eye from the rabbit or dog is hardened in Müller's fluid and alcohol. The cornea should now be excised close to the sclero-corneal junction, embedded in wax or liver, and thin sections made perpendicular to the surface, including the entire thickness. They may be stained double and mounted in glycerin.

A transverse section may be made from a bit of the sclera from the same eye ; stained double and mounted in balsam.

Sclero-corneal Junction, and Iris.—The cornea and sclera, in their relations to one another, and the ciliary bodies, and iris, may be examined in a specimen prepared as follows : An eye—that of the pig is best, if a fresh human eye cannot be procured—is placed, after making a short incision in the sclera, in Müller's fluid, where it remains for two weeks, the fluid being changed once or twice ; it is then soaked for an hour or two in water, and the hardening completed in dilute and strong alcohol. A bit is excised, including the sclero-corneal junction and adjacent parts, and embedded in cacao butter by the following method.*

This cacao-butter method of embedding is of great use in making sections of delicate parts where the tissues enclose spaces, or are not close enough together or firm enough to afford a sufficient resistance to the razor. The piece of tissue is transferred from alcohol to a small dish of oil of cloves, which in a short time will penetrate the tissue and render it transparent. It is then

* It is better to use celloidin. See Appendix, p. 252.

placed in melted cacao butter, whose temperature is kept just above its melting point, on a water-bath, for a couple of hours. It is now placed in a little box made from writing paper, in such a position that sections can be made in a suitable direction at the proper time, and the box filled with the melted cacao butter or with the wax mixture described on page II. When the wax is cold the whole forms a solid mass of suitable consistence for cutting, and the wax serves to hold the delicate parts together while the section is being made. Sections are made at right angles to the ciliary body.

The wax and the cacao butter must now be dissolved out by oil of cloves, the latter replaced by alcohol, and this by water; the sections are then stained double and mounted in balsam. This method seems long and complicated, but the excellence of the sections of delicate parts obtained by its use will well repay the worker for his pains.

Lens Fibres by Teasing.—A short incision is made through the sclera of a fresh eye which is soaked for three or four days in a mixture of alcohol and water, 1 to 2. The lens will be found on removal to be white and soft, and readily breaks up into layers; a bit of one of these is teased on a slide in eosin-glycerin and mounted in the same.

Sections of the Lens.—The eye of a rabbit or pig should be kept for a fortnight in Müller's fluid; the lens is then removed, care being taken not to rupture the capsule, and placed for a day or two in dilute and then in strong alcohol. It is embedded in wax,* and thin sections, made in an antero-posterior direction through

* Or celloidin.

the centre, are stained double and mounted in glycerin or balsam.

Transverse Sections of the Retina.—In a perfectly fresh human or pig's eye, one or two small openings are made through the sclera and it is placed in Müller's fluid; after a week the eye may be cut across just behind the sclero-corneal junction, and the posterior segment placed in fresh Müller's fluid. After another week it is transferred for twenty-four hours to dilute, and then put for two or three days in strong alcohol. A small piece is now cut from the retina at a little distance from the optic-nerve entrance and embedded in cacao butter (see above).* Thin transverse sections are made, the cacao butter dissolved out in the usual way, and stained double and mounted in balsam. By this method the general arrangement of the layers is well shown, but many of the finer details of structure are obscure.

* Celloidin is much better for embedding the retina.

APPENDIX.

PAGE 10. *Section-Cutting with the Microtome.*—Although it is very important for every worker in normal Histology to be able to cut thin sections with the free hand, it is desirable in many cases to make use of an instrument called the Microtome for this purpose; since, when many sections are to be cut, much time is thereby saved, and sections can be made much thinner and smoother. One of the best instruments is that devised by Prof. R. Thoma, of Heidelberg, and known as *Thoma's Microtome*. This instrument is made of three sizes, and the intermediate or largest size is most useful. This can be imported from the maker, Rudolph Jung, of Heidelberg, Germany; or it can be obtained from the Prang Educational Co., 7 Park Street, Boston, Mass., or of Meyrowitz Bros., corner of Fourth Ave. and Twenty-third St., N. Y. The method of using the instrument need not be described here, since with the instrument at hand any worker will readily make out for himself the necessary procedure.

The instrument and mode of using are described in *Four. Royal Microscopical Soc.*, vol. iii., p. 298, 1883.

The Freezing Microtome.—For many purposes it is desirable to study thin sections of fresh tissues which have not been subjected to the action of hardening agents. Such sections are best prepared with a so-called freezing microtome, by means of which, by the action usually of a spray of ether or rhigolene, small pieces of tissue may in a few seconds be made hard and easily cut off in thin slices. The

freezing microtome of Thoma is one of the simplest and cheapest, and can be obtained as above. A thin bit of the fresh tissue, not more than 2-3 *mm.* thick, is placed on the metal plate, and a spray of ether from an ordinary two-bulbed atomizer being directed against the lower side of the plate, the tissue will soon become solid, and sections may be shaved off by passing the knife—held a little obliquely on the edge, like the knife of a plane—over the glass plate. These sections may be studied unstained, or be stained with a one-per-cent. aqueous solution of anilin green. This method is very useful when it is desirable to determine the nature of a tissue without waiting for the action of hardening agents, as well as for seeing it in a nearly natural condition.

PAGE II. *Embedding in Celloidin.*—Although the methods of embedding given on pages II, II5, and 247, in wax and paraffin, gum and cacao butter, are useful for some purposes and were formerly universally employed, celloidin, which has been recently suggested for this purpose, is much better in almost all cases, and has largely superseded them.

Celloidin is a purified form of collodion, which is non-explosive, and comes in the market in the form of dense glue-like sheets or shavings. It may be obtained in a pure form from Bachrach and Brother, corner Eutaw and Lexington streets, Baltimore, Md. It is prepared for use by making a saturated solution in equal parts of common sulphuric ether and alcohol. The solution should be of about the consistence of moderately thick mucilage. The specimen to be embedded should have been previously soaked in alcohol. It is placed for a few hours in a mixture of equal parts of alcohol and ether, and then transferred to the celloidin solution and left until it is thoroughly penetrated by the latter. If the specimen is small this will usually be accomplished in from twelve to twenty-four hours. A small square box is now made of filter paper, and the specimen being placed in a proper position in this, the celloidin solution is poured around it so as to fill up the box. The box should be made considerably larger than the specimen, as the celloidin shrinks considerably in hardening. If the microtome is to be used for cutting the section, or if the bits of tissue are small, it is well to make the box by rolling the paper around

one end of a straight cork of the proper size, so that it will project from the end, and tying it with a thread. The cork is now set upon end with the cylindrical box uppermost, and the specimen placed in this, and the celloidin poured in as before. In this way the celloidin with the specimen will harden on to the cork which can be readily clamped in the microtome. In many cases, if the specimen is small, it will suffice, after it is permeated with the celloidin, to place it directly on the end of a cork, and pour a little celloidin—as much as will lie on the end of the cork—directly over it.

After enclosing the specimen in any of these ways in the semifluid celloidin, the latter is hardened by allowing the preparation to stand in the air or under a bell jar until some of the ether has evaporated, and the celloidin becomes partially hardened on the outside, and then placing it in a mixture of equal parts of alcohol and water. In this, after a longer or shorter time, the celloidin will acquire the proper consistency for cutting, shrinking considerably as it does so. By a little practice, the worker will soon learn just how thick to make the celloidin solution, and how long to leave it exposed to the air, and in the dilute alcohol for hardening.

When the sections are cut they may be stained in the usual way, and mounted in glycerin or balsam. It is not necessary to remove the celloidin from the section, since it is transparent, and for most purposes interferes but little with the subsequent study, and it greatly facilitates the handling of delicate specimens, holding as it does very fragile or friable tissues perfectly in place. In mounting in Canada balsam, if oil of cloves be used, the celloidin is dissolved by it, leaving the section free. The celloidin may be kept on the section by using for clearing up the specimen the white oil of thyme instead of oil of cloves. The uncut portion of the specimen may be preserved indefinitely, ready for cutting, in eighty per cent. alcohol.

The So-called Third Corpuscle of the Blood.—Several observers have described the occurrence in the blood of numerous pale discoidal bodies considerably smaller than the red blood cells. They are apt, when the blood is withdrawn from the vessels, to become clustered in irregular masses. These are often called blood-plates. It is probable that many of the “free granules” described in the text are the struc-

tures described under this name. Too little is as yet known about their structure and function, or the conditions under which they occur, to make it necessary to describe them further here.

Neuroglia.—The nerve elements of the central nervous system are supported and held in place in part by connective-tissue septa and prolongations which pass inward from the pia mater; in part by a delicate net-work of a peculiar form of connective tissue called neuroglia. The latter consists for the most part of fine fibrils, and of irregular-shaped flat-bodied cells, which frequently send off numerous exceedingly delicate branching processes. These cells are called *neuroglia cells*, and from their numerous and delicate process are very commonly known as “*spider cells*.”

Silver Staining of Bladder.—As the injection of an entire frog is somewhat difficult without considerable practice, the following procedure may be substituted for it: The bladder is exposed in a freshly-killed frog, and a canula being passed into it, the organ is moderately distended with air and ligated in this condition. It is then cut out, rinsed in water, and laid for twenty minutes in one-half-per-cent. solution of silver nitrate. It is then rinsed and exposed to the light, and treated as on page 126. The pictures are more distinct if the epithelium be scraped from the inner surface before mounting.

Respiratory Epithelium.—These thin transparent cells which partially line the air-vesicles are sometimes called *respiratory epithelium*, and it was formerly supposed that such cells were confined to the terminal air-spaces. It has been recently shown, however, chiefly by the researches of Kölliker, that the respiratory epithelium is abundant in the smaller bronchi as well, and these he accordingly calls *respiratory bronchioles*. The peculiar character and distribution of this epithelium, which seems so well fitted to facilitate the interchange of material between air and blood in the lungs, would seem to indicate, therefore, that the actual respiratory surface in the lungs is greater than we have been wont to believe.

Weigert's Acid-Fuchsin Method for Staining Nerve-Tissue.—While for a standard method in studying the central nervous system, the double staining with hematoxylin and eosin answers a very good purpose, it fails to show the nerve-elements with sufficient distinctness,

being best adapted to reveal the connective tissue. A method recently described by *Weigert*, on the contrary, when carefully followed, brings out the nerve fibres, even in their finest ramifications, with great distinctness. It is called the acid-fuchsin method, because the stain employed is one of the so-called acid anilines. It is rosanilin in which one atom of H is replaced by the radicle $S O^3H$. It is a sulphate of rosanilin. It does not stain the nuclei of cells, but stains the tissues diffusely. It is found, however, that on treating the stained sections with caustic potash, the color is largely removed from every thing but the nerve fibres, which remain of a deep red color. The ganglion cells are not much colored by it. It is necessary to use a particular preparation of acid-fuchsin for this purpose; namely, one known as acid-fuchsin S. of the Baden anilin factory, which may be obtained in small quantities from Dr. Grüber, 17 Dufour Strasse, Leipzig, Germany, or from Meyrowitz Bros., Fourth Ave. and Twenty-third Street, New York.

The details of this method are as follows: The nerve tissues (brain or spinal cord) must be carefully hardened in Müller's fluid. Alcohol may be used to complete the hardening, but should be used only at the end of the process. Sections are stained from one to twenty-four hours in a saturated aqueous solution of the fuchsin. The differentiation of the elements is accomplished by a saturated alcoholic solution of caustic potash, diluted with alcohol in the proportion of 1-10. The sections are taken from the stain, rinsed in water, and placed in the alkaline bath. The exposure in the latter should be very brief, usually not more than five or six seconds, the section being moved to and fro. If left in the potash too long the color will be removed altogether, and this is consequently a delicate part of the operation. A little practice will enable the operator to determine how long an alkaline exposure to give the section. The latter is now transferred immediately to pure water, which should be changed once or twice to insure the complete removal of the potash. The section may now be dehydrated with alcohol in the usual way, cleared up with oil of cloves, and mounted in balsam. The nuclei of the cells may be brought out by staining lightly with hematoxylin before dehydrating. The color of the preparations is somewhat

deepened by dipping the section for an instant, after the removal of the alkali, into a solution of hydrochloric acid and water 1-5.

In sections stained in this way, the connective-tissue elements have a gray or light violet color, the nuclei alone, if hematoxylin be used, being distinctly stained. Although not especially stained, the ganglion cells may usually be seen with great distinctness. The nerve fibres on the other hand stand out, in successful preparations, with great distinctness, in light or deep red, and we are able to trace their courses and ramifications in a highly satisfactory manner.

The hardening in chromic fluids—especially Müller's fluid—may be greatly hastened by keeping the fluid in which the specimens are immersed at a slightly elevated temperature—35° C. In this way the hardening may be accomplished in about one third the time required at ordinary temperatures. The fluid should be frequently changed. A little gum camphor may be put into the fluid to retard the development of bacteria.

INDEX

	PAGE
ACETIC ACID, action of, on tissues	16
Air-vesicles of lungs, demonstration of epithelium of structure of	176
Albuginea, of ovary	173
of testicle	198
Alcohol, as a hardening and preservative agent	3
Alveolar passages of lungs, structure of	172
Ammonium bichr., as a hardening agent	4
Ammonium chromate (neutral), as a hardening agent	4
Amœboid movement, in white blood-cells, character of	81
method of studying	89
Aniline-red, as a staining agent	35
Arachnoid, of brain	218
Areolar tissue	34
Arteries, structure of	120, 121
method of studying	126
Arterioles	120
Asphalt varnish, for enclosing specimens	24
Axis cylinder of nerve-fibres	104
BALSAM, method of mounting in	15
Blood	80
coagulation of	85
free granules in	84
method of studying fresh	87
plasma of	85
Blood-cells, red	82
action of water on	82
change of form in	83
coloring matter of	84
difference in, in different animals	84
nucleated, in marrow of bone	67
in spleen	139
number of	83

	PAGE
Blood-cells, red	
number of, relative to white blood-cells	83
origin of	86
size of	83
stroma of	84
varieties in	84
white	80
amœboid movements in	81, 89
demonstration of nuclei in	8
origin of	80
Blood-crystals	84, 88
Blood-vessels, adventitia of	120
arteries	120, 121
capillaries	119
classification of	119
intima of	120
musculosa of	120
method of preparing, for study	125, 126
veins	121
Blue gelatine mixture for injecting, formula for prep. of	10
Bone	61
canaliculi of	62
cells	62
decalcified, method of preparing	67
developing, preparation of	77
development of, intra-cartilaginous	71
sub-periosteal	74
intra-membranous	75
hard, method of preparing sections of	69
Haversian canals of	64
marrow of	65
periosteum of	65
Bone-tissue, spongy	62
compact	63
Sharpey's fibres in	64, 75
Brain, arachnoid of	218
blood-vessels of	217
dura mater	217
general structure of	215
pia mater	218
preparation of sections of	219
structure of cortex of cerebellum	217
structure of cortex of cerebrum	216
structure of white matter of	215

	PAGE
Bronchi, large, structure of	170
small, structure of	171
Bruch, membrane of, in choroid	238
Brunner, glands of, in duodenum	150
Budding, cell multiplication by	21
CACAO BUTTER, method of embedding in	247
Canada balsam, hard, for mounting bone	70
solution in chloroform for mounting	14
Canaliculi of bone	62
Capillaries, structure of	119
method of studying	125
Capsule, of cartilage cells	56
supra-renal	164
Carmine, preparation and use of, as a staining agent	7
Cartilage	56
cells of	56
artificial shrinkage of	60
classification of	57
fibro-	59
preparation of	59
fibro-elastic	59
preparation of	61
hyaline, basement substance of	57
preparation of	61
Cells, body of	17
bone	62
ciliated, from frog's mouth	25
classification of	22
connective-tissue	32
corneal, seen on edge	40
seen on flat	41
relation of, to basement substance	42
division of	21
endothelial	33
epithelial, of small intestine	149
ganglion	111
general structure of	17
goblet, in small intestine	150
liver	157
marrow	66
membrane of	19
nuclei of	18

	PAGE
Cells, nucleoli of	19
peptic	147
pigmented, in choroid	36
physiology of	19
plasma	33
practical study of	23
reproduction of	20
tendon	36, 38
Cell-spaces of connective tissue	44
Cement, in roots of teeth	78
Central nervous system	211
Central tendon, in diaphragm of rabbit	127
Chondrin	58
Chromic acid as a hardening agent	4
Chyle vessels, in small intestine	151
Ciliary motion, in cells from frog's mouth	25
Coloring tissues (see staining)	6
Conheim's method of gold staining	39
Coni vasculosi of testicle	189
Connective tissue, classification of	27
distribution of, in body	27
fibrillar	29
of nerves	106
origin of, in embryo	28
practical study of	33
reticular	54
method of preparing	55
Corium of skin	222
Corpus Highmori of testicle	188
luteum in ovary	201
spongiosum of penis	196
preparation of	197
DECALCIFICATION of bone	67
Delafield's method of preparing hæmatoxylin	6
Dentine	78
Double-staining	8
in Canada balsam mounting	14
Dura mater, structure of	217
preparation of	219
ELASTIC FIBRES in connective tissue	30
in ligamentum nuchæ	34

	PAGE
Elastic granules in connective tissue	31
Embedding in cacao butter	247
in gum	115
in liver	11
in wax	11
Emigration of white blood-cells	81
Enamel cuticle	79
of teeth	79
Endocardium, structure of	123
method of studying	127
Endogenous cell reproduction	22
Endothelial cells	33
Endothelium, of mesentery	45
of omentum	46
Eosin, mounting specimens stained with, in glycerin preparation and use of	13 8
Epidermis	220
Epithelial cells from rabbit's bladder	23
Epithelium, renal	182
Erectile tissue, nature of	195
Eye	232
aqueous fluid of	233
canal of Petit	245
capsule of Tenon	235
chambers of	233
choroid	237
ciliary body	233
cornea, structure of	235
preparation of	247
conjunctiva	244
dissection of	245
general structure of	232
hyaloid membrane	234
iris, structure of	238
preparation of	247
lamina fusca	235
lens, structure of	242
preparation of	248
ora serrata	233
retina, structure of	239
preparation of	249
sclera, structure of	234
sclero-corneal junction, preparation of	247

	PAGE
Eye, suspensory ligament	233
uvea	238
vitreous body	234
zonula ciliaris	234
Eyelids	243
FAT CELLS, structure of	50
development of	51
Fat tissue	50
fresh, preparation of	52
method of studying, in adult	53
method of studying, in young animal	53
Fatty infiltration	52
Fibres, elastic, in connective tissue	30
fibrillated, in connective tissue	30
nerve	104
muscle	95
Fibrillæ in tail tendon of mouse	34
primitive muscle	96
Fibrillar connective tissue	29
Fibrin from blood, characters of	85
method of preparing	90
Fibro-cartilage, structure of	59
Fibro-elastic cartilage	59
Fission, cell multiplication by	21
Fresh tissues, method of examining	2
Fuchsine (see aniline red)	35
GANGLION CELLS	111
Gastro-intestinal canal	143
Gelatin, for injecting	10
Gemination, cell multiplication by	22
Generative organs, female	197
male	188
Germ epithelium of ovary	202
Giant cells, in marrow of bone	66
Gianuzzi, crescents of, in submaxillary gland	156
Glands, Brunner's	150
general characters of	144
lymphatic	129
mammary	208
Meibomian	243
peptic	147

	PAGE
Glands, prostate	192
racemose	145
sebaceous	227
submaxillary	155
sweat	228
thyroid	166
tubular	145
vesicular	146
Glisson's capsule of liver	159
Glomeruli of kidney	179, 182
Glycerin as a mounting medium	12
Goblet cells	150
Gold chloride as a staining agent	39
Graafian follicles, structure of	199
development of	202
HÆMATOXYLIN, preparation and use of	6
Hæmoglobin, characters of	84
preparation of crystals of	88
Hair, cells in cuticula of	230
follicle, structure of	225
general structure and relations of	224
papillæ of	225
preparation of sections of	230
shaft, structure of	226
Häler's layer of chroid	237
Hardening agents	3
Haversian lamellæ	63
canals	64
Heart, endocardium	123
muscle of	101
valves of	124
Henle, sheath of	106
Hensen's line in muscle-fibre	97
Highmori, corpus, in testicle	188
Hyaline cartilage, structure of	57
method of studying	59
INDIFFERENT FLUIDS, use of	2
Infundibula of lungs, structure of	172
Injection, interstitial	6
of blood-vessels	10
Intestine, large, structure of	153

	PAGE
Intestine, large, method of studying	154
small,	149
agminated glands of	152
Brunner's glands	150
chyle vessels of	151
epithelial cells of	149
follicles of Lieberkuhn	149
goblet cells of	150
lymph-vessels of	151
muscularis mucosæ of	151
method of study of	154
Peyer's patches	152
solitary follicles of	151
villi of	149
KIDNEY, capsule of	178
connective tissue of	185
convoluted tubules of	181
cortex of	178
cortical pyramids of	179
epithelium of	182
general structure of	178
glomeruli of	179, 182
Henle's loops of	181
injected, preparation of	187
intercalated tubules of	181
labyrinth of	179
medulla of	178
medullary rays of	178
method of examining	185
papilla of	178
parenchyma of	180
position of tubules in	183
preparation of isolated tubules of	186
rabbit's, preparation of	185
straight tubules of	181
uninjected, preparation of	186
uriniferous tubules of	180
Krause, line of, in muscle-fibres	97
LACTATION, changes of mammary gland during	209
Lacunæ, of bone	62
Morgagni, in urethra	194

	PAGE
Lamellæ, of bone	63
Leucocytes	80
Lieberkuhn, follicles of, in small intestine	149
Ligamentum nuchæ	34
Littre, glands of, in urethra	194
Liver	157
blood-vessels of	158
cells of	157
preparation of	161
connective tissue of	161
gall-vessels of	160
general structure of	158
Glisson's capsule in	159
injection of blood-vessels of	162
gall-vessels of	163
lobules of	159
lymphatic vessels of	161
lymphoid tissue in	161
pig's, preparation of	162
human, preparation of	162
Lungs, air vesicles of	172
alveolar passages of	172
alveoli of	172
blood-vessels of	174
infundibula of	172
injected blood-vessels of	177
lobules of	171
method of examining	175
pigment in	175
uninjected, preparation of	175
Lymph	86
follicles	134
Lymphatic capillaries	125
glands	129
spaces	44
vessels	124
Lymphoid tissue	134
MALPIGHIAN BODIES, of kidney	179
of spleen	137
Malpighian layer, of skin	220
Mammary gland, structure of	208
preparation of	220

	PAGE
Marrow, of bone, structure of	65
preparation of	70
Medullary sheath, of nerve-fibres	104
Meibomian glands	243
Meissner's corpuscles	229
Menstruation, changes of uterine mucous membrane in	205
Mesentery, endothelium of	45
Motor-end plates	99
Mounting, in glycerin	12
in Canada balsam	14
Mucin, in embryonal tissue	49
Mucous tissue	48
in umbilical cord, preparation of	50
Müller's fluid, formula for	5
Muscle-cells, smooth	92
isolation of	93
preparation of, from frog's bladder	94
sections of, from intestine	94
Muscle, erector pilæ.	227
Muscle-fibres, general structure of	95
Hensen's line in	97
Krause's line in	97
nuclei of	98
preparation of fresh	99
by osmic acid	100
sections from tongue	100
sarcolemma of	98
sarcous elements of	97
Muscle-fibrillæ, primitive	96
Muscle-tissue, classification of	91
of heart	101
preparation of	102
smooth	92
striated voluntary	95
NAIL, structure of	223
preparation of sections of	229
Nerves, connective tissue of	106
Henle's sheath of	106
intra-fascicular connective tissue of	108
lamellar sheath of	107
peri-fascicular connective tissue of	107
preparation of sections of	115

	PAGE
Nerve-cells, classification of	111
preparation of, from brain	118
from spinal cord	117
processes of	111
sympathetic, structure of	112
preparation of	118
Nerve-fibres, axis-cylinder of	104
classification of	103
fresh, study of	113
incisures of Schmidt in	106
inter-annular segments of	105
medullary sheath of	104
medullated	104
neurilemma of	105
non-medullated	110
physiological significance of structure of	116
preparation of, with osmic acid	114
with silver	115
transverse sections of	114
Ranvier's crosses on	115
of Remak	110
sympathetic, preparation of	118
termination of, in nerve-centres	108
in the periphery	109
Nerve-tissue, classification of	103
Neuroglia, character of, in spinal cord	213
Nodes, lymph	129
Nucleated red blood-cells, in marrow	67
in spleen	139
ODONTOBLASTS	78
Oil of cloves, use of, in Canada balsam mounting	15
Omentum, endothelium of	46
Optical sections	126
Osmic acid, action of, on tissues	5
Osteoblasts	67, 73
origin of	76
Ovary, connective tissue of	198
general structure of	197
Graafian follicles of	199
preparation of	204
Ovum, structure of	200
PACINIAN BODIES, in skin	228

	PAGE
Panniculus adiposus	223
Papillae, of skin	222
of hair	225
Periosteum	65
Peyer's patches	152
Pia-mater, of brain	218
preparation of	219
of cord	211
Pigmented cells, of retina	24
of choroid	36
Pleura, pulmonary, structure of	175
Potassium bichromate	4
Preservative agents	3
Prickle-cells, in epidermis	221
Pritchard's method for gold staining	39
Prostate gland, structure of	192
preparation of	193
Protoplasm	18
Pulp, of spleen	139
of tooth	78
cords, in spleen	139
Purkinje's cells, structure of	112
position of, in cerebellum	217
RANVIER, crosses of, on nerve-fibres	116
Remak, nerve-fibres of	110
Respiratory apparatus	168
Rolando, substantia gelatinosa of	214
SARCOLEMMA	96
Sarcous elements	97
Schmidt, incisures of, in nerve-fibres	106
Schwann, sheath of	105
Sebaceous glands	227
Section cutting	9
Seminiferous tubules	188, 189
Serous membranes	44
Shaking, method of, in preparing tissues	55
Sharpey, fibres of, in bone	64, 75
Silver nitrate, methods of staining with	42, 45
Skin, blood-vessels of	223
corium of	222
epidermis of	220

	PAGE
Skin, from finger tip, preparation of	230
general structure of	220
horny layer of	220
injected, preparation of	229
mucous layer of	220
negro's	229
nerves of	228
papillae of	222
prickle-cells of	221
rete Malpighi	222
stratum lucidum	221
Spermatoblasts	190
Spermatozoa, development of	190
movements of	192
preparation of	191
structure of	191
Spinal cord, arrangement of gray matter in	211
blood-vessels of	214
central canal of	212
columns of	212
connective tissue of	213
cornua of	212
general structure of	211
gray commissures of	212
gray matter of, structure of	213
neuroglia	213
sections, preparation of	219
substantia gelatinosa of Rolando	214
white commissure	213
white matter, structure of	212
Spleen, cavernous venis of	140
distribution of blood in	140
follicles of	137
general structure of	136
preparation of	141
pulp of	139
Staining agents	6
Stellulae Verheyenii	185
Stomach, blood-vessels of	148
general structure of	146
lenticular glands of	148
mucous glands of	147
nerves of	148


	PAGE
Stomach, peptic glands of	147
preparation of sections of	153
Subcutaneous connective tissue, cells of	35
fibres of	33
Submaxillary gland, preparation of	157
relations and structure of	155
Suprarenal capsule, preparation of	164
structure of	165
Sweat-glands	228
Sympathetic, cells of	112
fibres of	110
TEETH.	78
Tendon, cells of, demonstration of	36, 38
fibrillæ of, demonstration of	34
Testicle, preparation of	192
structure of	188
Thyroid gland, formation of colloid in	166
general structure of	166
preparation of	167
Trachea, blood-vessels of	170
mucous glands of	169
preparation of	175
structure of	168
UMBILICAL CORD, mucous tissue in	50
Urethra, general structure of	193
lacunæ Morgagni of	194
Littre's glands of	194
preparation of	197
Uriniferous tubules	180
Uterus, general structure of	204
mucous membrane of	205
preparation of	206
VAGINA, general structure of	206
mucous membrane of	207
preparation of	207
Vas deferens	189
Veins, preparation of	126
structure of	121
valves of	123

	PAGE
WAX-MASS, for embedding	11
Welch's method of demonstrating subcutaneous connective-tissue cells	35
YELLOW elastic tissue	30
ZONULA ciliaris	234

INDEX TO THE APPENDIX.

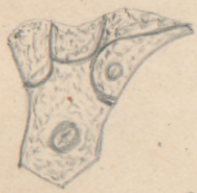ACID, chromic, mode of hastening action of	256
hydrochloric, use of in fuchsin staining of nerves	256
BLADDER, silver staining of blood-vessels of	254
Blood-plates	253
so-called third corpuscle of	253
Bronchioles, respiratory of lungs	254
CAMPHOR, use of in preventing the formation of bacteria in chromic fluids	256
Celloidin, use of as an embedding medium	252
Cells, neuroglia	254
spider	254
Chromic acid, method of hastening action of solutions of	256
EPITHELIUM, respiratory in lungs	254
FREEZING MICROTOME, cutting fresh tissues with	251
Fuchsin, acid, use of in staining nerve tissues	254
GREEN, anilin, use of in staining fresh tissues	252
MICROTOME, freezing, for cutting fresh tissues	251
section cutting with	251
Müller's fluid, mode of hastening action of	256
NERVE TISSUE, Weigert's method of staining with fuchsin	254
Neuroglia cells	254

	PAGE
OIL OF THYME, white, use of for clearing sections embedded in celloidin	253
PLATES, blood	253
Potash caustic, use of in Weigert's fuchsin nerve staining	255
RESPIRATORY BRONCHIOLES	254
epithelium in lungs	254
Rosanalin, acid sulphate of, use of in nerve staining	255
SECTION-CUTTING, with microtome	251
THIRD CORPUSCLE of blood	253
<i>Thoma</i> , microtomes devised by	251
Thyme, white oil of, use of in clearing sections embedded in celloidin	253
WEIGERT'S acid fuchsin, method of nerve staining	254



Cotton Fiber

Page 23





Epithelium cells
Rabbit's Bladder

Linon Fibre



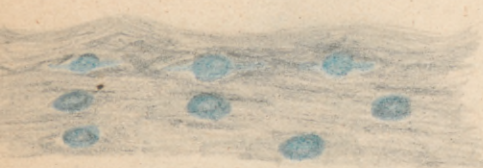
3 ciliated
Epithelium




Page 25

Dog's Trachea

Connective Tissue
cells of
cornea ⊗



Transverse
Section Page 40



Connective Tissue
cell cornea of
Rabbit
Lateral Section

Page 41

cornea treated
with silver
6



Page 42
Fat from Foetal
Pig

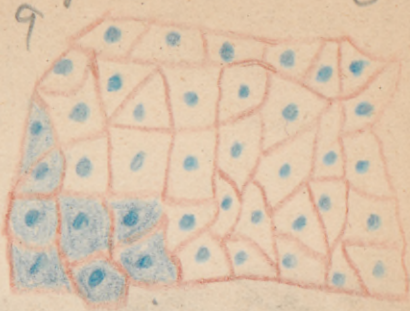
Subcutaneous
connective tissue
cell



8

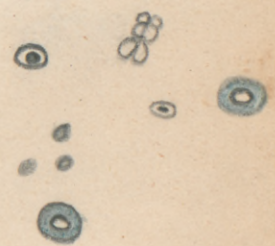
Page 45

3



Endothelial cells
Mesentery
Rabbit

Page 35
Page 46



Endothelial cells of
aerentum Dog

10

Fat globules
Foetal Pig

11

12

4

13



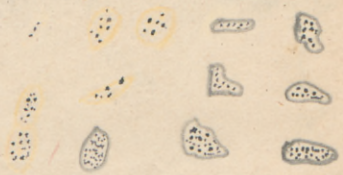should be yellow

Adipose Tissue
Human Testis
Subcutaneous Tissue

Adult subcutaneous Fat

Page 53

Hyaline cartilage



Should be yellow with granular bodies

14

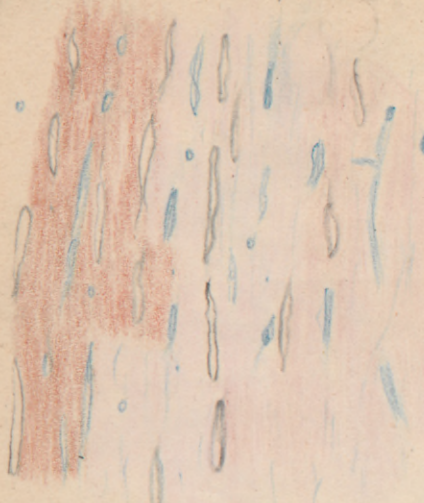15

nective Tissue
Lenticulated con

Page 59

Frog's Femur

Fibro cartilage



16

Yellow
Red Marrow from
Femur young
Rabbit



Epiglottis Page 60



18

Page 70

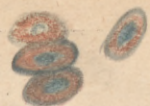
Section of Parietal
Bone foetus - 5 Mos
Page 77

Lacunas &
canaliculi

Page 70

19


Red Blood
Corpuscles
of Frog



6

Page 87 no specimen

Haemoglobin crystals Rat blood



Page 88 no specimen

Frog bladder Involuntary Mus-
cular Fiber,

no specimen







no specimen

Muscular
Fiber

Fibrillated




no



Fiber

Longitudinal Voluntary Muscle



21

Transverse Muscle Fiber
Human Tongue

Heart muscle

Heart muscle 8



22


P.d.

Longitudinal Section Page 107



23

Transverse Section Page 107



24

Page 108

Isolated cells from Longitudinal section Heart muscle.

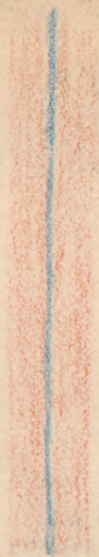
Page 114



25

Nerve fibres treated with Osmic Acid Page 114

26
#12042
Longitudinal section
Nerve Fiber

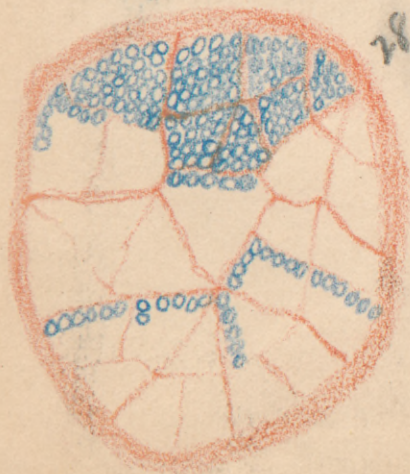

Nerve Cells

9

27


Transverse Section
Nerve Fiber



28

Nerve fibers treated
with Nitrate Silver
29

10



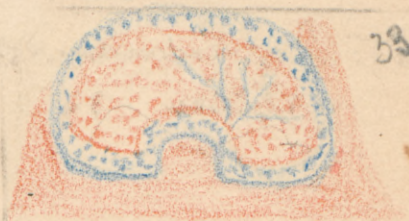
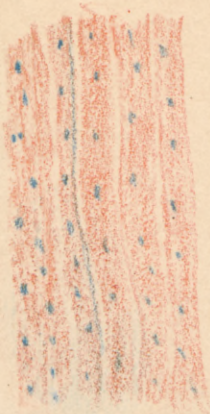
Non-Medullated
Fiber



30

17
Section of Esophagus
Intestine

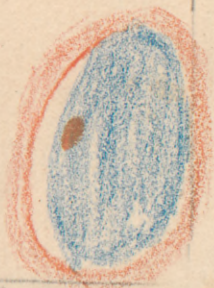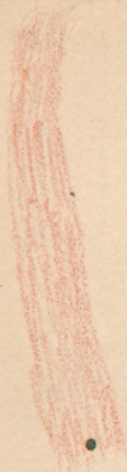
Nov 27th 32
Transverse section
human aorta



Lymphatic gland
from Dog.

Cats Spleen

34

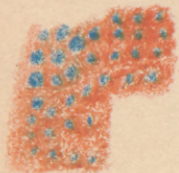
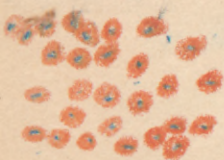


Minute structure
of Lymph node

35

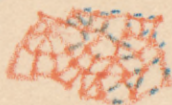
Section of human
Spleen

36



Section of dog
Spleen

37



Isolated spleen
cells.



8

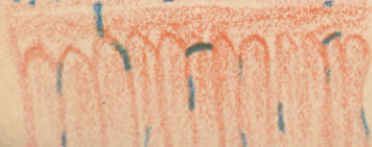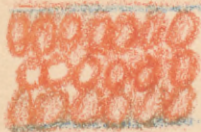


38

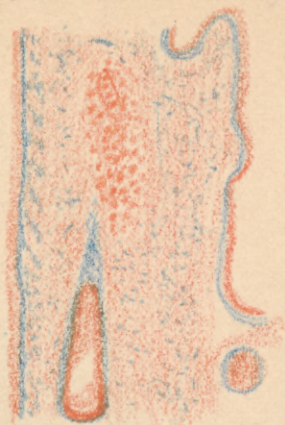
Qd

Section of large
intestine of dog

40



Section of Dog's
Stomach



39

Section of Dog's
Stomach

41



Section of Dog's Stomach

42

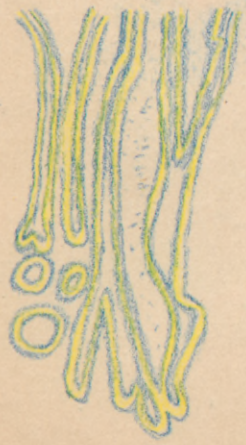Brunner's gland,
Small Intestine

43



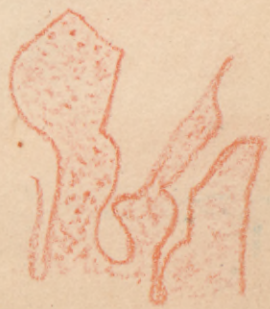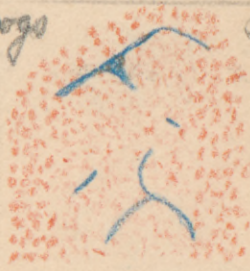
Section of Human
small intestine

44



Dogs

small
Intestine

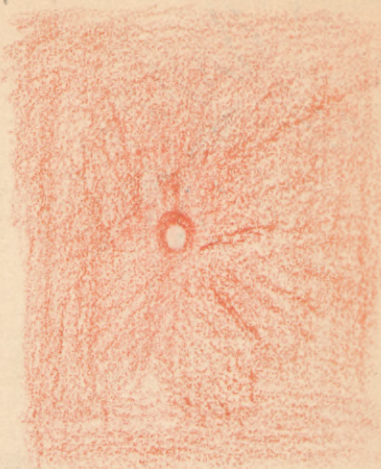


45

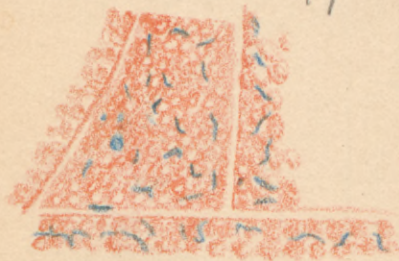
Sub Maxillary gland
Human

Section of Pigs
46
Liver 76

Have not any



Section of a dog's
Pancreas 47




Human Liver
48



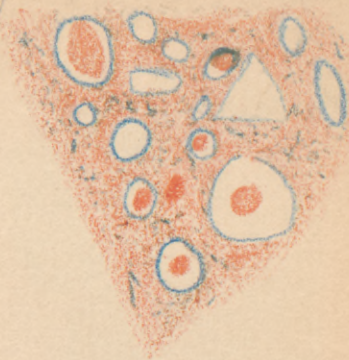
Rabbit's Liver

49

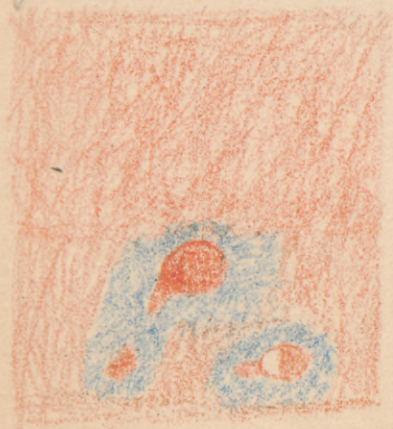


Thyroid Gland

50



Injected Liver



Supra-renal
Capsule

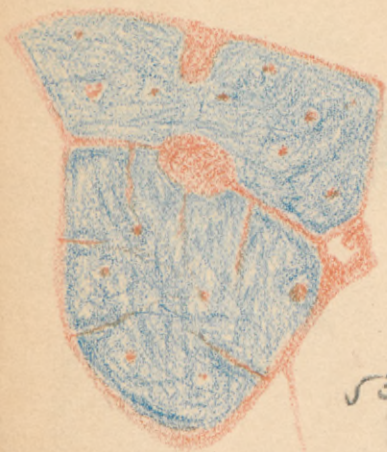#1 Box 3

51


52

Myrius Hand 18

Human Trachea



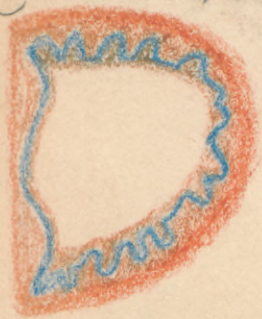53



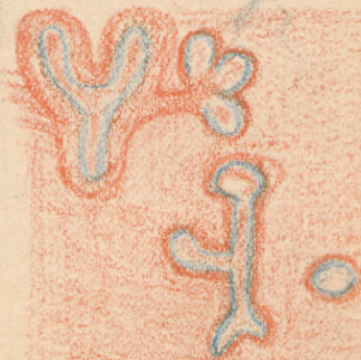54

Human Bronchi

Bronchi from
Fetal Pig 2 in -

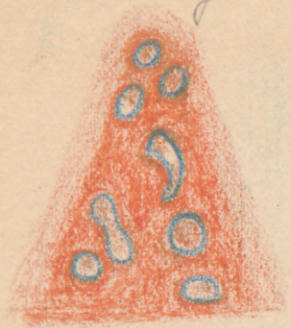


55-




56

Bronchi from
Foetal Pig 5m.



57

Injected Lung 59

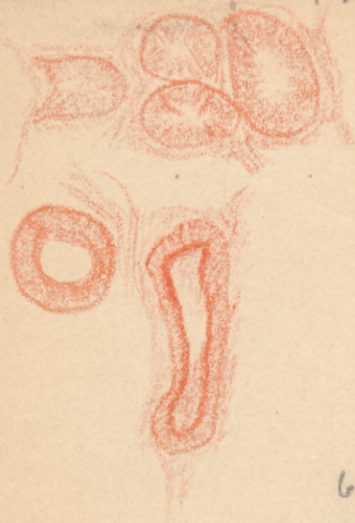

Human Kidney 19

58

Kidney 60

Rabbit's Testicle. 70



61

Human Spermatozoa




62

Human Testicles

63

Elephant's
Spermatozoa



64

Dogs Spermatozoa | Human Prostate
gland

65- 66

Rats Spermatozoa

Section of Penis

67

68



Section of Ovary 2nd
(8194)

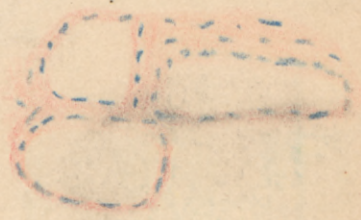Human Uterus

69

70

Cells of mucous membrane
of vagina

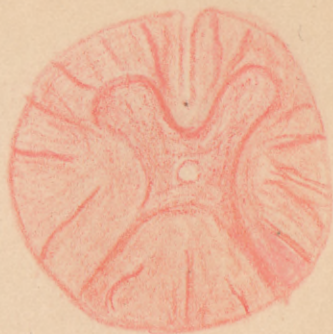Mammary Gland
active



Pd

Mammary Glands
at rest
No sketch

73 Section of a spinal
cord.

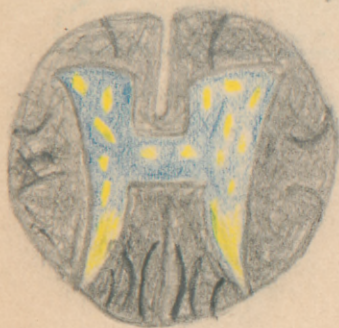

73

74

Section of spinal
cord

75

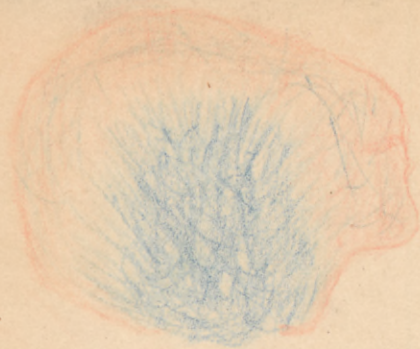


Section of Brain
#1 Box 4

76

Section of Cerebrum

24



77

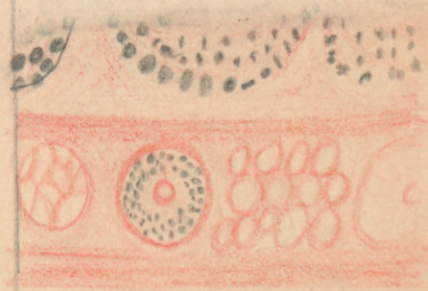
78



79

Section of skin

80



Wing

Human Skin 25



81

Injected.
Blood vessels
Skin from Finger Tips

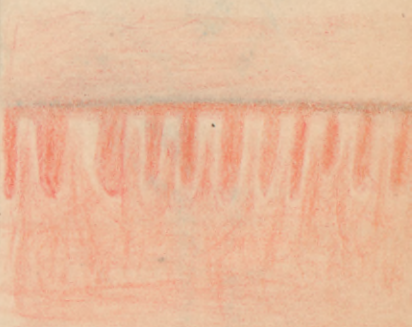


83



82

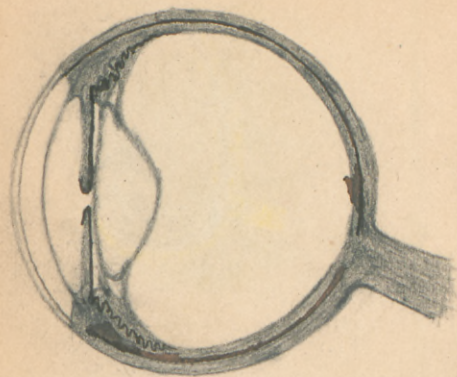
Skin
Chinaman's
Section of Nail



84

General Dissection of
An eye

Sclero-corneal
Junction + Iris



58

98

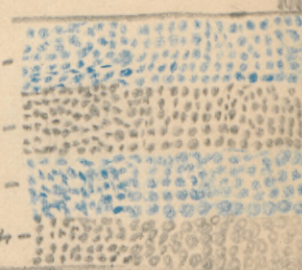
1- the sclera
2- nerve fibers
3- " " cells
4- 10 pigment layers
5- layer of rods + cones

6- Membrana limitans externa
7- Membrana limitans interna


8- Muscular


9- External muscular

10- Internal muscular



The 10 coats of the Retina









QSA P971m 1887

61220260R



NLM 05045782 4

NATIONAL LIBRARY OF MEDICINE