

QS
W765h
1896

QS W765h 1896

61140300R



NLM 05041944 8

NATIONAL LIBRARY OF MEDICINE

SURGEON GENERAL'S OFFICE


LIBRARY.

Section,

No. 156400.



**U.S. NATIONAL
LIBRARY
OF
MEDICINE**



RETURN TO
NATIONAL LIBRARY OF MEDICINE
BEFORE LAST DATE SHOWN

8
JUN 11 1984



SURFACE ANATOMY AND LANDMARKS


A HANDBOOK
OF
SURFACE ANATOMY
AND
LANDMARKS

BY
BERTRAM C. A. WINDLE, D.Sc., M.D.,
M.A. (DUBL.).

PROFESSOR OF ANATOMY IN MASON COLLEGE, BIRMINGHAM; SOMETIME
EXAMINER IN ANATOMY IN THE UNIVERSITIES OF CAMBRIDGE,
ABERDEEN AND DURHAM

SECOND EDITION

REVISED AND ENLARGED IN COLLABORATION WITH
T. MANNERS-SMITH, M.A. (CANTAB.), M.R.C.S.
LECTURER ON OSTEOLOGY AND SENIOR DEMONSTRATOR OF ANATOMY, MASON
COLLEGE, BIRMINGHAM



PHILADELPHIA
P. BLAKISTON, SON, & Co.
1012 WALNUT STREET
1896

Annex

Q5

W765h

1896

film no. 11394

'item 5

TO

ALEXANDER MACALISTER,

M.D., D.Sc., M.A., F.R.S., F.S.A.

PROFESSOR OF ANATOMY IN THE UNIVERSITY OF CAMBRIDGE.

PREFACE TO SECOND EDITION.

THIS second edition has been carefully revised and several new figures have been added. A sense of importance of the relations of the brain to the cranium and scalp has led us to bestow especial attention on this section, which has been largely re-written.

B. C. A. W.
T. M-S.

Mason College, Birmingham.
June 30th, 1896.

PREFACE TO FIRST EDITION.

THIS little book is not a surgical applied anatomy. Had its author ever entertained any idea of writing such a work, he would certainly have abandoned it, as the ground is already occupied by Mr. Treves' excellent manual on that subject, to which he is indebted for various hints. This book is intended for anatomical students in their first and second years as a guide to that important portion of the knowledge of the human body which can be gained without the use of the scalpel and forceps. Junior students will find it useful after having first dissected a part of the body, to study the relations of the various structures, as given herein, on a fresh part, or still better, on the living subject. It is scarcely possible to impress too strongly upon the student desirous of obtaining a thorough practical knowledge of his profession, the importance of taking advantage of the opportunities afforded to him in the wards of the hospital and elsewhere, of familiarising himself with the surface markings, surgical and medical landmarks, and relations to the exterior of the important structures, in the living body.

Whilst not pretending to be a surgical anatomy properly so-called, certain surgical facts have from time to time been mentioned, where the importance of the anatomical point in question might be overlooked, without reference to its practical bearing. But the writer has preferred to err on the side of omission in this

matter, lest the student should be confused by the introduction of too many unfamiliar facts.

Full directions have been given for the examination of certain of the orifices and for the use of some of the commoner surgical instruments, the author believing that it is of great value to the student to acquire a readiness and dexterity in handling them on the dead body, and that such should be learnt concurrently with the anatomical study of the parts in question.

It is difficult to exhibit any great originality in a work such as this (indeed much of what might be called original would inevitably be another name for incorrect), since the facts which are contained herein have mostly appeared in different manuals. To these it would be impossible to refer here in detail, but to their authors, whether their names are mentioned in the text or not, the writer desires to express his full acknowledgments. He has to thank his friend Dr. Crooke, Pathologist to the General Hospital in this town, for help in some of the details gained from the bodies in the post-mortem room of that Institution. Several careful dissections have been made in relation especially to the positions of certain of the thoracic and abdominal viscera, in order to ensure accuracy in the facts stated, and for assistance in these he has to thank his former pupil Mr. E. Teichelmann and his present pupils Messrs. A. R. Green and S. W. Warneford. He has also to thank his friend, Dr. Reid, for two blocks.

TABLE OF CONTENTS.

CHAPTER I.

THE FACE.

	<i>Pages</i>
Sections:—1. The Face. 2. The Eye and Appendages. 3. The Nose. 4. The Ear. 5. The Mouth	1-26

CHAPTER II.

THE SCALP.

Sections:—1. The Scalp. 2. Relation to Bony Vault. 3. Relation to Membranes of Brain and their Vessels. 4. Fontanelles. 5. Relation of Cranium to Brain. 6. Relation of Scalp to Brain	27-41
--	-------

CHAPTER III.

THE NECK.

Sections:—1. The Middle Line of the Neck. 2. Parts near Anterior Border of Sterno-Mastoid. 3. Structures Posterior to Sterno-Mastoid	42-51
--	-------

CHAPTER IV.

THE THORAX.

	<i>Pages</i>
Sections:—1. Bony Points. 2. Soft Parts. 3. Relations of Lungs to Thoracic Wall. 4. Relations of Heart to Thoracic Wall. 5. Relations of Vessels, &c., to Thoracic Wall	52-64

CHAPTER V.

THE ABDOMEN.

Sections:—1. Bony Prominences. 2. Skin Markings. 3. Relations of Viscera to the Abdominal Wall. 4. Relation of Vessels to the Abdominal Wall	65-74
--	-------

CHAPTER VI.

THE PERINEUM AND GENITALIA.

Sections:—1. The Male. 2. The Female	75-82
--------------------------------------	-------

CHAPTER VII.

THE BACK.

Spinal Cord and Nerves. Kidneys. Colon. Relations of Viscera, &c., to Vertebral Column	83-89
--	-------

CHAPTER VIII.

THE UPPER EXTREMITY.

	<i>Pages</i>
Sections:—1. Shoulder and Axilla. 2. Arm and Elbow. 3. Fore-	
arm and Wrist. 4. Hand	90-112

CHAPTER IX.

THE LOWER EXTREMITY.

Sections:—1. Buttock. 2. Thigh. 3. Knee. 4. Popliteal Space.	
5. Leg. 6. Ankle. 7. Foot	113-137
INDEX	139-143

LIST OF FIGURES.

FIG.	PAGE
1. Nervous Supply of Face and Scalp, &c.	8
2. Diagram of Cranium, showing Base Line of Brain, &c.	28
3. Diagram of Cranium, showing Lateral Sinus, &c.	<i>facing</i> 32
4. Diagram of Cranium, showing Fissures	<i>facing</i> 32
5. Relations of Chief Fissures to Scalp	35
6. Relations of Fissures and Convolutions to Scalp	39
7. Relations of Lungs to Wall of Thorax	57
8. Relations of Heart and Great Vessels to Wall of Thorax	61
9. Diagram of Anterior Abdominal Wall	67
10. Anterior Aspect of Abdomen	<i>facing</i> 70
11. Posterior Aspect of Abdomen	<i>facing</i> 86
12. Cutaneous Areas—Upper Extremity, Anterior Aspect	106
13. Cutaneous Areas—Upper Extremity, Posterior Aspect	107
14. Diagram of Side of Buttock	<i>facing</i> 114
15. Bony Prominences of Foot	132
16. Cutaneous Areas—Lower Extremity, Anterior Aspect	134
17. Cutaneous Areas—Lower Extremity, Posterior Aspect	135

A HANDBOOK
OF
SURFACE ANATOMY.

CHAPTER I.
THE FACE.

I. THE FACE.

Bony points.—The forehead presents on either side two elevations, the frontal eminences, varying considerably in the amount of their development in different individuals. Below and separated from these by a shallow groove is a supra-ciliary ridge on each side. These ridges which also vary greatly in size may, but need not necessarily, owe their prominence to large cavities in the substance of the bone—the frontal sinuses. This is a fact of surgical importance, since a fracture of this ridge apparently deep and serious may not open up the cranial cavity, but only that of the sinus.

Like other air cavities in connection with the cranial and facial bones, these sinuses are small or non-existent in the young child, developing gradually in the course of growth. Between the supra-ciliary ridges is a flat

smooth surface named the glabella, from which certain cranial measurements are made.

Below the supra-ciliary ridges are the margins of the orbit, or supra-orbital ridges as they are sometimes called.

Each ridge is bounded at either extremity by a strong prominent angle, the outer of which is by far the better marked; these angles are the external and internal angular processes. The former limits anteriorly the temporal fossa, the temporal muscle which it contains, and the temporal ridge with its attached fascia.

By pushing up the skin covering the eyebrows, the supra-orbital notch may generally be felt at about the junction of the middle and internal thirds of the supra-orbital ridge. This notch is sometimes replaced by a foramen, which may be situated somewhat deeply in the cavity of the orbit; its discovery is then more difficult, but it may be found by deep pressure. Through this notch or foramen pass the supra-orbital nerve and artery. The former, a branch of the ophthalmic division of the fifth nerve, is one of the common seats of facial neuralgia, for which complaint it may be necessary that it should be stretched or divided. Two other spots, at which branches of the fifth nerve emerge from bony canals are of similar importance. The infra-orbital branch of the superior maxillary division emerges from the infra-orbital canal beneath the prominent ridge which forms the lower margin of the orbit. The infra-orbital foramen whose aperture looks inwards, is covered

by muscles and cannot generally be felt from the surface. The same remark applies to the mental foramen situated in the inferior maxilla. Through this foramen which also looks inwards the mental branch of the inferior maxillary division of the fifth nerve escapes. The position of these two last mentioned foramina may be ascertained by drawing a line from the supra-orbital notch downwards and outwards so as to pass between both pairs of bicuspid teeth (*vide* fig. 1).

This line will cross the infra-orbital foramen about a quarter of an inch below the margin of the orbit. The position of the mental foramen varies according to the age of the individual examined. In the child at puberty it is placed rather nearer to the lower than to the upper border of the jaw. In the adult it lies nearly midway between the two borders and about a quarter of an inch below the fold of mucous membrane passing from the jaw to the cheek inside the mouth. In old edentulous persons, owing to the disappearance of the alveoli from atrophy, the foramen is placed close to the upper margin of the jaw.

In the middle line of the face below the glabella the points to be noticed are the nasal bones with the cartilages attached to them, the nasal spine of the superior maxilla which can be felt between the openings of the nostrils, and the ridge at the centre of the inferior maxilla which marks the symphysis menti.

Following outwards, on either side, the lower margin of the orbit, the zygoma is reached and may be traced in its entire extent. The space between it and the

cranial bones cannot be estimated in the undissected state, partly on account of the muscles which lie therein, and partly because of the firm and tense attachment of the temporal fascia above and of that of the parotid below. By passing the finger along the lower border of the zygoma, its tubercle may be distinguished immediately in front of the outer part of the glenoid fossa and the head of the inferior maxilla, the movements of which latter can be distinctly felt, and, in a moderately thin person, seen.

When the lower jaw is protruded its head will of course be brought nearer to the tubercle; when a dislocation occurs it is carried still further forward and passes over the tubercle into the zygomatic fossa. Behind the head of the lower jaw the posterior root of the zygoma (supra-mastoid crest) may be felt passing above the external auditory meatus. In the region below the orbit the canine eminence may be distinguished, though not so clearly as from within the mouth. On its inner side is the incisive fossa, on its outer, but at a higher level, the canine.

The greater portion of the inferior maxilla may be defined by manipulation, the symphysis, body, posterior portion of the ramus, head, and neck being all clearly distinguishable. The coronoid process almost to its apex may be felt by pressing the finger under the zygoma and protruding and depressing the jaw.

Skin, &c.—The skin over the forehead is fairly smooth and moveable, characteristics which it maintains as it covers the nose until it reaches the cartila-

ginous portion of that organ. Here its attachment becomes much firmer, a fact which explains the great pains caused by the small boils which form not unfrequently in the sebaceous follicles here very abundant. In the remainder of the face the attachments of the skin are loose save over the chin where its connections with the deeper parts are somewhat greater. It is this laxity of attachment which permits of the great mobility of the skin under the influence of the numerous muscles connected with it and engaged in the production of the various expressions of the countenance.

The depth of the hollow under the zygoma varies greatly in different individuals, presenting all varieties from the plump rounded contour of the young girl to the hollow cheek of the emaciated sufferer from some wasting disease. This difference is due to the presence or absence of a pad of fat, the "buccal pellet" which lies beneath the zygoma and in front of the masseter under both of which structures it sends prolongations. In the adult this portion of adipose tissue is one of the first to disappear in wasting diseases.

In the child the pads of fat in the cheeks are much larger than in the adult, a fact to which is partly owing the comparative squareness of the infantile face. According to Symington, besides the subcutaneous fat there exists a mass "in the form of one or more lobules surrounded by a clearly defined capsule, so that it can be very easily shelled out." These masses have been called "sucking-cushions" from the assistance which they are supposed to lend the infant in performing that function.

These cushions diminish in the process of development until they come to be represented by the pellets first alluded to. According to Ranke they are only slightly decreased in size in emaciated children in whom the subcutaneous fat is almost entirely absent.

The skin of the face may be furrowed by various lines, to some of which, when strongly marked, diagnostic importance has been attached. These lines individually and collectively differ greatly in the extent of their development in different persons. The most important of these furrows or wrinkles are:—1. The transverse rugæ of the forehead caused by the action of the occipito-frontal muscle. 2. The oculo-frontal rugæ passing vertically between the eyebrows to the root of the nose and due to the corrugator supercillii. 3. The linea oculo-zygomatica or line of Jadelot extending from the internal angle of the eye downwards and outwards to cross the face below the malar bone. This furrow is sometimes of a noticeably darker colour than the skin around it. 4. The naso-labial fold which commences between the side of the nose and the cheek, and passing obliquely downwards and outwards terminates near the commissure of the lips. It is almost always well-marked in old people. Lastly, so far as skin markings are concerned, the filtrum, a groove leading from the septum of the nose to the most prominent point of the upper lip, may be mentioned.

Blood-vessels.—The facial artery appears upon the face by crossing the inferior maxilla just in front of the masseter, where its pulsations may be felt and its flow

checked by compression against the bone. It may again be felt in its tortuous course near the commissure of the lips, where it gives off the coronary artery of either lip, which can be distinguished running beneath the mucous membrane. Two other branches may also be made out, the *lateralis nasi*, a short distance above and external to the ala of the nose, and the angular artery, whose pulsations may be felt at the side of the root of the nose. This vessel and the anterior branch of the superficial temporal are of service to the anæsthetist, since they often enable him to feel his patient's pulse without incommoding the operator.

The supra-orbital artery emerges from the notch or foramen with the nerve of the same name, and passes toward the vertex of the head. Nearer to the inner angle of the orbit, the frontal artery escapes; this vessel is included in the root of the flap in the Indian operation for the restoration of a partly destroyed nose, and affords it nutriment.

The transverse facial artery, a branch of the superficial temporal, cannot be felt save when exceptionally large, but its position may be found by remembering that it crosses the face immediately above Steno's duct, to which attention will shortly be drawn.

The pulsations of the trunk of the superficial temporal artery may be felt where the vessel crosses the zygoma immediately in front of the external auditory meatus. It divides into its anterior and posterior divisions two inches above the zygoma. Its anterior branch lies rather more than a finger's breadth behind

the external angular process, (*vide* fig. 1). This vessel is very liable to degeneration in old persons, in whom its tortuous trunk may be seen standing prominently out. Its pulsations also are very visible in some individuals, notably in those affected with incompetence

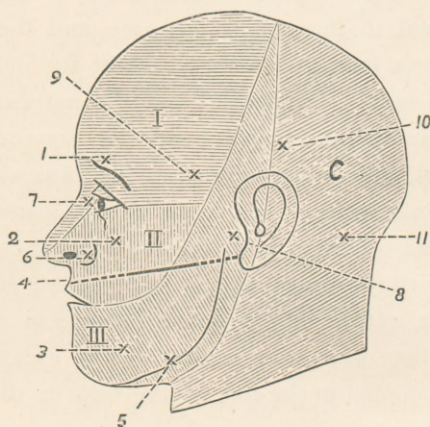


FIG. 1.—NERVOUS SUPPLY, ETC., OF FACE AND SCALP.

I. II. III. Regions supplied by the ophthalmic, superior and inferior maxillary divisions of the fifth nerve. C. Cervical nerves.

In this and succeeding similar figures it must, of course, be understood that the regions are not sharply marked off as would appear from the diagrammatic representation.

1, 2, 3. Points of exit of the supra- and infra-orbital and mental nerves. 4. Line of Steno's duct. 5. Point where facial artery crosses inferior maxilla. 6. Lateralis nasi. 7. Angular arteries. 8. Superficial temporal. 9. Anterior; and 10, posterior branches. 11. Occipital artery.

of the aortic valves. It is the vessel which was divided in the now seldom performed operation of arteriotomy. The posterior branch lies about two inches behind the anterior, under cover of the hair.

The veins of the face are not of much importance so far as their surface relations are concerned. The vein which runs with the angular artery, a vessel of great importance from its intra-cranial connections, through the ophthalmic vein, is not unfrequently to be seen, and may be very distinct, especially in children. Some individuals possess an exceptionally large frontal vein on one side or the other, which may be seen standing prominently out during laughter, &c. ; this vessel runs vertically down near the centre of the forehead to join the veins alluded to above. The facial vein pursues a straight course external to the artery from the inner angle of the orbit to the antero-inferior corner of the masseter.

Nerves.—The positions of the three branches of the fifth nerve have already been indicated in the description of their foramina of exit. The areas which they supply will be seen by a reference to the diagram ; in connection with which it should be noted that the supply of the upper part of the region belonging to the inferior maxillary division is gained from the auriculo-temporal nerve, which emerges from under cover of the parotid gland and crosses the zygoma near the superficial temporal artery. The facial, the motor nerve of the face, passes out of the substance of the parotid below the duct of the latter, some of its branches, notably the infra-orbital, running along the inferior border of that structure. The remainder ramify over the face in lines more or less divergent from that of the duct. The line of the nerve in the parotid may be indicated by drawing

a line forwards and slightly downwards from the anterior border of the mastoid process, where it meets the ear.

Other structures.—The parotid gland occupies a space fairly well defined on each side, save its anterior border, which lies for a variable extent upon the masseter, and from which projects its only superficial process, the *socia parotidis*, a portion which varies considerably in size. The body of the gland is limited above by the zygoma. Its inferior border may be marked out by a line drawn from the angle of the jaw to the mastoid process, whilst its posterior touches the external auditory meatus, the mastoid process and the sterno-mastoid muscle. From the anterior border emerges Steno's duct, which lies on the masseter below the *socia parotidis*. The position of the duct may be indicated by drawing a line from the point where the lobule joins the cartilage of the ear to a point midway between the nostrils and the red margin of the lips. About two inches of this line measured from the anterior border of the gland will correspond to the duct itself (*vide* fig. 1).

The student can readily ascertain its position in his own face by firmly clenching the jaws, when the masseter muscle will be tense and firmly contracted. By manipulating the central portion of the muscle with the points of the fingers the duct will easily be distinguished; it will be recognised by its whip-cord like feel and by the flow of saliva into the mouth which generally follows its stimulation.

Before passing to the cavities associated with the face, it may be well to call the student's attention to the very common asymmetry of the two sides in one or more particulars. Hasse, from a very careful examination of the face of the celebrated Venus of Milo, found that whilst the portion lying below the nose was comparatively symmetrical, the upper part presented various deviations. Thus, the nose deviates to the left, the left ear stands higher than the right, the left half of the skull is broader than the right, and the left eye is higher and nearer the middle line than the right. He was led from this observation to examine carefully various skulls and heads of living individuals, and, as a result, states that whilst symmetry of the lower half of the face is the rule, deviations such as those occurring in the statue, are commonly to be met with in the upper half.

II. THE EYE AND ITS APPENDAGES.

Orbit.—The bony margin of the orbit has been already alluded to, and it need therefore only here be mentioned that for protective purposes the outer and upper portions are stronger and more prominent than the inner and lower, and especially the former. By tolerably deep pressure in the internal and superior angle the little projection to which the pulley of the superior oblique muscle is attached, may be distinguished. The roof of the orbit as well as part of its

floor is excessively thin, the former in old persons being sometimes no thicker than writing paper ; it may therefore be easily fractured by a comparatively insignificant implement.

Eyelids, &c.—The skin covering the upper eyelid is thin and delicate, loosely attached to the subjacent tissues, fringed at its margin with two or more rows of hairs, the eye-lashes, and marked with several crescentic furrows, convex upwards. Incisions in this part should be made parallel to these lines. The lax attachment of the skin renders the accumulation of fluid in the subcutaneous areolar tissue an easy matter, the large effusion of blood in the common black eye being thus accounted for. This is also a position often selected for the first appearance of puffiness at the commencement of renal anasarca or dropsy.

By pinching up the eyelid in the subject the student will feel the so-called tarsal cartilage, to the inner end of which is attached the palpebral ligament or *tendo oculi* affixed at its other end to the margin of the orbit. To find this it is only necessary to close the eyelids and draw them outwards when the ligament will be made tense and appear under the skin as a transverse ridge. This ridge is an important surgical landmark, as it crosses the lachrymal sac at the junction of its upper and middle thirds, and thus serves as a guide to the surgeon in opening the latter for the evacuation of an abscess. The student should place his finger upon his own *tendo*, and open and close the eyelids several times, in order to note that each time the latter occurs

the ligament is made tense. A sucking action on the part of the subjacent sac is thus produced, by means of which the tears are drawn into its interior through the canaliculi.

Having studied this ligament the student may next practice eversion of the eyelid, one of those very minor operations on the deft performance of which so much of the comfort of a patient depends. Mr. Nettleship thus describes it:—"The patient looks down, a probe is laid along the lid above the upper edge of the "cartilage," the lashes, or edge of the lid, are then seized by a finger and thumb of the other hand, and turned up over the probe which is simultaneously pushed down. After a little practice the probe can be dispensed with, and the lid everted by the forefinger and thumb of one hand alone, one serving to fix and depress the lid, the other to turn it upwards."

When the lid is everted the roots of the hairs will be seen under the conjunctiva as well as the Meibomian follicles which appear like rows of yellow granules. It is in these or in connection with the hair follicles that the common styes are formed. The transition of epidermis into conjunctiva at the margin of the lid should be noticed, as also the fornix or cul-de-sac formed by the passage of the palpebral conjunctiva on to the eye. A similar but shallower depression exists in connection with the lower lid. The lid may now be restored to its normal position. At the inner angle or canthus will be noticed a recess bounded by two prominences, the papillæ lachrymales, on each of which opens the minute

aperture of the punctum lachrymale, the lower being a little larger and more external. Through these the tears pass by the canaliculi into the lachrymal sac, and thus into the inferior meatus of the nose by the nasal duct. The canaliculi may have to be slit open and a probe passed into this duct, which is a little more than half an inch in length, and is directed downwards and slightly backwards and outwards. Two other structures are to be noticed in connection with the above mentioned recess, the *plica semilunaris*, a fold of conjunctiva representing the *membrana nictitans* or third eyelid of birds, and the *caruncula lachrymalis*, a reddish eminence covered with a few fine hairs and containing in its interior specialised sweat glands and sebaceous glands.

Eyeball.—A description of the eyeball is outside the scope of this book, but the attention of the student may be drawn to the fact that neither the cornea nor the pupil are as a rule mathematically circular, the former having a tendency to be broader transversely. The pupil is situated very slightly to the inner side of the iris. The student should take the opportunity of examining a number of healthy eyes in order to form a standard in his own mind of the normal tension of the globe. With respect to this procedure, Nettleship states:—"The patient looks steadily down and gently closes the eyelids; the observer then makes light pressure on the globe through the upper lid, alternately with a finger of each hand as in trying for fluctuation but much more delicately. The finger-tips are placed

very near together, and as far back over the sclerotic as possible, not over the cornea. The pressure must be gentle, and be directed vertically *downwards, not backwards*. It is best for each observer to keep to one pair of fingers, not to use the index at one time and the middle finger at another. Patient and observer should always be in the same relative position, and it is best for both to stand and face one another. Always compare the tension of the two eyes. Be sure that the eye does not roll upwards during examination, for if this occur a wrong estimate of the tension may be formed. Some test both eyes at once with two fingers of each hand." The tension may be increased so that indentation of the globe is difficult or impossible, or on the other hand it may be decreased. For the scale employed in registering these changes, and the conditions in which they occur, the student is referred to special text-books on the eye.

III. THE NOSE.

There is not very much to be made out from an anterior inspection of this organ unaided by instruments, and the investigation of its posterior part may be more conveniently deferred to be considered with the cavity of the mouth. It should first be noticed that the apertures of the nostrils are placed at a lower level than the floor of the inferior meatus; in order therefore that this may be seen or that a speculum

may be introduced, it will be necessary to raise the tip of the nose, the head being thrown back. The mobility due to the cartilaginous basis of the anterior part of the nose, allows of the tip being raised and of the dilatation of either nostril.

The apertures of the nostrils are generally more or less compressed laterally in the adult, circular in children, and separated from one another by the thickened lower margin of the septum—the *columna nasi*. On looking into either, the vestibule or dilated anterior part is seen containing coarse hairs—the *vibrissæ*. The anterior extremity of the inferior turbinated bone can be seen and felt; in the undissected state only about one-twentieth of this consists of bone, the remainder consisting of the erectile tissue of *Voltolini* and others. The other turbinated bones cannot be seen without the aid of a speculum, which brings into view the middle one; but it is well to remember that they encroach largely upon the space in the posterior part of the organ. In inserting forceps, therefore, they should be so introduced that the blades may be opened upwards and downwards, not laterally. The septum in a portion of its extent may be seen, the part visible being chiefly cartilaginous; it is often deflected to one side or the other, or sometimes first to one side and then to the other, the so-called *sinous deflection*. In 76.9 per cent. of a large number of skulls examined by *Morell Mackenzie*, the bony septum was more or less asymmetrical. It is placed in the median line until the seventh year (*Zuckerkandl* and *Symington*),

and the subsequent deflection which is most often to the left is attributed by some writers to the habit of constantly blowing the nose with the same hand. It may be so great as to cause the introduction of instruments to be difficult or even impossible.

In connection with the examination of the nose from the front, the student should practise the operation of introducing the Eustachian catheter. Should the actual instrument not be at hand, one may be improvised from a probe or even a piece of wire of suitable size with a rounded end, either being bent at an angle of 60° a short distance from its extremity. The operator will be much assisted by practising at first upon a head which has been divided by a mesial antero-posterior section, as he will then be able to watch the point of his instrument as he endeavours to introduce it into the opening of the Eustachian tube. Should such a section be unattainable for this purpose, the position of parts should at least be examined in a specimen before the operation is attempted. The directions for performing the operation are thus given by Pritchard:—"The curved end is introduced into one nostril, keeping the beak close along the angle formed by the septum and the floor. By this means the surgeon will avoid getting into the middle meatus, and so finding himself in difficulty further on. When the catheter has passed the posterior nares, it will soon encounter the back of the pharynx, and this will be easily recognised by its tension, for it has been very aptly described as feeling like the outstretched palm

of the hand. The catheter should then be withdrawn about half an inch, and the point turned almost directly outwards, after which, on the catheter being again slightly pushed in, the point will enter the Eustachian tube."

When the catheter is engaged in the Eustachian aperture its beak will be found to point towards the outer angle of the orbit on the same side.

IV. THE EAR.

The external ear or pinna is formed throughout the greater part of its extent of a cartilaginous substratum, to which, as in the case of the cartilaginous part of the nose, the skin is very closely adherent. The dependent portion, the lobule, alone contains no cartilage, and consists mainly of fat, the amount of its connection with the side of the neck being variable. The plate of cartilage occupying the remainder of the pinna is folded so as to present several elevations and depressions, to which designations have been assigned. Surrounding the entrance to the meatus is the deepest hollow, the concha, which is prolonged downwards and forwards into a notch, bounded on either side by a prominence. The anterior of these, which bears hairs, is called the tragus, the posterior the anti-tragus. Superior and internal to the former the helix commences and passes round the outer border of the ear as a well-marked fold, which terminates at the posterior part of the lobule.

It is sometimes possessed of a pointed process placed on its inner border, and at its upper and posterior part, which was first noticed by Woolner, the sculptor, and to which attention was directed by Darwin in his *Expression of the Emotions*.

Commencing at the anti-tragus is another elevation, the anti-helix, which passing round the concha, bifurcates to enclose a triangular depression—the fossa triangularis or fossa of the anti-helix. Between the two elevations is a shallow groove—the fossa scaphoidea or fossa of the helix. The outer aperture of the external auditory meatus is largest from above downwards; it possesses a number of hairs, and under the skin are placed the ceruminous or wax-producing glands.

The canal of the meatus passes forwards in its entire course. Its outer portion also passes upwards and its inner downwards. In order to obtain a view of the meatus and membrana tympani, either with or without the aid of a speculum, it is necessary to straighten the canal as far as possible. This is done by taking hold of the pinna above and pulling it upwards and slightly backwards and outwards.

Bony points in connection with the ear.—Behind the ear is the mastoid process, which commences to become prominent about the second year. Its interior is occupied by air spaces, divided into two groups, viz.:—(a). The vertical which commence to develop about the time of puberty, these have a close relationship internally to the sigmoid sinus, and cerebellum. (b). The mastoid antrum, which is present at

birth, is horizontal in direction and communicates with the tympanum on the one hand and with some of the mastoid cells on the other. It is immediately subjacent to the temporo-sphenoidal lobe, a thin bony plate, which forms its roof, intervening between the two. The position of the superior limit of the antrum is indicated on the surface of the skull by the supra-mastoid crest. Its inferior limit is a little below the upper border of the external auditory meatus. The antrum may be reached from the surface by perforating the skull at the base of Macewen's supra-meatal triangle (*see* fig. 3). This is bounded above by the supra-mastoid crest, below by the posterior superior fourth of the external auditory meatus and behind by a base line joining the two dropped from the supra-mastoid crest on a level with the posterior border of the external auditory meatus.

V. THE MOUTH.

The cavity of the mouth may be divided into two parts. One between the lips and cheeks and the teeth—the vestibulum oris, and a second behind the teeth—the cavum oris. Still further back behind the pillars of the fauces is the upper part of the pharynx. In the vestibule there may be felt with the tip of the tongue in one's own mouth or with the fingers in another person's, a number of small granules under the mucous membrane. These are mucous glands, which may, in certain conditions, become chronically hypertrophied or

otherwise diseased. On the inner side of the cheek the aperture of the duct of Steno should be sought. This opening, which is much smaller than the calibre of the canal which it terminates, is placed opposite the second upper molar tooth.

It may be found in the living subject by everting the cheek and wiping the inner surface dry, when in a short time the appearance of a drop of saliva will indicate the opening. If the upper lip be everted a fold of mucous membrane—the *frænum labii superioris*, will be seen passing from it to the gums. A finger should be passed up between the cheek and the teeth and the coronoid process felt from within the mouth. The spot above the second bicuspid tooth, where the antrum is sometimes tapped, should also be noticed. Without pausing to describe the teeth, an account of which must be sought in the ordinary textbooks, we may pass to the *cavum oris* situated behind them. The tongue with its filiform and fungiform *papillæ* is the first object for inspection; a good idea of the distribution of the last mentioned *papillæ* will be gained by looking at them in a patient suffering from scarlet fever. At the posterior part will be seen the large *circumvallate papillæ*, seven to twelve in number, arranged in the form of a V, with the apex directed backwards, and the *foramen cæcum* situated just behind. If the tongue be pulled well out and to one side the student will see in front of the anterior pillar of the fauces on the border of the tongue, an area with a few, generally five, longitudinal folds—the *papilla foliata*.

A finger should now be introduced gradually backwards in the middle line, and the various structures met with investigated. Immediately behind the centre of the root of the tongue, a ridge of mucous membrane will be felt passing to the epiglottis. This is the glosso-epiglottic fold or frænum epiglottidis, on each side of which there is a shallow depression in which a foreign body may lodge. Behind this fold is the epiglottis itself, which may be distinctly felt and even seen in some individuals if the tongue is pulled well out in the middle line. Passing over the epiglottis the finger reaches the ary-epiglottic folds of mucous membrane with the entrance to the larynx between. On each side will be felt the hyoid space, another favourite spot for the lodgment of foreign bodies, and the great cornu of the hyoid bone.

In the middle line the cricoid, as far down as its lower border, can be made out, together with the commencement of the œsophagus. As this spot is one of the two narrowest parts of the gullet, insufficiently masticated lumps of meat and other bodies are liable to lodge in it. The posterior wall of the pharynx overlying the vertebral column may be investigated in its entire extent. In the course of these observations the student should consider their bearing upon the passing of an œsophageal tube or bougie, and in either case the end of the instrument should be kept well against the posterior wall in order to avoid any danger of its entering the larynx by mistake.

The tip of the tongue should now be turned upwards,

when the large ranine veins will be distinctly seen on the under surface of the organ. Two fringes of fimbriated mucous membrane which indicate the position of the more deeply seated ranine arteries, will also be noticed. Passing from the tongue to the floor of the mouth is a fold of mucous membrane, the *frænum linguæ*, sometimes abnormally short, and then causing the condition known as "tongue-tie." On each side of this a duct of Wharton opens on a papilla in the floor of the mouth. If one forefinger be pressed upwards and inwards from without, beneath the angle of the jaw, and the other be placed in a corresponding position under the tongue, the sub-maxillary gland will be felt between the two under the floor of the mouth. A long ridge of mucous membrane on either side of the floor contains the sublingual gland, and indicates to a certain extent the direction of Wharton's duct and the lingual nerve. Upon this ridge open, by a number of apertures, such of the ducts of the last mentioned gland as do not join the Whartonian canal. Finally, so far as this part is concerned, the attachment of the *genio-hyo-glossi* muscles may be felt under the floor of the mouth, immediately behind the symphysis of the lower jaw.

The tongue being restored to its place, the student should examine the hard palate, the shape of the arch of which varies in different subjects. The mucous membrane is very firmly adherent to the bones which it covers; under it on either side at the posterior part may be felt the pulsations of the posterior palatine

artery. The canal through which this vessel passes to reach the palate is placed just internal to the last molar tooth, and may be plugged for the arrest of hæmorrhage. Carry the finger a little further back and the point of the hamular process of the pterygoid plate, as well as that structure itself, and the pterygoid fossa may all be felt, together with the back of the antrum and the external pterygoid plate behind the last molar. The pterygo-maxillary ligament may be seen and felt when the mouth is widely opened, extending from the internal pterygoid plate to the lower jaw behind the last molar, and separating the buccinator from the superior constrictor. This ligament helps us to find the position of the gustatory nerve, which lies a little below it, on the bone below the last molar tooth. It is here that the nerve is sometimes divided for the relief of painful cancer of the tongue. The guides for the division of two other nerves in the cavity of the mouth may also here be mentioned. The inferior dental nerve is reached by an incision "from the last upper molar to the last lower molar, just to the inner side of the anterior border of the coronoid process. The cut passes through the mucous membrane down to the tendon of the temporal muscle. The finger is introduced into the incision, and passed between the ramus of the jaw and the internal pterygoid muscle, until the bony point is felt that marks the orifice of the dental canal. The nerve is here picked up with a hook, isolated and divided." (Treves).

The buccal nerve which is sometimes divided for

neuralgia is thus reached; "the surgeon places the finger nail upon the outer lip of the anterior border of the ascending ramus of the lower jaw at its centre, and divides in front of this border the mucous membrane and the fibres of the buccinator vertically. He then seeks for the nerve, separating the tissues with a director, and divides it." (Stimson).

The student should now examine the structures, separating the cavity of the mouth from the pharynx, the soft palate with its central dependence, the uvula, the folds of mucous membrane covering the palato-glossus and palato-pharyngeus, and forming the anterior and posterior pillars of the fauces, and the tonsil lying between them. This latter should not project under normal circumstances into the isthmus faucium, and a consideration of its inter-muscular position will explain the great pain caused in swallowing when it is enlarged, and especially when ulcerated also, as in "hospital sore-throat."

The head being thrown well back the posterior nares should be thoroughly explored. By hooking the finger round the soft palate the posterior part of the septum and of the middle and inferior turbinated bones may be felt, also the vault of the pharynx, the openings of the Eustachian tubes, the basilar process of the occipital, and the upper four cervical vertebræ. Of these the first is opposite the lower margin of the posterior nares, and the second, the soft palate. If the finger be pushed onwards into the inferior meatus, and the little finger of the other hand be introduced from the front

into the same, the two may be made to meet without difficulty unless the passage is abnormally constricted. The apertures of the posterior nares measure a little less than an inch vertically, and half an inch transversely. An investigation of this part will be useful in assisting the student to understand the operation of plugging the posterior nares.

CHAPTER II.

THE SCALP.

I. THE SCALP.

FOR purposes of convenience the scalp is here limited to the part of the head normally clad with hair. The skin and subjacent tissues are here closely united to one another so as to form a dense and thick covering to the cranium. Free movement is permitted, however, between the scalp and the bone beneath it, by the layer of loose connective tissue which lies between the aponeurosis of the occipito-frontalis muscle and the pericranium. The supra-orbital, frontal, and two branches of the superficial temporal artery have already been alluded to. Behind the ear and over the mastoid process, the pulsations of the posterior auricular artery may be felt; the occipital artery will be found slightly internal to the centre of a line drawn from the apex of the mastoid process to the external occipital protuberance. A lymphatic gland, the sub-occipital, which receives the lymphatics of the occipital and posterior parietal region, lies a short distance behind the mastoid process, and may be felt when enlarged, a condition which occurs in syphilis and in skin diseases of this region of the scalp.

II. RELATION TO BONY VAULT.

Comparatively few bony points are to be felt through the scalp, yet by means of a few measurements and rules, the positions of the various sutures may be

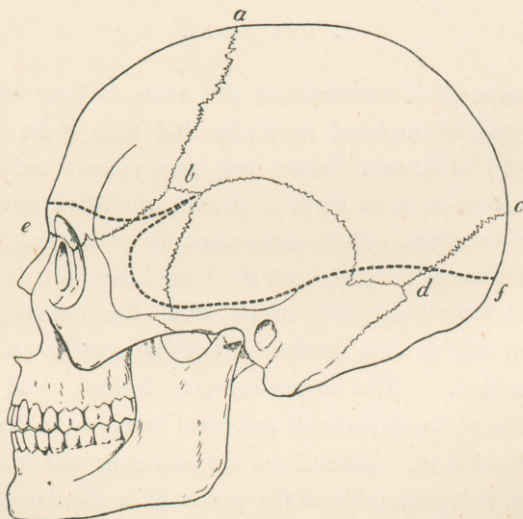


FIG. 2.—Cranium, showing Base-line of Brain (indicated by dotted line), &c. *a.* Bregma. *b.* Pterion. *c.* Lambda. *d.* Asterion. *e.* Nasion. *f.* Inion.

mapped out with considerable accuracy. The bony points which may be felt are the external occipital protuberance at the back of the head, with a portion of the superior curved line passing from it; above the former the apex of the occipital bone may often be distinguished. The mastoid process can be distinctly

felt behind the ear, and is a valuable landmark; it is much smaller in the child than in the adult, from the non-development of the air-cells in its interior.

The following points are valuable in mapping out the sutures:—

1. The *bregma*, or junction of the coronal, sagittal, and in the young subject, frontal sutures; this is placed at the centre of a line drawn across the vertex from one external auditory meatus to the other, the head being in the usual erect position.

2. The *pterion*, or junction of the frontal, temporal, parietal and sphenoid bones in the anterior part of the temporal fossa. This is generally shaped like an H, of which the anterior limb is formed by the fronto-parietal and sphenoid sutures, the posterior by the temporo-parietal and sphenoid, and the cross-bar by the parieto-sphenoid. The relations of the four bones to one another vary considerably, but we may take the cross-bar as being about half an inch in length in the majority of cases. The pterion is situated a little above a line drawn backwards from the external angular process, and from $1\frac{1}{4}$ to $1\frac{1}{2}$ inches posterior to that point.

3. The *lambda* or junction of the sagittal and lambdoidal sutures is situated about $2\frac{3}{4}$ inches above the external occipital prominence, and may often be felt through the scalp.

4. The *asterion* is the point of junction of the lambdoid and parieto-mastoid sutures; it is placed about $\frac{3}{4}$ of an inch behind and $\frac{1}{2}$ an inch above the superior part of the posterior border of the mastoid process.

5. The *nasion*, is the point of junction of the inter-nasal and naso-frontal sutures.

6. The *inion* is the external occipital protuberance.

With the aid of these points we may indicate on the scalp the position of the sutures of the vault as follows:—

Sagittal extends from the bregma to the lambda.

Coronal extends from the bregma downwards and forwards, to the anterior end of the pterion.

Lambdoidal extends from the lambda, past the asterion, and forwards internal to the mastoid process.

Squamous and *parieto-mastoid* may be indicated by drawing a curved line from the posterior part of the pterion to the asterion, the highest part of which is about two inches above the zygoma. The posterior inch is parieto-mastoid.

III. RELATION TO MEMBRANES OF BRAIN AND THEIR VESSELS.

The falx cerebri extends from the root of the nose along the frontal and coronal sutures to the external occipital protuberance, and the falx cerebelli is continued down in the middle line to the posterior margin of the foramen magnum. The tentorium so far as it is related to the cranial wall, will be indicated by a line from the external occipital protuberance to the asterion.

The middle meningeal artery reaches the side of the cranium near the lower end of the squamo-sphenoid suture, which it follows to the pterion by the posterior end of which it runs. From this point it runs nearly parallel to the coronal suture and about one inch posterior to it. A large branch is given off backwards which crosses the squama transversely at about its centre. This may originate near the foramen spinosum.

Erichsen gives the following rule for finding this artery; draw a straight line backwards from the external angular process, take a point at any distance between one and two and half inches on this line and draw a vertical line through it to the zygoma, measure a corresponding distance up this line and the point so found will be over the artery. If this distance be under one and a half inches, the artery will be found in a canal in the bone, beyond this it is usually in a groove.

The torcular Herophili corresponds nearly to the external occipital protuberance being usually slightly to its right; a line therefore from this point to the root of the nose will indicate the position of the superior longitudinal sinus and one from the former point downwards, that of the occipital.

The limit of the upper border of the lateral sinus, as far as the posterior part of the squamous suture is indicated by the base line of the brain in that region (p. 34). From this point it is directed downwards $\frac{1}{2}$ " behind the external auditory meatus towards the tip of the mastoid process, as far as a point $\frac{1}{4}$ " below the

lower level of the meatus, where it turns inwards to the base of the skull. As a guide to the position of the sinus in operations, Birmingham suggests the use of the following lines. One drawn convex upwards from a point $\frac{1}{3}$ " above the occipital protuberance to a point $1\frac{1}{2}$ " behind and $1\frac{1}{4}$ " above the centre of the meatus, and the second from $\frac{1}{2}$ " below the occipital protuberance to Reid's base-line $1\frac{1}{2}$ " behind the meatus. Between these two lines the sinus will be found; above or below the space included between them trephining may be practised with safety.

IV. FONTANELLES.

The student should examine the shape and position of the fontanelles in the head of a young infant. These are spots where the bony vault is incomplete, and where membrane alone underlies the scalp. The two most important, from the assistance they lend to the obstetrician, in diagnosing the position of the descending head of the child in parturition, as well as from their diagnostic value during infancy, are the anterior and posterior. The former is diamond-shaped, occupies the position of the bregma, and is included between the two frontal and two parietal bones. The latter is triangular with its apex directed forwards, it occupies the position of the lambda and is included between the parietal and occipital bones.

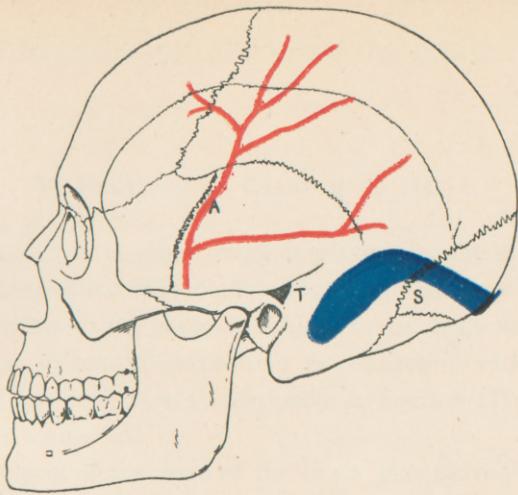


FIG. 3.—Diagram of Cranium, showing positions of middle meningeal artery (A), Lateral Sinus (S), and Supra-meatal Triangle (T). (Modified from Birmingham and v. Bardeleben.)

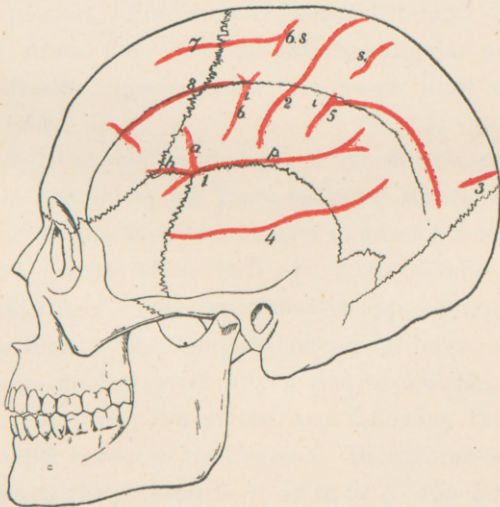


FIG. 4.—Diagram of Cranium, showing positions of fissures. 1. Sylvius *h.* horizontal, *a.* ascending, *p.* posterior. 2. Rolando. 3. Parieto-occipital, 4. Parallel. 5. Intraparietal joining inferior post-central (*i.*) Sup. post-central is above (*s.*) 6. Precentral, (*i.*) inferior and (*s.*) superior segments. 7. Superior Frontal. 8. Inferior Frontal. (Modified from Quain and v. Bardeleben.)

V. RELATION OF CRANIUM TO BRAIN.

Although it is much more important for the student to be acquainted with the relations of the different parts of the brain to the scalp, a subject to be dealt with in the next section, their position in connection with certain of the bony points mentioned in Section III. may here be mentioned.

The level of the base of the brain may be indicated in the following manner with sufficient accuracy:—

1. Draw a slightly sinuous line upwards and outwards from just above the nasion to the posterior line of the pterion. This line crosses the temporal ridge about $\frac{1}{4}$ " above the root of the external angular process, and indicates approximately the lower limit of the frontal lobe.

2. From the last point draw a line downwards and forwards parallel to the ptero-temporal suture, and at a maximum distance of a quarter of an inch from it, to a point a quarter of an inch above the middle of the pterygoid ridge. This line indicates approximately the anterior limit of the temporo-sphenoidal lobe.

3. From the last point draw a line backwards, crossing the ptero-temporal suture, and following the level of the upper border of the zygoma. Behind the zygoma it curves slightly upwards, so as to lie $\frac{1}{4}$ " above the external auditory meatus. Thence it passes backwards, slightly above the first $\frac{1}{2}$ " of the parieto-mastoid suture

and terminates $\frac{1}{4}$ " above the asterion. This line indicates approximately the lower border of the temporo-sphenoidal lobe.

4. From the last point draw a sinuous line to a point $\frac{1}{4}$ " above the superior curved line about its middle. Thence it passes backwards and slightly upwards to $\frac{1}{4}$ " above the external occipital protuberance. This line approximately indicates the lower border of the occipital lobe.

The *fissure of Sylvius* divides at the posterior end of the cross-bar of the pterion, its anterior ascending limb runs upwards and forwards to meet the coronal suture, its anterior horizontal corresponds to the cross-bar, and its posterior lies along the anterior part of the squamous suture, and where that turns down to pass to the asterion, continues backwards and upwards across the parietal bone. The *fissure of Rolando* commences a little less than two inches posterior to the bregma and a short distance from the middle line, and passes down towards the squamous suture, gradually approaching the coronal so as to be about $\frac{3}{4}$ " nearer to it below than above. The *external parieto-occipital fissure* lies just in front of or frequently coincides with the lambda. It should be mentioned that Symington has shown that in the child the fissure of Sylvius lies $\frac{1}{2}$ " or more above the squamous suture, and that the fissure of Rolando lies further forward than in the adult.

VI. RELATION OF SCALP TO BRAIN.

The more important fissures may be marked out on the scalp by the following rules.

The *longitudinal fissure* is indicated by a line from the nasion to the inion.

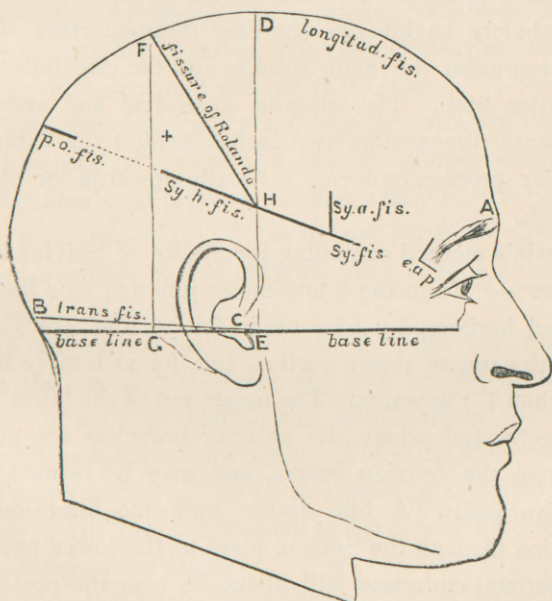


FIG. 5.—Showing Relation of Chief Fissures to Scalp. (Reid).

A. Glabella. B. External occipital protuberance. *e. a. p.* External angular process of frontal. B. C. Transverse fissure. A. B. Horizontal fissure. *Sy. fis.* Sylvian fissure. *Sy. h. fis.* Posterior limb of Sylvian fissure. *Sy. a. fis.* Anterior limb of Sylvian fissure. DE, FG. Perpendiculars alluded to in text. F. H. Fissure of Rolando. *p. o. fis.* Parieto-occipital fissure. + Most prominent part of parietal eminence.

The *transverse fissure* is indicated by a line drawn from $\frac{1}{4}$ " above the external auditory meatus to $\frac{1}{4}$ " above theinion (see p. 30).

The *fissure of Sylvius* (Reid) is found by taking a point an inch and a quarter posterior to the external angular process of the frontal, and drawing a line from thence to a point three-quarters of an inch below the most prominent part of the parietal eminence. Measured from before backwards, the first three-quarters of an inch represent the main fissure, and the remainder the posterior limb. The anterior ascending and anterior horizontal limbs start two inches behind the external angular process and run vertically upwards for about an inch.

Quain's method of finding the fissure of Sylvius is as follows:—"From the fronto-malar junction let a line be carried horizontally backwards for 35 mm. ($1\frac{1}{4}$ "') and from the end of this a vertical line for 12 mm. (a little less than $\frac{1}{2}$ "') upwards. The upper end of the latter line marks the spot where the anterior branches are given off from the Sylvian fissure, and may be termed the Sylvian point. A line drawn from the fronto-malar junction through the Sylvian point to the lower part of the parietal eminence will about lie over the posterior limb of the Sylvian fissure and may be called the Sylvian line. The anterior ascending and horizontal branches of the fissure may be marked by lines 2 cm. ($\frac{3}{4}$ "'), starting from the Sylvian point, the one directed upwards and forwards at right angles with the Sylvian line and the other horizontally forwards."

The *external parieto-occipital fissure* is found by drawing a line outwards for $\frac{3}{4}$ " from the lambda at right angles to the line indicating the longitudinal fissure.

To find the *fissure of Rolando* by Reid's method, it will be necessary to erect a kind of scaffold formed of three lines. The first or base runs through the lowest part of the infra-orbital margin and the middle of the external auditory meatus. Upon this line are erected two perpendiculars, one starting from the hollow in front of the external auditory meatus, the other from the posterior border of the mastoid process at its root.

These two perpendiculars, together with the line for the longitudinal fissure and that for the posterior limb of the fissure of Sylvius, enclose a quadrilateral space, and if a diagonal line be drawn from the posterior superior corner to the anterior inferior it will be over the fissure of Rolando.

An alternative method is to measure the distance from the nasion to the inion and take the centre of this line. A point $\frac{1}{2}$ " behind this will indicate the upper end of the fissure of Rolando. A line draw downwards and forwards for $3\frac{3}{8}$ " from this point, making an angle of 70° with the longitudinal fissure, will indicate the remainder of the fissure.

The student having thus mapped out on the scalp the great fissures of the brain and having fully mastered the method, he should next proceed to put in the smaller details as directed by Prof. Reid.

The *frontal lobe* is bounded above by the line for the longitudinal fissure, below by the line for the trunk

and horizontal limb of the Sylvian fissure, behind by the line for the fissure of Rolando, and in front by a line just above and parallel with the supra-orbital margin. The precentral sulci are situated $\frac{3}{4}$ " in front of the fissure of Rolando with which they are parallel. A line drawn from the supra-orbital notch backwards to within three-quarters of an inch of the line for the fissure of Rolando, and parallel with the line for the longitudinal fissure, will indicate the first frontal fissure. The frontal part of the temporal ridge will indicate the second frontal fissure. The first, second, and third frontal convolutions, will thus be mapped out. The ascending frontal convolution will occupy a space about three-quarters of an inch broad, parallel with, and in front of, the line for the fissure of Rolando.

The *parietal lobe* will be marked out by the line for the longitudinal fissure superiorly, and in front and behind by the lines for the fissure of Rolando and the parieto-occipital fissure respectively. Below, the line for the horizontal limb of the fissure of Sylvius will separate it from the temporo-sphenoidal lobe. The interval between the posterior end of the Sylvian line and the outer end of the parieto-occipital line is occupied by the junction of the postero-parietal lobule (*p. p. l.*, fig. 6) with the first annectant convolution, and the angular gyrus (*ang. g.*, fig. 6) with the second annectant convolution, the arrangement of these convolutions with regard to one another being very variable, the angular gyrus usually projecting somewhat more posteriorly than the postero-parietal lobule. We can,

therefore, only indicate the separation of this part of the parietal lobe from the neighbouring temporo-sphenoidal and occipital lobes by drawing a line (a, fig. 6) slightly convex downwards from the pos-

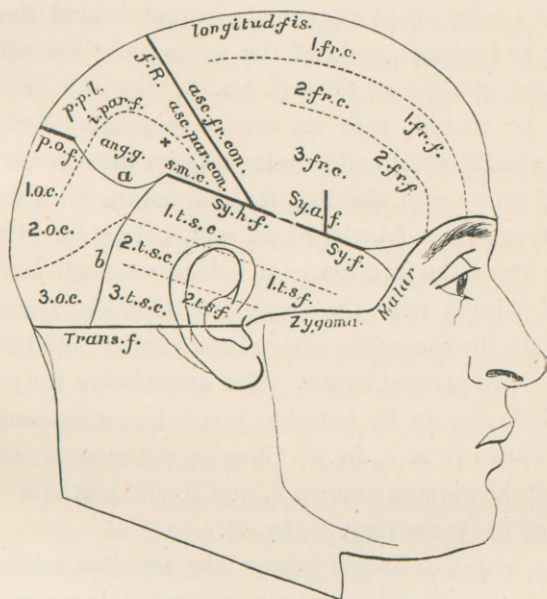


FIG. 6. —Showing Relation of Fissures and Convolutions of Brain to Scalp.
(Reid).

+ Most prominent part of parietal eminence. *a* Convex line bounding parietal lobe below. *b* Convex line bounding temporo-sphenoidal lobe behind. *1 fr. c.* First frontal convolution. *1 fr. f.* First frontal fissure. *f. R.* Fissure of Rolando. *Sy. f.* Sylvian fissure. *Sy. h. f.* Horizontal limb of Sylvian fissure. *Sy. a. f.* Ascending limb of Sylvian fissure. *p. o. f.* Parieto-occipital fissure. *i. par. f.* Intra-parietal fissure. *ang. g.* Angular gyrus. *s. m. c.* Supra-marginal convolution. *1 t. s. c.* First temporo-sphenoidal convolution. *1 t. s. f.* First temporo-sphenoidal fissure. *1 o. c.* First occipital convolution. *p. p. l.* Postero-parietal lobule.

terior end of the Sylvian line to the outer end of the parieto-occipital line. An irregularly triangular space will thus be marked out to indicate the parietal lobe. If in this space we draw a line from a point half an inch outside the outer extremity of the parieto-occipital line to a point about an inch above and behind the anterior and inferior angle of the space, this line will lie over the *intra-parietal fissure* (*i. par. f.*, fig. 6). The line must be curved, with its convexity directed forwards and inwards, and parallel in its anterior third or so (*post-central sulcus*) with the line for the fissure of Rolando, and about three-fourths of an inch behind it. In the space above the intra-parietal sulcus we shall have, in front, parallel with the whole length of the fissure of Rolando, the ascending parietal convolution, and behind, the postero-parietal lobule. The space below the sulcus will indicate, in its anterior part, the supra-marginal convolution (*s. m. c.*, fig. 6) filling up the most prominent part of the parietal eminence, and in its posterior part, the angular gyrus (*ang. g.*, fig. 6).

The *temporo-sphenoidal lobe* is, like the last, somewhat difficult to indicate posteriorly, because it becomes continuous there with the parietal and occipital lobes without any distinct line of demarcation. Its outline will lie in the lower part of the temporal region, extending a little beyond the temporal ridge behind. It will be bounded above by the line of the main trunk and horizontal limb of the fissure of Sylvius, below by the upper border of the zygoma and a line carried back from the posterior end of that to a point midway between the

external occipital protuberance, and the posterior border of the mastoid process at its root. The anterior border or apex of the lobe will extend as far forwards as the posterior superior border of the malar bone. Behind, the lobe will be bounded by a slightly convex line (*b.*, fig. 6) with the convexity directed backwards, extending from the posterior end of the Sylvian line to the posterior end of the line indicating the lower boundary of the lobe.

A line running about an inch below and parallel with the line for the main trunk and horizontal ramus of the fissure of Sylvius, will indicate the first temporo-sphenoidal fissure (*1 t. s. f.*, fig. 6) and another line about three-quarters of an inch below and parallel with the last, will indicate the second temporo-sphenoidal fissure (*2 t. s. f.*, fig. 6). Thus, the first, second, and third temporo-sphenoidal convolutions will be mapped out (*1 t. s. c.*, *2 t. s. c.*, *3 t. s. c.*, fig. 6).

The *occipital lobe* will occupy the remaining surface of the scalp. It will be bounded above by the parietal lobe, below by the superior curved line in its inner half, that is, the part of the line unoccupied by the lower limit of the temporo-sphenoidal lobe. Internally, the line of the longitudinal fissure, and externally, the convex line for the posterior border of the temporo-sphenoidal lobe, will bound it. The area of the lobe being marked out, the first, second, and third occipital convolutions, can be readily filled in (*1 o. c.*, *2 o. c.*, *3 o. c.*, fig. 6).

CHAPTER III.

THE NECK.

IN this section only the anterior and lateral portions of the neck will be dealt with, the posterior being included with the back.

The skin of the neck is loose and mobile, and is underlaid by a thin layer of muscle passing from the clavicle to cross the lower jaw. This is the platysma myoides, and its fibres run from above downwards and backwards. A great number of structures, many of which are of the highest surgical importance, lie in the region now under consideration, they will be dealt with in the following order:—those in the middle line, between that line and the anterior border of the sterno-mastoid, and those behind that muscle.

I. THE MIDDLE LINE OF THE NECK.

The first structure which can be felt beneath the lower jaw is the hyoid bone, the body and great cornua of which can be distinguished. The student in seeking for this should not stretch the tissues of the neck, but should allow the chin to fall and push his finger and thumb up underneath it, when the object of his search will readily be discovered. In the normal position this

bone corresponds to the fourth cervical vertebra. Beneath it is a space which overlies the anterior thyroid membrane, behind which lies the apex of the epiglottis. The next structure met with is the thyroid cartilage, or Adam's apple, the largest and most prominent hard body in the neck, of greater size and prominence proportionally in men than in women. The upper border with its notch and superior cornua, the angle, lower border and inferior cornua by the side of the cricoid, can all be distinguished. The middle of the angle corresponds to the attachment of the vocal cords. Beneath the thyroid cartilage lies the cricothyroid membrane, which is divided in laryngotomy, and on which lie the crico-thyroid branches of the superior thyroid arteries. The student will note that these are the first vessels met with in the middle line, and they are of small size; incisions for the relief of cellulitis of the neck may therefore be made in this line without fear of wounding any vessel of importance.

Below this membrane lies the cricoid cartilage, a surgical landmark of much importance, which corresponds with the disc between the fifth and sixth cervical vertebræ. At the lower border of this cartilage the pharynx ends, and the œsophagus commences, this point being, as has already been mentioned, one of the narrowest parts of that canal. Below the cricoid we reach the trachea, about eight of the rings of which lie above the sternum in the ordinary position, none of which can, however, be felt as separate structures. According to Holden only $1\frac{1}{2}$ inches of trachea lie above

the sternum, though an additional $\frac{3}{4}$ inch may be gained by stretching the neck, but Tillaux gives somewhat different figures. He states that in a child from three to five years there is $1\frac{1}{2}$ inches, from six to seven 2, from eight to ten $2\frac{1}{4}$, and in the normal adult $2\frac{3}{4}$, the head being in the ordinary position. In the operation of tracheotomy this tube is opened, in that of laryngo-tracheotomy its upper rings and the cricoid cartilage being divided. On account of these operations, and especially the former, which is by far the commoner, it is very important to know what structures lie in front of the trachea before it enters the thorax. The first in order from above downwards is a transverse communicating branch between the two superior thyroid veins, which is generally present, and lies over the first ring of the trachea. Next in order is the isthmus of the thyroid, which varies in size, but usually overlies the second, third, and fourth rings. According to Treves the importance of avoiding the wounding of this structure is overrated, and, as he points out, it has been shown that an injection will not cross the isthmus from one lobe of the thyroid to the other. Over the isthmus is a plexus of veins, and below it they unite into one or generally more inferior thyroid veins. In this position also is the thyroidea ima artery when such a vessel exists. At the root of the neck the trachea recedes considerably from the surface, a depth of an inch and a half intervening between it and the skin at the episternal notch. Just above this last is a transverse trunk uniting the two anterior jugular veins, which may themselves

lie in front of the trachea, though as a general rule they are some little distance from the middle line. In children, up to the age of two, the thymus gland covers the trachea for a variable distance above the sternum, and the innominate artery may also be in that high position, a position which it may retain, though rarely, in the adult also. Behind the trachea lies the œsophagus, which in this part of the neck lies slightly to the left side. In feeling for a hard foreign body the attempt should be made on the left side by the trachea, and here also the operation of œsophagotomy is performed.

II. PARTS NEAR ANTERIOR BORDER OF STERNO-MASTOID.

The student should first note the exact line of the anterior border of the sterno-mastoid muscle, as he is apt to obtain an incorrect idea of it, from an examination made in the dissected condition. When in an undisturbed condition it does not run a straight course from the sternum to the mastoid process, as it appears to do when its fascial connections have been cut. On the contrary its anterior border passes practically to the angle of the jaw, and is held there by its relations with the cervical fascia. It follows from this that the common carotid artery and its divisions, the external and internal carotids are completely covered in by the anterior border of the muscle in the undissected state. The muscle below arises by two heads, sternal and

clavicular, between which a triangular space of variable size is included. At its base lies the line of the sternoclavicular joint. If a needle be pushed in here on the right side, it will pass immediately above the innominate artery at its bifurcation, and will have below it and to the right the subclavian artery, external to it the internal jugular vein, and internal to it the common carotid artery. Sometimes in children, and even in adults, the innominate artery, as has been already mentioned, rises higher than the sternum, in which case a needle so introduced would pierce it.

A needle thrust through in a similar position on the left side would pierce the common carotid artery, and possibly the internal jugular vein.

The relations of these vessels to the lower end of the sterno-mastoid should be borne in mind, since it is sometimes necessary for the relief of wry-neck to divide some part of the muscle in that position. At the upper part of the anterior border, if a line be drawn from the hyoid to the mastoid process, it will correspond to the posterior belly of the digastric muscle. Above this lies that portion of the sub-maxillary gland, which is not deeply placed behind the jaw, and on its surface are some lymphatic glands, which are perceptible when enlarged. Farther down is the lateral lobe of the thyroid body, which cannot be distinctly made out save when enlarged, but which lies beside the inferior part of the thyroid cartilage, the cricoid, and the upper five or six rings of the trachea.

Two veins are related to the external surface of the

sterno-mastoid, viz., a communicating branch from the facial to the anterior jugular, which runs downwards along its anterior border, and the external jugular, which commencing at a point near the angle of the jaw crosses the muscle and terminates in the posterior angle at the middle of the clavicle. This latter vein can be made prominent by pressure applied at its lower extremity. The anterior jugular runs down slightly external to the middle line of the neck.

The most important structures in the region now under consideration are the carotid arteries, common, external and internal, with the branches of the second named vessel. A line from the sternal extremity of the clavicle to a point midway between the angle of the jaw and the mastoid process, indicates the position of the common carotid. It bifurcates as a rule on a line with the upper border of the thyroid cartilage. If a line be drawn downwards and outwards from the anterior part of the hyoid bone, so as to cross the line of the carotid at the level of the cricoid cartilage, it will indicate the position of the anterior belly of the omo-hyoid muscle. The cricoid cartilage is the guide for the incisions which are made along the anterior border of the sterno-mastoid muscle in ligature of the common carotid. This operation is performed either above or below the omo-hyoid; in the former case the centre of the incision is at the level of the cricoid, in the latter its upper extremity. At the level of the cricoid cartilage the carotid can be compressed against the vertebral column, and here also by deep pressure can be felt the anterior tubercle of the

transverse process of the sixth cervical vertebra, which is called the "carotid tubercle," and used sometimes as a guide in the operations mentioned above. It may also be used as a landmark in tying the vertebral artery. The internal jugular vein lies external to the artery, and the pneumogastric and sympathetic nerves posterior. As regards the branches of the artery, the superior thyroid comes off just below the great cornu of the hyoid, and curves downwards towards the lateral lobe of the thyroid body on the anterior surface of the upper portion of which it may be felt pulsating.

The lingual lies immediately above the great cornu of the hyoid, having above it the lingual nerve and the tendon of the digastric muscle. The facial arises immediately above the lingual, sometimes indeed by a common trunk with the latter, and passes under the jaw in the sub-maxillary gland; it emerges again and crosses the jaw in front of the masseter muscle. The occipital artery may be represented by a line starting from the carotid line just above the level of the great cornu of the hyoid, and passing backwards and upwards so as to cross the mastoid process, beneath which the vessel lies, about a quarter of an inch above its apex.

III. STRUCTURES POSTERIOR TO STERNO-MASTOID.

Behind the sterno-mastoid lies the posterior triangle of the neck, bounded behind by the anterior border of the trapezius, passing from the occiput to the point of the shoulder.

The lower portion of this triangle, separated from the remainder by the posterior belly of the omo-hyoid muscle, is surgically the most important part of the region, and is called the sub-clavian or supra-clavicular triangle. The belly of the muscle just alluded to may be seen in a thin neck after swallowing, when its contraction assists to depress the hyoid; it may also be seen in a person sobbing. It lies nearly parallel with the clavicle, and so short a distance above it that its inferior border is often beneath the edge of that bone, especially if the point of the shoulder is raised. It is only when the shoulder is depressed, and after the skin, fasciæ, and other superficial structures have been removed, that any very distinct triangle therefore exists.

The most important structure in the triangle is the sub-clavian artery, which there rises about half an inch above the clavicle, so that if a segment of a circle be described of that height, with one cornu at the sternal end and the other at the middle of the clavicle, it will correspond fairly to the position of the artery. Its vein lies on a plane anterior, but under cover of the clavicle. If the student stand behind a living subject, and press his finger or thumb behind the posterior border of the sterno-mastoid, downwards and a little inwards, he will feel the pulsations of the vessel, and can compress it against the first rib. The posterior border of the sterno-mastoid corresponds fairly to the outer border of the scalenus anticus lying under it, and is a guide to the surgeon in tying the artery. If pressure be made backwards and inwards a little above the artery, the trans-

verse process of the seventh cervical vertebra will be felt. The transverse cervical artery may be felt as a rule running a short distance above the clavicle and parallel to it. The cords of the brachial plexus may be felt and even seen in a suitable subject, especially if the arm be pulled down and the head drawn to the opposite side. The outer edge corresponds to a line drawn from a point a little above the cricoid cartilage to one a little external to the centre of the clavicle. The apex of the lung also reaches up into the neck in this position, a fact which should be borne in mind, since this portion is liable to be first attacked in phthisis. The sub-clavian artery arches over it, being only separated from the lung by the dome of the pleura and the fascia covering it. The lung extends into the neck for a distance varying from $\frac{3}{4}$ to $1\frac{1}{2}$ inch, being higher according to some observers on the right than on the left side. Eichorst, however, says that the apices are, almost without exception, placed at the same height. It is safe to conclude that if one side is higher than the other, it will almost certainly be the right.

At the upper part of the posterior triangle, indeed strictly speaking, in front of the triangle and under cover of the sterno-mastoid, the transverse process of the atlas may be felt just below and in front of the apex of the mastoid process. One inch below the tip of the mastoid the spinal accessory nerve passes beneath the anterior border of the sterno-mastoid. It leaves the posterior border of this muscle at a point opposite the third cervical spine. Its position in the posterior tri-

angle may be indicated by a line drawn from this point to the upper border of the trapezius where it again disappears at the level of the seventh cervical spine.

Three other nerve trunks lying in the upper part of the posterior triangle may be indicated by three lines, each drawn from the central point of the posterior border of the sterno-mastoid. The first line passing transversely across that muscle from behind forwards, will indicate the superficial cervical nerve; the second to the back of the cartilage of the ear, the great auricular; and the third along the posterior border of the muscle to the scalp, the small occipital.

CHAPTER IV.

THE THORAX.

IN this chapter only the anterior and lateral aspects of the thorax will be considered, the remainder being included in that on the back. It is not necessary here to describe the general shape and structure of the thorax, but the student should note the great difference produced in the skeleton by the removal of the shoulder girdle, and should study the relations of the clavicle to the upper part of the cavity. The right side of the thorax is, as a rule, larger than the left. According to Holden, "of ninety-two persons of the male sex and good constitutions, seventy-one had the right side the larger, eleven the left, ten had both sides equal. The maximum of difference in favour of the right was one inch and a quarter. The measurements were made on a plane with the nipple."

Bony points.—The sternum is of course the first object of study. Its upper border, the episternal notch, in inspiration is on a level with the disk between the second and third dorsal vertebræ, and about two inches anterior to it. If the finger be carried downwards, a prominent ridge or angle will be encountered at the junction of the manubrium and gladiolus. This is called the *angulus Ludovici*, it marks the part of the

sternum where union takes place latest, and is of especial importance as a landmark, since it corresponds to the junction of the second costal cartilages with the sternum, and thus enables us to find the second pair of ribs in a fat subject. This ridge corresponds with the lower border of the fifth dorsal vertebra. At the lower part of the sternum the junction of the manubrium with the xiphoid cartilage will be found, this point corresponding to the interval between the ninth and tenth dorsal vertebræ. It is placed a little below the junction of the seventh pair of costal cartilages with the sternum. Though distinct enough in the skeleton it is difficult to make out accurately the edges of the xiphoid cartilage in the recent condition, on account of the ligaments which pass to it from adjacent structures. Sometimes its apex is curved very distinctly forwards, in which case there is a cup-like depression between it and the end of the manubrium (infra-sternal depression or epigastric fossa).

On either side of the episternal notch the sternoclavicular articulation will be seen, and the changes produced at this joint, as well as in the position of the clavicle during its movements, should be studied by raising and lowering the arm of the subject.

The student should next direct his attention to the ribs, which can easily be counted in a thin person, but are more difficult to identify where there is much subcutaneous fat. The first can be felt by pressing the finger backwards and downwards under the clavicle, external to its articulation with the sternum. This rib

has much less mobility than the others, and its cartilage is more often ossified, this being not uncommonly the case in tolerably old subjects. The second corresponds to the *angulus Ludovici*. Rules for finding some of the others will be found in the next section, in connection with the muscular and other markings related to the soft parts.

By commencing above and counting downwards behind the posterior axillary line, the student will be able to discover the last two ribs, which from their position are sometimes difficult of detection. The last rib is very variable in length, being in some cases four times longer than in others. It is proportionately smaller in women than in men (*Macalister*). The importance of the last rib as a landmark will be dealt with in the chapter on the abdomen.

The oblique sweep of the ribs causes the anterior extremity of each to lie on a lower plane than its posterior, thus, the first rib in front corresponds to the fourth behind, the second to the sixth, the third to the seventh, the fourth to the eighth, the fifth to the ninth, the sixth to the tenth, and the seventh to the eleventh. By remembering these facts the student will be able to determine what ribs would be divided in a transverse section at any level. The anterior portions of the intercostal spaces are wider than the posterior, and of the former the third, second, and first are the widest, in the order mentioned. The operation of *paracentesis thoracis*, or tapping the pleura, is generally performed in the sixth interspace, at a point midway between the

anterior and posterior axillary lines. Some surgeons recommend that a space higher should be taken on the right side, on account of the fact that the dome of the diaphragm, rises higher on that side. The trocar should be inserted immediately above the upper border of the lower rib in the space indicated, since there is thus less danger of wounding the intercostal vessels, which lie under cover of the lower border of each rib, in the position in which the operation is performed.

II. SOFT PARTS.

One of the most important landmarks in the thorax is the nipple. This lies in the majority of cases in the interspace between the fourth and fifth ribs, and about four inches from the middle of the sternum. It may also lie on the fourth rib, more rarely on the fifth, most rarely in the fifth interspace. It is not unfrequently farther from the middle line on the right side, and may be placed at a higher level.

The female breast covers the thorax from the third to the sixth or seventh rib, and from the edge of the sternum to the anterior border of the axilla, its base being somewhat oval, with its long diameter directed downwards and inwards. The nipple is placed a little below the centre of the gland, and is surrounded by an areola, which is pink in the nullipara, dark brown, and dappled with lighter spots in the pregnant woman, and after pregnancy becomes a dingy brown, never returning

to its first hue. Beneath the clavicle the deltoid muscle and the upper border of the pectoralis major will be seen, with a triangular interval between. If the finger be pressed deeply into this space, the coracoid process will be felt. It is covered by the fibres of the former muscle.

If the arm be drawn outwards from the chest the great pectoral will be placed on the stretch, and its lower border will indicate the position of the fifth rib with which it corresponds.

If the arm be drawn up by the side of the head, the digitations of the serratus magnus muscle will be seen in a fairly thin subject. The highest of these which is visible corresponds to the fifth rib, the next, which is the largest and most prominent to the sixth, and the two below to the seventh and eighth.

III. RELATIONS OF LUNGS TO THORACIC WALL.

After studying the structures to be seen or felt in the wall of the thorax, the student should turn his attention to the relation of the various important structures which that cavity contains to its exterior. He may first proceed to map out the position of the lungs, which may be done in the following manner. A point should be taken behind the outer border of the sterno-mastoid muscle, and about an inch and a half above the clavicle. From this a line should be drawn, passing on each side through the sterno-clavicular articulation to the centre of the

angulus Ludovici. This line will be slightly indented above the clavicle by the notch for the subclavian vessels. From the centre of the angulus Ludovici the borders of the two lungs run downwards, parallel and close to one another, to a point midway between the

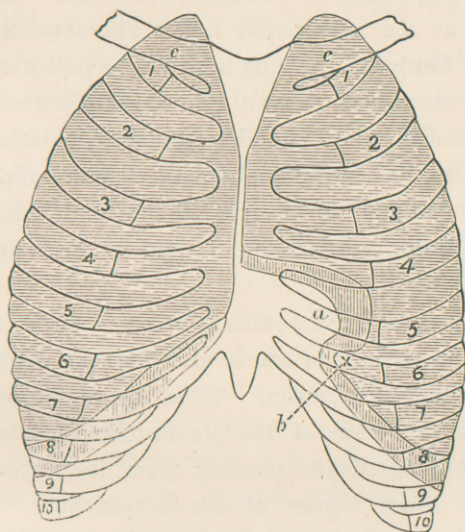


FIG. 7.—Diagram of Relation of Lungs to Chest Wall.

The portion shaded horizontally marks out the area of the lungs, that shaded vertically the supplementary pleural space. 1—10. Ribs. *c. c.* Clavicles. *a.* Incisura cardiaca. *b.* Processus lingualis.

fourth pair of costal cartilages, where they diverge. The left passes outwards along the fourth rib to the apex beat point, turns downwards, crosses the fifth rib, and again turns for a short distance inwards in the fifth interspace, and behind the sixth rib, to form a small

tongue-like process, the *processus lingualis*. The hollow or bay in the lung thus formed corresponds to the part of the heart uncovered by lung (the area of cardiac dulness, hereafter to be more particularly alluded to) and is called the *incisura cardiaca*. The right lung on the contrary, passes downwards to meet the sixth costal cartilage at the parasternal line. The level at which the lower border of the lung lies may be indicated in the following manner:—Draw a line slightly convex downwards, from the sixth chondro-sternal articulation round the chest to the tenth dorsal spine. In the nipple line the lung extends downwards to the sixth rib, in the posterior axillary to the eighth, and in the scapular to the tenth.

The sac of the pleura extends farther down than the limits mentioned, as of course also does the edge of the lung in a full inspiration. Thus, at the front of the chest the reflection of the pleura corresponds to the seventh rib cartilage, passing from its upper to lie below its lower border at the nipple line. In the axillary line it lies at the level of the ninth rib, and posteriorly at that of the twelfth, or lower if that rib be longer than usual. Thus, it is possible for the pleura and diaphragm to be wounded without the lung being involved, and also for the diaphragm to be pierced without any injury to lung or pleura.

IV. RELATIONS OF HEART TO THORACIC WALL.

The base of the heart corresponds to a line drawn across the sternum at the level of the upper border of the third costal cartilages, which extends half an inch to the right, and about one inch to the left. The right border may be indicated by a curved line drawn from the right extremity of the base to the junction of the seventh right costal cartilage with the sternum; this line will be rather more than $1\frac{1}{2}$ inches from the centre of the sternum at the level of the fourth costal cartilage. The lower border may be indicated by a line drawn from the termination of the last to a point in the left fifth interspace, two inches below the nipple, and three and a half from the middle line. The line for the left border runs from the apex in a curve to the left limit of the base. This line will be nearly three inches from the middle point of the sternum at the level of the fourth costal cartilage. The general position of the heart having thus been mapped out, it remains to be seen how its various cavities lie. The right auricle forms the major part of the right border, and lies beneath the third, fourth, and fifth costal cartilages, with the intervening spaces and a part of the sternum, the tip of its appendix being placed on the base line at the mid-sternum. The groove between right auricle and ventricle nearly corresponds to a line drawn from the third left costal cartilage at its junction with the sternum, to the sixth right at a similar point. The left border is

formed by the small portion of the left ventricle, which lies in front, the greater portion of the anterior surface unaccounted for belonging to the right ventricle.

The tip of the left auricular appendix lies behind the lower part of the second left interspace and the upper part of the third costal cartilage.

The position of the apex-beat is in the fifth interspace two inches below, and one inch internal to the nipple, that is about $3\frac{1}{2}$ inches to the left of the middle line, but varies slightly according to the position of the body. Symington and others have pointed out that in the infant the heart has a greater breadth in proportion to the size of the chest than in the adult. Consequently in children the apex-beat is often below or even external to the nipple line. Steffen believed that it was pathological if it lay more than $\frac{3}{8}$ inch external to that line. In children the beat may also be in the fourth interspace, whilst in the aged it may be in the sixth.

The portion of the heart uncovered by the lungs, or area of precordial dulness, may be indicated by a triangle, of which the base is formed by a line drawn from the apex-beat to a little to the right of the middle line of the lower end of the gladiolus, and the left side by a line from the apex to the mid-sternal line at the level of the fourth pair of costal cartilages. The third side is formed by joining the upper and lower sternal points. At the lower angle on the right side the cardiac dulness shades off into that caused by the liver. The precordial area may also be indicated by Latham's method, which consists in describing a circle two inches in diameter,

around a point midway between the left nipple and the end of the gladiolus. This circle is sufficiently accurate for practical purposes. The position of the valves should next be marked out. The pulmonary orifice

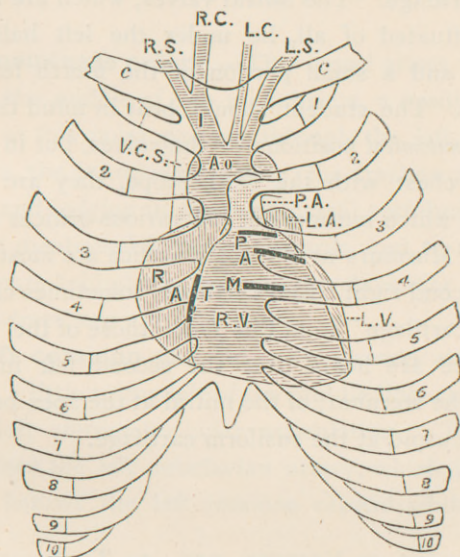


FIG. 8.—Diagram of Relation of Heart and Great Vessels to Chest Wall (modified from Quain).

1-10. Ribs. *c. c.* Clavicles. R. V. Right ventricle, L. V. Left ventricle. R. A. Right auricle. L. A. Left auricle. P. Pulmonary, A. Aortic, M. Mitral, T. Tricuspid valves. Ao. Aorta. R. I. Innominate artery. R. S. and R. C. Right subclavian and carotid. L. S. and L. C. Left subclavian and carotid. P. A. Pulmonary artery. V. C. S. Superior vena cava.

lies most superficially, and is placed to the left of the sternum, and behind it and the third costal cartilage. The aortic valves lie posteriorly and slightly inferiorly

to the last, being placed opposite the lower part of the third left cartilage and the third intercostal space. The tricuspid valves lie behind the sternum at the level of the fourth intercostal space and a part of the fourth costal cartilage. The mitral valves, which are the most deeply situated of all, lie under the left half of the sternum and a small portion of the fourth left costal cartilage. The student should bear in mind that these are the *anatomical* positions of the valves, but in examining the chest with the stethoscope, they are not the points at which murmurs at the various orifices are best heard. Murmurs at the aortic orifice are most distinct at the second right costal cartilage, sometimes called the "aortic cartilage" from this fact; those of the pulmonary orifice are heard over the second left interspace close to the sternum; of the mitral at the apex-beat; and of the tricuspid at the ensiform cartilage.

V. RELATIONS OF VESSELS, ETC., TO THORACIC WALL.

1. **Aorta.**—The ascending portion of the aortic arch passes from the lower part of the third left costal cartilage to the upper border of the second right, and passes just so far from under cover of the sternum that a needle driven through the second right interspace, close to the sternum, will penetrate the great sinus. The transverse portion crosses behind the sternum, just below the middle of the manubrium, a needle driven through at that point passing immediately above it. The end of

the transverse and the descending portions form such a curve that a needle, pushed in through the first left interspace beside the sternum, passes under the concavity of the arch close to the ductus arteriosus, and enters the right border of the descending portion deeper in the thorax.

2. **Innominate artery.**—This vessel arises from the arch at the middle of the manubrium, a needle pushed through at this point passing through the left vena innominata, the innominate artery, the trachea and œsophagus, and lodging in the third dorsal vertebra. From the point mentioned it passes upwards, and to the right to terminate behind the right sterno-clavicular articulation, or sometimes a little higher.

3. **Left common carotid.**—This vessel arises from the arch a little to the left of the middle line, and passes to the left sterno-clavicular articulation. To its left again arises the left subclavian artery, which is almost directly behind the left common carotid whilst in the thorax.

4. **Superior vena cava.**—A needle pushed through the first right interspace, half an inch from the sternum, pierces this vessel at the point of its formation by the junction of the right and left innominate veins. A needle pushed in through the third right interspace, half an inch from the edge of the sternum, pierces the vein where it opens into the right auricle.

5. **Left vena innominata.**—This lies transversely behind the sternum and just below its upper border. It may project into the neck, when the transverse part of

the arch is situated at a higher level than usual as may be the case especially in children.

6. **Inferior vena cava.**—The opening of this vein into the right auricle lies under the mesial portion of the fifth right interspace, and the adjacent part of the sternum.

7. **Internal mammary artery.**—This descends behind the clavicle, the costal cartilages and the first six intercostal spaces. It is situated about half an inch from the edge of the sternum and parallel to it.

8. **Trachea.**—The trachea bifurcates at or just below the angulus Ludovici, and opposite the fourth dorsal vertebra. The right bronchus lies behind the cartilage of the second right rib at the edge of the vertebral column, and the left behind the second left interspace in a similar position.

9. **Diaphragm.**—In the dead subject the dome of the diaphragm is generally said to rise as high as the fifth rib on the right side, and the sixth on the left. This is of course subject to great variations, according to the period of respiration in the living, and may vary also in the dead. Thus, a needle pushed through at the point of the apex-beat in the fifth interspace at the left side, may pass twice through the diaphragm, wounding the stomach intermediately.

CHAPTER V.

THE ABDOMEN.

IN this chapter the anterior part of the abdominal wall alone is considered, together with its relation to the viscera and other structures. The posterior and postero-lateral portions will be dealt with in the chapter on the back, and the perineum and male and female genitalia form a separate chapter.

I. BONY PROMINENCES.

The xiphoid cartilage and the costal arch have already been alluded to. At the lower part of the abdomen the crest of the ilium and anterior superior spine of the ilium are readily to be distinguished. In the erect posture a line drawn so as to connect the latter prominences on either side, passes a little above the promontory of the sacrum. The symphysis pubis, and on either side of it the pubic spine, should be identified. The former is covered by a pad of fat of considerable size in females, in whom it is called the *mons Veneris*, the term *mons Jovis* being sometimes applied to it in the male. Should any difficulty be found in distinguishing the spine it may be discovered by invaginating the

scrotum and pushing the finger up along the cord, or by abducting the leg and tracing upwards the border of the adductor longus muscle. The spine of the pubes is an important landmark in connection with inguinal and femoral herniæ, as it lies inferior and external to the first, and superior and internal to the last. It is nearly in the same horizontal line as the apex of the great trochanter.

II. SKIN MARKINGS, ETC.

The linea alba forms the middle line of the abdomen, it is the line of junction of the anterior aponeuroses in the interval between the two recti muscles, and though it extends from the xiphoid cartilage to the pubes, is only distinctly marked as a groove above the umbilicus. It is the thinnest and least vascular part of the abdominal wall, for which reasons it is selected usually as the site of the incision in abdominal sections. On each side of it lies the prominence of the rectus muscle, bounded externally by a curved line, the linea semilunaris, which extends from the tip of the ninth or tenth costal cartilage to the spine of the pubes. The rectus muscle is intersected by certain horizontal lines, the lineæ transversæ. There are usually three of these, one being placed at the tip of the xiphoid cartilage, a second midway between it and the umbilicus, or on a level with the tenth costal cartilages, and the third at the umbilicus itself. A fourth may be present below

the umbilicus. The position of the umbilicus is somewhat variable, but always below a point midway between the xiphi-sternal articulation and the symphysis pubis. It is generally described as corresponding to the disk between the third and fourth lumbar vertebræ, or

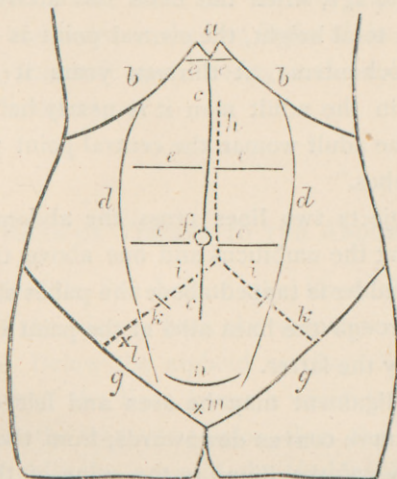


FIG. 9.—Diagram of Anterior Surface of Abdomen.

a. Xiphoid cartilage. *b. b.* Costal arch. *c. c.* Linea alba. *d. d.* Lineæ semi-lunares. *e. e.* Lineæ transversæ. *f.* Umbilicus. *g. g.* Poupart's ligaments. *h.* Abdominal aorta. *i.* Common, *k.* External iliac arteries. *l.* Internal. *m.* External abdominal rings. *n.* Supra-pubic fold.

to the tip of the spinous process of the third lumbar vertebra.

The older writers believed it to be the central point of the body, but this idea is incorrect. According to Mr. Roberts (*Anthropometry*) "at the time of birth, when the child is about the sixth of the height it will ulti-

mately attain to, the point which divides the total height into two equal parts is a little above the navel; at two years of age it is at the navel; at three years, when the child has attained half its total height, the central point is on a line with the upper borders of the iliac bones; at ten years of age, when the child has attained three-fourths of its total height, the central point is on a line with the trochanters; at thirteen years it is at the pubes, and in the adult man it is nearly half an inch lower. In the adult woman the central point is a little above the pubes."

In fat subjects two lines cross the abdomen transversely, one at the umbilicus and one above the pubes. When the bladder is tapped above the pubes the trochar is passed through the linea alba at the point where it is intersected by the latter.

Poupart's ligament may be seen and felt extending in a gentle curve convex downwards, from the anterior superior spine of the ilium to the spine of the pubes. The external abdominal ring lies just above the crest of the pubes, having the spine external to it. It may be felt by invaginating the scrotum and pushing the finger up in front of the cord.

The internal ring is situated half an inch above the middle point of Poupart's ligament. A line drawn from one ring to the other will indicate the position and limits of the inguinal canal. It should be remembered that in the child at birth there is scarcely any true inguinal canal, as the rings almost overlie one another.

The position of the nerves of the abdomen is of im-

portance in connection with certain forms of vertebral disease which cannot here be particularly considered, and the student should, therefore, be familiar with their approximate position. The tenth nerve is nearly in a line with the umbilicus, the eighth with the middle line transversa, the sixth and seventh supply the area above this and between the two limbs of the costal arch. The ilio-hypogastric and ilio-inguinal lie close above Poupart's ligament.

III. RELATIONS OF VISCERA TO THE ABDOMINAL WALL.

In the middle line behind the linea alba the disposition of the viscera from above downwards is briefly as follows. Below the xiphoid cartilage lies a part of the left lobe of the liver, beneath which is the stomach. Next comes the transverse colon, then the small intestine, and finally the apex of the bladder, if sufficiently distended. It will now be necessary to consider these and other viscera more particularly.

1. **Stomach.**—This organ, whilst comparatively fixed at its cardiac extremity, is moveable to a considerable extent at its pyloric, and consequently alters in its relations according to the amount of its distension. The cardiac orifice lies about one inch from the sternum behind the seventh left costal cartilage, and corresponds to the spine of the ninth dorsal vertebra posteriorly. The fundus lies to the left of this and on a higher level, rising as high as the upper border of the sixth sterno-

chondral articulation, or even higher, so as to be placed just behind the apex of the heart. If a line be drawn downwards from the right border of the sternum, and another from the end of the bony portion of the seventh rib, the point at which these intersect will indicate the position of the pylorus in the empty condition of the stomach. But when full the pylorus may move as much as three inches to the right, so as to lie behind the junction of the seventh and eighth right rib cartilages. It is situated more superficially than the cardiac opening. A line drawn so as to connect the tips of the tenth costal cartilages will indicate the lower limit of the moderately distended organ; when further distended it reaches to a point from $\frac{3}{4}$ to $1\frac{1}{2}$ inches above the umbilicus. In the operation of gastrostomy the incision is generally made parallel to the left side of the costal arch, and about two fingers breadth below it, as the stomach is here uncovered by liver, and in contact with the anterior abdominal wall. This area is bounded on the right by the edge of the liver, on the left by the cartilages of the eighth and ninth ribs and below by a horizontal line passing between the tips of the tenth costal cartilages.

2. **Liver.**—In the erect posture the liver descends about half an inch below the costal arch, though it is a matter of some difficulty to feel it in that position. It is much more obvious beneath the xiphoid cartilage, where in the angle of the costal arch the lower border of the organ may be indicated by a line drawn from the ninth right to the eighth left costal cartilage. The size of the left lobe is somewhat variable, and its left

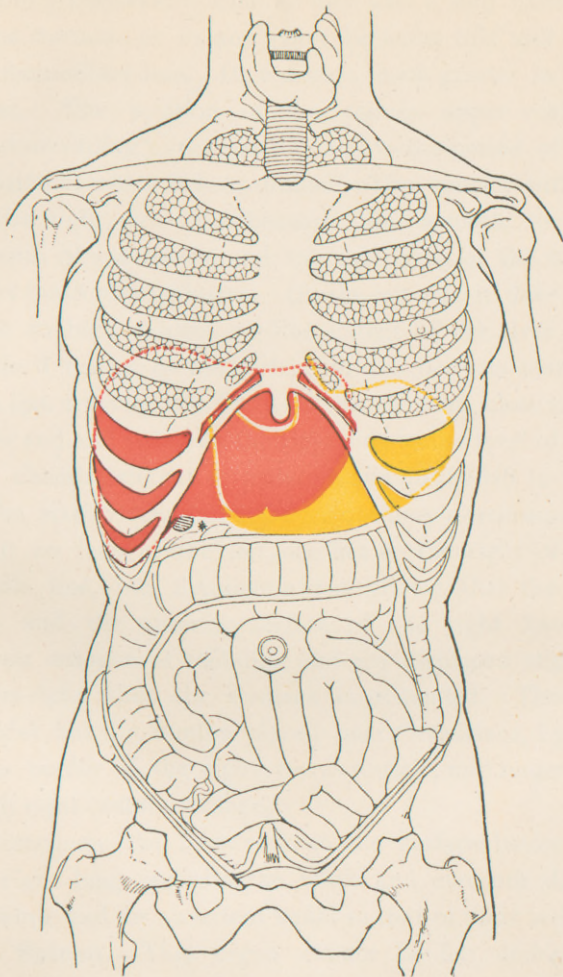


FIG. 10.—Diagram of Anterior aspect of Abdomen and Thorax, showing relations of Viscera to surface (*Luschka slightly modified*). Red, Liver; Yellow, Stomach. * Gall-bladder.

extremity may extend from an inch and a half external to the sternum, or to any point between this and the left mammillary line. Its extent is much greater in the infant. The position of the convex upper surface varies according to the posture, and to the period of respiration at which it is examined. The convex surface on the right side lies beneath the seventh to the eleventh ribs inclusive, and the cartilages of the sixth to the ninth also inclusive. On the left side it does not reach so high a level. "The extent of the liver upwards if traced on the surface of the body is marked by a line crossing the body of the sternum, close to its lower end and rising on the right side to the level of the fifth chondro-sternal articulation and on the left to that of the sixth" (Quain). Under ordinary circumstances about an inch of the left lobe lies to the right of the middle line, but Symington has shown that the left lobe and the anterior surface of the right have a certain amount of mobility, and are displaced slightly to the right when the stomach is distended. The gall bladder has its fundus placed near the surface, by the outer border of the right rectus muscle, and under the ninth right costal cartilage.

Posteriorly the liver reaches the surface below the right lung opposite the tenth and eleventh dorsal vertebræ and for an extent equal to that of their bodies.

3. **Spleen.**—This organ cannot be felt under the edge of the ribs save when pathologically enlarged. It lies beneath the ribs from the eighth or ninth to the eleventh inclusive, and nearly in the line of the posterior

part of the tenth. Its mesial extremity is about $1\frac{1}{2}$ inches from the middle line, and its outer about the same distance from the mid-axillary. It should, however, be remembered that it is subject, within physiological limits, to considerable variations in size.

4. **Pancreas.**—It is very rarely possible to feel this organ, but in a very thin subject with flaccid abdominal walls, it may be distinguished. It lies on the vertebral column over the disk between the first and second lumbar vertebræ and the adjacent bodies, and should consequently be sought in the middle line of the abdomen, nearly midway between the xiphoid cartilage and the umbilicus.

5. **Intestines.**—Save where it is hidden by the liver and spleen at the hepatic and splenic flexures, the transverse colon is near to the surface, varying in height from the region of the umbilicus or below it, to two inches or so above. When dilated by gas its situation may be ascertained by percussion, and masses of hardened fæces, when present, can be felt in its interior. The cæcum, which is the most superficial part, lies in the right iliac fossa. The sigmoid flexure, lies in the left iliac fossa. The vermiform appendix lies in a line from the anterior superior spine to the umbilicus and about three inches from the former (McBurney's point). The small intestine occupies the portion of the abdomen below the transverse colon. Mr. Treves concludes from his laborious investigations, that it is impossible to localise the position of any of the coils connected with the mesentery.

6. **Bladder.**—The bladder cannot be distinguished above the pubes save when distended. In this condition it may extend up to the umbilicus, or to any point between it and the pubic symphysis. In extreme distension from retention of urine, its outline can easily be distinguished, and the fluctuation of its contents felt. It carries the peritoneum before it as it pushes its way upwards, so that an uncovered space of greater or less extent exists, through which the trocar is passed in the operation of tapping above the pubes.

Other points in connection with the colon and the kidneys will be dealt with in the chapter on the back.

IV. RELATION OF VESSELS TO THE ABDOMINAL WALL.

The abdominal aorta commences rather above the centre of a line drawn from the supra-sternal depression to the umbilicus; lies on the left side of the vertebral column, and generally divides into the two common iliac arteries opposite the middle of the body of the fourth lumbar vertebra. Its bifurcation is, however, subject to considerable variations.

When it divides at the usual situation it will nearly correspond to a point a little to the left side of the centre of a line drawn so as to connect the highest parts of the two iliac crests. This point will be placed about $\frac{3}{4}$ of an inch below and to the left of the umbilicus. If two lines be drawn from it, curving slightly outwards, to a point a little internal to the middle of either

Poupart's ligament, they will correspond to the common and external iliac arteries. The former of these vessels is somewhat variable in length, but, speaking generally, about two inches of either line, or rather more on the right, will correspond to its limits. A line drawn from the point where Poupart's ligament crosses the external iliac to the edge of the rectus, about an inch or more below the umbilicus, will indicate the position of the deep epigastric artery, and the triangle thus included will correspond to Hesselbach's triangle. The cœliac axis corresponds to the twelfth dorsal vertebra behind, and to a point four or five inches above the umbilicus in front. The superior mesenteric artery arises just below this, and the renal arteries an inch lower down. The inferior mesenteric is given off about an inch above the umbilicus.

CHAPTER VI.

THE PERINEUM AND GENITALIA.

I. THE MALE.

THE student should first of all practise the operation of passing the catheter or sound, a procedure more difficult in the dead subject than in the living, when the latter is not affected with a stricture. The sound should be well oiled, and its passage will be facilitated by dilating the mouth of the urethra and pouring a little oil into it. The operator should stand on the left side of the body and hold the penis in the left hand. Stretching the penis he should introduce the instrument, keeping the handle in the line of the left groin at first. As it glides down the urethra it should gradually be carried towards the middle line, until its direction corresponds with the long axis of the body, from which it should not be allowed to swerve. When the instrument has been passed a certain distance a slight obstruction will be met with, which is the base of the triangular ligament. The handle should then be slightly depressed, when a little gentle pressure will carry the point of the instrument into the bladder. If the student finds it difficult to accomplish this he may pass his left forefinger into the rectum and guide the point of the instrument, which

will be easily felt with the point of the finger. Having passed the sound into the bladder, it should be withdrawn, and the manœuvre repeated several times. The instrument may then be left in the bladder.

1. **Penis.**—This organ should next be examined. The large dorsal vein will generally be visible on its upper surface, and on either side of it, in a well injected subject, an artery may be visible. The prepuce should be reflected and its frænum examined. The glans, with its corona at its base, and the constricted portion or cervix, around which are collected the glands of Tyson, will then be seen.

2. **Scrotum.**—The spermatic cord should be felt and the vas deferens distinguished from its other constituents, which can easily be done by its whipcord-like feel. The testicle is of course easily to be felt, and the epididymis lying posteriorly and superiorly should be distinguished from the gland itself. The rugæ of the scrotum are much less distinct in the dead subject than in a healthy living individual, on account of the relaxation of the muscular fibres of the dartos.

A median line or raphe, continuous with a similar line in the perineum, indicates the position where the originally separate halves came together and united in the process of development.

3. **Perineum.**—The scrotum should now be hooked up on the front of the abdomen, and the body placed in the lithotomy position, so that the perineum may be examined. This position is maintained by different methods in different schools, so that no particular

description need be given. The boundaries of the perineum should first be ascertained. Commencing in front, the pubic arch, rounded off by the sub-pubic ligament will be felt, and passing round on either side the rami of the pubis and ischium up to the tuberosity of the latter. In the middle line behind is the coccyx, and on either side of it the great sacro-sciatic ligament may be distinguished under cover of the edge of the gluteus maximus muscle. A line from the most prominent part of one tuber ischii to the other divides this diamond-shaped space into two triangles, an anterior or urethral, and a posterior or rectal. It is divided also by the mesial ridge or raphe, which has already been alluded to. Like many other middle lines of the body, this last is comparatively non-vascular, and incisions should consequently there be made for the escape of extravasated urine.

The central point of the raphe between the scrotum and anus corresponds to the central tendinous point of the perineum, or point of junction of the perineal muscles. This is placed at the centre of the lower border of the triangular ligament, which may be felt on each side of it when the legs are straight and the parts relaxed. The bulb of the urethra and its artery are always placed in front of this point. The urethra pierces the triangular ligament about three quarters of an inch in front of it, and its position can be distinctly felt when the sound is within it.

Around the anus, in dissecting room subjects, knots of venous enlargement or piles are not uncommonly

the most prominent structures. Apart from these pathological structures, the student will note the radiating folds into which the mucous membrane is thrown, as also a thin white line surrounding the aperture where the skin and mucous membrane join, which indicates the line of division between the external and internal sphincters. By everting the mucous membrane of the rectum slightly, the small pouches, one to three lines in depth, which lie between the ends of the columnæ recti, and are sometimes the seat of ulceration, will be seen.

The left forefinger should now be introduced into the rectum, while the staff is held in the right hand so that it may be moved about when necessary. In the anterior part of the cavity, the student will feel the sound in the membranous part of the urethra. It is here that strictures most commonly occur, and that the catheter requires at times that careful guidance, which, as will now be perceived, the finger in the rectum can give to it. Passing further upwards, the apex of the prostate gland will be met with at about an inch and a half from the anus, and the shape of the gland can be explored. About an inch and a quarter higher up, the superior border of the prostate will be reached, and the finger having passed beyond it will touch that part of the rectum where the bladder is in contact, without the intervention of peritoneum, and where the operation of tapping per rectum is performed. On each side of this point are placed the common ejaculatory ducts and seminal vesicles. The lowest of the transverse folds, valves of Houston or *plicæ transversales*, may be dis-

tinguished on the left side at about the level of the prostate, the next, about four inches from the anus, is on the right side, and roughly marks the lowest point to which the recto-vesical pouch of peritoneum descends. Otis has shown that by placing the dead body in what is known as the knee-elbow position, the rectum becomes dilated by atmospheric pressure, and by suitable illumination (electrical) three or four of these plicæ can be seen placed alternately on either side of the tube. Contrary to a commonly received view, he denies that they have any action as valves in holding back the fæces. At the sides of the rectum the finger can explore the ischio-rectal fossæ, and finally behind, near the orifice, the coccyx will be felt. It is sometimes movable in males, generally freely so in women who have borne many children.

Before leaving the perineum the student should mark out the lines of the incisions made in the operations of lithotomy. In the lateral operation the incision is commenced a little to the left of the middle line, and just below the central tendinous point, and is then carried downwards and outwards for two or three inches to a point just below the anus, but one-third nearer to the tuberosity of the ischium than to the margin of that orifice.

In the median operation the edge of the knife is turned upwards instead of downwards, and its point is entered in the middle line about half an inch in front of the anus, and carried onwards until it strikes the groove in the staff which is lying in the urethra.

II. THE FEMALE.

The labia majora, covered with hair on the outer surface, and on their inner with mucous membrane, are the first objects visible; they unite below the mons Veneris and in front of the perineum, these junctions being known as the anterior and posterior commissures. When these folds are separated, two smaller folds of mucous membrane, the nymphæ or labia minora, will be seen, each being about an inch and a half in length. Traced upwards these will be found to be continuous with the prepuce, covering the glans of the clitoris. Below the nymphæ, and uniting the labia majora, there is in the nullipara a transverse fold, the frænulum pudendi, forming with the posterior commissure a triangular area, the fossa navicularis. The student will generally seek in vain for these in dissecting room subjects, as the first parturition usually destroys them. Between the nymphæ is the vestibulum, and in it, about an inch below the clitoris, is the opening of the urethra. A tubercle is often stated in text-books to be placed at this orifice, but as a practical landmark it is almost valueless. Having ascertained the position of the orifice the student should practise passing the catheter. As this operation has to be performed on the living subject without causing exposure, it is well to accustom the fingers to the parts engaged. The subject should be placed on its back, with the knees slightly bent and separated from one another, and the operator should

stand on the left side. The forefinger of the left hand should be passed down between the vulvæ, over the clitoris, and into the vestibule, where the orifice of the urethra may sometimes be felt. In any case, by passing the point of the catheter along the palmar surface of the finger, it can, with a little practice, be made to enter the urethra easily. The ordinary sound found in dissecting rooms is an inconvenient instrument for the purpose, but a probe may be used, or still better, a piece of small sized glass tube about six or eight inches in length, one end of which has been sealed and rounded in a flame, and at the same time slightly bent. When the student has familiarised himself with this operation, he should leave the instrument *in situ*, and examine the relation of the urethra, which passes just below the sub-pubic ligament and the posterior wall of the bladder to the vagina. The close connection between the walls of these two cavities, and their comparative thinness, lead to their occasional rupture and the formation of a vesico-vaginal fistula. The same might be said of the posterior wall, where recto-vesical fistula occurs. The proper orifice of the vagina is just below the meatus urinarius, and is generally narrowed in the virgin by the hymen. This is a structure which is seldom seen in the dissecting room, but may be studied in a female fœtus at full term or in the post-mortem room, in the bodies of virgins. The examination of a sufficient number will teach the student that it is variable in size and shape. It may even in the virgin be entirely absent, or represented by a fringe.

On the other hand it may be imperforate, or its opening may be so small as only to admit the point of a probe. The aperture may be enlarged so that the hymen forms a circular ring, but most commonly it is semilunar, with its concavity directed towards the pubes. From all this, the student will perceive that any diagnosis of virginity, or the reverse founded upon the condition of the hymen alone, must be very guarded in its nature. After its rupture, small wart-like remains, the *carunculæ myrtiformes*, may persist, but these generally disappear after a few parturitions.

The forefinger should be passed into the vagina, and the os uteri with the anterior and posterior *cul-de-sac* explored. The posterior is the higher, and corresponds to the pouch of Douglas or recto-vaginal pouch in the cavity of the abdomen. This is the lowest point of that cavity, and the position, therefore, where fluid will first collect. One forefinger may be passed into the rectum and the other into the vagina, and the wall between examined. At the highest part the recto-uterine fold of peritoneum will lie between the fingers. The description of the anus, mucous folds of the rectum, ischio-rectal fossa, and coccyx, in the male, need not be repeated for the female. Between the anus and the uro-genital fissure, lies the perineum of the obstetrical text-books, about one inch in breadth. It is easy to see how the head of the child in parturition may tear through this, and even through the rectum and anus.

CHAPTER VII.

THE BACK.

IN the middle line of the back there is a furrow, more or less well-marked, according to the muscularity of the subject, and bounded by muscular masses, which are formed chiefly by the complexus muscle of either side in the cervical region, and by the *erectores spinæ* in the remainder of the back. At the bottom of this furrow the spines of the *vertebræ* may be felt, and, as Holden remarks, made evident in the living subject to the eye by friction in the median line, when red patches will appear and indicate their position. The spine of the axis may easily be felt beneath the occiput, and that of the seventh or *vertebra prominens* at the root of the neck, with frequently the spine of the sixth above it. The spines of the *vertebræ* between the second and the sixth cannot be felt as individual structures, but a ridge indicating their position and that of the *ligamentum nuchæ* can distinctly be made out.

The third dorsal spine corresponds to the inner end of the spine of the scapula, and the seventh to the inferior angle of that bone. The twelfth corresponds to the head of the last rib, and the lowest part of the *trapezius* muscle, which may be made evident in a thin

subject by raising the arm and scapula as high as possible. The highest point of the crest of the ilium corresponds to the fourth lumbar spine. On account of the downward direction of the spines of the dorsal vertebræ, these prominences do not all correspond to the rib which belongs to them. The second dorsal spine corresponds to the head of the third rib, and so on, each spine corresponding to the head of the rib of the vertebra below it, until the eleventh and twelfth spines, which are on a level with their own ribs.

The scapula covers the ribs from the second to the seventh inclusive, and its superior and inferior angles and spine can easily be distinguished.

The crest of the ilium and its posterior superior spine can be felt; at the central point of the former there is a triangular space bounded by the latissimus dorsi and external oblique muscles, known as Petit's triangle. The upper limit of the origin of the latissimus dorsi corresponds to a line drawn from the sixth dorsal spine transversely across the scapula.

The trachea bifurcates at a point midway between the third and fourth dorsal spines, the roots of the lungs thus lying a little below and external to that point, the edge of the lung extending as low as the spinous process of the tenth dorsal vertebra. The apex of the lower lobe is at the level of the third rib behind. The pleura reaches to the tenth dorsal spine or even lower.

The thoracic aorta commences at the left side of the vertebral column opposite the fourth dorsal spine; thence passes downwards, gradually approaching the

anterior aspect to bifurcate opposite the fourth lumbar spine.

Spinal cord and nerves.—The cord extends in the adult from the under surface of the foramen magnum to the lower edge of the first lumbar vertebra as a rule, or on the other hand, may be as low as the second lumbar. Its position alters slightly in the movements of the body, as it rises during flexion of the spine. In the child at birth it extends to the third lumbar vertebra. The cervical nerves are named after the vertebra above which they escape, the first nerve emerging above the first vertebra, and the eighth below the seventh, and between it and the first dorsal. The remaining nerves are numbered after the vertebra below which they escape. In relation to the symptoms following upon fractures and dislocations of different parts of the spinal column, it is important to know the point at which each nerve arises from the spinal cord, this point by no means corresponding to that at which it emerges.

The following rule will enable the student to find the relationship of the root origin of the cervical and dorsal spinal nerves to the spines of the vertebræ with sufficient accuracy. For the upper four nerves subtract one from the number of the nerve, thus the root origin of the third cervical is opposite the second spine. For the lower four cervical and upper six dorsal, subtract two from the number of each nerve, thus the root origin of the eighth cervical is opposite the sixth cervical spine. For the lower six dorsal nerves subtract three from the number of the nerve, thus the root origin of ninth dorsal is

opposite the sixth dorsal spine. The lumbar nerves arise in the neighbourhood of the tenth and eleventh dorsal spines and the sacral nerves between the eleventh dorsal and first lumbar spines. It is right, however, to say that these relations are subject to considerable variations.

Kidneys.—The kidneys lie on a level with the last dorsal and first two or three lumbar vertebræ, the right being about half an inch or more lower than the left, so that about one and a half inches on the left, and one inch on the right, intervene between the lower border of the gland and the iliac crest. The hilus lies from two to two and a half inches from the middle line, and is about opposite the first lumbar spine. The following method of mapping out the kidney on the posterior aspect of the body may be adopted:—1. Draw a line parallel with and one inch from the spine, between the lower edge of the tip of the spinous process of the eleventh dorsal, and the lower edge of the spinous process of the third lumbar vertebra. 2 and 3. Lines drawn from the top and bottom of this line outwards at right angles to it for $2\frac{3}{4}$ inches. 4. A line parallel to the first and connecting 2 and 3. Within this parallelogram the kidney lies (Morris). In the normal condition it is difficult to feel these organs, but in a thin subject with flaccid walls the rounded outer border may be made out. When abnormally enlarged they may be distinguished, and in searching for them the student should adopt the following method. Stand on the side of the body opposite to the kidney to be examined, pass one

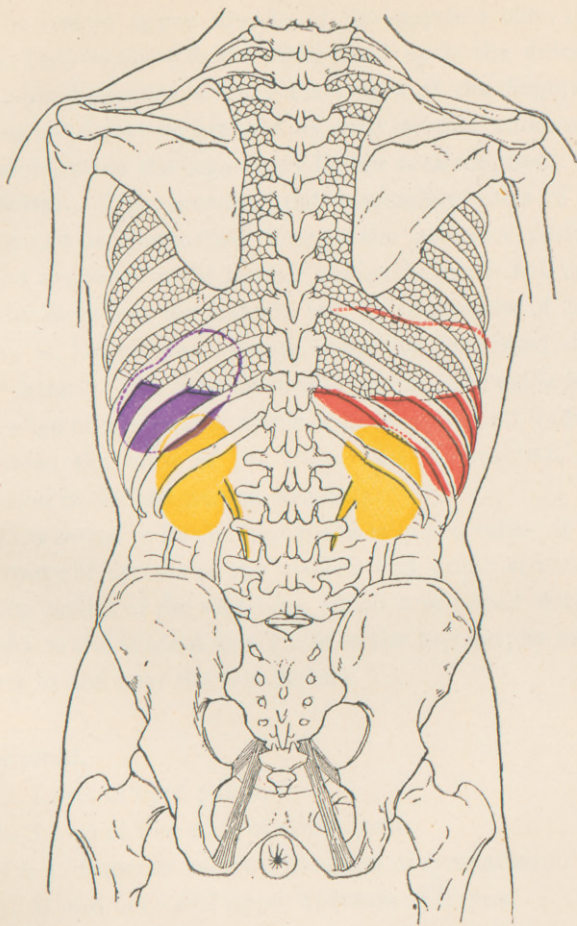


FIG. 11.—Diagram of posterior aspect of Abdomen and Thorax, showing relations of Viscera to surface. *Red*, Liver; *Purple*, Spleen; *Yellow*, the Kidneys and Ureters. (*Modified from Luschka*).

hand under the back until the fingers slip over the edge of the erector spinæ muscle of the opposite side, then press backwards with the other hand upon the anterior abdominal parietes, so that the points of the fingers of either hand may be brought as near to one another as possible, when the organ may be felt between them.

Colon.—The ascending and descending parts of the colon can be approached through the posterior parietes of the abdomen in the lumbar region between the crest of the ilium and the last rib, but the operation of colotomy is, for various reasons, generally performed upon the latter. The incision in this operation is made from the edge of the erector spinæ muscle, at a point midway between the crest of the ilium and the last rib, and parallel to the last named structure.

This seems to be the best place to give a table of the relations of certain of the viscera and other structures to the bodies of the vertebræ, which it is hoped may be useful to the student as a guide to the topography of the parts in and near the middle line.

Cervical.

1. Level of hard palate.
2. Level of free edge of upper teeth.
- 3 & 4. Superior cervical ganglion of sympathetic.
4. Hyoid bone and upper aperture of larynx.
5. Middle cervical ganglion ; rima glottidis.
6. Cricoid cartilage, end of pharynx, commencement of œsophagus and trachea.
7. Inferior cervical ganglion.

Dorsal.

1. Apex of lung.
2. Termination of second part of aortic arch (L).
Disk. Level of episternal notch.
3. Termination of arch of aorta (L). Bifurcation of
trachea (lower border).
4. Level of angulus Ludovici.
- 5 to 8. Base of heart.
6. Pulmonary orifice.
7. Aortic orifices.
8. Mitral and tricuspid orifices.
9. Level of lower end of gladiolus. Opening in dia-
phragm for vena cava inferior. 9 to 11. Spleen.
10. Level of tips of xiphoid cartilage. Opening in
diaphragm for œsophagus. Lower limit of lung
posteriorly (transverse process). 10 and 11.
Spigelian lobe of liver.
11. Supra-renal capsule; upper end L. kidney.
12. Disk—upper end of R. kidney. Aortic orifice in
diaphragm, cœliac axis (lower border).

Lumbar.

1. Pancreas. Superior mesenteric artery (lower bor-
der). Hilus of kidney (spine). Receptaculum
chyli.
Lower end of spinal cord.
2. Upper limit of third stage of duodenum (L). Renal
arteries.

Lumbar.

3. Lower limit of second stage of duodenum (R).
Inferior mesenteric artery.
Disk. Umbilicus.
4. Bifurcation of aorta. Level of highest point of
crest of ilium.
Disk. Ilio-cæcal valve.
5. Commencement of inferior vena cava.

Sacral.

3. End of first stage of rectum.

Coccyx, tip.

- End of second stage of rectum.

CHAPTER VIII.

UPPER EXTREMITY.

I. SHOULDER AND AXILLA.

1. **Bony points.**—The clavicle may be seen and felt in its entire extent. In the ordinary position in men it is not horizontal but slopes upwards from the middle line, the amount of this slope being increased when the weight is taken off the arm as in the recumbent posture. But in women commonly, and sometimes in men also, its slope is downwards from the middle line. The outer extremity of the clavicle leads to the acromion process, which, with the spine of the scapula, is quite distinct. The tip of the former is one of the prominences from which measurements of the upper limb are made, and it may be remembered that in the hanging position of the arm, the palm being directed forwards, it is in the same line as the external condyle of the humerus and the styloid process of the radius. The student should remember that the end of the acromion process may be unconnected with the spine, by a failure of bony union between the centres from which it and the spine are developed. Under cover of the deltoid muscle the two tuberosities of the humerus will be felt, the greater being external and in the line of the external

condyle, the lesser anterior. Between them the bicipital groove and tendon may sometimes be distinctly made out. By placing the hand on the apex of the shoulder and the thumb in the axilla, and pressing deeply with the latter, the arm being in the dependent position, the neck of the scapula and the lower border of the glenoid fossa can be distinguished. If now the arm be abducted and the thumb moved a little outwards the head of the humerus will be felt, and can be easily identified by rotating the arm, when its shape will be distinctly recognized. It lies in the same line as the internal condyle. By deep pressure beneath the clavicle, in the interval between the deltoid and pectoralis major muscles, the tip of the coracoid process will be felt under the former. This is another point from which measurements of the upper extremity are made, and is also valuable as a guide to the axillary artery in its first stage.

2. **Soft parts.**—The point of the shoulder is capped over by the deltoid muscle, the limits of which are easily to be defined. Under ordinary circumstances it forms a smooth rounded surface over the subjacent bony prominences; but in dislocation downwards of the humerus, and to a lesser degree in paralysis of the deltoid following upon injury to the circumflex nerve, a depression will be visible at the outer part of the shoulder corresponding to the interval between the head of the humerus and the acromion process. In the groove between the deltoid and pectoralis major lie the cephalic vein and the humeral thoracic artery. The coraco-

acromial ligament lies under the anterior fibres of the deltoid, and may there be distinguished, the shoulder joint being immediately underneath it. Under the clavicle is a hollow of variable depth, the sub-clavicular fossa, in which the axillary vessels lie; it is obliterated or replaced by a prominence in certain dislocations of the humerus. At a lower level the line of division between the clavicular and sternal portions of the pectoralis major may be distinctly seen in some subjects. The student should next examine the axilla and move the arm in different directions so as to observe the alterations in its shape caused thereby. Its base is somewhat triangular, the apex being at the humerus, and the base at the chest wall. The anterior fold contains the pectoralis major, and the posterior, the latissimus dorsi. The depression between the anterior and posterior folds is deepest when the arm is at an angle of 45° with the chest, and shallowest when the arm is raised above the level of the shoulder. The hollow, however, never quite disappears, a fact which is partly due to the action of the suspensory ligament, a part of the deep fascia connected with the skin below. The skin of the axilla is well supplied with hairs, sebaceous and sweat glands. Three sets of lymphatic glands are contained in the axilla, which, however, cannot be felt unless enlarged. These are placed, (1) along the anterior fold, (2) along the posterior, (3) along the vessels.

When the arm is stretched out at a right angle to the body, the prominence of the coraco-brachialis muscle

may be distinctly seen passing down to the middle of inner border of the humerus. If the arm be maintained in this position, and a line drawn from the centre of the clavicle to the humerus, internal to the lower end of the coraco-brachialis, it will correspond to the axillary artery. This vessel may be compressed in its first stage against the second rib, beneath the clavicle and internal to the coracoid process, pressure being applied downwards and backwards. In its third stage it may be compressed against the humerus by the side of the coraco-brachialis, pressure here being applied outwards and a little backwards. In its second stage it lies deeply beneath the pectoralis minor muscle. The boundaries of this last may be defined by two lines starting from the coracoid process, and running, the upper to the third rib close to the cartilage, and the lower to a similar point on the fifth rib. The point where the upper line crosses the line of the axillary artery indicates the site of the acromial axis. The long thoracic artery runs along the lower border of the pectoralis minor and consequently corresponds to a portion of the second line. The axillary vein is internal to its artery, lying in the angle between the clavicle and the first rib, and the nerve cords of the brachial plexus are, in the first stage, external to it.

The circumflex nerve winds round the back of the humerus, a little above the middle point between the apex of the shoulder and the lowest part of the insertion of the deltoid and its cutaneous branches ramify over the lower part of that muscle, the supra-acromial

branches of the cervical plexus lying over its upper portion.

II. ARM AND ELBOW.

I. **Arm.**—On either side of the distinct median prominence of the biceps will be seen a depression, that on the inner side being the better marked. These grooves are caused by the two partitions of fascia which cut off the anterior from the posterior muscles of the arm, the intermuscular septa. The external groove passes from the muscles above the outer condyle to the lower end of the insertion of the deltoid and corresponds also to a part of the cephalic vein. The internal groove extends from near the internal condyle to the insertion of the coraco-brachialis muscle and indicates a portion of the course of the brachial artery which lies on its outer side. The course of this vessel may be marked out by a line drawn from the inner side of the coraco-brachialis at its insertion to the centre of the elbow joint. Throughout it may easily be felt as it lies close beneath the skin, and may also be compressed against the humerus, though the direction in which the pressure is applied differs above where it lies internal to the bone, and below where it lies in front of it. The inner edge of the bicipital prominence is the guide to the surgeon in making his incision for the ligature of this artery in its upper part. Its first branch, the superior profunda, winds round the back of the arm with the musculo-spiral nerve at the level of the lowest point of the insertion of

the deltoid. It may be remembered that this point which is at the centre of the shaft of the humerus corresponds to the junction of the cylindrical and prismatic portions of that bone, a favourite site for fractures. A short distance below the insertion of the deltoid the cutaneous branch of the musculo-spiral nerve appears close to the external intermuscular septum. The triceps muscle is the only structure to be studied on the back of the arm; its details can be seen when a living person forcibly extends the forearm on the arm. The flat tendinous surface below with its pointed upper extremity and the two muscular masses, one arising on either side of it, are then brought into view in a well developed subject.

2. **Elbow.** *a. Bony points.*—The two condyles of the humerus should first be studied. The internal is the more prominent, descends lower, and is further from the line of the articulation than the external (more than one inch as compared with three-quarters of an inch). It can easily be grasped by the fingers as it lies under the skin, and the edge of the trochlear portion of the lower end of the humerus will be felt about three-quarters of an inch from its apex. The internal supra-condyloid ridge can only be traced for a short distance above it, but a sharp fibrous band will be felt under the skin, which is the internal intermuscular septum at its lower end. Between the internal condyle and the olecranon is a depression in which lies the ulnar nerve (the “funny-bone” as it is commonly called), the posterior ulnar recurrent and the posterior branch of the inferior pro-

brachial artery. The external condyle is less prominent, more rounded at its extremity, placed higher and nearer to the joint line. It can be distinctly felt, and especially posteriorly, and the external supra-condyloid ridge can be traced upwards from it for about three inches. It may be mentioned here that in about one out of every fifty arms (Struthers) there is a hook-like process of bone, the supra-condyloid process, above the internal condyle, which when present can be distinctly felt. The olecranon process is obvious in all positions of the joint, together with the triangular subcutaneous portion of the ulna which passes down from it and is covered by a bursa. The position of this bony eminence with respect to the condyles should be studied in the various positions of the joint. If the thumb and the next two fingers be placed on the three points respectively and the forearm be moved, this can easily be effected. It will then be found that in extension the three points lie on the same line, in semi-flexion the olecranon is below the condyles, and in extreme flexion it is in front of them. Thus normally the olecranon is never at a higher level than the condyles. The relation of these points to one another is of importance in the diagnosis of fractures and dislocations at or near the elbow joint. If the point of the thumb be pressed deeply under the muscles arising from the external condyle and forming the outer boundary of the triangular area in front of the elbow joint the head of the radius will be felt, and if the fingers be placed at a corresponding point at the back of the arm it may be grasped and felt rotating beneath

them during the movements of pronation and supination. In complete extension a small groove can be distinguished between the head of the radius and the back of the capitellum behind, as the two are not in contact with one another in that position. If the thumb be now shifted a little inwards and deep firm pressure be made, the coronoid process of the ulna will be felt, though not distinctly, especially in a muscular subject. In extreme pronation the tubercle of the radius may be felt behind a short distance below the head of that bone, though again not distinctly in a muscular subject.

b. Soft parts.—In the semi-flexed condition a curved crease passing from one condyle to the other and concave upwards, the “fold of the elbow,” will be first seen. This line does not quite correspond to the articulation but is placed a little above it. The student should next carefully study the position and relations of the large superficial veins, and for this purpose should select a muscular living subject. The vessels may be made prominent, and thus be investigated with greater ease, if a bandage be tied firmly round the arm a few inches above the elbow. It is impossible to adhere closely to regional limitations in this instance, and the veins should therefore be traced up from their origin to the elbow, the student remembering that deviations from the arrangement regarded as normal are very common.

The veins having been made prominent in the manner indicated, the commencement of the first trunk should be sought on the dorsum of the thumb. Above the cleft between the thumb and the index finger this vein is

joined by another coming from the back of the latter digit. The combined trunk passes to the flexor aspect of the fore-arm above the wrist, and runs along its radial border, receiving tributaries from both anterior and posterior surfaces. The veins on the ulnar side commence by tributaries which unite above the cleft between the ring and little fingers to form a trunk, the *vena salvatella*. This vessel runs up the back of the fore-arm turning round to its anterior surface below the elbow, where it is joined by the anterior ulnar vein which takes its course along the ulnar border on the anterior aspect. The median vein which runs up the centre of the anterior surface of the fore-arm is very variable in size and length. Below the ante-cubital fossa it receives a deep tributary which cannot be seen from the surface, and the combined trunk divides into two, the median basilic which passes inwards to join the common ulnar and form the basilic vein, and the median cephalic which, taking the opposite direction, unites with the radial to constitute the cephalic vein. The median basilic lies in front of the brachial artery, the bicipital fascia intervening between the two vessels, and is crossed by twigs of the internal cutaneous nerve. The median cephalic overlies branches of the external cutaneous nerve. The anatomy of these vessels is not surgically of such importance as it was in the not very distant days when phlebotomy was the commonest of minor operations. As this has, however, still sometimes to be performed the parts concerned should be considered in this relation. The median basilic is usually

the larger vessel and affords, therefore, the better supply of blood, but the median cephalic is the safer, because the former, as has been mentioned, is crossed by nervous fibres which being wounded may cause the patient to start, and the operator to plunge his scalpel through the vein into the subjacent artery, the result being the formation of an arterio-venous aneurism.

The muscular masses in front of the elbow enclose a triangular depression, the ante-cubital fossa. On the outer side is the extensor eminence, the inner border of which is formed by the supinator longus. On the inner side is the flexor eminence with the pronator radii teres externally. At the upper part or base the lower end of the bicipital elevation will be seen, and the tendon of that muscle can be seen and felt easily lying near the centre of the fossa. Passing off from the biceps at its upper end and on its inner side is a fibrous expansion the bicipital fascia which crosses and helps to bind down the flexor muscles. When this is fairly well-marked it can be seen in a thin subject during flexion, as it produces a furrow in the flexor mass about two finger breadths below the internal condyle. The student will notice that when the biceps is brought gradually into action, the globular mass which it then forms commences near the elbow, and ascends towards the level of the pectoralis major. If the finger be pressed into the ante-cubital fossa under the inner edge of the tendon of the biceps, the pulsations of the brachial artery will be felt at a point about a finger's breadth below the line of the internal condyle. The student

will feel just below this point, the sharp upper edge of the bicipital fascia preventing him from pushing his finger deeply further down towards the apex of the fossa. He should next place his fingers on his own radial artery, at the point where the "pulse" is felt, and flexing gradually his arm he will feel what an effect is produced upon the blood current by that movement. If he be fairly muscular he will be able to entirely stop the flow of blood in his radial artery, or at least, materially to decrease its volume. This fact is of surgical importance in connection with aneurisms of the brachial artery. The radial recurrent artery passes upwards in the groove between the supinator longus and brachialis anticus to anastomose with the superior profunda. The anterior ulnar recurrent runs on the opposite side between the brachialis anticus and pronator radii teres to anastomose with the inferior profunda and anastomotica. The posterior ulnar recurrent runs upwards to the depression between the internal condyle, and the edge of the trochlea, and the interosseous recurrent takes the same upward course to the interval between the olecranon and the external condyle. The brachial artery itself bifurcates at a point opposite the neck of the radius as a rule, but the student should be on the look out for a high division either of the axillary or brachial trunks, two arteries which may be distinguishable thus existing, a condition which obtains in about one in every five and a half cases. (R. Quain).

In the ante-cubital fossa the median nerve lies first internal to the brachial artery. The musculo-spiral

nerve, not strictly in the fossa, lies between the supinator longus and brachialis anticus and under cover of the former muscle. As already mentioned, the ulnar nerve lies in the depression between the internal condyle and the edge of the trochlea. Over the olecranon lies a bursa which is sometimes enlarged, as a result of some special occupation leading to constant pressure upon it, the disease being known as "miner's elbow."

III. FOREARM AND WRIST.

I. **Bony points.**—The radius can be explored posteriorly throughout its entire length, from its head to its lower end, though less distinctly for some inches below the head than in its lowest part, on account of the muscles which cover it. Externally and anteriorly, its styloid process can be distinctly felt a finger's breadth above the upper border of the ball of the thumb. Passing the finger round the back of the lower end, there will be felt, near its centre, a bony prominence, round which turns the tendon of the extensor secundi internodii pollicis, and still further, towards the ulnar side of the forearm, the groove between the radius and the ulna. Anteriorly, only about the lower half of the radius can be made out, and that not very distinctly. The ulna is also very distinct from the olecranon to the lower end, posteriorly. The rounded prominence of the latter is very obvious to sight and touch at some little distance above the wrist joint; internally and posteriorly, the

styloid process can be felt. The ulna also can only be indistinctly felt on its anterior aspect. The tip of the styloid process of this bone corresponds to the line of the wrist joint, but the styloid process of the radius is placed at a lower level, and corresponds to the scaphoid.

A line drawn from the tip of one styloid process to that of the other would consequently fall below the line of the joint. In order to indicate this it will be necessary to cause the line, joining the two above mentioned points, to form a curve, with its convexity upwards, and half an inch at its farthest point from the straight line alluded to.

2. **Soft parts.** (a) *Muscles.*—A little manipulation along the outer border of the forearm in its lower half will enable the student to feel the tendons of the radial extensors and supinator longus. If the thumb be fully extended, the bellies of the extensores ossis metacarpi and primi internodii pollicis will be seen distinctly as a rounded elevation, crossing the radius in its lower third, downwards, outwards, and forwards; their tendons can be made out close to the lower end of the radius, lying on the bone, and still more distinctly as they pass over the wrist joint. If the fingers of the right hand be laid on the posterior aspect of the left forearm at its lower part, and the left fingers be extended, the tendons of the extensor communis will be felt, and those of the little finger will be distinguished on the ulnar side, if that digit alone be brought into action. Still farther towards the ulnar side, the tendon of the extensor carpi ulnaris may be indistinctly made

out. Anteriorly, commencing at the ulnar side, the tendon of the flexor carpi ulnaris can be grasped as it lies under the skin, when the wrist is semiflexed and adducted. Extend the hand, and the palmaris longus tendon in the centre of the forearm becomes visible in a considerable part of its extent. This muscle is absent once in every ten bodies on the average, and is three times oftener symmetrically absent than asymmetrically (Macalister).

Under this tendon, and on each side of it, the tendons of the flexor sublimis digitorum can be felt by gentle pressure. At their outer border lies the strong, but not very distinctly to be felt, tendon of the flexor carpi radialis, and finally at the radial border, the tendons of the two first extensors of the thumb, as they cross the wrist joint.

(b) *Arteries*.—Just internal to the two last mentioned extensors, the pulsations of the radial artery can be felt against the subjacent radius, this being the position where the “pulse” is generally observed. A line drawn from this point to the outer border of the biceps tendon just below the head of the radius, will indicate the position of the artery. It is fairly superficial throughout, being overlapped above by the inner border of the supinator longus. It is in the line just mentioned that the incisions to tie the artery are made, the edge of the supinator longus and its tendon being the guide to the vessel.

If the wrist be semiflexed to relax the skin, &c., and the fingers be thrust under the tendon of the flexor

carpi ulnaris, the pulsations of the ulnar artery will be felt. A line drawn from this point and curved slightly, so as to be convex inwards, to the same upper point as that given for the radial artery, will indicate the position of the ulnar, which is, however, quite deeply placed in the upper part of the forearm. When it requires to be tied in the upper third of the arm the incision is made along a line drawn from the front of the internal condyle to the outer border of the pisiform, so that the centre of the incision is three fingers' breadth below the internal condyle.

(c) *Nerves*.—The course of the chief nerves of the forearm may be indicated by three lines. That for the median commences just internal to the brachial artery in the antecubital fossa, and is drawn to the centre of the front of the wrist joint, where it lies under, or on the ulnar side of, the tendon of the palmaris longus. The ulnar nerve is indicated by a line drawn from below and in front of the outer part of the internal condyle, to the outer side of the corresponding artery at the wrist. It meets the artery at the apex of its convexity, that is at the junction of the upper and middle thirds of the arm. The radial nerve is indicated by a line drawn from the outer edge of the upper part of the tendon of the biceps, meeting the artery about two inches below the elbow joint. It accompanies the artery to a point three inches above the wrist joint, where it leaves its vessel, passing to the back of the forearm under the tendon of the supinator longus muscle. The cutaneous nerve supply of the forearm, as well as that of the arm and hand,

will be seen from the diagrams (figs. 12 and 13), and the student should accustom himself to map out the parts in correspondence with their nerves.

IV. THE HAND.

1. **Bony points.**—On the radial side of the hand at the upper part of the muscles of the thumb a bony ridge can be made out, which is formed by portions of two bones, the tubercle of the scaphoid above, and the ridge on the trapezium below, but any line of division between the two is hard to distinguish. At the upper part of the hand, on the ulnar border, the pisiform is easily identified, and lower down the process of the unciform may be found, but with less readiness. At the lower end of the metacarpal bone of the thumb, and in front of the metacarpo-phalangeal joint, the two sesamoid bones of that digit can be felt. The lower ends of the metacarpals of the remaining digits can be felt in the palm, but not their proximal extremities, on account of the muscles and other structures lying upon them. On the back of the hand, since there are less soft structures between the skin and the bones, the outlines of the latter can be more distinctly made out. The upper end of the metacarpal bone of the thumb can be readily felt, especially if that digit be extended. The upper ends of the metacarpal bones of the other fingers are not so easy to distinguish, but the ulnar edge of that of the little finger can be felt at the border of

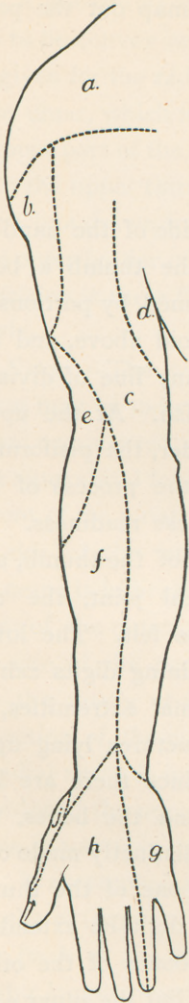


FIG. 12.—Cutaneous Areas Upper Extremity.
Anterior Aspect.

- a.* Supraclavicular (3, 4*c*).
- b.* Circumflex (5, 6*c*).
- c.* Internal cutaneous (8*c*, 1*d*).
- d.* Wrisberg and intercosto-humeral (1, 2*d*).
- e.* Musculo-spiral (up. ext. cut.) (6*e*).
- f.* Musculo-cutaneous (5, 6*c*).
- g.* Ulnar (1*d*).
- h.* Median (6, 7, 8*c*, 1*d*).
- j.* Radial (6).

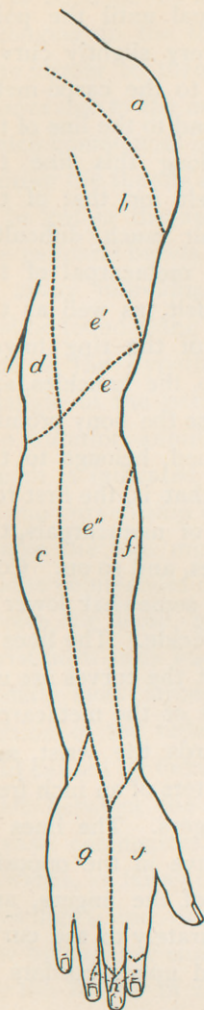


FIG. 13.—Cutaneous Areas Upper Extremity.
Posterior Aspect.

- a.* Supraclavicular (3, 4*c*).
- b.* Circumflex (5, 6*c*).
- c.* Internal cutaneous (8*c*, 1*d*).
- d.* Wrisberg and intercosto-humeral (1, 2*d*).
- e.* Musculo-spiral (int. cut.), (8*c*).
- e''.* Do. (lower ext. cut.), (6, 7, 8*c*), (the upper part of this area is supplied by the upper ext. cut. *e*).
- f.* Musculo-cutaneous (5, 6*c*).
- g.* Ulnar (8*c*).
- h.* Median (6, 7, 8*c*, 1*d*).
- j.* Radial (6, 7*c*).

the hand, if that member be adducted and pressure be made upwards along the metacarpal until the point sought for be reached. A line very slightly curved downwards, drawn from this point to the carpo-metacarpal joint of thumb, will correspond to the line of the carpo-metacarpal articulations. Along this line the articulations in question may be felt for, that of the index being distinguishable without much difficulty. The spur on the upper end of the metacarpal of the middle finger may be indistinctly felt, as well as the base of the corresponding bone of the ring finger. Attention should next be directed to the knuckles, and it will first be noted that in every case the bony prominence to which that name is attached, belongs to the proximal bone of the articulation, that is, the first row of knuckles is formed by the heads of metacarpals, the second by those of the first phalanges, and so on. Consequently the line of articulation is somewhat lower in each case than the corresponding knuckle. The lines of all the articulations are curved, but the curves are not all in the same direction. Those of the metacarpophalangeal joints are concave towards the wrist, and are situated from half to three-quarters of an inch from the free edge of the webs of the fingers. The lines of the remaining articulations are concave in the opposite direction, that is, towards the tips of the fingers, and correspond in their curves fairly accurately to the curve of the skin surrounding the attached upper borders of the nails.

2. **Skin and soft parts.**—The hollow of the palm

is somewhat triangular, with its apex directed upwards. It is bounded by a muscular elevation on either side, belonging to the thumb and little finger respectively. The former or thenar eminence is circumscribed by a groove due to the movement of the thumb in opposition, which commences on the ulnar side of the fold of skin uniting the thumb and index finger, and runs upwards to be lost in the apex of the triangle of the palm. If the palmaris brevis muscle be made to act, as it can be in many individuals, an irregular longitudinal crease will be found along the ulnar border of the hand at the side of the hypothenar eminence. The apex of the triangle of the palm corresponds to the lower border of the anterior annular ligament, the upper margin of which is indicated fairly accurately by the lower point of the curved skin crease, which crosses the wrist just above the two muscular elevations. Another palmar crease commences close to that of the thumb and passes across the hand, gradually approaching nearer to the wrist until it is lost on the hypothenar eminence. Its radial, most strongly marked portion, is due to the flexion of the index, the remainder being a secondary fold caused by flexion of the three inner digits. In the cleft between the index and middle fingers, another crease commences, which runs at first upwards and inwards, as far as the line of the cleft between the next two digits, and then inwards across the lower part of the hypothenar eminence. It is the primary fold caused by the flexion of the three inner digits. The first of these two last mentioned folds, as it crosses the third

metacarpal bone, corresponds to the lowest point of the superficial palmar arch. Its highest point may be indicated by a line drawn from the ulnar side of the commissure of the thumb, when that digit is extended transversely across the palm. The digital branches arise from this arch opposite the clefts of the fingers, bifurcate half an inch below the webs of the fingers, and run along the borders of the digits on their palmar surfaces, where their pulsations may distinctly be felt. The deep palmar arch lies about half an inch nearer the wrist than the superficial. The second crease crosses the necks of the metacarpal bones, and corresponds also pretty nearly to the upper limits of the synovial sheaths of the flexor tendons of the three inner digits, and to the point where the palmar fascia divides into its terminal slips. The folds at the joints of the fingers should next be examined. Those over the metacarpo-phalangeal articulations of the index and minimus are single, those of the other two digits double. Each is placed about three-quarters of an inch below the joint to which it corresponds. The creases over the first row of interphalangeal articulations are double in each case, and the line of the joint lies between the two. Those of the second interphalangeal articulations are single, and lie a very little above the corresponding joints. The thumb is crossed above and external to the thenar eminence by two oblique lines; the lower of these, which commences nearly at the radial side of the commissure, crosses the metacarpo-phalangeal articulation. The line of articulation in the case of each of the

joints is more distinct dorsally than on the palmar surface, on account of the flexor tendons, and especially of the so-called glenoid ligaments, which lie between these tendons and the articulations. The flexor tendons of the fingers can be indistinctly felt on the anterior surfaces of the fingers, and the long flexor of the thumb may be distinguished by pressing the finger under the ulnar border of the thenar eminence at its lower end, and extending the thumb. The superficialis volæ artery, when large enough, can be felt pulsating on the thenar eminence. The student will notice that there is no great amount of mobility between the skin in the palm of the hand and the subjacent tissues, a fact which is due to the connection of the former with the palmar fascia. A similar condition obtains at the pulps of the fingers, which is here due to the cutaneo-phalangeal ligaments of Cleland, which pass from the bone to the skin. The result of this immobility of the skin is to give a firmer grasp than would be afforded if the skin glided easily upon the subcutaneous tissues.

On the dorsum of the hand, at the radial side, will be seen, if the thumb be extended, a triangular hollow, "Cloquet's snuff-box," which is bounded radially by the tendons of the two first extensor muscles of the thumb, and on its ulnar side by that of the second internode. In its roof lies the vein which forms the origin of the radial vein of the arm. The base of the metacarpal bone of the thumb lies at its lower part, and the radial artery can be felt pulsating within it. Deeper still lie the scaphoid and trapezium. The princeps pollicis

artery can be felt pulsating in the thumb just below the radial end of the commissure, and the princeps indicis in its digit below the ulnar end of the same. Numerous veins are visible on the dorsum of the hand, passing upwards to form the radial or the posterior ulnar trunks. On the radial side of the index the prominence of the first dorsal interosseous muscle or abductor indicis is very distinct. The extensor tendons of the fingers can be seen and felt, and if the fingers be fully flexed, the lateral slips, passing from that for the ring finger, to those of the adjacent digits, can also be observed.

CHAPTER IX.

THE LOWER EXTREMITY.

I. THE BUTTOCK.

1. **Bony points.**—The crest of the ilium, which forms the upper boundary of this region, can be felt easily in its entire extent. At its posterior extremity its posterior superior spine will be encountered, lying at the level of the second sacral spine, and corresponding to the centre of the sacro-iliac synchondrosis. The spines of the sacral vertebræ lie in the middle line, and below them the tubercles of the last two sacral vertebræ. Just below the last of these, and practically undistinguishable from them, are the cornua of the first bone of the coccyx, the highest point of which process corresponds to the spine of the ischium. The upper border of the great sciatic notch is about on a level with the third sacral spine. The tip of the coccyx can be felt just behind the rectum, and can be grasped between the fingers, if one be inserted into that tube and the other placed on the surface opposite to it. It will be found to be mobile in many women and some men. The great trochanter is easily distinguished, even in fat persons, in whom its position is indicated by a small pit in the soft parts. Its apex corresponds with a point a little

above the centre of the hip-joint in old persons; in younger individuals, since the neck of the femur makes a larger angle with the shaft, it is placed a little lower down. It is covered by the fascial insertion of the gluteus maximus, between which and the bone lies a large and important bursa.

The tuberosity of the ischium can also be readily felt, especially in the sitting posture, when it comes from under cover of the gluteus maximus, and forms with its fellow of the opposite side the main support of the body. It is also covered by a bursa, which is one of three in the body especially liable to inflammation and enlargement, as a result of occupation. The disease commonly known as "Drayman's bottom" is due to this enlargement. In connection with certain of the bony points just mentioned, two methods have been adopted of determining the position of the trochanter in relation to injuries at the hips. The first of these is known as "Nélaton's line." This is a line drawn from the anterior superior spine of the ilium to the most prominent portion of the tuber ischii of the same side. It crosses the acetabulum near or above its centre, and just strikes the apex of the great trochanter. In dislocations at the hip, the apex of the trochanter will be either above or below this line. The second method of determining the position of the trochanter is known as "Bryant's ilio-femoral triangle." This is constructed by placing the subject in the recumbent position, and drawing a vertical line from the anterior superior spine of the ilium. A second is drawn from the same point to the

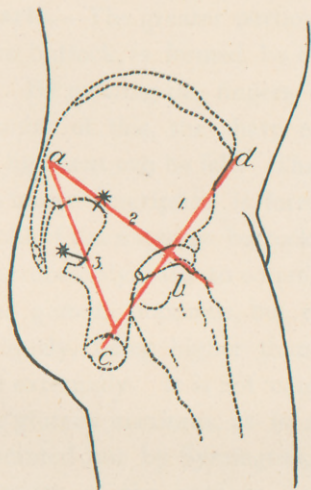


FIG. 14.--Diagram of side of Buttock. *a*. Post. Sup. Spine of Ilium; *b*. Great Trochanter; *c*. Tuber Ischii; *d*. Ant. Sup. Spine of Ilium.

1. Nélaton's line. 2. Line to find Gluteal Artery. 3. Line to find Sciatic Artery. (The pointer from the star in each case indicates the position of the artery).

apex of the great trochanter, and the third completes the triangle, and is drawn at right angles to the first line. The measurements must be made on both sides, when any increase or decrease of the third or test line on the affected as compared with the normal side can be ascertained.

2. **Soft parts.**—The greater portion of the rounded contour of the buttock is formed by the gluteus maximus muscle. By pushing the fingers upwards beneath the lower border of this, the sharp edge of the great sacro-sciatic ligament can be felt. The lower boundary of the region under description is formed by a distinct crease, the fold of the nates or buttock. This is commonly, but erroneously, said to correspond to the lower margin of the gluteus maximus, but this really crosses the fold obliquely, being higher than it mesially, and lower than it externally. It is not caused by the lower border of the gluteus maximus, as is also often stated, but as was pointed out by Symington, it is largely due to the tuberosity of the ischium, being always best marked where it passes outwards beneath that prominence. The skin is placed on the stretch in flexion of the thigh, and is relaxed during its extension, a fold thus being formed. The position of the arteries of the buttock can be found by means of lines described by Lizar. The first of these is drawn from the posterior superior spine of the ilium to the apex of the great trochanter, the thigh being rotated inwards. The point of junction of the inner and middle thirds of this line indicates the position at which the gluteal artery emerges

from the upper part of the great sciatic foramen. The second line is drawn from the posterior superior spine of the ilium to the outer part of the tuber ischii. Two inches below its upper extremity the line crosses the posterior inferior spine of the ilium, and four inches below the same point, the spine of the ischium. The sciatic artery emerges from the great sciatic foramen, at a point corresponding to the junction of the middle and lower thirds of the line. The pudic artery is, of course, external to the pelvis, as it crosses the spine of the ischium on its way from the greater to the lesser sciatic foramen.

If a line be drawn from the point at which the sciatic artery emerges from the foramen downwards, so as to lie midway between the great trochanter and the tuber ischii, it will correspond to the position of the great sciatic nerve.

The long or inferior pudendal nerve crosses the bone a short distance in front of the tuber ischii, and then curves round into the perineum, to be distributed to the posterior and under surface of the scrotum. The effects of pressure upon this nerve may often be felt in the sensation of "pins and needles" in this region, after long sitting upon a hard surface.

II. THE THIGH.

The anterior superior spine of the ilium and the spine of the pubes, both of which prominences have been

already alluded to, are the most important bony points in this region. The former is taken as the point from which measurements of the lower extremity are made, and the latter, which is at the same level as the apex of the great trochanter, is an important factor in the diagnosis between inguinal and femoral herniæ. If the two points just mentioned, and the most prominent part of the tuberosity of the ischium, be marked out, the acetabulum will lie about midway between them. Poupart's ligament, stretching in a line curved downwards between the anterior superior spine of the ilium and the spine of the pubes, is easily to be distinguished. The inner inch corresponds to the extent of Gimbernat's ligament.

Crossing the upper part of the thigh, a second line, described by Holden, and usually named after that surgeon, may in many cases be seen, especially if the limb be slightly flexed. It "begins at the angle between the scrotum and the thigh, passes outwards, and is gradually lost between the top of the trochanter and the anterior superior spine of the ilium." When present it runs across the front of the capsule of the hip-joint. The sartorius and adductor longus should be made out as they form the boundaries of Scarpa's triangle. The former is brought into action when the thigh is flexed and adducted, and the latter in abduction, its sharp internal edge, leading to the spine of the pubes, being very easily distinguished.

The femoral artery passes under Poupart's ligament at a point midway between the spine of the pubes and

the anterior superior spine of the ilium, where its pulsations may very distinctly be felt. If a line be drawn from this point to the tubercle for the adductor magnus on the inner condyle of the knee, its upper two-thirds will overlie the artery. The common femoral divides into its superficial and deeper portions about an inch and a half or more below Poupart's ligament. In the upper third of the thigh the common and superficial femoral arteries lie in Scarpa's triangle, and are superficial; below this point they have a deeper position. Pressure should be applied to the femoral in order to check its current, backwards and slightly upwards, below Poupart's ligament, the patient being in the recumbent position. At the apex of Scarpa's triangle, pressure should be applied outwards, as the artery is here on the inner side of the femur.

The femoral vein below Poupart's ligament lies internal to its artery, and has on its other side the femoral ring and crural canal. The former lies an inch out from the pubic spine, on a line drawn from that eminence to the apex of the great trochanter. It may also be found by ascertaining the position of the femoral artery by its pulsations, and allowing half an inch on its inner side for the vein. It is through this aperture that a femoral hernia escapes from the abdomen; in the crural canal, along the inner side of the vein, lie the deep set of femoral glands. The saphenous opening is placed just below Poupart's ligament, and its centre is about an inch and a half below and external to the spine of the pubes. The most important structure, surgically

speaking, which passes through it, is the long saphenous vein, which will be dealt with further on. This vessel may sometimes be seen in thin individuals, the position of the saphenous opening itself being at times indicated by a dimpling of the skin. Two sets of superficial lymphatic glands lie at the upper part of the thigh, one horizontal and in a line with Poupart's ligament, the other vertical and parallel to the femoral artery. The sources of the various lymph streams which enter these are of some importance, and are thus described in Mr. Treves' *Surgical Anatomy*.

Superficial vessels of lower limb = vertical set.

Superficial vessels of lower half of abdomen = middle glands of horizontal set.

Superficial vessels of outer surface of buttock = external glands of horizontal set.

Vessels of inner surface of buttock = internal glands of horizontal set. (A few of these vessels go to the vertical glands).

Superficial vessels from external genitals = horizontal glands, and a few to vertical.

Superficial vessels of perineum = vertical set.

These glands can sometimes be felt beneath the skin, especially in thin children.

Externally to the femoral artery lies the anterior crural nerve, and under it and the artery, and also external to both, is the ilio-psoas muscle, forming part of the floor of Scarpa's triangle. This muscle overlies the front of the capsule of the hip-joint, a large bursa intervening.

The chief remaining objects worthy of note in the thigh are the muscular markings, of which, besides those which have already been alluded to, the following may be observed. The tensor vaginae femoris forms an elevation directed downwards and backwards, and commencing at the anterior superior spine of the ilium, immediately behind the sartorius. Below it is inserted into the fascia lata, which in extension of the hip and knee will be noticed to be particularly tense and resistant on the outer side of the thigh. A specialised band of this fascia, called the ilio-tibial band, may be looked upon as the tendon of insertion of the muscle in question; it extends down to the outer part of the head of the tibia, and may be distinctly felt above the knee-joint, when the muscle is placed upon the stretch. The rectus femoris forms the median prominence of the quadriceps and about four inches above the knee-joint it joins a triangular tendon, which passes downwards to be attached to the patella. The outline of this tendon stands out very distinctly in a muscular individual when the knee is fully extended. In the same position the two vasti muscles are brought into prominence. The lower fibres of the inner descend as low as the inner border of the patella, those of the outer not descending so far by an inch or more. A groove between the inner vastus and the adductor muscles marks the position of the lower portion of the sartorius and the subjacent Hunter's canal. A similar groove on the outer side of the thigh marks the position of the external intermuscular septum, the line of demarcation between the vastus externus and the hamstring muscles.

III. THE KNEE.

The first object which the student should examine is the patella, and he can, with advantage, in this as in other parts of the body, carry out his observations upon himself. In order to examine this bone the leg should be placed in the extended position, the heel resting upon the ground so as to fully relax the muscles and other structures. Its shape can then be fully investigated, and the fingers can even be pushed a little underneath, so as to feel a small part of the posterior surface. It will be noticed that the patella can be moved freely in different directions, gliding easily over the smooth trochlear surface of the femur.

In the same position of the extremity, the whole of the outer border and a part of the upper limit and anterior surface of the articular surface of the external condyle can be felt. In semi-flexion the articular surface of the internal condyle becomes more easy of investigation, when its inner border and a part of its anterior surface can be felt. In extreme flexion the greater part of the anterior surface comes under observation, but not very distinctly, on account of the tension of the skin. Below the patella, and stretching between it and the tubercle of the tibia, is the ligamentum patellæ, which should be studied in the different positions of the joint. If the forefingers of both hands be pushed under the ligament on opposite sides, and alternate pressure be made, a feeling like fluctuation is obtained. This is due to the

presence, in that position, of a large pad of fat, lying between the ligament and the subjacent bone, and should not be mistaken for the presence of fluid. In front of the patella and a portion of its ligament, is a large bursa, the prepatellar bursa, which like some others is liable to be enlarged in certain occupations. In the case of the bursa in question, constant kneeling has this effect, and the condition is known as "Housemaid's knee." It may be noted that the ligamentum patellæ, the tubercle of the tibia, and the centre of the ankle joint, are all normally in the same straight line. The student should now carefully follow the movements of the patella, and its position in the varying conditions of the joint. He will observe that in extension this bone lies nearly altogether above the articular surface of the femur, its two inferior facets being then in contact with the upper part of the articular portions of the two condyles. In semi-flexion the positions of the bones alter so that the patella, resting on its two central facets, lies in contact with a lower part of the condyles. In greater flexion it rests on its two superior facets. Finally, in extreme flexion, the patella passes almost from off the internal condyle, being turned outwards partly by the increasing prominence of the inner condyle, and partly by the slightly oblique plane, in which the tibia is moved inwards in flexion. It then rests only on its internal narrow facet, which is in contact with the outer border of the inner condyle. Here, as in the other joints of the body, the student should not be content with a dissection of the dead subject, but should take frequent oppor-

tunity to examine the bony parts and other structures in all the various positions of the joints in himself and others. He will find much assistance in this study in the descriptions of the mechanism of the articulations in Mr. Morris' work on the *Anatomy of the Joints*.

The inner condyle of the femur, on its inner side, presents as its most prominent structure the tubercle for the attachment of the adductor magnus, the tendon of which muscle can be felt above the projection. The inner aspect of this condyle points nearly in the same direction as the head of the femur. At its lower border the interarticular line between the femur and the tibia can be readily felt. The external lateral ligament can be distinguished on the outer side, passing down to the head of the fibula.

The synovial membrane of the knee joint is more extensive than that of any articulation in the body, and reaches upwards in the extended condition of the limb for two inches or more above the patella. In flexion it sinks considerably, so that in operations about the lower end of the femur there is less danger of opening up the cavity of the knee joint if this position of the limb be adopted.

IV. POPLITEAL SPACE.

The student should first note that the shape of the space varies according to the position of the joint, being flattened out in extension, but hollowed in flexion. Commencing at the outer side, the tendon of the biceps

will be felt behind the external lateral ligament. In extension these two structures lie so close to one another that it is somewhat difficult to identify them separately. But if the knee be semi-flexed, the latter will be felt as a distinct rounded cord, whilst the former can be easily grasped beneath the skin. Anterior to the biceps tendon, between it and the ilio-tibial band of fascia, there is a depression, where, in consequence of the absence of large arteries, incisions can be made for surgical purposes. If the fingers be pushed under the inner border of the biceps tendon, a cord-like structure, which is the external popliteal nerve, will be felt. On the inner side of the knee three tendons are to be made out, and may be most easily studied in semi-flexion, with the foot on the ground so as to relax the tissues. The most external and most prominent of these is the semi-tendinosus. Internal to this is what at first appears to be a single tendon, but by a little manipulation the point of the finger can be made to sink into the interval between the semi-membranosus, with its thick rounded border, externally and the gracilis internally.

At the lower part of the space is the angular interval between the two heads of the gastrocnemius. Between the inner head of this muscle and the tendon of the semi-membranosus is a large bursa, often called the popliteal bursa, though there are several others in that region. In one subject out of every five, according to Holden, this bursa communicates with the cavity of the knee-joint. The popliteal artery in the upper part of the spaces lies to the inner side, under cover of the

semi-membranosus. Emerging from under this muscle the artery passes downwards in the centre of the space, terminating opposite the lower part of the tubercle of the tibia. The pulsations of the artery can be felt, and its current checked by compression against the femur in the flexed condition.

The internal popliteal nerve is in the direct continuation of the line of the great sciatic, and lies in the centre of the space.

The lymphatic glands of the space cannot be felt in the normal condition, but when enlarged they are to be made out, and should be remembered, as they may form important factors in coming to a diagnosis in certain surgical conditions.

V. THE LEG.

The tubercle and external and internal tuberosities of the tibia are all prominent at its upper extremity, and the large flat anterior subcutaneous surface, which forms the shin, can be traced downwards to the internal malleolus. Its sharp outer border should be felt, and the irregularity of its edge noted. The head of the fibula, with a small part of the shaft below, and the attachments of the external lateral ligament of the knee and the biceps tendon, will be found at the outer side. In the greater part of the leg this bone is hidden beneath masses of muscle, but in the lower third it can be felt again, and becomes subcutaneous over a triangular

area above the external malleolus. This triangular area lies between the peronei behind, and the extensors in front.

After the bony points have been fixed the muscular prominences should be studied. The prominence of the calf is mainly formed, so far as is visible from the surface, by the gastrocnemius, the strong tendon of which can be seen passing down to help to form the tendo Achillis, behind and above the heel. If the muscles of the back be caused to contract, as when the weight of the body rests on the toes and anterior part of the feet, the heels being raised from the ground, the outline of the soleus can be seen on either side of the upper part of the tendon, but more distinctly on the outer side of the leg, where it is less overlapped by the gastrocnemius. Anteriorly, starting from the outer border of the tibia, there can be felt and seen, when in action, first the tibialis anticus, next, and separated from the former by a groove, the extensor communis digitorum, a much narrower muscular mass, and finally the peronei. In the lower part of the leg the tibialis anticus and extensor communis digitorum separate from one another, and here the extensor proprius hallucis can be felt.

The popliteal artery, as has already been mentioned, bifurcates at a point opposite to the lower border of the tubercle of the tibia. Its posterior tibial branch is indicated by a line drawn from the point of meeting of the two heads of the gastrocnemius, to a point midway between the posterior part of the os calcis and the inner malleolus. At its lower part the artery is superficial,

and can be felt pulsating by the side of the tendo Achillis, but above it is deeply placed. In the upper part of the leg, it is reached, for purposes of ligation, by two methods. In the first the incision is made along the inner border of the tibia, and half an inch behind it, the vessel being thus reached from the side. In the second, which is called Guthrie's or the military operation, and is comparatively seldom performed, the incision is made in the centre of the calf, the two halves of the gastrocnemius being subsequently separated, and the artery approached directly from behind.

The peroneal branch of the posterior tibial runs along the inner margin of the fibula, on its posterior aspect. The incision to reach it is made along the posterior line of that bone, and rather above its centre.

The anterior tibial artery may be indicated by a line drawn from a point midway between the heads of the tibia and fibula, to a point over the centre of the front of the ankle. The groove, already alluded to, between the tibialis anticus and extensor communis digitorum, is a good guide to this vessel.

The veins of the leg are of great importance on account of the tendency, which for various reasons they possess, of becoming varicosed. The short or external saphenous vein in normal condition cannot always be seen. It is formed by branches which arise on the outer side of the dorsum of the foot. The trunk when constituted passes behind the external malleolus, runs along the border of the tendo Achillis, lies in the mesial line of the gastrocnemius, and enters the popliteal vein

in the popliteal space. The short saphenous nerve lies close to this vein. The internal or long saphenous vein is commonly visible even in the normal condition. It commences by radicles on the dorsum of the foot, passes upwards in front of the internal malleolus, and runs along the inner border of the tibia to the internal condyle of the knee. Here it lies close to the bone, and its current is liable to be arrested by pressure, such as is applied by tight garters or knickerbocker bands. From this point it ascends along the inner and anterior aspect of the thigh, passing through the saphenous opening into the femoral vein. As far as the knee it is accompanied by the internal saphenous nerve, which above this point lies under cover of the sartorius.

These veins become very visible after prolonged standing or exercise in the upright posture, and particularly if pressure has been applied to the longer of the two at the point mentioned above.

VI. THE ANKLE.

The two malleoli are very important bony landmarks in relation to this joint, and they present several points of contrast. The external in the first place descends half an inch lower than the internal, so that whilst the line of the ankle joint is about half an inch above the latter, it is an inch above the former. Secondly, the external is rather less prominent than the internal. Thirdly, the external is placed half an inch further back than the

internal, and finally the latter is considerably broader than the former, so that whilst its anterior border is so far in front of its fibular companion, the posterior borders of the two projections are on the same line. Owing to the numerous tendons which pass over the front of the ankle joint, it is rather difficult to feel any of the superior articular surface of the astragalus, but in semi-extension a small portion may be distinguished in front of the external malleolus, and outside the tendon of the peroneus tertius.

The student will notice, in looking at the bones of the foot, that the posterior portion of the superior articular surface of the astragalus is somewhat narrower than the anterior. In the ordinary position of the foot no movements are possible but those of flexion and extension. In the position of extreme extension the narrower part of the superior articular surface of the astragalus lies between the malleoli, and it is stated that at this point a very slight amount of lateral movement is possible. Theoretically, this doubtless is true, but the student by grasping the lower end of the leg with one hand, and the astragalus with the other, the foot being in the position indicated, will be able to satisfy himself that such movement in a muscular living subject is practically non-existent.

A large number of tendons which lie around the ankle joint, and materially contribute to its strength, should next be studied. Posteriorly, the tendo Achillis stands out as the most prominent structure in the region under consideration. Anteriorly, commencing at the tibial side

and passing to the fibular, the tendons of the tibialis anticus, extensor proprius hallucis, extensor longus digitorum and peroneus tertius, will be felt in the order mentioned. The best position in which to examine them is that of flexion.

The tendons of the peroneus longus and brevis lie immediately behind the external malleolus, but are indistinguishable as separate structures in this position. Behind the internal malleolus lie, from before backwards the tendons of the tibialis posticus, flexor longus digitorum, and flexor longus hallucis. The first named can be easily seen and felt, but it is impossible to make the other two out with any distinctness.

The anterior tibial artery with its nerve lies on the front of the joint, the latter being external, between the tendons of the extensores longus digitorum and proprius hallucis, and its pulsations can here be felt as it lies upon the lower end of the tibia.

The posterior tibial artery with its nerve, the latter being external, lies behind the internal malleolus, between the tendons of the flexores longus digitorum and longus hallucis, and can here be felt pulsating. The incision to tie the vessel in this position is made in the middle line between the posterior border of the tibia and the tendo Achillis, and parallel to the former.

As the last point in connection with the study of the ankle and foot, the student should consider the relation of the parts to the various amputations practised in that region. The line of each of these will consequently be mentioned here, the reader being referred for the details

of each operation to any of the text-books on operative surgery.

Syme's amputation, which is the one generally performed in the position under consideration, consists in removing the foot at the ankle joint, and subsequently sawing off the malleoli with the lower articular surface of the tibia. The two malleoli are the bony guides to the line of the joint in this operation, and consequently their relations to it, as given above, should be carefully borne in mind. In Pirogoff's operation the os calcis is sawn through, the posterior portion being retained in the flap.

VII. THE FOOT.

1. **Bony points.**—Along either border of the foot are certain bony prominences, the practical bearing of which will appear when the operations in which they are concerned are described; these points should first be identified.

Commencing posteriorly, there will be felt, along the outer border of the foot, first the external tuberosity of the os calcis, secondly, about an inch below the point of the external malleolus, the peroneal tubercle of the os calcis, thirdly, the spur on the outer side of the base of the fifth metatarsal bone, and finally the head of the same and the base of the adjacent phalanx.

Along the inner border from behind forwards are:—first, the internal tuberosity of the os calcis; secondly, about an inch below the internal malleolus, the edge of

the sustentaculum tali; thirdly, the tubercle of the scaphoid; fourthly, the internal cuneiform bone; fifthly, the base of the fifth metatarsal, and finally the head of the same bone with its sesamoid bones on its inferior surface. Two amputations only need be mentioned through various parts of the foot to show the practical bearing of these points.

Lisfranc's operation consists in an amputation through the tarso-metatarsal line of articulations. The line

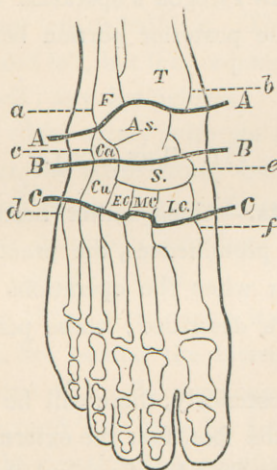


FIG. 15.—Diagram of Foot showing Bony Prominences and Lines of Operation (after Smith and Walsham).

T. Tibia. F. Fibula. As. Astragalus. Ca. Os calcis. Cu. Cuboid. S. Scaphoid. E. C., M. C., I. C. External, middle and internal cuneiform bones. *a, b.* External and internal malleoli. *c.* Peroneal tubercle. *d.* Spur of fifth metatarsal. *e.* Tubercle of scaphoid. *f.* Base of first metatarsal.

AA. Line of Syme's amputation.

BB. Line of Chopart's amputation.

CC. Line of Lisfranc's amputation.

of these joints is somewhat irregular, a fact which is chiefly due to the unequal lengths of the three cuneiform bones, but, speaking generally, extends across the foot in a slight curve, with its convexity directed downward, from the base of the fifth metatarsal to that of the first. If, therefore, the student grasps between his fore-finger and thumb the bases of these bones he will have the tarso-metatarsal line immediately behind them. Should he have any difficulty in finding the base of the first metatarsal he may remember that it is placed one and a half inches in front of the scaphoid tubercle, a prominence which is always recognizable.

Chopart's amputation passes through the mediotarsal joint, between the astragalus and scaphoid, and calcis and cuboid. The guide to the line between the first two bones is the tubercle of the latter. The line of the calcaneo-cuboid articulation lies midway between the external malleolus and the spur on the base of the fifth metatarsal bone.

2. **Soft parts.**—On the dorsum of the foot the numerous tendons will first claim the attention of the student. Commencing at the inner side, the strong tendon of the tibialis anticus will be seen passing downwards, and next to it that of the extensor proprius hallucis, the most prominent of all. Then, still further out will be seen the four tendons of the extensor longus digitorum passing obliquely across the foot from within outwards, with the tendon of the peroneus tertius lying to the outer side of the tendon for the fifth toe. Externally to this if the toes be extended, a rounded mus-

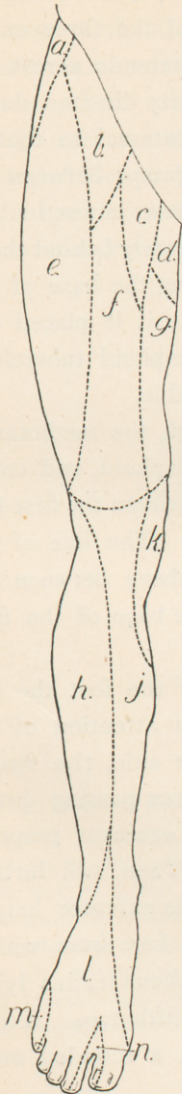


FIG. 16.—Cutaneous Nerve Areas,
Lower Extremity. Anterior Aspect.

- a.* Ilio-hypogastric (L, 1).
- b.* Genito-crural (L, 1, 2).
- c.* Ilio-inguinal (L, 1).
- d.* Small sciatic (S, 1, 2, 3).
- e.* External cutaneous (L, 2, 3).
- f.* Middle cutaneous (L, 2, 3).
- g.* Internal cutaneous (L, 2, 3).
- h.* Peroneal cutaneous (L. 5, S. 1, 2).
- j.* Internal saphenous (L. 3, 4).
- k.* Internal cutaneous and obturator
(L. 2, 3, 4).
- l.* Musculo-cutaneous (L. 4, 5, S. 1).
- m.* External saphenous (S. 1, 2).
- n.* Anterior tibial (L. 4, 5, S. 1).

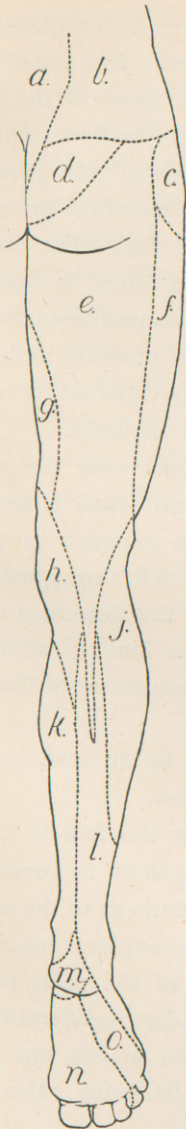


FIG. 17.—Cutaneous Nerve Areas,
Lower Extremity. Posterior Aspect.

- a.* Posterior sacral.
- b.* Posterior lumbar (L. 1, 2, 3).
- c.* Ilio-hypogastric (L. 1).
- d.* Perforating cutaneous (S. 2, 3).
- e.* Small sciatic (S. 1, 2, 3).
- f.* External cutaneous (L. 2, 3).
- g.* Internal cutaneous (L. 2, 3).
- h.* Do. and obturator (L. 2, 3, 4).
- j.* Peroneal cutaneous (L. 5, S. 1, 2).
- k.* Internal saphenous (L. 3, 4).
- l.* External saphenous (S. 1, 2).
- m.* Calcaneo-plantar (S. 1, 2).
- n.* Internal plantar (L. 4, 5, S. 1).
- o.* External plantar (S. 1, 2).

cular elevation the belly of the extensor brevis digitorum can be seen and felt lying on the front and outer side of the foot. Its tendons pass under those of the long extensors in an opposite direction, that is from without inwards, and may be seen sometimes in thin persons. On the outer side of the foot the tendons of the peroneus longus and brevis can be seen and felt. The former lies behind the peroneal tubercle, the latter in front of it. The tendons of the inner side cannot be made out distinctly, though that of the tibialis posticus with the calcaneo-scaphoid ligament lies in the interval between the malleolus and the tubercle of the scaphoid.

The dorsal artery of the foot passes over the ankle joint, and runs to the first metatarsal space along the outer border of the tendon of the extensor proprius hallucis, where its pulsations may be felt throughout its entire course. Under the skin over the dorsum a number of veins will be seen, forming a kind of arch, the extremities of which form the commencement of the two saphenous veins.

The metatarso-phalangeal joints lie an inch behind the skin commissures between the toes.

The skin on the plantar surface of the foot is firmly adherent to the subjacent structures, so as to permit of very little mobility. The remarks made as to the use of this arrangement, and the anatomical explanation of the same in connection with the skin of the palm of the hand, will apply also to that now under consideration.

The plantar arteries cannot be seen or felt, but their position may be marked out by the following rules:—A

point should be taken midway between the tip of the internal malleolus and the most prominent point of the plantar surface of the heel. A line drawn from this point to the middle of the plantar surface of the great toe indicates the position of the internal plantar artery.

A line drawn from the first named point to another one inch internal to the outer border of the base of the fifth metatarsal bone will indicate that portion of the external plantar artery which runs longitudinally. From this point it turns and runs across the bases of the metatarsal bones to the first interspace.

Before leaving the lower extremity the student should, as in the case of the upper, map out the areas of the subcutaneous nerves as given in the figures.

INDEX.

- Acromion, 90
Angular gyrus, 38
 processes, 2
Angulus Ludovici, 52
Ante-cubital fossa, 99
Anus, 77
Apex-beat, 60
Artery, aorta, 62
 abdominal and
 branches, 73
 thoracic, 84
 axillary and branches, 93
 brachial and branches, 94,
 99
 carotid, common, 46, 47,
 63
 external, 47
 crico-thyroid, 43
 dorsalis pedis, 136
 epigastric, deep, 74
 facial, 6, 48
 transverse, 7
 femoral, 117, 118
 gluteal, 115
 iliac, 74
 innominate, 46, 63
 lingual, 48
 mammary internal, 64
 meningeal, middle, 31
 occipital, 27, 48
 of elbow, 99
 palmar arch, 110
- Artery, plantar, 136
 popliteal, 126
 posterior auricular, 27
 palatine, 23
 princeps pollicis, 111
 pudic, 116
 radial, 103
 sciatic, 116
 subclavian, 46, 49
 superficialis volæ, 111
 superficial temporal, 7
 superior thyroid, 48
 supra-orbital, 7
 thyroidea ima, 44
 tibial anterior, 127, 130
 posterior, 126, 130
 transverse cervical, 50
 ulnar, 104
- Ary-epiglottic folds, 22
Asterion, 29
Asymmetry of face, 11
Atlas, transverse process of, 150
Auricle, left, 60
 right, 59
Axilla, 92
- Bicipital fascia, 100
Bladder, 73
Bones of hand, 105, 108
Brachial plexus, 50
Brain, base of, 33

- Breast, 55
 Bregma, 29
 Bryant's ilio-femoral triangle, 114
 Buccal pellet, 5
- Carotid tubercle, 48
 Carpo - metacarpal articulations, 108
 Caruncula lachrymalis, 14
 Catheter, passage of Eustachian, 17
 female, 81
 male, 75
 Chopart's amputation, 133
 Clavicle, 90
 Clitoris, 80
 Cloquet's snuff-box, 111
 Coccyx, 113
 Colon, 87
 Coraco-acromial ligament, 92
 brachialis muscle, 92
 Coracoid process, 91
 Coronal suture, 30
 Creases on hand, 109, 110
 Cricoid, 22, 43
 Crico-thyroid membrane, 43
 Crural canal, 118
 Cutaneo-phalangeal ligaments, 111
- Deltoid muscle, 56, 91
 Diaphragm, 64
 Douglas' pouch, 82
 Drayman's bottom, 114
- Ear, external, 18
 Epiglottis, 22
 Eustachian tube, 17
 External occipital protuberance, 28
- Eyeball, 14
 tension of, 14
 Eyelids, 12
 eversion of, 13
- Falx cerebelli, 30
 cerebri, 30
 Femur, condyles of, 123
 Fibula, 125
 Filtrum, 6
 Fissures of brain,
 longitudinal, 35
 parieto-occipital, 34, 37
 Rolando, 34, 37
 Sylvius, 34, 36
 transverse, 36
- Fontanelles, 32
 Foot, bony points of, 131
 tendons, 133
 Fossa navicularis, 75
 Frænum labii, 21
 linguæ, 23
 Frontal eminence, 1
 lobes and fissures, 37
- Genio-hyo-glossus muscle, 23
 Gimbernat's ligament, 117
 Glabella, 2
 Glands of Tyson, 76
 Glenoid fossa (scapular), 91
 Glosso-epiglottic fold, 22
- Heart, relation to chest wall, 59
 Hernia, 66
 Hesselbach's triangle, 74
 Holden's line, 117
 Housemaid's knee, 122
 Houston's valves, 78
 Humerus, condyles, 95

- Humerus, head, 91
 tuberosities, 90
 Hunter's canal, 120
 Hymen, 81
 Hyoid bone, 22, 42
 space, 22
- Ilium, anterior superior spine, 65,
 116
 crest, 65, 113
 posterior superior spine, 113
 Incisura cardiaca, 58
 Inferior maxilla, 4
 Infra-orbital foramen, 2
 sternal depression, 53
 Inion, 30
 Intestines, 72
 Intra-parietal fissure, 40
 Ischial tuberosity, 117
- Jaw, lower, 4
- Kidney, 86
 Knee joint, synovial membrane,
 123
- Labia majora, 80
 Lachrymal sac, 14
 Lambda, 29
 Lambdoid suture, 30
 Lateral sinus, 31
 Latham's circle, 60
 Ligamentum patellæ, 121
 Linea alba, 66
 oculo-zygomatice, 6
 semilunaris, 66
 Lineæ transversæ, 66
 Lisfranc's amputation, 132
- Lithotomy, 79
 Liver, 70
 Lizar's lines, 115
 Lung, in neck, 50
 relation to chest wall, 56,
 84
 Lymphatics of groin, 119
- McBurney's point, 72
 Macewen's triangle, 20
 Malleoli, 128
 Mastoid process, 19, 28
 Meibomian glands, 13
 Mental foramen, 3
 Metacarpo-phalangeal articula-
 tions, 108
 Miner's elbow, 101
 Mons veneris, 65
 Murmurs, cardiac, 62
 Muscles of calf, 126
 forearm, 99, 102
 thigh, 120
- Nasion, 30
 Naso-labial fold, 6
 Nates, folds of, 115
 Nélaton's line, 114
 Nerves, anterior crural, 119
 buccal, 24
 circumflex, 93
 facial, 9
 great auricular, 51
 gustatory, 24
 inferior dental, 24
 pudendal, 116
 infra-orbital, 2
 lingual, 24
 median, 100, 104
 mental, 2
 musculo-spiral, 94, 100

- Nerves, occipital, small, 51
 of abdominal parietes, 69
 pneumogastric, 48
 popliteal, 124
 radial, 104
 sciatic, great, 116
 spinal accessory, 50
 superficial cervical, 51
 supra-orbital, 2
 tibial, anterior and poste-
 rior, 130
 ulnar, 95, 101, 104
 Nipple, 55
 Nostrils, 16

 Occipital lobe and fissures, 41
 Œsophagus, 22, 43, 45
 Olecranon, 95, 96
 Omo-hyoid muscle, 49
 Orbit, 11

 Palate, 23
 soft, 25
 Palmaris brevis muscle, 109
 Pancreas, 72
 Papillæ of tongue, 21
 Paracentesis thoracis, 53
 Parietal lobe and fissures, 38
 Parieto-mastoid suture, 30
 Parotid gland, 10
 Patella, 121, 122
 Pectoralis major, 56, 92
 minor, 93
 Penis, 76
 Perineum, female, 82
 male, 76
 Petit's triangle, 84
 Pharynx, 43
 Piles, 77
 Pillars of fauces, 25

 Pirogoff's operation, 131
 Platysma myoides, 42
 Pleura, extent of, 58
 Plica semilunaris, 14
 Popliteal space, 123
 Posterior nares, 25
 Poupart's ligament, 68, 117
 Precordial dulness, 60
 Processus lingualis, 58
 Prostate gland, 78
 Pterion, 29
 Pterygoid process, 24
 Pterygo-maxillary ligament, 24
 Pylorus, 70

 Radius, head, 96
 shaft, 101
 tubercle, 97
 Rectal pouches, 73
 Rectus muscle, 66
 Ribs, 53
 Rings, abdominal, 68
 Rugæ, oculo-frontal, 6
 transverse, 6

 Sacro-sciatic ligament, great, 115
 Sagittal suture, 30
 Saphenous opening, 118
 Scalp, 27
 Scapula, 90
 Scarpa's triangle, 117
 Scrotum, 76
 Seminal vesicles, 78
 Septum nasi, 16
 Serratus magnus, 56
 Sinuses of dura mater, 31
 Spinal cord and nerves, 85
 Spine of pubes, 65, 116
 Spines of vertebræ, 83
 Spleen, 71

- Squamous suture, 30
 Steno's duct, 10, 21
 Sterno-clavicular articulation, 46,
 53
 mastoid, 45
 Sternum, 52
 Stomach, 69
 Subclavian triangle, 49
 Sub-clavicular fossa, 92
 Sub-maxillary gland, 23, 46
 Sub-occipital lymphatic, 27
 Sucking cushions, 5
 Supra-ciliary ridge, 1
 Supra-marginal convolution, 40
 Supra-mastoid crest, 4
 Supra-meatal triangle, 20
 Supra-orbital notch, 2
 Syme's amputation, 131
 Symphysis pubis, 65
- Temporo-sphenoidal lobe and fis-
 sures, 40
 Tendons at ankle, 129
 knee, 124
 Tendo oculi, 12
 Tentorium, 30
 Testicle, 76
 Thenar eminence, 109
 Thorax, size of, 52
 Thymus gland, 45
 Thyroid body, 44, 46
 cartilage, 43
 Tibia, 125
 Tongue, 21
 Tonsil, 25
 Torcular Herophili, 31
 Trachea, 43, 64, 84
 Triceps, 95
- Trochanter, great, 113
 Turbinate bones, 16
- Ulna, coronoid process, 97
 olecranon process, 95, 96
 shaft, 101
 Umbilicus, 66
 Urethra, female, 75
 male, 78
 Uvula, 25
- Vagina, 81, 82
 Valves of heart, 60
 Veins, basilic, 98
 cephalic, 91, 94, 98
 innominate, 63
 jugular, anterior, 44, 47
 external, 47
 internal, 46, 48
 ranine, 23
 saphenous, 119, 127, 128
 thyroid, 44
 vena cava, inferior, 64
 superior, 63
 salvatella, 98
- Ventricle, left, 60
 right, 60
 Vertebral column, relations of
 viscera to, 87-89
- Wharton's duct, 23
- Xiphoid cartilage, 53
- Zygoma, 3

CLASSIFIED SUBJECT
CATALOGUE
OF
MEDICAL BOOKS

AND

Books on Medicine, Dentistry, Pharmacy,
Chemistry, Hygiene, Etc., Etc.,

PUBLISHED BY

P. BLAKISTON, SON & CO.,

Medical Publishers and Booksellers,

1012 WALNUT STREET, PHILADELPHIA.

SPECIAL NOTE.—The prices given in this catalogue are absolutely net, no discount will be allowed retail purchasers under any consideration. This rule has been established in order that everyone will be treated alike, a general reduction in former prices having been made to meet previous retail discounts. Upon receipt of the advertised price any book will be forwarded by mail or express, all charges prepaid.

We keep a large stock of Miscellaneous Books, not on this catalogue, relating to Medicine and Allied Sciences, published in this country and abroad. Inquiries in regard to prices, date of edition, etc., will receive prompt attention.

Special Catalogues of Books on Pharmacy, Dentistry, Chemistry, Hygiene, and Nursing will be sent free upon application.

SEE NEXT PAGE FOR SUBJECT INDEX.

Gould's Dictionaries, Page 8.

SUBJECT INDEX.

Any books not on this Catalogue we will furnish a price for upon application.

SUBJECT.	PAGE	SUBJECT.	PAGE
Anatomy	3	Nervous Diseases	14
Anesthetics	3	Nose.....	20
Autopsies (see Pathology)	16	Nursing	15
Bandaging (see Surgery).....	19	Obstetrics.....	16
Biology (see Miscellaneous) ...	14	Ophthalmology.....	9
Brain	4	Osteology (see Anatomy).....	3
Chemistry	4	Pathology	16
Children, Diseases of	6	Pharmacy	16
Clinical Charts.....	6	Physical Diagnosis	17
Compends	22, 23	Physical Training (see Miscellaneous)	14
Consumption (see Lungs).....	12	Physiology	18
Deformities	7	Poisons (see Toxicology)	13
Dentistry	7	Popular Medicine.....	10
Diagnosis.....	17	Practice of Medicine.....	18
Diagrams (see Anatomy, page 3, and Obstetrics, page 16).		Prescription Books.....	18
Dictionaries	8	Railroad Injuries (see Nervous Diseases).....	14
Diet and Food (see Miscellaneous)	14	Refraction (see Eye)	9
Dissectors	3	Rheumatism	10
Domestic Medicine	10	Sanitary Science	11
Ear	8	Skin.....	19
Electricity	9	Spectacles (see Eye)	9
Emergencies (see Surgery).....	19	Spine (see Nervous Diseases) 14	
Eye	9	Students' Compend.....	22, 23
Fevers	9	Surgery and Surgical Diseases.....	19
Gout	10	Syphilis	21
Gynecology	21	Technological Books.....	4
Headaches	10	Temperature Charts.....	6
Heart	10	Therapeutics	12
Histology.....	10	Throat	20
Hospitals (see Hygiene).....	11	Toxicology.....	13
Hygiene.....	11	U. S. Pharmacopœia	16
Insanity	4	Urinary Organs	20
Journals	11	Urine.....	20
Kidneys	12	Veneral Diseases.....	21
Lungs	12	Veterinary Medicine.....	21
Massage.....	12	Visiting Lists, Physicians', (Send for Special Circular.)	
Materia Medica.....	12	Water Analysis (see Chemistry).....	11
Medical Jurisprudence	13	Women, Diseases of.....	21
Microscopy	13		
Milk Analysis (see Chemistry) 4			
Miscellaneous	14		

The prices as given in this Catalogue are net. Cloth binding, unless otherwise specified. No discount can be allowed under any circumstances. Any book will be sent, postpaid, upon receipt of advertised price.

~~By~~ All books are bound in cloth, unless otherwise specified. All prices are net.

ANATOMY.

- MORRIS.** Text-Book of Anatomy. 791 Illus., 214 of which are printed in colors. Cloth, \$6.00; Lea., \$7.00; Half Russia, \$8.00.
 "Taken as a whole, we have no hesitation in according very high praise to this work. It will rank, we believe, with the leading Anatomies. The illustrations are handsome and the printing is good."—*Boston Medical and Surgical Journal*.
- Handsome Circular of Morris, with sample pages and colored illustrations, will be sent free to any address.
- CAMPBELL.** Outlines for Dissection. Prepared for Use with "Morris's Anatomy" by the Demonstrator of Anatomy at the University of Michigan. *Just Ready.* \$1.00
- HEATH.** Practical Anatomy. A Manual of Dissections. 8th Edition. 300 Illustrations. \$4.25
- HOLDEN.** Anatomy. A Manual of the Dissections of the Human Body. 6th Edition. Carefully Revised by A. HAWSON, M.D., Demonstrator of Anatomy, Jefferson Medical College, Philadelphia. 311 Illustrations. Cloth, \$2.50; Oil-Cloth, \$2.50; Leather, \$3.00
- HOLDEN.** Human Osteology. Comprising a Description of the Bones, with Colored Delineations of the Attachments of the Muscles. The General and Microscopical Structure of Bone and its Development. With Lithographic Plates and numerous Illus. 7th Ed. \$5.25
- HOLDEN.** Landmarks. Medical and Surgical. 4th Ed. \$1.00
- MACALISTER.** Human Anatomy. Systematic and Topographical, including the Embryology, Histology, and Morphology of Man. With Special Reference to the Requirements of Practical Surgery and Medicine. 816 Illustrations, 400 of which are original. Cloth, \$5.00; Leather, \$6.00
- MARSHALL.** Physiological Diagrams. Life Size, Colored. Eleven Life-Size Diagrams (each seven feet by three feet seven inches). Designed for Demonstration before the Class. In Sheets, Unmounted, \$40.00; Backed with Muslin and Mounted on Rollers, \$60.00; Ditto, Spring Rollers, in Handsome Walnut Wall Map Case (send for special circular), \$100.00; Single Plates—Sheets, \$5.00; Mounted, \$7.50. Explanatory Key, .50. *Descriptive circular upon application.*
- POTTER.** Compend of Anatomy, Including Visceral Anatomy. 5th Edition. 16 Lithographed Plates and 117 other Illustrations. .80; Interleaved, \$1.25
- WILSON.** Human Anatomy. 11th Edition. 429 Illustrations, 26 Colored Plates, and a Glossary of Terms. \$5.00
- OBERSTEINER.** Anatomy of the Central Nervous Organs. 198 Illustrations. \$5.50
- BROWN.** Anatomy for Nurses. *In Press.*

ANESTHETICS.

- BUXTON.** On Anesthetics. 2d Edition. Illustrated. \$1.25
- TURNBULL.** Artificial Anesthesia. The Advantages and Accidents of; Its Employment in the Treatment of Disease; Modes of Administration; Considering their Relative Risks; Tests of Purity; Treatment of Asphyxia; Spasms of the Glottis; Syncope, etc. 3d Edition, Revised. 40 Illustrations. \$3.00

BRAIN AND INSANITY.

- BLACKBURN.** A Manual of Autopsies. Designed for the Use of Hospitals for the Insane and other Public Institutions. Ten full-page Plates and other Illustrations. \$1.25
- GOWERS.** Diagnosis of Diseases of the Brain. 2d Edition. Illustrated. \$1.50
- HORSLEY.** The Brain and Spinal Cord. The Structure and Functions of. Numerous Illustrations. \$2.50
- HYSLOP.** Mental Physiology. Especially in Relation to Mental Disorders. With Illustrations. \$4.25
- LEWIS (BEVAN).** Mental Diseases. A Text-Book Having Special Reference to the Pathological Aspects of Insanity. 18 Lithographic Plates and other Illustrations.
- MANN.** Manual of Psychological Medicine and Allied Nervous Diseases. Their Diagnosis, Pathology, Prognosis, and Treatment, including their Medico-Legal Aspects; with chapter on Expert Testimony, and an Abstract of the Laws Relating to the Insane in all the States of the Union. Illustrations of Typical Faces of the Insane, Handwriting of the Insane, and Micro-photographic Sections of the Brain and Spinal Cord. \$3.00
- REGIS.** Mental Medicine. Authorized Translation by H. M. BANNISTER, M.D. \$2.00
- STEARNS.** Mental Diseases. Designed especially for Medical Students and General Practitioners. With a Digest of Laws of the various States Relating to Care of Insane. Illustrated. Cloth, \$2.75; Sheep, \$3.25
- TUKE.** Dictionary of Psychological Medicine. Giving the Definition, Etymology, and Symptoms of the Terms used in Medical Psychology, with the Symptoms, Pathology, and Treatment of the Recognized Forms of Mental Disorders, together with the Law of Lunacy in Great Britain and Ireland. Two volumes. \$10.00
- WOOD, H. C.** Brain and Overwork. .40

CHEMISTRY AND TECHNOLOGY.

Special Catalogue of Chemical Books sent free upon application.

- ALLEN.** Commercial Organic Analysis. A Treatise on the Modes of Assaying the Various Organic Chemicals and Products Employed in the Arts, Manufactures, Medicine, etc., with concise methods for the Detection of Impurities, Adulterations, etc. 2d Ed. Vol. I, Vol. II, Vol. III, Part I. *These volumes cannot be had.* Vol. III, Part II. The Amines. Pyridin and its Hydrozins and Derivatives. The Antipyretics, etc. Vegetable Alkaloids, Tea, Coffee, Cocoa, etc. \$4.50
- Vol. III, Part III. Animal Bases, Cyanogen Compounds, Proteids, etc. \$4.50
- ALLEN.** Chemical Analysis of Albuminous and Diabetic Urine. Illustrated. *Just Ready.* \$2.25
- BARTLEY.** Medical and Pharmaceutical Chemistry. A Text-Book for Medical, Dental, and Pharmaceutical Students. With Illustrations, Glossary, and Complete Index. 4th Edition, carefully Revised. Cloth, \$2.75; Sheep, \$3.25
- BLOXAM.** Chemistry, Inorganic and Organic. With Experiments. 8th Ed., Revised. 281 Engravings. Clo., \$4.25; Lea., \$5.25

- CALDWELL. Elements of Qualitative and Quantitative Chemical Analysis. 3d Edition, Revised. \$1.50
- CAMERON. Oils and Varnishes, With Illustrations, Formulæ, Tables, etc. \$2.25
- CAMERON. Soap and Candles. 54 Illustrations. \$2.00
- CLOWES AND COLEMAN. Elementary Qualitative Analysis. Adapted for Use in the Laboratories of Schools and Colleges. Illustrated. \$1.00
- GARDNER. The Brewer, Distiller, and Wine Manufacturer. A Hand-Book for all Interested in the Manufacture and Trade of Alcohol and Its Compounds. Illustrated. \$1.50
- GARDNER. Bleaching, Dyeing, and Calico Printing. With Formulæ. Illustrated. \$1.50
- GROVES AND THORP. Chemical Technology. The Application of Chemistry to the Arts and Manufactures. 8 Volumes, with numerous Illustrations.
- Vol. I. Fuel and Its Applications. 607 Illustrations and 4 Plates. Cloth, \$5.00; Half Morocco, \$6.50
- Vol. II. Lighting. Illustrated. Cloth, \$4.00; Half Morocco, \$5.50
- Vol. III. Lighting—Continued. *In Press.*
- HOLLAND. The Urine, the Gastric Contents, the Common Poisons, and the Milk. Memoranda, Chemical and Microscopical, for Laboratory Use. 5th Ed. Illustrated and interleaved, \$1.00
- LEFFMANN. Compend of Medical Chemistry, Inorganic and Organic. Including Urine Analysis. 4th Edition, Rewritten. .80; Interleaved, \$1.25
- LEFFMANN. Progressive Exercises in Practical Chemistry. Illustrated. 2d Edition. \$1.00
- LEFFMANN. Analysis of Milk and Milk Products. Arranged to Suit the Needs of Analytical Chemists, Dairymen, and Milk Inspectors. \$1.25
- LEFFMANN. Water Analysis. Illustrated. 3d Edition. \$1.25
- MÜTER. Practical and Analytical Chemistry. 4th Edition. Revised to meet the requirements of American Medical Colleges by CLAUDE C. HAMILTON, M.D. 51 Illustrations. \$1.25
- OVERMAN. Practical Mineralogy, Assaying, and Mining. With a Description of the Useful Minerals, etc. 11th Edition. \$1.00
- RAMSAY. A System of Inorganic Chemistry. Illus. \$4.00
- RICHTER. Inorganic Chemistry. 4th American, from 6th German Edition. Authorized translation by EDGAR F. SMITH, M.A., Ph.D. 89 Illustrations and a Colored Plate. \$1.75
- RICHTER. Organic Chemistry. 3d American Edition. Trans. from the last German by EDGAR F. SMITH. Illustrated. *In Press.*
- SMITH. Electro-Chemical Analysis. 2d Edition, Revised. 28 Illustrations. \$1.25
- SMITH AND KELLER. Experiments. Arranged for Students in General Chemistry. 3d Edition. Illustrated. .60
- STAMMER. Chemical Problems. With Explanations and Answers. .50
- SUTTON. Volumetric Analysis. A Systematic Handbook for the Quantitative Estimation of Chemical Substances by Measure, Applied to Liquids, Solids, and Gases. 7th Edition, Revised. With Illustrations. *In Press.*

- SYMONDS.** Manual of Chemistry, for Medical Students. 2d Edition. \$2.00
- TRIMBLE.** Practical and Analytical Chemistry. Being a Complete Course in Chemical Analysis. 4th Ed. Illus. \$1.50
- WATTS.** Organic Chemistry. 2d Edition. By WM. A. TILDEN, D.Sc., F.R.S. (Being the 13th Edition of Fowne's Organic Chemistry.) Illustrated. \$2.00
- WATTS.** Inorganic Chemistry. Physical and Inorganic. (Being the 14th Edition of Fowne's Physical and Inorganic Chemistry.) With Colored Plate of Spectra and other Illustrations. \$2.00
- WOODY.** Essentials of Chemistry and Urinalysis. 4th Edition. Illustrated. *In Press.*
- ** Special Catalogue of Books on Chemistry free upon application.*

CHILDREN.

- BROTHERS.** Infantile Mortality During Childbirth and Its Prevention. *Just Ready.* \$1.50
- HALE.** On the Management of Children in Health and Disease. .50
- HATFIELD.** Compend of Diseases of Children. With a Colored Plate. 2d Edition. *Just Ready.* .80; Interleaved, \$1.25
- MEIGS.** Infant Feeding and Milk Analysis. The Examination of Human and Cow's Milk, Cream, Condensed Milk, etc., and Directions as to the Diet of Young Infants. .50
- MONEY.** Treatment of Diseases in Children. Including the Outlines of Diagnosis and the Chief Pathological Differences Between Children and Adults. 2d Edition. \$2.50
- POWER.** Surgical Diseases of Children and their Treatment by Modern Methods. Illustrated. \$2.50
- STARR.** The Digestive Organs in Childhood. The Diseases of the Digestive Organs in Infancy and Childhood. With Chapters on the Investigation of Disease and the Management of Children. 2d Edition, Enlarged. Illustrated by two Colored Plates and numerous Wood Engravings. \$2.00
- STARR.** Hygiene of the Nursery. Including the General Regimen and Feeding of Infants and Children, and the Domestic Management of the Ordinary Emergencies of Early Life, Massage, etc. 5th Edition. 25 Illustrations. *Just Ready.* \$1.00
- TAYLOR AND WELLS.** Diseases of Children. Illustrated. A New Text-Book. *Nearly Ready.*

CLINICAL CHARTS.

- GRIFFITH.** Graphic Clinical Chart. Printed in three colors. Sample copies free. Put up in loose packages of fifty, .50. Price to Hospitals, 500 copies, \$4.00; 1000 copies, \$7.50. With name of Hospital printed on, .50 extra.
- TEMPERATURE CHARTS.** For Recording Temperature, Respiration, Pulse, Day of Disease, Date, Age, Sex, Occupation, Name, etc. Put up in pads of fifty. Each, .50

DEFORMITIES.

- REEVES. Bodily Deformities and Their Treatment. A Hand-Book of Practical Orthopedics. 228 Illustrations. \$1.75
 HEATH. Injuries and Diseases of the Jaws. 187 Illustrations. 4th Edition. Cloth, \$4.50

DENTISTRY.

Special Catalogue of Dental Books sent free upon application.

- BARRETT. Dental Surgery for General Practitioners and Students of Medicine and Dentistry. Extraction of Teeth, etc. 3d Edition. Illustrated. *Nearly Ready.*
 BLODGETT. Dental Pathology. By ALBERT N. BLODGETT, M. D., late Professor of Pathology and Therapeutics, Boston Dental College. 33 Illustrations. \$2.25
 FLAGG. Plastics and Plastic Filling, as Pertaining to the Filling of Cavities in Teeth of all Grades of Structure. 4th Edition. \$4.00
 FILLEBROWN. A Text-Book of Operative Dentistry. Written by invitation of the National Association of Dental Faculties. Illustrated. \$2.25
 GORGAS. Dental Medicine. A Manual of Materia Medica and Therapeutics. 5th Edition, Revised. \$4.00
 HARRIS. Principles and Practice of Dentistry. Including Anatomy, Physiology, Pathology, Therapeutics, Dental Surgery, and Mechanism. 13th Edition. Revised by F. J. S. GORGAS, M. D., D. D. S. 1250 Illustrations. Cloth, \$6.00; Leather, \$7.00
 HARRIS. Dictionary of Dentistry. Including Definitions of Such Words and Phrases of the Collateral Sciences as Pertain to the Art and Practice of Dentistry. 5th Edition. Revised and Enlarged by FERDINAND F. S. GORGAS, M. D., D. D. S. Cloth, \$4.50; Leather, \$5.50
 HEATH. Injuries and Diseases of the Jaws. 4th Edition 187 Illustrations. \$4.50
 HEATH. Lectures on Certain Diseases of the Jaws. 64 Illustrations. Boards, .50
 RICHARDSON. Mechanical Dentistry. 6th Edition. Thoroughly Revised by DR. GEO. W. WARREN. 600 Illustrations. Cloth, \$4.00; Leather, \$5.00
 SEWELL. Dental Surgery. Including Special Anatomy and Surgery. 3d Edition, with 200 Illustrations. \$2.00
 TAFT. Operative Dentistry. A Practical Treatise. 4th Edition. 100 Illustrations. Cloth, \$3.00; Leather, \$4.00
 TAFT. Index of Dental Periodical Literature. \$2.00
 TALBOT. Irregularities of the Teeth and Their Treatment. 2d Edition. 234 Illustrations. \$3.00
 TOMES. Dental Anatomy. Human and Comparative. 235 Illustrations. 4th Edition. \$3.50
 TOMES. Dental Surgery. 3d Edition. 292 Illustrations. \$4.00
 WARREN. Compend of Dental Pathology and Dental Medicine. With a Chapter on Emergencies. Illustrated. .80; Interleaved, \$1.25
 WARREN. Dental Prosthesis and Metallurgy. 129 Ills. \$1.25
 WHITE. The Mouth and Teeth. Illustrated. .40

*** Special Catalogue Dental Books free upon application.*

DICTIONARIES.

GOULD. The Illustrated Dictionary of Medicine, Biology, and Allied Sciences. Being an Exhaustive Lexicon of Medicine and those Sciences Collateral to it: Biology (Zoology and Botany), Chemistry, Dentistry, Pharmacology, Microscopy, etc., with many useful Tables and numerous fine Illustrations. 1633 pages. 3d Ed. Sheep or Half Dark Green Leather, \$10.00; Thumb Index, \$11.00
Half Russia, Thumb Index, \$12.00

GOULD. The Medical Student's Dictionary. Including all the Words and Phrases Generally Used in Medicine, with their Proper Pronunciation and Definition, Based on Recent Medical Literature. With Tables of the Bacilli, Micrococci, Mineral Springs, etc., of the Arteries, Muscles, Nerves, Ganglia, and Plexuses, etc. 10th Edition. Rewritten and Enlarged. Completely reset from new type. 700 pp. Half Dark Leather, \$3.25; Half Morocco, Thumb Index, \$4.00

GOULD. The Pocket Pronouncing Medical Lexicon. (12,000 Medical Words Pronounced and Defined.) Containing all the Words, their Definition and Pronunciation, that the Medical, Dental, or Pharmaceutical Student Generally Comes in Contact With; also Elaborate Tables of the Arteries, Muscles, Nerves, Bacilli, etc., etc., a Dose List in both English and Metric System, etc., Arranged in a Most Convenient Form for Reference and Memorizing.

Full Limp Leather, Gilt Edges, \$1.00; Thumb Index, \$2.50

50,000 Copies of Gould's Dictionaries Have Been Sold.

. Sample Pages and Illustrations and Descriptive Circulars of Gould's Dictionaries sent free upon application.

HARRIS. Dictionary of Dentistry. Including Definitions of Such Words and Phrases of the Collateral Sciences as Pertain to the Art and Practice of Dentistry. 5th Edition. Revised and Enlarged by FERDINAND J. S. GORGAS, M.D., D.D.S. Cloth, \$4.50; Leather, \$5.50

LONGLEY. Pocket Medical Dictionary. With an Appendix, containing Poisons and their Antidotes, Abbreviations used in Prescriptions, etc. Cloth, .75; Tucks and Pocket, \$1.00

CLEVELAND. Pocket Medical Dictionary. 33d Edition. Very small pocket size. Cloth, .50; Tucks with Pocket, .75

MAXWELL. Terminologia Medica Polyglotta. By Dr. THEODORE MAXWELL, Assisted by Others. \$3.00

The object of this work is to assist the medical men of any nationality in reading medical literature written in a language not their own. Each term is usually given in seven languages, viz.: English, French, German, Italian, Spanish, Russian, and Latin.

TREVES AND LANG. German-English Medical Dictionary. Half Russia, \$3.25

EAR (see also Throat and Nose).

HOVELL. Diseases of the Ear and Naso-Pharynx. Including Anatomy and Physiology of the Organ, together with the Treatment of the Affections of the Nose and Pharynx which Conduce to Aural Disease. 122 Illustrations. \$5.00

BURNETT. Hearing and How to Keep It. Illustrated. .40

DALBY. Diseases and Injuries of the Ear. 4th Edition. 38 Wood Engravings and 8 Colored Plates. \$2.50

HALL. Compend of Diseases of Ear and Nose. Illustrated. .80; Interleaved, \$1.25

PRITCHARD. Diseases of the Ear. 3d Edition, Enlarged. Many Illustrations and Formulæ. Cloth, \$1.50

ELECTRICITY.

- BIGELOW.** Plain Talks on Medical Electricity and Batteries. With a Therapeutic Index and a Glossary. 43 Illustrations. 2d Edition. \$1.00
- JONES.** Medical Electricity. 2d Edition. 112 Illustrations. \$2.50
- MASON.** Electricity; Its Medical and Surgical Uses. Numerous Illustrations. .75

EYE.

A Special Circular of Books on the Eye sent free upon application.

- ARLT.** Diseases of the Eye. Clinical Studies on Diseases of the Eye, Including the Conjunctiva, Cornea and Sclerotic, Iris and Ciliary Body. Authorized Translation by LYMAN WARE, M.D. Illustrated. \$1.25
- FICK.** Diseases of the Eye and Ophthalmoscopy. Translated by A. B. HALE, M. D. 157 Illustrations, many of which are in colors, and a glossary. *Just Ready.* Cloth, \$4.50; Sheep, \$5.50
- FOX AND GOULD.** Compend on Diseases of the Eye and Refraction, Including Treatment and Surgery. 2d Edition. 71 Illustrations and 39 Formulæ. .80; Interleaved, \$1.25
- GOWERS.** Medical Ophthalmoscopy. A Manual and Atlas with Colored Autotype and Lithographic Plates and Wood-cuts, Comprising Original Illustrations of the Changes of the Eye in Diseases of the Brain, Kidney, etc. 3d Edition. \$4.00
- HARLAN.** Eyesight, and How to Care for It. Illus. .40
- HARTRIDGE.** Refraction. 96 Illustrations and Test Types. 8th Edition, Enlarged. \$1.50
- HARTRIDGE.** On the Ophthalmoscope. 2d Edition. With Colored Plate and many Wood-cuts. \$1.25
- HANSELL AND BELL.** Clinical Ophthalmology. Colored Plate of Normal Fundus and 120 Illustrations. \$1.50
- MACNAMARA.** On the Eye. 5th Edition. Numerous Colored Plates, Diagrams of Eye, Wood-cuts, and Test Types. \$3.50
- MEYER.** Ophthalmology. A Manual and Atlas of the Eye. Translated from the 3d French Edition by A. FREEDLAND FERGUS, M.B. 270 Illustrations, 2 Colored Plates. Cloth, \$3.50; Sheep, \$4.50
- MORTON.** Refraction of the Eye. Its Diagnosis and the Correction of its Errors. With Chapter on Keratotomy and Test Types. 5th Edition. \$1.00
- OHLEMANN.** Ocular Therapeutics. Authorized Translation, and Edited by DR. CHARLES A. OLIVER. *In Press.*
- PHILLIPS.** Spectacles and Eyeglasses. Their Prescription and Adjustment. 2d Edition. 49 Illustrations. *Just Ready.* \$1.00
- SWANZY.** Diseases of the Eye and Their Treatment. 5th Edition, Revised. 166 Illustrations, 1 Plain Plate, and a Zephyr Test Card. Cloth, \$2.50; Sheep, \$3.00
- WALKER.** Students' Aid in Ophthalmology. Colored Plate and 40 other Illustrations and Glossary. *Just Ready.* \$1.50

FEVERS.

- COLLIE.** On Fevers. Their History, Etiology, Diagnosis, Prognosis, and Treatment. Colored Plates. \$2.00
- GOODALL AND WASHBOURN.** Fevers and Their Treatment. Illustrated. \$3.25

GOUT AND RHEUMATISM.

- DUCKWORTH. A Treatise on Gout. With Chromo-lithographs and Engravings. Cloth, \$6.00
- GARROD. On Rheumatism. A Treatise on Rheumatism and Rheumatic Arthritis. Cloth, \$5.00
- HAIG. Causation of Disease by Uric Acid. A Contribution to the Pathology of High Arterial Tension, Headache, Epilepsy, Gout, Rheumatism, Diabetes, Bright's Disease, etc. 3d Edition. \$3.00

HEADACHES.

- DAY. On Headaches. The Nature, Causes, and Treatment of Headaches. 4th Edition. Illustrated. \$1.00

HEALTH AND DOMESTIC MEDICINE (see also Hygiene and Nursing).

- BUCKLEY. The Skin in Health and Disease. Illus. .40
- BURNETT. Hearing and How to Keep It. Illustrated. .40
- COHEN. The Throat and Voice. Illustrated. .40
- DULLES. Emergencies. 4th Edition. Illustrated. \$1.00
- HARLAN. Eyesight and How to Care for It. Illustrated. .40
- HARTSHORNE. Our Homes. Illustrated. .40
- OSGOOD. The Winter and its Dangers. .40
- PACKARD. Sea Air and Bathing. .40
- PARKES. The Elements of Health. *Just Ready.* \$1.25
- RICHARDSON. Long Life and How to Reach It. .40
- WESTLAND. The Wife and Mother. \$1.50
- WHITE. The Mouth and Teeth. Illustrated. .40
- WILSON. The Summer and its Diseases. .40
- WOOD. Brain Work and Overwork. .40
- STARR. Hygiene of the Nursery. 5th Edition. \$1.00
- CANFIELD. Hygiene of the Sick-Room. \$1.25

HEART.

- SANSOM. Diseases of the Heart. The Diagnosis and Pathology of Diseases of the Heart and Thoracic Aorta. With Plates and other Illustrations. \$6.00

HISTOLOGY.

- BILLSTEIN. Progressive Exercises in Practical Histology. *Nearly Ready.*
- STIRLING. Outlines of Practical Histology. 368 Illustrations. 2d Edition, Revised and Enlarged. With new Illustrations. \$2.00
- STÖHR. Histology and Microscopical Anatomy. Translated by A. SHAPER, M.D., Harvard Medical School. 260 Illus. *In Press.*

HYGIENE AND WATER ANALYSIS.

Special Catalogue of Books on Hygiene sent free upon application.

- CANFIELD.** Hygiene of the Sick-Room. A Book for Nurses and Others. Being a Brief Consideration of Asepsis, Antisepsis, Disinfection, Bacteriology, Immunity, Heating and Ventilation, and Kindred Subjects. \$1.25
- COPLIN AND BEVAN.** Practical Hygiene. A Complete American Text-Book. 138 Illustrations. \$3.25
- FOX.** Water, Air, and Food. Sanitary Examinations of Water, Air, and Food. 100 Engravings. 2d Edition, Revised. \$3.50
- KENWOOD.** Public Health Laboratory Work. 116 Illustrations and 3 Plates. \$2.00
- LEFFMANN.** Examination of Water for Sanitary and Technical Purposes. 3d Edition. Illustrated. \$1.25
- LEFFMANN.** Analysis of Milk and Milk Products. Illustrated. \$1.25
- LINCOLN.** School and Industrial Hygiene. .40
- MACDONALD.** Microscopical Examinations of Water and Air. 25 Lithographic Plates, Reference Tables, etc. 2d Ed. \$2.50
- MCNEILL.** The Prevention of Epidemics and the Construction and Management of Isolation Hospitals. Numerous Plans and Illustrations. \$3.50
- NOTTER AND FIRTH.** The Theory and Practice of Hygiene. (Being the 9th Edition of Parkes' Practical Hygiene, rewritten and brought up to date.) 10 Plates and 135 other Illustrations. 1034 pages. 8vo. *Just Ready.* \$7.00
- PARKES.** Hygiene and Public Health. By Louis C. Parkes, M.D. 4th Edition. Enlarged. Illustrated. \$2.50
- PARKES.** Popular Hygiene. The Elements of Health. A Book for Lay Readers. Illustrated. \$1.25
- STARR.** The Hygiene of the Nursery. Including the General Regimen and Feeding of Infants and Children, and the Domestic Management of the Ordinary Emergencies of Early Life, Massage, etc. 5th Edition. 25 Illustrations. *Just Ready.* \$1.00
- STEVENSON AND MURPHY.** A Treatise on Hygiene. By Various Authors. In Three Octave Volumes. Illustrated. Vol. I, \$6.00; Vol. II, \$6.00; Vol. III, \$5.00

** Each Volume sold separately. Special Circular upon application.

WILSON. Hand-Book of Hygiene and Sanitary Science. With Illustrations. 7th Edition. \$3.00

WEYL. Sanitary Relations of the Coal-Tar Colors. Authorized Translation by HENRY LEFFMANN, M.D., PH.D. \$1.25

** *Special Catalogue of Books on Hygiene free upon application.*

JOURNALS, ETC.

OPHTHALMIC REVIEW. A Monthly Record of Ophthalmic Science. Publ. in London. Sample number .25; per annum \$3.00

NEW SYDENHAM SOCIETY PUBLICATION. Three to six volumes each year. Circular upon application. Per annum \$8.00

KIDNEY DISEASES.

- RALFE.** Diseases of the Kidney and Urinary Derangements. Illustrated. \$2.00
- THORNTON.** The Surgery of the Kidney. 10 Illus. Clo., \$1.50
- TYSON.** Bright's Disease and Diabetes. With Especial Reference to Pathology and Therapeutics. Including a Section on Retinitis in Bright's Disease. Illustrated. \$2.50

LUNGS AND PLEURÆ.

- HARRIS AND BEALE.** Treatment of Pulmonary Consumption. \$2.50
- POWELL.** Diseases of the Lungs and Pleuræ, including Consumption. Colored Plates and other Illus. 4th Ed. \$4.00

MASSAGE.

- KLEEN.** Hand-Book of Massage. Authorized translation by MUSSEY HARTWELL, M.D., PH.D. With an Introduction by Dr. S. WEIR MITCHELL. Illustrated by a series of Photographs Made Especially by DR. KLEEN for the American Edition. \$2.25
- MURRELL.** Massotherapeutics. Massage as a Mode of Treatment. 5th Edition. \$1.25
- OSTROM.** Massage and the Original Swedish Movements. Their Application to Various Diseases of the Body. A Manual for Students, Nurses, and Physicians. Third Edition, Enlarged. 94 Wood Engravings, many of which are original. \$1.00

MATERIA MEDICA AND THERAPEUTICS.

- ALLEN, HARLAN, HARTE, VAN HARLINGEN.** A Hand-Book of Local Therapeutics, Being a Practical Description of all those Agents Used in the Local Treatment of Diseases of the Eye, Ear, Nose and Throat, Mouth, Skin, Vagina, Rectum, etc., such as Ointments, Plasters, Powders, Lotions, Inhalations, Suppositories, Bougies, Tampons, and the Proper Methods of Preparing and Applying Them. \$3.00
- BIDDLE.** Materia Medica and Therapeutics. Including Dose List, Dietary for the Sick, Table of Parasites, and Memoranda of New Remedies. 13th Edition, Thoroughly Revised in accordance with the new U. S. P. 64 Illustrations and a Clinical Index. Cloth, \$4.00; Sheep, \$5.00
- BRACKEN.** Outlines of Materia Medica and Pharmacology. By H. M. BRACKEN, Professor of Materia Medica and Therapeutics and of Clinical Medicine, University of Minnesota. \$2.75
- DAVIS.** Materia Medica and Prescription Writing. \$1.50
- FIELD.** Evacuant Medication. Cathartics and Emetics. \$1.75
- GORGAS.** Dental Medicine. A Manual of Materia Medica and Therapeutics. 5th Edition, Revised. \$4.00
- MAYS.** Therapeutic Forces; or, The Action of Medicine in the Light of Doctrine of Conservation of Force. \$1.25
- MAYS.** Theine in the Treatment of Neuralgia. ½ bound, .50

- NAPHEYS.** *Modern Therapeutics.* 9th Revised Edition, Enlarged and Improved. In two handsome volumes. Edited by ALLEN J. SMITH, M.D., and J. AUBREY DAVIS, M.D.
Vol. I. General Medicine and Diseases of Children. \$4.00
Vol. II. General Surgery, Obstetrics, and Diseases of Women. \$4.00
- POTTER.** *Hand-Book of Materia Medica, Pharmacy, and Therapeutics,* including the Action of Medicines, Special Therapeutics, Pharmacology, etc., including over 600 Prescriptions and Formulæ. 5th Edition, Revised and Enlarged. With Thumb Index in each copy. Cloth, \$4.00; Sheep, \$5.00
- POTTER.** *Compend of Materia Medica, Therapeutics, and Prescription Writing,* with Special Reference to the Physiological Action of Drugs. 6th Revised and Improved Edition, based upon the U. S. P. 1890. .80; Interleaved, \$1.25
- SAYRE.** *Organic Materia Medica and Pharmacognosy.* An Introduction to the Study of the Vegetable Kingdom and the Vegetable and Animal Drugs. Comprising the Botanical and Physical Characteristics, Source, Constituents, and Pharmacopoeial Preparations. With chapters on Synthetic Organic Remedies, Insects Injurious to Drugs, and Pharmacal Botany. A Glossary and 543 Illustrations, many of which are original. \$4.00
- WARING.** *Practical Therapeutics.* 4th Edition, Revised and Rearranged. Cloth, \$2.00; Leather, \$3.00
- WHITE AND WILCOX.** *Materia Medica, Pharmacy, Pharmacology, and Therapeutics.* 3d American Edition, Revised by REYNOLD W. WILCOX, M.A., M.D., LL.D. Clo., \$2.75; Lea., \$3.25

MEDICAL JURISPRUDENCE AND TOXICOLOGY.

- REESE.** *Medical Jurisprudence and Toxicology.* A Text-Book for Medical and Legal Practitioners and Students. 4th Edition. Revised by HENRY LEFFMANN, M.D. Clo., \$3.00; Leather, \$3.50
"To the student of medical jurisprudence and toxicology it is invaluable, as it is concise, clear, and thorough in every respect."—*The American Journal of the Medical Sciences.*
- MANN.** *Forensic Medicine and Toxicology.* Illus. \$6.50
- MURRELL.** *What to Do in Cases of Poisoning.* 7th Edition, Enlarged. \$1.00
- TANNER.** *Memoranda of Poisons. Their Antidotes and Tests.* 7th Edition. .75

MICROSCOPY.

- BEALE.** *The Use of the Microscope in Practical Medicine.* For Students and Practitioners, with Full Directions for Examining the Various Secretions, etc., by the Microscope. 4th Ed. 500 Illus. \$6.50
- BEALE.** *How to Work with the Microscope.* A Complete Manual of Microscopical Manipulation, containing a Full Description of many New Processes of Investigation, with Directions for Examining Objects Under the Highest Powers, and for Taking Photographs of Microscopic Objects. 5th Edition. 400 Illustrations, many of them colored. \$6.50
- CARPENTER.** *The Microscope and Its Revelations.* 7th Edition. 800 Illustrations and many Lithographs. \$5.50

- LEE.** The Microtometist's Vade Mecum. A Hand-Book of Methods of Microscopical Anatomy. 881 Articles. 4th Edition, Enlarged. *In Press.*
- MACDONALD.** Microscopical Examinations of Water and Air. 25 Lithographic Plates, Reference Tables, etc. 2d Edition. \$2.50
- REEVES.** Medical Microscopy, including Chapters on Bacteriology, Neoplasms, Urinary Examination, etc. Numerous Illustrations, some of which are printed in colors. \$2.50
- WETHERED.** Medical Microscopy. A Guide to the Use of the Microscope in Practical Medicine. 100 Illustrations. \$2.00

MISCELLANEOUS.

- BLACK.** Micro-Organisms. The Formation of Poisons. A Biological Study of the Germ Theory of Disease. .75
- BURNETT.** Foods and Dietaries. A Manual of Clinical Dietetics. 2d Edition. \$1.50
- DAVIS.** Biology. Illustrated. \$3.00
- GOULD.** Borderland Studies. Miscellaneous Addresses and Essays. 12mo. *Just Ready.* \$2.00
- GOWERS.** The Dynamics of Life. .75
- HAIG.** Causation of Disease by Uric Acid. A Contribution to the Pathology of High Arterial Tension, Headache, Epilepsy, Gout, Rheumatism, Diabetes, Bright's Disease, etc. 3d Edition, Enlarged. \$3.00
- HARE.** Mediastinal Disease. Illustrated by six Plates. \$2.00
- HENRY.** A Practical Treatise on Anemia. Half Cloth, .50
- LEFFMANN.** The Coal-Tar Colors. With Special Reference to their Injurious Qualities and the Restrictions of their Use. A Translation of THEODORE WEYL'S Monograph. \$1.25
- TREVES.** Physical Education: Its Effects, Value, Methods, Etc. .75
- LIZARS.** The Use and Abuse of Tobacco. .40
- PARRISH.** Alcoholic Inebriety from a Medical Standpoint, with Cases. \$1.00

NERVOUS DISEASES.

- GOWERS.** Manual of Diseases of the Nervous System. A Complete Text-Book. 2d Edition, Revised, Enlarged, and in many parts Rewritten. With many new Illustrations. Two volumes.
Vol. I. Diseases of the Nerves and Spinal Cord. \$3.00
Vol. II. Diseases of the Brain and Cranial Nerves; General and Functional Disease. \$4.00
- GOWERS.** Syphilis and the Nervous System. \$1.00
- GOWERS.** Diagnosis of Diseases of the Brain. 2d Edition, Illustrated. \$1.50
- GOWERS.** Clinical Lectures. A New Volume of Essays on the Diagnosis, Treatment, etc., of Diseases of the Nervous System. *Just Ready.* \$2.00
- GOWERS.** Epilepsy and Other Chronic Convulsive Diseases. 2d Edition. *In Press.*
- HORSLEY.** The Brain and Spinal Cord. The Structure and Functions of. Numerous Illustrations. \$2.50

- OBERSTEINER. The Anatomy of the Central Nervous Organs. A Guide to the Study of their Structure in Health and Disease. 198 Illustrations. \$5.50
- ORMEROD. Diseases of the Nervous System. 66 Wood Engravings. \$1.00
- OSLER. Cerebral Palsies of Children. A Clinical Study. \$2.00
- OSLER. Chorea and Choreiform Affections. \$2.00
- PAGE. Injuries of the Spine and Spinal Cord. In their Surgical and Medico-legal Aspects. 3d Edition. *Preparing.*
- PAGE. Railroad Injuries. With Special Reference to Those of the Back and Nervous System. \$2.25
- THORBURN. Surgery of the Spinal Cord. Illustrated. \$4.00
- WATSON. Concussions. An Experimental Study of Lesions Arising from Severe Concussions. Paper cover, \$1.00
- WOOD. Brain Work and Overwork. .40

NURSING.

Special Catalogue of Books for Nurses sent free upon application.

- BROWN. Anatomy for Nurses. *In Press.*
- CANFIELD. Hygiene of the Sick-Room. A Book for Nurses and Others. Being a Brief Consideration of Asepsis, Antisepsis, Disinfection, Bacteriology, Immunity, Heating and Ventilation, and Kindred Subjects for the Use of Nurses and Other Intelligent Women. \$1.25
- CULLINGWORTH. A Manual of Nursing, Medical and Surgical. 3d Edition with Illustrations. .75
- CULLINGWORTH. A Manual for Monthly Nurses. 3d Ed. .40
- CUFF. Lectures to Nurses. *In Press.*
- DOMVILLE. Manual for Nurses and Others Engaged in Attending the Sick. 8th Edition. With Recipes for Sick-room Cookery, etc. .75
- ULLERTON. Obstetric Nursing. 40 Ills. 4th Ed. \$1.00
- FULLERTON. Nursing in Abdominal Surgery and Diseases of Women. Comprising the Regular Course of Instruction at the Training-School of the Women's Hospital, Philadelphia. 2d Edition. 70 Illustrations. \$1.50
- HUMPHREY. A Manual for Nurses. Including General Anatomy and Physiology, Management of the Sick-Room, etc. 13th Edition. Illustrated. \$1.00
- SHAW. Notes for Visiting Nurses, and all those Interested in the Working and Organization of District, Visiting, or Parochial Nurse Societies. With an Appendix Explaining the Organization and Working of Various Visiting and District Nurse Societies, by HELEN C. JENKS, of Philadelphia. \$1.00
- STARR. The Hygiene of the Nursery. Including the General Regimen and Feeding of Infants and Children, and the Domestic Management of the Ordinary Emergencies of Early Life, Massage, etc. 5th Edition. 25 Illustrations. *Just Ready.* \$1.00
- TEMPERATURE CHARTS. For Recording Temperature, Respiration, Pulse, Day of Disease, Date, Age, Sex, Occupation, Name, etc. Put up in pads of fifty. Each .50
- VOSWINKEL. Surgical Nursing. 111 Illustrations. \$1.00

* * * *Special Catalogue of Books on Nursing free upon application.*

OBSTETRICS.

- BAR.** Antiseptic Midwifery. The Principles of Antiseptic Methods Applied to Obstetric Practice. Authorized Translation by HENRY D. FRY, M.D., with an Appendix by the Author. \$1.00
- CAZEAUX AND TARNIER.** Midwifery. With Appendix by MUNDÉ. The Theory and Practice of Obstetrics, including the Diseases of Pregnancy and Parturition, Obstetrical Operations, etc. 8th Edition. Illustrated by Chromo-Lithographs, Lithographs, and other full-page Plates, seven of which are beautifully colored, and numerous Wood Engravings. Cloth, \$4.50; Full Leather, \$5.50
- DAVIS.** A Manual of Obstetrics. Being a Complete Manual for Physicians and Students. 2d Edition. 16 Colored and other Plates and 134 other Illustrations. \$2.00
- LANDIS.** Compend of Obstetrics. 5th Edition, Revised by WM. H. WELLS, Assistant Demonstrator of Clinical Obstetrics, Jefferson Medical College. With many Illustrations, .80; Interleaved, \$1.25.
- SCHULTZE.** Obstetrical Diagrams. Being a series of 20 Colored Lithograph Charts, Imperial Map Size, of Pregnancy and Midwifery, with accompanying explanatory (German) text illustrated by Wood Cuts. 2d Revised Edition.
Price in Sheets, \$26.00; Mounted on Rollers, Muslin Backs, \$36.00
- STRAHAN.** Extra-Uterine Pregnancy. The Diagnosis and Treatment of Extra-Uterine Pregnancy. .75
- WINCKEL.** Text-Book of Obstetrics, Including the Pathology and Therapeutics of the Puerperal State. Authorized Translation by J. CLIFTON EDGAR, A.M., M.D. With nearly 200 Illustrations. Cloth, \$5.00; Leather, \$6.00
- FULLERTON.** Obstetric Nursing. 4th Ed. Illustrated. \$1.00
- SHIBATA.** Obstetrical Pocket-Phantom with Movable Child and Pelvis. Letter Press and Illustrations. \$1.00

PATHOLOGY.

- BLACKBURN.** Autopsies. A Manual of Autopsies Designed for the Use of Hospitals for the Insane and other Public Institutions. Ten full-page Plates and other Illustrations. \$1.25
- BLODGETT.** Dental Pathology. By ALBERT N. BLODGETT, M.D., late Professor of Pathology and Therapeutics, Boston Dental College. 33 Illustrations. \$1.25
- GILLIAM.** Pathology. A Hand-Book for Students. 47 Illus. .75
- HALL.** Compend of General Pathology and Morbid Anatomy. 91 very fine Illustrations. .80; Interleaved, \$1.25
- VIRCHOW.** Post-Mortem Examinations. A Description and Explanation of the Method of Performing Them in the Dead House of the Berlin Charity Hospital, with Special Reference to Medicolegal Practice. 3d Edition, with Additions. .75

PHARMACY.

Special Catalogue of Books on Pharmacy sent free upon application.

- COBLENTZ.** Manual of Pharmacy. A New and Complete Text-Book by the Professor in the New York College of Pharmacy. 2d Edition, Revised and Enlarged. 437 Illustrations. \$3.50

- BEASLEY. Book of 3100 Prescriptions.** Collected from the Practice of the Most Eminent Physicians and Surgeons—English, French, and American. A Compendious History of the Materia Medica, Lists of the Doses of all the Official and Established Preparations, an Index of Diseases and their Remedies. 7th Ed. \$2.00
- BEASLEY. Druggists' General Receipt Book.** Comprising a Copious Veterinary Formulary, Recipes in Patent and Proprietary Medicines, Druggists' Nostrums, etc.; Perfumery and Cosmetics, Beverages, Dietetic Articles and Condiments, Trade Chemicals, Scientific Processes, and an Appendix of Useful Tables. 10th Edition, Revised. \$2.00
- BEASLEY. Pocket Formulary.** A Synopsis of the British and Foreign Pharmacopœias. Comprising Standard and Approved Formulæ for the Preparations and Compounds Employed in Medical Practice. 11th Edition. \$2.00
- PROCTOR. Practical Pharmacy.** Lectures on Practical Pharmacy. With Wood Engravings and 32 Lithographic Fac-simile Prescriptions. 3d Edition, Revised, and with Elaborate Tables of Chemical Solubilities, etc. \$3.00
- ROBINSON. Latin Grammar of Pharmacy and Medicine.** 2d Edition. With elaborate Vocabularies. \$1.75
- SAYRE. Organic Materia Medica and Pharmacognosy.** An Introduction to the Study of the Vegetable Kingdom and the Vegetable and Animal Drugs. Comprising the Botanical and Physical Characteristics, Source, Constituents, and Pharmacopœial Preparations. With Chapters on Synthetic Organic Remedies, Insects Injurious to Drugs, and Pharmacal Botany. A Glossary and 543 Illustrations, many of which are original. \$4.00
- SCOVILLE. The Art of Compounding. A Text-Book for the Student and a Reference Book for the Pharmacist.** \$2.50
- STEWART. Compend of Pharmacy.** Based upon "Remington's Text-Book of Pharmacy" 5th Edition, Revised in Accordance with the U. S. Pharmacopœia, 1890. Complete Tables of Metric and English Weights and Measures. .80; Interleaved, \$1.25
- UNITED STATES PHARMACOPŒIA.** 1890. 7th Decennial Revision. Cloth, \$2.50 (postpaid, \$2.77); Sheep, \$3.00 (postpaid, \$3.27); Interleaved, \$4.00 (postpaid, \$4.50); Printed on one side of page only, unbound, \$3.50 (postpaid, \$3.90).
- Select Tables from the U. S. P. (1890).** Being Nine of the Most Important and Useful Tables, Printed on Separate Sheets. Carefully put up in patent envelope. .25
- WHITE AND WILCOX. Materia Medica, Pharmacy, Pharmacology, and Therapeutics.** 3d American Edition. Revised by REYNOLD W. WILCOX, M.D., LL.D. Cloth, \$2.75; Leather, \$3.25
- POTTER. Hand-Book of Materia Medica, Pharmacy, and Therapeutics.** 600 Prescriptions and Formulæ. 5th Edition. Cloth, \$4.00; Sheep, \$5.00

₃ *Special Catalogue of Books on Pharmacy free upon application.*

PHYSICAL DIAGNOSIS.

- TYSON. Hand-Book of Physical Diagnosis.** For Students and Physicians. By the Professor of Clinical Medicine in the University of Pennsylvania. Illus. 2d Ed., Improved and Enlarged. \$1.25
- MEMMINGER. Diagnosis by the Urine.** 23 Illus. \$1.00

PHYSIOLOGY.

- BRUBAKER.** Compend of Physiology. 8th Edition, Revised and Enlarged. Illustrated. .80; Interleaved, \$1.25
- KIRKE.** Physiology. (13th Authorized Edition. Dark Red Cloth.) A Hand-Book of Physiology. 13th London Edition, Revised and Enlarged. 516 Illustrations, some of which are printed in colors. Cloth, \$3.25; Leather, \$4.00
- LANDOIS.** A Text-Book of Human Physiology, Including Histology and Microscopical Anatomy, with Special Reference to the Requirements of Practical Medicine. 5th American, translated from the 9th German Edition, with Additions by Wm. STIRLING, M.D., D.Sc. 845 Illus., many of which are printed in colors. *In Press.*
- STARLING.** Elements of Human Physiology. 100 Ills. \$1.00
- STIRLING.** Outlines of Practical Physiology. Including Chemical and Experimental Physiology, with Special Reference to Practical Medicine. 3d Edition. 289 Illustrations. \$2.00
- TYSON.** Cell Doctrine. Its History and Present State. \$1.50
- YEO.** Manual of Physiology. A Text-Book for Students of Medicine. By GERALD F. YEO, M.D., F.R.C.S. 6th Edition. 254 Illustrations and a Glossary. Cloth, \$2.50; Leather, \$3.00

PRACTICE.

- BEALE.** On Slight Ailments; their Nature and Treatment. 2d Edition, Enlarged and Illustrated. \$1.25
- CHARTERIS.** Practice of Medicine. 6th Edition. \$2.00
- FOWLER.** Dictionary of Practical Medicine. By various writers. An Encyclopædia of Medicine. Clo., \$3.00; Half Mor. \$4.00
- HUGHES.** Compend of the Practice of Medicine. 5th Edition, Revised and Enlarged.
- Part I. Continued, Eruptive, and Periodical Fevers, Diseases of the Stomach, Intestines, Peritoneum, Biliary Passages, Liver, Kidneys, etc., and General Diseases, etc.
- Part II. Diseases of the Respiratory System, Circulatory System, and Nervous System; Diseases of the Blood, etc.
- Price of each part, .80; Interleaved, \$1.25
- Physician's Edition.** In one volume, including the above two parts, a Section on Skin Diseases, and an Index. 5th Revised, Enlarged Edition. 568 pp. Full Morocco, Gilt Edge, \$2.25
- ROBERTS.** The Theory and Practice of Medicine. The Sections on Treatment are especially exhaustive. 9th Edition, with Illustrations. Cloth, \$4.50; Leather, \$5.50
- TAYLOR.** Practice of Medicine. Cloth, \$2.00; Sheep, \$2.50
- TYSON.** The Practice of Medicine. By JAMES TYSON, M.D., Professor of Clinical Medicine in the University of Pennsylvania. A Complete Systematic Text-book with Special Reference to Diagnosis and Treatment. Illustrated. 8vo. *Just Ready.* Cloth, \$5.50; Leather, \$6.50; Half Russia, \$7.50

PRESCRIPTION BOOKS.

- BEASLEY.** Book of 3100 Prescriptions. Collected from the Practice of the Most Eminent Physicians and Surgeons—English, French, and American. A Compendious History of the Materia Medica, Lists of the Doses of all Official and Established Preparations, and an Index of Diseases and their Remedies. 7th Ed. \$2.00

- BEASLEY. Druggists' General Receipt Book.** Comprising a Copious Veterinary Formulary, Recipes in Patent and Proprietary Medicines, Druggists' Nostrums, etc.; Perfumery and Cosmetics, Beverages, Dietetic Articles and Condiments, Trade Chemicals, Scientific Processes, and an Appendix of Useful Tables. 10th Edition, Revised. \$2.00
- BEASLEY. Pocket Formulary.** A Synopsis of the British and Foreign Pharmacopœias. Comprising Standard and Approved Formulæ for the Preparations and Compounds Employed in Medical Practice. 11th Edition. Cloth, \$2.00
- PEREIRA. Prescription Book.** Containing Lists of Terms, Phrases, Contractions, and Abbreviations Used in Prescriptions, Explanatory Notes, Grammatical Construction of Prescriptions, etc. 16th Edition. Cloth, .75; Tucks, \$1.00
- WYTHE. Dose and Symptom Book.** The Physician's Pocket Dose and Symptom Book. Containing the Doses and Uses of all the Principal Articles of the Materia Medica and Official Preparations. 17th Ed. Cloth, .75; Leather, with Tucks and Pocket, \$1.00

SKIN.

- BULKLEY. The Skin in Health and Disease.** Illustrated. .40
- CROCKER. Diseases of the Skin.** Their Description, Pathology, Diagnosis, and Treatment, with Special Reference to the Skin Eruptions of Children. 92 Illus. 2d Edition. Enlarged. \$4.50
- IMPEY. Leprosy.** 37 Plates. 8vo. \$3.50
- VAN HARLINGEN. On Skin Diseases.** A Practical Manual of Diagnosis and Treatment, with special reference to Differential Diagnosis. 3d Edition, Revised and Enlarged. With Formulæ and 60 Illustrations, some of which are printed in colors. \$2.75

SURGERY AND SURGICAL DISEASES.

- CAIRD AND CATHCART. Surgical Hand-Book.** 5th Edition, Revised. 188 Illustrations. Full Red Morocco, \$2.50
- DEAVER. Appendicitis, Its Symptoms, Diagnosis, Pathology, Treatment, and Complications.** Elaborately Illustrated with Colored Plates and other Illustrations. *Just Ready.* Cloth, \$3.50
- DEAVER. Surgical Anatomy.** With 200 Illustrations, Drawn by a Special Artist from Directions made for the Purpose. *In Preparation.*
- DULLES. What to Do First in Accidents and Poisoning.** 4th Edition. New Illustrations. \$1.00
- HACKER. Antiseptic Treatment of Wounds, Introduction to the, According to the Method in Use at Professor Billroth's Clinic, Vienna.** With a Photo-engraving of Billroth in his Clinic. .50
- HEATH. Minor Surgery and Bandaging.** 10th Ed Revised and Enlarged. 158 Illustrations, 62 Formulæ, Diet List, etc \$1.25
- HEATH. Injuries and Diseases of the Jaws.** 4th Edition. 187 Illustrations. \$4 50
- HEATH. Lectures on Certain Diseases of the Jaws.** 64 Illustrations. Boards, .50
- HORWITZ. Compend of Surgery and Bandaging, including Minor Surgery, Amputations, Fractures, Dislocations, Surgical Diseases, and the Latest Antiseptic Rules, etc., with Differential Diagnosis and Treatment.** 5th Edition, very much Enlarged and Rearranged. 167 Illustrations, 98 Formulæ. Clo., .80; Interleaved, \$1.25

- JACOBSON.** Operations of Surgery. Over 200 Illustrations.
Cloth, \$3.00; Leather, \$4.00
- JACOBSON.** Diseases of the Male Organs of Generation.
88 Illustrations. \$6.00
- MACREADY.** A Treatise on Ruptures. 24 Full-page Litho-
graphed Plates and Numerous Wood Engravings. Cloth, \$6.00
- MOULLIN.** Text-Book of Surgery. With Special Reference to
Treatment. 3d American Edition. Revised and edited by JOHN B.
HAMILTON, M.D., LL.D., Professor of the Principles of Surgery and
Clinical Surgery, Rush Medical College, Chicago. 623 Illustrations,
over 200 of which are original, and many of which are printed in
colors. Handsome Cloth, \$6.00; Leather, \$7.00
- "The aim to make this valuable treatise practical by giving special
attention to questions of treatment has been admirably carried out.
Many a reader will consult the work with a feeling of satisfaction that
his wants have been understood, and that they have been intelligently
met."—*The American Journal of Medical Science.*
- PORTER.** Surgeon's Pocket-Book. 3d Ed. Lea. Cover, \$2.00.
- SMITH.** Abdominal Surgery. Being a Systematic Description of
all the Principal Operations. 80 Illus. 5th Ed. 2 Vols. Clo., \$10.00
- SWAIN.** Surgical Emergencies. New Edition. Cloth, \$1.75
- VOSWINKEL.** Surgical Nursing. 111 Illustrations. \$1.00
- WALSHAM.** Manual of Practical Surgery. 5th Ed., Re-
vised and Enlarged. With 380 Engravings. Clo., \$2.75; Lea., \$3.25
- WATSON.** On Amputations of the Extremities and Their
Complications. 250 Illustrations. \$5.50

THROAT AND NOSE (see also Ear).

- COHEN.** The Throat and Voice. Illustrated. .40
- HALL.** Diseases of the Nose and Throat. Two Colored
Plates and 59 Illustrations. \$2.50
- HALL.** Compend of Diseases of the Ear and Nose. Illus-
trated. .80; Interleaved, \$1.25
- HUTCHINSON.** The Nose and Throat. Including the Nose,
Naso-Pharynx, Pharynx, and Larynx. Illustrated by Lithograph
Plates and 40 other Illustrations. 2d Edition. *In Press.*
- MACKENZIE.** The Pharmacopœia of the London Hospital
for Diseases of the Throat. 5th Edition, Revised by Dr. F.
G. HARVEY. \$1.00
- McBRIDE.** Diseases of the Throat, Nose, and Ear. A Clinical
Manual. With colored Illus. from original drawings. 2d Ed. \$6.00
- MURRELL.** Chronic Bronchitis and its Treatment. (Author-
ized Edition.) A Clinical Study. \$1.50
- POTTER.** Speech and its Defects. Considered Physiologically,
Pathologically, and Remedially. \$1.00
- WOAKES.** Post-Nasal Catarrh and Diseases of the Nose
Causing Deafness. 26 Illustrations. \$1.00

URINE AND URINARY ORGANS.

- ACTON.** The Functions and Disorders of the Reproductive
Organs in Childhood, Youth, Adult Age, and Advanced Life,
Considered in their Physiological, Social, and Moral Relations.
8th Edition. \$1.75

- ALLEN. Albuminous and Diabetic Urine. Illus. \$2.25
 BEALE. One Hundred Urinary Deposits. On eight sheets,
 for the Hospital, Laboratory, or Surgery. Paper, \$2.00
 HOLLAND. The Urine, the Gastric Contents, the Common
 Poisons, and the Milk. Memoranda, Chemical and Microscopi-
 cal, for Laboratory Use. Illustrated and Interleaved. 5th Ed. \$1.00
 LEGG. On the Urine. 7th Edition, Enlarged. Illus. \$1.00
 MEMMINGER. Diagnosis by the Urine. 23 Illus. \$1.00
 MOULLIN. Enlargement of the Prostate. Its Treatment and
 Radical Cure. Illustrated. \$1.50
 THOMPSON. Diseases of the Urinary Organs. 8th Ed. \$3.00
 THOMPSON. Calculous Diseases. The Preventive Treatment
 of, and the Use of Solvent Remedies. 3d Edition. .75
 TYSON. Guide to Examination of the Urine. For the Use of
 Physicians and Students. With Colored Plate and Numerous Illus-
 trations engraved on wood. 9th Edition, Revised. \$1.25
 VAN NUYS. Chemical Analysis of Healthy and Diseased
 Urine, Qualitative and Quantitative. 39 Illustrations. \$1.00

VENEREAL DISEASES.

- COOPER. Syphilis. 2d Edition, Enlarged and Illustrated with
 20 full-page Plates. \$5.00
 GOWERS. Syphilis and the Nervous System. 1.00
 JACOBSON. Diseases of the Male Organs of Generation. 88
 Illustrations. \$6.00

VETERINARY.

- ARMATAGE. The Veterinarian's Pocket Remembrancer.
 Being Concise Directions for the Treatment of Urgent or Rare Cases,
 Embracing Semiology, Diagnosis, Prognosis, Surgery, Treatment,
 etc. 2d Edition. Boards, \$1.00
 BALLOU. Veterinary Anatomy and Physiology. 29 Graphic
 Illustrations. .80; Interleaved, \$1.25
 TUNSON. Veterinary Pharmacopœia. Including the Outlines of
 Materia Medica and Therapeutics. 5th Edition. \$2.25

WOMEN, DISEASES OF.

- BYFORD (H. T.). Manual of Gynecology. With 234 Illustrations,
 many of which are from original drawings. \$2 50
 BYFORD (W. H.). Diseases of Women. 4th Edition. 306
 Illustrations. Cloth, \$2.00; Leather, \$2.50
 DÜHRSSSEN. A Manual of Gynecological Practice. 105
 Illustrations. \$1.50
 LEWERS. Diseases of Women. 146 Illus. 3d Edition. \$2.00
 WELLS. Compend of Gynecology. Illus. .80; Interleaved, \$1.25
 WINCKEL. Diseases of Women. Translated by special authority
 of Author, under the Supervision of, and with an Introduction by,
 THEOPHILUS PARVIN, M.D. 152 Engravings on Wood. 3d Edition,
 Revised. In Preparation.
 FULLERTON. Nursing in Abdominal Surgery and Diseases
 of Women. 2d Edition. 70 Illustrations. \$1.50

COMPENDS.

From The Southern Clinic.

"We know of no series of books issued by any house that so fully meets our approval as these ?Quiz-Compendis?. They are well arranged, full, and concise, and are really the best line of text-books that could be found for either student or practitioner."

BLAKISTON'S ?QUIZ-COMPENDS?

The Best Series of Manuals for the Use of Students.

Price of each, Cloth, .80. Interleaved, for taking Notes, \$1.25.

☞ These Compendis are based on the most popular text-books and the lectures of prominent professors, and are kept constantly revised, so that they may thoroughly represent the present state of the subjects upon which they treat.

☞ The authors have had large experience as Quiz-Masters and attaches of colleges, and are well acquainted with the wants of students.

☞ They are arranged in the most approved form, thorough and concise, containing over 600 fine illustrations, inserted wherever they could be used to advantage.

☞ Can be used by students of *any* college.

☞ They contain information nowhere else collected in such a condensed, practical shape. Illustrated Circular free.

- No. 1. POTTER. HUMAN ANATOMY. Fifth Revised and Enlarged Edition. Including Visceral Anatomy. Can be used with either Morris's or Gray's Anatomy. 117 Illustrations and 16 Lithographic Plates of Nerves and Arteries, with Explanatory Tables, etc. By SAMUEL O. L. POTTER, M.D., Professor of the Practice of Medicine, Cooper Medical College, San Francisco; late A. A. Surgeon, U. S. Army.
- No. 2. HUGHES. PRACTICE OF MEDICINE. Part I. Fifth Edition, Enlarged and Improved. By DANIEL E. HUGHES, M.D., Physician-in-Chief, Philadelphia Hospital, late Demonstrator of Clinical Medicine, Jefferson Medical College, Phila.
- No. 3. HUGHES. PRACTICE OF MEDICINE. Part II. Fifth Edition, Revised and Improved. Same author as No. 2.
- No. 4. BRUBAKER. PHYSIOLOGY. Eighth Edition, with new Illustrations and a table of Physiological Constants. Enlarged and Revised. By A. P. BRUBAKER, M.D., Professor of Physiology and General Pathology in the Pennsylvania College of Dental Surgery; Demonstrator of Physiology, Jefferson Medical College, Philadelphia.
- No. 5. LANDIS. OBSTETRICS. Fifth Edition. By HENRY G. LANDIS, M.D. Revised and Edited by WM. H. WELLS, M.D., Assistant Demonstrator of Obstetrics, Jefferson Medical College, Philadelphia. Enlarged. 47 Illustrations.
- No. 6. POTTER. MATERIA MEDICA, THERAPEUTICS, AND PRESCRIPTION WRITING. Sixth Revised Edition (U. S. P. 1890). By SAMUEL O. L. POTTER, M.D., Professor of Practice, Cooper Medical College, San Francisco; late A. A. Surgeon, U. S. Army.

? QUIZ-COMPENDS ?—Continued.

- No. 7. **WELLS. GYNECOLOGY. A New Book.** By WM. H. WELLS, M.D., Assistant Demonstrator of Obstetrics, Jefferson College, Philadelphia. Illustrated. *Just Ready.*
- No. 8. **FOX AND GOULD. DISEASES OF THE EYE AND REFRACTION.** Second Edition. Including Treatment and Surgery. By L. WEBSTER FOX, M.D., and GEORGE M. GOULD, M.D. With 39 Formulæ and 71 Illustrations.
- No. 9. **HORWITZ. SURGERY, Minor Surgery, and Bandaging.** Fifth Edition, Enlarged and Improved. By ORVILLE HORWITZ, B.S., M.D., Clinical Professor of Genito-Urinary Surgery and Venereal Diseases in Jefferson Medical College; Surgeon to Philadelphia Hospital, etc. With 98 Formulæ and 71 Illustrations.
- No. 10. **LEFFMANN. MEDICAL CHEMISTRY.** Fourth Edition. Including Urinalysis, Animal Chemistry, Chemistry of Milk, Blood, Tissues, the Secretions, etc. By HENRY LEFFMANN, M.D., Professor of Chemistry in Pennsylvania College of Dental Surgery and in the Woman's Medical College, Philadelphia.
- No. 11. **STEWART. PHARMACY.** Fifth Edition. Based upon Prof. Remington's Text-Book of Pharmacy. By F. E. STEWART, M.D., PH.G., late Quiz-Master in Pharmacy and Chemistry, Philadelphia College of Pharmacy; Lecturer at Jefferson Medical College. Carefully revised in accordance with the new U. S. P.
- No. 12. **BALLOU. VETERINARY ANATOMY AND PHYSIOLOGY.** Illustrated. By WM. R. BALLOU, M.D., Professor of Equine Anatomy at New York College of Veterinary Surgeons; Physician to Bellevue Dispensary, etc. 29 graphic Illustrations.
- No. 13. **WARREN. DENTAL PATHOLOGY AND DENTAL MEDICINE.** Second Edition, Illustrated. Containing all the most noteworthy points of interest to the Dental Student and a Section on Emergencies. By GEO. W. WARREN, D.D.S., Chief of Clinical Staff, Pennsylvania College of Dental Surgery, Philadelphia.
- No. 14. **HATFIELD. DISEASES OF CHILDREN.** Second Edition. Colored Plate. By MARCUS P. HATFIELD, Professor of Diseases of Children, Chicago Medical College.
- No. 15. **HALL. GENERAL PATHOLOGY AND MORBID ANATOMY.** 91 Illustrations. By H. NEWBERRY HALL, PH.G., M.D., Professor of Pathology and Med. Chem., Chicago Post-Graduate Medical School; Mem. Surgical Staff, Illinois Charitable Eye and Ear Infirmary; Chief of Ear Clinic, Chicago Med. College.
- No. 16. **DISEASES OF NOSE AND EAR.** Illustrated. Same Author as No. 15.

Price, each, Cloth, .80. Interleaved, for taking Notes, \$1.25.

Handsome Illustrated Circular sent free upon application.

In preparing, revising, and improving BLAKISTON'S ? QUIZ-COMPENDS ? the particular wants of the student have always been kept in mind.

Careful attention has been given to the construction of each sentence, and while the books will be found to contain an immense amount of knowledge in small space, they will likewise be found easy reading; there is no stilted repetition of words; the style is clear, lucid, and distinct. The arrangement of subjects is systematic and thorough; there is a reason for every word. They contain over 600 illustrations.

Tyson's Practice of Medicine. Illustrated. Just Ready.

A Text-Book of the Practice of Medicine. With Special Reference to Diagnosis and Treatment. By JAMES TYSON, M.D., Professor of Clinical Medicine in the University of Pennsylvania; Physician to the Hospital of the University and to the Philadelphia Hospital; Fellow of the College of Physicians of Philadelphia, etc.

With Many Useful Illustrations.

Octavo. 1000 Pages.

Cloth, \$5.50; Sheep, \$6.50; Half Russia, \$7.50.

Dr. Tyson's qualifications for writing such a work are unequaled. It is really the outcome of over thirty years' experience in teaching and in private and hospital practice. As a teacher he has, while devoting himself chiefly to clinical medicine, occupied several important chairs, an experience that has necessarily widened his point of view and added weight to his judgment.

As an author Dr. Tyson has been more than usually successful, and by his book on "Examination of Urine," many thousands of which have been sold, has become known throughout the English-speaking world. The success of this little book lies in the fact that it is concise, simple, direct, broad. It furnishes the desired information and then stops. The same style has been largely used in the present work, and must be appreciated by the busy man and student.

Descriptive circulars and sample pages upon application.

QS W765h 1896

61140300R



NLM 05041944 8

NATIONAL LIBRARY OF MEDICINE