









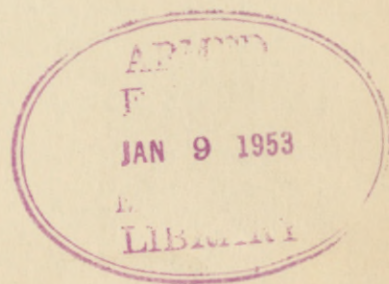






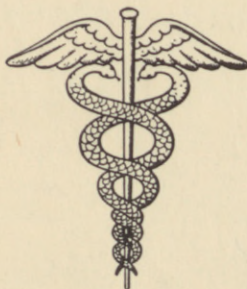*862*

# ABSTRACTS of ORTHOPEDIC SURGERY for 1949



OFFICE OF THE SURGEON GENERAL

DEPARTMENT OF THE ARMY

WASHINGTON, D. C.

October 1952







The Orthopedic Services in the Armed Forces again have undertaken to review the orthopedic literature. The following pages are submitted with the greatest humility and apologies for their tardiness and shortcomings. Three thousand and sixteen titles from world literature which seemed pertinent to orthopedic surgery were taken from the "Current List of Medical Literature" for 1949, published by the Armed Forces Medical Library. After a careful, discarding those that obviously did not pertain to orthopedic surgery, 1,000 titles were sent out to the editors of the various orthopedic journals. From these, 1,000 titles were selected and 1,000 abstracts were prepared to be included in this publication of orthopedic abstracts for 1949.

ABSTRACTS OF ORTHOPEDIC

SURGERY FOR 1949

Prepared by the Orthopedic Services

Of

The Medical Departments of the United States Armed Forces

Department of Defense

My deepest gratitude is extended to the editors of the various chapters, to Dr. Standa and Colonel Floyd Vergehnad for their help and encouragement, to the Armed Forces Medical Library for its unflinching cooperation, and to Mrs. Gene Baker for her untiring efforts in the preparation of this volume and its index.

WILLIAM A. THOMPSON  
Colonel, Medical Corps  
United States Army

2 June 1950



ABSTRACTS OF ORTHOPEDIC

SURGERY

Prepared by the Medical Services

ZWE  
168  
A164  
7 1949

The Medical Department of the United States Armed Forces

Department of Defense

c. 1



## P R E F A C E

The Orthopedic Services in the Armed Forces again have undertaken to review the orthopedic literature. The following pages are submitted with the greatest humility and apologies for their tardiness and shortcomings. Three thousand and sixteen titles from world literature which seemed pertinent to orthopedic surgery were taken from the "Current List of Medical Literature" for 1949, published by the Armed Forces Medical Library. They were culled, discarding those that obviously did not represent progress, and 1,594 titles were sent out to the editors. Some of these Armed Forces orthopedists were chiefs of services in large teaching hospitals with residents and secretarial help, some were isolated in small hospitals or in civilian residencies without help. All the titles were read and evaluated and 1,009 abstracts were submitted to the editor to be included in this publication of orthopedic abstracts for 1949.

My deepest gratitude is extended to the editors of the various chapters, to Dr. Shands and Colonel Floyd Wergeland for their help and encouragement, to the Armed Forces Medical Library for its un-failing cooperation, and to Mrs. Gwen Benick for her untiring efforts in the preparation of this volume and its index.

MILTON S. THOMPSON  
Colonel, Medical Corps  
United States Army

2 June 1952







ABSTRACTS OF ORTHOPEDIC SURGERY FOR 1949

EDITORIAL STAFF

EDITOR-IN-CHIEF

Milton S. Thompson, Colonel, MC, USA  
Brooke Army Hospital, Fort Sam Houston, Texas

ASSOCIATE EDITORS

Robert D. Anderson, Colonel, MC, Madigan Army Hospital, Tacoma, Washington  
Joseph D. Batch, Colonel, MC, Army and Navy Hospital, Hot Springs, Arkansas  
Ernest A. Brav, Colonel, MC, Letterman Army Hospital, San Francisco, Calif.  
Clarence R. Brown, Lt. Col., MC, Percy Jones Army Hospital, Battle Creek, Mich.  
Robert S. Brua, Colonel, USAF (MC), Rodriguez Army Hospital, Puerto Rico  
Knox Dunlap, Colonel, MC, Du Pont Institute, Wilmington, Delaware  
Alfred A. Grebe, Colonel, MC, Gorgas Hospital, Ancon, Canal Zone  
Irvine G. Jordan, Major, MC, Oschner Clinic, New Orleans, Louisiana  
Robert S. Lockwood, Lt. Col., MC, PMS and T, Omaha, Nebraska  
Harold S. McBurney, Colonel, MC, Fitzsimons Army Hospital, Denver, Colorado  
Carl M. Rylander, Colonel, MC, Tripler Army Hospital, Hawaii  
Albert W. Shiflet, Colonel, MC, St. Louis University, St. Louis, Missouri  
August W. Spittler, Colonel, MC, Walter Reed Army Hospital, Washington, D. C.  
Lloyd W. Taylor, Lt. Col., MC, Washington University, St. Louis, Missouri  
Victor B. Vare, Jr., Lt. Col., MC, Valley Forge Army Hospital, Phoenixville, Pa.  
Winston H. Vaughan, Colonel, MC, Wm Beaumont Army Hospital, El Paso, Texas  
William R. Willis, Major, MC, U. S. Army Hospital, Fort Benning, Georgia

ASSISTANT EDITORS

Resident and Consultant Staffs of the Orthopedic Services of the Hospitals  
of the  
United States Armed Forces

ADVISORY EDITOR

Alfred R. Shands, Jr., M. D.







## CONTENTS

CHAPTER	PAGE
I Diseases of Growing and Adult Bone .....	1
II Congenital Deformities.....	5
III Tumors of Bone and of Synovial Membrane.....	21
IV Conditions Involving the Hip Joint.....	40
V Conditions Involving the Foot and Ankle.....	56
VI Congenital Dislocations of the Hip.....	66
VII Tuberculosis of Bones and Joints.....	69
VIII Infections of Bones and Joints.....	72
IX Chronic Arthritis.....	78
X Infantile Paralysis.....	84
XI Infantile Paralysis: Research.....	89
XII Poliomyelitis.....	100
XIII Neuromuscular Disorders Exclusive of Poliomyelitis.....	106
XIV Fractures.....	112
XV Fracture Deformities.....	126
XVI Conditions Involving the Knee Joint.....	133
XVII Conditions Involving Neck, Shoulder and Arm.....	141
XVIII Conditions Involving Arm, Elbow, Forearm, Wrist and Hand....	158
XIX Conditions Involving the Spine and Thorax Exclusive of the Lower Back.....	170
XX The Low Back.....	174
XXI Amputations, Apparatus, and Technic.....	193
XXII-A Research.....	206
XXII-B Research.....	220
Subject Index.....	229
Author Index.....	261







## CHAPTER I

### DISEASES OF GROWING AND ADULT BONE

BY

C. R. Brown, Lt. Colonel, M. C., U. S. A.  
And Staff

This chapter deals with some of the normal physiologic processes occurring in bone and some of the pathologic conditions affecting normal physiology. This subject, a most interesting one, has stimulated relatively few publications during the year. Some of the material represents preliminary reports and therefore must stand the test of time before final evaluation.

A review of the histogenesis of cartilage and bone is given by Streeter (1), and Lorch (2) discusses the various laboratory findings regarding the role of phosphatase in the bio-chemical and histo-chemical mechanism of ossification. Findings indicate that extra-cellular phosphatase is necessary for ossification and it appears to be necessary also for fiber formation at the site of healing.

In a roentgenographic study of 100 healthy premature infants from birth to 8 months, Glaser (3) finds that double contour, cupping, and spurring of long bones are normal during the process of growth.

The problem of controlling epiphyseal growth is one of considerable interest. Lindsay (4) gives a review of the development of the present knowledge of the subject and Blount and Clarke (5) make a preliminary report on a continuation of the work of Haas in which stapling was used to arrest temporarily the growth of certain long bones.

Hirsch (6) writes on growth under abnormal conditions based on a study of 50 infants who underwent deprivation of food and sunlight for 3 months during the siege of Jerusalem; only 5 lost weight, all increased in height, 32 grew normally, but 18 increased in length, double and even triple the expected increase for age and time elapsed. The time of deprivation was too short to retard or arrest growth but instead acted as a stimulus. A pathologic study of bone changes occurring in inanition and specific nutritional deficiencies is described by Follis (7).

A method of prediction of unequal growth of lower extremities in anterior poliomyelitis is published by Stinchfield, Peidy, and Barr (8) The greatest discrepancy in length was found in the extremity showing the greatest difference in muscle strength.

Arteriovenous fistulae made between the external iliac artery and vein produced an increase in circumference and length of the tibia and femur in young dogs. Janes and Musgrove (9) present the question of its clinical application in leg lengthening in children.



A summary of the findings in 16 cases of dysplasia epiphysialis punctata is reported by Fairbank (10). The synonyms of this rare condition of infancy are stippled epiphyses and chondrodystrophia calcificans congenita. Orthopedic findings are multiple and the diagnosis depends upon radiographic examinations.

Ghormley and Clegg (11) review the bone and joint changes of hemophilia and suggest the possible etiology of hemophilic pseudo-tumor. MacRae (12) suggests that osteitis fibrosa disseminata may be due to parathyroid hormone imbalance, and Winter and Maiocco (13) find no significant correlation between osteogenesis imperfecta and odontogenesis imperfecta.

A summary of the current thought on the treatment of tibial torsion at various ages is written by Hutter and Scott (14), and a summary of the known treatments for many childhood orthopedic problems is compiled by Pease (15).

Osteoporosis following burns is the title of an article by Owens (16) which is a preliminary report on a series of burns, chiefly in babies and children, treated systemically and locally with penicillin, suspension immobilization and exposure to air at ward temperature.

Osteoporosis in elderly females is reviewed by Fineberg, Collins and Altschul (17) in the light of present day concepts that the dynamic state of bone is controlled by (1) hormonal factors, (2) stress and strain, and (3) nutrition.



## BIBLIOGRAPHY

1. Streeter, G. L.: Developmental horizons in human embryos; a review of the histogenesis of cartilage and bone, *Contr. Embryol. Carnegie Inst.*, 33: 149-168, Feb 1949
2. Lorch, I. J.: Alkaline phosphatase and the mechanism of ossification, *J. Bone Surg.*, 31 B: 84-94, Feb 1949
3. Glaser, K.: Double contour, cupping, and spurring in roentgenograms of long bones in infants, *Am. J. Roentg.*, 61: 482-492, Apr 1949
4. Lindsay, D. T.: Control of human epiphyseal growth, *Bull. Univ. Minnesota Hosp.*, 20: 450-469, Apr 8, 1949
5. Blount, W. P., and Clarke, G. R.: Control of bone growth by epiphyseal stapling; a preliminary report, *J. Bone Surg.*, 31 A: 464-478, July 1949
6. Hirsch, W.: Growth in infants under abnormal conditions, *Ann. paediat.*, Basel, 72: 339-343, May-June, 1949
7. Follis, R. H., Jr.: Nutrition and bone disease, *J. Mount Sinai Hosp.*, N. York, 16: 1-13, May-June, 1949
8. Stinchfield, A. J., Reidy, J. A., and Barr, J. S.; Prediction of unequal growth of the lower extremities in anterior poliomyelitis, *J. Bone Surg.*, 31 A: 478-486, July 1949
9. Janes, J. M., and Musgrove, J. E.: Effect of arteriovenous fistula on growth of bone; preliminary report, *Proc. Mayo Clin.*, 24: 405-408, Aug 3, 1949
10. Fairbank, H. A. T.: Dysplasia epiphysialis punctata; synonyms; stippled epiphyses, chondrodystrophia calcificans congenita (Hunerman), *J. Bone Surg.*, 31 B: 114-122, Feb 1949
11. Ghormley, R. K., and Clegg, R. S.: Bone and joint changes in hemophilia; with report of cases of so-called hemophilic pseudo-tumor, *J. Bone Surg.*, 30 A: 589-600, July 1948
12. MacRae, D. J.: Osteitis fibrosa disseminata, *Brit. M. J.*, 1: 389-392, Mar 5, 1949
13. Winter, G. R.; and Maiocco, P. D.: Osteogenesis imperfecta and odontogenesis imperfecta, *Oral Surg.*, 2: 782-798, June, 1949
14. Hutter, C. G., Jr., and Scott, W.: Tibial torsion, *J. Bone Surg.*, 31 A: 511-518, July 1949



15. Pease, C. N.: Pediatric orthopedic surgery, Surg. Clin. N. America, 29: 281-299, Feb 1949
16. Owens, N.: Osteoporosis following burns, Brit. J. Plastic Surg., 1: 245-256, Jan 1949
17. Fineberg, S. K., Collins, H. A., and Altschul, A.: Osteoporosis in elderly females, Harlem Hosp. Bull. (N.Y.) 2: 1-8, June 1949



## CHAPTER II

### CONGENITAL DEFORMITIES

By

Carl M. Rylander, Colonel, M. C., U. S. A.

The first group of references pertain to the etiology of congenital defects. Dekking (1) writes that toxoplasmosis may cause various congenital anomalies of the eye. Landtman (2) made comparative studies of the relation between maternal conditions during pregnancy and congenital malformations of the foetus. In the mothers with malformed children, the average age, the percentage of previous abortions, the incidence of ante-partum hemorrhage and the presence of various morbid states, including acute infectious disease, was higher than in the control group. He assumes that these morbid states may be involved in the pathogenesis of foetal malformations.

Abel and Van Dellen (3) wrote letters to mothers and found 87 per cent of babies born from mothers who had rubella in the first trimester of pregnancy, and 42 per cent of those from mothers who had it in the second trimester, had congenital defects. Chief among them were cataract, heart disease, and mental retardation. Beswick, Warner, and Warkany (4) saw 8 children whose congenital anomalies could be attributed to maternal rubella in the first trimester of pregnancy. Deafness was the most frequent defect. Kiskadden, Schechtman and Brock (5) give a rather complete review of the various theories as to the cause of congenital defects.

Lelong (6) wants to demonstrate that genetic factors are not the only causative agents. Many malformations are acquired in utero and he lists what genetic and nutritional factors will do and discusses hormonal, physical, infectious, and mechanical factors. Jentzer (7) describes a visit to Warkany in Cincinnati and the malformations he produced in rats by vitamin deficiencies. Thelander (8) reports a case of severe pneumococcal meningitis in an infant 2½ months old, treated by penicillin and sulfadiazine, with resultant microcephalia, amentia, and death.

In an address to the Society of Radiologists, Brailsford (9) discussed the hereditary and environmental influences on congenital abnormalities. What the embryo needs for normal development he summarizes, are: (1) Equal temperature, (2) Protection from trauma, (3) Adequate removal of waste products. Sincock (10) presents a short review of our present knowledge of nonhereditary causative factors in congenital malformations, namely, lack of vitamins and minerals, application of acting rays and endocrine disturbance.

On the basis of vital statistics in Philadelphia and Muncie, Indiana, Lucy (11) feels that a pregnant mother who has had x-ray therapy of the



pelvis or rubella during pregnancy, should be aborted because of the great frequency of congenital deformities in the fetus.

Sensenig (12) writes a rather long and technical article dealing with the embryology of the human vertebral column.

The second group of references in this chapter can be included under the heading of deformities. Forrest (13) analyzes 31 cases of bowlegs in children, 4 of which were operated upon and 27 of which were treated only with cod-liver oil and gentle home manipulation. All were corrected.

Cholmeley (14) writes a case study extending over about six years with numerous operative procedures for congenital bowing of the tibia.

Heyman and Herndon (15) discuss congenital angulation of the tibia and present 3 cases of posterior angulation. The authors divide this condition into 3 groups. Group I has an anterior or antero-lateral angulation of the tibia and with this pseudarthrosis usually develops. The bone is small and sclerotic. Most people think that a primary defect exists in the tibia as a fibrocystic lesion, an associated neurofibromatosis or congenital deficiency or absence of the nutrient artery. Group II has anterior bowing associated with short calf muscles and with a severe and resistant equinus. They do not as a rule go to pseudarthrosis. With this they have other congenital anomalies. There is usually shortening of the leg below the knee and thickening of the tibia on the concave side. Group III has posterior or postero-medial angulation at the junction of the mid and lower thirds and the fibula is bowed. They have a severe calcaneus deformity with tight anterior and weak posterior muscles. The bone appears normal other than the thickening on the concave side. It is not likely to fracture. The prognosis is good with conservative treatment. The authors present 3 cases. They found only 2 reported in literature and feel that the cause is probably a primary shortening of the anterior muscles causing the posterior and postero-medial bowing. They think surgery should not be done, and treated their cases with massage, stretching, brace and stop joint, and obtained good results.

Moore (16) writes an excellent article in which he briefly reviews the past history of congenital pseudarthrosis. He divides the cases into two groups: (1) Pre-pseudarthrosis in which the long bone is found to be bowed, with a narrow apex and a medullary cavity which is obliterated or recurring, followed by a spontaneous or induced fracture, followed by pseudarthrosis. (2) Pseudarthrosis, which may vary from simple fibrous to frank nearthrosis. The author repairs these with delayed autogenous bone graft. The graft is taken and then replaced in its original bed and left there about 18 days. If left longer in small children, it tends to lose its identity. At the end of this time, the site of pseudarthrosis is prepared by excising all the fibrous tissue and sclerosed bone. The bones are then aligned by use of two Kirschner wires above and two below the site of the defect, keeping well away from it. These wires are then held in an Abbott bone lengthening apparatus and aligned. The ends of the tibia are split longitudinally as far as the nearest pin. The graft is then wedged



and placed into these splits, with all the new bone attached. In the fibula the graft is placed along it and held with wire sutures above and below. A long leg plaster cast is then applied. The pins and plaster are left in place until the medullary cavity appears in the graft which averages 4 to 6 months. A double bar caliper brace is then worn for 2 years. The author did this procedure on 8 patients, but 2 of them had 3 operations due to spontaneous fractures. Cafe-au-lait spots were present in 7 cases and neurofibromata were present in 2. Six cases had tibia and fibula involved, 1 case had the femur and 1 case had the ulna involved. One case was not one of pseudarthrosis but was a defect due to old osteomyelitis. All these cases developed union but 5 had been followed only 8 months and the other 3 for a longer period.

Khoo (17) reports a case of congenital pseudarthrosis of the tibia in which repeated bone graftings were unsuccessful and gives a comprehensive review of the various aspects of the condition, laying particular stress on etiologic factors and surgical treatment. It is concluded that congenital pseudarthrosis of the tibia is, in all likelihood, a variant of fragilitas ossium.

Rodriguez-Miranda et al (18) on the basis of 27 cases of congenital pseudarthrosis of the tibia seen over a period of 32 years, states that the prognosis is bad whether operation is postponed to age 15 or done in infancy.

A case of Marfan's syndrome or arachnodactyly in a negro is reported by Adams and Porter (19). This syndrome was first reported by Marfan in 1896. It is a condition in which the individuals are melancholic, asthenic, and have skeletal deformity and poor musculature. They have prominent supraorbital ridges, bossing of the frontal eminences, large impacted ears, and massive chins. The palate is high, arched and narrowed. There is increase in length of the extremities and the span often exceeds the height. The spider-like deformity of the hands is due to long, narrow metacarpal and phalangeal bones. The joints, especially the fingers, elbows and knees are hypermobile. Contractures may be present. They may have funnel-chest, pigeon breast, kyphosis and scoliosis. Over 50 per cent have ocular defects such as ectopia lentis, iridodonesis, shallow anterior chambers, myosis. They may have partial or complete dislocation of the lens. Congenital cardiovascular lesions are present in the majority of the cases and of these a patent foramen ovale was the most common one. The case reported had a low BMR which was refractory to treatment with thyroid.

Tandeta (20) discusses early diagnosis in causes of crippling. The author thinks that congenital dislocation of the hip is a poor name, but that it should be congenital dysplasia of the acetabulum, the dislocations coming at a later date. The earliest evidence is usually limitation of abduction of the hip. On x-ray you look for obliquity of the acetabulum, shallow socket, anteversion of the femoral neck and leg in development of the capital epiphysis, and subluxation or dislocation. Clubfoot is quite a common anomaly, occurring about once in 1000 births. Early treatment of



both conditions is indicated for best results.

Wurl (21) reports a case of third generation clubbing of fingers and toes. No cardiac or lung pathology was found.

Marton and Steinbrocker (22) report a case of congenital contracture of the fifth finger.

Congenital metatarsus varus has been recognized as a clinical entity only recently. Kite (23) considers it as a third of a clubfoot. He also feels that it is often associated with other congenital lesions. There seems to be some weakness of the peroneal muscles and the stronger anterior tibial muscle tends to pull the foot into more deformity. With the heel held firmly, the forefoot cannot be abducted to the midline. The author treats these cases by casts and wedgings as he does with clubfeet. Some correct very easily but some are quite resistant. One must take care not to over-correct as this will result in a flat foot. They should be followed over a long period of time as with the clubfoot case.

Etienne (24) outlines the classical principles of treatment of congenital clubfoot by manipulation and casts, but adds subcutaneous tenotomy of tendo Achilles at the end of the first month. He emphasizes the importance of continuing night splints for a long time.

Stone (25) writes a review of the history of clubfoot and reports the results of 39 cases treated by the Denis Browne splint.

Agerholm-Christensen (26) reports on 18 months experience with the Denis Browne splint in 45 clubfeet, 40 per cent of which are clinically normal. Thomson (27) writes of 9 years experience with a modification of this splint. He found that most of the failures were due to the parents. With better follow-up from the social service department, better results were obtained. The underlying causes of failures were due to: (1) Myo-dystrophia foetalis with short, small resistant feet. (2) A similar type foot but with a primus metatarsus varus. (3) A neurogenic clubfoot; these may be resistant or go to a calcaneo valgus foot. (4) Subluxation of the first metatarso-phalangeal joint. (5) Idiopathic clubfoot of small size but with a fat ankle and leg. (6) Cases which develop an extremely flat foot early. The length of the bar of the splint was shortened to the width of the hips. The plates were made to fit more snugly and the baby was fitted with a pair of boots, which were fastened to the splint and the toe cap was removed. In 9 years, 260 cases were treated with the Denis Browne splint and the recurrence rate was about 17 per cent.

Kendrick (28) gives an illustrated exposition on its use.

Storen (29) in a 32-page article in English describes the operation which he uses in severe degrees of clubfoot in older children and adults and cites cases and results. The operation is carried out in three stages: (1) Soft tissue operation with skin graft if necessary, (2) Tendo Achilles lengthening and wire through heel incorporated in plaster, (3) A T-shaped wedge osteotomy with very little removal of bone. Its advantages include



minimal discrepancy in foot size.

Catterall (30) reports twins who had one clubfoot each, one right, one left.

Symmetrical deformity of hands and feet in 3 children of one family is reported by Howard (31). Only the smallest digit was present. The author found no other reported cases.

A case of congenital hemiatrophy with partial dental aplasia, cutaneous pigmentation and talipes is reported by Calnan (32). The father had a history of having had shingles shortly after the estimated date of conception of the child. The author feels that this may be significant in the etiology.

Costantini et al (33) report a case of a 20-year old Algerian with multiple skeletal deformities and epileptic seizures.

Anomalies of bone, agenesis and accessory bones include an article by Simril and Trotter (34) reporting a case of bilateral true accessory bone of the elbow. Gross, microscopic and roentgenographic evidence support this interpretation. The name "os cubiti anterius" is suggested for the anomalous bone.

Milch (35) writes on "short radius." Madelung's deformity is an "idiopathic, progressive curvature resulting in a deformity of the wrist giving the appearance of an anterior (or more rarely a posterior) subluxation of the ulnar head." This can easily be distinguished from a short radius, which the author feels is a dislocation of the carpus on the ulna. In this article he reports several cases, most of them due to trauma, often in childhood. This may damage the distal radial epiphysis with irregular growth or stoppage of it, giving a relatively long ulna. Darrach's suggested resection of the distal ulna subperiosteally grows back, gives a wide wrist, and destroys the ulnar collateral ligament giving a weaker wrist. The author prefers doing a Z or V osteotomy of the shaft of the ulna a short distance proximal to the joint and fixation with a plate. Without good fixation nonunion may result.

Catterall (36) presents a case of gross deformity of the forearm so that the thumbs lay against the medial humeral epicondyles. X-ray showed complete absence of both radii.

Kutz (37) reports a unique case of congenital absence of patellae in which there no other abnormalities. A brief review of the literature is presented with special reference to the explanation of the cause of this developmental defect.

Gonzalezulloa and Gonda (38) report a case of Klippel-Feil syndrome. They summarize it as a syndrome characterized by (a) absence or shortening of the neck, (b) limitation of motion of the head, (c) low hairline and with x-ray changes showing fusion of all or several cervical segments. At times with this there may be spina bifida of one or all of the cervical segments.



Exposito et al (39) review the literature and cite a case of cleidocranial dysostosis in a child 8 months old.

Jacobs (40) reports a case of supernumerary rib arising from the 3rd dorsal vertebra found at autopsy.

Thompson, Walker, and Weens (41) present 4 cases of iliac horns, a manifestation of hereditary arthrodysplasia.

A brief treatise on what age a child should reach before surgery should be done for various malformations is presented by L. G. (42). For example, he recommends that polydactylism should be operated upon at 6 to 12 months, and syndactylism at 4 to 6 years of age.

On muscle defects, Steindler (43) gives an excellent discussion of arthrogyrosis. Arthrogyrosis implies a deformity which is essentially produced by distortion of a number of joints of the body. There is a fatty and fibrous degeneration of muscles. These changes appear to occur late in embryonic life when the muscle fibers are already differentiated. There is a secondary shrinkage of capsular apparatus resulting in contractures. The outstanding symptom is the rigidity of one or more of the joints, but it never gives the impression of an absolute block. The various types of contractures are briefly described. The treatment recommended is, first, conservative: manipulation, wedge casting, traction and braces, and secondly, for the more resistant cases, surgical correction of the deformities. Timely treatment of this deformity is worthwhile. Only a few very severe cases derived no material benefit from treatment as outlined.

Griffith (44) presents a case of progressive myositis ossificans in a girl of 3 years, with notes on theories of etiology, clinical features, and differential diagnosis. Epstein (45) discusses amyotonia congenita with 3 cases presented and the clinical and pathological features reviewed. The findings suggest that the syndrome of amyotonia congenita is due to a congenital deficiency of the entire motor apparatus from the cells of Betz of the precentral convolution to the motor end plates and striated fibers of the effector mechanism.

Roth (46) reviews the possibility of a relationship between hereditary ataxia and peroneal muscular atrophy on the basis of 2 families in which Friedreich's ataxia and peroneal muscular atrophy occurred.

Beichl (47) cites the case of a 10-year old boy with a congenital defect of his deltoid.

Parisel (48) in his paper and Van Cauwenberghe (49) in its discussion cover the subject of myodystrophia foetale deformante. Two cases are presented, one 7 and one 9 years old, with marked atrophy of the musculature of the shoulder girdle and upper limbs and also to a lesser degree, of the lower limbs. Underlying these muscular lesions there is incomplete skeletal development.

On bone dystrophies there is a rather good brief discussion of infantile cortical hyperostosis by Sherman (50). The first case was recorded in



1930 and in 1945, Caffey and Silverman described four more. Author gives a brief summary of the condition. Onset is from 4-20 months of age. They have deep, painful soft tissue swellings associated with subperiosteal new bone. They have exacerbations and remissions but eventually have a cure. The symptoms may last for a period of 2 years or more. They have successive layers of new bone formed corresponding with the exacerbations. The cortex is absorbed from the inside so that the marrow cavity becomes larger but the total diameter of the bone is increased and the bone then appears osteoporotic. With growth this bone eventually goes back to normal.

Three case reports of osteopetrosis are presented by Dimson (51), Arden (52), and Harrel (53). Ribbing (54) describes diaphyseal sclerosis and hyperostosis affecting some few (1-4) long bones in four siblings. The condition does not seem to have been known previously. There are 5 articles included which deal with combined osseous and dermal dysplasias. Johnson and Falls (55) present a clinical and genetic study of 2 cases of Ehlers-Danlos syndrome based on a family pedigree of 123 persons of whom 21 men and 11 women had the syndrome. A plea is made by the authors, presumably dermatologists, for all physicians, particularly orthopedic surgeons, who often see the articular manifestations of the condition to note the other characteristics of the syndrome.

Fournier and Cockenpot (56) emphasize orthopedic interest of laxity of ligaments and articulations in Ehlers-Danlos syndrome and report a case of a child of 10 years.

Ronchese (57) reviews briefly a case reported 12 years ago and Turner (58), who felt that the condition was rather rare because he found less than 50 cases reported, describes a case of his own. Weber (59) discusses various reported cases of Ehlers-Danlos syndrome.

Four articles on osteogenesis imperfecta are included. Pelner and Cohen (60) write on 2 cases of the "tarda" type, also called fragilitas ossium by some authors. The literature is reviewed. Wyllie and Schlesinger (61) report 2 cases who were seen because of delay in walking and did not have fractures. Both had laxity of ligaments which is often present in these cases. In one case, the father and one uncle had had many fractures and another uncle had blue sclerae. The grandparents were apparently normal. Bailey (62) reports a case and Sichel (63) presents one of the Vrolik type of osteogenesis imperfecta congenita in a patient 5 months old. Halliday (64) describes an unusual case of bone dystrophy in which a positive diagnosis was not made.

Several articles on dwarfism are abstracted. Two are written by Fairbank (65), (66). The first, entitled gargoylism, points out that this type of chondro-osteo-dystrophy is characterized not only by dwarfism but also by a heavy, ugly facies, corneal opacities, mental deficiency, kyphosis, distention of the abdomen, and enlargement of the liver and spleen. To determine the characteristics of this disease the author has selected 50 reported cases of the disease for study. A discussion of etiology, clinical signs, radiographic appearances, progress, pathology, and diagnosis is presented. Three cases are presented with photographs of patients and x-ray



findings. The second deals with the Morquio-Brailsford type. This disorder is characterized by dwarfism with shallowness of the vertebral bodies, marked kyphosis, sometimes angular increase of the spinal curve at the dorsolumbar junction, and progressive changes in the femoral head and acetabulum in a child of normal intelligence. Hereditary influences are seldom apparent, whereas familial influences are common. Both sexes are affected but males slightly more than females. The cause of the disease is unknown. The clinical characteristics, the radiographic appearance, pathology, and differential diagnosis of the disease are discussed. Four cases with photographs are presented. Houet (67) reports 3 cases of gargoylism and at autopsy finds abnormal lipoid tissue as encountered in the idiotism of Tay-Sachs (lecithin).

Ernould (68) describes the polydystrophy of Hurler, congenital, progressive, symmetrical skeletal deformities (gargoylism). His pathogenic hypothesis is that it represents a vitiation of hypophyseal thyroid stimulating hormone. He suggests x-ray treatment to stimulate the hypophysis and administration of thyroid extract.

Reichard (69) reports a case of twins with chondrodystrophy showing amniotic deformities which support his assumption that amniotic pressure may have a pathogenetical role. This could cause a decrease in blood supply to the foetus just at the period of cartilage development. He points out that in addition to those rare and grave cases of achondroplasia that are dwarfs, the less grave, partial atypical achondroplasia must be diagnosed. Micromelia, i.e., shortness of limbs, is an essential symptom.

Mackenzie (70) in an article on dwarfism discusses those conditions amenable to endocrine therapy. Hone and Magarey (71) report a case of cretinism in a newborn baby following thirouracil therapy in the mother. Smallpiece (72) reports two cases of cretinism with goitre in infancy treated successfully with thyroid.

Potter (73) presents a severe case of Ollier's dyschondroplasia demonstrating extensive bilateral defects with a predominant basic unilateral pattern. The diagnosis was based on tuber-like phalangeal chondromata of the left hand and characteristic radio-translucencies in the metaphyses of the long bones. Potterfield and Gonzales (74) report a case of Ollier's disease.

The congenital neuro-orthopedic disorders encompass various disorders. An excellent article on transverse myelopathy in achondroplasia is written by Vogl and Osborne (75). A review of the literature, discussion of previously observed cases and the observation of a new case indicate that lesions of the cord are not infrequent in achondroplastic adults. They are related to the congenital narrowness of the spinal canal, which just accommodates the cord, to the virtual exclusion of the subarachnoid and epidural space. A dorso lumbar kyphosis of varying degree (due to a wedge-shaped deformity of one or two vertebral bodies between the 12th thoracic and 2nd lumbar, which is typical of the achondroplastic spine) predisposes to localized osteoarthritis with osteophyte formation above the deformed vertebra. The osteophytes encroach on the constricted spinal canal and give rise to compression of the



nutritive vessels and/or the nerve roots, with symptoms of root pain and/or progressive paraplegia. Early recognition of the connection between the lesion of the cord and the underlying skeletal anomaly permits effective and relatively simple treatment, namely, decompression laminectomy. It is imperative to extend the laminectomy above the malformed vertebra, to reach the level of the osteoarthritic osteophyte formation. This is especially important when there is no sensory level to indicate the exact site of the lesion. Without laminectomy, progressive compression of the cord with eventual paraplegia appears inevitable in such cases. In the case presented, the effect of the laminectomy was particularly prompt and gratifying, probably because it was done before any irreversible lesion of the cord had developed. In achondroplastic infants, the entire chain of unfortunate events may be avoided by the institution of orthopedic measures before the child assumes the upright position. In this way, compensation of the dorsolumbar kyphosis may be promoted and formation of a gibbus prevented. There may well be living today, perhaps in institutions, paraplegic achondroplastic dwarfs who are regarded as incurable. While they might have been saved by early operation, it is possible that some may still be benefited by decompression laminectomy.

A good review of the literature and case report of spina bifida with hydrocephalus in siblings is given by Chapman (76). Mills (77) reports a case of mother and child with spina bifida and meningocele, and Voris (78) writes a neurosurgical article on spina bifida and hydrocephalus.

Goldman (79) reports a rare case of hemivertebrae with meningocele. McKenzie and Dewar (80) discuss scoliosis with paraplegia and review 5 cases of their own, and 36 from the literature. These 41 cases have been studied with the object of determining the etiology of scoliosis, the reason the cord compression sometimes develops, and the results of conservative and operative treatment of such compression of the cord. The cause of paraplegia is nearly always compression of the spinal cord by the dura, which, in severe scoliosis, is under longitudinal tension because of its firm attachment to the foramen magnum above and the sacrum below. Such tension, resisting displacement of the spinal cord from the straight line, may be shown to cause incomplete spinal block even when there is no paralysis. When paralysis occurs, it usually develops during the years of most rapid growth, the tight dura being unable to accommodate itself to the rate of growth of the spinal column; cord compression is probably increased by narrowing of the dural sac by rotational displacement. The most striking results have been secured by laminectomy with section of the dura and sometimes division of dentate ligaments and tight nerve roots. After such division there is evidence of release of compression; the cord herniates through the dural slit and spinal pulsation returns.

It is important to control bleeding in order to avoid postoperative compression by blood clot and to prevent leakage of cerebro-spinal fluid through the arachnoid. It is unwise to perform spinal fusion at the same time as decompression because it increases the danger of hematoma formation. Conservative treatment of scoliosis with paraplegia should not be continued for long because prolonged compression causes irreversible changes. In 3 cases the paraplegia was not due to dural compression; one was found to be a syringomyelia, one was due to pressure of a bone spur, and one was due to



a congenital tight band of developmental origin which might have caused the scoliosis as well as the paralysis.

Arkin (81) writes on the mechanism of structural changes in scoliosis. Deformities of the vertebrae occur only before growth is complete, therefore the deformity must be related to the epiphysis. Cobb showed that idiopathic scoliosis does not occur if children are kept in bed. Haas showed that compression of an epiphyseal plate with a wire will arrest its growth. The author shows by diagrams a marked force exerted on the concave side of the vertebral bodies. He also shows by diagrams that the support of the vertebral body is on four points. With lateral bending, the support is on the two points closest to the concave side. If one of these points is depressed, then the support may be shifted to the point on the other side. This would tend to give rotation. The spinous process goes toward the concave side. The lordotic curve of the cervical and lumbar regions takes pressure off the bodies but the kyphosis of the dorsal area makes this the danger zone. For a full appreciation of this article, the original with its diagrams should be read.

Wright and Samitz (82) present a case of undernourishment, scleroderma and contractures of digits.

Abrahamson and Abrahamson (83) in the Irish Journal of Medical Science report a case of pulmonocardiac failure from chest deformity, and correlate the clinical and pathological findings.



## BIBLIOGRAPHY

1. Dekking, H. M.: Toxoplasmosis as a cause of congenital defects, *Ophthalmologica*, Basel, 117: 1-7, Jan 1949
2. Landtman, B.: On the relationship between maternal conditions during pregnancy and congenital malformations, *Arch. Dis. Childh.*, Lond., 23: 237-46, Dec 1948
3. Abel, S., and Van Dellen, T. R.: Congenital defects following maternal rubella, *J. Am. M. Ass.*, 140: 1210-2, Aug 13, 1949
4. Beswick, R. C., Warner, R., and Warkany, J.: Congenital anomalies following maternal rubella, *Am. J. Dis. Child.*, 78: 334-48, Sept 1949
5. Kiskadden, W. S., Schechtman, A. M., and Brock, C.: Theories of the etiology of congenital deformities, *Surg. Gyn. Obst.*, 88: 1-14, Suppl., Jan 1949
6. Lelong, M.: Etiologie des malformations congenitales, *J. prat.*, Par., 63: 61-3, Feb 10, 1949
7. Jentzer: Les malformations congenitales, *Praxis*, Bern, 38: 487, May 26, 1949
8. Thelander, H. F., and Boebel, G.: Microcephalia as a complication of pneumococcic meningitis, *Am. J. Dis. Child.*, 77: 642-6, May 1949
9. Brailsford, J. F.: Congenital abnormalities and their radiographic demonstration, *Radiography*, Lond., 15: 217-21, Oct 1949
10. Sincock, H. A.: Etiology of congenital malformations, *Wisconsin M. J.*, 48: 427-9, May 1949
11. Lucy, R. F.: A study of congenital malformations, *J. Lancet*, 69: 80, March, 1949
12. Sensenig, E. C.: The early development of the human vertebral column, *Contr. Embryol. Carnegie Inst.*, 33: 21-42, 5 pl., Feb 1949
13. Forrest, H. J.: Physiologic bowlegs, *Arch. Pediat.*, N. Y., 66: 349-51, Aug 1949
14. Cholmeley, J. A.: Congenital bowing of the tibia, *Proc. R. Soc. M.*, Lond., 41: 850-52, Dec 1948
15. Heyman, C. H., and Herndon, C. H.: Congenital posterior angulation of the tibia, *J. Bone Surg.*, 31-A: 571-80, July 1949
16. Moore, J. R.: Delayed autogenous bone graft in the treatment of congenital pseudarthrosis, *J. Bone Surg.*, 31-A: 23-39, Jan 1949



17. Khoo, F. Y.: Congenital pseudo-arthritis of the tibia and its relation to fabilitas ossium; report of a case and review of the literature, *Am. J. Dis. Child.*, 77: 201-16, Feb 1949
18. Rodriguez-Miranda, J. V., Minuyin, A., and Munigurria, C. J.: Seudoartrosis congenita de la tibia; tibia curva congenita, *Prensa med. Argent.*, 36: 220-3, Feb 4, 1949
19. Adams, R. A., and Porter, W. B.: Marfan's syndrome; report of a case, *South. M. J.*, 42: 844-8, Oct 1949
20. Tandeta, M.: Early diagnosis in congenital causes of crippling, *Clin. Proc. Child. Hosp., Wash.*, 5: 267-75, Sept 1949
21. Wurl, O. A.: Hereditary clubbing of the fingers and toes; case report, *Mil. Surgeon*, 105: 217-9, Sept 1949
22. Marton, R., and Steinbrocker, O.: Congenital contracture of the fifth finger, *N. Y. State J. M.*, 49: 1064-6, May 1, 1949
23. Kite, J. H.: Congenital metatarsus varus, *J. M. Ass., Georgia*, 38: 45-9, Feb 1949
24. Etienne, E., Daude, P., and Picard, J. J.: Les principes du traitement du pied bot congenital, varus equin, *Montpellier med.*, 35-36; 27 Jan-Feb, 1949
25. Stone, M. M.: El tratamiento de los talipes equinovarus congenito con la ferula modificada de Denis Browne, *Rev. cubana pediat.*, 21: 200-12, Apr 1949
26. Agerholm-Christensen, J.: On Denis Browne's treatment of clubfoot, *Acta orthop. scand.*, 19: 134-42, 1949
27. Thomson, S. A.: The treatment of congenital clubfoot; 9 years experience with a modification of Denis Browne method and splint, *J. Bone Surg.*, 31 A: 431-4, Apr 1949
28. Kendrick, R. E.: Congenital talipes equinovarus; treatment with the modified Denis Browne splint, *U. S. Nav. Bull.*, 49: 730-5, July-Aug 1949
29. Storen, H.: Operative treatment of clubfoot in older children and adults, *Acta orthop. scand.*, 18: 233-65, 1948-49
30. Catterall, R. C. F.: Symmetrical talipes equinovarus in identical twins, *Proc. R. Soc. M., Lond.*, 42: 93, Feb 1949
31. Howard, W. T.: Congenital symmetrical deformity of both hands and feet, *Memphis M. J.*, 24: 57, Mar 1949
32. Calnan, W. L.: Congenital hemiatrophy associated with other congenital defects, *Brit. M. J.*, 2: 56-8, July 9, 1949



33. Costantini, Le Genisskel and Durand: Un cas de malformations congenitales multiples du squelette, *J. radiol. electr.*, 30: 299, 1949
34. Simril, W. A. and Trotter, M.: An accessory bone and other bilateral skeletal anomalies of the elbow, *Radiology*, 53: 97-100, July 1949
35. Milch, H.: Short radius, *Arch. Surg.*, 59: 856-69, Oct 1949
36. Catterall, R. C. F.: Congenital deformity of the wrists, *Proc. R. Soc. M., Lond.*, 42: 600, Aug 1949
37. Kutz, E. R.: Congenital absence of the patellae, *J. Pediat. S. Louis*, 34: 760-2, June 1949
38. Gonzalezulloa, M., and Gonda, T. F.: Klippel-Feil syndrome; review of the literature and report of a case, *Plastic and Reconstr. Surg.*, 4: 109-13, Jan 1949
39. Exposito, L., Rojas, G., and Cabrales, G.: Disostosis cleidocraneana-pelvica o enfermedad de Pierre-Marie y Sainton, *Pediat. Americas, Mex.*, 7: 82-6, Feb 1949
40. Jacobs, S.: A supernumerary rib, *Am. Rev. Tuberc.*, 59: 76, Jan 1949
41. Thompson, E. A., Walker, E. T. and Weens, H. S.: Iliac horns; an osseous manifestation of hereditary arthrodysplasia associated with dystrophy of the fingernails, *Radiology*, 53: 88-92, July 1949
42. L.,G.: A quel age operer les malformations du nouveau-ne et de l'enfant? *J. prat., Par.*, 63: 127, March 17, 1949
43. Steindler, A.: Arthrogryposis, *J. Internat. Coll. Surgeons*, 12: 21-5, Jan-Feb, 1949
44. Griffith, G.: Progressive myositis ossificans, report of a case, *Arch. Dis. Childh., Lond.*, 24: 71-4, March 1949
45. Epstein, J. A.: Amyotonia congenita; a report of three cases with a review of the literature, *J. Mount Sinai Hosp., N. York*, 16: 149-74, Sept-Oct, 1949
46. Roth, M.: On a possible relationship between hereditary ataxia and peroneal muscular atrophy, with a critical review of the problems of intermediate forms in the degenerative disorder of the central nervous system, *Brain, Lond.*, 71: 416-33, Dec 1948
47. Beichl, L.: Angeborener Defekt des Musculus deltoideus, *Wein. med. Wschr.*, 99: 274, June 25, 1949
48. Parisel, F.: La myodystrophie foetale deformante, *Acta orthop. belg.* 14: 320-8, Dec 1948



49. Van Cauwenberghe, R.: La myodystrophie foetale deformante, *Acta orthop. belg.*, 15: 24, Jan 1949
50. Sherman, M. S.: Infantile cortical hyperostosis, *Proc. Inst. M. Chicago*, 17: 307, Apr 15, 1949
51. Dimson, S. B.: Albers-Schonberg disease, *Proc. R. Soc. M. Lond.*, 42: 77-80, Feb 1949
52. Arden, G. P.: Generalized osteopetrosis, *Proc. R. Soc. M., Lond.*, 42: 95, Feb 1949
53. Harrel, J. A., Jr., Osteopetrosis, *J. Pediat.*, S. Louis, 33: 783-7, Dec 1948
54. Ribbing, S.: Hereditary, multiple, diaphyseal sclerosis, *Acta radiol.*, Stockh., 31: 522-36, June 30, 1949
55. Johnson, S. A. M., and Falls, H. F.: Ehlers-Danlos syndrome; a clinical and genetic study, *Arch. Derm. Syph. Chic.*, 60: 82-105, July 1949
56. Fournier, A., and Cockenpot, F.: Syndrome d'Ehlers-Danlos; dilatation des bronches; retard staturo-pondéral, *J. sc. med. Lille*, 67: 92-6, Mar 13, 1949
57. Ronchese, F.: Dermofragility with dermohyperlaxity-hyperelasticity and arthrohyperlaxity; Ehlers-Danlos syndrome; additional data on a case reported 12 years previously, *Rhode Island M. J.*, 32: 80-3, Feb 1949
58. Turner, E. K.: Ehlers-Danlos syndrome in a child of 6 years, *Med. J. Australia*, 2: 165, July 30, 1949
59. Weber, F. P.: Combined osseous and dermal dysplasias; developmental osteodermophthies, *Med. Press, Lond.*, 221: 55, Jan 19, 1949
60. Pelner, L., and Cohen, J. N.: Osteogenesis imperfecta tarda, *Am. J. Roentg.*, 61: 690-8, May 1949
61. Wyllie, W. G., and Schlesinger, B.: Osteogenesis imperfecta presenting with delay in walking; two cases, *Proc. R. Soc. M., Lond.*, 42: 80-3, Feb 1949
62. Bailey, E. T.: Osteogenesis imperfecta in father and son, *Proc. R. Soc. M., Lond.*, 42: 278, Apr 1949
63. Sichel, M.: Un cas d'osteogenesis imperfecta congenital, type Vrolik, *J. radiol. electr.*, 30: 302, 1949
64. Halliday, J.: A rare case of bone dystrophy, *Brit. J. Surg.*, 37: 52-63, July 1949



65. Fairbank, H. A. T.: Gargoylism, *J. Bone Surg.*, 31 B: 302-8, May 1949
66. Fairbank, H. A. T.: Chondro-osteo-dystrophy, Morquio-Brailsford type, *J. Bone Surg.*, 31 B: 291-301, May 1949
67. Houet, R.: Une affection souvent meconnue, le gargoylisme, *Rev. Med. Liege*, 4: 84-9, Feb 1, 1949
68. Ernould, H. J.: Considerations sur le pathogenie endocrinienne de la polydystrophie de Hurler, gargoulisme, de l'achondroplasie et de certaines autres dystrophies, *Arch. fr. pediat.*, 6: 239-64, 1949
69. Reichard, J.: Das Problem der Achondroplasie (Chondrodystrophie). *Paediat. danub.*, Budap., 5: 214-23, Mar-Apr, 1949
70. Mackenzie, C. R. S.: A seminar on dwarfism, *McGill M. J.*, 18: 110-9, April 1949
71. Hone, G. M., and Magarey, I.: Cretinism associated with methyl thiouracil therapy, *Med. J. Australia*, 2: 524, Oct 30, 1948
72. Smallpiece, V.: Cretinism with goitre in infancy; two cases treated with thyroid, *Lancet, Lond.*, 1: 565-8, Apr 2, 1949
73. Potter, C. T.: Ollier's disease (dyschondroplasia), *Proc. R. Soc. M., Lond.*, 42: 559, July 1949
74. Potterfield, T. C. and Gonzales, J.: Ollier's dyschondroplasia, *J. Pediat.*, S. Louis, 33: 705-9, Dec 1948
75. Vogl, A., and Osborne, R. L.: Lesions of the spinal cord (transverse myelopathy) in achondroplasia, *Arch. Neur. Psychiat.*, Chic., 61: 644-62, June 1949
76. Chapman, J. C. F.: The occurrence of spina bifida and hydrocephalus in siblings; a review of the literature and case report, *Am. J. Obst.*, 57: 761-4, Apr 1949
77. Mills, W. G.: A case of inherited spina bifida, *Brit. M. J.*, 1: 139, Jan 22, 1949
78. Voris, H. C.: Spina bifida and cranium bifidum, *J. Internat. Coll. Surgeons*, 11: 634-9, Nov-Dec, 1948
79. Goldman, I. R.: Congenital malformation of vertebrae, hemivertebrae, with aplasia of corresponding ribs, associated with meningomyelocele; a report of a case, *Arch. Path. Chic.*, 47: 153-9, Feb 1949
80. McKenzie, K. G., and Dewar, F. P.: Scoliosis with paraplegia, *J. Bone Surg.*, 31 B: 162-74, May 1949



81. Arkin, A. M.: The mechanism of the structural changes in scoliosis, *J. Bone Surg.*, 31 A: 519-28, July 1949
82. Wright, C. S., and Samitz, H. H.: Scleroderma with phagedena of the feet, *Arch. Derm. Syph. Chic.*, 60: 133, July 1949
83. Abrahamson, L. and Abrahamson, M. L.: Pulmonocardiac failure from chest deformity, with report of a case, *Irish J. M. Sc.*, Page 227-30, May 1949



## CHAPTER III

### TUMORS OF BONE AND OF SYNOVIAL MEMBRANE

By

W. R. Willis, Major, M. C., U. S. A.

Part A. General, classification, research, diagnostic considerations.

In his clinic, Compere (1) divides bone tumors into (1) those of nonosseous origin, including Ewing's tumor, multiple myeloma, and metastatic lesions, and (2) those related to osteogenesis, benign and malignant. He stresses early clinical diagnosis and no treatment without biopsy.

In an excellent paper entitled, "The Natural History of Malignant Diseases," Cade (2) deals with cancer in general and not particularly with cancer of the musculo-skeletal system. The hereditary occurrence of malignant disease in certain families is commented upon, particularly that of Napoleon, where grandfather, father and four children all died of cancer of the stomach. The spread of malignant disease and its treatment by surgery, x-ray, cytotoxic poisons, radioactive isotopes, and nonradioactive substances, is mentioned. The use of endocrines in the treatment and control of cancer is a promising method.

Moore (3) analyzes over 32,000 skeletal x-rays and pathological reports. Bone syphilis and osteomyelitis have declined. Traumatic conditions, bone tuberculosis, vitamin deficiencies, Paget's disease, and bone marrow malignant tumors have been fairly steady. Metastatic carcinoma to bone has shown a very marked rise. Little (4) writes on an article which deals with research in biology and its relation to cancer. Doctor Little explains the use of mice in his laboratory in that many generations of mice can be followed in a relatively short period of time. He has developed strains of mice, some of which are very cancer-resistant; others are very likely to develop cancer. Some develop a condition which may be related to battle fatigue, in that very loud noises will cause them to have convulsions and die. He names 6 broad fields in biological research having importance to the cancer problem: (1) The genetic analysis of the strains of mice, (2) endocrine imbalance, (3) tissue compatibility, (4) the relationship between the process of mutation and cancer, (5) the reaction of different kinds of animals and different strains to chemical processes which predispose to cancer, (6) the influence of parental generations on their offspring. The importance of having a standardized strain of mice for different types of work is emphasized in the same way that standardized drugs are used in everyday practice.

The importance of early diagnosis of tumors of the bone is stressed by Coley (5) who deplors the fact that the time interval between the early symptoms and diagnosis of bone sarcoma averages 4-5 months. X-rays and biopsy and full cooperation between roentgenologist, pathologist and surgeon are necessary for diagnosis. He lists confusion problems and briefly



differentiates between: (1) myositis ossificans and osteogenic sarcoma, (2) bone cysts, giant cell tumors and central chondroma, (3) Ewing's sarcoma and reticulum cell sarcoma, (4) eosinophilic granuloma and malignant tumors of bone, (5) metastatic cancer and plasma cell myeloma, (6) Paget's disease and bone sarcoma, (7) hyperparathyroidism and metastatic bone cancer, and (8) osteitis and Ewing's sarcoma.

The technic, indications and usefulness of needle biopsies of bone marrow of sternum, ilium and spinous processes are described by Weisberger and Heinle (6), Polson (7), Peters and Larson (8), and Rheingold et al (9).

Gladstone (10) presents a new method of biopsy of surface lesions, scrubbing them with a gelfoam sponge which is then processed as any surgical specimen. (Ed. Note: This method would appear to have a limited use in orthopedics.)

Renewed awareness of the transformation of benign cartilaginous growths into chondrosarcomas of the secondary type is emphasized by Coley and Higinbotham (11). Eight case reports are given. A more rapid growth, more pain and more calcific deposits in periodic x-rays are quite significant. There also may be erosion of cortex.

Horwitz (12) writes on the significance of bone cartilage debris in the synovial membrane in the early diagnosis of neuro-arthropathy. In 5 cases presented, the diagnosis was suggested by the pathologist much earlier than x-ray, clinical, and sometimes laboratory examination. X-ray findings usually suggested osteoarthritis early, but follow-up pictures were more characteristic of neuro-arthropathy. The most striking feature under the microscope is the presence of bone debris and cartilaginous fragments ground into and embedded in the synovial membrane and subsynovial tissues.

Part B. Advances in the treatment of malignant disease is the subject of an article by Rhoads (13). The steps in the development of some preparations used in the treatment of cancer are given. These steps include experimental work with mice, using spleen and barley extracts, vitamin B complex, folic acid and synthetic conjugates of folic acid, namely, diopperin and teropperin. The development of the use of nitrogen mustards is related. Some of the clinical uses of diopperin and teropperin in malignancy are reviewed, as well as the antagonists of folic acid. It was the conclusion that diopperin and teropperin do not have any anti-cancer effect, though there is a sense of well-being associated with its use. The development of folic acid antagonist in the treatment of neoplasms is reviewed very thoroughly with stress on aminopterin and a-methopterin. Aminopterin seems to have little specific effect on neoplastic cells, compared with normal cells, whereas a-methopterin seems to have some preferential injurious action on certain types of sensitive tumors. It is concluded that the most important field for investigation has been opened and it is hoped that newer materials having effect on neoplastic cells will be obtained.

Poppe (14) writes about the treatment of osteogenic sarcoma based on 20 cases with two ten-year survivals, one of whom had been treated by amputation and the other a 5-year old girl who had had only x-ray therapy, but who after ten years still had nonunion of an old fracture from radiation



necrosis. The author suggests x-ray therapy before any procedure of major surgery.

An excellent and informative article on chemotherapy of cancer is written by Reiman and Nishimura (15). Experiments in chemotherapy of cancer have generally been without much organization as compared with chemotherapy of infectious diseases. Intracellular chemistry and physics have to be dealt with in this relatively new field. Before any organized attack on this problem is made, the differences between normal and cancer cells must be well defined. Up to the present, these differences are not too well known. The classification of materials to be used in the chemotherapy of cancer is as follows: (1) Substances which interfere with mytosis, an example is given as colchicine which interferes with cell mytosis in a certain state. Because of this it was thought that this drug could be used prior to x-ray therapy with better results. However, the dosage to be used is toxic as is the case with other compounds tried. (2) Substances which select cancer cells such as dyes - up to the present no dye with selectivity for cancer cells has been found. (3) Differential growth inhibitors, most of which come under the heading of antimetabolites. These include teropperin. The use of this drug has been investigated recently and the theories of its action are given. A method for determining blood levels was developed. The use of isotopes in the future may answer some important questions. The general dosage and effects of teropperin are given with two case histories. (4) Selective cell poisons; these of the nitrogen mustards and the bacterial polysaccharides. The authors have dealt with the latter and discuss it. The polysaccharides produced hemorrhage and necrosis in tumors. Clinical trials have been made in approximately 100 patients.

Nitrogen mustard therapy is discussed by Roswit and Kaplan (16) and Wintrobe (17). It is emphasized that nitrogen mustard is not a cure. It should be used in advanced cases of malignant lymphomas, in chronic leukemias, and in inoperable bronchiogenic carcinoma. Nitrogen mustard should be used neither in early localized Hodgkin's disease nor lymphosarcoma, nor in early generalized malignant lymphomas.

Surgical treatment by hemipelvectomy, Ariel and Hark (18), and by resection of the sternum, Campbell (19), for malignant disease are good articles.

X-ray treatment is discussed for miscellaneous orthopedic conditions by White and Rombold (20) and as preoperative therapy for osteogenic sarcoma by Scott (21) who gives a technic for irradiation which caused local improvement in 13 out of 18 cases. Pohle and Frank (22) report a case of pathological fracture from radiation osteitis eleven years after therapy.

#### Part C. Bone tumors of nonosseous origin.

A study was made by Falconer and Leonard (23) to determine some method of early recognition of Hodgkin's involvement of the skeletal bone marrow. Sternal biopsies were done on 79 cases of Hodgkin's disease. It was found that the bone marrow reacted without radiographic evidence of involvement by showing a "shift to the left" of myelocytic elements. In the great majority of cases, this shift was in the neutrophilic and eosinophilic myelocytes and there was an increase in plasmacytes. Also in a great majority of these cases



there was an increase of the megakaryocytes. Both of these reactions were interpreted to be indicative of marrow irritation and possible degenerative cellular changes. Moir and Brockis (24) present a case of Hodgkin's disease unusual in that there was necrosis of the inguinal glands followed by ulceration as well as destructive lesions of the skull and femur and fluctuant swellings over the skull region. In treatment of the case, x-ray therapy was given to the ulcerated lesions of the groin followed by healing. The bone lesions did not change after x-ray therapy. Gemmill (25) writes that a sternal swelling in a patient with healed pulmonary tuberculosis was found by biopsy of lymph nodes to be lymphadenoma. She was treated by x-ray with apparent good results.

Meyer and Overmiller (26) discuss the use of nitrogen mustard with 5 case reports; 2 cases of Hodgkin's and 3 of lymphosarcoma. Toxic manifestations were: a. Early - (1) Pain and tenderness with induration at the site if the solution was injected outside the vein; (2) Thrombophlebitis; (3) Nausea and vomiting; (4) Diarrhea. b. Late - (1) Lymphopenia; (2) Granulocytopenia; (3) Thrombocytopenia; (4) Anemia. Nitrogen mustard after x-ray therapy was not advised. These patients often obtained relief from pain as well as objective decrease in the size of the lymph nodes.

Examination of specimens of Ewing's tumor have shown necrosis, hemorrhage, and inflammatory cells accentuated after radiation, writes Unander-Scharin (27). No case of spontaneously healed Ewing's sarcoma has been reported, but the possibility exists as tumors treated by x-ray undergo considerable fibrosis and encapsulate tumor cells. The similarity between them suggests the possibility of spontaneous cures of Ewing's tumor as may be noted with retinoblastoma. Radiation should always be combined with radical surgery. The presence of coarse vessels in sections of Ewing's sarcoma suggest that the tumor is resistant to irradiation.

McSwain et al (28) discuss 20 cases of Ewing's tumor seen in a 25-year period. These tumors represent 10 per cent of the bone tumors and 28 per cent of malignant bone tumors. Three of the patients are living; one after amputation, one after irradiation, and one after irradiation and amputation. Coley et al (29) discuss 91 cases of Ewing's sarcoma. The ages ranged from 5 months to 36 years. None of the tumors developed in vertebrae, facial bones or skull. All but two cases were treated by surgery, radiation or both. The longest survival was 14 years and 7 months. Two other patients are living, one 6½ and one 12 years after treatment.

A general discussion of multiple myeloma is given by Adams et al (30) and Limarzi and Sloan (31). Electrophoretic studies are relatively new in the diagnosis of multiple myeloma and curves are obtained from the various fractions of the plasma protein. They found abnormal curves in all cases, but state that these are not always diagnostic. It is suggested that the finding of Bence-Jones protein in the urine of patients may result from the absence of a high molecular weight protein in the plasma. There is no known cure for multiple myeloma. The following drugs and agents have been tried without influence on the ultimate fatal outcome: X-ray and radium therapy, radioactive phosphorus, arsenicals, stilbamidine, nitrogen mustard, urethane, and diet. Treatment by folic acid antagonists is discussed by Littlefield and Zamecnik (32) and Chapman and Licciardello (33). Folic acid antagonists compete with folic



acid in its formation of purine components of nucleic acids. Thus folic acid is related to growth. In aminopterin, the hydroxy group of folic acid is replaced by an amino group and x-methopterin has a methyl group replacing the H-atom of the para-aminobenzoyl portion of folic acid. After 6 months of relief of bone pain with aminopterin, sternal puncture showed the same percentage of myeloma cells as before. Urethane may be a more promising agent in the temporary inhibition of myeloma. Treatment with stilbamidine and pentamidine is reviewed by Brewer (34). Six cases are reported. Stilbamidine was given with some recovery in 2 cases; the other 4 died within 4 months after treatment was started. Pentamidine was used when no results were obtained from stilbamidine. Relief of pain was not noted in all cases. Stippling of the myeloma cells, some tendency of blood chemistry to return to normal and an inconstant eosinophilia are noted with stilbamidine treatment. Toxic effects are nausea and vomiting. There was some reduction in the percentage of myeloma cells in sternal puncture specimens in 2 cases, and myeloma cells of peripheral blood disappears. Cases with severe anemia or very extensive renal damage are not good candidates for stilbamidine therapy.

Ten cases of multiple myeloma are reported by Claisse et al (35) which were unusual in that pain was not a constant complaint.

Bousser (36) brings out the clinical aspects, particularly of the bone lesions present after the age of 40 which may give kyphosis, spontaneous fractures and enlargement of the bone. There is hyperproteinemia mainly in the globulin fraction. Sternal puncture usually reveals the myeloma cells. Associated with the disease there may be metastatic calcifications, amyloidosis and obstruction of the loops of Henle by casts which may give azotemia and anuria. The treatment recommended is radio-therapy.

Breitenbucher and Hertzog (37) review 95 proven cases of multiple myeloma with 75 autopsies. All the cases could be classified as the plasma cell type. The presence of myeloma cells in the liver and spleen was not uncommon. Lawrence and Rosenthal (38) report 4 cases of multiple myeloma with polycythemia. Radio-active phosphorus was used for treatment and no definite conclusions are made.

Eosinophilic granuloma is discussed by Hill (39) who covers the historical background, histology and clinical, radiographic and microscopic features. He also reports 1 case. Wallace (40) reports 7 cases, each with biopsy diagnosis, in which skull involvement was constant. Eosinophilic granuloma, Hand-Schuller-Christian disease and Letterer-Siwe's disease are included in the term reticulo-endotheliosis. An extensive review of the literature is present. McCreary (41), Grant et al (42), Kruger et al (43), and Pinkus et al (44) report cases with varied involvement of skin, mouth, vulva, ribs, jaws, and lungs. Treatment was by P 32 and x-ray. The latter authors suggest a modified classification of proliferative reticulo-endothelial diseases: (1) reticulosis; (2) reticulo-granuloma, which includes the 3 above named diseases and also a mixed type; and (3) reticulo-sarcoma or malignant lymphoma.

Two cases of primary hemangioma of the knee joint treated by surgery are presented by Jacobs and Lee (45). The significant signs are: (1) a circumscribed mass in a joint, covered by normal skin, and increasing in size with dependency; (2) blood obtained on aspiration of the mass; and (3) x-ray appearance after injecting contrast substance into the mass and the rapid disappearance



of the substance.

White (46) reports a case of secondary hemangioma of bone associated with a similar adjacent soft tissue lesion in contrast to primary hemangioma in which the affected limb is otherwise normal. The bones were very friable and there was a nonunion treated by an onlay bone graft. The treatment consisted of deep x-ray therapy. Complete excision can only be done by amputation and fractures are common but usually unite readily. A table of some differences between primary and secondary hemangioma is given.

Collapse of vertebral bodies in sickle cell anemia is reported in two cases by Henkin (47). He reviews the literature and describes his two cases which showed decreased height of the lumbar vertebrae with ballooning of the intervertebral disc and often increased density of the vertebrae. No compression fractures were noted. The ages of the patients were 14 and 12½ years. The pathology is correlated with the x-ray findings and the similarity of the x-ray in Paget's is noted. However, polycythemia vera, Cooley's anemia and congenital hemolytic anemia showed no similar x-ray picture.

A summary of 15 cases of glomus tumors is presented by Lehmer (48). Contrary to the usual description, only 7 were painful, 3 nonpainful, and 5 had tenderness on pressure over the tumor. Pathological description and review of the literature is given. Langer (49) reports one of the hard palate which resembled hemangioma. Lehman and Kraissl (50) report two cases of involvement of the distal phalanx.

Congenital sarcoma is an exceedingly rare neoplasm. Dreyfuss (51) presents a case history of a newborn with a proven spindle cell sarcoma of the dorsum of the foot arising from the tendon sheaths. Analysis of all reported cases shows that congenital sarcoma of the extremities has a surprisingly good prognosis. Treatment is surgical with amputation at the lowest possible level. Radiation is no substitute for surgery but its possibilities cannot be judged at this time. Congenital sarcoma in other than the extremities offers a much graver prognosis.

A case of fibrosarcoma following chronic osteomyelitis is reported by Kirshbaum (52). This is a case of a 66-year old man who had had osteomyelitis of the tibia for 41 years with a draining sinus for 35 years. Biopsy followed by amputation revealed fibrosarcoma and osteomyelitis. Sarcomata developing at the site of osteomyelitis are rare. The case supports the theory of chronic inflammation as predisposing factor in malignant tumors. A clinicopathological conference case of fibrosarcoma of the distal femur in a 72-year old woman is presented by Anglem et al (53). They feel it was possibly related to the ingestions of "radium water" for rheumatoid arthritis.

Muirhead et al (54) write that synovial sarcomas accounted for less than 4 per cent of all sarcomas at Baylor Hospital, Dallas, Texas, but the tumor is important because of its usual fatal course and the need to differentiate it from other lesions of the synovia. Eight synovial sarcomas were studied. The clinical features include (1) the majority of cases were in the lower extremities; (2) pain was associated with a slowly growing tumor; (3) tenderness and impaired joint function were present. The location may be in joint, tendon sheaths and bursae. Symptoms often persist for years before medical



advice is sought. Treatment of synovial sarcomas is high amputation, possibly combined with the radical removal of regional lymph nodes. Treatment of "relatively benign synoviomas" is local excision.

Of 83 cases of malignant melanoma reviewed by Wilner and Breckenridge (5), only 9 showed bone metastases. Five of these cases are presented and the literature reviewed. All bone lesions in authors' cases were of the osteolytic type. By x-ray, some cases showed cystic lesions, some a moth-eaten appearance, but in general, resembled other metastatic bone lesions.

A case of bronchiogenic carcinoma which metastasized to the thumb is reported by Ross and Fodden (56). The lesion on the thumb showed carcinoma and further studies later revealed the rather large but asymptomatic lesion in the lung.

Metastasis from the bowel to the talus is reported by Johnson and Janes (57). The incidence of distant bone metastases from carcinoma of the lower bowel ranges from 0.5 per cent to 11.1 per cent. The anatomical pathways of spread are reviewed.

Metastasis from the breast to the mandible is reported by Cook (58) eleven months after radical mastectomy.

A case of afibrinogenemia in a man with carcinoma of the prostate with bone metastases is described by Marder and Weiner (59). Various laboratory procedures ruled out diminished prothrombin or coagulation time impairment as well as calcium deficiency. The addition of fibrinogen to the patient's blood, which otherwise would not clot, caused clotting in a very few minutes. It is suggested that fibrogen production may be stopped by disturbances such as infiltration by carcinoma of the bone marrow. The liver function appeared adequate.

#### Part D., Tumors related to osteogenesis.

Twenty-four cases of osteogenic sarcoma treated at Duke University Hospital are evaluated by Zarzecki (60). Biopsy was performed in each case for diagnosis. Four cases are five-year cures and the duration of symptoms apparently has no bearing on the survival time. It is concluded that irradiation after a biopsy diagnosis, followed by amputation where feasible, is the method of choice in treatment.

Lascaux (61) reports 3 cases treated by subtrochanteric amputation. A detailed operative technic is given. A racket type incision is made and the skin flaps are elevated. The femoral vessels and all branches and tributaries are ligated. The sartorius, tensor fascia lata, pectineus, rectus femoris, adductors and hamstring muscles are cut at the pelvic attachments. The femur is sectioned immediately below the lesser trochanter and the gluteus maximus is cut approximately at the level of section of the bone. Nerves are cut high after injection of novocain. The gluteus maximus is sutured to anterior fascia and the incision is closed with drain. This operation is stated to be less shocking than disarticulation.

Wolfe and Platt (62) report 2 cases of osteogenic sarcoma of nasal bones



following some years after superficial irradiation for skin lesions. One of these showed no x-ray evidence of bone involvement. After biopsy, this was treated by radical excision, and plastic repair was begun. Only one other case of osteogenic sarcoma of the nasal bones was found in the literature.

Guilleminet et al (63) resected the lower 25 cm. segment of a femur in a 13-year old boy for sarcoma. The segment was replaced by a reinforced acrylic prosthesis, fitting the femoral fragment above and inserted into the upper tibia below.

Halpert et al (64) describe a case of osteogenic sarcoma of multi-centric origin with extensive visceral metastases.

It is the opinion of Sear (65) that the incidence of sarcoma in Paget's disease is not more than 2 per cent. It develops in the fibrous but not in the sclerotic phase. After sarcoma develops, the prognosis is very poor and life expectancy is quite short. Features of malignant change are erosion of cortex or suspicious osteoporosis at a fracture site. Three case records are presented.

A symposium of 5 articles on giant cell tumor was published in the British volume of "The Journal of Bone and Joint Surgery" in 1949. The first is by Willis (66) on the pathology. The author prefers osteoclastoma to the term giant cell tumor of bone. There is a constant transition from chondroblast to fibroblast, osteoblast and osteoclast and vice versa. The general incidence as well as age and sex incidence is compared with other authors. Young tumors are red, brown, or pale, usually soft and friable. Older ones show fibrosis, cyst, hemorrhage, necrosis or calcification. The prevalent impression that the "soap bubble" appearance on x-ray is diagnostic is stated to be erroneous. Microscopic features of the healthy tumor show fusiform or rounded cells and multinucleated giant cells and no signs of osteoid or bone differentiation. The giant cells are up to 100 micra in diameter and there may be as many as fifty in a section. Mitotic figures may be found in the smaller cells but seldom if ever in giant cells. The author is not of the opinion that giant cell tumors are primarily benign or malignant, but that malignant change may occur in the tumor. He describes a rare osteoclastoma as a chondromatous osteoclastoma, and this is the same lesion called benign chondroblastoma by other authors. It is his opinion in thus classifying the lesion that the chondroblast and osteoclast are related and can be converted one to the other; therefore giving this variant in the microscopic picture. Some lesions resembling osteoclastoma are discussed briefly.

The second is by Prosser (67) on treatment with a review of 25 cases. An attempt has been made to evaluate x-ray therapy in giant cell tumor of the bone. Most authors feel that a biopsy should be made for accurate diagnosis. The 25 case reports are given briefly and a table summarizing the results of x-ray therapy are given. Some of these cases had both surgery and irradiation. He obtained 20 good results, 3 fair results, and 2 failures. One of the failures had recurrence of pain and involvement of the joint and amputation was advised. The other failure had a biopsy revealing benign tumor but had compression paraplegia and died from pyelonephritis. The 3 fair results showed incomplete recalcification in 2, regression in 1, but



swelling was still present. The general clinical features are given and the treatment is outlined. Excision is a treatment of choice where it can be done without loss of function. The conclusion is that irradiation alone is the treatment preferred. It is cautioned that there may be some progression of the tumor following x-ray therapy, followed later by regression. The technique of irradiation is given.

The third is by Windeyer and Woodyatt (68). Thirty-eight cases of osteoclastoma are presented; the ratio of males to females was 15 to 23; age ranged between 8 and 62 years with the majority in the second and third decade; 50 per cent were in the lower extremities. The authors think it advisable to have a biopsy of a suspected lesion. Cases are presented showing unusual features. Their treatment was of 3 types, (1) surgical, (2) radiation therapy, and (3) surgery with postoperative x-ray. Nineteen patients were treated surgically, 10 of these having postoperative x-ray treatment, and 19 patients were treated by radio-therapy alone. Of those treated by radio-therapy, 3 had the insertion of radium or radon. These latter 3 all had complications, one with scarring and telangiectasis and two had persistent draining sinuses. Malignant change occurred in 5 cases and all these occurred in long bones. Malignant change occurred more in osteoclastoma treated originally by curettage and irradiation. The authors' preference in the treatment is by x-ray therapy.

The fourth is by Ellis (69). The diagnosis and value of biopsy in the diagnosis is discussed and the differentiation of osteoclastoma from bone cyst is made by age incidence, the site of the involvement, the histology, and the radiographic appearances. The principles of treatment are outlined as curettage, resection, amputation (which is seldom justified) and irradiation. Radiation was given in a total of 21 cases. One of these was malignant and died one and one-third years later. The advantages claimed for radiation treatment are that it is curative, painless, free from complications, and the patient does not have to be admitted to the hospital. The disadvantage is that histological study of the tissue is not available. The author's method of using drill biopsy is of value. He believes that the tumor, if malignant, was so from the start and that the malignant change was not brought about by x-ray. He has not found any untoward effects on growth of the epiphysis from x-ray therapy. He summarizes the treatment of the suspected case by routine blood chemistry, drill biopsy, preceded by some irradiation if the tumor is suspected malignant. Then the standard dose, in most cases 3000 R, is given.

The fifth is by Russell (70). This is a report on 5 cases of malignant osteoclastoma, 3 associated with osteitis deformans. The 2 cases of metastasizing osteoclastoma showed in one a frankly malignant change in the stroma cells which was hard to distinguish from osteogenic sarcoma. In the second case, metastasis occurred without appreciable change in the microscopic appearance of the previously diagnosed benign lesion. The association of Paget's disease with malignant osteoclastoma is not conceded to be frequent. Malignant change with Paget's disease is usually stated to be osteogenic sarcoma. The author believes that on histological grounds malignant osteoclastoma is the type of malignancy present in 2 of her cases and probably in the 3rd, though osteogenic sarcoma might have been the case.



Buschke and Cantril (71) cite 10 cases and favor x-ray treatment. Matthews (72) reports a case of giant cell tumor of the maxilla treated by local excision. Straith (73) presents one with pathological fracture through a giant cell tumor of the mandible with a 25-year follow-up without recurrence. Treatment was by curettement and x-ray followed four years later by an iliac graft. Erway and Erickson (74) describe a giant cell tumor of the patella and Bowers (75) one of the sacrum. The excision of the tumor required a posterior and anterior incision. It is interesting that in securing the blood supply of the tumor anteriorly, the common iliac vessels were occluded with tape for a period of two hours and 45 minutes. After removal, there was immediate return of the pulsations in the extremities and no untoward aftereffects have been noted. Because of the situation of the tumor, the lower sacral nerves and the presacral nerve were sacrificed and urinary and rectal incontinence resulted. The patient still has weakness in the legs and developed a minimal pulmonary tuberculous lesion nine months after the operation which has since cleared. He is at present two years and thirteen months after operation with no recurrence.

A very thorough discussion of chondroblastic tumors of bone is given by Copeland and Geschickter (76). They prefer the name chondroblastoma and include the malignant form which they differentiate from chondrosarcoma. Their work was on a series of 25 patients; the age is in the second and third decade mainly with localization of the tumor primarily in the upper tibia and lower femur and upper humerus. The x-ray features include rarefaction with some periosteal reaction and extension across the epiphyseal line. The resemblance to sarcoma is prominent in the early stages. Chondroblastomas are predominantly found in the central portion of the bone but break through the cortex at the epiphyseal line. Confusion may arise between these tumors, giant cell tumor and Ewing's tumor, by x-ray. The gross and microscopic findings are given. The gross findings are not characteristic and may resemble giant cell tumor, so-called malignant aneurysms, or chondromas. A connection is usually seen between the mass of tumor and the destroyed epiphyseal cartilage. Microscopically there is very little intercellular substance in the mass of young and adult cartilage cells in which there is calcification, but no tumor bone. There is a characteristic lattice work of calcifying matrix, and the tumor is quite vascular with giant cells noted near the periphery. The authors state there are two diagnostic points in the interpretation of these tumors; (1) the differentiation from giant cell tumor, (2) the differentiation into benign and malignant forms. This latter is quite difficult. They disagree with Codman's description of these tumors as "benign epiphyseal chondromatous giant cell tumors." These tumors are a new clinical entity and somewhat rare. In the treatment they suggest biopsy followed by x-ray and review of the slides by competent pathologists. Resection or amputation should be done for the malignant forms, curettage, with or without deep x-ray therapy, for the benign. The paper is discussed by Dr. Bradley Coley who feels that the malignant chondroblastoma as described here should be interpreted as chondrosarcoma.

Lichtenstein and Kaplan (77) discuss benign chondroblastoma of bone with microscopic findings as well as location and age incidence. It is



emphasized that benign chondroblastoma must be differentiated from giant cell tumor, chondrosarcoma, and osteogenic sarcoma. The treatment of this lesion is curettement or irradiation and not radical therapy.

Stradford (78) reports a case of a 13-year old white male with pain in the lower tibia of 18 months. X-ray was interpreted as characteristic of solitary bone cyst. Excision and packing with iliac bone chips was done. Jaffe called it chondromyxoidfibroma of bone. This entity was described by Lichtenstein in 1948.

A case of Ollier's disease is cited by Lee (79) who attempts to correct the confused and inconsistent terminology. The author gives the titles of two papers by Ollier, one on multiple osteogenic exostosis and the other on dyschondroplasia. For the multiple exostosis, ecchondrodysplasia has been given and for dyschondroplasia, endochondrodysplasia has been given, thus avoiding the name, "Ollier's disease." The author, however, suggests the term multiple enchondromatoses to distinguish the dyschondroplasia of Ollier. A case of a 6-year old female is given in which there was leg length discrepancy, adduction of the left hip, valgus deformity of the left knee and varus deformity of the right knee. Clinical characteristics are given which are similar to the case described. The patients are normal mentally and muscularly. The deformities cease to progress as maturity is reached. X-ray examination of the involved areas shows longitudinal streaking or stippling along with some punched out areas, especially in the hand and foot bones. It is a relatively rare disease in which the prognosis for life is excellent. The treatment is in the prevention of deformity. Hormone therapy has not been proven to be effective. It is suggested that the term "Ollier's disease" be abandoned.

Kuzma and King (80) report a case with Maffucci's syndrome in a girl of 19 who had an associated ovarian teratoma and hemangiomata. Dyschondroplasia (Ollier's disease) associated with hemangiomatosis is known as Maffucci's syndrome. There is usually a normal child at birth, but in 1 to 12 years, nodules appear on the bones of the hands, feet, legs, and arms. Other bones may be involved and the lesions are enchondromata. About the time the enchondromas appear, hemangiomas also appear. The distribution may be asymmetric, rarely unilateral. Progressive deformities appear and amputation may be necessary. Progression usually ceases about the age of 20.

Osteochondromatosis is the subject of an article by Mussey and Henderson (81). Because the cartilaginous and osteocartilaginous bodies develop by metaplasia, it may well be a benign neoplasm. The pathology is reviewed. The treatment is surgical unless otherwise contraindicated and sometimes synovectomy should be performed. The knee was involved in 70 per cent of 104 cases at the Mayo Clinic and the elbow in 22 per cent. Osteoarthritis is often associated because of the trauma from the loose bodies and poor operative results often due to this factor. Loose bodies may disappear without specific treatment.

Shackelford and Brown (82) write that osteochondroma of the coronoid



process of the mandible may be the cause of painful and restricted motion of the jaw as noted in 3 cases. An osteoma of the zygoma may cause the same clinical findings and 1 case is included. Treatment in all cases was surgical excision followed by excellent recovery.

Wahrsinger and Kushner (83) report a case of ossifying fibroma of the sacrum of 10 years duration treated by x-ray originally and followed by two pregnancies. Both pregnancies were terminated by delivery with low forceps and in each instance there was a depressed fracture of the right frontal bone of the child. No growth of the tumor of the sacrum was observed during the 10-year period.

Scott and Temple (84) present a case of osteoma cutis in a 9-year old boy associated with convulsions, obesity and draining ears.

Twenty-two cases of fibrous dysplasia seen at Brooke General Hospital are reported by Wells (85). Nine cases were proven by biopsy. The historical, clinical, x-ray aspects, differential diagnosis and pathological findings are discussed.

The theories of etiology of monostotic and polyostotic fibrous dysplasia are given by Wyatt and Randall (86). Aids to diagnosis by the x-ray are (1) a homogeneous increase in the density of the apparently cystic areas - the so-called "ground glass" appearance; (2) dense calcific margins of the apparent cyst and (3) the shading off of this density of the margins into normal bone with no sharp line of demarcation.

Warrick (87) gives a short discussion of polyostotic fibrous dysplasia. Differential diagnosis includes hyperparathyroidism, Paget's disease, Ollier's disease, xanthamatoses, osteogenesis imperfecta; the monostotic may resemble giant cell tumor or neurofibroma. Four cases are reported, all in males, two of whom showed precocious puberty. All of the author's cases showed cutaneous pigmentation consistent with Albright's syndrome.

Schlesinger (88) presents a case in which there were many fractures and in whom an amputation was done for changes believed to be malignant in a tibia. Pathologic examination revealed no evidence of malignancy. Snapper (89) presents three cases of polyostotic fibrous dysplasia. Elliot and Taylor (90) report a case of nonosteogenic fibroma of bone with clinical pathological conference discussion.

Twenty-six cases of solitary bone cyst observed at the Memorial Hospital in New York are reviewed by James, Coley and Higinbotham (91). Symptoms were pain, tenderness, or pathological fracture. The average age was 14.7 years. The humerus was involved 17 times. No instance of malignancy has been noted after surgical treatment. Surgical treatment is the method of choice at which time a bone graft should be used in filling the defect. X-ray therapy is not advised.

A general discussion of osteoid osteoma based on 10 cases is given by Coley and Lenson (92). The majority of authors feel that it is a benign tumor of bone. The most constant clinical findings were pain,



swelling, and disability. The lower extremity was affected more than the upper. The differential diagnosis lies between osteomyelitis of the sclerosing type, Brodie's abscess, osteogenic sarcoma, Ewing's sarcoma, periostitis, bone repair after green-stick fracture, and osteoma. As to the x-ray findings, several different views may be necessary as well as different degrees of penetration in order that the nidus may be seen. The treatment of choice is complete removal of a block of bone enclosing the nidus. The authors state that they have had no experience with x-ray therapy.

Lapidus and Salem (93) report a case of osteoid osteoma of the shaft of the femur treated by surgery. Circumstances prevented microscopic confirmation of a gross pathological diagnosis. Four months later, a proven osteoid osteoma was removed from the region of the lesser trochanter of the same femur. This is the first reported instance of a probable double osteoid osteoma.

Fisk (94) describes a ganglion causing erosion of the tibial cortex. Herzog (95) reports a case of neurofibroma of the sole of the foot. A third entity is added to the condition of calcinosis by Thomson and Tanner (96). A report by Inclan and its discussion by Ghormley provided two entities. This third one labelled tumoral calcinosis occurs in young people of both sexes. The authors give a general description and report three cases occurring in the same family. Two are now living with no progression after maturity, and the third had long standing infection of an incised infected tumor and died of amyloidosis. All cases showed the tumors to be similarly located and not accompanied by pain or tenderness except in the fatal case with infection.



## BIBLIOGRAPHY

1. Compere, E. L.: Bone tumors, Surg. Clin. N. America, 29: 133-43, Feb 1949
2. Cade, S.: The natural history of malignant disease, Brit. J. Radiol., 22: 331-41, June 1949
3. Moore, S.: Relative incidence of bone lesions over a 37-year period, Am. J. Roentg., 62: 375-9, Sept 1949
4. Little, C. C.: Biological research in cancer, Bull. Chicago M. Soc., 52: 7-12, July 2, 1949
5. Coley, B. L.: The early diagnosis of tumors of the bone, Penn. M. J., 52: 457-60, Feb 1949
6. Weisberger, A. S., and Heinle, R. W.: Study of fixed tissue sections of sternal bone marrow obtained by needle aspirations; metastatic carcinoma in sternal bone marrow, Am. J. M. Sc., 217: 263-8, Mar 1949
7. Polson, R. A.: A comparison of sternal and spinous process bone marrow punctures, Manitoba M. Rev., 29: 65, Feb 1949
8. Peters, C. H., and Larson, L. W.: Bone marrow aspirations, J. Lancet, 69: 98-102, Mar 1949
9. Rheingold, J. J., Weisfuse, L., and Dameshek, W.: Multiple sites for bone marrow puncture with particular reference to children, N. Eng. J. M., 240: 45-6, Jan 13, 1949
10. Gladstone, S. A.: Sponge biopsy; a new method in the diagnosis of cancer, Cancer, N. Y., 2: 604-14, July 1949
11. Coley, B. L., and Higinbotham, N. L.: The significance of cartilage in abnormal locations, Cancer, N. Y., 2: 777-88, Sept 1949
12. Horwitz, T.: Bone and cartilage debris in the synovial membrane; its significance in the early diagnosis of neuro-arthropathy, J. Bone Surg., 30 A: 579-88, July 1948
13. Rhoads, C. P.: Advances in treatment of malignant disease, Bull. N. York Acad. M., 25: 271-84, May 1949
14. Poppe, E.: Osteogenic sarcoma; along what lines should it be treated, Acta radiol., Stockh., 31 A: 335-42, Apr 30, 1949
15. Reimann, S. P., and Nishimura, E. T.: Attempts at the chemotherapy of cancer, J. Michigan M. Soc., 48: 435-7, Apr 1949



16. Roswit, B., and Kaplan, G.: The role of nitrogen mustard as a systemic adjunct to the radiation therapy of certain malignant diseases, *Am. J. Roentg.*, 61: 626-36, May 1949
17. Wintrobe, M. M.: Nitrogen mustard therapy, *Bull. Chicago M. Soc.* 51: 557, Jan 29, 1949
18. Ariel, I. M., and Hark, F. W.: Disarticulation of an innominate bone (hemipelvectomy) for primary and metastatic cancer, *Ann. Surg.*, 130: 76-99, July 1949
19. Campbell, D. A.: Resection of the sternum for metastatic carcinoma, *Ann. Surg.*, 129: 394-8, Mar 1949
20. White, C. M. and Rombold, C.: Value of x-ray therapy in orthopedic cases, *J. Kansas M. Soc.*, 50: 325-9, July 1949
21. Scott, R. K.: Preoperative radiotherapy in the treatment of osteogenic sarcoma, *Med. J. Australia*, 2: 304, Aug 27, 1949
22. Pohle, E. A., and Frank, R. C.: Radiation osteitis of the ribs; report of a case with fractures appearing  $4\frac{1}{2}$  and 11 years after therapy, *J. Bone Surg.*, 31 A: 654-7, July 1949
23. Falconer, E. H., and Leonard, M. E.: Skeletal lesions in Hodgkin's disease, *Ann. Int. M.*, 1948, 29: 1115-31, Dec 1948
24. Moir, P. J. and Brockis, J. G.: Observations on bone lesions in Hodgkin's disease, *Brit. J. Surg.*, 36: 414-7, Apr 1949
25. Gemmill, J. S.: Sternal swelling as a presenting sign of Hodgkin's disease, *Brit. M. J.*, 2: 19, July 2, 1949
26. Meyer, A. H., and Overmiller, W. C.: The use of nitrogen mustard in Hodgkin's disease and lymphsarcoma, *Ann. Int. M.*, 30: 381-6, Feb 1949
27. Unander-Scharin, L.: On the tendency of Ewing's sarcoma to heal spontaneously, and on the alterations due to irradiation, *Acta. orthop. scand.*, 18: 436-76, 1948-1949
28. McSwain, B., Burd, B. F., Jr., and Inman, W. O., Jr.: Ewing's tumor, *Surg. Gyn. Obst.*, 89: 209-21, Aug 1949
29. Coley, B. L., Higinbotham, N. L., and Bowden, L.: Endothelioma of bone; Ewing's sarcoma, *Tr. Am. Surg. Ass.*, 66: 312-339, May 1949
30. Adams, W. S., Alling, E. L., and Laurence, J. S.: Multiple myeloma; its clinical and laboratory diagnosis with emphasis on electrophoretic abnormalities, *Am. J. Med.*, 6: 141-61, Feb 1949
31. Limarzi, L. R., and Sloan, L. H.: Clinical and hematological findings in multiple myeloma, *Bull. Chicago M. Soc.*, 51: 756-62, Mar 1949



32. Littlefield, J., Zamecnik, P., et al: Multiple myeloma, Am. Practitioner, 3: 442-4, Mar 1949
33. Chapman, E. M., Licciardello, T., et al: Multiple myeloma, Am. Practitioner, 4: 107-112, Oct 1949
34. Brewer, A. E.: Multiple myeloma treated with stilbamidine and pentamidine, Brit. M. J., 1948, 2: 978-82, Dec 4, 1948
35. Claisse, R., Bonduelle, M. and Lavergne, G. H.: Myelomes multiples des os; leur polymorphisme; a propos de dix observations, Sem. Hop., Par., 25: 249-56, Jan 22, 1949
36. Bousser, J.: Le Myelome osseux, Presse med., 57: 72 D, Jan 12, 1949
37. Breitenbucher, R. B., and Hertzog, A. J.: Multiple myeloma; a review of 95 proven cases with 75 autopsies, Minn. M., 32: 986-8, Oct 1949
38. Lawrence, J. H., and Rosenthal, R. L.: Multiple myeloma associated with polycythemia; report of four cases, Am. J. M. Sc., 218: 149-54, Aug 1949
39. Hill, R. M.: Nonspecific (eosinophilic) granuloma of bone, Brit. J. Surg., 37: 69-76, July 1949
40. Wallace, W. S.: Reticulo-endotheliosis; Hand-Schuller-Christian disease and the rarer manifestations, Am. J. Roentg. 62: 189-207, Aug 1949
41. McCreary, J. H.: Eosinophilic granuloma with simultaneous involvement of skin and bones, Arch. Derm. Syph. Chic., 58: 372-80, Sept 1948
42. Grant, A. R., House, R. K., and Crandell, W. B.: Eosinophilic granuloma of rib; report of a case observed for 8 years, N. Eng. J. M., 240: 541-3, April 1949
43. Kruger, G. O., Jr., Prickman, L. E., and Pugh, D. G.: So-called eosinophilic granuloma of the ribs and jaws associated with visceral (pulmonary) involvement characteristic of xanthomatosis, Oral Surg., 2: 770-9, June 1949
44. Pinkus, H., Capps, L. A., et al: Reticulogranuloma; report of a case of eosinophilic granuloma of bone associated with nonlipid reticulosis of skin and oral mucosa under the clinical picture of Hand-Schuller-Christian disease, Am. J. Dis. Child., 77: 504-19, Apr 1949
45. Jacobs, J. E., and Lee, F. W.: Hemangioma of the knee joint, J. Bone Surg., 31 A: 831-836, Oct 1949
46. White, J. A.: Secondary hemangioma of bone; report of a case, Brit. J. Surg., 37: 114-6, July 1949
47. Henkin, W. A.: Collapse of the vertebral bodies in sickle cell anemia, Am. J. Roentg., 62: 395-401, Sept 1949



48. Lemmer, K. E.: Glomus tumors; a summary of 15 cases, Arch. Surg., 57: 531-8, Oct 1948
49. Langer, R.: Glomustumor am harten Gaumen, Wien. med. Wschr., 99: 67, Feb 12, 1949
50. Lehman, W., and Kraissl, C.: Glomus tumor within bone, Surgery, 25: 118-21, Jan 1949
51. Dreyfuss, M. I.: Congenital sarcoma, J. Pediatr. St. Louis, 34: 583-587, May 1949
52. Kirschbaum, J. D.: Fibrosarcoma of the tibia following chronic osteomyelitis; report of a case, J. Bone Surg., 31 A: 413-6, Apr 1949
53. Anglem, T., Wyman, S. M., and Mallory, T. B.: Fibrosarcoma of femur, invading knee joint, N. England J. M., 240: 1056-9, June 30, 1949
54. Muirhead, E. E., Kreissl, L. J., Jr., and Gordon, C. E.: Synovial sarcoma and relatively benign synovioma, Texas J. M., 45: 202-9, Apr 1949
55. Wilner, D., and Breckenridge, R. L.: Bone metastasis in malignant melanoma, Am. J. Roentg., 62: 388-94, Sept 1949
56. Ross, E. F., and Fodden, J. H.: Metastasis of bronchogenic carcinoma to the thumb, Canad. M. Ass. J., 61: 310-12, Sept 1949
57. Johnson, E. W., Jr., and James, J. M.: Metastatic adenocarcinoma of the talus from the rectosigmoid region, J. Bone Surg., 31 A: 181-4, Jan 1949
58. Cook, T. J.: Adenocarcinoma with metastasis to the mandible, Oral Surg., 2: 780, June 1949
59. Marder, M., and Weiner, M., et al: Afibrinogememia occurring in a case of malignancy of the prostate with bone metastases, N. York State J. M., 49: 1197, May 15, 1949
60. Zarzecki, C. A.: Osteogenic sarcoma, North Carolina M. J., 10: 312-4, June 1949
61. Iascaux, B.: Amputation sous-trochanterienne du femur pour osteosarcome, Rev. chir., Par., 87: 135-51, May-June 1949
62. Wolfe, J. J. and Platt, W. R.: Post-irradiation osteogenic sarcoma of the nasal bone; a report of two cases, Cancer, N. Y., 2: 438, May 1949
63. Gulleminet, M., Creyssel, J., and Devic, G.: Resection epiphyso-diaphysaire de femur pour sarcome ave prothese interne acrylique, Lyon chir., 44: 457, July-Aug 1949
64. Halpert, B., Russo, P. E., and Hackney, V. C.: Osteogenic sarcoma with multiple skeletal and visceral involvement, Cancer, N. Y., 2: 789-92, Sept 1949



65. Sear, H. R.: Osteogenic sarcoma as a complication of osteitis deformans, some personal experiences and reflections, *Brit. J. Radiol.*, 22: 580-7, Oct 1949
66. Willis, R. A.: The pathology of osteoclastoma or giant-cell tumor of bone, *J. Bone Surg.*, 31 B, 236-40, May 1949
67. Prosser, T. M.: Treatment of giant-cell tumors of bone with a review of 25 cases, *J. Bone Surg.*, 31 B, 241-51, May 1949
68. Windeyer, B. W., and Woodyatt, P. B.: Osteoclastoma; a study of 38 cases, *J. Bone Surg.*, 31 B: 252-67, May 1949
69. Ellis, F.: Treatment of osteoclastoma by radiation, *J. Bone Surg.*, 31 B: 268-80, May 1949
70. Russell, D. S.: Malignant osteoclastoma and the association of malignant osteoclastoma with Paget's osteitis deformans, *J. Bone Surg.*, 31 B: 281-90, May 1949
71. Buschke, F., and Cantril, S. T.: Roentgentherapy of benign giant cell tumor of bone, *Cancer, N. Y.*, 2: 293-315, Mar 1949
72. Matthews, G. W.: Giant-cell tumor of the maxilla; report of a case, *Oral Surg.*, 2: 719-22, June 1949
73. Straith, C. L.: A mortised mandibular bone graft following giant cell tumor removal; a 25-year history, *Plastic & Reconstr. Surg.*, 4: 282-8, May 1949
74. Erway, C. E., and Erickson, R. B.: Giant cell tumor of the patella encountered during treatment for patellar fracture, *N. York State J. M.*, 49: 1201-3, May 15, 1949
75. Bowers, R. F.: Giant cell tumor of the sacrum, *Ann. Surg.*, 128: 1164-72, Dec 1948
76. Copeland, M. M., and Geschickter, C. F.: Chondroblastic tumors of bone; benign and malignant, *Ann. Surg.*, 129: 724-35, May 1949
77. Lichtenstein, L. and Kaplan, L.: Benign chondroblastoma of bone; unusual localization in femoral capital epiphysis, *Cancer, N. Y.*, 2: 793-8, Sept 1949
78. Stradford, H. T.: Chondromyxoidfibroma of bone, *Bull. Charlotte Mem. Hosp.*, 3: 7-11, Dec 1948
79. Lee, F. W.: Multiple enchondromatoses, *Bull. Charlotte Mem. Hosp.*, 3: 33-8, Dec 1948
80. Kuzma, J. F., and King, J. M.: Dyschondroplasia with hemangiomatosis (Maffucci's syndrome) and teratoid tumor of the ovary, *Arch. Path. Chic.*, 46: 74-82, July 1948



81. Mussey, R. D., Jr., and Henderson, M. S.: Osteochondromatosis, J. Bone Surg., 31-A: 619-27, July 1949
82. Shackelford, R. T., and Brown, W. H.: Restricted jaw motion due to osteochondroma of the coronoid process, J. Bone Surg., 31 A: 132-40, Jan 1949
83. Wahrsinger, P. B., and Kushner, J. L.: Pregnancy complicating osteogenic tumor of the sacrum, N. Y. State J. M., 49: 77, Jan 1949
84. Scott, E. P., and Tample, W. J.: Osteoma cutis, Am. J. Dis. Child., 77: 758-62, June 1949
85. Wells, P. O.: Fibrous dysplasia of bone (monostotic), Radiology, 52: 642-54, May 1949
86. Wyatt, G. M., and Randall, W. S.: Monostotic fibrous dysplasia, Am. J. Roentg., 61: 354-65, March 1949
87. Warrick, C. K.: Polystotic fibrous dysplasia; Albright's syndrome; a review of literature and report of four male cases, two of which were associated with precocious puberty, J. Bone Surg., 31 B: 175-83, May 1949
88. Schlesinger, P. T., Keats, S., and Ruoff, A. C., III: Fibrous dysplasia, J. Bone Surg., 31 A: 187-91, Jan 1949
89. Snapper, I.: Classification of bone diseases, N. York State J. M., 49: 511-5, Mar 1, 1949
90. Elliot, W., Taylor, G. W., et al: Nonosteogenic fibroma of bone, N. England J. M., 240: 30-2, Jan 6, 1949
91. James, A. G., Coley, B. L., and Higinbotham, N. I.: Solitary unicameral bone cyst, Arch. Surg., 57: 137-47, July 1948
92. Coley, B. L. and Lenson, N.: Osteoid osteoma, Am. J. Surg., 77: 3-9, Jan 1949
93. Lapidus, P. W., and Salem, E. P.: Osteoid osteoma; report of case with probable double lesion, Arch. Surg., 58: 318-27, Mar 1949
94. Fisk, G. R.: Bone concavity caused by a ganglion, J. Bone Surg., 31 B: 220, May 1949
95. Herzog, E. G.: Neurofibroma of the sole in a case of von Recklinghausen's disease, J. Bone Surg., 31 B: 227, May 1949
96. Thomson, J. E. M. and Tanner, F. H.: Tumoral calcinosis, J. Bone Surg., 31 A: 132-40, Jan 1949



## CHAPTER IV

### CONDITIONS INVOLVING THE HIP JOINT

By

W. H. Vaughan, Colonel, M. C., U. S. A.

Ninety-nine titles pertaining to this chapter were considered and sixty-four are abstracted herewith.

Fahey (1), in the corresponding chapter of "Progress in Orthopedic Surgery for 1946," discusses twenty-five articles of significance, devoting one paragraph to the salient feature of each.

Chandler (2) in a very compact article discusses fractures of the upper end of the femur. Good results can be anticipated in from 80 to 90 per cent of cases. Two cardinal principles were stressed: accurate reduction and adequate fixation. Good x-ray technic is needed for both. The author uses multiple threaded pins for fixation. Intertrochanteric and peritrochanteric fractures do not present the question of nonunion as do fractures of the femoral neck. The blood supply here is abundant but the death rate is high. For this group, fixation with some type of blade plate should be done early. The alternative is traction in bed for 10-12 weeks. Generous use of hydrochloric acid and dicalcium phosphate is indicated in fractures of the upper end of the femur in elderly patients. Age is no contraindication to surgery. Patients of 80 to 90 years withstand such procedures well and often become ambulatory.

Four articles on trochanteric fractures of the femur are reviewed by Murray and Frew (3). A series of 100 cases of trochanteric fractures were treated conservatively and they plead for conservative treatment. Skeletal traction was employed in only 6 cases; traction by adhesive strapping was used in all others. The anatomical and functional results are tabulated and compared with reports in the literature of the results from operative treatment.

A study of the treatment of trochanteric fractures is presented by Evans (4). One hundred and one cases were treated conservatively in the hospital; 22 cases treated by operative fixation with a nail-plate; and 25 cases sent home because of shortage of hospital beds. Of the 101 cases treated conservatively, the mortality rate was 15 per cent. The average stay in the hospital was 15 weeks and 21 per cent had residual coxa vara. The mortality rate in the 25 cases which had to be treated at home was 44 per cent. It is concluded that the older and more feeble the patient the more urgent is the need for operation. A summary of the mortality rates reported in the literature is given as well as a description of the operative method which included a specially made director for insertion of the nail.



Boyd and Griffin (5) review 300 cases of trochanteric fractures of the femur and compare the results of operative and nonoperative treatment. The cases are classified into 4 types and the prognosis given for each group. Type I designates fractures showing a linear break along the intertrochanteric line. Reduction is simple and easily maintained. Type II designates comminuted fractures with multiple breaks in the cortex. Reduction is more difficult in this group. Type III designates subtrochanteric fractures, much more difficult to reduce and maintain. Type IV designates comminuted fractures extending through the trochanteric region and into the shaft, with fracture lines in two planes. If open reduction is employed, two-plane fixation is required. The gross mortality rate in the series was 18 per cent. In comparing the results of treatment, it is pointed out that the mortality was no higher in the operative series, and the care of the elderly patient was considerably facilitated by internal fixation. It is concluded that operative treatment is the method of choice.

Funsten and Frankel (6) study the evolution of treatment of intertrochanteric fractures at the University of Virginia Hospital during the past 15 years with 180 cases treated; 131 by traction, 49 had open reduction. The mortality was reduced from 12 per cent to 8 per cent; average age was 71.8 years. Hospitalization of operated cases averaged 19 days and time for resumption of normal locomotion about 26 weeks.

Spears and Owen (7) studied documented femoral specimens by x-ray and placed them in a testing machine. A vertical load was applied to the head of the femur by a machine developed for this purpose. It was found that femora in the well-mineralized group were broken only when 600 inch pounds or more of pressure were applied while the demineralized group broke under 300 inch pounds or less. It appeared to the authors that in the intertrochanteric region the actual break may be due to shearing stress. They failed to substantiate "Poisson's ratio."

Subtrochanteric fractures are discussed by Rountree (8) reviewing the anatomical basis for forces exerted upon the fragments and therefore influencing the management of these fractures. The inadequacies of conservative treatment are enumerated, and it is concluded that open reduction with internal fixation adequate to provide firm immobilization without external fixation was the treatment of choice. A Neufeld nail or Blount blade plate was used.

An excellent and detailed description of the management of intracapsular hip fractures is given by McElvenny (9). Reduction in valgus position is recommended as absolutely necessary for obtaining union. The two most important factors in the operating room for successful nailing are considered to be the anesthesia and the x-ray technic. A standardized technic for x-ray views is strongly recommended, and the author feels an AP view with the limb in complete internal rotation is essential to judge proper reduction as well as the true lateral projection. He believes all adduction fractures should be converted into abduction fractures by reduction and then internally fixed. The author reports on 65 hips with intracapsular fractures with only one case of aseptic necrosis; 2 nonunions; 2 unreduced; (treated by osteotomy) 5 delayed unions; and one death; no serious infections. This statistical result is unusual. He concludes that care and reduction before nailing offer best possible chance for success. All of his failures of immediate bony union



have occurred in hips in the unreduced position. (Ed. This very detailed and convincing report is recommended for careful consideration by all surgeons who may be treating this type of fracture.)

and Prudden

Spotoft (10) reports 183 cases, Luomanen (11) 128 cases, Gallagher (12) 77 cases, and Hogg (13) 43 cases, with comparable results.

Apfelbach and Weinstein (14) discuss the history of femoral neck fracture treatment and the various methods in current use. They tell briefly of their investigation of the blood supply with radioactive phosphorus and postulate that all intracapsular fractures should be over-reduced in a valgus position.

An article on medical considerations in the case of elderly patients with hip fractures is written by Fahey, Kilfoyle and Shortell (15) who studied a series of 100 patients over the age of 70 years who had sustained fractures of the hip. The cases are divided into 3 groups. Group I comprises good surgical risks; Group II fair risks, and Group III, poor risks contraindicating surgery. Seventy-two of the 100 patients were operated upon with a mortality rate of 18 per cent. In the group treated conservatively, the mortality rate was 32 per cent. The high mortality in this group reflects the fact that it included many poor risk patients. The causes of death are discussed. Another by Snedecor (16) deals primarily with the care of the aged patient before and after internal fixation of hip fractures. It is recommended that the anesthesia be as light as possible, as well as the preliminary sedation. The author uses local infiltration supplemented by gas and oxygen. Immediate fixation of the fractured hip is felt to be mandatory within the first 24 hours. These old people will never again be in such good condition as they were at the time of fracture. Early ambulation is encouraged. Dehydration is the major problem so that fluids totalling 3000 cc. for the first few days are used, and the author feels that six small meals a day are better than three large ones. He concludes that fracture of the hip in the aged is no longer occasion for despair.

Moser (17) describes a method of local analgesia for surgical treatment of fractured neck of the femur evolved as a result of his experience in 104 cases. The method consists of two stages, first the injection of 30-40 cc. of 2 per cent procaine solution into the point of the fracture to allow reduction, and secondly, the use of 70-90 cc. of 0.5 per cent procaine solution with adrenalin injected into the field of operation.

Procaine injection for relief of pain in the hip is presented by Ergenbright and Lowry (18). Twenty-three patients with pain from various causes were treated by injection of obturator, and nerve to quadratus femoris with 1 per cent procaine. Nineteen had immediate and complete relief from 36 hours to 3 months. The authors pointed out it is useful in poor operative risks and as a therapeutic test before surgical denervation of the hip.

Because of the differences of opinion regarding the origin and distribution of the sensory fibres of the obturator nerve, Kaiser (19) performed 24 dissections. He finds two branches of the obturator nerve frequently encountered which are much more important than either the anterior or posterior



branch so far as innervation of the hip joint is concerned. The first branch takes its origin from the obturator nerve in the canal whence it passes to the pubococcygeus ligament which is directly adjacent to the outlet of the obturator canal. The second branch is large in size and quite constant; it originates from the obturator nerve inside the pelvis and as it traverses the canal, a filament of this nerve is given off and goes directly to the acetabular notch. The second branch goes on to supply the obturator externus muscle. The variations of these two branches indicate that frequently the anterior and posterior branch do not supply the capsule of the joint. This confirms previously recorded findings. (Ed. A thorough study of this article is recommended for surgeons performing obturator neurectomies.) The author comments that the nerve supply to the hip joint is more complicated than has previously been assumed and that the extrapelvic approach to the capsular branches is inadequate since a nerve to the acetabular notch when present in the accessory obturator nerve is not sectioned through this approach. The variability in the innervation of the capsule of the hip joint can explain the variable results which have been obtained in obturator neurectomy.

Key and Reynolds (20) report 20 cases treated by intrapelvic obturator neurectomy for the relief of pain of chronic arthritis of the hip. All of these patients were suffering from chronic painful conditions which affected one or both hips. In most, pain had been present for from six to twenty years. The effect of the operation was not specific. The variation in the relief from pain seems to be due in part to variation in the distribution of the nerve. Eighty per cent of these cases showed some clinical improvement.

Selective neurectomies of obturator, femoral and sciatic branches are reported by Obletz et al (21, 22) for relief of hip pain in chronic arthritis in 42 patients. The sensory nerve supply to the hip joint is by branches of the obturator nerve, occasionally an accessory obturator nerve, and branches of the femoral nerve and sciatic nerve. The patient selected should be one who has the obturator or posterior pattern of pain, not relieved by conservative therapy. A description of the operative method is given. The complete relief of pain was rarely acknowledged but partial relief was received with gratitude by most patients. Very few patients obtained increase in hip motion.

A combined approach to the obturator and femoral nerves is described by Freeman (23) for the relief of flexion and adduction spasm in patients with paraplegia. A short skin incision is made starting 1 cm. above the inguinal ligament, midway between the anterosuperior iliac spine and the symphysis pubis, and extending laterally and downward to a point 1 cm. lateral to the femoral artery and 1 cm. below the inguinal ligament. The external oblique fascia is opened and the muscle is separated in the direction of its fibers. The contents of the inguinal canal are retracted medially and upward. The posterior wall is then pierced bluntly 1 cm. medial to the femoral vessels. The pelvic extraperitoneal space is thus entered and blunt dissection is carried down to the obturator foramen. Here the nerve and artery can be palpated easily. The only precaution necessary is to avoid peeling off the parietal pelvic fascia along with the nerve and artery. Retractors are placed and the blood vessels and nerves are separated. The nerve is grasped with a hemostat, silver clips applied, and a segment of nerve is removed. The skin is then retracted laterally below the inguinal ligament and the superficial



fascia is incised. The fascia overlying the iliopsoas muscle is split vertically 1 cm. lateral to the femoral canal. Directly beneath, the femoral nerve can be seen and picked up. Section is accomplished. The wounds are closed in layers. (Ed. This method is not considered applicable for selective neurectomy for relief of coxalgia.)

The Smith-Petersen nail is perhaps the most widely used form of internal fixation. Netto (24) describes a "nail starter" with the 3 flanges sharpened. Leonard (25) pointed out that the normal shape of the femoral neck in cross section is tear drop. When a nail appears to be satisfactorily placed, it actually may be retrocortical. This inferior ridge of bone on roentgenogram examination overlies the nail. (Ed. Adequate facilities for hip nailing include means for taking lateral views.)

Godard (26) uses a tapered-cannulated lag screw rather than a Smith-Petersen nail because it requires 30 times more force to pull fragments apart. He describes his portable fracture table with traction apparatus and perineal post and four small legs to provide space for x-ray plates beneath. He uses grids with 2 cm. squares to measure length of femoral neck and to judge direction of guide wire. This fixation has been used in about 20 cases, the first of which at the end of year had a good result and normal gait.

Screws, bolts, threaded wires, multiple pins and other agents each have their staunch supporters. Lippmann (27) advocates two corkscrew bolts and weight bearing in 6-8 weeks. He holds that the firm impaction possible with these devices is their advantage. Cronin (28) reports a fracture of the femoral neck treated by a Godoy-Moreira stud bolt screw which showed a good range of active motion two weeks postoperatively except that flexion was limited to 45 degrees.

De Palma (29) treats fresh adduction fractures by wedge osteotomy essentially converting them thereby to the abduction type of fracture so that instead of a shearing force and a hyperemic absorption there is an impacting force which enhances healing. A preliminary report of 22 cases is submitted as well as the technic and radiographic illustrations of the procedure. He permits partial weight bearing in 10 days and full weight bearing in 5 months. Union occurred in all cases but aseptic necrosis in two. Other injuries to the hip include dislocations. Gordon and Freiberg (30) report a case of posterior dislocation of the hip with a fracture of the inferior anterior portion of the head of the femur. Treatment was by excision of the fragment through an anterior approach. No aseptic necrosis developed and results were excellent one year after injury. The immediate treatment was closed reduction of the dislocated hip immediately after admission to the hospital. (Ed. One wonders if this patient might not have recovered with no surgery to remove the fragment which was not in the acetabulum and did not involve the weight bearing portion of the head of the femur.)

Stuck and Vaughan (31) in a study of 44 cases of traumatic dislocation of the hip are impressed with the less serious disability in those cases that received prolonged bed rest for treatment of other associated fractures. In this series of 44 dislocations, 36 were posterior, and there were accompanying fractures of the head of the femur in 3 cases. When there is a fracture of the head of the femur, open reduction is necessary only when the fragment of the head prevents replacement of the hip. In the last decade it has become



recognized that early weight bearing is unsafe. This development is directly related to a clearer understanding of the circulatory damage which occurs at the time of the accident. The blood supply to the head of the femur comes from the capsule, the ligamentum teres and the nutrient artery of the shaft. Of these sources, two (the capsule and ligamentum teres) are nearly always torn when the hip is dislocated. Every two months, roentgen examinations of the hip should be made to determine if there has been any change in the form or density of the bone or if any thinning of the joint space has taken place. If weight bearing is prevented for six months, these phenomena are unlikely to occur.

Bender (32) reviewed the literature on the subject of bilateral traumatic hip dislocations and reported the case of a patient successfully treated by traction and closed manipulation 19 days following injury. Ratkoczy (33) reported on a medico-legal case in which he appeared as an expert witness. He told the court that following a dislocation of a hip, myositis ossificans, traumatic arthritis, and necrosis of the femoral head may result.

Eight articles on slipped epiphysis are abstracted. Stovall (34) presents a review of the literature, a discussion of etiology, and a review of the anatomy and mechanics of slipped epiphysis. The roentgenographic findings in the early or "preslipping stage," the slipping stage, and the late stages are given. The author states that Key gave a classic description of the clinical manifestations and little has been or could be added to this. The variety of therapeutic procedures employed is considered as evidence that none is completely satisfactory. It is generally agreed that the earlier treatment is begun, the greater is the opportunity for success. Treatment must be continued with no lapse until closure of the epiphysis occurs and firm bony union is established between the head and neck of the femur.

Fyfe (35) presents a suggestion that there may be definite patterns of papillary projections at the capital femoral epiphyseal line, with reciprocal depressions on the opposed metaphyseal surfaces to produce an interlocking effect. Trivial injuries may thus account for displacement of the epiphysis if applied in a direction corresponding to the axis of the grooves and ridges.

Boyd et al (36) present a series of 40 cases of slipped femoral epiphysis with an average age of 13. The follow-up study period ranges from 12 months to 9 years. Treatment consisted of internal fixation with 3 Knowles pins. When the displacement was one-third the diameter of the head, operative correction of this angulation at the point of the deformity was performed followed by internal fixation with Knowles pins. In the first group, 88 per cent showed satisfactory results; whereas in the second group, 45 per cent showed satisfactory results; while 55 per cent showed complications consisting of aseptic necrosis, diminished joint space, or coxa magna.

Howorth (37) analyzes 243 cases. The pathological findings were, (1) In the preslipping stage: The synovial membrane appears grossly swollen with similar changes in the periosteum and capsule. No gross changes are seen in the head or acetabulum. Microscopic sections of the synovial membrane show edema, hypervascularity with low cell infiltration. Decalcification and increased vascularity are present at the junction of the neck and the epiphyseal disc. (2) In the slipping stage: The epiphysis is displaced downward and backward attached by periosteum and fibrous tissue which grow over the closed



portion of the neck as the slipping occurs. The cartilaginous epiphyseal disc remains attached to the head and is gradually transformed into bone. There is much callus between the head and the neck inferiorly and posteriorly which is covered by synovial membrane. In this stage, the articular cartilage of the head and acetabulum remain normal. Microscopically the soft tissue is the same as in the preslipping stage. (3) In the healing stage: Shows the callus incorporated with the neck. Bony union occurs between the epiphysis and the neck. The synovial membrane and periosteum in this stage become less vascular and the inflammatory process subsides after several months, but union of the epiphysis may require two or three years in severe slipping. With separation of the head and neck, degenerative changes in the head are the rule. (4) In the residual stage: Shows the lesion healed and the epiphysis solidly united to the neck in the displaced position. The synovial membrane and capsule are sclerotic and inelastic. Osteoarthritic changes may be present in the joint. It is pointed out that these lesions heal spontaneously and any type of treatment is of no value unless it produces a better result than that which would have been accomplished by nature. In cases where no therapy of any kind is used, the lesion heals in one to three years and the deformity and osteoarthritis are the main residuals. Osteoarthritis usually develops in middle life. The author described the "pegging" operation as the treatment of choice which has been used since 1930. Through a Smith-Petersen incision, the joint capsule is incised close to the head of the rectus femoris; exposing the junction of the head and neck. With an osteotome a triangular window is made in the neck anteriorly. Through this opening three drill holes are placed through the epiphyseal junction. Three pegs are cut from the wing of the ilium approximately  $1\frac{1}{2}$  inches in length and  $\frac{3}{16}$  inch in diameter and inserted into the drill holes in the head. The window is covered with a small piece of muscle and the wound closed. Postoperatively, the extremity is suspended and active motion is begun in a few days. Walking is begun in 8 to 12 weeks and full activity resumed 4 months after surgery. This pegging operation has been used in 134 hips, in patients ranging from 8 to 17 years of age.

In no case did slipping occur after the pegging operation. The author feels that there are changes in the acetabulum in cases in which nailing of the hip is done, and that there are no such changes seen after pegging. Osteotomy of the neck of the femur in 3 cases gave results which were poor, with degenerative changes. Subtrochanteric osteotomy was used in 10 hips. The position of the fragments in this type of treatment could not easily be controlled with or without internal fixation. In conclusion, the author states that the hip should never be held in a position of tension, especially extension, abduction, and internal rotation because this further embarrasses the circulation and degenerative changes are more apt to result. Secondly, no operation should be done when acute pain and spasm are present or not at least until after two or three weeks bed rest.

Heyman (38) reports a study of 42 cases. Manipulation and plaster with the extremity widely abducted and internally rotated was the method of treatment in 21 cases. The clinical results were good to excellent in 81 per cent of the cases treated by manipulation. Manipulation with cast appeared to bring about a fairly prompt fusion of the epiphysis. The roentgenological result was good in 67 per cent of the cases in which manipulation was carried out. Twenty-eight per cent are classified as having a fair result and one case (5 per cent) had a poor result.



A survey of 51 cases treated by nailing is described by Klein and Joplin (39). The authors emphasize early mobilization and active weight bearing on crutches within 2 or 3 weeks after operation. In the 35 cases nailed in situ, traumatic arthritis and aseptic necrosis did not occur. Sixteen patients with slipping of more than 1 cm. were treated with osteotomy through the epiphyseal plate and nailing, and traumatic arthritis was encountered in two cases.

Twenty cases treated with wedge osteotomy of the neck of the femur are reported by Wagner and Donovan (40). Twelve had excellent results, 3 good, 1 fair, and 3 poor.

Five articles on Legg-Perthes' disease were selected. The first by Markheim (41) is the report of a case of Legg-Perthes' disease of one hip at the age of 11 and two years later, a slipped epiphysis in the other.

Howorth (42) describes coxa plana as a disease of the hip, usually occurring between the ages of 4 to 10 years and running a self-limited course. It is one of a group of diseases, the osteochondroses, which includes Osgood-Schlatter's disease and Scheuermann's disease. Eighty-five per cent of cases occur in boys and about 25 per cent of cases of congenital dislocation of the hip develop the disease. The pain follows the distribution of the obturator nerve. The diagnosis is made by x-ray. Treatment consists of rest in bed; no weight bearing should be allowed until healing is evident, usually in 1 to 3 years. The use of the drilling operation, placing 3 or 4 holes through the epiphyseal plate, was thought by the author to reduce the total amount of degeneration as well as to shorten the period of convalescence by about one-third.

Investigating the etiology of this condition, Randlov-Madsen (43) was able to produce it in young rabbits by injecting alcohol around the vessels and nerves to the femoral head. The microscopic, radiographic, and histologic changes thus produced resembled Calve-Perthes' disease, suggesting that this condition may be produced by a disturbance of growth of bone tissue influenced by constitutional, hormonal and traumatic factors.

Bromer (44) states that the primary process in Legg-Perthes' disease is an aseptic necrosis followed by resorption of necrotic cancellous tissue and, last, formation of new bone and cartilage. Reports have appeared of other conditions which can simulate the appearance of Legg-Perthes' disease, such as hypothyroidism, Gaucher's disease, the end results of reduced congenital dislocation of the hip, and possibly, the changes seen in caisson disease. The clinical history and physical signs are essential for correct interpretation of roentgen findings.

Bettman and Siffert (45) describe the radiographic appearance of the femoral capital epiphysis in Calve-Legg-Perthes' disease in the stages of aseptic necrosis followed by granulation tissue invasion or creeping substitution. During this plastic stage, the epiphysis is vulnerable to the deforming effects of pressure and weight bearing. This plastic phase of reconstitution may extend as long as four years and the criteria of its progress are the roentgen findings. Often roentgen examination is inadequate to reveal early evidence of Perthes' disease and large defects may be overlooked. Study of a series of 40 cases of Legg-Perthes' disease and experimentation with a specimen of a femur in which the portion representing the



capital epiphysis was sectioned into quadrants, revealed that overlapping of normal bone often makes it difficult to detect a defect on routine roentgen views even when an entire quadrant has been removed. Since unwise decisions for too early weight bearing may jeopardize the possibility of a well-functioning hip, it was recommended that more careful roentgen examination be employed in such cases, utilizing the "four plane" method which includes an antero-posterior projection of the entire pelvis including both hips simultaneously in the neutral position, internal and external rotation and lateral views. This method can be used in other types of hip disease where serial check-ups of localized lesion are necessary.

Haythorn (46) reports the pathological findings in 33 cases of Legg-Calve-Perthes disease. Material was curetted from the femoral heads and neck and studied microscopically. The author concludes that (1) changes are constant and show aseptic necrosis, degeneration and repair, partial ossification of displaced cartilage tissue, loss of polarity of cartilage cells, small cyst-like areas and giant cells in the wall of fibrous areas of degeneration; (2) disturbed metabolism appears to be substantiated by pathological study rather than trauma or infection.

A study of the arterial supply to the femoral head is reported by Tucker (47) who points out that the literature is contradictory and in need of clarification. His study was made of 44 femurs from fresh cadavers and the arterial system demonstrated by injections of radio-opaque material for x-ray examination. Histological sections of the neck and ligamentum teres were made. Three groups of vessels supply the upper femur, (1) the nutrient artery of the shaft, (2) the retinacular arteries of the capsule, and (3) the foveolar artery of the ligamentum teres. The retinacular vessels are the chief supply to the epiphysis and femoral head at all ages, and consist of three separate groups, (1) postero-superior, (2) postero-inferior, and (3) anterior. The foveolar artery constitutes a small subsidiary blood supply to the femoral epiphysis, penetrating the head in 33 per cent of young specimens and 70 per cent of adult specimens. The foveolar vessels increase in size with age and never constitute the chief vascular supply in children, hence the site of obstructive lesions causing avascular necrosis must be in the retinacular group. Epiphyseal fragmentation after reduction of congenital dislocation of the hip is probably due to avascular necrosis from pressure on the postero-superior retinacular vessels. Abduction beyond 45 degrees, especially with tight adductor muscles, may cause vascular impairment. Adductor tenotomy is considered preferable to forcible stretching. Avascular necrosis is not a frequent complication of gradual epiphyseolysis, but may occur as a result of damage to the retinacular and foveolar vessels in rapid displacement or as a result of vigorous manipulation or operative reduction.

In fractures of the femoral neck, there is likelihood of damage to the retinacular vessels. Since the interosseous vessels are necessarily destroyed, it is seen that the head is dependent in some cases upon the foveolar supply. Certainly every effort should be made to avoid damage to the foveolar arteries. The incidence of avascular necrosis in hips fixed with a Smith-Petersen nail is higher than in those fixed by multiple small nails, due to the greater interruption of foveolar and other vascular channels by the larger nail. Avascular necrosis following traumatic dislocation of the hip joint occurs as a result of foveolar vessel damage present in nearly every case, and a



variable degree of retinacular damage.

Flashman and Ghormley (48) review 21 cases of osteochondritis dissecans of the femoral head which have appeared in the literature up to 1946. The authors believe the causative factor to be subclinical trauma and occasionally severe trauma with its resultant disturbance in the circulation to the supero-lateral aspect of the head of the femur. Roentgenographic findings consisted of fragmentation of the bony nucleus with subsequent patchy decalcification and sclerosis in the early stages. As the disease progressed, hypertrophic arthritis was seen. Treatment of three cases by conservative nonweight bearing methods produced poor results. Simple surgical excision of the area of osteochondritis dissecans produced good results in two of three cases so treated. Two cases treated by drilling multiple holes to aid in revascularization without disturbance of soft tissue had good results. Three cases with the disease well advanced were treated with drilling followed by packing with small fragments of cancellous bone under the area of osteochondritis dissecans to maintain the contour of the head of the femur. Two cases had good results. Patients with advanced osteoarthritis were best treated with some form of arthroplasty or arthrodesis.

Phemister (49) points out that aseptic necrosis of the head of the femur in adults results from interruption of circulation by physical injury and nontraumatic occlusion of blood vessels as seen in caisson disease. Fracture and collapse of the head, after healing of the original fracture line, occur because the newly formed bone in the creeping substitution is for many days weaker than the old dead bone which it has replaced, and it will not withstand weight bearing during this period. Drilling and bone-pegging allow rapid replacement by new bone and thus prevent the occurrence of collapse and fracture.

Horwitz (50) and Robinson (51) discuss osteoarthritis of the hip from the surgical and medical standpoint respectively. The etiology, pathology, x-ray and clinical findings are described. Medical treatment consists of reassurance, bed rest, diet, vitamins, sedation, attention to foci of infection, exercises, traction, whirlpool, manipulation and procaine injections into joint and sciatic nerve. A review of the surgical treatment indicates that arthrodesis is the most reliable method and gave excellent results in about 70 per cent while arthroplasty gave excellent results in only about 40 per cent. The early adequate treatment of congenital and developmental deformities was emphasized in order to prevent osteoarthritis.

Kernwein (52) reviews the surgical treatment of osteoarthritis of the hip. It is pointed out that the prime function of treatment is to eliminate pain. Obturator neurectomy is widely applicable and gives good results in most cases. It also paralyzes the adductor muscles and releases muscle spasm. In many instances, the range of motion will be greatly increased and with correction of the flexion deformity the lumbosacral strain is eliminated and the backache greatly relieved. Arthroplasty is a technically difficult, shocking surgical procedure. The only absolute indication for arthroplasty is bilateral hip disease in which motion in both hips is lost. The vitallium cup technic is considered superior to other types. The indications for arthrodesis of the hip are: (1) failure to relieve pain by means of a lesser surgical procedure, (2) unilateral hip disease with the configuration of the



joint such as to preclude arthroplasty, (3) occupational requirements placing a premium upon a painless, stable hip, (4) willingness of the patient to accept a stiff hip. Arthrodesis is contraindicated in cases with significant degenerative disease of the spine or other hip.

Wiltse and Thompson (53) report 7 cases of absence of the femoral head and neck in which arthrodesis was performed. An operative technic is described which consists of a Smith-Petersen incision and the stripping of the musculature from both lateral and medial surfaces of the ilium and the entire upper femur down to the lowest point of the lesser trochanter. The acetabulum is exposed and the cartilage excised down to bleeding bone. A notch is made in the upper outer portion of the trochanter and a corresponding wedge fashioned in the superior acetabular rim. These are fitted together and a Lorenzo screw used for fixation. Flaps of bone are raised from the ilium and trochanter, and cancellous bone placed under the flaps. A hip spica cast is worn for about six months. Six of the seven cases resulted in successful fusion.

Smith-Petersen (54) states that joint surfaces must be shaped so as to function through the greatest possible arc without impingement. Thus, in the hip joint, it is necessary to expose the acetabulum as well as the femoral head and neck. The skin incision suggested extends from the junction of the middle and anterior thirds of the iliac crest to the anterior superior spine, deviating laterally along the medial border of the tensor fasciae latae. The anterior third of the ilium is exposed by the periosteal reflection. The iliopsoas is retracted medially. The rectus muscle and acetabular origin of the iliacus muscle are divided. An osteotomy of the anterior inferior iliac spine and the anterior acetabular wall is performed. This facilitates dislocation of the joint. The mold must be loosely fitted so as to allow the greatest possible range of motion between it and reshaped surfaces of the femoral head and acetabulum. In closure, the rectus is sutured and the abdominal muscles and fascia are sutured to the gluteal muscles and fascia.

Several interesting reviews are published. Gibson (55) presents a study of 111 cases of cup arthroplasty using a posterior approach, Stinchfield and Carroll (56), 45 cases, and Smith (57), 6 cases. Good results were obtained in 65-70 per cent. Patients with rheumatoid arthritis and Marie-Strumpell's disease were the least satisfactory.

Judet and Judet (58), (59), (60) review 2½ years experience with replacing femoral heads with their methyl methacrylate hip prosthesis in 126 cases. Pain was the chief indication for surgery. The oldest patient was 73 but one-half were over 60. Their technic is to expose the hip joint through an anterior incision, bore and shape the neck, drive on the prosthesis, apply a plaster cast for 25 days and start patients walking on the 35th day. Their results are 80 per cent relief of pain; the remaining 20 per cent usually can walk instead of being bedridden. After surgery there is no appreciable shock. Complications have been few, one death was from uremia on 21st day in an unrecognized nephritic. The pivot of 3 early prostheses broke. Now they are reinforced with a rod of stainless steel. They point out that years of observation are necessary to be certain of the final result.

Delorme and Watkins (61) discuss progressive resistance exercises in cup arthroplasties of the hip, then recommend that on the third postoperative



day the patient be started on exercises for the knee extensors, hip rotators, abductors, and extensors. These exercises are performed each waking hour during the first four weeks while the extremity is in suspension traction. During the next four weeks, the active nonresistive hip exercises are continued and in addition, a stationary bicycle is used for 10 minutes twice daily. Ambulation is initiated in a walker with minimal weight bearing, and later stair climbing. Full weight bearing is started between the sixth and ninth month. Twenty cases were presented. The authors attributed limping and pain to muscular weakness, and felt that by intensive therapy to strengthen the muscles, the symptoms could be relieved.

Three other papers on miscellaneous conditions of the hip joint were considered. Osteoporosis as a cause of hip fractures is discussed by Cobey (62) and his treatment includes high calcium, adequate vitamin D diet, and estrogenic therapy. Catterall (63) presents a case in which the first clinical manifestations of Charcot's disease of the hip joint became evident five years later after the original infection.

Babb et al (64) write on coxa vara. They state that the most attractive etiological theory of congenital coxa vara is that it involves an embryonic vascular disturbance. The pathological change seen is that of slipping of the head, due to a defect in the femoral neck. The Trendelenburg test is positive on the involved side. X-ray reveals that the femoral neck is bent so that the head is depressed and the distal part of the limb adducted. The aim of treatment is to promote ossification in the neck of the femur and to correct any deformity already present. Subtrochanteric osteotomy at about six to eight years of age, with wide abduction of the distal part of the limb is the treatment of choice. Adolescent and adult patients with untreated lesions exhibit what amounts to nonunion of the femoral neck. The Brackett operation is used in these adult cases. The author presented 15 cases of this condition and discussed them.



## BIBLIOGRAPHY

1. Fahey, J. J.: Conditions involving the hip joint, Arch. Surg., 58: 89-96, Jan 1949
2. Chandler, F. A.: Fractures of the upper end of the femur, Mississippi Valley M. J., 71: 83, May 1949
3. Murray, R. C., and Frew, J. F. M.: Trochanteric fractures of the femur; a plea for conservative treatment, J. Bone Surg., 31-B: 204-19, May 1949
4. Evans, E. M.: The treatment of trochanteric fractures of the femur, J. Bone Surg., 31 B: 190-203, May 1949
5. Boyd, H. B., and Griffin, L. L.: Classification and treatment of trochanteric fractures, Arch. Surg., 58: 853-66, June 1949
6. Funsten, R. V., and Frankel, C. J.: The treatment of intertrochanteric fractures, South. Surgeon, 15: 91-6, Feb 1949
7. Spears, G. N., and Owen, J. T.: The etiology of trochanteric fractures of the femur, J. Bone Surg., 31 A: 548-52, July 1949
8. Rountree, C. R.: Subtrochanteric fractures of the femur, J. Oklahoma M. Ass., 42: 128-30, Apr 1949
9. McElvenny, R. T.: Management of intrascapular hip fractures, Surg. Clin. N. America, 29: 31-58, Feb 1949
10. Spotoft, J.: Osteosynthesis of the neck of the femur, J. Bone Surg., 31 A: 836-846, Oct 1949
11. Luomanen, R. K. J., and Prudden, J. F.: Internal fixation of fractures of the femoral neck, Am. J. Surg., 78: 189-98, Aug 1949
12. Gallagher, J. T. F.: End results in 77 consecutive fresh fractures of the neck of the femur, Jackson Clin. Bull., Madison, 11: 142-6, Sept 1949
13. Hogg, T. G. H.: Fractures of the neck of the femur, Med. J. Australia, 2: 593-7, Nov 20, 1948
14. Apfelbach, G. L., and Weinstein, L.: The solved and unsolved problems of femoral neck fractures, Q. Bull. Northwest. Univ. M. School, 23: 276-9, Fall, 1949
15. Fahey, R. J., Kilfoyle, R. M., and Shortell, J. H.: Medical considerations in the care of elderly patients with hip fractures, N. England J. M., 241: 325-30, Sept 1, 1949
16. Snedecor, S. T.: A restoration program for hip fractures, Geriatrics, 4: 18-21, Jan-Feb, 1949



17. Moser, H. H. P.: Local analgesia for surgical treatment of fractured neck of femur, *Brit. J. Anaesth.*, 21: 145-8, Jan 1949
18. Ergenbright, W. V., and Lowry, F. C.: Procaine injection for relief of pain in the hip, *J. Bone Surg.*, 31 A: 820-822, Oct 1949
19. Kaiser, R. A.: Obturator neurectomy for coxalgia, *J. Bone Surg.*, 31 A: 815-819, Oct 1949
20. Key, J. A., and Reynolds, F. C.: Intrapelvic obturator neurectomy for the relief of chronic arthritis of the hips, *Surgery*, 24: 959-67, Dec 1948
21. Oblatz, B. E., Lockie, L. M., et al: Early effects of partial sensory denervation of the hip for relief of pain in chronic arthritis, *J. Bone Surg.*, 31 A: 805-814, Oct 1949
22. Oblatz, B. E.: Relief of pain in osteo-arthritis of the hip by partial denervation of the hip joint, *Ann. Rheumat. Dis. Lond.*, 7: 255, Dec 1948
23. Freeman, J. W.: A simple combined approach to the obturator and femoral nerves, *Surgery*, 24: 968-7, Dec 1948
24. Netto, L. J.: Fracture of the neck of the femur; an instrument to facilitate the introduction of the Smith-Petersen nail, *Am. J. Surg.*, 77: 537-9, Apr 1949
25. Leonard, M. H.: Low insertion of the hip nail, *J. Bone Surg.*, 31 A: 612, July 1949
26. Godard, H.: Le vissage des fractures du col, *Rev chir. Par.*, 86: 365-78, Nov-Dec, 1948
27. Lippman, R. K.: Recent experiences with the corkscrew bolt in fractures of the hip, *Am. J. Surg.*, 78: 54-64, July 1949
28. Cronin, J. D.: Fractures of femoral neck treated with a Godoy-Moreira stud bolt screw, *Proc. R. Soc. M., Lond.*, 41: 852, Dec 1948
29. De Palma, A. F.: Wedge osteotomy for fresh intracapsular fractures of the neck of the femur, *Ann. Surg.*, 129: 323-32, March 1949
30. Gordon, E. J., and Freiberg, J. A.: Posterior dislocation of the hip with fracture of the head of the femur, *J. Bone Surg.*, 31 A: 869-872, Oct 1949
31. Stuck, W. G., and Vaughan, W. H.: Prevention of disability after traumatic dislocation of the hip, *South Surgeon*, 15: 659-75, Sept 1949
32. Bender, T. J., Jr.: Bilateral traumatic hip dislocations, *Jefferson Hillman Hosp. Bull.*, 3: 115-9, July 1949



33. Ratkoczy, N.: Late complications of traumatic dislocations of the hip joint, *J. Internat. Coll. Surgeons*, 12: 728-34, Sept-Oct, 1949
34. Stovall, S. L.: Separation of the capital femoral epiphysis in the adolescent, *Surg. Gyn. Obst.*, 88: Suppl. 193-203, Mar 1949
35. Fyfe, F. W.: Some features of the interlocking pattern at the upper epiphyseal surface of the femur with reference to the slipped epiphysis, *J. Anat. Lond.*, 83: 85, Jan 1949
36. Boyd, H. B., Ingram, A. J., and Boukard, H. O.: The treatment of slipped femoral epiphysis, *South M. J.*, 42: 551-60, July 1949
37. Howorth, M. Beckett: Slipping of the upper femoral epiphysis, *J. Bone Surg.*, 31 A: 734-747, Oct 1949
38. Heyman, C. H.: Treatment of slipping of the upper femoral epiphysis; a study of the results of 42 cases, *Surg. Gyn. Obst.*, 89: 559-65, Nov 1949
39. Klein, A., and Joplin, R. J., et al: Roentgenographic changes in nailed slipped capital femoral epiphysis, *J. Bone Surg.*, 31 A: 1-22, Jan 1949
40. Wagner, L. C., and Donovan, M. M.: Wedge osteotomy of the neck of the femur in advanced cases of displaced upper femoral epiphysis; 10-year study, *Am. J. Surg.*, 78: 281-313, Sept 1949
41. Markheim, H. R.: Legg-Perthes disease and slipped epiphysis in the same patient; a case report, *J. Bone Surg.*, 31 A: 666-8, July 1949
42. Howorth, M. B.: Coxa plana, *J. Bone Surg.*, 30 A: 601-620, July 1948
43. Randlov-Madsen, A.: Experimental investigations into the aetiology of Calve-Perthes disease, *Acta orthop. scand.*, 19: 6-18, 1949
44. Bromer, R. S.: Legg-Perthes disease, *Am. J. Roentg.*, 61: 248, Feb 1949
45. Bettman, E. H., and Siffert, R. S.: Roentgen examination of the hip in Legg-Perthes disease, *Radiology*, 53: 548-51, Oct 1949
46. Haythorn, S. R.: Pathological changes found in material removed at operation in Legg-Calve-Perthes disease, *J. Bone Surg.*, 31 A: 599-611, July 1949
47. Tucker, F. R.: Arterial supply to the femoral head and its clinical importance, *J. Bone Surg.*, 31 B: 82-93, Feb 1949
48. Flashman, F. L., and Ghormley, R. K.: Osteochondritis dissecans of the head of the femur, *West. J. Surg.*, 57: 221-8, June 1949
49. Plemister, D. B.: Treatment of the necrotic head of the femur in adults, *J. Bone Surg.*, 31 A: 55-66, Jan 1949



50. Horwitz, T.: Degenerative osteoarthritis of the hip joint; survey of degenerative arthritis secondary to aseptic necrosis of the femoral head, Arch. Surg., 58: 251-72, March 1949
51. Robinson, A.: Osteoarthritis of the hip, Canad. M. Ass. J., 60: 161-5, Feb 1949
52. Kernwein, G. A.: The surgical treatment of degenerative disease of the hip joint, J. Lancet, 69: 74-79, Mar 1949
53. Wiltse, L. L. and Thompson, W. A. L.: Technic for arthrodesis of the hip when the femoral head and neck are absent, Arch. Surg., 59: 888-95, Oct 1949
54. Smith-Petersen, M. N.: Approach to and exposure of the hip joint for mold arthroplasty, J. Bone Surg., 31 A: 40-6, Jan 1949
55. Gibson, A.: Vitallium cup arthroplasty of the hip joint; review of approximately 100 cases, J. Bone Surg., 31 A: 861-8, Oct 1949
56. Stinchfield, F. E., and Carroll, R. E.: Arthroplasties of the hip, N. York State J. M., 49: 159-62, Jan 15, 1949
57. Smith, F. B.: Vitallium cup arthroplasty in the treatment of degenerative arthritis of the hip; report of six cases, Portland Clin. Bull., 3: 29-40, Sept 1949
58. Judet, R. and Judet, J.: Essais de reconstruction prothetique de la hanche apres resection de la tete femorale, J. chir., Par., 65: 17-24, 1949
59. Judet, J. and Judet, R.: Indications techniques et resultats du traitement chirurgical dans les arthrites chroniques de la hanche, Concours Med., 71: 111, Jan 15, 1949
60. Judet, J. and Judet, R.: Reconstruction de la hanche apres resection, Praxix, Bern, 38: 247, Mar 17, 1949
61. De Lorme, T. L. and Watkins, A. L.: Progressive resistance exercises in cup arthroplasties of the hip, Arch. Phys. M., 30: 367-74, June 1949
62. Cobey, M. C.: Fractures of the neck of the femur due to osteoporosis, Med. Ann. District of Columbia, 18: 243-9, May 1949
63. Catterall, R. C. F.: Charcot's disease of the hip joint, Proc. R. Soc. M., Lond., 42: 92, Feb 1949
64. Babb, F. S., Ghormley, R. K., and Chatterton, C. C.: Congenital coxa vara, J. Bone Surg., 31 A: 115-31, Jan 1949



## CHAPTER V

### CONDITIONS INVOLVING THE FOOT AND ANKLE

By

I. G. Jordan, Major, M. C., U. S. A.

One hundred and seventeen titles were submitted on this subject and 58 are abstracted below.

Of general interest is a 47-page study of the foot measurements of 8,232 Swedish conscripts by Dahlberg and Lander (1). They found the expected correlation between foot length and stature but none between foot length and occupation. Harris and Beath (2) report a follow-up on 1,391 of 3,619 Canadian soldiers examined initially. They present evidence that a short first metatarsal is seldom responsible for foot disability. Hubay (3) presents a roentgenologic study of the sesamoid bones of the hands and feet. The differential points between fracture and bipartition are brought out. The criteria for fracture of the sesamoids are as follows: (1) Irregular and unequal separation of the affected sesamoid with the fragments possibly being serrated, (2) Evidence or attempt at healing by formation of callus in the subsequent roentgenograms, (3) Absence of similar findings in roentgenograms taken of opposite side, (4) If operative removal has been done, gross and microscopic pathological evidence of fracture.

Congenital clubfoot is the subject of an article by Galloway (4). Surgical release of contracted soft tissue is discussed followed by plaster correction and metal clubfoot splints. Allan (5) briefly reviews the subject of congenital clubfoot.

Metatarsus adductovarus is distinguished from the rare metatarsus varus by McCormick and Blount (6) and the term "skewfoot" is offered as a simple synonym for the more commonly encountered condition. The incidence of skewfoot is increasing while that of clubfoot remains the same. The characteristic change in the foot is adduction of the metatarsals, most in the first and least in the fifth. There is always a valgus deformity of the heel. Depending upon the severity a cavus deformity may also develop. An abnormal attachment of the anterior tibial tendon is sometimes a deforming factor. The deformity is amenable to adequate early manipulative treatment with casts. Severe or untreated skewfoot in the older child requires operative treatment for adequate correction.

On painful conditions of the foot and ankle, Lewin (7) writes that disturbances of the foot and ankle may be congenital, infectious, traumatic, mechanical, paralytic or arthritic. Occupational and industrial conditions, tumors and a large group of miscellaneous conditions are contributing causes. Conservative treatment of flat feet, metatarsalgia and calcaneal spurs is discussed.

Hauser (8) points out that the symptoms which follow acute injury to



the foot are not necessarily in proportion to the extent of injury but may be due to secondary flat foot or weakness. He manipulates fractures early and uses compression dressings to hasten the subsidence of swelling before applying a cast. Statistical data on flat foot is given by the Navy (9). Noe et al (10) state that although the transplantation of muscles is not a success in most cases and is not generally accepted as good treatment, in some cases it has to be tried. The technique they use consists of transplanting the common extensor tendons from the toes to the head of the first metatarsal.

Pipkin (11) discusses the prognosis of sprains. Good (12) believes that many cases of painful feet are due to myalgia of the intrinsic muscles and cures them by injection of novocain.

Lake (13) analyzes the effect of high heels and states that the great majority of common foot complaints are shown to be directly the result of wearing high heels.

Schwartz and Heath (14) write that pronation in childhood is an expression of deficiency in the osteo-articular structures of the foot. By applying the principles of Wolff's law, pronation can be greatly improved or entirely eliminated by the time the child is 16. Full understanding of the needs of the human foot in action awaits the further application of measurements to the study of foot dynamics. Proved principles can then replace opinion in the design of shoe lasts and in the application of therapeutic measures.

Liebolt (15) discusses briefly several common orthopedic foot problems in children from the standpoint of diagnosis and treatment by the pediatrician.

Among the specific causes for foot pain, Morton's toe is the subject of papers by Fett and Pool (16), Redler (17), and Moore and Meredith (18). The usual symptoms are severe, sharp burning pain in the region of the head of the fourth metatarsal not relieved by orthopedic appliances, and a common finding is hypesthesia over the lateral side of the third and the medial side of the fourth toe.

Hammer toes are discussed by Coltart (19), and Ducroquet et al (20) write on the cure of hallux valgus by arthroplasty with interposition of cartilage.

Surgical treatment of painful clavus and case reports are presented by Lecoq (21) and Hoffman (22). Phalangectomy is applied for hammer toe, contractures due to arthritis, congenital overlapping and other deformities by Glassman et al (23).

The treatment of plantar warts in a Navy hospital is summarized by Wright (24). One hundred and six cases treated by carbon dioxide snow gave a cure rate of 96.9 per cent. Pipkin et al (25) treated 1,744 plantar warts by single massive doses of x-ray and obtained 91 per cent cures.

The three Montgomerys, A. H., R. M., and D. C. (26) present an excellent exposition on the problem of plantar radiodermatitis. The authors state that it is usually the result of carelessness on the part of physicians administering radiation therapy. The reason is failure to bring out in the history



information on previous radiation. It is best not to treat plantar warts with radiation when this has been used elsewhere. The differentiating points in the diagnosis of plantar radio-dermatitis is brought out in the article. Lesions 0.4 cm. in diameter should be treated by surgery. Those smaller than 0.4 cm. should have six months conservative treatment which is outlined. Surgical correction consists of local excision, with or without full thickness graft, or removal of a V-shaped area of the foot, the metatarsal and phalanx of the involved area. The last procedure, while radical, has given very satisfactory results. The only disadvantage is the difference in foot size.

Hempelmann (27) and Williams (28) write on the potential dangers of radiation exposures from the use of shoe fitting fluoroscopes. Dosages range from 0.5 to 5.8 per second, and the time of exposure from 5 to 45 seconds. Wall leakage may range 3 to 60 m r per hour and scattered radiation amounts to more than 100 m r per hour at distances up to ten feet from the unit. The most likely injuries are interference with normal foot development of children; acute radiation burns, and chronic radiation injury to the blood forming tissue of store employees. The dose necessary to cause epiphyseal damage is nearly equal to erythema dose.

If conservative treatment of Achilles bursitis fails, writes Wahren (29), not only the bursa but the posterior superior edge of the calcaneus has to be removed. Two cases of solitary cyst of the calcaneus are reported by Dunn (30). Sixteen cases have been reported previously.

Osteochondritis of the talus is discussed by Marek (31), Bailey (32), and D'Agostino (33). It is a frequent finding perhaps due to articular fracture. Surgical removal is recommended and a guarded prognosis is emphasized. The latter author reports a case in a child of six years.

Another source of pain is calcareous peritendinitis of the feet. Miller (34) reports a case involving the peroneal tendons and believed to be associated with the patient's occupation.

The pathology of trench foot is the subject of a detailed report by Block (35). Initially there is vasoconstriction which coincides with numbness and a pale appearance of the foot. Vasoconstriction is then replaced by vasodilatation and transudation of fluid. The escape of fluid leaves a dense mass of erythrocytes filling the distended vessel and greatly interfering with the circulation. Changes in permeability of vessels due to toxins allow RBCs to escape causing formation of hemolytic bullae. Thereafter degenerative changes occur in more specialized structures, epidermis, muscle, nerve, and marrow.

Reflections on Raynaud's disease by Wertheimer and Guillet (36) are based on the results in 35 cases treated surgically. Seventy sympathectomies were done. Periarterial sympathectomy cases all retained their sensitivity to cold but in 33 per cent, the progress of the disease was checked. Resection of the upper portion of the thoracic chain with or without stellate ganglionectomy is the most effective procedure in the treatment of patients with Raynaud's disease.



Silverman (37) reports a case of a soldier with burning pain of the extremities which he designates as erythermalgia and erythromelalgia.

Nino (38) reports a case of Madura foot in a young woman, caused by Madura mycotic mycetoma with white grains. The parasite was classified as *Allescheria boydii* Shear, 1921. This is the first case reported in Argentina and the third in the world literature. Moreau (39) reports a case of Madura foot which confirms the theory that the radiographic changes of patchy bone destruction are as important diagnostically as the laboratory findings.

An 82-page monograph on elephantiasis is contributed by Reyes-Pugnaire (40). It is based on 117 cases and discusses the various methods of surgical treatment. Conservative measures are not effective. Two hundred and fifty bibliographic references are given.

Common fractures of the foot by Bilcliffe (41) are grouped as (1) Fractures of the os calcis, (2) Fractures of the talus, and (3) Fractures of the navicular. Methods of treatment are described.

Ferciot and Stone (42) outline their conception of the management of fractures of the os calcis. They routinely use early reduction and immobilization and parasympathetic blocks with ammonium sulphate. At the end of 6-9 weeks the cases are evaluated and subastragalar arthrodesis done if it is felt that conservative treatment will be unsatisfactory.

Bateman (43), a veterinarian, describes a fresh approach to the repair of the os calcis in the greyhound.

Lambotte (44) discusses the painful "traumatic flat foot" that sometimes results from old fractures of the os calcis and describes an operation which he has done in two cases. A wedge is removed through a longitudinal incision over the cuneiform to correct the forefoot valgus. Its base is 2 cm. and it tapers to a point at the lateral margin of the foot. Then through a posterior incision, the os calcis is osteotomized horizontally throughout its length making a "duck bill" and the wedge is inserted to restore the tuber angle and the plantar arch. Both osteotomies are maintained by steel staples. The patient walks in 5 or 6 weeks.

Girardi and Olavarria (45) describe temporary internal fixation of posterior avulsion fractures of the os calcis with a transfixing Kirschner wire left in place for a month after suturing the fracture with chromic catgut.

Fractures of the astragalus are discussed by Foley (46). He divides them into four groups and the treatment in each group is described, (1) fractures of the neck without displacement, (2) fractures with impaction, (3) fractures with partial dislocation of the body and (4) fractures with complete dislocation of the body. The complications of such fractures are discussed. Jensenius (47) presents a series of 37 cases of fracture of the astragalus. Excision is often advised for fracture of the posterior process. The author emphasizes the importance of prolonged protection from weight bearing (12-20 wks) on the fresh fracture and the value of arthrodesis in the treatment of sequela.



Geckler (48) describes a method of maintaining the position of openly reduced dislocations by means of Kirschner wires.

Hatchette (49) reports a case of subtaloid dislocation of the foot. Several articles on foot stabilization operations are noteworthy. Ritter (50) discusses the indications for triple arthrodesis in deformities of the foot due to infantile paralysis and a summary of the history of the operation is presented. The operation is not recommended before the age of seven. The technic described by Ryerson, 1923, is given in detail. Rizzo and Lehmann (51) report 82 cases in which triple arthrodesis was used without follow-up. A study of the failure of fusion of the tarsal bones is given by Friedenberg (52) on the basis of 53 cases followed three years. They were analyzed to determine: (1) the incidence of bony bridging, (2) the effect of pathology on union, (3) most successful types of operation, (4) the joints most difficult to fuse, and (5) the reasons for failure. Twenty-three per cent of the 65 arthrodeses failed and the incidence was less in poliomyelitis than it was in cerebral palsy and clubfoot. The talo-navicular joint was most resistant to union and accounted for 73 per cent of failures. No one procedure was significantly more effective. The accurate cutting of wedges and positioning of the foot was emphasized.

Key (53) without going into detail, points out that in selected cases reconstruction procedures on arthritic feet are met with a great deal of success and comfort to the patient.

Bentzon and Agerholm-Christensen (54) feel that the ingenious operation of Lambrinudi for foot drop has not gained the popularity it deserves. The technic is described. Since 1945 the method has been used on 23 feet; 14 of poliomyelitis, 2 with peroneal palsy, one spastic, 4 with old clubfeet and 2 with equinus deformities. The preliminary results are promising but the possibility of future osteoarthritis from the continued strain of the ankle joint is mentioned.

Fractures of the medial malleolus are treated by Banks (55) by packing cancellous bone from the tibia across the fracture and fixation of the fragments with a screw. Sutro (56) summarizes 72 cases and concludes that fractures distal to the horizontal articular surface with wide separation of the fragments are best treated by excision. Fractures more proximal are given three months trial by immobilization before surgical intervention. Microscopic studies showed no aseptic necrosis and the author surmizes that delayed union is due to persistent mobility.

Kristensen (57) analyzes 200 cases of malleolar fractures treated by Lange-Hansen's method without open reduction. Eighty-nine per cent of the results were good in the 158 cases which were followed.

Dupuis and Hachez-Leblanc (58) discuss the mechanism of tibio-tarsal diastasis in the torsion fractures of the malleoli. They obtained better results with immediate operative reconstruction than with the plaster boot.

Borsotti (59) presents a discussion of torsion fractures involving the malleoli and astragalus from the point of view of aetiology, symptoms,



pathology and methods of treatment.

An experimental study of injuries to the lateral ligaments of the ankle is presented by Leonard (60). The anterior talo-fibular ligament is the important component of the fibular collateral ligament of the ankle. Inversion x-rays should be taken in severe sprains; if tenderness anterior to fibula, x-ray with foot inverted in equinus; if tenderness posterior, take film with foot inverted in neutral dorsiflexion. Unstable ankles should be immobilized in walking plaster for about six weeks and strapped for an additional 2-3 weeks.

Miscellaneous conditions which may involve the ankle include hernia of the anterior tibial muscle of which Oldfield (61) writes that two types of this herniation occur. Congenital defects are usually multiple and smaller than those due to trauma. Surgical correction is usually necessary.

Traumatic lesions of the sciatic nerve or its branches are presented by Fontaine et al (62). This report concerns 53 patients with lesions at various levels. Surgical suture rarely gives 100 per cent functional results and one must wait 2 or 3 years before maximum benefits are received. End to end approximation is ideal and if a free graft is necessary, fresh autografts excel all others. Trial (63) writes of osteolytic lesions in the metatarsal heads following sciatic nerve war injuries, confirming Leriche's theory of sympathetic hyperemia causing bone resorption.

Summers (64) reports thrombophlebitis in the lower extremity.

Two articles on plastic surgery are abstracted. McClintock (65) shows that certain cases of soft tissue destruction of the forefoot are amenable to repair by utilization of the soft tissue of an adjacent phalanx. Edwards (66) compares the method of Cannon et al for transferring large flaps of skin and subcutaneous tissue, to the method of the abdominal tube pedicle. It was found to be faster, more successful and to require less operative procedures than the abdominal tube method.



## BIBLIOGRAPHY

1. Dahlberg, G., and Lander, E.: Size and form of the foot in men, *Acta genet.*, Basel, 1: 115-62, 1948-1949
2. Harris, R. I., and Beath, T.: The short first metatarsal; its incidence and clinical significance, *J. Bone Surg.*, 31 A: 553-65, July 1949
3. Hubay, C. A.: Sesamoid bones of the hands and feet, *Am. J. Roentg.*, 61: 493-505, Apr 1949
4. Galloway, J. D. B.: The treatment of the recurrent congenital clubfoot, *J. Lancet*, 69: 177-80, May 1949
5. Allan, F. G.: Congenital clubfoot, *Med. Press, Lond.*, 221: 375-8, 1949
6. McCormick, D. W., and Blount, W. P.: Metatarsus adductovarus; skewfoot, *J. Am. M. Ass.*, 141: 449-53, Oct 15, 1949
7. Lewin, P.: Painful conditions of the foot and ankle, *Postgrad. M.*, 6: 292-8, Oct 1949
8. Hauser, E. D. W.: The painful foot following injury, *Indust. M.*, 18: 326-8 Aug 1949
9. Flat foot, *Statist. Navy M.*, 5: 6, Aug 1949
10. Noe, M., Ziegler, G., and Herrera, S.: Contribucion al tratamiento del pie plano valgus equino paralitico, *Rev. med. Chile*, 77: 342-5, May 1949
11. Pipkin, G.: Prognosis on sprains, *J. Insur. M.*, 4: 17-21, June-Aug., 1949
12. Good, M. G.: Painful feet, *Practitioner, Lond.*, 163: 229-32, Sept 1949
13. Lake, N. C.: High heels and low heels, *Practitioner, Lond.*, 163: 221-8, Sept, 1949
14. Schwartz, R. P., and Heath, A. L.: Conservative treatment of functional disorders of the feet in the adolescent and adult, *J. Bone Surg.*, 31 A: 501-10, July 1949
15. Liebolt, F. L.: The orthopedic management of foot problems in children, *N. York State J. M.*, 49: 505-10, Mar 1, 1949
16. Fett, H. C., and Pool, C. C.: Plantar interdigital neuroma or Morton's toe, *Am. J. Surg.*, 78: 522-5, Oct 1949
17. Redler, I.: Morton's toe, *N. Orleans M & S. J.*: 102: 23-5, July, 1949
18. Moore, E. L. and Meredith, E. W.: Morton's toe; a neuroma, *Am. J. Surg.* 77: 399-401, Mar 1949



19. Coltart, W. D.: Hammer toe, Practitioner, Lond., 162: 338, Apr 1949
20. Ducroquet, R., Ducroquet, J., and Les Coeur, J.: L'arthroplastic par interposition de cartilage appliques a la cure de l'hallux valgus, Presse med., 57: 312, Apr 2, 1949
21. LeCocq, E. A.: Subtotal phalangectomy for relief of painful clavus, Northwest M., 48: 398, June 1949
22. Hoffman, G. A.: Plastic web reconstruction for soft corn of fourth interspace, J. Nat. Ass. Chirpod., 39: 22-6, June 1949
23. Glassman, F., Wolin, I., and Sideman, S.: Phalangectomy for toe deformities, Surg. Clin. N. America, 29: 275-80, Feb 1949
24. Wright, W. L.: Plantar wart therapy, U. S. Nav. Bull., 49: 707-9, July-Aug 1949
25. Pipkin, J. L., Lehmann, C. F., and Resman, A.: The treatment of plantar warts by single dose method of roentgen ray, South M. J., 42: 193-202, March 1949
26. Montgomery, A. H., Montgomery, R. M., and Montgomery, D. C.: The problem of plantar radiodermatitis, N. York State J. M., 49: 1664-7, July 15, 1949
27. Hempelmann, L. H.: Potential dangers in the uncontrolled use of shoe-fitting fluoroscopes, N. England J. M., 241: 335, Sept 1, 1949
28. Williams, C. R.: Radiation exposures from the use of shoe-fitting fluoroscopes, N. England J. M., 241: 333-5, Sept 1, 1949
29. Wahren, H.: Bursitis achillea (Achillobursitis), Nord. med., 41: 421, March 4, 1949
30. Dunn, R. G., Jr.: Unicameral cyst of the calcaneus, Virginia M. Month., 76: 30, Jan 1949
31. Marek, F. M.: Osteochondritis dissecans of the talus in recurrent ankle sprains, N. York State J. M., 49: 163-8, Jan 15, 1949
32. Bailey, E. T.: Osteochondritis, right talus, Proc. R. Soc. M., Lond., 42: 279, Apr 1949
33. D'Agostino, A.: Osteocondrite dissecante dell'astragalo, Radiologia, Roma, 5: 55-9, Jan-Mar 1949
34. Miller, C. F.: Occupational calcareous peritendinitis of the feet, a case report, Am. J. Roenty, 61: 506-10, Apr 1949
35. Block, M.: Genesis of the gangrenous and reparative processes in trench foot, Arth. Path, Chic., 46: 1-34, July 1949
36. Wertheimer, P., and Guillet, R.: Reflexions sur la maladie de Raynaud; a propos de 35 observations, Lyon chir., 44: 145-57, Mar-Apr 1949



37. Silverman, J. J.: Erythromalgia (erythromelalgia) of the extremities of a soldier, *Mil. Surgeon*, 105: 240-3, Sept 1949
38. Nino, F. I.: *Allescheria boydii* Shear, 1921, Agente etiologico de micetoma podal maduro-micosico a granos blancos en la Republica Argentina, *Prensa Med. Argent.*, 36: 314-9, Feb 18, 1949
39. Moreau, M. H.: Un caso de pie de Madura, *Prensa med. Argent.*, 36: 230-2, Feb 4, 1949
40. Reyes-Pugnaire, M. De: Contribucion al tratamiento quirurgico de las elefantiasis, con algunas consideraciones generales sobre las mismas y en particular sobre las presentes en los territorios espanoles del Golfo de Guinea, *Rev. iber parasit.*, 9: 3-85, Jan 1949
41. Bilcliffe, F. J.: Common fractures of the foot, *Med. Press, Lond.*, 221: 574-7, June 15, 1949
42. Ferciot, C. F., and Stone, F. P.: Management of fractures of the os calcis, *Nebraska M. J.*, 34: 55-8, Feb 1949
43. Bateman, J. K.: A fresh approach to the repair of the os calcis in the greyhound, *Vet. Rec., Lond.*, 60: 674, Dec 18, 1948
44. Lambotte, A.: Fractures anciennes du calcaneum par ecrasement, *Bull. Acad. med. Belgique*, 14: 72-5, 1949
45. Girardi, V. A., and Olavarria, P. C.: Fractura posterior del calcaneo; osteosintessi temporaria, *Sem. med., B. Air.*, 56: 739-41, May 26, 1949
46. Foley, W. J.: Fractures of the neck of the astragalus, *Am. J. Surg.*, 77: 19-23, Jan 1949
47. Jensenius, H.: Fracture of the astragalus, *Acta orthop. scand.*, 19: 195-209, 1949
48. Geckeler, E. O.: Dislocations and fracture-dislocations of the foot, transfixion with Kirschner wires, *Surgery*, 25: 730-3, May 1949
49. Hatchette, C. V.: Subtaloid dislocation of the foot; case report of the outward type, *N. Orleans M. & S. J.*, 101: 549-53, May 1949
50. Ritter, R. O.: The indications and technic of foot stabilization in infantile paralysis, *Surg. Clin. N. America*, 29: 269-74, Feb 1949
51. Rizzo, P. C. and Lehmann, O.: Triple arthrodesis, *Am. J. Surg.*, 77: 10, Jan 1949
52. Friedenber, Z. B.: Arthrodesis of the tarsal bones; a study of failure of fusions, *Arch. Surg.*, 57: 162-70, July 1948
53. Key, J. A.: Surgical reconstruction of arthritic feet, *Ann. Rheumat. Dis., Lond.*, 7: 251, Dec 1948



54. Bentzon, P. K. K. and Agerholm-Christensen, J.: Lambrinudi's operation for drop-foot, *Acta orthop. scand.*, 19: 112-6, 1949
55. Banks, S. W.: The treatment of nonunion of fractures of the medial malleolus, *J. Bone Surg.*, 31 A: 658-62, July 1949
56. Sutro, C. J.: Fracture of the inner malleolus of the ankle with emphasis on treatment of nonunion, *Mil. Surgeon*, 105: 220-5, Sept 1949
57. Kristensen, T. B.: Treatment of malleolar fractures according to Lange Hansen's method; preliminary results, *Acta. Chir. Scand.* 97: 362-79, Jan 26, 1949
58. Dupuis, P. V., and Hachez-Leblanc, M.: Note sur le mecanisme du diastasis tibio-tarsien dans les fractures malleolaires par torsion, *Acta Orthop. belg.*, 14: 256-65, Aug-Oct 1948
59. Borsotti, P. C.: Fracture malleolo-astragaliche e distorsione, *Minerva chir.*, Tor., 4: 116-20, Feb 15, 1949
60. Leonard, M. H.: Injuries of the lateral ligaments of the ankle; a clinical and experimental study, *J. Bone Surg.*, 31 A: 373-7, Apr 1949
61. Oldfield, M. C.: Athletes' hernia of the tibialis anticus muscles, *Brit. J. Surg.*, 36: 405-8, Apr 1949
62. Fontaine, R., Dany, A., and Schumacher, P.: Lesions traumatiques du nerf sciatique et de ses branches; etude antaomo-clinique et resultats therapeutiques d'apres 53 cas, *Lyon chir.*, 44: 185-202, Mar-Apr, 1949
63. Trial: Les osteolysis mutilantes du pied par lesions nerveuses Peripheriques, *J. Radiol. electr.*, 30: 300, 1949
64. Summers, J. E.: Thrombophlebitis in the lower extremity, *Am. Practitioner*, 3: 315-7, Jan 1949
65. McClintock, J. A.: Toe pedicles in reconstruction of the forefoot, *J. Indiana M. Ass.*, 42: 1061-3, Oct 1949
66. Edwards, S.: Evaluation of the open flap for lower extremity soft tissue repair, *Ann. Surg.*, 128: 1131-35, Dec 1948



## CHAPTER VI

### CONGENITAL DISLOCATION OF THE HIP

By

I. G. Jordan, Major, M. C., U. S. A.

Broomhead (1) writes on the differential diagnosis of diseases of the hip in children and Encrantz (2) describes an early symptom occurring in various conditions in the hip which he calls distensional luxation. There may be a difference of 2 millimeters in the widths of the joint spaces. If the symptom is not accompanied by a rise in the sedimentation rate and temperature, it may be due to a causative overexertion, major trauma, or infection of low virulence. Koven and Koven (3) discuss early dysplasia of the hip, quoting from Hart, from the point of view of the pediatrician.

An excellent presentation on the etiology of congenital dislocation of the hip is offered by Badgley (4). The various theories are presented as well as the author's own hypothesis. The paper covers the subject very thoroughly. The author believes that congenital dislocation and congenital dysplasia of the hip may be regarded as the result of faulty development due to environmental factors extrinsic to the hip. Hart (5) (6) with the purpose of focusing attention on congenital subluxation of the hip as a definite clinical entity and establishing the common etiology of congenital subluxation and dislocation, makes a review of the literature and expresses his own clinical observations. If during embryonic or foetal life, a flat and shallow socket forms or a primary dysplasia of the acetabulum occurs because of genetic or biochemical influences, five possibilities exist for subsequent growth of the hip joint: (1) dislocation, (2) subluxation, (3) no displacement, (4) extreme dysplasia, short femur, malformed hip, and (5) spontaneous recovery. The only effectual means of treating dysplasia of the hip is by early recognition and gentle treatment before weight bearing (7 months).

Levitin (7) states that dysplasia of the hip may be present and unrecognized until middle age when arthritic changes develop as a result of repeated micro-traumata. By that time the process is irreversible. It can be recognized in infancy and corrective measures can be taken.

Dubousquet (8) makes an extensive study of the genealogy of many cases of congenital hip dislocation contending that it is anthropologic, not tertologic. The genetic theory seems to dissociate the congenital hip from other anomalies (except clubfoot) which may be coexistent.

Schnute (9) reviews treatment of congenital dislocation of the hip and Farill (10) presented before the American Orthopedic Association at Quebec a technic of treatment of certain irreducible congenital dislocations of the hip in infants. It consists of an open reduction and subtrochanteric osteotomy. The femur is shortened if necessary and a shelf operation is



done. The osteotomy is held by an intramedullary wire and a wire in the femoral neck which protrudes through the skin and is held by plaster to maintain rotation of the head fragment. He has done 12 of these hips in 9 children without infection or deformity.

Bertrand (11) discusses a similar technic for large children and adults. Here a low diaphyseal osteotomy is done for shortening and de-rotation of the femur, and the fragments are fixed with a Kuntscher nail.

Travernier (12) reports a case treated by osteotomy.

Langenskiold (13) reports four cases of coxa vara infantum with pseudarthrosis treated by osteotomy. Bony union was not obtained.

Pekarek (14), Arslanian and Majdalani (15) write on coxa vara and present cases. A study of the family trees suggests that the deformity appears as a dominant Mendelian characteristic.



## BIBLIOGRAPHY

1. Broomhead, R.: Differential diagnosis of diseases of the hip in children, *Med. Press, Lond.*, 221: 545-8, June 8, 1949
2. Encrantz, J. C.: Distensional luxation, an early symptom sometimes occurring in various conditions of pain in the hip joint, *Acta radiol., Stockh.*, 31: 257-63, March 31, 1949
3. Koven, B., and Koven, M. T.: Early dysplasia of the hip, *Arch. Pediat., N. Y.*, 66: 201-8, May 1949
4. Badgley, C. E.: Etiology of congenital dislocation of the hip, *J. Bone Surg.*, 31 A: 341-56, Apr 1949
5. Hart, V. L.: Congenital dysplasia of the hip joint; relationship between congenital subluxation and congenital dislocation, *J. Bone Surg.*, 31 A: 357-72, Apr 1949
6. Hart, V. L.: Congenital dislocation of the hip; early recognition and treatment during the first 6 months of life, *Minnesota M.*, 32: 749-52, July 1949
7. Levitin, J.: Dysplasia of the hip; a factor in the development of static osteo-arthropathy, *California M.*, 70: 401-6, May 1949
8. Dubousquet, M.: Luxation congenitale de la hanche; interpretation genetique du cadre nosologique et de quelques formes cliniques, *Sem. hop. Par.*, 25: 1917-24, June 14, 1949
9. Schnute, W. J.: Treatment of congenital dislocation of the hip, *Surg. Clin. N. America*, 29: 59-64, Feb 1949
10. Farill, J.: Treatment of certain irreducible congenital dislocations of the hip in infants, *Medicina, Mex.*, 29: 283-91, July 25, 1949
11. Bertrand, P.: Luxation congenitale de la hanche chez les grands enfants et les adultes; une nouvelle technique de reduction, *Sem. hop., Par.*, 25: 1584-8, May 18, 1949
12. Tavernier, L., and Pouzet, F.: Cure radicale en un seul temps d'une luxation congenitale de la hanche et d'une osteotomie soustrochanterienne visieusement consolidee, *Lyon chir.*, 44: 469-72, July-Aug, 1949
13. Langenskiold, F.: Coxa vara congenita or infantum pseudarthrosis in the neck of the femur, *Acta orthop. scand.*, 19: 25, 1949
14. Pekarek, F.: Widerspruche auf manchen Gebieten der Dysplasia cox. cong., *Wien. med. Wschr.*, 99: 49, Jan 29, 1949



## CHAPTER VII

### TUBERCULOSIS OF BONES AND JOINTS

By

Harold S. McBurney, Colonel, M. C., U. S. A.

During the year 1949, there was added confirmatory evidence as to the beneficial effect of streptomycin and other allied drugs in the treatment of tuberculosis of bone and joint. Block and Vennesland (1) studied the effect of streptomycin, para amino salicylic acid and their combination in vitro and in vivo and concluded that the combination of the drugs had a much more favorable effect on experimental tuberculosis in the guinea pig than either drug used alone. Jansey, Carr and Millar (2) reported that streptomycin appears to arrest the progress of bone and joint tuberculosis and makes the patient feel better. It is not a substitute for surgery but should be considered a useful adjunct to the proven principles of tuberculosis treatment. These are: Tranquility and repose; excellent nutrition; and time and patience.

Diasone, a sulfone drug, was used by Cattell (3) as an adjunct in the treatment of tuberculosis of bone and joint in children. In eighteen cases with no controls there were two fatalities. Three chronic sinuses were healed and most patients showed general improvement as manifested by better appetites, weight gain and drop in the sedimentation rate of the blood.

Tuberculosis of the hip was considered in reference to surgical techniques of treatment. Ahlberg (4) reported a survey of the radical operative treatment in 113 cases. He described the radical removal of tuberculous debris from the involved joint. The mortality rate was 12.4 per cent and successful fusion was obtained in 58.6 per cent. Failure of fusion was usually due to the necessary removal of large quantities of bone. The author believes that this type of surgery is indicated where there is an abscess in the joint vicinity; where sequestra are present and where there is a tendency to luxation or malposition within the joint. If osseous ankylosis is not obtained by this procedure, an extra-articular arthrodesis may be done at a later date. Garceau (5) compared the ilio-femoral and the ischio-femoral methods of arthrodesis for tuberculosis of the hip. There were 14 ischio-femoral types and 32 ilio-trochanteric types in this series. The average time for fusion with the ilio-trochanteric procedure was 23.7 months as compared with the ischio-trochanteric procedure which gave fusion in 5.8 months. The ischio-trochanteric method was concluded to be the fusion of choice for extra-articular arthrodesis where more rapid and solid fusion was obtained.

The surgical treatment of tuberculosis of the spine was analyzed by Bosworth and Levine (6). Tuberculosis of the neural arch gives a poor prognosis generally but even here fusion is frequently successful. Although negroes are more susceptible to tuberculosis of the spine, the prognosis is



no different from that in the white patient. Children with Pott's disease progressed poorly under conservative treatment but recovery was rapid in those on whom surgical fusion was done. Pulmonary tuberculosis when controlled by modern methods has no bad effect on the prognosis of surgical fusion. Amyloid disease in tuberculosis of the spine was found to be practically always fatal. Dunn (7) presented the late results of tuberculosis of the spine in children with special reference to spinal grafting and drew conclusions which are exactly opposite to those of Bosworth and Levine. He presented evidence that surgical grafting does not reduce the mortality, nor does it reduce the incidence of reactivity, nor does it control the development of a kyphosis. The proper treatment should be aimed at earlier diagnosis and treatment with immobilization until the bacillaemic stage is over. The author feels that it is better to avoid posterior grafting as this procedure may prevent anterior consolidation of the vertebral bodies. The English school of Orthopaedists seem to be far more conservative in regard to spinal fusion in tuberculosis than does the American school.

Love and Erb (8) present a series of 5 cases of anterior transplantation of the spinal cord for paraplegia secondary to Pott's disease of the spinal column. They feel that this is a useful procedure when the spinal cord is compressed by a bony ridge as well as by granulation tissue. It must be done in early cases of paralysis and the surgical procedure is now fairly safe when the patient has coverage with streptomycin.

Albert (9) reports an interesting case of rupture of a tuberculous paravertebral abscess into the pleural cavity. Dry cough and chest pain are common symptoms of pleural irritation and incipient rupture of a paravertebral abscess into the pulmonary cavity. The prognosis is not too bad in cases in which rupture occurs while the patient is recumbent and under treatment. Repeated aspirations are of great value in these cases. A rupture into a bronchus leads to secondary infection and the results of surgical drainage in these cases are poor. Rupture of the paravertebral abscess in cases with paraplegia produces a very grave prognosis.

A complete and carefully compiled survey on Pott's disease and Pott's paraplegia was presented by Girdleston (10) and this is work of reference which has definite value in the orthopaedic literature.

Wilkinson (11) in an address before the Royal College of Surgeons of England gave a masterful paper on observations on the pathogenesis and treatment of skeletal tuberculosis.



## BIBLIOGRAPHY

1. Block, R. G., and Vennesland, K., et al: The effect of streptomycin, para-aminosalicylic acid and their combination of the tubercle bacillus in vitro and in vivo, *Am. Rev. Tuberc.*, 59: 554-61, May 1949
2. Jansy, F., Carr, B. W., and Millar, E. A.: Streptomycin therapy in orthopedic tuberculosis, *Surg. Clin. N. Am.*, 28: 1659-62, Dec 1948
3. Cattell, L. M.: Diasone as an adjunct in the treatment of tuberculosis of bones and joints in children, *J. Internat. Coll. Surgeons*, 12: 12-15, Jan-Feb 1949
4. Ahlberg, A.: Radical operative treatment of the tuberculous hip; a report of 113 cases, *J. Bone Surg.*, 30 A: 550-91, July 1948
5. Garceau, G. J.: Arthrodesis of the hip for tuberculosis; a comparison of the ilio-femoral and ischio-femoral methods, *Q. Bull. Indiana Univ. M. Center*, 11: 23-5, Apr 1949
6. Bosworth, D. M., and Levine, J.: Tuberculosis of the spine: an analysis of cases treated surgically, *J. Bone Surg.*, 31 A: 267-74, Apr 1949
7. Dunn, D. M.: The late results of tuberculosis of the spine in children, with special reference to spinal grafting, *Proc. R. Soc. M., Lond.* 41: 858-60, Dec 1948
8. Love, J. G., and Erb, H. R.: Transplantation of the spinal cord for paraplegia secondary to Pott's disease of the spinal column, *Arch. Surg.*, 59: 409-21, Sept 1949
9. Albert, M.: Rupture of tuberculous paravertebral abscess into pleural cavity, *Proc. R. Soc. M., Lond.*, 42: 275-7, Apr 1949
10. Girdleston, G. R.: Pott's disease and Pott's paraplegia, *Ann. R. Coll. Surgeons, England*, 4: Apr 1949
11. Wilkinson, M. C.: Observations on the pathogenesis and treatment of skeletal tuberculosis, *Ann. R. Coll. Surgeons, England*, 4: 168-92, Mar 1949



## CHAPTER VIII

### INFECTIONS OF BONES AND JOINTS

By

Ernest A. Brav, Colonel, MC, U. S. A.

V. H. Jeffress, Col. MC, U. S. A.                      W. D. Sanderson, Capt. MC, U. S. A.  
A. J. Schoepflin, Lt. Col. MC, U. S. A.              J. D. DiMichele, Capt. MC, U. S. A.  
E. Lindig, Jr., Capt. MC, U. S. A.                      R. H. Garrett, Capt. MC, U. S. A.  
F. D. O'Brien, Capt. MC, U. S. A.                      F. R. Hook, Capt. MC, U. S. A.  
R. H. Cote, Capt. MC, U. S. A.

#### Treatment of Osteomyelitis

Henry, Dequesne and Dewinne (1) outline the treatment of osteomyelitis by means of surgery and penicillin. They show how surgery fortified by penicillin hastens the treatment of this disease. It is a review of the modern treatment of this disease in France and the results are similar to those seen in the United States.

Millbourn (2) sets up principles for the modern care of acute and chronic osteomyelitis. He states that many cases of acute osteomyelitis in young children may be cured by chemotherapy or antibiotics alone.

In severe cases of osteomyelitis, he recommends early surgery with adequate saucerization and culture of the material to determine the most efficacious chemotherapeutic or antibiotic agent. He also does a primary suture, allowing the muscles to fill in the bone defect and puts small drains in each end of the wound for a short time. He advocates the local application of sulfa or penicillin. Chronic osteomyelitis was treated in much the same manner.

Berry and Gudrandsson (3) report 7 cases of acute osteomyelitis in infants. All were treated vigorously with penicillin and sulfa drugs. Five responded well to therapy while two required bone surgery which was followed by improvement. Osteomyelitic bone changes were demonstrated by x-ray in all cases. In three, positive blood cultures revealed hemolytic staphylococcus aureus; in two, beta hemolytic streptococcus was isolated. The youngest child was 4 weeks old; the oldest was 8 weeks. One case was confused on admission with acute rheumatic fever. The course of therapy was penicillin in frequent large doses either intravenously or by bone marrow infusion, plus sulfadiazine 1 grain per pound per day. After acute symptoms subsided, the penicillin was then given intramuscularly 300 units twice daily for from 24 to 54 days. All organisms were studied for resistance to penicillin and streptomycin.

Carpenter (4) attempted to evaluate the response of chronic infected wounds, cases of chronic osteomyelitis, decubitus ulcers and stasis ulcers to treatment with chlorophyll preparations. The chronic osteomyelitis



cases were first subjected to thorough sequestrectomy followed by instillation of a chlorophyll-penicillin preparation through catheters placed in the depths of the wound. This was followed in 8 to 10 days by wound closure. Results in this group proved very favorable. In those cases where the wounds were of such size that closure could not be performed, split thickness grafts and pedicle grafts were performed in 8 to 21 days. The chlorophyll was used in plain solution impregnated in gauze or in combination with penicillin and streptomycin. In all cases, purulent granulation was replaced by healthy granulation in a short time. The exact treatment prior to the use of chlorophyll in these cases is not discussed and there were no controls for comparison. The author stresses the importance of general supportive treatment in the care of these patients.

Stebbins (5) presents a method for the early closure and healing of osteomyelitis cavities. The method consists of sequestrectomy and saucerization, followed in 7 days by split thickness skin grafting. One hundred and three cases are reported and 86 of these were completely healed in 60 days. The method is not new, but one or two points of technique are of interest, namely, the use of glycerin impregnated cotton, covered with rubber as initial dressing of the graft, and the preservation of excess split thickness skin in sterile containers under refrigeration, to be applied to the area if the original graft fails to adhere completely.

#### Unusual Forms of Osteomyelitis

Burch (6) presents the case of a 15-year old colored male who developed sudden severe swelling and pain in the lower right thigh accompanied by high spiking fever and delirium. Physical examination revealed splenomegaly and a swollen tender thigh. X-rays revealed a translucent lesion just proximal to the distal epiphysis of the right femur. Laboratory studies showed somewhat decreased red and white cells with eosinophilia. Penicillin, sulfadiazine and sodium salicylate failed to alter the course of the disease. Ten days after admission blood cultures revealed paratyphoid B. Agglutination tests were positive for paratyphoid B. at 1:640 and for typhoid H. at 1:320. The bone lesion progressed and surgery was performed. There was an abscess in the femur containing yellow-green pus. The femur was saucerized and the tissues were closed using a single drain. Sulfathiazole and penicillin powder were packed in the saucerized area before closure. Cultures of the pus were positive for paratyphoid B. Recovery was prompt and complete and the patient was asymptomatic 12 months after he had been seen initially.

Paratyphoid osteomyelitis is a rare condition. Ludwig (7) in reviewing the literature, finds the incidence of osteomyelitis due to paratyphoid B. was 8 times that of paratyphoid A. The author reports on a case of massive hematogenous osteomyelitis of the distal portion of the left femur in a 10-year old white girl following a minor fall. Early blood cultures revealed gram positive diplococci. However, later repeated blood cultures after penicillin therapy revealed gram negative bacilli identified as paratyphoid A. Culture of the abscess showed nothing on smear but gram positive cocci were grown on culture. That this was a mixed infection was proven by



the 31-day course of penicillin during which time the blood culture became negative for gram positive cocci, but the wound showed no tendency to heal. The wound healed rapidly after the patient was started on streptomycin. The cocci were identified as staphylococcus aureus. The course of the disease in this girl illustrated dramatically the specificity of penicillin and streptomycin for certain organisms.

Leibetseder (8) reports 8 cases of infectious nontuberculous spondylitis with septicemia and distal pyogenic metastases which responded well to penicillin therapy. They had higher leukocytosis, higher sedimentation rate and a further shift to the left in the differential blood count as compared with cases of Pott's disease.

Goldenberg and Brooks (9) report a single case of osteomyelitis of the spinous process of the 4th lumbar vertebra, which was diagnosed 3 weeks after a diagnostic lumbar puncture in a 37-year old male patient. Five weeks after the initial puncture, operation was performed, the offending spinous process excised, and the patient recovered without residuals. The author gives a short bibliography of similar cases.

Levalle and Hamm (10) discuss 7 cases in which a diagnosis of osteitis pubis was made following supra-pubic prostatectomy. They believe that the early diagnosis can be made on the basis of clinical signs before x-ray changes are noted. They suggest a method of treatment using short wave diathermy and intramuscular Vitamin B complex which apparently alleviates the symptoms. They state also that the disease is self-limiting in from 3 to 9 months without any therapy at all.

Four cases of osteitis pubis are reported by Hotchkiss, Schoenau and Accttola (11). The symptoms are symphyseal pain extreme upon motion, of the muscles attached to the pelvis. Localized tenderness and induration may be present. X-rays reveal periosteal fraying by the third week and later rarefaction of bone of the pubis and ischium. Metastatic carcinoma is important in the differential diagnosis.

Five cases of osteitis pubis following prostatectomy are reported by Abrams, Sedlezky and Stearns (12). These did not respond to chemotherapy. The authors feel that the process is inflammatory, but may be on a mechanical basis. They agree that the condition is poorly understood but that it is self-limiting in two to six months.

Infection of an intervertebral disc or vertebral body following lumbar puncture is uncommon. Most cases reported have occurred in children on whom lumbar puncture had been performed for meningitis. Bromley, Craig, and Kessell (13) report a case of a 12-year old girl who developed an abscess of the L-3, L-4 interspace following lumbar puncture. The abscess presented itself in the mid-lateral line 5 cm. above the inguinal ligaments. The lesion was cured by surgical intervention and penicillin therapy.

Metcalfe (14) reports a case of multiple osteomyelitic lesions due to syphilis, the diagnosis of which was obscured by previous penicillin therapy for gonorrhoea and again for balanitis. He points out that syphilitic osteomyelitis is an extremely rare entity. Serology on admission was negative



and biopsies gave no clues as to the diagnosis. Repeated serologies were done which were all negative until one month after admission. The patient was then treated with penicillin and mepharsen after which the multiple osseous lesions in the cranium, ribs, and phalanges regressed. The author then briefly discusses acquired and congenital syphilis and cautions that syphilis must always be suspected in bone lesions in young adults.

Nine cases of carcinoma arising in sinus tracts due to osteomyelitis are added to the literature by McAnally and Dockerty (15). In two of these cases metastases occurred. The authors recommend amputation when feasible as soon as the diagnosis is made. Excision of regional lymph nodes and radiation therapy may be of value when amputation is not possible.

### Granulomatous Bone Lesions

Holt and Owens (16) present a complete description of the osseous lesions in sarcoidosis with a review of the literature and illustrative case reports.

Seventeen cases of coccidioidal granuloma of bone are added to the literature by Miller and Birsner (17). This series of cases is interesting in that in none of them was the bone involvement due to extension from soft tissue granulomatous lesions.

### Allied Soft-Tissue Infections

Pulaski and Connell (18) report an analysis of 200 cases of streptomycin treated, nontuberculous infections of soft tissues in U. S. Army Hospitals. The conclusions drawn were that streptomycin is of benefit in surgical infections, but it is not a panacea. It is most effective in cellulitis, less effective in open wounds. Topical application has not given good results.

McCutcheon, Baxley and Foushee (19) present a review of present day knowledge and recent literature on the subject of gas gangrene together with a discussion of its incidence in military and civilian practice. The bacteriology, pathology, diagnosis and treatment are discussed. Two cases are presented, emphasizing the principles outlined in the article.

The management of wounds in one U. S. Army evacuation hospital which functioned under combat conditions in the European Theater from June, 1944, to May, 1945, is discussed by Benton (20). Analysis of 18 cases of gas bacillus infection is presented.

Fascio-aponeurotic necrosis was described by Starr (21) in 1945 with a report on 6 cases. Eleven cases are added to the literature by the same author. The causative organism is most frequently staphylococcus aureus. The condition is most often manifested by persistent soft tissue sinus tracts and is amenable to local and systemic administration of penicillin in conjunction with excision of the "facial sequestrum."



## BIBLIOGRAPHY

1. Henry, G., Duquesne, H., and Dewinne, P.: Nouvelle contribution a l'etude du traitement de l'osteomyelite aigue par la penicilline, Scalpel, Brux., 102: 187-200, Feb 12, 1949
2. Millbourn, E.: On the treatment of acute and chronic osteomyelitis of the long bones, Acta orthop. scand., 18: 387-420, 1948-1949
3. Berry, A., and Gudbrandsson, B.: Atypical osteomyelitis, Clin. Proc. Child. Hosp. Wash., 5: 303-11, Oct 1949
4. Carpenter, E. B.: Clinical experiences with chlorophyll preparations with particular reference to chronic osteomyelitis and chronic ulcers, Am. J. Surg., 77: 167-171, Feb 1949
5. Stebbins, C. E.: Chronic osteomyelitis; treatment by split thickness skin grafts, J. Michigan M. Soc., 48: 334-337, Mar 1949
6. Burch, J. E.: Paratyphoid osteomyelitis; a case report, South M. J., 42: 138, Feb 1949
7. Ludwig, F. E.: Osteomyelitis caused by Salmonella paraphi (Bacillus paratyphosus A.) Surgery, 26: 139-45, July 1949
8. Leibetseder, F.: Zur diagnose der spondylitis infectiosa, Wien. med. Wschr., 99: 207-10, May 7, 1949
9. Goldenberg, R. R., and Brooks, S.: Osteomyelitis of a vertebral spinous process following lumbar puncture, J. M. Soc. N. Jersey, 46: 466, Oct 1949
10. Lavelle, L. L., and Hamm, F. C.: Ostitis pubis; its diagnosis and treatment, J. Urol., Balt., 61: 83-95, Jan 1949
11. Hotchkiss, R. S., Schoenau, C. W., and Accttola, A. B.: Osteitis pubis, N. York State J. M., 49: 193-6, Jan 15, 1949
12. Abrams, M., Sedlezky, I., and Stearns, D. B.: Osteitis pubis, N. England J. M., 240: 637-41, Apr 21, 1949
13. Bromley, L., Craig, J. D., and Kessell, A. W. L.: Infected intervertebral disk after lumbar puncture, Brit. M. J., 1: 132, Jan 22, 1949
14. Metcalfe, J. W.: Syphilitic osteoperiostitis; skull, ribs, and phalanges; report of a case, U. S. Nav. M. Bull., 49: 528-35, May-June 1949
15. McAnally, A. K. and Dockerty, M. B.: Carcinoma developing in chronic draining cutaneous sinuses and fistulas, Surg. Gyn. Obst., 88: 87-96, Jan 1949



16. Holt, J. F. and Owens, W. I.: The osseous lesions of sarcoidosis, *Radiology*, 53: 11-30, July 1949
17. Miller, D., and Birsner, J. W.: Coccidioidal granuloma of bone, *Am. J. of Roent.*, 62: 229-236, Aug 1949
18. Pulaski, E. J., and Connell, J. F., Jr.: Streptomycin therapy in established wound infections, *Surgery*, 26: 622-5, Oct 1949
19. McCutcheon, W. B., Baxley, R. D., and Foushee, J. C.: Gas gangrene; a review of the subject and a report of two cases successfully treated by extensive debridement, *North Carolina M. J.*, 10: 479-84, Sept 1949
20. Benton, G. R., Jr.: The management of war wounds with reference to the prevention and treatment of Clostridial infections; analysis of 18 cases, *North Carolina M. J.*, 10: 120-129, Mar 1949
21. Starr, K. W.: Fascial necrosis; a new symptom-complex amenable to surgery combined with penicillin therapy, *J. Internat. Coll. Surgeons*, 12: 524-30, July-Aug 1949



## CHAPTER IX

### CHRONIC ARTHRITIS

By

Harold S. McBurney, Colonel, M. C., U. S. A.

Dahlberg and Sundelin (1) studied 1,002 cases of rheumatoid arthritis with reference to the function of the joints. They report that some joints are affected more than others but there is no true relationship to joint function influence.

Therapeutic criteria in rheumatoid arthritis has been well worked out by Steinbrocker, Traeger and Batterman (2). They give an excellent review of a workable classification in rheumatoid arthritis including a classification of rheumatoid progression, functional capacity and response of rheumatoid activity to therapy. Thus the stage of the disease, the presence of rheumatic activity and the degree of functional impairment are considered in the treatment. With treatment the stage of the disease rarely improves but either rheumatoid activity or functional impairment or both may respond.

Kennedy (3) studied the use of calcium succinate and acetyl salicylic acid in the treatment of rheumatic disease. In 63 patients studied, 55 per cent of the infective polyarthritis showed improvement; 41 per cent of the osteoarthritis showed improvement and 63 per cent of the nonarticular rheumatic group showed improvement. Forty-five grains of the drug were given each day and there was a relapse within one week on cessation of the treatment. The author concluded that there was no superiority of this combination over aspirin alone.

In an objective study of 21 cases of moderately and far-advanced rheumatoid arthritis, encouraging results were reported by Reich (4) in slightly more than one-half the cases employing large daily doses of progesterone in oil.

ACTH and cortisone were used in the treatment of rheumatoid arthritis and Boland and Headley (5) reported 8 cases using cortisone acetate. Large doses of the adreno-cortical preparation rapidly suppressed the clinical manifestations of rheumatoid arthritis but these changes were only temporary in nature. Markson (6) reported two cases that had prolonged treatment of rheumatoid arthritis with ACTH. These were followed for 5 and 6 months and have shown truly remarkable improvement. No other drug could have produced so much effect in so short a time but the author concludes that ACTH must be compared to insulin in that it must be continued in order to sustain results. Hench and Kendall (7) summed up the situation of the then known effects of the hormone of the adrenal cortex and of the pituitary adreno-corticotrophic hormone on rheumatoid arthritis by stating that: There are improved biochemical and clinical features of rheumatoid arthritis by the daily intramuscular injection of either hormone; there is lessening of articular and muscular symptoms with lowering of the sedimentation rate of the blood. However, when drug therapy was stopped, the signs and symptoms



usually returned or increased promptly. It was concluded that the hormones are useful in the treatment of rheumatic and associated diseases which are relieved by jaundice or pregnancy.

Rheumatic spondylitis was adequately covered in many aspects in the literature this year. Query (8) discussed its early diagnostic features and management. He reviewed 32 new patients in a 2-year period, 12 of whom were females. The diagnostic features stated are back pain with or without radiation, limitation of motion and flattening of the spinal curves, spasm of muscles, bilateral changes by x-ray in the sacro-iliac joints and increased blood sedimentation rates. Therapy has been directed to the care of the general health, rest regulation, deep breathing and postural exercises, physical therapy measures and x-ray therapy to the spine segments actively involved. Williams (9) contributed an excellent article on the technique of examination and the importance of the costal joints in rheumatoid spondylitis. He stresses that costal joint changes may and do occur before changes in the sacro-iliac joints appear. Costo-vertebral and costo-transverse joints encircle the nerve roots and if involved lead to neuritic irritation with referred symptoms. In his series, females were affected almost as often as males. In the x-ray technic, the tube is pointed 20 degrees cephalad and centered at the 5th to 7th thoracic vertebrae for good joint detail. Early recognition and treatment of these arthritic spinal joints gives good results in therapy. The author makes a plea not to wait for sacro-iliac changes to make a diagnosis of Marie-Strumpell arthritis. Norcross, Robins and Lockie (10) used D tubocurarine in oil-wax suspension in 6 cases of rheumatoid spondylitis in which the usual therapy did not fully erase the muscle spasm. The recorded results were relief of muscle spasm and pain, increased range of motion and strength, correction of flexion deformity of the spine, diminished abnormal motor activity on electromyography after treatment and finally the patients were able to take more physical therapy and postural exercises. One injection would give a curare effect up to 120 hours.

Krebs and Craddock (11) discuss Reiter's syndrome of arthritis, urethritis, and conjunctivitis and report a case of 5 years duration. This patient had the typical triad and methods of treatment attempted included fever therapy, sulfonamides, penicillin, salicylates, gold therapy, streptomycin and the arsenicals. All these methods of treatment were unsuccessful and recurrences persisted over the 5-year period of follow-up.

Wagner and Engelhardt (12) present an excellent article on gout which they term an ancient and neglected disease. Five to 8 per cent of all cases of joint diseases are gout. It may be defined as a metabolic disturbance giving increase of body urates, especially about joints and leading to chronic deforming arthritis. The purine metabolism is faulty. The blood uric acid is increased and chronic gout shows impaired renal function. The urate foreign bodies formed cause the inflammation. Ninety per cent of patients are males and the fifth decade is the most common time of occurrence. If the disease is established, excessive intake of purines and alcohol will accentuate the signs and symptoms. There are premonitory symptoms of malaise which usually initiate the attack. The great toe, foot, knee, hand, shoulder, and vertebrae are affected in the order stated. The 5-8 day



course of the disease is altered by the administration of colchicum, 65 mg. every two hours until relief or the appearance of toxic symptoms. There is no suppuration and only chronicity of the disease leads to the x-ray findings of the punched-out lytic joint lesions. Aspirin is a good drug to use and urinary output must be maintained during the course of the disease and its therapy. The question of injury versus gout is discussed by Kirkpatrick (13) who reviews the reported cases in the literature and concludes that an attack of gout has its inception over a period of days before the acute symptoms are evident. Consequently, gouty bursitis or peri-arthritis which manifests itself in the course of an individual's usual work, should not be considered industrially connected or aggravated.

Robinson and Hirsh (14) presented gc. arthritis with a study of 202 patients treated with penicillin, sulfonamides or fever therapy. It was found that penicillin was the drug of choice with two to five million units administered over a period of 5-10 days. Sulfonamides gave excellent results and were easy to administer and should be used in those cases where penicillin fails. Fever therapy is best in those patients with previous arthritis but there are side dangers in the use of this therapeutic agent.

Brown (15) discussed an interesting and rather odd subject in the cause of cracking joints and their relation to weather and fibrositis. The cracking joint noise is a sound caused by the stretching of contracted inflamed fibrous tissue found in fibrositis. The fibrositis is caused by a streptococcus toxin from some foci of infection. The cracking sound is increased with chilling and stormy weather and is definitely decreased in warm weather.

Numerous drugs were reported in the treatment of chronic arthritis and Wyatt (16) used prisol hydrochloride in 50 patients excluding cases of spondylitis. This drug was mainly given to test the favorable action on the peripheral circulation and the gastrointestinal functions. There was subjective improvement in 88 per cent of the early group and in 62 of the moderate group. The patients had better motion, function, less joint swelling and lowered blood sedimentation rate. All these effects were transitory and depended on the continuation of the drug. Graniver (17) studied the effects of antireticular cytotoxic serum on 16 patients with osteoarthritis. Ten of these had no benefit, 2 showed marked improvement, and 4 patients only slight improvement. Fifty per cent of all patients treated showed marked local reaction to the serum. The serum is made by man's spleen and bone marrow cells injected into rabbits.

Hernaman-Johnson (18) stated that x-ray has proved therapeutic value in the treatment of osteoarthritis. It is local treatment and some toxic effects in some patients may contraindicate its use. X-ray has definite resolving power to inflammation.

Ishmael (19) surveyed 1,000 cases of degenerative arthritis and stated that certain changes in this disease result from a traumatic breakdown of a joint which has been disturbed by the same factors known to produce the more common forms of osteoporosis and osteomalacia and correction of these results in the relief of the patient's symptoms. The treatment in these cases consisted of the following measures: Sex hormone administration if



the patients were in the older age group; correction of the serum protein levels; mobilization of bones and joints to correct any disuse atrophy; correction of niacin and thiamin deficiencies; and finally, if no calcium was present in the urine, then activated ergosterol therapy was instituted. Of the 1,000 cases treated, 884 became symptom free during the above treatment regime.

Surgery in chronic arthritis was fully and carefully reviewed by Kuhns (20). The laboratory and clinical evidence of the quiescence of the disease should be established in general before survey is initiated. Surgical aims are: to make the diagnosis, relieve pain, correct or improve deformities and to obtain motion in stiff joints. In rheumatoid arthritis, the following procedures are used: manipulation; tendon, capsular and fascial surgery for contractures; synovectomy; corrective osteotomy; arthrodesis (rarely needed) and arthroplasty. In osteoarthritis, surgery is primarily used for the relief of pain. Manipulation has an important role followed by such procedures as neurectomy, cheilotomy, joint toilets, arthroplasty, aids to bone circulation such as bone drilling and muscle transplants, osteotomy and finally arthrodesis. Kelikian (21) gives an excellent review of the principles and indications for surgery in chronic arthritis. His article contains excellent illustrations of pathology, technique, x-ray films, and final functional results. There is an interesting section on joint toilets of the knee.

Colclough (22) reports an interesting case of compression of the spinal cord by osteitis deformans. This represents the thirtieth case recorded and the twentieth one in which laminectomy lead to neurological recovery complete without recurrence. The case reported is one of monostotic Paget's disease, the process being confined to the 6th and 7th thoracic vertebrae. The case is confirmed by pathological examination. Queckenstedt test, myelography and early decompression are recommended. The patient was a white male, 50 years of age, with a two week history of lower extremity spasticity and weakness.



## BIBLIOGRAPHY

1. Dahlberg, G. and Sundelin, F.: Rheumatoid arthritis and the function of the joints, *Acta Med. Scand.*, 135: 40-6, July 18, 1949
2. Steinbrocker, O., Traeger, D. H., Batterman, R. C.: Therapeutic criteria in rheumatoid arthritis, *J. Am. M. Ass.*, 140: 659-62, June 1949
3. Kennedy, A. F.: The use of calcium succinate and acetyl-salicylic acid in the treatment of rheumatic disease, *Rheumatism*, London, 5: 86-9, July 1949
4. Reich, N. E.: The use of large doses of progesterone in rheumatoid arthritis, *Am. Practitioner*, 4: 1-5, Sept 1949
5. Boland, E. W., Headley, N. E.: Effects of cortisone acetate on rheumatoid arthritis, *J. Am. M. Ass.*, 141: 301-8, Oct 1949
6. Markson, D. E.: Prolonged treatment of rheumatoid arthritis with pituitary adrenocorticotrophic hormone, *J. Am. M. Ass.*, 141: 458, Oct 1949
7. Hench, P. S., Kendall, E. C.: The effect of hormone of the adrenal cortex and of the pituitary adrenocorticotrophic hormone on rheumatoid arthritis, *Proc. Mayo Clin.*, 24: 181-97, Apr 13, 1949
8. Query, R. Z.: Rheumatoid spondylitis; its early diagnostic features and management, *J. Am. M. Ass.*, 139: 692-8, Mar 12, 1949
9. Williams, A. J.: Rheumatoid (Marie-Strumpell) spondylitis; technique of examination and importance of costal joints, *California M.*, 70: 257-61, Apr 1949
10. Norcross, B. M., Robins, H. M., Lockie, L. M.: D-tubocurarine in oil-wax suspension in rheumatoid spondylitis; its use as an adjuvant, *J. Am. M. Ass.*, 140: 397-400, May 28, 1949
11. Krebs, C., Craddock, W. L.: Reiter's disease; syndrome of arthritis, urethritis, and conjunctivitis, report of case of 5 years duration, *Northwest M.*, 48: 477-80, July 1949
12. Wagner, E. L., Engelhardt, H. T.: Gout, an ancient and neglected disease, *N. Orleans M. & S. J.*, 101: 415-9, Mar 1949
13. Kirkpatrick, J. E.: Injury vs gout, *Indust. M.*, 18: 464-6, Nov 1949
14. Robinson, J. A., Hirsh, H. L.: Gonococcal arthritis; a study of 202 patients treated with penicillin, sulfonamides or fever therapy, *Ann. Int. M.*, 30: 1212-23, June 1949



15. Brown, E. E.: Cause of cracking joints; relation to weather and fibrositis, Northwest M., 48: 537-41, Aug 1949
16. Wyatt, B. L.: The use of priscol hydrochloride in the chronic arthritides; preliminary report, Ann. West. M. & S., 3: 273, Aug 1949
17. Granirer, L. W.: The effect of antireticular cytotoxic serum on patients with osteoarthritis, N. Y. State J. M., 49: 1067, May 1949
18. Hernaman-Johnson, F.: X-ray treatment in osteo-arthritis, Rheumatism, Lond., 5: 44-7, Apr 1949
19. Ishmael, W. K.: Degenerative arthritis, Am. Practitioner, 4: 97-101, Oct 1949
20. Kuhns, J. G.: Surgery in chronic arthritis, N. Eng. J. M., 240: 605-10, Apr 14, 1949
21. Kelikian, H.: Surgery in the treatment of chronic arthritis, Surg. Clin. N. America, 29: 87-115, Feb 1949
22. Colclough, J. A.: Compression of the spinal cord by osteitis deformans; report of a case, Surgery, 25: 760-5, May 1949



## CHAPTER X

### INFANTILE PARALYSIS

By

Albert W. Shiflet, Colonel, M. C., U. S. A.

#### GENERAL AND PATHOGENESIS

Guyton (1), University of Mississippi, supplies an excellent article on the reaction of the body to poliomyelitis and the recovery process. The information is based on personal experiences of the author as a result of having had the disease while engaged in the study of neurosurgery and neurology, a background eminently fitting him to make keen accurate observations. Relation of the pathologic physiology to symptoms is especially well covered, the pain and muscle spasm in the acute phase is considered to be on a vaso-spasm basis, secondary to lesions in the medulla. The process of recovery is discussed with particular emphasis on arborization of peripheral nerves. A regimen of treatment based on physiologic concepts of the disease is presented.

Study of 1,172 cases of acute poliomyelitis by Smith et al (2) gives evidence that the sympathetic nervous system is probably more often involved, 90 per cent of cases, than is the anterior horn system, 50 per cent. Practically all parts of the sympathetic system have been found to be involved. It is believed that the pain and muscle spasm of acute poliomyelitis is due to angiospasm similar to that in Raynaud's or intermittent claudication thus explaining the relief obtained from hot packs or short wave diathermy directed toward the painful areas, on the basis of vasodilatation. The common vasodilator drugs do not give sufficient effect on the spastic blood vessels to afford the relief obtained from local heat.

On a basis of study of 14 strains of poliomyelitis viruses by means of immunological methods, Rodian et al(3) have identified at least 3 distinct types and grouped them according to their relationship to 2 well-known types, Lansing and Brunhilde.

#### EPIDEMIOLOGY

The First Army Medical Bulletin (4) answers 24 questions about poliomyelitis in the light of present knowledge of its epidemiology. The incubation period is given as 7-14 days but extremes of 3-35 days are mentioned. The virus has been found in feces occasionally for several months after onset. One-half to two-thirds of the cases in New York City are paralytic.

Howe (5) writes that the epidemiology of poliomyelitis, in the light of modern research, is not definitely established and that while many of the usually accepted methods of transmission such as by flies contaminating food have incriminating evidence for their existence, there are many voids in the



epidemiological knowledge that make present control measures of problematical value.

Adamson et al (6) describe poliomyelitis in the Arctic. In a population composed largely of nonimmune Eskimos, poliomyelitis is extremely serious with mortality up to 5 per cent, paralysis up to 14 per cent, and morbidity up to 50 per cent.

Van Riper (7) reflects that the changing patterns of poliomyelitis with regard to age groups, virulence, and geographic distribution may be due to the human host's changes in resistance, brought about by subtle influences from water, soil, diet, or "way of life" rather than through (1) existence of different strains of virus in different parts of the world, (2) changes in viral virulence through mutations, (3) latent immunity produced through subclinical contact with the virus in childhood.

Wesselhoeft (8) states that tonsillectomy in the face of possible exposure to poliomyelitis is definitely contraindicated.

Nau (9) reviews the literature and concludes that tonsillectomy has no definite relationship to the incidence of poliomyelitis; however, recent tonsillectomy does appear to predispose toward the bulbar type of polio if the disease does occur. Operations on the mouth and pharynx are contraindicated during polio season in the presence of an epidemic due to the much more severe nature of the bulbar versus the spinal type infections.

#### DIAGNOSIS

Kilham et al (10) from the point of view of differential diagnosis write that the unequivocal diagnosis of nonparalytic poliomyelitis is at present difficult or impossible to make on the basis of clinical, laboratory and epidemiological observations, being almost impossible to differentiate from such conditions as mumps meningoencephalitis.

Periodic paralysis, according to Kamman (11), characterized clinically by the development of intermittent attacks of flaccid paralysis of skeletal muscles of the extremities, loss of deep tendon reflexes, and loss of excitability to both faradic and galvanic currents, is a condition which may be confused with a more serious paralysis. Periodic paralysis is brought about by various etiological factors such as acute infections, thyrotoxicosis, Addison's disease, the most common being ingestion of a high carbohydrate meal. The most constant laboratory finding is a low serum potassium and treatment is based on supplying potassium in the form of KCL intravenously during the acute phase and orally later. Intravenous KCL would be of value in the differential diagnosis since the paralysis of periodic paralysis disappears within minutes after injection of the KCL.

#### TREATMENT

Poliomyelitis patients with respiratory involvement, write West and Bower (12), should be given a high tracheotomy early, bronchoscopic equipment and trained personnel should be immediately available at all times, mechanical problems should be anticipated and facilities for their correction



should be at the bedside. Feeding for the acute stages should be by the parenteral method. Contrary to this is the opinion of Wesselhoeft (8) that tracheotomy is seldom, if ever, warranted in polio patients with respiratory difficulty. Postural drainage, he believes, with careful, thorough, gentle suction will give equally good results without the added danger and stress of a tracheotomy.

A study of the persistent sequelae of bulbar poliomyelitis by Lueck et al (13), including cinematographic analysis, of 50 patients from  $1\frac{1}{2}$  to 38 years of age 15 to 17 months following acute bulbar poliomyelitis, with little or no spinal nerve involvement, revealed a high percentage of residual disability in function of the face and particularly of the pharynx, i.e., paralysis of the palate was found in 56 per cent.

Twelve-year follow-up studies by Inclan (14) show permanent satisfactory results considered excellent or good in 85 per cent of 68 cases of physiological bone blocking of flail joints, including anterior and posterior blocking of ankle and elbow. Only 7.4 per cent late loss, either partial or complete, of the original blocking is reported.

The role of the iliotibial band in producing deformity in poliomyelitis is discussed by Irwin (15). Shortening of the iliotibial band is due to shortening of the intermuscular septa and muscle enveloping fascia. Deformities produced by tight iliotibial bands involve the hip, pelvis, knee, and even the foot. They include pelvic obliquity, exaggerated lumbar lordosis, flexion, abduction and external rotation contracture of the hip, genu valgum, flexion deformity of the knee, external torsion of the tibia, and varus deformity of the foot. Conservative treatment is of no avail and only surgical release of the shortened structures will correct the deformities. Combined Ober's and Yount's fasciotomy is the procedure of choice.

Harmon (16) submits an operation to motivate a paralyzed triceps by transplanting the latissimus dorsi alone or the teres major with it to the triceps aponeurosis.

A study of 134 cases of hamstring tendon transplants for quadriceps paralysis is reported by Schwartzmann and Crego (17) who conclude that simultaneous transplantation of the biceps femoris and semitendinosus to the patella is a highly satisfactory procedure and is better than transplantation of the biceps alone. No cases of lateral dislocation of the patella occurred in the 13-year follow-up.



## BIBLIOGRAPHY

1. Guyton, A. C.: Reaction of the body to poliomyelitis and the recovery process, Arch. Int. M., 83: 27-47, Jan 1949
2. Smith, E.: Rosenblatt, P., and Lamauro, A. B.: The role of the sympathetic nervous system in acute poliomyelitis: preliminary report, J. Pediat., S. Louis, 34: 1-11, Jan 1949
3. Bodian, D., Morgan, I. M., and Howe, H. A.: Differentiation of types of poliomyelitis viruses; the grouping of 14 strains into 3 basic immunological types, Am. J. Hug., 49: 234-45, Mar 1949
4. -----: Poliomyelitis, Med. Bull. U. S. First Army, 4: 9-14, Aug 1949
5. Howe, H. A.: Epidemiology of poliomyelitis in the light of modern research, Am. J. Med., 6: 537-50, May 1949
6. Adamson, J. D., Moody, J. P., et al: Poliomyelitis in the Arctic, Canad. M. Ass. J., 61: 339-48, Oct 1949
7. Van Riper, H. E.: Report on polio, Merck. Rep., 58: 4-8, Jan 1949
8. Wesselhoeft, C.: The problem of tonsillectomy and tracheotomy in relation to poliomyelitis, Laryngoscope, 59: 726-30, July 1949
9. Nau, C. H.: Poliomyelitis following tonsillectomy; a review of literature, Arch. Pediat. N. Y., 66: 49-53, Feb 1949
10. Kilham, L., Levens, J., and Enders, J. F.: Nonparalytic poliomyelitis and mumps meningoencephalitis; differential diagnosis, J. Am. M. Ass., 140: 934-6, July 16, 1949
11. Kamman, G. R.: Periodic paralysis, Minnesota M., 32: 1028-30, Oct 1949
12. West, H. E.; and Bower, A. G.: Treatment of poliomyelitis involving the respiratory system, Am. J. M. Sc., 217: 252-5, March 1949
13. Lueck, W., Galligan, J., et al: Persistent sequelae of bulbar poliomyelitis, Bull. Univ. Minnesota Hosp., 20: 333-5, Feb 1949
14. Inclan, Alberto; End results in physiological blocking of flail joints, J. Bone Surg., 31 A: 748-754, Oct 1949
15. Irwin, C. E.: The iliotibial band, its role in producing deformity in poliomyelitis, J. Bone Surg., 31 A: 141-6, Jan 1949



16. Harmon, P. F.: Muscle transplantation for triceps palsy; the technique of utilizing the latissimus dorsi, J. Bone Surg., 31 A: 409-12, Apr 1949
17. Schwartzmann, J. R., and Crego, C. H., Jr.: Hamstring tendon transplantation for the relief of quadriceps femoris paralysis in residual poliomyelitis; a study of 134 cases, J. Bone Surg., 30 A: 541-9, July 1949



## CHAPTER XI

### INFANTILE PARALYSIS: RESEARCH

By

Robert C. Anderson, Colonel, M. C., U. S. A.

Assisted By

C. O. Brackebusch, Capt. MC, USA      Grant L. Griebie, Capt. MC, USA  
John H. Painter, Capt. MC, USA      C. W. Bierman, 1st Lt. MC, USA

#### General

Of historical interest is a seventeenth century case which Maloney (1) believes demonstrates that the classical picture of poliomyelitis has been recurring in recognizable form for at least 250 years. Professor Jean Godfrey Salzmänn of the medical faculty of Strasbourg University in December, 1734, published a case report, "On the Disappearance of Most of the Muscles of the Leg," which was recounted in the third book of L'Orthopedie by Nicholas Andry. A man, lame in the right leg, died of a fever at age 40 years. Professor Salzmänn dissected the leg, found that the muscles remaining scarcely retained even their normal outline. To find the cause of this patient's affliction, he journeyed to the patient's home village. There he found that when the patient was six years of age, he was riding on his brother's shoulders when he experienced an attack of considerable weakness in his legs. His parents had treated them with hot mineral waters, liniments, ointments, and succeeded in curing the left leg but not the right.

Miller (2) and Lepine (3) review the problem of poliomyelitis and suggest the trends of current research. There are three strains of viruses involved, not killed by chlorination, surviving for months in sewage, and existing in man as only reservoir of infection. The most important portal of entry is the pharynx. The most important lesions are in anterior horn cells, but the brain is also involved. During an epidemic large numbers of healthy carriers are present. Chilling, physical exertion, and ENT operations increase frequency of CNS involvement. The virus passes from person to person via feces or nasopharyngeal secretions, at present feces are apparently more important, as evidenced by seasonal variations. The forms taken by disease are subclinical, abortive, preparalytic, and paralytic. Physical findings are fever under 103 degrees, irritability, somnolence, nuchal rigidity, Kernig's sign, muscular spasm, and later muscular paralysis. The acute phase runs a self-limited course of 3 to 7 days. The CSF is frequently abnormal with a predominance of lymphocytes and an elevated protein. There is no specific treatment. Bed rest, immobilization of involved muscles, and heat to spastic muscles, oxygen, tracheotomy, and respirator for bulbar involvement are the standard measures. For prevention, tonsillectomies should be avoided during seasons of prevalence and undue physical exhaustion and chilling.



Shutkin (4) reports on 362 cases of acute anterior poliomyelitis seen at the North Carolina Orthopedic Hospital during the year 1948. Sixty-two per cent of the patients were from an urban area and 38 per cent from a rural area. There were 300 cases in which siblings were in close contact immediately prior to the illness and only 10 contracted the disease. Of 205 cases admitted to the hospital, 199 had a positive spinal tap (more than 10 cells and a positive Pandy), 96 had the spinal type, 21 bulbar. There were 28 deaths in the hospital group and all but 3 of these deaths showed severe encephalitic involvement.

### Immunity and types

Three separate groups of poliomyelitis virus have been identified by Kessel and Pait (5) by inoculation of monkeys and injections of immune serum. There are numerous substrains of these three groups.

Morgan (6) and Hammon (7) discuss the mechanism of immunity in poliomyelitis and its bearing on differentiation of types. Immunization of monkeys by the disease virus itself has been accomplished repeatedly but with inactivated virus immunization is considerably more difficult. An attack of poliomyelitis from one of the three immunologic types of the virus which have been found does not confer immunity to the other two types. Only fifty per cent of monkeys recovered from one type can be infected with another. In human beings, Howe estimates that for every paralytic case, there are 100 nonapparent ones. In a study of 303 children it was found that 86 per cent had developed a neutralizing antibody to the Lansing strain. To date there has been no proven method of immunizing humans against poliomyelitis.

Studies of the types include the work of Yager, Olitsky et al (8) who found that the MEFI strain of poliomyelitis would not multiply in chick embryos as the murine type does.

Dalldorf (9) (10) reports on a virus recovered from the feces of children which was pathogenic/suckling mice but not for the rhesus monkey. Enders et al (11) give preliminary results of cultivating Lansing strain polio virus in human embryonic tissues not of neural origin. Frisch (12) concluded that human convalescent serum and hyperimmune monkey serum failed to neutralize Lansing C (M) "egg adapted" virus in Swiss mice.

Attempts to attain a practical application for clinical use of this new knowledge are reported by Roberts (13). This paper describes a flocculation test for poliomyelitis. It is assumed that the virus has a negative charge. Protamine has a positive charge. A method has been developed to absorb the virus causing poliomyelitis on the protamine molecule. This antigen can be stored for at least one month at -15° C. without loss of activity. It is suggested that the flocculation test may offer a method for the grouping of the poliomyelitis viruses. The test is simple and relatively inexpensive since the cords of two monkeys supply sufficient antigen to test eight or ten sera.

Lepine et al (14) show the failure of a suggested simple laboratory



test using mice, primarily because of the difficulty of immunizing the mouse.

Toomey et al (15) wondered if food could act as a catalyst in producing poliomyelitis. Using cotton rats and the Flexner M. V. virus, they concluded that various fruits, especially peach mash, accelerated the production of the disease. They accomplished it also with injections of succinic acid and succinonitril, a synthetic chlorophyll.

### Epidemiology

In an article entitled "Recent Advances in Poliomyelitis, the Epidemiology," Gear (16) gives a discussion regarding the epidemiology, precursor to infection, and pathogenesis of poliomyelitis. He stresses the probable significance of exhaustive exercise and undue fatigue in the paralyzing form of the disease and the advisability of not performing tonsillectomy or other operations on oronasal mucous membranes at the time of an epidemic.

Sabin (17) discusses the mode of spread of poliomyelitis virus and the three popular theories (1) Respiratory, (2) Alimentary, and (3) Alimentary plus nonbiting flies.

A number of articles appeared this year regarding the disease in different parts of the world. The rates at which U. S. troops contracted poliomyelitis in different parts of the world are compared by Paul (18) to the rates seen within the local population. From these studies, it is felt that the rates in the Far East and the Philippine Islands were higher than elsewhere and that poliomyelitis in these areas is endemic and becomes apparent when foreign troops arrive.

In a study of poliomyelitis in Dufferin County, Ontario, Silverthorne et al (19) investigated 28 cases of polio. Of these, 4 were paralyzed and the remainder had a minor type. Polio virus was isolated from the stools of 7 patients. Two virus isolations were from persons with minor illnesses. Careful inquiries suggested that the disease was spread by close contact between children, from 8 days before onset of symptoms to 11 days thereafter.

Nissen (20) discusses an epidemic of poliomyelitis among 5,000 inhabitants of St. Helena. There were 217 diagnosed cases, 77 of whom were paralyzed, and 11 deaths.

Levine (21), Paine (22), and Caughey (23) reported the disease in Centralia, Illinois; Berlin; and New Zealand respectively.

### Pathology and Physiology

A systematic and detailed study of 42 brains is reported by Peers and Lissie (24). In the medulla, they recognize lesions of three sorts: (1) An infiltration of small lymphoid cells and mononuclear cells in the Virchow-Robin spaces, forming perivascular collars; (2) A proliferation of microglial cells in the ground substance; and (3) necrosis of nerve cells.



The lesions of maximum severity are regularly encountered in the reticular substance, nucleus ambiguus, supraspinal and spinal accessory nuclei. Necrotic cells with the typical reaction indicate that the cells of the sensory nuclei are not completely refractory to the virus of poliomyelitis. There is found no grouping of lesions that suggest an essential difference in pathogenicity of supposedly different strains of virus. There is no consistent difference in disease pattern corresponding to the duration of illness or to whether it began with bulbar or spinal symptoms. The authors conclude that death in poliomyelitis occurs when a certain and fairly constant amount of damage is produced in the medulla.

Rhian et al (25) used ultracentrifuge and electron microscopy to study CNS tissue from mice and rats because they felt there was some doubt as to the polio virus ever having been visualized. After a careful study, it was shown that the characteristic particles from both normal and infected tissues are approximately spherical and alike in size. Thus, the authors feel that no evidence that a virus of the poliomyelitis group has ever been unequivocally identified on electron micrographs thus far has been published.

In the field of clinical pathology, Rhodes et al (26), Joffe et al (27), and Cummings (28) describe laboratory studies on poliomyelitis. Rhesus monkeys are inoculated nasally with raw stool extracts and injected intraperitoneally with etherized stool extracts to recover poliomyelitis virus. Serological tests indicate mumps meningitis, St. Louis encephalitis, lymphocytic choriomeningitis and Western and Eastern equine encephalomyelitis. Spinal fluid examination shows a high cell count in purulent meningitis and lower (50-500 cu. mm.) in tuberculosis meningitis and poliomyelitis. Over 15 per cent of the total cells are usually lymphocytes in the two latter entities. Poliomyelitis is differentiated from the other two by the relatively normal protein, sugar, and chloride levels. The protein may persist as high as 300 mgm. for 8 weeks. The colloidal gold curve may be as large as 0122110000 and globulin is frequently positive until the fourth week.

A neurophysiological interpretation of the clinicopathological findings in bulbar poliomyelitis based on a study of 83 cases is submitted by Brown and Baker, (29). There was a death rate of 44 per cent. Four syndromes are classified: (1) The cranial nerve nuclei group, (2) The respiratory center group, (3) The circulatory center group, (4) The encephalitic group. Most of the deaths occurred as a result of involvement of the respiratory and circulatory centers in the medulla, or from added failure of peripheral mechanism of respiration. Hemorrhagic pulmonary edema was a prominent finding at necropsy. This was secondary to upper respiratory tract obstruction. As a guide to handling bulbar poliomyelitis, early elective tracheotomy with adequate suction is recommended. Where pulmonary edema is expected, 40 per cent oxygen under positive pressure is recommended.

Buchthal (30) discusses the problems of the pathologic physiology of poliomyelitis. Clinically, poliomyelitis is primarily a lower motor neuron disease with segmental distribution and yet all observers agree that the histologic lesions are never confined to the spinal cord, but are found in a number of other parts of the central nervous system, including the pre-central areas of the cerebral cortex. The nerve cells are primarily



affected. The virus spreads by way of the axon. It is the large anterior horn cells, especially those in the cervical and lumbar enlargements, which are particularly involved. Recovery after paresis depends upon severity and upon which muscle is affected. Age has no influence on the degree of recovery. Electromyographic examination has shown that recovery in an individual muscle may continue for six months. Extensor muscles are said to have a lower recovery rate. Paresis of the urinary bladder belongs to the reversible affections of poliomyelitis. It remains an open question whether circulatory disturbances are secondary to the inactivity or are due to direct damage to the autonomic ganglia. In man, damage was found in certain ganglia but the sympathetic chain usually escaped. In patients with cervical cases, the sympathetic centers in the lateral horns were found to be only rarely involved. These observations are in agreement with the assumption that it is principally neurons with fibers of large diameter which are susceptible to the poliomyelitis virus.

The electrical reactions of a paralyzed muscle give an indication of the integrity of the nerve cells and axons which supply that muscle states Mackenzie (31). In poliomyelitis this fact can be used to determine whether the anterior horn cells are completely destroyed. To be able to distinguish this early in the disease, greatly benefits the patient in the type of treatment that is started. By the use of the Strength-Duration curve used to study the excitability of voluntary muscle, one can determine the prognosis and type of treatment to be instituted by the fourth week after the onset of the disease. The practical application is also important. If the prognosis is good, a person can spend long periods of treatment on rest and re-education, and if the prognosis is bad, the patient can be fitted with the necessary supports early and save long periods of hospitalization.

Hargreaves (32) and Nisbet (33) present opposite views on the effect of exercise during the preparalytic stage on the severity of paralysis. The former, on the basis of 30 cases followed for 3 months, feels that physical activity leads to disastrous results. The latter tabulated the muscular activity of 16 patients during the preparalytic stage and finds no causal relationship between physical activity and the severity of paralysis.

Discussions on differential diagnosis from the standpoint of the pediatrician are given by Scobey (34) (35), Shaw (36), and Seidenfeld (37). Multiple neuritis is an illness whose clinical picture resembles poliomyelitis in many ways and the pathological changes in multiple neuritis, regardless of the cause, are found in the spinal cord and consist of degeneration of the anterior horn cells. Beriberi and pellegra are related with neuritic manifestations, and they, as poliomyelitis does, occur more commonly in children and young adults. Miasmatic poisoning was a term in common usage at the time of the Civil War. It referred to a host of diseases common to swampy ground and the literature of that period reveals that poliomyelitis was put in this category. Poliomyelitis and herpes zoster both affect the central nervous system and microscopically the changes occurring in nervous tissue are similar, but occur in different areas of the cord. The prodromal signs are similar and occasionally polio affects the posterior root cells, and herpes zoster the anterior root cells.



The Guillain-Barre syndrome, Petch (38) points out, frequently follows an antecedent febrile illness, and is characterized by symmetrical flaccid paralysis with abolition of tendon reflexes, subjective but not objective sensory change, and absence of fever. Of eight patients reported, all showed a symmetric flaccid paralysis involving particularly the proximal muscles of the limbs and extending in severe form to the cranial nerves, four patients showing facial involvement. An increase in spinal fluid protein is common, but not pathognomonic. There are no specific pathological changes. Its cause is unknown. Treatment is symptomatic and the author did not observe a beneficial effect from neostigmine. Physiotherapy is of value. The patient usually completely recovers.

### Treatment

Under the heading of prevention, a presentation by Cunning (39) of poliomyelitis-tonsillectomy statistics is inserted here. The author of this article has been compiling statistics since 1946 to determine whether or not a causal relationship exists between tonsillectomies and poliomyelitis. All tonsillectomies had been performed one to thirty days prior to onset of poliomyelitis. He is of the opinion that no definite relationship has been established between tonsillectomy and poliomyelitis. He does believe, however, that tonsillectomy should be postponed when there is a rise in the rate of poliomyelitis bordering on epidemic proportions, as is true of all elective procedures.

Various drugs have been tried in vitro and in vivo to find a specific remedy. Jones et al (40) found that oxythiamine, an inhibitory analogue of thiamine, produced a significant degree of protection against Lansing poliomyelitis virus in mice but not as marked as was the protection afforded the mice on a low thiamine diet.

Darvisul, a new sulfonamide compound (phenosulfazole), is reported in four articles. Schaeffer (41), Grayson (42), and Whelton (43) used the drug in 68, 45, and 32 patients respectively, compared the results with larger groups untreated and found no significant difference in the two groups. Harrington (44) used it on 79 patients and concluded that the results were favorable.

Plasma was administered intravenously by Eaton (45) and the rationale based on finding a decrease in serum albumin in patients with poliomyelitis. This fact, they hypothesize, may contribute to spinal cord edema, which may accentuate irreversible changes. This process of local edema may be increased in both rate and degree by slightly lowered serum albumin. The authors mention beneficial results of treatment of 76 patients with 600 to 900 cc. of plasma daily, to be reported elsewhere.

Controlled clinical experiments with curare are reported by Paul and Couch (46) done at Iowa University Hospital. A group of 69 patients was treated in the early stages of poliomyelitis with one of three methods: (1) hot packs and stretching, (2) stretching alone, and (3) stretching and curare. At the conclusion of the experiments it was felt that the acute phase of poliomyelitis can be adequately treated by physical means



without the use of hot packs. The most important part of the early treatment is the use of exercise or stretching to relieve tightness and pain. Exercise relieved only a few patients. Often it was impossible to carry out the desired range of motion due to pain. Curare in small doses enabled the therapist to carry out adequate stretching. It was not felt that curare had any curative effect other than facilitating physical therapy by its muscle relaxing properties.

Treating bulbar poliomyelitis as a problem in respiratory obstruction produced favorable results for Galloway and Seifert (47). They believe anoxia and carbon dioxide accumulation due to difficulty in swallowing produce most of the severe central effects seen in bulbar poliomyelitis. To substantiate their beliefs they point out that they had no deaths in 15 consecutive cases of bulbar poliomyelitis while the mortality rate for the bulbar form of the disease was 38.8 per cent in Illinois outside of Chicago during 1947 and 1948 and in Chicago in 1947, the rate was 27 per cent. Details of treatment for drainage of secretions from the larynx and pharynx are given and also the indications for tracheotomy with emphasis on the fact that the latter procedure should be done more frequently and earlier in these cases. Fluid balance and the use of the respirator in poliomyelitis are also discussed.

Hospital Progress (48) prints an article on how St. Anthony's Hospital, St. Louis, handled an outbreak of poliomyelitis. Overcoming mass hysteria is emphasized. Patients were discharged to out-patient care in 15 days to make room for more patients.

Bayer (49) discusses management of an epidemic in England with standard methods of diagnosis, treatment and nursing care.

The place of physical treatment in poliomyelitis is early, advocates Cholmeley (50), consisting of heat for pain, massage with passive movement as soon as temperature is normal and tenderness has disappeared, and continued for six months.

The adaptation of a rocking bed for providing artificial respiration in poliomyelitis is described by Lenarsky (51). He concludes that it does not replace the respirator but is supplemental to it as an aid in weaning patients from the respirator.

An article on the use of orthopedic appliances in the treatment of poliomyelitis is written by Capener (52) to show that surgery is not the only answer to paralysis of the limbs. It discusses the use of "physiological splints," devices made to render support and assistance without total immobilization. It stresses the importance of optimal position of different parts of the body, either for function or maximal relief of undue stress on paralyzed component muscles. There is a reminder on the importance of simplicity of design with weight being kept to a minimum. Bulk may defeat the purpose for which the splint was designed, unless these factors are kept in mind.



## BIBLIOGRAPHY

1. Maloney, W. J.: A 17th century case of poliomyelitis, *Edinburgh M. J.*, 56: 304-11, July 1949
2. Miller, E. S.: The pathogenesis, diagnosis and management of acute poliomyelitis, *J. Arkansas M. Soc.*, 46: 93-6, Oct 1949
3. Lepine, P.: Le probleme de la poliomyelite et l'orientation des recherches, *Union med. Canada*, 78: 7-11, Jan 1949
4. Shutkin, N. M.: Statistical survey of cases of acute anterior poliomyelitis, *Arch. Phys. M.*, 30: 455-8, July 1949
5. Kessel, J. F., and Pait, C. F.: Differentiation of three groups of poliomyelitis virus, *Proc. Soc. Exp. Biol., N. Y.*, 70: 315, Feb 1949
6. Morgan, I. M.: Mechanism of immunity in poliomyelitis and its bearing on differentiation of types, *Am. J. Med.*, 6: 556-62, May 1949
7. Hammon, W. M.: Immunity in poliomyelitis, *Bact. Rev., Balt.*, 13: 135-59, Sept 1949
8. Yager, R. H., Olitsky, P. K., and Lahelle, O.: Additional properties of the MEF 1 strain of poliomyelitis virus, especially with reference to attempts at cultivation in the chick embryo, *J. Bact., Balt.*, 58: 112, July 1949
9. Dalldorf, G., Sickles, G. M., et al: A virus recovered from the feces of poliomyelitis patients pathogenic for suckling mice, *J. Exp. M.*, 89: 567-82, June 1, 1949
10. Dalldorf, G.: Suggested studies of poliomyelitis, *N. York State J. M.*, 49: 1330, June 1, 1949
11. Enders, J. F., Weller, T. H., and Robbins, F. C.: Cultivation of the Lansing strain of poliomyelitis virus in cultures of various human embryonic tissues, *Science*, 109: 85-7, Jan 28, 1949
12. Frisch, A. W., and Henriques, C. C.: Failure of human convalescent and hyperimmune monkey poliomyelitis serums to neutralize egg adapted Lansing C (M) variant, *Proc. Soc. Exp. Biol., N. Y.*, May 1949
13. Roberts, E. C.: A flocculation test as a possible method for differentiating immunologic types of the poliomyelitis virus, *Pub. Health Rep., Wash.*, Feb 18, 1949
14. Lepine, P. R., Steigman, A. J., and Sabin, A. B.: Further consideration of suggested laboratory test for poliomyelitis virus, *Science*, 109: 17, Jan 7, 1949



15. Toomey, J. A., Takacs, W. S., and Pirone, P. P.: Accelerated production of poliomyelitis, *Am. J. Dis. Child.*, 78: 1-15, July 1949
16. Gear, J. H. S.: Recent advance in poliomyelitis, the epidemiology of poliomyelitis, *Postgrad. M. J., Lond.*, 25: 3-8, Jan 1949
17. Sabin, A. B.: Problems in the natural history of poliomyelitis, *Ann. Int. M.*, 30: 40-54, Jan 1949
18. Paul, J. R.: Poliomyelitis attack rates in American troops, *Am. J. Hyg.*, 50: 57-62, July 1949
19. Silverthorne, N., Armstrong, M. P., et al: Studies on poliomyelitis in Ontario; observations on the apparent infectiousness of the acute case, *Canad. M. Ass. J.*, 61: 241-50, Sept 1949
20. Nissen, K. I.: Epidemic of poliomyelitis in St. Helena, *Postgrad. M. J., Lond.*, 25: 13-7, Jan 1949
21. Levine, H. J.: Forty-two cases of poliomyelitis in Centralia, *Illinois M. J.*, 96: 178-80, Sept 1949
22. Paine, R. S.: Poliomyelitis in Berlin, *Med. Bull. Europ. Command.* 6: 3-9, Aug 1949
23. Caughey, J. E.: Some aspects of poliomyelitis in New Zealand, *Brit. M. J.*, 2: 406-10, Aug 20, 1949
24. Peers, J. H., and Lissie, R. D.: The topographic pathology of the cerebral lesions of acute poliomyelitis in man; the medulla oblongata, *Am. J. Path.*, 25: 725-39, July 1949
25. Rhian, M., Lensen, S. G., and Williams, R. C.: An electron microscope study of material from tissue of the central nervous system of poliomyelitis and normal mice and cotton rats, *J. Immun., Balt.*, 62: 487-504, Aug 1949
26. Rhodes, A. J., McClelland, L., and Donohue, W. L.: Laboratory studies on poliomyelitis, Toronto 1947, *Canad. M. Assn. J.*, 60: 359-63, Apr 1949
27. Joffe, H. H. and Wells, A. H.: Laboratory studies of cerebrospinal fluid in meningitis and poliomyelitis, *Minnesota M.*, 32: 608-12, June 1949
28. Cumings, J. N.: The cerebrospinal fluid in poliomyelitis, *Postgrad. M. J., Lond.*, 25: 19, Jan 1949
29. Brown, J. R., and Baker, A. B.: Bulbar poliomyelitis; a neurophysiological interpretation of the clinicopathological findings, *J. Nerv. Ment. Dis.*, 109: 54-78, Jan 1949



30. Buchthal, F.: Problems of the pathologic physiology of poliomyelitis, *Am. J. Med.*, 6: 579-91, May 1949
31. MacKenzie, I. G.: Electrical reactions of muscle in poliomyelitis, *Proc. R. Soc. M., Lond.*, 42: 488-90, July 1949
32. Hargreaves, E. R.: Poliomyelitis, effect of exertion during the pre-paralytic stage, *Brit. M. J.*, 1948, 2: 1021-22, Dec 11, 1948
33. Nisbet, B. R.: The effect of exercise on the severity of poliomyelitis, *Health Bull., Edinb.*, 7: 73, Oct 1949
34. Scobey, R. R.: Multiple neuritis and poliomyelitis, *Arch. Pediat., N. Y.*, 66: 110 passim. Mar 1949
35. Scobey, R. R.: Acute anterior and acute posterior poliomyelitis; are they the same disease? *Arch. Pediat., N. Y.*, 66: 402-10, Sept 1949
36. Shaw, E. B., and Thelander, H. E.: Clinical concepts of poliomyelitis, *Pediatrics, Springf.*, 4: 277-86, Sept 1949
37. Seidenfeld, M. A.: Psychologic aspects of poliomyelitis, *Pediatrics, Springf.*, 4: 309-18, Sept 1949
38. Petch, C. P.: The Guillain-Barre syndrome or acute infective polyneuritis, *Lancet, Lond.*, 2: 405-8, Sept 3, 1949
39. Cunning, D. S.: Poliomyelitis-tonsillectomy survey, *Laryngoscope*, 59: 441-53, May 1949
40. Jones, J. H., Foster, C., and Henle, W.: Effect of oxythiamine on infection of mice with the Lansing strain of poliomyelitis virus, *Proc. Soc. Exp. Biol. N. Y.*, 69: 454-8, Dec 1948
41. Schaeffer, M., and Toomey, J. A.: Experience with darvisul in the treatment of clinical and experimental poliomyelitis, *Am. J. Med.*, 6: 667, May 1949
42. Grayson, R.: The use of darvisul in acute poliomyelitis, *North Carolina M. J.*, 10: 492-4, Sept 1949
43. Whelton, R. L., Caldwell, E. R., Jr., (et al): The treatment of poliomyelitis with phenosulfazole, *J. Pediat., S. Louis*, 35: 447-50, Oct 1949
44. Harrington, P. R.: Chemotherapy and poliomyelitis; the use of darvisul on human subjects, *Texas J. M.*, 45: 470-3, July 1949
45. Eaton, R. M., and Bower, A. G.: A rationale for plasma therapy in poliomyelitis, *Science*, 110: 428, Oct 21, 1949



46. Paul, W. D., and Couch, O. A.: Preliminary report on the treatment of anterior poliomyelitis with exercise and curare, Arch. Phys. M., 30: 277-85, May 1949
47. Galloway, T. C., and Seifert, M. G.: Bulbar poliomyelitis; favorable results in its treatment as a problem in respiratory obstruction, J. Am. M. Ass., 141: 1-8, Sept 3, 1949
48. -----: Treating polio cases in the general hospital; 1949 outbreak teaches lessons, Hosp. Progr., 30: 280, Sept 1949
49. Bayer, P.: The management of acute phase of poliomyelitis, Postgrad. M. J., Lond., 25: 9-12, Jan 1949
50. Cholmeley, J. A.: The place of physical treatment in poliomyelitis, Postgrad. M. J., Lond., 25: 31, Jan 1949
51. Lenarsky, M.: The rocking bed; its use in poliomyelitis, Arch. Pediat., N. Y., 66: 339-48, Aug 1949
52. Capener, N.: The use of orthopaedic appliances in the treatment of anterior poliomyelitis, Postgrad. M. J., Lond., 25: 21-30, Jan 1949



## CHAPTER XII

### POLIOMYELITIS

By

L. W. Taylor, Lt. Colonel, M. C., U. S. A.

In editing the articles for publication of the abstracts in this chapter, an honest attempt has been made to review only those articles which reflect progress in orthopaedic surgery. The failure to publish abstracts of many good articles should not be considered a criticism of the article itself except that the substance of the material covered by the subject article has been previously published. The abstract is intended to furnish sufficient information to those who may be interested in the subject material, with a guide to the basic reference.

#### General

Kiernander (1) in a discussion of the physical medicine departments and rehabilitation centers in both civilian and military forces of England, gives the trend of establishment of additional physical medicine departments in the various hospitals in the United Kingdom. These departments are being headed by physical medicine specialists who hold a diploma in physical medicine from the Royal College of Surgeons after a course of one year post-graduate study.

Stewart (2), Rusk (3) give good discussions of general aspects of physical reconditioning and rehabilitation, and Deaver (4) reviews the rehabilitation of the amputee.

#### Poliomyelitis

An outline of the treatment of patients suffering with poliomyelitis is given by Hansson (5), including a brief discussion of early treatment which includes maintenance of nutrition by proper diet supported by amino acid, testosterone, and esterin; instruction in body mechanics in bed; early passive exercises to keep normal range of motion in joints and prevent contractures; therapeutic measures for muscle spasms, including heat to muscles which show pain; and individual tank with whirlpool and curare; muscle re-education to secure the maximum return of muscle function. The disadvantages of bedrest are stressed. A brief discussion of physical rehabilitation is given with the opinion expressed that the sixth month should be set as the beginning of physical rehabilitation which stresses functional activity and practical purposes. The period of physical rehabilitation is followed and fused with mental rehabilitation and vocational training. This article is of a generalized nature and covers briefly the main points in the treatment of patients with poliomyelitis. Nothing is new or significant in its concept.

Capener (6) reviews the use of orthopedic appliances in the treatment



of poliomyelitis and Bennett (7) the care of its after effects. Green and Gucker (8) discuss moist heat treatment and Bennett (9) the responsibilities of the physician in general practice with respect to the treatment of poliomyelitis.

### Arthritis

Watkins (10) describes the physical medicine treatment of degenerative joint disease. The subject material has been previously reported.

### Techniques

An excellent review of the importance and usefulness of electromyography in orthopaedics is given by Watkins (11). In poliomyelitis, electromyography gives a rough quantitative measurement of muscle spasm and strength; disorders of normal reciprocal innervation can be detected; high voltage, spontaneous discharges at rest are consistent with a favorable prognosis for improvement; and fibrillation denervation potentials are a poor prognostic sign. In studying peripheral nerve injuries, electromyography can detect early signs of re-innervation of a muscle before there is clinical evidence of regeneration, and since normal potentials may be discharged from a muscle which is apparently paralyzed, it is of value in establishing cases of hysteria and malingering. Electromyograms of patients with pain in the upper extremity from ruptured intervertebral discs show the presence of discharges from resting muscles, presumably from irritation of cervical roots, and thereby aid in the localization of the lesion. However, electromyograms on patients with pain in a lower extremity caused by ruptured intervertebral discs are of no aid in the localization of the level of the lesion because of the overlap of segmental innervation of muscles of the leg. Progressive muscle atrophy and amyotrophic lateral sclerosis shows diphasic spikes of very irregular voltage and frequency at an early stage when clinical signs reveal only localized muscle atrophy. Electrical recording of the tremor characteristic of Parkinson's disease is so constant that the electromyogram is of diagnostic importance and makes differentiation of this tremor from that of hysterical origin accurate and easy. The electromyogram is of little or no use in muscle dystrophy, myasthenia gravis and spasticity.

Gallagher and De Lorme (12) discuss the use of the technique of progressive-resistance exercises in the after care of knee injuries and low back strain, and in the muscle development of arms, shoulder girdle and chest in adolescence. Statistical tables of the increase in muscle power are given as well as pictures of special equipment used in the development of additional muscle power. The value of progressive-resistance exercise lies primarily in the prevention of recurrence of previous disability from lack of adequate muscle power. Adequate proof is shown that additional muscle power developed by progressive-resistance exercise is not lost subsequent to the development of this additional power. This is noted whether or not the exercises are continued after the additional power is acquired. The psychological development of added muscle power in adolescence is emphasized.

Bennett (13) gives a discussion of functional tests and training in



physical medicine as differentiated from the normal physical functions of developing individual muscles or muscle groups. General tables are given as a guide or index to this program of functional testing and training of a disabled or impaired patient with neuromuscular and musculoskeletal diseases. The plan utilized in this program has been adopted from the Georgia Warm Springs Foundation. Particular emphasis is placed on the proper timing of functional training because it is felt that the greatest danger in such a program would be the initiation of functional activity before the patient was properly prepared for these activities by sound and thorough muscle re-education as a result of judicious physical therapy.

Tichy (14) describes the technique of preventing venous thrombosis and primary embolism by electrical stimulation of the leg muscles.

#### Apparatus

Thompson (15) gives a description of the workings and functions of a retraining shop, which was built and equipped for the purpose of rehabilitating employees by using standard machines and bench assembly work selected from a factory and modified where necessary to provide remedial exercises and graded work. The work performed by patients is prescribed by visiting surgeons or the industrial medical officer.

Young (16) describes and illustrates mechanical aids for patients with muscular disability. A description of canes to assist the handicapped individual in mounting steps which would ordinarily be too high is given. These modifications include attachments to the distal end of an ordinary walking cane to permit the individual to mount a high step by placing the foot on the added attachment of the walking cane. An illustration is shown of a modified handle of approximately  $3\frac{1}{2}$ " in diameter which may be utilized as the stepping portion of the walking cane when required, with reversion to a normal walking cane on reversing the ends of the stick. A description and illustration of a spring-type chair seat mounted in an ordinary chair is given to facilitate the disabled patient to stand who is unable to rise from a sitting position. The spring mechanism is concealed in the sides of the chair which are covered by leather and lifts the seat forcefully, thereby facilitating the patient's rising to a standing position after sitting.

Coughlin (17) describes an abduction exercise splint for the shoulder and pictures are shown. The splint consists of "U-shaped" metal bar which is strapped to the body by means of cross straps and an axillary ring on the opposite shoulder. In addition, there is a shoulder strap on the affected side to prevent the shoulder from being elevated during the period of abduction. Extension of the elbow shortens the rope from the elbow to the pulley, which is situated approximately 6 inches above the level of the shoulder and by means of a sling around the elbow the arm is brought into abduction. The degree of abduction may be varied by shortening or lengthening the rope extending from the elbow sling to the hand grip.

Poole (18) presents a unique wheelchair to accommodate a patient having complete paralysis of both lower extremities and one upper extremity, and almost complete paralysis of the contralateral upper extremity.



Mechanical details for the construction of this wheelchair are not furnished in this article, but can be obtained on request from the author.

## Research

Hill (19) reports in detail physiological experiments on the study of muscle contraction and the internal mechanical condition of an excited muscle which has been examined by applying quick stretches at various moments after a maximal shock. Although proof is not conclusive, it seems reasonably certain that excitation of a muscle fibre occurs at the surface rather than being stimulated by the arrival of some chemical substance, which diffuses after liberation at the surface of the muscle cell.

Wakim and Elkins (20) present data to show the effects of blood flow in normal and paralyzed extremities when exercised. These studies indicate that exercises of the normal upper extremity do not materially change the circulation of the paralyzed lower extremity and neither is there evidence that it influences atrophy of muscle or bone in the paralyzed limb. Data is presented to show that patients who have normally enervated immobilized extremities could safely exercise the free extremities through the use of heavy resistance exercises. They might thereby reduce atrophy of disuse and loss of power in the immobilized extremities and maintain better general physical condition. It is stressed that fairly strenuous exercise is necessary to increase circulation of blood. Emphasis is placed on the necessity of supervision in order for heavy resistance exercises to be effective. Data is shown to illustrate that lack of supervision gives poor results.

Hollander and Horvath (21) give a detailed description of the method for measuring the intra-articular temperatures. It has not yet been shown that raising the joint temperature in treating arthritis is necessarily beneficial. In fact, in cases of active arthritis the forms of physical therapy which raise the temperature most (short wave diathermy, microwave and paraffin application) clinically appear to aggravate pain in acutely involved joints. The author further concludes that cold, pain, fear, and even smoking all lower the skin temperature and raise the joint temperature. Re-evaluation of the methods of physical therapy chosen for the treatment of rheumatoid arthritis should be made with actual reaction of the joint involved rather than on purely surface temperature changes since it has been observed that changes in joint circulation do not parallel those in skin, but frequently are directly opposite.



## BIBLIOGRAPHY

1. Kiernander, B.: Recent advances in physical therapy in the United Kingdom, Arch. Phys. M., 30: 296-300, May 1949
2. Stewart, M. J.: Aspects of physical reconditioning, J. Bone Surg., 31 A: 394-9, Apr 1949
3. Rusk, H. A.: Rehabilitation and general practice, J. Am. M. Ass., 139: 14-16, Jan 1, 1949
4. Deaver, G. G., and Daniel, E. H.: The rehabilitation of the amputee, Arch. Phys. M., 30: 638-56, Oct 1949
5. Hansson, K. G.: Rehabilitation in poliomyelitis, N. York State J. M., 49: 923-7, Apr 15, 1949
6. Capener, N.: The use of orthopaedic appliances in the treatment of anterior poliomyelitis, Overseas Postgrad. M. J., Lond., 3: 165-74, Jan 1949
7. Bennett, R. L.: Care of the after effects of poliomyelitis, Am. J. Med., 6: 620-7, May 1949
8. Green, W. T., and Gucker, T., III: Moist heat in the treatment of poliomyelitis, Am. J. Med., 6: 606-13, May 1949
9. Bennett, R. L.: Physical treatment of poliomyelitis; responsibilities of the physician in general practice, J. Am. M. Ass., 139: 1053, Apr 1949
10. Watkins, A. L.: Physical medicine in the treatment of degenerative joint disease, Med. Clin. N. America, 33: 1313-9, Sept 1949
11. Watkins, A. L.: Electromyography in orthopedics, J. Bone Surg., 31 A: 822-830, Oct 1949
12. Gallagher, J. R., and De Lorme, T. L.: The use of the technique of progressive-resistance exercise in adolescence, J. Bone Surg., 31 A: 847-58, Oct 1949
13. Bennett, R. L.: Functional testing and training in physical medicine, Arch. Phys. M., 30: 263-71, May 1949
14. Tichy, V. L.: Prevention of venous thrombosis and pulmonary embolism by electrical stimulation of leg muscles, Surgery, 26: 109-16, July 1949
15. Thompson, A. R.: Engineering methods in occupational rehabilitation, Indust. M., 18: 385-90, Sept 1949
16. Young, P. T.: Mechanical aids for patients with muscular disability, J. Bone Surg., 31 A: 428-30, Apr 1949



17. Coughlin, E. J., Jr.: An abduction exercise splint for the shoulder, J. Bone Surg., 31 A: 438, Apr 1949
18. Poole, A. G. B.: A wheelchair, Lancet, Lond., 1: 480-2, Mar 19, 1949
19. Hill, A. V.: The abrupt transition from rest to activity in muscle, Proc. R. Soc., Lond., Ser. B., 136: 399-420, Oct 1949
20. Wakim, K. G., Elkins, E. C., et al: The effects of therapeutic exercise on the peripheral circulation of the normal and paraplegic individuals, Arch. Phys. M., 30: 86-95, Feb 1949
21. Hollander, J. L., and Horvath, S. M.: Changes in joint temperature produced by diseases and by physical therapy; preliminary report, Arch. Phys. M., 30: 437-40, July 1949



## NEUROMUSCULAR DISORDERS EXCLUSIVE OF POLIOMYELITIS

By

A. A. Grebe, Colonel, M. C., U. S. A.

Unusual Causes

The toxic effects of penicillin on nerve tissue are fortunately not frequent. Broadbent et al (1) report 4 cases of this antibiotic induced neuritis following the injection of large concentrations of penicillin into or adjacent to major peripheral nerve trunks. It is characterized by intense, immediate pain radiating distally along the affected nerve segment. In two cases the symptoms regressed rapidly but in the other two cases, chronic and static disability resulted. The reaction may be more intense in the presence of a vehicle such as wax, but is probably not wholly dependent on such a vehicle.

Griffin (2) reports a case of isolated paralysis of the serratus anterior muscle; a rare condition, caused by malfunction of the posterior thoracic nerve which gives a pronounced winging of the scapula and inability to elevate the arm above the shoulder. Since practically all these cases recover in 3 months to 3 years unless the nerve has been severed, treatment should be conservative; vitamin B<sub>1</sub>, support of the arm with the scapula held to the side of the chest by use of a sling, brace, shoulder spica, etc.

Stephens (3) states that paralysis associated with reduced serum potassium concentration is an uncommon but serious complication of therapy of diabetic acidosis. The neurologic manifestations are progressive muscular weakness and flaccid paralysis of the extremities.

Landells (4) presents what is apparently the first case published of intramedullary cyst of the spinal cord due to cestode *Multiceps multiceps* in the coenurus stage.

Iselin et al (5) discusses ischemic pain of the limbs and suggest that instead of embolism, the cause is a primary dynamic arrest of the arterial pulsations; clot formation would then occur secondarily due to the interference of secretion of heparin by the arterial walls. This theory is based on operative findings and on the differences distinguishing the disease in man from experimental embolism in animals. The proposed treatment is first medical, and in case of failure, surgical.

Differential Diagnosis

Phenomena of pain of the upper extremity without apparent cause are frequent. Fontaine et al (6) mention among other better known causes,



radicular tumor, cervical disk, foraminal changes, narrowing of the costo-clavicular space, and compression of the axillary artery between the median nerve roots. The authors report 9 cases broken down as follows: Scalenus syndrome, 4 cases; *ibid.* plus hypertrophy of transverse process, 2; *ibid.* plus cervical ribs, 1; and cervical ribs only, 2 cases. Scalenotomy was beneficial in most cases where only paresthesiae were present, not so good in the presence of vascular impairment. They conclude that different causes may produce similar syndromes and that the true explanation may perhaps be determined by further study.

Progressive muscular dystrophies are divided into three groups in a paper by Bourguignon (7), a Paris interne, on the subject. (1) The myopathies diagnosed in children consisting of a generalized amyotrophy. They are characterized by their grave prognosis, surviving usually 20 or 30 years. (2) Thomsen's disease, on the other hand, shows myotonia, true muscle hypertrophy and a good prognosis for life. (3) Steinert's disease is between these two extremes in which amyotonia and myotonia are associated, and endocrine changes are present. It progresses slowly and is usually terminated by death at 40 or 50 years. In the first group the author describes (1) the facio-scapulo-humeral type of dystrophy, typical of which is a child of 15 years who can not close his eyes or whistle and whose upper lip protrudes (*levre de tapir*) and who has atrophy of the scapulae and arms, and a familial history of antecedents with similar affliction; (2) the pseudohypertrophic type of Duchene de Boulogne generalized or limited to the lower limbs with the upper limbs amyotrophic; and (3) Erb's juvenile type of scapulo-humeral myopathy which progresses much more slowly. The second group was described by Thomsen about himself and his family and is rarer than the other. The third group affects the face first, then the neck, hands and feet. The author makes a synthesis of all these groups and concludes they are different forms of the same entity from the standpoint of physiopathology. Treatment is discouraging.

The use of intravenous neostigmine in the diagnosis of myasthenia gravis is reported by Tether (8). Intramuscular injection was used by Veits and Schwab but the intravenous modification gives more rapid, clear-cut and complete improvement. The test has been used in several hundred instances without serious reactions.

The treatment of myasthenia gravis is reviewed by Stone and Rider (9) in the JAMA. The dramatic and beneficial effects of treatment with neostigmine and tetraethylpyrophosphate are outlined in detail. The effectiveness of these drugs is said to be comparable to that of insulin in the treatment of diabetes. The disadvantages of neostigmine therapy are that its action is relatively short, it may produce toxic symptoms, and it is relatively expensive. The management of toxic reactions to these drugs is discussed in detail.

Welte (10) reports 3 cases of myasthenia gravis (*pseudoparalytica*) which showed definite objective improvement following x-ray therapy of thymus gland.

A report on familial periodic paralysis is published by Ziegler (11) This little understood and comparatively rare syndrome was studied in



two families. Attacks of paralysis were precipitated by the administration of insulin in some cases, by dextrose in others, and by water diuresis in still others. Serum potassium values during paralysis were low normal on two occasions and pathologically low on two others. The oral administration of potassium chloride seemed to hasten return of muscular function.

### Peripheral Nerves

The student of modern peripheral nerve surgery must be a student of military neurosurgery writes Woodhall (12). Advances in neurosurgery are related to the decided increase in peripheral nerve injuries which always occurs during war and to the laboratory studies that have been initiated as a consequence of the unusual mass of clinical material. The modern history of peripheral nerve surgery is considered to have started in the latter part of 1942. Tantalum wire as suture material has proven to be relatively inert but its use demands considerable dexterity. The use of plasma-glue in nerve repair has not been fully delineated. Much remains to be done in the field of nerve grafting. Causalgia was found to occur in approximately 3 per cent of major nerve injuries; usually in cases of incomplete nerve division. Chemical or surgical interruption of the sympathetic pathways to the part involved is a highly successful treatment for causalgia. The value of delayed suture of nerves as compared with primary suture is almost incontrovertible except possibly in the hands of skilled neurosurgeons working under ideal conditions. The Peripheral Nerve Registry of World War II is conducting follow-up studies in some 7,000 nerve injury cases which should have a far reaching effect in the future treatment of peripheral nerve injuries.

Recovery following radial nerve suture is satisfactory in a high percentage of cases, Aldrich (13) concludes after studying a series of 88 cases. The degree of recovery is not greatly influenced by the period between injury and suture up to a maximum of one year. Recovery does not begin before 6 months after suture, but progresses over a period of a year or more.

De Frenelle (14) believes that in radial paralysis, tendon transplants should be done early and as reasons states, (1) Nerve sutures are often unsuccessful and (2) Even when successful the recovery period is so long that the muscles and joints deteriorate and ultimate hand function is impaired.

Tardy paralysis of the cubital (radial) nerve 59 years after fracture of the external condyle is reported by Mouchet and Seille (15) because of its medicolegal implications.

### Treatment

A theory is proposed by Furmanski (16) that neuropathies are initially reversible biochemical disorders of the neuron and that no structural changes of degeneration occur. Dithiol 2, 3, dimercaptopropanol (Bal) has the ability to restore disrupted cellular metabolism by its action on the enzyme systems.



Four cases of infectious and metabolic neuropathies are reported. These cases did not respond to therapy with vitamin or crude liver extract. The addition of Bal to the treatment resulted in rapid recovery in 3 cases and improvement in one case.

The surgical treatment of spasmodic torticollis is discussed by Putnam et al (17). Three principal approaches have been applied to the surgical treatment of torticollis: myotomy, section of peripheral nerves, and intradural section of cervical roots and spinal accessory nerve fibers. Myotomy has been abandoned in favor of denervation. Emphasis is placed on the necessity of varying the operative procedures to the individual case and the possible need for several procedures to eliminate all spasmodic movements is pointed out. The psychologic attitude of the patient both before and after operation must be taken into consideration.

The surgical treatment of Parkinson's syndrome is reviewed by Gardner (18). Cerebral sympathectomy accomplished by resection of the superior cervical sympathetic ganglia is of slight value in the treatment of Parkinson's syndrome. The chief benefit is a favorable alteration of the mood and this may be responsible for reduction of rigidity and impaired ability to perform acts in a few instances. None of the present day operative procedures are entirely satisfactory but the distress of these patients, the relatively ineffectiveness of medical treatment, and the occasional brilliant surgical result continue to stimulate efforts in this field.

Guttman (19) discusses the surgical treatment of traumatic paraplegia. Exploratory laminectomy versus conservative treatment in traumatic paraplegia remains a controversial subject. Among those advocating surgical intervention there is disagreement as to the optimum time for laminectomy. In open or compound spinal injuries, operative treatment is advocated as soon as general shock has been overcome. In closed injuries of the spine with complete paraplegia, conservative treatment is recommended. In closed injuries with incomplete paraplegia, conservative treatment is also favored except in rare cases of rapidly increasing epidural hemorrhage. Late laminectomy has been carried out for the following purposes: (a) Restoration of neural function - as a general rule this is not accomplished. (b) Treatment of intractable pain. This complication is best treated by general rehabilitation and training. (c) Treatment of violent flexor or extensor spasms. This complication is best treated by appropriate preventive measures at an early date after injury. Neurectomies and tendon lengthening are preferable to major cord surgery.

Myositis ossificans in paraplegics was studied by Miller and O'Neill (20). The incidence of myositis ossificans has been reported to be as high as 48.7 per cent but was found to be not nearly so high by the authors in the treatment of a large number of cases. Blood chemistry studies revealed no significant changes. Roentgenographic findings are obvious. Pathological findings are essentially those previously described in the literature. Several theories concerning the formation of the lesions are presented.



## BIBLIOGRAPHY

1. Broadbent, T. R., Odom, G. L., and Woodhall, B.: Peripheral nerve injuries from administration of penicillin; report of four clinical cases, *J. Am. M. Ass.*, 140: 1008-10, July 23, 1949
2. Griffin, J. P.: Isolated paralysis of the serratus anterior muscle; case report, *J. Indiana M. Ass.*, 42: 1068, Oct 1949
3. Stephens, F. I.: Paralysis due to reduced serum potassium concentration during treatment of diabetic acidosis; report of case treated with 33 grams of potassium chloride intravenously, *Ann. Int. M.*, 30: 1272-86, June 1949
4. Landells, J. W.: Intramedullary cyst of the spinal cord due to the cestode *Multiceps multiceps* in the coenurus stage; report of a case, *J. Clin. Path., Lond.*, 2: 60-3, Feb 1949
5. Iselin, M., and Heim De Balsac, R.: Syndrome d'ischemie aigue des membres, *Sem. hop., Par.*, 25: 337-42, Jan 30, 1949
6. Fontaine, R., Franck, P., and Rivaux, R.: Contribution a l'etude des acroparesthesies nocturnes; faux syndromes de Raynaud, syndrome du scalene, syndrome de cote cervicale; a propos de neuf cas operes, *Medecin Fr.*, 9: 47-9, Feb 25, 1949
7. Bourguignon, A.: Diagnostic et pronostic des dystrophies musculaires progressives, *Medecin fr.*, 9: 65-6, Mar 10, 1949
8. Tether, J. E.: Intravenous neostigmine in diagnosis of myasthenia gravis, *Ann. Int. M.*, 1948, 29: 1132-8, Dec 1948
9. Stone, C. T., and Rider, J. A.: Treatment of myasthenia gravis, *J. Am. M. Ass.*, 107-11, Sept 10, 1949
10. Welte, E.: Ueber die Behandlung der Myasthenia pseudoparalytica durch Rontgenbestrahlung der Thymusdruse, *Deut. Arch. klin. Med.*, 194: 112-20, 1949
11. Ziegler, D. K.: Familial periodic paralysis; report on two families with observations on the pathogenesis of the syndrome, *Arch. Int. M.*, 84: 419-30, Sept 1949
12. Woodhall, B.: Modern history of peripheral nerve surgery; World War II and the postwar study of peripheral nerve regeneration, *J. Am. M. Ass.*, 139: 564-6, Feb 26, 1949
13. Aldrich, E. M.: Radial nerve division; report of 88 cases, *South Surgeon*, 15: 118-22, Feb 1949
14. Dupery de Frenelle: Traitement de la paralysie radiale des extenseurs des doigts et de la main par des parties tendineuses mortices,



15. Mouchet, A., and Seille, G.: Paralysis tardive du nerf cubital et accident du travail, Presse med., 57: 197, March 5, 1949
16. Furmanski, A. R.: Bal therapy of severe peripheral neuropathies, Arch. Neuro. Psychiat., Chic., 60: 270-8, Sept 1948
17. Putnam, T. J., Herz, E., and Gloser, G. H.: Spasmodic torticollis; surgical treatment, Arch. Neur. Psychiat., Chic., 61: 240-70, Mar 1949
18. Gardner, W. J.: Surgical aspects of Parkinson's syndrome, Postgrad. M. 5: 107-11, Feb 1949
19. Guttman, L.: Surgical aspects of the treatment of traumatic paraplegia, J. Bone Surg., 31 B: 399-403, Aug 1949
20. Miller, L. F., and O'Neill, C. J.: Myositis ossificans in paraplegics, J. Bone Surg., 31 A: 283-94, Apr 1949



## CHAPTER XIV

### FRACTURES

By

Robert S. Lockwood, Lt. Colonel, M. C., U. S. A.

#### General

Of considerable historic interest is an article by Kamel Hussein (1) who discusses selected cases from the Edwin Smith Papyrus, a treatise on traumatology written 2800 years before Christ by an unknown "clinician," who "had powers of clinical observation even greater than those of Hippocrates, and whose recorded methods of treatment have not been excelled today."

Griffiths and Brockbank (2) write on the origin of "The Vidian Pictures," by Guido Guidi (1500-1569) with particular reference to traction devices, and reproduce representative original illustrations.

Johnson and Stovall (3) report on results of a survey of medical schools of the United States with regard to the teaching of fractures. In over half the schools, fracture treatment and instruction of undergraduate students was assigned to the department of orthopedic surgery.

Hanlon et al (4) report on causes of injury in children. Fractures and dislocations constituted 14 per cent of injuries with almost half occurring in the radius or ulna. Sixty-two per cent were children under 9 years of age and 38 per cent of injuries were due to falls, with 5 per cent due to auto injuries.

Aiken et al (5) present discussions covering fracture problems in cervical spine injuries, pelvic fractures, central dislocation of hip, length of immobilization, shoulder-dislocation, well-leg traction in intratrochanteric fractures, epiphyseal separation in tibia, manipulative therapy in low back pain, herniated intervertebral disc, nonunion of neck of femur, and crushing injuries to chest.

#### Emergency Treatment

Allredge and Banks (6) outline standard principles of splinting, traction, and immobilization of fractures. Rationale and technique of application are included.

Wright (7) and Massart (8) discuss the emergency treatment and transportation of fractures and the proper handling of the general condition of the patient.

Girdlestone (9) describes the organization of a regional Orthopedic



and Accident Service within the National Health Service of Britain. The organization is built around a central Orthopedic Hospital with area hospitals providing for orthopedic out-patient service, short term cases and accident service to all patients in the region.

Nale (10) suggests standing orders for emergency treatment of traumatic cases in industrial dispensaries to be rendered before the physician arrives.

### Closed Treatment

Stinchfield (11) reviews the principles of traction and suspension treatment in fractures, the details in proper application and adjustment of the apparatus and points out common faults.

Speed (12) in discussing comminuted and segmental fractures of leg gives causes, aims in treatment, accurate assessment of injury, and outlines reduction by fixed traction, followed by splinting, continuous skeletal traction, external skeletal fixation, followed by splinting and delayed ambulation. Four illustrative cases are presented with drawings from x-rays.

Winant (13) presents a study of 68 cases of fractures of femur in which skeletal traction was used in the treatment. A Kirschner wire in the supracondylar area rather than through the tibial crest was preferred. Traction was maintained until solid clinical and roentgenographic union was present. Average time from injury to weight bearing was 6.1 months. Open reduction with internal fixation and/or bone grafting was done in 18 cases. Knee motion was present in 61 cases to 180 degrees extension and in 32 cases to 90 degrees or more flexion. (Thirty-six cases had less than 90 degrees flexion.)

Mock (14) reports illustrative cases in the use of skeletal pinning and external fixation. Included were fracture-dislocation of hip treated by traction to reduce the hip after reduction of a femoral shaft fracture had been obtained with pins and external bars; fractures near joints where early motion was sought; fractures of shafts of long bones for early crutch ambulation and in handicapped patients; maintaining position after arthrodesis and maintaining limb length in fractures with bone loss. The disadvantages are: there is the ever present danger of infection; it is technically slower and more difficult; and it is not as easy as it might appear. Author stresses that this method of treatment should be utilized only in selected problems and the majority of fractures treated by the "time-honored closed reduction methods."

Fan (15) presents 16 cases (4 were still under treatment) of fractures of shafts of tibia and fibula treated by closed reduction with Steinmann pins inserted in the proximal tibial fragment and in the os calcis, and incorporated in a skin tight plaster cast. The pins were removed in 6-8 weeks.

Naden (16) reviews 237 cases involving fractures of the tibia treated by external skeletal-fixation equipment by Roger-Anderson method. Modifications in the surgical technic are brought out and representative cases



illustrated by roentgenograms. Average hospital period was 8 days for simple fractures and 16 days for compound shaft fractures. Average length of time required for union was sixteen weeks. Minor skin irritation about the pins occurred in 5 per cent.

Paterson (17) reviews 86 fractures of long bones in 83 patients (1939-1941), the majority of which were treated by external skeletal fixation with Roger Anderson dual pins, and several with Stader splint or transfixing pins and wires. Results were excellent to satisfactory in 65 patients, with this treatment appearing to have been a good method of treatment in 30 of the patients; not the method of choice in 27; and in 10, the choice would be questionable or indifferent. The author feels that the relatively high incidence of delayed union, nonunion, and osteitis has led to a preference for other methods of treatment.

### Open Treatment

In an experimental study on dogs by Fitts et al (18) they distinguish a periosteal callus, often far removed from the fracture site, which reaches its maximum in four to six weeks and is gradually absorbed. They postulate that the periosteal callus is caused by pressure of the nail on the inner cortex and that its disappearance is due to absorption of bone and release of pressure. The true callus appears at the fracture site about the same time and goes on to consolidation.

The present concepts and metals used for internal fixation are discussed by Townsend and Gilfillan (19) and results of 179 open reductions are reported by McLaughlin (20). Fixation in two planes was used. They were classified as "by choice," "by necessity," and in "compound fractures." One hundred and thirteen had end results completely normal and 27 additional cases with slight angular deformity had approximately normal results.

The United States Navy in a series of installments translates the experiences of Haebler (21) with intramedullary nailing of approximately 900 fractures. He selects fractures of the true shaft which are not comminuted. The only tibial fracture suitable for early weight bearing are those of the stable type. He uses them in forearm bones only if reduction can not be held in plaster. In compound fractures, the nail is left in until the fracture heals. Almost all were done by the closed nailing technique.

A discussion of the Rush pin and the various lengths and diameters available is presented by Rush and Rush (22). They describe its use and advocate external support to control rotation in tibial and femoral fractures. In their hands complications were minimal.

The operative procedure, principles and types of cases suitable for Kuntscher's medullary nailing are described by Professor Bohler and his son (23). The operative procedure, principles, and types of cases suitable for Kuntscher's medullary nailing are discussed. They advocate closed medullary nailing of the femur for simple fractures, and have discarded



its use in the tibia and forearm, only occasionally using it in closed transverse fractures of the humerus. Their experience covers 700 cases.

A careful article on the wide use of the intramedullary nail is presented by Kamel Hussein (24). Its use is advocated for all shaft fractures except those of the radius and tibia. Open reduction and retrograde insertion of the nail is recommended.

Kuhlmann (25) discusses certain principles of intramedullary nailing. Closed reduction is preferred. Skeletal traction with Kirschner wire is useful in reduction when gross displacement is present. A Christian-Rocher nail is preferred for the tibia, cylindrical nail with triangular point for the humerus, Kuntscher nail for femoral shafts, and Sven Johannsen nail for subtrochanteric fractures.

Swynghedaw et al (26) report results of intramedullary nailing in 25 cases; 56 per cent showed perfect anatomical results; 24 per cent had complications.

Kuhlmann and Le Maistre (27) advocate the use of the cylindrical nail of Christian-Rocher for intramedullary fixation of oblique fractures of the humerus and tibia.

Intramedullary nailing is advocated as the treatment of choice in compound fractures of the humerus and femur even in the presence of infection by Pointot (28). For the tibia and forearm bones he is less positive.

Ehrenhaft and Tidrick (29) report on 10 cases of pathological fracture of the shaft of the femur (4 due to Paget's disease, 5 to metastatic carcinoma and 1 to multiple myeloma) treated by intramedullary fixation using Kuntscher and "Hansen-Street" nails. Stress is on patient's relief of pain, free mobility of extremity, lessened nursing care, and decreased hospitalization.

In an article on nailing of "neck" fractures of femur in children, Moser (30) points out the importance of restoring the correct angle between the neck and shaft of the femur as this angle varies during growth, also avoiding damage to the capital epiphyseal plate by the nail. As most fractures of the neck of the femur in children are lateral and a relatively long neck fragment present on the proximal, the nail should be driven to the epiphyseal line without penetrating it.

### Head and Trunk

Fractures of the facial bones are discussed by Dubecq and Marcard (31) and an account of the apparatus used, and the principles involved is given.

Christensen (32) reports a case of compound, comminuted bilateral fracture of mandible due to gunshot wound which terminated in death from



shock 12 hours after debridement and intramaxillary wiring.

Jones (33) reports a case of bilateral forward dislocation of the temporo-mandibular joints of 10 years duration following tonsillectomy, treated by osteotomies through the necks of the rami (Kostecka's operation). The corrected position was maintained for 6 weeks by previously constructed dental splints.

Graubard (34) presents two cases of isolated fracture of the atlas bringing the total cases recorded in literature to 56. Mechanism of trauma and treatment are discussed.

Borsotti (35) introduces a method of "closed" intramedullary fixation of fractures of the clavicle, with Kirschner wire passed through the lateral fragment from the fracture site withdrawn enough to permit manipulative reduction, then drilled into the medullary cavity of the medial fragment. The wire is withdrawn in 15-20 days.

Cohen (36) and Paulley et al (37) report cough fractures of the ribs, 6 in tuberculous patients and 4 in pregnancy respectively.

#### Upper Extremity

Twenty-one cases of fractures of the upper end of the humerus with pronounced displacement treated with good results by open reduction and fixation with the Kuntscher nail, are presented by Widen (38). Four patients had some degree of limitation of abduction, but all were free of pain.

Jessing (39) describes an apparatus (Persson Frame) consisting of a square (60 x 60 cm.) tubular frame with chest piece onto which the arm is secured with traction bands applied to the forearm and upper arm for repositioning of the fracture. Application and use of the frame are discussed. Photographs are included and three different cases considered difficult treated in this manner are presented.

Open reduction of fractures of the external condyle of the humerus in children is advocated by Tondeur (40) due to the high incidence of ulnar neuritis and palsy.

Quigley (41) reports 7 cases of fracture of the head of the radius without displacement treated by aspiration of the elbow with early restoration of full range of motion. Aspiration was usually done 24 hours after injury with 10-15 cc. of blood being removed.

Patrick (42) briefly discusses fractures of the elbow with reference as to types, treatment, and complications.

Antila (43) presents a case of displacement of the ulnar epicondylar fragment into the joint cavity treated by open reduction and fixation with a nail. Discussion includes a review of the literature and pros and



cons for open versus conservative reduction.

Knight and Purvis (44) review the end results of 100 cases of fractures of both bones in the forearm in adults. A high incidence of unsatisfactory results was present (71 per cent in closed reduction; 85 per cent in open reduction without any kind of internal fixation; 65 per cent in open reduction with plate fixation.) An important causative factor was improper rotational alignment. Open reduction and rigid internal fixation was advocated for upper third fractures and oblique or comminuted fractures at any level, and primary bone grafting for comminuted fractures of the shafts. Intramedullary fixation was found to be a very satisfactory method of maintaining the reduction and alignment of complicated fractures. Plaster fixation had to be maintained until roentgenographic union was present regardless of the type of internal fixation.

Stuck and Thompson (45) report 19 cases of fractures of forearm bones requiring open reduction, treated by intramedullary fixation using wires and pins. Discussion stresses lessened surgical exposure at fracture site and improved reduction without interference of bony union by this method. External support by cast was necessary for 6-8 weeks with solid bony union seldom present before 3 months.

Carothers and Boyd (46) discuss a technic of reducing Colles' fractures by thumb traction. The method avoids soft tissue trauma, requires a minimum of equipment and assistance, and facilitates obtaining postreduction x-rays and application of the cast. It utilizes a skin tight forearm cast which is split along the ulnar side and avoids acute volar flexion of the wrist.

Rush and Rush (47) report 6 cases in which longitudinal pin fixation was used for Colles' fracture of the wrist. The pin was inserted into the lateral surface of the styloid of the radius through a 1/4th inch stab wound after manipulative reduction. Fixation was secure enough not to require external immobilization.

A method of treatment of fractures of the shafts of metacarpals is presented by Meyer (48). It consists of manipulation and application of a plaster cast which permits full range of motion in the metacarpophalangeal joint. A diagram illustrating the cast is given.

An unusual variety of fracture of the proximal end of the humerus is reported by Rodino (49). He reviews the classification of fractures of the proximal end of the humerus and adds another type which he describes as fracture of the greater tuberosity with simultaneous splitting of the surgical neck. The latter fracture is almost always subperiosteal and therefore there is no displacement. Treatment is conservative with early mobilization of the joint.

#### Lower Extremity

Goodwyn (50) discusses in brief but comprehensive manner, fractures of the lower extremity giving indications for open or closed treatment and pointing out complications which can be avoided by careful planning and selection of the best procedure for a given type of fracture.



Eleven cases of trauma to long bones in newborn infants delivered breech first are reported by Snedecor and Wilson (51). Causative mechanism, pathological changes, and course of recovery are discussed. The injuries followed a pattern of epiphyseal separation, periosteal stripping, or both, showing x-ray evidence of calcification in 5 to 7 days.

The treatment of a case of intra-uterine fracture of the tibia and fibula with malunion by osteotomy and plating at 3 months of age is reported by Lawson (52). The result at age 5 was satisfactory.

The treatment of intracapsular fractures of the femur with a combined Smith-Petersen nail and fibular graft is advocated by Patrick (53). Operative technique is given. In his series of 47 cases with two-year follow-up, however, 87 per cent showed degrees of aseptic necrosis of the head, and 21 per cent developed osteo-arthritis, "due to graft penetrating the joint."

Fowler and Riordan (54) advise careful selection of cases for use of the Kuntscher intramedullary nail in the femur; limiting its use to fractures within the upper two-thirds of the shaft and at least one inch below the lesser trochanter, and where the fracture line is transverse, or nearly so.

Altenberg and Shorkey (55) present four problem cases of supracondylar fracture of the femur treated successfully by open reduction and blade-plate fixation. Rigid fixation, early joint mobilization, and early ambulation were possible. Operative technique is given.

Nusselt (56) discusses the choice of the most suitable treatment for tibial fractures. He states that the value of treatment is based on the function and result, the duration of treatment and the risk. Analysis of 64 cases treated in the Clinic of Giessen reveals fractures of the middle third are suitably treated by intramedullary nailing, those of the distal third by skeletal traction with or without plaster. Bone plating was unsatisfactory.

Stuck and Dunlap (57) review 68 cases of compound fractures of the tibia. Their discussion stresses the importance of proper initial treatment, thorough wound cleansing with minimal removal of skin edges and bone fragments and early closure by secondary suture or skin graft. Manipulation and cast resulted in highest per cent of union but with more likelihood of angulation and overlapping. Wires or pins incorporated in cast caused the most secure union with best functional result, while internal fixation resulted in extension of infection and nonunion in over 50 per cent of cases.

Blanco (58) reports satisfactory results in 5 cases of recurrent lateral dislocation of the patella, treated by transplanting the medial half of the patellar tendon in a modified Goldthwaite's procedure. Operative technique, results, and brief discussion of other procedures are covered.

Schrey (59) discusses mechanism of trauma in posterior lipping



fractures of the tibia and the surgical procedures for repair through postero-medial approach and fixation with screws.

Herzog (60) postulates that contrary to the opinion of many, the fractures of the fibular malleolus are inversion injuries rather than eversion with the axis of rotation of the foot occurring at ground level and not in the ankle joint. Diagrams and past theories are presented.

La Ferte (61) presents two cases of fracture-dislocation of the ankle with fracture of the astragalus.

Hamilton (62) records a case of lateral and forward dislocation of the os calcis without any associated fracture of the foot or ankle, produced by severe trauma forcing the patient's leg backwards against his fixed heel. Treatment was by closed reduction and boot cast for 9 weeks. Painless motion in ankle, subtaloid, and mid-tarsal joints was present 11 months after injury.

Cagnoli (63) discusses the mechanism of fractures of the posterior-superior portion of the os calcis ("duck's bill"), and classifies them as to whether or not impaction is present. If impacted, open reduction is advocated with fixation of the fragments by circumferential suture. A case illustrating above is presented.

#### Complications and Special Procedures

Campbell et al (64) record a case of delayed brachial plexus palsy caused by excessive callus about an old nonunion fracture at the junction of the middle and distal thirds of the clavicle. Initial injury occurred 10 years before onset of symptoms of interosseous weakness, hypoesthesia, and hypalgesia over cutaneous ulnar nerve distribution, and partial obliteration of radial pulse with arm hanging at side. Excision of the fragments and callus leaving the proximal and distal quarters of the clavicle gave relief without loss of function.

Miller (65) reports a case of severe fracture of humerus with arterial spasm of brachial artery relieved by use of intravenous ether-saline solution 3 per cent and papaverine. Details of technique, preparation, and administration are discussed.

Forty cases from the literature and 4 cases of his own of median nerve injury associated with wrist fractures and dislocations are reported by Meadoff (66). Causes, classification, and anatomical considerations are discussed.

A technique for transplanting an intact musculo-spiral nerve through the fissure between bone fragments in open reduction of fractures of mid-shaft of the humerus is described by Schnitker (67). This routes the nerve through a soft tissue bed posterior to the neurovascular bundle.

Compere (68) comments from the literature and presents 5 cases to illustrate avascular necrosis of large segmental fracture fragments of



long bones, emphasizing the prognostic importance, and pointing out that "with good fixation, healing of the fracture will take place before the large fragment has undergone complete replacement by creeping substitution."

The clinicopathologic findings in a 33-year old seaman who sustained a compound, comminuted fracture of the right tibia is reported by Binford and Spriggs (69). He became comatose 14 hours after injury aboard ship and died on the 6th day. Autopsy findings included lipoid material in brain, lungs, and kidney capillaries, along with petechial hemorrhages in skin and conjunctiva which the authors attribute to "fat embolism."

Lambert (70) discusses concepts of bone grafting covering classification, fate of the graft, function, techniques, general principles, and indications and contraindications for bone grafts.

D'Aubigne (71) compares the intramedullary nailing to bone grafting in ununited fractures of the long bones. Bone grafting is preferred in nonunion of more than 6 months duration.



## BIBLIOGRAPHY

1. Kamel Hussein, M.: An ancient Egyptian treatise on traumatology, 2800 B. C., J. Bone Surg., 31 B: 309-12, May 1949
2. Griffiths, D. L., and Brockbank, W.: Orthopaedic surgery in the 16th and 17th centuries; traction apparatus; the Vidian pictures, J. Bone Surg., 31 B: 313-7, May 1949
3. Johnson, H. F., and Stovall, S. L.: Departmental teaching of fractures in the medical schools of the United States, J. Bone Surg., 31A: 202, Jan 1949
4. Hanlon, C. R., Butchart, J. B., and Kempf, P. R.: Injuries in childhood, J. Pediat., S. Louis, 34: 688-98, June 1949
5. Aiken, G. A., Brown, J. B., et al: Symposium on trauma, J. Missouri M. Ass., 46: 701-15, Oct 1949
6. Allredge, R. H., and Banks, T. E.: Principles of emergency splinting, traction, and immobilization of fractures, N. Orleans M. and S. J., 102: 112-9, Sept 1949
7. Wright, P. B.: Emergency treatment of fractures, South. M. J., 42: 687-91, Aug 1949
8. Massart, R.: Le traitement conservateur dans les fractures ouvertes et les grandes ecrasement des membranes, J. prat., Par., 63: 85-7, Feb 24, 1949
9. Girdlestone, G. R.: A regional orthopaedic and accident service, Brit. M. J., 1: 720-2, Apr 23, 1949
10. Nale, T. W.: Standing orders for traumatic cases in industrial dispensaries, Indust. M.: 18: 229-42, June 1949
11. Stinchfield, Frank E.: The principles of traction and suspension in the treatment of fractures, South. M. J., 42: 770-6, Sept 1949
12. Speed, K.: Comminuted and segmental fractures of the leg, Surg. Clin. N. America, 29: 1-13, Feb 1949
13. Winant, E. M.: The use of skeletal traction in the treatment of fractures of the femur, J. Bone Surg., 31 A: 87-93, Jan 1949
14. Mock, H. E., Jr.: Skeletal pinning and external fixation; pros and cons, Am. J. Surg., 78: 29-35, July 1949
15. Fan, K. S.: Fractures of shafts of tibia and fibula with special reference to treatment with two pin traction cast, Chin. M. J., 67: 313-6, May 1949



16. Naden, J. R.: External skeletal fixation in the treatment of fractures of the tibia, *J. Bone Surg.*, 31 A: 586-98, July 1949
17. Paterson, L. T.: External skeletal fixation, *Bull. U. S. Army M. Dep.*, 9: 766-9, Sept 1949
18. Fitts, W. T., Jr., Roberts, B., et al: The effect of intramedullary nailing on the healing of fractures; an experimental study, *Surg. Gyn. Obst.*, 89: 609-15, Nov 1949
19. Townsend, K., and Gilfillan, C.: Open reduction with metallic fixation in man, *J. Am. Vet. M. Assoc.*, 114: 141-3, Mar 1949
20. McLaughlin, H. L., Gaston, S. R., et al: Open reduction and internal fixation of fractures of the long bones, *J. Bone Surg.*, 31 A: 94-101, Jan 1949
21. Haebler, C.: Experiences with the marrow nail operation according to the principles of Keuntscher, *U. S. Nav. M. Bull.*, 49: 423, May-June 1949
22. Rush, L. V., and Rush, H. L.: Evolution of medullary fixation of fractures by the longitudinal pin, *Am. J. Surg.*, 78: 324-33, Sept 1949
23. Bohler, L., and Bohler, J.: Kuntscher's medullary nailing, *J. Bone Surg.*, 31 A: 295-305, Apr 1949
24. Kamel Hussein, M.: Intramedullary nailing, *J. Egypt. M. Ass.*, 32: 512-22, 7 pl., June-July, 1949
25. Kuhlmann, J.: Remarques sin la technique de l'enclouage medullaire, *Bull. Med. Par.*, 62: 525-30, Dec 11, 1948
26. Swynghedauw, Salembier, and Legrand: Resultats d'une serie d'enclouages centro-medullaires, *Echo Med. Nord.*, 19: 251, Oct 1949
27. Kuhlmann, J., and Le Maistre, D.: Le traitement des fractures obliques de l'humerus et du tibia par enclouement medullaire, *Strasbourg med.*, 109: 67-71, Feb 25, 1949
28. Poinot, J.: La place de l'enclouage entromedullaire dans les fractures ouvertes des membres, *J. med. Bordeaux*, 126: 138, Mar 1949
29. Ehrenhaft, J. L., and Tidrick, R. T.: Intramedullary bone fixation in pathologic fractures, *Surg. Gyn. Obst.*, 88: 519-27, Apr 1949
30. Moser, H.: Zur Frage der Nagelung jugendlicher Schenkelhalsbruche, *Wien. klin. Wschr.*, 61: 55-8, Jan 28, 1949
31. Dubecq, X. J., and Marcard, P.: Le probleme de l'immobilisation des fractures du massif facial, *Rev. odont., Par.*, 71: 316, Apr 1949



32. Christensen, R. O.: Compound bilateral fracture of mandible with fatal sequelae; report of a case, *J. Am. Dent. Ass.*, 39: 371, Sept 1949
33. Jones, J. C. B.: On the treatment of unreduced bilateral forward dislocation of temporo-mandibular joint, *Brit. Dent. J.*, 86: 275-8, June 3, 1949
34. Graubard, D. J., and Ritter, H. H.: Isolated fracture of the atlas; report of two cases, *Ann. Surg.*, 130: 261-6, Aug 1949
35. Borsotti, P. G.: Le fratture della clavicola, *Minerva chir. Tor.*, 4: 13-6, Jan 1, 1949
36. Cohen, R. C.: Cough fracture of ribs, *Brit. M. J.*, 1: 133-5, Jan 22, 1949
37. Paulley, J. W., Lees, D. H., and Pearson, A. C.: Cough fracture in late pregnancy, *Brit. M. J.*, 1: 135-7, 135-7, Jan 22, 1949
38. Widen, A.: Fractures of the upper end of humerus with great displacement treatment, *Acta chir. Scand.*, 97: 439-41, Feb 2, 1949
39. Jessing, A.: Behandling af den supracondylaere humerusfractur ved hjalp af Persson's framme, *Ugeskr. laeger*, 111: 419-22, Apr 19, 1949
40. Tondeur, F.: La fracture du condyle externe de l'humerus traitement chirurgical; resultats immediats et eloignes, *Acta. Chir. Belg.*, --: 424-32, Oct 1948
41. Quigley, T. B.: Aspiration of the elbow joint in the treatment of fractures of the head of the radius, *N. England J. M.*, 240: 915, June 9, 1949
42. Patrick, J.: Fractures of the elbow, *Nurs. Mirror, Lond.*, 88: 39, Apr 16, 1949
43. Antila, L. E.: Displacement of an ulnar epicondylar fragment into the joint cavity, *Ann. chir. gyn. fenn.*, 38: 67-75, 1949
44. Knight, Robert, and Purvis, George D.: Fractures of both bones of the forearm in adults, *J. Bone Surg.*, 31 A: 755-764, Oct 1949
45. Stuck, W. G., and Thompson, M. S.: Treatment of fractures of the forearm with intramedullary pins, *Am. J. Surg.*, 77: 12-8, Jan 1949
46. Carothers, R. G., and Boyd, F. J.: Thumb traction technic for reduction of Colles' fracture, *Arch. Surg.*, 58: 848-52, June 1949
47. Rush, L. V., and Rush, H. L.: Longitudinal pin fixation in Colles' fracture of the wrist, *South. Surgeon*, 15: 679-86, Sept 1949



48. Meyer, R.: Treatment of fractured metacarpals, Harefuah, Tel Aviv, 37: 16, July 15, 1949
49. Rodino, D.: Una varieta poco nota di fratture del l'estremo superiore dell'omero, Minerva chir., Tor., 4: 145-8, Mar 1, 1949
50. Goodwyn, T. P.: Fracture problems of the lower extremity, J. M. Ass. Georgia, 38: 443-52, Oct 1949
51. Snedecor, S. T.; and Wilson, H. B.: Some obstetrical injuries to the long bones, J. Bone Surg., 31 A: 378-84, Apr 1949
52. Dawson, G. R., Jr.: Intra-uterine fractures of the tibia and fibula; report of a case with correction by osteotomy and plating, J. Bone Surg., 31 A: 406-8, Apr 1949
53. Patrick, J.: Intracapsular fractures of the femur treated with a combined Smith-Petersen nail and fibular graft, J. Bone Surg., 31 A: 67-80, Jan 1949
54. Fowler, S. B., and Riordan, D. C.: Internal fixation of the femur with the Kuntscher intramedullary nail, South. M. J., 42: 545-51, July 1949
55. Altenberg, A. R., and Shorkey, R. I.: Blade-plate fixation in non-union and in complicated fractures of the supracondylar region of the femur, J. Bone Surg., 31 A: 312-6, Apr 1949
56. Nusselt: Zur Frage der zweckmassigsten Behandlung der unterschenkel-schaftbruche, Chirurg., 20: 92, Feb 1949
57. Stuck, W. G., and Dunlap, K.: End results of treatment of compound fractures of the tibia, Mil. Surgeon, 105: 282-6, Oct 1949
58. Blanco, Pio: Recurrent dislocation of the patella; end results following surgical treatment, N. York State J. M., 49: 169, Jan 15, 1949
59. Schrey, E. L.: Surgical repair of posterior lipping of the tibia, Proc. Inst. M. Chicago, 17: 306, Apr 15, 1949
60. Herzog, E. G.: Malleolar fractures; an inquiry into their mechanism, Lancet, Lond., 2: 52, July 9, 1949
61. La Ferte, A. D.: Fractures, Indust. M., 18: 341-3, Aug 1949
62. Hamilton, A. R.: An unusual dislocation, Med. J. Australia, 1: 271, Feb 26, 1949
63. Cagnoli, H.: La fractura en pico de pato del calcaneo, Bol. Soc. cir. Uruguay, 19: 392, 1948



64. Campbell, E., Howard, W. P., and Burkland, C. W.: Delayed brachial plexus palsy due to ununited fracture of the clavicle, report of a case, J. Am. M. Ass., 139: 91, Jan 1, 1949
65. Miller, R. H.: Use of 3 per cent ether-saline solution as a vasodilator in arterial spasm following a fracture of the humerus; medical aspect, Surgeon Circ. M. Sect., Far East Command, 4: 14-6, May 1949
66. Meadoff, N.: Median nerve injuries in fractures in the region of the wrist, California M., 70: 252-6, Apr 1949
67. Schnitker, M. T.: A technique for transplant of the musculo-spiral nerve in open reduction of fractures of the midshaft of the humerus, J. Neurosurg., 6: 113-7, March 1949
68. Compere, E. L.: Avascular necrosis of large segmental fracture fragments of the long bones, J. Bone Surg., 31 A: 47-54, Jan 1949
69. Binford, C. H., and Spriggs, J. B.: Clinical pathologic conference, Am. J. Clin. Path., 19: 388-92, Apr 1949
70. Lambert, C. N.: Bone Grafts, Surg. Clin. N. America, 29: 77-86, Feb 1949
71. D'Aubigne, R. Merle: A propos du traitement des pseudarthroses des os longs, P. verb. Congr. Soc. internat. Chir. (1947) 1: 12 Congr. 547, 1948



## CHAPTER XV

### FRACTURE DEFORMITIES

By

Ernest A. Brav, Colonel, M. C., U. S. A.

V. H. Jeffress, Colonel, MC, USA	W. D. Sanderson, Capt. MC, USA
A. J. Schoepflin, Lt. Col. MC, USA	J. D. DiMichele, Capt. MC, USA
E. Lindig, Jr., Capt. MC, USA	R. H. Garrett, Capt. MC, USA
F. D. O'Brien, Capt. MC, USA	F. R. Hook, Capt. MC, USA
R. H. Cote, Capt. MC, USA	

#### Treatment of Nonunion of Long Bones

A group of 18 cases of nonunion of fractures of the lower tibia treated by onlay bone grafts is presented by Markin (1). This treatment, based on the original work of Phemister, consists of placing a cortical tibial bone graft on the lateral surface of the tibia over the nonunion site after subperiosteal exposure. This is done without metallic fixation and without breaking down the fibrous union which is present. Two failures are cited, one due to early unauthorized weight bearing by the patient and the other due to infection.

Full thickness skin flaps afford the most satisfactory cover after limb injuries with loss of skin and subcutaneous tissue, according to Braithwaite and Moore (2). They stress the importance of replacing unstable and scarred skin prior to attempting bone reconstruction. The cross-leg flap technique is recommended in the foot and leg except in children, young women, and the aged. Delayed transfer of the flap, free excision of avascular scar tissue and plaster immobilization of the limbs are advised.

According to Wickstrom (3), replacing of scarred and devitalized tissue over an area of nonunion of the long bones is essential prior to bone grafting. Seven cases, illustrating the need for careful evaluation of cicatricial defects over operative sites that require deep surgical repair, are presented. The author recommends the most direct method possible of transferring a flap, individualizing each case.

One hundred twenty-six cases of nonunion of the long bones treated by different methods together with their end results are presented by D'Aubigne (4). The majority of the cases were war wounds, many of them with large bone defects and severe infections. The use of the following methods, (1) intramedullary nails, (2) tibial grafting, and (3) cancellous bone, is discussed. The results of the various methods displayed are given in tabulated form.

Sherrill (5) presents a preliminary report of 18 cases of delayed or nonunion of fractures of long bones treated by chip bone grafts from the ilium of the tibia combined with Kuntscher nail immobilization. The



technique of operation is discussed. The author states that excellent results have followed this method of treatment.

In a review of his experience in 126 bone grafting procedures, largely done in a military hospital, Horwitz (6) concludes that cancellous bone is superior to cortical bone as a graft, because of greater rapidity and efficiency of revascularization. It cannot be used alone at mid-shafts of long bones and other areas where the features of cortical bone are needed for strength. The author cautions against the failure to consider the "weak period" during the time the graft is undergoing resorption, which he observed to be as long as 18 months, but usually noted at 2 to 3 months. In infected gunshot fractures, it is recommended that 8 months should have elapsed since the last drainage before bone grafting is attempted.

In cases of pseudarthrosis following gunshot fractures, Demel (7) recommends utilization of the "splintering" method originated by Kirschner in 1929. In using this method the false joint is adequately exposed without disturbing the periosteum. The ends of the bone adjacent to this false joint are then splintered by use of a chisel directed in a longitudinal direction. The operative procedure is followed by plaster immobilization. The author feels that the chief advantage of this method is that there is less danger of infection than when using a free autogenous bone graft.

#### The Use of Bank Bone Grafts

Weaver (8) reports the results of 49 consecutive operations of various types on 46 patients employing frozen, homogenous bank bone. The bone was obtained from patients at operation or from fresh cadavers. A number of case histories illustrating both favorable and unfavorable results are included. The general impression was that the results in bank bone grafts are highly encouraging.

Reynold and Oliver (9) present a preliminary report on the use of homogenous bone grafts preserved in aqueous merthiolate solution. The report presents the findings in 42 consecutive bone graft operations of various types and concludes that early results obtained with grafts of this type compare favorably with autogenous grafts under similar circumstances.

#### Treatment of Nonunion of Femoral Neck Fractures

A thorough analysis of the cause of failures in fractures of the hip is discussed by Schneider (10). The various types of hip fractures (impacted abduction fractures, extracapsular fractures, and cervical fractures without impaction) are considered individually and causes of failures are listed. According to Schneider, impacted abduction fractures should first be recognized and should then be treated conservatively without surgical intervention. Extracapsular fractures invariably heal but anatomic reduction and firm internal fixation and guarded postoperative care are requisites for successful treatment. Cervical unimpacted fractures are by far the most difficult group to treat because of mechanical and biological problems. The problem of union increases progressively as the plane of the fracture approaches the head and inclines from the horizontal to the vertical.



The blood supply of the femoral head is greatly disturbed by the initial displacement of the fragments. Therefore, early and accurate reduction of these fractures is essential and adequate internal fixation must be accomplished. Metallic fixation must sometimes be augmented by a tibial or fibular bone graft. Even under most favorable conditions, failures are encountered because of the initial damage to the blood supply with subsequent avascular necrosis of the head of the femur. Nonunion with or without death of the femoral head is still encountered in one-fourth of these cases. Schneider emphasizes the importance of the general care of the patient with a fractured hip and the necessity for evaluation and treatment of constitutional diseases in order to avoid medical complications.

Storen (11) presents a classification of types of pseudarthrosis of the femoral neck and describes the various types of treatment including osteosynthesis, bone grafting with or without osteotomy, intertrochanteric osteotomy and the Brackett operation. He then describes his operative method which consists of extensive removal of connective tissue of the pseudarthrosis through a wide canal in the trochanter, followed by insertion of a cancellous iliac graft through the neck into the head. An intertrochanteric osteotomy then secures a favorable angle of the neck. This operation, which the author has performed on only four cases, must await further evaluation.

#### Corrective Operative Procedures

Foley (12) describes an operation for ischio-femoral extra-articular arthrodesis of the hip joint by the posterior open approach based on the techniques of Trumble and Brittain. The operation has the advantage of affording adequate exposure of the sciatic nerve and bone grafting under direct vision. The operation was performed on 19 cases, mostly tuberculosis of the hip, with only one failure.

A report of 10 arthrodeses of the ankle joint performed because of paralytic deformities, traumatic arthritis, and osteomyelitis is made by Hiestand (13). The technique used was that of excision of the entire articular cartilage of the upper surface of the astragalus and the lower tibia and fibula. A cortical bone graft taken from the lower tibia was placed over the anterior aspect of the joint between the tibia and astragalus. Bone fusion was obtained in 9 of the 10 patients and functional use of the foot was improved in all 10 cases.

Stinchfield and Carroll (14) review 45 cup arthroplasties of the hip with follow-up studies averaging 3 years. While the authors draw no definite conclusion from this small series, they observed that 70 per cent of patients were relieved of pain. There was a definite period postoperatively during which the range of motion increased and flexion deformity decreased. This occurred, in general, between the second and third postoperative years. Following this, the reverse trend was observed. The best results occurred in those patients having slipped femoral epiphyses. No explanation for this is offered.



Lucas and Cattrell (15) describe a new type of notched osteotomy of the tibia that they have employed in 25 cases. An M-shaped osteotomy is made through about two-thirds of the circumference of the tibia across its upper portion. By twisting the bone at its osteotomy site a green-stick fracture is accomplished. The lower fragment is then twisted outward in such a manner as to engage the point of the most medial projection of the M of the distal fragment into the lateral notch of the proximal fragment. The advantages cited for this method are: (1) the engagement is firm, (2) there is no problem holding the leg while the cast is being applied, and (3) fast healing at the osteotomy site. The authors recommend this procedure for correction of torsion of tibia in cases of congenital club-foot. The method may also be used for osteotomy of (1) the upper femur for congenital dislocation, (2) supracondylar region of the femur for genu valgum and supracondylar region of the humerus for cubitus varus deformity.

A method of subtrochanteric limb shortening with fixation by the use of a specially designed trochanteric plate and a Smith-Petersen nail is described by Thornton (16). The article is well illustrated by diagrams and roentgenograms.

A summary and brief discussion of the principles of open reduction and internal fixation for fractures of the tibia and ankle are presented by McLaughlin and Ryder (17). The prerequisites, timing of operation, indications, technique and postoperative management are discussed. The article is well illustrated with diagrams.

#### Unusual Case Reports

Sabaino (18) reports 5 cases of localized osteomalacia of the carpal lunate secondary to old undiagnosed or inadequately treated fractures. The clinical and radiological aspects are discussed and the relation to Kienbock's disease is emphasized. It is pointed out that Kienbock's necrosis is classically described as following trauma to the wrist other than fracture and that fractures seen in this condition are generally thought to be a secondary manifestation.

An unusual case of ununited fracture of the tibial spine is reported by Guttman (19). There was overgrowth of the ununited fragment over a period of 8 years and eventual blocking of the last 15 degrees of extension. The patient was treated by surgical excision with complete relief.

A case of nonunion of a fracture of the mid-shaft of the right femur in a 37-year old male is presented by Walley (20). The case was considered a curiosity, in that although there was nonunion clinically and radiographically and 4-1/2 inches shortening, the patient could "stand on the right leg unsupported for periods of minutes on end."

#### Medicolegal Problems

According to Hawkinson (21), it is apparent that there have often been



gross discrepancies in the evidence given by so-called medical experts in medicolegal cases. Individuals who offer a personal service to the public should undergo constant self-examination of the most critical kind to determine whether or not they are rendering the best service. It is no longer possible for one individual to consider himself a medical expert in all the fields of medicine and yet this has happened frequently in the past. State control of the evidence in medical testimony could do a great deal in doing away with much of the irregular testimony but as yet most states have not attempted to do this. It is up to both the medical and legal professions to tactfully police their own memberships.

Hammes (22) states that since July, 1940, the State of Minnesota has had a committee on medical testimony consisting of six members to review the court cases in which medical testimony appeared to have been so contradictory as to indicate that one or more of the medical witnesses was consciously deviating from the truth. After reviewing the entire testimony in a case, the committee may call upon additional specialists for their opinions regarding the testimony in question. The committee itself has no judicial or disciplinary power but it can submit a complete report of its findings to the State Board of Medical Examiners who have the power to revoke the State licenses. At the end of 8 years with this plan, all indications are that the reliability of expert medical testimony has been materially improved and that it has done away with many of the abuses noted in the past.



## BIBLIOGRAPHY

1. Markin, L.: Onlay bone grafts without fixation, Proc. Inst. M., Chicago, 17: 360, June 15, 1949
2. Braithwaite, F., and Moore, F. T.: Skin grafting by cross-leg flaps, J. Bone Surg., 31 B: 228-35, May 1949
3. Wickstrom, O.: Plastic repair of surface defects in preparation for bone grafting, U. S. Nav. Bull., 49: 736-43, July-Aug, 1949
4. D'Aubigne, R.: Surgical treatment of nonunion of long bones, J. Bone Surg., 31 A: 256-66, Apr 1949
5. Sherrill, J. D.: Use of chip bone graft in long bones: a preliminary report, Jefferson Hillman Hosp. Bull., 3: 107-14, July 1949
6. Horwitz, T.: The behavior of bone grafts, Surg. Gyn. Obst., 89: 310-16, Sept 1949
7. Demel, R.: Treatment of gunshot fractures with false joint by Kirschner's splintering method, P. Verb. Congr. Soc. Internat. Chir. 12: 527-541, 1948
8. Weaver, J. B.: Experiences in the use of homogenous (bone bank)bone, J. Bone Surg., 31 A: 778-92, Oct 1949
9. Reynolds, F. C., and Oliver, D. R.: Clinical evaluation of the merthiolate bone bank, J. Bone Surg., 31 A: 792-99, Oct 1949
10. Schneider, C. C.: An analysis of the causes of failures in fractures of the hip, Wisconsin M. J., 48: 733-39, Aug 1949
11. Storen, H.: A contribution to the treatment of pseudarthrosis of the femoral neck, Acta orthop. scand., 19: 125-33, 1949
12. Foley, W. B.: Ischio-femoral arthrodesis of the hip by posterior open approach, J. Bone Surg., 31 B: 222-26, May 1949
13. Hiestand, H. B.: Arthrodesis of the ankle joint, Am. J. Surg., 78: 36-39, July 1949
14. Stinchfield, F. E. and Carroll, R. D.: Vitallium cup arthroplasty of the hip joint; an end result, J. Bone Surg., 31 A: 628-38, July 1949
15. Lucas, L. S., and Cattrell, G. W.: Notched rotation osteotomy; a method employed in the correction of torsion of the tibia and other conditions, West J. Surg., 57: 5-8, Jan 1949



16. Thornton, L.: A method of subtrochanteric limb shortening, *J. Bone Surg.*, 31 A: 81-6, Jan 1949
17. McLaughlin, H. L., and Ryder, C. T., Jr.: Open reduction and internal fixation for fractures of the tibia and ankle, *Surg. Clin. N. America*, 29: 1523-34, Oct 1949
18. Sabaino, D.: La malacia dell' osso semilunare del carpo secondaria a frattura, *Minerva chir.*, Tor., 4: 48-53, Jan 15, 1949
19. Guttman, A. P.: Fractures of the tibial spine with a case of overgrowth of the ununited fragment, *J. internat. Coll. Surgeons*, 12: 541-44, July-Aug, 1949
20. Walley, G. J.: Ununited 9-year old fracture of the mid-shaft of the femur, *Proc. Royal Soc. Med.*, Lond., 42: 279, Apr 1949
21. Hawkinson, O.: The pseudo-medical expert witness, *J. Omaha Clin. Soc.*, 10: 71-12, Jan 1949
22. Hammes, E. M.: Eight years experience with the control of medical testimony; the Minnesota plan, *J. Omaha Clin. Soc.*, 10: 13-17, Jan 1949



## CHAPTER XVI

### CONDITIONS INVOLVING THE KNEE JOINT

By

Robert D. Anderson, Colonel, M. C., U. S. A.

Assisted By

Alfred O. Heldobler, Major, M. C., U. S. A.

Robert Leake, 1st Lt. MC, USA, and J. R. McDonald, 1st Lt. MC, USA

#### General

An eighteen-page article by Lewin (1) takes up "the knee joint" more or less completely from a short discussion on its mechanics to a more complete consideration of the various disturbances that may affect this joint. The method of history taking and examination are thoroughly outlined and the differentiation of injuries, infections, arthritis, neoplasms, synovitis and osteochondritis. As an example, his description of the lesions of the fat pad includes a discussion of (1) Hoffa's lesion, (2) lipoma arborescens, (3) contusion, and (4) hypertrophy of the fat pad. Conservative and surgical treatment is considered.

McKelvey (2) divides internal derangements of the knee into congenital, traumatic, and pathological derangements for discussion and reviews the whole subject from etiology to treatment, and Voshell (3) and Mitchell (4) give practical reviews of the diagnosis and treatment of numerous occurrences about the knee.

Stack (5), (6) discusses synovitis, fat pad hypertrophy, chondromalacia of the patella and postmenisectomy pain. The latter may be due to quadriceps atrophy, genu valgum, overweight, or instability.

Mathur and Ghormley (7) studied tensile strength of dog menisci and found medial menisci tear more readily than the lateral ones.

#### Congenital

McCough and Deering (8) indicate that tendon spicules of the vastus intermedius could inhibit knee jerks.

Oeconomos (9) reviews causes and treatment of congenital dislocation of the patella and reports a case with genu valgum in which he transplanted the patella medially and obtained good results.

#### Pathologic

Microscopic studies of the synovial membrane by Soeur (10) reveal three



responses of synovial cells to irritants and three irritant conditions. The responses are: (1) Synovial activity which means an increase in the number of folds and villi, multi-stratification of the intima, and hyper-vascularization, (2) Fibrosis, and (3) Infiltration which includes multiplication of free cells. The three irritant conditions are: (a) Meniscal tears in which synovial activity is marked at the onset, but subsides after 6 months. Fibrosis is the predominant element. (b) Effusions of blood in which the synovial activity is immediate, intense, and is limited to the intima. There is no fibrosis and the infiltration of the intima is acute. The condition is not progressive and the synovial membrane becomes normal. (c) Synovial arthritis in which synovial activity is intense and generalized. The infiltration is either diffuse or in the form of nodules. Fibrosis is a secondary element. The author believes, from these studies, that in the future it will be possible to establish a diagnosis through a biopsy of the infrapatellar fat pad.

Synovial osteochondromatosis is discussed by Huguenin et al (11), and Leydig and Odell (12). It is derived from the undifferentiated synovium and grows, thereby, not unlike a benign tumor. Infection seems to play a role in its occurrence and it is found in tertiary syphilis and tabetics. The absence of changes in bone or on articular surfaces refutes a theory of traumatic causation. Surgical synovectomy is advised for treatment.

Osteochondritis dissecans of both patellae in a 16-year old boy is reported by Kleinberg (13). There was no history of antecedent illness or trauma. The author states that this condition as a bilateral lesion of the patella is rare, but not unknown.

Chondromalacia patellae and our present knowledge of it is summarized by Sideman et al (14). The article adds nothing of newer knowledge concerning this condition but is an excellent compilation of present trends of thought regarding etiology, diagnosis, and methods of treatment.

Osteoarthritis of the knee is considered by Bach (15) in association with inefficient circulation of the lower extremities. He advocates bandaging the lower extremity and exercising to increase muscle power.

Tuberculosis of the knee with negative laboratory findings is discussed by Blankoff (16) and 10 cases are reported in which the other possible differential diagnoses did not coincide with clinical, x-ray, and gross pathological appearances. Skin tests, cultures, and histology were in all cases negative for tuberculosis. In the author's experience this occurs in 10 per cent of the cases.

Salmonella infection in the knee of a child is reported by Gordon et al (17).

Rheumatoid arthritis of the knee is noted for its high incidence of flexion contractures. Hill et al (18) obtained good results in over 90 per cent of their cases using rest, exercises, and casts.

Charcot's joint in a diabetic patient is reported by Wilson et al (19).



Osgood-Schlatter's disease is discussed on the basis of present knowledge by Echeverri et al (20). They report best results with conservative treatment consisting of rest in bed followed by repeated novocain infiltration.

Calcification of the bursae of the knee is felt to be related to decreased circulation by Norley and Bickel (21). Eight cases seen in the Mayo Clinic are the basis of discussion of etiology, symptoms, and treatment. They advise that procaine be tried before excision is done.

Luck and Smith (22) report a compilation of knee operations performed at certain Army Air Force Hospitals during World War II. The series includes a total of 1,411 cases of internal derangement of the knee. Meniscectomy was the most frequently performed operation. Causes of meniscus lesions were listed as intrinsic and extrinsic. Of the intrinsic causes, poor cartilage, poor knee mechanics and unstable ligaments are important. Of the extrinsic causes, trauma, hyperflexion or hyperextension, and muscle imbalance, are listed. Treatment, generally, was more radical when the lesions were incurred in line of duty. It was noted that rehabilitation to full duty was less successful in long-standing cases. The use of two capsular incisions gained favor during the war. Cysts of the menisci were encountered in 59 cases. Of these, the lesion was in the medial meniscus in four. Chondromalacia of the patella and femur were repeatedly observed. Results from meniscectomy for uncomplicated lesions of the meniscus were good. The second highest incidence was loose bodies. Osteochondritis dissecans of the femoral condyle and the patella accounted for at least half the loose bodies. Chondromalacia of the patella was treated as conservatively as possible. Poor results were generally obtained on surgical treatment of ruptured ligaments of the knee and conservative policy was adopted.

Cysts of the semilunar cartilages by Brav (23) is a discussion of the frequency, etiology, symptoms, pathology, and treatment. Removal via two capsular incisions is advocated.

Fractures of the tibial spines or so-called cruciate ligament fractures are the subject of a dissertation by Bradford et al (24). The cruciate ligaments attach to a cartilaginous area proximal to the tibial spine. Methods of closed reduction and of operative repair are described. Meyerding et al (25) describe a technic of internal fixation of the anterior tibial spine with a screw.

Osteochondral fracture of the patella in a 16-year old boy is reported by Batchelor (26). Following a slight fall, x-ray revealed two loose bodies in the knee. At surgery they were found to have come from the inferior part of the articular surface of the patella. The fracture is believed to have been produced, as described by Coleman (27), by the tangential force applied by the pull of the quadriceps after a subluxation of the patella over the lateral condylar ridge of the femur.

(28)

Fractures of the patella are reviewed by Scott and Noyes (29). Emphasis is placed on the importance of capsular repair. Immobilization is relatively short and comminuted fragments are removed.



Fractures of the lateral tibial condyle are discussed by Haggart (30) who states that Barr's indications for exploration should be followed (if more than 1/4th inch of displacement). In extensive, bursting types of injuries where no operative procedure is advisable, traction is employed. The importance of re-aligning the fractured joint is stressed.

Fracture of the medial condyle of a tibia into a neuropathic joint is reported by Tucker (31).

Penetrating wounds of the knee are presented by Hendry (32) who studied 83 cases sustained by British personnel in Burma. There is considerable evidence that the passage through the cancellous bone of femoral or tibial condyles of a missile moving sufficiently fast not to be retained produces cell death over a wide area, and that x-rays taken in the first few weeks after wounding show much less bone damage than has actually taken place. The dire effects of infection in penetrating gunshot wounds are due not only to the presence of cavities in the bone, but also to the presence on either side of the joint of two large masses of cancellous bone which can be extensively devitalized by high velocity missiles. Infection of such a wound requires the widest possible drainage and it is suggested that the heavily infected knee is best drained by two parapatellar incisions with division of the internal collateral ligament, and immobilization of the joint in valgus. In uninfected cases, results are likely to be better if weight bearing is avoided until the density of the infected condyle has returned to normal.

Cannon and Trott (33) advocates expeditious use of direct flaps in extremity repairs. The donor site is covered with an immediate split thickness graft. As much scar tissue as possible should be excised from recipient site in order to give a good bed, and tendons should be sutured to the subcutaneous fat of the pedicle graft in order to avoid sloughing.

A case of traumatic genu recurvatum resulting from a deficiently developed femoral condyle is reported by Trevor (34).

Repair of rupture of the quadriceps tendon is described by Michele and Krueger (35). After a mattress suture is placed on the proximal stump of the tendon, the tongue is retracted distally and sutured into a transverse groove of the patella. Fascial repairs do not seem to work as well.

A case of dislocation of the gracilis tendon and its treatment by fixation to the semimembranosus tendon is reported by Bleuler (36).

#### Technic and Apparatus

A review and profitable description of practical approaches to the knee joint is written by Shipp (37). Exposure of the entire knee joint is advocated through a Coonse and Adams approach to the knee where the patella is reflected distally. The medial approach is done through a Fisher "U-shaped" incision with vertical incisions through the capsule anterior and posterior to the medial collateral ligament.

The problem of postarthrotomy effusion is discussed by Chandler (38)



and various forms of control, such as arthrocentesis and loosely suturing the synovial membrane are mentioned. The author suggests establishing a drainage tract through the apex of the suprapatellar pouch by inserting a forceps through, into the deep intermuscular plane. Early joint movement will "milk" the joint fluid into the intermuscular spaces where it can be easily absorbed.

Arthroplasty of the knee is the subject of an article by Speed and Trout (39) and a less informative one by Samson (40). It is emphasized that the cases must be carefully selected. Indications for arthroplasty of the knee are fibrous or bony ankylosis due to: (1) Acute infectious arthritis, (2) Suppurative arthritis from wounds, or (3) Traumatic arthritis without infection. Contraindications are: (1) Multiple rheumatoid arthritis, (2) Tuberculosis, (3) Osteomyelitis, (4) Obesity, and (5) Osteoporosis. The surgical treatment emphasizes the use of the Campbell technic, the fundamental principles being: (1) The construction of the simplest type of hinged joint with single broad femoral tibial condyle, and without trying to form a tibial spine or wedge to fit between the femoral condyle, (2) Disturb the extension apparatus as little as possible, (3) Remove sufficient bone from the posterior parts of the femoral condyle to permit free movement, (4) Never do a hemi-arthrotomy, (5) A fascial covering over the femoral condyle seems to aid, and (6) Preserve wide weight-bearing surface and ligamentous and muscular support. The results of the former series of 65 cases were good or fair in 70 per cent. It was discovered in the follow-ups that the major functional adaptation of the knee joint takes place within the first five years following surgery.

Positive pressure arthrodesis after the method of Key is described by Vesely (41) using Steinmann pins and turnbuckles.

An ankylosed knee which made functional use of a femoral pseudarthrosis is reported by Batch and Fontneau (42). There was no pain in the region of the false joint which was supracondylar level. He had complete extension and flexion to right angles and was able to walk moderate distances with the aid of a cane.

The surgical treatment of elephantiasis is reviewed by Blocker (43). He favors the Poth modification of the Macey technic where the tissues are excised and calibrated grafts used to cover the sites.

A new instrument is described by Dunlap and Stuck (44) for the removal of the semilunar cartilage. The knife is designed to cut around the periphery of the attachment of the cartilage and the posterior horn is cut with Turbinate knife. The entire cartilage is said to be removed. The knife is copied after that of Lowe and Breck. The curved Jones incision is advocated for better visualization.



## BIBLIOGRAPHY

1. Lewin, P.: The knee joint, J. Internat. Coll. Surgeons, 11: 604-22, Nov-Dec, 1948
2. McKelvey, G. J.: Internal derangement of the knee, Portland Clin. Bull., 2: 69-82, Mar 1949
3. Voshell, A. F.: Some injuries of the knee joint, Med. Ann. District of Columbia, 18: 512-15, Oct 1949
4. Mitchell, W. R. D.: Injuries round the knee joint, Mod. Treatm. Yearb. Lond., 1: 51-61, 1948
5. Stack, J. K.: The injured knee; the negative x-ray, Indust. M., 18: 91-4, Mar 1949
6. Stack, J. K.: Lesions of the knee; clinical versus x-ray diagnosis, Q. Bull. Northwest. Univ. M. School, 23: 386-90, Fall, 1949
7. Mathur, P. D., McDonald, J. R., and Ghormley, R. K.: A study of the tensile strength of the menisci of the knee, J. Bone Surg., 31 A: 650-4, July 1949
8. McCough, G. P., Deering, I. D., et al: Inhibition of the knee jerk from tendon spindles of crureus, Am. J. M. Sc., 217: 587-, May 1949
9. Oeconomos, D.: Les luxations congenitales de la rotule, Bull. med. Par., 62: 477-84, Nov 11, 1948
10. Soeur, R.: The synovial membrane of the knee in pathological conditions, J. Bone Surg., 31 A: 317-40, Apr 1949
11. Huguenin, A.; Charles and Venezia: Osteochondromatose des synoviales des genoux, Algerie, med., 51: 550-2, Dec 1948
12. Leydig, S. M., and Odell, R. T.: Synovial osteochondromatosis, Surg. Gyn. Obst., 89: 457-63, Oct 1949
13. Kleinberg, S.: Bilateral osteochondritis dissecans of the patella, J. Bone Surg., 31 A: 185, Jan 1949
14. Sideman, S., Glassman, F., and Wolin, I.: Surg. Clin. N. America, 29: 261-7, Feb 1949
15. Bach, F.: Osteoarthritis of the knee; notes on the principles of Bisgaard in treatment, Brit. J. Phys. M., 12: 124-6, Sept-Oct, 1949
16. Blankoff, B.: A propos de cas de tumeurs blanches du genou avec response negative de laboratoire, Scalpel, Brux., 102: 1, passim. Jan 1949
17. Gordon, H. S., Hoffman, S. J., et al: Serous arthritis of the knee



joint; report of a case caused by *Salmonella typhosa* and *Salmonella montevideo* in a child, *J. Am. M. Ass.*, 141: 460, Oct 15, 1949

18. Hill, D. F.: Holbrook, W. P., et al: Knee contractions in rheumatoid arthritis, *Ann. Rheumat. Dis. Lond.*, 7: 253, Dec 1948
19. Wilson, I. H., McIntyre, C. H., and Albertson, H. K.: Charcot's joint, with unusual features in a diabetic patient, *California M.*, 70: 420-2, May, 1949
20. Echeverri, A. J., and Quintans, Pardo, A.: Enfermedad de Osgood-Schlatter, *Galicia clinic.*, Coruna, 21: 1-11, Jan 1949
21. Norley, T., and Bickel, W. H.: Calcification of the bursae of the knee, *J. Bone Surg.*, 31 A: 417-20, Apr 1949
22. Luck, J. V., Smith, H. M. A., et al: Orthopedic surgery in Army Air Forces during World War II; introduction and internal derangements of the knee, *Arch. Surg.*, 57: 642-74, Nov 1948
23. Brav, E. A.: Cysts of the semilunar cartilages of the knee joint, *Mil. Surgeon*, 105: 278-82, Oct 1949
24. Bradford, C. H., Adams, R. W., and Magill, H. K.: Fractures of the tibial spines, *N. England J. M.*, 241: 137-41, July 28, 1949
25. Meyerdig, H. W., and Walsh, A. C.: Avulsion fracture with nonunion of the anterior tibial spine treated by fixation with beef-bone screw; report of a case, *Surg. Clin. N. America*, 29: 1029-33, Aug 1949
26. Batchelor, J. S.: Osteochondral fracture of the patella, *Proc. R. Soc. M., Lond.*, 41: 853, Dec 1948
27. Coleman, H. M.: Recurrent osteochondral fracture of the patella, *J. Bone Surg.*, 30-B: 153, Feb 1948
28. Scott, J. C.: Fractures of the patella, *J. Bone Surg.*, 31 B: 76-81, Feb 1949
29. Noyes, M. B., and Mozden, W. S.: Fractures of the patella, *Am. J. Surg.*, 77: 215-19, Feb 1949
30. Haggart, G. E., and Clemmons, H. M.: The surgical treatment of fractures of the lateral tibial condyle, *Surg. Clin. N. America*, 29: 893-903, June, 1949
31. Tucker, W. E.: Neuropathic joint showing a fracture of the lower end of the right femur and internal condyle of the right tibia both involving the knee joint, *Proc. R. Soc. M., Lond.*, 42: 600, Aug 1949
32. Hendry, N. G. C.: Penetrating wounds of the knee; *J. R. Army M. Corps*, 92: 55-76, Feb 1949



33. Cannon, B., and Trott, A. W.: Expeditious use of direct flaps in extremity repairs, *Plastic & Reconstr. Surg.*, 4: 415-9, Sept 1949
34. Trevor, D.: Traumatic genu recurvatum, *Proc. R. Soc. M., Lond.* 42: 599, Aug 1949
35. Michele, A. A., and Krueger, F. J.: Rupture of the quadriceps tendon, *Mil. Surgeon*, 105: 292-4, Oct 1949
36. Bleuler, R.: Ueber einen Fall von habitueller Luxation der Gracillissehne; Beitrag zum Proplem des schnellenden Knies, *Helvet chir. acta*, 15: 462-75, Dec 1948
37. Shipp, F. L.: Arthrotomy of the knee joint, *Surg. Clin. N. America*, 29: 913-21, June 1949
38. Chandler, F. A.: Closed drainage of the knee joint following arthrotomy, *J. Bone Surg.*, 31 A: 580, July 1949
39. Speed, J. S., and Trout, P. C.: Arthroplasty of the knee; a follow-up study, *J. Bone Surg.*, 31-B: 53-60, Feb 1949
40. Samson, J. E.: Arthroplasty of the knee joint; late results, *J. Bone Surg.*, 31 B: 50-2, Feb 1949
41. Vesely, D. G.: Positive pressure arthrodesis of the knee, *Jefferson Hillman Hosp. Bull.*, 3: 129-36, July 1949
42. Batch, J. W., and Fontneau, N. C.: A case of functional utilization of femoral pseudarthrosis in the presence of ankylosis of the knee, *Bull. U. S. Army M. Dep.*, 9: 235-40, Mar 1949
43. Blocker, T. G., Jr.: Surgical treatment of elephantiasis of the lower extremities, *Plastic and Reconstr. Surg.*, 4: 407-14, Sept 1949
44. Dunlap, K., and Stuck, W. G.: Excision of the semilunar cartilage, *Bull. U. S. Army M. Dep.*, 9: 484-7, June 1949



## CHAPTER XVII

### CONDITIONS INVOLVING NECK, SHOULDER, AND ARM

By

M. S. Thompson, Colonel, M. C., U. S. A.

J. D. Blair, Colonel, MC, USA	S. F. Moorehead, Capt., USAF (MC)
J. K. Tillotson, Lt. Col., MC, USA	T. N. Nicholas, Capt., MC, USA
L. O. Travis, Lt. Col., MC, USA	M. G. Veal, Capt., MC, USA
G. L. Long, Lt. Col., MC, USA	B. D. King, Capt., MC, USA
G. H. Chambers, Major, USAF (MC)	L. P. Kleuser, 1st Lt. JG, USN (MC)

#### Anatomical

A minute study of the sensory pathways from the shoulder joint is presented by Wrete (1) (2) based on serial sections of three human fetuses previously impregnated with a silver nerve stain. The nerves were followed and reconstruction charts made. He found that the joint receives 9-12 articular branches from the axillary, suprascapular, musculocutaneous and subscapular nerves, representing spinal segments C-4 through C-7. Both segmental and post-ganglionic sympathetic fibers from the 3 cervical ganglia are present. The author concludes that almost all of the articular sensory nerve supply is so situated that it can be surgically interrupted without sacrificing motor tracts.

An article by Hadley (3) discusses the pathology that may be seen by various x-ray views of the cervical spine. Oblique views best demonstrate foramina, the narrowing of which gives nerve root irritation. The P-A chewing technic demonstrates alignment of spinous processes, thickness of disks, and the posterior articulations whose interpedunculate distance represents the size of the foramina.

Bocklage (4) reviews the principles of x-ray technic to blur out superimposed shadows by shortening focal distance and breathing with long exposure time. He illustrates a postero-anterior bilateral articulation.

Jit and Shah (5) record measurements on 80 axis and atlas vertebrae of Punjabees. Among other anthropologic details, they found the axis bones not as short as in the aborigines of Australia.

#### General

The association of the shoulder-hand syndrome with heart disease evoked papers by Hilker (6), and Frame, Ropes, et al (7). Reflex dystrophy of an extremity as a sequel to trauma has been known at least 70 years, but only recently as a sequel to herpes, osteoarthritis, hemiplegia and heart disease. The two papers are based on 12 cases, 9 of which followed severe myocardial infarction, 2 angina and 1 rheumatic valvular heart disease. As heart function improves, the syndrome improves. In the first stage, the hand is hot, discolored, and painful. In the second stage, the swelling subsides but pain and stiffness persist. In the last stage, there is a claw hand with shortening of tendons and fascia and trophic changes in muscles and bones, and it is not reversible. The etiology is not known



but two hypotheses are offered: (1) sympathetic impulses from heart via internuncial pool to anterior horn cells or sympathetics of extremity, (2) anoxia due to hypotension possibly perpetuates the condition. Lymphoma with involvement of the spinal cord is one of the things that must be ruled out.

Seven articles entitled "The Painful Shoulder" have been abstracted. Withers (8) reviews 100 cases with negative x-rays and recognizes three causes: (1) rupture of the supraspinatus, partial and complete, as distinguished by arthrograms with radio-opaque material, (2) supraspinatus tendinitis caused by forceful contraction between 80 degrees and 100 degrees abduction and resulting in mechanical irritation, and (3) capsulitis, an inflammatory thickening later becoming adhesive.

Harrison (9) defines degenerative changes as being irregularity in the cortical bone of the greater tuberosity, erosion of bone from the articular surface of the humeral head, loss of the normal outline of the anatomical neck, cystic cavitations and areas of sclerosis. The term "degenerative" is used because the x-ray findings are shown to be associated with degeneration in the overlying tissues. In injuries to the shoulder in the presence of degenerative changes, convalescence can be expected to be prolonged.

Armstrong (10) describes (1) frozen shoulder (periarthrititis or capsulitis), (2) supraspinatus syndrome characterized by pain in mid-abduction includes (a) tendinitis, traumatic, 57 per cent, (b) calcification, 16 per cent, (c) minimal tears near tendon insertion, 15 per cent, and (d) changes secondary to subacromial bursitis, 11 per cent. (3) sequelae of traumatic synovitis (posttraumatic stiffness) due to organization of inflammatory exudate.

Nachlas (11) describes the effect on nerve roots of sprains, fractures, degenerative and rheumatoid arthritis and even normal motions of the intervertebral foramina.

Somerville-Large (12) considers the differential diagnosis of shoulder pain in two groups: (1) referred pain from (a) intrathoracic disease, tumors, lung, heart, (b) cervical nerve root affections, traction, pressure, disk, syringomyelia, cord tumors, tuberculosis, spondylitis, and (c) brachial plexus lesion; and (2) shoulder joint lesions causing pain as (a) the acromioclavicular joint, arthritis, ankylosis, (b) the subacromial bursa, injury or infection, (c) rupture of musculo-tendinous capsule, trauma, degeneration, (d) calcification of supraspinatus tendon, and (e) rupture of the biceps tendon and subscapularis. Four x-ray views are suggested - (1) mid-position, (2) internal rotation, (3) external rotation, and (4) external rotation with body twisted the same way.

Hedges (13), Noble (14), Alexander (15), Stamm (16), and Savage (17) summarize our present knowledge of the painful shoulder.

#### Cervical

Fractures and dislocations of the cervical spine are on the increase



writes Edmunds (18). When an auto stops suddenly, the head keeps going and then snaps back, giving the most frequent injury (the "whip lash" injury). This may cause a transient dislocation with severe cord injury and negative x-rays. The second important cause is diving. He summarizes four points of treatment (1) protect cord, (2) x-rays, (3) traction, (4) perhaps manipulation, and three types of fractures: (1) compression fracture, (2) crush fracture, with and without dislocation, (3) pedicle, axis, and odontoid fractures. If paraplegia is complete, he advocates tidal drainage immediately. If Queckenstedt test indicates a block and skeletal traction does not correct it, he believes a laminectomy should be done at once. If there is no block, there is no indication for laminectomy.

Treatment of fracture-dislocation by internal fixation is recommended by Kenny (19) because it is more humane than prolonged traction. After reduction, an anterior plaster mould is made and the patient is ready for general anesthesia. He uses a stainless steel wire (Babcock 24) figure-of-eight suture, drawn tightly around the spinous processes.

Colsen (20), Titrud et al (21), Sullivan (22), and Patton (23) discuss atlanto-axial dislocation. It can follow infection about the mouth or neck especially in children. The prognosis is good with the usual treatment of skeletal traction and brace. One of the three cases reported had quadriplegia, and was treated by laminectomy.

One article from Russia by Jaricyn (24) reports in detail the physical findings in a man of 62 with a cervical spine fracture treated in 3 kg. traction for a month, then by a Shands collar.

The present state of knowledge of ruptured cervical disks has been reviewed by Lievre (25). The most frequent locations for such a herniation are at the 5th and 6th interspaces. Disks typically produce a single root syndrome. Cervical arthritis may simulate it. A large disk may produce cord symptoms. He believes that the proper treatment is cervical hemilaminectomy and removal of the disk.

Cervical disks may simulate multiple sclerosis, primary lateral sclerosis, amyotrophic lateral sclerosis and it is pointed out by Bucy (26), (27) that before patients are tabulated as suffering from a hopeless degenerative disease of the spinal cord that myelography and the ruling out of a cervical disk be done.

Horrox and Poppen (28) review 60 patients with meningiomas and neurofibromas of the spinal cord. Eighty-five per cent with symptoms of less than one year were cured or greatly improved.

Hypertrophic spurs encroaching upon the cervical foramina and the mechanism of their formation as opposed to the hypertrophic spurs in the lumbar region, which extend anteriorly, is the basis of a well-illustrated exposition by Seze et al (29). They believe that the pure cervical brachial radiculitis lends itself poorly to surgical treatment as opposed to the lumbar disks which do better with surgery.



In remarks on the clinical diagnosis, Bonduelle (30) reports the words of Scoville that hypertrophic spurs localized in an intervertebral space in the cervical spine are in favor of a ruptured disk as opposed to cervical arthritis. It is not, however, an absolute criterion. He presents a case to illustrate his point. A case of cervical disk healed by traction is presented by Lievre and Attali (31). The patient had a typical syndrome of disk protrusion between C-6 and C-7 and was treated with 5 kilograms of traction. He obtained relief in 20 days.

The treatment of injuries to the brachial plexus is described by Bjorkesten (32). His experience is based on 97 cases of war injuries, one caused by traction and the remainder by missiles. No marked benefit from neurolysis could be demonstrated. Suture of the 5th and 6th roots, the first primary trunk and infraclavicular lesions seemed to yield satisfactory results. Conservative treatment to all other lesions seemed most suitable. Surgery to traction injuries is considered inadvisable.

Two cases of traction type brachial plexus injuries are presented by Keer (33). Sensory loss corresponding to C-2, C-3, and C-4 returned completely in both cases, although brachial plexus was not kept in one. He states that the usual injury applies traction to the cervical plexus as well, and that sensory loss in cervical dermatomes is not a prognostic sign of severity of brachial plexus injury. Sixty-three traction injuries of the brachial plexus in adults are reviewed by Barnes (34). Forcible separation of the head and shoulders is the initial mechanism of injury; if this occurs with arm at side an upper lesion results and if it is elevated, a lower type of lesion occurs. Lesions were divided into (1) C-5, C-6, 14 cases; (2) C-5, C-6, C-7, 19 cases; (3) whole plexus, 28 cases; (4) C-7, C-8, and T-1, 2 cases. Recovery usually good with upper root lesions and generally poor in whole plexus lesions. Conservative treatment was indicated for all types. Late exploration is only rarely necessary and for pain only. Reconstructive surgical procedure should not be instituted before 15 months.

A slightly different operative approach to supraclavicular plexus injuries is described by Bateman (35). The patient is placed in a sitting position with the shoulder dependent at the side. The incision begins at the lateral border of the mid-third of the sternomastoid muscle and extends to the mid-third of the clavicle. The advantages are (1) the trunks remain more superficial, (2) a wider field can be explored, less frequently necessitating division of the clavicle, and (3) it is a more comfortable position for the operator.

Forty-two cases of open wounds of the brachial plexus are reviewed by Brooks (36). The cases are divided into (1) lesions of roots and trunk of C-5, C-6 whose recovery is good, (2) lesions of posterior cord, recovery fair, (3) lesions of C-8 and T-1 with medial cord, whose recovery is poor. Exploration was performed in 22 cases because of (1) complete lesions of plexus, (2) complete lesion of localized part, or (3) persistent pain. Only 4 cases of complete interruption of continuity were found. The conclusion reached by the author is that routine exploration of open wounds of the brachial plexus is not justifiable.



Residual paralysis after brachial plexus injuries, states Hendry (37), should be treated by the methods in the following order of preference: (1) muscle transplant may give adequate function, (2) shoulder arthrodesis only when muscle transplant is out of the question and (3) amputation, almost never necessary.

An unusual case is presented by Penfield (38) in which a man developed incapacitating spastic weakness of both lower extremities of 9 years duration, 37 years following an avulsion of the brachial plexus. At surgery it was found that cicatrix of T-1 had drawn the cord into the bony foramina of T-1 with canal cord compression. Release of the scar was followed by complete return of function 3 years postoperatively.

Erb's palsy is discussed by Abdel Aziz Hanna (39) on the basis of a review of 94 cases of unilateral and 4 cases of bilateral paralysis. They were treated by massage, electrotherapy, and airplane splints. Another case of Erb's palsy associated with phrenic nerve paralysis is reported by Turner and Bakst (40). A complete pathologic anatomic study was made at autopsy of this six-weeks old infant. There was avulsion of the anterior roots of C-5 and C-6. The right side of the diaphragm was atrophic and elevated and there were degenerative changes in the right phrenic nerve.

The scalenus anticus syndrome is reviewed by Delafield (41). The syndrome was recognized by Adson and Coffey in 1927. The diagnosis is made by their maneuver, which consists of turning the head to the affected side and elevating the chin. This may make the pain worse or stop the pulse. In the differential diagnosis, arthritis, disk, Klumpke's paralysis, angina and hand-nerve compression syndrome must be considered. Two cases are presented.

Magnusson (42) reports an instructive case with a relatively large cervical rib shown upon which the subclavicular artery was compressed. Division of the scalenus anticus muscle without resection of the rib produced complete relief of symptoms.

A new syndrome named "costoclavicular compression" is presented by McGowan and Velinsky (43), who show that many symptoms attributed to scalenus anticus or cervical rib syndromes are actually due to costoclavicular compression of the artery and nerves. The clinical test, which they found 99 per cent accurate in a series of both symptomatic patients and so-called normal controls, is marked reduction or obliteration of the pulse to the arm when the shoulders are placed in the "attention" position. False-positive results of the Adson test for scalenus anticus syndrome are explained by their finding that most patients so tested automatically push the shoulder back and down during the Adson maneuver. They state that scaleniotomy has probably benefited cases of costoclavicular compression, in that section of the muscle has allowed the first rib to descend and has also removed some bulk of tissue, both resulting in increase of the costoclavicular space. Some cases are benefited by exercises to increase the shoulder-elevating functions of the levator scapulae and trapezius muscles. If exercises fail, scaleniotomy or resection of cervical rib or a portion of the first thoracic rib is recommended, and resection of the



middle third of the clavicle is suggested although it has not been tried by the authors.

Ten cases of scoliosis of the cervical spine are presented by Boldrey et al (44) as a first manifestation of disease of the spinal cord. These cases consisted of congenital anomalies, cystic lesions of the cord, angiomata spinal varis, adhesions and extramedullary tumors. The convexity of the curve is usually toward the side of the lesion. Reports are quoted of 60 cases of surgically proven disease of the upper spinal region, 25 per cent of which showed scoliosis, and of 2,000 cases of scoliosis with only 7 neurological lesions.

Spasmodic torticollis studied by electromyography is reported by Herz et al (45).

Muscular torticollis is discussed by Chandler (46) and is based upon the study of 225 patients. The literature is reviewed and most authors agree that the tumors of the sternomastoid muscle are hematomas. In older children, he advises detachment of the sternal and clavicular heads of the muscle and retention in an overcorrected position. In infants, he excises the "tumor" and uses a light plaster splint to maintain over-correction for 4 weeks.

The entire problem of torticollis is thoroughly reviewed by Brown (47). He considers acute, chronic, and spasmodic types resulting from bone and joint disease, muscle and ligament affections, neurological disease and those associated with glandular and local infections of the neck. The most common type of the acute stiff neck, the fibrositis type, comes on often following a chill. Similar complaints may be associated with unilateral facet dislocation of cervical disk. Spasmodic torticollis occurs in adults and there are recurrent clonic or tonic spells. The cause is obscure but emotional stress and central nervous system lesions are the two most probable. The clonic type may respond to section of the spinal accessory nerve. Cases of acute stiff neck relieved by ethyl chloride spray are reported by Travell (48).

Ocular torticollis in a 5½ year old boy is reported by Sprunt (49). The child had paresis of the right superior oblique muscle. Dr. Marshall Parks in discussion explains that the child had diplopia except when he tilted his head to the left. He makes two important differences between ocular and nonocular torticollis. (1) In ocular torticollis, the head is always turned in the direction of the head tilt. In nonocular torticollis, the head is turned in the opposite direction from head tilt. (2) In ocular torticollis due to muscular paresis, the strabismus is apparent and the patient should experience diplopia except when the head is in the habitually assumed position.

There are several papers on Miscellaneous subjects pertaining to the cervical spine. Randolph (50) states that some allergenic foods can produce symptoms of pulling, drawing, tightness and aching in the posterior cervical muscles.



Pathologic changes in the cervical region as a cause of headaches is the subject of an interesting paper by Josey (51). He reviews the literature in the past 40 years and the case histories of 6 patients are presented. All had occipital or frontal headaches, usually related to the position of the head and to exertion and all had aching in the posterior cervical region. In many patients, the frontal headaches could be reproduced by lateral pressure over the second vertebral body. All cases had loss of the normal cervical lordotic curve by x-ray. Since the fore part of the head and cranial structures are supplied by the 5th cranial nerve and the posterior part of the head and the subtentorial structures supplied by the upper 3 cervical and the 9th and 10th cranial nerves, it was difficult to explain how the frontal headaches could be produced through these pathways. The author thought that trauma producing an injury in the nature of a sprain to the paravertebral structures was probably the primary factor producing the headaches and accentuating the secondary muscle spasm. Several types of treatment were tried and simple immobilization and traction gave the most satisfactory relief.

X-ray of the cervical spine by tomographic analysis is demonstrated in a case of congenital anomaly of the cervical spine by Faulong and Djian (52) to reveal radiological evidence which cannot be secured by routine conventional films.

A case of osteomyelitis of the 6th and 7th cervical vertebrae with quadriplegia is reported by Butterworth and Carpenter (53) and the literature reviewed. Hibbs fusion was done and 8 months later the patient had made almost complete recovery except for some residual stiffness in the fingers of both hands. A case of Charcot's disease in the cervical spine is reported by Cutting (54). X-rays showed deformity, partial collapse and backward subluxation of C-3, 4, and 5, with bony contusion of a wavy appearance and an irregular new bone formation especially on the anterior aspects of these vertebrae.

### Shoulder

A general discussion of industrial injuries to the shoulder joint by Bingham (55) considers three main groups. (1) Major fractures, (2) Dislocations, (3) Musculotendinous capsular disorders. The treatment of recent dislocations and fracture-dislocations of the shoulder is discussed by Milch (56). Anatomical study of the shoulder shows all muscles traversing the shoulder joint are aligned only when the arm is in maximal overhead abduction. Employing this fact, six cases of dislocation are described in which reduction was readily affected by fixing the dislocated humeral head in one hand while the arm was abducted with the other. When in maximal abduction, the humeral head is readily pushed into place. Tension on nerves is eliminated.

The problem of comminuted fracture-dislocations of the shoulder and a seven-year follow-up on 2 cases is presented by Michaelis (57). These cases were treated by excision of fragments and an abduction splint and showed little or no disability.



Surgical approaches to the shoulder joint by Abbott and Saunders et al (58) is an anatomical and physiological review of the sternoclavicular, acromioclavicular and scapulohumeral joints. The indications for, position of the patient for, and the incision with operative approach to each joint are given with drawings. (Ed. Attention is recalled to the films of surgical approaches prepared by these authors.)

Acute anterior dislocation of the shoulder with a review of 27 cases is presented by Nicola (59). The injury determines the pathology, Hyper-abduction tears the humeral attachment of the capsule and even the subscapularis attachment from the humerus. If an impacting force is present simultaneously, the labium glenoidal scapular attachment of the capsule may tear free in a longitudinal fashion.

The technic and merits of the Delitala operation are described by Belgrano and Gambier (60). The essential differences from the Bankart operation are that the capsule is fixed to the glenoid with T-shaped nails and immobilization is in mid-abduction.

Henderson (61) gives a follow-up on the tenosuspension operation which he first described in 1943. Seventy-four shoulders have been operated upon. Twenty-two of the operations were on epileptics with 55 per cent successful results. In nonepileptics, 50 operations were traced with 78 per cent successful results. The results were not as good as the author had reason to expect and he concludes that some other more radical procedure that may entail more reconstructive mobility probably should be used.

Jakobsson (62) reports results of Eden-Hybinette's bone block operation. The incidence of redislocation was 1.5 per cent in 200 cases. By Bankart's technic there were three recurrences in 134 cases and by Nicola's, 42 in 187 cases.

The results of 12 cases treated by the Bankart operation are reported by Edwards (63). He attached the capsule with a small vitallium plate and two screws. All patients were followed until their return to duty in the Navy and no recurrences are mentioned.

A modification of the Bankart procedure is presented by Luckey (64) which consists of the utilization of pull-out wires of stainless steel for fixation of the capsule. He states that it simplifies Bankart capsulorrhaphy. The series is not yet old enough for conclusive follow-up. No originality is claimed for this technique.

Congenital subluxation of the shoulder in a child born by Caesarian section is reported by Goldstein (65). Posterior dislocation in 11 cases is discussed by Wilson and McKeever (66). They were due to acute trauma. There is usually a tear of the posterior scapular attachment of the capsule. Treatment is by closed manipulation. This is improved by maximal internal rotation of the humerus or by crossed transfixion wires through the humeral head and acromion. Late treatment, even with open reduction, is unsatisfactory.



Five cases of posterior dislocation treated by the Eden-Hybinette type of bone block operation are reported by Fried (67). In one case, the graft absorbed and dislocation recurred in one year.

Ekman (68) reports a case of habitual posterior subluxation of the shoulder joint operated according to Clairmont-Ehrlich. The patient was a young woman who had excessive discomfort. After two years, re-examination showed good results. A review of the literature on posterior habitual humeral luxation is included.

A case of intrathoracic dislocation of the humerus is presented by West (69). The author could find no similar dislocation in the literature.

Complete acromioclavicular dislocation is discussed by Bosworth (70). Operative and nonoperative treatments are discussed, including strappings, casts, and pressure pads which at times are effective but difficult to manage. Excision of the distal clavicle, fusion of the joint and repair operations are too risky or too major procedures. In 38 cases in which the lag screw was used, there were two failures. Touney (71) describes the use of Kirschner wires for fixation across the acromioclavicular joint, removing them in eight weeks. In cases of osteoarthritis, he prefers to remove the distal 2.5 cm. of clavicle. He also states the wire fixation is not satisfactory for late cases. Bramann (72) gives a brief statement regarding the various methods used in treatment of chronic acromioclavicular separation. He uses nails with good cosmetic and functional results.

The evaluation of shoulder pain by suprascapular nerve block is considered useful by Milowsky and Rovenstine (73). Complete tears may be differentiated from partial ones. Manipulation can be accomplished for peri-arthritic adhesions and the vasodilations secondary to the block may favor the absorption of calcium deposits.

Brown (74) also writes on procaine infiltration as a guide to treatment of supraspinatus tears. The excision of the acromion in 95 cases of supraspinatus syndrome are reported by Armstrong (75). Eighty of these were successful. He removes the acromion back of the acromioclavicular joint and resutures the deltoid to the exposed bone. The operation does not result in functional loss or cosmetic defect.

The classification of subacromial bursitis is given by McCurrach et al (76) as acute, subacute, chronic, and chronic with exacerbation. Success of roentgen therapy was in relation to acuteness and the presence of calcium.

Wylie (77) reviews the history, etiology, pathology, symptomatology, classification, and physical and x-ray findings of subdeltoid bursitis. He concludes that empirical x-ray therapy is the treatment of choice. Fifty cases are considered.



Lattomus and Hunter (78) review 235 cases of subdeltoid bursitis treated by x-ray. The best results were in acute bursitis. They concluded that low voltage x-ray therapy is just as effective as high voltage therapy. Pelland and Hoffman (79) advocate surgical excision of calcified bursa as initial treatment.

Capsulitis of the shoulder is also referred to as peri-arthritis or in the late cases of frozen shoulder. Simmonds (80), Ott and Wiederker (81), and Julliard (82) report on this condition. It is an inflammatory lesion in the musculotendinous cuff invoked by a local area of degeneration, usually in the supraspinatus tendon. The most effective treatment during the acute phase is rest with heat or cold. In the chronic phase, manipulation is often necessary. Swelling and pain in the armpit in a 7-year old white girl is reported by Slotkowski (83). A biopsy showed Brill-Symmer's disease, also known as giant follicular hyperplasia of lymph nodes and spleen, giant follicular lymphoblastoma, giant follicular lymphoma, and giant follicular lymphadenopathy.

There are a number of miscellaneous articles pertaining to the shoulder. Kirakozov (84) describes a case of injury to the left shoulder girdle complicated by gas infection. (Ed. This 1-1/2 page article was not translated from the Russian).

A case of osteomyelitis of the scapula in a 2-1/2 year old girl is reported by Immerman (85).

A pathological fracture through a cyst of the scapula is reported by Buxton (86). Ten months before patient was seen, she had strained her arm pulling a pram up some steps and had burning in the shoulder region. X-ray showed fracture through a cyst in her right scapula.

Rounds (87) reports a case of isolated fracture of the coracoid process caused by a fall with no direct trauma.

A case with an anomalous coracoclavicular joint is reported by Wertheimer (88). The literature contains reports of 50 of these cases. This joint was painful because of osteoarthritis. After resection, painless normal function was established.

Osteochondromatosis in a shoulder joint in a patient with pulmonary tuberculosis is reported by Weisman-Netter et al (89). She was a 45-year old housewife whose x-ray showed the shoulder joint filled with loose bodies of all dimensions and shapes.

Calcium deposits in the vicinity of the shoulder and other joints is discussed by Key (90), in an interesting and comprehensive review. The various methods of treatment are discussed. The author believes that operative removal of the calcific deposits to be the surest method of affording prompt and permanent relief. The technic and extent of surgery recommended is described. The author prefers this method to needling



the shoulder, and prefers both to x-ray therapy. Additional remarks of interest are found in the discussion.

Calcification of the supraspinatus tendon is described by Jones (91). Six cases are presented which were treated with rest and with heavy sedation alone. Spontaneous recovery occurred in four of the patients in 28 days with absorption of deposits.

Two cases of unusual calcareous bursitis are reported by Kleinberg (92). One case involved the radiohumeral bursa and the other the knee. In both of these cases, the extensive calcification lead to suspicion of bone neoplasm. Both were found by microscopic examination to be calcifications of bursal wall.

Robbins (93) reports 52 cases of supraspinatus calcification, treated by multiple needling.



## BIBLIOGRAPHY

1. Wrete, M.: The sensory pathways from the shoulder joint, *J. Neurosurg.*, 6: 351-60, Sept 1949
2. Wrete, M.: The innervation of the shoulder joint in man, *Acta anat.*, Basel, 7: 173-90, 1949
3. Hadley, L. A.: Roentgenographic studies of the cervical spine, *Postgrad. M.*, 5: 492-501, June 1949
4. Bocklage, M. H.: A comparison of roentgenographic examinations of the sternum and sternoclavicular joint; illustrating a postero-anterior bilateral articulation, 21: 19-27, July 1949
5. Jit, I., and Shah, M. A.: Some observations on atlas and axis vertebrae of the Punjabees, *Ind. M. Gaz.*, 84: 93-5, Mar 1949
6. Hilker, A. W.: The shoulder-hand syndrome; a complication of coronary artery disease, *Ann. Int. M.*, 31: 303-11, Aug 1949
7. Frame, B., Ropes, M. W., et al: The shoulder-hand syndrome, *Am. Practitioner*, 3: 633-7, June 1949
8. Withers, R. J. W.: The painful shoulder; review of 100 personal cases with remarks on the pathology, *J. Bone Surg.*, 31 B: 414-7, Aug 1949
9. Harrison, S. H.: The painful shoulder; significance of radiographic changes in the upper end of the humerus, *J. Bone Surg.*, 31 B: 418-22, Aug 1949
10. Armstrong, J. R.: The orthopedic treatment of the painful shoulder, *Rheumatism, Lond.*, 5: 124-7, Oct 1949
11. Nachlas, I. W.: Upper extremity pain; the orthopedist's point of view, *Med. Ann. District of Columbia*, 18: 394-7, Aug 1949
12. Somerville-Large, C.: Pain in the shoulder girdle from an orthopaedic viewpoint, *Rheumatism, Lond.*, 5: 63-77, July 1949
13. Hedges, F. H., Jr.: The painful shoulder, *Surg. Clin. N. America*, 29: 145-54, Feb 1949
14. Noble, J. A.: The painful stiff shoulder, *Nova Scotia M. Bull.* 28: 141-5, June 1949
15. Alexander, J. S.: The painful shoulder, *S. Afr. M. J.*, 23: 707-9, Aug 20, 1949



16. Stamm, T. T.: Brachial neuritis, Med. Press, Lond., 221: 243-5, March 9, 1949
17. Savage, O.: The frozen shoulder, Med. Press, Lond., 221: 623-6, June 29, 1949
18. Edmunds, L. H.: Fractures and dislocations of the cervical spine, Bull. Mason Clin. Seattle, 3: 25-31, Sept 1949
19. Kenny, P. J.: The treatment of fracture dislocation of the cervical spine by internal fixation, Austral. N. Zealand J. Surg., 19: 81-5, Aug 1949
20. Colsen, K.: Atlanto-axial fracture-dislocation, J. Bone Surg., 31 B: 395-8, Aug 1949
21. Titrud, L. A., McKinlay, C. A., et al: Nontraumatic atlanto-axial dislocation; report of case with recovery after quadriplegia, J. Neurosurg., 6: 174-80, Mar 1949
22. Sullivan, A. W.: Subluxation of the atlanto-axial joint, sequel to inflammatory processes of the neck, J. Pediat. S. Louis, 35: 451-64, Oct 1949
23. Patton, E. F.: Cervical vertebral subluxation, Ann. West. M. & S., 3: 258, July 1949
24. Jaricyn, A. A.: Diagnosis of fractures of the cervical vertebrae, Vest. khir., 69: 56, 1949
25. Lievre, J. A.: Les hernies discales de la region cervicale, Presse Med., 57: 303-6, Apr 2, 1949
26. Bucy, P. C.: The simulation of multiple sclerosis and other degenerative diseases of the spinal cord by herniation of the cervical intervertebral discs, Cincinnati J. M., 30: 16-18, Jan 1949
27. Bucy, P. C.: Simulation of multiple sclerosis and other degenerative diseases of spinal cord by herniation of cervical intervertebral discs, Mississippi Valley M. J., 71: 85-7, May 1949
28. Horrax, G., Poppen, J. L., et al: Meningiomas and neurofibromas of the spinal cord; certain clinical features and end results, Surg., Clin. N. America, 29: 659-65, June 1949
29. Seze, S. De, Debeyre, J., et al: Algie cervicobrachiale, hernie du disque intervertebral et osteophytose unco-vertebrale, Sem. hop., Par., 24: 3101-11, Dec 22, 1948
30. Bonduelle, M.: Remarques sur le diagnostic clinique et radiologique de la hernie discale cervicale, Rev. rhumat., Par., 16: 284-6, June 1949



31. Lievre, J. A., and Attali, P.: Syndrome de hernie discale cervicale; guerison par extension, Rev. rhumat., Par., 16: 293, June 1949
32. Bjorkesten, G. A. F.: Behandling av lesioner i plexus brachialis (Treatment of injuries to the brachial plexus), Nord. med., 41: 211-5, Feb 4, 1949
33. Keer, A. S.: Cervical plexus injuries as an extension of brachial plexus injuries, J. Bone Surg., 31 B: 37-9, Feb 1949
34. Barnes, R.: Traction injuries of the brachial plexus in adults, J. Bone Surg., 31 B: 10-16, Feb 1949
35. Bateman, J. E.: An operative approach to supraclavicular plexus injuries, J. Bone Surg., 31 B: 34-6, Feb 1949
36. Brooks, D. M.: Open wounds of the brachial plexus, J. Bone Surg., 31 B: 17-33, Feb 1949
37. Hendry, A. M.: The treatment of residual paralysis after brachial plexus injuries, J. Bone Surg., 31 B: 42-9, Feb 1949
38. Penfield, W.: Late spinal paralysis after avulsion of the brachial plexus, J. Bone Surg., 31 B: 40, Feb 1949
39. Abdel Aziz Zaky Hanna: A case of double Erb Duchenne paralysis with a comment on electrotherapy, J. Egypt. M. Ass., 32: 230-5, Feb-Mar, 1949
40. Turner, L. B., and Bakst, A. A.: Phrenic nerve paralysis associated with Erb's palsy in the newborn; a clinical and anatomicopathologic study, J. Mount Sinai Hosp., N. York, 15: 374-9, Mar-Apr, 1949
41. Delafield, R. H.: The scalenus anticus syndrome, Am. Practitioner, 3: 730, Aug 1949
42. Magnusson, R.: The scalenus anticus syndrome; report of an instructive case, Acta orthop. scand., 19: 153-8, 1949
43. McGowan, J. M., and Velinsky, M.: Costoclavicular compression; relation to the scalenus anticus and cervical rib syndrome, Arch. Surg., 59: 62-73, July 1949
44. Boldrey, E., Adams, J. E., and Brown, H. A.: Scoliosis as a manifestation of disease of the cervicothoracic portion of the spinal cord, Arch. Neur. Psychiat. Chic., 61: 528-544, May 1949
45. Herz, E., and Hoefler, P. F. A.: Spasmodic torticollis, physiologic analysis of involuntary motor activity, Arch. Neur. Psychiat., Chic. 61: 129-36, Feb 2, 1949



46. Chandler, F. A.: Muscular torticollis, *J. Bone Surg.*, 30 A: 566-9, July 1948
47. Brown, D.: Torticollis, *Med. Press, Lond.*, 222: 183-7, Aug 31, 1949
48. Travell, J.: Rapid relief of acute stiff neck by ethyl chloride spray, *J. Am. M. Women Ass.*, 4: 89-95, Mar 1949
49. Sprunt, W.: Ocular torticollis, *Clin. Proc. Child. Hosp., Wash.*, 5: 276-9, Sept 1949
50. Randolph, T. G.: Food allergy as a cause of myalgia of the posterior cervical muscles, *Ann. Otol. Rhinol.*, 58: 295-8, Mar 1949
51. Josey, A. I.: Headache associated with pathologic changes in cervical part of spine, *J. Am. M. Ass.*, 140: 944-9, July 16, 1949
52. Faulong, L., and Djian, A.: Analyse tomographique de malformations congenitales cervico-dorsales multiples, *Rev. rhumat.*, Par., 16: 336-9, July 1949
53. Butterworth, R. D., and Carpenter, E. B.: Pyogenic osteomyelitis of the cervical spine with quadriplegia secondary to cord pressure; recovery following spinal cord fusion, *So th. M. J.*, 42: 561-4, July 1949
54. Cutting, P. E. J.: A case of Charcot's disease of the cervical spine, *Brit. M. J.*, 1: 311, Feb 19, 1949
55. Bingham, D. L. C.: Some industrial injuries of the shoulder joint, *Canad. M. Ass. J.*, 61: 32-6, July 1949
56. Milch, H.: The treatment of recent dislocations and fracture-dislocations of the shoulder, *J. Bone Surg.*, 31 A: 173-80, Jan 1949
57. Michaelis, L. S.: Comminuted fracture-dislocation of the shoulder; result seven years after excision of fragments and treatment on abduction splint, *Proc. R. Soc. M., Lond.*, 42: 597, Aug 1949
58. Abbott, I. C., Saunders, J. B. D., et al: Surgical approaches to the shoulder joint, *J. Bone Surg.*, 31 A: 235-55, Apr 1949
59. Nicola, T.: Acute anterior dislocation of the shoulder, *J. Bone Surg.*, 31 A: 153-9, Jan 1949
60. Belgrano, M., and Gambier, R.: On the subject of recurrent dislocation of the shoulder, *Acta orthop. scand.*, 18: 319-28, 1949
61. Henderson, M. S.: Tenosuspension operation for recurrent or habitual dislocation of the shoulder, *Surg. Clin. N. America*, 29: 997-1007, Aug 1949



62. Jakobsson, A.: On recurrent dislocation of the shoulder joint; a contribution to its pathomechanics and the results of Eden-Hybinette's bone block operation, *Acta orthop. scand.*, 18: 284-318, 1948-1949
63. Edwards, E. G.: Bankart operation for recurrent dislocation of the shoulder, *U. S. Nav. M. Bull.*, 49: 244-52, Mar-Apr, 1949
64. Luckey, C. A.: Recurrent dislocation of the shoulder, modification of Bankart capsulorrhaphy, *Am. J. Surg.*, 77: 220-2, Feb 1949
65. Goldstein, R.: Congenital subluxation of the shoulder with snapping, *Acta med. orient.*, Jerusalem, 8: 114-20, July-Aug 1948
66. Wilson, J. C., and McKeever, F. M.: Traumatic posterior (retro-glenoid) dislocation of the humerus, *J. Bone Surg.*, 31 A: 160-72, Jan 1949
67. Fried, A.: Habitual posterior dislocation of the shoulder joint; a report on five operated cases, *Acta orthop. scand.*, 18: 329-45, 1948-1949
68. Ekman, H.: A case of habitual posterior subluxation of the shoulder joint operated according to Clairmont-Ehrlich, *Acta Chir. Scand.*, 97: 322-30, Jan 26, 1949
69. West, E. F.: Intrathoracic dislocation of the humerus, *J. Bone Surg.*, 31 B: 61, Feb 1949
70. Bosworth, B. M.: Complete acromioclavicular dislocation, *N. England J. M.*, 241: 221-5, Aug 11, 1949
71. Toumey, J. W.: Surgery of the acromioclavicular joint, *Surg. Clin. N. America*, 29: 905-12, June 1949
72. Bramann, V.: Die Behandlung der Luxatio acromioclavicularis, *Deut. Tesundhwes*, 4: 168, Feb 15, 1949
73. Milowsky, J., and Rovenstine, E. A.: Suprascapular nerve block; evaluation in the therapy of shoulder pain, *Anesthesiology*, 10: 76-91, Jan 1949
74. Brown, J. T.: Early assessment of supraspinatus tears; procaine infiltration as a guide to treatment, *J. Bone Surg.*, 31 B: 423-5, Aug 1949
75. Armstrong, J. R.: Excision of the acromion in treatment of the supraspinatus syndrome; report of 95 excisions, *J. Bone Surg.*, 31 B: 436-42, Aug 1949
76. McCurrach, A. C., Norton, G. I. and Bouchard, J.: Subacromial bursitis; review of 235 cases, *Delaware M. J.*, 21: 115-7, July 1949



77. Wylie, P. E.: Subdeltoid bursitis, *Mil. Surgeon*, 105: 237-40, Sept 1949
78. Lattomus, W. W., and Hunter, L. M.: Roentgen therapy of subdeltoid bursitis; review of 235 cases, *Delaware M. J.*, 21: 115-7, July 1949
79. Pelland, P. O., and Hoffman, W.: Operative treatment of acute subdeltoid bursitis with calcification, *Induts. M.*, 18: 79-81, Feb 1949
80. Simmonds, F. A.: Shoulder pain with particular reference to the frozen shoulder, *J. Bone Surg.*, 31 B: 426-32, Aug 1949
81. Ott, V. R., and Wiederkehr, J.: La periarthrite scapulo-humerale rhumatismale, *Rev. rhumat., Par.*, 16: 187-95, May 1949
82. Julliard, C.: La periarthrite de l'espaule, *Rev. Med. Suisse rom*, 69: 31-7, Jan 25, 1949
83. Slotkowski; Swelling and pain in the armpit, *Case Rep. Child. Hosp. Chic.*, 8: 1307-11, Jan 1949
84. Kirakozov, M. D.: Povrezhdenie levogo plechevogo poyasa oslozhnivshegosya gazovoi flegmonoi, (Injury of the left shoulder girdle, complicated by gas phlegmon), *Vest. Khir.*, 69: 54, 1949
85. Immerman; Osteomyelitis of the scapula, *Case Rep. Child., Hosp., Chic.*, 8: 1491-3, Oct 1949
86. Buxton, S. J. D.: Pathological fracture through a cyst of scapula, *Proc. R. Soc. M., Lond.*, 42: 273, Apr 1949
87. Rounds, R. C.: Isolated fracture of the coracoid process, *J. Bone Surg.*, 31 A: 662, July 1949
88. Wertheimer, L. D.: Coracoclavicular joint; surgical treatment of a painful syndrome caused by an anomalous joint, *J. Bone Surg.*, 30 A: 570-8, July 1948
89. Weisman-Nette, R., Mendelsohn, B., and Krewer, B.: Osteochondromatose scapulo-humerale chez une tuberculeuse pulmonaire, *Bull. Soc. med. hop.*, Paris, 65: 766-70, June 3 and 10, 1949
90. Key, J. A.: Calcium deposits in the vicinity of the shoulder and of other joints, *Ann. Surg.*, 129: 737-55, June 1949
91. Jones, G. B.: Painful shoulder; calcification of the supraspinatus tendon, *J. Bone Surg.*, 31 B: 433-5, Aug 1949
92. Kleinberg, S.: Calcareous bursitis, *N. York State J. M.*, 49: 171-3, Jan 15, 1949
93. Robbins, J. V.: Supraspinatus tendonitis calcarea, *N. York State J. M.*, 49: 389, Feb 1949



## CHAPTER XVIII

### CONDITIONS INVOLVING THE ARM, ELBOW, FOREARM, WRIST AND HAND

By

Victor B. Vare, Lt. Colonel, M. C., U. S. A.

And

Wm. B. Stanton, Capt, MC, USA, and Erle E. Peacock, Jr., 1st Lt., MC, USA

#### ARM

A case of rupture of the left pectoralis major muscle is reported by Pulaski and Martin (1) having as its stated purpose the addition to the literature of the twenty-second such case report. The clinical and operative findings are given. The authors state that diagnosis is not difficult and that surgical repair is the treatment of choice.

Waugh et al (2) use their series of 50 cases of rupture of the biceps brachii as the basis for an excellent, comprehensive review and discussion of the subject. The incidence of these 50 cases is small, from a total of 60,792 hospital admissions over a period of 14 years. Forty-five cases involved the long head, five the distal tendon. The insertion of the pectoralis major is recommended as the site of re-attachment of the tendon of the long head. Their recommendations are based on personal experience rather than new proposals.

Restoration of major defects of the arm in severe compound injuries by a combination of plastic, orthopedic and neurologic surgical procedures, is described by Brown, Cannon, et al (3). Scar tissue is removed, soft parts and bones replaced to anatomical position, and skin cover provided with a pedicle graft from the trunk, which is severed in 14-21 days. The donor site and raw under surface of the pedicle is covered with split thickness skin. The wound is usually closed and bone, tendon, joint and nerve repair may be done.

#### ELBOW

Congenital accessory bones in the form of patella cubiti are reported by Hardman (4). Another case of bilateral patella cubiti is added to the literature by Sachs and Degenshein (5). This condition itself rarely causes symptoms and the mild limitation of extension requires no correction. When avulsion occurs, the diagnosis depends on the fact that the combined length of the patella cubiti and the ulna is greater than normal, as well as on the absence of a jagged fracture line. The authors choice of treatment



is rigid fixation of the sesamoid to the olecranon by means of a screw.

The treatment of various fractures about the elbow joint is outlined by Dickson (6).

Lou (7) tabulates the results of 45 olecranon fractures treated by various methods. He outlines the indications for excision established by McKeever and Buck (1947) and Watson-Jones (1946). Three cases in the series were treated in this manner and the author concludes additional cases may have been benefited had the fragments been excised.

A case of anterior dislocation of the right elbow in a 28-year old male is reported by Nambiar (8). He resorted to open reduction but includes no follow-up to clarify mobility of the joint or outcome of an associated radial palsy.

Stack (9) discusses the anatomy, pathology, diagnosis and therapy of olecranon bursitis and tennis elbow (radio-humeral bursitis) and Swenson (10) analyzes 62 cases of tennis elbow and their response to various therapies including (1) heat and massage, (2) manipulation under local anesthesia, (3) roentgen therapy and (4) surgery.

Amorth (11) presents four cases of chronic bursitis (patellar and olecranon) treated by weekly injections of a 5 per cent solution of mono-ethanolamine oleate (trade name "Tindanol"), a sclerosing solution. In every case, a complete cure was effected with adhesions of the cavity resulting. Only the serous or hemorrhagic type should be treated this way; the other types, proliferative, fibrinous, or lipomatose need more radical treatment.

#### FOREARM

Discussion of the accepted principles of grafting and repairs of flexor and extensor tendons in the forearm, wrist and hand is presented by Wagner (12) and Nichols (13).

On the treatment of radial palsy by tendon transplants, Scuderi (14) with 45 cases and Rojel (15) with 8, use the flexor carpi ulnaris for finger extension. The former then uses the palmaris longus for thumb extension while the latter author recommends tenodesis of the paralyzed tendons to prevent palmar flexion deformity.

The incidence of tardy ulnar palsy was 7 cases in 154 ulnar nerve lesions in a series studied by Magee and Phalen (16). The treatment of median and ulnar palsies by tendon transfers and arthrodesis is completely described by Littler (17). A complete analysis of motor power to be replaced and the available reserve to be used, as well as an analysis of opposition with criteria for judging results in opponens transfer is given. The single most important contribution is the pointing out of the fact that the abductor pollicis brevis muscle performs all of the functions of opposition and that its tendon of insertion should be used in opponens transfer.



A table of optimum position for arthrodesis is included.

Nicod (18) reports a few cases of spastic paralytic wrist drop treated by tendon transplants as in radial nerve injury.

Desenfans (19) reports two cases of internal fixation of the radius with bone plate and screws and the ulna with intramedullary nail.

#### WRIST

Two cases of dislocation of distal ulna without fracture are reported by Axer and Spann-Etzioni (20). The pronator quadratus contracts to perpetuate the deformity and necessitates open reduction or excision of distal ulna.

Dieulafe (21) recognizes but two indications for excision of distal ulna. The first is the inverse of the Monteggia fracture. It is a fracture of the radius with dislocation of the ulna at the wrist. The second is Madelung's deformity which he treats by lengthening the radius with bone excised from the ulna, thereby arresting the distal epiphyses of both.

Fracture and displacement of the radio-ulna fibrocartilage is felt by Overton (22) to be the important reason for a painful wrist following Colle's fracture. On the basis of 56 cases studied, he advocates careful reduction in supination and holding with unpadded plaster splints.

Crisman and Shortell (23) reviewed 300 fractures of the distal radius and found 15 cases (5 per cent) complicated by an associated fracture of the carpal scaphoid, and frequently overlooked. When found, they believe the thumb should be incorporated in the plaster and the wrist position changed to a cock-up after 4 weeks.

A case of rheumatoid arthritis of the wrist helped by removing as much of the synovial membrane as possible through a dorsal incision is reported by Wilkinson (24). The follow-up is inadequate.

Pauzat and Lasserre (25) dissertate at length upon arthroses of the hand and wrist under which term they group all the arthropathies so frequent in the hand, from the distal interphalangeal joints to the carpus. Symptomatic and sympathetic treatment and physiotherapy are described. They feel surgery is rarely indicated.

#### HAND

A detailed gross anatomy of the dorsal aponeurosis of the human finger by Landsmeer (26) demonstrates the physics behind the function of flexion and extension of the metacarpo-phalangeal and finger joints through the interplay of muscles from both volar and dorsal surfaces. Whillis and Channell (27) anaesthetized the radial and ulnar nerves, stimulated directly the lumbricals and interossei and surmise that there is no direct attachment of these muscles to the extensor mechanism but that flexion and



and extension of the interphalangeal joints occur through flexion of the metacarpo-phalangeal joints by these intrinsic muscles, thus tightening the long extensor tendon and its associated extensor mechanism.

That physiologic hypertrophy of the thenar muscles can occur is attested to by Koon (28). He feels that his case was possibly due to recurrent dislocation at the metacarpo-phalangeal joint and confirmed this contention by exploratory surgery.

Fifteen articles on hand injuries and infections are worthy of inclusion. Hakala (29) gives an anatomical review of sensory distribution of hand, innervation of intrinsic hand musculature, and functional tests for intrinsic musculature. Mason (30), (31), Burnett (32), J. Kansas Med. Soc. (33), Rank (34), and Eyre-Brook (35) outline the principles of therapy of compound fractures, severed tendons and nerves and other injuries of the hands and fingers, including the use of splints, antibiotics and cervical sympathetic blocks. All that discuss tendons advocate primary repair in "tidy" wounds. "The Care of Hand Injuries" in New York Med. (36), advocates with few exceptions repairing nerves, fascia and skin, leaving all tendon work for a future date.

Clark (37) includes an excellent discussion of the histology of tendon repair according to time after suture. In the middle of the second post-operative week, vascularization is greatest and danger of adhesions is greater.

Blum (38) gives three cases in which myotomy was done to facilitate primary suture of flexor tendons in the fingers and advocates the use of such a procedure.

Two cases of De Quervain's disease are reported by Murphy (39), in both of which the flexor pollicis brevis tendon had a separate sheath and was affected alone.

A case of swelling of the tendon sheaths of the hands and wrist, diagnosed as bilateral compound palmar ganglia, is presented by Bloom, (40). Biopsy revealed occasional rice bodies and yellow, jelly-like fluid. There was no evidence of tuberculosis but the concluding diagnosis was tuberculous synovitis anyway.

Fractures about the base of the thumb metacarpal are discussed chiefly from the standpoint of management by Macey and Murray (41).

Sabaino (42) presents a study of 135 carpal fractures and the percentage of each type that was compensable in Italy was: hamate, 100 per cent; lunate, 80 per cent; greater multangular, 33 per cent; scaphoid, 26 per cent; triangular and capitate, 25 per cent; of multiple fractures, 60.7 per cent were compensable because of resulting disabilities.

One hundred and seventy-seven fractures of the carpal scaphoid bones,



three fractures of trapezium, one of semilunar, and five cases of Kienbock's disease in New Zealand service personnel are reported by Wilson (43). Many were found to be of long standing and many were undiagnosed for prolonged periods. Reasons for this failure are discussed. Conservative management (immobilization in plaster cast) and necessity for perseverance in this treatment is discussed, as is operative treatment of drilling of fragments, bone grafting, excision of fragments, and arthrodesis. The high incidence of disabling sequelae is mentioned, and comments are directed to improving the overall recognition and treatment of carpal fractures.

Seven articles pertaining to fractures of the scaphoid are reviewed briefly by Farrell et al (44). Caspers (45) discusses types and mechanism of injury and generally accepted methods of treatment.

Andersen and Therkelsen (46), (47) give an eight-year follow-up of 92 scaphoid fractures. They make the incredible statement that "union occurred in one week in 23 of 25 cases immobilized immediately." They advocate drilling after the method of Beck for delayed union if nonunion is not established. They find that nonunion will persist despite prolonged immobilization. Functional end results of union and nonunion with and without surgery are presented.

Stack (48) advocates pegging for symptomatic nonunion of the carpal scaphoid and presents 16 cases. A review of pertinent literature is also offered. Goeringer (49) champions excision of the scapholunate system for displaced fractures, nonunion with cystic or mild arthritic change.

Ruttner (50) in a ten-page article reports a clinical and pathological study of pseudarthrosis of the scaphoid which term he prefers to necrosis and malacia even though the features characterizing this lesion correspond to a large extent to those in Kienbock's disease of the lunate. It results from a fracture or numerous microtraumatism causing an insidious fracture.

An old fracture of the lunate was excised because of sclerosis by Buxton (51) and the resulting defect filled with an acrylic cast.

Therkelsen and Andersen (52) report a study of 109 cases of malacia of the lunate or Kienbock's disease. Ninety-two cases were followed for over 6 years and of these 21 were excellent, 40 good and 31 poor. The authors feel that repeated trauma plays a large part in the etiology and single trauma is an extremely rare cause. They state that surgical excision gives the worst results.

Insley (53) improvised a simple splint to prevent subluxations of the proximal interphalangeal joint by limiting extension at that joint yet permitting flexion.

Contractures from dorsal burns of the hand are described by Braithwaite and Watson (54). They result in reversal of the palmar arch,



hyperextension of the metacarpo-phalangeal joints and hyperflexion of the proximal finger joints. The authors ascribe this deformity to infection, edema, and fibrosis treatment, early excision of slough, skin grafts and in severe cases by arthrodesis of the proximal interphalangeal joint. Splinting will not prevent the deformity.

Circumstantial evidence that trigger finger was caused by excessive heat is offered by Engel (55). Three cases are presented (welding gun, infra-red therapy.) Sprecher (56) reports 12 cases of trigger thumb in infants. He surmises that the etiology is traumatic. The treatment is surgical. In  $7\frac{1}{2}$  years follow-up, there were no recurrences or untoward results.

Watson and Griffiths (57) conclude that finger pulp infections respond better to local treatment with streptomycin than penicillin.

Measurement of infected pulp space finger volume by water displacement leads Lennard-Jones (58) to conclude that when swelling is 20 per cent or more, delay of incision and drainage is harmful; those 10 per cent or less respond on systemic penicillin and those between generally require operation despite penicillin therapy.

Hypertrophic arthritis of the carpo-metacarpal joint of the thumb is studied by Weissenbach and Francon (59) from the point of view of incidence, history, etiology, symptomatology, roentgenology, pathology, and treatment. The latter includes sedation, physical therapy, splinting with plaster, and drilling of the trapezoid and base of metacarpal.

Reconstruction of digits by attachment of tubed pedicles and inserting bone grafts is discussed briefly by Baxter et al (60). Six cases are presented. Graham and Riordan (61) describe problems in and four methods of reconstruction of a thumb. The importance of maintaining sensation and opposition are stressed.

Metacarpal transfer for improving function of a crippled hand, its indications and examples are given by Hyroop, (62).

Reconstruction of the thumb by phalangization of the first metacarpal is the simplest, quickest and safest method of procuring a thumb suitable for a laborer, office worker or housewife, writes Sandblom (63). A tubular pedicle with bone graft (Nicoladoni I) or transplantation of a toe or finger (Nicoladoni II) are less firm, weaker, less mobile, and have less sensation; they take longer and the risk of complications or failure is greater. A similar procedure is presented by Graham et al (64), using a portion of the second metacarpal to make a longer thumb.

The four methods available for treating scar contractures of the thumb are described by Young (65) as (1) Z plasty, (2) local flaps, (3) free grafts, and (4) pedicle grafts. The author concludes that a thin pedicle flap is probably necessary in most all cases where the scar is deep or extensive.



Favorable results in treating Dupuytren's contracture with vitamin E are reported in one case each by Chevallier and Beauzamy (66) and Thomson (67). The former authors also used thyroid extract and diethyl-stilbestrol.

King (68) treated 13 cases of Dupuytren's with vitamin E in the form of 100 mgm. alpha-tocopheral t.i.d. He obtained side effects of headache, nausea, fatigue, drowsiness, tinnitus, vertigo, blurred vision, enlargement of tongue and sweating. At the end of one year no change was noted in 12 of 13 patients and treatment was abandoned.

The surgical technique in Dupuytren's for excision of the palmar aponeurosis used by Mouchet (69) is a transverse incision along the distal palmar crease with excision of the fascia with all its deep extensions. Z-incisions are used at the base of the fingers and if necessary, the fascia here is removed out to the middle phalanx.



## BIBLIOGRAPHY

1. Pulaski, E. J., and Martin, G. W.: Rupture of the left pectoralis major muscle; report of a case, *Surgery*, 25: 110, Jan 1949
2. Waugh, R. L., Hathcock, T. A., and Elliott, J. L.: Ruptures of muscles and tendons with particular reference to rupture or elongation of long tendon, of biceps brachii with report of 50 cases, *Surgery*, 25: 370-92, Mar 1949
3. Brown, J. B., Cannon, B., et al: Restoration of major defects of the arm by combination of plastic, orthopedic and neurologic surgical procedures, *Journal Plastic and Reconstructive Surgery*, 4: 337-40, July 1949
4. Hardman, G. L.: A sesamoid at the elbow analogous to the patella, *Brit. J. Radiol.*, 22: 384, July 1949
5. Sachs, J. and Degenshein, G.: Patella cubiti; a new method of treatment for its avulsion, *Arch. Surg.*, 57: 675-80, Nov 1948
6. Dickson, F. D.: Fractures of the upper end of the radius and ulna, *Surg. Gyn. Obst.*, 38: 69-78, Jan 1949
7. Lou, I.: Olecranon fractures treated in the Orthopaedic Hospital, Copenhagen, 1936-47; a follow-up examination, *Acta orthop. scand.*, 19: 166-79, 1949
8. Nambiar, P. P. C.: A case of anterior dislocation of the elbow, *Ind. J. Surg.*, 11: 133, June 2, 1949
9. Stack, J. K.: Acute and chronic bursitis in the region of the elbow, *Surg. Clin. N. America*, 29: 155-62, Feb 1, 1949
10. Swenson, L. L.: Tennis elbow, *J. Michigan M. Soc.*, 48: 997, Aug 8, 1949
11. Amorth, G.: Terapia sclerosante nella cura delle borisits croniche semplici, *Minerva Chir. Tor.*, 4: 90-2, Feb 1, 1949
12. Wagner, C. J.: Tendon grafts in the hands, *Mil. Surgeon*, 105: 196-200, Sept 3, 1949
13. Nichols, H. M.: Anatomy of hand in relation to tendon repairs, *Northwest M.*, 48: 327-30, May 5, 1949
14. Scuderi, C.: Tendon transplants for irreparable radial nerve paralysis, *Surg. Gyn. Obst.*, 88: 643-51, Jan-June, 1949
15. Rojel, K.: On the treatment of radial palsy by tendon transplantation, *Acta orthop. scand.*, 19: 86-111, 1949
16. Magee, R. B., and Phalen, G. S.: Tardy ulnar palsy, *Am. J. Surg.*, 78: 470-4, Oct 4, 1949



17. Littler, J. W.: Tendon transfers and arthrodesis in combined median and ulnar nerve paralysis, *J. Bone Surg.*, 31 A: 225-34, Apr 2, 1949
18. Nicod, L.: Application des transplantations tendineuses dans le traitement des paresthesies spastiques de l'avant-bras, *Rev. med. Suisse rom.*, 69: 447-52, July 25, 1949
19. Desenfans, G.: A propos de deux cas D'osteosynthese des deux os L'avantbras, *Acta orthop. belg.*, 14: 316, Dec 1948
20. Axer, A., and Spann-Etzioni, J.: Dislocation of ulna at the radio-ulnar joint without fracture of radius; report of two cases, *Acta med. orient.*, Jerusalem, 8: 54-7, Mar-Apr, 3-4, 1949
21. Dieulafe, R.: Deux indications rares de resection partielle de e' extremite inferieure du cubitus, *Toulouse med.*, 49: 747-52, Nov 1948
22. Overton, L. M.: Colles' fracture with report of end results in 56 cases, *Rocky Mountain M. J.*, 46: 842-5, Oct 10, 1949
23. Crisman, O. D., and Shortell, J. H.: Fractures of the distal end of the radius complicated by fractures of the carpal scaphoid, *N. England J. M.*, 241: 58, July 2, 1949
24. Wilkinson, M. C.: Arthritis of wrist relieved by synovectomy, *Proc. R. Soc. M., Lond.*, 42: 593, Aug 8, 1949
25. Pauzat, D., and Lasserre, C.: Affections rhumatismales de la main et du poignet; les arthroses, *J. med. Bordeaux*, 126: 153-68, Apr 1949
26. Landsmeer, J. M. F.: The anatomy of the dorsal aponeurosis of the human finger and its functional significance, *Anatomical record*, 104: 31-44, May 1, 1949
27. Whillis, J., and Channell, G. D.: The action of the lumbrical and interosseous muscles in some movements of the digits, *J. Anat., Lond.*, 83: 60, Jan, Part I, 1949
28. Koon, E. S., Jr.: Hypertrophy of the thenar muscles, *Hosp. Corps. Q.* 22: 29, Feb 1, 1949
29. Hakala, E. W.: Recognition of nerve and tendon severance in the hand, *Surgeon Cir. M. Sect. Far East Command*, 4: 8-14, June 6, 1949,
30. Mason, M. L., and Allen, H. S.: The treatment of compound fractures of the hand, *Clin. N. America*, 29: 15-29, Feb 1, 1949
31. Mason, M. L.: The management of acute injuries of the hand, *Connecticut M. J.*, 13: 414-9, May 5, 1949



32. Burnett, H. A.: An early regime for severe finger injuries, Mil. Surgeon, 105: 25, July 1, 1949
33. Principles of early management of hand injuries, J. Kansas M. Soc., 50: 485-7, Oct 10, 1949
34. Rank, B. K.: Hand injuries, Med. J. Australia, 1: 228-31, Feb 19, 1949
35. Eyre-Brook, A. L.: The problem of cut flexor tendons in fingers, Bristol Med. Chir. J., 66: 63-8, July, 1949
36. The care of hand injuries; lacerated wounds, N. York Med., 5: 19, May 9, 1949
37. Clark, J. M. P.: Treatment of the severed flexor tendon in the hand, Med. Press, Lond., 222: 246-50, Sept 11, 1949
38. Blum, L.: The application of myotomy to tendon repair in the fingers, Surgery, 1948, 999-1000, Dec 6, 1948
39. Murphy, I. D.: An unusual form of De Quervain's syndrome; report of two cases, J. Bone Surg., 31 A: 858-859, Oct 4, 1949
40. Bloom, R.: Bilateral compound palmar ganglia, Proc. R. Soc.M., Lond. 42: 96-98, Feb 2, 1949
41. Macey, H. B., and Murray, R. A.: Fractures about the base of the first metacarpal with special reference to Bennett's fracture, South. M. J., 42: 931-5, Nov 11, 1949
42. Sabaino, D.: Sulle fratture delle ossa del carpo, Infortun. traumat. lavoro, 14: 189-212, Nov-Dec 6, 1949
43. Wilson, D. M.: Fractures of the carpal scaphoid bone, N. Zealand M. J., 48: 167-73, Apr 1949
44. Farrell, J. T., Jr., Williams, B. L., and Cinquino, M. A.: Roentgen findings in injuries of the wrist, Pennsylvania M. J.: 52: 1359-61, Sept 12, 1949
45. Caspers, C. G.: Treatment of carpal navicular injuries, Minnesota M., 32: 992-4, Oct 10, 1949
46. Andersen, K., and Therkelsen, F.: Fractures of the carpal bones with particular reference to the scaphoid, Acta orthop. scand., 19: 143, 1949
47. Andersen, K., and Therkelsen, F.: On fractures of the carpal bones especially of the scaphoid, Acta radiol, Stockh., 31: 343-57, Apr 30, 1949



48. Stack, J. K.: End results of excision of the carpal bones, Arch. Surg., 57: 245-52, Aug 2, 1949
49. Goeringer, C. F.: Follow-up results of surgical treatment for nonunion of the carpal scaphoid bone; report of 19 cases, Arch. Surg., 58: 291-307, Mar 3, 1949
50. Ruttner, J. R.: Zur klinik und pathologischen anatomic der naviculare fraktin pseudarthrose und malacie, Helvet chir. acta, 16: 25-35, Feb, 1949
51. Buxton, S. J. D.: Fractured lunate bone replaced by plastic cast, Proc. R. Soc. M., Lond., 42: 274, Apr 4, 1949
52. Therkelsen, F., and Andersen, K.: Om lunatummalaciens prognoses og behandling, Nord., med., 40: 2384, Dec 17, 1948
53. Insley, J. L.: Splint to control dorsal subluxation of proximal interphalangeal joints of fingers, Brit. M. J., 2: 472, Aug 1949
54. Braithwaite, F., and Watson, J.: Some observations on the treatment of the dorsal burn of the hand, British Journal of Plastic Surgery, 2: 21-31, Apr 1949
55. Engel, D.: Trigger finger produced by excessive heat, Surgery, 26: 659-63, Oct 4, 1949
56. Sprecher, F. E.: Trigger thumb in infants, J. Bone Surg., 31 A: 672-4, July 3, 1949
57. Watson, J. B., Griffiths, E. R., and Plewes, L. W.: Streptomycin in finger infections, Brit. M. J., 1: 1081, June 1949
58. Lennard-Jones, J. E.: Measurement of swelling of an infected finger, Lancet, Lond., 1: 429, Mar 11, 1949
59. Weissenbach, R. J., and Francon, F.: L'osteoarthrite hypertrophique degenerative trapezo-metacarpienne du pouce, Presse therm. clin. 26: 103-9, May-June, 1949
60. Baxter, H., Entin, M., et al: Reconstruction of digits of deformed hands, Canad. M. Ass. J., 61: 401-5, Oct 4, 1949
61. Graham, W. C., and Riordan, D.: Reconstruction of the thumb, N. Y. State J. M., 49: 49-51, Jan 1, 1949
62. Hyroop, G. L.: Transfer of a metacarpal, with or without its digit, for improving the function of the crippled hand, Plastic Reconstructive Surgery, 4: 45-48, Jan 1, 1949
63. Sandblom, P.: Reconstruction of the thumb by phalangization of the first metacarpal bone, Nor. med., 40: 2403-10, Dec 24, 1948



64. Cannon, B., Graham, W. C., and Brown, J. B.: Restoration of grasping function following loss of all five digits, Surgery, 25: 420-3, Mar 3, 1949
65. Young, F.: Cicatricial contractures of the thumb, Surg. Gyn. Obst., 89: 264-70, Sept 3, 1949
66. Chevallier, P. and Beauzamy, P.: Sur un case de guerison medicale de la maladie de Dupuytren', Clinique, Par., 43: 26, Dec-Jan, 1948-1949
67. Thomson, G. R.: The treatment of Dupuytren's contracture with Vitamin E, report of a case, Glasgow M. J., 30: 329-32, Sept 9, 1949
68. King, R. A.: Vitamin E therapy in Dupuytren's contracture; examination of the claim that vitamin therapy is successful, J. Bone Surg., 31 B: 443, Aug 3, 1949
69. Mouchet, A.: La retraction de e sponevrose palmaire; maladie de Dupuytren, Paris med., 39: 1-4, Jan 8, 1949



## CHAPTER XIX

### CONDITIONS INVOLVING THE SPINE AND THORAX

#### EXCLUSIVE OF THE LOWER BACK

By

C. R. Brown, Lt. Colonel, M. C., U. S. A.

Seventeen articles are abstracted in this chapter. Fifteen were reviewed and were felt to represent no new concepts. Nineteen more were classed as case reports and not included. There were fifteen others which I was unable to obtain locally or elsewhere and ten foreign articles of which I obtained reprints, but was unable to obtain translations.

#### Scoliosis

A concept of its pathogenesis is based on the premise that idiopathic scoliosis is due to asymmetrical forces caused by pressure, arrest and distortion of growth as presented by Arkin (1). The pressure is due to gravity alone in minor asymmetries and gravity plus a soft tissue bow string effect in major asymmetries.

Seidler (2) summarizes the known treatments of scoliosis.

After observing the results of surgical treatment of 1500 cases of scoliosis, Von Lackum and Miller (3) conclude that excessive correction of the primary curve results in recurrent primary deviations or new deviations to establish body balance.

Delchef and De Doncker (4) report the results of 14 spinal fusions for structural scoliosis and conclude that operative treatment is the best means for arresting scoliosis in the course of its evolution, but cannot be expected to correct it.

#### Fractures of Spine

An analysis of 166 cases of fractures of the dorsal lumbar spine leads Nicoll (5) to refute the assumption that a perfect anatomical result is indispensable to a perfect functional result in most cases. His hypothesis is that by careful early classification of the injury that certain stable fractures can be recognized which are better treated by functional treatment without reduction or fixation.

Norcross (6) and Turner and Mead (7) summarize the methods of treatment of fractures of the lumbar and dorsal spine.



In fractures of the ankylosed spine writes Bergmann (8), deformities may be corrected and healing occurs very rapidly.

Fractured vertebrae secondary to shock therapy in 24 patients evaluated 10 years later by Polatin and Linn (9) showed no residual neurological findings. Twenty patients were asymptomatic and 4 had nondisabling vague aches.

### Spondylitis

Rheumatoid spondylitis and our current knowledge thereof is summarized by Toone (10).

Spondylitis found in 35 paraplegic cases by Abramson and Kamberg (11) manifested itself as exostoses, diarthrodial joints, ligamentous changes, massive soft tissue ossification, pathological depositis of calcium, sclerosis, and osteoporosis. The absence of neurotrophic lesions added proof that repeated trauma in addition to loss of joint sensibility is necessary to produce the typical joint changes.

Osteitis of the spine may follow prostate or bladder neck surgery. Donahue (12) believes that infections follow the distribution of metastatic carcinoma of the prostate. Calcification and ossification with fixation of the spine may follow.

### Spinal fusion

A method of spinal fusion is described by Michele and Harper (13) which entails fusing the articular facets by bone pegging in addition to iliac strips along the spinous processes and laminae.

The diagnosis of pseudarthrosis of the spine at the site of operative fusion cannot always be established except by exploration, write Ralston and Thompson (14). Localized pain and tenderness, progression of deformity or disease, or roentgenographic evidence of failure of the fusion aid in arriving at the diagnosis. Repair of pseudarthrosis by the technique of these authors was successful in 78 per cent of the cases.

### Anterior Thorax

Surgical repair of the funnel-chest deformity is described by Poppe (15).

Skeletal traction to the sternum by means of one or two modified uterine forceps is used by Kinsella and Bronson (16) in treating traumatic anterior thoracic instability.

Retrosternal dislocation of the clavicle is discussed by Kennedy (17). In this rare form of dislocation, the costoclavicular ligament is torn. Operative reduction and reconstruction by means of fascial sutures (Bankart 1938) is shown to be the most reliable treatment.



## BIBLIOGRAPHY

1. Arkin, A. M.: Scoliosis; a concept of its pathogenesis; preliminary report, J. Mount Sinai Hosp. N. York, 16: 200-2, Sept-Oct, 1949
2. Seidler, F.: Treatment of scoliosis, Surg. Clin. N. America, 29: 207-14, Feb 1949
3. Von Lackum, W. H., and Miller, J. P.: Critical observations of the results in the operative treatment of scoliosis, J. Bone Surg., 31 A: 102-6, Jan 1949
4. Delchef, J., and De Doncker, E.: Indications, technique et resultat de la rachisynthese dans la scoliose, Acta. Orthop. belg., 15: 17-23, Jan 1949
5. Nicoll, E. A.: Fractures of the dorso-lumbar spine, J. Bone Surg., 31 B, 376-94, Aug 1949
6. Norcross, J. R.: Compression fractures of the spine complicated by injury to the spinal cord, Surg. Clin. N. America, 29: 189-94, Feb 1949
7. Turner, V. C., and Mead, N. C.: Compression fractures of the dorsal and lumbar spine in elderly people, Surg. Clin. N. America, 29: 195-205, Feb 1949
8. Bergmann, E. W.: Fractures of the ankylosed spine, J. Bone Surg. 31 A: 669-71, July 1949
9. Polatin, P., and Linn, L.: An orthopedic and neurological follow-up study of vertebral fractures in shock therapy, Am. J. Psychiat., 105: 825-8, May 1949
10. Toone, E. C., Jr.: Rheumatoid spondylitis; observations on the incidence and response to therapy among veterans of the recent war, Ann. Int. M., 30: 733-9, Apr 1949
11. Abramson, D. J., and Kamberg, S.: Spondylitis; pathological ossification and calcification associated with spinal-cord injury, J. Bone Surg., 31 A: 275-83, Apr 1949
12. Donahue, C. D.: Osteitis of the spine, J. Urol. Balt., 61: 405-9, Feb 1949
13. Michele, A. A., and Harper, T. C.: A method of spinal fusion by arthrodesis and iliac bone grafts, Mil. Surgeon, 104: 90-4, Feb 1949
14. Ralston, E. L., and Thompson, W. A. L.: The diagnosis and repair of pseudarthrosis of the spine, Surg. Gyn. Obst., 89: 37-42, July 1949



15. Poppe, J. K.: Surgical repair of the funnel-chest deformity, Northwest M., 48: 189-91, Mar 1949
16. Kinsella, T. J., and Bronson, R. G.: Skeletal traction in the treatment of traumatic anterior thoracic instability, Minnesota M., 32: 486, May 1949
17. Kennedy, J. C.: Retrosternal dislocation of the clavicle, J. Bone Surg., 31 B: 74, Feb 1949



## CHAPTER XX

### THE LOW BACK

By

Joseph W. Batch, Colonel, M. C., U. S. A.

and Staff

The causes of low back pain which have been listed from time to time are multitude. The ascribed principal etiologic factor has varied from time to time as a fadism, passing through periods of lumbago, sciatic neuritis, sacro-iliac strain, and lumbosacral strain. With more concrete evidence at hand, a principal cause of low back pain, particularly that with sciatic radiation, has come to be recognized as that produced by herniation of the nucleus pulposus.

#### General Incidence

As stated by Rechtman (1), "Backache is a symptom, not a disease or a diagnosis. It is so common that few people reach adult life without having back annoyance at some time."

Scuderi (2) has pointed out that it is one of the most confusing of all industrial medical complaints which causes the loss of millions of working hours and costs millions of dollars in medical care and compensation yearly. He urges that early, accurate diagnosis be made by a thorough physical examination to include x-rays. In this way, even though the initial examination be negative, it provides a basis for the observation of subsequent developments.

Tish (3) reports that of the 29,641 Government employees retired during the period between July 1, 1939 and June 30, 1947, with an average age of 57.4 years, 3,737, or 12.6 per cent, were retired because of bone and joint disease. It was the third most common cause for retirement, being exceeded by diseases of the cardiovascular system, 46.0 per cent, and the nervous system, 16.0 per cent. (Ed. Note: No breakdown of this group was made, but it can be presumed because of the age incidence that osteoarthritis was a principal factor.)

Barton (4) in an analysis of 50 cases of back pain, found that lumbosacral and iliolumbar strain were the most common diagnoses. The most common cause of complaint was lifting; the next was falling, particularly by women. Of the 50 cases, 38, or 76.0 per cent, were subjected to x-ray examination. Thirteen, or 34.0 per cent, showed one or more abnormalities on the x-ray. The most common finding was osteoarthritis in 11 cases, 7 of which were 50 years of age or older. In another series of 50,



asymptomatic preplacement x-ray examinations of the back in people 50 years of age revealed 96.0 per cent of them showed osteoarthritic changes. An incidence of spina bifida occulta of 26.0 per cent in those x-rayed is the same as that found in a series of 1,446 x-ray examinations which he has previously reported. Spondylolisthesis was found in 8.0 per cent of those x-rayed as compared to 2.0 per cent found in the asymptomatic series. Age played a factor in that, with the exception of the elderly employees, the severity of back complaints increased directly with the age of the employee.

Robertson (5) also advocates partial work therapy as a means of shortening disability.

### Anatomy and Pathology

The blood supply of the vertebral body is described by Willis (6) beginning with its embryological development. He gives a detailed description of the principal supply to the vertebral body through four branches from the intercostal or lumbar arteries which converge centrally to enter the center of the body beneath the posterior longitudinal ligament.

Roche (7) presents a dissection study of the last four lumbar segments and sacrum removed from a cadaver previously known to have bilateral defects in the neural arch of the fifth lumbar vertebra and a spondylolisthesis. The findings were: (1) the complete absence of an isthmus on one side and on the other side, a defective isthmus strongly fixed by ligaments and three times the length of the normal isthmus above; (2) the abnormal conformations of the laminae and their pseudo-articulations with the pedicles; (3) the structural variations noted in the ligamentum flavum on each side (accessory ligaments, not hypertrophy); (4) the associated presence of a partial developmental lumbarization of the first sacral segment and a sacralization of the first coccygeal segment.

### Etiology

Sloan (8) in a discussion of backache points out that in the young, focal infection must be considered as a causative factor. He also relates that backache is associated with infectious diseases, such as smallpox, scarlet fever, tonsillitis, influenza, undulant fever, and virus infections of the respiratory tract.

In individuals of employable age, sex bears a distinct relationship to the problem. The asthenic female will frequently develop backache when called upon to do too much, a fatigue or frustration reaction. In the older female, similar reactions develop because of fatigue of effort at home and at the office. In the older group of females, pelvic conditions, such as residual infection, ovarian cysts, endometrial tumors, post-menopausal osteoporosis and carcinoma of the pelvis, of the cervix, of the ovaries, of the rectum and colon, must be considered. Endocrine disturbances of the thyroid and pituitary gland may be the causative factor.

In the male, osteoarthritis is one of the commonest conditions.



Myositis, fibrositis, sacro-iliac arthritis, lumbosacral strain and spondylolisthesis are seen. In the young male, Marie-Strumpell's arthritis and tuberculosis may be the causative factors. In the older male, metastatic malignancy of the spine from primary carcinoma of the lung, less often hypernephroma, pancreatic lesions, and often the stomach, should be considered. Paget's disease, multiple myeloma, hyperparathyroidism, prostatic disease, leukemia, Hodgkin's disease, brucellosis and gout may also be the etiological factors.

Rechtman (1) states that "static or postural strain is observed in at least half of the patients who seek treatment for backache." He believes that "congenital anomalies of the spine, as such, are usually not a competent cause for backache; however, they may predispose to arthritic changes, which may be associated with backpain." He does not feel that hypertrophic changes of the spine are significant unless the interarticular joints are involved. (Ed. Note: I concur.) A history of trauma is given in 75.0 per cent of patients with herniated nucleus pulposus. About 95.0 per cent of disk lesions are located in the lumbar region.

Phalen (9) states that the most common type of backache is the mechanical backache, which is caused by some alteration in body balance. This balance may be altered by certain mechanical factors such as faulty posture, obesity, relaxed abdominal musculature, weak back muscles and inequality of length of the lower extremities.

Browder (10) discusses lumbosacral pain under three headings: (1) that limited to the lower back, which initially may be very difficult to diagnose and requires frequent examinations; (2) that with pain in the back radiating into one lower extremity, which is usually caused by a herniated disk; and (3) that with pain in the lower back and radiating down both lower extremities, which may be a disk, but primary or secondary carcinoma is a leading cause.

In a discussion of pelvic pain in women, Mengert (11) classifies the pain as of: (1) genital origin, and (2) extragenital origin which includes pelvic neurosis, the largest cause of pain, and pain originating in other pelvic structures such as the pelvic girdle, urinary tract and intestinal tract.

We are reminded of the prevalence of fibrositis, both primary and secondary, as a cause of backache by Wilson (12) and Sherwood and Zimmerman (13). The latter authors also point out that psychogenic backache can be diagnosed with equal positiveness as backache associated with anatomic pathology.

Because of the medicolegal significance of spondylolysis, Lachapele (14) discusses the various hypothetical causes of this condition. He states that in 50 cases of true spondylolysis he has not encountered a single case related directly or indirectly to trauma sufficient to tear the interarticular ligaments of one of the last three lumbar vertebrae.



The frequent co-existence of spondylolysis and other developmental anomalies of the lumbar spine is greatly in favor of the dysontogenetic theory without considering other arguments.

In an analysis of 869 early ambulated puerperal patients who were intensively exercised, Toaff (15) found 4 cases of pubosacroiliac arthropathy as compared to one case in 1200 puerperal patients with a more moderate routine of early ambulation.

Gillespie (16) in a study of 500 laminectomies for disk protrusions and 500 cases of normal spines, found a higher incidence of spinal abnormalities, 34.2 per cent, in the laminectomy series than in the normal series, 8.8 per cent, which suggests that the abnormal spines tend to be weaker and more susceptible to disk protrusion.

Solomon (17) has pointed out that muscle spasm and increased muscle tonus under certain conditions precipitate an arthritic attack and that psychogenic low back pain may be the result of unconscious stimulation of the voluntary muscles of the back.

Jackson (18) reports on a family in which 26 cases of familial lumbosacral syringomyelia developed in 4 generations. He presents a new concept regarding the significance of developmental errors of the spinal cord and column. He describes status dysraphicus as an inherited constitutional defect, which appears to be an underlying factor in the etiology of syringomyelia and other forms of myelodysplasia.

Dean (19) made a study of disseminated sclerosis in man in South Africa and England and compared it with the incidence of swayback disease in sheep, which is related to copper deficiency. He cites the report of Campbell, et al (1947) of 4 cases of disseminated sclerosis out of 7 workers on research into swayback disease, an incidence much greater than the average 160 cases per million in England. Since a virus responsible for disseminated sclerosis is stated to have been isolated by Margulis, Soloviev and Shubaldze (1946), he states that perhaps, therefore, an infective factor is common to both diseases, a relative copper deficiency in the host being the predisposing factor. He suggests the use of copper sulfate be given a trial in the treatment of disseminated sclerosis in man.

#### Variety of Low Back Entities

Hellstadius (20) reports on a series of 16 cases with anterior paradiscal defects. He believes that the defect on the anterior surface of the body of the vertebra communicates with the disk and is due to impaction of the nucleus pulposus into the body similar to Schmorl's node.

An unusual case of spondylolisthesis secondary to unilateral isthmus defect with a rotational subluxation of the opposite intervertebral



articulation in a patient with spina bifida is described by Anderson and Breck (21).

A case of bilateral drop foot in a patient with spondylolisthesis is reported by Arden (22).

Mentzer (23) reports on 150 cases of coccygodynia. There are two types, true and referred; the latter outnumbers the true 12 to 1. Focal infection is thought to be the etiological factor in referred coccygodynia. Treatment is primarily massage of the levator and coccygeus muscles with gratifying results. Infection is eliminated by surgery or medical treatment.

A case of coccygeal arthritis developing in a 23-year old female two months after spontaneous delivery of her third child is reported by Notter (24).

In a discussion of intraspinal neoplasma, Adson (25) states that most are benign and that 80.0 per cent are operable. The diagnosis is based on characteristic radicular pain, constant or intermittent, and may be aggravated by sneezing or straining, awakening the patient after four to six hours of sleep. This indicates compression of nerve roots and is the first symptomatologic phase. The second phase is that of beginning compression of the cord and these symptoms vary with the location of the tumor mass. They are motor or sensory. The third phase is that of paralysis below the tumor and is caused by extreme compression of the cord. Intramedullary tumors rarely produce pain. A complete neurologic examination combined with spinal puncture and roentgenographic studies of the spine may be necessary for diagnosis and localization of the tumor. In his series of cases the location of the tumor was as follows: 18.0 per cent, cervical region; 54.0 per cent, thoracic region; 21.0 per cent, lumbar region; and 7.0 per cent, sacral region. With reference to type of tumor, there were 29.0 per cent neurofibromas, 25.0 per cent meningiomas, 8.5 per cent extramedullary hemangio-endotheliomas, 6.0 per cent miscellaneous extramedullary tumors, 6.0 per cent extramedullary ependymomas, 11.5 per cent intramedullary tumors, 10.0 per cent sarcomas and 4.0 per cent chordomas. Metastatic tumors, inflammatory lesions and herniated disks must be considered in the differential diagnosis.

Schneider, Webster, and Lofstrom (26) report a follow-up on 56 patients with penetrating wounds of the spine. Sixteen, or 29.0 per cent, had no neurological disability; 20, or 36.3 per cent, had no improvement - 15 of these were paraplegics. Four of the 19 originally complete paraplegics developed partial recovery. Forty-three per cent of the group were engaged in earning all or part of their support.

A study of the effect of injury to the spinal cord and cauda equina on the sexual potency of man is reported by Munro, Horne and Paull (27). They discuss the neuroanatomy and physiology of the male generative organs, the various effects of cord injury. They conclude that unless he has a destructive lesion of the sacral cord, a transection of the cauda



equina or injury to the cord between the sixth thoracic and third lumbar segments extensive enough to interrupt completely the thoracolumbar sympathetic outflow, a patient should be potent. They present one case of a patient with complete paralysis below the xiphoid who successfully impregnated his wife.

Horne (28) reports a study on fertility in 18 human males with injury to the spinal cord. There seemed to be no correlation between the level or type of injury and total sperm count, although the counts were lower in cauda equina and lumbosacral cord injuries. Nine of the patients had no spermatozoa or were nonmotile. One patient with a lesion at C-5 and another at T-6 had successfully impregnated their wives.

Ankylosing spondylitis, a condition occurring primarily in males in the second to fourth decades, has as its commonest complaint backache in the lumbosacral area and the condition is very frequently misdiagnosed. After remissions and exacerbations, it may progress to complete rigidity of the spine and hips. Hart, et al (29) report a one to six year follow-up study on 43 old cases and include an additional 30 fresh cases. Mowbray, et al (30) report on the radiological, clinical and biochemical investigations in 137 cases, consisting of 118 male and 19 female patients. Simpson and Stevenson (31) present an analysis of 200 cases of ankylosing spondylitis. Each of the above authors has concluded that ankylosing spondylitis is a separate entity and not a variant of rheumatoid arthritis. The differences are in sex distribution, character of the disease, radiographic appearance, reaction to x-ray therapy, response to gold therapy, and biochemically in the negative serum flocculation test and normal 17 keto steroid excretion in ankylosing spondylitis.

Two instruments, the pendulum arthrometer for measuring hip motion, and the spondylometer for measuring motion in the spine in cases of ankylosing spondylitis, are described by Dunham (32).

In a historical discussion on rupture of the intervertebral disk, Mixter (33) states that probably the first illustration of this lesion appeared in an old book by Charles Bell written in 1824. Like so many other later references it was concealed under the diagnosis of a fracture. In 1896 Kocher reported a case history of a man who fell 100 feet, landing on his feet. Autopsy findings revealed rupture of the first lumbar intervertebral disk. In 1907 Krause reported a case of enchondroma of the vertebral column compressing the cauda equina on which he operated. In 1909 Krause and Oppenheim reported another case with what are now recognized as symptoms of the disk complex. What was reported to be a tumor was removed from the area opposite the second lumbar disk anterior to the dura. This was most probably a disk. In 1911 Middleton and Teacher in England and Goldthwait in this country reported cases of severe injury to the intervertebral disk with transverse lesions of the cord. During the next seventeen years no mention is found of



isolated injury of the intervertebral disk but there are reports by Frazier, Elsberg, Stookey, Ott, Adson, and Mixer of enchondromas which are now known to have been ruptured disks and not true tumors. During the latter part of this period (1927) Schmorl began his studies. In 1929 Dandy reported two cases of transverse lesions of the cauda equina caused by free fragments of disk tissue in the spinal canal. He was the first to postulate this as a cause of sciatica. In 1930 and 1931, Alajouanine and Petit-Dutaillis and Crouzon, Petit-Dutaillis and Christophe reported two similar cases. Bucy reported one case and collected fifteen similar cases which he called enchondromas. He gives a very interesting account of the study of this condition by Barr and himself which led to the publication of their paper August 2, 1934.

Since this time the story of herniation of the disk has grown and come to be recognized as a major etiologic factor of low back pain with sciatic radiation. Even so, with a wealth of literature on the subject, the condition is not fully understood and there remains much controversy on this subject as pointed out by Alpers (34), who gives an interesting discussion on the various concepts of the pathogenesis of sciatica.

The anatomy, pathology, symptoms, signs, diagnosis, and treatment of herniated intervertebral disks are discussed by Chandler (35) and Keats (36). Chandler speculates that some of the unexplained pain may be due to irritation from products of disintegration of the nucleus.

Schneider (37) reports two cases of traumatic herniation of the nucleus pulposus causing acute cord compression and paralysis.

The posterior tibial nerve sign elicited by compression over this nerve is reported to be more accurate than the Lasègue sign by Sloboziano (38). He states that the posterior tibial nerve sign is present in 85.3 per cent of cases and the Lasègue sign present in 71.0 per cent of cases of sciatica.

Hoffman (39) states that nerve root involvement occurs in osteoarthritis, ankylosing spondylitis and rheumatoid arthritis, particularly osteoarthritis. He considers the involvement due to settling down of the vertebral bodies with bulging of the annulus and effusion in the intervertebral joint further encroaching on the foraminal space.

Hadley (40) states that foramina at which there is motion are normally five or six times as large as the diameter of the nerve which passes through. Foramina not the site of movement are only slightly larger than the nerves which traverse them. Dorsal extension and lateral flexion may decrease the diameter by as much as one-third. He believes that this remaining cushion space for the nerve may be encroached upon by trauma, either fracture or dislocation. He further states that osteoarthritis is responsible for many cases of encroachment with spurs projecting backward from the disk in front, or forward from the margin of the posterior articulation. With thinning of the disk space, the lower vertebra becomes wedged forward - a reverse spondylolisthesis, decreasing



the anteroposterior diameter of the foramen. Along with this subluxation the upper tip of the lower articular process becomes thrust forward into the foraminal canal. Adhesions and fibrotic changes further contribute to the narrowing of the cushion space with a loss of the 1:5 ratio and causing nerve root compression.

McBride (41) states that with adequate history and physical examination there should be little confusion at arriving at an accurate diagnosis of a herniated disk and describes a number of tests employed.

#### Roentgenographic Examination

In a discussion on the roentgenographic examination of the spine, Case (42) states that good anteroposterior lateral and oblique films are necessary for proper interpretation and that it is better to take a number of smaller films rather than trying to get the entire spine on one film.

Cunningham (43) describes a technic employed for screening candidates for the Los Angeles Police Department whereby the anteroposterior and lateral views of the lumbar spine are placed on one 14 x 17 film with considerable savings in film cost.

Etter and Carabello (44) made x-ray studies of dried disarticulated spinal column with markers placed to indicate the respective right and left apophyseal joints. Their findings indicate that regardless of terminology or position used, the postero-oblique views show the apophyseal joints of the same side and all antero-oblique views show the opposite joints.

Varicosities of the spinal canal veins which produce symptoms indistinguishable from herniation of a disk is discussed by Platt (45). Two case histories are presented. He describes the roentgenographic features of varicosities by myelography. They are: (1) Defect is on a plane other than that of the intervertebral space; (2) Multiple varicosities produce serrated defects on the margin of the column of oil and out of relation to the disk space; (3) Inconsistency of defect due to compressibility of the varix; and (4) Trapping of oil in tortuous varicose furrows gives a characteristic picture.

Murphy (46) reports two cases in which the clinical evidence located the disk lesion on one side, whereas myelography revealed the defect on the opposite side. Exploration was performed on the side in which the defect was demonstrated by the myelogram. A disk was removed in each case which was pressing the cord to the opposite side, thereby causing the contralateral pain.

Chatterton (47) presents a case of a 39-year old female with spondylolisthesis at the lumbosacral joint and spondylolysis between L-4 and L-5. A myelogram was performed with the patient prone and left side up. No abnormality was noted on the first excursion of the media. On the second



excursion with the patient standing on her left foot, pain suddenly became manifest and a classical extradural defect in the column of the media became apparent at the level of the lumbosacral joint on the left side. This is good radiographic evidence to show that intermittent protrusion of a ruptured disk does occur, accounting for intermittent symptoms.

In an analysis of sixty pantopaque studies for herniation of the nucleus pulposus, Rees and Donely (48) found the examination to be positive and accurate in 86.8 per cent of the cases. There were 6.6 per cent of negative findings in which disks were found at surgery. There was one case, 1.6 per cent, false positive in which no disk was found at surgery and three cases, or 5.0 per cent, in which there were radiographic errors in localization of the disk. They conclude that the test gives accurate information in the majority of cases, but that negative myelographic findings are unreliable if the dural sac is narrow and measures less than twelve millimeters.

### Treatment

The treatment of herniation of the nucleus pulposus is generally described as being conservative or surgical.

Sheldon (49) points out that all cases are not necessarily surgical, and that with accurate diagnosis and treatment nearly all can be relieved of their pain. He states that conservative measures, such as infiltration of trigger points with local anesthesia, supports, a low back brace, and traction, should be tried initially. When conservative measures fail, surgery should be considered and a myelogram performed, which he states is about 65.0 per cent accurate. Decompression of the nerve root, either by removal of the herniated disk or foraminectomy, is the goal. Spinal fusions are performed when instability of the back is demonstrated at the time of surgery.

Wagner (50) believes that conservative treatment of industrial backs using the Williams flexion technique gives satisfactory results. Colonna and Friedenberg (51) observed 28 patients with the clinical diagnosis of displaced lumbar intervertebral disks, supported by oil myelography who were treated conservatively. Twenty-nine per cent remained free of pain for periods longer than one year; 39 per cent suffered insufficient residual pain to cause disability; 32 per cent were disabled by recurring attacks or constant pain. They conclude that these results compare unfavorably with results obtained in carefully selected operative series.

Emma and Hershey (52) recommend the use of endotracheal anesthesia of nitrous oxide potentiated by 0.1 per cent sodium pentothal. (Ed. Note: Local anesthesia gives excellent results with less hemorrhage in the operative site.)

The kneeling position of the patient for all explorations of the spinal canal in the lumbar region is advocated by Ecker (53). Advantages



noted are: (1) maximal space between laminae; (2) greatly diminished bleeding from the epidural veins due to the lack of pressure on the abdomen; (3) relaxation of the affected nerve root by maximal flexion of the knees; and (4) maximal flexion of the bodies of the lumbar vertebrae. (Ed. Note: The lateral decubitus position offers these and other advantages.)

In an analysis of 346 cases of low back pain with sciatic radiation, Crawford, Mitchell and Granger (54) found 40 per cent are due to frank rupture of the disk, 20 per cent to a prominent disk and 38 per cent to compression of a nerve in or around the foramen. They therefore consider it necessary to remove the inferior articular process to uncap the nerve root for better visualization and decompression of the nerve root.

Keats (36) also advocates foraminotomy to locate the cause of pressure when not accounted for otherwise. He advocates spinal fusion following all procedures involving the lumbosacral joint and the adjacent intervertebral foramen.

Lievre (55) advocates fusion of involved areas to prevent residuals of sciatica.

Rosner (56) believes that removal of the spinous process and laminae of involved vertebrae is necessary in order that complete exploration and removal of the disk be done. He criticizes spinal fusion alone because it does not remove the pathology and results in incapacitation for six months. He further believes that if a patient recovers from back pain with sciatic radiation on conservative measures, the underlying pathology is a subluxation of the disk rather than a complete rupture.

Echols and Rehfeldt (57) studied 32 cases which were explored but no herniation of the disk found. In reviewing the operative notes, they found adequate cause of symptoms in 18 cases; in 14 cases which remained no pathologic condition could be demonstrated. The reasons postulated are: (1) inadequate exploration; (2) unrecognized intradural lesions; (3) root pressure within the intervertebral foramen; (4) pressure within the sacral canal; or, (5) is there a toxic radiculitis resembling the disk syndrome.

In a follow-up on 40 of 175 explorations for herniated disks, Wertheimer (58) found 34, or 85.0 per cent, had excellent or good results. Grafts were done in 95 of the total cases with excellent results.

Miller and Vanderfield (59) report a one to ten year follow-up on 108 cases. Ninety-seven, or 90.0 per cent, were back to original work, either asymptomatic (54) or with insignificant residual or recurrent symptoms (43). Ten patients were unable to return to their former work and three were unable to do any work.

Miller, Edmunds and Armstrong (60) report on the end results of 82 cases of surgery for low back pain. They claim 81.0 per cent excellent



to good results. Spinal fusion was performed in all and screw fixation of the apophyseal joints in 71.0 per cent of their cases.

Raaf and Berglund (61) report on a series of 224 patients explored for protruded intervertebral disk. The preoperative clinical diagnosis was 81.25 per cent correct. One hundred and three of these patients had pantopaque studies with an accuracy of 76.7 per cent. Eighty-eight compensation cases operated upon lost an average of 365.5 working days. The average cost to the insurance carrier handling each of the 88 cases was \$3,188.75. A one to ten year follow-up on 160 of the 224 patients revealed that 61.25 per cent obtained excellent results, 28.75 per cent good results, and 10.0 per cent poor results. Private patients reported better results following operation than did compensation patients. In the series of 224 patients, 37.9 per cent had spinal fusion at the time the protrusion was removed.

Echols (62) reports 91.0 per cent of good results by mere excision of the herniated disk.

Hall (63) reports a series of 93 laminectomies on service personnel, 88 of whom had disk protrusion at operation. A high percentage had residual pain in the follow-up of 34 patients. However, 70 per cent were able to return to work.

Spurling and Grantham (64) report a follow-up study on 327 cases operated upon for ruptured lumbar intervertebral disks in private patients. Forty per cent were complete cures. Thirty-nine per cent had more or less unsatisfactory results. In the remaining 21 per cent, the results were only fairly successful or operation was regarded as a failure. More than 85 per cent of the patients were able to return to their previous occupations, while only 2.2 per cent were unable to work at all. Operation consisted in simple removal of diseased disk.

In an analysis of 113 industrial cases of intervertebral disk injury operated upon, Marble and Bishop (65) found 66 per cent were rated as excellent and good, 34 per cent were rated as poor or bad results. Neurosurgeons performed 50 operations of which 76 per cent were rated as excellent or good and 24 per cent as poor or bad results. Orthopedic surgeons performed 39 operations, of which 59 per cent were rated as excellent or good and 41 per cent as poor or bad. General surgeons performed 12 operations of which 58 per cent were rated as excellent or good, and 42 per cent as poor or bad. Those cases in which a spinal fusion was performed, mainly by orthopedic surgeons, were more unfavorable. There were 35 spinal fusions performed with 16 or 46 per cent excellent or good results, and 19 or 54 per cent, poor or bad results. Ratings were based on the time interval of the patient to return to work. The average cost for compensation varied from \$661.00 to \$4,977.00, and the cost of medical care varied from \$691.00 to \$1,087.00, being proportionately greater the longer the time interval before returning to work.

Kraus (66) presents a simple formula for testing and evaluating muscle strength of the trunk muscles which should be employed individually



prior to prescribing an exercise routine for the back. He claims 77.0 per cent of 143 patients with back pain without an anatomic diagnosis were relieved by exercises. In an acute back, he advocates surface anesthesia with ethyl chloride with gentle, gradually increasing exercises for the relief of pain prior to employing the muscle test.

Manipulation of the lumbar spine is rarely indicated according to Bastow and Crisp (67). In general, lumbar pain secondary to a disk lesion is best treated by rest. Manipulation, if any, should be limited to traction, lateral flexion and extension.

Spilthoff (68) believes that a frequent cause of lumbar backache is a simple breakdown of the supporting structures of the back due to excessive demands upon the part. He describes and advocates the use of a pelvic flexion cast and flexion exercises for the condition. He states that relief is obtained in the majority of cases.

Watt (69) believes that the symptoms of bouts of backache, urinary frequency, iliac fossa aching and general pelvic dragging in cases wearing strong corsets are due to compression of firm fat around the inferior vena cava with obstruction to the venous return from the lower extremities, with stagnation in the pelvic veins. The symptoms can be relieved by dispensing with the corset or wearing it loosely. The syndrome can be prevented by gradually increasing the abdominal compression over a period of months.

A trephine needle and technique employed to biopsy the lumbar vertebral bodies are described by Siffert and Arkin (70).

Masseboeuf (71) describes a technical improvement in the interlaminar approach to the herniated disk first employed by Jean Guillaume. They claim that by going through the muscular region without disinserting it, the anatomic integrity of the back is maintained, thereby preventing postoperative lumbar pain. They claim 93 per cent success in over 1,000 cases.

Michele and Krueger (72) describe 5 methods of direct approach to the thoracic and lumbar vertebral bodies, whereby adequate biopsy material may be obtained for accurate diagnosis and therapy instituted.

In discussing lumbosacral fusion, King (73) advocates a technic of internal fixation with metal screws through the intervertebral articulations. In his series of 44 cases, 40, or 90 per cent, had solid bony fusion two to seven years postoperatively. McBride (74) describes a facet bone block under interlaminar distraction. He has employed this method in 135 cases with gratifying results.

Sicard (75) employs a tibial graft notched at each end which is mortised between the spinous process of L-4 and S-1 after resection of the spinous process of L-5.



Miller, McCollough and Jewett (76) report a type of fusion which is a combination of the McBride transfacet bone block, the H-type graft similar in principle to that reported by Sicard, and a modified Hibbs procedure. With this method they claim early graduated ambulation is possible with a brace in about three weeks. They report 27 cases; in only one case the result was poor because the brace was removed too early. (Ed. Note: An excellent all-inclusive procedure. Follow-up period on cases is too short to evaluate.)

Thompson and Ralston (77) reviewed the results of all spine fusion operations of varying techniques performed during the period 1936 to 1945 at the New York Orthopaedic Dispensary and Hospital. They found that of 1,096 patients followed at least one year from the time of surgery there was a 16.6 per cent incidence of pseudarthrosis.

A discussion of x-ray treatment in lumbosacral pain syndromes is presented by Sarasin (78) and is very beneficial in ankylosing spondylitis. It is also stated to be beneficial in small doses in osteoarthritis and sciatica.

A case of sacro-iliac disarticulation is reported by Johnson and Kearney (79) for synovioma in the iliac region. The common iliac artery was ligated instead of the external iliac as advocated by Pack and Ehrlich. Convalescence was satisfactory and the wound healed by primary intention.

A discussion of surgery of the five sacral nerves is presented by Guillaume et al (80). They review the areas supplied by each of these nerves and give indications and contraindications for nerve section associated with chronic pain in the areas supplied by them.

Intractable pain associated with the low back, of unknown etiology with neurosis has been observed by Scott and Wycis, (81). In a series of five cases they conclude that absolute alcohol, rhizotomy, spinothamic tractectomy and sympathectomy are contraindicated. Prefrontal lobectomy may proved to be the procedure of choice in this type of patient, especially if there is an associated narcotic addiction.

Badaro and Berbir (82) report a case of x-ray dermatitis in the sacrococcygeal region secondary to radiation therapy for carcinoma of the cervix which was successfully treated by presacral neurectomy.

In the treatment of 72 cases of low back pain which failed to respond to other types of therapy because of underlying personality problems, Bendheim (83) instituted psychotherapy. Narcotherapy was the type of psychotherapy employed and in each instance the psychogenic nature of the disorder was elicited. Of the series, 29 were private and mainly non-traumatic and 43 were nonprivate and mainly traumatic. The results of therapy were much better in the private group than in the nonprivate group.



## BIBLIOGRAPHY

1. Rechtman, A. M.: Backache and the orthopedic surgeon, *Indust. M.*, 18: 203-9, May 1949
2. Scuderi, C.: Backache from an industrial standpoint, *Surg. Clin. N. America*, 29: 215-21, Feb 1949
3. Tish, A.: Prevalence of disabilities among government employees, *Occup. med.*, 5: 634-9, June 1948
4. Barton, P. N.: Analysis of 50 cases of back pain, *Indust. M.*, 18: 391-3, Sept 1949
5. Robertson, R. C. L.: Ruptured intervertebral disc in industry, *South. M. J.*, 42: 891-5, Oct 1949
6. Willis, Theodore; Nutrient arteries of vertebral bodies, *J. Bone Surg.*, 31 A: 538-40, July 1949
7. Roche, Maurice B.: Pathology of neural arch defects, *J. Bone Surg.*, 31 A: 529-37, July 1949
8. Sloan, L. H.: Low back pain; the medical viewpoint, *Indust. M.*, 18: 3-5, Jan 1949
9. Phalen, G. S.: The diagnosis and treatment of mechanical backache, *J. Am. M. Ass.*, 141: 445-8, Oct 15, 1949
10. Browder, J.: Pain in the lumbosacral region, *Bull. N. York Acad. M.* 25: 434-40, July 1949
11. Mengert, W. F.: Pelvic pain in women, *J. Iowa M. Soc.*, 39: 417-19, Sept 1949
12. Wilson, G. D.: Fibrositis, *South M. J.*, 42: 383-92, May 1949
13. Sherwood, K. K., and Zimmerman, B.: Fibrositis and psychogenic backache, *Northwest M.*, 48: 465-9, July 1949
14. Jachapele, A. P.: La spondylolyse est-elle traumatique? *J. de radiol. et d'electrol.*, 30: 608, 1949
15. Toaff, R.: Arthropathy of pelvic joints after overexertion in early ambulated puerperal patients, *Acta med. orient. Jerusalem*, 8: 86-9, May-June, 1949
16. Gillespie, H. W.: The significance of congenital lumbosacral abnormalities, *Brit. J. Radiol.*, 22: 270-5, May 1949



17. Solomon, A. P.: Low back pain; the psychosomatic viewpoint; a preliminary report, *Indust. M.*, 18: 6-12, Jan 1949
18. Jackson, M.: Familial lumbosacral syringomyelia and the significance of developmental errors of the spinal cord and column, *Med. J. Australia*, 1: 433-9, Apr 2, 1949
19. Dean, G.: Disseminated sclerosis in South Africa; its relationship to swayback disease and suggested treatment, *Brit. M. J.*, 1: 842-5, May 14, 1949
20. Hellstadius, A.: A contribution to the question of the origin of anterior paradiscal defects and so-called persisting apophyses in the vertebral bodies, *Acta orthop. Scand.*, 18: 377-86, 1948-1949
21. Anderson, K. J., and Breck, L. W.: Spondylolisthesis; a rare variant with a unilateral isthmus defect and slight displacement, *South. Surgeon*, 15: 470-7, July 1949
22. Arden, G. P.: Spondylolisthesis with bilateral drop foot, *Proc. R. Soc. M., Lond.*, 42: 601, Aug 1949
23. Mentzer, C. G.: Coccygodynia; report of 150 cases, *J. Florida M. Ass.*, 36: 27-9, July 1949
24. Notter, A.: Luxation en avant du coccyx apres arthritie coccygienne survenue 2 mois apres un accochement spontane, *Lyon med.*, 180: 884, Dec 19, 1948
25. Adson, A. W.: Surgical lesions of the spinal cord; diagnosis and treatment, *Mississippi Valley M. J.*, 71: 117-23, July 1949
26. Schneider, R. C., Webster, J. E., and Lofstrom, J. E.: A follow-up report of spinal cord injuries in a group of World War II patients *J. Neurosurg.*, 6: 118-26, Mar 1949
27. Munro, D., Horne, H. W., Jr., and Paull, D. P.: The effect of injury to the spinal cord and cauda equina on the sexual potency of men, *N. England J. M.*, 239: 903-11, Dec 9, 1948
28. Horne, H. W., Paull, D. P., and Munro, D.: Fertility studies in the human male with traumatic injuries of the spinal cord and cauda equina, *N. Eng. J. M.*, 239: 959-61, Dec 1948
29. Hart, F. D., Robinson, K. C., et al: Ankylosing spondylitis, *Q. J. Med.*, Oxf., 18: 217-34, July 1949
30. Mowbray, R., Latner, A. L., and Middlemiss, J. H.: Ankylosing spondylitis; radiological, clinical and biochemical investigations in a series of cases, *Q. J. Med.*, Oxf., 18: 187-201, July 1949



31. Simpson, N. R. W., and Stevenson, C. J.: An analysis of 200 cases of ankylosing spondylitis, *Brit. M. J.*, 1: 214-6, Feb 5, 1949
32. Dunham, W. F.: Ankylosing spondylitis; measurement of hip and spine movements, *Brit. J. Phys. M.*, 12: 126-9, Sept-Oct 1949
33. Mixer, W. J.: Rupture of the intervertebral disk; a short history of its evolution as a syndrome of importance to the surgeon, *J. Am. M. Ass.*, 140: 278-82, May 21, 1949
34. Alpers, B. J.: The diagnosis and treatment of sciatica, *Bull. Chicago M. Soc.*, 52: 127-32, Aug 13, 1949
35. Chandler, F. A.: Herniated intervertebral disk, *Indust. M.*, 18: 283-7, July 1949
36. Keats, S.: Management of pain associated with disturbances of the intervertebral disc, *J. M. Soc. N. Jersey*, 46: 376-9, Aug 1949
37. Schneider, R. C.: Acute traumatic posterior dislocation of an intervertebral disc with paralysis, *J. Bone Surg.*, 31 A: 566-70, July 1949
38. Sloboziano, H.: Le signe du tibial posterieur dans la sciatique, *Paris med.*, 39: 149, Apr 16, 1949
39. Hoffman, H. L.: Nerve root involvement in vertebral arthritis, *Proc. R. Soc. M., Lond.*, 42: 575-9, Aug 1949
40. Hadley, L. A.: Constriction of the intervertebral foramen; a cause of nerve root pressure, *J. Am. M. Ass.*, 140: 473-6, June 4, 1949
41. McBride, E. D.: Low back pain; the value of specific tests in differential diagnosis, *Rocky Mountain M. J.*, 46: 631-8, Aug 1949
42. Case, J. T.: Low back pain, the x-ray viewpoint, *Indust. M.*, 18: 13-15, Jan 1949
43. Cunningham, A. G.: A method for placing both anteroposterior and lateral projections of the lumbar area on one film, *X-ray Technician*, 20: 356, May 1949
44. Etter, L. F., and Carabello, N. C.: Roentgen anatomy of oblique views of the lumbar spine, *Am. J. Roentg.*, 61: 699-705, May 1949
45. Piatt, A. D.: Varicosities of the spinal canal veins in the lumbar region simulating disc herniations, *Ohio M. J.*, 45: 979-82, Oct 1949
46. Murphy, J. P.: Lumbar intervertebral disc protrusion contralateral to the side of symptoms and signs; myelographic verification in two cases, *Am. J. Roent.*, 61: 77-9, Jan 1949



47. Chatterton, C. C., and Nash, L. A.: Radiographic evidence of intermittent protrusion of an intervertebral disc; case report, *Minn. M.*, 32: 730, July 1949
48. Rees, S. E., and Donely, C. E.: The accuracy of pantopaque studies in diagnosis of herniated intervertebral disc, *Northwest M.*, 48: 180-2, Mar 1949
49. Sheldon, K. W.: The false fear of disc surgery, *Nebraska M. J.*, 34: 326-9, Sept 1949
50. Wagner, C. J.: Low back pain and sciatica, *Am. J. Surg.*, 78: 203-9, Aug 1949
51. Colonna, P. C., and Friedenber, Z. B.: The disc syndrome; results of the conservative care of patients with positive myelograms, *J. Bone Surg.*, 31 A: 614-8, July 1949
52. Emma, E., and Hershey, S. G.: Management of anesthesia for laminectomy, *Current Res. Anesth.*, 28: 50-3, Jan-Feb, 1949
53. Ecker, A.: Kneeling position for operations on the lumbar spine; especially for protruded intervertebral disc, *Surgery*, 25: 112, Jan 1949
54. Crawford, A. S., Mitchell, C. L., and Granger, G. R.: Surgical treatment of low back pain with sciatic radiation; preliminary report on 346 cases, *Arch. Surg.*, 59: 724-33, Sept 1949
55. Lievre, J. A.: Le traitement chirurgical de la sciatique, *Presse Med.*, 57: 147-9, Feb 12, 1949
56. Rosner, S.: The problem of the ruptured lumbar intervertebral disc, *J. Insur. M.*, 4: 11-3, June-Aug 1949
57. Echols, D. H., and Rehfeldt, F. C.: Failure to disclose ruptured intervertebral disks in 32 operations for sciatica, *J. Neurosurg.*, 6: 376-82, Sept 1949
58. Wertheimer, P., Mansuy, L., et al: A propos des lombo-sciatiques et de leur traitement chirurgical, *Lyon chir.*, 44: 240-2, Mar-Apr, 1949
59. Miller, D., and Vanderfield, G. K.: The results of operative treatment of intervertebral disk protrusion; a follow-up report of 108 cases, *Med. J. Australia*, 2: 283, Aug 20, 1949
60. Miller, J. W.; Edmunds, L. H., and Armstrong, T. M.: Surgical treatment of low back pain; an end result of 82 cases, *Northwest M.* 48: 614-6, Sept 1949



61. Raaf, J., and Berglund, G.: Results of operations for lumbar protruded intervertebral disc, *J. Neurosurg.*, 6: 160-8, Mar 1949
62. Echols, D. H.: Surgical treatment of sciatica; results 3 to 8 years after operation, *Arch. Neur. Psychiat.*, Chic., 61: 672-9, June 1949
63. Hall, H.: Review of 93 laminectomies for low backache and crural pain, *J. R. Army M. Corps*, 91: 156, Oct 1948
64. Spurling, R. G., and Grantham, E. G.: The end results of surgery of ruptured lumbar intervertebral discs, a follow-up of 327 cases, *J. Neurosurg.*, 6: 57-64, Jan 1949
65. Marble, H. C., and Bishop, W. A.: Intervertebral disc injury; an analysis of 113 industrial cases, *J. Indust. Hyg.*, 31: 46-50, Jan 1949
66. Kraus, H.: The role of therapeutic exercises in the treatment of low back pain, *N. York State J. M.*, 49: 1523, July 1, 1949
67. Bastow, J., Crisp, E. J., et al: Discussion on manipulative treatment, *Proc. R. Soc. M.*, Lond., 42: 417-20, June 1949
68. Splithoff, C. A.: Pelvic flexion cast in treatment of chronic lumbar backache, *Am. J. Surg.*, 78: 384, Sept 1949
69. Watt, L. O.: Strong corsets and pelvic congestion, *Brit. M. J.*, 1: 324, Feb 19, 1949
70. Siffert, R. S., and Arkin, A. M.: Trephine biopsy of bone with special reference to the lumbar vertebral bodies, *J. Bone Surg.*, 31 A: 146-9, Jan 1949
71. Masseurboeuf, A.: Une technique neuro-chirurgicale nouvelle du traitement de la sciatique discale, la voie trans-musculaire, *Maroc. med.*, 28: 180-2, Apr 1949
72. Michele, A. A., and Krueger, F. J.: Surgical approach to the vertebral body, *J. Bone Surg.*, 31 A: 873-878, Oct 1949
73. King, D.: Internal fixation for lumbosacral fusion, *J. Bone Surg.*, 30 A: 560-5, July 1948
74. McBride, E. D.: A mortised transfacet bone block for lumbosacral fusion, *J. Bone Surg.*, 31 A: 385-93, Apr 1949
75. Sicard, A.: L'arthrodise lombo-sacree dans les lombalgies et les lombo-sciatiques, *J. Chir.*, Par., 65: 5-16, 1949
76. Miller, R., McCollough, N. C., and Jewett, F. L.: Early ambulation of the low-fused back, *J. Florida M. Ass.*, 36: 211-15, Oct 1949



77. Thompson, W. A. L., and Ralston, E. L.: Pseudarthrosis following spine fusion, *J. Bone Surg.*, 31 A: 400-5, Apr 1949
78. Sarasin, R.: La radiotherapie des syndromes douloureux lombosacres, *Praxis, Bern*, 38: 487, May 26, 1949
79. Johnson, F. H., and Kearney, E. A.: Sacro-iliac disarticulation, *U. S. Naval M. Bull.*, 49: 110-2, Jan-Feb, 1949
80. Guillaume, J., Seze, S. De, et al: Chirurgie des dernieres racines sacrees, *Presse med.*, 57: 85-87, Jan 21, 1949
81. Scott, M., and Wycis, H. T.: Survey of the value of neurosurgical treatment for the relief of intractable pain, *Am. J. Surg.*, 77: 718-36, June 1949
82. Badaro, J., and Berbir, A.: Radiodermite de la region sacro-coccygienne; resection du nerf presacre, guerison, *Rev. med. moyen-orient*, 5: 490-3, Oct-Dec, 1948 .
83. Bendheim, C. L.: Psychiatric aspects of low back syndrome; narcotherapeutic approach, *Arizona Med.*, 6: 30-34, July 1949



## CHAPTER XXI

### AMPUTATIONS, APPARATUS, AND TECHNIC

By

August W. Spittler, Colonel, M. C., U. S. A., Editor  
And  
Edwin W. Hakala, Colonel, M. C., U. S. A., Ass't Editor

One hundred and twenty-one articles relating to amputations appeared in the world literature in 1949 and 50 were selected for review as representing progress in orthopedic surgery.

Considering indications for amputation, Hulnik, Highsmith, and Boutin (1) report that 42 per cent of 600 amputations performed at Walter Reed General Hospital during two years beginning October, 1945, were done in cases of complex injury which would have maintained viability of the extremity but with seriously limited function. The primary indications for amputation were (1) irreparable nerve damage, (2) injury to major vessels without gangrene, (3) bone defects with excessive shortening, (4) skin defects, (5) osteomyelitis, and (6) partial foot amputations that did not preserve the bases of the metatarsals. Spittler and Taylor (2) evaluate the indications for amputation in 220 cases at Walter Reed General Hospital during 1947 and 1948. No amputations were done because of osteomyelitis alone. The Syme amputation was considered an outstanding type and was felt to be functionally superior to a completely arthrodesed foot. Skin grafts on an amputation stump were condemned. In reconstructive surgery on an extremity, surgical approaches should be planned so that if amputation becomes necessary it can be done at the most functional level.

On amputations performed for specific indications, Bosworth and Gravil (3) on the basis of 35 amputations because of tuberculous joints, concluded that (1) amputation of a tuberculous joint can offer little hope of saving the life of a patient with an active pulmonary lesion, (2) amputation provides desirable pain relief even in the presence of far-advanced bilateral pulmonary tuberculosis and (3) most of these patients left the hospital in  $3\frac{1}{2}$  months with a resultant saving in their time and money, as contrasted to the usual prolonged treatment program aimed at fusion of the involved joint.

McKittrick

Fursteand Herrman (4), McKittrick and Risley (5), and Guttman (6) recommend transmetatarsal amputation for gangrene of the toes in obliterative arterial disease with or without diabetes. In selected cases where local cellulitis can be controlled, one can avoid the usual supracondylar femoral amputation. One cannot predict preoperatively which patients will do well, but resting pain is a poor sign. Before the advent of antibiotics, these were open amputations but recently they have been the final



closed type with the plantar flap slightly longer than the dorsal one to provide a dorsal suture line.

Vogl (7) discusses a short foot amputation and states the chief advantage is that a prosthesis is unnecessary. Even when the toe extensors have been preserved, they are unable to resist gastrocnemius pull and division of the tendo-Achilles may be useful to prevent an equinus deformity.

West and Papper (8) analyse 521 amputations in diabetic patients at Bellevue Hospital from the standpoint of anesthesia. There is no agreement on the use of refrigeration. The anesthetic agent was chosen on the basis of the diabetes, hyperextension, arteriosclerosis and other cardiovascular complications. Cyclopropane has little direct effect on fasting blood sugar and none on acid-base balance. Pentothal and procaine spinal anesthesia act the same, but without the adverse effects on carbohydrate metabolism. Ether, which is the anesthetic of choice in other clinics, is condemned by the authors because it interferes with liver function, elevating the blood sugar level and facilitating development of acidosis and ketosis. Nitrous oxide was not considered suitable.

Peters, Broberg and Light (9) review 185 major amputations in an attempt to establish the relationship of mortality and morbidity to the anesthetic agent employed. No morbidity figures are stated. Mortality rate was 14 per cent. The principal causes for amputation were arteriosclerotic gangrene and malignancy. No conclusions are drawn as to the role of the anesthetic agents in these deaths. Ethylene-oxygen was considered the agent of choice.

Seven articles on hemipelvectomy were published during the year. A literature review by R. A. Wise (10) discloses 138 cases reported up to 1946. Le Quesne (11) discusses history, indications, preoperative care and the technic of operation in detail. He further states that the mortality has dropped from 50 per cent to 15 per cent in the past 25 years. Five of these articles were case reports, usually with some mention of indications, preoperative and postoperative care, and technique of the procedure as follows: Palumbo (12) - osteogenic sarcoma of the ilium. Ravitch (13) - two cases of osteogenic sarcoma, 1 case of Marjolin's ulcer and 1 case of congenital angiomas. Gordon-Taylor and Wiles (14) - pulsating endothelioma of the innominate bone. Brittain (15) - Four cases of malignancy and 1 of hip joint tuberculosis with multiple sinuses. Bowers (16) - Three cases of slow-growing melanoma. Also reports 1 case of interscapulo-thoracic amputation for the same condition. Most authors felt that the procedure offered the only hope for the longevity in malignancies of the upper two-thirds of the femur or the innominate bone. Brittain had no deaths in his series of 5 cases; one of these was successfully fitted and used a prosthesis.

Janes and Jackson (17) report on 24 cases of open-flap amputation done at the Mayo Clinic. The indications are the same as for the usual



open-circular amputation, with the following advantages: (1) rapid stump healing, (2) minimum scarring, (3) re-amputation is avoided, and (4) skin traction is unnecessary. Skin flaps are in 1:1 ratio and no myofascial flap is used. A single suture anchors the flaps together over a petrolatum gauze roll impregnated with sulfathiazole and penicillin. The roll is removed five days postoperatively under anesthesia and a secondary closure is done if the wound is clean. They feel that this type amputation is a life-saving measure in cases in which an extremity is infected and the operative risk is poor, without the disadvantage of the flapless or open-circular type. This method may have some merit in chronic infections but for acute infection in the badly traumatized extremity encountered in war surgery, the open-circular amputation is the safest. Traction should not always be avoided because this aids in fixation of the muscles at their optimum length while bringing the skin down over the stump end.

Rosenberg (18) describes a method of skin traction in "guillotine" amputations. "Ace Adherent" is applied to the distal 4-5 inches. Sterile stockinette is applied over the adherent. It should be long enough to extend about 12 inches beyond the end of the stump. A knot is tied in the end of the stockinette and traction made through a rope attached to it. A piece of gauze bandage is tied snugly around the stockinette at the level of the skin edge to draw the skin down closely. An elastic bandage is wrapped about the stump. Traction is continuous. Daily additional ligatures are placed around the stockinette close to the stump to hold the skin firmly over the raw end. We have been using this type of traction at Walter Reed Army Hospital and find it superior to any other method. Even with a large amount of drainage, traction does not have to be removed for dressings because they are on the outside of the stockinette.

Phantom limb pain developed in only 5.8 per cent of 120 amputees writes L. C. (19), when the proximal nerve trunks were ligated with unabsorbable sutures approximately 3 cm. above the level of section. The authors advocate the injection of absolute alcohol into the nerve ends. The authors claim that along with Sliosberg they found phantom limb pain greatly reduced with intravenous thiamin chloride; most of the failures with this treatment occurred in upper extremity amputees. In certain cases, obvious but short lasting benefit with procaine sympathetic block indicated the possibilities of sympathetic ganglionectomy. Local radiation therapy was worthless, although good results in 15 out of 17 cases were reported following radiation therapy in the groin or axilla. As a last resort, surgical excision of the neuroma is attempted. A mention is made of chordotomy and prefrontal lobotomy in the more desperate cases.

The use of repeated percussion to decrease phantom limb pain is reported by Russell (20). The treatment was based on the following three points: (1) the normal limb nerve endings in the skin are rendered insensitive by occupations which involve repeated minor trauma or prolonged firm pressure on the skin, (2) conduction of a mixed nerve is deeply interrupted by repeated pressure, without the production of any spontaneous pain, (3) the



regenerating nerve fibers in an amputation stump are likely to be no less vulnerable to minor trauma or pressure than are normal nerves in their endings. The neuromata were either hammered with a wooden mallet or a mechanical vibrator. The author reports complete disappearance of pain in 7 cases. There seems to be some merit in this method of decreasing pain in stumps, which may or may not be due to neuromata. Similar methods have been reported repeatedly for many years.

A 30 per cent incidence of amputation neuromata is reported by Teneff (21) in his series of cases. This compares with Hermann and Gibbs report of 6 per cent incidence and Sliosberg's report of a 72 per cent incidence. The author recommends ligation of the nerve with nonabsorbable material and injection of the nerve end with tannic acid and 2 per cent formic acid which causes scarring of the nerve end. He recommends implantation of the nerve ends in nearby muscle. Implantation of the nerve end into bone does not prevent neuroma formation.

Arrowood and Sarnoff (22) report on the investigation of pain following amputation. Differential spinal block with continuous subarachnoid infusion of 0.2 per cent procaine was carried out on 7 lower extremity amputees with painful stumps. The authors wished to determine (a) whether the pain is of local origin or from the sensory cortex and (b) if it is of local origin, whether interruption of sympathetic impulses will relieve it. This type of spinal infusion blocks autonomic efferents, pin prick and stretch afferents; it does not affect somatic efferents, touch, position, or vibration afferents, or pain afferents other than pin prick. If the procedure results in relief, the pain is of local origin and its cessation the result of interruption of either sympathetic or sensory fibers, the type of which mediate the perception of pin prick. By means of subsequent paravertebral sympathetic block, one determines whether sympathetic fibers are involved. Five patients got complete relief. Three of these five received paravertebral sympathetic block and none had as satisfactory relief of pain as that produced by differential block. Two of the seven did not get complete relief of pain following differential block, but did when full spinal anesthesia was induced. This indicates that pain originating in an amputation stump is of at least two types. It is suggested that the one type is mediated by small unmyelinated or poorly myelinated fibers which are easily blocked, and the other type is mediated by fibers which require higher concentrations of procaine to block. Treatment can thus be more logically outlined. Further study of this difficult problem on a large series of cases must be done before one can definitely determine a direct line of approach to treatment.

Craft (23) gives the following stump lengths as ideal: Arm, 8-9 inches; forearm, 6-7 inches; thigh, 10-12 inches; leg,  $4\frac{1}{2}$ -5 inches, and states that the Syme amputation provides an ideal end-bearing stump. He presents a table of disability ratings for amputations at various levels varying from 90 per cent for hip and shoulder disarticulations, to 30 per cent for an end-bearing foot stump. In children, the amputated femur grows very little, whereas the humerus, radius, ulna, tibia and fibula continue to grow at nearly the normal rate. Therefore, child amputees



need periodic adjustment and replacement of prostheses.

Experience with 100 cases of thigh amputations fitted with suction socket prostheses is discussed by Canty and Ware (24). Generally speaking, the suction socket can be used by any thigh amputee who can successfully wear the conventional type of prosthesis. Stump length is not an important factor. The Gritti-Stokes and supracondylar stump as well as extremely short stumps may be successfully fitted with this type prosthesis. The shortest stump they fitted was one inch long. Contraindications are as follows: (1) associated injuries of the pelvis, in opposite leg or about the hip joint with instability, (2) increased capillary fragility, (3) dermatitis, (4) active osteomyelitis, (5) stump scars, particularly at the top of the thigh, (6) large neuromas and sensitive bone spurs, (7) stumps with marked contractures. The advantages of the suction socket over the conventional limb are: (1) greater freedom of movement in all directions, (2) elimination of the pelvic belt and joint or shoulder harness, (3) less physical hindrance and less wear and tear of clothing, (4) prosthesis is lighter and feels like part of the body, (5) friction between the skin and sides of the socket is eliminated, (6) elimination of stump sock, (7) stump muscles hypertrophy instead of atrophy, resulting in better control of the prosthesis, (8) the subcutaneous fat roll which occurs at the top of the socket with conventional plug fit is alleviated. Most failures are in the psychologically unstable patient. The suction socket requires a most accurate fit and alignment. An initial period of shrinking often takes place because of the disappearance of edema following circulatory improvement. This is later followed by hypertrophy of the muscles. These two stages of atrophy and hypertrophy require frequent adjustments in fitting of the socket. It takes longer for the amputee to learn to walk with a suction socket. Fabrication, fitting and alignment are discussed. Suction sockets have been successfully fitted for below knee, above elbow and below elbow amputees. The authors conclude that above knee suction sockets can be successfully fitted in about 90 per cent of above knee amputees. Suction sockets are actually indicated in stumps with impaired circulation because of the beneficial effect of the alternating positive and negative pressure. In patients with extremely short stumps, a suction socket provides the very necessary method of holding the stump in the socket.

McMaster and Mazet (25) report of their experiences with 16 cases of above knee amputees fitted with suction socket prosthesis. In general, their indications, contraindications, advantages, and disadvantages are in accord with Canty and Ware. McMaster and Mazet, however, feel that end bearing thigh stumps should not be fitted with a suction socket prosthesis nor should any stump shorter than  $4\frac{1}{2}$  inches measured from the adductor tubercle of the pubis be fitted with this type prosthesis.

The Orthopedic Appliance and Limb Manufacturers' Journal (26) discusses the above knee suction socket prosthesis from the standpoint of the limb fitter. Indications, contraindications, fabrication, fitting and alignment are described.



Canty (27) reports a method of taking plaster impressions of amputation stumps for the purpose of socket construction. This method was used in over 500 patients in 1945. It is taken with the patient in weight bearing position. Using an adjustable molding stand partially filled with wet plaster, the patient places his stump in the wet plaster and maintains the correct upright position with the assistance of adjustable handrails. As the plaster hardens, he bears 50 per cent weight in the soft plaster. The author feels the fit is superior to the fit obtained by taking the impression in a sitting position.

A successful prosthesis for hemipelvectomy is described by Wise (28). This patient had a sacroiliac disarticulation and was satisfactorily fitted with a prosthesis which transmitted weight bearing to the wing of the sacrum through the remaining gluteal muscles and to the lower thoracic rib cage. A knee controlled strap over the opposite shoulder anchors the prosthesis to the body. The patient can walk with the assistance of a single cane.

Weakley (29) describes the construction of a slip socket for short below knee amputation stumps. During weight bearing, the socket will press down on a crossed pair of straps of elastic webbing; during the swing phase the elasticity of the webbing will force the socket upward, keeping it on the stump. Slip sockets are an excellent way to fit extremely short stumps following hamstring section. They occasionally are useful in tender stumps. Some wearers object to the spring effect on weight bearing.

New advances in the production of prosthetic gloves are described by Clarke and Weinberg (30). They describe in great technical detail an electroplated metal mold which reproduces a natural appearing prosthetic glove. They also describe the fabrication of a partial hand prosthesis utilizing the cosmetic glove.

A method of well leg traction for transportation is described by Baluss (31). Pins are inserted through each tibial tubercle and incorporated into long leg plaster casts. A transverse arm of wood is attached to the well leg cast at the ankle extending medially toward the injured leg for a sufficient distance so that the cast on the injured leg can rest on this transverse arm. Another piece of wood is attached transversely to the posterior surface of the cast of the injured leg just above the knee extending several inches beyond the cast both medially and laterally. Traction on the injured leg is then applied by multiple rubber bands running from each end of the transverse bar on the injured leg to the transverse bar on the good leg. (Editor's Note: This is not a very practical method for routine use. A well fitted plaster hip spica with rapid transportation to the hospital for definitive treatment is best.)

A long forceps for handling bone plates is presented by Stone (32). It has hooks which engage the holes in the plate and a self-retaining retractor for paravertebral muscles is introduced by Jensen (33).



Bodenham (34) describes a replaceable blade for a skin graft knife, 7-3/4ths inches long, with a cutting edge like a safety razor blade.

Bunnell (35) advocates a dynamic spring splint to supinate or pronate the hand to replace the former fixed type of splint against which the patient could not exercise. A ribbon of spring steel (10 x 0.5 x 0.035) is fastened by a clamp at its proximal end to the medial edge of the upper portion of the forearm piece of a standard right angle elbow splint. A padded flat cuff which is adjustable as to size fits across the palm of the hand without interfering with flexion of the metacarpo-phalangeal joints. This cuff is attached to the distal end of the ribbon of spring steel by means of a clamped-in collar with which the ribbon of steel can be twisted into either pronation or supination and fixed in the desired position holding the hand and forearm in the degree of pronation or supination desired. This is another of the excellent dynamic splints which emphasize function rather than fixation.

An adjustable and simple hip splint which permits motion in all directions is described by Thompson and Cherry (36). It is advocated for cup arthroplasty during the postoperative period.

Celastic, a light, strong plastic, is used by Thompson and Howard (37) to replace molded leather cuffs in braces. (Ed. Note: Other plastics can be used in similar manner. Plaster of Paris bandages soaked in a resinous solution is a readily workable material for this purpose.

A perforated glove-like splint made of dental acrylic was used by Patton and Strain (38) for a patient with flexion contractures of fingers treated by split thickness skin graft.

A pressure gauge for objective recording of tenderness has been devised by Steinbrocker (39) and called a "palpometer."

A quadruped base for the forearm crutch is described by Ziemnowicz (40) to give greater stability.

A new type of cervical brace is described by Spicer and Bayless (41) in which turnbuckles are replaced by an aluminum strip which can be bent to fit the patient and in which traction force can be increased by shortening the shoulder straps.

La Cour and Hendrickson (42) describe a method of dressing injured fingers using tube gauze applied over the ordinary metal finger splint. Two layers of tube gauze can be readily placed over the injured finger.

Diveley (43) describes a low-back brace constructed by incorporating a rectangular steel frame into a duck belt that is held in place by 3-4 straps. Two additional straps attached to the steel above and below hold the steel firmly against the back.



Finder (44) summarizes his experiences with manipulation in orthopedics. The article confines itself to basic principles of manipulation and management in cervical disc syndrome, fibrositis of the shoulder, elbow, wrist, and fingers, low back derangements, coccygodynia, osteoarthritis of the hip, slipped femoral epiphysis, knee meniscus syndrome, fibrosis of the knee joint and lesions of the foot and ankle. He makes a plea for accuracy in diagnosis. He feels that the medical profession has been discouragingly slow in accepting manipulation as a recognized form of treatment.

Castillo, Odena, Gamberoni, and Ramballi (45) report on osteotomy in three cases of coxa vara, one genu valgum and one cubitus varus.

Basom, Breck and Leonard (46) report on the use of tibial bolts in the treatment of certain fractures. Open reduction is preferred in the management of fractures of tibial condyles. In fractures of the distal fibula with diastasis the bolt is slanted upward into the tibial metaphysis. Many fractures of the tibial condyle do not need open reduction.

Kirklín, Murphey and Berkson (47) clearly demonstrate the importance of early suturing of severed nerves, the better results in distally located lesions compared to the proximal, the feasibility of end to end anastomosis even if there has been a large gap after resection of neuroma, the ineffectiveness of tantalum foil wrapping and the advisability of having good healthy nerve ends before repair. Slight tension at the suture line is preferable to having neuroma or glioma in the sutured nerve ends.

Bruecke and Moser (48) discuss a new operative approach to the interior of the true pelvis which they have used in four cases. An incision is made parallel to and slightly below the iliac crest, extending about two inches beyond the anterior superior spine, and carried down to bone just below the crest. The gluteal muscles are stripped downward subperiosteally off the entire outer aspect of the ilium to the greater sciatic foramen, exposing the superior gluteal vessels. The entire crest, with the attached muscles, including the entire full thickness wall of the ilium, is displaced medially and upward after osteotomizing the ilium in a slightly curved line. Subperiosteal stripping of the inner surface of the ilium may be continued downward toward the pelvic brim. This exposes the anterior aspect of the sacroiliac joint, the inner aspect of the acetabulum and the horizontal ramus of the pubis. In closing the wound, the gluteal muscles are sutured to the iliac crest. It is unnecessary to use internal fixation on the osteotomized edges of the ilium. Consolidation is adequate in four weeks.

(49)

Reidy recommends a universal method of measuring and recording joint ranges of motion. He uses the standard position of the body at attention to indicate neutral position of joints. In that position every joint is considered to be at 0. He suggests recording range of motion as  $0^{\circ} \leftarrow \text{-----} \rightarrow 135^{\circ}$ . The article includes a listing of normal ranges of all joints. Standardization of joint motion measuring and recording is definitely needed in our modern industrial age with so many compensation cases being settled on a loss of range of motion.



Tsinoukas (50) presents his findings in 37 cases of neuralgia of the extremities treated by periarterial injections of 1 per cent novocain. He injected 5 to 10 cc. in the periarterial tissues in Scarpa's triangle in cases of the lower extremity and the supra-clavicular area for upper extremities. The pain subsided in 10 to 15 seconds. For complete permanent relief of pain, 2 to 15 injections at 24 to 48 hour intervals were necessary.



## BIBLIOGRAPHY

1. Hulnik, A., Highsmith, C., and Boutin, F. J.: Amputation for failure in reconstructive surgery, *J. Bone Surg.*, 31 A: 639-49, July 1949
2. Spittler, A. W., and Taylor, L. W.: Causes for amputations performed at Walter Reed General Hospital during 1947 and 1948, *J. Bone Surg.*, 31 A: 800-804, Oct 1949.
3. Bosworth, D. M., and Gravl, W. P.: Amputation for tuberculosis of joints, a study of the therapeutic and prognostic value, *J. Bone Surg.* 31 A: 194-7, Jan 1949
4. Furste, W., and Herrmann, L. G.: Value of transmetatarsal amputations in the management of gangrene of toes, *Arch. Surg.*, 57: 497-512, Oct 1948
5. McKittrick, L. S., McKittrick, J. B., and Risley, T. S.: Transmetatarsal amputation for infection or gangrene in patients with diabetes mellitus, *Ann. Surg.*, 130: 826-42, Oct 1949
6. Guttman, A. P.: Transmetatarsal amputation for diabetic gangrene of toes, *Manitoba M. Rev.*, 29: 361, July 1949
7. Vogl, A.: Fuss-Kurzstiimpfe, *Chirurg.*, 20: 67-9, Feb 1949
8. West, J. S., and Papper, E. M.: Amputation in patients with diabetes mellitus, *N. York State J. M.*: 49: 1415-8, June 15, 1949
9. Peters, M. P., Broberg, G. R., and Light, G. A.: Anesthesia for extremity amputations; a statistical review of 185 major amputation cases, *Am. J. Surg.*, 78: 220-5, Aug 1949
10. Wise, R. A.: Hemipelvectomy for malignant tumors of the bony pelvis and upper part of the thigh, *Arch. Surg.*, 58: 867-74, June 1949
11. Le Quesne, L. P.: Hind-quarter amputation, *Postgrad. M. J. Lond.* 25: 422-42, Sept 1949
12. Palumbo, L. T.: Hemiplevectomy in treatment of osteogenic sarcoma of the ilium, *Am. J. Surg.*, 77: 654-60, May 1949
13. Ravitch, M. M.; Hemipelvectomy, *Surgery*, 26: 199-214, Aug 1949
14. Gordon-Taylor, G., and Wiles, P.: Pulsating angio-endothelioma of the innominate bone treated by hindquarter amputation, *J. Bone Surg.* 31 B: 410-413, Aug 3, 1949



15. Brittain, H. A.: Hindquarter amputation, *J. Bone Surg.*, 31 B: 404-9, Aug 1949
16. Bowers, R. F.: Quarterectomy; its application in malignant melanoma, *Surgery*, 26: 523-36, Sept 1949
17. Janes, J. M., and Jackson, A. E.: Open flap amputation, *Surg. Clin. N. America*, 29: 1049-64, Aug 1949
18. Rosenberg, G. V.: Skin traction in guillotine amputations, *Am. J. Surg.*, 77: 505-, Apr 1949
19. L. C.: Los dolores de los amputados, *Dia Med., B. Air.*, 21: 45-8, Jan 3, 1949
20. Russell, W. R.: Painful amputation stumps and phantom limb; treatment by repeated percussion to the stump neuromata, *Brit. M. J.*, 1: 1024-5, June 11, 1949
21. Teneff, S.: Prevention of amputation neuroma, *J. Internat. Coll., Surgeons*, 12: 16-20, Jan-Feb, 1949
22. Arrowood, J. G., and Sarnoff, S. J.: Differential spinal block use in investigation of pain following amputation, *Anesthesiology*, 9: 614-22, Nov 1948
23. Craft, A. W. J.: Amputations, limb fitting and artificial limbs, *Ann. R. Coll. Surgeons, England*, 5: 190-207, Sept 1949
24. Canty, T. J., and Ware, R. M.: Suction socket for above-knee prosthesis, *U. S. Naval M. Bull.*, 49: 216-33, Mar-Apr, 1949
25. McMaster, P. E., and Mazet, R., Jr.: The suction socket for above-knee amputees, *Surg. Gyn. Obst.*, 89: 335-8, Sept 1949
26. -----: Suction (The) socket above-knee artificial leg, *OALMA J.*, 3: 5-35, Spring, 1949
27. Canty, T. J.: Plaster impressions of amputation stumps, *Hosp. Corps, O.*, 22: 16-9, May 1949
28. Wise, R. A.: A successful prosthesis for sacroiliac disarticulation (hemipelvectomy), *J. Bone Surg.*, 31 A: 426, Apr 1949
29. Weakley, H.: The Walter Reed slip socket, *Bull. U. S. Army M. Dep.* 9: 795-7, Sept 1949
30. Clarke, C. D., and Weinberg, F.: New advances in seamless prosthetic hands, *Arch. Surg.*, 59: 355-72, Aug 1949
31. Baluss, J. W., Jr.: Improved well-leg traction; a description of the apparatus and its application to military surgery, *Mil. Surgeon*, 105: 146-9, Aug 1949



32. Stone, M. M.: Forceps for grasping and holding bone plates, *J. Bone Surg.*, 31 A: 665, July 1949
33. Jensen, W. P.: A spine retractor of simple construction, *J. Bone Surg.*, 31 A: 436, Apr 1949
34. Bodeham, D. C.: A new type of knife for cutting skin grafts, using replaceable blades, *Brit. J. Plastic Surg.*, 2: 136, July 1949
35. Bunnell, S.: Spring splint to supinate or pronate the hand, *J. Bone Surg.*, 31 A: 664, July 1949
36. Thompson, P. C., and Cherry, J. H.: Universal splint for hip motion, *J. Bone Surg.*, 31 A: 434-6, Apr 1949
37. Thompson, M. S., and Howard, R. J.: A rigid plastic corset for arm and leg braces, *J. Bone Surg.*, 31 A: 439, Apr 1949
38. Patton, H. S., and Strain, J. C.: The moulded acrylic splint for palm and finger grafts, *Plastic and Reconstr. Surg.*, 4: 292-4, May 1949
39. Steinbrocker, O.: A simple pressure gauge for measured palpation in physical diagnosis and therapy, *Arch. Phys. M.*, 30: 289, May 1949
40. Ziemnowicz, S.: Ny modell av krycker som jhalpmedel vid invalidiserande sjukdomar id nedre extremiteterna (New model of crutches), *Nor. med.*, 41: 26-8, Jan 7, 1949
41. Spicer, C., and Bayless, A. E.: A new type of cervical brace, *J. Neurosurg.*, 6: 263, May 1949
42. LaCour, F., and Hendrickson, E. G.: A practical applicator for dressing the various body appendages, *Indust. M.*, 18: 246, June 1949
43. Diveley, R. L.: A lumbosacral support, *J. Bone Surg.*, 31 A: 441, April 1949
44. Finder, J. G.: Manipulative surgery in orthopedics, *Surg. Clin. N. America*, 29: 243-59, Feb 1949
45. Castillo, Odena, I., Gamberoni, P., and Bamballi, E.: Osteotomia-osteoclasia, *Prensa med. argent.*, 36: 677-80, Apr 15, 1949
46. Basom, W. C., Breck, L. W., and Leonard, M. H.: The use of tibial Bolts, *Mil. Surgeon*, 105: 200-2, Sept 1949
47. Kirklin, J. W.; Murphey, F., and Berkson, J.: Suture of peripheral nerves; factors affecting prognosis, *Surg. Gyn. Obst.*, 88: 719-30, June 1949



48. Bruecke, H., and Moser, H.: Osteoplastic mobilization of the ilium; a new operative approach to the interior of the true pelvis, *Surgery*, 26: 653-8, Oct 1949
49. Reidy, J. P.: Measurement of joint ranges; suggestions for simplicity, *Brit. J. Plastic Surg.*, 2: 32-7, Apr 1949
50. Tsinoukas, B. G.: Traitement des neuralgie des extremités par l' infiltration novocainique periarterielle, *Progr. med. Par.*, 77: 12, Jan 10, 1949



## CHAPTER XXII A

### RESEARCH

By

Knox Dunlap, Colonel, M. C., U. S. A.

Donegan, Messer, and Orgain (1) reported two cases of Ertron poisoning to emphasize that the prolonged administration of massive doses of antirachitic substances may produce disturbance in calcium-phosphorus metabolism with serious renal damage.

Pearl (2) makes a comparison of the effects of tetraethyl ammonium chloride given intravenously and of vasoconstrictor paralysis produced by peripheral nerve procaine block which shows that tetraethyl ammonium chloride is undependable.

Freeman (3) makes a study of the metabolism of calcium in over 700 paraplegic patients with special reference to calcium metabolism. The incidence of urinary tract calculi approximates 23-35 per cent during prolonged recumbency. Ambulation reduces the incidence of calculi to such a degree that the presence of calculus can be taken as an indication of the failure to ambulate sufficiently.

Nichols (4) points out that the repair of tendons in the hand calls for a variety of surgical techniques. A gelatin sponge may be placed around a sound tendon without danger but when the sponge is used about a tendon juncture, the sponge causes excessive fibrosis and prolonged fixation of the tendon. Tendon grafts are apparently autolyzed when surrounded by gelatin sponge.

Yeager and Cowley (5) discuss some studies on the use of polythene as a fibrous tissue stimulant. Implantation of "Polythene-du Pont" into abdominal walls of experimental animals resulted in marked fibroplasia. This material was used clinically to wrap a common carotid aneurysm and an aortic aneurysm. Diminution in size of the aneurysms and relief of symptoms resulted without interference of circulation through the involved vessels. This plastic material was used in the repair of 15 hernias, particularly recurring hernias with large fascial defects. No recurrences of the hernias occurred during a three to eight months follow-up period. Polythene, cellophane-polythene and polyethylene are synonymous terms. Pure polythene is relatively inert when implanted into tissue. "Polythene-du Pont" is adulterated by dicetyl phosphate in the "stripping process." Dicetyl phosphate is the tissue excitant factor.

Graubard and Peterson (6) evaluate the results in the management of 448 cases in which 1954 intravenous procaine infusions were given. The



type of cases treated include: (1) fractures, (2) post-dislocation arthralgia, (3) sprains, (4) traumatic arthritis, (5) myofascitis, (6) herniated intervertebral disk, (7) postoperative pain, (8) reflex sympathetic dystrophy, and (9) laceration and contusion. The article concludes that procaine intravenously should be considered as an adjuvant in the treatment of selected traumatic inflammatory and spastic conditions.

Barcroft and Hamilton (7) give the results of sympathectomy in the upper limb with special reference to Raynaud's disease. The authors examined 56 upper limbs which had undergone preganglionic sympathectomy of the Smithwick type one month to six years previously. Almost all the hands before operation showed vaso-spastic attacks. In 18 out of 36 hands, there was no recurrence of spastic attacks one year to six years after operation. In a further 14 hands, the attacks were much less serious. In only four hands did the operation give no improvement.

Rat skeletal muscle, frozen in liquid air, has been the principal object of study by Pease and Baker (8). Most of the observation has been done with the electron microscope. It has been found that the myofibril consists of a wall made up partly of myosin filaments. It also contains an "A" substance which may be largely responsible for the bi-refrigrant properties of the muscle. The existence of a cement substance between muscle fibers and its solubility in dilute salt solutions have been demonstrated. The sarcolemma as a discrete fibrous sheath has not been found.

Eggers, Shindler, and Pomerat (9) present some pressure studies on bone healing. A bone flap was made in the skull and compression made by elastic bands. Without compression, there was virtually no evidence of osteogenesis compared with the prompt healing with compression.

Antonio (10) performed quantitative studies on the optical properties of human bone from subjects three to sixty years of age, the index of refraction at room temperature of air-dried human bone was found to be almost constant and ranged around  $1.560 \pm 0.002$ .

Some circulatory disturbances of the skeletal system are discussed by Phemister (11). Local bone lesions arise from interruption of the circulation and the rapid death of the bone of the devascularized area, which cannot in x-ray films be differentiated from the surrounding bone until much later. Of the fractures, dislocations and operations causing aseptic necrosis, the most common are those about the head and neck of the femur. If weight bearing is not allowed until very late, there may be complete replacement of the necrotic fragment. Treatment of aseptic necrotic bone is called for only when it borders on a joint, at which time therapy should be directed towards prevention of collapse of opposing surfaces. If fixation of the fragments and rest alone do not result in invasion with new bone, drilling of the fragments may be beneficial.



Hellman (12) states that it has long been known that attacks of acute gouty arthritis can be precipitated by exposure to nonspecific stresses. This reaction is commonly known as "the alarm reaction." ACTH has been given to four patients with gout and has precipitated three attacks of acute gouty arthritis in five trials. The administration of ACTH to two patients during an attack of acute gouty arthritis produced a prompt disappearance of the acute arthritis. The results suggest that stimulation of adrenal cortical function is the common pathway in the precipitation of acute gouty arthritis by nonspecific stress and that pituitary adrenocorticotropin may be useful as a therapeutic agent in gout.

The adherence of tendons at the site of trauma or infection has been, and continues to be, a difficult problem for the surgeon to overcome, write Weckesser, Shaw, Spears, and Shea (13). These experiments consisted of using six materials on dogs about the tendons to prevent adhesions: (1) human fibrin film, (2) bovine fibrin film, (3) cellophane, (4) autogenous fascia, (5) gelfoam, (6) oxycel cotton. The first four were most effective in preventing adhesions. Autogenous fascia was of definite value. Film materials may seriously interfere with the nourishment of tendons if wrapped about them.

Riegel, Koop, Schwegman, Barnes, and Grigger (14) report that nitrogen balance studies showed no difference in efficacy between casein hydrolysate and fibrin hydrolysate. A method for quantitative measurement of tissue reaction to suture materials is presented by Pareira (15). Comparative studies with the use of this method indicate a significantly greater tissue reaction to surgical gut than to cotton or silk and a greater reaction to silk than to cotton.

According to MacConaill (16), muscles acting upon any joint can be divided into two principal groups: muscles of displacement or spurt muscles, and muscles of stabilization or shunt muscles. Muscles which arise far from the joint are spurt muscles and those which arise near it are shunt muscles. The fibrous tendon sheaths are joint-stabilizing mechanisms. The arrangement of the musculature is such as to ensure a constant pressure across the joint cavity during rest or uniform movement.

In tests described by Weir, Bell, and Chambers (17), three groups of one month old rats were fed for a period of four to five weeks, one rachitogenic diet (Group R), the same rachitogenic diet with Vitamin D (Group N), and a complete diet (Group S). The three different diets produced significant differences in breaking stress S B, Young's modulus E, and percentage of ash in the bones. The bones produced on the good diet (Group S) were much stronger than those of Groups N and R, although the strain at the elastic limit was the same.

Szent-Gyorgyi (18) writes that the contractile structure of muscle is built of a protein complex "Actomyosin" discovered at Szeged. The myosin partner of this complex is in many ways different from earlier myosin and was crystallized by the author; Actin was isolated by



F. B. Straub. In itself, neither Actin nor myosin shows any sign of contractility, nor does actomyosin in itself. What makes it work is the master substance of muscle adenosine triphosphate.

The survival of skeletal muscle of rats and mice after somatic death is very much shorter than with frogs, reports Sollman and Estable (19). Muscle rigor also occurs early, but this is not the cause of the loss of excitability, as muscle in rigor may still respond to stimulation. Response to stimulation of the nerve fibers or endplates deteriorates even more rapidly than the muscle.

Duran-Reymals first described the presence in testicular extract of a factor which is capable of facilitating the spread of vaccine virus in the skin of rabbits, write Som, Schneier, and Sussman (20). Since then, this factor has been shown to be identical with hyaluronidase. In 24 out of 26 patients with chronic suppurative disease of the sinuses and all 5 normal subjects, a significant penicillin level in the blood was found after intra-antral instillation of 200,000 units of crystalline penicillin G. In both groups, the addition of hyaluronidase to the instilled penicillin resulted in even higher blood levels.

A quotient of polymerization of joint fluid hyaluronic acid may be estimated, report Ragan and Meyer (21). In normal patients, this quotient was found to be above 10. In joint fluid from patients with rheumatoid arthritis, the quotient was below 10. This study suggests that the defect in rheumatoid arthritis lies in the normal process of polymerization rather than the excessive breakdown of hyaluronic acid.

Lindquist (22) writes that if wounds experimentally produced on the skin of the white rat are treated with wool fat, the wool fat is absorbed by the granulation tissue and forms extraneous bodies there, that seem to have a retarding influence on the wound healing. The effect of roentgen rays on the healing of skin incisions in doses of 10, 25, 150, 300, 350, and 700 r was studied in 122 rats by Pohle, Ritchie, and Moir (23). Although all wounds were examined daily, no consistent difference in the healing time between irradiated and nonirradiated portions of wound could be detected.

Warren and Dixon (24) write of chick embryos and young chicks which were exposed to continuous radiation by injections of P 32 which has a half life of fourteen days and insures sustained radiation. The P 32 concentrated largely in the bones and caused an over-all growth retardation, resulting in small but well proportioned birds. The cartilage cells of the epiphyses were much more radio-sensitive than the osteoblasts and osteoclasts.

Moehlig (25) writes that about one-third of a group of 41 patients with osteitis deformans gave a family history of diabetes. Protamine zinc insulin is used only to relieve pain and not as a cure for the disease.



Progressive marked alteration of growth with skeletal deformities were noted following brief exposure to cold in newborn rats, reports Scow (26). The skeletal changes were shown to result from necrosis of cartilage cells.

Zuelzer (27) gives a good discussion of the function of bone marrow. It is pointed out the bone marrow reacts in a uniform manner to stimuli and behaves in this respect as an organ. Aspirated bone marrow gives reliable information about qualitative changes.

Grossman of Berlin introduced tomography in 1935 and the method has been applied very generally to the lungs. Wood (28) recommends its use in the x-ray examination of the spine, ribs, sternum and perhaps the hip joint.

In the past, colorless acrylic resin has been unavailable at times and the pink form had to be used, report Virengue and Coronel (29). Subcutaneous implantation of pink acrylic resin shows no greater inflammatory reaction than that seen after the implantation of the colorless form. When left in place for five months, the reaction still only consists of a mild fibroblastic proliferation around the substance and never attains the form of true scarring or sclerosis. When injected into the eye to test for allergy, the conjunctival reaction is usually very mild. Yet, definite cases of true allergy and anaphylaxis have been described, and many of them have been traced to the dye used; in France, mainly cadmium sulfosecalamine; in the U. S. A., the dyes mainly used are alizarine dyes; in Britain, sudan 3 and 5. Eosin has been largely discarded since it has long been known to be an allergen in lipsticks. In summary, it is better to use colorless acrylic resins.

Ingraham, Alexander, and Matson (30) analyze the synthetic plastic materials for use in surgery. Only the resins have been useful in surgery. Some plastics are hard and brittle so that a "plasticizer" is used to increase their flexibility. These plasticizers tend to separate from the plastic, making the latter impractical for the following reasons: (1) the uncertainty of obtaining a standard product, (2) the possibility that plasticizers released in tissue might be noxious, and (3) the plastics might be altered following loss of the plasticizer. The prerequisites of a synthetic substance for use in surgery are: (1) they should not be physically modified by tissue fluid, (2) they should be chemically inert, (3) they should not excite an inflammatory or foreign body response in the host tissues, (4) they should be noncarcinogenic, (5) they should be nonepileptogenic when buried in brain tissue.

VINYL RESINS: Contain plasticizers so are not recommended except as catheters.

CELLULOSE PLASTIC: Many different types so the literature is controversial. A standard product cannot be obtained, furthermore the cellulose is a tissue irritant and should be used only where scarring is desired.



BAKELITE, PROTEIN SUBSTANCES, AND CERTAIN ALGINATES: Insufficient experimental data.

NYLON: Used chiefly as sutures but the knots tend to slip. Very strong, elastic and chemically inert. Is resistant to autoclaving and chemicals. May be produced in sheets and tubes.

METHYLMETHACRYLATE: May be obtained in a standard product and in any form. It is chemically inert and stable, does not absorb water, is non-porous to bacteria, unchanged by tissues and well tolerated by them.

POLYETHYLENE: A tough, flexible plastic that can be produced in any form, resistant to water and most solvents, and is chemically inert. Causes no tissue reaction, cannot be autoclaved and chemical sterilization is very satisfactory. Has been used in almost every portion of the body with success.

Tetraethylammonium increases peripheral blood flow solely by a sympathetic blocking action and does not act at all on the denervated extremity, report Avera, Hoobler, McClellan and Little (31). The drug is more effective when given intravenously than when given intra-arterially. Priscol increases blood flow by a direct vasodilator action. The increase in peripheral blood flow after the use of dihydroergocornine is, for similar reasons, probably not dependent on its sympathetic blocking properties. In the usual intravenous dosage, benzodioxane has no peripheral vasodilator action.

Three minutes in formol vapor proved to be the most satisfactory fixation procedure for phosphatase technics as applied to bone marrow smears, report Rabinovitch and Andrewcci (32). The reaction of normal human bone marrow cells to both phosphatase technics is presented.

The history of plastic surgery is discussed in brief by Maneksha (33), while the different methods of skin grafting are described in some detail. It is pointed out that in ulcerations treated daily, the fresh and delicate capillaries are severed as each dressing is changed and naturally healing is delayed. Skin grafts are preferred.

Samuel (34) has reported a detailed histological study of the innervation of the articular capsule of man and of the cat. It was found that a large proportion of the nerves which ramified in the joint capsule did so in company with the blood vessels. They were distributed in a plexiform manner through the fibrous ligament and synovial membrane, and gave off branches which (a) innervated the blood vessels; (b) formed a true nerve plexus in the synovial membrane; and (c) ended in various types of free nerve endings. The exact nature of the nerve fibers in the articular capsule has hitherto remained unsolved, and in an effort to acquire more precise knowledge, the knee joints of twelve sympathectomized cats have been studied and compared with joints of normal animals. The conclusions reached were that, though a large component of the nerves in the joint capsule were of a sympathetic origin,



the synovial membrane, contrary to the views of Gerneck (1932), Plasserman and Daubenspeck (1938), and others, had a substantial somatic nerve supply.

Ashley (35) describes the examination of 14 cadavers and 4 fetuses to determine (a) whether the pectoralis major tendon is bilaminar or trilaminar; (b) which of the fibers actually twist before reaching their insertion; (c) through which lamina the various fibers are inserted. In all cases the tendon was found to be bilaminar. This is contrary to the view expressed by Grant of Toronto. The only fibers involved in twisting are the SUPERFICIAL fibers from the lower sternocostal and abdominal elements, plus occasionally a few superficial fibers from the manubrial and clavicular portions. These fibers join an aponeurosis on the inferior border of the muscle one-half inch from the bone before twisting backwards, upwards and then laterally, fanning out to form the posterior lamina of the tendon. These fibers of the pectoralis major are not described in the text-books.

The importance of accurate evaluation of disability is well recognized, says Newman (36). Muscle strength, to a great extent, governs the amount of function of a part. The myometer is a new device for accurately measuring muscle strength. This device is self-contained, is light in weight, and gives a direct reading.

Woolmer, R. (37), describes some of the advances made in anaesthesia. The following muscle relaxants are discussed: Curare is probably the most widely used. Myanesin is not as good a relaxant and may cause haemolysis and venous thrombosis. Flaxedil is a synthetic benzene derivative. Decone is a methylated ammonium derivative. Both of these last two mentioned drugs are powerful relaxants. Erythroidin and quinine are weak relaxants. Continuous spinal anesthesia can be used in long operations. The following are some of the anesthetic agents being used: Cyclobutane is very similar to cyclopropaine. Methadon appears to be a better analgesic than morphine. A new local analgesic is xylocaine.

Dextran was developed because of the demand in the second World War for a plasma substitute, reports Ingleman (38). It was found that this polysaccharide was formed in sugar beet juices which were infected with the bacterium *heuconostoc mesenteroides* or similar micro-organisms. About 40,000 bottles of dextran had been used in Swedish hospitals up to February, 1949. The chemical tests have shown that the result of shock treatment with dextran is good and that when required, several liters of dextran solution can be injected without the occurrence of injurious secondary reactions. (Ed. Note: Swedish Dextran has caused severe reactions in U. S. soldiers and is being studied).

Elbel (39) discusses the relationship between leg strength and other body measurements. Five hundred ninety pilots and potential pilots were used as subjects. This work has shown that the height of the individual is not related to leg strength nor leg endurance.



Blood flow in the skin of the extremities was studied by Green and Ogle (40). Vasoconstriction was induced by placing the subject in a cool environment, then vasodilator effects of tetraethyl ammonium and benzyl imidazoline injection intramuscularly and warming the body with heat lamps were recorded. Body warming was most effective in abolishing vasoconstriction in the hand and tetraethyl ammonium in the foot. Benzyl imidazoline was about equally effective on both hand and foot.

Silberberg and Silberberg (41) have written an article entitled "The Role of Hormones in the Growth and Aging Process of the Skeleton and their Importance in the Pathogenesis of Arthritis Deformans." It is known that hormonal influences on the skeleton are dependent on a number of other factors, such as the species, age and sex, nutrition, vitamin and mineral metabolism and the interplay of other endocrines. This realization has changed the concept of the specificity of hormones.

**Growth and Aging of the Skeleton:** In the skeletal development, three phases can be distinguished: (1) Growth period - In the areas of growth there is active cartilage proliferation and in the young cartilage are great amounts of cholesterol, glycogen, phosphatase, and phosphorylase. Simultaneously with length growth, there is periosteal bone formation, accounting for increase in thickness. (2) Period of degeneration: Begins around puberty. Cartilage-proliferation slows down and finally halts altogether. The content of cholesterol, glycogen, enzymes decreases at the same time. Meanwhile, ossification of the epiphyseal space continues, as does the growth in thickness. (3) Period of reabsorption - During this phase, destructive processes are prevalent, first only in the cartilage, but later also in the bone. The bone decreases in mass and H<sub>2</sub>O content, thus increasing proportionately in inorganic matter. This explains the increased fragility. In this period, degenerative joint changes increase in number and severity. The duration of the different phases is dependent upon genetic qualities, e.g., familial incidence of arthritis deformans.

**Sex Influence:** The female skeleton ages faster, the bearing female even faster than the nonbearing. The difference seems to be determined by the amount of female sex hormones. The skeletal changes run parallel to the sex characteristics, rather than chronological age. Influence of the different hormones: (1) Hypophysis - Decrease in anterior pituitary hormone prolongs the period of growth and decreases cartilage growth and ossification. Early cessation of growth then leads to dwarfism, while at the same time slowing in development and aging of the cartilage delays epiphyseal closure. Even in completely pituitary-ectomized animals, length-growth does continue for a short period. The hypophysectomized dog does not change teeth and the hypophysectomized rat gets his incisors and molars late or not at all. The younger the animal at the time of operation, the more pronounced the results of hypophysectomy. The female animal is more sensitive to the loss of the hormone than the male. Even purified crystallized anterior pituitary hormone does not fully restore growth when implanted in the hypophysectomized animal. Animals do much better if together with this hormone



they are given thyroid hormone or male sex hormone or placental gonadotropin. Also, the lactogen hormone of the pituitary increases growth in the congenitally hypopituitary dwarf mice. A number of the hormones are thus involved in the growth process. In absence of Vitamin B complex, growth is arrested so it too could be designated as a specific growth stimulant. Probably the anterior pituitary growth hormone is involved in growth largely as playing a role in the general cell metabolism. It increases storage of nitrogen. Giant rats developing after the injection of anterior pituitary hormone, show no real increase in length growth. They appear giant because of increased subcutaneous fat deposition and an increase in water swells up the epiphyseal cartilage as well as the intervertebral discs. At the same time, cartilage growth and endochondral ossification are speeded up. Nobody has been able to produce resumption of growth by giving anterior pituitary hormone, once it has stopped physiologically.

In the growing, animal growth can temporarily be speeded, but as a result the epiphyses close sooner and aging processes appear earlier. Anterior pituitary hormone is useful in therapy of the dwarfed. After growth has finished, anterior pituitary hormone therapy produces earlier appearance of aging processes. This can be observed in the joints where changes similar to those of arthritis deformans appear. This may explain both the greater frequency of arthritis deformans in the acromegalic and the frequent onset of the arthritis in menopause. In the first, we are dealing with an increase in anterior pituitary hormone and the latter a decrease in sex hormones induces an increase in anterior pituitary hormone formation. One has observed a growth inhibition in animals treated with anterior pituitary hormone coming from the same species. Explanation: The hormone increases ovarian action which in turn slows down the growth; the gonadotrophic action of the anterior pituitary being much stronger than the growth stimulation action. In these there is no dwarfing, because with the inhibition there is simultaneously a prolongation of the growth period.

(2) Thyroid - Absence of thyroid hormone leads to inhibition or even standstill of the growth of skeleton and teeth. Sex, species, and age are of influence. Females are more sensitive to loss of the hormone. Similar changes are seen as after loss of anterior pituitary hormone: Epiphyses remain open longer and look younger longer. Cartilage growth is slowed, but less than after the loss of anterior pituitary hormone. Development and aging of the cartilage are slowed. Endochondral ossification is more affected than the intramembranous ossification, leading to thick and short bones. Moderate doses of the hormone increase growth and aging of cartilage. They speed epiphyseal closure and tooth eruption. Hyperthyroid children show increase in length growth. Treatment with large doses speeds aging in the cartilage more than it speeds growth, leading to premature closure of the epiphyses and dwarfism. This can therapeutically be used to stop the growth in certain forms of giant growth. Another action of thyroid hormone is faster bone destruction leading to the so-called smooth bone atrophy. Hypothyroidism shows under



therapy, resumption of growth and a normal course in the epiphyseal closure and development of the ossification centers. In children during the first year of therapy there is an increase in the speed of growth, which decreases gradually as the child catches up with the normal, so that even with thyroid hormone one cannot increase a child's stature beyond its genetically determined growth potential. There is a difference in the aging action of the two hormones, anterior pituitary and thyroid. The former leads to increased fluid retention in the cartilage leading to liquefaction, the latter in contrast solidified the cartilage. Thyroid thus prevents the degenerative aging processes and in old mice with thyroid therapy there was a reduction of incidence of arthritis deformans from 70 to 14 per cent. This explains possibly the greater frequency of arthritis deformans in hypothyroidism.

(3) Parathyroids - Action of the hormone is largely dependent on the amount of calcium available. Parathyroid hormone absence slows bone production. Parathyroid hormone increases proliferation of periosteal, metaphyseal, and endosteal connective tissue, but not that of cartilage. However, aging processes in the cartilage are speeded leading to premature epiphyseal closure and dwarfism. In chronic renal disease in the human, the retention of P in the blood stimulates the parathyroid, leading to a picture of osteitis fibrosa by stimulating the fibrous proliferation and increasing the bone resorption in patients with a limited calcium supply. With a sufficient calcium supply it can lead in addition to increased bone growth.

(4) Sex hormones - Castrated boys and animals are slow in growth as the result of the inhibition of cartilage formation rather than cartilage growth. The slowing is also evidenced by the late closure of the epiphyses and the diminished bone formation. The skeleton, therefore, remains young for a long time. With increase in age the skeleton then ages faster than normal. Removal of ovaries is very similar in action to testicular absence, except that growth is less affected. In the joints of both, one finds a decreased hardening of the matrix, which predisposes to greater arthritic changes, which also occur earlier. Excess of sex hormones speeds developmental and aging processes of the cartilage, leading to dwarfism. Estrogens in addition decrease vascularization of the bone marrow, hyalinize the connective tissue and decrease the resorption of bone and cartilage.

(5) Adrenals - In experimental animals, adrenalectomy leads to bone atrophy. How specific this action is nobody knows, especially since ACTH decreases growth in male rats. Yet adrenal-cortical extract in the hypophysectomized increases cartilage growth. In adrenal adenomas in children, abnormal height growth and faster skeletal development has been observed.

(6) Thymus - Offspring of thymectomized rats showed decreased growth. Some authors, however, could determine no influence of the thymus on the skeleton. It is hard to determine the action of any one hormone on the skeleton, since there is interplay in all of them. The anterior pituitary



hormone probably acts directly on the cartilage and bone since it is even active in the thyro-adreno-oophorectomized animal. Some think the estrogens act on the skeleton through the pituitary by decreasing its activity. Yet in the hypophysectomized the changes seen in estrogen therapy are not found. There probably is at least some direct action on bone and cartilage. In the normal, one deals with a sensitive equilibrium. Hormones are not truly antagonists since when given together each gives its specific action. Thyroid and estrogens are antagonists. Estrogenic osteosclerosis can be counteracted by thyroid. However, on the cartilage they are synergistic. Both hormones harden the matrix, and the aging processes are increased beyond what each could do alone. Simultaneous treatment with anterior pituitary and thyroid hormones increases the aging process at the epiphyseal line beyond the single action of each. However, they are antagonistic when given together in their action on the cartilage, the softening by the anterior pituitary is overbalanced by the hardening by thyroid, influencing beneficially the arthritic age-changes. Age and tissue predisposition - morphology and metabolism of tissues change with age. Hormonal influences change with the receptivity of the tissue. The absence of a hormone becomes more strongly noticeable the more it is necessary for the essential processes in the skeleton. Thus after completion of growth the lack of anterior pituitary hormone is less effective.

Yet aging processes can be speeded more and show greater changes when aging is well established to begin with. In the young, for example, estrogens produce osteosclerosis, whereas it can enhance the natural osteoporotic process in the old. Adaptation of the organism to the hormone: The decrease of hormonal influence on an organism with continued administration is well known. It is unknown whether this is a desensitization of the tissue to the substance or a change in function in the other endocrines. Nutritional influences - Length growth continues in malnutrition, but aging processes are slowed. Endocrines also are slowed down by malnutrition. Vitamin A deficiency gives skeletal changes similar to those caused by estrogens. Estrogenic bone proliferation in turn is dependent on the presence of Vitamin C. The actual point of action on which the hormones work is unknown. Most likely hormones are direct or indirect catalysators, which influence growth by acting in the construction and demolition of organic matter.



## BIBLIOGRAPHY

1. Donegan, C. K., Messer, A. L., and Orgain, E. S.: Vitamin D intoxication due to ertron; report of two cases, *Ann. Int. Med.*, 30: 429-435, Feb 1949
2. Pearl, F. L.: Tetraethyl ammonium chloride; its effects on surface temperatures of arteriosclerotic extremities, *Ann. Surg.*, 128: 1100-1111, Dec 1948
3. Freeman, L. W.: Metabolism of calcium in patients with spinal cord injuries, *Ann. Surg.*, 129: 177-184, Feb 1949
4. Nichols, H. M.: Discussion of tendon repair with clinical and experimental data on the use of gelatin sponge, *Ann. Surg.*, 129: 223-234, Feb 1949
5. Yeager, G. H., and Cowley, R. A.: Studies on use of polythene as fibrous tissue stimulant, *Tr. Am. S. A.*: 66: 265-276, May 1948
6. Graubard, D. J., and Peterson, M. C.: Therapeutic uses of intravenous procaine, *Anesthesiology*, 10: 175-187, May 1949
7. Barcroft, H., and Hamilton, G. T. C.: Results of sympathectomy in upper limb, *J. Anat.*, 83-58, Jan 1949
8. Pease, D. C., and Baker, R. F.: Fine structure of mammalian skeletal muscle, *Am. J. Anat.*, 84: 175-200, Mar 1949
9. Eggers, G. W. N., Shindler, T. O., and Pomerat, C. M.: Pressure studies on bone healing; a preliminary report, *Texas Rep. Biol. and Med.*, 7: 125-128, Spring 1949
10. Antonio, A.: Quantitative researches on optical properties of human bone, *Nature*, 163: 604, Apr 1949
11. Phemister, D. B.: Some circulatory disturbances of skeletal system, *Proc. Inst. Med.*, 17: 254-261, Feb 1949
12. Hellman, L.: Production of acute gouty arthritis by adrenocorticotropin, *Science*, 109: 280, Mar 1949
13. Weckesser, E. C., Shaw, B. W., Spears, G. N., Shea, P. C.: Comparative study of various substances for prevention of adhesions about tendons, *Surgery*, 25: 361-369, Mar 1949
14. Riegel, C., Koop, C. E., Schwegman, C. W., Earnes, M. T., Grigger, R. P.: Evaluation of mixture of ossein gelatin, hydrolyzed protein and glucose in parenteral nutrition of postoperative patients, *Surgery*, 25: 672-675, May 1949



15. Pareira, M. C.: Reaction in surgical wounds to surgical gut, silk, and cotton sutures, Arch. Surg., 58: 308-311, Mar 1949
16. MacConnail, M. A.: Movements of bones and joints; function of musculature, J. Bone and Joint Surg., 31 B: 100-104, Feb 1949
17. Weir, J. B. D., Bell, G. H., and Chambers, J. W.: Strength and elasticity of bone in rats on rachitogenic diet, J. Bone and Surg., 31 B: 444-451, Aug 1949
18. Szent-Gyorgyi, A.: Attacks on muscle, Science, 100: 411-413, Oct 1949
19. Sollman, T., and Estable, J. J.: Survival of refrigerated mammalian muscle and nerve after somatic death, Am. J. Physiol., 156: 328-332, Mar 1949
20. Som, M. L., Schneierson, S. S., and Sussman, M. L.: Enhancement of penetration of penicillin into inflamed and normal mucous membranes by hyaluronidase, Proc. Soc. Exp. Biol., 70: 96-99, Jan 1949
21. Ragan, C., and Meyer, K.: Hyaluronic acid of synovial fluid in rheumatoid arthritis, J. Clin. Invest., 28: 56-59, Jan 1949
22. Lingquist, G.: Influence of wool fat on healing of wounds, Acta. Path. Microb. Scandinav., 25: 598-602, 1948
23. Pohle, E. A., Ritchie, G., and Moir, W. W.: Studies of effect of roentgen rays on healing wounds; histological changes in skin wounds in rats following postoperative irradiation with very small and moderate doses, Radiology, 52: 707-713, May 1949
24. Warren, S., and Dixon, F. J.: Effects of continuous radiation on chick embryos and developing chicks; growth rate, gonads, and bone, Radiology, 52: 714-729, May 1949
25. Moehlig, R. C.: Insulin therapy for relief of pain in osteitis deformans, J. Clin. Endocr., 9: 385, Apr 1949
26. Scow, R. O.: Destruction of cartilage cells in newborn rat by brief refrigeration, with consequent skeletal deformities, Am. J. Path., 25: 143-161, Jan 1949
27. Zuelzer, W. W.: Normal and pathologic physiology of bone marrow, Am. J. Dis. Childhood, 77: 482-502, Apr 1949
28. Wood, F. G.: Tomography of bones and joints, Proc. Roy. Soc. Med., 41: 856, Dec 1948
29. Virenque, M., and Coronel,: Remarques sur l' inclusion intratissulaire de l'acrylique rose, Rev. Odont. Stomat., 5: 29, Jan 1949



30. Ingraham, F. D., Alexander, E., Jr., and Matson, D. C.: The use of synthetic plastic materials in surgery, Practitioner, Lond., 162: 152-159, Feb 1949
31. Avera, J. W., Hoobler, S. W., McClellan, S. G., and Little, W. J.: Comparative sympathetic blocking and adrenolytic action of four drugs in human subject, Am. J. Med., 6: 669, May 1949
32. Rabinovitch, M., and Andrewcci, D.: Histochemical study of "acid" and "alkaline" phosphatase distribution in normal bone marrow smears, Blood, 4: 580-594, May 1949
33. Maneksha, R. J.: Tissue transplantation, Antiseptic, 46: 173-177, Mar 1949
34. Samuel, E. P.: Innervation of articular capsule of knee joint, J. Anat., 83: 80-81, Jan 1949
35. Ashley, G. T.: On insertion of pectoralis major, J. Anat., 83: 68, Jan 1949
36. Newman, L. B.: New device for measuring muscle strength; myometer, Arch. Phys. Med., 30: 234-237, Mar 1949
37. Woolmer, R.: Advances in anaesthesia, Practitioner, 163: 320-327, Oct 1949
38. Ingleman, B.: Investigation on dextran and its application as a plasma substitute, Upsala foren forh, 54: 107-122, Mar 1949
39. Elbel, E. R.: Relationship between leg strength, leg endurance and other body measurements, J. Appl. Physiol., 2: 197-207, Oct 1949
40. Green, H. D., and Ogle, B. C.: Use of vasodilator drugs and body warming in evaluating peripheral vascular disease, J. Appl. Physiol., 1: 663-669, Mar 1949
41. Silberberg, M., and Silberberg, R.: Die Rolle der Hormone in wachstum and altern des skeletts und ihre bedeutung fur die pathogenese der arthritis deformans, Schweiz. med. Wschr., 79: 127-132, Feb, 1949



## CHAPTER XXII B

### RESEARCH

By

Robert S. Brua, Colonel, USAF (MC)

#### Osteogenesis

Eggers, Shindler and Pomerat (1) studied the effect of compression force in osseous repair. The term "contact compression factor) was selected and described as the combination of contact and the force applied to promote that contact, and its effect on osteogenesis. Surgical fractures produced in skulls of white rats were used for study. Some of these fractures were subjected to contact and compression, some to contact and excessive pressure, and in some no contact or compression was used. The margins with excessive pressure and contact became necrosed with a delay in osteogenesis, the margins with ideal compression force and contact showed excellent osteogenic activity, and those with no contact at all showed none or little osteogenic response. The presence of infection did not alter osteogenic activity in fractures subjected to ideal contact compression forces.

An article by Hartley et al (2) deals with experimentation along the line that there is an osteogenic substance in the marrow and bone of rabbits. The substance seems to be soluble in alcohol. No conclusive proof has been produced to demonstrate that the production of new bone at the site of injection is a specific phenomenon. Three out of eleven rabbits injected with the alcoholic bone extract showed growth and microscopic evidence of new bone formation.

The relationship between the presence of glycogen in cartilage and the calcification process is clarified by Follis (3). In rachitic cartilage, glycogen is present only in the most recently mature hypertrophic cells. The broad zones of hypertrophic cells beneath is devoid of glycogen. This localization coincides with the area where inorganic elements deposit during the initial stages of healing. Weanling rats were placed on the Steenbock rachitogenic diet supplemented with crystalline vitamins. After one to five weeks on this regimen, some of the rats were injected intraperitoneally with 2.5 cc. per 100 g of animal of a mixture of one part M/10  $\text{NaH}_2\text{PO}_4$  and 4 parts M/10  $\text{Na}_2\text{HPO}_4$  to produce healing. Rats were sacrificed and the upper end of the tibia was fixed and stained for glycogen. Glycogen was not present in the widened zone of hypertrophic cells, so characteristic of rickets. Glycogen was present in the usual increasing amounts in the cells which are undergoing the normal maturation cycle at the upper margin of the widened zone of hypertrophic cells.

#### Radiation

Hoecker and Roofe (4) study the distribution and deposition of



radium in bones of rats in order to correlate the high incidence of osteogenic sarcoma in victims of radium poisoning. These sarcomas have been attributed to the presence of radium in the bones and the bombardment of osteoid tissue by alpha particles. This study demonstrated the existence of microscopic localizations of radium deposited in the bones of rats and that the largest concentrations appeared to be in the periosteum and endosteum.

### Chemotherapy

Using the bone marrow as the source for study in the level of penicillin from various areas of injection, Blum et al (5) found no difference in the level between intravenous and intra-arterial routes of administration. The most satisfactory method was one of intra-arterial injection following a preliminary intravenous or intra-arterial dose.

Thiersch et al (6) state that the antifolic compounds 4-aminopteroylglutamic acid and 4-amino-N<sup>10</sup>-methylpteroylglutamic acid inhibit the growth of sarcoma 180 in mice. Folic acid deficiency caused a parallel effect on bone marrow and tumor cells, reduction of the normal erythropoiesis being coincident with the inhibition of tumor growth. On cessation of treatment, both the erythropoiesis and the growth of sarcoma 180 recovered within five days.

A specific combination of chemicals identified as "calcium chloride complex" is introduced to the medical profession by Schreiber et al (7) as a new fungistatic and bacteriostatic agent for foot clothing and the skin. This chemical compound also proved to be deodorant, nonirritating, and even seemed to increase the tensile strength and elasticity of the materials processed. The physical properties of the CACL complex are described, also its action on human skin. Processing of foot clothing is described.

### Muscle Physiology

Hill (8), of the University College, London, has re-examined the thermodynamics of muscular contraction, using improved galvanometers and the "projected thermopile," described by him in 1937 and 1938. With these instruments, he was able to take continuous photographic recordings of the heat produced during the course of a muscle contraction with little distortion. He concludes that the heat produced in a single muscle twitch is made up of two parts: the heat of activation and the heat of shortening. The heat of shortening occurs at the same time as the shortening. The heat of activation has its maximum rate at the start, very soon after the stimulus; it falls off in rate from then onwards. The heat of maintenance in a tetanic contraction is the summated effect of the heats of activation resulting from successive elements of the stimulus.

Barracquer-Bordas (9) exposes the current confusion among some physiologists in regard to several ways of getting the ankle reflex.



He states that basically this reflex is caused by traction and stimulation to the triceps surae muscle. The frontal tap reflex described by Gowers, the Piotrowski reflex, the Bing reflex, the Benedeck reflex, and the Balduzzi reflex are all but indirect ways of getting essentially the same ankle reflex. In all of these traction and stimulation to the triceps sural muscle is exerted in some way.

### Miscellaneous

An addition to the knowledge of the pharmacological response of endocrine glands to chemicals is made by Malcolm et al (10) in their study of the changes in the parathyroid and pituitary glands. It was found through microscopic study of these glands, that long term administration of the above gastrogens led to an enlargement of the parathyroid glands. The adrenal glands showed only negligible changes. It was also found that after 14 months or more of feeding of thiourea and thiouracil compounds, a generalized osteitis fibrosa was found in 9 of 33 animals tested along with enlargement of the parathyroid glands.

Lutz and Solomon (11) report the increased use of intravenous procaine for anesthesia and analgesia in orthopedics. The solution most commonly used is 1:1000 in a volume varying from 200 to 1000 cc. Uses listed for intravenous procaine are (1) as an anesthetic or analgesic agent with sodium pentothal; (2) for relief of pain due to myositis, arthritis, bursitis, or acute fracture. The authors state that administration of intravenous procaine is a safe hospital procedure if carefully controlled; but warn that its use may prove dangerous and that cases must be selected. Further investigation is desired.

Goniometry in general is discussed by Moore (12). A simple instrument is described which is felt to offer several advantages over more complicated ones in use. Methods of recording range of joint motion and the importance of using standard nomenclature are noted. The placement of the goniometer and its dependence upon the axis of motion are stressed. Mention is made of the impossibility of locating the axis of motion by any one anatomical landmark. A table of norms of comparison is provided. The remainder of the article deals with the basic elements of technic for each individual joint.

Polyethylene tubes were used by Gonzales (13) for experimental tendon repair in the dog. They were found superior to absorbable tubes in preventing binding adhesions, but adequate immobilization for at least 40 days must be provided, using Bunnell's tension wire and pull-out loop method for the anastomoses and wire screened casts to prevent loss of immobilization. In 40 days tendons healed strongly within polythene tubes, their function approaching normal. For secondary repair, tendolysis followed by polythene wrapping might prove to be of value in restoration of tendon function.

### Roentgen Ray

Microspectrographic investigation of inflammatory bone destruction



in the mastoid is described by Engstrom et al (14). Corresponding pieces of bone were used as controls, both in preoperative x-ray studies and postoperative microspectrographic studies. It was found that while there is considerable variation in "normal" calcium content in this area of temporal bone, the majority of cases which show decreased bone density by x-ray studies also demonstrate marked bone softening and decalcification.

### Education

Ghormley (15) gives an interesting resume of the evolution of orthopedics as a surgical specialty and emphasizes the need for intensive training in the fields of both childhood and adult orthopedics.

Fourteen authors under the chairmanship of Shands (16) discuss post-graduate work in Orthopaedic Surgery during the annual meeting of the American Orthopaedic Association in 1949. In 1944, a committee on post-graduate training was appointed. Its first objective was to increase the facilities for orthopaedic training. In two years time, the number of training services was increased from approximately 79 to 238, and the number of training services was increased from approximately 253 to 726. The present conference was called to review methods and types of post-graduate education and an attempt was made to define the objective of resident training and build up a program for training which will result in the development of the ideal orthopaedist.

Dr. Alan DeForest Smith presented "A Program for Training in Adult Orthopaedic Surgery and Fractures," in which he emphasized the preference for segregating fracture cases in separate wards and spoke of the three year program at the New York Orthopaedic Hospital, in which the first year is devoted to work on both adults and children as an assistant resident. Six months of the second year are devoted to a study of basic sciences, and six months to fractures. The third year is spent as a fellow-ship in which each man is a senior resident for three months and during the remainder of the year, works in the out-patient clinic and in the operating room and attends rounds and conferences. It is felt that education in the resident state is best carried out by practical instruction at rounds, conferences, staff meetings, and in the operating room and clinic. Each man is required to carry out some clinical investigation or research project which is read at a staff meeting during his three-year period.

"The Ideal Curriculum in Children's Orthopaedic Surgery," is presented by Dr. William T. Green, in which he describes the essentials for a training program which should consist of (1) sufficient diversified representative clinical material and capable teachers with sufficient experience in children's orthopaedics. He believes that the best type of training should represent an apprenticeship to a hospital service and should consist of progressive responsibilities and experiences for the trainee. There should be a large out-patient clinic available and ideally the hospital should be concerned with all types of pediatric problems, both medical and surgical. The man in training should do the work, as observation has a limited value. Representative "formal rounds" and



"resident rounds" should be conducted regularly by appropriate staff members. The use of regular seminars, clinical pathological conferences, and follow-up clinics is stressed.

"The Ideal Curriculum for Basic Science Instruction in Orthopaedic Surgery" is described by Dr. Guy A. Caldwell. He states that the ideal curriculum should insure that anatomical and pathological specimens are always available for dissection and that free access be had to consultants in physiology, bacteriology, and biochemistry. He further states that an ideal plan requires (1) a limited number of patients with varied orthopaedic problems, (2) easy access to sufficient anatomical and pathological material, adequate library facilities, competent instructors in the basic sciences, and (3) sufficient time which is free from routine hospital duties so that the resident can utilize the above facilities. He believes that an ideal program of basic science instruction will not be realized until staff members themselves appreciate its value and importance enough to assist in the organization of such a program in all of its details. The idea is also stressed that there should be orthopaedic surgeons, or those interested in orthopaedic surgery, who are trained in anatomy and the other basic sciences and can present them most forcibly from an orthopaedic standpoint.

Dr. Carl E. Badgley speaks about "The Ideal Curriculum of Resident Training in a University Clinic." He calls attention to the importance of the relationship between orthopaedic residents and the men on other services and believes there should be close cooperation with the various departments throughout the hospital. Orthopaedic residents should be utilized for the purpose of teaching in orthopaedic subjects, also surgical anatomy, surgical technique, etc., to undergraduate groups of nurses, etc. He believes that the most important thing in training men is to give them a sense of responsibility.

"The Ideal Curriculum of Resident Training in a Private Clinic" is presented by Dr. J. S. Speed. He believes that the ideal training program is not found in either the strictly charitable hospital or the strictly private hospital and clinic, but rather a combination of the two. Training in a private clinic benefits the resident by showing him the business side of medical practice and the value of handling patients in such a way that their finances and welfare are kept uppermost in mind. The training offered the resident should be properly balanced and complete. He presents in detail the three-year residency program that is used at the Campbell Clinic in Memphis.

"Resident training in a Veterans' Administration Hospital" is described by Dr. Dana M. Street, who referred to the present program at Kennedy Veterans' Administration Hospital in Memphis, Tennessee. He describes the program in use in detail and calls attention to the strong and weak points.

The program which is being used throughout the Army is described under "The Resident Training in an Army Hospital," by Colonel Milton S. Thompson. He describes the graduate professional-education in general



terms and illustrates the type of residency training in orthopaedics by means of a diagram. (Ed. Note - (R.S.B.): The admitted weakness of such a program is chiefly found in the relative paucity of crippled childrens' work in this type of hospital.) Statistics are presented showing the number of patients, both in-patients and out-patients, being treated, as well as the number of orthopaedic beds in the various Army general hospitals in the United States.

Dr. Joseph S. Barr describes briefly "Resident Training in a Navy Hospital." Here again, the greatest defect is the lack of crippled childrens' training; however, residents are being sent to civilian institutions for such training.

A description is given of "The Special Training the Resident Should Have in Cerebral Palsy," by Dr. Robert A. Knight. He emphasizes the relatively large part that Dr. W. M. Phelps of Baltimore has played in bringing a better understanding of the problems of the cerebral-palsy patient to the surgeon's attention. He describes the development of a cerebral-palsy unit and the necessary personnel for it. It is unnecessary for certain patients to spend more than a relatively short time in such a unit, after which subsequent treatment can be carried out at home.

Dr. Raymond E. Lenhard speaks about "Special Training for the Resident Staff in Infantile Paralysis." He describes the training which residents should have in various phases of care of such patients through all stages of the disease and the long convalescent period, and reiterates the need for physical rehabilitation, mental adjustment, and vocational rehabilitation.

"The Special Training the Resident Should Have in the Fitting and Making of Braces and Prostheses," is described by Dr. Atha Thomas. He states that there are few modern texts on the subject and that the literature is meager and not readily available. He emphasizes that many young orthopaedic men are deficient in their knowledge of braces and appliances due to the tendency in many places to leave this apparatus largely to the judgment of the appliance maker. He calls attention to the instructional course in brace-making given by the Mellon Institute and University of Pittsburgh Medical School, and mentions the atlas on braces and artificial limbs that is being written by the Army, Veterans' Administration and orthopaedic appliance industry.

Dr. Fremont A. Chandler speaks about "Research, Publications, Physical Medicine, and Other Special Subjects in a Resident-Training Program." He calls attention to the fact that it is only relatively late in their course that most surgeons begin to appreciate the need and satisfaction of investigative effort. He believes that residents in orthopaedic surgery should spend a certain amount of time in doing the procedures engaged in by the department of physical medicine, that they should serve as technicians for short periods in x-ray laboratories,



and become familiar with neurology and rheumatology insofar as they pertain to orthopaedic surgery.

The subject of "The Graduate School of Medicine" is presented by Dr. Jesse T. Nicholson, who states that such graduate study was planned in such a way as to lay a foundation for appropriate clinical and thesis studies so as to succeed the basic studies. He describes briefly the composition of the course at the University of Pennsylvania Graduate School along these lines.

Dr. J. Albert Key describes "What Constitutes a Satisfactory Preceptorship Training," and admits that it is inferior to formal training in orthopaedic surgery, but that it sometimes is necessary for economic reasons. He states that much depends upon the initiative of the individual in gaining the maximum benefit from this type of training. He believes that approximately twice as much time should be spent in such training contrasted with that required in a well-organized center. He believes the reason that this type of training is not conducted more frequently is "because both the candidate and the preceptor must be men of exceptional character."

"The Results of the Survey on the Requirements for Basic-Science Training" is presented by Dr. Francis M. McKeever. He describes the results of a poll that was made of 500 individuals who had taken one or both parts of the examination of the American Board of Orthopaedic Surgery during the years 1946 to 1948. The basic science requirement was approved by 93.2 per cent of those who answered. In conclusion he stated that as a result of this survey, (1) the basic science requirement should be continued; (2) clinical residencies should not be accredited for basic science training unless they fulfill certain specified requirements; (3) basic science courses in a few teaching centers should be encouraged to continue operating; and (4) the administration of basic science courses should be organized so that the resident may continue contact with clinical work during the time that he is taking basic science instruction.



## BIBLIOGRAPHY

1. Eggers, G. W. N., Shindler, Thomas O., and Pomerat, Charles M.: The influence of the contact-compression factor on osteogenesis in surgical fractures, *J. Bone Surg.*, 31 A: 693-716, Oct 1949
2. Hartley, J., Tanz, S. S., and Schneider, M.: Osteogenesis produced by a chemical extract of bone, *J. Mount Sinai Hosp.*, N. York, 15-7, 383-7, Mar-Apr, 1949
3. Follis, R. H., Jr.: Glycogen in rachitic cartilage and its relation to healing, *Proc. Soc. Exp. Biol.*, N. Y.: 71: 441-3, July 1949
4. Hoecker, F. E., and Roofe, P. G.: The metabolism and distribution of radium in bone, *Research Rev. (U. S. Navy)*, Page 10-24, Aug 1949
5. Blum, L., and Schneierson, S. S.: Intra-arterial administration of penicillin with special reference to bone marrow concentration; an experimental study, *Arch. Surg.*, 59: 176-84, July 1949
6. Thiersch, J. B., and Stock, C. C.: Bone marrow of mice-bearing sarcoma 180 treated with 4-amino-pteroylglutamic acid and with 4-aminoN<sup>10</sup>-methyl-pteroylglutamic acid, *Cancer*, N. Y., 2: 863, Sept 1949
7. Schreiber, L. F., and Schreiber, K. F.: Introducing calcium chloride complex for foot-clothing and the skin, *J. Nat. Ass. chiropod.*, 39: 23-31, Apr 1949
8. Hill, A. V.: The heat of activation and the heat of shortening in a muscle twitch, *Proc. R. Soc., Lond.*, Ser B 136: 195-211, June 23, 1949
9. Barraquer-Bordas, L.: Estudios sobre fisio-patologia neuromuscular; el reflegjo del triceps sural la contraccion ideomuscular y el fenomeno del contraste, *Clin. laborat.*, Zaragoza, 47: 326-46, May 1949
10. Malcolm, J., Griesbach, W. E., et al: Hyperplasia of the parathyroids associated with osteitis fibrosa in rats treated with thiouracil and related compounds, *Brit. J. Exp. Path.*, 30: 17-23, Feb 1949
11. Lutz, A. R., and Solomon, C. J.: Intravenous procaine in orthopedics; personal observations and review of the literature, *West Virginia M. J.* 45: 225-7, Oct 1949
12. Moore, M. L.: The measurement of joint motion; the technic of goniometry, *Phys. Ther. Rev. Chic.*, 29: 256-64, June 1949
13. Gonzalez, R. I.: Experimental tendon repair within the flexor tunnels; use of polyethylene tubes for improvement of functional results in the dog, *Surgery*, 26: 181-98, Aug 1949



14. Engstrom, A., Hamberger, C. A., and Welin, S.: A roentgen-ray microspectrographic investigation of the inflammatory destruction of the mastoid bone, Brit. J. Radiol., 22: 309-24, June 1949
15. Ghormley, R. K.: Specialization in medicine; what is orthopaedic surgery, J. Bone Surg., 31 A: 459-63, July 1949
16. Shands, A. R., Jr., et al: Conference on post-graduate education in orthopaedic surgery, J. Bone Surg., 31 A: 887-912, Oct 1949



SUBJECT INDEX

- A -

- Acetabulum, dysplasia of, 7
- Achilles reflex, 221
- Achondroplasia, 12
- Acromio-clavicular joint, disease of, 142
  - dislocation of, 149
- Acrylic implants, 210
- Actomysin, 208
- Adrenal glands, 215
- Adreno-cortico-trophic hormone, in treatment of arthritis, 78
- Adhesions, fascial grafts in, 208
- Adson maneuver, 145
- Ambulation, calculi and, 206
  - early and pelvic arthroplasty, 177
  - early, in fracture of femur, 42
- Amputation, closed, 194
  - indications for, 193
  - in tuberculosis, 193, 194
  - open, 193, 194
  - Syme, 193
  - transmetatarsal, 193
  - treatment of sarcoma, 27
- Amputee, rehabilitation of, 100
- Amyloidosis, 25, 33, 69
- Amyotrophic lateral sclerosis, EMG in, 101
- Amyotonia, 107
  - congenita, 10
- Analgesia, local, in treatment of fracture of femur, 42
- Anatomy, cadaver studies on pectoralis major, 212
  - sensory distribution to hand, 161
- Anesthesia, in amputation, 194
  - relaxants in, 212
- Ankle, arthrodesis of, 128
  - fracture of, 60, 118
    - astragalus, 119
    - malleolus, 119
    - tibial posterior lip, 118
  - fracture-dislocation of, 119
  - painful conditions of, 56
  - sprain, 57
  - strain following foot stabilization, 60
  - tears of ligaments of, 61
- Anterior tibial tendon, deforming factor, 56
- Anteversion, neck of femur, 7
- Antifolic compounds, 221



- Apparatus, abduction exercise splint for shoulder, 102
  - Abbott, 6
  - cane, 102
  - celastic cuff, 199
  - finger, splint, 162, 199
  - for fracture of facial bones, 115
  - hip splint, 199
- Arachnodactyly, 7
- Arm, conditions involving, 141, 158
  - tissue defects in, 158
- Army hospitals, resident training in, 224
- Artery, disease of, 106, 119, 193
  - compression of axillary, 107
- Arthritis, 101
  - acromio-clavicular joint, 149
  - backache and, 176
  - cervical spine, 144
  - chronic, 78
    - treatment of, 78, 80
  - foot, 57, 60
  - gonococcal, 80
  - gout, 79
  - hip joint, 43, 46, 49
  - hypertrophic, of thumb, 163
  - joint temperatures in, 103
  - knee, 133
  - nerve root involvement, 180
  - osteoarthritis, 78, 80
  - rheumatic, 78
  - rheumatoid, 78
- Arthritis deformans, pathogenesis of, 213
- Arthrodesis, ankle, 128
  - extra-articular, 128
  - foot, 193
  - hip, 49, 69, 128
    - contraindication to, 50
  - ischio-femoral, 128
  - knee, 137
  - proximal interphalangeal joint, 163
  - spine (see spinal fusion), 171
  - subastragalar, 59
  - triple, 60
  - wrist, 159
- Arthrodysplasia, 10
- Arthrogryposis, 10
- Arthrometer, pendulum, 179
- Arthroplasty, in arthritis, 81
  - hip, 49, 50, 128
    - cup, 50
  - knee, 137
  - pubosacro-iliac, 177



Artificial respiration, in polio, 95  
Aseptic necrosis, 60, 207  
    femur, 41, 44, 47, 48, 49  
Aspiration, of elbow, 116  
Aspirin, in treatment of arthritis, 78  
Astragalus (talus), fracture of, 119  
Atlas, fracture of, 116  
    measurement of, 141  
Avascular necrosis, in long bones, 119  
Axis, measurement of, 141

- B -

Back, conditions involving low back, 174, 175, 176, 177  
    backache, bony abnormalities of, 174  
        corsets and, 185  
        etiology of, 174, 175  
        endocrine disturbance, 175  
        exercise in, 101, 184  
        frustration reaction and, 175  
        in industrial medicine, 174  
        in the male, 175, 176  
        intra-spinal tumor, 178  
        malignant disease, 176  
        mechanical, 176  
        osteoarthritis and, 174  
        postural, 176  
        psychogenic, 176, 177, 186  
        spondylitis, ankylosing, 179  
        symptoms due to disease other than musculo-skeletal, 175  
Bankart operation, 148  
    modifications of, 148  
Bedrest, undesirable features of, 100  
Benzyl-imidazoline, 213  
Beri-beri, 93  
Betz cells, 10  
Biceps brachii, rupture of, 158  
    Biceps tendon, rupture of, 142  
Biceps femoris transplant, 86  
Biochemistry, research in, 208, 209  
Biopsy, drill, 29  
    needle, 22  
        of vertebral body, 185  
        of thoracic and lumbar vertebrae, 185  
Blood flow, experimental studies, 213  
    tetraethylammonium, 206, 211  
Body, growth of infants deprived of food and sunlight, 1  
Bone, accessory, 9  
    agenesis of, 9  
    bank, 127 (deep freeze, merthiolate)



- Bone - cont'd
  - block, in poliomyelitis, 86
    - in spinal fusion, 186
  - change in hemophilia, 2
  - circulatory disturbance of, 207
  - cyst of, 22
  - deformity of, in arachnodactyly, 7, 9
  - disease, in relation to nutrition, 1, 12
  - dysplasia, 11
  - dystrophy, 10
  - epiphyseal growth, 1
  - grafting, 126, 127, 128
    - forearm fractures, 117
    - general repair, 120
    - hip fractures, 118
    - tibial pseudarthrosis, 6, 7
  - granuloma, 75
  - growth, 1, 2
  - healing, 207, 220
  - histogenesis, 1
  - lengthening, 6
  - Madelung's disease, 9
  - marrow, function of, 210
    - fixation, 211
    - penicillin level in, 221
  - multiple deformities of, 9
  - optical properties, 207
  - osteomyelitis, 7, 72
  - osteoporosis, 2
  - physiologic changes, 1
  - solitary, 31, 32
  - subperiosteal, new, 11
  - tuberculosis, 6, 9
  - tumors of, 21
- Brachial artery spasm, with fracture of humerus, 119
- Brachial plexus injury, 119, 144, 145
- Brackett operation, 51, 128
- Brain, involvement in poliomyelitis, 89, 91, 92
- Breech delivery, trauma to long bones, 118
- Brill-Symer's disease, 150
- Brodie's abscess, 33
- Burns, exposure treatment, 2
  - of hand, 162
  - penicillin in, 2
- Bursa, calcaneal, 58
  - calcification about knee, 135
  - excision of shoulder bursa, 150
- Bursitis, Achilles, 58
  - calcareous, gouty, 80
  - knee, 151
  - olecranon, 159



Bursitis, cont'd

- radiation therapy in, 149, 150, 151
- radio-humeral, 151, 159
- shoulder, 142, 149, 150, 151
- subacromial, 149
- subdeltoid, 149, 150

- C -

Cafe-au-lait spots and tibial pseudarthrosis, 7

Calcaneus, 6

- calcaneal spur, 56

Calcinosis, 33

Calcium-phosphorous metabolism, 206

Calcium succinate, 78

Callus, in internal fixation, 114

- in delayed brachial plexus palsy, 119
- in diagnosis of foot injuries, 56

Cancellous grafts, 127

Cancer, research in, 21

- surgical treatment in, 23, 28
- treatment of, 22, 23

Capsulitis, of shoulder, 150

Carcinoma, bronchiogenic, 27

- metastatic, in bone, 21, 22, 27

Carpal bones, cystic lesions of, 162

- fracture of, 161
- lunate, 162
- scaphoid, 162

Cartilage, histogenesis, 1

- necrosis of, due to cold, 210
- tumor of, 22

Cast, in arthrogyposis, 10

- in clubfoot, 8
- wedging, 8

Cavus foot, 56

Cerebral palsy, resident training in, 225

Cervical, disk, 107, 143, 144

ganglia, 141

rib, 107, 145

- resection of, 145

plexus, injuries of, 144

operative approach to, 144

spine, Charcot's disease of, 147

- congenital anomalies of, 146, 147
- degenerative changes of, 142
- dislocation, 143
- fracture, 112, 143
- fracture-dislocation of, 143
- laminectomy, 143



- Cervical spine - cont'd
  - nerve root irritation, 141
  - osteomyelitis, 147
  - scoliosis of, 146
  - tomography of, 147
  - x-ray views of, 141
- Chest, crushing injuries of, 112
  - funnel, 7
- Charcot's disease, of cervical spine, 147
  - of hip, 51
  - of knee joint, 134
- Children, ages for special surgery, 10
  - bone grafting in, 6
  - Erb's palsy, 145
  - foot problems in, 57
  - fractures and dislocations, 112
  - nailing of femoral fractures, 115
  - open reduction of humeral condyle, 116
    - of tibia, 118
  - orthopedic problems, 2
  - spine fusion for tuberculosis, 70
- Chlorophyll, 72
- Chondromalacia of patella, 133, 134, 135
- Chondro-osteo-dystrophy, 11
- Chondrosarcoma, 22
- Chondroblastoma, 30
- Chondrodystrophia calcificans congenita, 2
- Chondrodystrophy, 12
- Christian-Rocher nail, 115
- Circulatory disturbances of bone, 207
- Clairmont-Ehrlich operation, 149
- Clavicle, delayed brachial plexus palsy, 119
  - dislocation of, 171
  - fracture of, 116, 119
  - intramedullary fixation of fractures of, 116
  - retrosternal dislocation, 171
- Cleido-cranial dysostosis, 10
- Closed nailing technic, 114
- Closed reduction of fractures, 113, 117
- Clubbing of digits, 8
- Clubfoot, 7
  - congenital, 56
  - idiopathic, 8
  - incidence of, 7
  - neurogenic, 8
  - surgical correction of, 8
  - treatment of, 8, 56
  - twins, 9
- Cod-liver oil, in the treatment of bowlegs, 6
- Co-existent disease of hip and foot, 66
- Colchicine, treatment of gout, 80



- Colles fracture, 117, 160
  - arthritis of, 160
  - median nerve injury, 119
- Compression factor in bone healing, 207, 220
- Compensation, patient, result in treatment of disk lesion, 184
- Congenital, accessory bones of elbow, 156
  - Anomalies of spine, 176
    - deformities, 5
      - deltoid, 10
      - digits, 9
      - forearm, 9
      - genetic factors in, 5
      - hemi-atrophy, 9
      - hereditary, 5
      - muscles, 10
      - neck, 9
      - radiation factors in, 15
    - derangement of knee, 133
    - dislocation of hip, 66
      - of patella, 133
    - palsy of upper extremity, 145
    - subluxation of shoulder, 148
- Contracture, digits, 14
  - foot, 57
  - hand, 162
  - joints, 7
- Coccidiomycosis, 75
- Coccygodynia, 178
- Copper, deficiency of, 177
- Coraco-clavicular joint, anomalous, 150
- Cordotomy, 195
- Cortical hyperostosis, infantile, 10
  - diaphyseal, 11
- Cortisone, in treatment of arthritis, 78
- Costal joints in spondylitis, 79
- Costoclavicular compression syndrome, 145
- Corset syndrome, 185
- Coxa plana, 47
- Coxa vara, 51, 67, 200
- Cracking joints, 80
- Cretinism, 12
- Cruciate ligament, damage of, 135
- Cubitus varus, 200
- Curare, 79, 212
  - in polio, 94
- Cyst, bone, 22
  - cestode, of spinal cord, 106
  - meniscus, 135
  - solitary, of calcaneus, 58
- Cystic lesion, of carpal bones, 162
  - humeral head, 142
  - spinal cord, 146



Cytologic diagnosis, 22  
Cytotoxic poisons, 21, 23  
    serum, treatment of arthritis, 80

- D -

Decubitus ulcer, 72  
Deformity of foot, 57  
    in poliomyelitis, 86  
Degenerative changes, of shoulder, 142, 149  
    of cervical spine, 142, 143, 144  
Delayed union, 126  
    in external skeletal fixation, 114  
Delitala operation, 148  
Deltoid muscle, congenital defect, 10  
Denis-Browne splint, 8  
Dental aplasia, 9  
De Quervain's disease, 161  
Development of skeleton, 213  
Dextran, 212  
Diabetes, amputation in, 193, 194  
    osteitis deformans, and, 209  
Diasone, 69  
Diastasis, tibio-talar, 60  
Dicalcium phosphate, 40  
Digits, arachnodactyly, 7  
    contracture of, 14  
    deformity of, congenital, 9  
    polydactylism, 10  
    reconstruction of, 163  
    syndactylism, 10  
Disarticulation, of sacro-iliac, 186  
Dislocation, acromio-clavicular, 149  
    ankle, 119  
    carpus, 9  
    elbow, 159  
    foot, 60  
    gracilis tendon, 136  
    hip, 7, 44, 112  
    os calcis, 112  
    patella, 118  
    shoulder, 112, 148  
    sterno-clavicular joint, 171  
    surgical repairs, 148  
    temporomandibular joint, 116  
    ulna, 9  
    wrist, 119  
Disseminated sclerosis, 177  
Dupuytren's contracture, 164  
Dwarfism, 11, 12



Dysplasia, epiphysialis punctata, 2  
of acetabulum, 7  
Dystrophy, hemiplegia, 141  
herpes, 141  
osteoarthritis, 141  
reflex due to heart disease, 141  
trauma, 141  
Dysontogenetic theory, 177

- E -

Eden-Hybinette's bone block operation, 148, 149  
Education, of orthopedists, 223, 224, 225, 226  
Edwin Smith Papyrus, 112  
Effusion, of knee joint, 136  
Ehlers-Danlos syndrome, 11  
Elbow, conditions involving, 158  
dislocation, 159  
fractures involving, 116, 159  
Electrical stimulation, and venous thrombosis, 102  
Electromyography, in amyotrophic lateral sclerosis, 101  
in hysteria, 101  
intervertebral disk, 101  
malingering, 101  
muscle dystrophy, 101  
myasthenia gravis, 101  
Parkinson's disease, 101  
peripheral nerve injury, 101  
poliomyelitis, 93  
spastic disease, 101  
spondylitis, 79  
torticollis, 146  
Elephantiasis, 59, 137  
Embryology, of human vertebral column, 6  
Embolism, arterial, 106  
Endocrine, disturbance and backache, 175  
factors in growth, 213, 214  
fetal development, 5  
glands, response to chemicals, 222  
Eosinophilic granuloma, 22, 25  
Epidemic poliomyelitis, management of, 91, 95  
Epidemiology, of poliomyelitis, 84, 85, 89, 90, 91  
Epiphyseal  
arrest, 1  
dysplasia, 2  
growth, 1  
ossification, 213  
plate, 14  
separation of tibial, 112  
stapling, 1  
stippled, 2  
Epiphysis, slipped femoral, 45  
osteochondrosis of femoral, 47  
drilling of, 47



Ertron poisoning, 206  
Equinus, 6  
Erb's palsy, 145  
Erythralgia, 59  
Erythromelalgia, 58  
Exercise, for low back pain, 184  
    passive, in poliomyelitis, 100  
    progressive resistance, 50, 101  
    research in, 103  
    shoulder elevating, 145  
Exploration, surgical, of disk lesions, 182, 183, 184, 185  
External skeletal fixation, 113  
    infection in, 113  
    Roger-Anderson, 113, 114  
    Stader splint, 114  
Extra-articular arthrodesis, of hip, 128  
Extremity, epiphyseal stapling, 1  
    growth prediction, 1  
    leg lengthening, 1  
    reflex dystrophy of, 141  
    tibial torsion, 2  
Ewing's tumor, 21, 24

- F -

Familial periodic paralysis, 107  
Fasciotomy, in poliomyelitis, 86  
Fat embolism, 120  
Fat pad, hypertrophy, in knee, 133  
Femoral head, blood supply of, 128  
Femoral shaft, fracture of, 113  
    intramedullary nail, 115  
    nonunion of, 129  
    pathological fracture, 115  
Femur, absence of head, 50  
    fracture of, 40  
    osteoporosis of, 51  
    slipping of epiphysis, 45  
Fever therapy, treatment, Reiter's syndrome, 79  
    treatment, gonococcal arthritis, 80  
Fibroma, ossifying, 32  
Fibrous dysplasia, 32  
Fibrosarcoma, 26  
Fibrositis, 80  
    backache and, 176  
Fibula, fracture of malleolus, 118  
    shaft, 113  
Finger, dorsal aponeurosis of, 160  
Fistula, arteriovenous, 1  
Flat foot, 8  
    secondary, 57  
    traumatic, 59  
Flocculation test for poliomyelitis, 90  
Foetus, development, 1, 2, 5, 6



Foetus, cont'd  
     malformations, 5  
 Foot, acute injury of, 56  
     arthrodesis in, 59  
     cavus of, 56  
     complaints due to high heels, 57  
     deformities of toes, 57  
     dislocation, 60  
     drop, 60  
     industrial conditions of, 56  
     measurements of, 56  
     myalgia of, 57  
     painful condition of, 56, 60  
     peritendinitis of, 58  
     pronation of, 57  
     sesamoid bones of, 56  
     short first metatarsal, 56  
     sprains of, 57  
 Forearm, "both bones", fracture, 117, 160  
     conditions involving, 8, 15  
     congenital deformity, 9  
     open reduction of fracture, 117  
     tendon repairs, 159  
 Foramina, arthritis and, 180  
 Fracture, of ankle, 60, 118, 119  
     ankylosed spine, 171  
     astragalus, shaft of, 119  
     atlas, 116  
     avascular necrosis with, 119  
     base of thumb metacarpal, 161  
     "both bones" of forearm, 117, 160  
     callus, 114, 119  
     carpal bones, 160, 161  
     carpal scaphoid, 160  
     cervical spine, 112  
     children, 112, 115, 116, 118  
     clavicle, 116, 119  
     closed treatment, 113, 117  
     Colles, 117  
     comminuted, 113  
     compound, 113  
     conservative treatment of, 40  
     delayed union, 114  
     elbow, 116  
     emergency treatment of, 112  
     facial bones, 115  
     femur, 40, shaft of femur, 113, 115  
     fibula, 113, 119  
     foot, 59  
     general, 112



## Fractures - cont'd

- gunshot, 127
  - hip, 112, 113, 115, 118
  - humerus, 115, 116, 117, 119
  - immobilization of, 112
  - internal fixation, 40, 41, 42
  - intracapsular, of femur, 118
  - instruction, in medical school, 112
  - intrauterine, 118
  - lower extremity, 117
  - metacarpal, 117
  - Nicoll classification, 170
  - nonunion, 112, 114, 117
  - open treatment, 114, 116, 117, 118
  - os calcis, 59, shaft of, 119
  - osteotomy, 116, 118
  - patella, 135
  - pathological, 32, 115
  - pelvis, 112
  - radius, 112, 115, 116, 117, 160
  - ribs, 112, 116
  - spine, 170
  - spontaneous, 6, 25
  - splinting, 112
  - suspension treatment, 113
  - table, portable, 44
  - talus, 58, 59, 60
  - tibia, 113, 115, 118, 119, 120
    - shaft of, 113, 115, 118
  - tibial condyle, 136, 200
  - tibial spine, 135
  - transportation of, 112
  - ulna, 112, 115, 117, 160
  - upper extremity, 116
  - vertebrae, following shock therapy, 171
  - with fat embolism, 120
  - wrist, shaft of, with median nerve injury, 119
- Fracture-dislocation, of hip, 44
- Fracture deformities, bone graft in, 126
- bony loss, 126
  - delayed union, 126
  - infection, 126
  - internal fixation, 126
  - nonunion of tibia, 126
  - skin coverage, 126
- Fragilitas ossium, 7
- Friedreich's ataxia, 10
- Frozen shoulder, 142
- manipulation of, 149
- Fungistatic compound, 221
- Funnel-chest deformity, 171
- Fusion, spinal, 183, 184, 185
- bone block and, 186



- Ganglion, 33
  - of palm, 161
- Gangrene, gas, 75
  - of shoulder, 150
  - of toes, 193
- Gargoylism, 11, 12
- Gelatin sponge, 206
- Genetic factor in congenital deformity, 5
- Genu recurvatum, 136
- Genu valgum, 133, 200
- Genu varum, 6
- Giant cell tumor, 22, 28, 29
- Gibbus, 13
- Glove prosthesis, 198
- Glycogen, relation to calcification, 220
- Goldthwait procedure, patella, 118
- Goniometry, 222
- Gout, 79, 80, 208
- Gracilis tendon, dislocation, 136
- Graft, bone, autogenous, 6
  - bone, to spine (see spinal fusion)
  - bone, in tibial pseudarthrosis, 6, 7
  - fascial, 208
  - skin, in amputation stumps, 193
  - historical, 211
  - in treatment of clubfoot, 8
- Granuloma, of bone, 75
- Guillain-Barre syndrome, 94
- Gunshot fractures, 127

- Hand, arthritis of, 160
  - conditions involving, 158
  - contractures, 162
  - dorsal aponeurosis of finger, 162
  - dorsal burns, 162
  - hypertrophy of thenar muscles, 161
  - sensory distribution, 161
  - sesamoid bones, 56
  - tendon repair, 159, 206
  - treatment of injuries, 161
- Hansen-Streeter nail, 115
- Hand-Schuller-Christian disease, 25, 32
- Hallux valgus, 57
- Hammertoe, 57
- Hamstring transplant, 86
- Headache due to cervical pathology, 147
- Heart disease, association of shoulder-hand syndrome, 141



- Heat, treatment of poliomyelitis, 84, 94, 101  
Heel, valgus of, 56  
Hemangioma, primary, 25  
    secondary, 26  
Hemophilia, 2  
Hemiatrophy, congenital, 9  
Hemipelvectomy, 194  
    prosthesis for, 198  
Henderson operation, shoulder, 148  
Heredity, in congenital anomalies, 5  
    coxa vara, 67  
    hip dislocation, 66  
Herpes Zoster, 93  
Hip, ankylosis, 69  
    arthrodesis, 69, 128  
    arthroplasty, 128  
    central dislocation, 112  
    congenital dislocation, 7, 66  
    diseases, 66  
    dysplasia, 66  
    fracture, 112, 118  
    fracture-dislocation, 113  
    fracture, nonunion of, 127  
    fracture, internal fixation, 128  
Histology, innervation of articular capsule, 2 11  
    muscle fiber, 207  
Hodgkin's disease, 23, 176  
Hoffa's lesion, 133  
Homogenous grafts, 127  
Hormones, relation to fetal development, 5  
    sex, in treatment of degenerative arthritis, 80  
    therapy in osteoporosis, 51  
    thyroid stimulating, 12  
Humerus, brachial artery spasm, 119  
    degenerative changes of head, 142  
    fracture of, 115  
    fracture of external and internal condyle, 116  
    fracture of upper end, 116, 117  
    intramedullary fixation, 115, 116  
    open reduction in children, 116  
Hyaluronic acid, 209  
Hyaluronidase, 209  
Hydrocephalus, 13  
Hyperparathyroidism, 22, 32  
Hysteria, electromyography in, 101  
    mass, in poliomyelitis, 95

- I -

- Iliotibial band, in poliomyelitis, 86  
Ilium, bone of, 10



- Immobilization, in burns, 2
  - fractures, 112, 114
  - pseudarthrosis of tibia, 6
- Industrial, backache, 174
  - conditions of the foot, 56
  - injuries of shoulder, 147
  - medicine, 174
  - trauma, emergency treatment, 113
- Infantile paralysis, 84, 89
- Infants, trigger thumb, 163
- Infection, bone, 72
  - external skeletal fixation, 113, 114, 115
  - finger pulp, 126
  - of joints, 72
- Infectious disease, in infancy, 5
  - in pregnancy, 5
- Inflammatory destruction of bone, 223
- Injury, and gout, 80
  - of hand, treatment of, 161
- Instability, of anterior thorax, 171
- Instruments, bone plate forceps, 198
  - self-retaining retractor, 198
- Internal derangement, of knee, 133, 135
- Internal fixation, 126, 128
  - blade-plate, in femur, 118
    - bone grafting, 120
  - children, 114
  - Christian-Rocher, 115
  - Colles fracture, 117
  - fracture of femoral neck, 40, 41, 42
  - forearm, 117
  - intramedullary nail, 114
  - Kuntscher nail, 114, 116, 118
  - metals utilized, 114
  - open technic, 114
  - present concepts, 114
  - tibial spine, 135
  - two-plane type, 114
  - ulna, 9
- Interossei, function, 160
- Intervertebral disk, cervical, 143, 144
  - differential diagnosis, 180
  - herniation, 112
  - historical, 179
  - infection following lumbar puncture, 74
  - localization by electromyography, 101
  - ruptured, 174, 176
- Intervertebral foramina, narrowing of, 141
  - normal motion of, 142
- Intramaxillary wiring, 116
- Intramedullary nail, 114, 115
  - Christian-Rocher, 115
  - closed technic, 114
  - Kuntscher, 114
  - Rush pin, 114



Intrauterine fractures, of tibia, 118  
Ischemia, of limbs, 106  
Ischiofemoral arthrodesis, 128

- J -

Joint, arthritis, chronic, of, 78  
arthrodysplasia, 10  
arthrogryposis, 10  
aspiration of elbow, 116  
bone block in, 86  
cracking of, 80  
deformity of, 10  
degenerative disease, 101  
fracture, of ankle, 119  
fracture, of elbow, 116  
fracture, of wrist, 119  
hemangioma of, 25  
hypermobility of, 7  
interarticular arthritis of, 176  
infectious arthritis of, 80  
gout, 79  
temperature measurement of, 103  
range of motion, 200, 222  
tuberculosis of, 69  
Judet prosthesis, 50

- K -

Kienbock's disease, 129, 162  
Kinesiology, 208  
Klippel-Feil syndrome, 9  
Klumpke's paralysis, 145  
Knee, exercise of, 101  
Knee joint, arthritis of, 133, 134  
arthrodesis of, 137  
arthroplasty, 137  
calcified bursae, 135  
Charcot's joint, 134  
conditions involving, 133  
effusion of, 136  
fat pad hypertrophy, 133  
internal derangement, 133, 135  
loose bodies in, 135  
osteoarthritis, 134  
osteocondritis, 133  
penetrating wound of, 136  
quadriceps atrophy, 133  
rheumatoid arthritis, 134  
tibial spine fracture, 135  
tuberculosis, 134



Kuntscher nail, 126  
Kyphosis, 7, 11, 12, 13, 14

- L -

Lag screw, 44  
Lambrinudi operation, 60  
Laminae, defects in, 175  
Laminectomy, in achondroplasia, 13  
    in scoliosis, 13  
Latissimus dorsi transplant, 86  
Legg-Perthes' disease, 47  
Letterer-Siwe's disease, 25  
Ligamentum flavum, structural variations in, 175  
Limb length, inequality and backache, 176  
    maintenance of in fractures, 113  
Limb shortening, 129  
    subtrochanteric, 129  
Lipoid, 12  
Lipoma arborescens, 133  
Lobectomy, prefrontal, 186  
Lobotomy, prefrontal, 135  
Long bones, trauma during delivery, 118  
    avascular necrosis, 119  
Loose bodies, of knee, 135  
Lorenzo screw, 50  
Low back pain, manipulation, 112  
Lower extremities, spastic weakness of, 145  
Lumbago, 174  
Lumbarization, 175  
Lumbrical function, 160  
Lunate bone, osteomalacia of, 129  
Lymphadenoma, 24  
Lymphosarcoma, 24

- M -

Madelung's deformity, 9, 160  
Madura foot, 59  
Malignancy, metastatic, backache and, 176  
Malignant disease, amputation and, 194  
    of bone, 21  
Malingering, electromyography in, 101  
Malleolus, fracture of, 60  
Manipulation, 200  
    arthrogryposis, 10  
    clubfoot, 8  
    in the treatment of bowlegs, 6  
    shoulder joint, 149, 150  
    spine, 185  
    tennis elbow, 159  
    treatment of chronic arthritis, 81  
Marfan's syndrome, 7  
Marie-Strumpell's arthritis, 79  
Marjolin's ulcer, 194



- Measurements of body in relation to strength, 212
- Mechanical factors, in relation to congenital deformity, 5
- Median nerve, injury, 119
  - palsy, 159
- Medicolegal, 45
  - problems, 129, 130
  - significance in spondylolisthesis, 176
- Melanoma, malignant, 27
- Meningioma, of cord, 143
- Meningitis, pneumococcal in infants, 5
- Meningocele, 13
- Meniscus, cyst of, 135
  - instrument for removal of, 137
  - tear of, 133, 134, 135
  - tensile strength, 133
- Metacarpal, fracture, 117
  - transfer, 163
- Metatarsal, short first, 56
- Metatarsalgia, 56
- Metatarsus, adductovarus, 56
  - varus, 8
- Metabolism, calcium and phosphorous, 206
  - in paraplegia, 206
  - nitrogen balance, 208
- Metastatic carcinoma, pathological fracture, 115
- Methadon, 212
- Microcephalia, 5
- Microspectrography, 222
- Monteggia fracture, 160
- Morquio-Brailsford disease, 12
- Mortality in fracture of femur, 40, 41, 42
- Morton's toe, 57
- Muscle, congenital defect, 10
  - deltoid defect, 209
  - fiber, physiology of, 209
  - functional tests and training, 102
  - histology, 207
  - hypertrophy of, 161
  - In hypotassemia, 106, 108
  - motor end plates, 10
  - myositis ossificans, 10
  - paralysis of, 106
  - peroneal atrophy, 10
  - physiology, 103, 208, 221
  - shunt, 208
  - spurt, 208
  - testing of low back, 184
- Muscle dystrophy, EMG in, 101
  - facio-scapulo humeral, 107
  - hypertrophic, 107
  - progressive, 107
  - pseudohypertrophic, 107



Musculo-tendinous cuff, inflammation of, 150  
    rupture of, 142  
Multiple myeloma, 21, 22, 24, 176  
    pathological fracture, 115  
Multiple neuritis, 33  
Myalgia, of foot, 57  
Myasthenia gravis, 107  
    EMG in, 101  
Mycotic infection, of foot, 59  
Myelodysplasia, 177  
Myelopathy, in achondroplasia, 12  
Myodystrophia foetale deformante, 8, 10  
Myositis ossificans, 10, 22  
    in paraplegia, 109  
Myometer, 212

- N -

Nail starter, 44  
Navy hospitals, resident training in, 225  
Nearthrosis, 6  
Neck, conditions involving, 141  
    intervertebral disk lesion, 143  
    torticollis, 146  
    pathology causing headache, 147  
Neoplasm, intraspinal, 178  
Neostigmine, diagnostic, 107  
Nerve, axillary, 141  
    block, 149  
    injury of, 200  
    musculocutaneous, 141, 149  
    neurectomy, 43, 49, 81, 141, 186  
    to shoulder joint, 141  
    subscapular, 141  
    suprascapular, 141  
    surgery of, 186  
    suture of, 200  
    tantalum foil cuff of, 200  
Nerve roots, effect of sprains, fractures, and arthritis, 147  
    involvement in arthritis, 180  
Neuralgia, 201  
Neurectomy, in arthritis, 81  
    in shoulder joint pain, 141  
    obturator, 43, 49  
    presacral, 186  
Neuritis, due to penicillin, 106  
    sciatic, 174  
Neuro-arthropathy, 22  
Neurofibroma, 7, 32, 33, of cord, 143  
Neurofibromatosis, 6  
Neuroma, in amputation pain, 195, 196



Neuromuscular disorders - not poliomyelitis, 106  
 Neuropathic joint, knee, 136  
 Neuropathy, infectious, 109  
     metabolic, 109  
     penicillin, 106  
     toxic, 109  
     treatment of, 108  
 Neutralizing antibodies, in poliomyelitis, 90  
 Nicola operation, 148  
 Nitrogen balance, 208  
 Nitrogen mustard, 23  
 Nonparalytic poliomyelitis, 85  
 Nonunion, of carpal scaphoid, 162  
     external skeletal fixation and, 114  
     femoral neck, 112, 127  
     femoral shaft, 129  
     forearm bones, 117  
     ulna, 9  
     upper femur, 40, 41  
 Nucleus pulposus, differential diagnosis, 180  
     herniation of, 174, 176, 177, 178, 179  
     historical, 179  
     radiographic diagnosis, 181, 182  
     treatment, 182  
 Nutrition, association with bone disease, 1, 2, 5  
     in poliomyelitis, 100  
     influence on skeletal growth, 216, 200  
 Nutritional deficiencies, 1, 5, 14  
 Nylon, sutures, 211

- 0 -

Obturator nerve, distribution, 43  
 Odontogenesis imperfecta, 2  
 Olecranon, fracture, 159  
 Ollier's disease, 12, 31, 32  
 Open reduction, of fractures, 114, 117  
 Opponens transfer, 159  
 Orthopedic Surgery, postgraduate training, 223  
     training program, adult, 223, 224, 225  
     training program, children's 223, 224, 225  
     training in basic sciences, 224, 226  
 Os calcis, cyst of, 58  
     dislocation of, 119  
     fracture of, 59, 119  
 Os cubiti anterius, 9  
 Osgood-Schlatter's disease, 135  
 Ossification, 1  
 Osteitis, in external skeletal fixation, 114  
     of pubis, 174  
     of spine, 171



- Osteitis deformans, 81
  - protamine zinc insulin in, 209
- Osteitis fibrosa disseminata, 2
- Osteoarthritis, 31, 46, 49
  - achondroplasia, 12, 13
  - etiology, 80
  - in males, 175
  - of knee, 134
  - retirement for, 174
  - silent, of spine, 175
- Osteochondritis, of femoral condyle, 133, 135
  - of patella, 134
  - of talus, 58
- Osteochondroma, 31
- Osteochondromatosis, of shoulder joint, 150
- Osteochondrosis, femoral head, 47, 48, 49
  - investigation of etiology, 47, 48
- Osteoclastoma, 28, 29
- Osteogenesis, 207, 220
- Osteogenesis imperfecta, 2, 11, 32
- Osteogenic sarcoma, 221
  - substance, 220
- Osteoid osteoma, 32, 33
- Osteolytic lesions, of metatarsals, 61
- Osteomalacia, 80
- Osteomyelitis, 7, 21
  - carcinoma and, 75
  - cervical spine, 147
  - due to staphylococcus aureus, 72
  - of scapula, 150
  - sclerosing, 33
  - surgery in, 72
  - syphilitic, 74
  - treatment of, 72
  - unusual forms, 73
  - with fibrosarcoma, 26
- Osteopetrosis, 11
- Osteoporosis, 2, 80
  - following burns, 2
  - in elderly females, 2
  - of hip, 51
  - postmenopausal, 175
- Osteophyte, vertebral, 12, 13
- Osteosynthesis, 42
- Osteotomy, 118
  - dislocated hip, 66, 67
  - femur, 41, 44, 46, 47, 51
  - femoral neck, 128
  - foot, 8, 59
  - for coxa vara, 200



Osteotomy - cont'd  
  mandible, 116  
  tibia, 129  
  ulna, 9  
Oxythiamine, 94

- P -

Paget's disease, 21, 22, 28, 29, 32, 81, 176  
  pathological fracture, 115  
Pain, anesthetics for, 212  
  coccyx, 178  
  following amputation, 195, 196  
  intractable, 186  
  intravenous procaine in, 207, 222  
  ischemia and, 106  
  lumbosacral, 174, 176  
  pelvic, 175, 176, 177  
Para-amino salicylic acid, 69  
Paralysis, due to hypopotassemia, 106  
  in poliomyelitis, 84, 85  
  of palate, 85, 95  
  of quadriceps, 86  
  respiratory, 85, 95  
  triceps, 86  
Paraplegia, 178  
  abdominal calcification in, 171  
  achondroplasia and, 13  
  calcium metabolism in, 206  
  due to Pott's disease, 70  
  from cervical spine injury, 143  
  laminectomy in, 109  
  myositis ossificans, 109  
  neurectomy in, 109  
  scoliosis and, 13  
  tendon lengthening in, 109  
  traumatic, 109  
Parathyroid hormone, 2  
Parathyroids, 215  
Paratyphoid infection, 73  
Paravertebral abscess, 70  
Palpometer, 199  
Parkinson's disease, 101, 109  
Patella, chondromalacia of, 133, 134, 135  
  congenital absence of, 9  
  congenital dislocation of, 133  
  fracture, 135  
  osteochondritis dissecans of, 134  
Patella cubiti, 158  
Pathological fracture, of femur, 115  
Pectoralis major, rupture of, 158



- Pedicle graft, 61  
Pegging operation, 46, 49  
Pellegra, 93  
Pelvis, fracture of, 112  
Penicillin, 72  
    in hand infections, 163  
    intravenous administration, 221  
    level in bone marrow, 221  
    neuritis toxic, 106  
    treatment of gonococcal arthritis, 80  
Percussion, in treatment of phantom limb, 195  
Periarthritis, gouty, 80  
    of shoulder, 149  
Peripheral nerve injury, electromyography in, 101  
    surgery in, 108  
Periodic paralysis, 85  
Periosteal callus, 114  
Peritendinitis, of foot, 58  
Persson's frame, 116  
Peroneal muscle weakness, 8  
Phalanges, chondromata of, 12  
Phalangization, 163  
Phantom limb, 195  
Pharmacology, response of endocrine glands to chemicals, 222  
Phrenic nerve paralysis, 145  
Physical activity in poliomyelitis, 93  
Physical medicine, departments of, in England, 100  
    review of subject, 100  
    research in, 103  
    residents' training in, 225  
Physical reconditioning, in poliomyelitis, 100  
Physiology, research in, 206, 208, 209, 221  
Phosphatase, 1  
    technic, 211  
Phosphorous, 32, 209  
Pituitary growth hormone, 213, 214  
Plasma, in poliomyelitis, 94  
Plastics in surgery, 210  
Plastic Surgery, historical, 211  
Polydactylism, 10  
Polyethylene, 211  
    tissue stimulant, 206  
    tubes, 222  
Poliomyelitis, anterior, 1  
    artificial respiration in, 95  
    bulbar, 86, 92, 95  
    care of aftereffects, 100  
    clinical course, 89  
    diagram of, 85, 93  
    electromyography in, 93  
    epidemiology, 84, 85, 89, 90, 91  
    flocculation tests for, 90



- Poliomyelitis - cont'd
  - historical, 89, 93
  - hysteria in, 95
  - immunity in, 90
  - in the Arctic, 85
  - in the Far East, 91
  - muscle activity and, 93
  - neurophysiology, 99
  - nonparalytic, 85
  - orthopedic appliances in, 95
  - paralysis in, 84, 85
  - pathology in, 91, 92
  - program, 93
  - research in, 89, 94
  - rocking bed in, 95
  - statistical survey, 90
  - surgery for deformities, 86
  - sympathetic nervous system in, 84
  - treatment in, 84, 85, 94, 95, 100
  - virus strains, 84, 85, 89, 90
- Poisson's ratio, 41
- Posture, backache and, 176
- Potassium, paralysis in low serum concentration, 106
  - treatment of periodic paralysis, 85
- Pott's disease, 70
- Preceptorship training, 226
- Prefrontal lobotomy, 195
- Pregnancy, environmental factor related to congenital deformities, 5
  - infection in, 9
- Priscol, 211
  - treatment of chronic arthritis, 80
- Private clinic, resident training, 224
- Procaine block, nerves to hip, 42
  - intravenous, for pain, 207, 222
- Progesterone, in treatment of arthritis, 78
- Prognosis, in fracture of femur, 40
- Progressive muscular atrophy, EMG in, 101
- Progressive resistance exercise, 50
- Pronation, of foot, 57
- Prosthesis, plastic glove, 198
  - slip socket, 198
  - suction socket, 197
- Pseudarthrosis, 22, 127
  - carpal scaphoid, 162
  - femur, 137
  - femoral neck, 128
  - spine fusion, 171
  - tibia, 6, 7
- Psychotherapy, low back pain and, 186
- Pubis, osteitis of, 74
- Pulmonary embolism, prevention of, 102



Quadriceps tendon, rupture of, 136

- Rachitogenic diets, 208, 220  
Radiation therapy, 23, 24, 25, 28, 29  
    effects upon fetal development, 5  
    lumbosacral pain, 186  
    myasthenia gravis, 107  
    necrosis, 22, 23  
    osteoarthritis, 80  
    research, 221  
    treatment of plantar wart, 57  
Radial head, fracture of, 159  
Radial nerve, palsy of, 159  
    suture of, 108  
    tardy paralysis, 108  
    transplant, 119  
Radicular tumor, 107  
Radiculitis, cervical, 143  
Radio-active isotopes, 21, 23, 25  
Radiodermatitis, 57, 58  
Radium therapy, 29  
    poisoning, 221  
Radius, "both bone" fracture, 117  
    congenital absence of, 9  
    epiphyseal growth, 9  
    fracture of, 112, 116, 160  
    Internal fixation, 160  
    intramedullary nail, 115  
    Madelung's deformity, 9  
Raynaud's disease, 58, 207  
Reconstruction of digits, 163  
Refrigeration, in amputation, 194  
Regional Accident Service, organization of, 112  
Rehabilitation, center of, in England, 100  
    in poliomyelitis, 100  
    of amputee, 100  
    of knee, 135  
    retraining shop, 102  
Reiter's syndrome, 79  
Renal calculi, 206  
Research, 206, 220  
    cancer, 2  
    physical medicine, 103  
    publications, 225  
Responsibilities, of physician in poliomyelitis, 101  
Reticulo-sarcoma, 25  
Reticulo-endotheliosis, 25  
Retirement, government employees, 174  
Rheumatic arthritis, 78, 79  
    spondylitis, 79



- Rheumatoid arthritis, 78
  - effect on nerve roots, 142
  - hyaluronic acid and, 209
  - knee, 134
  - physical therapy in, 103
  - relation to ankylosing spondylitis, 179
  - wrist, 160
- Rheumatoid spondylitis, 79, 171, 179
- Rhizotomy, 186
- Ribs, fracture of, 116
  - supernumerary dorsal, 10
- Rickets, research in, 208
- Roentgenography, arthrogram of shoulder, 142
  - aspects of dwarfism, 11
  - blurring of shadows, 141
  - cervical spine, 141, 147
  - chewing technic, 141
  - effects of radiation on fetal development, 5
  - examination of the spine, 181
  - in epiphyseal dysplasia, 2
  - of the hip, 45
  - Ollier's disease, 12
  - skeletal x-rays, 21
  - study of normal premature infants, 1
  - technic of examination in spondylitis, 79
  - tomography, 210
- Rocking bed, in poliomyelitis, 95
- Rubella, in relation to congenital anomalies, 5
- Rupture, of quadriceps tendon, 136
- Rush pin, 114

- S -

- Sacral nerve, surgery of, 186
- Sacroiliac joint, disarticulation of, 186
  - in spondylitis, 79
- Salmonella infection of knee, 134
- Sarcoidosis, 75
- Sarcoma, bone, 21, 22
  - congenital, 26
  - Ewing's, 33
  - osteogenic, 27, 28
  - preoperative treatment, 23
  - treatment of, 22, 23
- Saucerization, 73
- Scalenus anticus syndrome, 107, 145
- Scalenotomy, 145
- Scapulo-humeral joint, 148
  - manipulation of, 149
- Scapula, cyst of, 150
  - fracture of coracoid process, 150

(254)



Scapula - cont'd  
     osteomyelitis of, 150  
     pathological fracture of, 150  
 Sciatica, pathogenesis of, 180  
 Sciatic nerve, lesions of, 61  
 Schmorl's node, 177  
 Sclerosis, diaphyseal, 11  
     disseminated, 177  
     of lunate bone, 162  
 Scoliosis, cervical spine, 146  
     idiopathic, 170  
     pathogenesis, 170  
     structural changes in, 14  
     treatment of, 170  
 Sensory pathways, of shoulder joint, 141  
     surgical intervention of, 141  
 Sequestrectomy, 73  
 Serratus anterior, paralysis of, 106  
 Sesamoid bones, fracture of, 56  
 Sex hormones, effect on growth, 213, 215  
 Sexual potency of male, cord injuries and, 178, 179  
 Shand's collar, 143  
 Shock therapy, fracture of vertebrae, 171  
 Shortening operation, on lower limb, 129  
 Shoulder, abduction exercise splint, 102  
     bursitis of, 142  
     calcium deposits, 149, 150, 151  
     capsulitis of, 147,  
     conditions involving, 141, 147  
     congenital subluxation of, 148  
     exercise of, 101  
     dislocation of, 147, 148  
     fracture-dislocation, 147  
     "frozen", 142  
     gas infection, 150  
     industrial injuries, 147  
     joint lesions, 142  
     manipulation of, 149, 150  
     osteochondromatosis, 150  
     pain, differential diagnosis of, 142  
     painful, 142  
     periarthrititis of, 142, 149, 150  
     sensory pathways of, 141  
     surgical approach, 148  
 Shoulder-Hand syndrome, 141  
 Skeletal deformities, research, effect of cold, 210  
 Skeletal growth, 213  
 Skewfoot, 56  
 Skin flaps, 61  
 Skin grafts, 73, 126  
     arm, 158  
     for open knee knjury, 136  
     pedicle for finger, 163  
     replaceable blade knife, 199



- Sickle-cell anemia, 26
- Sign, posterior tibial nerve, 180
  - Lasegue, 180
- Slip sockets, 198
- Slipped femoral epiphysis, 45, 128
- Smith-Petersen, surgical approach to hip joint, 50
- Spastic disease, EMG in, 101
- Splints, of fractures, 112, 113
  - physiological, in poliomyelitis, 95
- Spina bifida, 175, 178
  - of cervical spine, 9
  - sacral, 13
- Spinal cord, angioma of, 146
  - compression of, in Paget's disease, 81
  - cyst of, 106
  - cystic lesion of, 146
  - degenerative disease of, 143
  - hemangioma, 143
  - neurofibroma, 143
  - transplantation of, in Pott's disease, 70
  - traumatic paraplegia, 169
  - tumors and, 178
  - wounds, 178
- Spinal fluid, in Guillain-Barre, 94
  - in poliomyelitis, 92
- Spinal fusion, 171, 13, 70, 183
  - pseudarthrosis of, 171
- Spinal segments, cervical, 141
- Spine, abnormalities of, 177
  - canal of, 8
  - conditions involving, 170
  - developmental errors of, 177
  - fractures of, 170
    - of ankylosed spine, 171
  - fusion of (see spinal fusion)
  - laminae defects in, 175
  - osteitis of, 171
  - osteomyelitis of, 174
  - spondylitis of, 171
  - syphilis of, 74
  - tuberculosis of, 69
- Spondylolisthesis, asymptomatic, 175
  - bilateral foot drop and, 178
  - dissection study of, 175
  - myelogram and, 181
  - reversed type, 180
  - unilateral defect, 177
- Spondylitis, 171
  - ankylosing, 179
  - nontuberculous, 74
  - rheumatoid, 79



Spondylometer, 179  
 Sprain, of foot and ankle, 57, 61  
 Steinert's disease, 107  
 Sternoclavicular joint, 148  
 Sternum, skeletal traction in, 171  
 Streptomycin, in hand infection, 163  
     treatment of osteomyelitis, 74, 75  
     treatment of tuberculosis, 69  
 Stretching, treatment of poliomyelitis, 94  
 Strain, iliolumbar, 174  
     lumbosacral, 174  
     sacroiliac, 174  
 Stump lengths, ideal, 196  
 Subscapularis, rupture of, 142  
 Subluxation, of first metatarso-phalangeal joint, 8  
     of hip, 7  
     of ulna head, 9  
 Suction socket prosthesis, 197  
 Sulfone, 69  
 Sulfonamides, in poliomyelitis, 94  
     gonococcal arthritis, 80  
 Suprascapular nerve block, 149  
 Supracondylar wire, for traction, 113  
 Supraspinatus, calcification of, 142  
     degeneration of, 150  
     rupture of, 142  
     syndrome, 142  
     tendinitis of, 142  
 Surgery, in chronic arthritis, 81  
 Surgical approach, exposure of forearm fracture, 117  
     of hip, 118  
     of knee joint, 136  
     technic, Dupuytren's contracture, 164  
     to shoulder joint, 148  
 Sutures, tissue reaction to, 208  
     nylon, 211  
 Syme amputation, 193, 196  
 Syndactylism, 10  
 Syndrome, Albright's, 32  
     corset, 185  
     costoclavicular compression, 145  
     Ehlers-Danlos, 11  
     Guillain-Barre, 94  
     Maffucci's, 31  
     Parkinson's, 101, 109  
     Reiter's, 79  
     Scalenus, 107, 145  
     Shoulder-Hand, 141  
     supraspinatus, 142, 149  
 Synovia, in arthritis, 22  
     sarcoma of, 26



- Synovial membrane, osteochondromatosis of, 134
  - pathologic study of, 133
  - tumor, 21
- Synovectomy, 134
- Synovitis of knee, 133
  - traumatic, of shoulder, 142
- Sympathetic hyperemia, 61
  - nerve to shoulder joint, 141
- Sympathectomy, 186, 195
  - For Raynaud's disease, 58, 207
  - In causalgia, 108
  - In Parkinson's disease, 109
  - In poliomyelitis, 84, 93
- Syringomyelia, 13
  - familial, 177
- Syphilis of bone, 21
  - of spine, 74

- T -

- Talipes, (see clubfoot) 7
- Talus, fracture of, 58, 59, 60
  - osteochondritis of, 58
- Tendons, adhesions, 208
  - lengthening in paraplegic spasm, 109
  - repairs, 161
    - of hand, 159, 206
    - of forearm, 159
    - of wrist, 159
  - research, 222
  - sheath, sarcoma of, 26
    - inflammation of, 161
  - transfer, 57
    - in poliomyelitis, 86
    - in radial nerve injury, 108
  - transplants, forearm, 159
- Tenotomy, in treatment of clubfoot, 8
- Tennis elbow, 159
- Tetra-ethyl ammonium chloride, 206, 211
- Tibia, angulation of, 6
  - bowing of, operative treatment, 6
  - internal fixation, 129
  - intramedullary nail, 115
  - fracture, of condyle, 136
    - of shaft, 113, 118, 119
    - of spine of, 135
  - nonunion, tibial spine, 129
  - pseudarthrosis of, 6, 7
  - tibial crest wire for traction, 113
  - torsion of, 2



Thomsen's disease, 107  
Thornton plate, 129  
Thrombophlebitis, of lower extremity, 61  
Thorax, conditions involving, 170  
Thumb, carpal-metacarpal joint arthritis, 163  
    contractures of, 163  
Thymus, 215  
Thyroid, effect on growth, 214  
Traction, adhesive, 40  
    in intertrochanteric fracture, 112  
    principles in fracture treatment, 112, 113  
    skeletal, 40, 113  
    skin, in amputation, 195  
    well leg apparatus for amputation transportation, 198  
Trench foot, 58  
Trigger finger, 163  
Tuberculosis, of bone, 21, 69  
    diasone in, 69  
    indications for amputation, 193  
    joints, 69  
    knee, 134  
    hip, 69  
    paraplegia in, 70  
    pathogenesis in, 70  
    spine, 69  
    surgery, 169  
    synovial structure of wrist, 161  
    treatment of, 69, 70  
Tubocurarine, treatment of spondylitis, 79  
Tumors, bone, 21  
    nonosseous origin, 23  
    of synovia, 21  
    osteogenic, 27, 28  
Tomography, 210  
Tonsillectomy, related to poliomyelitis, 85, 91, 94  
Torticollis, electromyography in, 146  
    muscular, 146  
    spasmodic, 109, 146  
Toxoplasmosis, 5

- U -

Upper extremity, exercise of, 101  
    palsy of, 145  
University Clinic, resident training in, 224  
Ulna, both bone fracture, 117  
    dislocation at wrist, 160  
    excision of distal end, 160  
    fracture of, 112  
    intramedullary fixation, 115, 160  
Ulnar nerve, tardy paralysis, 159



Venous thrombosis, prevention of, by electrical stimulation, 102  
Vertebrae, cervical, congenital fusion of, 9  
    dwarfism, 12  
    hemivertebrae, 13  
    scoliosis, 14  
    spina bifida, 9  
Vertebral body, blood supply of, 175  
    developmental defects of, 177  
Vertebral column, embryology of, 6  
Veterans' Administration Hospitals, resident training in, 224  
Virus of poliomyelitis, strains of, 84, 85, 89, 90  
Vitamin, deficiency and congenital malformation, 5  
Vocational training, 100

- W -

Wart, plantar, 57  
Weather changes, in fibrositis, 80  
Wounds, healing of, 209

- X -

Xanthomatoses, 25, 32



AUTHOR INDEX

- Abbott, L. C., 148  
 Abel, S., 5  
 Abrams, M., 74  
 Abrahamson, L., 14  
 Abrahamson, M. L., 14  
 Abramson, D. J., 171  
 Accttola, A. B., 74  
 Adamson, J. D., 85  
 Adams, R. A., 7  
 Adams, W. S., 24  
 Adson, A. W., 178  
 Agerholm-Christensen, J., 8, 60  
 Ahlberg, A., 69  
 Aiken, G. A., 112  
 Albert, M., 70  
 Aldrich, E. M., 108  
 Allan, F. G., 56  
 Alexander, E., Jr., 210  
 Alexander, J. S., 142  
 Allredge, R. H., 112  
 Alpers, B. J., 180  
 Altenberg, A. R., 118  
 Altschul, A., 2  
 Amorth, G., 159  
 Andersen, K., 162  
 Anderson, K. J., 178  
 Andrewcci, D., 211  
 Anglem, T., 26  
 Antila, L. E., 116  
 Antonio, A., 207  
 Apfelbach, G. L., 42  
 Arden, G. P., 11, 16, 178  
 Ariel, I. M., 23  
 Arkin, A. M., 14, 170, 185  
 Armstrong, J. R., 142, 149  
 Armstrong, T. M., 183  
 Arrowood, J. G., 196  
 Arslanian, 67  
 Ashley, G. T., 212  
 Attali, P., 144  
 Avera, J. W., 211
- Babb, F. S., 51  
 Bach, F., 134  
 Badaro, J., 186  
 Badgley, C. E., 66
- Bailey, C. E., E. T., 11, 58  
 Baker, A. B., 92  
 Baker, R. F., 207  
 Bakst, A. A., 145  
 Baluss, J. W., Jr., 198  
 Bamballi, E., 200  
 Banks, S. W., 60  
 Banks, T. E., 112  
 Barcroft, H., 207  
 Barraquer-Bordas, L., 221  
 Barton, P. N., 174  
 Barnes, M. T., 208  
 Barnes, R., 144  
 Barr, J. S., 1  
 Basom, W. C., 200  
 Batch, J. W., 137  
 Batchelor, J. S., 135  
 Bateman, J. E., 144  
 Bateman, J. K., 59  
 Batterman, R. C., 78  
 Baxley, R. D., 75  
 Baxter, H., 163  
 Bayless, A. E., 199  
 Beath, T., 56  
 Beauzamy, P., 164  
 Beichl, L., 10  
 Belgrano, M., 148  
 Bell, G. H., 208  
 Bender, T. J., Jr., 45  
 Bendheim, O. L., 186  
 Bennett, R. I., 101  
 Benton, G. R., Jr., 75  
 Bentzon, P. K. K., 60  
 Berbir, A., 186  
 Bergmann, E. W., 171  
 Berglund, G., 184  
 Berkson, J., 200  
 Berry, A., 72  
 Bertrand, P., 67  
 Beswick, R. C., 5  
 Bettman, E. H., 47  
 Bishop, W. A., 184  
 Birsner, J. W., 75  
 Bingham, D. L. C., 147  
 Binford, C. H., 120  
 Bilcliffe, E. J., 59  
 Bickel, W. H., 135



Bjorkesten, G. A. F., 144  
Blanco, P., 118  
Bleuler, R., 136  
Block, M., 58  
Block, R. G., 69  
Blocker, T. G., Jr., 137  
Bloom, R., 161  
Blount, W. P., 1, 56  
Blum, L., 161, 221  
Bocklage, M. H., 141  
Bodeham, D. C., 199  
Bodian, D., 84  
Bohler, J., 114  
Bohler, L., 114  
Boldrey, E., 146  
Boland, E. W., 78  
Bonduelle, M., 144  
Borsotti, P. C., 60, 116  
Bostow, J., 185  
Bosworth, B. M., 149  
Bosworth, D. M., 69, 193  
Bourguignon, A., 107  
Bousser, J., 25  
Boutin, F. J., 193  
Bower, A. G., 85  
Bower, R. F., 30, 194  
Boyd, F. J., 117  
Boyd, H. B., 41, 45  
Boyer, 95  
Bradford, C. H., 135  
Brailsford, J. F., 5  
Braithwaite, F., 126  
Bramann, V., 149  
Brav, E. A., 135  
Breck, L. W., 178, 200  
Breckenridge, R. L., 27  
Brewer, A. E., 25  
Brittenbucher, R. B., 25  
Brittain, H. A., 194  
Broadbent, T. R., 106  
Broberg, G. R., 194  
Brock, C., 5  
Brockbank, W., 112  
Brockis, J. G., 24  
Bromley, L., 74  
Bromer, R. S., 47  
Bronson, R. G., 171  
Brooks, D. M., 144  
Brooks, S., 74  
Broomhead, R., 66  
Browder, J., 176

Brown, D., 46  
Brown, E. E., 80  
Brown, J. B., 158  
Brown, J. R., 92  
Brown, J. T., 149  
Brown, W. H., 31  
Bruecke, H., 200  
Buchthal, F., 92  
Bucy, P. C., 43  
Bunnell, S., 199  
Burch, J. E., 73  
Burnett, H. A., 161  
Buschke, F., 30  
Butterworth, R. D., 47  
Buxton, S. J. D., 150, 162

Cade, S., 21  
Cagnoli, H., 119  
Calnan, W. L., 9  
Campbell, D. A., 23  
Campbell, E., 119  
Cannon, B., 136, 158  
Cantril, S. T., 30  
Canty, T. J., 197, 198  
Capener, N., 95, 100  
Carabello, N. C., 181  
Carothers, R. G., 117  
Carpenter, E. B., 72, 147  
Carr, B. W., 69  
Carroll, R. D., 128  
Carroll, R. E., 50  
Case, J. T., 181  
Caspers, C. G., 162  
Cattell, L. M., 69  
Catterall, R. C. F., 9, 51  
Cattrell, G. W., 129  
Chambers, J. W., 208  
Chandler, F. A., 40, 136, 146, 180  
Channell, G. D., 160  
Chapman, E. M., 24  
Chapman, J. C. F., 13  
Chatterton, C. C., 181  
Cherry, J. H., 199  
Chevallier, P., 164  
Cholmeley, J. A., 6, 95  
Christensen, R. O., 115  
Claisse, R., 25  
Clark, J. M. P., 161  
Clarke, C. D., 198  
Clarke, G. R., 1



Clegg, R. S., 2  
 Cobey, M. C., 51  
 Cockenpot, F., 11  
 Cohen, J. N., 11  
 Cohen, R. C., 116  
 Colclough, J. A., 81  
 Coleman, H. M., 135  
 Coley, B. L., 21, 22, 24, 32  
 Collins, H. A., 2  
 Colsen, K., 143  
 Colonna, P. C., 182  
 Coltart, W. D., 57  
 Compere, E. L., 21, 119  
 Connell, J. F., Jr., 75  
 Cook, T. J., 27  
 Copeland, M. M., 30  
 Coronel, 210  
 Costantini, 9  
 Costello, O. I., 200  
 Couch, O. A., 94  
 Coughey, J. E., 91  
 Coughlin, E. J., Jr., 102  
 Cowley, R. A., 206  
 Craddock, W. L., 79  
 Craft, A. W., Jr., 196  
 Craig, J. D., 74  
 Crawford, A. S., 183  
 Crisp, E. J., 185  
 Cronin, J. D., 44  
 Cumings, J. N., 92  
 Cunning, D. S., 94  
 Cunningham, A. G., 181  
 Cutting, P. E. J., 147  
  
 D'Agostino, A., 58  
 Dahlberg, G., 56, 78  
 Dalldorf, G., 90  
 D'Aubigne, R. M., 120, 126  
 Dawson, G. R., Jr., 118  
 Dean, G., 177  
 Deaver, G. G., 100  
 De Doncker, E., 170  
 Deering, I. D., 133  
 De Frenelle, D., 108  
 Degenshein, G., 158  
 Dekking, H. M., 5  
 Delafield, R. H., 145  
 Delchef, J., 170  
 De Lorme, T. L., 50, 101  
 Demel, R., 127  
  
 De Palma, A. F., 44  
 Desenfans, G., 160  
 Dewar, F. P., 13  
 Dewinne, P., 72  
 Dickson, F. D., 159  
 Dieulafe, R., 160  
 Dimson, S. B., 11, 16  
 Diveley, R. L., 199  
 Dixon, F. J., 209  
 Djian, A., 147  
 Dockerty, M. B., 75  
 Donahue, C. D., 171  
 Donegan, C. K., 206  
 Donely, C. E., 182  
 Donovan, M. M., 47  
 Dreyfuss, M. L., 26  
 Dubecq, X. J., 115  
 Dubousquet, M., 66  
 Ducroquet, R., 57  
 Dunham, W. F., 179  
 Dunlap, K., 118, 137  
 Dunn, D. M., 70  
 Dunn, R. G., Jr., 58  
 Dupuis, P. V., 60  
 Duquesne, H., 72  
  
 Eaton, R. M., 94  
 Echeverri, A. J., 135  
 Echols, D. H., 183, 184  
 Ecker, A., 182  
 Edmunds, L. H., 143, 183  
 Edwards, E. G., 148  
 Edwards, S., 61  
 Eggers, G. W. N., 207, 220  
 Ehrenhoft, J. L., 115  
 Ekman, H., 149  
 Elbel, E. R., 212  
 Elkins, E. C., 103  
 Elliot, W., 32  
 Ellis, F., 29  
 Emma, E., 182  
 Encrantz, J. C., 66  
 Enders, J. F., 90  
 Engel, D., 163  
 Engelhardt, H. T., 79  
 Engstrom, A., 223  
 Epstein, J. A., 10  
 Erb, H. R., 70  
 Ergenbright, W. V., 42  
 Erickson, R. B., 30



Ernould, H. J., 12  
 Erway, C. E., 30  
 Estable, J. J., 209  
 Etienne, E., 8  
 Etter, L. E., 181  
 Evans, E. M., 40  
 Eyre-Brook, A. L., 161  
 Exposito, L., 10

Fahey, J. J., 40  
 Fairbank, H. A. T., 2, 11, 21  
 Falconer, E. H., 23  
 Falls, H. F., 11  
 Fan, K. S., 113  
 Farill, J., 66  
 Farrell, J. T., 162  
 Faulong, L., 147  
 Perciot, C. F., 59  
 Fett, H. C., 57  
 Finder, J. G., 200  
 Fineberg, S. K., 2  
 Fisk, G. R., 33  
 Fitts, W. T., Jr., 114  
 Flashman, F. L., 49  
 Fodden, J. H., 27  
 Foley, W. B., 128  
 Foley, W. J., 59  
 Follis, R. H., Jr., 1, 220  
 Fontaine, R., 61, 106  
 Fontneau, N. C., 137  
 Forrest, H. F., 6  
 Fournier, A., 11  
 Fowler, S. B., 118  
 Frame, B., 141  
 Francon, F., 163  
 Frank, R. C., 23  
 Frankel, C. J., 41  
 Freeman, J. W., 43  
 Freeman, L. W., 206  
 Freiberg, J. A., 44  
 Frew, J. F. M., 40  
 Fried, A., 149  
 Friedenber, Z. B., 60, 182  
 Frisch, A. W., 90  
 Funsten, R. V., 41  
 Furmanski, A. R., 108  
 Furste, W., 193  
 Fyfe, F. W., 45

Galloway, J. D. B., 56  
 Galloway, T. C., 95  
 Gamberoni, P., 200  
 Gambier, R., 148  
 Garceau, G. J., 69  
 Gardner, W. J., 109  
 Gear, J. H. S., 91  
 Geckler, E. O., 60  
 Gemmill, J. S., 24  
 Geschickter, C. F., 30  
 Ghormley, R. K., 2, 49, 133, 223  
 Gibson, A., 50  
 Gilfillan, C., 114  
 Gillespie, H. W., 177  
 Girardi, V. A., 59  
 Girdlestone, G. R., 70, 112  
 Gladstone, S. A., 22  
 Glaser, K., 1  
 Godard, H., 44  
 Goldenberg, R. R., 74  
 Goldman, I. R., 13  
 Goldstein, R., 148  
 Gonda, T. F., 9  
 Gonzales, J., 12  
 Gonzalez, R. I., 222  
 Gonzalezulloa, M., 9  
 Good, M. G., 57  
 Goodwyn, T. P., 117  
 Gordan, E. J., 44  
 Gordon, H. S., 134  
 Gordon-Taylor, G., 194  
 Graham, W. C., 163  
 Granger, G. R., 183  
 Granirer, L. W., 80  
 Grant, A. R., 25  
 Grantham, E. G., 184  
 Graubard, D. J., 116, 206  
 Gravl, W. P., 193  
 Grayson, R., 94  
 Green, H. D., 213  
 Green, W. T., 101  
 Griffin, J. P., 106  
 Griffin, L. L., 41  
 Griffith, G., 10  
 Griffiths, D. L., 112  
 Griffiths, E. R., 163  
 Grigger, R. P., 208  
 Gucker, T., III, 101  
 Gudbrandsson, B., 72  
 Guillaume, J., 186  
 Guilleminet, M., 28  
 Guillet, R., 58  
 Guttman, A. P., 129, 193

Gallagher, J. F. F., 42  
 Gallagher, J. R., 101



- Guttman, L., 109  
 Guyton, A. C., 84
- Eachez-Leblanc, M., 60  
 Hadley, L. A., 141, 180  
 Haebler, C., 114  
 Hakala, E. W., 161  
 Hall, H., 184  
 Halliday, J., 11  
 Halpert, B., 28  
 Hamilton, A. R., 119  
 Hamilton, G. T. C., 207  
 Hamm, F. C., 74  
 Hammes, E. M., 130  
 Hammon, W. M., 90  
 Hanlon, C. R., 112  
 Hanna, A. A., 145  
 Hansson, K. G., 100  
 Hardman, G. L., 158  
 Hargreaves, E. R., 93  
 Hark, F. W., 23  
 Harmon, P. H., 86  
 Harper, T., 171  
 Harrel, J. A., Jr., 11  
 Harrington, P. R., 94  
 Harris, R. I., 56  
 Harrison, S. H., 142  
 Hart, F. D., 179  
 Hart, V. L., 66  
 Hartley, J., 220  
 Hatchette, C. V., 60  
 Hauser, E. D. W., 56  
 Hawkinson, O., 129  
 Haythorn, S. R., 48  
 Headley, N. E., 78  
 Heath, A. L., 57  
 Hedges, F. H., Jr., 142  
 Heinle, R. W., 22  
 Hellman, L., 208  
 Hellstadius, A., 177  
 Hempelmann, L. H., 58  
 Hench, P. S., 78  
 Henderson, M. S., 31, 148  
 Hendrickson, E. G., 199  
 Hendry, D. M., 145  
 Hendry, N. G. C., 136  
 Henkin, W. A., 26  
 Henry, G., 72  
 Hernaman-Johnson, F., 80  
 Herndon, C. H., 6  
 Herrmann, L. G., 193  
 Hershey, S. G., 182  
 Hertzog, A. J., 25  
 Herz, E., 146
- Herzog, E. G., 33, 119  
 Heyman, C. H., 6, 46  
 Hiestand, H. B., 128  
 Highsmith, C., 193  
 Higinbotham, N. L., 22, 32  
 Hilker, A. W., 141  
 Hill, A. V., 103, 221  
 Hill, D. F., 134  
 Hill, R. M., 25  
 Hirsh, H. L., 80  
 Hirsch, W., 1  
 Hoecker, F. E., 220  
 Hoffman, G. A., 57  
 Hoffman, H. L., 180  
 Hoffman, W., 150  
 Hogg, T. G. H., 42  
 Hollander, J. L., 103  
 Holt, J. F., 75  
 Hone, G. M., 12  
 Hoobler, S. W., 211  
 Horne, H. W., 179  
 Horne, H. W., Jr., 178  
 Horrax, G., 143  
 Horvath, S. M., 103  
 Horwitz, 22, 49, 127  
 Hospital Progress, 95  
 Hotchkiss, R. C., 74  
 Houst, R., 12  
 Howard, R. J., 199  
 Howard, W. T., 9  
 Howe, H. A., 84  
 Howorth, M. B., 45, 47  
 Hubay, C. A., 56  
 Huguenin, A., 134  
 Hulnik, A., 193  
 Hunter, L. W., 150  
 Hutter, C. G., Jr., 2  
 Hyroop, G. L., 163
- Inclan, A., 86  
 Ingleman, B., 212  
 Ingraham, F. D., 210  
 Immerman, 150  
 Insley, J. L., 162  
 Irwin, C. E., 86  
 Iselin, M., 106  
 Ishmael, W. K., 80
- J. Kansas M. Soc., 161  
 Jackson, A. E., 194  
 Jacobs, J. E., 25  
 Jacobs, S., 10  
 Jakobsson, A., 148



James, A. G., 32  
Janes, J. M., 1, 27, 194  
Jansey, F., 69  
Jaricyn, A. A., 143  
Jensen, W. P., 198  
Jensenius, H., 59  
Jentzer, 5  
Jessing, A., 116  
Jewett, E. L., 186  
Jit, I., 141  
Johnson, E. W., Jr., 27  
Johnson, F. H., 186  
Johnson, H. F., 112  
Johnson, S. A. M., 11  
Joffe, H. H., 92  
Jones, G. B., 151  
Jones, J. H., 94  
Jones, J. C. B., 116  
Joplin, R. J., 47  
Josey, A. I., 147  
Judet, J., 50  
Judet, R., 50

Kamberg, S., 171  
Kaiser, R. A., 42  
Kamel Hussein, M., 112, 115  
Kamman, G. R., 85  
Kaplan, G., 23  
Kaplan, L., 30  
Kearney, E. A., 186  
Keats, S., 180  
Keer, A. S., 144  
Kendall, E. C., 78  
Kendrick, R. E., 8  
Kennedy, A. F., 78  
Kennedy, J. C., 171  
Kenny, P. J., 143  
Kelikian, H., 81  
Kessell, A. W. L., 74  
Kessel, J. F., 90  
Kernwein, G. A., 49  
Key, J. A., 43, 60, 150  
Kiernander, B., 100  
Kilfoyle, R. M., 42  
Kilham, L., 85  
King, D., 185  
King, J. M., 31  
King, R. A., 164  
Kinsella, T. J., 171  
Kirakozov, M. D., 150  
Kirklin, J. W., 200

Kirkpatrick, J. E., 80  
Kirschbaum, 26  
Kiskadden, W. S., 5  
Kite, J. H., 8  
Khoo, F. Y., 7  
Klein, A., 47  
Kleinberg, S., 134, 151  
Knight, R., 117  
Koon, E. S., Jr., 161  
Koop, C. E., 208  
Koven, B., 66  
Koven, M. T., 66  
Eraissl, C., 26  
Kraus, H., 184  
Krebs, C., 79  
Kristensen, T. B., 60  
Krueger, F. J., 136, 185  
Kruger, G. O., Jr., 25  
Kuhlmann, J., 115  
Kuhns, J. G., 81  
Kushner, J. L., 32  
Kutz, E. R., 9  
Kuzma, J. F., 31

L., C., 195  
L., G., 10  
Lachapele, A. P., 176  
La Cour, F., 199  
La Ferte, A. D., 119  
Lake, N. C., 57  
Lambert, C. N., 120  
Lambotti, A., 59  
Landells, J. W., 106  
Lander, E., 56  
Landsmeer, J. M. F., 160  
Langenskiold, F., 67  
Langer, R., 26  
Landtman, B., 5  
Lapidus, P. W., 33  
Larson, L. W., 22  
Lascaux, 27  
Lasserre, C., 160  
Lattomus, W. W., 150  
Lavelle, L. L., 74  
Lawrence, J. H., 25  
LeCocq, E. A., 57  
Lee, F. W., 25, 31  
Lehman, W., 26  
Lehmann, O., 60  
Leibetseder, F., 74  
Lelong, M., 5



Le Maistre, D., 115  
 Lemmer, K. E., 26  
 Lenarsky, M., 95  
 Lennard-Jones, J. E., 163  
 Lenson, N., 32  
 Leonard, M., E., 23  
 Leonard, M. H., 44, 61, 200  
 Lepine, P. R., 89, 90  
 Le Quesne, L. P., 194  
 Levine, H. J., 91  
 Levine, J., 69  
 Levitin, J., 66  
 Lewin, P., 56, 133  
 Leydig, S. M., 134  
 Liebolt, F. L., 57  
 Lievre, J. A., 143, 144, 183  
 Licciardello, T., 24  
 Lichtenstein, L., 30  
 Light, G. A., 194  
 Limarzi, L. R., 24  
 Lindquist, G., 209  
 Lindsay, D. T., 1  
 Linn, L., 171  
 Lippman, R. K., 44  
 Lissie, R. D., 91  
 Little, C. C., 21  
 Little, W. J., 211  
 Littlefield, J., 24  
 Littler, J. W., 159  
 Lockie, L. M., 79  
 Lofstrom, J. E., 178  
 Lorch, I. J., 1  
 Lou, I., 159  
 Love, J. G., 70  
 Lowry, F. C., 42  
 Lucas, L. S., 129  
 Luck, J. V., 135  
 Luckey, C. A., 148  
 Lucy, R. C., 5  
 Lueck, W., 86  
 Ludwig, F. E., 73  
 Luomanen, R. K. J., 42  
 Lutz, A. R., 222

Magnusson, R., 145  
 Maiocco, P. D., 2  
 Majdalani, 67  
 Malcolm, 222  
 Maloney, W. J., 89  
 Maneksha, R. J., 211  
 Marble, H. C., 184  
 Marcard, P., 115  
 Marder, M., 27  
 Marek, F. M., 58  
 Margarey, I., 12  
 Markheim, H. R., 47  
 Merkin, L., 126  
 Markson, D. E., 78  
 Martin, G. W., 158  
 Marton, R., 8  
 Mason, M. L., 161  
 Massart, R., 112  
 Masseboeuf, A., 185  
 Mathur, P. D., 133  
 Matson, D. C., 210  
 Matthews, G. W., 30  
 McAnally, A. K., 75  
 McBride, E. D., 181, 185  
 McClellan, S. G., 211  
 McClintock, J. A., 61  
 McCollough, N. C., 186  
 McCormick, D. W., 56  
 McCough, G. P., 133  
 McCreary, J. H., 25  
 McCurrach, A. C., 149  
 McCutcheon, W. B., 75  
 McElvenny, P. T., 41  
 McGowan, J. M., 145  
 McKeever, F. M., 148  
 McKelvey, G. J., 133  
 McKenzie, K. G., 13  
 McKittrick, L. S., 193  
 McLaughlin, H. L., 114, 129  
 McMaster, P. C., 197  
 McSwain, B., 24  
 Mead, N. C., 170  
 Meadoff, N., 119  
 Mengert, W. F., 176  
 Mentzer, C. G., 178  
 Meredith, E. W., 57  
 Messer, A. L., 206  
 Metcalfe, J. W., 74  
 Meyer, A. H., 24  
 Meyer, K., 209  
 Meyer, R., 117

Macey, H. B., 161  
 MacConnail, M. A., 208  
 Mackenzie, C. R. S., 12  
 MacKenzie, I. G., 93  
 MacRae, D. J., 2  
 Magee, R. B., 159



Meyerding, H. W., 135  
 Michaelis, L. S., 147  
 Michele, A. A., 136, 171  
 Milch, H., 9, 147  
 Millar, E. A., 69  
 Millbourn, E., 72  
 Miller, C. F., 58  
 Miller, D., 75, 183  
 Miller, E. S., 89  
 Miller, J. P., 170  
 Miller, J. W., 183  
 Miller, L. F., 109  
 Miller, R., 186  
 Miller, R. H., 119  
 Miller, W. G., 13  
 Milowsky, J., 149  
 Mitchell, C. L., 183  
 Mitchell, W. R. D., 133  
 Mixter, W. J., 179  
 Mock, H. E., Jr., 113  
 Moehlig, R. C., 209  
 Moir, P. J., 24  
 Moir, W. W., 209  
 Montgomery, A. H., 57  
 Montgomery, D. C., 57  
 Moore, E. L., 57  
 Moore, F. T., 126  
 Moore, J. R., 6  
 Moore, M. L., 222  
 Moore, S., 21  
 Moreau, M. H., 59  
 Morgan, I. M., 90  
 Moser, H., 200  
 Moser, H. H. P., 42  
 Mouchet, A., 108, 164  
 Mowbray, R., 179  
 Muirhead, E. E., 26  
 Munro, D., 178  
 Murphy, F., 200  
 Murphy, I. D., 161  
 Murphy, J. P., 181  
 Murray, R. A., 161  
 Murray, R. C., 40  
 Musgrove, J. E., 1  
 Mussey, R. D., Jr., 31  
  
 Nachlas, I. W., 142  
 Naden, J. R., 113  
 Nale, T. W., 113  
 Nambiar, P. P. C., 159  
  
 Nau, C. H., 85  
 Netto, L. J., 44  
 Newman, L. B., 212  
 Nichols, H. M., 159, 206  
 Nicod, L., 160  
 Nicola, T., 148  
 Nicoll, E. A., 170  
 Nino, F. L., 59  
 Nisbet, E. R., 93  
 Nishimura, E. T., 23  
 Nissen, K. I., 91  
 Noble, J. A., 142  
 Noe, M., 57  
 Norcross, B. M., 79  
 Norcross, J. R., 170  
 Norley, T., 135  
 Notter, A., 178  
 Noyes, M. B., 135  
 Nusselt, 118  
 N. York Med., 161  
  
 OALMA J., 197  
 Obletz, B. E., 43  
 Odell, R. T., 134  
 Odena, I., 200  
 Oeconomos, D., 133  
 Ogle, B. C., 213  
 Olavarria, P. C., 59  
 Oldfield, M. C., 61  
 Olitsky, P. K., 90  
 Oliver, D. R., 127  
 O'Neill, C. J., 109  
 Orgain, E. S., 206  
 Osborne, R. L., 12  
 Ott, V. R., 150  
 Overmiller, W. C., 24  
 Overton, L. M., 160  
 Owen, J. T., 41  
 Owens, N., 2  
 Owens, W. I., 75  
  
 Paine, R. S., 91  
 Pait, C. F., 90  
 Palumbo, L. T., 194  
 Papper, E. M., 194  
 Pareira, M. C., 208  
 Parisel, F., 10  
 Paterson, L. T., 114  
 Patrick, J., 116, 118



Patton, E. F., 143  
 Patton, H. S., 199  
 Paul, J. R., 91  
 Paul, W. D., 94  
 Paull, D. P., 178  
 Paulley, J. W., 116  
 Pauzat, D., 160  
 Pearl, F. L., 206  
 Pease, C. N., 2  
 Pease, D. C., 207  
 Peers, J. H., 91  
 Pekarek, F., 67  
 Pelner, L., 11  
 Pelland, P. O., 150  
 Penfield, W., 145  
 Petch, C. P., 94  
 Peters, C. H., 22  
 Peters, M. P., 194  
 Peterson, M. C., 206  
 Phalen, G. S., 159, 176  
 Phemister, D. B., 49, 207  
 Piatt, A. D., 181  
 Pinkus, H., 25  
 Pipkin, G., 57  
 Pipkin, J. L., 57  
 Platt, W. R., 27  
 Pohle, E. A., 23, 209  
 Pointot, J., 115  
 Polatin, P., 171  
 Polson, R. A., 22  
 Pomerat, C. M., 207, 220  
 Pool, C. C., 57  
 Poole, A. G. B., 102  
 Poppe, E., 22  
 Poppe, J. K., 171  
 Poppen, J. L., 143  
 Porter, W. B., 7  
 Potter, C. T., 12  
 Potterfield, T. C., 12  
 Prosser, T. M., 28  
 Prudden, J. F., 42  
 Pulaski, E. J., 75, 158  
 Purvis, G. D., 117  
 Putnam, T. J., 109  
  
 Query, R. Z., 79  
 Quigley, T. B., 116  
  
 Raaf, J., 184  
 Rabinovitch, M., 211  
 Ragan, C., 209  
 Ralston, E. L., 171, 186  
 Randall, W. S., 32  
 Randlov-Madsen, A., 47  
 Randolph, T. G., 146  
 Rank, B. K., 161  
 Ratkoczy, N., 45  
 Rechtman, A. M., 174  
 Redler, I., 57  
 Rees, S. E., 182  
 Reich, N. E., 78  
 Reichard, J., 12  
 Reidy, J. A., 1  
 Reidy, J. P., 200  
 Reimann, S. P., 23  
 Reyes-Pugnaire, M. de, 59  
 Reynolds, F. C., 43, 127  
 Rheingold, J. J., 22  
 Rhian, M., 92  
 Rhoads, C. P., 22  
 Rhodes, A. J., 92  
 Ribbing, S., 11  
 Rider, J. A., 107  
 Riegel, C., 208  
 Riordan, D., 163  
 Riordan, D. C., 118  
 Risley, T. S., 193  
 Ritchie, G., 209  
 Rizzo, P. C., 60  
 Robbins, J. V., 151  
 Roberts, E. C., 90  
 Robertson, R. C. L., 175  
 Robins, H. M., 79  
 Robinson, A., 49  
 Robinson, J. A., 80  
 Roche, M. B., 175  
 Rodino, D., 117  
 Rodriguez Miranda, J. V., 7  
 Rojel, K., 159  
 Rombold, C., 23  
 Ronchese, F., 11  
 Roofe, P. S., 220  
 Ropes, M. W., 141  
 Rosenberg, G. V., 195  
 Rosenthal, R. L., 25  
 Rosner, S., 183  
 Ross, E. F., 27  
 Roswit, B., 23  
 Roth, M., 10  
 Rounds, R. C., 150  
 Rountree, C. R., 41  
 Rovenstine, E. A., 149



Rush, H. L., 114, 117  
Rush, L. V., 114, 117  
Rusk, H. A., 100  
Russell, D. S., 29  
Russell, W. R., 195  
Ruttner, J. R., 162

Sabaino, D., 129, 161  
Sabin, A. B., 91  
Sachs, J., 158  
Salem, E. P., 33  
Samitz, H. H., 14  
Samson, J. E., 137  
Samuel, E. P., 211  
Sandblom, P., 163  
Sarasin, R., 186  
Sarnoff, S. J., 196  
Saunders, J. B. D., 148  
Savage, O., 142  
Schaeffer, M., 94  
Schechtman, A. M., 5  
Schlesinger, E., 11  
Schlesinger, P. T., 32  
Schneider, C. C., 127  
Schneider, R. C., 178, 180  
Schneiersen, S. S., 209  
Schnitker, M. T., 119  
Schnute, W. J., 66  
Schoenau, C. W., 74  
Schreiber, L. F., 221  
Schrey, E. L., 118  
Schwartz, R. P., 57  
Schwartzmann, J. R., 86  
Schwegman, C. W., 208  
Scobey, P. R., 93  
Scott, E. P., 32  
Scott, J. C., 135  
Scott, M., 186  
Scott, P. K., 23  
Scott, W., 2  
Scow, R. O., 210  
Scuderi, C., 159, 174  
Sear, H. R., 28  
Sedlezky, I., 74  
Seidenfeld, M. A., 93  
Seidler, F., 170  
Seifert, M. G., 95  
Seille, G., 108  
Sensenig, E. C., 6

Seze, S. de, 143  
Shackelford, R. T., 31  
Shah, M. A., 141  
Shands, A. R., Jr., 223  
Shaw, B. W., 208  
Shaw, E. B., 93  
Shea, R. C., 208  
Sheldon, K. W., 182  
Sherman, M. S., 10  
Sherrill, J. D., 126  
Sherwood, K. K., 176  
Shindler, T. O., 207, 220  
Shipp, F. L., 136  
Shorkey, R. I., 118  
Shortell, J. H., 42, 160  
Shutkin, N. M., 90  
Sicard, A., 185  
Sichel, M., 11  
Sideman, S., 134  
Siffert, R. S., 47, 185  
Silberberg, M., 213  
Silberberg, R., 213  
Silverman, J. J., 59  
Silverthron, N., 91  
Simmonds, F. A., 150  
Simril, W. A., 9  
Simpson, N. E. W., 179  
Sincock, H. A., 5  
Sloan, L. H., 24, 175  
Sloboziano, H., 180  
Slotkowski, 150  
Smallpiece, V., 12  
Smith, E., 84  
Smith, F. B., 50  
Smith, H. M. A., 135  
Smith-Petersen, M. M., 50  
Snapper, I., 32  
Snedecor, S. T., 42, 118  
Soeur, R., 133  
Sollman, T., 209  
Solomon, A. P., 177  
Solomon, C. J., 222  
Som, M. L., 209  
Somerville-Large, C., 142  
Spann-Etzioni, J., 160  
Spears, G. N., 41, 208  
Speed, J. S., 137  
Speed, K., 113  
Spicer, C., 199  
Spittler, A. W., 193



- Splithoff, C. A., 185  
 Spotoft, J., 42  
 Sprecher, E. E., 163  
 Spriggs, J. B., 120  
 Sprunt, W.,  
 Spurling, R. G., 184  
 Stack, J. K., 133, 159, 162  
 Stamm, T. T., 142  
 Starr, K. W., 75  
 Stearns, D. B., 74  
 Stebbins, C. E., 73  
 Steinbrocker, O., 8, 78, 199  
 Steindler, A., 10  
 Stephens, F. I., 106  
 Stevenson, C. J., 179  
 Stewart, M. J., 100  
 Stinchfield, A. J., 1  
 Stinchfield, F. E., 50, 113, 128  
 Stradford, E. T., 31  
 Strain, J. C., 199  
 Straith, C. L., 30  
 Streeter, G. L., 1  
 Stone, C. T., 107  
 Stone, F. P., 59  
 Stone, M. M., 8, 198  
 Storen, H., 8, 128  
 Stovall, S., 45, 112  
 Stuck, W. G., 44, 117, 118, 137  
 Sullivan, A. W., 143  
 Summers, J. E., 61  
 Sundelin, F., 78  
 Sussman, M. L., 209  
 Sutro, C. J., 60  
 Swenson, L. L., 159  
 Swynghedaaw, 115  
 Szent-Gyozsi, A., 208  
  
 Taylor, G. W., 32  
 Taylor, L. W., 193  
 Tandeta, M., 7  
 Tanner, F. H., 33  
 Temple, W. J., 32  
 Teneff, S., 196  
 Tether, J. E., 107  
 The First Army Med. Bulletin, 84  
 Thelander, H. E., 5  
 Therkelsen, F., 162  
 Thiersch, J. B., 221  
 Thompson, A. R., 102  
 Thompson, E. A., 10  
 Thompson, M. S., 117, 199  
 Thompson, P. C., 199  
 Thompson, W. A. L., 50, 171, 186  
 Thomson, G. R., 164  
 Thomson, J. E. M., 33  
 Thomson, S. A., 8  
 Thornton, L., 129  
 Tichy, V. L., 102  
 Tidrick, R. T., 115  
 Tish, A., 174  
 Titrud, L. A., 143  
 Toaff, R., 177  
 Tondeur, F., 116  
 Toomey, J. A., 91  
 Toone, E. C., Jr., 171  
 Toumey, J. W., 149  
 Townsend, K., 114  
 Traeger, D. H., 78  
 Travell, J., 146  
 Travernier, L., 67  
 Trevor, D., 136  
 Trial, 61  
 Trott, A. W., 136  
 Trotter, M., 9  
 Trout, P. C., 137  
 Tsinoukas, B. G., 201  
 Tucker, F. R., 48  
 Tucker, W. E., 136  
 Turner, E. K., 11  
 Turner, L. B., 145  
 Turner, V. C., 170  
  
 Unander-Scharin, L., 24  
  
 Van Cauwenberghe, R., 10  
 Van Dellen, T. R., 5  
 Vanderfield, G. K., 183  
 Van Riper, H. E., 85  
 Vaughan, W. H., 44  
 Velinsky, M., 145  
 Vennesland, K., 69  
 Vesely, D. G., 137  
 Virenque, M., 210  
 Vogl, A., 12, 194  
 Von Lackum, W. H., 170  
 Voris, H. C., 13  
 Voshell, A. F., 133  
  
 Wagner, C. J., 159, 182



*Polignac*

Wagner, E. L., 79  
 Wagner, L. C., 47  
 Wahren, H., 58  
 Wahrsinger, P. B., 32  
 Wakim, K. G., 103  
 Walker, E. T., 10  
 Wallace, W. S., 25  
 Walley, G. J., 129  
 Ware, R. M., 197  
 Warkany, J., 5  
 Warner, R., 5  
 Warren, S., 209  
 Warrick, C. K., 32  
 Watkins, A. L., 50, 101  
 Watson, J., 162, 163  
 Watt, L. O., 185  
 Waugh, R. L., 158  
 Weakley, H., 198  
 Weaver, J. B., 127  
 Weber, F. P., 11  
 Webster, J. E., 178  
 Weckesser, E. C., 208  
 Weens, E. S., 10  
 Weinberg, F., 198  
 Weiner, M., 27  
 Weinstein, L., 42  
 Weir, J. B. D., 208  
 Weisberger, A. S., 22  
 Weisman-Netter, R., 150  
 Weissenbach, R. J., 163  
 Wells, P. O., 32  
 Welte, E., 107  
 Wertheimer, L. D., 150  
 Wertheimer, P., 58, 183  
 Wesselhoeft, C., 85  
 West, E. F., 149  
 West, H. E., 85  
 West, J. S., 194  
 Whelton, R. L., 94  
 Whillis, J., 160  
 White, C. M., 23  
 White, J. A., 26  
 Wickstrom, O., 126  
 Widen, A., 116  
 Wiederker, J., 150  
 Wiles, P., 194  
 Wilkinson, M. C., 70, 160  
 Williams, A. J., 79  
 Williams, C. R., 58  
 Willis, R. A., 28  
 Willis, T., 175  
 Wilner, D., 27  
 Wilson, D. M., 162  
 Wilson, G. D., 176  
 Wilson, H. B., 118  
 Wilson, I. H., 134  
 Wilson, J. C., 148  
 Wiltse, L. L., 50  
 Winant, E. M., 113  
 Windeyer, B. W., 29  
 Winter, G. R., 2  
 Wintrobe, M. M., 23  
 Wise, R. A., 194, 198  
 Withers, R. J. W., 142  
 Wolfe, J. J., 28  
 Wood, F. G., 210  
 Woodhall, B., 108  
 Woodyatt, P. B., 29  
 Woolmer, R., 212  
 Wrete, M., 141  
 Wright, C. S., 14  
 Wright, P. B., 112  
 Wright, W. L., 57  
 Wurl, O. A., 8  
 Wyatt, B. L., 80  
 Wyatt, G. M., 32  
 Wycis, H. T., 186  
 Wylie, P. E., 149  
 Wyllie, W., 11  
  
 Yager, R. H., 90  
 Yeager, G. H., 206  
 Young, F., 163  
 Young, P. T., 102  
  
 Zamecnik, P., 24  
 Zarzecki, C. A., 27  
 Ziegler, D. K., 107  
 Ziemnowicz, S., 199  
 Zimmerman, B., 176  
 Zuelzer, W. W., 210
































JUN 25 1958

88



NATIONAL LIBRARY OF MEDICINE



NLM 02916991 0