

260
AM who's who
(Hitler)

0224784

CONFIDENTIAL

OI/CIR/4
29 Nov 45

19433

HEADQUARTERS
UNITED STATES FORCES EUROPEAN THEATER
MILITARY INTELLIGENCE SERVICE CENTER
APO 757

OI CONSOLIDATED INTERROGATION REPORT (CIR) No 4

HITLER AS SEEN BY HIS DOCTORS

<u>Sources</u>	<u>Position</u>
MORELL, Prof Dr Theo	Hitler's Personal Physician
GIESING, Prof Dr Erwin	Oberstabsarzt
LOEHLEIN, Prof Dr Walter	Director, University Eye Clinic, BERLIN
WEBER, Prof Dr Karl	Director, BAD NAUHEIM Heart Institute
NISSLE, Prof Dr A.	FREIBURG Research Institute
BRINKMANN, Prof Dr E.	Medical Diagnostic Institute, BERLIN

The primary source of this report is Prof Dr Theo MORELL. The main body of the report deals with his observation of Hitler over the eight-year period during which he was the Fuehrer's "Leibarzt". Some of his information is produced from memory; some is based on documentary evidence found in his papers. In general, the information on Hitler may be regarded as reliable, while statements dealing with his own person should be treated with great care. It should also be noted here that MORELL's memory seems to be better at some times than at others: on some occasions he can recall things which he later is unable to confirm.

Quite naturally, Hitler's Personal Physician conferred with a number of specialists on his patient's condition. These are the secondary sources listed above. It has been clearly indicated when any other views than those of the primary source are cited. For the most part, reports submitted to MORELL by these secondary sources are contained in appropriate annexes.

Dr MORELL has been the subject of a large number of intelligence reports, all of which refer to him in a most uncomplimentary manner. Some reports describe him as a shrewd, money-crazed quack doctor who believes in his own quackery; others describe his hygienic habits as being those of a pig. This interrogator has very little to add, and can only agree with the writers of earlier reports.

(For Table of Contents see page 1).

1945 JAN 11 PM 4:00
WAR DEPT - S.G.O.
IN

CONFIDENTIAL

Table of Contents

	<u>Page</u>
1. <u>REFERENCES</u>	2
2. <u>REASON FOR REPORT</u>	2
3. <u>REPORT: "HITLER AS SEEN BY HIS DOCTORS"</u>	
a. <u>Hitler's State of Health and Medical Characteristics</u>	2
(1) GENERAL	2
(2) MEDICAL HISTORY	2
(3) SCARS	3
(4) SKIN	3
(5) FACE	3
(6) HEAD	3
(7) NECK	4
(8) CHEST	4
(9) LUNGS	5
(10) HEART	5
(11) ABDOMEN	5
(12) LYMPHATIC GLANDS	5
(13) BACK	5
(14) RECTAL AND GENITAL REGIONS	5
(15) EXTREMITIES	6
(16) NEUROLOGICAL DATA	6
(17) PSYCHIATRIC DATA	9
(18) UROLOGICAL DATA	10
(19) SEXUAL LIFE	10
(20) X-RAY EXAMINATIONS	10
(21) FECAL EXAMINATIONS	10
(22) BLOOD EXAMINATIONS	11
(23) ELECTROCARDIOGRAPHY	11
b. <u>Medication by Dr MORELL</u>	11
4. <u>COMMENTS AND RECOMMENDATIONS</u>	15

ANNEXES

- ANNEX I : Chronology of Life and Career of Prof Dr Theo MORELL
- ANNEX II : Five X-rays of Hitler's Head
- ANNEX III : Report of Eye Examination
- ANNEX IV : Results of Ear Examination
- ANNEX V : Drawing of Hitler's Mouth
- ANNEX VI : Record of Heart Examination
- ANNEX VII : Four Electrocardiograms
- ANNEX VIII: Results of Two Urinalyses
- ANNEX IX : Results of Three Fecal Examinations
- ANNEX X : Drawing of Hitler's Nose
- ANNEX XI : Blood Sedimentation Rate Test
- ANNEX XII : Blood Calcium Test
- ANNEX XIII: Wassermann, Meinicke and Kahn Tests
- ANNEX XIV : Differential Blood Count
- ANNEX XV : Blood Serum Differential
- ANNEX XVI : Translation of Consultation Notes by MORELL

NOTE: In a number of the Annexes, the subject of examination is referred to as "A". Prof Dr MORELL swears to the statement that this was his code designation for Hitler. and identifies him on all his medical papers.

1. REFERENCES

- a. CCPWE # 32 ("ASHCAN"), Report DI-17, dated 30 Jun 45
- b. CCPWE # 32 ("ASHCAN"), Report DI-21, dated 2 Jul 45
- c. CCPWE # 32 ("ASHCAN"), Report DI-30, dated 12 Jul 45
- d. USFET-MIS Center, Report OI-CIR # 2, dated 15 Oct 45

NOTE: MORELL has been the subject of a number of reports which, however, are not on file with this unit.

2. REASON FOR REPORT

This is the second report of a series dealing with Hitler. It is based on information which was obtained from a doctor who was with him for eight years--until 21 Apr 45.

The information is being published in order to provide:

- a. medical data useful for the identification of Hitler or his remains;
- b. further material for the debunking of numerous Hitler Myths;
- c. the knowledge needed to expose those frauds who in later years may claim to be Hitler, or who may claim to have seen or talked to him.
- d. research material for the historian, the doctor and the scientist interested in Hitler.

3. REPORT: "HITLER AS SEEN BY HIS DOCTORS"a. Hitler's State of Health and Medical Characteristics(1) GENERAL

Dr MORELL became personal physician to Adolf Hitler in 1936. At this time Hitler looked his age, and was suffering from gastro-intestinal disturbance. He weighed about 70 kg and was about 176 cm tall. Temperature, pulse, and respiration were normal, and continued within normal limits for about eight years. His blood classification group was "A", (Landsteiner), see Annex VI. His psychic state was very complex.

(2) MEDICAL HISTORY

In 1936, when MORELL first examined Hitler, the Fuehrer was suffering acutely from gastro-intestinal disturbances and had difficulty with his diet. Upon palpation a swelling was noted in the pyloric region of the stomach, the left lobe of the liver was found to be enlarged, and pain was elicited in the region of the right kidney. An eczema on the left leg was noted which apparently was related to the upset digestion.

Dr MORELL thereupon had a fecal examination made by Prof Dr NISSELE Director of the Bacteriological Research Institute in FREIBURG, the result of which showed the presence of dysbacterial flora in the intestinal tract. NISSELE had at this time prepared an emulsion of a strain of coli communis bacillus which had the property of colonizing the intestinal tract, known commercially as "Mutaflor", and MORELL instituted treatment with it, prescribing 1-2 capsule by mouth after every morning meal. As a result of this treatment Hitler's digestive system began to function more normally, the eczema disappeared within about six months, and he began to gain weight. During the war, when the supply of "Mutaflor" decreased, a similar coli preparation named "Trocken Coli Hamma" made by Prof LAVES of the University of GRAZ was also used.

/Hitler suffered

MEDICAL HISTORY (contd)

Hitler suffered also from meteorism. This condition was aggravated by his vegetarianism. To relieve the meteorism, MORELL prescribed Dr KOSTER's Antigas Pills, two to four at every meal. These pills (extr nux vom, extr Bellad, extr Gent) were taken over a period of years, and both Drs GIESING and BRANDT believe that the cumulative effect of the strychnine component may be responsible for the epigastric pain, icteric discoloration of sclera and bronzing of skin (see also USFET-MISC Report OI-CIR # 2) noted during 1944. Dr MORELL, on the other hand, believes that Hitler was afflicted with gastro-duodenitis with obstruction of bile flow, and that the icteric discoloration may be traced to this. He supports this view by the fact that pain was felt in the region of the gall bladder. The urine at times was of a dark brown color and contained bile pigment. MORELL treated Hitler with Gallestol to restore normal flow of bile.

Since Hitler's diet was insufficient and unbalanced, MORELL supplemented it with Vitamultin-Calcium (vitamin B-1, ascorbic acid, calcium, nicotinic acid amide), often administering it intravenously together with glucose in order to counteract loss of energy. A special preparation of Vitamultin-Calcium tablets "F" made for Hitler only was also taken by mouth.

Although the epigastric pain was greatly diminished by the "Mutaflor" treatment, it continued to recur at times with great severity, particularly after meals. As an additional measure Dr MORELL prescribed injections of Progynon (a preparation with benzoic acid and dihydro-follicle hormone) which increases circulation in the gastric mucosa and tends to prevent spasm of the gastric walls. Progynon B Ol. Forte (50,000 international benzoate units) was administered intramuscularly; it afforded some relief. (For details of medication see section b.).

(3) SCARS

A scar, the result of a wound in World War I, was present on the left thigh at the middle and lateral aspect.

(4) SKIN

Facial and body skin was pale and of a fine texture. An eczema on the left leg during 1936 disappeared entirely after the treatment with "Mutaflor" began. Petechiae were not observed. Skin was normally sensitive to heat and cold and to sharp and dull touch.

(5) FACE

Facial expression had an intense quality that subdued and captivated most individuals who met the Fuehrer. There was no noticeable asymmetry. Estimate of the facial index indicates more or less long-faced type. Several horizontal wrinkles on forehead were permanent, as were two short vertical wrinkles in glabella region. Tenderness over maxillary and ethmoid sinuses was present only when these were inflamed (see also Annex II).

(6) HEADa. General

Form of skull was slightly dolichocephalic. Temporal vessels were not prominent. Mastoid pathology was not evident.

/b. Scalp

HEAD (contd)b. Scalp

Scalp showed no evidence of scars. Hair was very dark brown, almost black, with only slight thinning evident. Some greying was noted at temples, less on rest of scalp.

c. Eyes

A minimal degree of exophthalmus was always present. Eye tension was normal for age group. Movement of eyes well-coordinated and free in all directions. Lids showed no lag or other evidence of pathology. Pupillary reflexes were normal. Conjunctiva, cornea, and sclera were normal. Eyes were blue with faint tinge of grey. Superciliary arches were rather prominent. (For further details, see Annex III).

d. Ears

External ears were both of medium size and set close to the skull. No evidence of pathology or deformity of any part of external ears was noted. External auditory canals were of medium width and otherwise normal. No evidence of deformity or pathology of helix, fossa of anthelix, tragus, lobule, antitragus, concha, anthelix or fossa of helix was observed. (See Annex IV).

e. Nose

The nose was straight with a slight protuberance on the dorsum. The lower portion was thick and fleshy with rather prominent nares. Hitler suffered frequently from catarrhal inflammation and obstruction of the nasal passages. (See Annex XVI).

f. Mouth

Labia were normally red in color and rather small. Lip mucosa showed no pathology. Teeth were orthognathous but defective. Gingivitis in 1936 was completely cleared up by treatment with vitamin C and anti-septic mouthwashes. Tongue was of medium size and during 1935-36 was frequently furred as a result of gastric disturbance. Cicatrization of tonsils was probably due to childhood tonsillitis (see Annex V). Uvula and palate showed no abnormality. The nasopharynx, oropharynx, and larynx were often inflamed as a result of upper respiratory infections. Fetor ex ore was present in March, April 1945. Nasolabial folds were rather prominent.

(7) NECK

Mobility of neck was normal in all directions. No pulsations were observed. No neoplasm or palpable nodes were present, and no evidence of thyroid or parathyroid pathology. Prof Dr von EICKEN operated on Hitler in 1935 and again in 1944 to remove a polyp from the left vocal cord.

(8) CHEST

Skin of the chest was pale white. Hair was absent on both chest and back. Breasts showed no hypertrophy or other pathology. Supraclavicular, suprasternal, clavicular, sternal, mammary, inframammary, scapular, interseapular, infrascapular, axillary, and infra-axillary regions all found normal on examination. Shape of thorax was sthenic; circumference and diameters were not measured. No retraction or pulsation was observed.

(9) LUNGS

Expansion of the lungs was normal. Auscultation revealed no pulmonary pathology.

(10) HEART

Blood pressure as taken on many occasions averaged 143 mm systolic, about 100 mm diastolic. Under excitement the systolic pressure rose to 170, 180, or sometimes as high as 200 mm (see Annex VI).

Percussion disclosed moderate enlargement of the left ventricle with displacement of the heart apex to the left of the midclavicular line, though still within the fifth intercostal space. Under auscultation accentuation of second aortic sound was heard in second intercostal space in the right parasternal line. Electrocardiograms made by MORELL and interpreted by Prof Dr WEBER of the Heart Institute at BAD NAUHEIM indicated rapidly progressive coronary sclerosis. (See Annex VII).

Heart rate averaged 72 with only very slight respiratory arrhythmia. There was no evidence of extra systole, or of atrioventricular or bundle branch block. Pacemaker was the sinus node. Exercise test of the heart was not made.

(11) ABDOMEN

Contour of abdomen was normal. Examination in 1936 showed pain and tenderness in epigastric region, consistency and enlargement of liver in right hypochondriac region, and tympanites in left hypochondriac and umbilical regions. Palpation also elicited pain in region of right kidney. MORELL believes that pains, tenderness, and cramps in epigastric region were caused by gastro-duodenitis with disturbance in normal flow of bile, and that this condition is also responsible for the icteric discoloration of skin and sclera noted during 1944, but which later cleared up. Urinalysis at this time showed presence of bile pigments, and increased amounts of urobilinogen and urobilin. MORELL instituted careful diet and treatment with Gallestol, "Mutaflo", and Bad Kissinger Pills, and effected marked improvement in the condition.

No tenderness was ever apparent over McBurney's point. Abdominal and cremaster reflexes were always normal. No inguinal or femoral hernia was present.

(12) LYMPHATIC GLANDS

No tender or enlarged lymphatic glands were observed by MORELL.

(13) BACK

Spine had normal mobility. Slight kyphosis of dorsal spine became somewhat evident in later years. It involved also a very slight scoliosis of dorsal and lumbar spine with, however, only minimal disturbance of symmetry. There was no tenderness over spine or pelvis.

(14) RECTAL AND GENITAL REGION

There was no disturbance of vesical or rectal sphincter tone, and no evidence of prostatic pathology or hemorrhoids.

/(15)

(15) EXTREMITIES

Hitler told MORELL that he had fractured his left scapula in the region of the inferior aspect of the glenoid cavity during the Putsch in 1923, and that range of abduction and rotation of the upper left arm was limited for many years. Complete recovery of function apparently was achieved later.

A slight tremor of the left arm and leg and slight dragging of left leg was first observed in 1942 or 1943 shortly after Hitler contracted a grippe-like disease during an inspection trip to VINNITSA in the Ukraine. MORELL believes the tremor to have been of hysterical nature but does not exclude the possibility of its having resulted from the above illness. The tremor gradually increased in severity until the attempt at Hitler's assassination on 20 Jul 44 immediately after which it completely disappeared. It then reappeared after a short interval in aggravated form and continued to grow worse until Apr 45.

(16) NEUROLOGICAL DATAa. General

Posture was somewhat stooped during later years owing to slight kyphosis of dorsal spine, but position of head and shoulders showed no abnormality. Prompt response to questions, etc, showed normal state of consciousness. Skin was of fine texture and not abnormally pigmented. Secondary sexual characteristics were generally normally developed. Head hair was smooth and black-brown, showing normal development. Perspiration was normal both locally and generally. Head was more or less dolichocephalic. Palpation produced no evidence of exostosis. No bruit heard in head on auscultation and no tenderness or abnormal resonance on percussion.

b. Cranial Nerves

- I. No olfactory hallucinations or impairment of smell.
- II. No papillo-edema. No visual hallucinations.
- III, IV
and VI. No diplopia, no convergent or divergent strabismus.
No nystagmus. Pupils were regular, equal, and showed normal reaction to light.
- V. No sensation of neuralgia or numbness. No paresthesia.
No deviation of jaw and no motor disturbance of muscle or mastication. Corneal reflex not tested.
- VII. No taste perversion or other pathology of anterior two-thirds of tongue. Lacrimation and salivation normal. Facial symmetry present. Was able to wrinkle forehead.
- VIII. (See Annex IV).
- IX. No dysphagia. Taste sensation on posterior one-third of tongue normal.
- X. Functions of swallowing and speaking not impaired. No projectile vomiting. No deviation of soft palate. Pressure on eyeball or on carotid sinus slowed the pulse but Dr MORELL cannot remember what year he made the test.

/XI.

Cranial Nerves (contd)

- XI. Was able to shrug shoulders.
- XII. Protruded tongue showed no deviation and showed no fibrillation or atrophy.

c. Cerebrum

- Frontal: Cerebration normal. Concentration excellent. No euphoria, incontinence, anosmia, or personality changes.
- Motor Area: No convulsions, paresis, paralysis, or aphasia.
- Premotor Area: No forced grasping or clumsiness.
- Parietal: Sensation intact. Could distinguish shape.
- Occipital: No visual hallucinations. No quadrantic field effects (see Annex III).
- Temporal: No auditory or visual hallucinations. No sensory aphasia. No dream states.
- Corpus striatum: Tremor of left arm and leg and slight dragging of left leg first noted in 1942 or 1943. No rigidity observed.

d. Cerebellum

No hypotonicity, nystagmus, dysarthria, ataxia, asynergy, or adiadokokinesis.

e. Spinal Cord

No local or general muscle weakness observed excepting slight weakness of vocal cord muscle.

Normal response of superficial (abdominal, cremasteric) and deep (biceps, triceps, patella) reflexes. Babinsky was done. No pathology indicated.

NOTE: MORELL made all the usual reflex tests. When "no pathology" is indicated under reflexes that would not usually be tested, it signifies only that in eight years of treating Hitler, source had no occasion to suspect that the reflex was abnormal.

f. Reflex Centers and Spinal Root FunctionsRoot C-1

No motor disturbance or pathology of small neck muscles. Turning and extension of head normal. No sensory disturbance or pathology of neck or occiput.

Roots C-2 and C-3

No motor pathology or disturbance of neck muscles or trapezius. Flexion of head and raising of shoulders normal. No sensory pathology or disturbance of occiput or of lateral aspects of neck.

/Root C-4

Reflex Centers and Spinal Root Functions (contd)Root C-4

No motor disturbance or pathology of scalenes, diaphragm, levatores scapulae, or rhomboids. Inspiration normal. External rotation of upper arm normal. (A transient limitation of abduction and rotation of left upper arm caused by fracture in glenoid region of scapula in 1923 disappeared after several years). No sensory disturbance or pathology of neck, shoulder, chest to second rib, or of back to spine of scapula.

Root C-5

No motor disturbance or pathology of deltoid, biceps, coracobrachialis, brachioradialis, supinator, or of supra- or infraspinatus. Raising of upper arm and flexion and supination of forearm normal. No sensory disturbance or pathology of dorsum of shoulder and arm or of lateral aspect of upper arm. Biceps reflex normal.

Root C-6

No motor disturbance or motor pathology of pectorals, latissimus dorsi, teres major, subscapularis, serratus anterior, triceps, or of pronators of forearms. Adduction and internal rotation of upper arm and extension and pronation of forearm normal. No sensory disturbance or pathology of lateral aspect of upper arm or radial side of forearm. Triceps reflex normal.

Root C-7

No motor disturbance or pathology of extensors of wrist, fingers, or flexors of wrist. Flexion and extension of wrist normal. No sensory disturbance or pathology of radial side of forearm or of thumb.

Root C-8

No motor disturbance or pathology of long extensors or long flexors of fingers and thenar muscles. No sensory disturbance or pathology of flexor or extensor surfaces of middle of forearm and of hand.

Root T-1

No motor disturbance or pathology of small muscles of hand and fingers. No sensory disturbance or pathology of ulnar side of whole arm or of little finger.

Roots T-1 to T-12

No motor disturbance or pathology of muscles of back, intercostals, or abdominal muscles. No sensory disturbance or pathology from cervical spine to fifth lumbar vertebra in the back, or from cervical spine to the Poupart ligament in the front. Abdominal reflexes normal.

Root L-1

No motor disturbance or pathology of lower abdominal muscles, quadratus lumborum, psoas, or sartorius. No sensory disturbance or pathology of outside of gluteal region or of inguinal region.

Root L-2

No motor disturbance or pathology of ilio-psoas or of cremaster. No sensory disturbance or pathology in region of lateral aspect of thigh and of testicles. Cremaster reflex normal.

/Root L-3

Reflex Centers and Spinal Root Functions (contd)Root L-3

No motor disturbance or pathology of ilio-psoas, adductors of thigh, or quadriceps. Flexion, internal rotation and adduction of thigh normal. No sensory disturbance or pathology of anterior or of inner aspect of thigh and knee. Patellar reflex, left exaggerated.

Root L-4

No motor disturbance or pathology of quadriceps. Extension of leg normal. No sensory disturbance or pathology of anterior aspect of thigh or of inside of thigh, leg, or foot.

Root L-5

No motor disturbance or pathology of gluteus medius or minimus, or of semimembraneus, semitendineus, biceps, tensor fascia lata, or of tibialis anterior. Adduction of thigh and flexion of leg normal. No sensory disturbance or pathology of external aspect of leg or foot.

Root S-1

No motor disturbance or pathology of gluteus maximus, obturator internus, pyriformis, gemelli, quadratus femoris, tibialis anterior, or of extensor digitorum longus. Extension and external rotation of thigh and dorsiflexion of foot and toes normal. No sensory disturbance or pathology of posterior aspect of calf or of sole of foot, outer border of foot, or of toes. Plantar and Achilles reflex normal.

Root S-2

No motor disturbance or pathology of gastrocnemius soleus, extensor and flexor digitorum communis longus, or hallucis longus, tibialis posterior, or of small foot muscles. Plantar flexion of foot and toes normal. No sensory disturbance or pathology of saddle area, outside of leg, or of outer border of foot.

Root S-3

No motor disturbance or pathology of rectal muscles, sphincters, or of sex organs. No sensory disturbance or pathology of saddle area, perineum, scrotum, or penis.

Roots S-3 to S-5

Voluntary initiation of urination and defecation under control. No sensory disturbance or pathology of perineum, anus, or perianal area. Anal reflex not tested by Dr MORELL.

(17) PSYCHIATRIC DATA

- a. Orientation as to time, place, and persons was excellent.
- b. Memory as to events, both recent and remote, was excellent.
- c. Immediate retention of figures, statistics, names, etc, was excellent.
- d. Hitler's general background was characterized by his lack of university training, for which he had, however, compensated by acquiring a large body of general knowledge through reading.

/e.

PSYCHIATRIC DATA

- e. Judgment of time and spatial relations was excellent.
- f. Reaction to environment was normal.
- g. He was changeable, at times restless and sometimes peculiar, but otherwise co-operative and not easily distracted.
- h. Emotionally very labile. Likes and dislikes were very pronounced.
- i. Flow of thought showed continuity. Speech was neither slow nor fast and was always relevant.
- j. Globus hystericus was not observed. No amnesia. Epigastric pain may possibly have been of hysterical origin.
- k. No phobias or obsessions.
- l. No hallucinations, illusions, or paranoid trends present.

(18) UROLOGICAL DATA

In 1936 Hitler suffered pain in the region of the right kidney but none in the regions of the bladder, prostate, testicles, epididymes, urethra, or ureters. Urination showed no abnormal difficulty, in frequency, dribbling, retention, or blood content. There were no palpable masses in lower or upper abdomen or in costovertebral angle.

Urinalyses were performed on several occasions to check the genito-urinary tract and to determine if other pathological manifestations were present. (See Annex VIII).

(19) SEX CHARACTERISTICS

Sexual organs showed no indications of abnormality or pathology and secondary sex characteristics were normally developed. Hitler was very fond of the society of attractive women, particularly during the years of his rise to power. In later years his libido was apparently sublimated with the increase in duties and responsibility. MORELL believes that Hitler, although not strongly inclined to sexual activity, did have sexual intercourse with Eva BRAUN, though they were accustomed to sleep in separate beds.

(20) X-RAY EXAMINATIONS

Five X-rays of Hitler's head are attached as Annex II. The three plates marked 19 Sep 44 were made at the Army Hospital at RASTENBURG, East Prussia, while Dr GIESING was treating Hitler for injuries suffered in the assassination attempt of 20 Jul 44. The two plates marked 21 Oct 44 were found among MORELL's records, but he can no longer remember when or why they were made.

(21) FECAL EXAMINATIONS

Repeated fecal examinations were made because of the presence of dysbacterial intestinal flora and in order to check the therapeutic effect of treatment with "Mutaflo". (See Annex IX).

/(22)

(22) BLOOD EXAMINATIONS

Following blood tests were made at various times to get a general orientation: red blood count, color index, hemoglobin determination (Sahli), white blood count, white corpuscle differential, blood sedimentation rate, blood sugar determination, blood calcium determination, blood serology (Wassermann, Kahn, and Meinicke), and interferometric determination of catabolic fermentation in blood serum. Specimens of reports made on these tests were found among Dr MORELL's records and are reproduced in Annexes VI, XI, XII, XIII, XIV, and XV.

(23) ELECTROCARDIOGRAPHY

Four electrocardiograms covering a period of three years (Aug 41 to Sep 44) are attached as Annex VII. Dr MORELL performed these examinations and sent the charts to Dr WEBER, the widely-known authority on heart diseases and director of the Heart Institute at BAD NAUHEIM/Hesse for interpretation and diagnosis. On the basis of such charts alone, Dr WEBER diagnosed a rapidly progressive coronary sclerosis--an opinion which he recalls and confirms now.

b. Medication by Dr MORELL

The following is an almost complete list of the drugs used by Dr MORELL during his treatment of Hitler. Some were used almost every day, while others were administered only when the need arose.

Morphia, hypnotics, etc, are not included in this list. But it does contain the names of substances which have a very rapid effect. Glucose, for example, is absorbed quite rapidly and consequently produces a feeling of well-being. Hitler might have dealt with situations very differently after a glucose injection.

Constant medication over a period of years may have upset the physiological balance of his body to such an extent that even normally harmless drugs would be relied on. Thus a person may become dependent on such medication, even though the substances employed are not drugs of a habit-forming nature.

(1) ULTRASEPTYL

One tablet of 2-(p-aminobenzolsulfonamido)-4-methylthiazol contains 0.5g. These tablets were prescribed by Dr MORELL because Hitler suffered from persistent catarrhal inflammations of the upper respiratory tract and angina. Application: 1-2 tablets per os, with addition of much fluid (fruit juice or water) after a meal. Fluid was taken in order to prevent the formation of calculi. Reference: Ultraseptyl-Sanabo, Vienna XII/82. (See also Annex XVI for translation of one of Dr MORELL's notes).

(2) EUBASIN

A sulfa drug. One ampoule equals 5cc. Injected intragluteally. Was only injected one, since it caused pain. Therapeutically used for colds.

/(3)

Medication by Dr MORELL(contd)

(3) CHININURIN

Hamma product. Prepared by Dr MULLI. This drug contains some chinin. Application per os, after a meal. Therapeutically used against colds. It was used in place of Ultraseptyl.

(4) OMNADIN

Omnadin is a mixture of proteins, lipid substances of gall and animalic fats, supposed to have all antigenic properties and therefore should be used at the beginning of infections. It is nearly specific against colds. Dr MORELL preferred Omnadin over Ultraseptyl because it was non-toxic. At times Omnadin was given in conjunction with Vitamultin -CA (see B.(13)). 1 Ampoula -2cc was given intramuscularly at a time. Omnadin was used whenever HITLER was afflicted with colds and as a substitute for Ultraseptyl.

(5) PENICILLIN-HAMMA

Prepared by Dr MULLI. Penicillin was used once in form of powder, on a skin wound on HITLER's right hand, 8-10 days after the attempt on his life July 20, 1944. The skin wound was of pea size.

(6) OPTALIDON

A proprietary analgesic, a combination of amidopyrine and barbiturate: containing Sandoptal (a proprietary hypnotic-iso-butylallyl barbituric acid): 0.05; Dimethylamino phenazon(pyramidon):0.125; Caffein:0.025. Application: 1-2 tablets per os, was used for headaches.

(7) BROM-NEEVACIT

Composed of KBr 4%, Na3PO4 0.1%, Naphodyl 1%; diethylbarbituric acid + phenyldimethylpyrazolon, spiritus, sacch, et sacch t. fact. Aroma. Used as sedative in order to induce sleep and when excited. Dosage: 1-2 tablespoons. In order to prevent a Bromine reaction Dr MORELL prescribed it only every other 2 months.

(8) SEPTOIOD

Product of DIWAG Chemical factory, AG, BERLIN-WAIDMANNSLUST. Dr MORELL used Septoiod against respiratory infections. He also thought it would prevent the progress of HITLER's arteriosclerosis, and used it in place of Ultraseptyl. At times it was applied intravenously up to a maximum dose of 20cc.

(9) CIRCULATORY ANALEPTICS

CARDIAZOL (Pentanethylenetetrazol)
CORANIN(Pyridin- β -carboxylic acid-diethylanid)

In 41, Dr MORELL observed edema on external and internal malleoli of fibulae and tibiae; in order to overcome the circulatory insufficiency and to stimulate circulation, cardiazol and coranin were administered. It was used in the form of a solution of which 10 drops were given internally for the period of a week, after that medication was discontinued for a month, used occasionally again when edema became manifest.

/(10)

Medication by Dr MORELL (contd)

(10) SYMPATHOL

Para-oxyphenylethanolmethylamin, only 1/100 as effective as adrenalin. It was administered by Dr MORELL in order to increase the heart-minute-volume of blood. It regulates heart activity and overcomes vessel insufficiency. It was supplied in solution and applied internally, 10 drops a day for temporary periods since 42.

(11) STROPHANTIN

A crystalline glucoside, used as a heart tonic. Electrocardiograms of HITLER suggested coronary sclerosis in 1941. Dr MORELL therefore instituted treatment with intravenous injections of strophantin, giving 0.02mg a day for periods of approximately 2-3 weeks. This type of treatment was repeated several times during the last 3 years.

(12) PROSTROPHANTA

Supplied in ampoules, each containing 0.3mg of strophantin in combination with glucose and Vitamin B complex (nicotinic acid). Was used same as strophantin.

(13) VITAMULTIN-CA

Contained: A, B, C complex, C, D, E, K, P. It was supplied by HAMMA, GMBH, HAMBURG, in form of ampoules and tablets. Has been produced since 38. Dr MORELL injected 4.4cc intragluteally every other day. He also prescribed tablets which HITLER sometimes used. It was used from 38 to 44 with short interruptions. It often was taken in combination with other drugs.

(14) INTELAN

Consists of Vitamins A, D, and glucose. Used therapeutically just as Vitamultine, in order to induce appetite, overcome tiredness and strengthen body resistance. Intelan was given in later years, from 42-44. It was supplied in tablet form and was taken twice a day, at meals.

(15) GLUCOSE

Glucose (5-10%) solution was given in order to supply calories. Also used as a mixer with, and to counteract the contractive effect of, strophantin. It was injected intravenously every 2nd or 3rd day (10cc) for a period of years (from 37-40) with brief interruptions.

(16) TONOPHOSPHAN

Bayer product. It is the sodium salt of dimethyl-amino-methyl-phenyl-phosphinic acid. It is a stimulant for unstriated muscles and was also given to supply phosphor. It is supplied in ampoules and tablets. Ampoule contains a 1-2% solution, tablet 0.1g. Tonophosphan was administered subcutaneously and was used only temporarily during the years 42-44.

(17) MUTAFLOR

It is an emulsion, a particular strain of Bacillus coli communis, and prepared in enteric soluble capsules. Reference: Prof NISSLE, Hageda, A.G., BERLIN NW 21. Questions regarding the product were directed to Prof NISSLE at FREIBURG, 1 B.

According to Prof NISSLE, certain strains of Bacillus coli communis have the property of colonizing the intestinal tract. Such a property is not

/demonstrated by

Medication by Dr MORELL(contd)

demonstrated by the Yoghurt or acidophylus Bacillus. Because HITLER suffered so much from indigestion (36-40), Dr MORELL thought an abnormal bacterial flora of intestinal tract was the cause. A fecal examination proved this was the case. Dr MORELL therefore instituted treatment with Mutaflor. It relieved HITLER of some of the pain and of indigestion. As the supply of Mutaflor diminished as a result of the war, former teacher, Prof LAVES of University of Graz made a similar Coli preparation, named Trocken Coli Hamma. Prof LAVES also examined HITLER's feces and concluded dysbacterial intestinal flora. Mutaflor treatment consisted of administering a series of capsules: on the first day a yellow capsule, from the 2nd to the 4th day one red capsule per day, and from then on 2 red capsules per day for a period of many years (36-43), with some interruptions. (Trocken Coli Hamma used as substitute)

(18) LUIZYM

This is a digestive enzyme preparation containing ferments which split cellulose, hemicellulose and carbohydrates. It was used for digestive weakness, meteorism, and to make vegetable food more digestible. (HITLER was a vegetarian).

It was supplied in tablets or dragees. Luizym was taken once in a while when flatus and indigestion became worse. Dose: 1 tablet after meals.

(19) GLYCONORM

Dr MORELL treated HITLER with Glyconorm (2cc injected intramuscularly) in order to check digestive disturbance. It was used only rarely and only during the years 38-40.

It is also supplied in bean form. It is mainly used for the prevention of pellagra. Glyconorm contains metabolic ferments (COZYHASE I and II) vitamins, and amino acids.

Produced by NordeMark Werke/HAMBURG.

(20) DR KOESTERS ANTIGAS PILLS

Contains: extr. Nux vom., extr. Bellad. aa0.5, extr Gent. 1.0 -- 2-4 pills were taken at every meal for a period of many years from 36-43 with temporary interruptions because HITLER suffered from meteorism. Dr BRANDT and Dr GIESING think the cumulative effect of this drug produced the icteric discoloration of skin and sclera and epigastric cramps noted Sep 44.

(21) EUFLAT

Combined preparation of radix angelica, papaverin, aloe, active bile extracts, coffee-charcoal, adsorb. pancreas extract. Was supplied in pill form and used orally for better digestion and against meteorism. This drug was only used during years 39-44.

(22) EUKODAL (Dihydro-oxycodoinchlorhydrate)
and

(23) EUPAVERINUM (synthetic alkaloid)

Both were taken for epigastric cramps. Was injected intravenously whenever cramps and pain became manifest.

(24) CAMOMILE

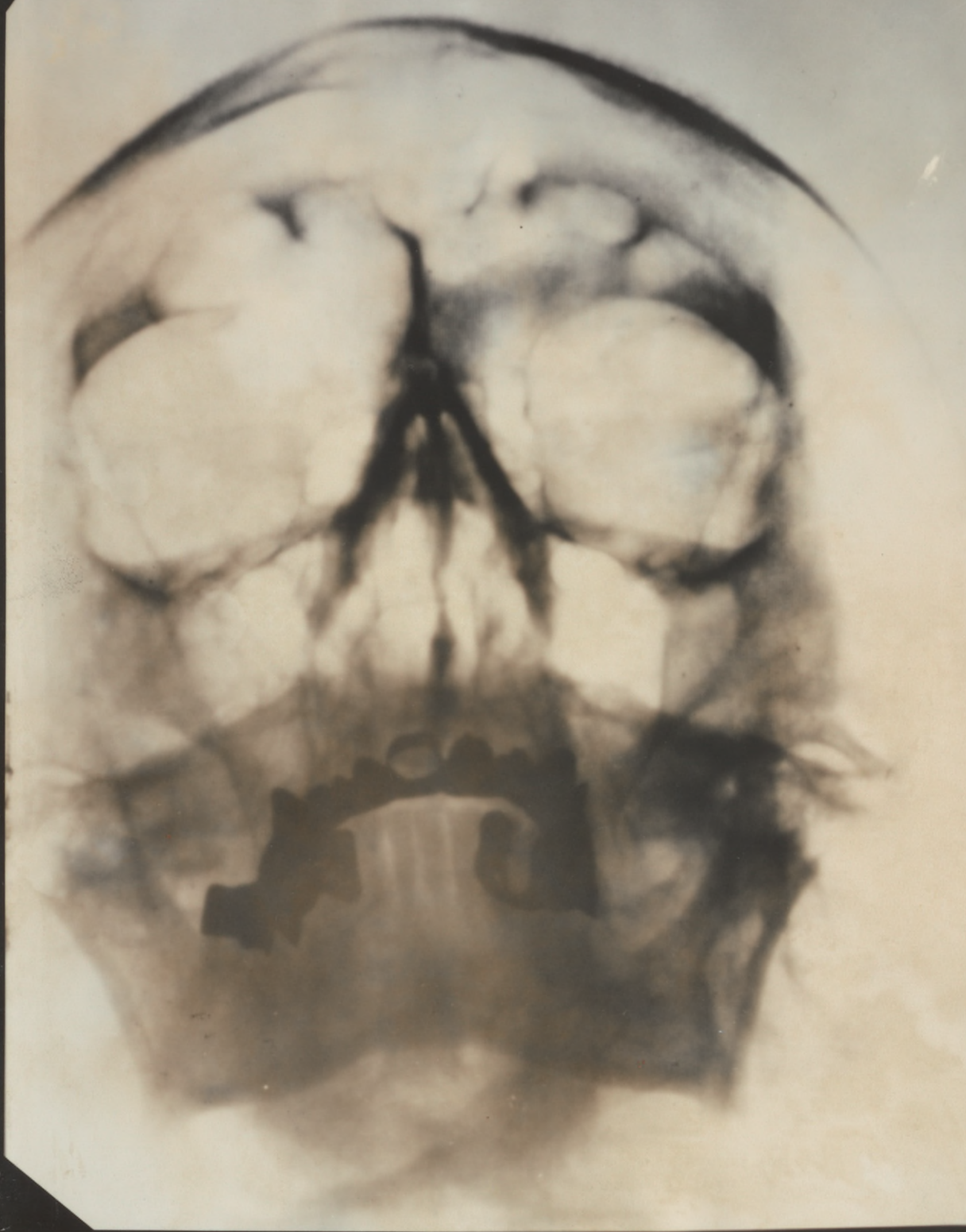
Used frequently for cleansing enemas, which Hitler administered himself.

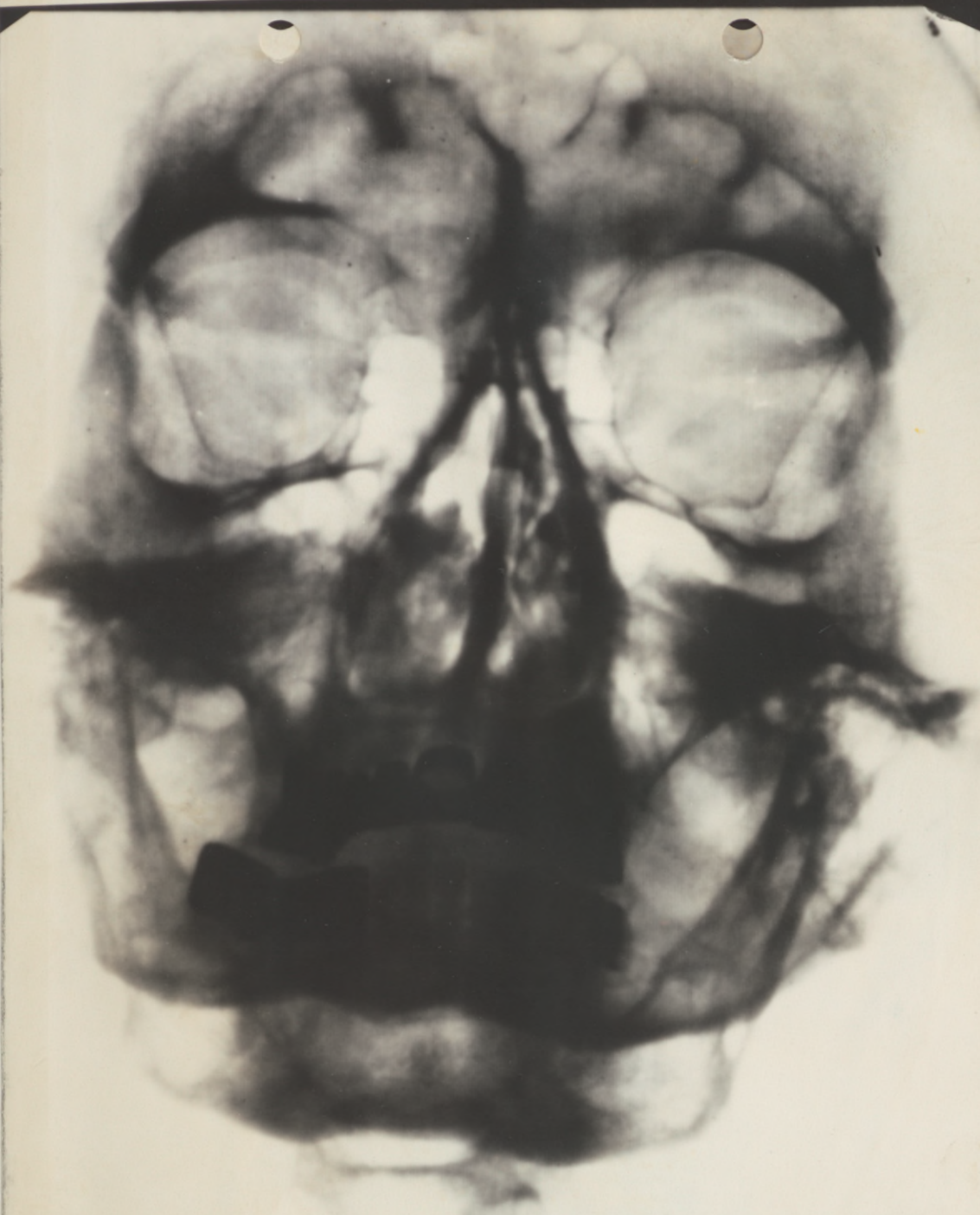
HORLANS:

/(25)

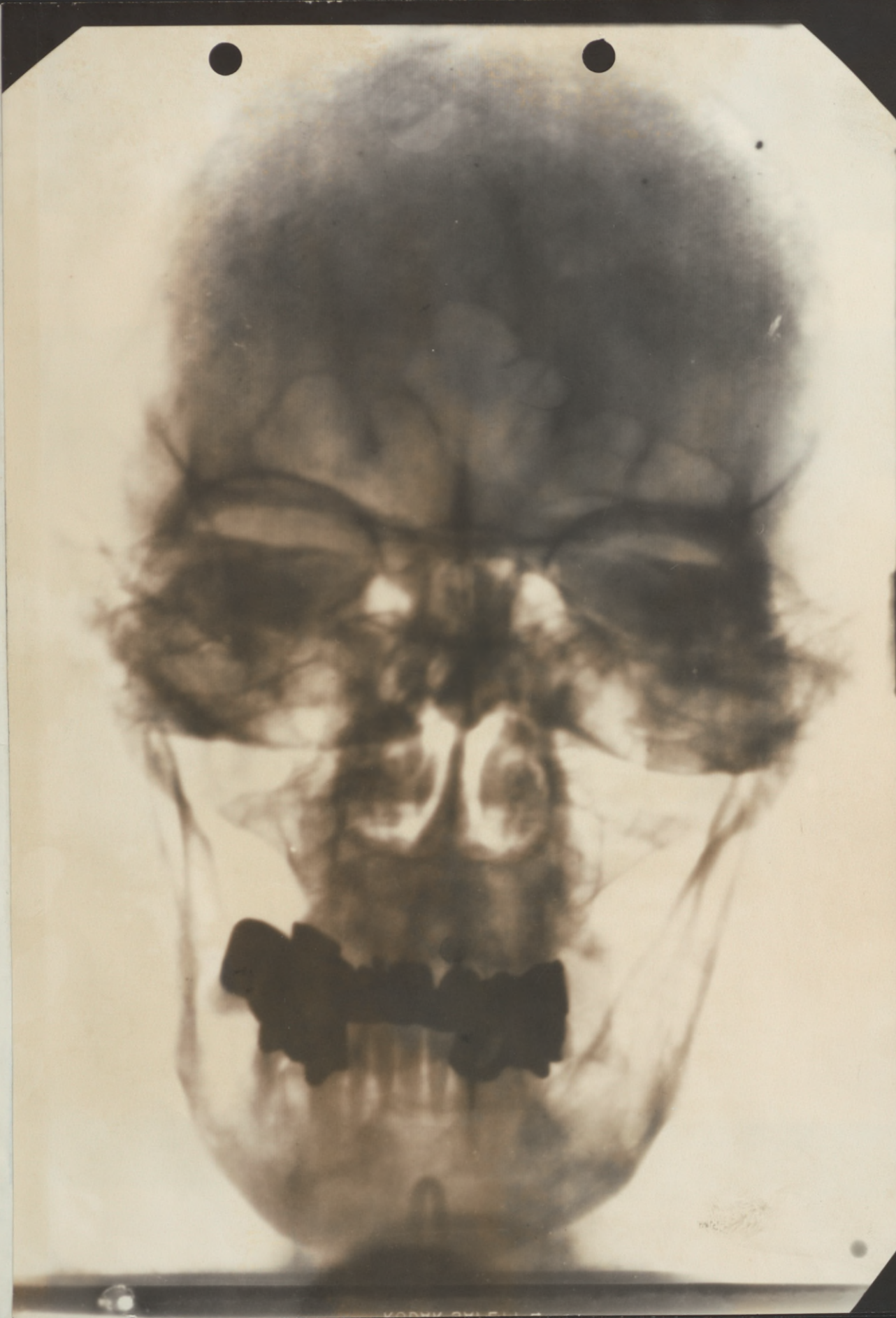KODAK SAFETY FILM

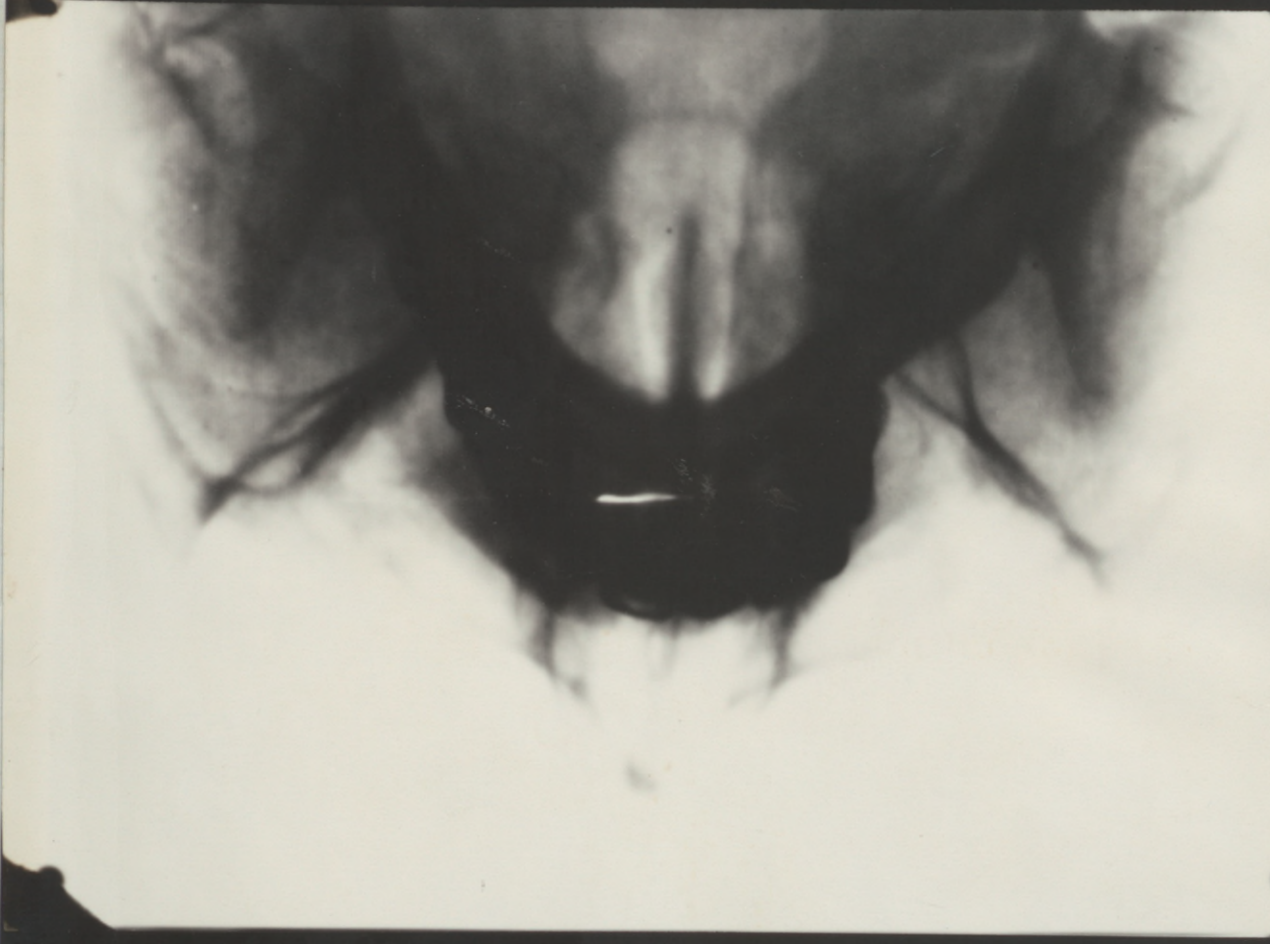
KODAK S



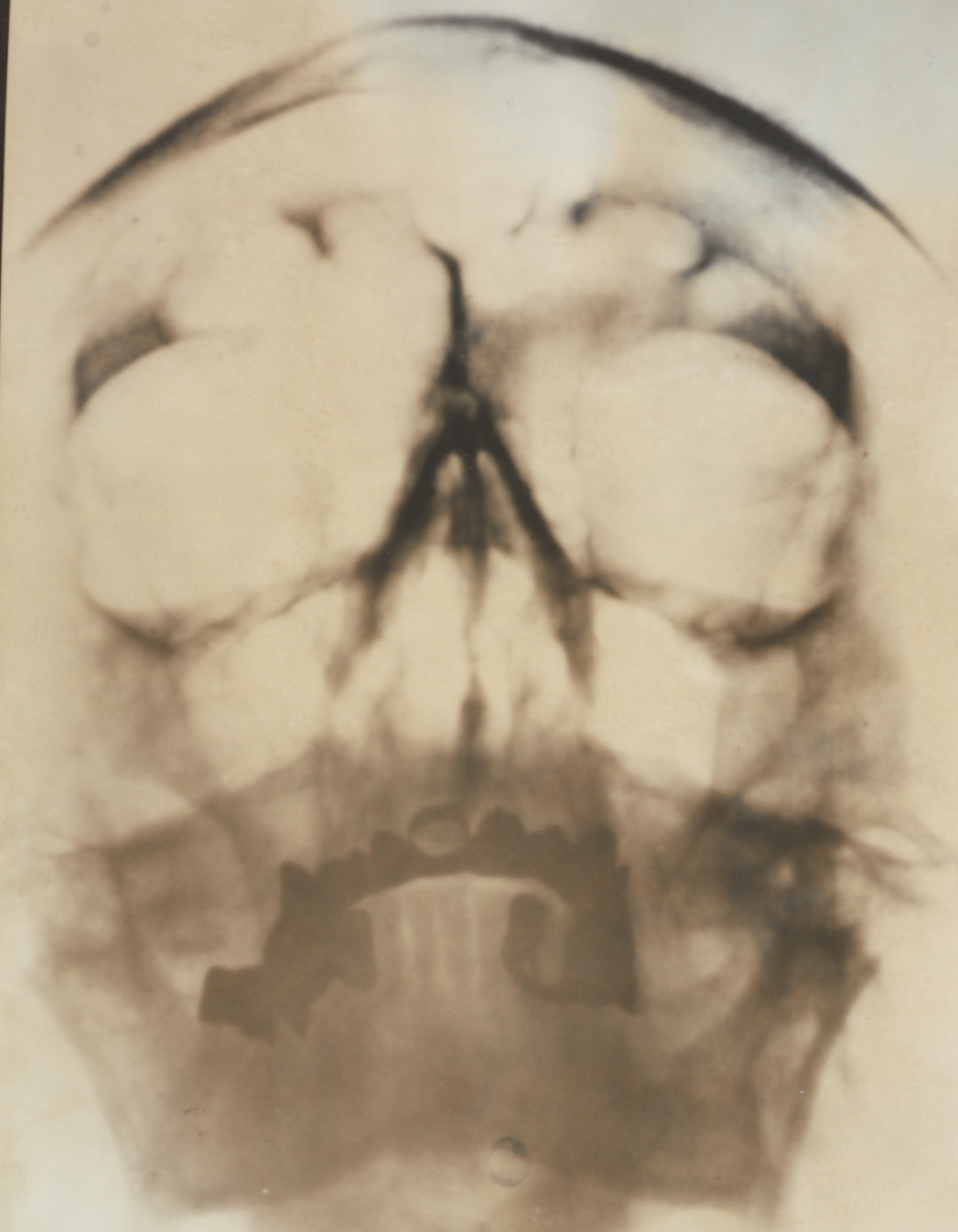


R





KODAK



Chomarsky

Klin. Diag.:
Clin. Diag.:
Diag. clin.:




Nr. Name: *X*
No. Nom:

Alter: *51*
Age:

Beruf: _____
Profession:

Datum: *14. IV. 41*
Date:

Abl.
Circuit
Dérivation



Prof. Dr. Th. Wessell

mit 6 gestricheln
11. Mai 1943.




Name: Pet. A.

Vorname: _____

Wohnung: _____

Krkcht.: _____

Jahrgang:	54 Jhr.
Quartal:	A



ELECTROCARDIOGRAM II.

DATE: May 11, 1943

Disease Coronary sclerosis

AGE: 54

AURICULAR RATE: 85-90

P-QRS Interval: 0.12

VENTRICULAR RATE: 85-90

QRS complex: 0.08

RHYTHM: pacemaker, apparently originates in the uppermost region of Tawara node or in the lowermost region of Sinus node

Axis deviation: left

LEAD I: Slight notching of base of R, low -inverted T, very slight low take off of R-T segment, P-wave 3 mm, R-wave 9.5 mm, Q-wave 0.75 mm.

LEAD II: slurring of R, practically isoelectric T, Low take off of RS-T segment, voltage of P 3 mm, voltage of R 3 mm.

LEAD III: slight slurring of R / S, low voltage; nearly isoelectric T, voltage of R 1 mm, voltage of S 5.5 mm.

NOTE: Standardization is not present.

Horizontal spacing: 0.04 sec, vertical sp: 1 mm

actual square-spacing: 0.075"

/Electrocardiogram III (a)

Nr.

Name: *Pati A.*


Klin. Diag.: *Coronarskizze*

Datum: *24.9.44*


Beruf:

Alter:


Stufe 4



I



II



III

Name: *Pate A.*

Klin. Diag.:

Nr.:

Datum: *24.9.44*

Alter:

Beruf:


Stufe 4



Abi. I



II



III

Ertragsdiagramm

Stufe 6

Klin. Diag.:

Pat. A.

Name:

24.9.44

Nr.:

Datum:

Stand:


Mer:



AM-
I



II



III

ELECTROCARDIOGRAM III (a).

DATE: September 24, 1944

Clinical diagnosis: Switch on A..

AGE:

AURICULAR RATE: 85-90

P-QRS Interval: 0.10-11

VENTRICULAR RATE: 85-90

QRS Complex: 0.08

RHYTHM: Pacemaker apparently originates in the uppermost portion of Tawara node. (conduction time: 0.10-11).
Axis deviation: Left

LEAD I: low inverted T, slight low take off of R-T segment, notching of P, voltage of P 0.3 mm, small Q wave(1 mm), voltage of R 8.5 mm,

LEAD II: slight slurring of R, isoelectric T, low take off of R-T segment, voltage of P 0.3 mm, voltage of R 3 mm,

LEAD III: slight slurring of base of R, Voltage of R 1.3 mm, voltage of S 6 mm.

NOTE: Standardization present.

Horizontal spacing: 0.04 seconds, Vertical spacing: 1 mm.

actual square-spacing: 0.075".

/ Electrocardiogram III (b)

HEADQUARTERS
 UNITED STATES FORCES EUROPEAN THEATER
 MILITARY INTELLIGENCE SERVICE CENTER
 APO 757

ANNEX IX

RESULTS OF THREE FECAL EXAMINATIONS (TRANSLATION)

<u>Sources:</u> NISSLE, Prof Dr	<u>Position:</u> Staff of FREIBURG RESEARCH in-
	stitute
MORELL, Prof Dr Theo	Hitler's Personal Physician

Table of Contents

1. Examination made 18 Jan 40
 2. Examination made 5 Jun 44
 3. Examination made 8 Jun 44
-

1. Prof. Dr. A. Nissle	Freiburg i Br., <u>18 Jan., 1940</u> _____
Research Institute	Postal Check Account: Karlsruhe 27431
Fuerstenberg Str. 15	
Tel: 7844	

RESULT OF EXAMINATION

To: Prof. Dr. Morell, n.d. _____
 Berlin W 15

Examination of the stool specimen, received on 15 Jan., 1940, of patient A _____ showed the following:

Reaction acid
 Strikingly poor growth

Only a few acid-forming Coli bacteria were present; they did not behave typically under culture and did not completely correspond serologically to the MUTAFLOX strain, showing themselves to be inferior and antagonistic. Concentration of the fecal specimen resulted only in increased growth of the same organism, no other bacteria and no helminthous eggs.

Microscopic examination of the stool specimen showed an entirely normal picture, only vegetable fibres being observed.
 /s/ Nissle

2. Private Research Laboratory	Hamburg, <u>5 Jun 1944</u> _____
Prof. Dr. Theo MORELL	
HAMBURG 39, Bellevue 42.	

Result of Feces Examination of A.

The specimen submitted is dirty grey-brown, very thin and mushy, and without courser components.

Reaction is weakly acid with a Ph of 5.5.
 /Microscopic examination

2. Result of Feces Examination of A(contd)

4. Examination of single colonies:

A. The colonies known as bacillus "lactis aerogenes" exhibit in part somewhat swollen ends with irregular staining (usually bipolar nodes). The bacteria are Gram-positive. In the 1% pepton solution with addition of glucose, lactose, maltose, and saccharose there was acid formation.

Methyl Red reaction: positive.

Voges-Proskauer reaction: negative.

B. Four strains growing red on Endo medium in Pepton solution:

	after 12 hours				after 24 hours
	red I	red II	red III	red IV	I-IV
1. glucose	+	+	+	+	+
2. saccharose	+	+	+	+	+
3. lactose	-	-	-	-	+
4. maltose	+	+	+	+	+
5. levulose	+	+	+	+	+
6. dulcitate	+	+	+	+	+
7. methylred test	+	+	+	+	+
8. Voges-Proskauer reaction	-	-	-	-	-
9. gelatine liquidation	-	-	-	-	-

On the anaerobe plates there are isolated clostridia of the type putrificus.

CONCLUSION: Examination of the submitted stool specimen reveals a generally normal picture. Presence of Paracoli bacteria could not be demonstrated, though the coli bacteria show a slight decline in fermentive activity which is plainly due to the acid reaction of the specimen.

Examination of individual bacteria of the aerogenes and aerobacter group shows no pathological deviation.

Summary: Practically speaking, result of examination is normal.
/s/(illegible)

3. Bacteriological Research Institute Freiburg i. Br., 8 Jun 1944
 Director, Prof. Dr. A. Nissle Postal check account: Karlsruhe
 Freiburg i. Br. /27431
 (17 a)
 Furstenberg St. 15 Tel: 7844

Result of Examination

To: _____ Professor Dr. Morell _____ M.D. _____
 _____ Berlin W 8 _____

Examination of the stool specimen received on ___ 3 Jun 1944 ___
 of _____ PATIENT A _____

showed the following:

/Reaction acid

HEADQUARTERS
UNITED STATES FORCES EUROPEAN THEATER
MILITARY INTELLIGENCE SERVICE CENTER
APO 757

A N N E X X

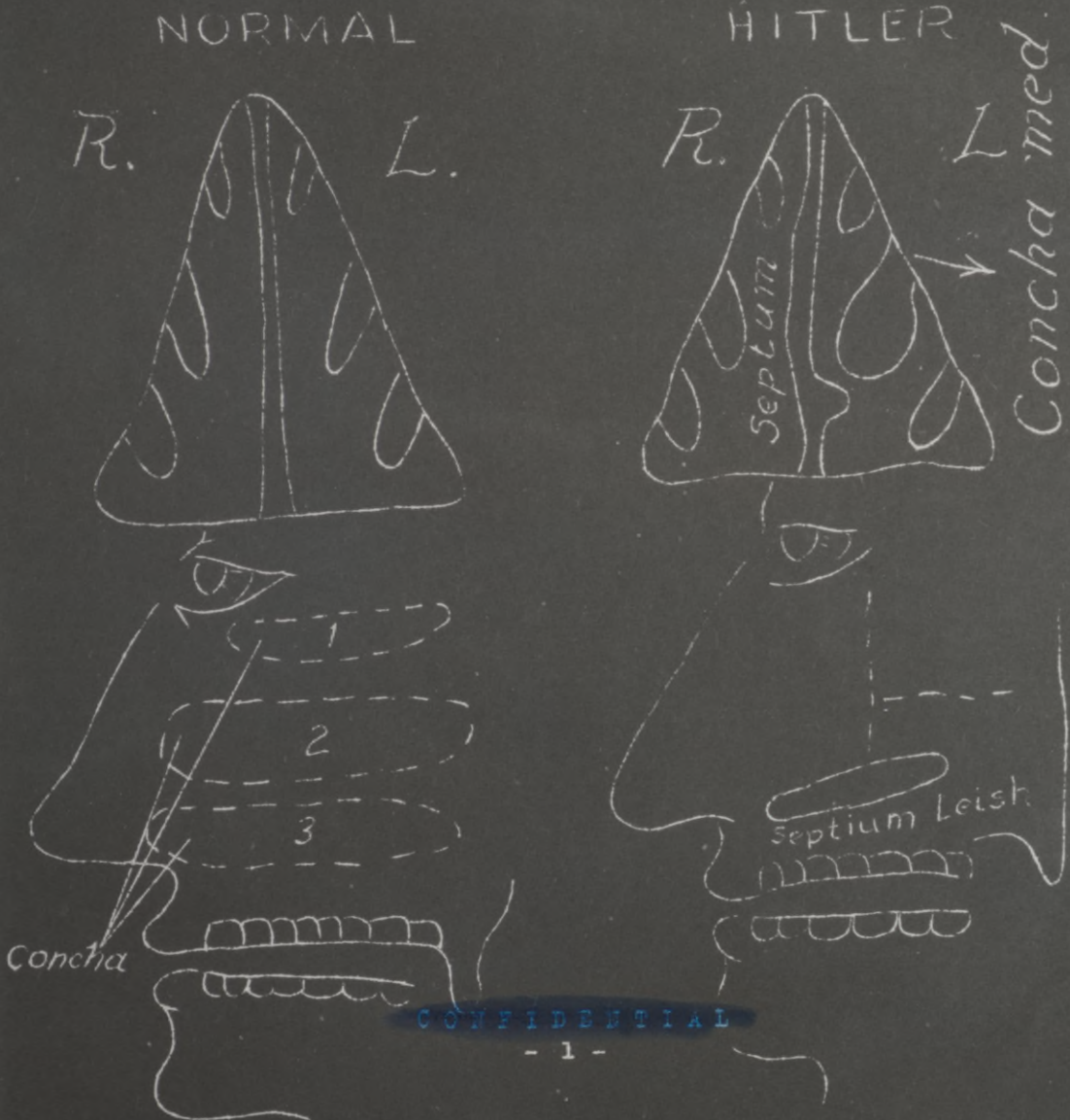
DRAWING OF HITLER'S NOSE

Sources: GIESING, Prof Dr

Position: Oberstabsarzt

This sketch was drawn from memory in June 1945 by Prof Dr GIESING, formerly Oberstabsarzt in charge of the ear, nose and throat clinic at the Army General Hospital, in RASTENBURG, East Prussia. He treated ear injuries suffered by HITLER during the assassination attempt on 20 Jul 44. The sketch illustrates hypertrophy of concha media and deviation with bony ridge formation of septum in Hitler's nose as contrasted with the normal.

/Annex XI



HEADQUARTERS
UNITED STATES FORCES EUROPEAN THEATER
MILITARY INTELLIGENCE SERVICE CENTER
APO 757

A N N E X X I

BLOOD SEDIMENTATION RATE TEST

Source: MORELL, Prof Dr Theo

Position: Hitler's Personal
Physician

PROF. Theo MORELL, M.D.

BERLIN W 15, 9 Jan 1940
Kurfürstendamm 216 (corner Fasanen St.)
Subway station: Uhland St.

Tel: 917382

PATIENT: PATIENT A

SEDIMENTATION RATE of blood corpuscles

WESTERGREEN METHOD

1st hour= 4 mm

NORMAL VALUE: up to 10mm.

2nd hour= 9 mm

Medium value: 6.5 mm

BLOOD SUGAR DETERMINATION, SEIFFERT METHOD.

110 mg%

Normal value: 90 - 120 mg%

/Annex XII

CONFIDENTIAL

OI - CIR/4

HEADQUARTERS
UNITED STATES FORCES EUROPEAN THEATER
MILITARY INTELLIGENCE SERVICE CENTER
APO 757

A N N E X XII

BLOOD CALCIUM TEST

Sources: MORELL, Prof. Dr.
BRINKMANN, Prof. Dr. E.

Position: Hitler's personal Physician
Staff of Medical Diagnostic
Institute, REFLIN

MEDICAL Diagnostic Institute

Dr. Schmidt-Burbach, M.D.
Berlin NW7, Schiffbauerdamm 3
Tel: 423759 - Postal check account
Berlin 183620

LAB. N. 28687

To: Prof. Dr. Morell M.D.

BERLIN W 15

RECEIVED for Examination on 9 Jan 1940

a SAMPLE of BLOOD

Mrs.
of PATIENT A
Mr

Result of examination: Calcium: 11.3 mg%

Berlin, 15 Jan 1940

/s/by/E. Brinkmann

/Annex XIII

CONFIDENTIAL

HEADQUARTERS
 UNITED STATES FORCES EUROPEAN THEATER
 MILITARY INTELLIGENCE SERVICE CENTER
 APO 757

A N N E X X V

BLOOD SERUM DIFFERENTIAL

<u>Sources:</u> MORELL, Prof Dr Theo	<u>Position:</u> Hitler's Personal Physician
BRINKMANN, Prof Dr E.	Staff of Medical Diagnostic Institute, BERLIN

The following is a translation of a report submitted to Dr. MORELL by the Medical Diagnostic Institute of Dr. SCHMIDT-BURBACH in BERLIN, after tests had been made to determine deficiencies of individual glandular secretions in the blood of HITLER. The process followed involves the use of an interferometer to determine to what degree each of the glandular secretions in Hitler's blood serum was affected by catabolic fermentation. "Normal" destruction of glandular secretions by fermentation is obtained from a table which has been set up to provide an indication as to the sufficiency of concentration.

The determination is made by preliminary calibration of the interferometer with fresh serum in both chambers: units of drum reading are used to express the amount of deviation between the two beams. Then the serum in one chamber of the instrument is substituted for an equivalent amount of serum which has been incubated for 24 hours at 37° C, after the addition of a predetermined amount of standardized glandular extract (Organogenoste). Then the two beams of the interferometer are again brought into phase. The amount of change necessary to accomplish this, again expressed in units of drum reading, indicates the degree to which the particular glandular secretion involved has been affected by catabolic fermentation in the blood of the patient. The operation is repeated for each glandular secretion to be investigated.

Graphical representation of the findings appearing on the following report have not been included because of the difficulties of reproduction.

MEDICAL DIAGNOSTIC INSTITUTE
 DR. A. SCHMIDT-BURBACH, M.D.
 Berlin NW 7, Schiffbauerdamm 3
 Tel.: 423759
 Postal Check Account: Lab. No. 286
 Berlin 183620
 Reading on calibration with fresh serum 1467 drum units.

(The drum reading for each individual component is the sum of the calibration reading and the catabolic valuation reading listed below.)

Component	Catabolic Valuation (in drum units)		Evaluation
	Normal	Patient	
Hypophysis, pars ant.	13	13	
- Hypophysis, pars post.	17	12	
Hypophysis, total	14	..	

/Parathyroid gland

