

ack
WV 100 B393a 1923

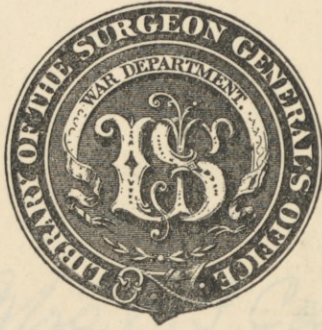51320520R



NLM 05267972 4

NATIONAL LIBRARY OF MEDICINE

ARMY MEDICAL LIBRARY
WASHINGTON
Founded 1836



Section

Number 321078

GPO 3-10543

FORM 113c, W. D., S. G. O.
(Revised June 13, 1936)

DUE TWO WEEKS FROM LAST DATE

L JAN 4 1949

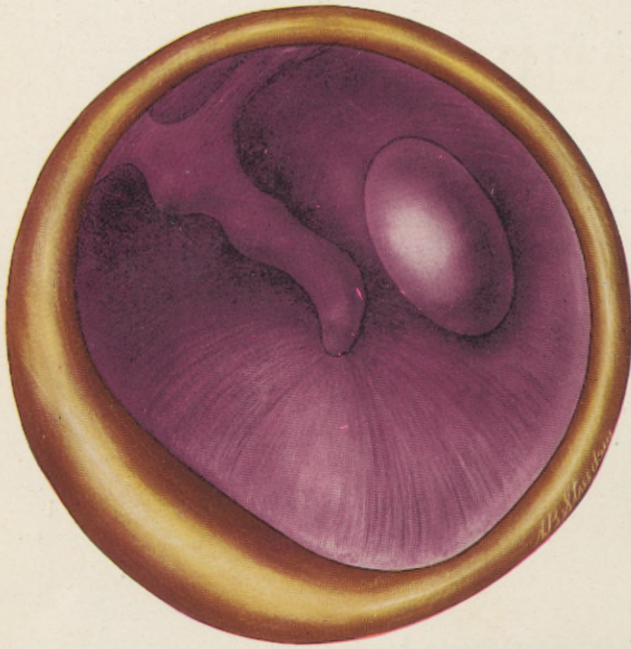JAN 6 1951

JAN 8 1952

MED. LIBR. ASSN. EXCH.

Univ. Va.

APPLIED PATHOLOGY IN DISEASES OF
THE
NOSE, THROAT, AND EAR



BULLA OF THE MEMBRANA TYMPANI IN ACUTE INFECTION OF THE INFLUENZAL TYPE

APPLIED PATHOLOGY
IN DISEASES
OF THE
NOSE, THROAT, AND EAR

BY

JOSEPH C. BECK, M.D., F.A.C.S.

ASSOCIATE PROFESSOR OF LARYNGOLOGY, RHINOLOGY, AND OTOTOLOGY,
UNIVERSITY OF ILLINOIS COLLEGE OF MEDICINE; CHIEF
OF STAFF, OTOLARYNGOLOGY, NORTH CHICAGO
HOSPITAL, CHICAGO



WITH 268 ORIGINAL ILLUSTRATIONS
INCLUDING 4 COLOR PLATES

ST. LOUIS
C. V. MOSBY COMPANY

1923

WV
100
B3932
1923

COPYRIGHT, 1923, BY C. V. MOSBY COMPANY

(All Rights Reserved)

Printed in U. S. A.

Press of
C. V. Mosby Company
St. Louis, Mo.

TO
THE FUTURE OF OTOLARYNGOLOGY
AND
TO MY SON
JOSEPH C. BECK, JR.

FOREWORD

I have long felt the need for such a work as I am herein presenting, both from my own experience as well as the communications from many other otolaryngologists. There is not, even to this day, an English text book that is limited to the Pathology of Nose, Throat, and Ear Diseases and their borderline conditions, but I hope for the early appearance of one.

The work of Oscar Beck, of Vienna, to be published in the form of an atlas "Atlas der Histopathologie der Nase und ihrer Nebenhöhlen (Atlas of Histopathology of the Nose and Accessory Sinuses) will shortly appear in German and I have accepted the translation of it into English. The colored illustrations which so beautifully demonstrate the pathologic processes will enhance the value of this volume. There are many illustrations of the same conditions found in my work, only that they are plain, not retouched, microphotographs.

It has further been determined to make this work one on applied pathology, in the belief that a greater benefit will be derived from applying the pathological entities to etiology, symptoms, diagnosis, and prognosis, thereby arriving at a rational basis for treatment, *exclusive of the strictly surgical interventions*. In other words, the fundamental object in the analysis and management of a case is a definite knowledge of the underlying pathological change present.

It is my desire to limit this work almost exclusively to my personal experiences and therefore it should not be considered as a text book. There will be many subjects that will not appear either because I have had no personal experience pertaining thereto, or because I cannot offer any data as to their pathology. Particularly is this true in acute conditions wherein it is but seldom possible to secure actual pathological specimens, it being either surgically contraindicated, or otherwise uncalled for. However, by analogy, adhering to the fundamental principles of pathology, one may infer such changes as would naturally occur, for instance, in acute inflammation elsewhere.

Certain gross illustrations, other than those from my own cases, have been taken and modified after other investigators only when they seemed to serve better than if taken from the original, but they always represent and typify case groups and conditions found in my own work. I wish, therefore, to acknowledge the work of Denker, Katz, Preysing, Blumenthal and Wittmaack.

In the study of pathological changes, I have considered each subject as shown grossly in the patient during examination and further corroborated by laboratory data, as x-ray, etc., or during operative procedure or treatment; next, the gross specimen after removal, if such be the case, with subsequent microscopical examination. I have been fortunate in a few instances to have secured postmortem specimens. The subjects presented both in gross and microscopical sections, as well as in the photographs, are selected as typifying groups rather than individual cases. In all the laboratory work, experts have collaborated and I wish, therefore, to express my appreciation to Drs. Ludwig Hektoen, Maximilian Herzog, W. A. Evans, and Carl Beck.

More than any other contributory factor in making this work possible has been the interest shown by some of my students and fellow-workers, and I desire at this time to mention a few who figure prominently in the work: Drs. Clara Moore, Theresa Lane, W. J. Neuzil, Frank J. Novak, Jeanette Shefferd, Harry L. Pollock, as well as my collaborators and former students, Drs. Arnold B. Kauffman and Francis L. Lederer. In appreciation of their cooperation, I have purposely used the pronoun "we" throughout the work. I also wish to express my thanks to the artist, Mr. A. B. Streedain, for his cooperation.

I desire to acknowledge the fact that in the text the reader will frequently find that I am at variance with many of the accepted principles both in diagnosis and treatment, and I expect criticism on this score, but these are my beliefs and I have carried them out in our practice with satisfactory results.

It will be noted that there is an absence of much of the borderline of ear, nose and throat conditions, as well as operative surgery, with which work I have been identified, but owing to the enormity of the material, these could not be incorporated in this volume. Should the demands warrant it, I have promised

myself the writing of such books with the same pleasure as the writing of this volume has given me.

In regard to the absence of radiographic illustrations, I wish to state that a great part of my radiographic work has already appeared in my "Radiographic Atlas" published a number of years ago by The Laryngoscope, and more modern work will appear in a future joint publication on radiography, covering subjects especially interesting to otolaryngologists, by Drs. Randall, Bigelow, Iglauer, Gerber and myself.

CONTENTS

PART I

ACUTE DISEASES

	PAGE
CHAPTER I	
ACUTE DISEASES OF THE NOSE	17
Fracture, 17; Furunculosis, 20; Frost-bite, 20; Vestibulitis Acuta, 21; Foreign Bodies, 22; Septal Abscess and Hematoma, 23; Epistaxis, 24; Acute Rhinitides (Rhinosinitis), 24; Paranasal Sinus Disease—Acute, 30; Acute Sinus Disease in Children, 31; Acute Fulminating Sinuitis, 33.	
CHAPTER II	
ACUTE DISEASES OF THE PHARYNX	36
Epipharyngitis, 36; Retropharyngeal Abscess, 37; Acute Bursitis (Thorn- waldt's Disease), 37; Acute Ostium-Tubitis (Salpingitis), 38.	
CHAPTER III	
MESOPHARYNX	39
Mesopharyngitis (Tonsillopharyngitis), 39, Acute Peritonsillar Abscess (Quinsy), 42; Acute Tonsillar Abscess, 44; Membranous Pharyngitis, 45; Hypopharyngitis, 48; Pharyngeal Bleeding, 50.	
CHAPTER IV	
ACUTE DISEASES OF THE LARYNX	51
Acute Simple Laryngitis, 51; Acute Laryngitis, Severe Type, 51; Diph- theritic Laryngitis, 52; Trauma, 53.	
CHAPTER V	
ACUTE DISEASES OF THE TRACHEA	55
Acute Tracheitis, 55; Foreign Bodies in the Trachea, 55; Injuries, 56; Acute Diseases of the Bronchi, 59; Acute Esophagitis, 59.	
CHAPTER VI	
ACUTE DISEASES OF THE EAR	60
Otitis Externa, 60; Acute Ostium Tubitis, 66; Acute Otitis Media, 66; Acute Mastoiditis, 72.	
CHAPTER VII	
ACUTE COMPLICATIONS OF MASTOIDITIS	84
Acute Labyrinthitis, 85; Perisinus Abscess, 86; Sinus Thrombosis, 87; Extradural Abscess, 89; Intradural Abscess (Acute Brain Abscess), 90; Hernia Cerebri, 91; Meningitis, 91; Acute Facial Paralysis, 93; Acute Facial Paralysis Unassociated with Mastoid Disease, 94.	

PART II

CHRONIC DISEASES

CHAPTER VIII

CHRONIC DISEASES OF THE NOSE	96
External Nose, 96; Rhinophyma, 96; Lupus and Tuberculosis, 96; Lues,	

98; Rhinoscleroma, 100; Pus Infections—with or without Destruction of the Soft Parts, 100; Tumors, 100; Paraffinoma, 105; Vestibulum of the Nose, 109; Internal Nose, 109; Nasal Septum, 109; Traumatic Septum, 115; Lues, 117; Tuberculosis of the Septum, 119; Malignant Disease of the Septum, 120; Papilloma of the Septum, 120; Congenital Absence of the Septal Cartilage, 122; Closure of the Posterior Choanae, 122; Septum in Atrophic Rhinitis, 122; Synechia, 123; Inferior Turbinate, 124; Turgescence, 124; Hypertrophy, 125; Atrophy, 134; Atrophic Rhinitis, 134; Hyperplasia, 138; New Growths of the Inferior Turbinate, 138; Lupus or Tuberculosis of the Inferior Turbinate, 139; Syphilis of the Inferior Turbinate, 139; Chronic Rhinosinuitis, 139; Pathology of Individual Structures, 140; Hyperplastic Rhinosinuitis, 149; The Middle Turbinate and Sinuses in Atrophic Rhinitis, 155; Sarcoma of the Sinuses, 157.

CHAPTER IX

NASOPHARYNX AND OROPHARYNX	167
Chronic Tubitis, 167; Pharyngitis—Lateralis Hypertrophicus, 168; Atrophic Pharyngitis, 169; Thornwaldt's Disease, 170; Syphilis of the Pharynx, 171; Tuberculosis of the Pharynx, 174; Tumors of the Pharynx, 175; Sarcoma of the Tonsil, 177; Carcinoma of the Pharynx, 177; Tonsil and Adenoid Diseases, 179; Tuberculosis of the Tonsil, 188; Luetic Tonsil, 192; Actinomyces of Tonsil, 192; Hyperkeratosis of the Tonsil, 193; Benign Tumors, 194.	

CHAPTER X

CHRONIC DISEASES OF THE LARYNX	197
Carcinoma of the Larynx, 197; Tuberculosis of the Larynx, 206; Syphilitic Laryngitis, 210; Chronic Simple Laryngitis, 212; Fibrous Polyp, 213; Papilloma of the Larynx, 215; Eecondroma of Larynx, 218; Laryngeal Paralysis, 218.	

CHAPTER XI

CHRONIC DISEASES OF THE TRACHEA, BRONCHI AND ESOPHAGUS	221
Chronic Mucopurulent Tracheitis, 221; Syphilitic Tracheitis, 222; Neoplasms of the Trachea, 222; Adenoma of the Trachea, 223; Bronchorrhea, 223; Carcinoma of the Esophagus, 223; Esophageal Diverticulum, 224; Strictures of the Esophagus, 224.	

CHAPTER XII

CHRONIC DISEASES OF THE EAR	227
Chronic Otitis Externa, 227; Chronic Otitis Media, 243; Chronic Suppurative Tympanomastoiditis, 244; Chronic Nonsecretive Otitis Media, 249; Adhesive Otitis Media, 250; Atrophic Otitis Media, 250; Otitis Media Residualis of Wittmaack, 251; Chronic Otitis Media Serosa or Seromucosa, 254; Summary of Pathologic Processes in Chronic Mastoid Disease, 260; Chronic Diseases of the Internal Ear, 268.	

ILLUSTRATIONS

FIG.	PAGE
Bulla of the membrana tympani in acute infection of the influenzal type (Color Plate)	Frontispiece
1. Abscess of the septum; resection for deflection following traumatic hematoma, showing marked cellular infiltration with destruction of cartilage	18
2. Septal cartilage removed subsequent to hematoma of the septum, showing an active chondritis	18
3 and 4. Compound fracture of the nose	19
5. Simple fracture of the nose	19
6. Same case as in Fig. 5 after recovery	19
7. Frost bite	21
8. Septal abscess (Color Plate)	22
9. Notched nose following septal abscess	23
10. Meeting of the septal and the triangular cartilage with the lateral masses at the tip and bridge of the nose	23
11. Suction apparatus with capillary suction tube	25
12. Beck's Irrigation Unit	26
13. Beck's postural method of treatment of nose and throat	28
14. Cameron's antralamp	32
15. Brigg's method of transillumination of antrum	32
16. Mucous membrane and bone in acute fulminating Sinuitis	34
17. Acute follicular tonsillopharyngitis, with hyperplasia of the tonsils	39
18. Head traction method (as demonstrated by Lyman) to aid swallowing	41
19. Acute peritonsillar abscess with a follicular tonsillitis of the opposite side	42
20. Incipient peritonsillitis and peritonsillar abscess formation (Color Plate)	42
21. Tonsillar abscess with localization and exudate appearing on the surface of the tonsil	44
22. Acute inflammation of the lingual tonsil and base of tongue	49
23. Laryngeal diphtheria	52
24. Gas burn ulceration	57
25. Othematoma	61
26. Trauma of external auditory meatus and canal following self-infliction with saturated solution of carbolic acid	65
27. Tympanic membranes in acute inflammation of the middle ear	67
27. Retrogression of acute middle ear process (Color Plate)	68
28. Herniation of the tympanic membranes in severe forms of acute otitis media suppurativa	69
29. Nipple perforation	70
30. Cortex of mastoid in acute mastoiditis, showing necrosis and fistulous tract	73
31. Thickened periosteum in acute mastoiditis	73
32. Acute mastoiditis, cell route infection, showing cortex of mastoid and adjoining cells	74
33. Curettements from the interior of the mastoid in acute mastoiditis, cell route infection, showing the lining membrane of the cells thickened and infiltrated with leucocytes	74

FIG.	PAGE
34. Acute mastoiditis, cell route invasion	75
35. Acute mastoiditis, cell route infection	76
36. Mastoid chip in acute mastoiditis, cell route infection, showing necrosing osteitis	76
37. Acute mastoiditis, cell route invasion	77
38. Acute mastoiditis, with curettement showing nothing but abscess formation	77
39. Reparative osteitis in a mastoid chip removed in a reoperative case of chronic suppurative otitis media	78
40. Same as Fig. 39, high power	78
41. Acute mastoiditis, vascular or osteophlebitic route	80
42 and 43. Sinus thrombosis	88
44. Extradural abscess	89
45 and 46. Cerebral hernia	92
47. Rhinophyma (Pound Nose)	98
48. End result of lupus of lip and both alae nasi showing marked cicatrization	97
49. Luetic destruction of septum nasi including the columella and center of upper lip	98
50. Gumma of external nose with marked destruction of the interior of the nose and the columella	99
51. End result of deformity and cicatrization in gumma of nose	99
52. Nevus of external nose (scar at tip following boiling water injection)	101
53. Rapidly developing nevus, and result after various methods of treatment	101
54. Sarcoma of nose producing the typical frog face appearance	102
55. Sarcoma of nose involving the external parts with a fistula formation	103
56. Epithelioma of external nose about the ala	103
57. Epithelioma of external nose confined to the tip	104
58. Paraffinoma of external nose showing a scar where attempts were made to remove it	106
59. Masses of paraffinoma removed	106
60. Paraffinoma of the nose, showing persistent particles of paraffin surrounded by fibrous tissue and numerous fat cells	107
61. Paraffinoma of the nose, showing definite node formation about the paraffin particles	107
62. Paraffinoma of the nose, showing dense fibrous tissue and cellular infiltration about fibrous particles	108
63. Paraffinoma of the nose, showing nodule surrounded by fibrous tissue and numerous fat cells	108
64. Septal spur taken posteriorly near the sphenoid, showing marked rarefaction in the bone and the presence of osteoblasts with the deposition of new, deeply staining bone in the walls of the larger spaces	110
65. Gross illustration showing septal ridges at the floor of the nose	110
66. Large ridge from the premaxilla, showing marked rarefaction	111
67. Septal ridge showing blood vessels	111
68. Septal ridge, showing at the junction of the bone and cartilage large blood vessels filled with blood	112
69. Septal cartilage taken high up anteriorly from a young individual, showing marked thickening of the subperichondrium with great karyokinetic figures in the cartilaginous cells at this point	112

FIG.	PAGE
70. Septal ridge, showing cartilage and bone activity at their junction; rarefaction is also clearly demonstrable	113
71. Septal exostosis, showing areas of rarefaction and dense bone	113
72. Septal ridge, showing rarefaction of bone and great activity of the bone and cartilage cells at their junction, and blood vessels filled with blood	114
73. Traumatic septum; resected cartilage in a traumatic football nose caused primarily by an abscess of the septum	115
74. Septal cartilage, showing round cell infiltration and the great activity of the cartilage cells themselves; also cross section of blood vessels	116
75. Same as Fig. 74 (high power)	116
76. Septal defects, anteriorly and posteriorly, luetic origin	117
77. Typical saddle or notched nose following gummatous destruction	118
78. Gumma of the septum	118
79. Multiple papillomata of the septum	120
80. Benign papilloma of the nose, showing structural formation with finger-like projections	121
81. Papilloma of the nose showing hornification	121
82. Lip of wound in atrophic rhinitis, showing hyperplasia of the mucous membrane, especially the glands	123
83. Epithelial hypertrophy of the inferior turbinate with folded-in masses	125
84. Same as Fig. 83, high power, showing epithelial lakes	126
85. Hypertrophy of the inferior turbinate, showing marked thickening of the epithelium with folded-in masses	126
86. Eschar following cauterization of the inferior turbinate	127
87. Papillary hypertrophy of the inferior turbinate, showing the epithelial hypertrophy	127
88. Papillary hypertrophy of the inferior turbinate	128
89. Mulberry hypertrophy of the posterior end of the inferior turbinate	128
90. Posterior end of the inferior turbinate showing "mulberry hypertrophy"	129
91. Diffuse papillary hypertrophy of the inferior turbinate	129
92. Inferior turbinate, showing rarefaction	130
93. Chronic intumescence of the inferior turbinate, showing predominance of connective tissue with round cell infiltration of the surface epithelium and almost complete atrophy of the glands, together with new blood vessel formation	130
94. Same as Fig. 93, high power	131
95. Beck's conchotribe	132
96. Crushing of the inferior turbinate (conchotribe); section taken on the third day showing marked round cell infiltrated masses of necrobiosis	133
97. Eschar of the inferior turbinate following actual cautery in a case of vascular hypertrophy, showing fibrinous organization and papillary formation, together with marked leucocytic infiltration	133
98. Atrophy of the turbinates in atrophic rhinitis	134
99. Inferior turbinate and early atrophic rhinitis, showing distention of the glands	135
100. Inferior turbinate and early atrophic rhinitis, showing metaplasia of the epithelium of the median side and thickening of the antral side	135

FIG.	PAGE
101. Middle turbinate in early atrophic rhinitis, showing metaplasia of the epithelium of the median side and thickening of the antral side . . .	135
102. Apparently true myxomatous polypi of the inferior turbinate; showing also rarefaction of the bone	138
103. Chronic hypertrophy of the middle turbinate in chronic suppurative sinusitis, showing an increase in the normal tissue elements with preservation of the glands	141
104. Glandular hypertrophy of the middle turbinate, showing besides the increase in glandular elements a rarefying osteitis	141
105. Rarefying osteitis of the ethmoids in suppurative sinusitis	143
106. Ethmoid curettements in chronic suppurative ethmoiditis, showing areas of bone necrosis	143
107. Lining membrane of the frontal sinus in chronic suppurative pansinusitis, showing infiltration and thickening, with areas of myxomatous degeneration	145
108. Solitary polyp in the frontal sinus in a case of chronic suppurative sinusitis, showing areas of myxomatous degeneration	146
109. Same as 108 (high power)	146
110. Pyogenic membrane lining the antrum of Highmore in chronic, suppurative pansinusitis, showing practically a leucocytic wall	147
111. Anterior wall of the sphenoid with chronic suppurative pansinusitis, showing connective tissue fibrosis	147
112. Pyogenic membrane lining the sphenoid in chronic suppurative sinusitis	148
113. Tooth with granuloma attached extending to the antrum, removed in case of unilateral chronic suppuration of the antrum and ethmoid sinuses	148
114. Multiple polyp under the middle turbinate in early hyperplastic ethmoiditis	150
115. Solitary sphenoid polyp	150
116. Sphenoid polyp	151
117. Solitary pedunculated fibrous polyp removed from the naso-frontal duct, in case of chronic nonsuppurative sinusitis	151
118. Cystic formation in a nasal polyp in nonsuppurative sinusitis	152
119. Polyp arising from middle turbinate proper	152
120. Anterior end of the middle turbinate removed in a case of hyperplastic ethmoiditis, showing the loss of glandular structure and fibrous changes	153
121. Middle turbinate in nonsuppurative sinusitis, showing degenerated glands and infiltrated mucous membrane	153
122. Turbina bullosa of the anterior end of the middle turbinate	154
123. Same as Fig. 122 (sagittal section). Turbina bullosa	154
124. Cyst of the middle turbinate	155
125. Ethmoid mass in case of chronic nonsuppurative ethmoiditis, showing no differentiation but practically complete myxomatous degeneration and some vacuolization	155
126. Middle turbinate in early atrophic rhinitis, showing metaplasia of the epithelium and persistence of mucous glands	156
127. Nasal polyp, removed in chronic suppurative pansinusitis, showing myxomatous degeneration	156
128-152. Sarcoma of the antrum treated by surgery, x-ray and radium	157

FIG.	PAGE
153. Spindle-celled sarcoma of the anterior wall of the antrum of Highmore, associated with chronic suppuration	163
154. Large, small, round, and spindle cell sarcoma of the antrum	163
155. Sarcoma of the nose, showing a highly vascular growth	164
156. Melanosarcoma, high power	164
157. Radium exudate in the same case as in Fig. 156. The exudate consists chiefly of fibrin and disintegrated cells	165
158. Lateral pharyngitis (chronic) showing thickened epithelium, bone, lymphoid tissue, round-celled infiltration and old connective tissue	168
159. Rubber catheter drawn through nose and out mouth to expose area for treatment	169
160. Healed out luetic cicatrices of the velum palati	172
161. Pharyngeal stenosis-healed lues	173
162. Unilateral carcinoma of the tonsil	178
163. Hyperplasia of tonsils with infection, also adenoid mass	179
164. Tonsil—hyperplasia of lymphoid tissue, showing but slight dilatation of the crypts and absence of cheesy masses in them	182
165. Adenoids, showing marked increase of lymphoid tissue and very little connective tissue	183
166. Adenoids, showing degeneration of the lining epithelium	183
167. Tonsil, showing remnants of lymphoid tissue and marked increase in connective tissue	184
168. Tonsil in chronic lacunar inflammation, showing dilated crypts filled with cheesy masses	184
169. Tonsil, showing dilated crypts filled with detritus containing cholestrin crystals in case of chronic tonsillar infection	185
170. Same as Fig. 168, high power, showing cheesy masses filling dilated crypts	185
171. Tonsil, showing trabeculae of fibrous tissue starting at the inner surface of the capsule and enclosing masses of degenerated lymphoid tissue; also, large number of blood vessels of small lumen present	186
172. Persistent granulation after removal of adenoids	187
173. Multiple tonsilloliths	189
174. Tuberculosis of the tonsil, showing cheesy masses in a dilated crypt	189
175. Tuberculosis of the tonsil, showing numerous tubercles and a dilated, degenerated crypt	190
176. Tuberculosis of the tonsil, with caseation, showing typical tubercles formed about the central giant cells	191
177. Luetic tonsils, showing round cell infiltration and caseous gummata	192
178. Leptothrix	193
179. Tonsillar crypt filled with bismuth paste, showing the communication of the crypts	195
180. Photomicrograph showing the foreign body giant cells most numerous in the region of the bismuth masses	196
181. Carcinoma of the arytenoids and cords	198
182. Carcinoma of larynx, extending from the pyriform fossa	198
183. Carcinoma of the hypopharynx extending into the larynx	199
184. Carcinoma of the larynx, involving the tongue, showing hard, ragged, infiltrated and ulcerated mucous membrane	200

FIG.	PAGE
185. Carcinoma of the larynx	200
186. Carcinoma of the larynx, showing typical epithelial pearls	201
187. Carcinoma of the larynx showing some typical epithelial pearls	202
188. Carcinoma of the larynx, showing typical epithelial pearls under high power	202
189. Carcinoma of the larynx, showing marked activity of the malignant epithelial cells	203
190. Carcinoma of the larynx, showing epithelial pearls and a considerable number of blood vessels and connective tissue	203
191. Carcinoma of the larynx, showing combined activity of the cartilage cells	204
192. Carcinoma of the larynx, showing "nests" of epithelial cells and older connective tissue and uninvaded blood vessels	204
193. Carcinoma of the larynx, after radiation, showing some round cell infiltration and evidence of chronic inflammatory changes but no active malignant cells	205
194. Interytenoid tuberculoma simulating papilloma	206
195. Tuberculous infiltration of the cord and epiglottis	207
196. Tuberculosis of the larynx, involving the arytenoids and the epiglottis which is markedly edematous	207
197. Tuberculosis of the larynx	208
198. Tuberculosis of larynx showing typical tubercle formation	208
199. Chronic inflammation of the larynx in case of advanced pulmonary tuberculosis, showing marked round cell infiltration but no tubercle formation or giant cells	209
200. Laryngeal stenosis; luetic origin	211
201. Singers' nodules	212
202. Solitary fibrous polyp of the cord (pedunculated)	213
203. Laryngeal polyp showing fibrous tissue in various stages and numerous capillaries	214
204. Benign papilloma of the ventricular band	216
205. Multiple papillomata of the larynx	216
206. Papillomatous formation about the tracheal fistula	217
207. Papilloma of the larynx, showing typical papillae formation	217
208. Electrically heated bougie for esophagus with thermostat	225
209. A group of congenital malformations of the ear in the process of reconstruction. Four degrees, complete absence to presence of half of the auricle	228
210-225. Congenital partial absence of auricle, complete absence of middle and internal ear right. Polyotia, left. Plastic reconstruction, Gills method of tube formation from neck. Septal cartilage implants. Twelve separate steps in the operation	229
226. Congenital macrotia and macrocephalia	233
227. Congenital deafness, external ear deformity and right facial paresis in brothers	233
228. Congenital verruca (wart)	233
229. External ear completely torn off in elevator accident	234
230. Part of external ear bitten off by dog	234
231A. Artificial ear used in correction of case shown in Fig. 230	234

FIG.	PAGE
231B. Artificial ear held in place by spectacles	234
232. Partial destruction of external ear and scars about the face and scalp	235
233. Practically complete loss of external ear associated with scarring of the left side of the face and neck following burn of third degree . .	235
234. Partial loss and contracture of the external ear and side of the face following accidental application of 95 per cent carbolic acid . .	235
235. Retroauricular fistula following radical mastoid operation	235
236. Chronic perichondritis	237
237. Chronic perichondritis	237
238. Chronic perichondritis with fistula following incision of a subperiosteal abscess	237
239. Chondroma of pinna and external auditory canal	238
240. Paraffinoma of pinna injected to correct a soft roll ear	239
241-A. Epithelioma of pinna and external auditory canal	239
241-B. Complete destruction of auricle following epithelioma and radium ap- plication	239
242. Schematic outlines of perforations as to prognosis	244
243. Schematic illustration of multiple perforations	245
244. Polyp in ear completely filling the external canal in case of chronic sup- purative otitis media	245
245. Incus removed in case of chronic suppurative otitis media, showing an osteitis in its long process	245
246. Ankylosis of the malleus and incus removed in case of chronic sup- purative otitis media, showing necrotic areas in both bones	246
247. Center perforation healed over by thin scar	246
248. Thickened margin of central perforation, showing marked injection of the lining of the middle ear	246
249. Beck's wall plate	248
250. Marked retraction of the drum with displacement of the ossicles	250
251. Calcareous deposit in a drum membrane	250
252. Section through the mastoid of a six-year-old child after latent hyper- plastic otitis, showing complete arrest of pneumatization	251
253. Section through the mastoid tip in a two-year-old baby, showing a partly pneumatized mastoid, with the nonpneumatized portion filled with marrow cells and a partly developed cellular network	252
254. Section through the mastoid in an adult 60 years of age, showing normal pneumatization	253
255. Osteofibrosis and chronic suppurative otitis media showing complete fibrosis of the mastoid cells	254
256. Apparatus for introduction of nascent iodine	256
257. Schematic drawing for the Pfannenstiel treatment	257
258. Mercury tube	258
259. Chronic suppurative otitis media, showing osteofibrosis with fistulae forma- tion	261
260. Otitis media suppurativa chronica (high power), showing necrosis with accompanying fibrous reparative process—a chronic osteofibrosis with fistulous tract, filled with pus and granulation tissue	261

FIG.	PAGE
261. Chronic suppurative otitis media, showing osteofibrosis, fistulous tracts and cholesteatomatous infiltration	262
262. Otitis media suppurativa chronica	262
263. Otitis media suppurativa chronica	263
264. Otitis media suppurativa chronica, showing tuberculous focus with fistula	263
265. Sequestral osteitis showing particularly the worm-eaten appearance of the edges of the sequestrae	264
266. Sequestral luetic osteitis	264
267. Mastoid chip in chronic suppurative otitis media of luetic origin, showing an osteofibrosis	266
268. Epidermal scar of healed radical mastoid cavity, showing the absence of any blood vessels or any resemblance to true skin	267

APPLIED PATHOLOGY IN DISEASES OF THE NOSE, THROAT AND EAR

PART I

ACUTE DISEASES

CHAPTER I

ACUTE DISEASES OF THE NOSE

1. FRACTURE

Fracture of the nose is now relatively infrequent in this country compared with the days preceding prohibition. The cases in the Receiving Wards of all public hospitals have been reduced from six to eight a day to two or so a month, and similarly in proportion in private practice. The gravity of the condition is, of course, in its compound form. The hematoma, with subsequent infiltration is particularly significant on account of the reposition of the displaced and fractured bones, since in many cases reduction is impossible until the acute reaction has subsided. It is to be noted that in addition to the fractured nasal bones, there is nearly always associated a bending, displacement or fracture of the septum, cartilaginous, osseous or both. The immediate attention to such injuries gives the best prognosis and cosmetic results. Subsequent attention to these cases, as in resecting the cartilage to correct deformity, shows in section, a loss of cartilage cells with the formation of connective tissue especially in the subperichondrial region and the areas of absorbed cartilage (Figs. 1 and 2).

CASE 1.—Compound fracture of nose. Fragments protruding externally and internally. Four days' standing, complicated by emphysema, adenitis and subsequent cellulitis and septicopyemia (Fig. 3). Operation: Opened externally and reapposition of parts which were held together by silver wire. Rubber tube

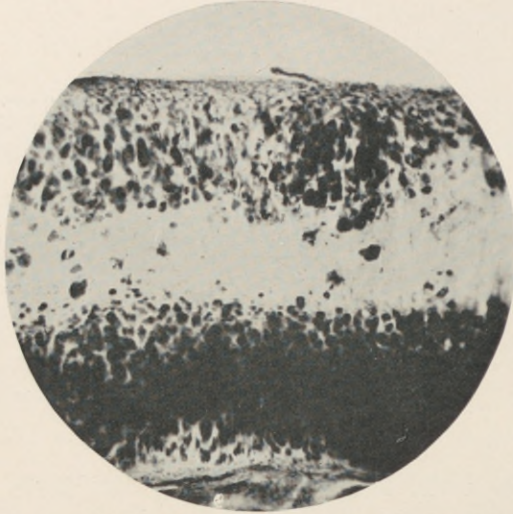


Fig. 1.—Abscess of the septum; resection for deflection following traumatic hematoma, showing marked cellular infiltration with destruction of cartilage.

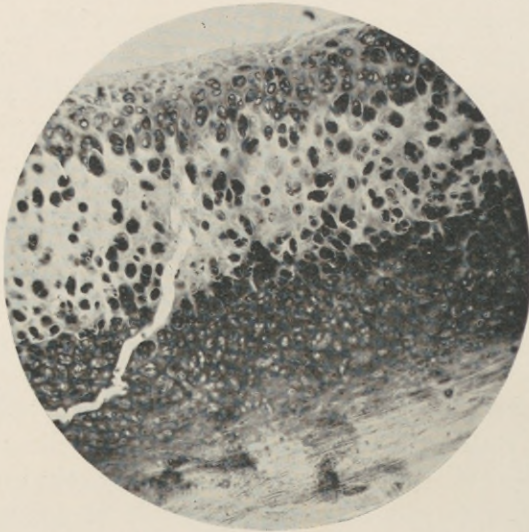


Fig. 2.—Septal cartilage removed subsequent to hematoma of the septum, showing an active chondritis.

intranasal drainage. Further uneventful recovery,—seventeen weeks (Fig. 4).

This case illustrates the most severe pathologic entity of fractures in which the soft tissues become infected and the bones

necrotic with subsequent sequestration and extrusion. In contradistinction is Case 2.

CASE 2.—Simple fracture of nose following “bump against door.” Examination showed crepitation, blood suffusion along

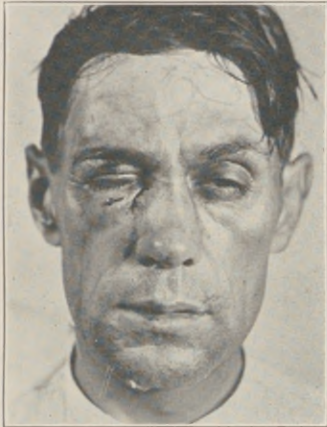

Fig. 3.



Fig. 4.

Figs. 3 and 4.—Compound fracture of the nose.



Fig. 5.—Simple fracture of the nose. Fig. 6.—Same case as in Fig. 5 after recovery.

lower lid, septal hematoma. X-ray verifies nasal bone severance from the nasal spine of the frontal bone. Immediate readaption with proper intranasal splinting and external strapping. (Method of Lee Cohen.) Recovery in three weeks with good cosmetic result. (Figs. 5 and 6.)

2. FURUNCULOSIS

The most frequent cause of furunculosis lies in the habit of pulling out vibrissae and picking the nose, with subsequent folliculitis. Associated there may be frequently some constitutional disorder that should not be overlooked. In this respect it has been noted that not infrequently a high blood sugar content is found without glycosuria. The symptoms are entirely out of proportion to the pathologic changes—pain, swelling and disfigurement. Essentially the condition is a cellulitis with subsequent localization; the venous channels are blocked; the outlets of the follicles are sealed up by crusts. The intensity of the pain is explained by lack of loose areolar tissue at the site of infection. The course as a rule is uneventful. Recovery without deformity but frequent recurrence is to be noted. The treatment *par excellence* is the avoidance of manipulation as squeezing, cutting, picking and neither excess heat nor cold. The best results are obtained with warm compresses and an excess of petrolatum in the vestibule. We have also used with good results Credé's ointment locally or 10 per cent ichthyol ointment instead of the petrolatum. In rare instances this process becomes grave and fatal cases have been seen, especially in anemia, diabetes and malnutrition, and particularly where surgical intervention has been practiced; here the thrombus extends to the superior longitudinal sinus through the foramen cecum. The complications are perichondritis with deformity and erysipelas.

3. FROST-BITE

This condition affecting the nose is comparatively rare in contradistinction to frost-bite of the ear. The most important symptom for diagnosis is the blanching of the skin with a sharp line of demarcation above the alae on either side.

CASE 1.—Cab driver, alcoholic, suffering from acne rosacea. Shows the characteristic white blanching of alae and the lower portion of the tip of the nose (Fig. 7). Complained of loss of sensation followed by excruciating pain radiating to temples. Treatment: Snow applications of no avail. Necrosis of blanched parts and subsequent slow healing with cicatrization.

CASE 2.—Ordinary case of mild severity, showing blanching

(constriction of superficial vessels) followed by loss of sensation. Rubbing with snow and moist cold compresses were fol-

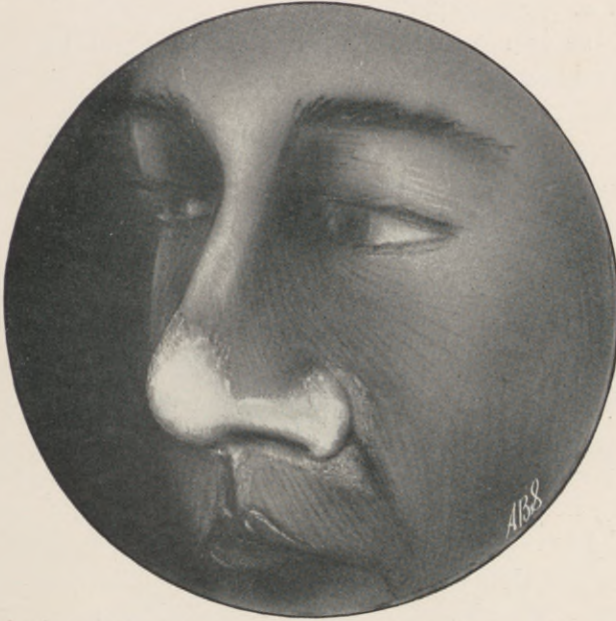

Fig. 7.—Frost bite. Note sharp line of demarcation.

lowed by intense pain (secondary engorgement). Leeches applied with almost immediate relief. Slow recovery with atrophy of skin which became thin, parchment-like.

4. VESTIBULITIS ACUTA

Invariably associated with, or immediately following acute rhinosinuitis there is some vestibular inflammation present, usually on the inner alar surfaces and the contiguous portion of the vestibule to the upper lip. Occasionally, the septal denudation, associated with the above-mentioned rhinosinuitis, extends to the dermal surface of the vestibule, at times in the most anterior-superior portion of the vestibule, where the vibrissae are the most numerous; caking of accumulated and dried mucus will irritate the skin and occasionally lead to what is much more frequent in chronic vestibulitis, viz., fissure formation. The upper lip is commonly affected in this small excoriation contiguous to the vestibule. The treatment, of course, must be directed toward the etiological factor, viz., the rhinosinuitis, by neutral-

izing the excessive alkalinity of the secretion as well as influencing the action of the bacterial content. This management is described in the subsequent chapters. Treatment of the vestibulitis per se is most satisfactorily carried out by the use of ammoniated mercury ointment (2 per cent) freely applied within the vestibule.

5. FOREIGN BODIES

Foreign bodies in the nose are found most frequently in children; wads of paper, small buttons, small pebbles, and marbles are among the commonest forms. In the adult, the formation of concretions by accretions of various salts from the mucous secretions, particularly magnesium phosphate, is the most frequent foreign body, and at that, it is comparatively rare. We have had a case in which a rhinolith of the magnesium phosphate variety was of such size as to make its removal impossible either anteriorly or posteriorly through the nose. However, by applying strong acetic acid we were able to so alter its composition as to make crushing and piece-meal removal possible. The resultant destruction within the nasal cavity from pressure, was a defect in the lateral wall and a perforation in the posterior part of the septum.

Parts of instruments broken off during surgical operations, particularly knives and chisels, are found with sufficient frequency to record them. Gauze and cotton left in the nose following treatment or operation, have also been observed. The x-ray is of great value in diagnosis. The symptoms resulting from all foreign bodies consist in the main of unilateral, thick foul discharge, bleeding, especially when associated with ulceration, and nasal obstruction. Vestibulitis invariably accompanies foreign bodies.

Treatment.—Removal of the foreign body is the only procedure to be considered, and each case is an entity in itself. In children, it is best to remove the foreign body under general anesthesia, although, if it is located anteriorly it may be removed without an anesthetic; in adults, removal is best accomplished under local anesthesia. Metallic substances have in many instances been removed by aid of the Haab magnet, although in several cases it was necessary to remove some of the overlying bony structures.

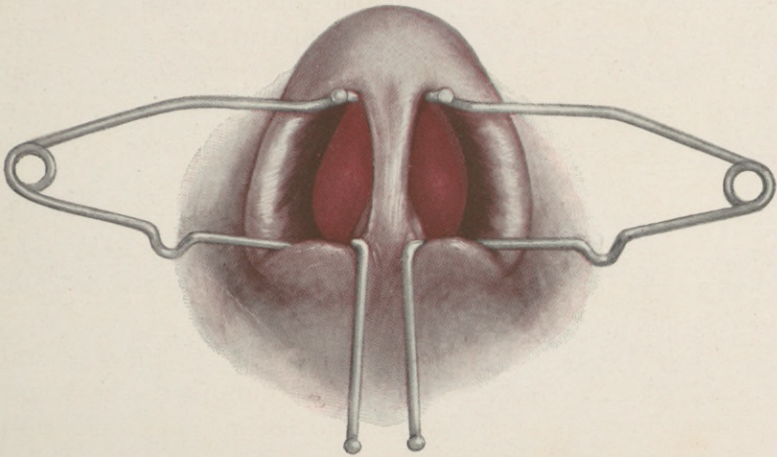


Fig. 8.—Septal abscess.

While foreign bodies should be considered under the heading of acute conditions, if they are retained over a period of time, they cause chronic disease, or eventually lead to a foreign body tumor.

6. SEPTAL ABSCESS AND HEMATOMA

Septal abscess usually follows a fall or direct trauma of the tip of the nose. We have seen one case in a child of nine of what apparently must be called an idiopathic septal abscess, there being no history of trauma. Examination shows a bilateral occlusion and when the tip is lifted, two smooth, rounded masses are revealed extending from the septum laterally and



Fig. 9.—Notched nose following septal abscess.

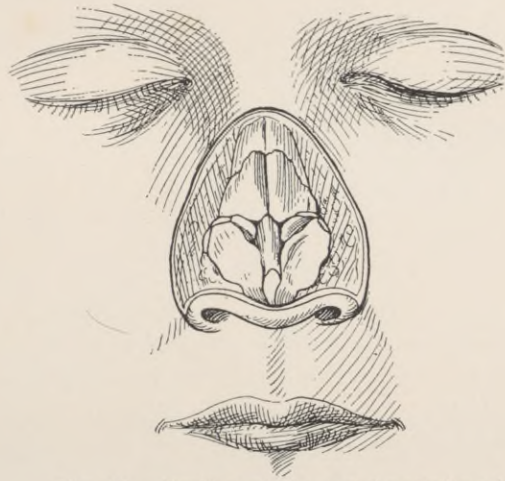

Fig. 10.—Meeting of the septal and the triangular cartilage with the lateral masses at the tip and bridge of the nose.

filling the entire nares (Fig 8). This is doughy to the touch and not particularly tender. If the hematoma remains uninfected, which is rare, absorption will follow with probable pressure atrophy of the cartilage with the resultant corresponding kink or notch nose (Fig. 9). This is caused by complete absorption of the triangular septal cartilage at its important supporting triangle. (Fig. 10.)

When there is abscess formation, there may be a rise of temperature and pain radiating to the root of the nose and the temples. Usually there is a submaxillary adenitis. The treatment

of both hematoma and abscess is immediate evacuation under strict aseptic conditions with firm packing on both sides. Drainage can be obtained irrespective of the packing by the insertion of a few strands of silkworm gut into the depth of the wound. (The treatment of deformities has been taken up in the Chapter by Dr. J. C. Beck in Loeb's "Operative Surgery of the Nose, Throat and Ear.")

7. EPISTAXIS

Epistaxis is rather a symptom than a disease. One of the commonest causes is a nose-picker's ulcer of the septum. In children it is associated with exanthemata and in former years it was the great prodromal symptom of typhoid fever. It is also found in blood dyscrasias, such as anemias, hemophilia and cardiovascular diseases, characterized by high arterial tension, but in the largest number of cases it is associated with operation. The commonest site is at the locus of Kieselbach in the anterior inferior portion of the cartilaginous septum. In most instances these conditions are chronic and will be discussed later. Immediate treatment is directed toward the bleeding points by sufficient packing with Bernay splints or post-nasal tampon and subsequent use of caustics, such as full strength silver nitrate, chromic and trichloroacetic acid and at times actual cautery. In cases where bleeding persists, submucous resection becomes necessary.

8. ACUTE RHINITIDES (RHINOSINUITIS)

Acute rhinitis should be thought of as a rhinosinuitis. Whether one or the other is primary is a problem. The pathologic changes in this disease must be studied in the various stages.

1. At the onset the mucous membranes, if they could be measured, would be much thinner than normal owing to the narrowing of the vessels. On inspection, a corresponding ischemia is to be noted. This period lasts but a short time and is most frequently associated with irritation of the nerves characterized by dryness and repeated sneezing.

2. The first stage is followed by vascular dilatation, in which there is a swelling of the mucous membranes with the outpouring of a watery serous discharge, nonirritating at first. This stage again is fleeting and of short duration.

3. Leucocytic infiltration, as well as the outpouring of lymph and the increase of alkaline content of the transudate follows. The swelling of the mucosa becomes greater and is accompanied by round-cell infiltration. There is often superficial rhexis and, at times, slight bleeding. This stage is likewise of short duration.

4. Pus formation with a marked increase of mucin, giving the mucopurulent character to the discharge, succeeds the leuco-




Fig. 11.—Suction apparatus with capillary suction tube.

cytic infiltration. At this period we advise the patient to try not to blow his nose if possible. If the secretion is very thick, capillary suction may be used to great advantage (Fig. 11). As little manipulation as possible is advisable. The common olive tip suction is not to be recommended because of the increased possibility of drawing in the mucous membrane and thus obstructing the outlet of the paranasal sinuses.

The purulent period is of the longest duration because of obstruction to the outlets of the paranasal sinuses and secondary or other changes in the sinuses from closure, increased secretion, greater swelling of the membranes or increased bacterial activity. There may likewise be even putrefaction or actual necrosis. It is desirable as soon as the sensation of a "heavy feeling" over the sinuses is noticed, to shrink the mucous membranes in

the region of the sinus outlets with a small pledget of cotton, moistened with either a weak cocaine solution or apothecin solution to which a few drops of adrenalin may be added. Adrenalin alone, over a longer period of time, is to be avoided because of

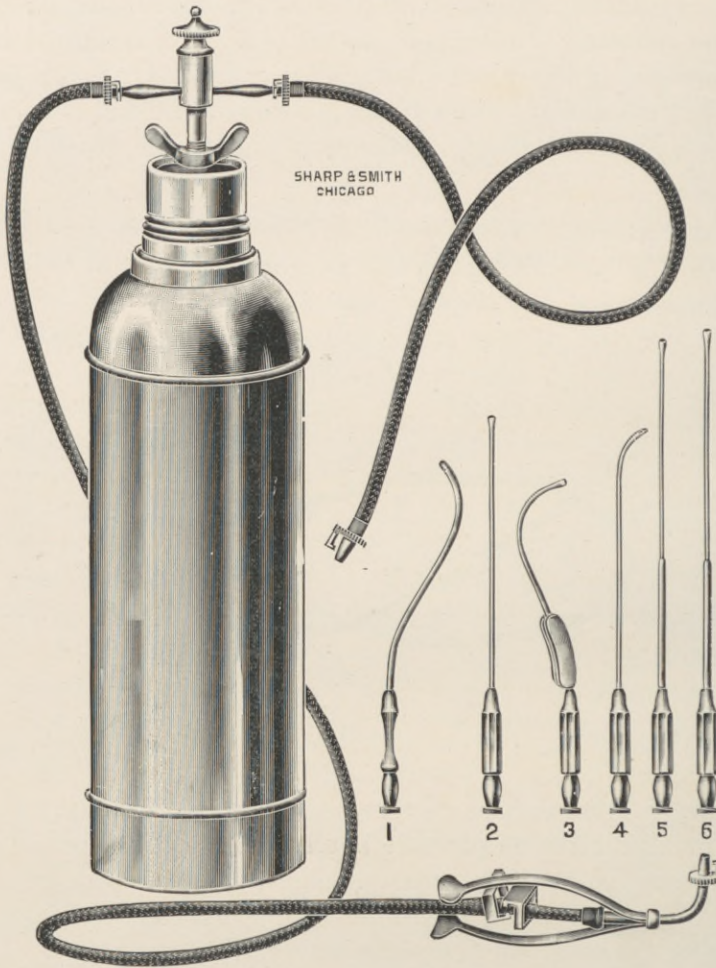


Fig. 12.—Beck's irrigation unit.

the marked secondary dilatation of the blood vessels which produces further engorgement of the mucous membranes. Rinsing the secretions back into the throat is to be preferred to frequent blowing of the nose, even though this method may not be esthetic. Capillary suction under direct inspection can be used to

advantage but again we advise strongly against the bulb suction tips. The use of mild alkaline antiseptics or normal saline solution may be employed by the aid of cannula irrigation under direct ocular inspection. We employ the apparatus as shown in Fig. 12, which consists, in the main, of a thermos bottle fed by compressed air. Cannulas of various sizes and shapes as they may be required in irrigation of the nose, throat or ear are also shown. Solutions which we have found valuable in these conditions are silvol or neosilvol (5 to 20 per cent solutions) introduced preferably by Beck's postural method (Fig. 13). It is to be emphasized here that for the most part, these conditions are self-limited and as little as possible manipulation is to be practiced. The general treatment must not be neglected, i. e., intake of fluids, free catharsis, etc.

As a general rule, if there has not been too much interference or too many complications, the patient recovers from his marked discomfort within a limited period. There is a gradual resolution and the discharge becomes thicker, scantier, and the vestibule tends to crusting, at which time the patient is apt to pick the nose and add the complication of a possible vestibulitis with fissure formation. At this time, one frequently finds in the effort to dislodge the thick secretions, blood-streaked mucus and often the beginning of a chronic septal ulceration. Coincidentally, there is increased space in the nose associated with improvement in the general symptoms and feeling of well-being. This usually occurs about the second week.

Complications:

1. Acute Sinuitis, one or all sinuses.
2. Tubotympanitis—by extension.
3. Acute tonsillitis.
4. Pharyngolaryngitis.
5. Tracheitis.

It is known that the symptoms of infection may begin in the lower respiratory passages and extend upwards.

If the process tends to become subacute, local treatment to the

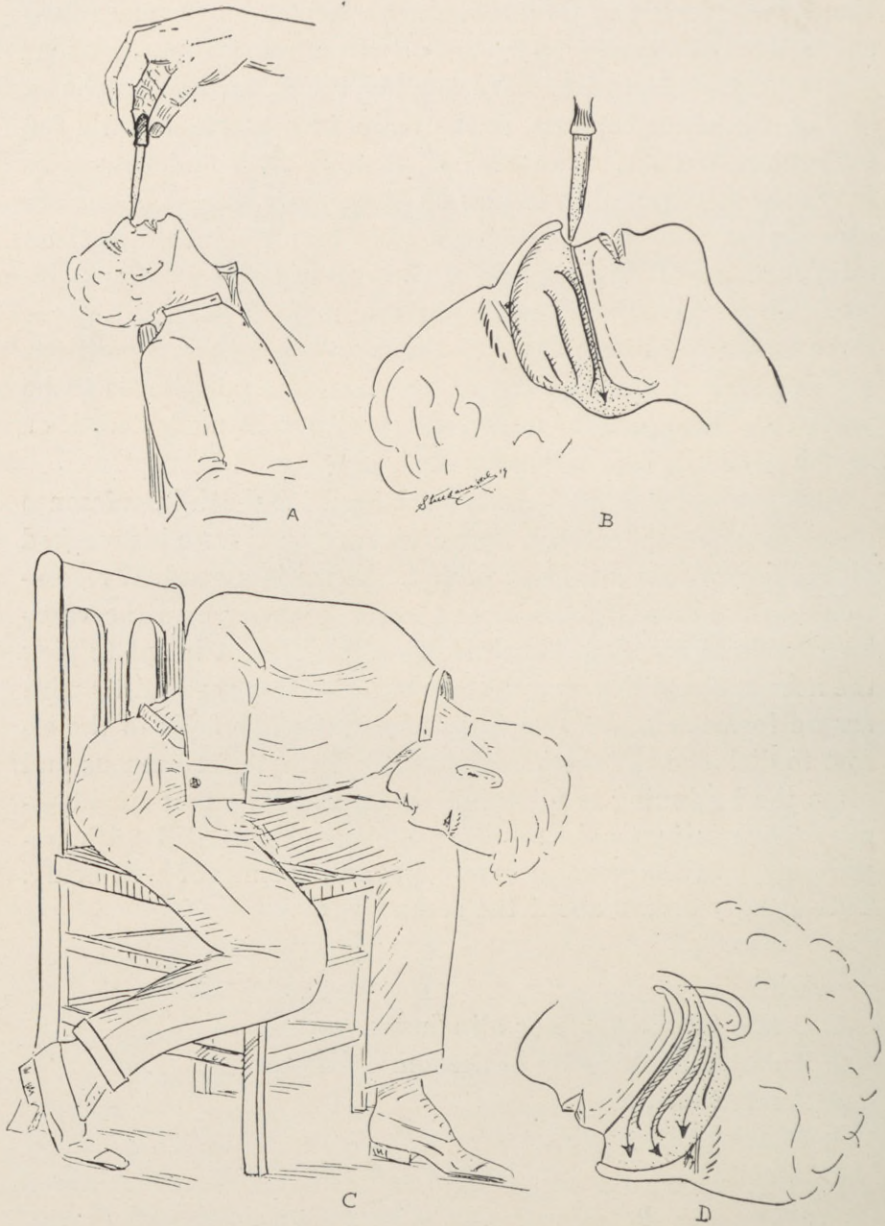


Fig. 13.—Beck's postural method of treatment of nose and throat.

nasal mucous membranes of the coal tar products, as ichthyol, and various emollients, as petrolatum, are of great benefit.

As far as the microscopic changes are concerned, the initial stage will rarely be studied because of its transient duration and we can only infer here the absence of inflammatory products. The most important change is the marked vascular dilatation, many of the vessels being literally choked up with leucocytes. In many places active diapedesis and marked leucocytic infiltration can be observed. The superficial epithelium in many places is denuded. The marked hyperactivity of the mucous glands manifests itself in distention and the columnar cells show great activity,—the granules staining deeply.

In the later stage, the round-cell infiltration becomes more marked and in many instances there are hemorrhagic areas. The glands are reduced in size. Pus corpuscles can be seen in great numbers on the surface; and in tissues stained for bacteria, the prevailing microorganisms, with corresponding disappearance of the usual nasal flora, can be seen.

The mucous membranes lining the sinuses differ only in the glandular changes, as they are sparingly distributed, but on the other hand, since the membrane serves as periosteum to the nasal accessory sinuses, there are observed areas of definite superficial osteitis in addition. In very virulent infections, there is an actual necrosis in addition to the osteitis, the engorgement and increased number of osteoblasts especially in the first layers of the lacunae. Not infrequently there are definite areas of superficial bony necrosis which in most instances tends toward resolution. (Gerber.) We ourselves have not studied these changes, but accept the work of authorities.

Bacteriology.—Without entering into either the literature or references to this subject, we prefer to take the old basis of authorities for our classification of the acute and chronic flora of the nasal cavities. The most prevalent organism in the acute cases is the staphylococcus, predominating in the ordinary "cold." Even in the majority of the exanthemata in children this is true, and only in the epidemics or pandemics of "La Grippe" is the influenzal bacillus found together with the pneumococcus or streptococcus. The question of transmutation of

bacteria (Rosenow) found in acute processes is not accepted, but one frequently observes an acute rhinosinitis in which the influenza bacillus is present early but is later supplanted entirely by the pneumococcus and then even later by the staphylococcus and streptococcus. Rarely diphtheritic organisms have been found in acute cases (without membrane or exudate). Spirochetes are likewise rarely found.

PARANASAL SINUS DISEASE—ACUTE

Acute paranasal sinus disease as a sequence to the acute rhinitides is comparatively infrequent, as by far the majority of "colds" clear up, although latent infection may remain in the sinuses making predisposition to further attacks quite likely. When it does occur we find the involvement more frequently unilateral, and if bilateral, one side is more active than the other. As to the sinuses involved, the anterior group is known to be involved much more frequently than the posterior group. In the former, in order of frequency of involvement comes the antrum, the ethmoid and then the frontal. Primarily the antrum may not be most frequently involved, but secondarily to frontal and ethmoid infection as well as to dental infection. In the posterior group comes in order of frequency, the posterior ethmoid and sphenoid sinuses.

Acute sinus disease is found apart from complicating, or as a sequence to, rhinosinitis, associated with the following conditions:

1. Influenza, epidemic as well as pandemic form.
2. Bronchitis.
3. Bronchopneumonia.
4. Acute exanthemata, especially in children.
5. Secondary to nasal operations, especially where packing was done.
6. Secondary to dental disease (antrum infection).

Pathology.—As in rhinosinitis, there are various stages of involvement in both the mucous membrane and the bone. There

is first a venous engorgement, followed immediately by a transudation, depending on the severity, leading to small rhexis. Then within a very short time, twenty-four hours or so, free fluid is found in the cavities. The fluid itself is slightly cloudy, of watery consistency, and chemically of a strong alkaline reaction. Bacteriologically, this fluid is scant in organisms, except in cases of antrum infections associated with dental disease, when organisms are present in great numbers. However, many leucocytes are invariably found. If a puncture of the antrum be made within forty-eight hours, for example, the fluid is thicker in consistency, and a marked increase in bacteria, particularly the staphylococcus, is to be noted. There is a rapid change in the mucosa with tremendous swelling about the ostia and in the mucous membrane of the ethmoid labyrinth, (as has been shown when opened through the external route). Complete closure of a cavity has been noted due to the excessive swelling of the mucous membrane.

If the case progresses without drainage being established, there is a rapid change to marked round-cell infiltration in the subepithelial layers of the mucous membrane, together with active congestion by arterial dilatation which gives rise to the throbbing sensation so often mentioned by the patient. Should the organisms be hemolytic in type, streptococcus or pneumococcus, Group III type, we notice frequent small ulcerations and the bone may show a definite osteitis. At this point we might mention that it is our opinion that a sinus once affected by an infective process never undergoes complete resolution; especially is this true of the ethmoid labyrinth where predisposition to repeated attacks is so often seen.

ACUTE SINUS DISEASE IN CHILDREN

There is conclusive evidence from recent studies that acute sinus disease in children, especially antrum and ethmoid involvement, is much more frequently present than heretofore believed. The continued "running nose" in infants and children and the excessive discharge continuing longer than the usual acute rhinosinitis, is sufficient to lead one to suspect the pres-

ence of a subacute sinus involvement. The symptom of indefinite pressure about the face is very commonly complained of by older children and indicated frequently by even the younger. Upon intranasal inspection, the inflammation of the nasal mucous membrane is not sufficient to explain this excessive discharge. The persistent engorgement of the conjunctiva, especially on the nasal side, is an additional finding of considerable aid in arriving at a diagnosis. The application of adrenalin to




Fig. 14.



Fig. 15.—Brigg's method of transillumination of antrum.

the upper straits of the nose frequently discloses secretions confined to the lateral wall of the nose. The nasopharyngoscope is of considerable value to demonstrate the affection involving the ethmoid. A puncture into the antrum and then suction through the trocar will often demonstrate the secretion. The x-ray will often demonstrate the involvement, especially in unilateral antrum disease. The small cold lamp can be used nicely in transillumination, especially when introduced against the infraorbital margin and directed into the oral cavity (Figs. 14 and 15).

The pathologic changes are quite different in acute sinusitis than when the condition is acutely engrafted upon a chronic process; i. e., acute exacerbation of a chronic process, which

condition frequently comes to operation. This subject will be taken up with the chronic conditions. Definite bony and membranous changes have been demonstrated.

ACUTE FULMINATING SINUITIS

Gross Pathology.—There is marked swelling and edema of all the mucous membranes of the nasal cavity, especially about the anterior end of the middle turbinate and the adjacent lateral wall of the nose. The sinuses, frontal, antrum or ethmoid, show the following changes: the overlying skin and periosteum are edematous and acutely infiltrated; the bone bleeds freely and as soon as the cavity is opened a flow of secretion escapes under tension. The mucous membrane lining of the cavity is markedly thickened and edematous; it bulges through the opening and bleeds very freely and appears to be lifted off the underlying bone.

Microscopic examination shows marked thickening of the sub-epithelial structures. There is marked engorgement and there are some thrombotic vessels. The underlying bone shows an acute osteitis and in places may show definite bony necrosis. (Fig. 16.) This is of particular importance in relation to secondary orbital and cranial infections.

Application.—From the pathology present, it can be seen that this condition should always be attacked surgically through the external route. In the antrum, sublabially; the ethmoid, trans-orbitally; and the frontals, likewise externally. In the posterior group we have no record of operations in the fulminating type. For the technic of the various operative procedures, the reader is referred to the many texts on this subject, as Loeb's, etc.

Prevention.—After reviewing the changes taking place in the nose and paranasal sinuses, we must particularly emphasize the correction of anatomical malformations of the interior structure of the nose, i. e., deflected septums, especially the type associated with marked thickening of the tuberculum septi. Attention, too, must be directed toward middle turbinate enlargements which produce irritation from pressure and contact, or enlargements from previous sinus disease.

To our dental and oral hygiene should be added nasal hygiene,

particularly as preventive measures during epidemics of respiratory infections. Nasal irrigations of the sinuses should only be done by the experienced rhinologist. The use of oral and nasal masks during the virulent epidemic influenza has undoubtedly proved itself of value.

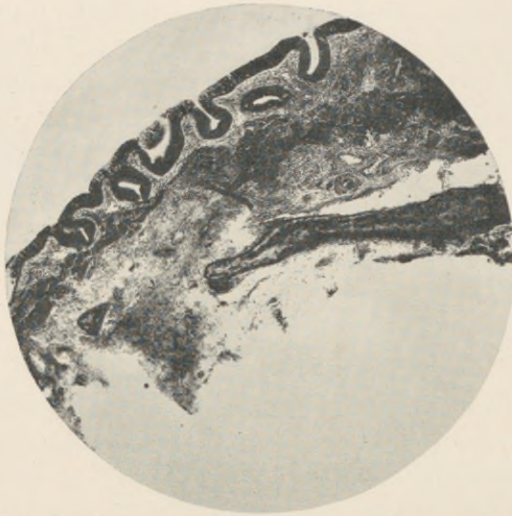

Fig. 16.—Mucous membrane and bone in acute fulminating sinusitis.

Irritation from manipulation during the acute rhinitides should be avoided. The general condition of the patient must of course be brought up to the highest point of resistance.

Antrum

Treatment.—The treatment differs in no marked respect from that given in the consideration of the acute rhinitides,—treatment that is rationally based on the pathology present. However, if we would have definite proof of tension within the antrum, the passing of a Pierce cannula into the natural opening of the sinus after cocainization is indicated. The head is then bent down and after suction is applied, irrigation again followed by suction should be carried out. We here caution against the blowing of air into the sinus under any consideration either for diagnostic or therapeutic purposes. *We do not advise puncture under the inferior turbinate in acute processes unless puncture*

through the natural opening cannot be done, although we are aware of the fact that this method is practiced by the majority of rhinologists.

Frontals

In the frontal sinus, under no circumstances do we consider the passage of sounds or cannulae in acute conditions, because we have seen, in consultation, severe complications and even fatalities from such procedures. If a more radical procedure should be necessary, we much prefer the adoption of a safer procedure. The sinus is entered through a small external opening. However, infraction of the middle turbinate for the purpose of securing better drainage is a perfectly safe procedure. Many rhinologists remove the anterior end of the middle turbinate for this purpose, but we do not recommend it.

Ethmoids

Surgical intervention in the ethmoid labyrinth during acute processes is bad practice, holding with it the danger of extension to the cribriform plate and perineural lymph spaces of the olfactory filaments. These cells, if the condition is of the fulminating type, can be attacked through the transorbital route.

Posterior Ethmoid and Sphenoid

Surgical interference in this posterior group during an acute process either for irrigation or sounding does not conform to our principles of treatment, and from our experience we strongly advise against it.

CHAPTER II

ACUTE DISEASES OF THE PHARYNX

Distinct clinical entities are rarely confined to one portion of the pharynx; thus acute conditions involving the epi-, meso- or hypo-pharynx are usually confluent.

EPIPHARYNGITIS

A distinct entity involving the epipharynx has been for a long time recognized clinically and spoken of by the German pediatricians as "Kinderdrüsenfieber." This condition is characterized by a complete lockage of the postnasal space with an acute swelling of the adenoid tissue and is accompanied by a cervical adenitis. The angular glands of the neck are like small packets and suboccipital adenitis is usually present. The middle ear, with or without subsequent discharge, seldom escapes. The condition gives rise in infants and children to a most persistent recurrence of septic temperature, with a rapidly developing secondary anemia, sweats and emaciation, and even, when uncomplicated, is of considerable duration.

The pathologic change in the adenoid tissue is but a simple hyperplasia and suppuration is almost unheard of. Hanoch has shown that the organism involved is usually a filtrable virus. Such adenoids removed surgically by mistake are accompanied with a comparatively small amount of bleeding. The remaining mucous membrane on the oropharynx appears thickened but smooth, and is not markedly injected.

Treatment.—Supportive measures, with little or no local treatment, have, in our experience, produced the most satisfactory results. Hexamethylenamine given internally, entirely on an empirical basis, has been very satisfactory and has been found to be almost specific in this inflammatory process. Local instillation of silvol preparations through the nose and Credé's ointment applied externally to the involved glands has perhaps the greatest number of advocates. Where surgery has been em-

ployed we have observed no particularly brilliant results, and in some cases the toxemia has continued to be intense and a rapidly developing emaciation has ensued.

In adults, an acute lacunar adenoiditis is not infrequently seen, although it more often is associated with a lateral pharyngitis. This condition is found particularly where there is a compensatory hypertrophy of the posterior pharyngeal lymphoid tissue subsequent to previous tonsillectomy.

RETROPHARYNGEAL ABSCESS

Retropharyngeal abscess is observed most frequently in infants and children and not uncommonly incorrectly diagnosed diphtheria. The gross changes observed in the pharynx show a thickening of all the mucous membranes about the pharynx, together with a noticeable hypersecretion. The mucous membranes are not very much injected at first and invariably one side of the pharynx appears more swollen than the other, and on palpation a distinct boggy mass is felt. Within a short time, twenty-four hours or so, the sensation of bogginess gives way to a feeling of lack of resistance rather than definite fluctuation. Incision is usually very gratifying and is accompanied with comparatively little bleeding. The use of the suction tube immediately after incision is quite advantageous. The pathology of these conditions is an infection of the retropharyngeal lymphatic glands, which break down very quickly, and the invading organism is usually the staphylococcus. Recovery as a rule is uneventful without further attention, and recurrences are rare, but do occasionally occur, especially if drainage is insufficient either because of the size of the opening or the incision having been made straight rather than oblique. The oblique incision has the advantage of actually cutting some of the muscle fibers and thus preventing too early complete closure of the wound by the constrictor muscle fibers.

ACUTE BURSITIS (THORNWALDT'S DISEASE)

Occasionally in the case of Thornwaldt's disease, an acute bursitis, involving the retropharyngeal bursa, is observed. The mucous membrane having become invaginated and the opening

closed, retention is apt to ensue. On examination a smooth, bulging mass is found in the upper vault of the pharynx where the adenoid tissue is located. The mass appears to fluctuate on palpation and very often an attempt to make a diagnosis digitally effects a cure by squeezing out the retained fluid. Dysphagia is a persistent and obstinate feature of this condition. The differential diagnosis is concerned chiefly with upper Pott's disease. The treatment consists mainly of emptying the bursa by downward incision.

ACUTE OSTIUM-TUBITIS (SALPINGITIS)

Salpingitis, although usually taken up in connection with diseases of the ear, is often confined to the lips of the tube or extends only as far as the isthmus. It is very seldom an entity in itself, but usually is found associated with a rhinitis or tonsillopharyngitis.

One finds on examination with the mirror that both lips of the tube are very red and swollen so that the usual recess opening is practically obliterated. In a later stage the glairy mucus at the opening can be seen. With a well-retracted soft palate, in cases where this process is secondary to a lateral pharyngitis, the direct extension of the inflammatory process along the lateral walls of the pharynx up to the posterior lip of the tubal orifice and the fossa of Rosenmüller can be seen. Not infrequently definite adhesions in the fossa are observed, which are the remains of atrophied lymphoid tissue together with inflammatory products. Where there is much thickening, the existence of a definite perichondritis can be assumed. If palpated, the stiffened posterior lip of the tube is felt and very often adhesions in Rosenmüller's fossa give way.

Treatment.—Mild astringents applied intranasally by dropping in the medication with the head well back and slightly tilted to the side will reach the parts. We have used in our practice, with satisfactory results, solutions of zinc sulphate and silvol. Later, direct applications of 2 to 5 per cent silver nitrate solution to the ostium tubae may be used. It is to be noted that in these conditions, although no middle ear symptoms may be present and the acute process has subsided, catheterization should nevertheless be instituted.

CHAPTER III
MESOPHARYNX

MESOPHARYNGITIS (TONSILLOPHARYNGITIS)

Mesopharyngitis is most frequently found as an entity confined to the mesopharynx. The inflammatory process, as a rule, involves the tonsillar ring and the base of the tongue. Inflammation of the tonsil without involvement of the pillars is rare. Usually the entire Waldeyer ring becomes affected when lymph-

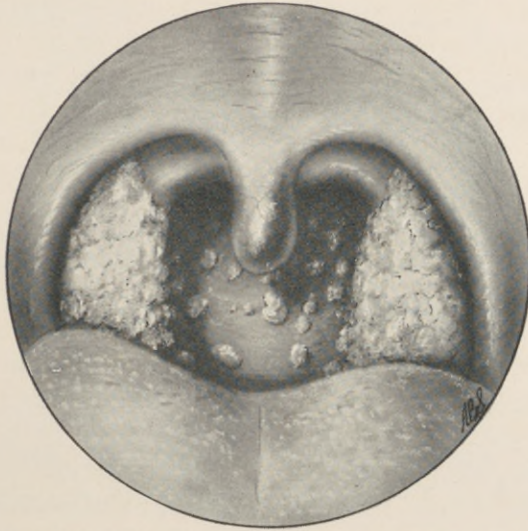


Fig. 17.—Acute follicular tonsillopharyngitis, with hyperplasia of the tonsils.

oid tissue is the seat of the trouble, but a localized acute inflammation of the tonsil, pillars, and uvula is the rule.

The gross changes observed are an injection of the whole area, one side more than the other, soon followed by swelling of the pillars and tonsils, also more marked on one side than the other. The extent of the coagulation necrosis in the lacunae, spoken of as the “white spots” of tonsillitis (Fig. 17), depends on the virulence of the invading organism. This in turn leads to a greater swelling of the tonsil because of the accumulation

in the crypts and hyperemia of the pillars. The uvula becomes less mobile and elongated because of the edema and subsequent stretching of the mucous membrane. Associated with this inflammatory process is a peritonsillitis and a pharyngeal myositis, which accounts for the predominating symptom, pain on swallowing, especially of small amounts of saliva or fluids. Should the peritonsillitis assume borderline manifestations of a peritonsillar abscess, then the uvula and the plica supratonsillaris show the first signs of edema. This is likely to occur in cases where the sinus supratonsillaris of Killian is present, the large superior crypt becoming hidden by the supratonsillar fold. The receding of this process or progress to a peritonsillar abscess, depends upon previous attacks and the presence of a sinus supratonsillaris. In the majority of cases, however, apparent resolution takes place and the first symptom of difficulty in swallowing disappears because of undoubted relaxation of the muscles. The white, flaky material correspondingly disappears. The histopathology in these cases can only be thought of in analogy with inflammation elsewhere.

Treatment.—The symptom of pain as well as the discomfort of dryness is best overcome by the use of warm solutions as gargles, particularly the milder astringents containing a small amount of salicylic acid or wintergreen. As in rhinitis, so here, not too frequent flushing of the throat is advisable because in the secretions covering the inflamed mucous membranes are contained the immune bodies of Nature's defensive forces. Rough handling, as in frequent swabbing and probing, is to be avoided. The value of external applications of warm, moist compresses cannot be overestimated. This is best accomplished by the use of cotton pads the width of the neck, moistened in tepid water, the excess squeezed out, and wrapped around the neck. Another similar compress may be placed under the chin and brought over the ears and after covering with oiled silk still another dry cotton pad is placed and retained by a four-tailed bandage. This type of compress retains the heat for a very long time and is soothing.

Because of the painful swallowing and the importance of plenty of fluids, the use of the head traction method during the effort of swallowing liquids can be very successfully applied.

With the patient sitting up, the one applying traction places his hands over the ears with the tips of the fingers directed toward the temples, the palms over the ears, the thenar and hyperthenar eminence over the mastoid. Traction is then directed upwards. (Fig. 18.) The internal administration of salicylates, elimination and attention to general hygiene should be instituted. The use of urotropin is advised against because of the already present irritation of the renal epithelium in these cases, apart from



Fig. 18.—Head traction method (as demonstrated by Lyman) to aid swallowing.

the possible chemical irritation of the formalin. In the abating period of acute tonsillitis, direct irrigation with a fine stream of a mild antiseptic solution against the tonsillar surface, followed by capillary suction of the small crypts by means of a small trumpet-end capillary tube may be used advantageously (Fig. 11). This should be followed by application of a 2 to 5 per cent silver nitrate solution. The types of gargles recommended are those of oxidizing nature, as potassium chlorate and potassium permanganate.

In the treatment of peritonsillitis bordering on peritonsillar

abscess formation, great caution is to be observed in the danger of the unnecessary procedure of incision, especially incision into the tonsillar tissue. The best treatment for this unilateral swelling and infiltration is the constant application of heat by the use of small amounts of hot water repeatedly to be held in the throat as long as possible. Warm water irrigations may likewise be used.

ACUTE PERITONSILLAR ABSCESS (QUINSY)

Development of the preceding conditions into peritonsillar abscess formation is due to the extension of the process into the loose peritonsillar tissue. In the majority of cases this occurs in the superior and external part of the tonsillar fossa, but the posterior inferior portion is also more or less infiltrated. This

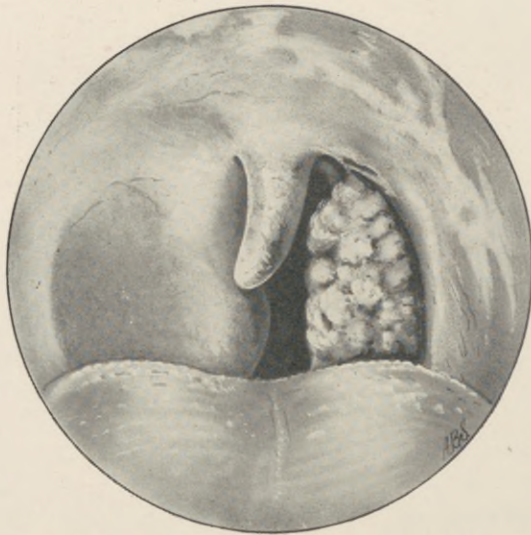


Fig. 19.—Acute peritonsillar abscess with a follicular tonsillitis of the opposite side.

latter area particularly blocks the venous return, giving rise to edema about the uvula which occasionally reaches great proportions. As the case progresses, extension laterally may ensue, with infiltration of the pterygoid muscles, giving rise at the height of the process to "lockjaw."

The tonsil itself in most cases is practically hidden by the swelling of the pillars, but when seen, since this is usually the

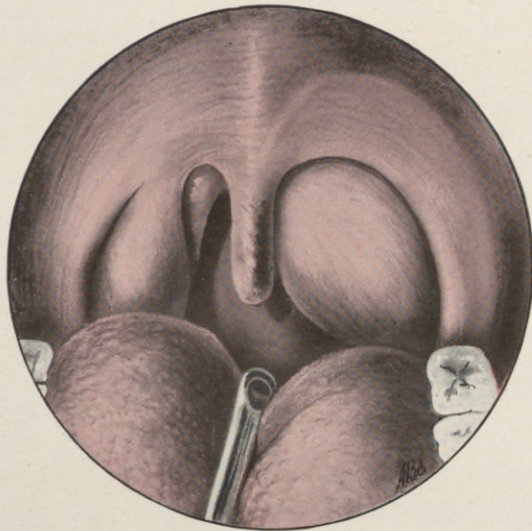


Fig. 20.—Incipient peritonsillitis and peritonsillar abscess formation.

sequence of acute tonsillitis, the lacunae are filled up with exudative material (Fig. 19). Abscess formation is noted usually within forty-eight hours in the region of the superior external portion of the palatoglossal fold. On palpation two points are observed, softness and tenderness (Fig. 20). The posterior pillar when markedly enlarged should always be suspected of containing a sinking abscess, and is of great importance in the prognosis of a possible mediastinitis developing. In the event of the lower anterior pillar becoming very much swollen, including the base of the tongue, a graver prognosis of the possibility of a Ludwig's angina must be considered. When in this connection swelling occurs in the anterior thyroid region, it is almost certain that a sinking abscess has passed along the stylohyoid muscle and ligament, and acute thyroiditis is the impending danger.

Two other unusual locations for the possible rupture of a peritonsillar abscess are into the pterygoid fossa and into the tonsil itself. In the event of its occurrence in the former site the persistent inability to relieve the lockjaw, together with the characteristic neck swelling near the scalenae, simulating a Bezold's mastoid, is observed. In the event of its rupture into the tonsil itself, pus is seen oozing out of the crypts. This is not to be confused with an acute tonsillar abscess.

In recent years attempt has been made to curtail the course of this condition by obtaining drainage by removal of the tonsil. Although contrary to the well-established surgical principle of operating in acute conditions, the result has been uneventful as far as serious consequences are concerned. This method of procedure is not popular. Tonsils removed in this condition leave an operative terrain of muscle exposure—the fascia and aponeurosis coming along with the tonsillar capsule. Dissection in these cases is comparatively easy and is not accompanied by any greater bleeding than usual. Cross sections of tonsils thus removed show nowhere any evidence of abscess formation, and cut with greater ease than the ordinary tonsil removed for chronic disease. Microscopic examination shows an acute inflammatory process.

Treatment.—The treatment follows along the same lines as

that given above, with the addition of promoting suppurating or eventual resolution by heat, external and within the oral cavity. As soon as localization is determined, free incision should be made in line with the arcus palatinus, being certain not to cut into or through the tonsillar capsule. Other methods of producing drainage, such as direct opening into the superior tonsillar fossa by use of a scissors or artery forceps, are quite satisfactory. A particularly gratifying gargle in these cases is composed of warm tea and seltzer, equal parts. Head traction is likewise of value in relieving the pain of swallowing (see Fig. 18). The accumulation of secretions in the mouth is best removed by suction. Warm saline irrigations with the head held forward are effective.

ACUTE TONSILLAR ABSCESS

Acute tonsillar abscess is quite rare and found almost exclusively in the adult. It must always be considered a grave dis-

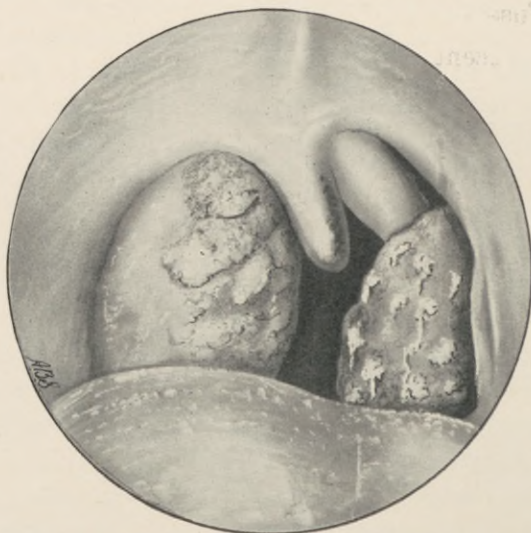


Fig. 21.—Tonsillar abscess with localization and exudate appearing on the surface of the tonsil.

ease. The patient is very septic and not infrequently the temperature rises to 105° F. The process is confined to the tonsil itself, and the surrounding tissues are not greatly involved. The tonsil is large, deeply injected, particularly over the site of

the abscess, is hard to the touch and not painful. It is usually unilateral, although we have had one case with bilateral involvement. We have observed three cases, two being fatal, one of which was incised and the other not. The third case, with recovery, was treated by enucleation of the tonsil. The invading organism was streptococcus viridans. In this latter case the patient gave a history of two previous attacks of Vincent's angina. We have seen one additional case in consultation, in which the tonsillar abscess undoubtedly followed, and was caused by, an unnecessary incision in an acute tonsillitis (Fig. 21).

MEMBRANOUS PHARYNGITIS

The term membranous pharyngitis is a general one and includes any of the following:

1. Diphtheria.
2. Vincent's angina.
3. Lues.
4. Locally induced (escharotics, operations, x-ray and radium).
5. Pseudomembranous.
6. Streptococcic sore throat.

Each condition has its definite pathological as well as bacteriological differentiation, although clinically they may look alike.

Diphtheria

Diphtheritic tonsillopharyngitis, while a disease within the realm of the laryngologist, is really more in the domain of the pediatrician or the internist. The membrane is located principally on the tonsil and extends to the velum. It is adherent to the surface, and bleeding follows its removal. The color depends on the duration; it is at first white and later may become grayish-white or a dirty black. The membrane is fibrinous in character with a tremendous leucocytic infiltration and contains much free blood. The organisms are easily demonstrable in stained specimens, and cultures and smears are definitely diagnostic. The treatment is only too well known; that

is, the early use of antitoxin or toxin-antitoxin mixtures. The inefficiency of local medication is well recognized, and if attempted, only the mildest of antiseptic solutions should be used and great caution should be exercised in their application. In the immediate postdiphtheritic throat a 2 to 5 per cent silver nitrate solution can be applied over the raw area with a camel's hair brush.

Vincent's Angina

In Vincent's angina there is a massive dirty grayish-white exudate in and about the tonsil, the favorite location being at the palatoglossal fold. The exudate lasts but a short time before it sloughs away, taking with it part of the tissue itself, leaving a crater-like ulceration. This in turn becomes covered with a similar membrane and the same change goes on, which may ultimately destroy most of the tonsillar tissue if left untreated. In one case of a bilateral infection we have observed an almost complete tonsillar destruction. Attempt to remove the membrane is futile, and scraping with a dull curet is likewise inefficient. The membrane contains little fibrin but many leucocytes and symbiotic organisms, the spirillum of Vincent and *Bacillus fusiformis*.

The variance of subjective symptoms, both local and general, is quite noteworthy. We have seen cases with extensive involvement of both tonsillar areas without the patient's being conscious of any throat disturbance; on the other hand, we have seen cases wherein but a small plaque was present on the tonsillar surface, associated with tremendous dysphagia and glandular enlargement. As a rule, however, the general symptoms are not associated with any marked degrees of sepsis and the average case is without very marked local or systemic symptoms.

Treatment.—The treatment, apart from the general systemic attention, is directed towards the invading organism, either through local or general means. Among the most satisfactory methods is the use of neoarsphenamine, either intravenously or applied locally in a concentrated aqueous solution or both. Other methods of treatment that have proved satisfactory are:

Tryptoflavin ($\frac{1}{2}$ per cent solution) as a spray to the affected tonsil several times a day, and the use of the same solution as a gargle with 20 drops to a glass of water. Locally 10 per cent solution of salicylic acid in equal parts of alcohol and glycerine, or pyoktanin in 1 per cent solution, applied until an intense blue color is produced, combining with the latter a gargle of potassium chlorate solution, used every two hours. Methylene blue has also been used locally to advantage.

Lues

While luetic manifestations in the main are included in the chronic diseases, acute primary as well as secondary manifestations are not infrequently found. The "plaques mucose" is very frequently mistaken for both of the above-mentioned conditions. It is characterized by the absolute inability to remove the membrane by stripping or even with the curet. Examination can be made only by actual excision of the part, which when properly stained will show the *Spirocheta pallida*, when observed with the dark-field illumination. The serum can be obtained by pressure or with a curet and likewise contains the spirochete, which fact is important, particularly in those cases which have a coexisting Vincent's angina. In the luetic plaques we find lesions of the tongue, cheek, posterior pharyngeal wall and soft palate. Treatment is, of course, directed towards anti-luetic measures while locally strict oral hygiene must be maintained. Potassium chlorate gargle is quite effective.

Locally Induced Membranous Pharyngitis

Any variety of conditions may produce a membranous pharyngitis. Thus we find a definite membrane or exudate in post-operative conditions, after the use of escharotics, and particularly after exposure to the x-ray or radium application. Clinically these cases appear very similar and differential diagnosis can usually be made by means of a careful history. The treatment is individual, depending upon the history, but the point to be borne in mind is to desist from removal of the membrane.

Pseudomembranous Pharyngitis

Pseudomembranous pharyngitis is quite rare in this country and is found principally where rhinoscleroma exists. One case we have observed, in a Swedish-American child brought up in the very best of environment. The second case was observed in an adult with wood alcohol poisoning, but unattended by subjective throat symptoms and in this case was seen a milky white exudate extending from the nose into the pharynx, with no associated inflammation. The membrane can be stripped off very easily and breaks up into a cheesy appearing mass, leaving an apparently normal mucous membrane. Microscopic examination shows it to be practically structureless and a poorly staining homogeneous mass. The membrane tends to recur within twenty-four hours but never as thick as the first time. The most effective gargle we have found to consist of equal parts of peroxide, witch hazel, listerine and alcohol, which are diluted in turn with an equal part of water.

Streptococcic Sore Throat

Streptococcic sore throat is not always associated with membranous formation. As a rule, it is not a local condition *per se*, but rather a local manifestation of a constitutional disturbance, as in scarlet fever, influenza, etc.

HYPOPHARYNGITIS

Any of the preceding conditions may, of course, be found in the hypopharynx. However, we may find more or less localized involvement of the base of the tongue, pyriform fossa, epiglottis or mouth of the esophagus.

1. **Base of the Tongue.**—At the base of the tongue the lingual tonsil is found undergoing acute inflammation, usually as an extension from the mesopharynx and associated with a tonsillitis. Examination shows the swelling appearing to fill up the vallecula and pushing the epiglottis away from the tongue. There is an associated inflammation at the base of the tongue proper, which manifests itself clinically by marked resistance in

any attempt to depress the tongue (Fig. 22). The epiglottis shows a peculiar, stiffened appearance. Treatment is concerned with rest of the part, obtained by giving rectal feedings for forty-eight hours. Hot mouth fillings (not gargles) are soothing. If there is an abscess formation superficial incisions are usually sufficient. As a rule, it is necessary to subsequently remove the lingual tonsil.

2. Edema in the Pyriform Fossa.—Edema in this locality, with or without associated edema of the epiglottis often simu-

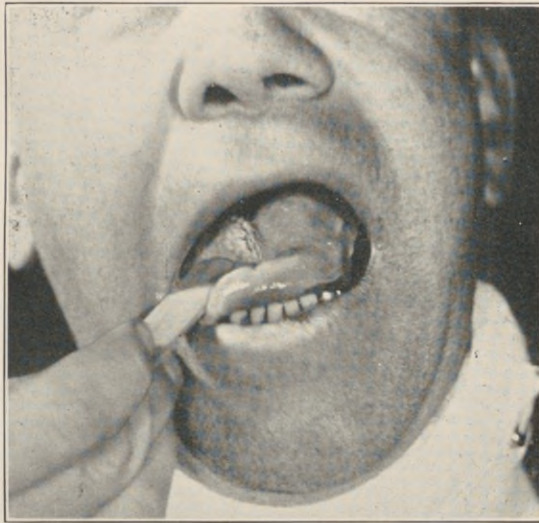

Fig. 22.—Acute inflammation of the lingual tonsil and base of tongue.

lates malignancy. It is always secondary to tonsillitis after recession of the acute symptoms and the neck is usually swollen and tender on the involved side. Treatment consists of watchful waiting and the application of heat externally.

3. Epiglottitis.—Acute conditions involving the epiglottis are discussed in connection with the larynx.

4. Mouth of the Esophagus.—An acute esophagitis in this locality is usually traumatic, following the careless ingestion of foods, excessive stretching secondary to other trauma, such as burns, x-ray or radium. Treatment here, too, consists chiefly in rest of the part.

PHARYNGEAL BLEEDING

While the most frequent bleeding occurs after operative interference, particularly enucleation of the tonsils and adenoids or severe ulcerative processes, there is one particular hypopharyngeal condition that produces the most annoying pharyngeal bleeding and that is varices at the base of the tongue or from the lingual tonsil. This latter condition is usually associated with cardiovascular and renal disease. It suffices to say, however, that the bleeding vessel, if it be an artery, must be grasped and ligated. If however, it occurs at a later period after operation, say a day or so, or if associated with severe ulcerative processes, then a thorough disinfection of the parts, usually by a formalin solution (5%) and, if necessary, the eventual use of a compression clamp and such remedies as horse serum, thromboplastin, calcium lactate and pituitrin are indicated.

CHAPTER IV

ACUTE DISEASES OF THE LARYNX

ACUTE SIMPLE LARYNGITIS

In acute simple laryngitis the ventricular bands are at first injected and somewhat swollen. This is almost immediately followed by hyperemia of the cords, usually posteriorly. The edema of the vocal processes prevents the approximation of the cords and hoarseness results. The epiglottis invariably is without change and as a rule, resolution takes place within several days, but if maltreated, irritated or abused by the use of the voice, the process may go on and assume the pathological changes of the next type.

ACUTE LARYNGITIS, SEVERE TYPE

In the severe type of infection every structure from the epiglottis to the trachea is in a state of violent inflammation. The ventricular bands are not involved to the extent of the cords, but the inflammation undoubtedly extends to the joints and muscles because of the associated pain on any effort of movement, such as speaking, in addition to the complete aphonia. There is an associated laryngeal cough, which is painful, and swallowing likewise is attended with marked discomfort. This condition does not resolve quickly but tends to last several weeks and is frequently complicated by a typical tracheitis, with a mucopurulent and blood-streaked expectoration.

Treatment.—Complete rest of the voice, neither extremes of heat nor cold in foods and drinks, inhalations of medicated vapors, the free use of instillations of warmed oils and liquid petrolatum, and warm, moist compresses externally, are very gratifying. We would here emphasize the avoidance of topical application of the silver preparations. When the acute process has abated, mild astringents, as weak solutions of silver nitrate or zinc sulphate, may be applied either by means of the laryngeal

spray or direct instillation. It is most important that this process be allowed to undergo complete resolution, for if the voice is used strenuously either in speaking or singing before this occurs, a chronic indurative laryngitis is very apt to follow.

DIPHTHERITIC LARYNGITIS

Although diphtheritic laryngitis is a laryngeal condition, it is considered more in the realm of the pediatrician or the general practitioner. In laryngotracheal diphtheria, usually occurring in infants and children, the appearance of increasing

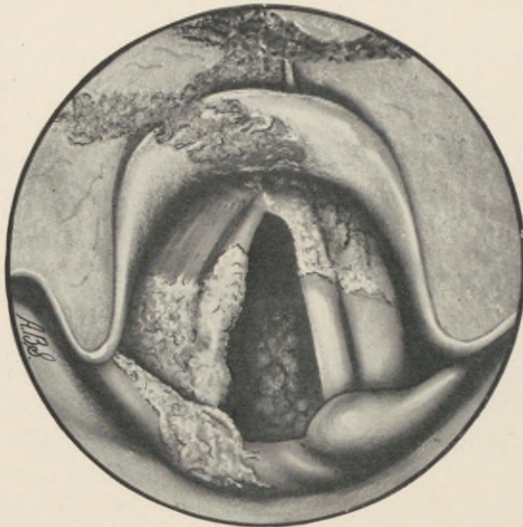

Fig. 23.—Laryngeal diphtheria.

hoarseness, fever and obstructed respiration, inspiratory or expiratory, should be sufficient for a laryngoscopic examination to confirm the diagnosis. The appearance of the larynx is quite characteristic, in addition to the above-mentioned laryngoscopic procedure one is also enabled to make a culture and smear directly from the larynx.

Examination reveals the characteristic catarrhal inflammation of the fauces, and the appearance of a white or grayish-white membrane in the larynx, perhaps extending into the trachea. The important feature of this membrane is that it does not form an integral connection with the mucous surface—it is not incor-

porated nor does it penetrate into the mucous membrane, as in marked contradistinction to the membrane in tonsillopharyngeal diphtheria with membrane formation. The former type of membrane appears on mucous surfaces that are lined with columnar epithelial cells and the surrounding mucous surfaces are swollen, red, and inflamed, and often covered with a mucopurulent secretion (Fig. 23).

The treatment is, of course, antitoxin, but herein we caution the use of too large a dosage in diphtheritic laryngitis whereby too rapid sloughing of the membrane may occur and result in unlooked-for obstruction, necessitating an immediate intubation or tracheotomy. The actual removal of the membrane after passage of the laryngoscope or bronchoscope or the production by its passage of sufficient irritation so that the cast is coughed up and expelled has proved its value in the pioneer work of the late Henry L. Lynch, of New York. Intubation or tracheotomy may at any time be necessary in this condition.

TRAUMA

1. Foreign Bodies.—Foreign bodies in the larynx, until removed or displaced, produce an early inflammatory reaction of injection and swelling of the tissues. They usually lodge between the ventricular bands and the cords. Following dislodgement or removal we may expect resolution unless too severe a trauma has occurred, in which case ulceration is very apt to be superinduced.

2. Cut Throat.—In cut throat a smooth or jagged surface is produced which becomes rapidly infected. Treatment depends upon the nature and extent of the injury.

3. Strangulation is usually associated with a fracture of the thyroid cartilage and the tremendous secondary edema is an outstanding feature.

4. Gunshot Wounds.—The injury is dependent upon the missile and the location, shrapnel wounds being the most destructive.

5. Chemicals.—Either as a manifestation of an occupational disease, as in the inhalation of arsenic, or accidental during treatment of the upper air passages, the larynx may be involved.

In all these conditions attention is called to the secondary changes of adhesive bands and cicatricial stenosis. The treatment depends upon the individual case and any laryngeal condition must be watched for the possible development of secondary edema requiring tracheotomy. It is, therefore, good practice to do a tranquil tracheotomy in order to give the parts a chance to heal. However, intubation for the same condition is not to be overlooked.

6. Burns.—As the result of cautery, by the electrocoagulation method or the galvanocautery, also reactions (sometimes called burns) of radium or x-ray, lead to severe symptoms that may later become chronic. The treatment is wholly expectant.

CHAPTER V

ACUTE DISEASES OF THE TRACHEA

ACUTE TRACHEITIS

Acute tracheitis is usually found in association with acute inflammatory processes involving the respiratory tract by virtue of continuity of structure. In severe cases breathing and coughing are both painful. By the aid of the bronchoscope the mucous membranes, especially in the posterior portion, are seen to be very much thickened and actually in folds. They are highly injected and the mucous glands become hyperactive and soon throw out masses of mucus, which relieves the acute irritative symptoms. Within a short time the tenacious mucus becomes mucopurulent and begins to shed in masses, usually in the morning. There are superficial ulcerations which account for the blood-streaked expectoration and at times the bleeding may be considerable but it is usually mixed with much mucus. The musical râles heard during an attack are due to air tunneling through the thick, mucous secretions which span the trachea. Resolution takes place only to a degree and a patient once having tracheitis is almost sure to have a yearly recurrence, but not always of the same severity.

Treatment.—Absolute rest, expectorant mixtures, Dover's powders in good sized doses, steam and benzoin inhalations, are extremely soothing as soon as the very acute condition has subsided. Unless the blood-streaked expectoration appears, ammoniated mixtures to stimulate excretion are indicated. Almost specific is a change of climate, particularly to the mountains of North Carolina or the pine regions of Florida. Direct application of medicaments to the trachea to dissolve the mucus and subsequent removal (washing and suction), followed by mild astringents, are nicely borne. The free use of petrolatum, by either direct or indirect intratracheal injection, is quite soothing.

FOREIGN BODIES IN THE TRACHEA

Foreign bodies lodging in the trachea are either too large to pass beyond or are caught by irregular projections of the for-

eign body. The lesion is an irritative one like that produced in the larynx. Treatment consists of removal and as a rule little after-treatment is necessary.

INJURIES

1. Cut Throat.—Cut throat in this region is really a transverse tracheotomy. The injury is never of the trachea alone but involves the neighboring structures, particularly the thyroid gland and large neck vessels. Bleeding is severe and frequently fatal, drowning the individual in his own blood. Should the tracheal opening be small and the patient seen early so that the bleeding may be controlled, then a primary closure is usually successful.

2. Missiles.—As in the case of the larynx, shrapnel wounds are the most destructive.

3. Burns.—Radium and x-ray burns in this region are not uncommon.

4. Gas.—During the war, the treatment of gas burns of the respiratory tract was one of the most important and arduous duties of the nose, throat and ear service. Mustard gas particularly, depending on the degree of concentration and the time of exposure, produced intense inflammation of the respiratory tract. Practically the entire tract was affected to varying degrees and the esophagus likewise rarely escaped. The vestibule of the nose very frequently showed more marked involvement than did the remaining intranasal structures.

The pathology of gas burns has been excellently described by Lafayette Page, and his treatment can be by analogy applied in occupational gas injuries of the respiratory tract. He reports that "The pathology of gas burns is similar to that of an escharotic chemical applied to the tissues. If gas sufficient to produce serious effects is inhaled, there results an extreme engorgement of all the vessels and capillaries of the lungs, followed by the outpouring of a serous exudate from the injured bronchial and alveolar linings.

"Necrosis of the bronchial walls and lung tissue resulted in a varying degree from exposure to the gas. These areas were, of

course, promptly invaded by whatever bacteria were present in the respiratory tract, resulting in ragged, foul ulcerations of the larynx, trachea and bronchi, and in multiple abscesses of the lung.

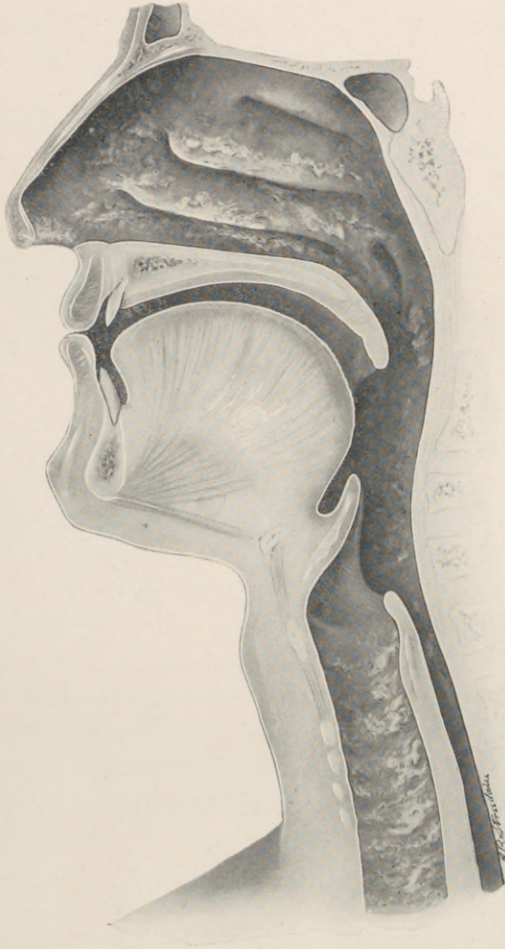


Fig. 24.—Gas burn ulceration. (After Lafayette Page.)

“**Examination.**—In the milder forms of mustard-phosgen poisoning, we found the nasal, laryngeal and bronchial mucosa red, dry or edematous, in the early stages. The general appearance was not unlike an ordinary laryngitis or bronchitis. After a short time, the membranes began to pour out large quantities

of mucus. In many of these cases of mild gassing, the patients recovered in a few days, and, in those patients who had been exposed to a high degree of gas concentration, the mucosa showed an intense hyperemia and dryness at first, followed later by flooding of the air passages with the frothy mucus, often mixed with blood. After two or three days, the burned areas were covered with a fibrinous membrane. These patches were found in the vestibule of the nose, on the turbinates and, in some instances, extending into the accessory sinuses (Fig. 24). The mouth and pharynx seemed to show resistance to the caustic action of the gases, owing, probably, to the character of the epithelial lining; while the larynx, especially the arytenoid region, seemed to be particularly vulnerable. Burns were often found to be deep, with infiltration and edema about the vocal bands, causing aphonia, which occasionally persisted for weeks and months. The tracheal lining was usually burned in irregular patches and in many cases the entire lining of the trachea, extending into the small bronchi, was involved. Edema of the lungs was always present to a greater or less extent when there had been exposure to the mixture of mustard and phosgen in any high degree of concentration. Bronchopneumonia with multiple abscesses was not infrequently present.

“**Treatment.**—Intratracheal medication of guaiacol, menthol and camphor, 5 per cent of each in liquid petrolatum, is clearly indicated in all forms of inflammation of the lower respiratory tract resulting from the caustic action of poison gases. It should be used as early as possible after gassing, for the purpose of relieving the first symptoms of pain and asphyxia and reducing the extent of secondary infection, by facilitating drainage of the trachea and bronchi and rendering the passages as sterile as possible, through the antiseptic properties of the oil solutions.

“This method of treatment shortens the process of suppuration in the secondary stage by aiding the lung reflexes, in expelling the necrotic membranes and products of inflammation, and in healing the ulcerated surfaces, thus relieving the strain on the nerve centers and checking the cough and spasmodic efforts to expel the débris; and thus improving oxidation, diminishing toxic absorption and affording rest to the whole organism.

“Through shortening the healing process, the permanent

damage to the pulmonary mechanism is lessened, and there is less surface denuded of epithelium, less scar formation, less peribronchial thickening and, consequently, less tendency to chronic bronchitis and predisposition to tuberculosis infection."

ACUTE DISEASES OF THE BRONCHI

Acute bronchitis when associated with an acute laryngo-tracheitis is not in the domain of the laryngologist. In an acute suppurative process following foreign body in the bronchus, direct treatment with the bronchoscope is of considerable assistance. Foreign bodies in the bronchi are in the special field of the bronchoscopist, hence, we shall not consider this subject from the pathological viewpoint. For the borderline pathological conditions in the mediastinum and lung the reader is referred to the excellent monographs by Jackson and others.

ACUTE ESOPHAGITIS

This subject is dealt with in the consideration of strictures of the esophagus under chronic diseases, wherein the various etiologic factors are considered. It is well, however, to emphasize the fact of the ease with which the esophagus is traumatized and secondarily infected. The most delicate mucous membrane of the entire gastrointestinal tract and one that stands the least amount of insult is found here. During the war it was noted that the gases, while they irritated the nose, mouth, pharynx, larynx and trachea, would produce marked changes in the mucosa of the esophagus. The sensation, however, appears to be less than in the above-mentioned locations and one may manipulate the esophagus without anesthetization. The well-known toleration to thermic insults, particularly food, emphasizes this point.

CHAPTER VI

ACUTE DISEASES OF THE EAR

OTITIS EXTERNA

- (a) Pinna.
- (b) External Auditory Canal.

(a) Pinna

1. **Frost-bites.**—For this subject we refer the reader to the same condition of the external nose.

2. **Othematoma.**—Othematoma is of both spontaneous and traumatic origin, the former being very rare but we have observed this condition in one case of intense cholangitis accompanied by marked jaundice and in another case unaccounted for. The much more common form is the post-traumatic, occurring in the amateur boxer and prize-fighter. The most frequent location is between the rim and the concha (Fig. 25), although the subcutaneous extravasation does at times extend into the concha and almost occludes the meatus. On palpation the feeling is at first doughy and later of a firmer consistency. If not interfered with and not infected, the process goes to the chronic form of the so-called “tin or cauliflower ear” which is described under the chapter of chronic ear conditions. Treatment of this acute form consists in controlling further bleeding by compression or elastic bandage, the entire pinna being encased in cotton moistened in hot aluminum acetate. To assist absorption of the blood clot Credé or ichthyol ointment is applied externally. Under no circumstances should the ear be incised because infection under the strictest aseptic precautions has not been avoided. This mistake has caused most of the deformed ears of boxers since it has been the common practice in the ring to cut the ear immediately after the hematoma forms.

3. **Acute Perichondritis and Abscess.**—Both of these pathological conditions can and do develop following othematoma. Especially is this true if a puncture or incision is made into it.

Perichondritis, primary, is comparatively rare and usually of traumatic origin or occurs in sequence to a severe frost-bite. Acute perichondritis in most instances is observed in mastoid operation due to rough manipulation of instruments, especially retractors, followed by secondary infection. The mildness of the subjective symptoms, namely, pain, is entirely out of proportion to the severity of the ultimate result—fre-

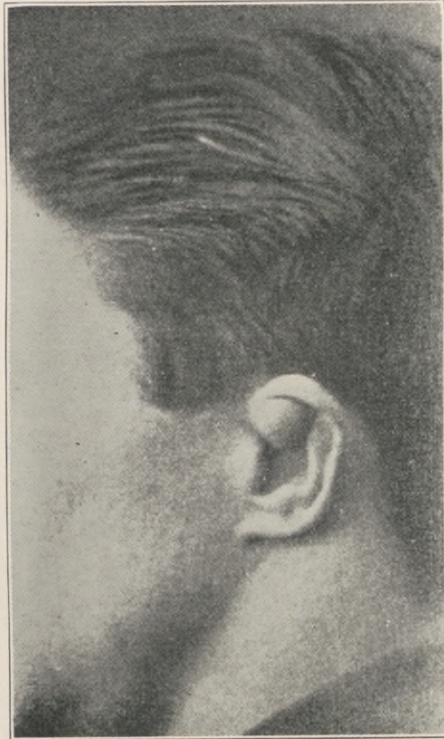


Fig. 25.—Othematoma.

quently complete deformity of the external ear from septic absorption of the cartilage. In perichondritis, the overlying skin is somewhat red and swollen and slightly tender to the touch. As soon as the abscess forms, which is most frequently located between the cartilage and perichondrium, a fluctuating mass is felt. Absorption, systematically, from such an abscess is very slight, therefore, the general reaction is also slight. Regional adenopathy may be present. Aspiration of the contents of the

abscess for diagnosis reveals in most instances a serosanguineous fluid which microscopically shows leucocytes in great abundance and culturally the type of invading organism may be found. Perhaps nowhere in the body is the indication for active interference so urgent as in abscess of the pinna, owing to the danger of cartilage absorption.

Treatment.—In perichondritis without fluid formation, the support of the auricle by a wet aluminum acetate compress and a light bandage, usually suffices. When, however, the fluid forms and this becomes infected, the indication is to open widely by a crucial incision over the most prominent part of the swelling, turning out all of the material, swabbing the cavity with tincture of iodine and readapting the skin and perichondrium to the cartilage. These should be held in contact by dental-compound splints placed in front and back of the auricle, conforming the splints to the natural shape of it, by applying the compound after softening in hot water, further surrounding with cotton, and applying a fairly firm bandage.

4. Burns.—One of the most frequent causes of burns is the use of the hot-water bag, the patient falling asleep while lying on it, thus producing a first degree burn with occasional vesicle formation. Occupational injuries or those produced by fire are next in frequency. These are of more severe type, even to the extent of complete destruction. The end results of such injuries will be considered under chronic diseases of the external ear.

Treatment.—The mild forms of burns usually respond well to such emollients as stearate of zinc ointment. In the more severe types where pain may be an important symptom, a sterile mixture of lime water and linseed oil, thoroughly mixed, and cotton saturated in the mixture applied locally has proved very efficacious. Other treatment is directed toward the etiologic factor and extent of the trauma.

5. Dermatitis.—Various forms of acute inflammation of the skin of the auricle usually occur secondarily or are associated with similar processes about the external auditory canal or the face. In the course of an acute otitis media suppurativa, in which the discharge is highly alkaline, and of a streptococcic variety, we find very often the concha and lobule in the state of acute dermatitis. In connection with the mastoid operation

not infrequently an erysipeloid condition may be observed. The true erysipelas we have observed a number of times, primarily about the auricle, and it must be distinguished from the chemical dermatitis, secondary to the use of iodoform medication.

Treatment of these various types mentioned consists mainly of the treatment of the cause, but the accepted lotions and ointments advised by dermatologists have given us the best results.

(b) Auditory Canal—External

1. **Otitis Externa Furunculosa** is the most frequent type of acute disease met with in the external canal, unless it be the ceruminous plug which can scarcely be designated as a disease. The furuncle is the result of the infection of one of the sebaceous glands close to the external auditory meatus where they are in greatest abundance. Such an infectious process is promoted by the mechanical irritation in response to the first symptom, that of itching. If examination is made during this early period, one may find at the site of the infected gland a small dark point surrounded by a light reddish area. The connective tissue surrounding the gland is very rapidly converted into acute inflammation, giving the usual edematous swelling which is so extremely painful owing to the traction on the periosteum. The coagulation necrosis in furuncle formation is usually brought about within twelve hours, showing the white-pointing of the abscess. Any surgical interference, such as puncture, before this point appears, leads to severe complications. The multiple infections of these sebaceous glands, which occur by one ruptured abscess infecting the other, constitute one of the most characteristic conditions of this disease. The cardinal diagnostic point, besides those observed by inspection, is the pain produced on lifting the auricle. The hearing is seldom, if ever, affected. The glands at the angle of the jaw, as well as the retroauricular glands, are at times enlarged and tender, leading in some instances to a faulty diagnosis of mastoiditis. The differential diagnosis from boils in the canal, associated with diabetes, is important to remember.

Treatment.—The initial stage described above is very important for early diagnosis and will be productive of an abortive

eure. A cotton wad, rolled firmly, of a size slightly larger than that of a normal external canal, is dipped into pure alcohol and inserted into the canal. Every fifteen minutes thereafter, for an hour or two, this cotton is resaturated by means of a medicine dropper. One will be gratified, in many instances, to find the process aborted in twenty-four hours. When the furuncle has formed, but before it is ripe, one may promote either resolution or abscess formation by the use of hot Billroth solution dressing. This solution consists of lead acetate (1), alum (10), and water (100) parts, the lead and alum being added to the water while boiling. The solution must be shaken before using because of sedimentation. A strip of narrow gauze is saturated in the solution and the canal is packed. Thin layers of cotton are also saturated in this solution and packed in front and back of the auricle and mastoid. This is covered by a piece of oil silk, a large dry pad, a bandage. If necessary the procedure is repeated until the resolution or abscess formation occurs. Lying on a hot water bag will aid the action of this moist dressing. If resolution has taken place, an ointment, sterile vaseline, is applied over the macerated area. If an abscess has developed, an incision is made, but cutting into the periosteum should be avoided unless one is certain that it, too, is involved. After incision care must be exercised to avoid spreading the pus, therefore mopping or swabbing should not be practiced, but the wound should be let alone with only a light dressing. Lying on a hot water bag will promote further discharge, so that on the following day by gentle pressure the so-called "core" or coagulated necrotic mass can usually be expressed. The after-treatment consists of the use of mild ointments, such as ammoniated mercury (2 per cent) or sterile vaseline.

2. Otitis Externa Diffusa is most frequently observed secondarily to a chronic middle ear disease, although in recent years in communities where beach-bathing has become very popular in the hot summer days, many cases of acute otitis externa diffusa have been observed. The cause in this latter condition is believed to be maceration of the skin from dehydration with secondary infection, possibly from manipulation. The disease is popularly termed "tank ear," the belief being that the water is contaminated by the masses of bathers. Treatment consists

of a moist dressing as already described and later insertion of a strip of gauze saturated in 10 per cent ichthyol in glycerine.

3. Otitis Externa Traumatica.—Probably the most frequent cause of trauma of the external canal lies in the faulty attempt at removal of ceruminal plugs. The use of hair pins, tooth picks, pencils, and the specially devised ear spoons for laymen's use, in attempting to remove detritus or dry particles of cerumen is responsible for this affection. Attempt to incise the drum head without the aid of the head mirror or by those not skilled in this work is another cause. Instillations of caustics and irritants may also produce such a condition. A unique case of severe trauma is that of a man who poured pure carbolic acid into both his ears in an attempt to avoid being drafted into the service during the late war. The resultant injury to the

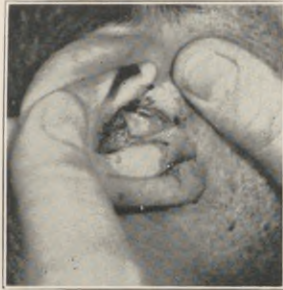

Fig. 26.—Trauma of external auditory meatus and canal following self-infliction with saturated solution of carbolic acid.

canal can be imagined. Fig. 26 shows the resultant trauma of the external meatus and the concha six weeks after the injury. His hearing was practically normal, although the drum was considerably destroyed. Treatment is principally by disinfection to avoid secondary infection and individual as to cause.

4. Foreign Bodies in the ear are found most frequently in children, and pebbles and sand are the commonest objects introduced; older children insert little balls of paper. One of the most unique forms of foreign body was observed by us in the case of a man aged thirty-five, who was being treated for an uncontrollable salivation. In our routine examination we discovered a dark object in the fundus of each ear, not unlike a ceruminal plug. After several days of attempted removal by

washing, mechanical procedures, etc., we discovered a smooth round object, which slipped away from forceps. Finally, we were successful in rolling out, by the aid of a fine hook, a small cherry pit; the same was done on the opposite side. The patient was as greatly surprised as we were, as he could not remember ever having inserted these. It is also interesting to note that there were never any symptoms produced from the ears. The excessive salivation cleared up entirely following this removal. The explanation was a parotid irritation. The treatment of foreign bodies in the ears consists in their removal by washing or mechanical procedure.

5. Animal Foreign Bodies.—Small flies and bed-bugs are the commonest types found which invade the external canal. Personal experience with one such case will teach a great lesson, for the agony produced by the movements of such a living thing, especially when it moves across the drum membrane, cannot be described. Inspection will reveal the culprit and its destruction is the most important thought at the time, preferably by introducing a drop of chloroform and then washing it out. The immediate relief is so gratifying that one will congratulate himself upon the result. We have never seen a patient who has had such an experience who has not afterwards shown evidence of neurosis as though he had suffered from a great shock.

ACUTE OSTIUM TUBITIS

Acute ostium tubitis has been discussed under the acute diseases of the pharynx.

ACUTE OTITIS MEDIA

In acute otitis media the most frequent affection is of the milder form, in which the inflammatory process extending from the tube to the middle ear consists of engorgement and swelling of the mucous membrane of the tube and the modified mucous or serous membrane of the middle ear. The greatest opportunity for swelling of this modified mucous membrane is in that portion lining the membrana tympani because of its resiliency, and particularly that lining Shrapnell's portion (Fig. 27 A).

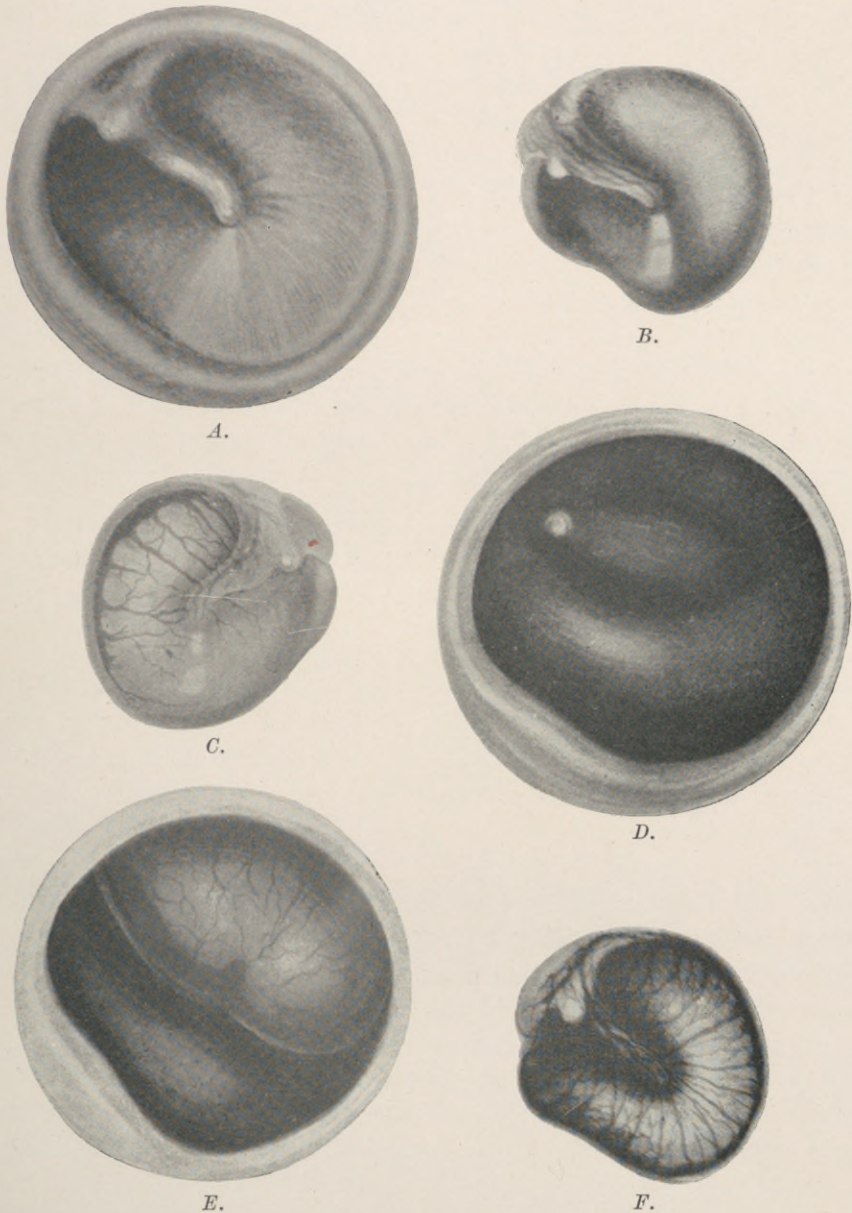


Fig. 27.—Tympanic membranes in acute inflammation of the middle ear. *A.* Normal tympanic membrane. *B.* Earliest manifestation of acute inflammation of middle ear. *C.* Further progress in the acute inflammation of the tympanic membrane. *D.* Marked enlargement of the tympanic membrane with bulging. *E.* More advanced process with excessive bulging and exudate showing through. *F.* Marked injection of the tympanic membrane and the middle ear cavity filled with pus, but no bulging. (After Preysing.)

The anatomical configuration of the membrana tympani plays an important rôle in the pathologic changes that occur. Owing to the close proximity of the upper and posterior portion of the promontory of the cochlea to the junction of Shrapnell's membrane with the membrana tensa and the extreme tympanic limit of the external wall of the aditus, the tympanic cavity in an acute process is divided into two distinct parts when the swollen membranes covering the above regions come in contact. This contact will in most instances cause retention to develop in the upper portion of the middle ear; i. e., the attic and inner portion of the aditus, giving rise to swelling of the drum in its upper posterior portion (Figs. 27 *B* and *C*). If the process is one of greater virulence, so that the inflammatory reactionary changes are accompanied by transudation and symptoms of tension develop, in which case the entire drum shows marked engorgement, together with the above-mentioned swelling of the upper posterior part, actually bulging (Figs. 27 *D* and *E*). In these virulent processes the inflammatory changes extend entirely throughout the mastoid cellular system. At this juncture is the turning point as to whether an acute otitis media resolves, with or without treatment, requires interference or progresses further (Fig. 27 *F*). Interference depends equally as much on the general systemic reaction as on local manifestations. The x-ray picture, so frequently employed to indicate the degree of pathologic change, is not to be relied upon, since every acute case will show cloudiness of the mastoid cells. Besides, one must not forget that the mastoid might have had a previous infection or may be of the type referred to by Wittmaack as an incomplete or arrested pneumatisized mastoid.

Should interference be necessary, which is the free incision of the drum, then the ensuing pathologic change is the marked relaxation of the inflamed membrane with the accompanying pulsation of the hyperemic vessels and the outpouring of large quantities of serosanguineous fluid mixed with varying amounts of mucus. The fluid obtained after incision of the drum membrane, depends usually on the type of the invading organism, so that in the hemolytic streptococcic infection it will be principally serosanguineous, while in the pneumococcic or influenzal or streptococcus mucosus infection, the fluid will be thicker in

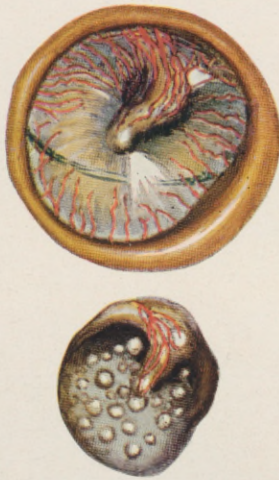

Fig. 27.

(g) Retrogression of acute middle ear process showing a line of the neveau of exudate.

(h) Same as the above after catheterization, with scattered bubbles showing through the membrane.

consistency because of the additional mucus from the nose and tube.

The discharge is rapidly changed in character. The blood soon disappears except in the hemolytic streptococic or the epidemic influenzal infection, when the bloody discharge is of considerable duration. This point is important in judging the pathologic process that is going on. The change in the discharge is due to a secondary infection that occurs from the canal, which is unavoidable, as well as through changes that may take place in the invading organisms, according to the transmutation theory advanced by Rosenow. We have obtained




Fig. 28.—Herniation of the tympanic membranes in severe forms of acute otitis media suppurativa. (After Preysing.)

cultures from the ear, immediately after incision, of typical hemolytic streptococci, and on the following day have obtained pure cultures of pneumococci.

The changes in the opening of the drum are of the utmost importance and in the main are due to the changes going on in the middle ear. So marked is the relaxation of the drum in some of these cases as to produce complete eversion of the lips of the incision, and the swollen membrane herniates (Figs. 28 *A* to *E*). Owing to the closure of the perforation, on account of eversion and subsequent retention, combined with further relaxation

of the tympanic membrane, the nipple formation with occasionally but a minute opening in the center becomes very noticeable (Fig. 29). The lack of understanding of this pathologic change has led to the therapeutic abuse of repeated re-incisions of this portion with no result other than the stirring up of an already acute process into a more violent one, and early mastoid destruction. We have observed one case in which an incision had been repeated fourteen times in thirty-six hours, because of failure to recognize this type of nipple perforation. While it is true that reopening a perforation which is insufficient is a distinct indication, yet it is comparatively rare that it is necessary.

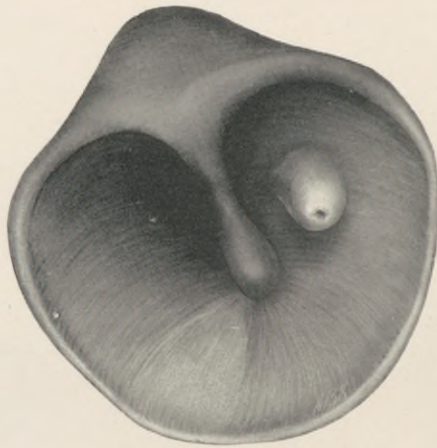

Fig. 29.—Nipple perforation.

A frequent additional finding is the presence of blisters on the drum extending to the external canal (frontispiece). This is found particularly in influenzal and virulent streptococcic infections. The blebs contain a serous or serosanguineous fluid and the presence of the invading organism can readily be demonstrated. There is usually marked pain in this condition and many a fairly normal tympanic cavity is complicated by the opening of the blister into the tympanic cavity because it is mistaken for a true bulging of the drum. The puncturing of the blisters is invariably sufficient to relieve the condition.

Treatment.—The principles of treatment of uncomplicated acute otitis media, before perforation takes place, are based on the earliest ventilation of the middle ear cavity. Attention to

the nasopharynx and to the opening of the tube is of the utmost importance. Depletion, both by local and general measures, should be adopted. One of our most efficacious measures is the use of moist dressings by loosely filling the external canal with gauze saturated in warm Billroth solution as already described under otitis externa. This is left on for from two to four hours or more and repeated. The pain can be controlled by pyramidon or the salicylate mixtures. It is important to remember from the aforesaid pathology when resolution has taken place that there are contact points both in the tube and the middle ear that should be prevented from organization by early inflation. *However, nothing is more disastrous than inflation while the process is still acute.*

As to the management of cases where either a spontaneous or operative perforation of the drum has taken place, treatment depends upon the capillary dry gauze wick drainage introduced to the perforation and placed loosely in the canal. Nowhere else in the body have we a natural drainage tube where gauze may be used as a drain such as exists in the external canal. Early, when the discharge is profuse it may be necessary to replace the drain several times a day. Acute cases should, therefore, be hospitalized. In infants when this treatment is not practical, capillary suction is preferred, and can be well carried out in the home (Fig. 11).

We seldom use irrigation unless it is necessary to get rid of unusually thick or viscid discharge, and then only the mildest of syringing, using hypotonic solutions. We are of the opinion that the usual continuous boric acid irrigation produces some damage to the vitality of the cells.

In the event of the presence of a nipple perforation, the most satisfactory means of treatment is to fill the canal with the following solution, which is allowed to remain for one hour, and which is repeated every two hours for a day.

Tincture of iodine, ℥	15
Phenol ℥	15
Alcohol drams	4
Distilled water to oz.	1

In the interim, gauze wick drainage is carried on, being certain that the gauze wick comes in contact with the perforation.

Should the nipple be very large and retention marked, it may be practically excised by the aid of Hartman's ear punch forceps, but under no circumstances should another portion of the drum be incised.

ACUTE MASTOIDITIS

Analogous to the condition in the nose which is spoken of as a rhinosinitis, a similar combined condition exists in the middle ear, a tubo-tympano-mastoiditis, so that in every case where the symptoms of tension are manifest the complete mastoid chain will be affected, at least the roentgenogram will show evidence of ray obstruction or cloudiness. The changes in the modified mucous membrane of the mastoid cells, as well as in the bony partitions, depend almost entirely upon the type of infection. This is particularly evidenced when the causative organism is the *Streptococcus mucosus capsulatus* or the *Streptococcus hemolyticus*, associated with the influenzal bacillus. It is of great practical value to know that these changes within the mastoid may go on to extensive destruction without symptoms of pain referable to the mastoid. This absence of pain has deceived many an otologist who has failed to recognize indications for an early operation which would undoubtedly have saved the patient from horrible complications.

Pathologic changes occurring during an attack of mastoid disease are determined by several factors, including the anatomy of the temporal bone involved, the causative organism, as mentioned above, the secondary infection, the resistance of the patient, as well as the treatment instituted. We are able to divide this process into three great classes, depending primarily upon the method of its extension, i e.:

1. *Cell route, or confluent type*, in which all the cells are practically simultaneously affected. The swelling of the lining membrane breaks down the bony partitions, resulting in a coalescing mastoiditis.

2. *Vascular route, or the osteophlebitic mastoiditis* of Grünert, in which the blockage of the veins with the concomitant bony changes is conspicuous, but with little or no exudate within the cells themselves, except it be a specific hemorrhagic type.

3. *Acute exacerbation* of a chronic mastoiditis, which will be taken up under chronic diseases.

Cell Route Infection

Gross Changes.—In this type an external fistula is usually found over the antrum or near the tip (Fig. 30) with consider-

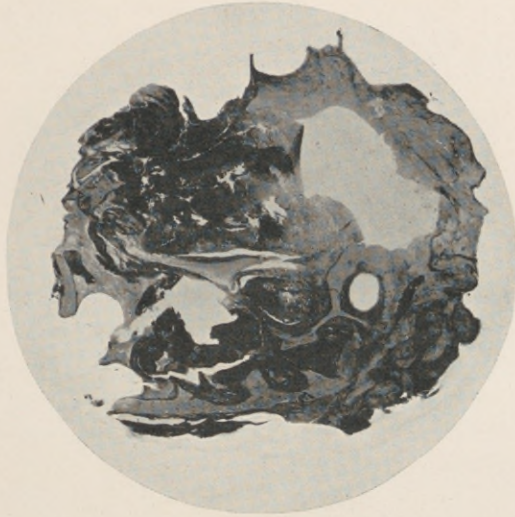

Fig. 30.—Cortex of mastoid in acute mastoiditis, showing necrosis and fistulous tract.

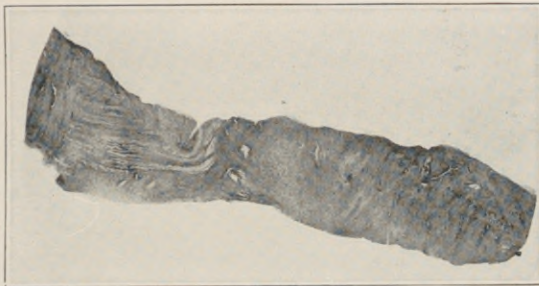


Fig. 31.—Thickened periosteum in acute mastoiditis.

able infiltration of the periosteum (Fig. 31). The bone bleeds easily and at times appears darker, due to the edematous and engorged membranes under the thin cortex. As soon as the latter is removed, a fair quantity of pus escapes, usually under tension, depending on the presence or absence of a fistula

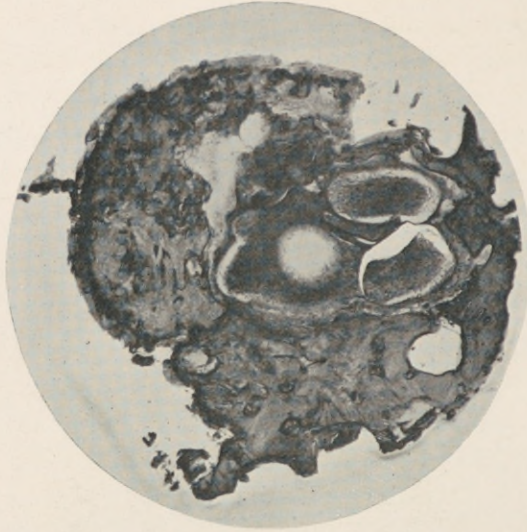


Fig. 32.—Acute mastoiditis, cell route infection, showing cortex of mastoid and adjoining cells. These cells are noticed to be coalescing and are filled with pus and edematous lining membrane. The cortex itself shows little evidence of any destructive process, but the underlying bone is necrotic although a small portion is fairly well preserved yet much inflamed.

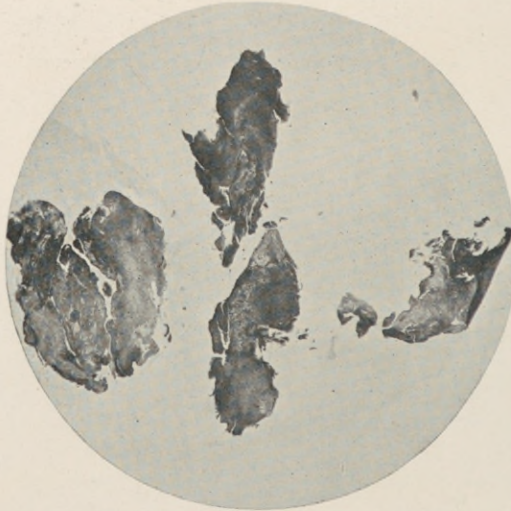

Fig. 33.—Curettements from the interior of the mastoid in acute mastoiditis, cell route infection, showing the lining membrane of the cells thickened and infiltrated with leucocytes. The bone is necrotic, probably beyond possibility of repair.

and the type of microorganism present. The bleeding is usually free and the lining membrane may protrude through the opening made, which may give the impression that the sinus has been exposed. The intercellular septa are usually broken down either over the antral region or the tip, and at times over both regions. This emphasizes the necessity of a complete exenteration. Not infrequently the lateral sinus, digastric fossa or the dura are exposed.

Histopathology.—The early changes are those of simple inflammation. The blood vessels of the lining mucous membrane are dilated; the membrane thickened, edematous and infiltrated

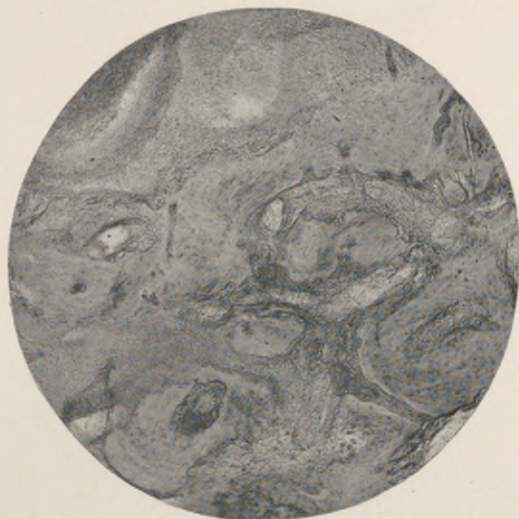

Fig. 34.—Acute mastoiditis, cell route invasion. Practically every cell is filled with edematous membrane and pus. There is cloudy swelling of the bone but no necrosis. The intercellular septae are preserved.

with leucocytes. The exudation, at first serous, later purulent, into the cells, together with the swollen membrane, usually obliterates the cell (Fig. 32).

The lining membrane may be detached from the bony walls and the bone become necrotic (Fig. 33); the bony inner surface of the cells eroded in all directions eccentrically—the cavities thus become enlarged, coalescing and filling with pus (Figs. 34 and 35). Multinuclear giant cells are seen. As the process extends the periosteum shows signs of acute inflammation, while

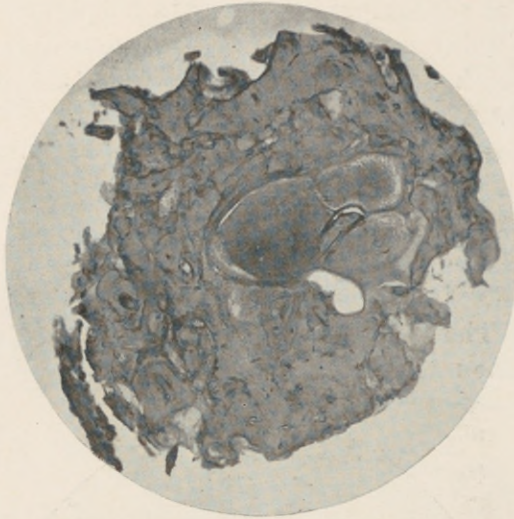

Fig. 35.—Acute mastoiditis, cell route infection. Practically the same changes as in Fig. 34, only more advanced in the coalescence of cells filled with pyogenic material.

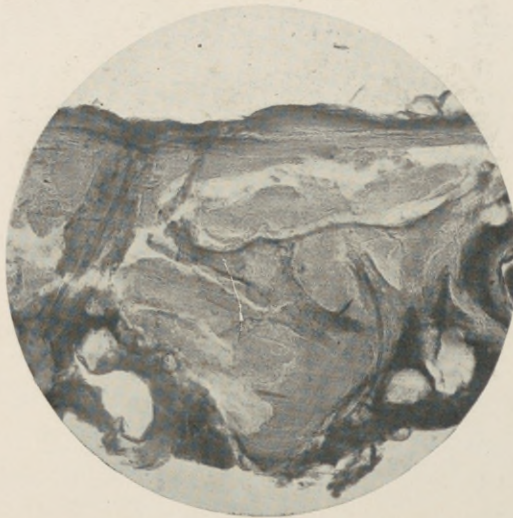

Fig. 36.—Mastoid chip in acute mastoiditis, cell route infection, showing necrosing osteitis.

the changes in the bone may go on to further destruction or repair (Fig. 36). In the former case, the membrane being destroyed and the nutrition of the bone being impaired, pieces of bone are cast off as sequestra, leaving in reality an abscess

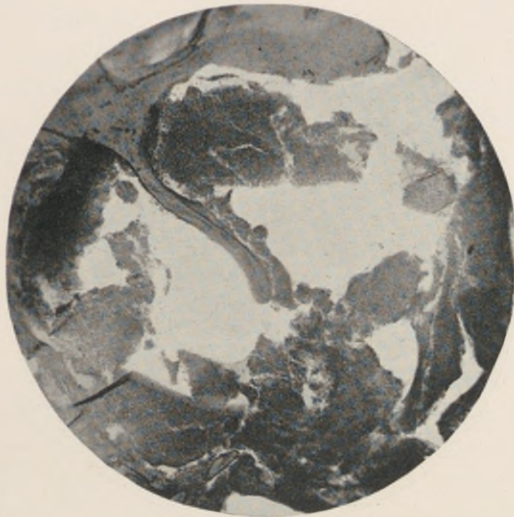

Fig. 37.—Acute mastoiditis, cell route invasion. Bone necrosis markedly advanced and abscess formation is noted. Only a sliver of bone is left here and there.

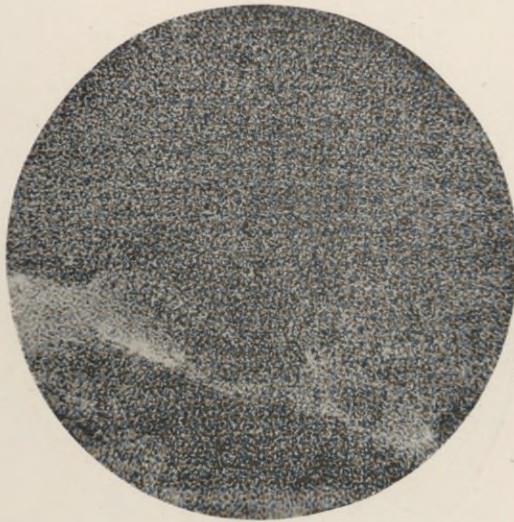


Fig. 38.—Acute mastoiditis, with curettage showing nothing but abscess formation.

cavity with only a sliver of bone here and there (Figs. 37 and 38). During the reparative process as soon as drainage is accomplished, new bone formation takes place, the osteoblasts being at the extreme periphery of the involved area (Figs. 39 and 40). A sclerotic area, then, replaces the former air cells.

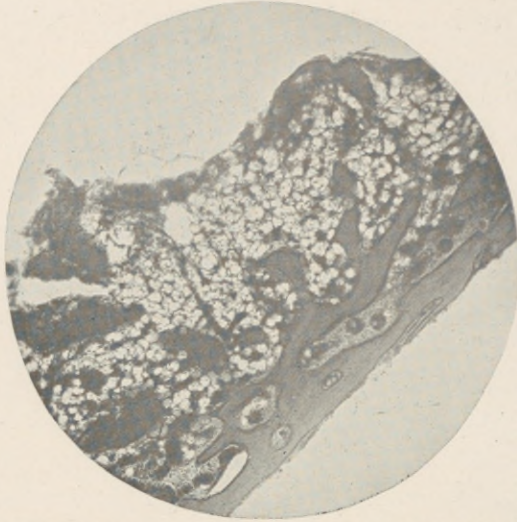

Fig. 39.—Reparative osteitis in a mastoid chip removed in a reoperative case of chronic suppurative otitis media. At the margin are seen fairly healthy trabeculae of bone from which young osteogenic structures loosely arranged with a large number of small capillary vessels are in evidence. The new bone formation is from the cortical region rather than from the interior of the mastoid terrain.

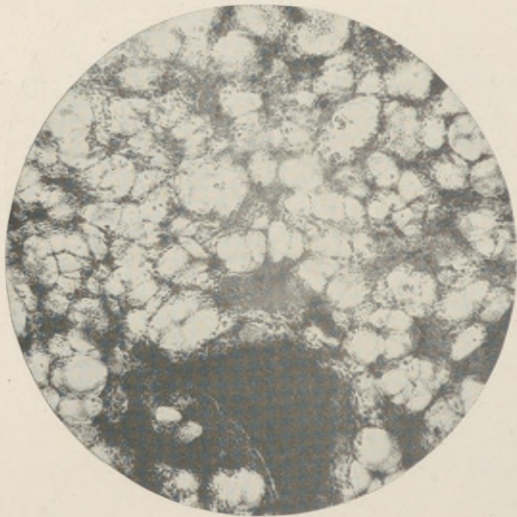


Fig. 40.—Same as Fig. 39, only high power.

It is to be noted that the dura itself and the bony walls of the sinus, usually are more resistant to the spread of the infectious process. It is also to be noted that necrotic bone present is

dissolved with greater difficulty and much more slowly than other tissues, and acts as a foreign body. This is also true of bone dust if the burr is used, or chips of bone if the chisel is employed which, if allowed to remain in the operative territory retard recovery because of the slow dissolving action of the endothelial leucocytes (foreign body, giant cells or osteoclasts). In our clinic, where the burr is used almost exclusively, after the mastoid cells are exenterated if any evidence of bone dust remains, the wound is washed out with normal saline solution (gravity method). Furthermore, in the repair of bone the fibroblasts (which produce the osteoid material) are derived, we believe, from the periosteum. This fact is made use of in the closure of the mastoid wound when the periosteum is brought together, having been at the beginning of the operation reflected carefully. The healing process is also assisted by the placing of the drain through a posterior stab wound instead of through the mastoid wound proper.

Vascular Route Infection

In this type we find the tissues overlying the cortex very little changed and so we are less apt to find on external examination any redness or edema over the mastoid. The tissues bleed very little and have otherwise a fairly normal appearance. On opening the mastoid we find the bone, however, very red and there is little or no pus escaping. The cells are fairly well preserved and their lining membrane is not very edematous, in contradistinction to the cell route type of infection. The preserved intercellular septa on close inspection show the marked engorgement spoken of above. Only in the later stage in which a possible secondary infection takes place, can one find any exposures of the lateral sinus, although the same may be exposed to the infection. In this regard we find it advisable not to expose the sinus unless definite indications clinically make it advisable, as this in itself may light up an infection about or within the sinus wall, which otherwise may be dormant. It is this form of mastoiditis which has the greatest percentage of perisinus abscesses and sinus thrombosis developing, owing to extension within the venous channels. The same is true as regards the erosion of the other vital areas, such as the dura of

the cerebrum or cerebellum, the labyrinth, the facial canal, or the digastric fossa.

Histopathology.—The cells are seen well preserved and empty. The bone is highly inflamed and minute necrotic areas all through the section are in evidence. Thrombi in the venous

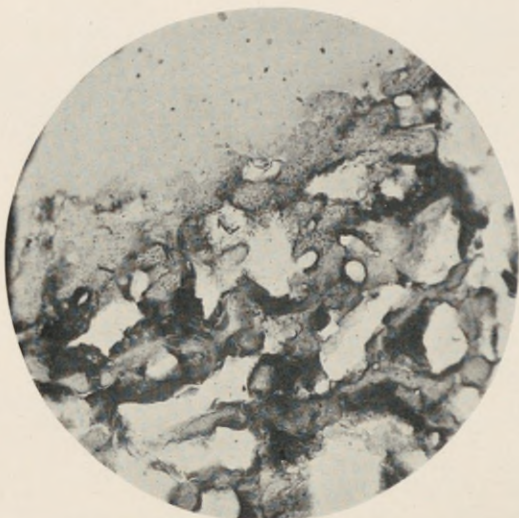


Fig. 41.—Acute mastoiditis, vascular or osteophlebitic route. The cells are well preserved and empty. The bone is highly inflamed, with minute, necrotic spots throughout the section. Some of the vessels are definitely thrombotic.

channels can be distinguished at times (Fig. 41). In streptococcal infections the mastoid cells frequently contain serosanguineous fluid.

Application

Cell Route Type.—The knowledge of the pathologic changes is of great value, particularly in regard to prognosis and the future course of the reparative process. If we examine either grossly or microscopically chips of bone and determine the type to be of the confluent variety, the chances are favorable for a comparatively short course. We must, however, take into consideration the general condition of the patient and the preexisting anatomical formation of the mastoid as to its complete, partial or arrested pneumatization, in addition to the fact that the operative and postoperative procedures were technically correct.

The earlier the cell route type case is operated upon the quicker is the recovery, the more prompt is restoration of hearing and the less marked is the destruction. In many cases the aural discharge will completely cease before the end of the fifth day and drainage from the mastoid wound can be removed without any further treatment. The question of operation must also be considered if only for the future preservation of hearing.

Vascular Route Type.—The value of the knowledge of the pathology in this type lies particularly in the correlation of symptoms to the degree of changes taking place. The x-ray may show, even in markedly affected mastoids, practically normal cell nests with the cellular outlines well preserved. Again, there may be little mastoid tenderness, the hearing well preserved, but marked general symptoms. If one is fortunate enough to open the drum in these cases under the strictest aseptic conditions and obtain a pure culture of *Streptococcus mucosus capsulatus* or *Streptococcus hemolyticus*, then corroborating blood cultures will convince one of the necessity for an early operation. It is to be noted, however, that one may frequently find a positive blood culture in this type of mastoiditis without a sinus thrombosis being present. It is also to be noted that in this type of mastoiditis one not infrequently finds upon examination a fairly normal drum.

Atypical Types of Acute Mastoiditis

Periostitis with or without Subperiosteal Abscess.—In infants and children periostitis and cellulitis, with or without abscess formation, is not infrequent. It is well recognized as brought out by Luc that a dehiscence or nonunion exists at the squamo-mastoidal suture, with direct continuity to the middle ear. This may exist without either a perforation or any symptoms from the middle ear. It must be borne in mind that the conception that the mastoid of an infant contains no mastoid cells, is erroneous. Wilde's incision in these cases is not sufficient. The cortex should be opened and a complete exenteration performed irrespective of the gross appearance of the cortex on its first exposure. Some of these fissures or dehiscences in the mastoid may extend well over the attic and at times pus will burrow anteriorly towards the glenoid fossa, with corresponding swell-

ing in the preparotid region. This is most significant, as the mastoid in these cases should be opened at the earliest possible moment to prevent the occurrence of an ankylosis of the mandibular joint.

Squamozygomatic Mastoiditis.—This term is applied in cases where large cells extend into the squamous and zygomatic portions of the temporal bone and often to the greater wing of the sphenoid. Aside from the symptom of swelling over the zygoma without tenderness elsewhere, and restricted, painful motion of the jaw, the *tic douloureux* is the most significant feature. Delay in operative procedure may mean an extension of the destructive processes to the subdural space along the anterior portion of the temporal bone and the resulting appearance of a semi-Gradenigo syndrome (abducens paralysis and trigeminal irritation).

Koerner Cell Infection.—When these cells are particularly large and extensive, and involve the cells in the petrous portion surrounding the vestibule, cochlea, bulb and dura about the Gasserian ganglion and the sixth nerve, a complete Gradenigo syndrome with jugular bulb labyrinthine symptoms may develop.

Bezold's Mastoid.—This term is applied to that type of mastoiditis in which there is a fistula from the internal and anterior portion of the mastoid tip, anterior to the digastric fissure, together with a sinking abscess formation. This dissecting abscess may extend into the posterior mediastinum. Aside from the swelling in the upper posterior triangle between the tip of the mastoid and the angle of the jaw, is the early development of a peripheral facial paralysis. The pain is usually referred to the lower teeth and radiates towards the temple, being due to pressure on the auriculotemporal and inferior dental branch of the fifth nerve.

We must here keep in mind a pseudo-Bezold mastoid that is produced during an operative procedure and is the result of cutting the fibers of the sternomastoid at their origin which allows the infection to spread into the neck. Here, too, might be mentioned a similar process due to cutting of the fibers of the temporal muscle and the deep temporal vein which might produce symptoms about the eyelids mistaken for a cavernous sinus thrombosis.

Differential Diagnosis.—Herpes zoster oticus and sphenopalatine irritation may both produce symptoms of marked otalgia simulating a mastoid involvement. A secondary cellulitis from an otitis externa, as found in the bather's "tank ear," in which there is pain and swelling over the mastoid and tragus, likewise may simulate a mastoid involvement. A broken down retroauricular gland, frequently found in infants and children is not infrequently confused with a mastoiditis.

CHAPTER VII

ACUTE COMPLICATIONS OF MASTOIDITIS

The complications of acute mastoiditis are, as a rule, practically preventable and the intimate knowledge of the before mentioned pathology should enable one to minimize the possibility of their occurrence. For example, knowing that the osteophlebitic type of mastoiditis predisposes to sinus thrombosis and that by reckless or unnecessary exposure of the sinus a thrombus may actually be produced, unusual care should therefore be taken not to expose it. Likewise, it should be borne in mind that a mastoiditis of this type if insufficiently operated upon, or not operated early enough, a sinus thrombosis is apt to develop. One must, therefore, be on guard for the earliest appearance of any symptoms indicating its onset. Many times before the actual toxic reaction, septic temperature and chills, one can by repeated blood cultures anticipate much trouble. On the other hand, we must suspect in the cell route type of infection, where the coalescing osteal changes are marked, with destruction of any part of the tegmen, the possibility of a dissecting extradural abscess. The bacteriologic findings are likewise of importance in the assumption of the usual pathologic changes associated with the various types of organisms, but neither the bacteriologic nor the blood cultural studies are yet of positive practical value. The acute complications usually found are:

1. Acute labyrinthitis, serous or purulent.
2. Perisinus abscess.
3. Sinus thrombosis.
4. Extradural abscess.
5. Intradural abscess.
6. Meningitis.
7. Chronic mastoiditis.
8. Facial paralysis.

ACUTE LABYRINTHITIS

Labyrinthitis complicating an acute mastoiditis usually follows the osteophlebitic type and rarely the cell route type of infection, wherein the middle ear and antrum are markedly distended, producing by pressure disturbance transmitted through the round or oval window.

Localized serous labyrinthitis is produced when there is an osteitis in the region of the horizontal semicircular canal or Trautmann's triangle. An irritation therefore results and a labyrinthitis is manifested clinically by vertigo, etc. Functional tests, however, show a normal labyrinthine response. The intralabyrinthine fluid is undoubtedly increased in pressure by virtue of the associated engorgement. There doubtless is by this time an already existing neuritis. The future course depends to a certain extent on the invading organism. The process may go on to a suppurative or a diffuse labyrinthitis.

Mass Labyrinthitis (acute, suppurative, diffuse labyrinthitis). The line of demarcation between a suppurative labyrinthitis *per se* and a meningitis is so fine that at times it is very difficult to distinguish between them. We can assume that there is present at least a localized basilar meningitis associated with every case of suppurative labyrinthitis. There is usually also associated with this condition an acute suppuration within the aqueduct of Fallopius, with a resulting facial paralysis.

Both branches of the auditory nerve undergo changes, but the vestibular nerve is much more resistant and will often recover from inflammatory changes when the cochlear branch will not.

Acute exacerbation of a chronic localized labyrinthitis. A flare-up of this type is not unlike that described under localized labyrinthitis.

Application.—Recognizing the changes as they occur in an acute localized labyrinthitis one can understand that the functional tests are practically normal, except that they may respond more quickly. There is no spontaneous nystagmus present and there is no change in reaction to the caloric or turning tests other than this. However, when there is a marked increase of fluid, resulting in disturbed tonus, spontaneous nystagmus may occur. The stormier the symptoms the more rapid is the in-

crease in pressure and the toxicity of the fluid, with the likelihood of a resulting suppurating labyrinthitis. We can also assume a more destructive lesion by judging the rapidity with which the spontaneous nystagmus appears and disappears, and the rapid development of the spontaneous compensatory nystagmus on the healthy side, which ordinarily develops slowly. When this does occur, even in the face of acute symptoms, an immediate operation is indicated, especially if an early irritative symptom of meningitis appears—photophobia.

The all-important aim is to obtain resolution with a functioning labyrinth and to prevent the development of a meningitis. In a localized process with irritation and a serous labyrinthitis the absolute rest of the entire body, particularly the head, is essential. Under no circumstances should any operation be performed whereby the least “shaking up” will occur, as the danger of meningitis developing is imminent. We have, however, on two occasions performed a simple drainage (by the burr) of the antrum when the primary culture obtained after incision of the drum showed the presence of the hemolytic streptococcus. Both of these patients recovered and the mastoid operation was completed several months after the acute symptoms subsided. The hearing in one case was markedly impaired on the involved side and in the other case was almost completely gone. We need but mention here the contraindication of lumbar puncture in that it might start up a diffuse process.

In the suppurative type operative procedure should not be delayed awaiting the appearance of symptoms of meningitis.

PERISINUS ABSCESS

If during the course of an acute mastoiditis, whether operated upon or not, the patient has a sudden rise of temperature, with or without chills (usually without), a leucocytic increase, a sensation of pressure and increased tension, rather than osteal pain, the possibility of a perisinus abscess formation should be thought of. Suspicion should be immediately followed by exploratory proof. The pus accumulates in the outer and lower portions of the sinus—that portion in close contiguity with the

mastoid, and usually before it reaches the knee of the sigmoid because there the sinus is freer.

One of the niceties in pathologic diagnosis at this time is to state whether or not a sinus should be explored. Our custom during the last ten years when an abscess is present and consists of not more than ten or fifteen drops of pus, especially if the organism is not the hemolytic streptococcus, has been not to open the sinus or even to handle it, but to drain the abscess and wait for at least twenty-four hours before doing anything further. Of course very free drainage of the mastoid cavity should be obtained, the sinus fully exposed, and the mastoid wound left open. We believe that any manipulation of the sinus at this time might increase the progress of a developing thrombosis. In several of the cases we have had under observation we are convinced that because of the failure of early mastoid operation in the above condition a true parietal thrombosis has developed.

SINUS THROMBOSIS

The change that takes place is usually by continuity in the osteophlebitic type of mastoiditis. The adventitia of the sinus is rapidly permeated by the bacterial invaders and the subsequent inflammatory change extends into the intima with the development of a thrombus on one side of the sinus towards the bulb or torcula, usually towards the bulb. Starting in one or the other direction the progress is all in that direction. However, the entire circumference of the sinus wall sooner or later takes part in this phlebitis. The complete obstruction of the sinus does not take place for a number of days, which accounts for the repeated showers clinically characterized by symptoms of chills, fever and sweats. Nothing is known to enhance or prevent the loosening up of the thrombus or particles of it, except the classical operation or spontaneous arrest of the process. Some observers have reported cases rapidly progressing, but which cleared up with absolute rest and no operative interference. A case has been described in which subsequent retunneling of the thrombosed sinus was observed several years after.

The longer the process is permitted to exist, the more frequent are the showers, owing to liquefaction of the thrombus,

especially when the hemolytic streptococcus is the invading organism. The various changes that may take place are:

1. Spontaneous arrest with resolution.
2. Continuous progress towards the jugular bulb, torcula, or beyond to the superior longitudinal, occipital or cavernous sinuses.
3. Liquefaction, including the sinus wall and rupture intracranially with hemorrhage.

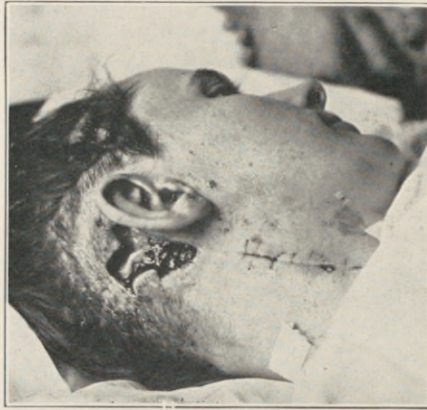

Fig. 42.

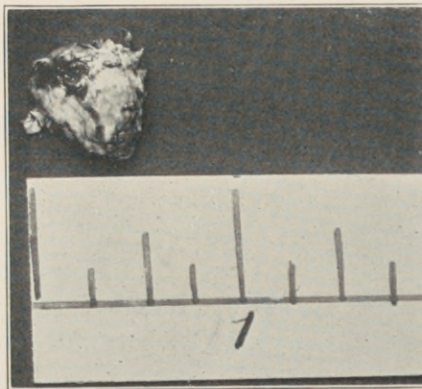


Fig. 43.

Externally, rupture with hemorrhage between the bone and the sinus has never been observed by us. The associated path-

ology, aside from perisinus abscess, is a localized meningitis, with or without abscess; adenitis and cellulitis of the neck, and myositis, particularly of the sternomastoid muscle. In one of our cases in which resection of the jugular vein was done, a secondary dilatation of the carotid artery with a fusiform aneurysm was observed, and it was a question whether the phlebitis or traumatism during the resection was the cause. Vagus irritation has been observed; secondary neuritis following the phlebitis and its resulting symptomatology is an aid in diagnosis.

Based upon the pathologic findings it is clear that even though further spread be shut off by ligation or resection of the neck veins, and the blocking off of the sinus torculawards, the sinus should be opened, the clot removed (Figs. 42 and 43) and the parts drained in order to prevent spreading of the infection into the cranial cavity by contiguity. In this way the possibility of a brain abscess or cerebritis developing is minimized.

EXTRADURAL ABSCESS

Perisinus abscess is the simplest form of an extradural abscess. The most frequent location, however, is in the tempo-

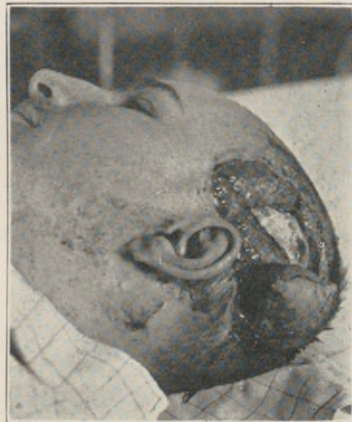

Fig. 44.

sphenoidal lobe following tegmental necrosis—the pus traveling forward and inward, dissecting up the dura (Fig. 44). There is an associated pachymeningitis and an early involvement of

the arachnoid which accounts for the irritative symptoms and the cellular changes in the spinal fluid. The bone, aside from the atrium of infection, is not much changed. The longer the duration of the abscess, and it may exist unrecognized for years, the more dense becomes the surrounding dura from a fibrosis. The concomitant pathological changes are dependent upon the location of the abscess. Thus there may be involvement of the fifth and sixth cranial nerves or if the abscess is located posteriorly, especially close to the tip of the petrous portion of the temporal bone, one may encounter changes within the circle of Willis, as described in Brieger's classical case. The next most frequent location is towards the cerebellum by virtue of the paths of least resistance. The cerebellar dura in the posterior fossa is much more difficult to dissect up and consequently an intradural or true abscess is most frequently met with in this location.

The amount of pus will play an important rôle in the symptomatology. It is important to note that absorption is comparatively slight and therefore the temperature is not an important factor. The possibility of the coexistence of an extradural abscess in the middle and posterior fossa, producing Gradenigo's syndrome, must be recognized. This condition must then be differentiated from the involvement of Koerner's cells in atypical mastoiditis, as described previously. The presence of intracranial irritative and pressure symptoms will aid in the differential diagnosis. We have observed one unusual case of an extradural abscess in the temporosphenoidal region in which necrosis of the thin, squamous portion of the temporal bone took place, with the subsequent burrowing of the pus under the temporal muscle and the zygoma.

INTRADURAL ABSCESS (ACUTE BRAIN ABSCESS)

While brain abscess is much more frequently found in consequence of chronic suppuration of the ear, it does occur following immediately in the wake of an acute mastoiditis. This occurs especially if the mastoid operation has been delayed and extension is by the vascular route. The usual onset of this change is the presence of severe symptoms of cerebral involve-

ment with the rapid dissolution of this tissue—so rapid is this that Nature's defensive forces of encapsulation rarely occur. However, in less virulent cases the brain tissue may fortify itself against further invasion by the formation of a pseudocapsule, and the knowledge of the presence of this barrier is of the utmost importance in that in operative interference it should not be destroyed. It is therefore a good, practical deduction to wait a limited time for the formation of this barrier before operating, provided the symptoms of dissolution or destruction are not too severe or fulminating. It would be well, then, to delay with caution another twenty-four hours or more before drainage, provided the mastoid wound has previously been opened.

Acute abscess following mastoiditis is very frequently multiple and is one of the greatest difficulties in operative cure, so that one may drain one abscess while another may go on to further destruction unrecognized. The cerebritis is of the massive form, contrary to the superficial type associated with meningitis, and the destruction is more by pressure than through the extension of the infectious process through the vascular or lymphatic routes. The passing of strips of iodoform gauze between the meninges and brain to form a cofferdam, and thus prevent further inward destruction, is of value.

HERNIA CEREBRI

In the drainage of large brain abscesses in which large dural incisions are necessary or where the dura becomes infected and subsequently destroyed, there develops, at times, this most disagreeable complication. At first only a small protrusion of the cerebral tissue is noted (Fig. 45), and if the proper treatment is not instituted or is impossible to carry out, the hernia becomes more pronounced (Fig. 46) with eventual cerebrospinal fistula formation. The best results have been obtained by ventricular puncture through a sterile field, or by spinal puncture. Gentle compression bandages are applied to the wound.

MENINGITIS

With all of the above complications there is always an associated meningitis, localized, be it a pachymeningitis or lepto-

meningitis. The pia and arachnoid are agglutinated to the dura and are injected. A true meningitis of otitic origin occurs most frequently by the process extending through the labyrinth and internal auditory meatus. In the beginning the infectious process travels along the auditory and facial nerve sheaths and con-

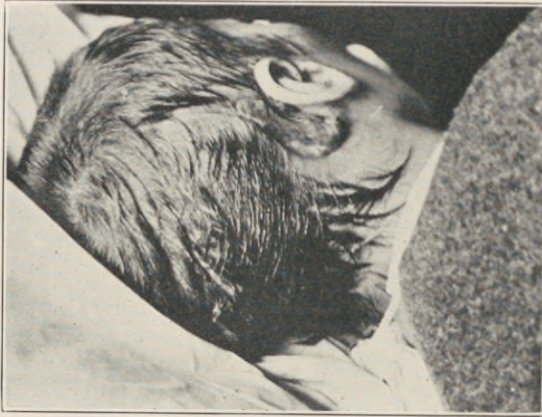

Fig. 45.

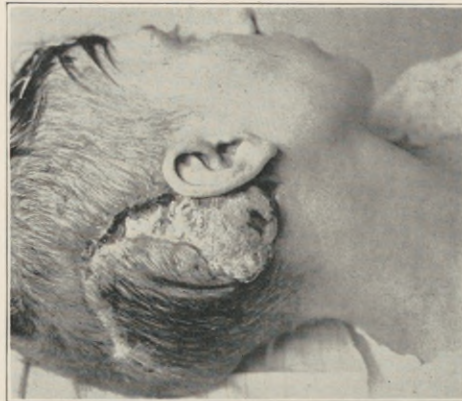

Fig. 46.

tiguous parts. In this process the arachnoid takes on the greatest activity of inflammatory reaction, which is quickly followed by an increase in fluid production, which in turn, as the organisms are present, spreads diffusely.

The headache, which is the cardinal subjective symptom, is

not caused so much by the infection of the meninges as by pressure. The location of this pain is in no way a criterion of the location of the diseased process, and pain by *contre-coup* as in brain tumor, is well recognized. A rapidly diffuse form of meningitis does occur, but is comparatively rare. It is principally dependent upon the type of the invading organism and its virulence. The invasion of the pia, which dips down into the sulci, which do not drain very freely into the arachnoid space, is, perhaps, the most important factor in the fatality from this disease. Another factor is the involvement within the confines of the circle of Willis which is anatomically impossible to drain. The plastic exudate that occurs in meningitis is another hindrance to drainage. The extension of the process along the cranial nerves and spinal cord marks the case practically as hopeless, even if a recovery is made from the meningitis.

The study of the cerebrospinal fluid, its changes physically, chemically, cytologically and bacteriologically, is one of the most practical indices we have in diagnosis. The viable bacterial content especially of virulent organisms is the most important prognostic finding, which if present, gives usually a fatal outlook. The presence of organisms in the spinal fluid that are found only on direct smear and do not grow on culturing does not necessarily give a fatal prognosis. The pressure of the spinal fluid is of some consequence and is of importance insofar as its influence on nutrition of the brain is concerned. Other tests are more of scientific interest than of practical importance. Any type of acute meningitis, no matter how slight, if the arachnoid is irritated, will immediately respond and the spinal fluid will show cytological changes, even though the fluid appear normal in color and pressure.

It is only necessary to mention the various conditions that may be confused with a meningitis of this origin, viz., lethargic encephalitis, tuberculous meningitis and typhoid fever, any of which may have a coexisting otitis media and thus give a picture similar to that described above.

ACUTE FACIAL PARALYSIS

Acute facial paralysis is far more frequent in relation to acute mastoiditis because of anatomical reasons. There are frequently

dehiscences in the fallopian canal. In infants and children the mastoid tip cells are in close proximity to the nerve. In Bezold's mastoiditis the abscess lies in close proximity to the nerve.

Facial paralysis coming on during the course of an acute mastoiditis without labyrinthine symptoms means the extension of the osteitis to the facial canal, with a resulting perineural inflammation and neuritis. Edema and pressure within the canal are very apt to result in the rapid degeneration of the nerve, and therefore the earliest possible unloading of the mastoid as far as the aditus, even to completing a radical mastoid operation, we consider good practice.

Acute traumatic facial paralysis may be the result of surgical intervention. This may be true particularly when the simple mastoid operation is performed in children, where the nerve lies close to the surface and the incision extends too far below or to the front of the tip of the mastoid. Again, this may occur in the over-extensive exenteration towards the anterior-inferior portion. By far the greatest number of cases have resulted since the radical mastoid operation has been in vogue and a great many temporary facial paralyses have been caused by the very instrument devised for its protection (Stacke's protector), which is now practically obsolete.

If the nerve is actually cut during operation, the facial paralysis develops immediately. If it develops later and gradually after the operation, it is either an inflammatory reaction involving the nerve, or the result of pressure, or granulation tissue formed about the nerve.

ACUTE FACIAL PARALYSIS UNASSOCIATED WITH MASTOID DISEASE

In order to arrive at a rational basis for differential diagnosis, it would be well to mention here several other conditions giving rise to the development of an acute facial paralysis, apart from the frequent "Bell's palsy."

Traumatic.—Trauma has played an important part in the production of facial paralysis, particularly during the war when various types of missiles produced marked destruction in the face, and as a rule part of the nerve was actually torn away. In fracture of the base of the skull through the petrous portion

of the temporal bone, facial paralysis accompanied by labyrinthine destruction was not infrequent. In most of the latter cases meningitis with fatality developed.

Infectious Diseases.—Many of the infectious diseases, particularly mumps and measles and occasionally diphtheria, are associated with a bilateral facial paralysis more or less acutely developing. Except in the latter case it is an infectious neuritis, and in this, a toxic neuritis.

Miscellaneous.—Congenital lesions and various brain lesions incidental to birth, as following forceps delivery, might be mentioned. We have seen several unusual cases develop due to varied causes. In one case following a sublabial antrum operation in which there was long continued retraction of the cheek towards the upper and outer portion of the face, there resulted a temporary facial paralysis. In another case at the conclusion of a radical mastoid operation trichloroacetic acid was carried into the eustachian tube and some of the caustic undoubtedly came in contact with an exposed facial canal, with a resultant temporary facial paralysis. In another case a complete facial paralysis developed after the use of 100 mg. of radium properly screened, placed below the lobule of the auricle for the treatment of a tumor. The paralysis persisted for two weeks before there were any signs of improvement.

Application.—When the variability of etiological factors is realized, each case is an entity as to its management. Suffice it to say that unless the facial nerve has actually been cut through and a portion removed one may expect recovery, even though it may be protracted. An important fact to remember is that in this watchful waiting for recovery, when the nerve is restored to function it may be of no avail if the muscles supplied by this nerve have not previously been stimulated by galvanic or deep sinusoidal current in order to retain their tonus and nutrition. The thorough knowledge of the reaction of degeneration is the final word for prognosis or as to the indication for nerve anastomosis. When one applies the cathode to the parotid region at 5 to 15 milliamperes of current and then fails to produce the characteristic vermicular contraction of the muscle fibers supplied by the facial nerve, an unfavorable prognosis must be given, both as to recovery and the effectiveness of nerve anastomosis.

PART II

CHRONIC DISEASES

CHAPTER VIII

CHRONIC DISEASES OF THE NOSE

It is much less difficult to obtain pathologic material in chronic than in acute conditions inasmuch as the greater percentage of the chronic conditions met with are amenable only to surgery. It is surprising how very little use has been made of this fact in the study of pathology of the nose, throat and ear, simply because it is assumed that most of the material that can be obtained is of the "common garden" variety. This is perhaps true but it is only the correlation of the gross and microscopic findings with the specific case that is of value, both as to its course and the treatment that may be indicated.

EXTERNAL NOSE

1. Rhinophyma

Rhinophyma may vary from a slight arterial and venous engorgement, thickening of the epithelium and some atheromatous changes, to that of marked hypertrophy of the skin and verrucous formation. The blood vessels become markedly dilated, giving the nose a bulbous appearance (Fig. 47). This condition has been called "pound nose," or elephantiasis. Microscopical examination shows hypertrophic changes of all the layers of the skin, together with marked hyperplasia of the sebaceous glands.

Treatment.—In the milder cases the use of surgical diathermy, radium and the galvanic needle will be of considerable benefit. The technic of these procedures can be found in the various special books on electrotherapeusis and radiology. In most of the cases operation, that is, decortication and skin plastic must be resorted to.

2. Lupus and Tuberculosis

Neither lupus nor tuberculosis is at all uncommon, although lupus is the one most frequently observed. This latter condition

is usually found on the alae and begins as the characteristic apple-jelly tubercle which soon breaks down and another one or more form in its vicinity, while the earlier ones ulcerate and subsequently cicatrize (Fig. 48). This process will go on until




Fig. 47.—Rhinophyma (Pound Nose).



Fig. 48-A.

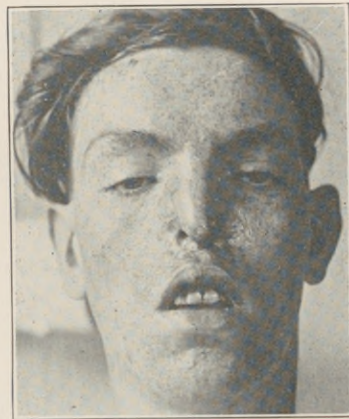


Fig. 48-B.

Fig. 48.—End result of lupus of lip and both alae nasi showing marked cicatrization.

the greater part of the external nose is involved unless active treatment is instituted. It is to be noted that other diseases such as lupus erythematosus must be differentiated, but they are of dermatological importance and not in the scope of this work.

The microscopic findings are typical of the tubercle, with many giant cells present. The treatment is principally electrotherapeusis, the Finsen light, fulguration or surgical diathermy. X-ray and radium have also given excellent results. Surgical removal of the nodules by curettage and subsequent active cauterization will give curative results, but the resultant cicatrization is greater than when the former methods are employed.

3. Lues

In lues it is usually the gummatous stage that is seen. Several of the nasal structures as well as those of the palate are simultaneously involved. The columella usually undergoes the



Fig. 49.—Luetic destruction of septum nasi including the columella and center of upper lip.

most marked destruction (Fig. 49). At first there occurs a great deal of swelling, the skin showing a deep red color (Figs. 50 and 51); it is usually not painful to touch or pressure. Later on the entire mass breaks down and a deep sulcus results. Necrotic masses are seen at the bottom of the ulceration. After the final sloughing the border of the ulceration is sharply defined. The resultant cicatrization is made up of very dense scar tissue (Fig. 51). Microscopically the usual picture of a gumma is found. The Wassermann reaction, of course, in these cases is usually found to be positive.

Treatment.—Treatment consists, naturally, in very vigorous antiluetic measures, although at times the best results are ob-

tained by limiting the treatment at this stage to the arsphenamine preparations. At other times the combined treatment with mercury and the iodides appears to give the best results.

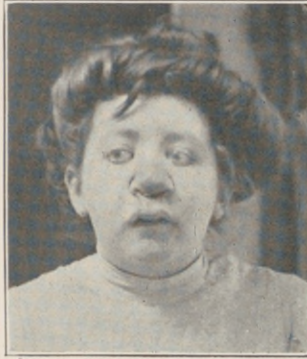

Fig. 50.—Gumma of external nose with marked destruction of the interior of the nose and the columella.



Fig. 51.—End result of deformity and cicatrization in gumma of nose.

Locally cleansing methods should be employed and ammoniated mercury ointment, 5 per cent, freely used, has been found advantageous.

4. Rhinoscleroma

In connection with a typical rhinoscleroma of the interior of the nose and throat we have had a case of this pathologic entity involving the external portion of the nose. The skin of the entire external nose feels indurated and has a diffuse, light red color. The microscopic changes as well as the treatment will be taken up with the same subject in the throat.

5. Pus Infections—with or without Destruction of the Soft Parts

Pus infections may be manifold since each case will have a different etiological factor. Many are the result of fracture, becoming either primarily or secondarily infected. During the World War we observed many cases of chronic infection of the external nose with or without the presence of foreign bodies or necrosis of the cartilage or bones. The staphylococci were the most frequent organisms found in these pyogenic infections.

Treatment.—Treatment consists of a very thorough cleansing of the parts, the removal of all foreign substances as well as any sequestra of bone or cartilage, and the removal of the skin adjoining any fistulous tracts. The wound is allowed to heal openly.

As the result of any of the above-mentioned conditions affecting the external nose, the deformity may be considerable and require further correction. For this plastic work the reader is referred to my chapter on Plastic Surgery in Loeb's text book on "Operative Surgery of the Ear, Nose and Throat."

6. Tumors

Nevus is a very frequent neoplasm of the external nose and is either a true nevus or telangiectasis. These present themselves principally in infants and at that time are very small. They develop rapidly and may finally involve half of the face. The skin is somewhat stretched and has a light bluish appearance. The tumor feels spongy and springs back after compression. When localized at the tip of the nose it may encroach upon the size of the nostrils. The progress of growth is shown in the change of the skin to a deeper red color and finally elevation above the uninvolved portion (Fig. 52). Microscopically there

is shown at first only slightly dilated veins and a fair preservation of the connective tissue stroma, but as the process progresses one finds practically a disappearance of the connective tissue and only large, thin-walled blood vessels (veins). In some instances there is found much free blood between the vessels.

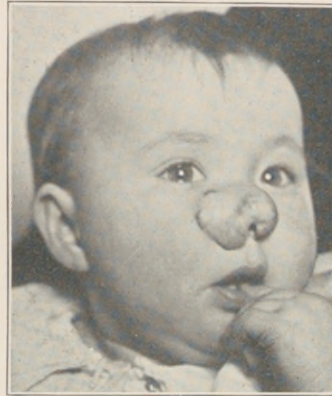
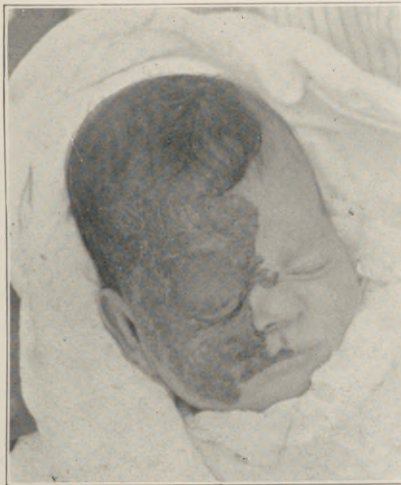
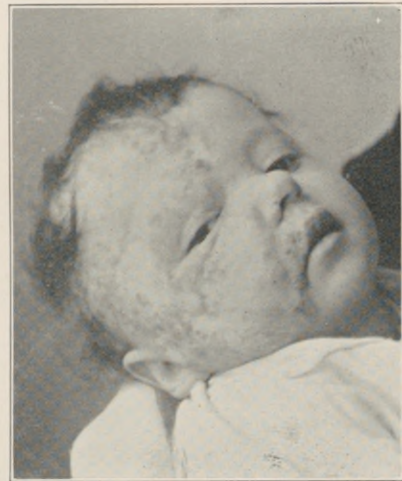Fig. 52.—Nevus of external nose (scar at tip following boiling water injection).



A



B

Fig. 53.—*A*. Rapidly developing nevus (three weeks) from a small blue spot on the upper eye lid.

B. Various methods of treatments employed. The forehead, temple, and scalp, carbon dioxide snow; upper and lower eye lids, radium; cheek and upper lip, boiling hot water injections; marginal below the ear and lower jaw, subcutaneous silk ligatures.

Treatment.—The treatment depends upon the stage and extent of the process. In the earliest cases surgical diathermy and radium are very efficacious, but when the veins are already markedly dilated and the skin transformed in the angiomatous process, the use of carbon dioxide snow gives the best results. The latter may also be used in combination with diathermy and radium. Injections of boiling hot water have also been found to be of advantage. Peripheral ligation of the vessels may arrest progress, but the deformity and cicatrization resulting is a great disadvantage. X-ray has not proved of much value in our hands in this condition; the same is true in regard to the use of the electric cautery, igni puncture, or the galvanic electrolytic needle. We have had one case in which these various methods have been used (Figs. 53 A and B).

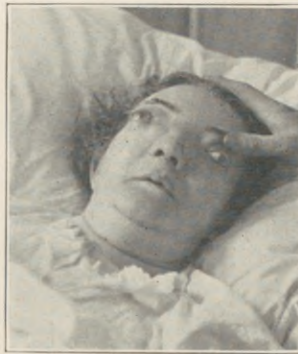

Fig. 54.—Sarcoma of nose producing the typical frog face appearance.

Sarcoma is usually secondary by direct extension or continuity of structure. It is comparatively rare in frequency as compared with involvement of the interior of the nose. The most frequent change is the spreading of the nasal bones in conjunction with the involvement of the ethmoid labyrinth, giving the patient the characteristic "frog-face" appearance (Fig. 54). When the tissues of the external nose have become sarcomatous, the nose exhibits a very red appearance, except at one point, usually at the bridge, where it is pale, and the growth often breaks down at this point to form a fistula (Fig. 55). Palpation frequently reveals crepitus due to the necrosis of the nasal bones from pressure. Microscopic examination will show the

prevalent type of cells. Most of our cases showed mixed and small spindle cells, although we have had two cases of melanosarcoma involving the external nose. These sections will be

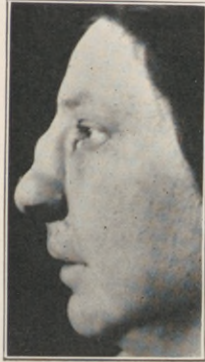

Fig. 55.—Sarcoma of nose involving the external parts with a fistula formation.

shown in connection with sarcoma involving the interior of the nose.

Epithelioma occurs very frequently, and strange to say it remains for a long period in a quiescent stage as a very superficial lesion. The lesion at first is a small elevation of hornified




Fig. 56.—Epithelioma of external nose about the ala.

epithelium resembling a wart and in some cases is multiple. Its location is usually on the side of the nose or ala (Fig. 56), although we have had one case in which the primary lesion

occurred on the tip of the nose (Fig. 57). In due time the cancer cells penetrate below the basement membrane and soon after the regional lymph glands become involved. The masses soon ulcerate and are open to secondary infection. In the case we have mentioned occurring at the tip of the nose the growth protruded externally to the size of a walnut rather than growing inwards, as is usually the case. Microscopically the typical



Fig. 57.—Epithelioma of external nose confined to the tip.

epithelial cells showing mitotic figures and epithelial pearls are to be seen.

Treatment.—The treatment is to remove or destroy the growth at its very earliest appearance. This can be accomplished with either the knife, the cautery, x-ray, radium, surgical diathermy or a combination of these procedures. In the specific case we have mentioned x-ray and radium appeared to stimulate the growth rather than to destroy it. The dosage used in this case, unfortunately, was not available.

Papilloma usually affects the interior of the nose but we have had two cases which developed on the columella, so they really belong in this category. A small, rounded elevation was observed. In one of our cases it was sessile, in the other, distinctly pedunculated. The surface is very irregular and bleeds easily. Microscopically, it has a typical papillomatous appearance with considerable hornification of the surface epithelium. In our two cases the amount of connective tissue and round cell infiltration, together with the vascular supply, was at variance.

Treatment.—The treatment consists in the early surgical removal, best obtained by the use of a cold wire snare followed by deep cauterization of the growth by the galvanocautery point. Radium, x-ray, carbon dioxide snow, or surgical diathermy may be substituted. We have in one instance excised the small growth by sharp dissection and subsequently applied a skin graft which healed very promptly and has shown no recurrence to this date.

7. Paraffinoma

Paraffinoma usually results from improper technic of injecting paraffin, although there are cases on record in which the correct technic was employed. The cases which have come under our observation have all been injected by charlatans or advertising quacks, and in one case, by the patient herself. Up to a number of years ago we injected quite a number of deficiencies about the nose and face with paraffin and did not have a paraffinoma as the result in any case. This method is now obsolete and we do not any longer employ or recommend its use.

The symptom from such a condition, aside from the uncosmetic appearance (Fig. 58) is severe pain of a neuralgic character. The skin, which is invariably involved in this process, is passively congested, giving a bluish-red appearance and on palpation, the mass or masses (Fig. 59) seem to be adherent to the underlying structures. The paraffin is diffusely infiltrated throughout the subcutaneous tissue.

Microscopic examination reveals particles of paraffin subdivided by trabeculae of newly formed connective tissue making a mesh work. Newly formed blood vessels, which remain of small calibre, are plentiful. The usual foreign body reaction,

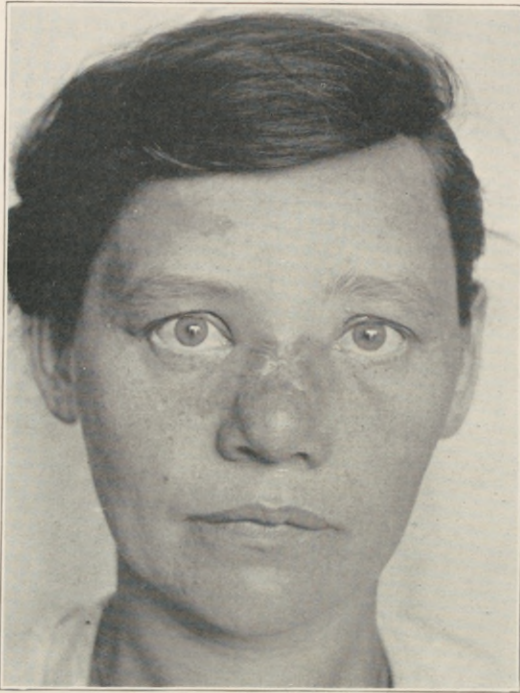

Fig. 58.—Paraffinoma of external nose showing a scar where attempts were made to remove it.




Fig. 59.—Masses of paraffinoma removed. These are very hard to the touch.




Fig. 60.—Paraffinoma of the nose, showing persistent particles of paraffin surrounded by fibrous tissue and numerous fat cells.

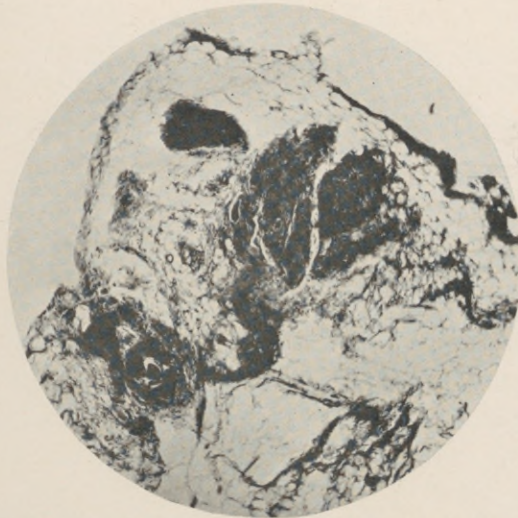

Fig. 61.—Paraffinoma of the nose, showing definite node formation about the paraffin particles.

attended by round-cell infiltration and numerous multinuclear giant cells, is also present, especially in the region of the paraffin globules (Figs. 60, 61, 62, and 63).

Treatment.—Treatment is mainly surgical and consists in the

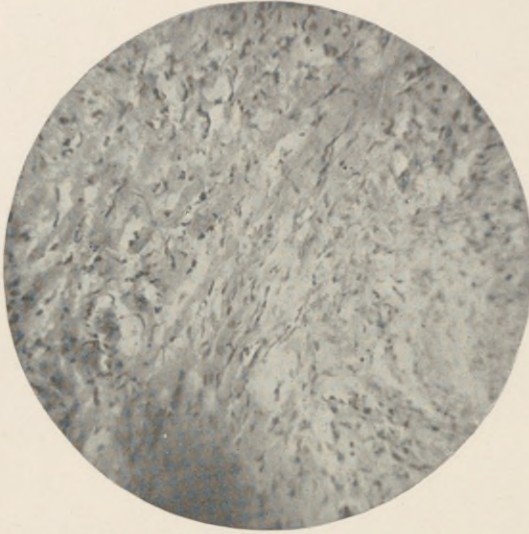


Fig. 62.—Paraffinoma of the nose, showing dense fibrous tissue and cellular infiltration about fibrous particles. The specimen resembles, and is often mistaken for, a spindle cell sarcoma.

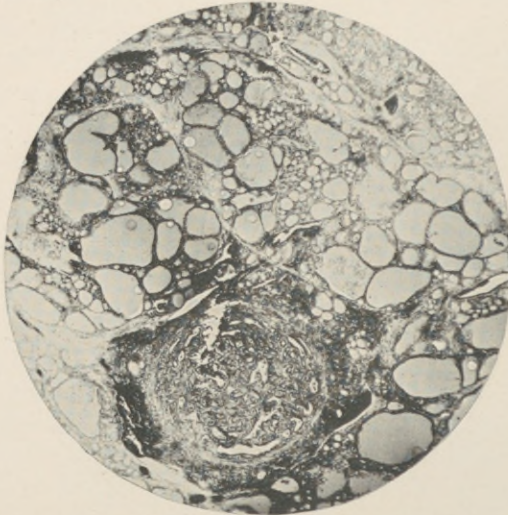

Fig. 63.—Paraffinoma of the nose, showing nodule surrounded by fibrous tissue and numerous fat cells.

removal of all the masses, including the skin, although one may attempt to remove them subcutaneously.

Recurrences are very frequent and this has given rise to the belief that paraffinomas become malignant but we have never found evidence of this microscopically.

Vestibulum of the Nose

Chronic Vestibulitis is one of the most distressing and unsatisfactory conditions to manage. The chief difficulty lies in the failure to recognize the etiologic factor. There is usually found crust formation at the base of the vibrissae, which gives the patient a constant desire to remove them. This adds to the irritation, and a dermatitis, spreading to the tip as well as the ala of the nose, results. After soaking and carefully removing these crusts one often finds fissures anteriorly as well as posteriorly in the vestibule. There may be associated a rhinosinusitis, which may be the causative factor in producing the irritation. Not infrequently definite abscess formation or furuncles may occur on the tip of the nose. Diabetes as an etiological factor should not be overlooked.

Treatment.—The very liberal use of 5 per cent ammoniated mercury ointment, both night and morning, gives considerable relief. X-ray or medical diathermy has been used but with no particularly gratifying results. Attention must be directed to the nasal accessory sinuses and to the general health of the patient. The fissures should be cauterized very carefully with a 20 per cent silver nitrate solution daily for three or four days.

INTERNAL NOSE

1. Nasal Septum

A. Deviations may be classified pathologically into (a) cartilaginous; (b) bony; (c) mixed. Deviations have usually superimposed upon them spurs or crests, the deviation being chiefly confined to the cartilaginous portions. The ridges begin in the inferior meatus and run along the floor of the nose backwards and upwards. Spurs are most frequently found posteriorly, opposite the end of the middle turbinated body (Fig. 64). The type of deviations may vary in shape from a simple bowing to an S-shaped twist. Many times the anterior part of the deviation may protrude from the nostril, simulating a dislocation, thus occluding both nostrils. In many instances there is a combined bony and cartilaginous ridge near the floor of the nose, probably arising from the premaxillary bone (Figs. 65, 66, 67

and 68) and joining the septal cartilage. It is important here to remember the anatomical configuration of the perichondrium and periosteum as it passes from one side of the nose to the other. There also occurs a bilateral thickening of the septal

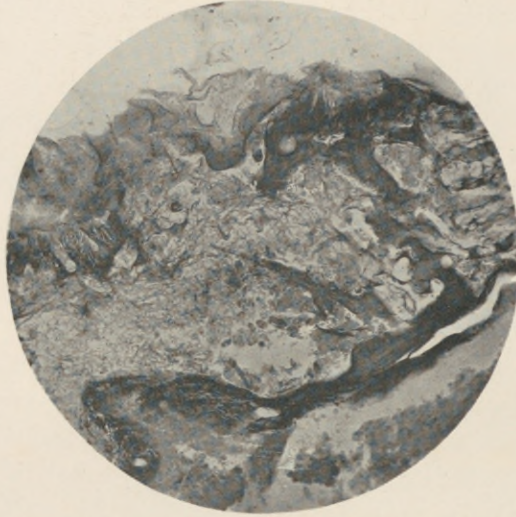

Fig. 64.—Septal spur taken posteriorly near the sphenoid, showing marked rarefaction in the bone and the presence of osteoblasts with the deposition of new, deeply staining bone in the walls of the larger spaces.

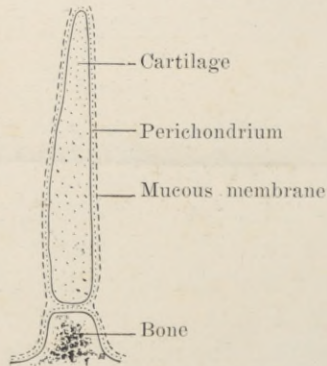


Fig. 65.—Gross illustration showing septal ridges at the floor of the nose.

cartilage in its anterior and upper portion known as the tuberculum septi (Fig. 69).

The mucous membrane of the septum, especially over the crests and spurs, shows frequent evidence of ulceration. It is

also more adherent to the underlying cartilage or bone. In the most anterior deviations where a crest or ridge is present one

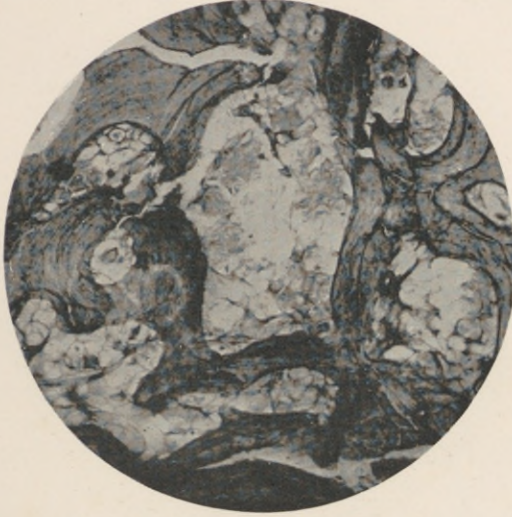

Fig. 66.—Large ridge from the premaxilla, showing marked rarefaction.

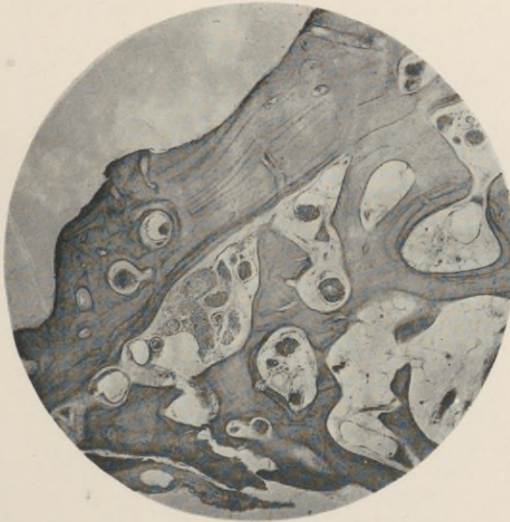

Fig. 67.—Septal ridge showing blood vessels. (Low power.)

frequently finds the mucous membrane entirely destroyed and the cartilage exposed. At times even the cartilage itself is destroyed, leaving only a thin layer of mucoperichondrium on the

opposite side. This condition is frequently the result of the constant removal of crusts.

Micropathology.—In numerous sections of deflected septa and

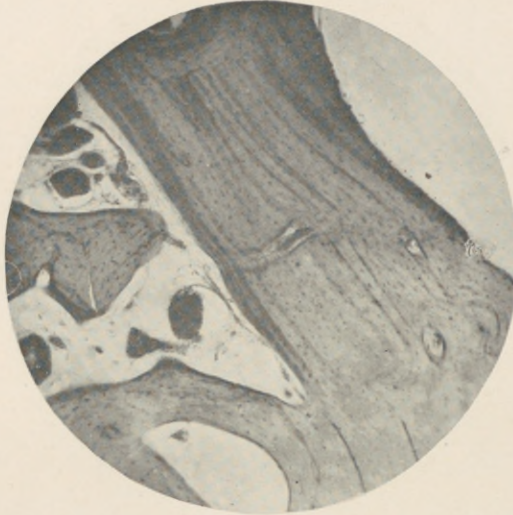

Fig. 68.—Septal ridge, showing at the junction of the bone and cartilage large blood vessels filled with blood. (High power.)

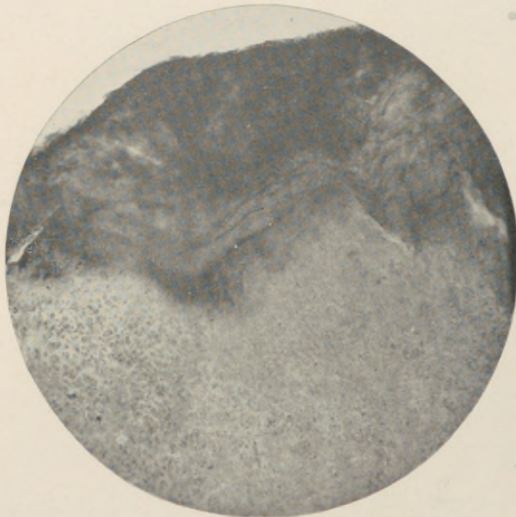


Fig. 69.—Septal cartilage taken high up anteriorly from a young individual, showing marked thickening of the subperichondrium with great karyokinetic figures in the cartilaginous cells at this point. (Only a colored reproduction by a master artist's hand could show the above mentioned findings so clearly demonstrated under the microscope.)

ridges, excluding those of traumatic origin, there is seen definite change in the bone and cartilage. In the bone are areas of rare-

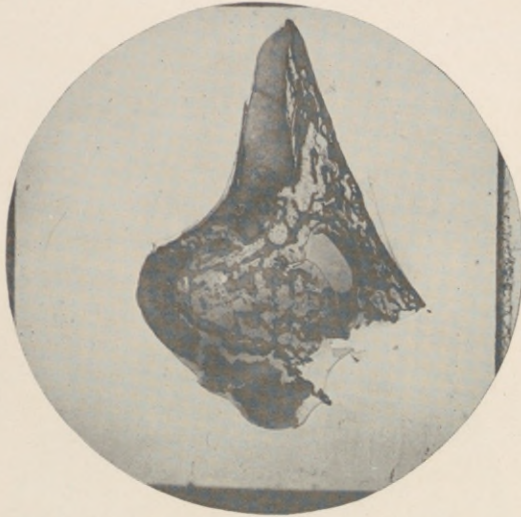


Fig. 70.—Septal ridge, showing cartilage and bone activity at their junction; rarefaction is also clearly demonstrable.

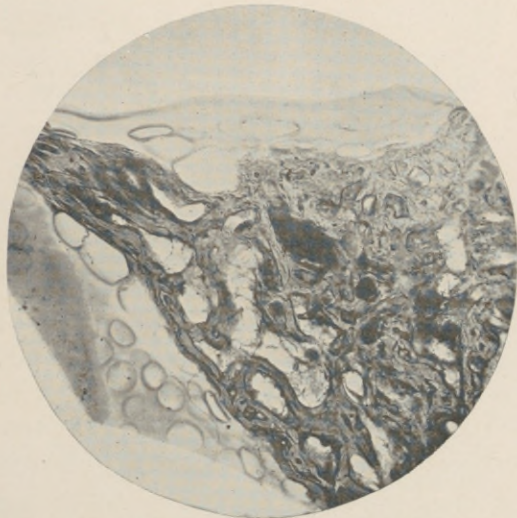


Fig. 71.—Septal exostosis, showing areas of rarefaction and dense bone.

faction or spongification (Fig. 70), a softening of the bone, with other areas which are apparently later changes where the bone is dense and sclerotic (Fig. 71). The process is apparently not

unlike that described by Siebenmann in the early stages of otosclerosis. First there is a dilatation of the bony canals with increased vascularity. Next there is a lacunar absorption, resulting in the formation of rarefied areas. Later, new, deeply staining bone is deposited in the walls of these large spaces. The septal cartilage shows round cell infiltration and great activity of the cartilage cells themselves, together with the definite presence of blood vessels at times (Fig. 72). Similar bony changes are found in osteomalacia, rickets, and physiologically in the first few months of pregnancy. It might be

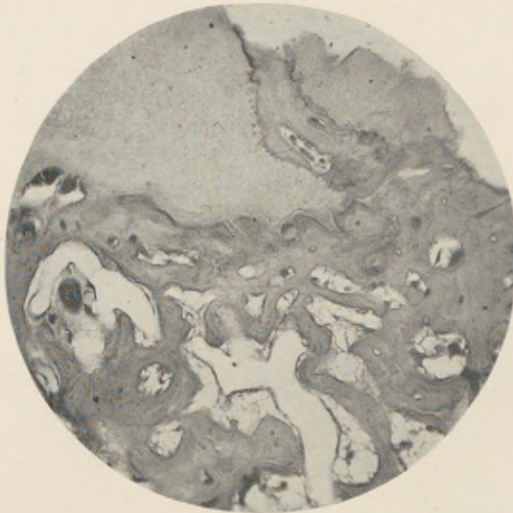

Fig. 72.—Septal ridge, showing rarefaction of bone and great activity of the bone and cartilage cells at their junction, and blood vessels filled with blood.

suggested at this point, as to the relationship of septal deviations to the bony and cartilaginous changes found in deficiency diseases, particularly where the fat soluble A vitamin and the calcium content of the blood are lowered, that the septum during this pathological process may yield to external pressure.

The mucous membrane over certain septal deflections and the tuberculum septi is at times very markedly hypertrophied. There is a marked increase in the blood vessels and specimens show many dilated veins. Those changes found here are not unlike those present in the mucous membrane of the inferior turbinate in its intumescent state. The presence of this patho-

logic condition frequently gives rise to the clinical symptom on the part of the patient to constantly try to force air from the postnasal space forward in expulsive jerks.

Treatment.—Insofar as preventive measures are concerned relative to deflected septa, but little can be suggested. The avoidance of trauma, of course, is important. In addition, care should be taken during the growing period that the diet be not deficient either in the vitamin content or inorganic salts (particularly calcium), which factors are essential to the normal growth and development of bone. When the deflection has occurred, surgical removal is indicated. It is important to note that complete resections should not be done under the age of sixteen, previous to which time full growth has not occurred and following resection deformity is apt to result. Graduated resections of the cartilaginous septum may be necessary in the young.

2. Traumatic Septum

A different picture is shown in resected cartilage to correct the deformity following cases of hematoma or abscess of the

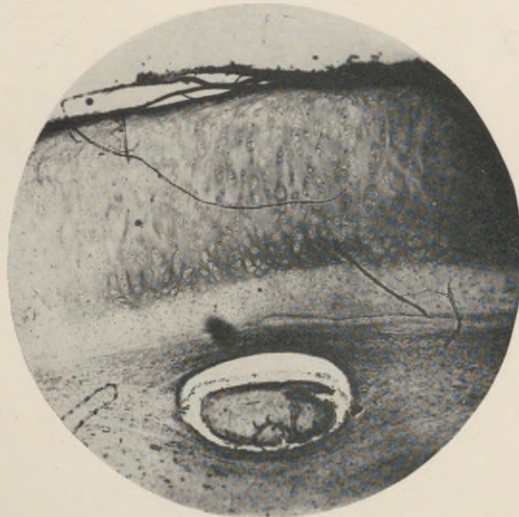


Fig. 73.—Traumatic septum; resected cartilage in a traumatic football nose caused primarily by an abscess of the septum. The perichondrium is very much thickened and an organized blood clot is shown within a large vein. The cartilage cells in many places are shriveled. (Lower power.)

septum. There is loss of cartilage cells with the formation of connective tissue, especially in the subperichondrial region and

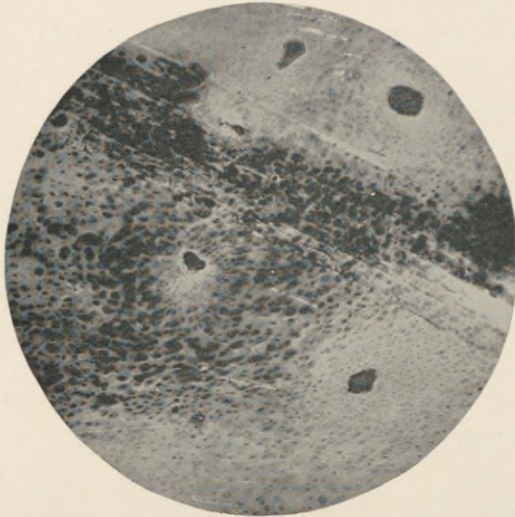


Fig. 74.—Septal cartilage, showing round cell infiltration and the great activity of the cartilage cells themselves; also cross section of blood vessels.

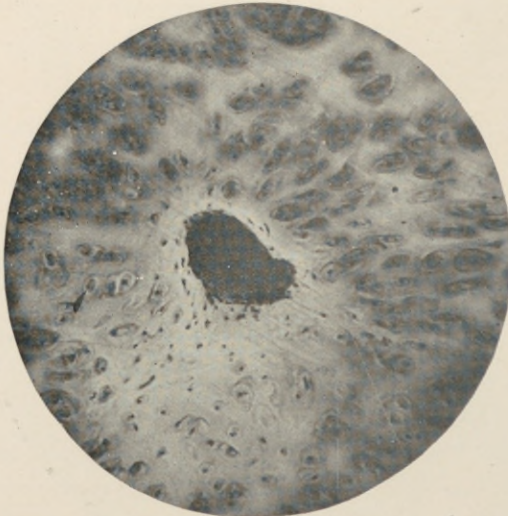


Fig. 75.—Same as Fig. 74. (High power.) Blood vessel in the cartilage is clearly shown.

the areas of absorbed cartilage. The hyalin degeneration is evidenced in the homogeneous appearance (Figs. 73, 74, and 75).

3. Lues

The characteristic picture of the gummatous stage involving the septum is a bilateral swelling usually extending from the tip of the nose back and downwards onto the floor of the nose. It is brawny, indurated, and not painful. The hard palate in oral examination shows an associated swelling and redness. The external nose may also be involved. As the process progresses the gumma breaks down, usually at the junction of the cartilage of the septum with the bone at the floor of the nose. Ulceration

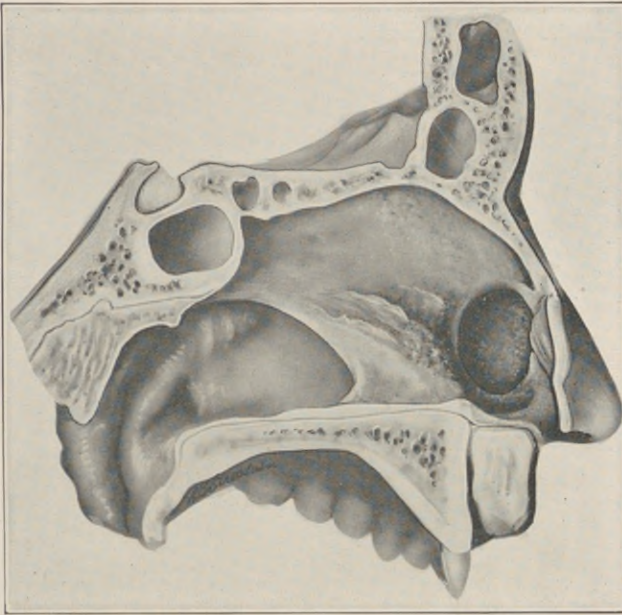


Fig. 76.—Septal defects, anteriorly and posteriorly, luetic origin.

and subsequent sloughing then appears and continues until repeated sequestration occurs. As a result of this destruction there will be seen perforations of the septum (Fig. 76) and not infrequently perforations of the hard palate into the mouth. The edges of these perforations, at first granulating, soon heal over fairly smooth and are sharply defined. If the process involves the septum and the lateral cartilages towards the bridge of the nose, a typical saddle or notched nose (Fig. 77 *A* and *B*) may result.

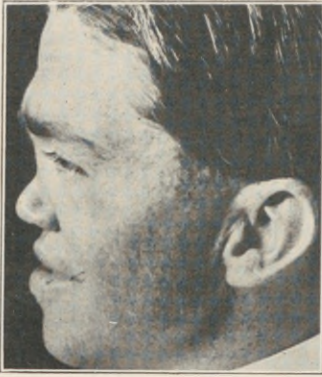*A.**B.*

Fig. 77.—Typical saddle or notched nose following gummatous destruction.

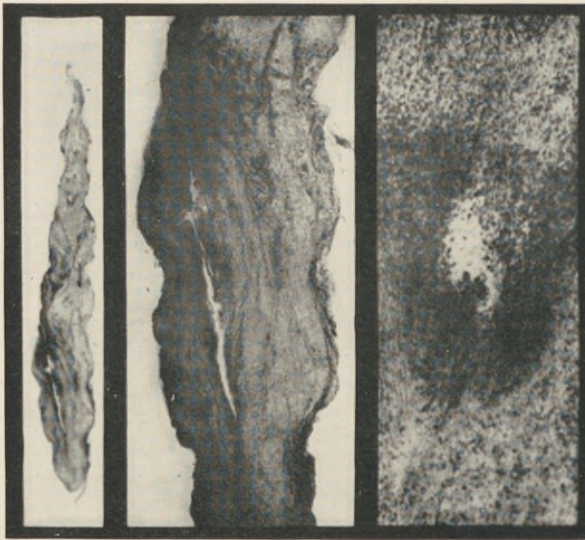
*A.**B.**C.*

Fig. 78.—Gumma of the septum. *A.* Luetic exudate (low power). *B.* Same (high power). *C.* Gumma.

Microscopic examination of the exudate covering the ulcer is somewhat homogeneous and the gumma is typical of such lesions occurring elsewhere in the body (Fig. 78 *A*, *B*, and *C*).

Treatment.—The treatment, of course, is directed towards vigorous antiluetic measures. Some patients respond splendidly

to arsphenamine, while others respond much more rapidly when arsphenamine is combined with mercury and the iodides. Locally, the usual cleansing measures with alkaline solutions, the removal of all bony sequestra without trauma, and cauterization of the granulations comprise the principal procedures. The objectionable symptom of the fetor due to necrosis is best overcome by frequent douching with potassium permanganate solution (1:5000) or by the free use of hydrogen peroxide. Crust formation is best prevented by the generous use of 5 per cent ammoniated mercury ointment.

4. Tuberculosis of the Septum

Primary tuberculosis of the septum is comparatively rare, but is associated at times with a tuberculous involvement of the ala of the nose or lupus. The lesion usually begins on one side close to the tip in the form of a nodule which soon breaks down into the typical caseous mass. The granulations about the margin of the ulceration are rather profuse. At the bottom of the ulcer the denuded septal cartilage may at times be observed and in case this has been destroyed in the process the opposite mucous membrane becomes subsequently involved. The process is distinctly chronic; there is usually an associated secondary infection with a resultant swelling and injection of the surrounding mucous membrane and enlargement of the regional glands. The immediate surrounding area so often described as typically pallid has not been observed, as a rule, in our cases. The associated nasal discharge, because of its severity, produces a dermatitis about the nostril and upper lip. Clinically, there is a persistent, radiating pain into the face and teeth in contradistinction to the absence of pain in luetic destruction of the septum. The tubercle bacilli can be found if persistent efforts are made and histological examination of a small resected portion will confirm the diagnosis.

Treatment.—In addition to general hygienic measures that must be adopted, radium and x-ray therapeutics have offered the best results. Complete removal of the diseased portion with the curet and subsequent actual cauterization has produced the best results in our experience.

5. Malignant Disease of the Septum

Sarcoma and epithelioma of the septum have been observed by us, but it is doubtful whether they were primary in this region. Diagnosis can be made with certainty only upon removal of a section and subsequent microscopic examination. One should be prepared in all instances, if the tissue removed shows evidences of malignancy, to continue more radical procedures within twenty-four hours. Surgical excision beyond the confines of the growth, surgical diathermy, supplemented either before or after by radium or x-ray therapy, offer the only means for its control.

6. Papilloma of the Septum

In addition to the papillomatous growths about the columella already described, we have had a case of extensive papillomatous formation over the greater portion of the septum on one

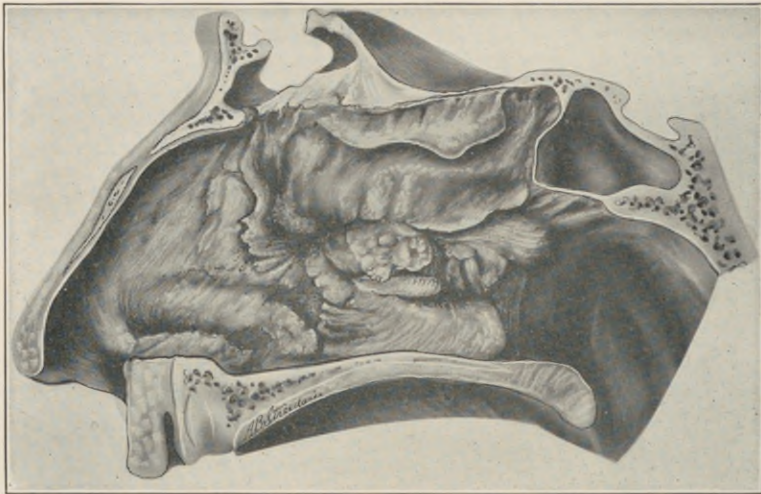


Fig. 79.—Multiple papillomata of the septum.

side. The irregular excrescences, and in many places multiple wart-like formations, characterized it (Fig. 79). At the lower posterior portion of the septum it was so marked as to block the nose. Bleeding was very slight. Microscopic examination showed the typical papilloma formation, the finger-like processes of epithelium (Fig. 80) being in many places capped by

markedly thickened and hornified epithelium (Fig. 81). The blood vessels were very sparse.

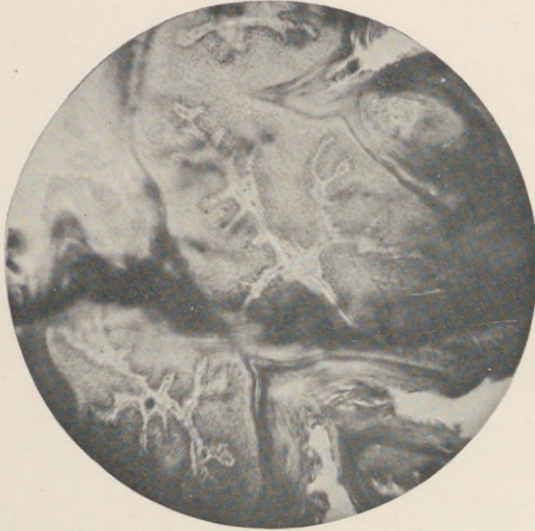

Fig. 80.—Benign papilloma of the nose, showing structural formation with finger-like projections.

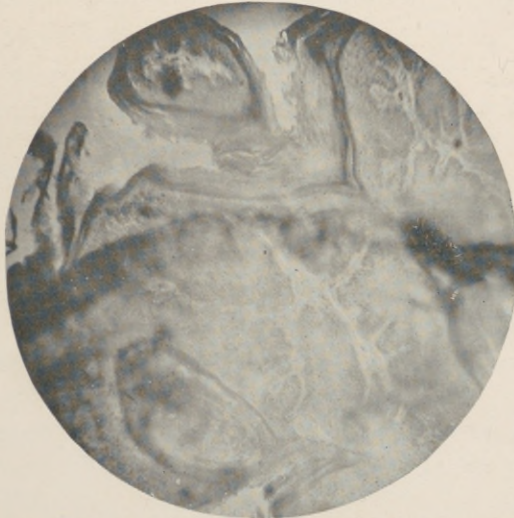

Fig. 81.—Papilloma of the nose showing hornification. Papilloma had its origin from the septum.

Treatment.—Treatment can be satisfactorily carried out by the use of carbon dioxide snow applied in aluminum tube appli-

cators. In the case above mentioned after seven applications the growth entirely disappeared, healing with a fairly smooth surface, and has remained healed for a period of over six years. Radium, fulguration, surgical diathermy and the actual galvanocautery have been used with equal success.

7. Congenital Absence of the Septal Cartilage

Congenital absence of the septal cartilage may either be partial or complete. The usual picture shows a drop tip and no resistance to lateral movement. Palpation reveals the absence of any or part of the triangular cartilage. The treatment consists of a plastic operative procedure involving as a rule an autotransplant. (Refer to chapter on Plastic Surgery, by Beck, in Loeb's text book.)

8. Closure of the Posterior Choanae

Closure of the posterior choanae may be unilateral or bilateral, partial or complete, membranous or bony. The diagnosis is usually overlooked in the routine examination of the nose. Digital examination or posterior rhinoscopy will determine the condition. The treatment consists in punching out sufficient portions of the septal closure and the insertion of a rubber tube from behind forward, which is allowed to remain in place for several days.

9. Septum in Atrophic Rhinitis

The septum in atrophic rhinitis is of interest from the pathologic viewpoint only as it relates to treatment. Various efforts have been made to diminish the size of the large air spaces present in the nose by building up the septum. In the various attempts to implant into a submucously dissected pocket in the septum, small pieces of cartilage from the septum of another individual, only a percentage was successful. One side should be operated upon at a time. In one of our successful cases where the implant held nicely, a piece of the lip of wound, including cartilage, was removed just preliminary to implanting and the following microscopic conditions noted (Fig. 82): the perichondrium was very much thickened and a low-grade in-

flammatory process involved the cartilage. The mucous membrane was somewhat hypertrophied and the glands showed a definite increase and hypertrophy, instead of the usual atrophic condition found in the mucous membrane overlying the inferior turbinate in such cases. We have been encouraged in this procedure and have subsequently adopted the transplantation of a piece of the patient's costal cartilage below the mucoperichondrium and mucoperiosteum, especially in the region of the inferior meatus. The successful lessening of the air space gives

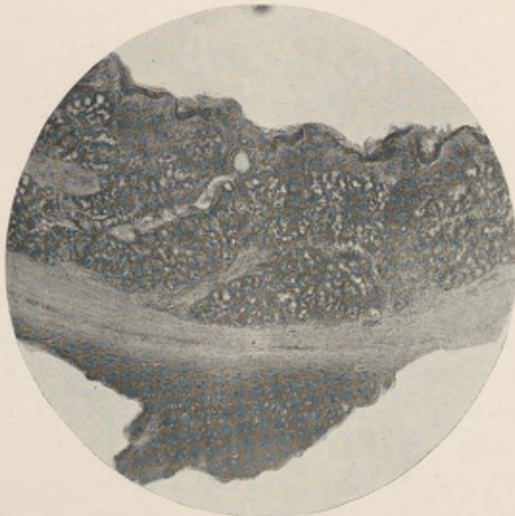

Fig. 82.—Lip of wound in atrophic rhinitis, showing hyperplasia of the mucous membrane, especially the glands. The perichondrium is thickened and cartilage unchanged.

relief to the two most annoying symptoms of atrophic rhinitis, namely, crust formation and fetor.

10. Synechia

In intranasal operative procedures and following any mechanical, chemical or thermal manipulation within the nose, in which the mucous membrane of contiguous surfaces is injured, a synechia is likely to result. This consists of dense fibrous tissue with a fine layer of surface epithelium, at times appearing almost like a piece of dense mucous membrane. Cutting the adhesion and keeping the adjoining parts separated by

paraffin or wax splints until healing takes place constitutes the treatment.

INFERIOR TURBINATE

Pathologic changes in the inferior turbinate may be primary or secondary. Thus the following conditions may manifest themselves by changes in the inferior turbinated body.

1. Chronic engorgement, associated with renal and cardiac disease.
2. Hyperplastic rhinitis, presenting either the ischemic or boggy appearance.
3. Vasomotor conditions, manifested by the rapid alternating dilatation and contraction.
4. Accessory sinus disease.
5. Atrophic rhinitis.
6. Syphilis, tuberculosis, sarcoma, carcinoma, and myxoma.

Histological examination, however, reveals the following principal types. It is possible at times, even by clinical examination, to anticipate the microscopic findings.

1. Turgescence
2. Hypertrophy
 - a. Epithelial
 - b. Fibrous
 - c. Vascular
 - d. Osseous
3. Atrophy

Turgescence

A temporary or chronic engorgement, usually vasomotor or infectious, will shrink under cocaine. This change is very frequently found in certain types of individuals with a very sensitive and highly reactive nervous mechanism. These same individuals are for the most part over-sexed. Clinical examination during the period of turgescence shows a large, smooth turbinate in its entirety. There is but slight deepening of the normal color of the mucous membrane. At times one may see, during the same examination, the stage of contraction and the

turbinate assume almost a picture of atrophy with an ischemic appearance.

Treatment is directed chiefly to general hygienic measures. The galvanocautery at times is helpful. These patients are very susceptible to suggestion and it is important to note that no operative procedure is indicated.

Hypertrophy

Macroscopically the types of hypertrophy appear about the same but histologically they are quite different. Although the various types are usually combined, one type as a rule predominates.

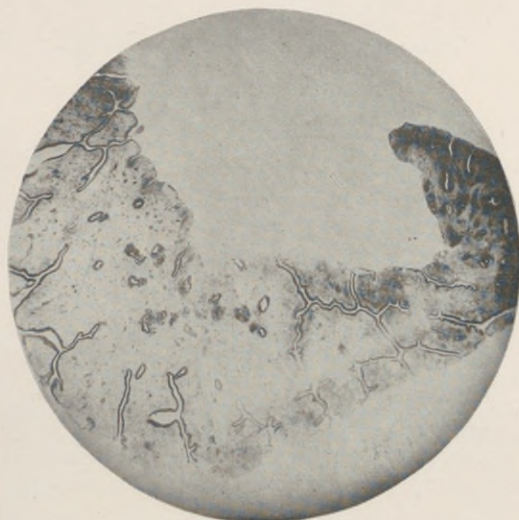

Fig. 83.—Epithelial hypertrophy of the inferior turbinate with folded-in masses. (Low power.)

a. **Epithelial** hypertrophy occurs usually in association with connective tissue hypertrophy. The most marked hypertrophy of the epithelium is found in cases of chronic suppurative sinusitis. It is at times infolded and upon microscopic examination appears as lakes or channels (Figs. 83, 84 and 85). It is unusual to find any considerable amount of glandular hypertrophy.

The treatment is principally surgical in the removal of the dragging, redundant mass at the floor of the nose. The actual

cautery may be employed, but the following histologic specimen shows the apparent futility of such procedures (Fig. 86).

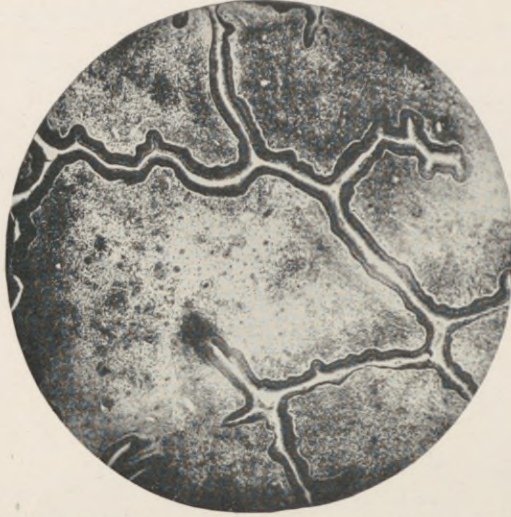

Fig. 84.—Same as Fig. 83, high power, showing epithelial lakes.

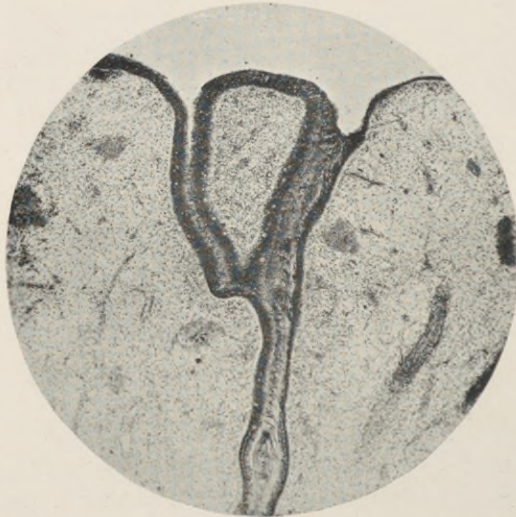

Fig. 85.—Hypertrophy of the inferior turbinate, showing marked thickening of the epithelium with folded-in masses. (High power.)

b. Fibrous.—The majority of specimens show connective tissue predominating; the glands and vessels are frequently destroyed by pressure necrosis. The papillary changes of the

posterior ends are principally made up of connective tissue with thick layers of epithelium (Figs. 87 and 88). These are spoken

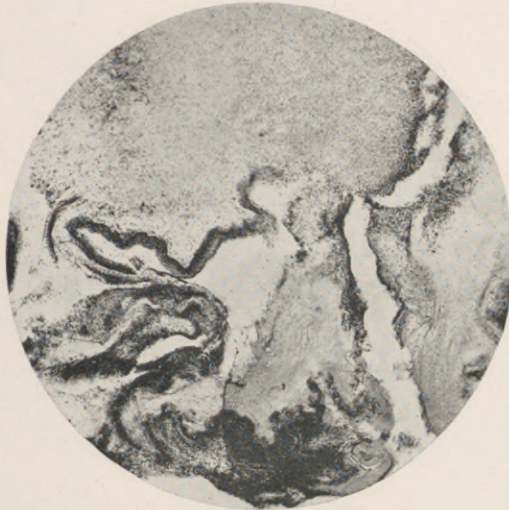

Fig. 86.—Eschar following cauterization of the inferior turbinate. Specimen taken eleven days afterwards, showing involution of the epithelium and its covering with a thick, homogeneous exudate. The original pathologic change in this turbinate was epithelial hypertrophy.

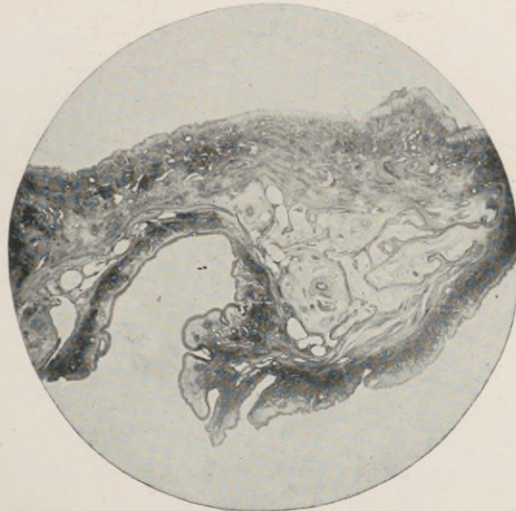

Fig. 87.—Papillary hypertrophy of the inferior turbinate, showing the epithelial hypertrophy.

of as posterior hypertrophies or mulberry enlargements (Figs. 89 and 90). Clinically the picture is one of persistent ob-

struction rather than alternating and periodical obstruction such as is found in the turgescient or the intumescent type. Due

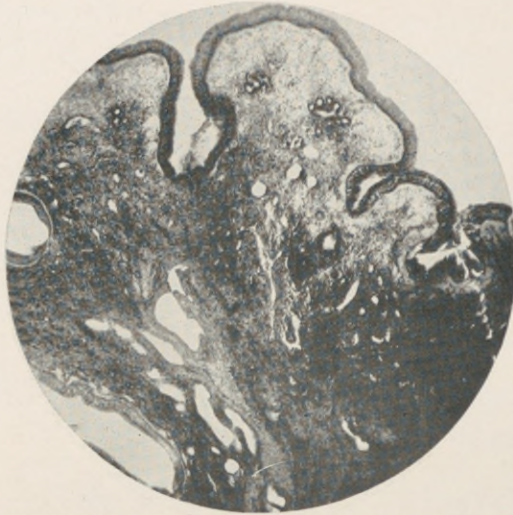

Fig. 88.—Papillary hypertrophy of the inferior turbinate.

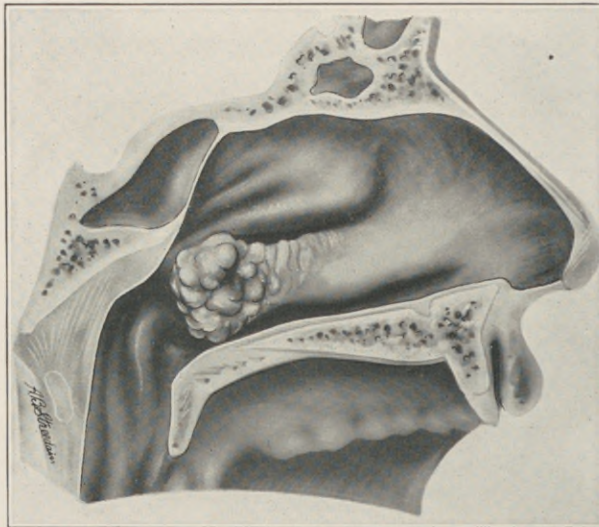


Fig. 89.—Mulberry hypertrophy of the posterior end of the inferior turbinate.

to these dependent enlargements, particularly posteriorly (Fig. 91), nasal secretions frequently accumulate and patients often describe a sudden dropping of mucus into the throat. They

likewise frequently complain of a sensation of a foreign body in the back part of the nose, and develop the habit, on this account, of rasping back into the throat. Adrenalin or cocaine applied will result in a rather slow contraction, and in the area of the dependent enlargements there will be noted very little



Fig. 90.—Posterior end of the inferior turbinate, showing "mulberry hypertrophy."

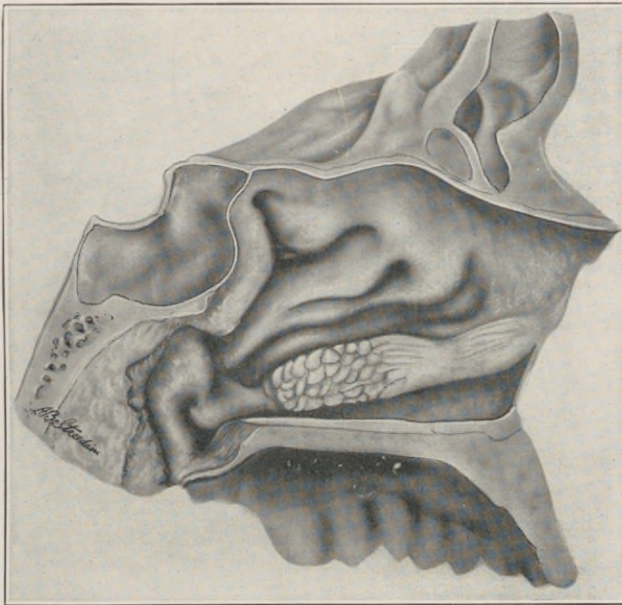


Fig. 91.—Diffuse papillary hypertrophy of the inferior turbinate.

change. The periosteum overlying the bone is not infrequently involved in the inflammatory process. The bone itself shows but little change; in one case, however, we found great rarefaction (Fig. 92).

Treatment.—Contrary to the other types of hypertrophy, the

treatment in this type is only surgical. The only caution to be exercised is not to remove too much of the bony structure.

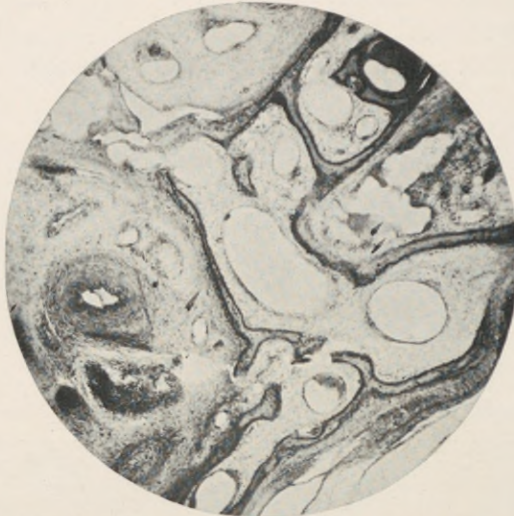


Fig. 92.—Inferior turbinate, showing rarefaction.



Fig. 93.—Chronic intumescence of the inferior turbinate, showing predominance of connective tissue with round cell infiltration of the surface epithelium and almost complete atrophy of the glands, together with new blood vessel formation.

c. Vascular.—In chronic intumescence of the inferior turbinate, although the connective tissue usually predominates, the tissue is somewhat edematous and shows many newly formed

blood vessels (Figs. 93 and 94). The epithelium is frequently infiltrated with round cells.

This change may be either primary or secondary to some sinus infection or systemic disease of the renal, cardiovascular system. The clinical appearance of the turbinate shows a diffuse swelling of the soft tissue with a preponderance at the lower and posterior portions. The color is a deep red and often when due to cardiovascular conditions it may appear somewhat cyanotic. The obstruction seems to be more marked in variation of position of the head and this intermittent blockage is a

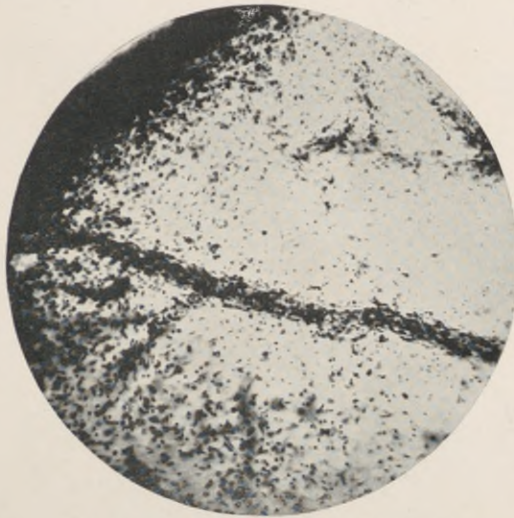


Fig. 94.—Same as Fig. 93, high power.

frequent symptom. Upon applying cocaine or adrenalin solution one will find a rapid contraction, of short duration, of the soft tissues.

Treatment is directed towards determining the causative factor, whether it be sinus disease or a cardiovascular change. Locally, various deturgescent remedies may be applied, as, for instance, 10 per cent ichthyol-glycerine tampons, allowed to remain for ten to fifteen minutes, during which time there will be a rather profuse outpouring of secretions. Secondly, the use of mild astringents, as 5 to 10 per cent zinc sulphate solutions, 2 per cent silver nitrate solution, or a similar solution of tannic acid is advantageous. A 5 or 10 per cent solution of silvol or

neosalvol is our usual remedy for the patients for home use, employed in the Beck postural method of treatment (see Fig. 13). Should this simple treatment in the course of a few weeks not suffice, then ignipunctures with the electric cautery needle may be made. These punctures are best made from before backwards, usually four or five in number, equally distributed. As a rule this condition is bilateral and but one side should be done at a time. Plenty of sterile vaseline should be used as after-treatment. Operative procedures, such as the removal of any part of the turbinate or deep linear cauterization, are contraindicated, yet the latter is the procedure most frequently employed.

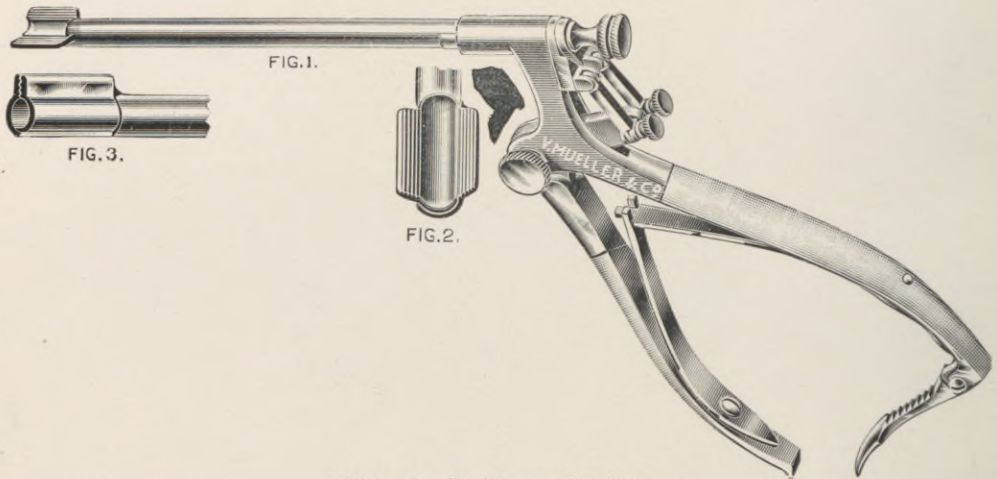


Fig. 95.—Beck's conchotribe.

As an extreme measure in a limited number of cases we have used the Beck conchotribe (Fig. 95), with which the tissue is squeezed to a pulp. This pulp subsequently becomes more or less absorbed without granulation tissue formation. Sections taken at intervals of these hypertrophies so crushed have shown on the third day (the height of the reaction) marked round-cell infiltration and areas of necrobiosis (Fig. 96). On the tenth day the tissue is practically all shrunken and but little evidence of organized tissue remains. Macroscopically after repair has taken place the turbinate appears reduced in size and characteristically rounded and smooth surfaced. When the galvano-cautery is used there is usually involution of the epithelium and

considerable leucocytic infiltration along the margins of the cautery incision (Fig. 97).




Fig. 96.—Crushing of the inferior turbinate (conchotribe); section taken on the third day showing marked round cell infiltrated masses of necrobiosis.



Fig. 97.—Eschar of the inferior turbinate following actual cautery in a case of vascular hypertrophy, showing fibrinous organization and papillary formation, together with marked leucocytic infiltration.

d. Osseous.—There are seldom osseous changes, although occasionally in marked suppurative sinus disease there is an osteitis present.

Atrophy

A tendency towards atrophy of the turbinate is occasionally seen in cases of chronic sinusitis. In the borderline cases of this type it may be difficult to differentiate between this and a true atrophic rhinitis. The pathology varies but in degree; however, in the former there does not seem to be any primary hypertrophy.

Atrophic Rhinitis

Whether or not the term atrophic rhinitis is a misnomer, it is generally accepted and applied to a distinct disease entity mani-

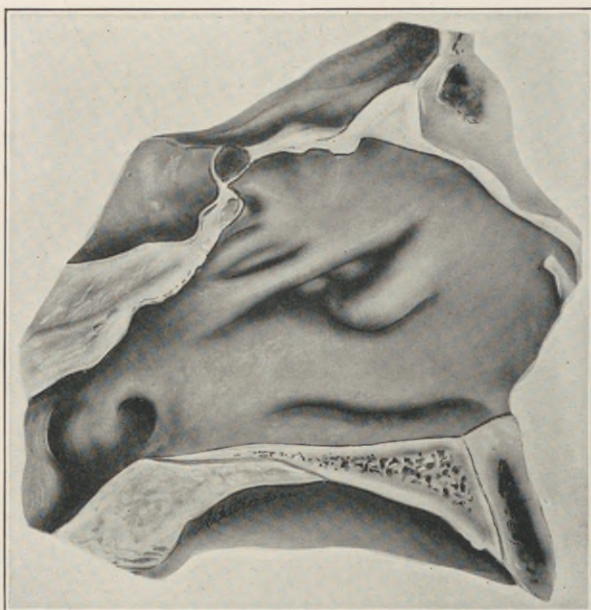


Fig. 98.—Atrophy of the turbinates in atrophic rhinitis.

festated clinically by a foul odor (ozena) and extensive crust formation in the nose. Whatever possibility we may favor as to its etiology, i. e., a specific infection or secondary to a purulent rhinitis or accessory sinus disease, or a faulty local development, syphilis, or as a local manifestation of some other disturbance—the ultimate pathologic examination reveals the one picture. Macroscopically the turbinates, particularly the inferior, appear small and collapsed (Fig. 98). Early the mucous membranes ap-

pear gelatinous-like, later dry and pale. The crust formation and odor are prominent features. Microscopically, in the early

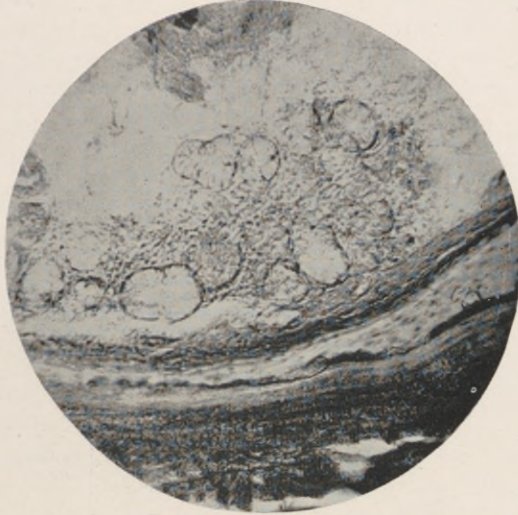


Fig. 99.—Inferior turbinate and early atrophic rhinitis, showing distention of the glands. The bone appears normal in structure.

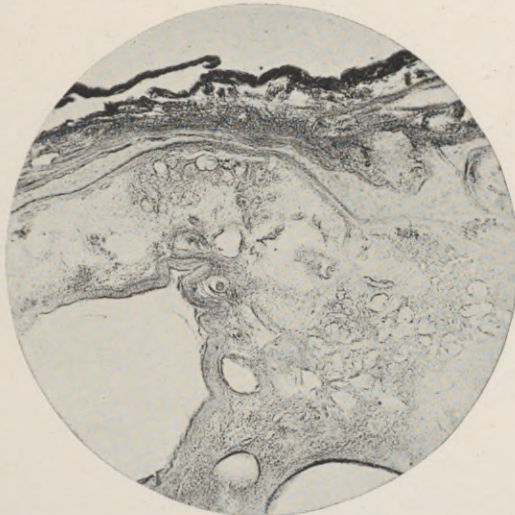

Fig. 100.—Inferior turbinate and early atrophic rhinitis, showing metaplasia of the epithelium of the median side and thickening of the antral side. The mucous glands are still present, although distended.

stages, there is an actual hypertrophy, particularly of the glands. These later become markedly distended and by this process lose

their function (Fig. 99). The lining ciliated epithelium becomes squamous in type, while the tissue lining the antral side shows marked thickening (Fig. 100). The principal change is in the bone; i. e., the early disappearance of the marrow spaces (Fig. 101). In the early period the mucous membrane is covered with a mucilaginous secretion, frequently spanning over to the septum. After this is wiped off the surface, the glazed appearance of the turbinate is in evidence. Very rapidly there seems to be a flattening of the bony structure and a corresponding atrophy over it. Finally there is almost complete disappearance of the

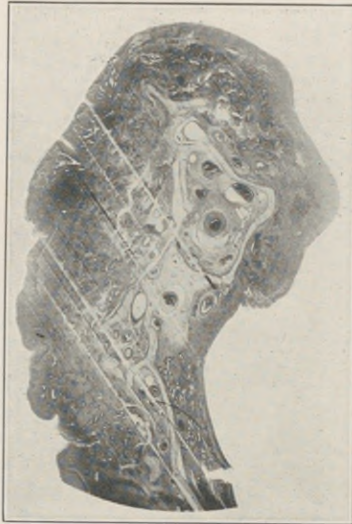


Fig. 101.—Middle turbinate in early atrophic rhinitis, showing metaplasia of the epithelium and disappearance of marrow spaces. (With apologies for artifacts in specimen.)

inferior turbinate; simply a small ledge remains along its entire attachment (Fig. 98).

The persistent crust formation in the form of definite casts is quite pathognomonic and frequently at their forcible removal, either by the patient or mechanically, denuded areas will be seen. The changes in general appear to be due to nutritional disturbance, such as the early increase of connective tissue, disappearance of the mucous glands, fatty degeneration and desquamation of the epithelium. Secondary infection always takes place and nonpathogenic organisms can be isolated. The bac-

terial flora is made up of many staphylococci and many varieties of bacilli. The bacillus fetidus ozena (putrefactive organism) has been considered a specific cause of the disease. The crusts when examined show microscopically a great deal of fibrin in the meshes of which are many dead epithelial cells and leucocytes.

We believe that the type of pathologic change suggests that the disorder is a manifestation of some nutritional disturbance. Although an associated sinus disease can usually be found, we do not believe that there is a direct connection between the two conditions. Nevertheless, in the treatment of this condition attention must also be directed to the sinus disease if it is present. A number of years ago Beck and Pollock brought out in their investigation of this condition the marked deficiency in the fibrin content of the blood, and expressed the hypothesis that there might be some disturbance in the glands of internal secretion, perhaps the thyroid. Since that time the basal metabolism test has been made on a number of these patients and a minus metabolism rate of from 15 to 40 has been found almost routinely. We have therefore added, in the treatment of this condition, polyglandular substances—as thyroid, pituitrin, adrenalin, ovarian or testicular extracts.

Locally, the cleansing of the ethmoid labyrinth and the irrigation of the antrum adds considerably to the comfort of the patient. At this time, as a routine, we add autotransplants of costal cartilage, placing them in a submucously dissected pocket in order to lessen the air space.

For the patient's home use we advise the application of vaseline to soften the crusts and should irrigation become necessary, special instructions must be given to avoid ear complications from autoinflation. Alkaline or normal salt solutions are to be preferred. For controlling the putrefaction, a 10 per cent glucose solution in glycerine is given, which is instilled into the nose according to the postural method of treatment, or tampons soaked in the solution may be used. We have found vaccines of all kinds of practically no value. The complications of this disease are secondary atrophic pharyngitis, laryngitis, and tracheitis. Autoinflation otitis media from the forcible blowing of the nose is not at all uncommon.

The social side of this disease must be considered, for the individual is very conscious of his affliction and is shunned by others. Employment is difficult to obtain, especially when it entails personal contact with others, and marital difficulties are often encountered. Instances have been reported where separate maintenance has been granted by the court based on the claim of the impossibility of living together because of the fetor.

Hyperplasia

Associated with hyperplastic sinusitis, in which the ethmoid labyrinth, including the middle turbinate body, is involved, there

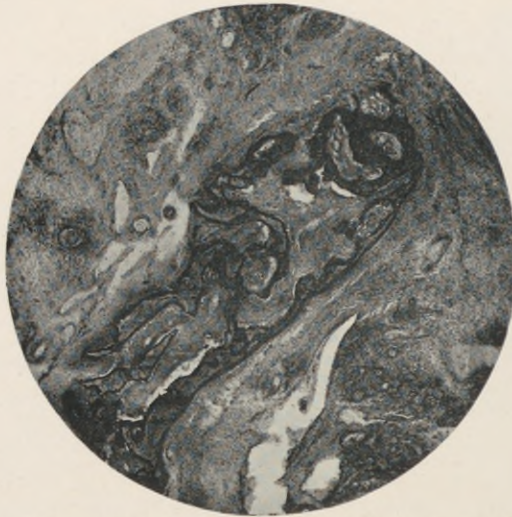

Fig. 102.—Apparently true myxomatous polypi of the inferior turbinate; showing also rarefaction of the bone.

is frequently observed a similar process of the inferior turbinate. The gross appearance of such a change is a boggy or edematous pale inferior turbinate. The microscopic examination reveals the bone rarefied, the mucous glands sparse and the greater portion of the soft tissue not unlike the structure of a myxomatous nasal polyp (Fig. 102).

New Growths of the Inferior Turbinate

Sarcoma and carcinoma involving the inferior turbinate are usually secondary to that of the antrum, nasopharynx or the

superior maxilla. True myxoma or polypi of the inferior turbinate are uncommon. They are to be distinguished from inflammatory edema of the anterior or posterior end. We have had one case of a primary solitary carcinoma of the inferior turbinate in a Chinaman, in which the microscopic picture was melanotic in character. The treatment of malignant growths in this region is radical surgery, supplemented by x-ray or radium.

Lupus or Tuberculosis of the Inferior Turbinate

We have had one case of lupus of the inferior turbinate which was extensively described by Ballenger in his text book. It is interesting to note that this particular patient established her home on an island off the coast of Florida and continued to expose her face, especially the nostrils, to the sun's rays daily for an interval of an hour or two. Within two years, when we again observed her, the ulcerations had healed, leaving a smooth cicatrix and she has remained cured.

Syphilis of the Inferior Turbinate

Syphilitic changes in the later stages are manifest as granulations, exudates and sequestra. The former show the same picture microscopically as elsewhere in the body, but the exudate lacks the round cell infiltration as in luetic exudates elsewhere. (See Fig. 78.) This condition is, as a rule, always associated with a luetic ozena, the characteristics of which are ulceration of the mucous membrane and bone destruction. The diagnosis can be confirmed by a strongly positive Wassermann reaction and the treatment is correspondingly antiluetic. Locally, the cleansing methods should be employed.

CHRONIC RHINOSINUITIS

As in the acute, so may we in the chronic conditions accept the statement that chronic rhinitis is also usually sinusitis. It is a fact, however, that we may have isolated or predominating symptoms and findings of one or the other sinus. It is certainly true as far as one or the other side of the nose is concerned. Again, the subdivision of the anterior or posterior group of sinuses, so splendidly divided by the anatomical structure, the

middle turbinate, can well be thought of as limiting the disease to those parts. The infection of one isolated sinus or cell is not likely to occur unless it be the antrum of Highmore and that of dental origin, and even this will not remain very long without involving at least the ethmoid cells by extension.

As to the frequency of infection of the sinuses, there is a great variance of opinion among authors, and our statistics would show about as follows: Unilateral sinus infection about four times as frequent as bilateral, the anterior group (frontal, anterior ethmoid and antrum) about ten times as frequent as posterior group (posterior ethmoid and sphenoid). In regard to the frequency of infection of the various sinuses of the anterior group, we feel that the antrum of Highmore shows positive evidence of infection more frequently than either the anterior ethmoid or frontal. This perhaps is caused by dental infections extending to this structure. The ethmoid labyrinth is next in frequency affected, and then the frontal sinus. On account of the lack of symptoms, particularly pain or discomfort, when the antrum and ethmoid are affected, the majority of patients do not present themselves until they have the symptom of pain referring to the frontal sinus. This explains to us the discrepancy in the statistics as to which sinus is most frequently involved.

From the pathologic point of view rhinosinuitis must be divided into various types, principally the suppurative or non-suppurative (hypoplastic rhinosinuitis). The suppurative is then subdivided into the pyogenic, tuberculous, syphilitic, rhinoscleroma, actinomycotic. Aside from the simple pyogenic variety, the other forms are quite rare. There are certain generalities that apply to all chronic rhinosinuitis, and then characteristics that are typical of one type or the other. All chronic sinus diseases are associated with discharge, pain or headache, disturbance of the sense of smell, respiratory disturbance, light obstruction and radio-obstruction, disturbances of visual apparatus.

Pathology of Individual Structures

1. Middle Turbinate.—In chronic suppurative sinuitis (pyogenic) local examination shows the middle turbinate to be dif-

fusely enlarged, the mucous membrane injected and thickened, usually covered with streaks of pus. When it is severed during

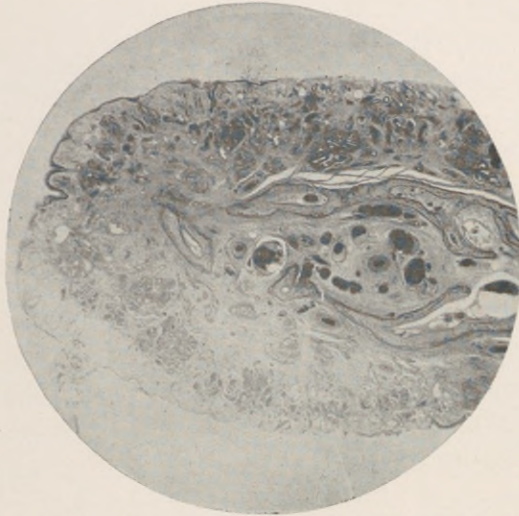


Fig. 103.—Chronic hypertrophy of the middle turbinate in chronic suppurative sinusitis, showing an increase in the normal tissue elements with preservation of the glands.

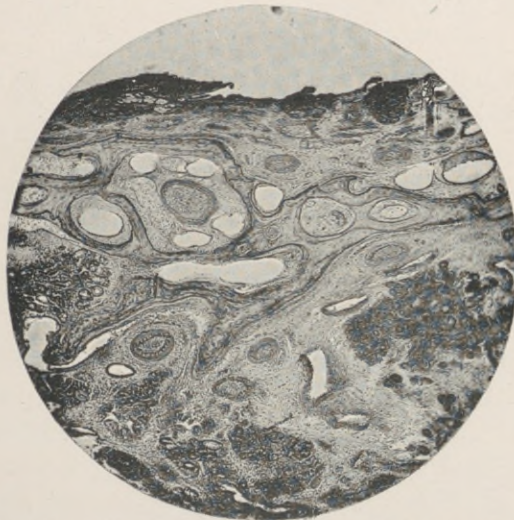

Fig. 104.—Glandular hypertrophy of the middle turbinate, showing besides the increase in glandular elements a rarefying osteitis. Case is one of chronic suppurative ethmoiditis.

therapeutic measures, it cuts through easier than normal, indicating bone inflammation. The findings in the microscopic exam-

ination will depend on the length of time the disease has existed. The epithelium is thickened early, and leucocytic infiltration occurs in irregular distributions. The glands are fairly well preserved (Fig. 103), the bone shows but slight change; later the inflammatory process permeates the soft structures so that the glandular apparatus is very much damaged and its place is taken by young and old connective tissue. The bone is considerably rarefied (Fig. 104) but inflamed, that is to say, the lime salts have been removed by the infection. Not alone is the epithelium thickened, but it is in many places destroyed and replaced by connective tissue. In the event of the conditions being syphilitic, tuberculous, rhinoscleromatous, or actinomycotic, one will hope to find the histological characteristics of these diseases. Rarely is it that the *Spirocheta pallida*, the tubercle bacillus, the bacillus of Frisch (or the bacillus of rhinoscleroma) or the ray fungus can be demonstrated in the nasal discharges, and histology and serology will have to be depended upon for diagnosis.

2. Ethmoid Labyrinth.—Usually after the middle turbinate body has been removed the principal mesial placed cells will be found (bulla naso-frontalis, ethmoidalis, and processus uncinatus) covered with a similarly infected thickened mucous membrane. On cutting into these cells at operation the operator will note the degree of inflammation and softening that has taken place. In many instances free escape of pus from the individual cells will be encountered, and on examination of the particles removed true granulation is often found. This form of ethmoiditis has been recognized as a necrosing variety. At the completion of the ethmoidectomy to the lateral orbital wall, the nature of the wall can be determined by palpation with a blunt instrument. In markedly progressive cases, it has been found to be soft, giving the sensation of wet pasteboard. Microscopic examination of particles of ethmoid cells removed will show the varieties or degrees of inflammation and the epithelium thickened, round, with leucocytic cellular infiltration. The bone varies from a rarefied state of inflammation (Fig. 105) to that of complete necrosis with pus infiltration (Fig. 106), and true findings of granulations in many places. The bacteri-

ologic examination of the pus will usually reveal a mixed infection in which the staphylococcus pyogenes predominate.

From the above-described pathologic pictures the conclusion must be drawn that in the majority of instances conservative treatment, such as washing, suction and local application, will

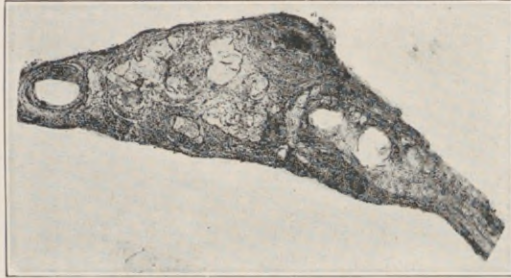

Fig. 105.—Rarefying osteitis of the ethmoids in suppurative sinusitis.

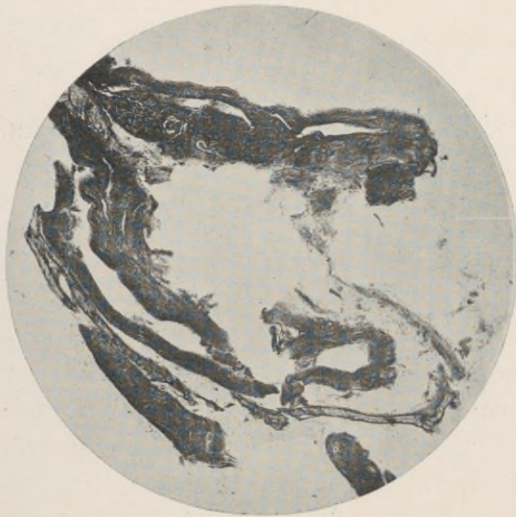


Fig. 106.—Ethmoid curettements in chronic suppurative ethmoiditis, showing areas of bone necrosis.

be of very little benefit; in fact, only the most thorough removal of all the cells, because in most instances all the cells are infected, should be considered. It is true that the anatomical configuration of the ethmoid labyrinth is such that not all the cells can be reached by the usual route (intranasal) but the above treatment refers to all cells that can be reached thus.

Again, no reference has been made as to a division between the anterior and posterior ethmoidal cells because, invariably, they are considered as one, namely, the ethmoid labyrinth, and are operated upon at the same time. For technic employed, the reader is referred to Loeb's text book on "Surgery of Ear, Nose and Throat."

3. The Other Sinus Cavities.—The pathologic changes in the cavities of the frontal, the antrum, and sphenoid will vary but little, since these cavities are all rigid, noncollapsible spaces, lined by modified mucous membrane which serves as their periosteum. They have only one opening for the inlet and outlet for air, for drainage, and ventilation. The only exception is the antrum of Highmore where at times accessory openings are found. The location of the natural openings of the sinuses being in each instance apparently unfavorably placed, usually high, would lead one to suspect that this is an important factor in the resultant pathologic changes. The pathology of these outlets will be considered separately from the cavities themselves. This is especially important in relation to the frontal sinus, the opening of which is in reality a channel—the nasal frontal duct.

(a) The anatomical configuration of the nasal frontal duct is so important in the pathology and treatment of the frontal sinus, that we shall review this phase.

Anatomical consideration of the various structures of the ethmoid and frontal bone would be necessary to elucidate the subject if surgical technic were being discussed, but for the purpose of bringing out the pathological significance as it applies to diagnosis and treatment, it will suffice to say that that portion of the frontal bone where it joins the nasal bones, namely, the internal nasal crest, is the most important. The reactions of the bone of this nasal crest to infections are quite different from the reactions of the bones of the ethmoid cells. The mucous membrane, particularly at the recessus frontalis of Killian, which is a sharply outlined fossa into which the frontal sinus opens, is the most important in relation to blockage to the outlet of the frontal sinus.

The fact that the mucosa is very richly supplied with blood in this locality and serves as the periosteum of the duct, will

explain the ease with which reaction occurs from inflammations, and the persistence in the pathology in the form of swelling which leads to permanent changes within the sinus. Necroses of the bony walls of this duct are not at all uncommon, and the reparative changes following surgical procedures are significant in their bony proliferations.

(b) The ostium maxillaris or opening of the antrum of Highmore being formed by two elliptical thickenings of bone and covered by a mucous membrane, makes it also subject to easy closure. Frequently from the continuous outpouring of pus

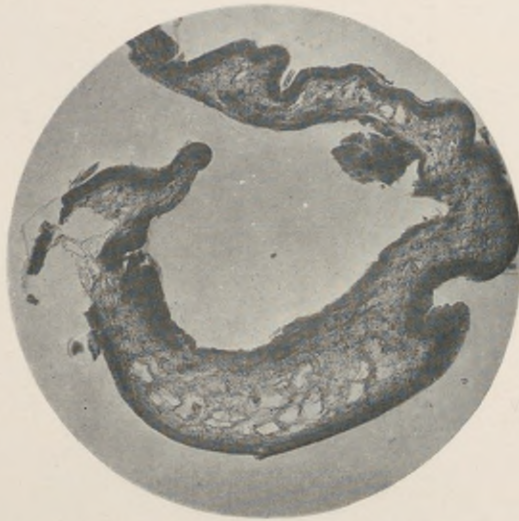


Fig. 107.—Lining membrane of the frontal sinus in chronic suppurative pansinusitis, showing infiltration and thickening, with areas of myxomatous degeneration.

from this opening the bone is irritated to growths, and a pathologic entity has been described by Kaufman (Prague) as osteophytic growths of the ostium-maxillarae.

(c) The sphenoid opening, located in practically the highest point of the sinus, is simplest of all considered from the pathologic standpoint, in that it is very large and made up practically of two layers of mucous membrane, (1) that lining the cavity and (2) mucous membrane of the nose. Therefore, very rarely is it subject to closure. The reason given for the frequency of sphenoid sinus disease is its depth which subjects it to retention.

The lining membrane of the cavities themselves is subject to the changes indicated in the legends of Figs. 107-112: micro-

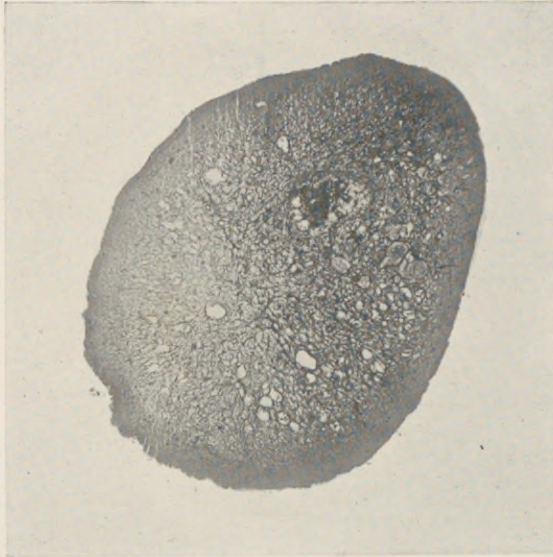


Fig. 108.—Solitary polyp in the frontal sinus in a case of chronic suppurative sinusitis, showing areas of myxomatous degeneration.



Fig. 109.—Same as 108 (high power).

scopically the epithelium thickens, the subepithelial tissue becomes infiltrated with pus and round cells and leucocytes, and

the deeper part of the structure is transformed into a structure not unlike granulations. That, of course, is the more pro-

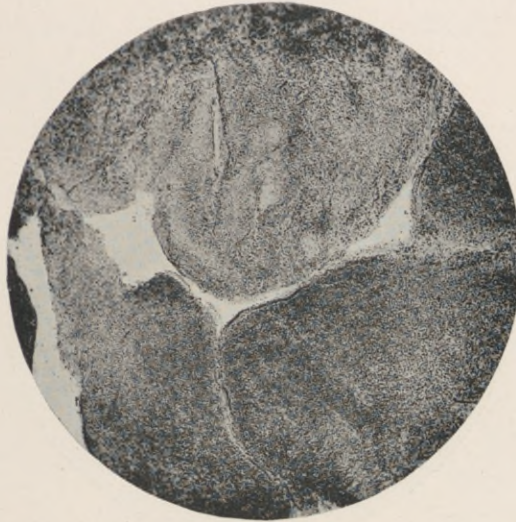


Fig. 110.—Pyogenic membrane lining the antrum of Highmore in chronic, suppurative pansinusitis, showing practically a leucocytic wall.

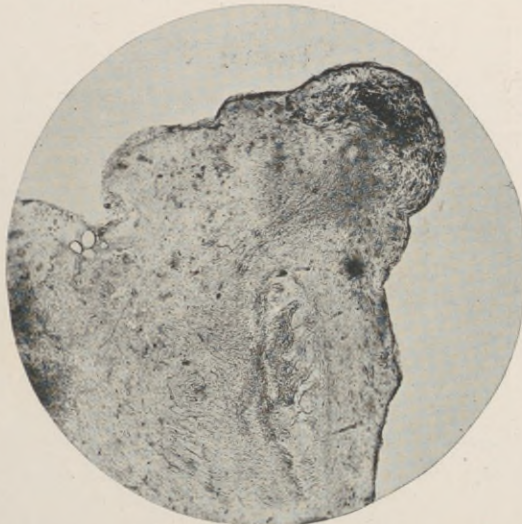

Fig. 111.—Anterior wall of the sphenoid with chronic suppurative pansinusitis, showing connective tissue fibrosis. The bone is not involved to any extent.

nounced picture. In many instances one will discover this preservation of some of the mucous glands. Not infrequently

degenerative processes, such as myxoma, are observed. The membrane is thickened, very much infected, and covered with mucopus. Small areas of epithelial denudation are irregularly



Fig. 112.—Pyogenic membrane lining the sphenoid in chronic suppurative sinusitis.

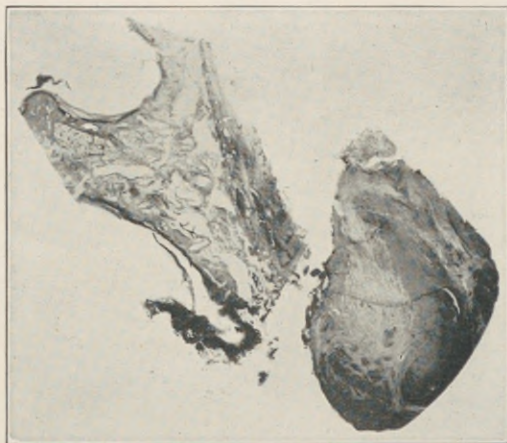


Fig. 113.—Tooth with granuloma attached extending to the antrum, removed in case of unilateral chronic suppuration of the antrum and ethmoid sinuses.

distributed and if the bone is examined at these locations, definite evidences of surface necrosis will be found. In very markedly advanced suppuration of the cavity, it will be found completely filled out with this thickened material, not unlike

a polypus; but, histologically, as will be shown, it is not that. In the antrum of Highmore it is necessary to emphasize the pathology in the vicinity of the apices of the teeth reaching this cavity. The mucous membrane may be entirely wanting, and a granulation containing a fistula may lead to the infected apex of the tooth (Fig. 113). Special attention must be called to the pathologic changes within the sphenoid as well as to the body of the sphenoid proper. We have observed a fair number of cases, clinically, and one postmortem, in which this bone was so softened, due to the process of septic absorption, that a definite diagnostic method was developed, namely transmitted pulsation from the carotid artery, that could be observed in the region of the sphenoid. This was described as an entity by Dr. H. L. Pollock as pulsating sphenoiditis. It is perhaps only coincident, but a fact, that the majority of the cases of pulsating sphenoids in which there is pus present are syphilitic and may have positive Wassermanns.

Hyperplastic Rhinosinuitis

Hyperplastic rhinosinuitis is a very common occurrence and has such a clear clinical picture that there can scarcely be an excuse for an error in diagnosis. We have already called attention to this pathologic entity in the septum and inferior turbinate body. The same process in the bone and mucous membrane takes place in the middle turbinate and nasal accessory sinuses, particularly the ethmoid labyrinth. Clinically the patients present themselves with a definite history of nasal obstruction, especially in the upper straits of the nose, attacks of sneezing from five to twenty-five times in succession, followed by a diffuse watery discharge, at times requiring the use of three or four handkerchiefs. These patients invariably complain about their eyes, and headache is rarely ever wanting, not only headache, but actual neuralgic pains about the head and face. The sense of smell is affected and in most instances it is absent (anosmia) or noticeably deficient (hyposmia). In some it is exaggerated (hyperosmia or parosmia) and in others it is perverted (kakosmia).

The examination is definite and striking, in that the nose is crowded with pale, waterlogged, thick mucous membrane. In-

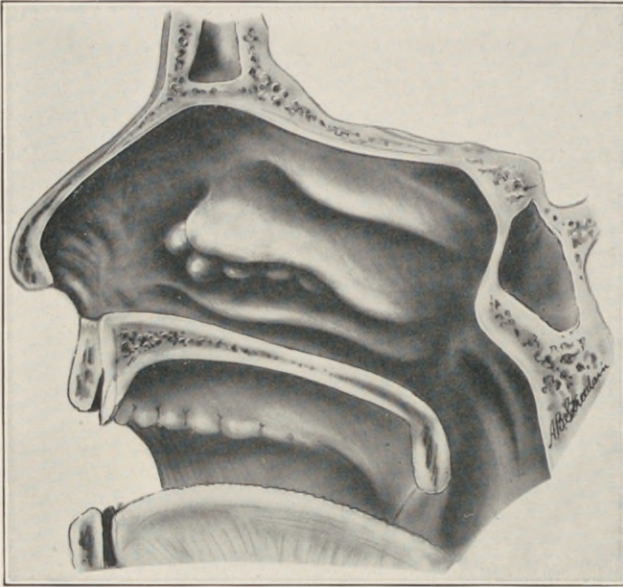


Fig. 114.—Multiple polypi under the middle turbinate in early hyperplastic ethmoiditis.

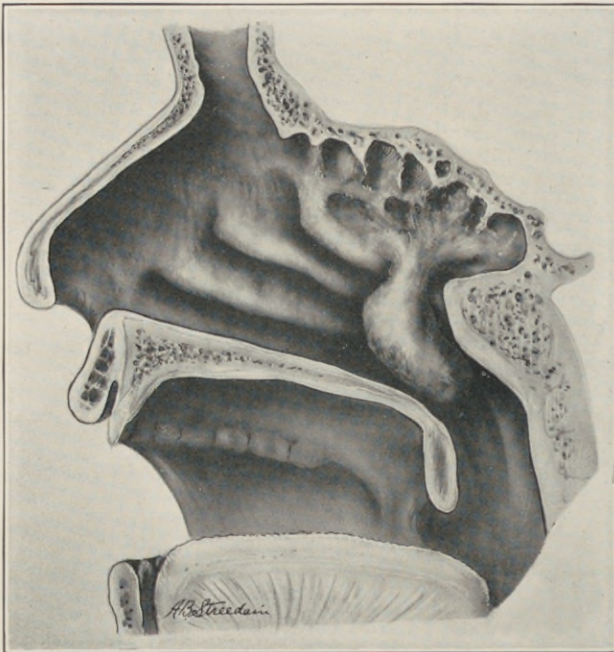


Fig. 115.—Solitary sphenoid polyp.

variably there are polypi present of variable size (Fig. 114), in some instances so large as to protrude externally through the anterior naris, and posteriorly through the nasal pharynx (Figs. 115 and 116). One of the most frequent associated general conditions, and not yet well understood, is bronchial asthma. Macroscopically, the nasal polypi are invariably multiple, may

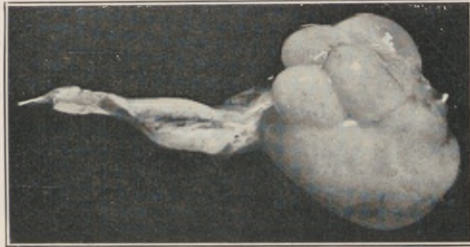

Fig. 116.—Sphenoid polyp.

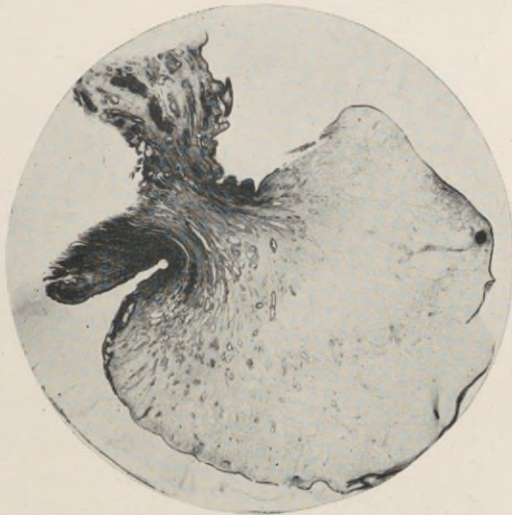

Fig. 117.—Solitary pedunculated fibrous polyp removed from the naso-frontal duct, in case of chronic nonsuppurative sinusitis.

be pedunculated (Fig. 117) or sessile. They are grayish white in appearance, and when sectioned, permit the escape of a watery substance. Only very thin capillaries are found on the surface. Histologically, each polypus has its capsule and stroma of fibrous tissue within which there are cyst formations (Fig. 118) of variable sizes. The blood vessels are very scanty and

only demonstrable on the capsule. There is no evidence of any nerve supply. The mucous membrane of the middle turbinate may itself undergo a similar myxomatous change to that seen in the polypi (Fig. 119), although in most instances there still remains considerable resemblance to a mucous membrane in

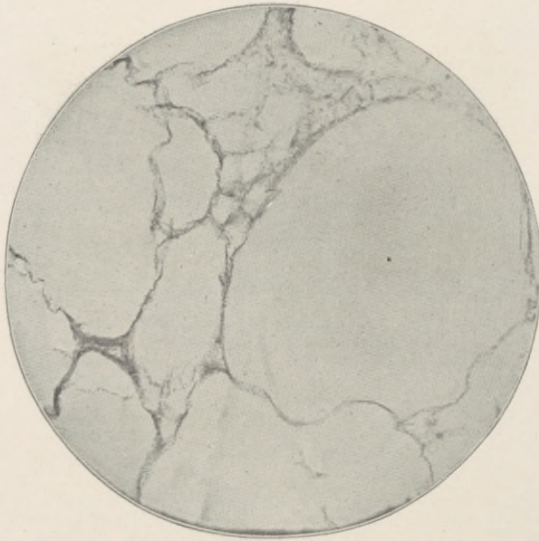


Fig. 118.—Cystic formation in a nasal polyp in nonsuppurative sinusitis.



Fig. 119.—Polyp arising from middle turbinate proper.

that the epithelium is fairly well preserved, the subepithelial tissue up to the bone appears to be in a state of edema (Fig. 120), and there is leucocytic infiltration (Fig. 121). The bone itself is invariably rarefied with large marrow spaces. Sometimes one of these marrow spaces is so distended as to form a

bony bleb (called turbina bullosa) (Figs. 122, 123, and 124). The lining of this bulla (bleb) is endothelial and the fluid con-

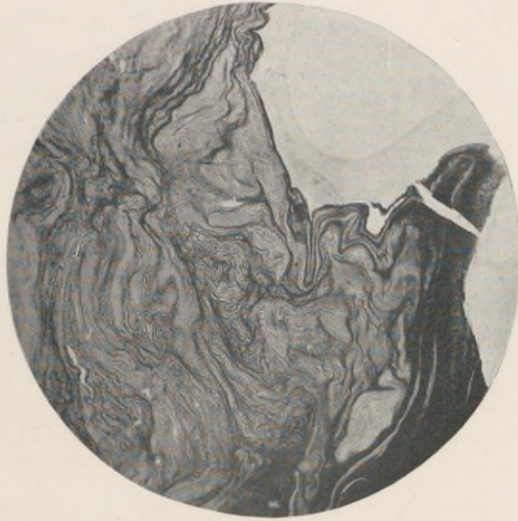

Fig. 120.—Anterior end of the middle turbinate removed in a case of hyperplastic ethmoiditis, showing the loss of glandular structure and fibrous changes.

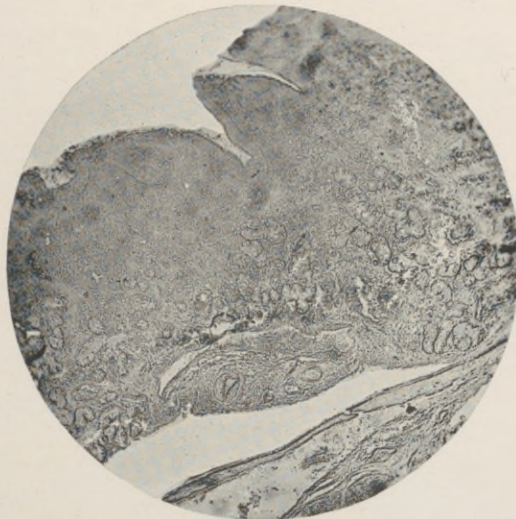

Fig. 121.—Middle turbinate in nonsuppurative sinusitis, showing degenerated glands and infiltrated mucous membrane.

tained therein is of a gelatinous homogeneous character. The ethmoid labyrinth is in a similar rarefied bony condition and

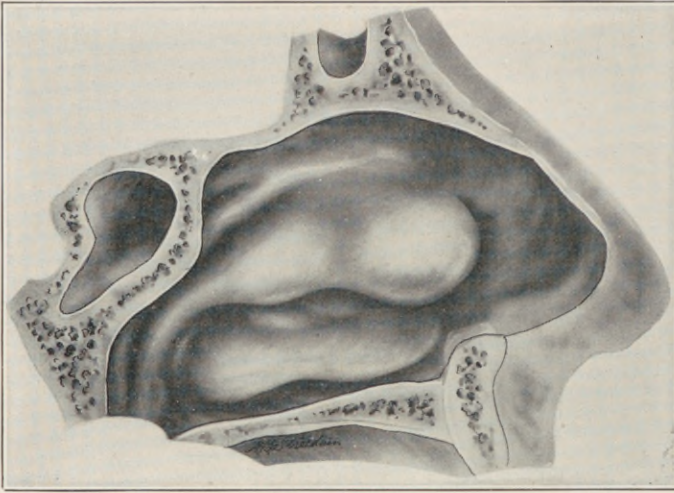


Fig. 122.—Turbina bullosa of the anterior end of the middle turbinate.

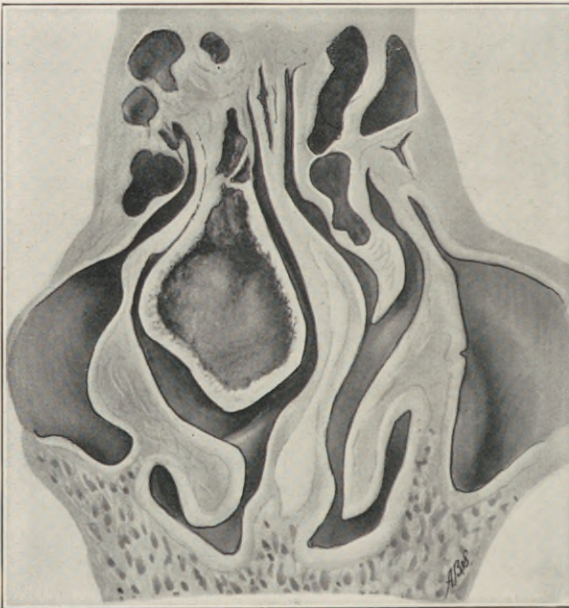

Fig. 123.—Same as Fig. 122 (sagittal section). Turbina bullosa.

when broken into will be found to be filled either with crowded small polypi or myxomatous degeneration (Fig. 125). In opening any of the nasal accessory cavities, one will find the same

type of degenerated mucous membrane and very frequently polypi are present or even crowded within the cavity.

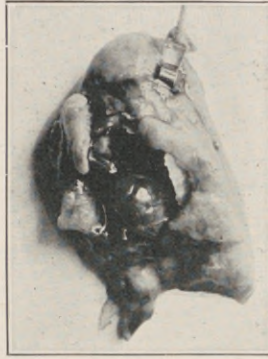

Fig. 124.—Cyst of the middle turbinate.

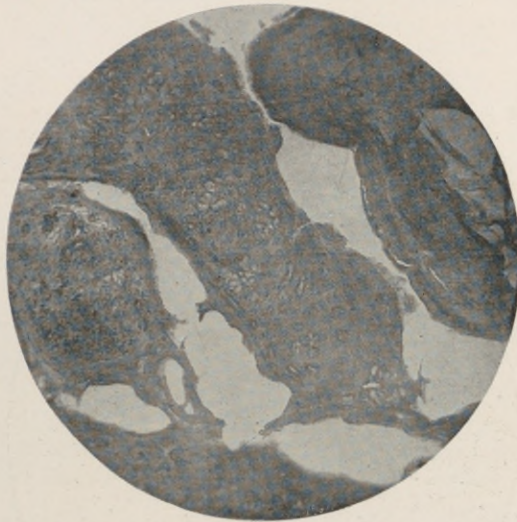


Fig. 125.—Ethmoid mass in case of chronic nonsuppurative ethmoiditis, showing no differentiation but practically complete myxomatous degeneration and some vacuolization.

The Middle Turbinate and Sinuses in Atrophic Rhinitis

The same changes that are observed in the inferior turbinate take place in the middle turbinate, except very much later, and never to the same extent as in the inferior turbinate. The histological examination of the mucous membrane appears to show a persistence in the mucous glands; however, the epithelium

shows that same metaplastic variety (Fig. 126). The sinuses, particularly the ethmoid labyrinth, appear to be infected, but

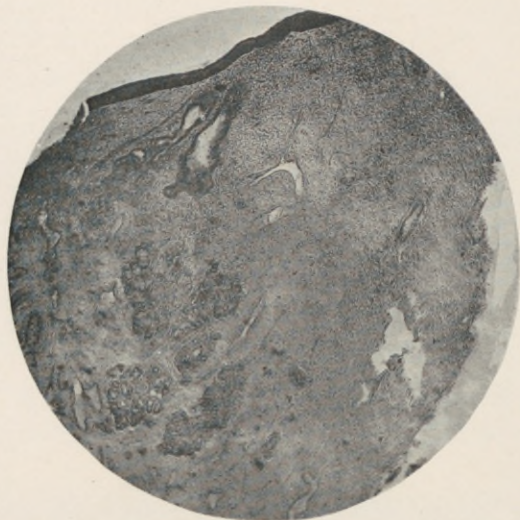

Fig. 126.—Middle turbinate in early atrophic rhinitis, showing metaplasia of the epithelium and persistence of mucous glands.

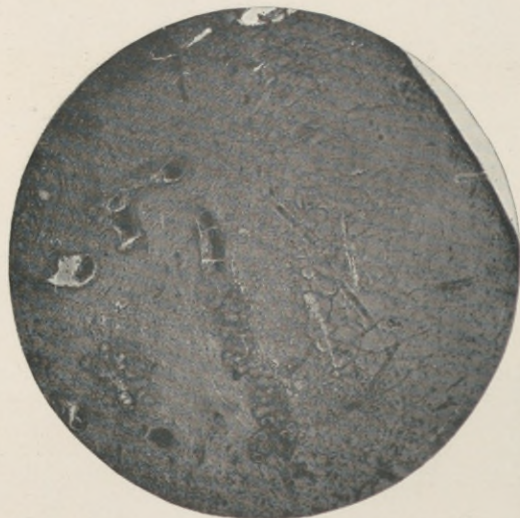

Fig. 127.—Nasal polyp, removed in chronic suppurative pansinusitis, showing myxomatous degeneration.

whether this is a primary or secondary disease has not been determined. All the sinuses are smaller in size and in many

instances the radiogram shows the absence of the frontal sinus; histologically, the bony structures appear to have little if any of the marrow spaces compared to the normal.

Summary

In summarizing the various chronic pathologic states, it must not be overlooked that very frequently chronic hyperplastic sinusitis can become infected and so transformed into a chronic suppurative hyperplastic sinusitis, showing pathologic evidences of both conditions (Fig. 127), viz., hyperplastic and suppurative. Again, a chronic sinusitis does very frequently take on an acute exacerbation in which the pathology will show the evidences of chronic, as well as the acute, conditions (refer to chapter on acute inflammation).

SARCOMA OF THE SINUSES

We have already alluded to this subject in connection with sarcoma of the external nose, but as an entity confined to the sinuses, it is in the antrum that we have met the disease most

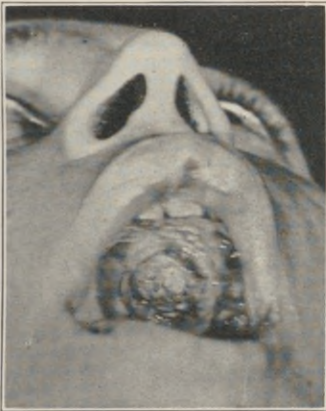

Fig. 128.

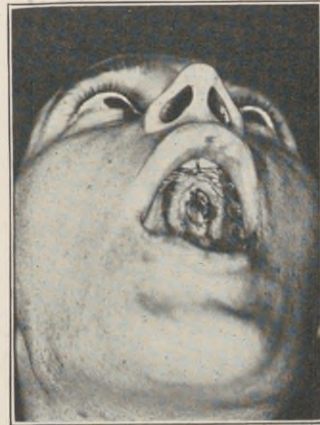

Fig. 129.

Figs. 128-152.—Sarcoma of the antrum treated by surgery, x-ray and radium. (For description see text.)

frequently. As to its origin, we feel that it springs most probably from the junction of the posterior ethmoid and antral wall.

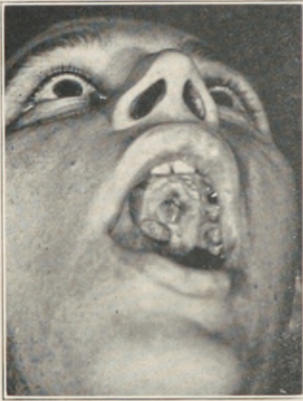

Fig. 130.

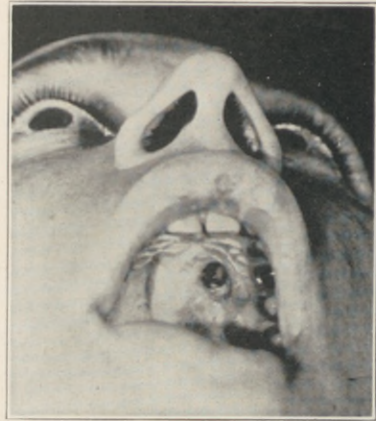


Fig. 131.

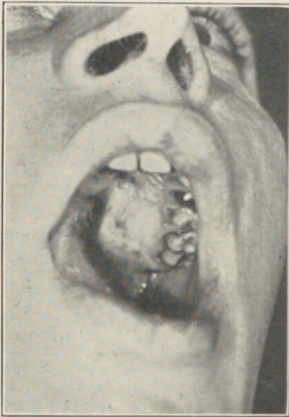


Fig. 132.

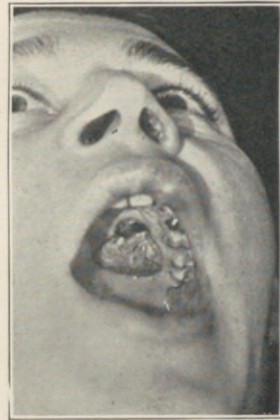

Fig. 133.

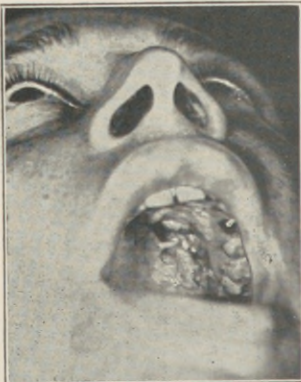


Fig. 134.



Fig. 135.

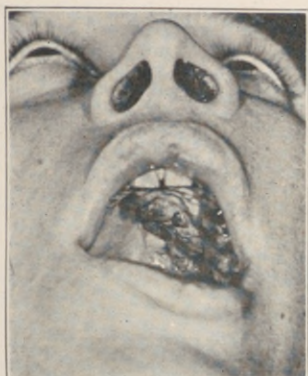

Fig. 136.



Fig. 137.

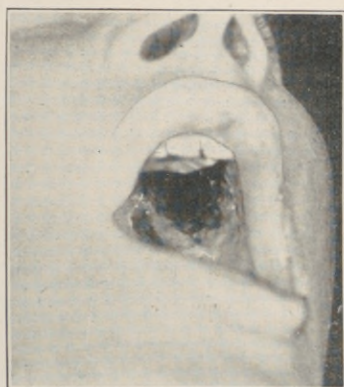


Fig. 138.

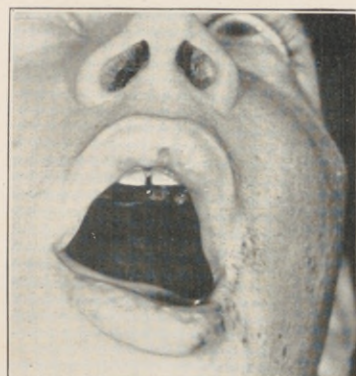

Fig. 139.

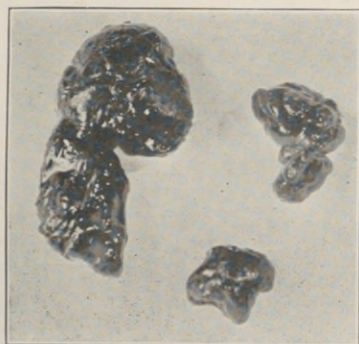


Fig. 140.

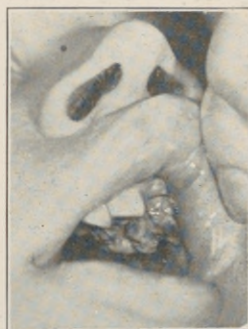

Fig. 141.

One of the most pronounced and interesting cases of sarcoma of the sinuses that we have observed, had its origin from the alveolar process. The course of this case will be best studied from the photographs (which in our practice are always stereoscopic photographs) taken at various times during the three



Fig. 142.

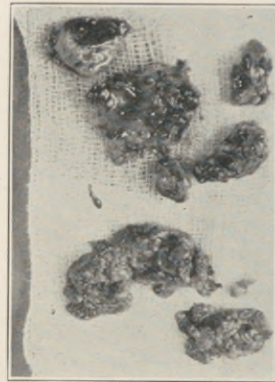


Fig. 143.



Fig. 144.

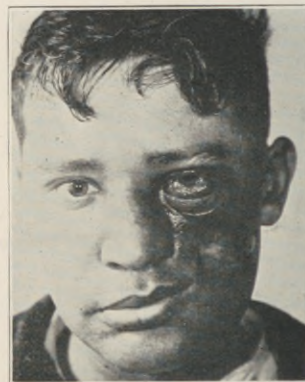

Fig. 145.

years we observed and treated the patient (Figs. 128 to 152). (128) When first presented (June 19, 1920). (129) Radium needling result (June 24, 1920). (130) Recession of growth (July 1, 1920). (131) Perforation into antrum (August 6, 1920). (132) Flattening out of growth and loss of teeth (November 30, 1920). (133) Growth returning (January 18, 1921). (134)

Greater recurrence (July 30, 1921). (135) Progress of growth into antrum (November 6, 1921). (136) Growth showing ulceration (November 6, 1921). (137) Reoperated and specimens showing maxilla (November 9, 1921). (138) Radical exenteration—partial resection of upper jaw (November 15, 1921).

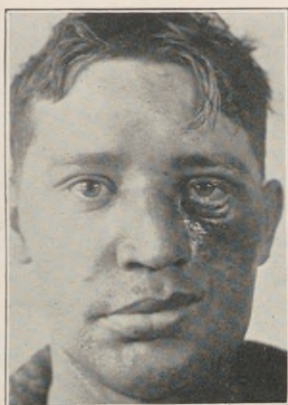

Fig. 146.

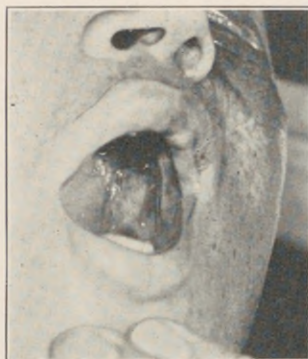


Fig. 147.




Fig. 148.



Fig. 149.

(139) Artificial prosthesis improving feeding and speech (November 14, 1921). (140) Recurrence and more tissue removed by cauterization (December 3, 1921). (141) Recurrence in two weeks (December 21, 1921). (142) Greater recurrence showing externally (December 21, 1921). (143) Tissue removed (December

24, 1921). (144) Massive dose of radium applied internally and externally with (Dose 150 mg. for 24 hrs.) checking of growth. Plus x-ray (S. W. L.) (February 11, 1922). (145) Reaction following—skin discolored, eye intact (June 30, 1922). (146) Beginning fistula externally below orbit (July 7, 1922). (147) No growth showing in cavity (July 7, 1922). (148) Deformity

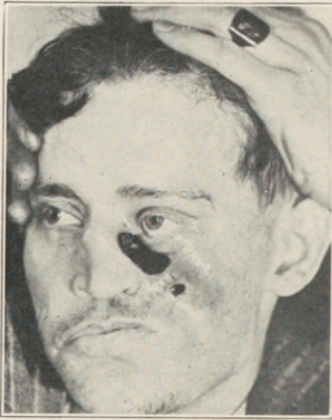

Fig. 150.

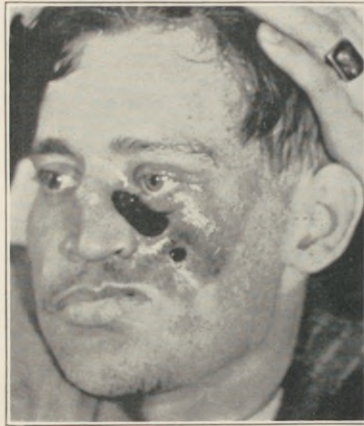

Fig. 151.

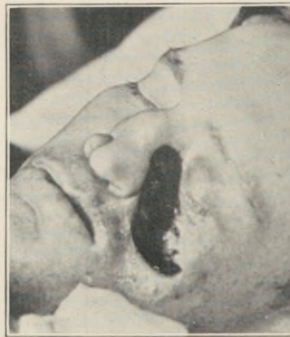

Fig. 152.

following destruction (September 7, 1922). (149) Greater deformity—eye motility and vision remaining normal (October 18, 1922). (150) Greater external destruction; small tendency to recurrences, easily controlled by radium (January 4, 1923). (151 and 152) Greater destruction to exitus from general weakness; but no evidence of recurrence (January 4-15, 1923).

In the majority of instances the tumor is confined to one side of the nose and sinuses, but in several instances that we have

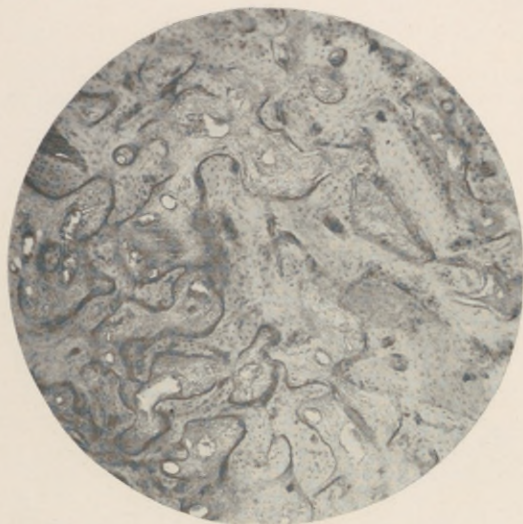


Fig. 153.—Spindle cell sarcoma of the anterior wall of the antrum of Highmore, associated with chronic suppuration.

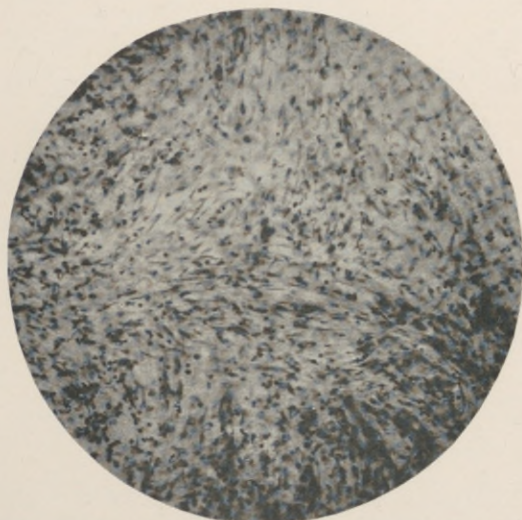


Fig. 154.—Large, small, round, and spindle cell sarcoma of the antrum.

observed, the septum was destroyed in the process and the other side was subsequently involved. When the progress of the growth of this neoplasm is backwards towards the sphenoid and

apex of the orbit, there will be observed additional symptoms referable to the nerve supply of the eye muscles (paralysis of

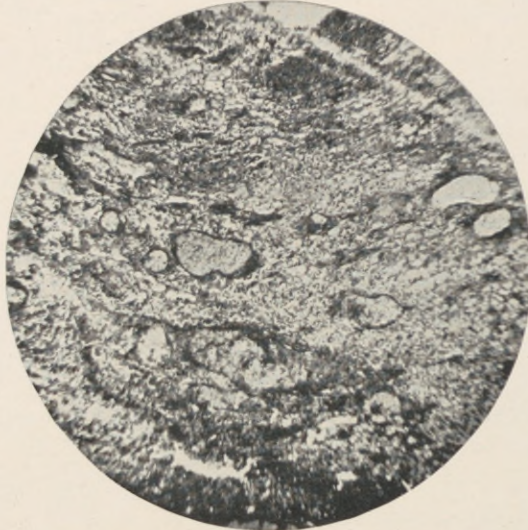


Fig. 155.—Sarcoma of the nose, showing a highly vascular growth.

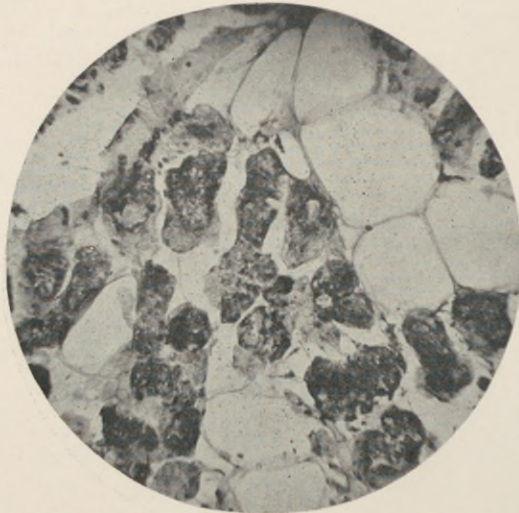


Fig. 156.—Melanosa sarcoma, high power. The pigment granules are clearly seen in the cells.

the recti). These cases develop very early meningeal involvement and die from extension of the growth. One of our sphenoid sarcoma cases simulated very much a hypophyseal neo-

plasm. This patient was treated with radium needles and very rapidly succumbed to meningitis. In another sphenoid sarcoma, involvement of the carotid artery was followed by a spontaneous rupture of the vessel with uncontrollable hemorrhage and death. Macroscopically the growth appears so characteristic that it leaves no doubt in diagnosis. Frequently particles of the bony structures, especially when in the region of the antrum, are found within the tumor mass. The bone itself may well preserve its structural characteristics (Fig. 153). The histological changes vary from that of small spindle cell, to




Fig. 157.—Radium exudate in the same case as in Fig. 156. The exudate consists chiefly of fibrin and disintegrated cells.

that of large spindle cell, round cell and mixed cell (Fig. 154). At times the sarcoma contains many blood lakes and vessels (Fig. 155). Very rarely are found tumors containing the giant melanotic cells which give the poorest prognosis because of their rapid destruction (Fig. 156). Following radium treatment of sarcoma marked exudates form which differ from exudates due to other causes as well as radium exudates in other pathologic structures (Fig. 157).

Treatment.—In the treatment, aside from surgery, radium and x-ray, Coley's toxin has been employed by us without any

appreciable benefit. Electrothermic coagulation, either by the fulguration or the surgical diathermic methods, has been employed by us with more or less success.

The various complications that may result during the course of the disease or during treatment such as hemorrhage, pain, toxemia (particularly the radiation toxemia), anemia and the ultimate deformities, should be met with by the accepted methods. Glandular metastases we have not observed, but when regional adenopathy occurs, it is taken to be of infectious origin in contradistinction to carcinoma, where metastases are very frequently met with.

CHAPTER IX

NASOPHARYNX AND OROPHARYNX

The most frequent chronic pathologic conditions within the nasopharynx or oropharynx are the adenoid changes, and since the symptom-complex, as well as the treatment, is so closely associated with chronic tonsillar disease, it will be more practical to describe these conditions as an entity, namely, tonsil and adenoid diseases, in a subsequent subhead.

1. CHRONIC TUBITIS

As a sequence to acute conditions of inflammation of the ostium tubae there remains a marked thickening of both the lips and the contiguous mucous membrane of the tube at least as far as the isthmus. Either direct or indirect inspection shows a chronic engorgement, and often a plug of glairy mucus within the opening of the tube. Digital palpation will give the impression of stiffness, compared to a normal tube.

Treatment.—The treatment is entirely antiphlogistic, and the best means is to apply directly by nasal route, cotton applicators saturated with ichthyol and glycerine in and about the lips and mouth of the tube. After a course of a week or two of such treatment the direct application of a weak solution of silver nitrate (2 to 5 per cent) to the tube, will further relieve the inflammatory process. Subsequently finger massage by way of the mouth will hasten the absorption of the chronic inflammatory products. The use of a eustachian catheter for the treatment of the tubal inflammation proper is to be preferred. The ichthyol and glycerine can thus be introduced by way of the catheter, and the silver nitrate also, although it is preferable to employ a flexible silver wire probe, a small pledget of cotton which is saturated with the silver nitrate solution being wound on the rough end. This being passed through the catheter, through the lumen of the tube as far as the isthmus, can be allowed to remain *in situ* for a minute or two. It must be stated

here that this process rarely limits itself to the area described, but extends on through the remains of the tube, into the cavum tympani, causing the pathologic changes which will be taken up later.

2. PHARYNGITIS—LATERALIS HYPERTROPHICUS

Pharyngitis is one of the commonest forms of chronic inflammation found in an adult, and one that is capable of producing a great variety of symptoms. Inspection usually reveals a mass of thickened mucous membrane behind the posterior pillar of

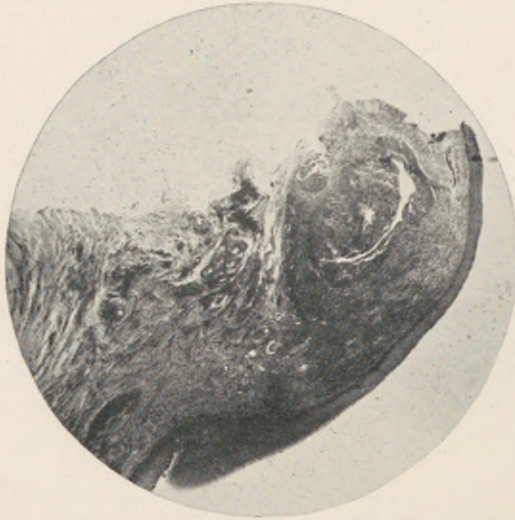


Fig. 158.—Lateral pharyngitis (chronic) showing thickened epithelium, bone, lymphoid tissue, round-celled infiltration and old connective tissue.

the fauces, incorporating it. It extends from the lowest portion of this pillar upwards, as far as the eustachian orifice and even behind the posterior lip into the Rosenmueller fossa. On very close inspection one can frequently see lymphoid masses in this structure, especially behind the soft palate. Histologically, it is made up principally of markedly thickened mucous membrane, rich in mucous gland and lymphoid tissues. The subepithelial tissue is much increased in connective tissue of all varieties from round cell to senescence (Fig. 158). The treatment is most satisfactorily accomplished by the removal either by actual cautery or excision. In order to reach every part of it,

especially that about the eustachian tube, it is best to pass a urethral rubber catheter through the nose and out through the mouth, drawing the catheter forward laterally and upward, thus exposing the area to be treated either by direct inspection or by the aid of a postnasal mirror (Fig. 159).

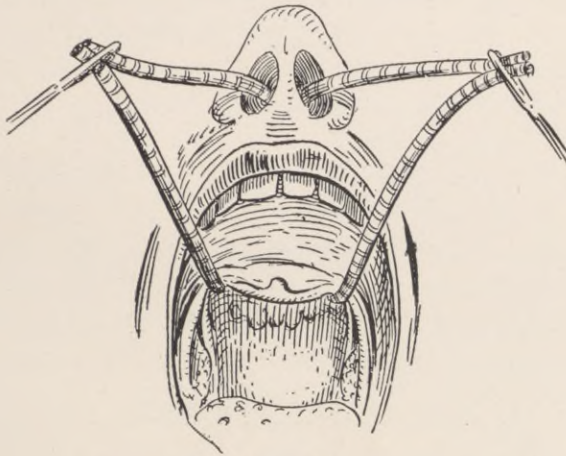


Fig. 159.

3. ATROPHIC PHARYNGITIS

Atrophic pharyngitis is most frequently secondary to either a chronic suppurative sinus disease or atrophic rhinitis. Clinical examination shows the surface to be dry and somewhat glazed in appearance. It is of a deep red color, and in the effort of swallowing the motion of the mucous membrane is limited. Although this process is principally confined to the naso- and oro-pharynx, yet not infrequently will one observe the extension into the larynx, especially on the side of the vocal cords. In this particular location more often than in the oropharynx, crust formation develops; however, in the nasopharynx this finding is not at all infrequent. Histologically the prominent change is the marked round-cell infiltration with the loss of the surface epithelium, and wasting of the mucous glands, while the blood vessels are very markedly increased in size and number.

Treatment.—Treatment may be divided into two types, although both are essential: (a) to the etiologic factor, namely,

the sinus disease or atrophic rhinitis, and (b) directly to the atrophic process of the throat.

The local treatment that has given us the most satisfactory result, especially from the annoying symptom of dryness, has been digital massage by means of a rough finger cot. It may be dipped into an oily solution to prevent trauma. The topical application to the entire pharynx, by means of cotton wound probes, of Mendel's solution is still one of the most accepted methods of treatment.

Iodine crystals	1 gr.
Potassium iodide crystals	10 gr.
Glycerine to make an ounce.	

The patient will obtain a great deal of relief from the instillation through the nose, with the head tilted back, of a solution of glucose in glycerine (10 per cent).

4. THORNWALDT'S DISEASE

(Chronic Bursitis)

Thornwaldt's disease is comparatively rare and yet very frequently overlooked because the one cardinal symptom and finding is not recognized; namely, the periodical uncontrollable outpouring of a stagnant fluid. If one be fortunate enough to have the patient return this fluid, the examination will reveal the following characteristics—acid in reaction, rusty in appearance, foul odor, and if it is permitted to sediment in a conical glass or centrifuge, it will reveal microscopically clumps of mucus, many varieties of bacteria, some red blood corpuscles. The bursa, which is an embryonic remnant or incomplete closure of the recess which is formed at the shutting off of the sella turcica, becomes infected. The constant accumulation of fluid causes further increase in size by distention and acts mechanically not at all unlike an esophageal diverticulum.

Inspection, either direct or indirect method, will show in the median line of the nasopharynx a swelling, which may vary in size according to the amount of granulation tissue and diseased mucous membrane within the bursa or whether the contents has been expelled or not. The opening of the bursa which is located

usually at the highest point is not very readily made out and really represents a slit rather than a round opening. By pressing on the swelling from below upwards, one may determine this opening by seeing the fluid escape. A blunt-pointed cannula introduced into the opening will enable the examiner to outline the cavity, and the injection of a syringe of bismuth paste through the cannula will further outline the size. An x-ray picture, lateral stereoscopic, will give perfect information. The pathologic structure of this sac is a fairly normal mucous membrane externally, whereas the interior is made up of markedly thickened pyogenic membrane; but no evidences of any mucous glands, and the above-mentioned mucous clumps of the fluid which must have found their way in from the nose and throat.

Treatment.—The treatment is to slit this bag from the opening down to the lowest level and if possible make two lateral incisions. By means of a curet, thoroughly scrape away this pyogenic membrane. Subsequently cauterize this raw surface so that a perfectly smooth scarred area is obtained. It is important that no recesses or vestiges of this sac remain, else the process will recur.

5. SYPHILIS OF THE PHARYNX

Both the secondary and tertiary lesions of syphilis are observed within the pharynx, although primary chancre has also been described in this locality. One of the earliest evidences of a secondary stage of the disease is the pharyngitis which in reality should be classed as an acute inflammatory process. It manifests itself in a very violent inflammation of the mucous membrane and it appears very much thickened and devoid of secretion. It is, however, of very short duration, irrespective of treatment, and usually returns to its normal state. It is quite different in tertiary lesions, which are very frequent in this locality, all the way from the vault of the pharynx to the pyriform fossae. The gummatous process, which is usually a diffuse swelling, has a cyanotic appearance, and within a very brief period of time will show in the center a yellowish or breaking down appearance. Following this disintegration there appears a

deep sulcus, crater-like lesion, lined with necrotic tissue and the line of demarcation of the slough or the gumma can be made out by the surrounding violent inflammation. If not treated and this sloughing is allowed to go on, there will be seen a sharp punched-out lesion with unhealthy granulation in the bottom. The secondary infection of such an ulcerated process adds frequently the element of suppuration to it. A bit of tissue from the margin of the ulcer microscopically examined will show the typical histological elements of the syphilitic lesion, namely, marked round-cell infiltration, with a scarcity of blood vessels,

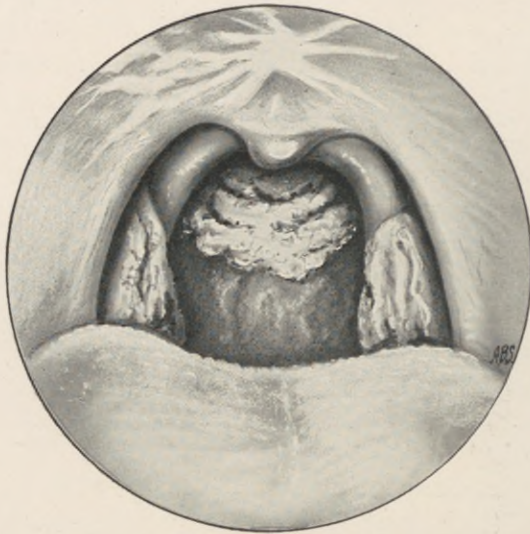

Fig. 160.—Healed out luetic cicatrices of the velum palati.

and those that are present will show the arterial walls thickened and the lumina blocked (endarteritis obliterans).

Treatment.—If treatment is instituted early enough, some of the destructive changes often including the uvula will be halted. However, at its best, the end results of cicatrization will occur (Fig. 160). In those cases where the process has broken down and sloughed, the resultant cicatrix is pathognomonic of this disease. It is white, radiating stellate in appearance, deforming the remaining normal contour of the pharyngeal structure (Fig. 161). The treatment, of course, *a priori* is very energetic, antiluetic, making use of the three principal substances, mer-

cury, arsphenamine, and potassium iodide. Locally the gummatous or swollen process can be very little influenced. In conjunction with the general treatment one may hasten absorption and improve the circulation by constant warm applications, both in the throat as well as externally, by steam inhalations or normal salt solution gargles. When the process has once broken down, the sooner the slough is thrown off the better. Right here great caution must be exercised against the mechanical removal of this slough, because one never can predict how much tissue can be saved by the aid of general medication.

The use of mild irrigation of the crater under direct inspec-

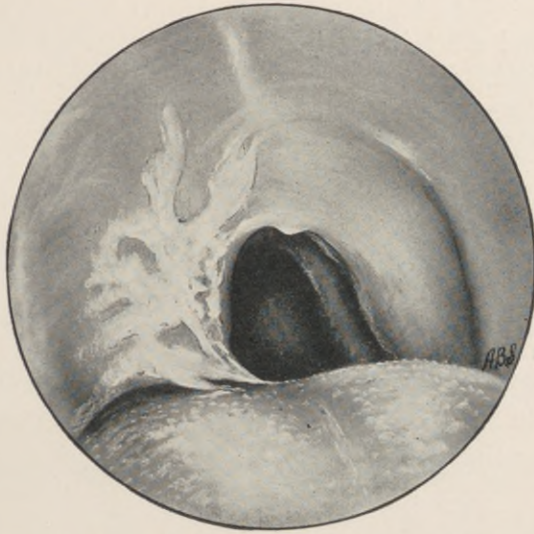


Fig. 161.—Pharyngeal stenosis—healed lues.

tion, the application of mild antiseptics are advocated. Nitrate of silver (either in stick or strong solution) carefully applied to the crater will hasten the cleansing process. At times the crater extends into the tonsillar fossa; in such an event, the cavity may be filled and caused to retain by position, balsam of Peru or solution of methylene blue, acriflavin or Dakin's solution. The same is true of an ulceration in the vault of the pharynx. In such an event the head tilted below the level of the neck, will help to retain these fluids in that position. Once the ulcer is thoroughly clean, it should be cauterized with the actual stick

of nitrate of silver. This will hasten the process of cicatrization. Rarely is the symptom of pain present in spite of this tremendous destruction, but when present, will require heroic doses of morphine because it is the actual neuritis that is causing this (nerve exposure).

The pathology of the cicatricial changes is so individual as to require special technic in treatment. Suffice it to say, however, that whatever is done by way of relief of the cicatrices, must be of extensive resection and long continued after-treatment, otherwise the difficulties will recur. In assisting the softening of the cicatrices, especially in strictures caused by adhesion of the velum palate to the posterior wall of the pharynx, we have found electrically heated bougies (Fig. 208) to be of especial benefit. The use of thiosinamin, gr. iii, t.i.d., or any of its derivatives (fibrolysin, 1 ampule three times weekly hypodermically) by internal and hypodermic administration, may aid in softening the cicatrices.

6. TUBERCULOSIS OF THE PHARYNX

Primary tuberculosis of the pharynx is a very rare disease, but we have observed it twice in our experience. In both instances the ulceration was located in the postnasal space, and fairly close to the median line. The history of the one case is so interesting that we shall describe it in detail, thus covering the subject:

Patient, Mr. X, constantly desired to clear the back of his nose, and was very much annoyed by crust formations, of which he could rid himself only by removing them with his fingers, which procedure was always accompanied by bleeding. His complaint had lasted over three years when he first presented himself to us. On examination we found an ulcerated swollen area on the vault of the pharynx and we considered the possibility of infected remains of an adenoid. In removing the tissue and examining it microscopically, we found it to be typical of tuberculosis, namely, many giant cells, epithelioid cells, round-cell infiltration, slight amount of stroma, and no lymphoid tissue. The remaining surface after the operation appeared to be the anterior common ligament. The healing process was very slow and after three months of attempting to heal

the surface, we removed some particles of tissue, which still showed microscopic evidence of tuberculosis.

The patient's two cardinal symptoms were those of dysphagia and radiating pains toward the back of the head. An x-ray picture showed that there was no evidence of any bone lesion of the vertebra. By means of rubber catheter retraction of the soft palate (Fig. 159) this area was made more accessible for the application of the actual cautery. As a result of this latter treatment, more rapid healing took place, with a perfectly smooth cicatrix. There resulted, however, some permanent difficulty in deglutition, but of no particular consequence. I failed to state that the regional lymphatic glands of the neck in the posterior triangle on both sides were markedly enlarged during the entire process of the disease, on the left side breaking down and necessitating operation. Examination of part of the gland removed, demonstrated tuberculosis. This patient's chest and the rest of the body were entirely free from tuberculosis, and seven years later all that remained was a slight enlargement of the glands above mentioned. For this condition he has received a course of x-ray treatment combined with tuberculin injections.

Secondary tuberculosis of the pharynx is an entirely different disease, for we find usually in the terminal stage pulmonary tuberculosis in connection with tuberculous laryngitis. This part of the subject will be dealt with in connection with the laryngeal diseases.

7. TUMORS OF THE PHARYNX

The most frequently met with neoplasm of the malignant type is fibrosarcoma. Usually the patients have presented themselves to us after the postnasal space is filled out, the soft and posterior part of the hard palate pushed down, and part of the growth visible in the oropharynx. It is of a pinkish-gray color, somewhat resistant to the touch and smooth. The histological examination which is usually deferred until the growth is removed on account of possible danger of hemorrhage, will show the type of sarcoma, whether round, small or large spindle celled. It is also important to note whether the blood lakes are in excess or not. The most important in the histological picture is the amount of fibrous tissue—stroma—present. This usually denotes its malignancy, or rather the benignancy. The more

fibrous tissue, the less malignancy and the less probability of recurrence when removed.

The greatest complaint of these young patients is, of course, respiratory, especially if the neoplasm reaches well down into the pharynx, thus when falling asleep, the tongue comes in contact with the growth, causing immediate choking. The other symptoms are deafness due to the long-continued block of the eustachian tube, with secondary involvement of the middle ear. Again pressure on the nerves causes considerable pain radiating from the head and neck. The speech is definitely nasal. In some of the cases where the growth becomes infected, and ulcerates, there is bleeding and temperature with the secondary anemia present.

Treatment.—The treatment is invariably surgical. However, we should give radium, x-ray, and surgical diathermy an opportunity to prove their worth. By means of radium needles we have been able in several cases even in the recurrent type, to riddle the growth from all directions and thus effect its disappearance. In those cases we were better able to make out the possible origin than when we removed the growth surgically. Contrary to the accepted belief that these neoplasms arise from the sphenoid, ethmoid, posterior lateral wall of the nose, we have found their origin to be from Rosenmueller's fossa. In the surgical treatment the soft rubber catheter retraction of the soft palate (Fig. 159) should be used.

We have used radium needles directly into the growth as a preliminary measure to surgical removal. The reaction to the radium shows a definite increase in the amount of fibrous tissue and a definite diminution in the size and number of the blood vessels and blood lakes. We have used both the cold wire snare, the electrically heated snare, and the method suggested by Stuckey of removal with a heavy postnasal forceps. The resultant hemorrhage is at times very alarming, and it is well to have ready, tied to the aforesaid rubber catheters, a postnasal tampon, which as soon as the growth is delivered is forced back into the postnasal space and retained there by the two tapes coming through the nose, which are tied over a gauze sponge across the columella. Such tampons should remain in place for twenty-four hours and if bleeding still occurs on their removal,

they should again be replaced for another twenty-four hours. After the surface at the point of severance has healed, and should there be observed any remnant of this growth, it is proper to cauterize this area by the actual cautery.

8. SARCOMA OF THE TONSIL

While sarcoma of the tonsil is not so frequent as the previously described disease, it is, nevertheless, of sufficient importance to mention the fact that its growth is much more malignant. The appearance of the growth is at first like that of a hypertrophic tonsil, but soon reaches into the supratonsillar area, causing it to bulge not unlike the peritonsillar abscess. It has frequently been mistaken for this condition, since limitation and fixation of the lower jaw is an accompanying symptom. The speech defect here is of the "mouth full of mush" type; the patient, however, has rarely any difficulty in breathing until very late, because the nose is free. Glands of the neck are rarely present. The histological examination of this group is usually of a lymphosarcomatous nature (not Hodgkin's). Blood lakes are very scarce, and there is very little fibrous stroma present. The treatment of this condition is most satisfactory by either radium or the x-ray, and if surgery is employed then these agents should be made use of afterwards, because recurrences are very common. An old treatment which we have favored in these conditions has been the use of Coley's toxins (*Streptococcus erysipelatis* and *Bacillus prodigiosus*). The surgical technic in removal is usually wide excision of the growth taking with it normal tissue of the palate and muscles surrounding the growth. The danger of hemorrhage is so great that a preliminary ligation of the external carotid artery is to be advised.

9. CARCINOMA OF THE PHARYNX

The most frequent location of cancer of the pharynx is at the junction of the base of the tongue, *plica triangularis*, and the base of the tonsil. The usual appearance is that of an irregular, pinkish mass, surrounded by infiltrated areas of the structures named. The tongue is limited in its protruding action on the affected side. Glands in the submaxillary region or near the

angle of the jaw are always enlarged, and frequently matted together with the surrounding structures. Radiating pain into the ear is an early symptom and painful swallowing soon follows. The removal of a particle of this tissue will disclose the typical epithelial cancer in which the pearls are very numerous. This is usually so rapid in its progress as to very early encroach upon the larynx (Fig. 162) at least to the epiglottis, thus interfering both with breathing and speaking. Only a step further and the mouth of the esophagus will be involved, causing more difficulty in swallowing.

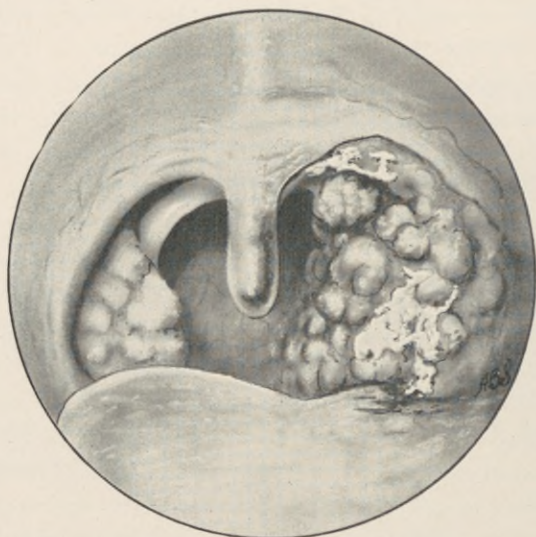


Fig. 162.—Unilateral carcinoma of the tonsil.

Treatment.—The treatment is rarely feasible of surgical attainment, because the patients usually present themselves after the glands have become involved. In the many attempts that we have made in resecting the growth wide of the margin, within the pharyngeal cavity including the base of the tongue and the removal completely of all the tributary glands of the neck externally, with the preliminary ligation of the external carotid and the subsequent use of x-ray and radium, we have not in a single instance been able to save the patient nor even slow the tide. We have, however, treated a limited number of cases recently of this type by use of the combined treatment of radium

and electrothermal coagulation from within and the short wavelength x-ray therapy from without, that promise to give better results.

10. TONSIL AND ADENOID DISEASES

Probably the most important subject in diseases of the pharynx is that of the pathologic changes in the lymphoid tissue. Three definite structures, one of which is bilateral, comprise the anatomical group, namely the lymphoid tissue in the nasopharynx, called adenoids, the two definitely incapsulated lymphoid glands situated laterally in the oropharynx, called faucial tonsils, and a conglomerated mass of lymphoid tissue at the base of the tongue,

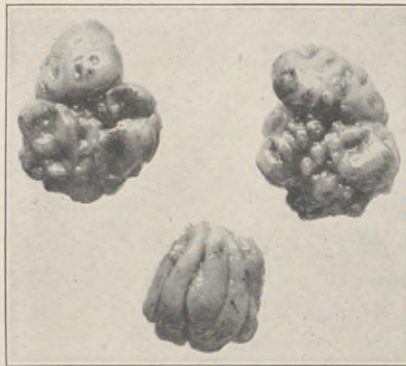

Fig. 163.—Hyperplasia of tonsils with infection, also adenoid mass.

known as the lingual tonsil. The distribution of the solitary lymphoid follicles in the remains of the pharynx must also be reckoned with in recognizing diseases of the pharynx. The two principal types of pathologic changes that these lymphoid tissues are subject to are (a) hyperplasia, (b) hypertrophy with infection. In the former, which usually occurs in infants and young children, there is a marked reproduction of the normal lymphoid cells, with very little, if any, of the growth of connective tissue (Fig. 163). The appearance of this hyperplastic structure is pale, smooth, and soft to the touch. The tissue is subject to infection and then the second type of disease occurs in which marked increase in vascularization takes place, with the other concomitant elements of inflammation, such as round-

cell infiltration and fibrous formation, taking place. This infectious material is principally located in the crypts of the tonsil, although the folds within the lymphoid masses in the adenoids frequently harbor the infectious material. The bacteria which usually remain after the acute process subsides, find their way from the crypts and folds into the lymphoid tissue and thus we have not only cryptic infection, but also lymphoid infection. This is particularly noticeable in the solitary follicles of the pharynx, as well as the lymphoid tissue at the base of the tongue.

As the process of recurrent acute inflammation in the crypts and lymphoid tissues occurs, so does the retention of the infectious material within these crypts increase. This retention causes these crypts to dilate with accumulative masses of degenerated epithelium of the crypts, clumps of bacterial flora, particles of food and mucus. These masses otherwise known as cheesy masses, act as additional factors of irritation. Slowly but certainly does this hypertrophic process begin to produce atrophy by squeezing out the lymphoid tissue, and there remains in the majority of the cases a retracted inflammatory mass between the two pillars of the fauces, the plica supratonsillararis above, and the plica triangularis below. This is known as the submerged, retracted, phimosed tonsil. Owing to retraction very frequently the most important crypts are covered over by the plicæ, producing absolute retention. Thus we have established a natural incubator with numerous distended crypts containing bacteria, which are constantly either by themselves or their toxins absorbed into the circulation—directly into the blood stream or by way of the lymphatics.

While it is true that in the bacteriologic examination of retained secretion, there is not very often found any marked virulence of the organism, it appears that by this being shut off in these crypts, virulent hemolytic streptococci find their way into the blood stream and thus produce the severe lesions in distant parts of the body, as, for instance, vegetation on the valve of the heart, inflammatory and destructive lesions in and about the joints, inflammations in the sheaths of the nerves, etc. This is what we understand as chronic sepsis from foci of infection. So far as the adenoid tissue in the postnasal spaces is concerned,

there is less likelihood of producing severe disease, yet the surfaces of retention between the cleaves of the adenoids are so large and numerous that the absorption of septic matter from them produces definite toxic symptoms. The condition is particularly noticeable in children in whom, as a consequence of chronic toxemia, we see marked anemias develop.

The most important symptoms from these infected adenoids in the nasal pharynx are obstructive, so that the child, being a mouth-breather, does not receive the necessary amount of properly warmed air, which in turn gives off less oxygen than were the process normal nasal respiration. Obstruction of the eustachian tubes frequently leads to recurrent tubal catarrhal otitis media. By far the most important difficulty with obstructive and infected adenoids is the recurrent infection in the nose and down into the trachea and bronchi, otherwise known as frequent "colds." Of course, there are many other symptoms of conditions resulting from adenoid disease such as malformation of the upper jaw, etc.

The conglomerated mass of lymphoid tissue at the base of the tongue, otherwise known as the lingual tonsil, is but rarely complained of. Yet if it is carefully investigated one will find at least in the adults that this mass is responsible for many symptoms, especially cough. The infection of this lymphoid tissue is unquestionably very frequently brought about by the infected surface of the tongue. Examination both direct as well as with the mirror will reveal irregularly distributed lymphoid masses, principally on either side of the epiglottis, reaching down into the periform fossa. When the mass enlarges more in the center, that is, in the vallecular region and touches the epiglottis, there is almost certain to be present an unproductive cough, which can always be relieved by locally applying cocaine as a test, or by the removal of this tissue. The infection and retention in this lymphoid tissue at the base of the tongue play a very minor rôle in the toxic absorption. The lingual tonsil is notoriously known to become compensatorily hypertrophied in many cases where the tonsils and adenoids have been removed. It may be one of our great safety valves against harm being done by the promiscuous removal of tonsils in children. This subject will be treated later in connection with tonsil stumps.

In regard to the solitary lymphoid follicles of the pharynx, it will frequently be found in connection with chronic tonsillar and adenoid disease, or as mentioned in the previous chapter in chronic lateral pharyngitis, that they become enlarged. There are seen one or two distinct blood vessels running to or from them, their distribution being along the posterior wall of the pharynx. It is quite likely that each follicle thus enlarged is actually infected, although no crypts can be demonstrated. These follicles also take on activity in some of the cases where the tonsils and adenoids have been removed. The histologic

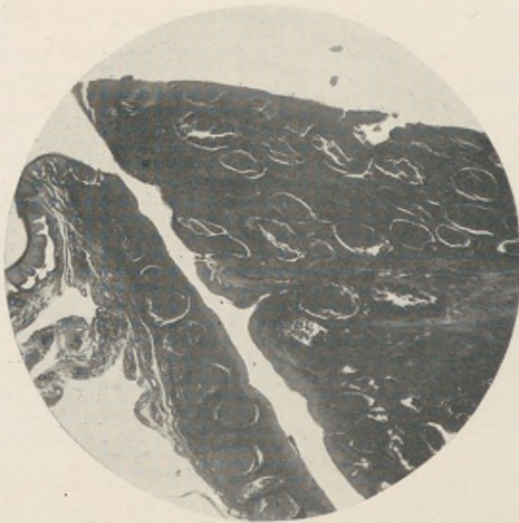


Fig. 164.—Tonsil—hyperplasia of lymphoid tissue, showing but slight dilatation of the crypts and absence of cheesy masses in them. Normal sinus supratonsillaris showing.

examination of the diseased lymphoid tissue of the pharynx, as just described, will vary considerably. If the hyperplastic form is examined, principally lymphoid tissue increase, very little stroma or inflammatory disease (Figs. 164 and 165) will be found. Once the process has become infected, the first changes in the epithelium covering the tonsils and adenoids is its desquamation (Fig. 166) (both in the surface of the tonsil as well as the crypts). The capsule of the tonsil, which is a part of this structure, is frequently found in a state of inflammatory reaction, and firmly adherent to the structures surrounding it.

In some of the extreme cases, there are only small remnants of lymphoid tissue, and the entire tonsil is transformed into a

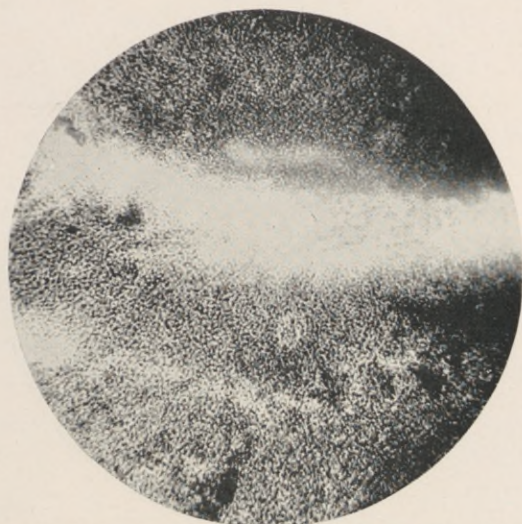


Fig. 165.—Adenoids, showing marked increase of lymphoid tissue and very little connective tissue.

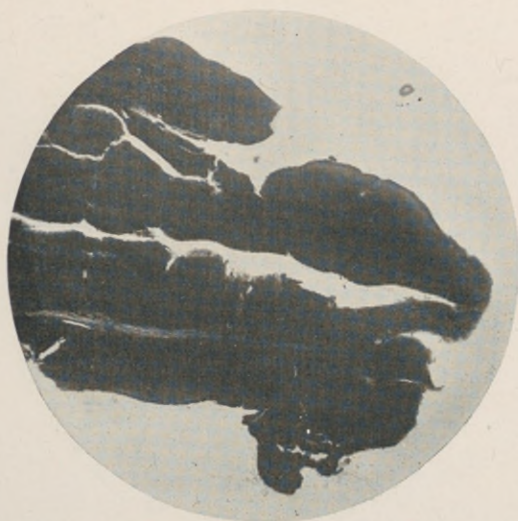

Fig. 166.—Adenoids, showing degeneration of the lining epithelium.

chronic fibrosed mass (Fig. 167), with disease-distended crypts running in all directions (Figs. 168, 169, and 170). The examination of the solitary follicles as well as the lingual tonsil,

reveals a round-cell infiltration and apparently some new blood vessels.

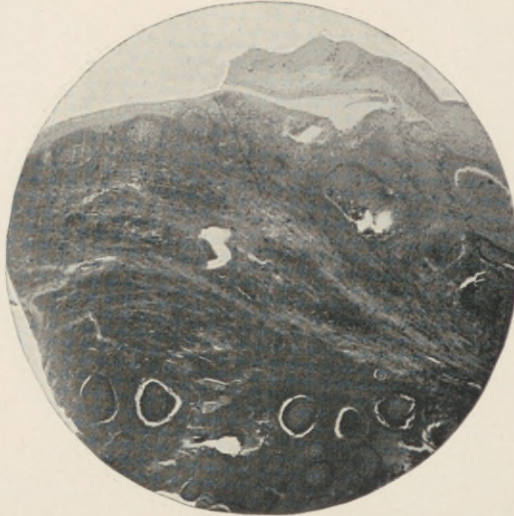


Fig. 167.—Tonsil, showing remnants of lymphoid tissue and marked increase in connective tissue.

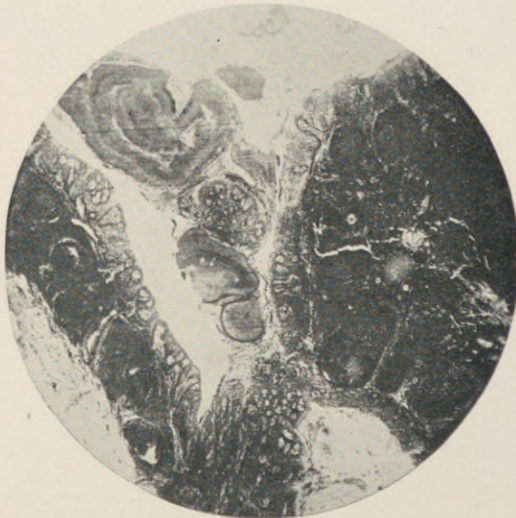

Fig. 168.—Tonsil in chronic lacunar inflammation, showing dilated crypts filled with cheesy masses.

Quite frequently these markedly retracted tonsils are practically transformed into a granulation mass, and on attempting

to grasp them and draw them out with volsellum forceps the instrument will tear out very easily. Histologic examination

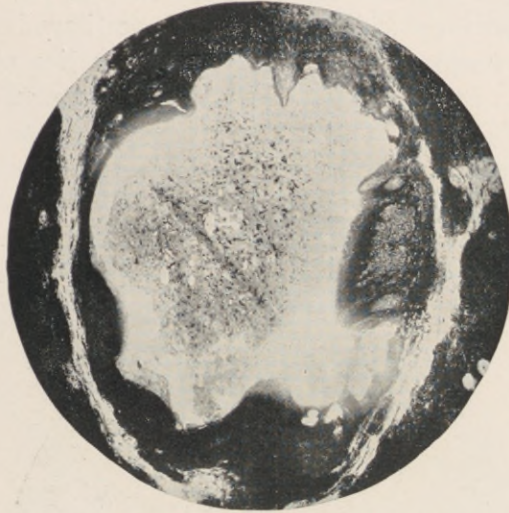


Fig. 169.—Tonsil, showing dilated crypts filled with detritus containing cholesterol crystals in case of chronic tonsillar infection.




Fig. 170.—Same as Fig. 169, high power, showing cheesy masses filling dilated crypts.

will demonstrate considerable fibrous tissue, yet it is not of a senescent character. There are also present numerous degenerated masses as well as many small blood vessels (Fig. 171).

From this pathologic picture of chronic tonsil and adenoid disease of the pharynx, the treatment must necessarily be divided into two distinct forms, the surgical and the electrotherapeutic. In that form of hyperplasia where there is no infection in the crypts, there is no doubt that the reduction of the lymphoid tissues can be accomplished by the employment of x-ray or radium, and thus relieve all the symptoms, whereas in that form of disease in which infection and degeneration play a part, the cure of the condition by any such method cannot be expected, and surgical intervention must be employed. The technic of applying the x-ray and radium as is employed in our clinic, is as

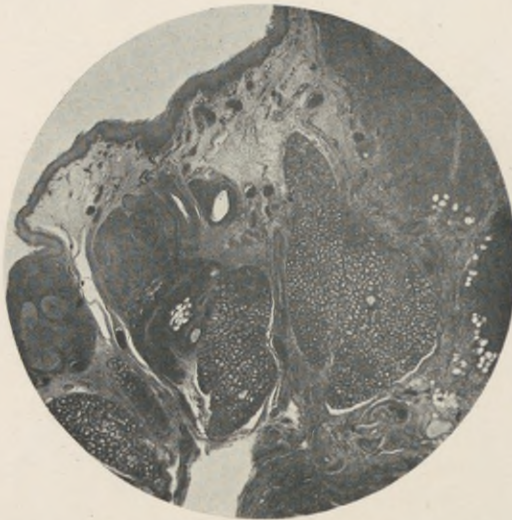

Fig. 171.—Tonsil, showing trabeculae of fibrous tissue starting at the inner surface of the capsule and enclosing masses of degenerated lymphoid tissue; also, note the large number of blood vessels of small lumen present. The surface epithelium is well preserved.

described in any modern publication on radio- and electrotherapeutics.

As to the technic of the surgical procedure on the tonsils and adenoids the reader is referred to Loeb's book "Surgery of Ear, Nose and Throat." We wish to say here, however, that nothing short of complete enucleation of the tonsil and the very careful, painstaking, thorough removal of the adenoid tissue in the vault of the pharynx will suffice. Notwithstanding this thorough removal, following the uneventful healing of the parts, masses of

tissue strongly resembling tonsil and adenoid tissue will be observed in their previous localities. So far as this tissue in the vault of the pharynx is concerned, microscopic examination will show it to be made up mostly of granulation tissue, which for some reason or other developed at the seat of the denuded area (Fig. 172). Perhaps it might be accounted for from overoperation, leaving exposed the anterior common ligament which slowly granulates. The treatment of this granulation in the postnasal space can very well be controlled by the application of strong astringent solution of silver nitrate. This is best

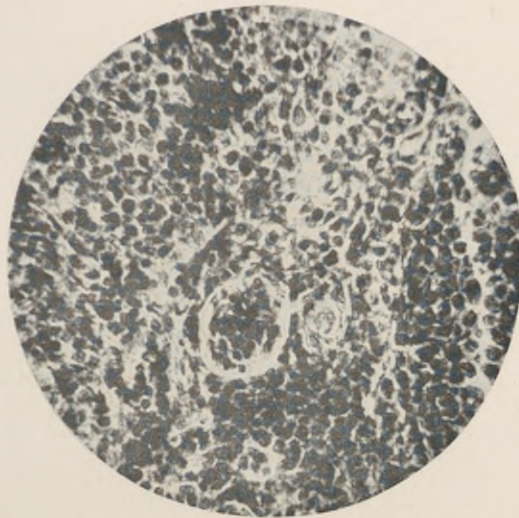


Fig. 172.—Persistent granulation after removal of adenoids.

accomplished with the palate drawn forward by means of a rubber catheter, the head hanging over the edge of the table, thus preventing possibility of the solution dropping into the larynx and causing disagreeable symptoms. Although the masses found at the lower portion of the tonsillar fossa resemble tonsillar tissue, it will be found that this tissue is not tonsil, but rather granulation tissue. However, here we do frequently find lymphoid tissue which has developed from the neighboring structures and the plica. These masses are very important of recognition and to differentiate from what we term tonsil stumps. Tonsil stumps are remains of portions of tonsils from an imperfect operation, and must in no way be confounded with

the tissue masses at the lower pole of the tonsillar fossa, which Nature has produced there to fill up the otherwise large retention cavity.

It is true that these masses are subject to inflammation or infection because, as was stated before, they contain lymphoid tissue. When this difficulty arises, especially with any degree of frequency, it is very easily controlled by the use of an electrothermal coagulation. We believe it is poor practice to resect these masses on account of the bleeding being difficult to control and the occurrence of subsequent contraction between the base of the tongue and the pillars of the fossa. It is entirely different with the tonsil stumps in which there are repeated recurrent attacks of tonsillitis, in which case they produce general symptoms. Such stumps must be thoroughly removed and frequently it is a much more difficult operation than an ordinary tonsillectomy. In regard to the solid lymphoid follicles or enlarged lingual tonsil, these are best controlled by the use of the galvanocautery, although operative procedures are also found in the chapter in Loeb's book.

11. TUBERCULOSIS OF THE TONSIL

The primary tuberculosis of the tonsil has been for a good many years a very moot question and much discussed subject. The great variance in the reports of percentages of primary tuberculosis of the tonsil makes it questionable whether such a disease really exists. By personal observations in our own cases we have, in having sectioned many tonsils, discovered true tuberculosis in an otherwise absolutely healthy individual but once. We have, however, found quite a number of tuberculous diseased tonsils in patients who had tuberculous glands of the neck and were apparently free from lung or other systemic tuberculosis. Yet on very careful investigation it was always possible to find (especially by the aid of the x-ray of the chest) evidences of tuberculosis of the lungs, but more often of the peribronchial lymphatic glands. We therefore believe that all these apparently primary tuberculous tonsillar infections are really secondary and become infected through the blood stream. There is another type of tuberculous tonsil which does become

infected by either continuity of structure from the laryngopharyngeal tuberculosis or from the sputum expectorated by the patient, lodging in the tonsillar crypts. A tuberculous tonsil unless in a state of ulceration varies but little from the ordinary chronic infected tonsil. In one or two instances we

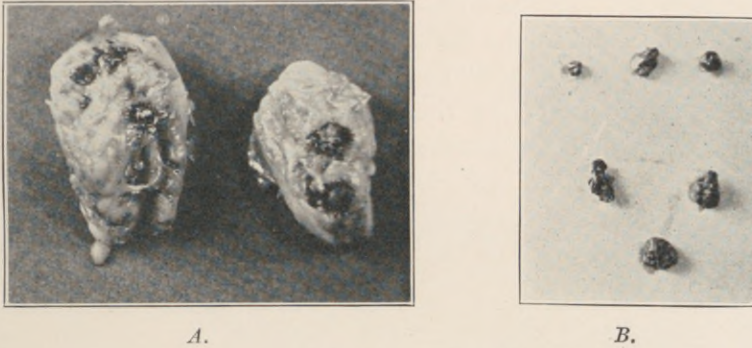


Fig. 173.—Multiple tonsilloliths.

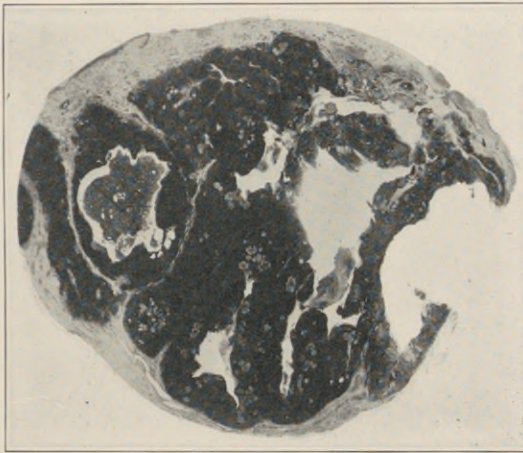


Fig. 174.—Tuberculosis of the tonsil, showing cheesy masses in a dilated crypt (low power).

have been fortunate in observing caseation before ulceration took place. This caseating process must not be confounded with the accumulation and retention of cheesy mucus within a crypt whose mouth has become sealed over by adhesions, forming a so-called cold abscess.

While on this subject we might mention that at times these

cheesy or cold abscesses are transformed by deposition of lime salts into definite concretions, otherwise known as tonsilloliths. We have had two such cases; in one the stone weighed $3\frac{1}{2}$ grams, and the case resembled clinically a carcinoma, and in the other the concretions were multiple (Fig. 173). To continue with the tuberculous process, we find the associated glands of the neck are very suspicious; such glands when removed frequently show tuberculosis. Whether the glands become secondarily infected from the tonsil by the lymph stream, or through the blood at the same time as the tonsil, has not been definitely

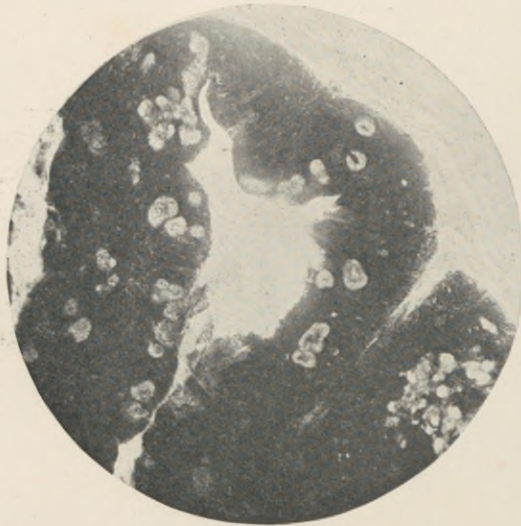

Fig. 175.—Tuberculosis of the tonsil, showing numerous tubercles and a dilated, degenerated crypt, (higher power).

determined, although Grober's and Weixelbaum's experiments on animals would tend to show that the former is the case. The microscopic examination of tuberculous tonsils is so definitely characteristic of this disease that there can be no mistake made in the diagnosis. There are all elements of chronic tonsillar infections present with their dilated crypts, etc., plus the giant cell, epithelioid cell, round-cell infiltration about these, with many areas of caseation or necrosis (Figs. 174, 175, and 176). We have never been able either to isolate the tubercle bacillus from such tonsillar infections, nor have we been able to iden-

tify in sections the tubercle bacillus when especially stained for it.

Treatment.—The treatment of tuberculous tonsil in the types described as so-called primary tuberculosis is complete enucleation,—the fact of the matter is that the diagnosis is usually made after their removal and subsequent histological examination. In the tuberculous tonsil wherein ulceration has taken place and in which there is associated tuberculosis of the larynx and pharynx, and in which there are other general tuberculous manifestations, we advise palliative or local treatment rather

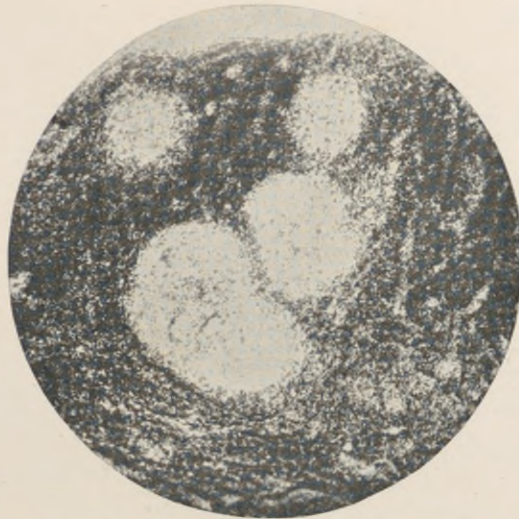

Fig. 176.—Tuberculosis of the tonsil, with caseation, showing typical tubercles formed about the central giant cells (high power).

than surgery. Nothing more radical should be done than actual cauterization of the ulcer. In the case of the large or infected tonsil of a tuberculous patient whose sputum is laden with tubercle bacilli, but whose general condition is good, we have removed such tonsils under local anesthesia with definite benefit to the patient's local as well as general condition. The hygienic, dietetic and climatic treatment must not be overlooked when once the diagnosis has been made and such therapeutic measures as tuberculin medication and possibly x-ray or surgery to the glands of the neck should be urged.

12. LUETIC TONSIL

Every one knows that patients who have systemic lues may have simple chronic infections of their tonsils and are operated on for such difficulties. A subsequent examination of such tonsillar tissue both grossly and microscopically does not show any evidence of luetic changes. There are, however, syphilitic lesions in the tonsil, as already described in the same disease of the pharynx, which are not operable. At the same time we must recognize a syphilitic entity of the tonsil, syphiloma, which differs clinically, as well as pathologically. We have had one such

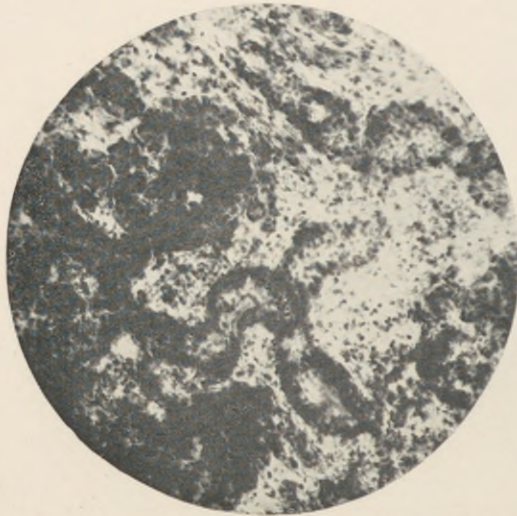


Fig. 177.—Luetic tonsils, showing round cell infiltration and caseous gummata.

case in whom a unilateral swelling of the tonsil existed and in whom there were no other evidences of syphilis, not even a positive Wassermann reaction. This tonsil was removed and on subsequent histologic examination showed definite signs of syphilis, namely, thickened blood vessels, marked round cell infiltration, and caseous gumma formation (Fig. 177). The healing of the wound was uneventful, contrary to the usual slow healing process in luetic individuals.

13. ACTINOMYCOSIS OF TONSIL

Actinomyces of the tonsil is usually associated with the disease about the mouth called "lumpy-jaw." The author has ob-

served one such case from the Pathologic Institute of Prague, in which the actinomycotic process appeared first within the tonsil and extended from the eustachian tube to the middle ear. The pathologic appearance of the tonsil showed a great deal of induration and very firm adherence to the peritonsillar structures. Numerous fistulas not recognized as crypts virtually riddled the tonsil and from them could be expressed greenish yellow bodies which proved under the microscope to contain the typical ray fungus. The treatment is general—potassium iodide and x-ray and radium.

14. HYPERKERATOSIS OF THE TONSIL

Hyperkeratosis of the tonsil must be regarded as a part of the same disease of the entire lymphoid ring of the pharynx, other-

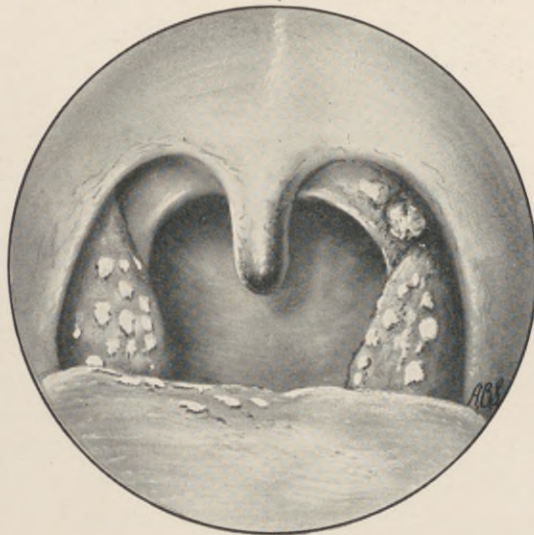


Fig. 178.—*Leptothrix*. The characteristic whitish spots are observed on the base of the tongue as well as on the tonsil and pillars.

wise known as Waldeyer's ring. It is characterized by the formation of yellowish white masses within the crypts as well as on the surface of the tonsil, fairly well scattered (Fig. 178). It resembles much the appearance of an acute follicular tonsillitis, except there is no redness or swelling of the remainder of the pharynx. In attempting to remove these masses by swab or

by forceps one will find that they are tenaciously adherent, but upon successful removal of the particle little or no bleeding occurs and no pain is experienced.

Microscopical examination of such keratinous material (horny), when properly stained with Lugol's solution (Grams-iodine), will demonstrate the characteristic *leptothrix buccalis* having dead epithelial cells and many non-pathogenic microorganisms in its masses with scarcely any pus cells present.

As stated above, the associated pathology of the base of the tongue, that is, of the lingual tonsil, the postnasal space, the adenoid region, the lateral masses behind the posterior pillars and occasionally on the anterior pillars, is quite characteristic. The patients thus affected complain but very little of dryness in the throat, irritating and tickling (scratchy feeling), but are very much perturbed by the appearance of the whitish masses in their throats. Since the general practitioner is usually first consulted, and in many instances is not acquainted with this pathologic entity, one obtains a history of the previous administration of antitoxin because of its being mistaken for diphtheria. The etiology is not known but one does find the presence in many cases of poor mouth hygiene and dental caries. The *leptothrix* is perhaps a purely accidental component due to putrefaction. It is seldom found in any one who uses tobacco.

The microscopic picture is one of chronic infection of the tonsil leading to fibrosis. On the surface and within the top of the crypts are found in great abundance the keratinous changes.

Treatment.—The treatment is best directed toward the cauterization of these masses by the use of the galvanocautery point, but it is accepted by the majority, and we believe it, that the chronic infection within the tonsil is probably the most potent factor and therefore tonsillectomy is advised.

The dental hygiene is of the utmost importance. Mouth washes of the super-oxidized solutions, such as hydrogen peroxide, perchloride of iron, chlorate of potash, and potassium permanganate are the favorite forms.

15. BENIGN TUMORS

Almost every type of benign tumor has been described in literature as having occurred in this region, but we have had ex-

perience only with lipoma, adenoma with colloid degeneration, eechondroma, mixed tumor (mixo-fibro-angioma), bismuthoma, and cysts. It no doubt would be of interest, at least casuistically, to describe each individual condition, but it will suffice from the pathologic point of view to group them as a whole and say that with the exception of the lipoma they are all unilateral. The actual pathologic diagnosis was always made after the tumor was removed. The universal symptoms were those of phonetic disturbances, some embarrassment in breathing especially during sleep, but rarely any pain. The bilateral lipoma was associated with a case of Dercum's disease. In regard to

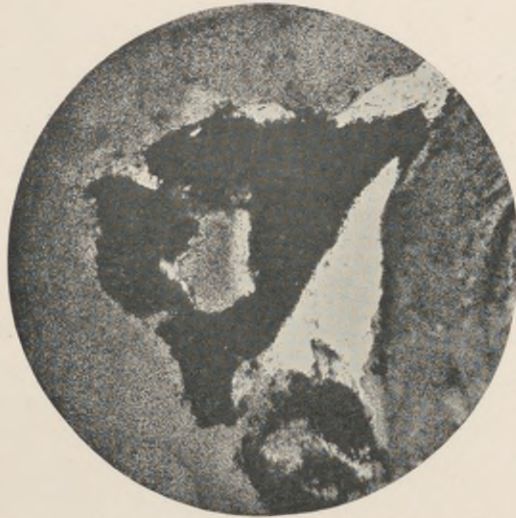

Fig. 179.—Tonsillar crypt filled with bismuth paste, showing the communication of the crypts.

the bismuthoma, it is necessary to mention that the bismuth paste was injected for therapeutic purposes. Several months after this treatment the patient presented himself with this definite unilateral enlargement. The tonsil was removed and on section showed the crypt blocked and distended with bismuth (Fig. 179).

The bismuth paste had acted as a foreign body irritant and produced a connective tissue reaction around the bismuth vaseline particles. These spaces, surrounding the paste are lined with a rather narrow rim of multinucleated cytoplasmic bands

resembling syncytium. Between the spaces, in the more cellular parts of the tissue, are larger and smaller multinucleated giant cells of the foreign body type, in some of which, as well as in the adjacent smaller cells, may be fine bismuth granules (Fig.

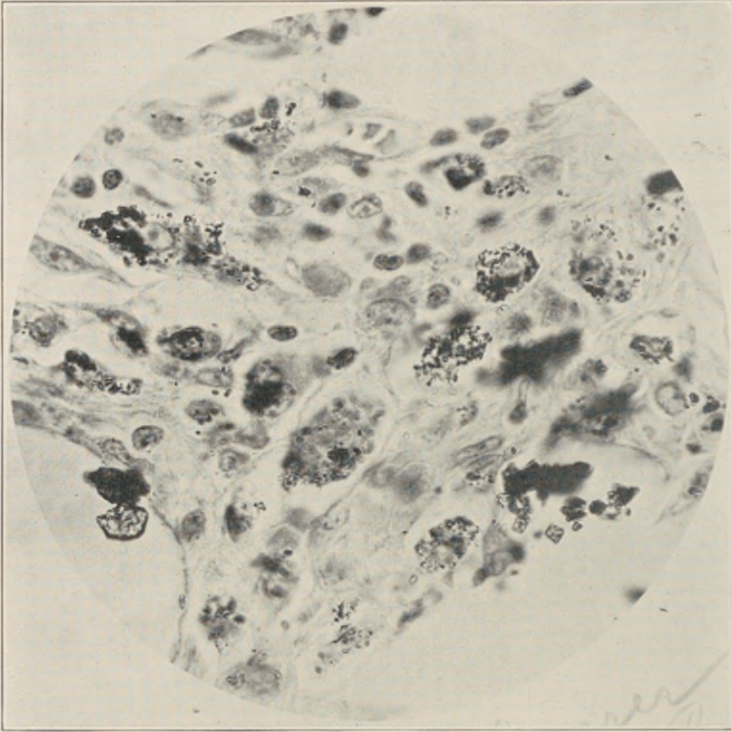


Fig. 180.—Photomicrograph showing the foreign body giant cells most numerous in the region of the bismuth masses. Some are small, containing 3 to 5 oval nuclei irregularly arranged, others are larger and contain 10 or more nuclei. Some of the giant cells as well as the endothelial-like cells are seen to have a phagocytic tendency. (High Power $\times 7000$.)

180). A few scattered areas of round-cell infiltration occur among the hyperplastic connective tissue. The cells are chiefly small lymphocytes together with a moderate number of plasma cells.

CHAPTER X

CHRONIC DISEASES OF THE LARYNX

The most frequent chronic disease of the larynx met with in our experience is cancer. Most laryngologists, however, will probably come in contact with more cases of the chronic, simple laryngitis. In the diagnosis of the various pathological processes affecting the larynx there is one absolutely necessary factor; that is, experience. It is necessary to have seen a great number of cases and to have a very competent and reliable teacher to interpret correctly the clinical findings. While it is true that the microscopic examination of sections of tissue removed will reveal the actual pathology, it is not so desirable from the practical viewpoint in diagnosis as the clinical examination.

There are two methods of examining the larynx, the direct and the indirect; and the former again may be subdivided into the spatula and suspension methods, each having its definite value. The indirect method is the simplest and most agreeable to the patient and is to be preferred. However, in some instances a combination of all the methods will be necessary in order to make a diagnosis. The various aids, such as bacteriological, serological and x-ray examination will prove of additional diagnostic value. A clear history is essential, especially as to such symptoms as interference with the voice, its duration, the association of pain, cough, etc.

CARCINOMA OF THE LARYNX

As we have mentioned before, carcinoma is the most frequent pathologic condition affecting the larynx that we have met with in our experience. It is to be noted that in different localities the laryngologist sees different prevalent types of laryngeal pathology. For example, in the west, as in California, Colorado and New Mexico, tuberculosis of the larynx will probably be seen most frequently; while in the resorts—as Hot Springs,

Arkansas, syphilitic laryngitis will probably be met with most frequently. We have for years followed an axiom in diagnosis,

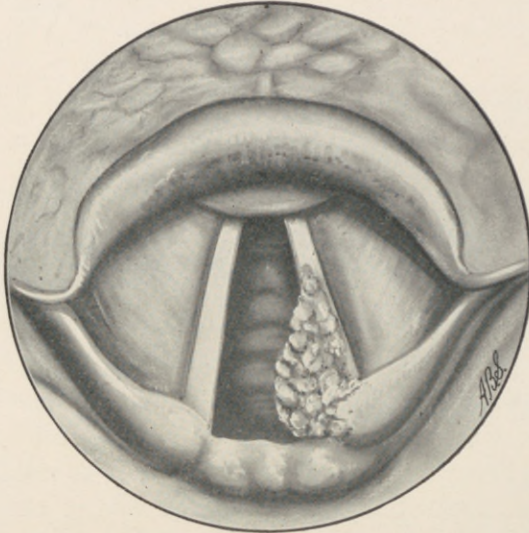


Fig. 181.—Carcinoma of the arytenoids and cords. The polypoid nature is to be noted.

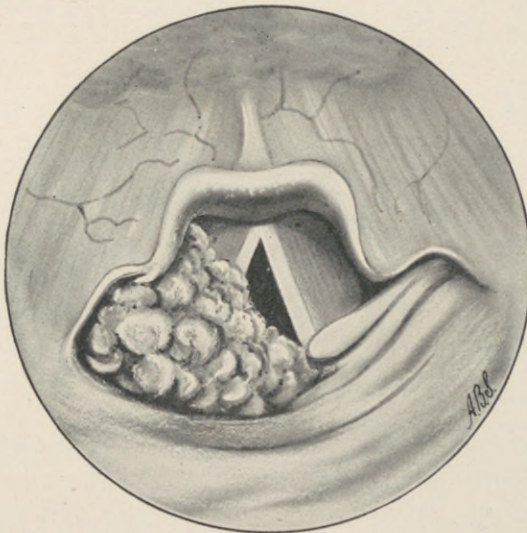

Fig. 182.—Carcinoma of larynx, extending from the pyriform fossa.

from which we have had no reason to deviate—that any man over forty who has had hoarseness that has existed for six weeks

or longer, and which has not disappeared during that period, is to be suspected of having cancer. Unfortunately, in by far the majority of cases that we have seen, because of the advanced nature of the process, there was not much difficulty in making the diagnosis. There was usually marked swelling within the larynx with cauliflower-like excrescences (Figs. 181, 182, and 183). One or both arytenoid cartilages would be limited in their motion, or perhaps fixed. Corresponding to the side involved, definitely palpable lymph glands in the anterior or superior tri-

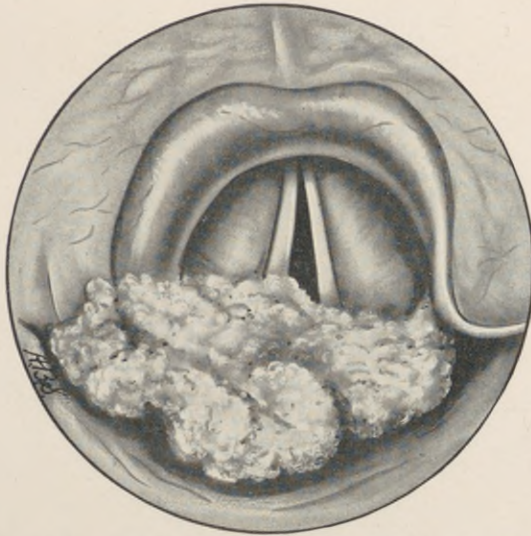


Fig. 183.—Carcinoma of the hypopharynx extending into the larynx.

angles of the neck along the course of the great vessels were observed.

Some impairment of the voice is practically always present, from a varying degree of hoarseness to complete aphonia. There is a constant desire to clear this part of the throat and an annoying laryngeal cough is usually in evidence. Very frequently there is painful and difficult swallowing, owing to the encroachment on the pharyngo-esophageal region. Invariably when a process has extended to this degree the contiguous part of the epiglottis and base of the tongue is likewise involved (Fig. 184). In such an extensive process as this encroachment upon the sensory nerves of the neck results in marked neuralgic

pains, referred to different parts of the head and neck, especially the ear.

The absolute diagnosis, after having excluded such conditions as syphilis and tuberculosis, can be established by biopsy and microscopic examination of a section of the tumor. Very early in the disease the diagnosis is much more difficult, especially

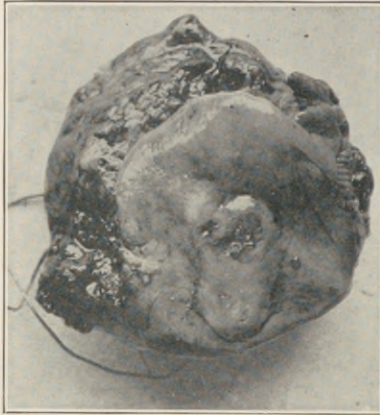


Fig. 184.—Carcinoma of the larynx, involving the tongue, showing hard, ragged, infiltrated and ulcerated mucous membrane.

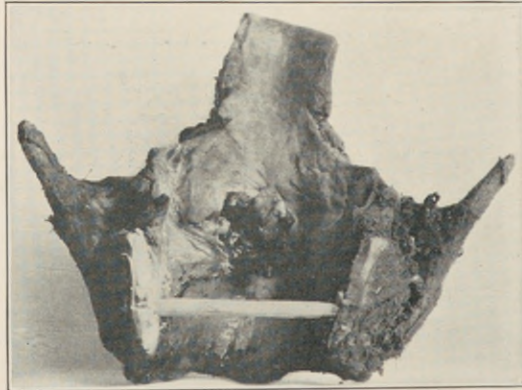


Fig. 185.—Carcinoma of the larynx. Gross specimen.

when there is a coexisting syphilis or tuberculosis of the larynx. Again it is to be emphasized that one should always be prepared to carry out radical procedures immediately, or within twenty-four hours, after the section has been removed for examination. There is no doubt but that a biopsy hastens the development of metastases in carcinomatous involvement.

Pathology.—Grossly, the lesions, as shown in the clinical picture in Figs. 181, 182, and 183, namely, located in the posterior half and necessarily involving the neighboring structures as the pharynx and tongue have the appearance of irregular cauliflower-like masses and are quite soft to the touch. In the cases where the masses are located intralaryngeally and anteriorly they very frequently find their way subglottic and extend within the ventricle of the larynx as far as the cricoid cartilage (Fig. 185). Not infrequently are these neoplasms ulcerated and become secondarily infected. If the growth has been present

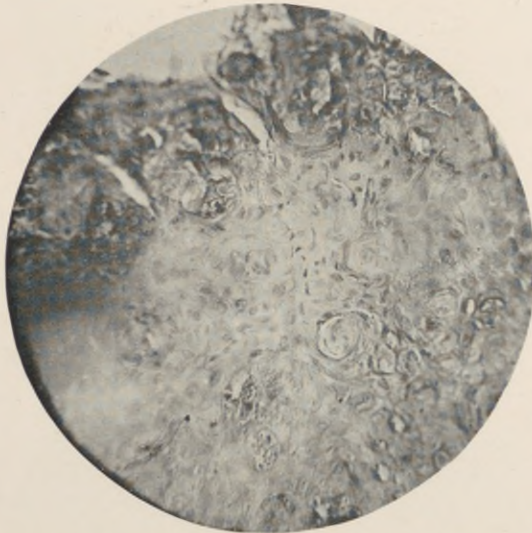


Fig. 186.—Carcinoma of the larynx, showing typical epithelial pearls (low power).

for a sufficient length of time the cartilage in the vicinity of the growth undergoes absorption and this change may easily be verified by the x-ray showing irregularities in the outline.

Just as soon as the perichondrium becomes involved in the carcinomatous process, the case must be considered extrinsic because the lymphatics draining this structure become readily infected and involve the regional glands. It is quite different with carcinoma in the posterior half because the contiguity, as mentioned before, of these structures with the esophagus and pharynx, makes them positive of malignant invasion. Therefore the statement that is so prevalently made that a cancer

within the larynx, the so-called laryngeal "safety-box," is not well taken. There is no safety location in cancer of the larynx.

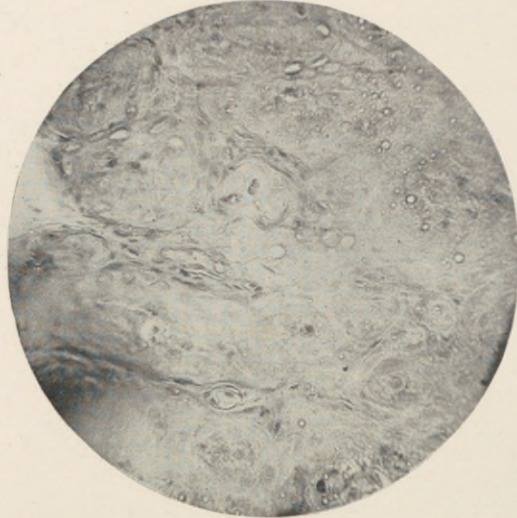


Fig. 187.—Carcinoma of the larynx showing some typical epithelial pearls (high power.)

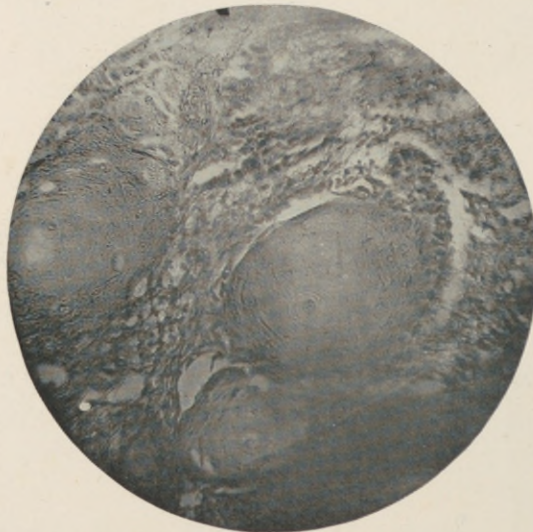


Fig. 188.—Carcinoma of the larynx, showing typical epithelial pearls under high power. The early central degeneration is shown in one of the pearls (high power).

The fixation of the arytenoids is not solely caused by the neoplasm, but the associated inflammatory infiltration. Compara-

tively rarely is the epiglottis involved in this process but it is important to note that it is free because it may be permitted to

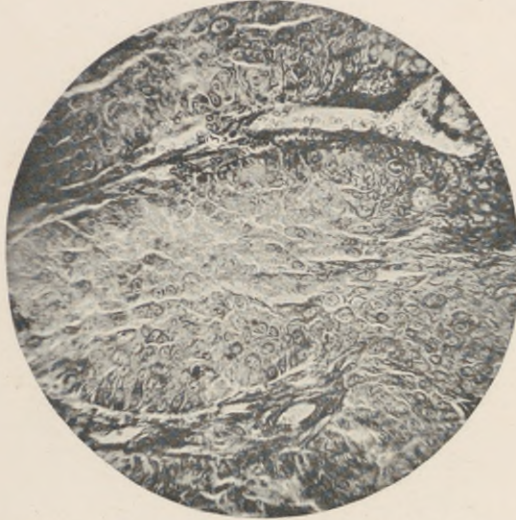

Fig. 189.—Carcinoma of the larynx, showing marked activity of the malignant epithelial cells.



Fig. 190.—Carcinoma of the larynx, showing epithelial pearls and a considerable number of blood vessels and connective tissue.

remain in a total extirpation of the larynx. Should the epiglottis be involved and be left, it would defeat the purpose of the procedure.

Microscopic Examination.—The most frequent type that we have encountered has been the straight epithelial variety which

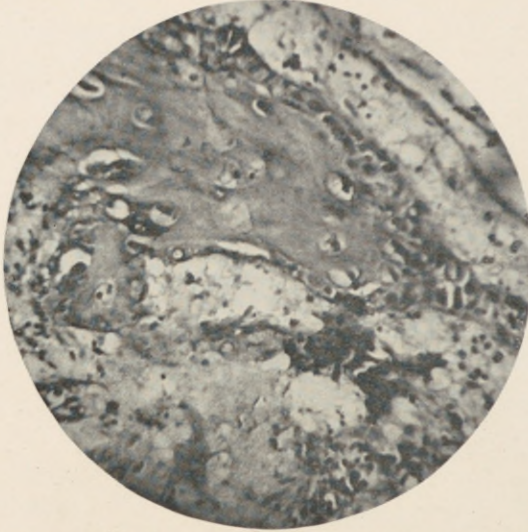

Fig. 191.—Carcinoma of the larynx, showing combined activity of the cartilage cells.

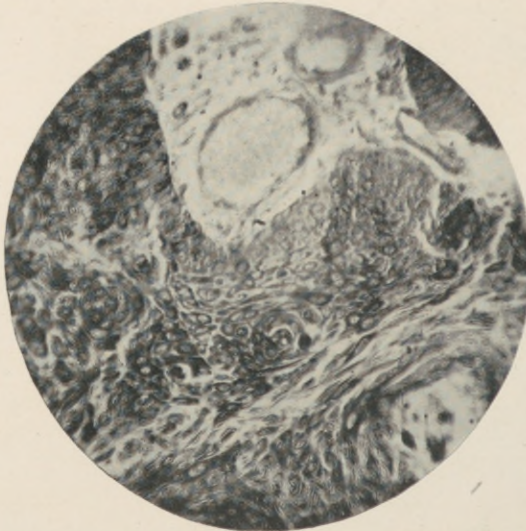


Fig. 192.—Carcinoma of the larynx, showing "nests" of epithelial cells and older connective tissue and uninvaded blood vessels.

has been characterized by the presence of "pearls" (Figs. 186, 187, and 188). In other types where the epithelial pearls are

more sparse, carcinoma cells are found in great masses of multinuclear epithelial cells, so-called medullary carcinoma (Fig. 189). Again, in other instances, wherein epithelial pearls are present, a considerable number of blood vessels and connective tissue are demonstrable (Fig. 190). Sections in which the cartilage was infiltrated with carcinoma cells seem to indicate the inflammatory reaction with activity of the cartilage cells (Fig. 191). In one instance of a slow growing carcinoma, the section revealed considerable older fibrous tissue (Fig. 192). In such cases, where x-ray and radium are employed extensively, there

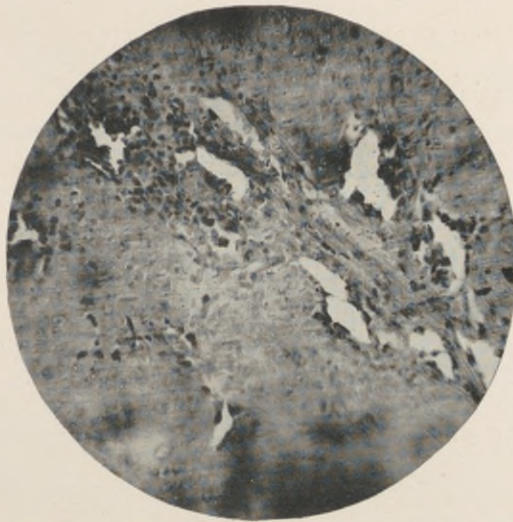


Fig. 193.—Carcinoma of the larynx, after radiation, showing some round cell infiltration and evidence of chronic inflammatory changes but no active malignant cells.

are changes demonstrable, that are both interesting and important. The round-cell infiltration with fibrous tissue formation, degenerative epithelial cells and no active malignant cells are the usual findings (Fig 193).

Treatment.—The prognosis of cancer of the larynx is always very grave and the only type of case that offers any encouragement for cure is one that is seen in an early stage, where the neoplasm is small and confined to the anterior and interior portion of the larynx, and only then when it can be widely removed. Our most successful results have been obtained when

we removed the entire larynx. X-ray, radium, fulguration, surgical diathermy, and the various "medicinal" cures for carcinoma, have not proved to be beyond the experimental stage, so that we believe surgery is the method of choice and thus far offers our only hope. However, such measures as we have mentioned may supplement surgical procedure. At the same time, we wish to state that the use of short wave-length x-ray therapy is of great aid to surgery. It should be employed before and after operation so as to insure against a most serious possibility, namely, cancer cell implantation through the manipulation.

TUBERCULOSIS OF THE LARYNX

The question is still unsettled as to whether we may or may not have a primary tuberculosis of the larynx. Insofar as our

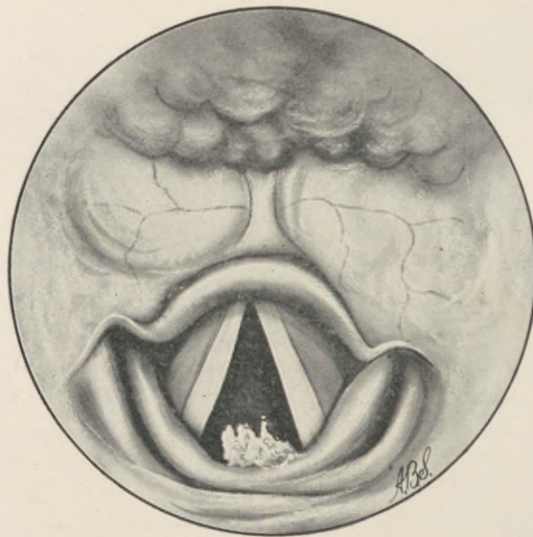


Fig. 194.—Interarytenoid tuberculoma simulating papilloma.

own experience goes, we have never encountered a case where there was not definite evidence of a tuberculous process in the lungs. We have, however, many times seen quite a progressive lesion of the larynx in an apparently healthy, robust individual, but on closer examination, especially by means of the radiogram, and particularly stereoscopically viewed, either a latent

or active process in the lungs could always be demonstrated. The laryngeal picture varies considerably from a simple inter-

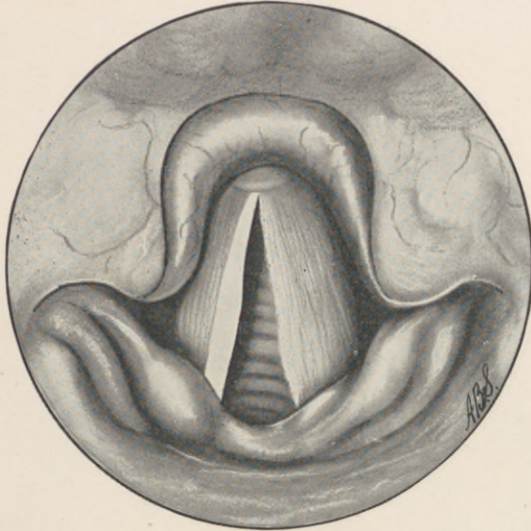


Fig. 195.—Tuberculous infiltration of the cord and epiglottis. More of the type of subepithelial infiltration.

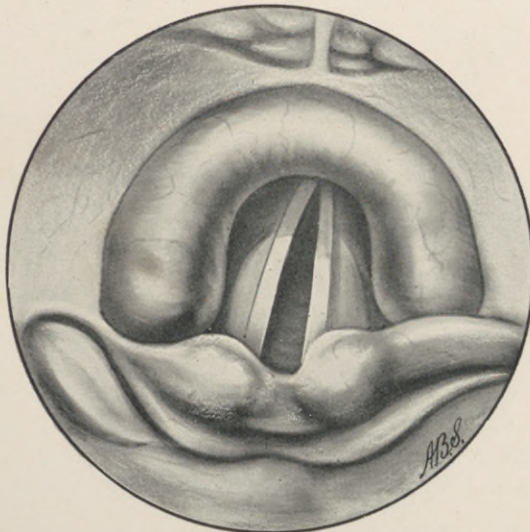


Fig. 196.—Tuberculosis of the larynx, involving the arytenoids and the epiglottis which is markedly edematous.

arytenoid excrecence to the most markedly edematous, infiltrated, ulcerated condition (Figs. 194, 195, 196, and 197). One

can clearly observe from the study of these illustrations the marked edema and infiltration of the epiglottis as well as the

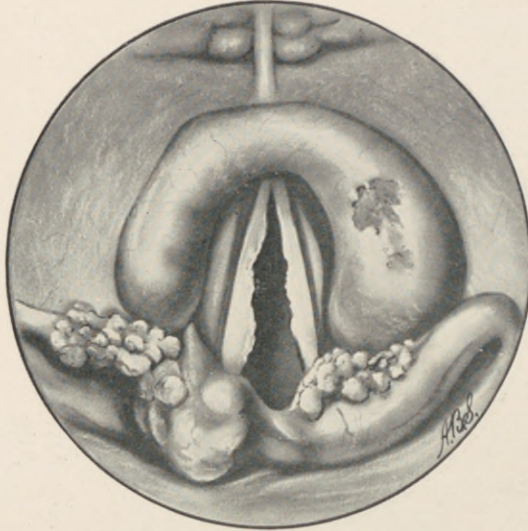


Fig. 197.—Tuberculosis of the larynx. The tuberculoma formation about the arytenoids, together with ulcerations on the epiglottis are to be noted. Also note the rat-bitten appearance of the cords.

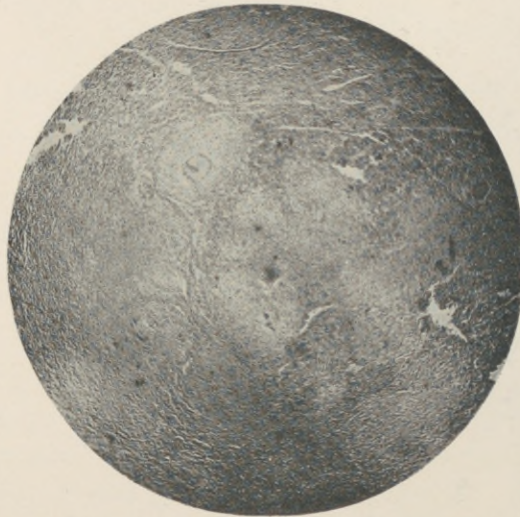


Fig. 198.—Tuberculosis of larynx showing typical tubercle formation.

arytenoids. The “rat-bitten” appearance of the vocal cords, usually confined to one side, is characteristic. These tremen-

dous infiltrations, and especially when ulcerated, are responsible for the dysphagia that accompanies this disease. There is one form of tuberculosis of the larynx that does not show very much on laryngeal examination, in which the pathologic process is a subepithelial infiltration and which is oftentimes baffling in a differential diagnosis between lues and tuberculosis (Fig. 195).

Histologically, there is found the characteristic tubercle formation which is diagnostic (Fig. 198). At times tissue removed from a tuberculous larynx will not show the character-

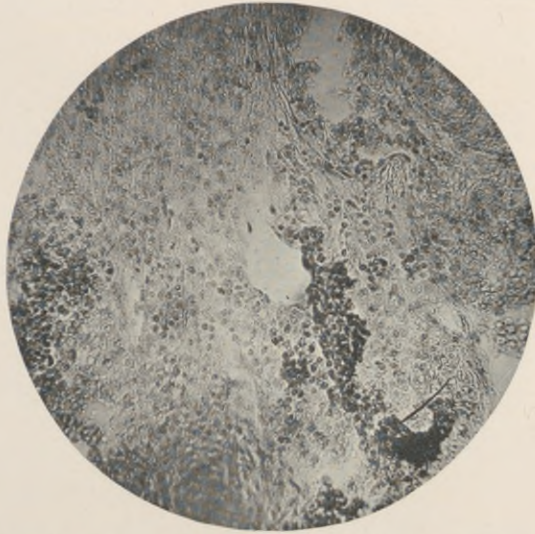


Fig. 199.—Chronic inflammation of the larynx in case of advanced pulmonary tuberculosis, showing marked round cell infiltration but no tubercle formation or giant cells.

istic tubercle or giant cell (Fig. 199), but rather a chronic inflammatory process.

Treatment.—The treatment of tuberculous laryngitis is directed primarily toward the focus in the lung and that is more in the realm of other fields of medicine. The local treatment to the larynx is practically of no curative value and only palliative measures have a place in the management of this disease. We have reference particularly to the dysphagia and hoarseness. Topical application of local anesthetics such as cocaine, anesthesine, orthoform, and the various emollients, as liquid petrolatum, and chloretone have all been tried with more or less,

principally less, benefit in the management of this affection. Intralaryngeal injection of a weak formalin solution or the iodoform-ether mixture spray are of decided benefit for the relief of pain on swallowing. Painful ulcerative surfaces are best controlled by topical application of lactic acid (50 per cent) to the ulcer. Surgical and semisurgical measures, as, for instance, curettement of the ulceration, actual cautery, amputation of the epiglottis, injection of the superior laryngeal nerve with alcohol, tracheotomy to place the larynx at rest, all have their definite indications, and, at times, startling results are obtained from their employment. That special pathologic form of subepithelial infiltration, of which variety we have only observed a very few cases, but which have been observed by Mullen, Lockhardt and Carmody of Colorado, has best been influenced by climatic change under the guidance of specialists in tuberculosis, particularly laryngologists. Recently we have observed a case of this form of luetic laryngitis which was treated in combination by a laryngologist and radium therapist with reactions (burns) most distressing.

SYPHILITIC LARYNGITIS

In large laryngeal clinics, especially abroad, one will observe very many cases of this disease but in this country and in private practice it is not so frequently met. It goes very commonly, masquerading under the guise of a chronic laryngitis in which no other symptom except hoarseness is present. The appearance is that of a deep injection of the entire larynx and the infiltration is mostly confined to the cords and subglottic region. Occasionally there are local gummatous formations, either in the arytenoids or epiglottis and in very pronounced cases the entire thyroid cartilage becomes markedly infiltrated, particularly the perichondrium. Breaking down of the gumma, which becomes secondarily infected, forms one of the most destructive lesions of the larynx and in such instances the symptom of respiratory embarrassment is very marked, and often necessitates tracheotomy. When the cricoid cartilage takes part in this pathologic change, then the associated difficulty in deglutition is also pronounced. As the result of these destructive

changes, which are associated with marked sloughing, there will be, when the end result is obtained, marked deformity and cicatricial formation (Fig. 200). The history and other concomitant findings of lues together with a serological test (positive Wassermann), will suffice to make a diagnosis. A particle of tissue if removed by biopsy will reveal a true picture of chronic inflammation with the syphilitic vascular changes, endarteritis obliterans.

Treatment.—The treatment is very energetic antiluetic with arsphenamine, mercury and potassium iodide, by their accepted

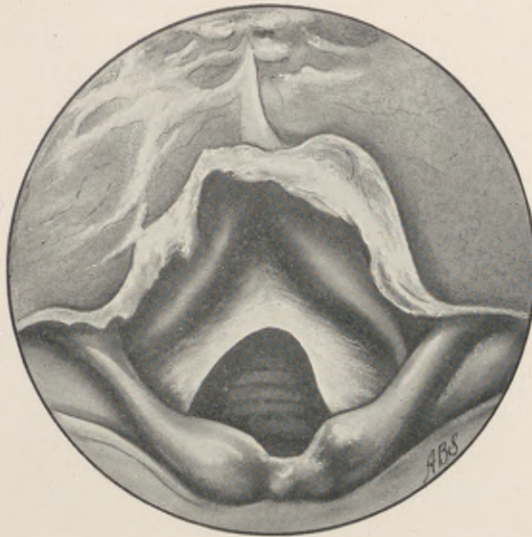


Fig. 200.—Laryngeal stenosis; luetic origin. The marked cicatrization and the almost complete destruction of the epiglottis are to be noted.

methods of introduction. It must be remembered that in a larynx that is already stenotic when iodides or arsphenamine are administered, especially in large doses, a sudden increased difficulty in breathing may result from what is known as the Herxheimer reaction, which is an acute edema. It is noteworthy that antiluetic treatment for the disease in this locality is not so prompt in its action and the explanation may be sought in that the perichondrium is principally involved and responds but very slowly. Surgical measures are at times necessary, such as emergency tracheotomy, as was stated before, as well as reliev-

ing tension perichondritis, thus preventing complete cartilaginous absorption. The procedure corresponds to an atypical or incomplete laryngotomy. We have just completed a case of this kind wherein such measures proved their efficacy. The management of the deformities due to cicatrization is mainly mechanical and may be found described in Loeb's textbook.

CHRONIC SIMPLE LARYNGITIS

The principal changes in this disease are hypertrophy of the mucous membrane or the submucous tissue or both; involving anatomically all of the divisions of the larynx but principally the ventricular bands and the true vocal cords. Not only is the

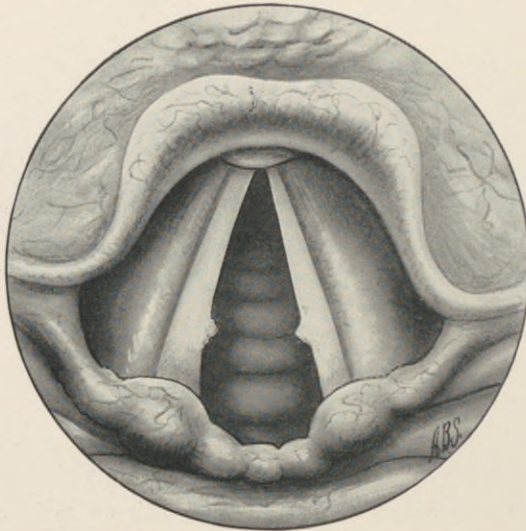


Fig. 201.—Singers' nodules.

larynx involved but invariably is the nose, pharynx and trachea associated in the process. The fact of the matter is, the laryngitis is usually secondary to some chronic nasal or sinus disease and consequently the treatment should be directed towards the nose.

The appearance of the larynx is of a mottled-red, the cords, having lost their luster, show very frequently markedly injected blood vessels over their surface and occasionally, with the cords in complete abduction, subglottic hypertrophies can be made

out. On phonation, especially in the highest register, the vocal cords, in their attempt at approximation will fail on account of their thickened margins and the hoarse voice is the result. From the faulty use of the voice during the attack of chronic laryngitis, on some part of the edge of the cord, an excrecence forms, which at first may be only the size of a pinhead, gradually grows, with a slightly broader base and to a point which assumes a whitish color. This is the so-called *singer's node* and in our clinic we have coined the phrase "corns" on the vocal cords because it is almost analogous in its etiology and pathology to the corns on the toes. Occasionally, these nodes are bilateral and when they occur they are usually at the vocal process (Fig. 201). When the vocal nodule takes on more active growth with additional degeneration we have another pathologic entity of the larynx, namely, a fibrous polyp.

FIBROUS POLYP

The symptoms of hoarseness in fibrous polyp (Fig. 202) are the same as in the previous condition except much more pro-

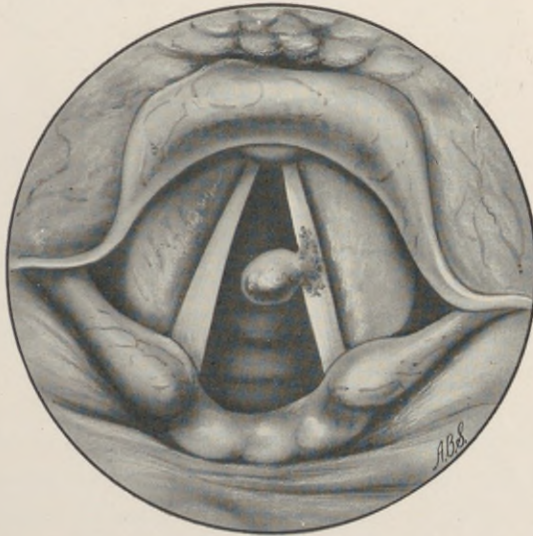


Fig. 202.—Solitary fibrous polyp of the cord (pedunculated).

nounced and there is a constant effort made of clearing the larynx of this movable growth which is usually pedunculated

in character. On inspection during phonation, the greater part of the growth may be found caught between the cords and may deceive the observer as to the actual size of the neoplasm, therefore it is well in doing such an examination to have the patient make a forcible expiratory effort.

The microscopic examination of the vocal nodule, as well as the fibroma, shows simple fibrous tissue in varying stages of development. In the vocal nodule, however, is considerable degeneration of the epithelium, particularly hornification; whereas, in the polyp, we find myxomatous degenerative changes. Throughout the polyps are found numerous capillaries (Fig. 203).

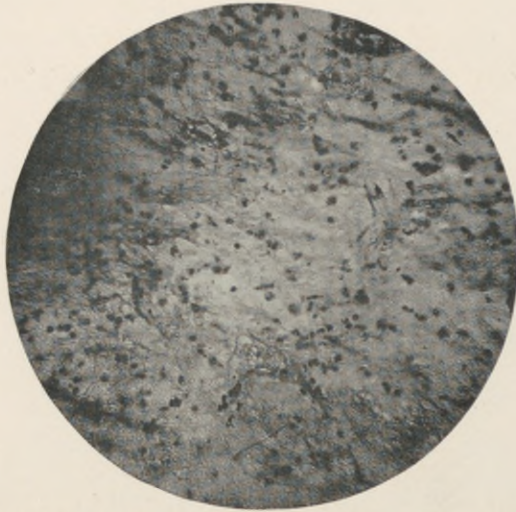


Fig. 203.—Laryngeal polyp showing fibrous tissue in various stages and numerous capillaries. (Low power.)

Treatment.—The treatment of chronic simple laryngitis has already been alluded to in advising attention to the nose and nasal accessory sinuses. As to the larynx, direct vocal hygiene which implies proper use of the voice, avoidance of irritants as tobacco and dust and such other irritants as very hot and cold food or drinks. Topical applications should be used with the greatest of discretion because we have seen numerous cases which have been over-treated by strong astringents, such as nitrate of silver. The mildest astringent treatment in the form of zinc sulphate (1 to 2 per cent solution) and used either in

spray or laryngotracheal injection, as well as liquid petrolatum or chloretone inhalant used similarly, are very gratifying to the patient. It is very rarely that one sees a chronic laryngitis of the type mentioned clear up entirely with recovery of clear voice. One of the most striking recoveries that we have had in this condition has followed the removal of markedly infected tonsils and the clearing up of a grave pyorrhea alveolaris.

In the treatment of the singer's nodes, the best results have been obtained by advising the proper use of the voice, particularly under supervision of an experienced vocal teacher. Occasionally, the nodules are so large as not to respond to the latter treatment and surgical intervention will be required. While we do not describe any surgical measures in this text, we would like to mention here that we had the best results in removing the tiniest vocal nodules by suspension laryngoscopy. Radium has not proved of any value in the treatment of this condition in our hands. The true fibroma polyp is only dealt with surgically.

PAPILLOMA OF THE LARYNX

Papilloma of the larynx is distinctly a disease of childhood and is characterized by hoarseness and very frequently difficulty in breathing. If the physician is fortunate enough to see the case in the very beginning, he will find that the growth usually starts from the free edge of the vocal cord near the posterior commissure (Fig. 204). The entire surface of the larynx becomes involved very rapidly (Fig. 205), and the growth migrates both downwards and upwards, giving rise to considerable embarrassment in respiration.

Early in the disease the growth is soft to the touch and particles can easily be removed during even such a simple examination. If, however, the growth has been removed and recurs, which it frequently does, the sensation on palpation is much firmer. The secondary pus infection of this neoplasm is an important consideration in the pathologic change. The respiratory embarrassment, as well as the therapeutic measure employed to give laryngeal rest, frequently requires tracheotomy and we have observed in two of our cases a true papilloma growing externally around the tracheal fistula (Fig. 206). It is

frequently quite difficult to make an examination in these children but there is one method which to us has proved best and that is by a direct Jackson illuminated laryngoscope.

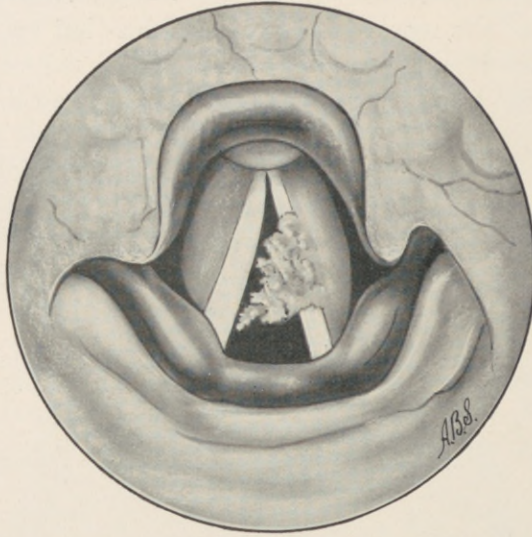


Fig. 204.—Benign papilloma of the ventricular band.

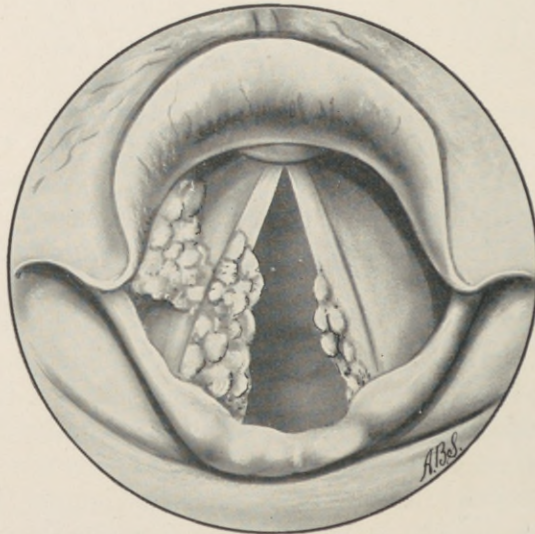


Fig. 205.—Multiple papillomata of the larynx. The sessile base is to be noted.

The histologic pathology consists of the characteristic papillary, finger-like projections, which are principally made up of

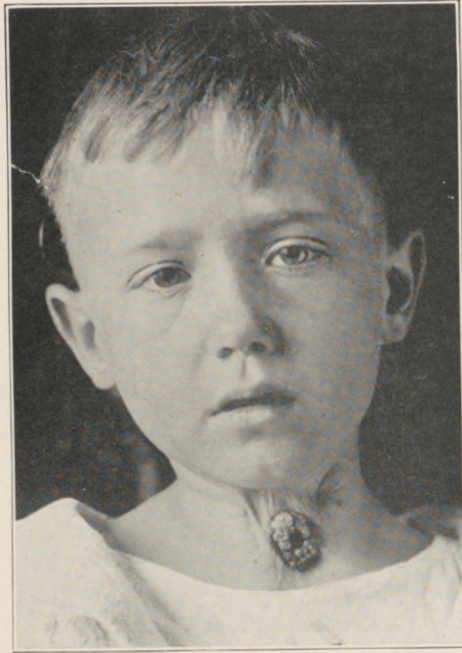

Fig. 206.—Papillomatous formation about the tracheal fistula.

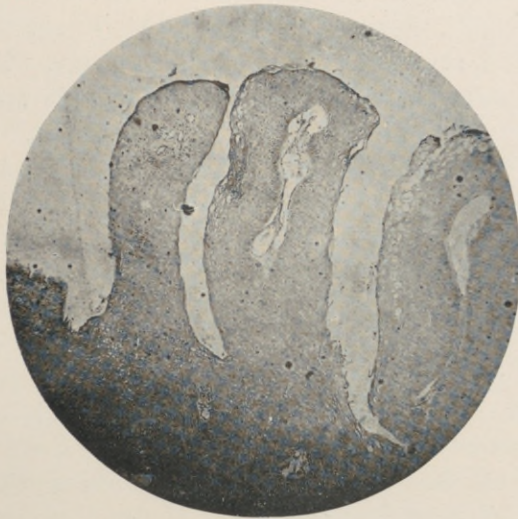

Fig. 207.—Papilloma of the larynx, showing typical papillae formation.

connective tissue containing many small blood vessels and covered with a thin layer of pavement epithelium (Fig. 207).

In the examination of the tissue from the recurrent papilloma, more evidence of connective tissue formation is found, probably due to the secondary infection.

The treatment has received a great impetus in recent years in the employment of radium. No other neoplasm is so favorably influenced by radium as is this, especially if attacked early or in the nonrecurrent type, but even in the event of the recurrence this mode of treatment has proved efficacious. As to the technic of radium application, as we do in other electro- and radio-therapeutic measures, we refer the reader to standard texts on the subject. We would like to say, however, that we practice teamwork in having the radiologist treat these cases with us. The principal treatment still in vogue in this condition is the surgical removal and in reference to this phase the reader is referred to Loeb's text book.

ECCHONDROMA OF LARYNX

We have observed two cases of this unusual condition of the larynx, one occurring in a vocal teacher. These neoplasms were in both cases small, sessile, one being located near the posterior commissure and the other being most anterior. The cardinal symptom in both was hoarseness, the diagnosis clinically was fibroma, and surgical intervention was carried out. One growth was removed by suspension laryngoscopy and the other by the external subhyoid route and both patients obtained very satisfactory voices.

The histologic examination revealed the growth to be principally made up of hyaline cartilage.

LARYNGEAL PARALYSES

Laryngeal paralysis does not at all times come within the domain of the laryngologist. It may be considered as distinctly borderline. The most frequent form of paralysis of the laryngeal muscles is that due to involvement of the *left recurrent laryngeal nerve*. This is the result of pressure either by an

aneurysm or mediastinal growth. Other such cases have resulted either from pressure on the nerve by an enlarged thyroid gland or postoperatively in removal of this gland. We have seen one case in which the clinical diagnosis was tuberculosis of lymphatic glands of the neck and in which the sputum showed large numbers of the tubercle bacilli, even though the chest examination was absolutely negative for tuberculosis. X-ray examination in this case likewise showed no evidence of a tuberculous focus in the lungs. The larynx, in addition to the paralysis, showed a very mild inflammatory process that could not from clinical examination be considered a tuberculous laryngitis.

Treatment is directed towards the etiologic factor. Little can be done for the associated hoarseness and cough.

Abductor paralysis of the larynx is invariably associated with other bulbar symptoms. Immediate tracheotomy becomes necessary when the alarming symptom of suffocation, with inspiratory stridor is present. The pathologic change is a nerve degeneration from the bulb. The prognosis is very grave and a permanent tracheotomy is usually necessary. In recent years laryngologists have practiced removal of the vocal cords on one side and we have had two such cases with permanent relief from this procedure. In one case the larynx was slit, while in the other the resection was done under suspension laryngoscopy. In this type of paralysis sensation of the larynx is abolished, which gives the additional difficulties of food and fluids entering the respiratory tract. This, as a rule, results in a severe spasmodic cough and not infrequently in a bronchial or pulmonary infection. It is to be noted here that in recurrent laryngeal nerve paralysis the pathological process is in reality a pressure atrophy. The nerve is at first stretched and subsequently undergoes degenerative processes.

A functional or hysterical laryngeal paralysis is quite common. The only change that has been noticed in these cases in which there has been persistence of the aphonia is the apparent atrophy of the musculature of the vocal cords. The clinical picture of such a case is the bilateral bowing of the vocal cords, leaving a large space in the middle in the efforts at approximation. The arytenoids come together fairly well.

Suggestive therapeutics or psychoanalysis have been used. Our most successful results have been obtained when these measures have been combined with treatment directed to the larynx; i. e., the application of the galvanic, faradic or high frequency current. The most frequent error in differential diagnosis between the various types of paralyses is that of mistaking a unilateral paralysis for a neoplasm with fixation of the arytenoids.

CHAPTER XI

CHRONIC DISEASES OF THE TRACHEA, BRONCHI, AND ESOPHAGUS

It has been only in recent years, since the advent of direct bronchoscopy, that diseases of the trachea entered the realm of the laryngologist.

CHRONIC MUCOPURULENT TRACHEITIS

In chronic mucopurulent tracheitis there is marked thickening of the mucosa and increase in both vascular and glandular elements. Examination shows a deep red injection with irregularly distributed areas of thick, tenacious secretions. Microscopically, the picture is typical of a chronic inflammation and the mucous glands are distended.

Treatment.—In the treatment, one must direct his efforts to determine the primary etiological factor; i. e., whether the condition is secondary to sinus disease or is a primary infection of the trachea itself. It is very often secondary as a complication of an acute rhinopharyngitis. Local treatment consists essentially of removal of the secretions by suction, either by direct bronchoscopy or under suspension. The local application of mild astringents, such as silver nitrate, is of benefit. Intratracheal injections of oily mixtures are soothing to the irritable cough which is invariably present. Autoinjections can be accomplished by the technic suggested by Dundas-Grant. This can be simplified by teaching the patient to pass a soft rubber catheter until it extends just below the soft palate and with the head well back, slowly injecting the solutions into the larynx and trachea, making an effort not to swallow during the period of injection. If methylene blue is added to the solution, it can be definitely proved that medication applied in this manner reaches the larynx and trachea.

At times the mucus is so tenacious as to necessitate irrigation with normal salt or sodium bicarbonate solutions. The internal administration of expectorant mixtures, such as ammonium

chloride and ipecac is of benefit. Change of climate, particularly to the mountains of North Carolina, in reality gives the very best results.

SYPHILITIC TRACHEITIS

Syphilitic tracheitis is usually associated with an extensive syphilitic laryngitis. The pathologic process is essentially the same as in the latter case, but the ulcerations are usually multiple and at times involve the complete circumference of the trachea. During the process of healing marked cicatricial contractures occur.

Treatment.—In addition to antisyphilitic measures, the local application of silver nitrate solutions to the lesions is of advantage. This can be done either by direct bronchoscopy or suspension. In the resultant scars and strictures it may be necessary to pass bougies, particularly electrically heated bougie tube (Fig. 208), and at times intubation or tracheotomy is indicated.

NEOPLASMS OF THE TRACHEA

Although any of the forms of malignant or benign growths may involve this region, we have seen only carcinoma, papilloma and adenomatous thyroid gland perforated by pressure.

Carcinoma of the Trachea

Carcinoma of the trachea is usually so far advanced when the patient presents himself for examination as to leave very little doubt as to the diagnosis. Upon examination an irregular mass is seen, usually, with streaks of blood over its surface. Hemoptysis is frequent, particularly after the violent spasms of coughing. Removal with a punch forceps or curet of a piece of tissue for examination will reveal the type of malignancy. In our case it was an adenocarcinoma.

Treatment.—Surgical resection supplemented by radium or x-ray offers the only hope.

Papilloma of the Trachea

We have had three cases of papilloma of the trachea, all co-existent with papillomata of the larynx. In one of our cases an

extensive papillomatous mass extended externally through the tracheotomy wound. (See Fig. 206.) The treatment consists of radium and surgical removal.

ADENOMA OF THE TRACHEA

Primary adenoma is exceedingly rare in this location. We have had one case which was a direct extension of adenoma of the thyroid and pressure of the growth caused atrophy of the cartilaginous rings. The associated growth of the thyroid gland suggested the diagnosis and the removal of the main gland verified it. A secondary plastic reconstruction of the trachea with a rib transplant gave a very good result.

BRONCHORRHEA

Bronchorrhea is essentially a disease for the internist to manage but in recent years, since the advent of the bronchoscope and suction, considerable benefit has been obtained in this stubborn condition. It is essentially a chronic purulent bronchitis.

Treatment.—The patient is placed in a semi-Trendelenburg position and irrigation instituted through the bronchoscope of one side of the lung at a time with a sodium bicarbonate solution (10 grains to the ounce), alternating with immediate suction and subsequent insufflation of bismuth powder is carried out.

CARCINOMA OF THE ESOPHAGUS

The most frequent chronic disease of the esophagus that the laryngologist meets with is carcinoma. The location of the neoplasm varies and in our experience we have found it most frequently in the upper half, and the majority of these (perhaps 50 per cent) in the vicinity of the cricoid cartilage. Unfortunately in most of these instances the growth was so far advanced that only palliative measures could be instituted. The examination by the esophagoscope is positive but precaution is to be exercised in passing the instrument so as to prevent hemorrhage and perforation with its complications. Biopsy and microscopic sections may be made. Early gastrostomy is to be

advocated so as to enable the radium treatment to be successfully carried out. This latter treatment may be either implantation of radium emanations, radium needles or a tube containing radium capsules (refer to texts on this subject). We have also employed short wave-length x-ray.

ESOPHAGEAL DIVERTICULUM

Esophageal diverticulum is a borderline condition and the description of the same is withheld to the publication of the borderline of nose, throat, and ear diseases. Suffice it to say, however, that in the differential diagnosis, many times this condition has been confused with a carcinoma of the esophagus. The radiogram together with the barium meal is so positive a diagnostic test of this condition that it leaves very little doubt. The esophagoscope in finding the opening to the diverticulum is of additional value.

STRICTURES OF THE ESOPHAGUS

The most common form of strictures is secondary to burns by caustic lye which is being employed as a household cleanser. Efforts are being made to prohibit the sale of this substance for such purposes because of these accidents and to educate the laity; however, such mishaps still occur and with considerable frequency. Other caustics such as carbolic acid and strong alkalis and acids taken accidentally form another larger group of possible etiologic factors. Post-syphilitic and diphtheritic ulcerations are potent factors, as in their healing-out process there is a great tendency toward cicatrization and subsequent stricture formation. The removal of foreign bodies, especially if they have remained in the esophagus for a longer period, during which time decubitus by pressure has occurred, is frequently followed by stricture. The unskilled use of the esophagoscope and other instruments used in this locality often lead to traumatic esophagitis which may result in stricture. Infection of the esophagus which is comparatively easy, may be followed by abscess and ultimate stricture formation.

Tumors within the mediastinum, such as aneurisms and

Hodgkin's disease may compress the esophagus from without and produce constriction by pressure. The enlarged liver, particularly the lobus spigelii, may constrict the esophagus in its course through the diaphragm. The reader is referred to the pioneer work of Mosher on this subject. Trophic ulcers following extreme burns often occur and give rise to constriction after healing. A large group of strictures of the esophagus are functional or spasmodic, usually occurring in neurotic women. We have already mentioned the stricture caused by malignant disease. The recent war has also brought out the effect of poisonous gases on the esophagus and the subsequent stricture formation.

The diagnosis of all strictures is usually made positive by aid of the fluoroscope and radiogram by use of the barium meal. As



Fig. 208.—Electrically heated bougie for esophagus with thermostat (two other sizes made, one for the nose, another for the eustachian tube.)

to the determination of actual pathology the esophagoscope will be of most value. A thorough history is of inestimable value.

Pathology.—The gross pathology of strictures of inflammatory character will vary as to the causative factor and the duration of the stricture. Post-diphtheritic and syphilitic cicatrices are most dense and form webs partly or completely annular in type. Excision of a particle of a cicatrix will demonstrate the histological character, whether dense or less so. The best prognostic findings are blood vessels within the scar because one can anticipate more successful bouginage and subsequent absorption of the inflammatory products. The cicatrices following the use of caustics are much more amenable to bouginage.

Treatment.—The treatment, aside from that in malignant strictures and those caused by extrinsic tumors, is best carried on by bouginage. The exact technic of this procedure really must be referred to in special texts on the surgery of these parts.

It suffices here, however, to state that medicinal aid such as thiosinamin (gr. iii t.i.d.) or its derivative, fibrolysin, are of value, the latter being given hypodermatically, one ampule every other day.

The electrically heated bougie of Freund (Fig. 208) has given excellent results in the few cases in which we have employed it. The technic we have employed is after passing the bougie through the stricture the current is allowed slowly to reach 55° C. It is permitted to remain *in situ* at first five minutes and, within a week, up to thirty minutes, depending upon the results of softening of the stricture.

CHAPTER XII

CHRONIC DISEASES OF THE EAR

CHRONIC OTITIS EXTERNA

Chronic Otitis Externa may be classified anatomically as follows:

1. Pinna.
2. External Auditory Canal.

1. Pinna

Malformations.—These may be congenital or acquired. The following table with accompanying illustrations made up of cases that have come under our observation will suffice to outline the subject:

CONGENITAL

- I. Complete absence of one or both auricles.
- II. Absence of part of ear.
- III. Asymmetry of the two ears.
- IV. Accessory or multiple ears (poliotia).
- V. Abnormally large ears (Macrotia or Otomegaly).
 1. Of the cartilaginous portion.
 2. Of the lobule (length or width).
- VI. Abnormally small ears (Microtia).
- VII. Abnormal form but normal size.
 1. Flattening of the periphery.
 2. Cleft lobule.
- VIII. Abnormal protrusion of auricle (Otopostasis).
- IX. Drooping ears (Roll or dog ears).
- X. False position of the auricle (Heterotopy).
- XI. Adhesions of the ear (Synechia).

ACQUIRED

- I. Complete or partial absence due to:
 1. Traumatic or mechanical destruction.
 2. Thermal.
 3. Chemical.

4. Disease—

- (a) Infectious.
- (b) Malignancy.
- (c) Symptomatic.

II. Enlargements of ear:

- 1. Hematomata.
- 2. Neoplasms.
- 3. Inflammations.



Fig. 209.—A group of congenital malformations of the ear in the process of reconstruction. Four degrees, complete absence to presence of half of the auricle.

III. Abnormal protrusions.

IV. Abnormal form but normal size due to:

Shriveling following perichondritis, infected hematoma or abscess.

V. Adhesions of the ear after abscess, etc. Cicatrization from burns. Postoperative adhesions.

VI. Postauricular deficiencies—Retroauricular fistulae following radical mastoid operations.

A detailed description of this subject would take up more space than can be given in this book. Furthermore, it should be

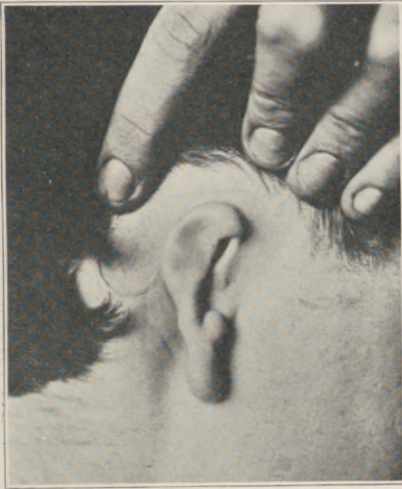


Fig. 210.

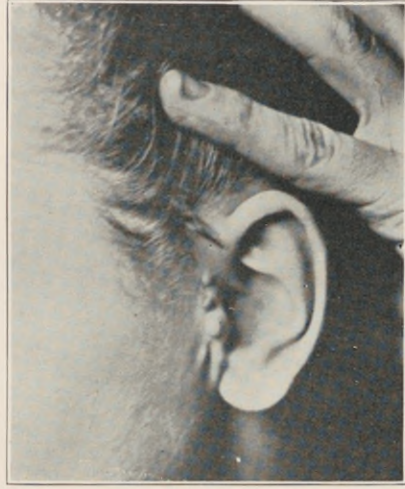


Fig. 211.




Fig. 212.

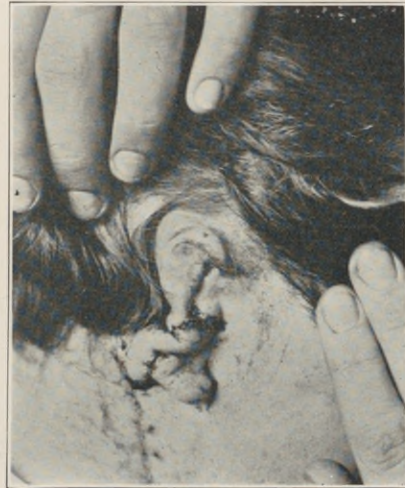


Fig. 213.

Figs. 210-225.—Congenital partial absence of auricle, complete absence of middle and internal ear, right. Polyotia, left. Plastic reconstruction, Gillis method of tube formation from neck. Septal cartilage implants. Twelve separate steps in the operation.

considered as a borderline subject and as such it will be treated in the prospective volume. We wish to call attention, however, to the fact that these ear affections have not received the atten-

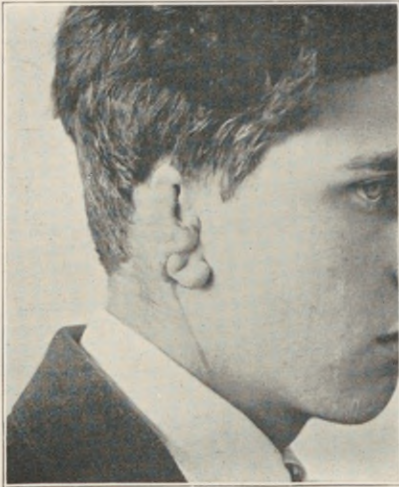


Fig. 214.

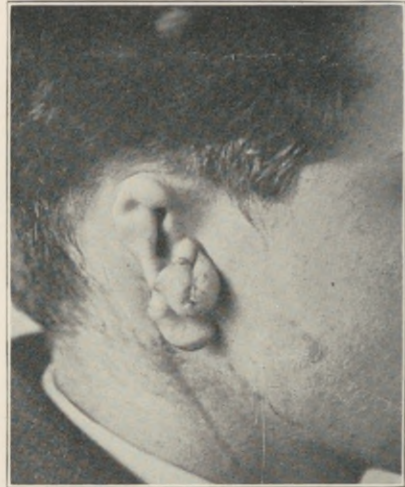


Fig. 215.

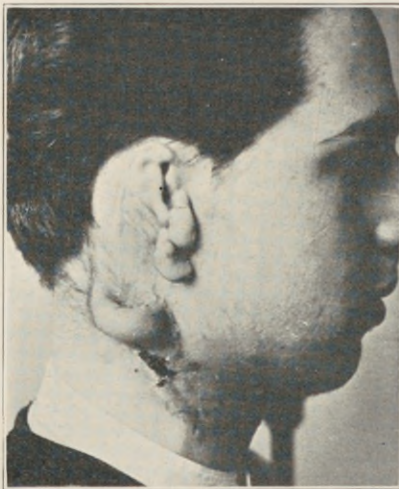

Fig. 216.

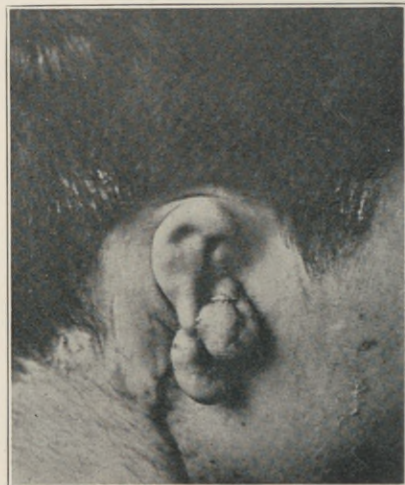


Fig. 217.

tion they should have by the otologist. It is true that this is the most discouraging work we have to do and results from treatment are most unsatisfactory. Yet there are points of

social importance that compensate for the effort. One is the depression that the parents feel in having a deformed child, especially if the condition is congenital, and they wish to have

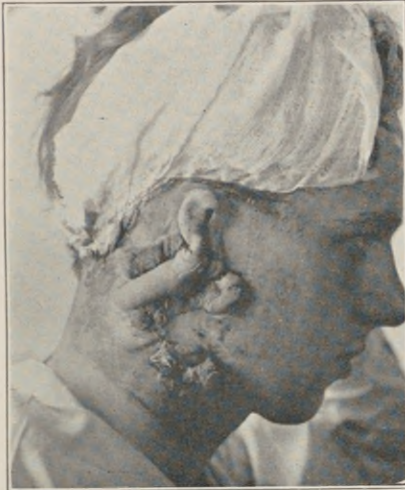

Fig. 218.

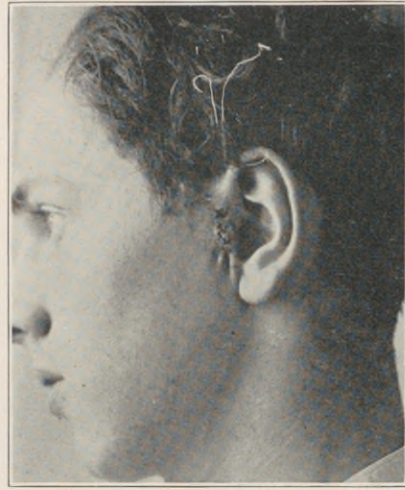


Fig. 219.

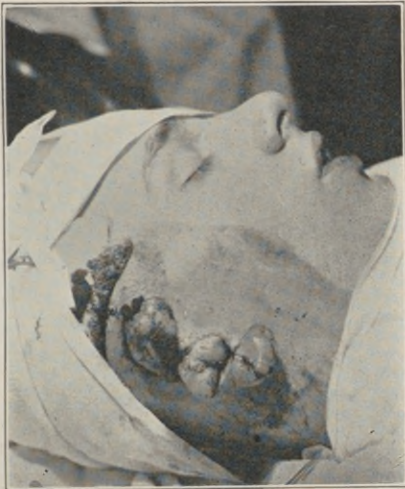

Fig. 220.

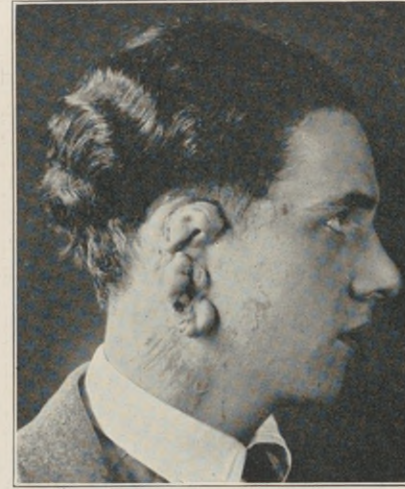

Fig. 221.

something done to correct this deformity (Fig. 209); and the other is the individual, himself, who frequently shuns society on account of the deformity (Figs. 210-225). In most of the con-

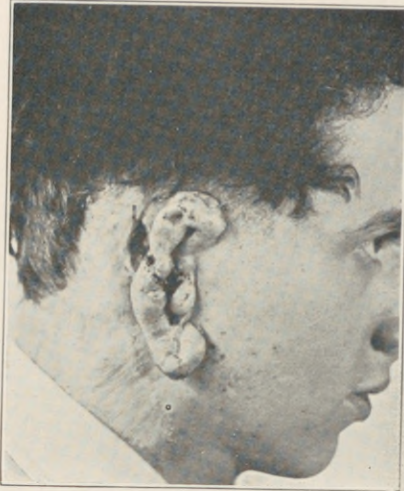


Fig. 222.

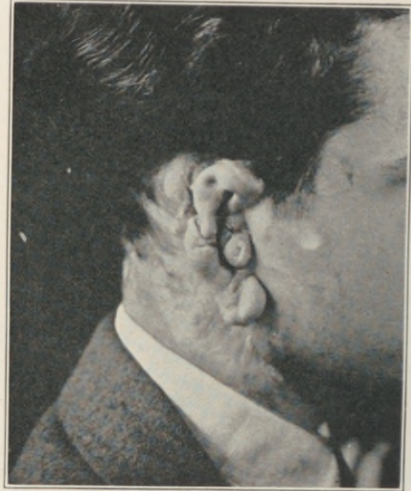


Fig. 223.

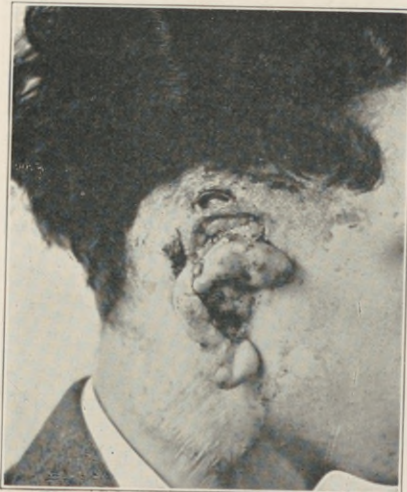


Fig. 224.

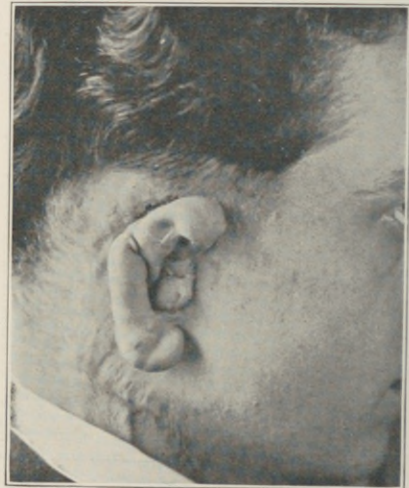
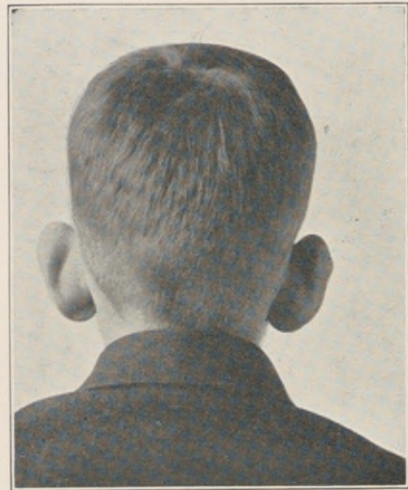


Fig. 225.



A.



B.

Fig. 226.—Congenital macrotia and macrocephalia. Front and back views.



Fig. 227.—Congenital deafness, external ear deformity and right facial paresis in brothers.

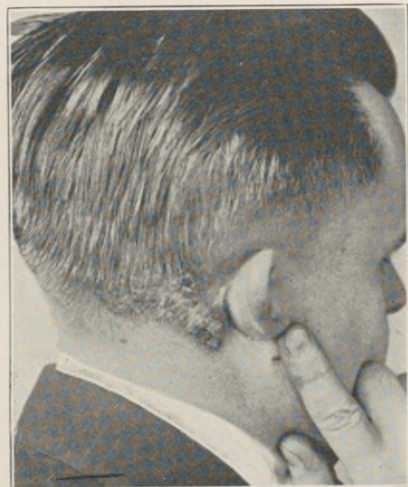



Fig. 228.—Congenital verruca (wart) deeply brown pigmentation. Behind ear.

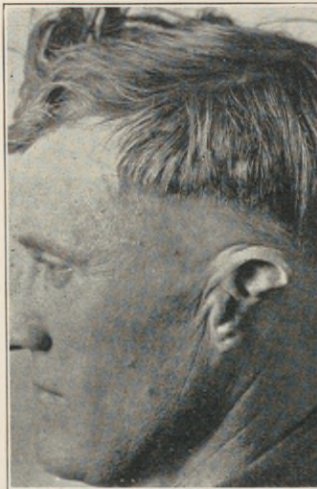

A.

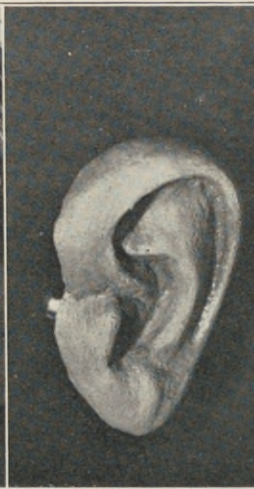


B.

Fig. 229.—External ear completely torn off in elevator accident. Side and back views.



230



231A



231B

Fig. 230.—Part of external ear bitten off by dog.

Fig. 231A.—Artificial ear used in correction of case shown in Fig. 230, as well as in case shown in Fig. 229.

Fig. 231B.—Artificial ear held in place by spectacles.

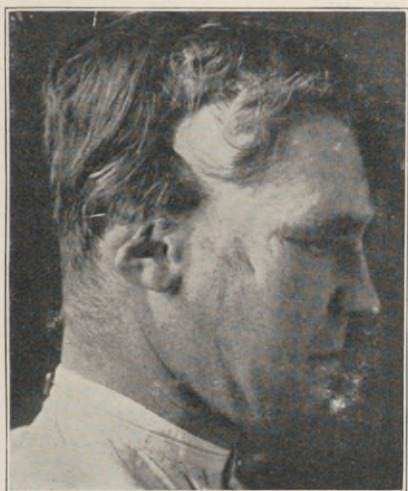


Fig. 232.—Partial destruction of external ear and scars about the face and scalp. The usual deformity following injury by shrapnel in the late war.

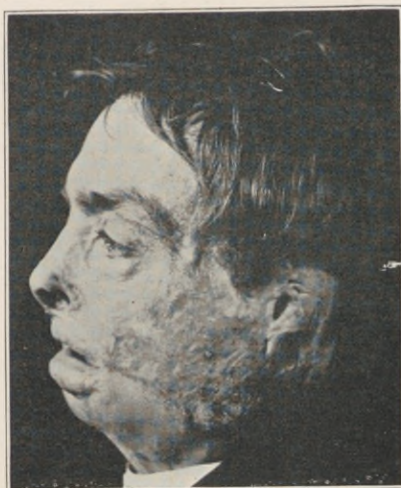

Fig. 233.—Practically complete loss of external ear associated with scarring of the left side of the face and neck following burn of third degree.

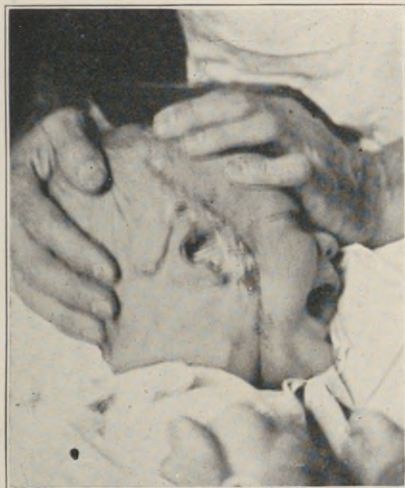


Fig. 234.—Partial loss and contracture of the external ear and side of the face following accidental application of 95 per cent carbolic acid.

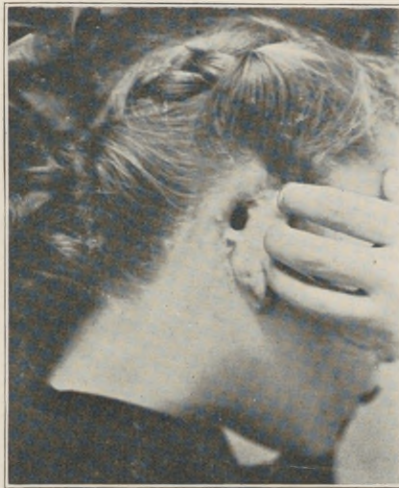

Fig. 235.—Retroauricular fistula following radical mastoid operation.

genital cases the canal, middle and internal ear are also involved. The thorough knowledge of the embryology is imperative in the proper conception of the subject of congenital cases. A large group of the cases are those following disease and injury especially since the war.

In the acquired form each case is an entity of its own and necessitates individual treatment, invariably surgical. The reader is referred to Beck's chapter in Loeb's "Surgery of the Nose, Throat and Ear" (Figs. 229 to 235).

Chronic Eczema of Pinna.—Most of the times chronic eczema of the pinna is associated with the same pathologic process of the external auditory canal; however, there are many cases confined to the pinna and to only part of it. This is particularly the case in association with what is termed status eczematosus in children wherein there is present a phlyctenular conjunctivitis, adenoid and tonsil disease, and enlarged lymphatic glands of the neck. The most frequent location of this eczematous process of the pinna is in the crease behind it and over the lobule. We had one case of the most persistent chronic eczematous condition of the pinna and canal on both sides in which there was present a chronic middle ear suppuration. The bacterial flora was the most complex and the bacillus pyocyaneus could not be recovered from cultures, and there was no green colored appearance of the colonies. If any organism was at all predominating it was the *Bacillus pseudodiphtheriae* and prodigiosus. Only after a radical mastoid on both sides did the eczematous process abate, but the condition never did clear up entirely.

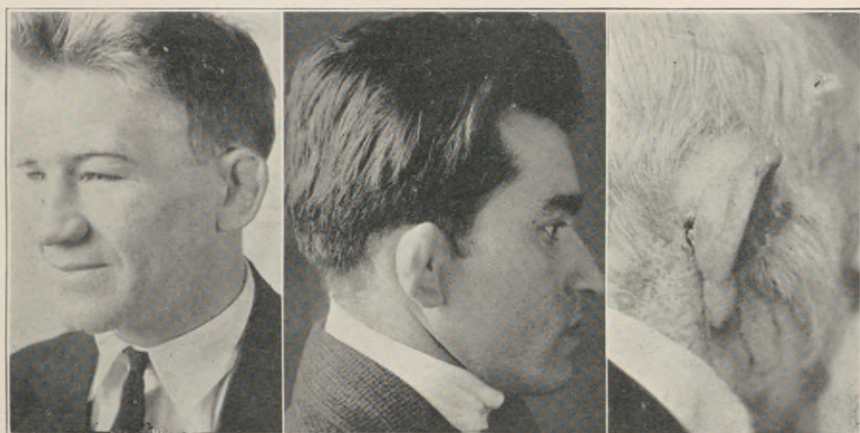
The treatment is that of chronic eczematous condition anywhere of the body and since the bacillus pyocyaneus is very frequently present in abundance, one will find that boracic acid powder and the application of silver nitrate, 5 to 10 per cent solution, will be the most effective in relieving the symptoms of moisture and itching. Water locally is to be avoided.

Chronic Perichondritis.—Following the acute process of perichondritis, especially of the traumatic infectious form, chronic perichondritis is the most frequently met with. Owing to the absorption of the cartilage and the subsequent contraction of the inflammatory connective tissue, there results a deformity, at

least a marked thickening of the skin and underlying structures (Figs. 236, 237 and 238).

The treatment consists in cleaning up any infectious tract or place that may still be present. The chronic inflammatory products are little if at all influenced by the application of most remedies: Ichthyol or Credé's ointments and tincture of iodine occasionally applied may influence the process of absorption. The deformity is only amenable to surgical plastic measures as implants of cartilage or fascia lata.

Tumors of External Ear.—1. **BENIGN TUMORS.**—We have seen only two cases of nonmalignant tumor, namely, chondroma and paraffinoma, of the auricle.



236

237

238

Fig. 236.—Chronic perichondritis. Prize fighter's tin ear.

Fig. 237.—Chronic perichondritis. Roll or cauliflower ear following spontaneous hematoma opened and infected.

Fig. 238.—Chronic perichondritis with fistula following incision of a subperiosteal abscess.

Chondroma.—There was no history of trauma or inflammation. More than three-fourths of the pinna and part of the external auditory canal began to enlarge and thicken when the patient was a small boy and by the time we saw him at the age of twenty-three he had a smooth growth especially at the helix and antihelix (Figs. 239), which was hard to the touch yet it could be bent slightly. It had not grown any for the past five years and he came only on account of cosmetic reasons. Part of the growth was resected and it cut with considerable diffi-

culty although nowhere was any sensation of bone encountered. The histologic examination revealed normal cartilage cells and no inflammatory products were present.

Paraffinoma.—The patient had a soft roll ear (congenital defect) and an attempt was made to stiffen and reshape it by paraffin injections. The melting point of the paraffin that was injected could not be determined but judging by the feeling of the growth it probably was what is known as Eckstein's hard paraffin which is usually injected hot. The main mass was located at the antihelix (Fig. 240) and on the posterior surface of the auricle. The color of the whole ear was dark red and in

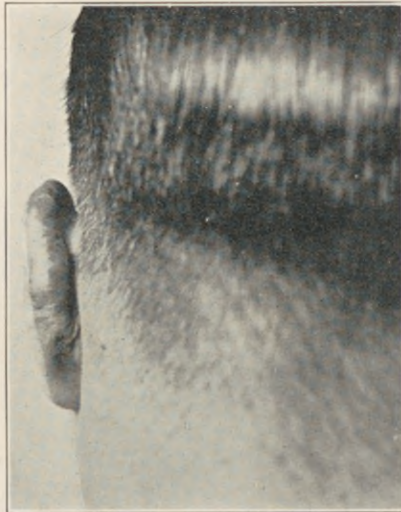


Fig. 239.—Chondroma of pinna and external auditory canal.

cold weather would become cyanotic. Pain was constantly present. The patient said that the mass especially posteriorly was growing. We resected a small and safe portion of the mass from the posterior region and found it to be histologically characteristic of a paraffinoma (Figs. 60-63).

2. MALIGNANT TUMORS.—The most frequently met with malignant neoplasm is epithelioma, or carcinoma, and it is the only kind we have had in our practice. The usual location of its development is at the external auditory meatus. From there it invades the tissues externally towards the parotid gland and neck and inwardly into the canal. The regional lymphatic

glands of the neck are involved very early. The pain, especially of a radiating neuralgic character, is usually present. The

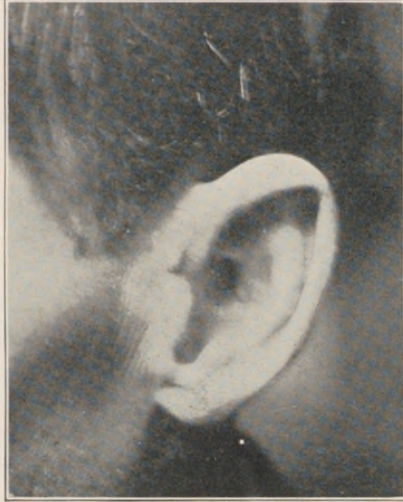

Fig. 240.—Paraffinoma of pinna injected to correct a soft roll ear.

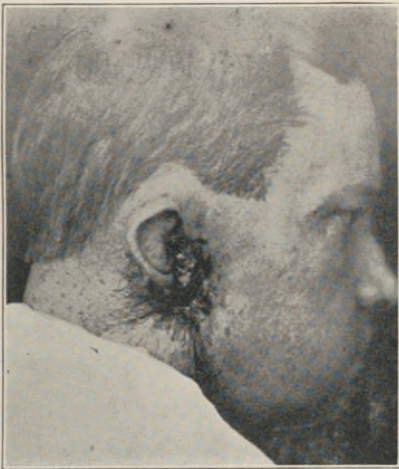


Fig. 241 A.—Epithelioma of pinna and external auditory canal having a parotid salivary fistula, facial paralysis, glands of the neck, and partial ankylosis of the mandibular joint.

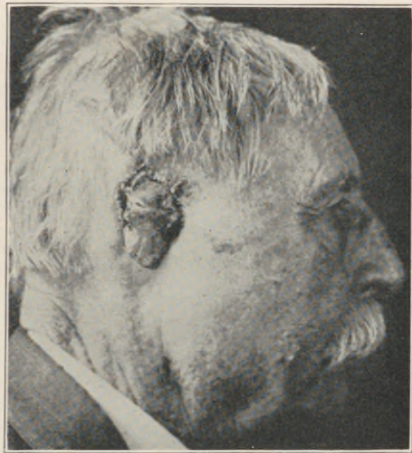

Fig. 241 B.—Total loss of pinna following use of radium for epithelioma. The squama, root of zygoma, and mastoid process exposed and dry (no evidence of bone necrosis or odor).

growth soon ulcerates, becomes secondarily infected, and breaks down, so that a defect soon develops. The neighboring struc-

tures, especially the parotid gland with the facial nerve, become involved very early so that the patient has both a salivary fistula and a facial paralysis. It is also very common to have a marked limitation of motion to the lower jaw from involvement of the mandibular joint.

The patient shown in Fig. 241 *A* had all the symptoms and findings described above. The microscopic examination of such an epithelioma is quite characteristic of poorly differentiated epithelial cells and the pearls are present in large numbers. The blood supply was unusually great in this case and there were frequent hemorrhages from the wound.

If one sees and diagnoses a case very early, then a thorough, wide excision is the only possible chance for a cure. It is very good practice to employ radium and x-ray (short wave-length) before and after operation, but they are not to be substituted for the operation. Only when the case has so far advanced that it is inoperable should x-ray and radium be employed alone. It is further necessary to remove all enlarged and small or visible lymphatic glands which are tributary to the location of the growth. Large doses of morphine are frequently necessary to subdue the severe pain. The odor which is always present is best controlled by formalin soaked dressings. Recently we employed the electrocoagulation method of destruction of an epithelioma of the pinna and found that the odor was much less than following the use of the cold method of operating. Should a patient have no recurrence following any methods of treatment, then the defect is to be corrected by plastic. It must be remembered, however, not to cover too early any area that is the least suspicious; therefore, waiting for six months to a year is good practice.

External Auditory Canal

Cerumen.—Inspissated wax in the external auditory canal is a very common trouble and only when it either completely blocks the canal or comes in contact with the tympanic membrane does it produce symptoms. Certain individuals are more predisposed to suffer from the accumulation of ear wax, particularly those persons following certain occupations. We have observed it mostly in bakers, street cleaners and people working in cloth and clothing factories.

Very frequently during the extremely hot weather, the patient will notice the sudden shutting off of his ear and difficulty in hearing. Contact with the drum may produce more stormy symptoms, such as tinnitus, dizziness, vertigo and pain. The pain frequently radiates toward the head and neck. Slight deviation from the normal configuration of the canal or bony excrescences may play a part in the retention of the wax, especially if for some reason the ceruminous glands may become irritated and hypersecretive. The treatment is to remove the wax and this is best accomplished by syringing it out. The stream is to be directed up and backwards in the auditory canal. The inspissation of the wax plug is often so marked as to require a preliminary softening for removal. A solution of sodium bicarbonate, gr. xv, glycerine dr. iii, and water oz. i, dropped into the ear several times during the day will suffice. Peroxide of hydrogen may be used instead. Should the ceruminous plug not come away after this application, followed by syringing with warm water, then one must remove it mechanically. This is to be performed with the greatest of care since traumatism is very easily produced. At times a cholesteatomatous mass mixed with it or with dirt may be mistaken for a wax plug and this is usually much more difficult to remove than simple cerumen.

Chronic Eczema of the External Auditory Canal.—This is very frequently associated with either an eczematous process of the pinna or it may be secondary to, or associated with, an acute or chronic suppurative middle ear disease. The pathologic change is the same as eczema in any part of the body. The most distressing symptoms are itching and scabbing. This leads to the patient's using all sorts of things to scratch the ear, such articles as ear spoons, hairpins, matches, toothpicks, pencils and the finger nails. This usually causes an infection and oftentimes an acute diffuse otitis externa.

Treatment consists in prohibiting the use of these implements and avoidance of the use of water. The canal should be packed with gauze impregnated with ointments and we have found the ammoniated mercury, 5 per cent, or ichthyol ointment, 10 per cent, most satisfactory in our practice. Most frequently after the process has almost recovered, there is a recurrence, and therefore we consider this affection practically incurable. The

stenosis of the canal that so frequently accompanies this condition, especially in the cases of chronic suppurative otitis media, may become very significant in the possible cause of retention. The treatment of this latter difficulty is the gradual dilatation by firm gauze packing. The underlying pathologic condition of the stricture is a chronic subcutaneous infiltration, even a perichondritis and periostitis; especially is this found in the cases that followed the repeated acute diffuse otitis externa and particularly where the bacillus pyocyaneus was predominating or where the moulds existed for a longer period.

Chronic Otitis Externa Sicca or Exfoliata.—Some of the most persistent external ear cases are those where the patient complains of constant itching and where we find nothing but a dry canal and instead of cerumen a detritus which when closer examined is found to be mostly exfoliated epithelial cells and small particles of hard wax. This formation is probably the result of the constant scratching of the canal in response to the itching. The dry canal without the itching is frequently found associated with progressive deafness of the chronic inflammatory form. We are of the opinion that both the dryness and itching of the external auditory canal is the result of a disturbance of the fifth nerve either ganglionic or peripheral, the itching being irritative and the dryness trophic. There is possibly an analogy between this ear affection and that described as herpes zoster oticus, which has been definitely established by J. Ramsey Hunt as a disease of the geniculated ganglion. We have in one case of herpes zoster oticus complicated with facial paralysis, elicited a history of marked itching of the canal for a longer period preceding the acute attack of blisters. We also associated a chronic peritonsillitis with recurrent quinsy as a possible etiologic factor. The marked itching that this patient had had was cured following a tonsillectomy, as was the more rapid recovery of the herpes zoster and facial paralysis. We also have a fair number of these dry and itching ear canals that were relieved by tonsillectomy and attention to the teeth. Other treatment than the above is only symptomatic. We have found the home use of an ointment made up of phenol, menthol and anesthesin each gr. x in lanolin ʒ i, to give most relief. This is applied into the canal by means of a properly cotton wound

tooth pick. Internally sedatives as bromides are at times of benefit.

Chronic Otitis Externa in Which Moulds Are Present.—

Chronic otitis externa in which moulds are present is a very persistent form of ear disease, unless a positive diagnosis by the aid of the microscope is made, when treatment is usually very efficacious. The mould present may be the *Aspergillus* which may be black (*niger*) or yellow (*flavus*) and at times greenish (*fumigatus*). The *Penicillium* variety may also be present, as well as other varieties, as *Verticillium*.

The extreme itching present with the patients frequently removing masses of detritus from the ears is very significant. Pain is not an infrequent sign due to the inflammation of the canal. As stated before the microscopic examination showing the mycelium is absolutely necessary. The treatment consists in withholding watery solutions in irrigation of the ear. Instillation of salicylic acid in alcohol, 5 per cent solution, every two or three hours (this is at times very painful for a few moments) for one day, is, as a rule, all that is necessary. The raw canal can be painted with 5 to 10 per cent solution of silver nitrate and that followed by zinc salve.

Animal parasites that appear in chronic external ear diseases or connected with chronic suppuration of the middle ear are rare, yet we have observed some cases in public institutional practice. These are cases of very negligent indolent persons whose bodily hygiene is bad. It is the maggot that is found incorporated in pus and epithelial masses. The external auditory canal is very much inflamed and in one particular case the regional glands in the neck were much enlarged and tender. The mechanical removal of these larvae (maggots) and thorough cleansing of the canal is usually all that is necessary. Of course, the general hygienic improvement is most important.

CHRONIC OTITIS MEDIA

The various pathologic types may be mentioned as:

1. Chronic otitis media purulenta.
 - (a) Pyogenic
 - (b) Pyogenic and cholesteatomatous

- (c) Tuberculous
 - (d) Syphilitic
 - (e) Foreign bodies
 - (f) Neoplastic
2. Chronic nonsecretive otitis media.
 - (a) Hyperplastic or hypertrophic
 - (b) Adhesive
 - (c) Atrophic.
 3. Otitis media residualis of Wittmaack.
 4. Otitis media serosa or mucosa.

While it is true that the middle ear may be solely involved, yet in the majority of the above-mentioned conditions the mastoid cells likewise participate in the same process. It would be well, therefore, to consider these conditions as tympanomastoid disease.

CHRONIC SUPPURATIVE TYMPANOMASTOIDITIS

Chronic suppurative tympanomastoiditis, which usually follows an acute process which has failed to heal, will show the following pathologic changes:

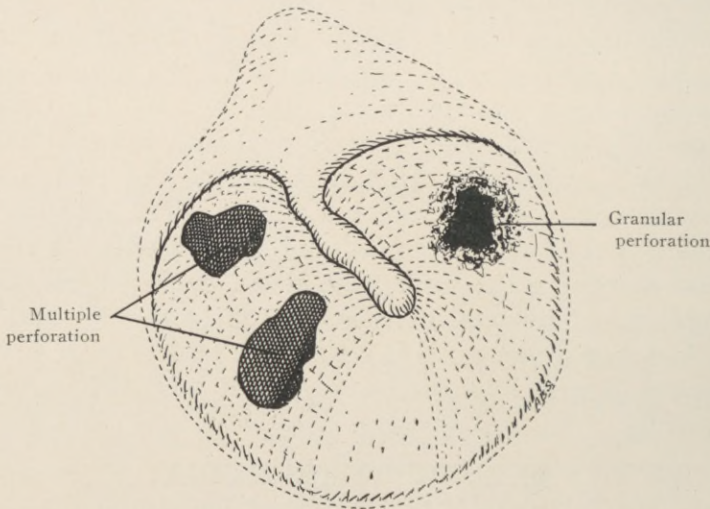


Fig. 242.—Schematic outlines of perforations as to prognosis.

Perforations.—Perforations may be single or multiple, central or peripheral. Considerable information is suggested by the lo-

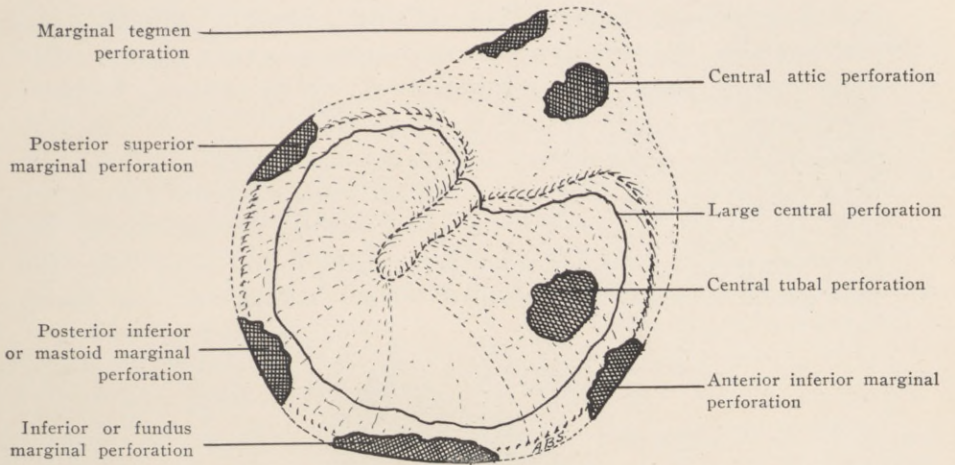


Fig. 243.—Schematic illustration of multiple perforations.



Fig. 244.—Polyp in ear completely filling the external canal in case of chronic suppurative otitis media.

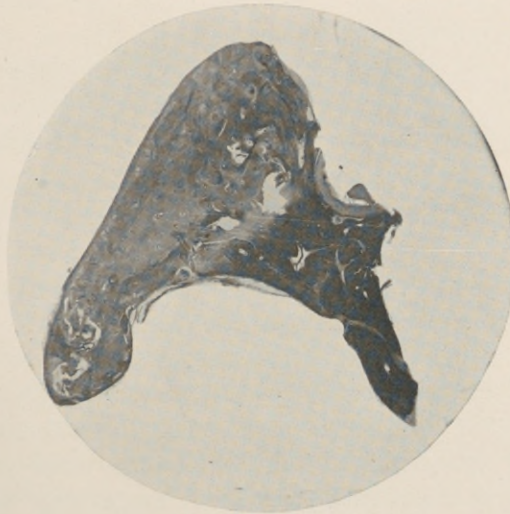


Fig. 245.—Incus removed in case of chronic suppurative otitis media, (showing an osteitis in its long process.)

cation of the perforation. Thus, following the illustrations (Figs. 242 and 243), the central perforations are, as a rule, of very little consequence from the standpoint of complications, whereas peripheral perforations are always dangerous, as to the possibility of the development of intracranial complications. An attic perforation is very apt to be followed by brain abscess or meningitis. Posterior-superior perforations, or necrosis at the incudostapedial joint, are also likely to be followed by intracranial complications. In posteroinferior perforations the facial



Fig. 246.—Ankylosis of the malleus and incus removed in case of chronic suppurative otitis media, showing necrotic areas in both bones.



Fig. 247.—Center perforation healed over by thin scar.



Fig. 248.—Thickened margin of central perforation, showing marked injection of the lining of the middle ear.

nerve and horizontal semicircular canal may be involved. In inferior or fundus perforations the jugular bulb may be involved, with a subsequent thrombosis. In anteroinferior perforation the internal carotid artery must be considered. Multiple perforations whether central or peripheral are suggestive of syphilis or tuberculosis. When granulations surround the perforation it is more likely to be tuberculous. Granulations protruding from a single perforation, especially marginal, are usually of pyogenic origin complicated by cholesteatoma and

necrotic bone. At times this type of granulation may grow into the external canal, forming an aural polyp (Fig. 244).

The ossicles are usually well preserved in chronic tympano-mastoid disease (Fig. 245). However, very frequently, especially in the large central perforations, part of a hammer handle will be found either absorbed or necrotic. Likewise, the malleus and incus may be completely ankylosed (Fig. 246). Healing takes place only in moderately large perforations and a membrane forms which is usually of a grayish, shiny appearance, and can be made out clearly with the aid of a Siegle's otoscope (Fig. 247). The lining membrane of the middle ear proper can frequently be seen through a central perforation, apparently thickened (Fig. 248).

In the mastoid cells from the aditus ad antrum and extending through the entire cellular system one may find various pathologic changes. Either the lining membrane of the cells is thickened as well as the bone, or the cells may be filled with granulation tissue and the bone is soft. At times cholesteatomatous masses may occupy the mastoid cavity to a greater or less extent. The cholesteatomatous matrix can be peeled out in layer formation. Fistulous tracts may be present throughout the mastoid, either single or multiple.

Treatment.—In central perforations, whether large or small, the case is not, as a rule, an operative one. In marginal perforations there is always associated bone necrosis and surgical interference is usually necessary. We believe that the watchful waiting in this type of case is a dangerous procedure. Again, in central perforations attention must be directed to the nasopharynx. Direct medication can be applied through the eustachian tube and middle ear proper. Recurrence will usually follow an attack of acute rhinitis. Such other procedures may be adopted as Bier's hyperemia, suction, vaccines, etc. We have in recent years been using in addition to strong solutions of silver nitrate applied directly to the granulation tissue in the middle ear, such solutions as suggested by Callison, instilled directly into the ear. (Tincture of iodine, 15 drops; phenol, 15 drops; alcohol, 4 drams; water q. s. 1 ounce.) It should be mentioned here that every chronic discharging ear may give rise

at any time to intracranial complications and necessitate operative procedure.

We emphasize the importance of keeping it dry by instructing the patient not to allow water to get into the external ear. Boric acid powder, when the perforation is large, is lightly packed into the canal as far as the tympanic membrane, or strips of gauze are lightly placed in the canal in contact with the perforation. Here we would like to make the point again as we did in acute otitis media, that the external auditory canal is the only place in the body where gauze alone may rationally be used as capillary drainage. Another great aid in our treatment, and




Fig. 249.—Beek's wall plate. Filtered compressed air and gauge; vacuum bottle and gauge; rheostat for light and cautery; illuminating gas outlet; three separate sockets.

which we employ constantly in every case, is capillary suction. The suction is obtained from an automatic pump placed far away from the offices and the vacuum bottle with a gauge is attached to our wall plate (Fig. 249). The cannulae which are the same as shown in Fig. 12, are used and are worked by the same cutoff.

We have also in a limited number of patients given this suction treatment as home treatment by employing the water suction apparatus as shown in Fig. 11, and using the oil silk or rubber flexible tip which prevents injury.

Other means are tried by us such as are employed by most otologists with varying success. In using such antiseptic solutions as acriflavin (1:1000), mercurochrome (5 per cent solution) and gentian violet (1 per cent solution), all of which have a disagreeable tendency to stain the skin about the ear, it will be found that covering the external parts of the ear with lanolin will avoid this staining somewhat. Dakin's solution has been found too irritating and of no particular value.

CHRONIC NONSECRETIVE OTITIS MEDIA

There is a form of middle ear disease that does not show any demonstrable pathology in the accessory spaces of the mastoid. A hyperplastic process involving the drum itself is part of this pathologic condition. The luster of the drum disappears and a distinct thickening of the drum membrane is to be noted. We have had one such case which terminated fatally during an intercurrent cardiovascular disease* in which we were able to demonstrate postmortem diffuse hyperplasia of the mucous membranes in the middle ear. This condition, however, is to be differentiated from a distinctly hypertrophic form, which is a definitely inflammatory disease extending from the nasopharynx through the eustachian tube. Roentgen-ray examination in this type of case will show much greater density in the middle ear region and some clouding of the mastoid cells. We have also had a postmortem examination of a case of this type (hypertrophic) in which death was due to an intercurrent affection.* The mastoid was well pneumaticized and the cells were lined with a thickened membrane. The bone itself was unchanged, in marked contradistinction to the definitely hyperplastic changes involving the bone in the first-named type. In the cavum, the attic, and aditus ad antrum the membrane showed a distinct hypertrophy. The epithelium was considerably thickened and the subepithelial structures much infiltrated, while a large amount of connective tissue was present. The mucous glands appeared larger and more numerous than normal, in the region of the tympanic membrane near the eustachian tympanic opening.

*Microscopic sections of specimens removed at the postmortem were exhibited at the meeting of the American Academy of Ophthalmology and Oto-Laryngology in Denver in 1908. These were lost by the committee on Pathologic Exhibit and consequently it is impossible to have the microphotographs for this publication.

Within the cells proper there was found a serous, though sterile, fluid.

ADHESIVE OTITIS MEDIA

Adhesive otitis media is usually the legacy of a previous hypertrophic otitis media with resulting adhesions throughout the entire tympanic cavity, including the attic. These adhesions may result in change of position of the ossicles and of the drum (Fig. 250). The mobility of the tympanic membrane is therefore restricted to a greater or less extent. At times one will find calcareous deposits in these markedly retracted drums, especially if there is a history of previous existing suppuration (Fig.



Fig. 250.—Marked retraction of the drum with displacement of the ossicles.

Fig. 251.—Calcareous deposit in a drum membrane.

251). In one available specimen from a postmortem examination of a case diagnosed clinically as of this type* there were found to be dense fibrous adhesions in the attic, between Shrapnell's membrane and the ossicles. The ossicles themselves appeared somewhat ankylosed to each other. The eustachian tube showed marked thickening and hypertrophy of the mucous membrane, particularly in the region of the isthmus. Microscopic examination showed hypertrophy of the lining membranes and considerable increase in the connective tissue elements. The blood vessels were small in size and few in number.

ATROPHIC OTITIS MEDIA

Atrophic otitis media is apparently but a further stage of the hypertrophic form in which there is secondary atrophy. The tympanic membrane in these cases is markedly retracted and

*See footnote on page 249.

very greatly relaxed, being easily drawn out but immediately recoiling into its original position. A physical force has been described as the causation of this retraction, a vacuum being produced as the result of occlusion of the eustachian tube. Histologic examination of specimens in this condition* reveals an atrophied tympanic membrane made up chiefly of scar tissue covered with a thin layer of epithelium.

OTITIS MEDIA RESIDUALIS OF WITTMAACK

(Writer's Terminology with apologies to author)

One of the most interesting and fascinating contributions to

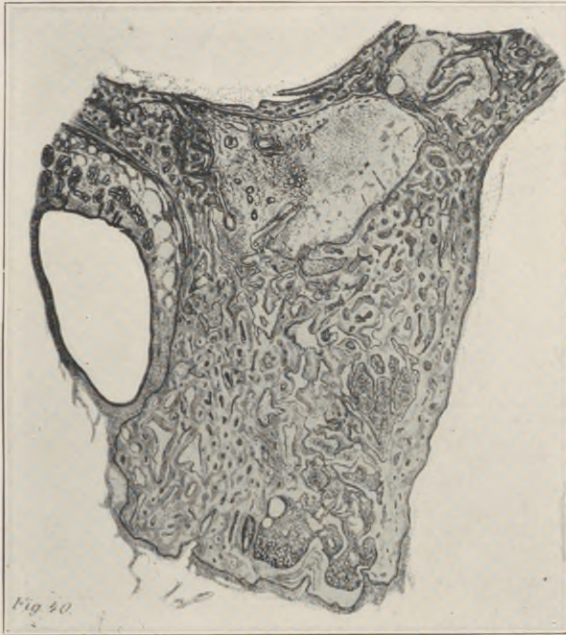

Fig. 252.—Section through the mastoid of a six year old child after latent hyperplastic otitis, showing complete arrest of pneumatization. The bone is sclerotic and the subepithelial tissue filling the antrum is hyperplastic. (After Wittmaack.)

otology is that of Wittmaack. His work is based on years of observation and investigation of the temporal bone at various ages, from fetal life to old age (Figs. 252, 253, and 254). It has particular reference to the pneumatization of the mastoid process. He believes that the ultimate structure of the mastoid is dependent on developmental conditions at birth, which he desig-

*See footnote on page 249.

nates as otitis media neonatorum. This is the result of amniotic fluid finding its way into the middle ear during parturition, thus giving rise to a cessation of the normal process of absorption and subsequent pneumatization. He is of the opinion that a type of myxomatous material remaining within the middle ear is responsible for the development in later life of various affections of the ear. He feels that this material is subject to infection, giving rise to the recurrent otitis media of childhood and

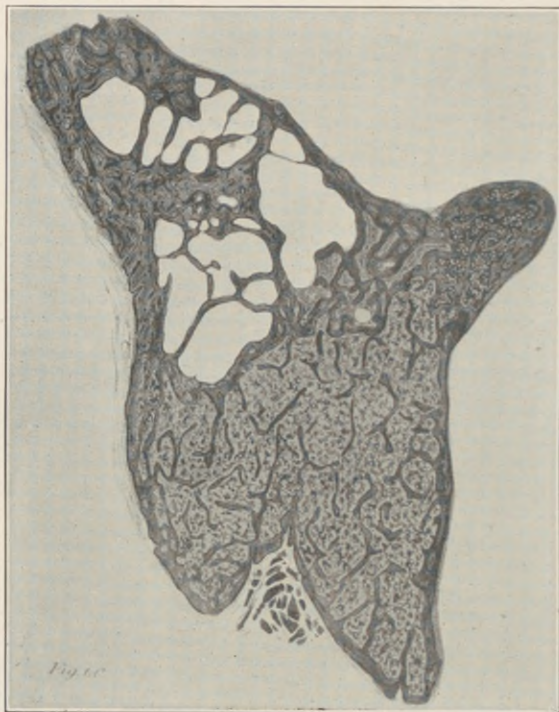


Fig 253.—Section through the mastoid tip in a two year old baby, showing a partly pneumaticized mastoid, with the nonpneumaticized portion filled with marrow cells and a partly developed cellular network. The mucous membrane shows fibrinous changes and there is much fat present. (After Wittmaack.)

to the chronic adhesive processes of later life. Arrested pneumatization may therefore result, which predisposes towards suppurative conditions of the mastoid cavity. He believes, furthermore, that the so-called sclerosed mastoid associated with chronic suppuration is not the result of the suppuration *per se*, but that the sclerosis is primarily an arrest or failure of pneumatization.

We are at variance with several factors suggested by Wittmaack. For the past ten years we have as a routine x-rayed the tympanomastoid region of every case of progressive deafness, and have found clear pneumatization of the mastoid cells in a great majority of cases of chronic, nonpurulent otitis media. We furthermore believe that the sclerotic process is a reaction

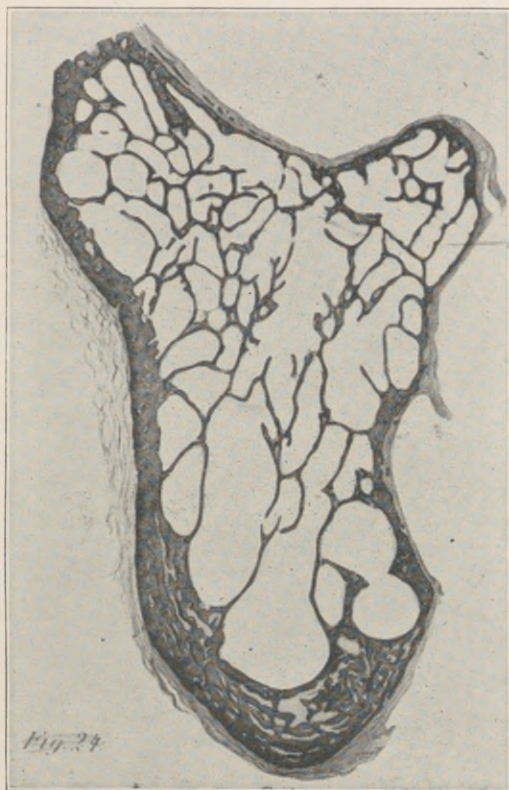


Fig. 254.—Section through the mastoid in an adult 60 years of age, showing normal pneumatization. At the periphery one sees active pneumatization going on. (After Wittmaack).

to inflammation and not a developmental abnormality as a result of the presence of amniotic fluid within the middle ear cavity. A case will emphasize our belief.

Miss H., aged twenty-five years, a medical student, developed a violent right acute otitis media with bulging red drum and pain over the mastoid and temporal region, necessitating paracentesis. Stereoroentgenograms of both mastoids showed a

clear and extensive pneumatization of both mastoid processes. The acute processes progressed to a chronic suppurative otitis media and after nine weeks' observation and treatment, the patient went to China. Eight years later she returned to us and examination of the right ear showed a purulent discharge from the postero-inferior marginal perforation, with a very foul odor. The hearing in that ear was markedly reduced. The patient complained of vertigo and unilateral headache. Roentgen examination at this time, eight years after the acute process, showed a completely blocked mastoid with no vestige of any mastoid cells in evidence. A radical mastoid operation was performed and not a single cell was found throughout the entire process, with the exception of the antrum which was likewise

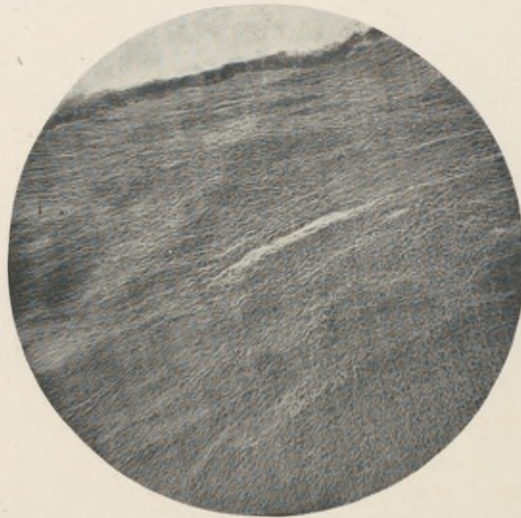


Fig. 255.—Osteofibrosis and chronic suppurative otitis media showing complete fibrosis of the mastoid cells. The bone is changed into fibrous tissue. There is no evidence of any recognizable bony structure or necrosis.

practically obliterated. Microscopic examination of chips of bone removed showed a distinct fibrosis and no evidence of pneumatic cells (Fig. 255).

CHRONIC OTITIS MEDIA SEROSA OR SEROMUCOSA

Chronic otitis media serosa is comparatively rare and seldom the forerunner of an infectious process. It usually occurs in the aged, particularly in those who appear to have excessive secretions in the nasopharynx. The tympanic membrane appears thickened and gray and often shows a dark line traversing it horizontally. This line appears to change its position when the

head is tilted forward or backward. Upon inflation one can hear the gurgling sound of free fluid in the cavity. Inspection of the drum immediately after such inflation will show scattered spots. Upon incision of the drum membrane a serous or seromucous fluid will be emitted, especially when aided by the Valsalva method. At times it has been necessary to establish a permanent perforation with the actual cautery in order to provide exit for this increased seromucous secretion because these incisions have a tendency to close too soon. We have operated upon one such case in which the patient complained of considerable mastoid pain, and heaviness of the head, the x-ray showing marked mastoid involvement. We operated upon the mastoid and found a marked accumulation of serous fluid within the mastoid cells. The membrane lining of the cells was considerably thickened and the fluid was sterile inasmuch as upon bacteriologic examination, both smear and culture were practically negative. Microscopic examination showed hypertrophy of the epithelium and subepithelium but no glandular hypertrophy. The bone was unchanged. This condition occurring as a unilateral affection would suggest that it probably is not of systemic origin.

Treatment of Chronic Nonsecretive Otitis Media.—The treatment should be directed towards an effort to determine the underlying etiologic factor and correlating the type of pathology present. In all cases the nasopharyngeal pathology should be corrected. However, when there are adhesions, for instance, little therapeutic result can be expected by the straightening of a deflected septum or the removal of hypertrophied tonsils. These measures are much more valuable in the very earliest manifestations of these various aural conditions. In the hyperplastic and hypertrophic forms the introduction of electrically heated bougies through the eustachian tube, by way of a eustachian catheter, is of value (similar to technic in esophageal bouginage) (Fig. 208). The injection of a few drops of a 2 per cent dionin solution into the middle ear once or twice a week will hasten the absorption of inflammatory products. This can best be introduced through the eustachian tube by means of the Weber-Liehl catheter, through a eustachian catheter.

After the dionin produces the desired reaction (hyperemia of the drum membrane), a Bier's suction pump is adjusted to the

external meatus, hermetically closed; and gentle pull on the pump will further tend to break up adhesions. Caution must be exercised so as not to forcibly produce hemorrhage of the membrane.

Nascent iodine introduced per eustachian catheter by means of the apparatus herein illustrated has been used (Fig. 256). The Pfannenstiël treatment has been a favorite of ours for years. This consists of the internal administration of a saturated sodium iodide solution in large doses, 60 to 100 drops within 24 hours. Hydrogen peroxide is then immediately introduced into the external auditory meatus with the head inclined to the opposite side, the peroxide being retained in the canal for



Fig. 256.

ten minutes with five changes of the solution during this time. A chemical reaction takes place in which there is free nascent iodine liberated within the tissues by a process of osmosis (Fig. 257). This is followed by the use of Bier's pump as described before.

The local use of nascent heat will hasten the absorptive process. To accomplish this we have employed heated metallic

mercury, introduced into the external auditory canal against the drum membrane by means of a tube (Fig. 258). The tube contains about 50 grams of metallic mercury, which is heated readily over an alcohol flame for a few seconds. The neck of the tube near the mouth has a rubber collar which allows it to fit tightly into the external auditory canal. To-and-fro motion of the head from shoulder to shoulder while firmly holding the tube in the ear, gives the desired massage and heat to the membrane and the impulse is transmitted to the ossicles. The mercury massage has the combined value of the heat and the action of the impulse against the drum. Inflation is of assistance and the introduction of medicaments, as ethyl iodides, through the Politzer bag is also of value. Mild massage by the

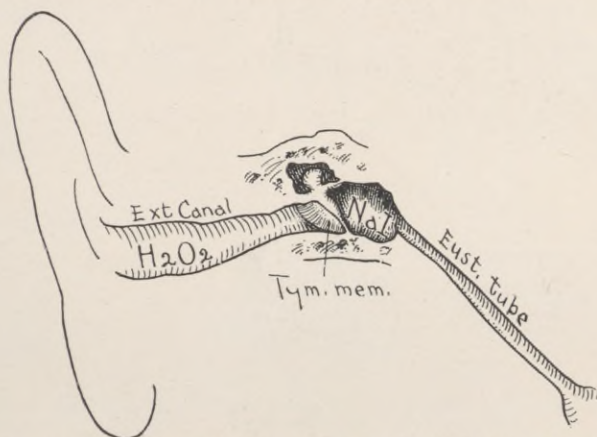


Fig. 257.—Schematic drawing for the Pfannenstiel treatment.

rhythmic pressure of the tragus, producing a condensation of air in the external canal, can be used by the patient. This should be done four to ten times a day, about twenty compressions being made each time. The use of any or all of these remedies, while strictly indicated, is very frequently abused and the condition is aggravated rather than relieved. It is particularly true in the use of the many mechanical appliances, such as the vacuum pumps and concussion apparatuses. In the hyperplastic form it is well to remember the importance of correcting any possible dietary deficiency that may be present, particularly the fat soluble A vitamin and inorganic salts. In the adhesive types not too much relief should be expected from any

method of treatment. Various surgical procedures have been suggested for removing the adhesions but even these have been unsuccessful for the most part. Persistence in treatment and attempts at treatment may accomplish a great deal, and often accomplishes a brilliant result as illustrated by the following case, and could be foisted and made unfair use of in advertising.

THE WEST CASE.—While attending a convention in a small city, in a neighboring state, I was asked to see a lady, twenty-nine years of age, a music teacher, who had for years been very hard of hearing and was now anticipating the unpleasantness of



Fig. 258.—Mercury tube.

having to give up her vocation on this account. The examination showed that she could hear the loud voice only on contact and the tympanic membrane was dull and markedly retracted. The Rinné was negative and with markedly prolonged bone conduction; high tones were very well heard. Inflation gave practically no improvement and Siegle's otoscope showed limitation in mobility of the drum. There was a distinct history of many attacks of rhinosinitis and the family history and the

question of lues were absolutely negative. The Pfannenstiel treatment was advised in combination with the Bier's hyperemia by suction pump which was carried out by her own physician. As a result of this treatment the patient had such startling benefit, as to improvement of hearing, that all who knew the patient were tremendously impressed. The most important point was the lasting effect, which extended over a period of three years during which time the hearing was practically normal for both conversation and whispered voice. At this time the patient died following an infection from an intercurrent disease. In attempting to obtain similar results by this means of treatment in many cases of the same type, we have never succeeded as in this case, but have been able to improve a fair number.

Other methods of treatment by others, as, for instance, the passing of a flexible wire applicator wrapped with a small piece of cotton and dipped into a weak solution of silver nitrate, into the pharyngeal end of the eustachian tube, have been heralded as cures just because of perhaps one case's claiming to be markedly benefited. Such happenings as the West case and the latter may lead to the exploitation of hopeless cases.

In the adhesive type, furthermore, we have used the following procedures: Thiosinamin, 3 grains three times a day is given by mouth. Fibrolysin, one ampule three times a week, has been given hypodermatically. Gentle massage of the tympanic membrane and ossicles by means of the Delstanche pump, in connection with periodical inflation, galvanism, medical diathermy and the high frequency current should be given a trial. We have also used x-ray and radium, with no particular benefit.

In the atrophic variety very little can be accomplished. This condition is usually the end result of a much neglected or much over-treated case. Especially is this true when the practice of autoinflation (Valsalva method) has been followed over a long period of time. This in itself can produce much stretching of the tympanic membrane with secondary atrophy. Heath, of London, has recommended a procedure which has not been accepted generally, but with which we have had, in well selected cases, favorable results. The principle of the procedure is to produce a chemical inflammatory reaction in the drum membrane by the introduction of solutions of cantharidin and sodium hydroxide in varying strengths. This is applied particularly

in the upper posterior portions of the drum. The applications are continued daily until a marked reaction occurs. By gentle massage the resulting scales on the drum can be removed. Inasmuch as the musculus stapedius and the tensor tympani may likewise be relaxed, the deep sinusoidal current should be employed.

In the otitis media seromucosa type, the injection either through the eustachian tube or perforation made in the drum, of mild astringent solutions, especially of zinc, is of some benefit.

SUMMARY OF PATHOLOGIC PROCESSES IN CHRONIC MASTOID DISEASE

Chronic Mastoid Disease

The various changes occurring in the chronic form of mastoiditis can be classified as the following (the various processes, however, may coexist):

1. Osteofibrosis or sclerosis.
2. Osteofibrosis with fistular tracts.
3. Osteofibrosis, fistular tracts and cholesteatomatous infiltration.
4. Osteofibrosis, fistular tracts, cholesteatomatous infiltration with cavity formation containing cholesteatomatous matrix.
5. Tuberculous osteitis.
6. Syphilitic osteitis.
7. Actinomycotic osteitis.
8. Reparative osteitis.
9. Foreign body in mastoid.
 - (a) Sequestrum.
 - (b) Any other substance.
10. Neoplasms.
 - (a) Sarcoma.
 - (b) Carcinoma.
 - (c) Endothelioma.

1. Osteofibrosis.—As the name implies, the mastoid bone is converted into a more or less solid bone (see Fig. 255). The cortex is hard and bleeds very little. The cells are conspicuous

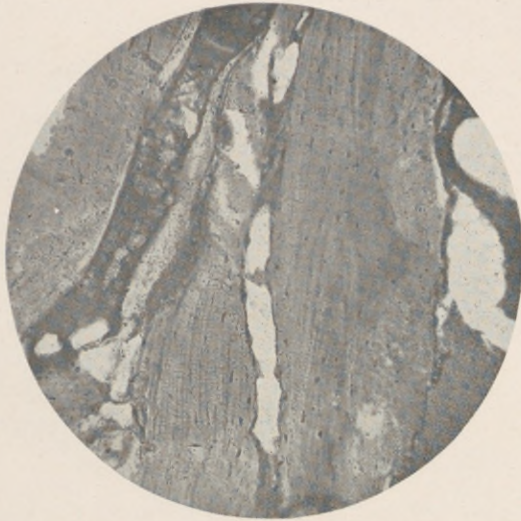


Fig. 259.—Chronic suppurative otitis media, showing osteo-fibrosis with fistulae formation. There are evidences of necrosis, with tracts lined with granulation tissue and filled with pyogenic material. (Low power.)

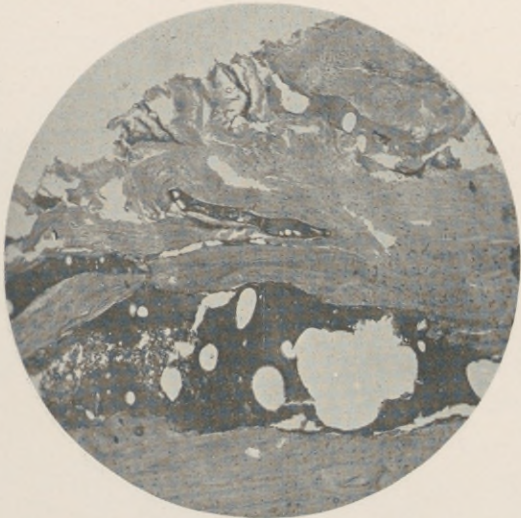


Fig. 260.—Otitis media suppurativa chronica (high power), showing necrosis with accompanying fibrous reparative process—a chronic osteofibrosis with fistulous tract, filled with pus and granulation tissue.

by their absence, and oftentimes not a single cell is found until the antrum is reached. If any cells are present, they are very small and usually located in or near the tip. The degree of

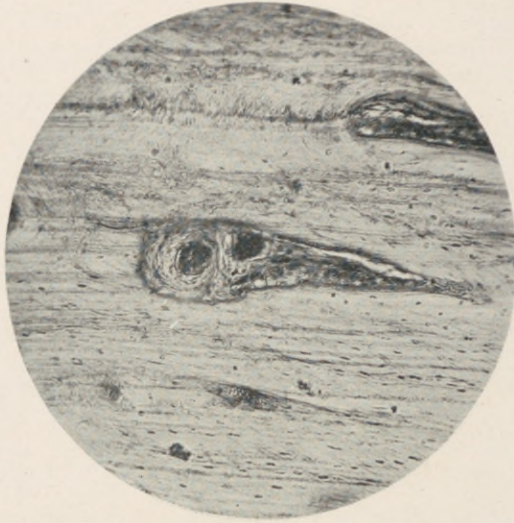

Fig. 261.—Chronic suppurative otitis media, showing osteofibrosis, fistulous tracts and cholesteatomatous infiltration. The epithelial masses have a center of pus and show the spreading into the bone.

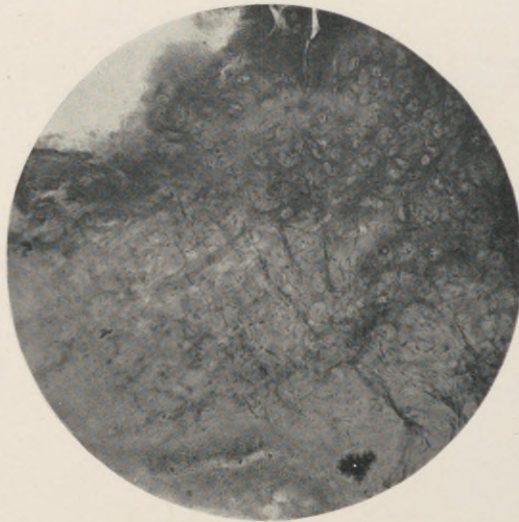


Fig. 262.—Otitis media suppurativa chronica. Showing cholesteatomatous matrix from the mastoid cavity, with erosion of surrounding tissues. The material is poorly stained and shows no differentiation.

sclerosis depends a great deal upon the preexisting type of mastoid structure, i. e., pneumatic or diploic. In the former the fibrosis is more complete than in a large celled mastoid. The

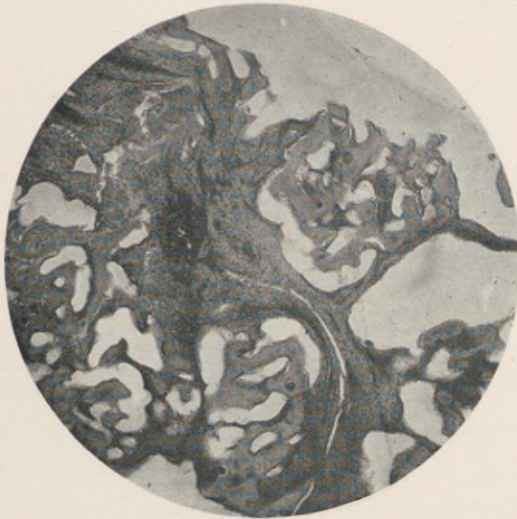


Fig. 263.—Otitis media suppurativa chronica. Tuberculous osteitis with fine, fistulous tract leading towards the surface. The center of the tubercle shows evidence of caseation and round-celled infiltration.

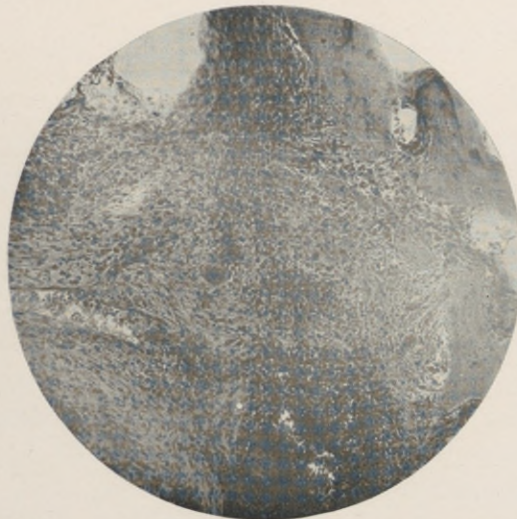


Fig. 264.—Otitis media suppurativa chronica. Showing tuberculous focus with fistula.

histologic findings show the dense bony structure or necrotic areas.

2. Osteofibrosis with Fistular Tracts.—Practically the same findings are encountered as in the preceding form except that a few cells are met with, and a number of tracts lined with granu-

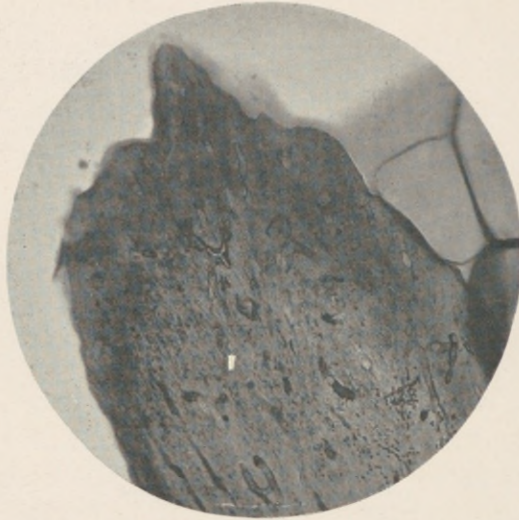


Fig. 265.—Sequestral osteitis showing particularly the worm-eaten appearance of the edges of the sequestrae.

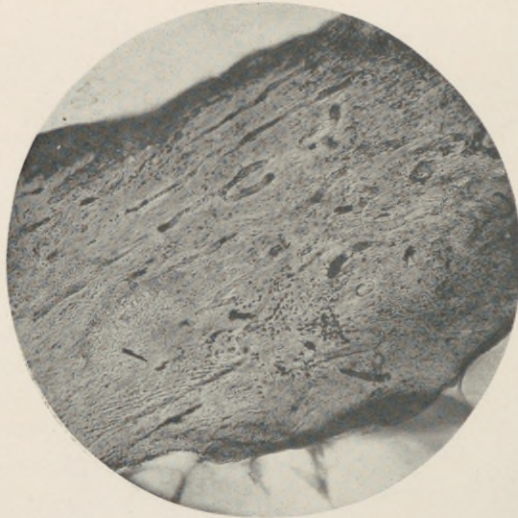

Fig. 266.—Sequestral luetic osteitis.

lation tissue and pus (Figs. 259 and 260). The bleeding is also more pronounced. In these cases there is frequently found an exposure over the promontory of the horizontal canal as well as the tegmen, a condition well to remember in the acute exacerbations, as causes of brain abscess, meningitis and labyrinthitis,

The facial canal, bony lateral sinus wall and other portions of the labyrinth are less frequently the seat of these necrotic areas. These localized necrotic areas are usually covered with granulations and it is considered bad practice to remove them as they serve as protection to further septic invasion.

3. Osteofibrosis, Fistular Tracts and Cholesteatoma.—Again the same pathologic changes are found as in the two varieties previously mentioned and in many cases the cholesteatomatous changes are not possible of detection grossly in the mastoid, but are microscopically (Fig. 261). However, when the antrum, aditus and attic are exposed by operation one will be able to remove a considerable mass of cholesteatomatous material (Fig. 262). All are familiar with the characteristics of these masses, but they can be further identified grossly by the Bruehl test, by adding a few drops of chloroform to a mass which will turn a yellowish green (cholesterin). The microscope will always demonstrate the characteristic crippled epithelial cells.

4. Osteofibrosis, Fistular Tracts, Cholesteatoma with Cavity Formation.—The cavity that is found in these cases varies in size from that of a small marble to the size of the mastoid process and extends in some cases beyond its confines. The location of this cavity may be at the tip, over the antrum or continuous with the attic to the antrum, the so-called spontaneous radical mastoid operation. Pressure atrophy of the bone due to the continuous formation of epithelium in layers like an onion, plus the necrosis due to the infection, is the explanation of this cavity formation. These masses often contain particles of necrotic bone (bone dust) which may be demonstrated by microscopic examination of previously centrifuged washings from the ear. The cavity itself is lined by a glistening membrane known as the matrix from which the new epithelial cells form (see Fig. 262). This matrix is not a mucous membrane or skin, not even an epithelial cicatrix.

5. Tuberculous Osteitis of the Mastoid.—Grossly, this condition cannot be identified, except that it may be suspected when the fistular tract formation is very marked, even finding one or more on the cortex, which is uncommon in other forms of chronic otorrhea. Again there are often softened areas of considerable size surrounded by very dense bone (Figs. 263 and

264). Granulations are also more numerous throughout the mastoid process. Actual collections of pus are present in which, however, we have never found the tubercle bacillus.

6. Syphilitic Osteitis of the Mastoid is as a rule a sclerosed process but not eburnated. At times it is entirely softened containing sequestra of considerable size (Figs. 265 and 266). The granulations surrounding such a sequestrum are large and flabby and do not bleed very much. The three cases of this type which we have identified with subsequent microscopic examination all had the characteristic of having very little calcareous material remaining in the bone (Fig. 267).




Fig. 267.—Mastoid chip in chronic suppurative otitis media of luetic origin, showing an osteofibrosis. The bone is soft in areas and fibrous in other places. Bismuth infiltration also is seen.

7. Actinomycosis of the Mastoid.—Two cases of actinomycosis are on record, one by Majochi and the other which the author had the pleasure of studying under his service with Professor Zaufal and the pathologist Professor Chiari at the University of Prague. It was found that the mastoid bone including the cortex was practically riddled with fistulae containing thick pus in which there were the characteristic yellowish bodies (actinomyces). The bone was quite soft otherwise.

The patient was a farmer of middle age. He was operated upon for mastoid which had a very stormy and protracted

course. Intracranial invasion complicated the case and the patient died following a rupture of the internal carotid artery which became involved in the process as it passed through the temporal bone. Particles of tissue removed from different parts of this bone, as well as the soft parts, showed the characteristic histologic picture of actinomycosis.

The treatment, aside from surgery of the necrotic areas, is the administration of potassium iodide in fairly large doses and the x-ray.

8. Reparative Osteitis of the Mastoid.—The pathologic process refers to the reoperated cases. The previously exenterated



Fig. 268.—Epidermal scar of healed radical mastoid cavity, showing the absence of any blood vessels or any resemblance to true skin. It is scar tissue covered by a thickened epithelial layer.

cavity is either filled with granulations, cholesteatomata or both, or it is lined by the characteristic epithelial scar (Fig. 268). The bone of these cavities is as a rule very hard and the edges or margins of the cavity are thickened and irregular. It always appears (especially if one does the reoperating on his own case) as though the bony cavity were much smaller than when it was made at the previous operation. Bleeding is very free from these granulations as well as from the bone. (See Figs. 39 and 40.) There can scarcely be a description of the various parts of the mastoid since each case is an entity in itself.

9. Foreign Body in the Mastoid.—(a) The sequestered type is, except in the syphilitic osteitis already described, most frequently met with in children, usually the result of an incomplete simple mastoid operation, especially in the cell route or confluent variety of mastoiditis. These sequestra are always surrounded by somewhat healthy granulations, bleeding very freely. The sequestrum is usually very easily dislodged, is irregular in shape and has the appearance of being the axial part of several mastoid cells. At times these sequestra are very small, flat, with very pointed edges (Fig. 265). (b) As to other foreign bodies, they may be shots, bullets, shell fragments, parts of instruments, such as gouges, knife and scissor blades. Surrounding such a foreign body is usually an infected area with or without granulations, depending upon the length of time that the foreign body has been in the mastoid. The only treatment of both types is early operative interference.

10. Neoplasms of the Mastoid.—We have had all the three varieties of malignant growth, sarcoma, carcinoma and endothelioma, but they always resulted from extension of similar growths in the vicinity of the mastoid. In the case of sarcoma, it was a retromaxillary tumor that finally involved the mastoid process. In the carcinoma, it was the result of a progressive epithelioma of the external ear, and in the case of endothelioma it followed a primary growth of that nature from the middle ear. The gross pathology was that of a malignant disease of bone anywhere in the body, except that it was complicated by secondary infection. The microscopic changes are also those characteristic of sarcoma, carcinoma and endothelioma. The type of endothelioma in this particular case was endovascular.

CHRONIC DISEASES OF THE INTERNAL EAR

A thorough knowledge of the pathologic processes concerned in the various diseases of the internal ear is imperative in order to arrive at a proper diagnosis and to institute the proper treatment. Unfortunately, in this country postmortem material is scarce and but little actual pathologic examination of the temporal bone in chronic diseases of the internal ear has been made. Our source of information has, therefore, been from the

clinics abroad. The chief conditions involving the internal ear in a chronic process are as follows:

1. Neuritis of the eighth nerve.
2. Neuritis secondary to middle ear inflammation.
3. Chronic suppurative labyrinthitis.
4. Syphilitic labyrinthitis.
5. Otosclerosis.
6. Traumatic labyrinthitis.
7. Hemorrhage into the labyrinth.
8. Occupational labyrinthine disease.
9. Congenital labyrinthine affections.
10. Neoplasms.

1. Neuritides of the Eighth Nerve.—The etiology in these cases is, as a rule, either toxic or infectious. The process, having been instituted as an acute one, may continue and become chronic. Inflammatory processes may be primary in the nerve itself, or secondary in the nerve as the result of inflammation elsewhere; i. e., otitis media, acute infectious diseases, etc. Alcohol, lead and quinin are particularly apt to cause a neuritis of the eighth nerve. Almost any toxemia, whether it be gastrointestinal or otherwise, may be the determining factor in a chronic neuritis of the auditory nerve. Either portion of the nerve may be involved with equal frequency. Syphilis is a most frequent cause, and there is no doubt that focal infections, particularly in the teeth, tonsils and sinuses, give rise to a chronic neuritis of the auditory nerve, either of the cochlear or vestibular branch, or both. The pathologic process may involve any portion of the nerve.

The symptoms are those of irritation and subsequent destruction of the nerve. In the former instance there is hyperacusis, tinnitus, or dizziness with nystagmus followed by deafness. The functional reactions of the vestibular apparatus are altered.

Treatment.—Treatment primarily is to be directed toward the etiologic factors. If it is toxic in origin, for instance, because of the use of alcohol or tobacco or various drugs, the cause should be removed and vigorous elimination established. When the process is syphilitic, vigorous antisiphilitic treatment should be instituted. During the initial administration of arsphenamine

the clinical symptoms become much worse and this has led many otologists to avoid the use of this arsenic preparation in the treatment of this condition. We, however, are firmly of the belief that it is not a question of omitting arsphenamine but of increasing the size and frequency of the dose. The reaction is rather typical and is known as the Herxheimer reaction. If the cause is suspected to be secondary to some chronic focus of infection, then that should be removed if possible.

2. Neuritis Secondary to Middle Ear Inflammation.—Either during an acute or chronic inflammatory process of the middle ear one may find a true affection of the auditory nerve without the bony structures of the labyrinth being destroyed. In the acute conditions it is very easy to understand how by contiguity of tissues the nerve may become inflamed. In the chronic processes it is more of an anesthesia, if such term is permissible, or from the fact that deafened people forget to listen and thus the nerve stops functioning from nonuse. The treatment is directed to reeducation of the nerve and lip reading. Hearing devices are also advised.

3. Chronic Suppurative Labyrinthitis is usually associated with chronic suppurative tympanomastoid disease or is a sequence to acute labyrinthitis. The infectious process is located usually either over the promontory of the horizontal semicircular canal, at the floor of the antrum, or in and about the oval window, or it may be located anywhere in the vicinity of the labyrinth. There is present a bone necrosis which may be partial or complete, and the typical fistula symptoms may be elicited. It is important that this fact be kept in mind when doing a radical mastoid operation. Should a defect in the horizontal canal or any part of the labyrinth be encountered covered with granulations, then the granulations should be let alone, or else a localized process might be converted into a diffuse labyrinthitis. Syphilis or tuberculosis may be the primary factor in this process. We have observed a rather complete mass necrosis of this region in several cases during the course of a chronic suppurative process, and during the operative procedure sequestra and portions of the cochlea were removed with the granulation tissue. In three such cases that we have observed, no meningeal reaction followed, due probably to well formed barriers at the

internal auditory meatus. All three cases had a permanent facial paralysis before operation and there was complete deafness and absence of any vestibular response. When the fistula test proves positive after a radical mastoid operation has previously been performed and suppuration still persists from the region of the labyrinth, it may be necessary to destroy the labyrinth and thus do away with a potent factor in the development of a meningitis, etc.

4. Syphilitic Labyrinthitis.—In connection with chronic suppurative ear disease, the labyrinth may be involved. There may be present a syphilitic osteitis without suppuration, same as a gummatous process anywhere else in the body. The x-ray picture in such cases is very much like the one we find in very active osteospongiosa (otosclerosis). The serological examination is of the greatest value and in the cases we have observed, the Wassermann test was usually strongly positive. The treatment is, of course, antiluetic.

5. Otosclerosis.—The term otosclerosis has been accepted by otologists since the work of Politzer, Siebenmann and Katz as indicating a definite entity. Most authors are agreed as to the pathologic change itself. This knowledge has been gained by the microscopic examination of such specimens as have been available. There is osteoporosis of the bone of the labyrinth in consequence of which the dense petrous bone is replaced in certain areas by vascular, spongy bone, especially in the region of the anterior bony margin of the oval window. In its early stages the process is a true new formation of osteoid tissue and not a transformation of old bone. It is characterized by the large size of the osseous spaces and the haversian canals; the spaces are filled with connective tissue rich in cells, which surround large and small blood vessels. Osteoclasts are not seen at any time. Later on the diseased area becomes sclerosed by the deposition of the new bone in the walls of the spaces. There is usually a sharp line of demarcation from the uninvolved portions. In the early stages the nerve structures are as a rule normal.

It must be recognized that several varieties of the disease may exist, varying in mechanical results according to the region involved, i.e., the oval window, with resulting fixation of the

foot-plate of the stapes; foci of pathological changes in widely separated portions of the petrous bone, and in parts of the labyrinthine capsule not closely related to structures essential to cochlear function; and in parts involving directly the cochlear structures.

The etiology of this condition is obscure. Kauffman has produced experimentally in young rats, which have been maintained on a diet low in fat soluble A vitamins and in calcium, abnormalities of the osseous capsule of the internal ear which are identical with the lesions above described. The analogies between the changes in the temporal bone in experimental rickets and the lesions which have been described in otosclerosis suggest that the latter condition may be a late result of rickets or a manifestation of a dietary deficiency still existent during adult life.

The pathologic process has suggested the use of the x-ray as an aid in making the diagnosis and this often reveals the rarefactive process in the region of the foot-plate of the stapes.

Treatment.—Recognizing the change, it is evident that but little can be expected from treatment unless it is instituted very early in life. In addition to hygienic measures, the various extracts of the glands of internal secretion have been used. As soon as the diagnosis is made it is best to start lip reading and not wait until the patient has become very deaf. The various devices on the market to aid hearing are at times of benefit.

6. Traumatic Labyrinthitis most frequently occurs in conjunction with a basal skull fracture. It may be unilateral or bilateral. Although most frequently such conditions are acute and prove fatal, occasionally a chronic process does result. We have had one such case of bilateral posttraumatic chronic labyrinthitis that recovered and although a facial paralysis persisted on one side there was still some functional response in the labyrinth of both sides. Another etiologic factor is trauma during a mastoid operation, particularly the radical procedure. The injury, in all probability, is directed at the *locus minoris resistentiae*, the horizontal semicircular canal. Again, in the removal of the ossicles the foot-plate of the stapes is luxated, and infection enters through the oval window. It is, as a rule, a localized process although intracranial infection may follow.

Gunshot wounds and injuries from high explosives were re-

sponsible during the World War for many such cases. We have observed two cases of the latter type which subsequently recovered and the labyrinth continued to function, although the foreign bodies remained *in situ*. In brain concussion, with probably hemorrhage into the canal, a similar condition may ensue.

Treatment.—The treatment depends entirely upon the individual case. In that type associated with basal skull fracture it is important that no irrigation or manipulation be done. The patient should be warned against blowing his nose after consciousness is regained. Absolute rest is essential; ice-cap to the head, and the internal administration of urotropin are indicated, during the acute stage. Little can be done after the process becomes chronic, except surgical procedures. As a preventive measure during the radical mastoid operation great caution should be maintained not to injure the region of the horizontal canal. Likewise, in removal of the ossicles little force should be used in order not to dislocate or actually remove the stapes should there be an ankylosis of the ossicles.

7. Hemorrhage into the Labyrinth.—Although hemorrhage into the labyrinth is in reality an acute process, its tendency to recur as Menier's symptom complex makes it of sufficient importance to be mentioned. Apart from concussion, renal and cardiovascular disease and the blood dyscrasias are the most frequent etiologic factors. Recovery, as a rule is rare and some disturbance of the labyrinth persists. The blood becomes organized within the labyrinthine capsule and postmortem specimens have been seen in which there was complete obliteration of parts of the labyrinth undoubtedly due to such organization. The treatment is directed towards the systemic pathological condition.

8. Occupational Labyrinthine Disease.—Foundry workers are particularly liable, because of the constant hammering, to suffer from labyrinthine disease. The continued exposure to excessive heat connected with such labor may also be an etiologic factor. There is said to be a severance of the nerve fibers in the organ of Corti. It is to be emphasized that as soon as one engaged in such an occupation presents the first symptom of labyrinthine irritation, as hyperacusis, diplocusis, tinnitus, dizziness or deafness, he should be strongly advised to give up his work. Cassion

workers sooner or later, because of the great change from positive to negative pressure, develop some pathologic change within the labyrinth. Some observers believe that the nerve degeneration present is rather the result of the toxic action of the gases. Here, too, the giving up of the occupation at the first evidence of disturbance of function of the labyrinth should be advised.

9. Neoplasms.—The most frequent neoplasm is rather retro-labyrinthine and involves the auditory nerve. The location of auditory nerve tumors is usually in the internal auditory meatus. The tumor progresses in its growth towards the brain and the exit of the auditory nerve at the cerebello-pontile angle, at which point it frequently develops into considerable size. As the facial nerve is also located in the internal auditory meatus, it may likewise become involved either by pressure or by direct extension of the growth. The type of tumor is either neuroma, glioma or sarcoma. The treatment is, of course, surgical.

10. Congenital Affections of the Labyrinth.—These occur most commonly in the congenitally deaf and secondary to a syphilitic meningitis or rickets intra utero. Both the cochlea and semi-circular canals are markedly distorted in their bony formation and at times found obliterated. There is usually present complete atrophy or lack of development of the nerve and of the membranous structures. Any number of anomalies may be present in the anatomical structures of the middle ear. Only education, as lip reading, can be of assistance in these cases.

INDEX

A

- Abductor paralysis of the larynx, 219
- Abscess, acute peritonsillar, 42
 - and perichondritis, 60
 - brain, acute, 90
 - extradural, 89
 - intradural, 90
 - of septum, 18
 - perisinus, 86
 - retropharyngeal, 37
 - tonsillar, acute, 44
- Absence of auricle, 229
- Actinomyces of the mastoid, 266
 - of the tonsil, 192
- Acute diseases of the ear, 60
 - of larynx, 51
 - of nose, 17
 - of pharynx, 36
 - of trachea, 55
- esophagitis, 59
- fulminating sinusitis, 33
- labyrinthitis, 85
- mastoiditis, 72
- ostium tubitis, 38, 66
- otitis media, 66
 - perichondritis and abscess, 60
 - paranasal sinus disease, 30
 - peritonsillar abscess, 42
 - rhinitides, 24
 - sinus disease in children, 31
 - tonsillar abscess, 44
- Adenoid and tonsil diseases, 179
- Adenoma of the trachea, 223
- Adhesive otitis media, 250
- Angina, Vincent's, 46
- Animal foreign bodies in the ear, 66
- Ankylosis of malleus and incus, 246
- Anosmia, 149
- Antrum in sinusitis, 34
 - sarcoma of, 157
 - of Highmore, in rhinosinusitis, 145
- Artificial ear, 234
- Atrophic otitis media, 250
 - pharyngitis, 169
 - rhinitis, 134
 - middle turbinate and sinuses in, 155
 - septum in, 122
- Auditory canal, chronic eczema of, 241
 - diseases of, 63
 - external, diseases of, 240
- Auricle, absence of, 229

B

- Bacteriology of rhinosinusitis, 29
- Beck's conchotribe, 132
 - irrigation unit, 26
 - wall plate, 248
- Bell's palsy, 94
- Benign tumors of the tonsils, 194
- Bezold's mastoid, 82
- Bleeding, pharyngeal, 50
- Burns, injuries to trachea by, 56
 - of ear, 62
 - of larynx, 54
- Bursitis, acute, 37
 - chronic, 170
- Brain abscess, acute, 90
- Bridge of nose, 24
- Brigg's method of transillumination of antrum, 32
- Bronchi, acute diseases of, 59
 - chronic diseases of the, 221
- Bronchorrhoea, 223

C

- Carcinoma of the esophagus, 223
 - of the hypopharynx, 199
 - of the larynx, 197
 - of the pharynx, 177
 - of the trachea, 222
- Cell route infection in mastoiditis, 73
- Cerebral hernia, 91
- Cerumen, 240
- Chemical wounds of larynx, 53
- Cholesteatoma of mastoid, 265
- Chondroma, 237
- Chronic bursitis, 170
 - diseases, 96
 - of the larynx, 197
 - of the nasopharynx, 167
 - of the nose, 96
 - of the trachea, 221
 - mastoid disease, 260
 - mucopurulent tracheitis, 221
 - nonsecretive otitis media, 249
 - otitis media, 243
 - serosa, 254
 - perichondritis, 236
 - rhinosinusitis, 139
 - tubitis, 167
- Complications of mastoiditis, 84
- Compound fracture of nose, 17
- Conchotribe, Beck's, 132
- Congenital absence of septal cartilage, 122

Congenital—Cont'd
 affections of the labyrinth, 274
 deafness, 233
 lesions, facial paralysis and, 95
 macrotia, 233
 malformations of ear, 227
 Crust formation in atrophic rhinitis, 136
 Cut throat, 53
 trachea in, 56
 Cyst of middle turbinate, 155
 Cystic formation in nasal polyp, 152

D

Dermatitis of ear, 62
 Deviations of the septum of the nose, 109
 Diphtheria, 45
 Diphtheritic laryngitis, 52
 tonsillopharyngitis, 46
 Disease of the larynx, 51
 Diverticulum, esophageal, 224

E

Ear, acute diseases of, 60
 adhesive otitis media, 250
 animal foreign bodies in the, 66
 artificial, 234
 atrophic otitis media, 250
 burns of, 62
 chronic diseases of the, 227
 congenital macrotia, 233
 congenital malformations of, 227
 dermatitis of, 62
 eczema of, 236
 foreign bodies in the, 65
 frost-bites of, 60
 internal, chronic diseases of the, 268
 malformations of, 227
 malignant tumors of, 238
 otitis externa, 60
 diffusa, 64
 furunculosa, 63
 traumatica, 65
 paraffinoma of, 238
 trauma of, 234
 tumors of, 237
 verruca behind, 233
 Eochondroma of the larynx, 218
 Eczema, chronic, of auditory canal, 241
 of pinna, chronic, 236
 Edema of the pyriform fossa, 49
 Eighth nerve, neuritides of the, 269
 Electrically heated bougie, 225
 Electrothermal coagulation, 188
 Endarteritis obliterans, 172
 Epiglottis, 49
 tuberculous infiltration of, 207
 Epipharyngitis, 36
 Epithelial hypertrophy of inferior turbin-
 ate, 125

Epithelioma of ear, 239
 Epithelioma of the nose, 103
 Epistaxis, 24
 Esophageal diverticulum, 224
 Esophagitis, acute, 59
 Esophagus, carcinoma of the, 223
 chronic diseases of the, 221
 mouth of, 49
 strictures of the, 224
 Ethmoid labyrinth in chronic rhinosin-
 uitis, 142
 Ethmoids in sinusitis, 35
 Ethmoiditis, hyperplastic, 150
 External nose, chronic diseases of the,
 96
 Extradural abscess, 89

F

Facial paralysis, acute, 93
 infectious diseases associated with,
 96
 Fibrous hypertrophy of inferior turbin-
 ate, 126
 polyp of larynx, 213
 removed from naso-frontal duct, 151
 Fissure formation in nose, 21
 Follicular tonsillopharyngitis, 39
 Foreign bodies in the ear, 65
 in the larynx, 53
 in mastoid, 268
 in nose, 22
 in the trachea, 55
 Fracture of the nose, 17
 Frost-bite of nose, 20
 of the ear, 60
 Frontal sinus, in rhinosinusitis, 144
 polyp of, 146
 Frontals in sinusitis, 35
 Furunculosis of the nose, 20

G

Gas burn ulceration, 57
 injury of respiratory tract by, 56
 Glandular hypertrophy of middle turbin-
 ate, 141
 Granulation, persistent, after removal of
 adenoids, 187
 Granuloma in antrum of Highmore, 148
 Gumma of external nose, 99
 Gunshot wounds, 53

H

Head traction to aid swallowing, 41
 Hematoma of nose, 23
 Hemorrhage into labyrinth, 273
 Hernia cerebri, 91
 Herniation of the tympanic membranes,
 69

Hyperkeratosis of the tonsil, 193
 Hyperosmia, 149
 Hyperplasia of the inferior turbinate, 138
 Hyperplastic rhinosinuitis, 149
 Hypertrophy, fibrous, 126
 of inferior turbinate, 125
 osseous, 133
 vascular, of inferior turbinate, 130
 Hypopharyngitis, 48
 Hypopharynx, carcinoma of, 199
 Hyposmia, 149
 Hysterical laryngeal paralysis, 219

I

Inferior turbinate, 124
 atrophy of, 134
 hyperplasia of, 138
 hypertrophy of, 125
 new growths of, 138
 syphilitis of, 139
 tuberculosis of, 139
 turgescence of, 124
 Inflammation of the larynx, 209
 Injuries of the trachea, 56
 Interarytenoid tuberculoma simulating papilloma, 206
 Internal ear, chronic diseases of the, 268
 Intradural abscess, 90
 Irrigation unit, Beck's, 26

K

Kakosmia, 149
 Koerner cell infection, 82

L

Labyrinth, congenital affections of, 274
 hemorrhage into, 273
 neoplasms of, 274
 Labyrinthine disease, occupational, 273
 Labyrinthitis, acute, 85
 chronic suppurative, 270
 complicating mastoiditis, 85
 syphilitic, 271
 traumatic, 272
 Laryngeal diphtheria, 52
 paralysis, 218
 polyp, 213
 stenosis, 211
 Laryngitis, acute simple, 51
 chronic simple, 212
 syphilitic, 210
 Larynx, acute diseases, of, 51
 carcinoma of, 197
 Larynx, chronic diseases of, 197
 inflammation of, 209
 echondroma of the, 218
 foreign bodies in the, 53

Larynx—Cont'd

 papilloma of the, 215
 singer's nodules, 212
 trauma of, 53
 tuberculosis of, 206
 Lateralis hypertrophicus, 168
 Leptothrix, 193
 Lingual tonsil, diseases of, 181
 inflammation of, 49
 Lues of the septum, 117
 of the mesopharynx, 47
 Luetic cicatrices of velum palati, 172
 tonsil, 192
 Lumpy jaw, 192
 Lupus of the nose, 96
 Lupus or tuberculosis of the inferior turbinate, 139

M

Macrocephalia, congenital, 233
 Macrotia, congenital, 233
 Malformations, of ear, acquired, 227
 Malignant diseases of the septum, 120
 tumors of ear, 238
 Mastoid, actinomycosis of, 266
 cholesteatoma of, 265
 disease, chronic, pathologic, 260
 fistular tracts of, 263
 foreign bodies in, 268
 neoplasms of, 268
 osteofibrosis of, 260
 reparative osteitis of the, 267
 syphilitic osteitis of, 266
 tuberculous osteitis, 265
 Mastoiditis, acute, 72
 complications of, 84
 facial paralysis as complication of, 93
 atypical types of, 81
 cell route, 72
 infection, 73
 extradural abscess as complication of, 89
 hernia cerebri as complication of, 91
 histopathology in, 75
 intradural abscess as complication of, 90
 labyrinthitis complicating, 85
 meningitis as complication of, 91
 osteophlebitic, 72
 perisinus abscess complicating, 86
 sinus thrombosis as complication of, 87
 squamozygomatic, 82
 vascular route, 72
 vascular route infection, 79
 Melanosarcoma, 164
 Membrana tympani, anatomical configuration of, 68
 perforations of, 244

Membranous pharyngitis, 45, 47
 Meningitis, 91
 Mercury tube for pressure treatment and
 massage in ear diseases, 258
 Mesopharyngitis, 39
 Mesopharynx, 39
 Middle ear inflammation, neuritis second-
 ary to, 270
 Middle turbinate and sinases in atrophic
 rhinitis, 155
 cyst of, 155
 glandular hypertrophy of, 141
 in atrophic rhinitis, 136
 pathology of, in rhinosinitis, 140
 polyp from, 152
 turbina bullosa of, 154
 Missiles, injuries to trachea by, 56
 Mucopurulent tracheitis, chronic, 221
 Mulberry hypertrophy of inferior tur-
 binate, 129
 Myxomatous degeneration, 145, 156

N

Nasal frontal duct, in rhinosinitis, 144
 infection in adenoid disease, 181
 septum, congenital absence of, 122
 deviations of the, 109
 diseases of, 109
 lues of, 117
 malignant diseases of, 120
 papilloma of the, 120
 traumatic, 115
 tuberculosis of, 119
 Nasopharynx, chronic diseases of, 167
 Necrosis in mastoiditis, 73
 Neoplasms of the labyrinth, 274
 of the mastoid, 268
 of the trachea, 222
 Neuritides of the eighth nerve, 269
 Neuritis secondary to middle ear inflam-
 mation, 270
 Nevus of the nose, 100
 New growths of the inferior turbinate,
 138
 Nipple perforation of the membrana
 tympani, 70
 Nose, abscess of septum, 18
 acute diseases of, 17
 bridge of, 24
 chronic diseases of the, 96
 chronic vestibulitis, 109
 epistaxis, 24
 epithelioma of the, 103
 fissure formation in, 21
 foreign bodies in, 22
 fracture of, 17
 frostbite of, 20
 furunculosis of the, 20
 gumma of, 99
 hematoma of, 23

Nose—Cont'd

 inferior turbinate, 124
 internal, diseases of, 109
 lues, 98
 lupus of, 96
 nevus of the, 100
 notches, following septal abscess, 24
 papilloma of, 105
 pus infections of, 100
 rhinophyma, 96
 rhinoscleroma, 100
 rhinosinitis, 25
 sarcoma, 102, 164
 septal abscess of, 23
 tuberculosis of the, 96
 tumors of the, 100
 vestibulitis acute, 21
 vestibulum of the, 109
 Notched nose following septal abscess,
 24

O

Occupational labyrinthine disease, 273
 Oropharynx, chronic diseases of, 167
 Osseous hypertrophy, 133
 Osteitis of the ethmoids, 143
 reparative, in mastoiditis, 78
 Osteofibrosis and chronic suppurative
 otitis media, 254
 of mastoid, 260
 Osteophlebitic mastoiditis, 72
 Osteofibrosis with fistular tracts of
 mastoid, 263
 Ostium maxillaris, in rhinosinitis, 145
 Ostium tubitis, acute, 38, 66
 Othematoma, 60
 Otitis externa, 60
 diffusa, 64
 furunculosa, 63
 sicca, chronic, 242
 in which moulds are present, 243
 traumatica, 65
 media, acute, 66
 adhesive, 250
 atrophic, 250
 chronic, 243
 nonsecretive, 249
 residualis of Wittmaack, 251
 serosa or seromucosa, chronic, 254
 Otosclerosis, 271

P

Pansinitis, suppurative, 145
 Papilloma of the larynx, 215
 of the nose, 105
 of the septum, 120
 of the trachea, 222
 Paraffinoma of ear, 238
 of the nose, 105

Paralysis, acute facial, 93
 laryngeal, 128
 Paranasal sinus disease, acute, 30
 Parosmia, 149
 Perforation, nipple, of the membrana tympani, 70
 Perforations of tympanic membrane, 244
 Perichondritis and abscess, 60
 Periostitis in mastoiditis, 81
 Perisinus abscess, 86
 Peritonsillar abscess, acute, 42
 rupture of, 43
 Perichondritis, chronic, 236
 Pfannenstiel treatment, 257
 Pharyngeal bleeding, 50
 stenosis, 173
 Pharyngitis, 168
 atrophic, 169
 membranous, 45, 48
 Pharyngitis, pseudomembranous, 48
 Pharynx, acute bursitis, 37
 diseases of, 36
 carcinoma of the, 177
 epipharyngitis, 36
 hypopharyngitis, 49
 retropharyngeal abscess, 37
 salpingitis, 38
 syphilis of the, 171
 Thornwaldt's disease, 170
 tuberculosis of, 174
 tumors of the, 175
 Pinna, acute diseases of, 60
 chronic eczema of, 236
 malformations of, 227
 Pneumatization of mastoid, 253
 Polyp, fibrous, of larynx, 213
 in ear, 245
 in frontal sinus, 146
 Polypi in ethmoiditis, 150
 Posterior choanae, closure of the, 122
 ethmoid and sphenoid in sinusitis, 35
 Postural method, Beck's, for introduction of fluid into nose, 27, 28
 Pseudomembranous pharyngitis, 48
 Pus infections of the nose, 100
 Pyriform fossa, edema of, 49

Q

Quinsy, 42

R

Radium exudate, 165
 Reparative osteitis of the mastoid, 267
 Respiratory tract, gas burns of, 56
 Retroauricular fistula following radical mastoid operation, 235
 Retropharyngeal abscess, 37
 Rhinitides, acute, 24

Rhinitis atrophic, 134
 middle turbinate and sinuses in, 155
 septum in, 122
 Rhinophyma, 96
 Rhinoscleroma, 100
 Rhinosinusitis, 24
 chronic, 139
 complications, 27
 ethmoid labyrinth in, 142
 hyperplastic, 149
 pathology of middle turbinate, 140

S

Salpingitis, 38
 Sarcoma of the nose, 102, 164
 of the sinuses, 157
 of the tonsil, 177
 Septal abscess of nose, 23
 Septum, nasal (see Nasal septum)
 Sequestral luetic osteitis, 264
 Seromucosa, otitis media, 254
 Serous labyrinthitis, 85
 Singer's nodules, 212
 Sinusitis, acute fulminating, 33
 antrum in, 34
 ethmoids in, 35
 frontals in, 35
 Sinus cavities in rhinosinusitis, 144
 disease in children, 31
 paranasal, 30
 thrombosis in mastoiditis, 87
 Sinuses, sarcoma of the, 157
 Sphenoid opening, in rhinosinusitis, 145
 polyp, 150
 Squamozygomatic mastoiditis, 82
 Stenosis of the larynx, 211
 pharyngeal, 173
 Strangulation, 53
 Streptococcal sore throat, 48
 Strictures of the esophagus, 224
 Subperiosteal abscess in mastoiditis, 81
 Suction apparatus, 25
 Suppurative pansinusitis, 145
 sinusitis, 140
 tympanomastoiditis, chronic, 244
 Swallowing, head traction to aid, 41
 Synechia, 123
 Syphilitic labyrinthitis, 271
 laryngitis, 210
 osteitis of the mastoid, 266
 tracheitis, 222
 Syphilis of the inferior turbinate, 139
 of the pharynx, 171

T

Thornwaldt's disease, 37, 170
 Tongue, base of, in hypopharyngitis, 48
 Tonsil, actinomycosis of, 192
 and adenoid diseases, 179

- Tonsil—Cont'd
 hyperkeratosis of the, 193
 luetic, 192
 sarcoma of the, 177
 tuberculosis of, 188
- Tonsillar abscess, acute, 44
- Tonsillooliths, multiple, 189
- Tonsillopharyngitis, 39
- Tonsils, benign tumors of, 194
 hyperplasia of, with infection, 179
- Trachea, acute diseases of, 55
 adenoma of the, 223
 carcinoma of the, 222
 foreign bodies in the, 55
 injuries of the, 56
 injuries to, by gas, 56
 neoplasms of the, 222
 papilloma of the, 222
- Tracheal fistula, papillomatous formation
 about, 217
- Tracheitis, acute, 55
 chronic mucopurulent, 221
 syphilitic, 222
- Transillumination of antrum, Brigg's, 32
- Trauma of ear, 234
 of larynx, 53
- Traumatic facial paralysis, 94
 labyrinthitis, 272
 septum, 115
- Tuberculosis of the inferior turbinate,
 139
 of the larynx, 206
 of the nasal septum, 119
 of the nose, 96
 of the pharynx, 174
- Tuberculosis—Cont'd
 of the tonsil, 188
- Tuberculous osteitis of the mastoid, 265
- Tubitis, chronic, 167
- Tumors of the external ear, 237
 of the nose, 100
 of the pharynx, 175
- Turbina bullosa of the middle turbinate,
 154
- Turgescence of inferior turbinate, 124
- Tympanic membranes, herniation of the,
 69
 nipple perforation of the, 70
- Tympanomastoiditis, chronic suppurative,
 244
- U
- Unilateral carcinoma of the tonsil, 178
- V
- Vascular hypertrophy, 130
 route infection in mastoiditis, 79
- Velum palati, luetic cicatrices of, 172
- Verruca, congenital, behind ear, 233
- Vestibulitis acuta, 21
 chronic, 109
- Vincent's angina, 46
- W
- Wax, inspissated in auditory canal, 240
- West case, 258
- Wittmaack, otitis media residualis of,
 251

WV 100 B393a 1923

51320520R



NLM 05267972 4

NATIONAL LIBRARY OF MEDICINE