

WP 660 5936g 1923

47530560R



NLM 05244398 9

NATIONAL LIBRARY OF MEDICINE

Division of

Books

NATIONAL LIBRARY OF MEDICINE

NATIONAL LIBRARY OF MEDICINE

NATIONAL LIBRARY OF MEDICINE

Health Service

Health, Education,

Health Service

Health, Education,

Health Service

Health, Education,

and Welfare, Public

and Welfare, Public

and Welfare, Public

and Welfare, Public

and Welfare, Public

and Welfare, Public

NATIONAL LIBRARY OF MEDICINE

NATIONAL LIBRARY OF MEDICINE

NATIONAL LIBRARY OF MEDICINE

Health, Education,

Health Service

Health, Education,

Health Service

Health, Education,

Health Service

NATIONAL LIBRARY OF MEDICINE

NATIONAL LIBRARY OF MEDICINE

NATIONAL LIBRARY OF MEDICINE

U.S. Department of

Bethesda, Md.

U.S. Department of

Bethesda, Md.

U.S. Department of

Bethesda, Md.

NATIONAL LIBRARY OF MEDICINE

NATIONAL LIBRARY OF MEDICINE

NATIONAL LIBRARY OF MEDICINE

Bethesda, Md.

U.S. Department of

Bethesda, Md.

U.S. Department of

Bethesda, Md.

U.S. Department of

Health Service

Health, Education,

Health Service

Health, Education,

Health Service

Health, Education,

NATIONAL LIBRARY OF MEDICINE

NATIONAL LIBRARY OF MEDICINE

NATIONAL LIBRARY OF MEDICINE

and Welfare, Public

and Welfare, Public

and Welfare, Public

and Welfare, Public

and Welfare, Public

and Welfare, Public

NATIONAL LIBRARY OF MEDICINE

NATIONAL LIBRARY OF MEDICINE

NATIONAL LIBRARY OF MEDICINE

Health, Education,

Health Service

Health, Education,

Health Service

Health, Education,

Health Service

NATIONAL LIBRARY OF MEDICINE

NATIONAL LIBRARY OF MEDICINE

NATIONAL LIBRARY OF MEDICINE



Gynoplastic Technology

WITH A CHAPTER ON
"SACRAL ANESTHESIA" 514

BY
ARNOLD STURMDORF, M.D.

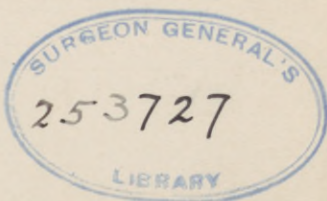CLINICAL PROFESSOR OF GYNECOLOGY, NEW YORK POLYCLINIC MEDICAL SCHOOL;
VISITING GYNECOLOGIST, NEW YORK POLYCLINIC HOSPITAL; CONSULTING
GYNECOLOGIST TO THE MANHATTAN STATE HOSPITAL, THE COMMUNITY
HOSPITAL, AND JEWISH MEMORIAL HOSPITAL, NEW YORK CITY;
FELLOW OF THE AMERICAN COLLEGE OF SURGEONS, THE
NEW YORK ACADEMY OF MEDICINE, AND THE
AMERICAN MEDICAL ASSOCIATION,
Etc., Etc.

Illustrated with 157 Half-tone and Photo-engravings in the
Text, some in Colors, and 23 Full-page Plates,
with 35 Figures, all in Colors

SECOND REVISED EDITION



PHILADELPHIA
F. A. DAVIS COMPANY, PUBLISHERS
1923



WP
660
59366
1923

COPYRIGHT, 1919
COPYRIGHT, 1923
BY
F. A. DAVIS COMPANY ✓

Copyright, Great Britain. All Rights Reserved

PRINTED IN U. S. A.
PRESS OF
F. A. DAVIS COMPANY
PHILADELPHIA, PA.

© CIA752113

JUL 14 '23 ✓ R

no 11

PREFACE TO SECOND EDITION.

THE very liberal reception accorded the first edition of "Gynoplastic Technology" by the medical profession in general, and the gratifying commendations bestowed upon it by the medical press in particular, have necessitated the preparation of a second edition after a comparatively short interval.

The present edition while strictly adhering to the plan, scope and context of the original, has been carefully revised and amplified by the addition of a chapter on "Pudental Hernia."

ARNOLD STURMDORF.

P R E F A C E .

THE evolution of technological progress, and the promulgation of its advanced basic conceptions, must of necessity contend with prevailing principles of practice, some of which are founded on theories of pathology long abandoned, some due to misdirected research or erroneous clinical deductions, while others present the mere relics of an obsolete dogma, upheld by authoritative sanction, which perpetuates surgical measures that can no longer be defended on either theoretical or practical grounds.

Attempts at plastic restoration of the injured birth canal present the very genesis of gynecological surgery. As an art, these reconstructive procedures were developed to a high degree of perfection by the ingenuity of Sims, Emmet, Simon, Hegar, Schroeder and others, but as a science the technological principles standardized by these master-minds are no longer tenable.

The present volume embodies an elaborated compilation of the author's previous publications on the various phases of gynecoplastic technology.

Each topic is presented in monographic form, as better adapted to the exposition of its controversial aspects.

The various operative procedures are detailed and illustrated to illuminate underlying principles of practice rather than to standardize any individual method as one of universal applicability, while the historical data are given only where they reveal the progressive stages in the evolution of advanced gynecoplastic technology. Finally, as no modern work on regional surgery would be complete without a consideration of sacral anesthesia, a chapter on "Sacral Anesthesia" has been included.

ARNOLD STURMDORF.

3375 D

CONTENTS.

	PAGE
CHAPTER I.	
GENERAL PRINCIPLES	3
CHAPTER II.	
PREOPERATIVE AND POSTOPERATIVE PERIODS	11
CHAPTER III.	
SACRAL ANESTHESIA IN GYNECOPLASTIC OPERATIONS	17
CHAPTER IV.	
TRACHELOPLASTY	26
CHAPTER V.	
CHRONIC ENDOCERVICITIS	32
CHAPTER VI.	
ETIOLOGY OF ENDOCERVICITIS	53
CHAPTER VII.	
TREATMENT OF CHRONIC ENDOCERVICITIS	58
CHAPTER VIII.	
THE CERVICOPLASTIC TREATMENT OF STERILITY	84
CHAPTER IX.	
PERINEORRHAPHY	88
CHAPTER X.	
THE MECHANISM OF INTRAPELVIC VISCERAL SUPPORT	93
CHAPTER XI.	
THE LEVATOR ANI MUSCLE	109

	PAGE
CHAPTER XII.	
THE PELVIC FASCIA	115
CHAPTER XIII.	
LEVATOR MYORRHAPHY	124
CHAPTER XIV.	
THE RETRODISPLACED UTERUS AS A COMPLICATION IN PELVIC FLOOR INJURY	150
CHAPTER XV.	
CYSTOCELE	164
CHAPTER XVI.	
OPERATIONS FOR CYSTOCELE	174
CHAPTER XVII.	
LACERATION THROUGH THE ANAL SPHINCTRE	198
CHAPTER XVIII.	
VESICOVAGINAL FISTULA	209
CHAPTER XIX.	
OPERATIONS FOR VESICOVAGINAL FISTULA	212
CHAPTER XX.	
FUNCTIONAL URINARY INCONTINENCE	234
CHAPTER XXI.	
EXSTROPHY OF THE BLADDER	240
CHAPTER XXII.	
FECAL FISTULÆ	246
CHAPTER XXIII.	
CANCER OF THE VULVA	252
CHAPTER XXIV.	
ELEPHANTIASIS VULVÆ	268

CONTENTS.

ix

CHAPTER XXV.

PAGE

CONGENITAL MALFORMATIONS 275

CHAPTER XXVI.

MALFORMATIONS OF THE VAGINA AND VULVA 291

CHAPTER XXVII.

OPERATIVE CORRECTION OF CONGENITAL MALFORMATIONS 309

CHAPTER XXVIII.

PUDENDAL HERNIA 323

LITERATURE QUOTED 335

INDEX 341

LIST OF ILLUSTRATIONS.

FIG.	PAGE
1. Separation of spinal and sacral canals (<i>Gray-Spitzka</i>)	18
2. Coccygeal vertebra fused with sacrum (<i>Thompson</i>)	20
3. Coccygeal vertebra fused with sacrum, very long hiatus	21
4. Curved type of sacrum (<i>Thompson</i>)	22
5. Sacral blocking, areas of anesthesia, etc.	23
6. Normal cervical glands	33
7. Normal endocervical mucosa	34
8. Normal cervical gland	36
9. Normal utricular glands of the corporeal endometrium	37
10. Corporeal endometrium	38
11. Automatic contractions of uterine muscle four hours after hysterectomy (<i>Lieb</i>)	39
12. Automatic contractions of a muscle strip from a non-pregnant uterus three hours after hysterectomy (<i>Lieb</i>)	40
13. Sagittal section of the uterus (<i>Abel</i>)	42
14. Periadnexal lymphatics, sheep's uterus (<i>Leopold</i>)	45
15. Distribution and course of the periuterine and periadnexal lymphatics (<i>Color</i>)	47
16. Periadnexal adhesions and phlebectasia, the result of endo- cervicitis	49
17. Infantile endocervicitis—"vulvovaginitis"	53
18. Chronic endocervicitis, section from a cervix after cauteriza- tion (<i>Abel</i>)	54
19. Chronic endocervicitis, section of erosion of the cervix (<i>Abel</i>) ..	55
20. Infantile erosion—"chronic endocervicitis" (<i>Chrobak</i> and <i>Rosthorn</i>)	57
21. Chronic endocervicitis	59
22. Chronic endocervicitis, round-cell infiltration in sub-epithelial layers	60
23. Chronic endocervicitis with miliary abscess	61
24. Cancerous endocervical gland (<i>Abel</i>)	62
25. Carcinoma of the cervix (<i>Abel</i>)	63
26. Advancing carcinoma of cervix	65
27. Advanced carcinoma	66
28. Tracheloplasty (author's method). Outlining the edge of the flap on the vaginal sheath of the cervix	67
29. Tracheloplasty (author's method). Elevating the flap edge preparatory to its free mobilization	68
30. Tracheloplasty (author's method). Mobilization of the cylin- drical vaginal flap	70
31. Tracheloplasty (author's method). Excision of endocervical cone	71
32. Tracheloplasty (author's method). Denuded funnel of cervical muscularis	72
33. Tracheloplasty (author's method). Silkworm strand passed transversely through the vaginal surface of the anterior flap segment	74
34. Modified Peaslee needle	75
35. Tracheloplasty (author's method). Introducing the right free suture end into and above the internal os	76

FIG.	PAGE
36. Tracheloplasty (author's method). Needle emerging on the anterior vaginal fornix	77
37. Tracheloplasty (author's method). Left free suture end passed upward and forward	78
38. Tracheloplasty (author's method). Traction on the two anterior suture ends, etc.	80
39. Tracheloplasty (author's method). Anterior and posterior sutures drawn taut and tied	82
40. Normal nulliparous vulva	94
41. Normal parous vulva. Competent levator ani muscle	95
42. Parous vulva, gaping from lacerated levator ani muscle	96
43. Initial direction of intra-abdominal pressure at pelvic brim	102
44. Normal pressure deflection by the intrapelvic planes	106
45. Levator ani seen from below (<i>Dickinson</i>)	110
46. Origin of the left anterior loop of the levator ani	111
47. The intra-pelvic line of origin of the levator ani (<i>Haynes</i>) ...	112
48. Levator ani fibres normally present in the rectovaginal septum. 113	113
49. Anatomy of the female perineum. Superficial area	116
50. The pelvic outlet	117
51. Anatomy of the female perineum. Mid-area	118
52. The levator fascia	119
53. Anatomy of the female perineum. Exposure of the levator muscle after removal of the levator fascia	120
54. Anatomy of the female perineum. Exposure of the rectovesical fascia after removal of the levator muscle	121
55. Perineoplasty (author's method)	125
56. Perineoplasty (author's method). Flap is carefully elevated from the underlying layer	126
57. Elevating the vaginal mucosa	127
58. Method of flap dissection	128
59. Fascial slits for levator exposure	129
60. Incorrect method of exposing the levator muscle	130
61. Perineoplasty (author's method). Suture traction	132
62. Perineoplasty (author's method). The levator ani partly exposed	133
63. Perineoplasty (author's method). The sutures passed entirely round (not through) the muscle-shanks	134
64. Perineoplasty (author's method). Levator sutures <i>in situ</i> and tied	136
65. Perineoplasty (author's method). The elevated flap of vaginal mucosa is not ablated	138
66. Perineoplasty (author's method). The hollow cone of vaginal mucosa is inverted upon itself	139
67. Perineoplasty (author's method). Diagrammatic sagittal section	140
68. Perineoplasty (author's method). Sutures introduced to unite the musculofascial layers	142
69. Diagram of the vulvoperineal musculature	143
70. Transverse perinei often mistaken for the levator edge	144
71. Fascial layers in relation to the levator ani	145
72. Incorrect denudation	146
73. Incorrect exposure	148
74. Normal or neutral type of posture	152
75. Kangaroo type of posture	153
76. Axis of abdominal cavity, axis of pelvic cavity	155
77. Author's method of determining the lumbar index	157

FIG.	PAGE
78. Diagram of relation of pelvis to abdomen	158
79. Anterior colpocele simulating cystocele	164
80. Urethrocele	165
81. Inversion of the vagina with cystocele and procidentia uteri ..	166
82. Initial direction of intra-abdominal pressure at pelvic brim ..	167
83. Misdirected pressure deflection	169
84. Perineal laceration	170
85. Procidentia uteri	171
86. Bladder pillars	175
87. Operation for cystocele. Exposure of the bladder pillars (<i>Frank</i>)	176
88. Cystocele operation. Cervical sutures tied holding bladder (<i>Frank</i>)	177
89. Vaginal hysterectomy, ligature of uterine artery	179
90. Vaginal hysterectomy, ligature of broad ligament	187
91. Vaginal hysterectomy, ligature of the utero-ovarian artery and tube	190
92. Vaginal hysterectomy, stumps of the broad ligament seen in the wound	192
93. Broad ligament stumps sutured across the midline (<i>Goffe</i>) ..	194
94. Upper free end of ligaments tied (<i>Goffe</i>)	195
95. Complete laceration of the perineum through anal sphincter (<i>Kelly</i>)	199
96. Warren-Ristine operation for complete perineal laceration through the anal sphincter	201
97. Child's outlining apron flap in the Warren-Ristine operation ..	202
98. Warren-Ristine operation	203
99. Child's sutures in the Warren-Ristine operation	205
100. Cross-section of figure-of-eight sutures (<i>Child</i>)	206
101. Closure of bladder fistula with buried catgut sutures (<i>Macken- rodt</i>)	213
102. Vesicovaginal fistula. Mackenrodt's operation	214
103. Lateral vaginoperineal incision (<i>Ward</i>)	217
104. Schuchardt's incision outlined (<i>Ward</i>)	219
105. Schuchardt's incision completed (<i>Ward</i>)	221
106. Plane of Schuchardt's incision (<i>Ward</i>)	223
107. Mobilization of the bladder (<i>Ward</i>)	224
108. Displacement downward of the bladder (<i>Ward</i>)	226
109. Vaginal suture <i>in situ</i> (<i>Ward</i>)	228
110. Exposure and suture of sphincter vesicæ (<i>Frank</i>)	229
111. Operation for incontinence of urine	235
112. Operation for urinary incontinence	236
113. Kelly's mattress suture	237
114. Shortening of the vesical sphincter	238
115. Operation for exstrophy of the bladder	242
116. Operation for exstrophy of the bladder. Uretero-intestinal anastomosis (<i>Mayo</i>)	243
117. Adenocarcinoma of the left vulvovaginal gland (<i>Kelly</i>)	253
118. Primary carcinoma of clitoris (<i>Taussig</i>)	254
119. Lymphatics of the external genitalia (<i>Crossen</i>)	255
120. The lymphatics of the urethra and vagina (<i>Crossen</i>)	256
121. Regional layer dissection of vulvar structures	258
122. Regional layer dissection of the vulvar structures	260
123. Outlines for the "block excision" of the external genitals (<i>Crossen</i>)	261
124. First step in the "block excision" (<i>Crossen</i>)	262

FIG.	PAGE
125. The block of tissue partially excised (<i>Crossen</i>)	263
126. Denuded area after removal of inguinal glands	264
127. Block excision, wound closed (<i>Color</i>)	266
128. Elephantiasis (<i>Stein</i>)	270
129. The rudimentary sexual ducts (<i>Adami</i>)	276
130. The indifferent stage in the development of the generative organs (<i>Piersol</i>)	277
131. Development of the female generative organs (<i>Piersol</i>)	278
132. Development of the male generative organs (<i>Piersol</i>)	279
133. Double uterus (<i>Mann</i>)	283
134. Bicornate uterus	284
135. Left tube, ovary and uterine nodule (<i>Kelly</i>)	285
136. Double uterus, vagina and planiform fundus (<i>Kelly</i>)	286
137. Pregnancy in a rudimentary left uterine horn (<i>Color</i>) (<i>Kelly</i>) ..	288
138. Development of the external genitals	294
139. Anus vulvalis (After <i>Dwight</i>)	296
140. Pseudohermaphroditism (After <i>Pozzi</i>)	297
141. Agglutination of the labia	299
142. Atresia of the vulva (<i>Sulton and Giles</i>)	302
143. Atresia of the vagina (<i>Sulton and Giles</i>)	303
144. Feminine pseudohermaphroditism	305
145. Agglutination of the labia, after division of the membrane ...	310
146. Widening the vaginal opening for dyspareunia (<i>Crossen</i>)	312
147. Forming an artificial vagina (<i>Crossen</i>)	314
148. Intestinal resection for artificial vagina (<i>Crossen</i>)	316
149. Intestinal resection, the intestinal loop in place (<i>Crossen</i>)	318
150. Artificial vagina from a section of the rectum (<i>Crossen</i>)	319
151. Artificial vagina, traction made on the gauze strip (<i>Crossen</i>)	320
152. Artificial vagina, later steps in the operation (<i>Crossen</i>)	321
153. Pudendal hernia presenting through anterior and left vaginal wall and labium, simulating cystocele	324
154. Showing the "levator hernia" before operation (<i>Chase</i>)	325
155. Showing the weak points in the pelvic diaphragm (<i>Chase</i>)....	327
156. Showing the "subpubic" triangle and its boundaries	329
157. Vaginal route (<i>Chase</i>)	331

LIST OF PLATES.

PLATE	FACE PAGE
I. Chronic endocervicitis (<i>Palmer Findley</i>)	32
II. Injection specimen, normal nulliparous uterus, transverse section of myometrium (<i>Leopold</i>)	44
Transverse section of uterine muscle	44
III. Chronic interstitial myometritis—"fibrosis uteri"	48
IV. Histopathology of "cervical erosion"	56
V. Healed non-infected bilateral laceration	64
Mild endocervicitis, bilateral laceration	64
VI. Virginal chronic endocervicitis	64
VII. Virginal chronic endocervicitis with "erosion"	64
Chronic endocervicitis with mild manifestation at the external os	64
VIII. A. Gonorrhoeal condylomata	64
B. Gonorrhoeal endocervicitis	64
IX. Chronic endocervicitis	64
Chronic endocervicitis, mild infection	64
X. Chronic endocervicitis—"papillary erosion"	64
Chronic endocervicitis, infected laceration	64
XI. Chronic endocervicitis, infected laceration with "ulceration and suppurative nabothian folliculitis"	64
Chronic endocervicitis, infected laceration, "ectropium with follicular suppuration"	64
XII. Chronic endocervicitis, infected laceration with "granular erosion" and nabothian folliculitis	64
Chronic endocervicitis, with mucous polypi	64
XIII. Chronic endocervicitis, with carcinomatous papilloma	64
Endocervical carcinoma in the initial stage	64
XIV. Chronic endocervicitis, with carcinomatous ulceration	64
Carcinoma of cervix with sloughing into the posterior vaginal vault	64
XV. Carcinoma of cervix, with endocervical necrosis	64
Endocervical carcinoma in section	64
XVI. Syphilitic ulcer in angle of laceration	66
XVII. Tracheloplasty (author's method)	68
XVIII. Tracheloplasty (author's method), schematic sagittal view of the suture course in the anterior flap segment	80
XIX. Arterial supply of the perineal region	128
XX. Complete perineal laceration through the anal sphinctre, with exposure of the posterior vaginal and rectal walls.	196
XXI. Circumscribed epithelioma of the vulva	254
Diffuse ulcerative epithelioma of the vulva	254
XXII. Elephantiasis of the vulva	268
XXIII. Syphilitic gummata	272

INTRODUCTORY.

GYNECOLOGY is in the dawn of a new era; its operative technology is slowly emerging from empirical formularies into rational procedures based upon fundamental factors established by modern research.

Current investigations of surgical "end results," while as yet in their initiative, have already demonstrated that healed incisions and purely objective restitutions to hypothetical normals do not prove the cure—plastic reconstructions as such do not restore functions, and a symptomologic nosology does not convey a diagnosis.

Concept dominates practice. We were taught to see a passive retention wedge in the "perineal body" where we must recognize an active myodynamic deflector of intra-abdominal pressure in the levator ani muscle.

The "law of deflection" applied to the dynamics of that elusive force—intra-abdominal pressure—clarifies the problems of normal and abnormal uterine poise; it reveals the nature of congenital retro-positions as compensatory static deviations, normal to certain types of skeletal contour in which the multifarious corrective operations upon the uterine ligaments should be relegated to the limbo of the obsolete.

The time has passed when the term "endometritis" encompassed the beginning and end of uterine pathology—when "reflex neurosis" presented the shibbo-

leth of its general symptomatology, and curettement the slogan of its therapy.

Kundrat in 1873 exposed "endometritis" as a normal premenstrual manifestation in pathological guise.

Leopold in 1874 blazed the path to a rational uterine pathology by depicting the myometrial lymph course; and Henricius in 1889 unwittingly revealed a fundamental factor in uterine physiology by demonstrating that the normal *non*-gravid uterus is a *rhythmically contracting organ*.

More recently, Hertoghe's observations on hypothyroidism established an endocrine pathogenesis in the category of metrorrhagias; and Rosenow succeeded in tracing the metastatic habilitation of bacteria within the ovarian tissues from distal latent foci.

The biochemic factors evolved by these latter researches illumine the haze of the "reflex neuroses," in which we begin to discern lineaments of insidious sepsis and toxicosis.

These specific phases of established validity and far-reaching significance are elucidated in a widely scattered literature, which has not yet been correlated to that concrete homogeneity essential to their more general dissemination and practical application.

This is conspicuously evident in the current textbook chapters on the cervix and perineum.

CHAPTER I.

GENERAL PRINCIPLES.

PRELIMINARY to the special technology of the various operations about the vulvovaginal tract, it is essential to dwell upon certain general principles which apply to the preoperative, operative, and post-operative stages of gynecoplastic procedures as a class.

The majority of these procedures are essentially multiple, necessitating prolonged anesthesia and extensive denudations of vascular areas in a more or less contaminated field. Prolonged anesthesia and extensive denudation of vascular areas in a contaminated field obviously embody elements of serious potentialities which are too frequently disregarded in this branch of surgery.

The success of a gynecoplastic operation depends not only upon the technical skill of the operator, but upon his clinical ability to estimate in a given case the local and systemic factors that will dominate the immediate and remote effects of his surgical procedure.

Gynecoplasty is elective surgery, and, as such, affords ample time to determine the presence of the local, visceral, or systemic complications that would tend to jeopardize the operative outcome.

Minor degrees of shock, hemorrhage, and infection, ordinarily negligible, are nevertheless inseparable from the major surgery of the urogenital

region; and while no surgeon can predicate with any approach to accuracy a patient's inherent resistance, he can, and should, eliminate or minimize most of the factors that tend to enhance the gravity of these morbid concomitants.

Omitting a categorical elucidation of the gross organic disorders which constitute obvious contraindications to surgical measures, it is essential to indicate the more insidious pathological factors that frequently predetermine the operative and postoperative morbidity.

Crile states: "A good heart and normal blood-vessels, with active innervation, and with the capability of maintaining an average blood-pressure, give the patient a strong defense against operative traumatism. With almost human ingenuity, however, disease processes strike at the strongest defenses of their intended victim, and, as a consequence, all too seldom does a patient come to the surgeon with this protective mechanism unimpaired.

"It is essential, then, that we understand well the causes which may produce menacing deviations in blood-pressure, that we may be able to combat successfully these conditions by preliminary and coincident measures."

Hypertension may be but a temporary condition induced by a continued and intense emotion—worry, grief, or anger. It may be due to acute or chronic infection, to exophthalmic goitre, or to increased intracranial pressure, as well as to such more immediate causes as cardiovascular disease and physical changes in the blood-vessel walls. From this enumeration it is obvious that, while some of the causes of hypertension

are temporary and remediable, others are permanent and irremediable.

In estimating, therefore, the surgical risk in a patient with hypertension, it is essential to differentiate the remediable from the irremediable class, eliminating the operative hazard in the former, and reducing it in the latter, by resort to palliation until an approximation to normal vascular tension is induced by appropriate measures.

Gynecological patients range from the adolescent to the senile; their different disorders embody all the etiological factors of abnormal circulatory pressure—senescent arteriosclerosis; severe anemia, secondary to menorrhagia or metrorrhagia; chronic toxemia, from infectious foci in the cervix or tubes; renal involvement, especially in cases of marked cystocele with retention.

The hormonal influence of the ovaries on vascular tension is clinically evidenced during menstruation and the climacteric, while emotional states and general psychic erethism are characteristic concomitants of gynecic disorders.

A superposed element of danger in operating upon patients with hypertension is the anesthetic. Ether, however skilfully controlled, induces psychic stress in the primary stage of its administration. It impairs the immunity of the patient; it retards the coagulation-period of the blood; as a fat solvent it disintegrates many of the body lipoids, especially those in the brain, the renal epithelium, and the liver, with consequent increase in waste products, and augmented tax upon the excretory organs.

The strain of ether nausea and vomiting, always

a disturbing feature, is especially so in cases of hypertension. Therefore, its administration in these cases must be reckoned as a distinct risk *per se*, because it injures and taxes the kidneys, predisposes to embolism and pneumonia, and intensifies the traumatic and psychic dangers.

A class of patients particularly prone to shock and infection are those presenting severe secondary anemias of recent origin, frequently found among the adolescent and preclimacteric metrorrhagiacs, in none of which should any operative procedure be undertaken when the hemoglobin has fallen to 50 per cent. of the normal.

As operative risks, the heart, the kidneys, and blood-pressure are so intimately correlated that they may be discussed collectively.

The presence of cardiac murmurs or enlargement of the heart is readily determined.

Cardiac hypertrophy with valvular lesions will withstand an operative strain better than a heart that is apparently normal in size without such lesions, but with a weakened or dilated myocardium.

The relative range of the systolic and diastolic blood-pressure presents an approximate index of the myocardiac and vascular tonicity.

The blood-pressure should be noted before, during, and after every extensive operation as a gauge of the patient's resistance to the anesthetic and surgical trauma. A sudden drop in the systolic pressure is a danger signal.

The normal systolic pressure, taken with the 10 or 12 cm. cuff, ranges from 110 to 140 mm. of mercury, the diastolic running from 20 to 40 mm. lower.

The normal pulse may affect the normal pressure. A pulse under 65 gives about 123 mm., and over 85, 130 mm. Transitory rise may occur from apprehension, requiring a second or third reading. It will rise after eating and drinking, persisting for nearly an hour. Exercise will augment it from 5 to 15 mm. A very low blood-pressure (100 mm. of mercury) in an adult denotes a weak heart.

A persistent blood-pressure exceeding 140 should suggest a possible arteriosclerotic or renal menace.

There are various indirect methods of testing the functional capacity of the heart; the simplest is to note the relative pulse-rate in different attitudes—sitting, standing, lying—or its increased rapidity on slight exertion.

Normally, on assuming the recumbent posture, the pulse becomes slower.

If the patient is recumbent, rising, or even turning, will reveal abnormal cardiac strain. If the pulse rapidity is greatly increased, and lasts more than a few minutes, the heart is defective.

A urinary examination of the twenty-four-hour specimen, with the patient on full diet, should reveal not only the presence of albumin, casts, sugar, the estimated excretion of nitrogen and the more important inorganic salts, but also the permeability of the kidneys as demonstrated by aniline tests.

Under normal conditions, blue urine is excreted in ten to twelve minutes after an intramuscular injection of 4 mils of a 4 per cent. indigo-carmin solution.

Any marked delay in the color excretion denotes a renal impairment.

If nephritis is present, or if an insidious intersti-

tial nephritis is suspected, the operative prognosis, especially under prolonged anesthesia, is serious; such kidneys may readily cease functioning.

If the blood-pressure, the strength of the heart, and the kidney efficiency approximate the normal, the prognosis from these points of investigation is clear.

When the kidneys are but slightly involved, a short period of carbohydrate diet, with rest in bed and liberal intake of water, will minimize the danger of uremia, acetonuria, or acidemia.

An equally vital consideration is the condition of the gastro-intestinal function. The presence of such conditions as dilated stomach, motor impairment, intestinal stasis with impacted feces, may induce the absorption of putrefactive and fermentative toxins, all of which demand preoperative correction.

Prolonged starving of a patient for from twenty-four to forty-eight hours, and profuse purging with more or less drastic cathartics, are not to be commended as rational preparatory treatment.

These measures cleanse the gastro-intestinal tract, while they deplete the patient's strength and resistance.

The preferable method is to administer mild purgatives of the vegetable class for several days previous to the operation, thus giving the intestine time to regain its normal activity without debilitating the patient.

For twenty-four hours before an operation the patient's diet should consist mainly of simple carbohydrates. The greater the quantity of such nutrient assimilated, the less danger from excessive post-operative vomiting, acetonuria, or fatal acidemia.

Hospital surgeons generally prefer to operate during the early morning; in such instances the patient has probably fasted for from twelve to fourteen hours.

While under ordinary conditions an individual is at his lowest temperature, lowest blood-pressure, and lowest cardiovascular tone from four o'clock to eight in the morning, there is on the other hand a decided advantage in operating upon a patient who has enjoyed a good night's sleep, free from the depressing influence of anxious anticipations.

Other things being equal, it may be well in the majority of cases to operate during the morning hours, *provided, however, that the patient has received some stimulating nourishment*, such as a cup of coffee or tea with sugar but without milk, two hours previous to the operation.

The caffeine in the coffee will temporarily raise the blood-pressure. This is especially desirable when the circulatory apparatus had gradually adapted itself, through a long period, to increased vascular tension, the sudden diminution of which may induce an acute cardiac, respiratory, or cerebral failure.

Thyrotoxicosis, especially of the more insidious type, is a frequent complication of gynecic disorders. A rapid heart may present the only symptom of this condition, in which postoperative shock, or so-called "delayed shock," should be anticipated. In very mild or suspicious cases it may be wise to administer a hypodermatic injection of morphine before operating.

As a routine practice, however, the preoperative administration of morphine or scopolamine is not to be commended. It is generally recognized that in

marked hyperthyroidism surgery should be postponed until general measures have mitigated the toxicity of the excessive thyroid secretion.

The sleeping habits of the patient will repay investigation. A woman who, from anxiety or other cause, has not slept for days or weeks prior to an operation, will not do so without medication after such operation; a succession of sleepless nights will not tend to conserve her mental and physical stamina for the operative ordeal. A mild hypnotic is therefore indicated in all such cases during the preparatory period, and, while generally objectionable as a routine practice, it will obviate the necessity for the exhibition of stronger narcotics during the postoperative stage in women of this class.

The premenstrual and menstrual period are unfavorable to gynecoplastic surgery, for, aside from obvious objections, the functional hyperæmia and the presence of an active anticoagulative substance in the menstrual blood may induce a very copious oozing during operation, and enhance the possibility of postoperative hemorrhage.

Finally, an active gonorrhœa, cystitis, vulvar eczema, excoriations, dermatitis or furunculosis should be eliminated before attempting any plastic procedure about the urogenital canal.

In all cases of complete procidentia of long standing it is advantageous to replace and retain the prolapsed organs mechanically, while confining the patient to bed for at least four days prior to operation.

If the cervix presents infected ulcerations, these should be previously cauterized.

CHAPTER II.

PREOPERATIVE AND POSTOPERATIVE PERIODS.

THE older gynecologists invariably subjected their patients to a very protracted preoperative routine, extending in some instances over several months, while modern gynecologists generally operate within a twenty-four-hour preparatory interval.

All routine practice is bad practice; protracted meddling is superfluous. On the other hand, inadequate precautions are dangerous pitfalls. Every case presents its own specific indications, which should be met to the smallest detail.

Repeated copious irrigation of the vaginal canal for disinfecting purposes should be restricted. The vaginal lining is generally regarded as incapable of absorbing pharmacologic agents; nevertheless, numerous cases of mercuric chloride, zinc sulphate, iodoform, arsenic, belladonna and phenol poisoning are recorded as the result of medicated douches and local applications.

The studies of D. I. Macht "On the Absorption of Drugs and Poisons Through the Vagina," published in the *Journal of Pharmacology and Experimental Therapeutics*, 1918, make it evident that "alkaloids, inorganic salts, esters and antiseptics are readily absorbed by the vaginal mucosa," and he concludes "that systemic poisoning of obscure origin may find its explanation in absorption of toxic agents through contact with the vagina."

On the afternoon or evening before operation the external genitals and adjacent surfaces are shaved, and the patient's lower bowel irrigated.

This obviates the necessity of disturbing the patient's rest in the early morning. All local preparations should be completed at least half an hour before operating.

With the anesthetized patient on the operating table, the genitalia, the vaginal canal, and the surfaces surrounding the operative field are scrubbed thoroughly but gently with green soap, warm sterile water, and gauze mops.

The soap is rinsed off, and the surfaces thoroughly dried with sterile towels, after which the bladder is emptied with a glass catheter, the tip of which is previously dipped in 20 per cent. argyrol solution.

Two per cent. tincture of iodine may then be freely applied to all parts, the excess being dried by gauze sponges.

Ease of accessibility and perfect exposure of the operative field must be secured as prerequisite essentials to accurate reconstruction, every step of which must be conducted with deliberation and painstaking attention to details.

Anything like an attempt at speed in plastic work denotes the self-consciousness of the operator rather than his actual skill in this special branch of surgery. At the end of each operation the whole field should be scrupulously inspected to assure the correctness of approximations, the absence of undue tension, the control of all bleeding, and the obliteration of dead spaces.

Bleeding vessels should be clamped without crush-

ing surrounding tissues, the finest catgut being used for ligation.

Rigid, scarred, non-vascular or inflamed and œdematous tissues are useless for plastic purposes. All flaps should consist of well-nourished segments, neither redundant nor inadequate, permitting of natural coaptation without stretching.

Not only tight sutures, but multiple sutures, are to be avoided.

Figure-of-eight stitches are undesirable in perineoplasty. The various layers, exhibiting different degrees of resistance, demanding different degrees of tension, cannot be controlled in any figure-of-eight stitch, the deep loop frequently proving too loose or too tight for the superficial loop.

No line of union should be sewn hermetically, but minute spaces left between interrupted stitches to obviate the retention of blood-clots and preclude infection.

It is safer to harbor bacteria in dry open spaces than in closed cavities filled with decomposing blood.

In the postoperative stage the immediate dangers are shock and postoperative hemorrhage; the more remote danger is infection. All three are better prevented than cured.

The anesthesia should be discontinued at the earliest feasible moment. The margin of safety in the anesthesia is frequently passed during the final stage of the operation.

The proximity of the bowel and bladder complicate the problem of wound dressings about the vulvar region.

All intravaginal douches are interdicted during

the healing period, the parts being kept as dry as possible. This is best accomplished with sterile pads during the oozing period, after which all dressings are discarded, and the parts kept dusted thoroughly with a mixture of stearate of zinc and boric acid. The great advantage of this stearate mixture is that it sheds water; and, while it may gradually become moist, it is possible, with reasonable care, to maintain a sufficient degree of dryness and comfort. This treatment is especially advantageous in obese patients with closely apposed buttocks.

Barring cases of urinary fistulæ, all patients should be encouraged to void voluntarily. When necessary, the catheter may be used every eight hours, its sterile tip being invariably dipped into and filled with 20 per cent. argyrol solution prior to introduction. The necessary resort to catheterization is the signal for the internal administration of urotropin, 5 to $7\frac{1}{2}$ grains *t.i.d.*

In fistula operations demanding rubber retention catheters, *urotropin* should be *avoided*, as its elimination in the urine will disintegrate the catheter, depositing particles of rubber or the entire catheter bulb within the bladder.

The sovereign remedy for shock is morphine in $\frac{1}{8}$ -grain doses by hypo. every four hours, with camphor in sterile oil or caffeine as a temporary adjuvant. Strychnine is always useless, and occasionally harmful.

The amount of urine secreted is the most practical guide to the circulatory condition of the patient. The more nearly this amount approximates 1500 grams per day in a previously normal condition the safer the patient.

Albumin and casts are found in the urine so frequently after etherization that they may almost be expected, especially the albumin after prolonged operations.

The amount varies from a faint trace to considerable quantities. The profuse perspirations occurring during operation, the nausea, vomiting, and the small amounts of fluids ingested previously, depress urinary excretion.

The greater the amount of urine excreted, the greater the elimination of toxins; hence the patient should receive water as soon as possible by mouth, rectum, or hypodermoclysis.

After the effects of the anesthetic have passed, there should be no restriction as to the amount of liquid taken by the patient. A few sips of water are given at first. If these are retained, the quantity is rapidly increased, so that within twenty-four to forty-eight hours at least three pints of fluid should be ingested daily. The necessity for fluids is especially urgent in those who have lost much blood, and in toxic patients. A cup of coffee or tea may be safely given within four hours after the operation, provided there is no nausea or vomiting. After the first post-operative bowel movement, full diet is permissible.

Excessive and prolonged vomiting should be combated promptly by stomach lavage, which is more especially indicated in the early stages of acute gastric dilatation.

Unless there is much discomfort from flatus or distention, it is not necessary to administer laxatives for the first three or four days.

Enemata are objectionable, as they tend to contaminate the adjacent surgical area.

The tendency of a deficient heart to acute post-operative dilatation should prompt caution in first directing the patient to assume the upright position. The elevation should be very gradual, approaching the vertical when the blood-pressure has resumed and maintained the level normal to the individual as established by preoperative observation.

CHAPTER III.

SACRAL ANESTHESIA IN GYNECOPLASTIC OPERATIONS.

AMONG the various methods and means for the induction of regional anesthesia, the one most applicable and uniformly efficacious in gynecoplastic surgery is "sacral blocking" or "caudal anesthesia" by extradural novocain injection.

The epidural space surrounding the dura mater from the foramen magnum to the hiatus sacralis comprises the area between the dura mater and the periosteum lining the spinal canal.

The sacral canal is a continuation of the spinal canal, but at the second sacral segment communication between these two parts is interrupted by the closure of the dura mater around the nerve trunks.

This isolation of the sacral from the spinal canal is demonstrable anatomically (see illustration). Laewen showed that colored fluids injected into the sacral canal never appeared in the spinal canal or stained the upper part of the cord, thus proving the absolute isolation of these two sections of the dural area from one another, so that, while the nerves are transmitted from the spinal into the sacral canal, there is no other communication between the two. This marks the distinction between sacral and spinal anesthesia; in the former, the anesthetizing fluid is injected through the hiatus sacralis into the sacral canal,

while in the latter the injection is made through the lumbar origin into the spinal canal.

Upon the outer surface of the dura, in the epidural space, especially at the sides, are extensive venous plexuses and loose adipose tissue.

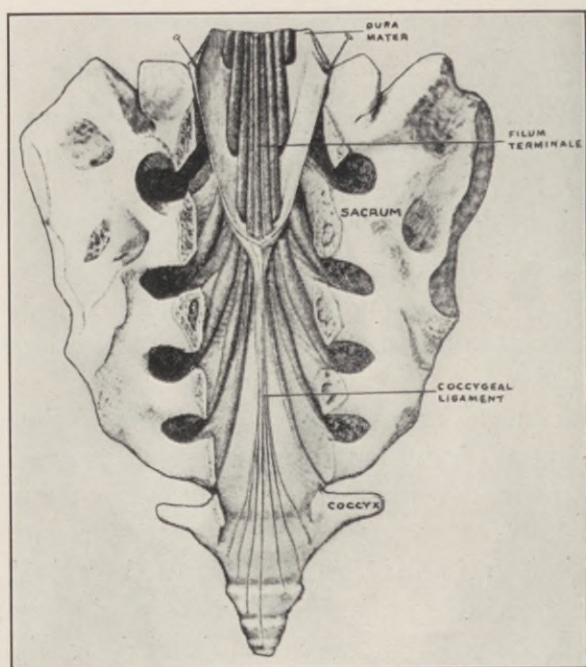


Fig. 1.—Showing separation of spinal and sacral canals by closure of dura mater. Sacral nerves exposed. (*Gray-Spitzka.*)

The sacral canal terminates below in the hiatus sacralis, forming a triangular opening, the sides of which are marked by the bony ridges known as the sacral cornua.

This opening varies in size in different individuals. It may be abnormally large, owing to a deficiency in

one or more of the vertebral arches, or it may be reduced even to the extent of complete obliteration by ossification.

Normally, the hiatus is closed by the posterior sacrococcygeal ligament, which may be recognized on palpation by passing the finger along the sacral spines from above downward.

Laewen has aptly compared the palpatory character of this membrane with its bony borders to that of a fontanel.

Technique of Administration. The patient is placed on her right side, on an inclined surface, with head elevated and the spine flexed to the limit of comfortable tolerance, bringing the knees and chin as nearly together as possible.

The area over the sacrum and the immediate neighborhood is cleaned with benzine, dried, and painted with iodine.

The sacral hiatus is located just below the rudimentary sacral spinous processes and above the coccyx.

Having infiltrated the skin and deeper soft tissues over the hiatus with the anesthetizing solution, a long needle fitted with a wire stilet is thrust through the membrane covering the hiatus.

In penetrating the membrane the needle is inserted at an angle of 45 degrees to the skin surface, after which its head is depressed almost to a level with the body plane, and its point diverted upward exactly in the midline following the axis of the canal for a distance of $1\frac{1}{2}$ to 2 inches (Lewis and Bartels).

When the needle is *in situ*, the stilet is withdrawn. If cerebrospinal fluid appears, the needle must be

withdrawn until the flow ceases, when its point will be in the sacral canal.

If blood escapes through the needle, a vein has been entered, and the position of the needle must be changed to avoid an intravenous injection of the anesthetic. It is not necessary to introduce the needle beyond 3 or 4 cm.

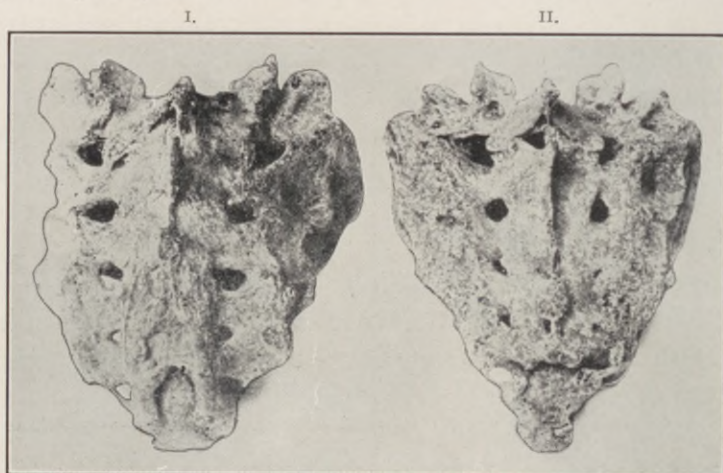


Fig. 2.—I. Showing first coccygeal vertebra fused with sacrum. Upper end of hiatus low down between the fourth and fifth sacral foramina. Hiatus well formed. Margins of hiatus formed by the fused spinous processes of the fifth sacral and first coccygeal vertebrae. The fifth foramen complete posteriorly and anteriorly. II. Fusion of first coccygeal vertebra with sacrum. The fifth foramen complete in front; represented by a fissure behind. Hiatus represented by a transverse slit at the level of the fifth sacral foramen. (*J. E. Thompson.*)

If the needle is in the sacral canal, there is practically no obstruction to the flow of fluid from the syringe. If it should lie superficial to the sacrum, there will be considerable resistance, and a subcutaneous bulging develops over the site of the injection.

Laewen determined that less than 20 mils of a $1\frac{1}{2}$ to 2 per cent. novocain solution will prove ineffectual.

Anesthesia is first noted at the tip of the coccyx, from which it gradually extends over the perineum, then laterally to the gluteal region.

The clitoris is the last to become anesthetized. In other words, the coccygeal plexus is first to become

I.

II.

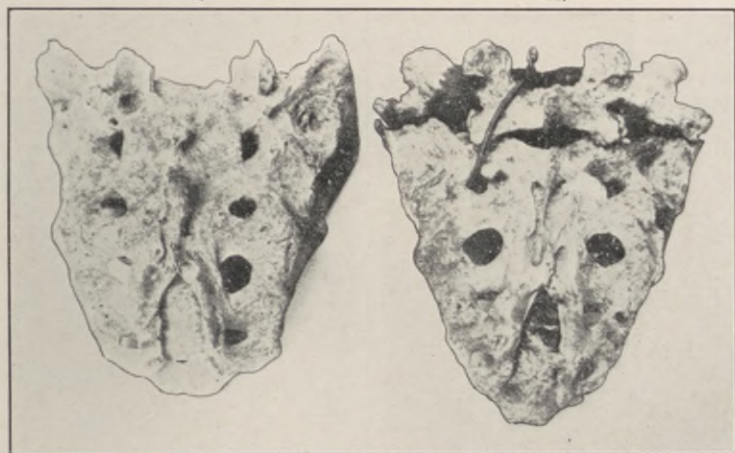

Fig. 3.—I. Hiatus very long, and shaped like a horse-shoe. The upper end is at the level of the third sacral foramen. The margins of the hiatus are formed by two flattened ridges, in which can be seen rudiments of the spinous processes of the fourth and fifth sacral vertebrae. II. Hiatus very long, and shaped like an isosceles triangle. The upper end reaches to the upper margin of the third sacral foramen. The margins are flattened, and are formed by the fused spinous processes of the fourth and fifth sacral vertebrae. (*J. E. Thompson.*)

anesthetized, followed by the hemorrhoidal, the perineal, and, lastly, the pudendal plexus.

It is difficult to determine the extent of the anesthesia, as the various operations involve more or less traction upon tissues innervated by nerves originating above the caudal region.

Thompson states: "As a rule, one injection of 3 tablets, each of which contains novocain, 0.125 Gm., suprarenin, 0.000125 Gm., dissolved in 30 mils of distilled water, to which 10 drops of a 50 per cent. solution of calcium chloride is added, is sufficient, and at the end of half an hour anesthesia is complete in the branches supplied by the sacral nerves.

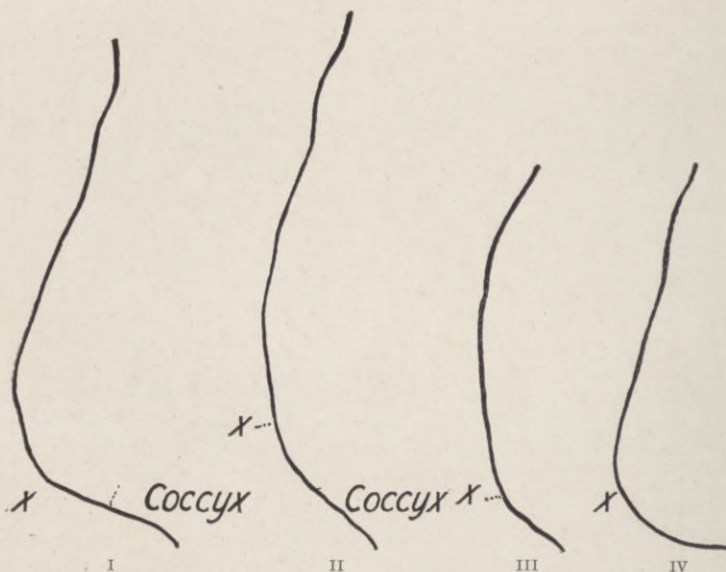


Fig. 4.—I. Curved type of sacrum, fused coccyx; opening of hiatus shown by a cross. II. Long flattened type of sacrum, fused coccyx; opening of hiatus shown by a cross. III. Short flattened type of sacrum; opening of hiatus shown by a cross. IV. Curved type of sacrum; opening of hiatus shown by a cross. (J. E. Thompson.)

"We have injected a second time not infrequently, and have never failed after a second injection to secure perfect anesthesia. The quantity of novocain used has been considerable, as much as 0.750 Gm. having been introduced into the peridural space in

two injections. As far as our experience goes, we have never seen evidence of toxic symptoms."

The appended chart, designed by Prof. William Keiller for Thompson's article quoted above, depicts the areas of anesthesia, the time taken for the anesthetic to produce its effect, and the spinal segments involved by diffusion.

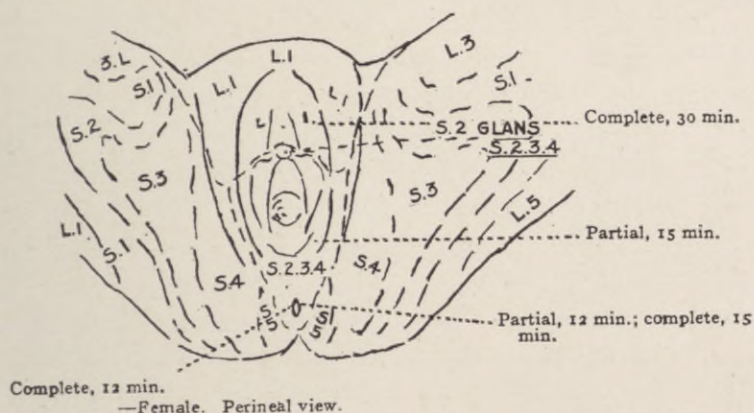


Fig. 5.—"Sacral blocking." Areas of anesthesia, time of manifestation, and spinal segments involved by diffusion.

To Cathelin belongs the credit for first demonstrating the feasibility of producing local anesthesia by extradural injection through the hiatus sacralis into the sacral canal. He used cocain, but was unable to produce satisfactory results in the human subject with safe quantities of this drug.

Stockel utilized Cathelin's method successfully in parturient women, substituting 30 mils of a $\frac{1}{2}$ per cent. solution of novocain for cocain.

Schlimpert and Schneider report 34 operations, comprising perineal repairs, curettage, rectoscopy and cystoscopy, under sacral novocain anesthesia.

Laewen gives a detailed report of 80 cases, with 7 failures, and recommends the method for forceps delivery and repair of obstetric injuries.

Schlimpert, in a second communication, enumerates 55 cases, with 11 failures. In 12 others, general anesthesia had to be induced, owing to the long duration of the operation.

Hertzler contends: "My own experience with 'sacral blocking' has convinced me of the value of the method in perineal operations. It sometimes fails more or less, but if one is ready to supplement the sacral blocking by local infiltration, the shortcomings of the method do not work much of a hardship.

"My plan is to use quinine in the sacral canal, and novocain-epinephrin for local infiltration, or *vice versa*.

"In this manner it is possible to meet all indications without using an excess of the novocain-epinephrin solution.

"By using this combined method, I have never had to resort to general anesthesia.

"The usual cause of failure, aside from such gross errors as injecting the fluid outside the canal or into a vessel, results from the use of too small an amount of solution.

"Two ounces of a $\frac{1}{2}$ per cent. solution give more certain results than half this amount of twice the strength.

"The large nerve trunks of the legs may become anesthetized. This may result in complete sensory anesthesia, and may affect the motor fibres to the extent that the patient is unable to walk for several hours. This soon passes off."

In operations on the cervix, the traction pain is very marked, owing to the pull on the broad ligaments.

The same holds good for the manipulation necessary in levator myorrhaphy for perineal lacerations, necessitating the local infiltration of the levator ani bundles prior to their mobilization and suture.

When all is said and done, it must be stated that at the present writing, notwithstanding the positive claims embodied in the quoted excerpts, the region of the female genitalia and the pelvic floor do not offer an ideal field for major surgery under sacral anesthesia. The diversity in the source, ramification, and anastomosis of the sensory innervation, added to the patient's attitudinal discomfort from a necessarily prolonged lithotomy position, constitute intrinsic obstacles and disconcerting factors, which to a greater or lesser degree are encountered in a large majority of cases.

CHAPTER IV.

TRACHELOPLASTY.

LACERATION of the cervix uteri was recognized in ancient times.

The textbooks on Obstetrics published during the eighteenth century refer to the "cleft condition of the cervix" as a product of difficult delivery, and to the cicatricial tissue resulting from previous lacerations as a cause of tedious labor.

J. H. Bennett wrote extensively on the appearance and results of the lesion under the title, "Ulceration of the Cervix." This pathological misnomer established the general practice of treatment by caustics, in the attempt to heal the supposed ulcer.

Microscopic examination of such an "ulceration," when removed intact from the living during operation, will invariably disclose that the apparent ulcer is covered by a layer of normal epithelium, that its granular appearance is produced by surface corrugations, and that its tendency to bleed on touch is due to the extreme friability of its thin epithelial covering.

Modern textbooks generally apply the term "erosion" to these readily bleeding patches, and describe two types:

(1) The "papillary erosion", in which the affected surface presents a field studded with papillæ, each covered with a single layer of columnar epithelium; and

(2) "Glandular erosion", a condition where the surface is smoother, but in which many cervical glands are present. This latter form is also designated as "eversion".

The term "erosion", however, like "ulceration", is inapplicable, as it suggests a solution of surface continuity, while all of these involved areas actually present an intact epithelial covering. The whole process simply represents an extension of the diseased endocervical mucosa (chronic endocervicitis) to the vaginal covering of the cervix. In this situation the tissue is subjected to friction and to the irritation of the acid vaginal secretions.

As the disease progresses, the squamous vaginal epithelium proliferates over the affected surface, gradually replacing the columnar endocervical epithelium, and thus occludes the outlets of all subjacent cervical glands within the involved area.

The resulting retention cysts finally penetrate from the inner to the vaginal aspect of the cervix as small shot-like elevations, familiarly known as "nabothian follicles", the presence of which is invariably pathognomonic of chronic endocervicitis.

Ambrose Paré first advocated amputation of the cervix.

Osiander in 1802 published the first detailed treatise on the operative procedure, after performing it upon 23 patients.

Among the advocates of the method as proposed by Osiander appear the names of Dupuytren, Recamier, Lisfranc, and others of equal fame.

The operation was performed by means of the bistoury, scissors, the *écraseur* and galvano-cautery;

the latter method was perfected by John Byrne, of Brooklyn. All of these methods left an uncovered raw cervical stump to heal by granulation.

The first plastic amputation of the cervix uteri, utilizing a cuff of vaginal mucosa as a stump covering, was practiced by Marion Sims in 1861. One year later T. A. Emmet performed his first successful trachelorrhaphy, the technique and results of which, however, were not published until 1874. In discussing Emmet's operation, Sims declared: "We can't modify it, we can't change it, for it is perfect—perfect in its method and perfect in its results."

Emanating from so prominent a source, and endorsed by such authority, these operations, which embody the origin and principles of all subsequent tracheloplastic methods, found enthusiastic adoption in America, and to a large extent in England, while at the same time their introduction among Continental surgeons instigated an interminable maze of controversy and modifications.

Today, after a tenure of nearly half a century, the conviction is gaining ground that the reputed efficacy of these standardized operations is not substantiated by final analysis.

This is convincingly revealed in a recent report by Leonard, from Howard Kelly's clinic at the Johns Hopkins Hospital, who tabulated the immediate and end results of the classic cervix amputations performed during the past twenty years.

One hundred and twenty-eight complete postoperative histories, from among 400 cases, forced Leonard to conclusions, which "were quite unexpected, and in many ways disappointing."

"Nearly 5 per cent. of the patients presented serious postoperative hemorrhage, occasionally after established convalescence.

"Ten per cent. of the cases suffered from decided augmentation of a preëxisting menorrhagia or dysmenorrhea.

"Four-fifths of the women, in whom pregnancy might reasonably have been anticipated to follow the operation, remained sterile.

"On the other hand, 50 per cent. of the pregnancies occurring after cervix amputation terminated prematurely, while among the few who progressed to full term even a larger proportion experienced difficult and prolonged labor.

"The operation in all of the cases presented consisted of the classic circular amputation, removing about three centimeters of the cervix above the external os."

Actuated by these "disappointing results", Leonard next tabulated the postoperative effects of *trachelorrhaphy* for comparative analysis with those of *cervix amputation*, concluding as follows:

"The presence of a marked endocervicitis should be considered as contraindicating simple trachelorrhaphy, for although trachelorrhaphy may render a *mild* endocervicitis more amenable to treatment, it cannot be considered, like amputation of the cervix, a curative measure for this condition.

"Fertility is much more likely to follow trachelorrhaphy than amputation of the cervix.

"After amputation of the cervix, the incidence of abortion and premature delivery is greatly increased,

while trachelorrhaphy has no effect upon the course of subsequent pregnancy.

"Labor after cervix amputation is usually difficult, while after trachelorrhaphy it is almost always normal; hence amputation of the cervix is to be avoided in the child-bearing period, trachelorrhaphy being the operation of choice in *properly selected cases.*"

Accepting these data from authoritative sources, as a correct exposition of facts, the obvious deduction is, that with *chronic endocervicitis* as the recognized *pathologic indicator*, trachelorrhaphy is an inadequate, and cervix amputation an injurious, operation.

That it is not the tear in the cervix, but the induced complications, which bring the patient to the operating table, is amply demonstrated by the countless women who bear cleft cervices, presenting ununited cicatrized edges, that are unproductive of any symptoms whatsoever, and it follows that the limitations of trachelorrhaphy, like the indications for cervix amputation, must be governed by the nature and degree of existing concomitants and not by the extent of the cervical injury. A single shallow tear may initiate the most serious train of complications in one patient, while a more extensive multiple injury may prove perfectly innocuous in another; and the question naturally obtrudes itself: What factor establishes the immunity from symptoms in the one and the morbidity of the other? Why is trachelorrhaphy ineffectual, and cervix amputation harmful, in so large a proportion of the cases?

The solution to these problems demands a radical revision of current elementary conceptions of cervical

disease, and modification in the technique of its operative cure.

The fundamental dominant that establishes the morbidity of any cervical lesion is the *incidence* of *infection*.

Clinically, the course of such infection assumes one of two types: it may reveal its initial stage as a frank puerperal sepsis of varying intensity, with a gradual subsidence of its systemic manifestations; or, what is more common, it pursues a more or less insidious course from the beginning. The first type usually merges into the second, so that ultimately both types eventuate in varying degrees of the same symptom-complex, designated as "chronic endocervicitis".

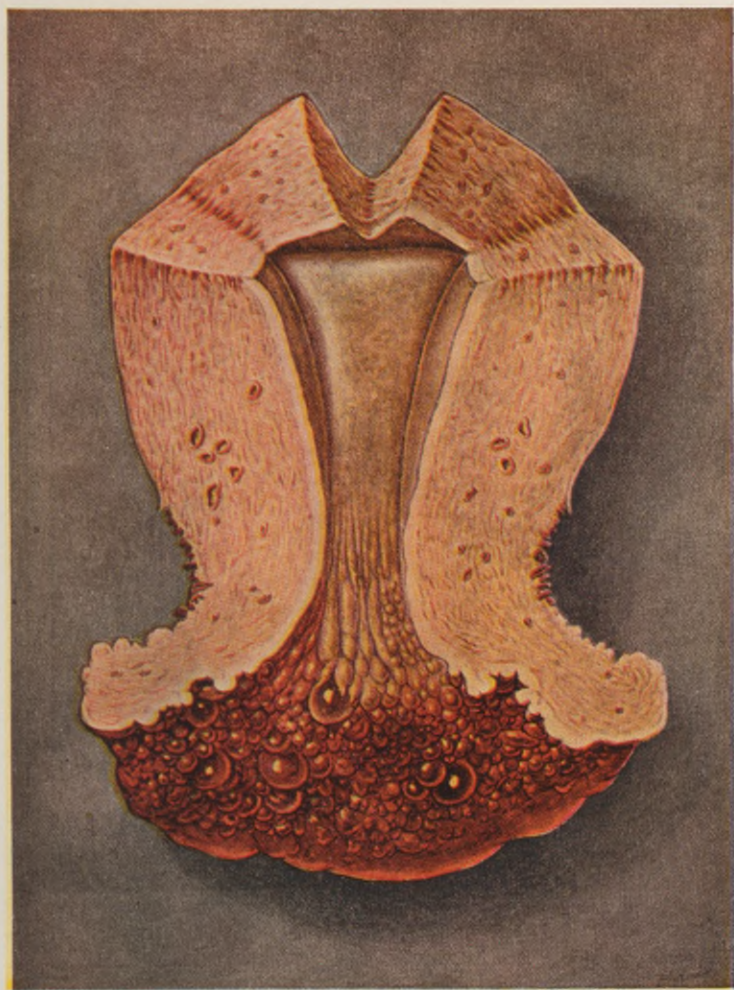CHAPTER V.

CHRONIC ENDOCERVICITIS.

CHRONIC endocervicitis or endotrachelitis is the most prevalent and most familiar objective manifestation among gynecological disorders. It constitutes a concrete clinical entity of pathogenic potentialities which may menace the integrity of the entire gynecic system. Nevertheless, it is accorded no special consideration as such in current textbooks, where its description is scattered among numerous chapters as an incidental feature under various captions, as "cervical catarrh," "simple follicular or papillary erosion," "eversion," "ectropium," "ulceration," "hypertrophy of the cervix," etc., all of which depict only different features of the same infectious process, the nature, course, and significance of which is obscured by perpetuated misconceptions and misleading dogma that dominate its ineffectual treatment.

In structure and in function, a sharp line of demarcation differentiates the cervical mucosa from the corporeal endometrium. Physiologically, the cervical canal presents nothing more than a passive communicating channel between the vagina and the uterine cavity proper. The cervical mucosa is composed of deeply penetrating racemose glands, which simply secrete mucus. It does not participate in the cyclic metamorphosis of the corporeal endometrium essential to menstruation or decidualation. But more significant than this structural and functional con-

PLATE I.



Chronic endocervicitis. "Follicular erosion." Showing sharp line of demarcation between the diseased cervical lining and the normal corporeal endometrium. (*Palmer Findley.*)

trast is the striking disparity in pathological manifestations displayed below and above the internal os.

The cervical mucosa evinces a marked susceptibility to infection, while the corporeal endometrium, contrary to orthodox conception, is practically im-

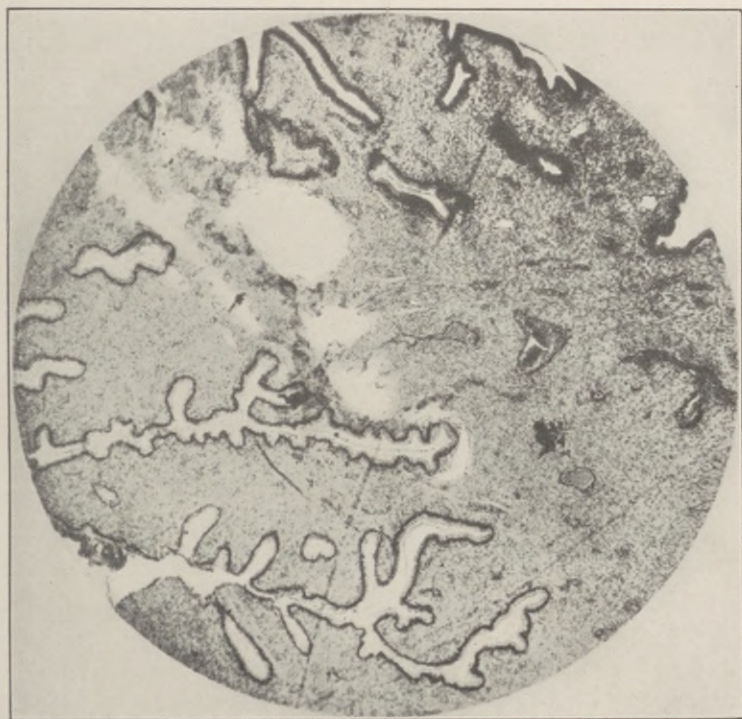

Fig. 6.—Normal cervical glands. Note racemose outlines and depth of penetration.

mune. In short, the cervical mucosa could be aptly termed the tonsil of the uterus.

Kundradt first, in 1873, and more recently Hitschman and Adler, have conclusively demonstrated that all of the histologic features generally depicted as

“chronic endometritis”, inclusive of typical round-cell infiltration, constitute only the normal transition of the endometrium into the transudative phase of its menstrual cycle. Even that infrequent condition clinically labelled “hypertrophic endometritis”, more correctly termed glandular hyperplasia, is never inflammatory in character, but a functional adenoma-

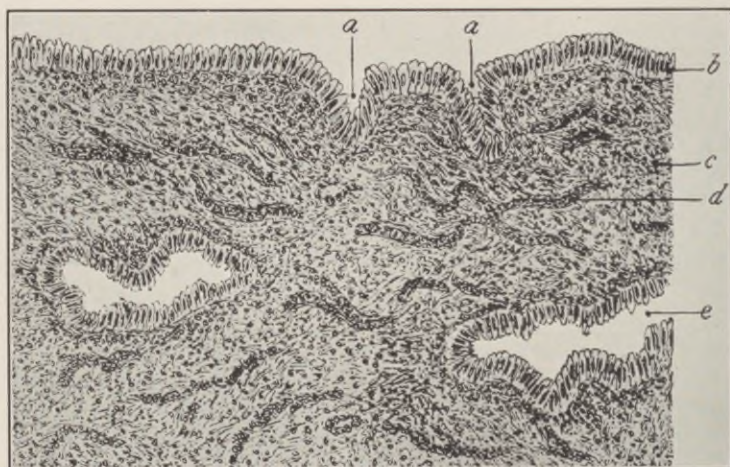


Fig. 7.—Normal endocervical mucosa. *a*, Gland opening cut obliquely in sectioning. *b*, Columnar epithelium (ciliated). *c*, Connective tissue stroma. *d*, Capillaries filled with blood. *e*, Oblique section through cervical glands.

tous overgrowth, analogous to that presented by the thyroid gland in Graves' disease. While this subject is still a matter of academic controversy, the majority of pathologists concede that, clinically at least, chronic corporeal endometritis may be safely discarded.

The most recent bacteriological studies fully substantiate the relative immunity of the corporeal endo-

metrium to ascending surface infection from the cervical mucosa.

Arthur H. Curtis, in "A Combined Bacteriological and Histological Study of the Endometrium in Health and Disease", embracing a series of 118 cases, states:

"It has been my object to make a study of the endometrium, exclusive of the cervix, in all conditions usually encountered except those associated with pregnancy. All material has been secured from uteri removed at operation. Scrapings from the endometrium are so liable to contamination that cultures from them are not included in this series.

"The variety of media employed and other procedures followed are in close accord with details described in the bacteriological study of uterine fibroids (*l.c.*).

"With sterile instruments and culture material in readiness, the stump of the cervix and entire length of the peritoneal surface of the uterus are cauterized, and the anterior wall bisected. The greater part of the endometrium is excised in its entire thickness, down to the muscle layer, and is placed in sterile containers to be ground and cultured. The remainder serves for immediate examination, for inoculation of culture media with unground tissue, and for microscopic study.

"This technique affords immeasurably more material than is secured by pipette or platinum loop. Through examination of so much endometrium, including the deeper portion, it is hoped that the possibility of overlooking dormant infections has been reduced to a minimum.

"From this work I believe that the endometrium

of nullipara, without history or gross evidence of pelvic infection, is almost invariably free from bacteria; it is also microscopically normal.

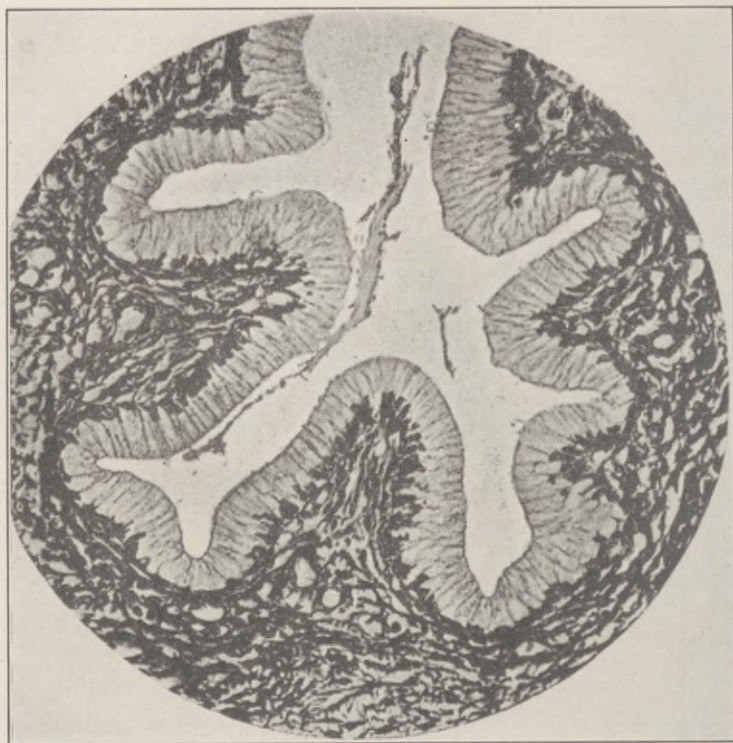

Fig. 8.—Normal cervical gland. High-power view showing racemose form, lined with a single layer of tall columnar epithelium, each cell with its nucleus at the base set upon a basement membrane. These terminal tufts extend deeply into the cervical tissues, and, once infected, nothing short of extirpation will prove curative.

“Almost all women who have undergone normal pregnancy, with pelvic history otherwise negative, likewise possess bacteria-free endometria. The possibility of infection appears to be but slightly in-

creased by pregnancy and the usual changes consequent thereto.

“Patients with a history of chronic infection, from whose endometrium bacteria are obtainable, almost all have salpingitis with equally good growth. *Pyometra and recent exploration of the uterus excepted, the endometrium almost never shows bacteria except when there is infection of adjacent pelvic tissues. Chronic*

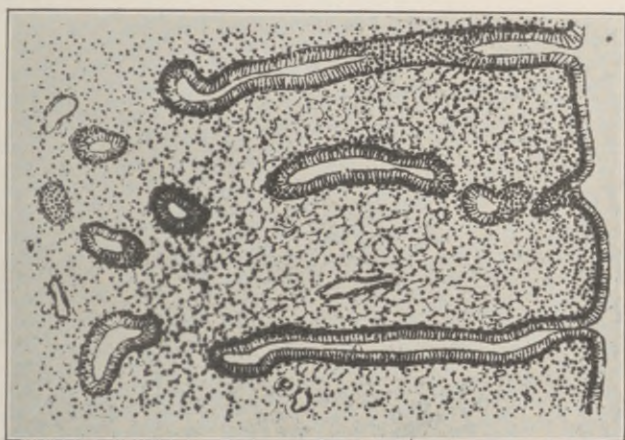


Fig. 9.—Normal utricular glands of the corporeal endometrium, showing their straight tubular form.

endometritis, per se, with bacteria present in smears or cultures, is practically to be ruled out as a clinical entity.

“In certain cases normal scrapings have been obtained from the uterus; then, several days thereafter, in the endometrium secured by hysterectomy, mixed cultures and endometritis have been found. Infection is perhaps not a customary result of curettage, but it appears not uncommon.

“Some will wonder why, if curettage tends to con-

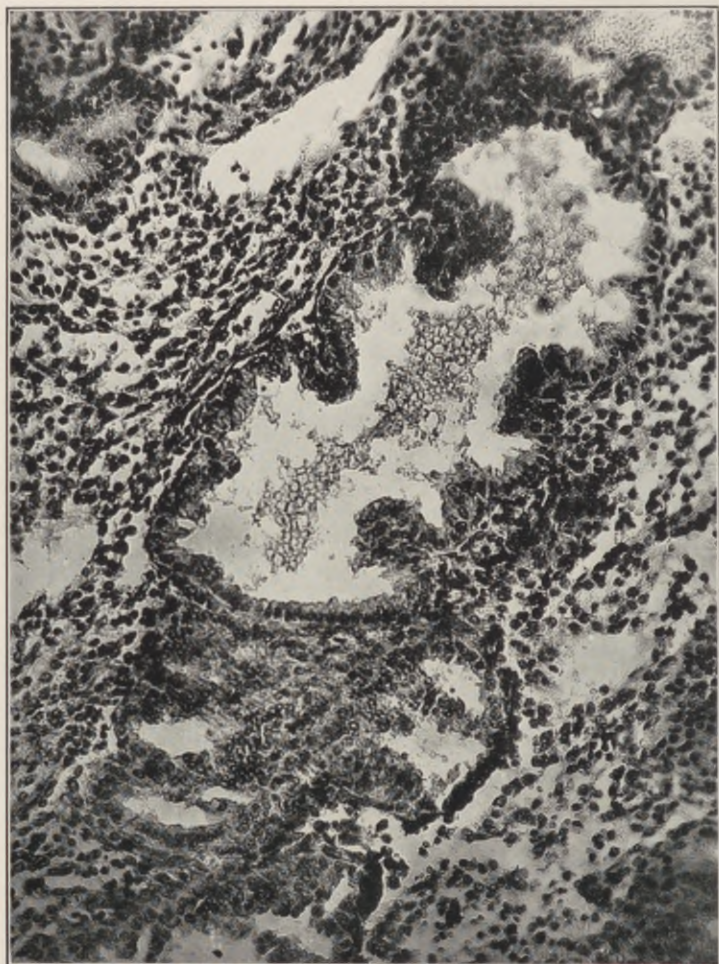


Fig. 10.—Corporeal endometrium in the transudative phase ("premenstrual") of its menstrual cycle, showing the normal presence of round cells and polymorphonuclear infiltration, simulating an inflammatory process.

taminate the endometrium, infection does not complicate hysterectomy in patients with preliminary curettage. Fortunately, nature can dispose of a few bacteria at the time they are introduced. But patients not operated upon until several days later, when the bacteria have had time to multiply, I believe are not ideal subjects. The problem is, in miniature, that which confronts the abortionist—he can meddle once with comparative safety, but if tempted to interfere

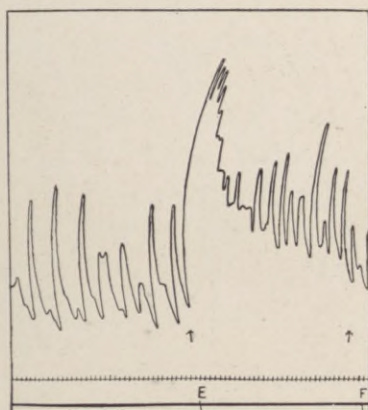


Fig. 11.—Automatic contractions of a non-pregnant uterus four hours after hysterectomy. At E, Epinephrin I: 2,000,000. (*Lieb.*)

again, to complete the task, he works in a contaminated and dangerous field.”

Nevertheless, the cardinal symptoms of chronic endocervicitis—namely, the disturbances in menstruation and deciduation—point so directly to an involvement of the corporeal endometrium, that their occurrence in the absence of endometritis demands elucidation.

To correlate the pathology and symptomatology of

chronic endocervicitis and place its therapeutics on a rational basis, we must revise some current conceptions of the myometrial structure and its dynamics.

The specific functions of the uterus in menstruation and gestation demand a wide range in the control of its blood supply, and, like the heart, the uterus automatically responds to its fluctuating circulatory necessities by rhythmic contraction and dilatation, *not only during pregnancy*, but throughout its functional

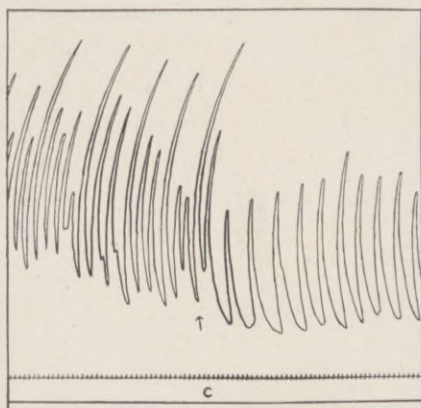


Fig. 12.—Automatic contractions of a muscle strip from a non-pregnant uterus three hours after hysterectomy. At C, Pituitrin 1: 100. (*Lieb.*)

existence (Henricius). An immobile muscle, whether in the uterus or elsewhere, degenerates. Moreover, the uterine veins, being devoid of valves, leave no provision other than muscular contractions to prevent local circulatory stasis and its consequences.

The myometrium is composed of smooth muscle fibres, which, like all non-striated muscle, exhibits the intrinsic phenomenon of rhythmic automatic contraction independent of any neurogenic stimuli.

Two familiar clinical manifestations will serve as a practical demonstration to depict the extreme phases of this muscular virility in the non-gravid uterus. The time-honored practice of applying silver nitrate solutions on a cotton-wrapped probe to the endometrium induces, in some patients, a most distressing tetanic response of the whole uterine musculature, which firmly clutches the probe, causes violent colicky pains, and mild but unmistakable symptoms of general shock. No hibernating muscle can manifest such tonicity. On the other hand, an equally distracting moment is experienced when, during a curettage, the operator suddenly finds himself "beyond his depth," the curette losing contact by a paralytic dilatation of the uterine cavity, simulating traumatic perforation of the uterine wall. Only a virile muscle exhibits such absolute paralytic flaccidity. Between these two extremes we will find every grade of perverted muscular irritability, with its objective and subjective concomitants.

The key to the architectural scheme of the uterine musculature is revealed in its formative, not in its matured state, and to gain a clear conception of its mechanism it is necessary to discard the accepted subdivision of this single muscle into several layers. Such a subdivision is purely arbitrary. There are no distinct layers, but a single muscle, presenting different angles in the course of its component bundles. Briefly stated, these bundles are arranged in a succession of fan-shaped muscle-sprays that wind spirally downward from each fallopian angle throughout the whole uterus to the external os.

Every muscle contracts toward its fixed point, and

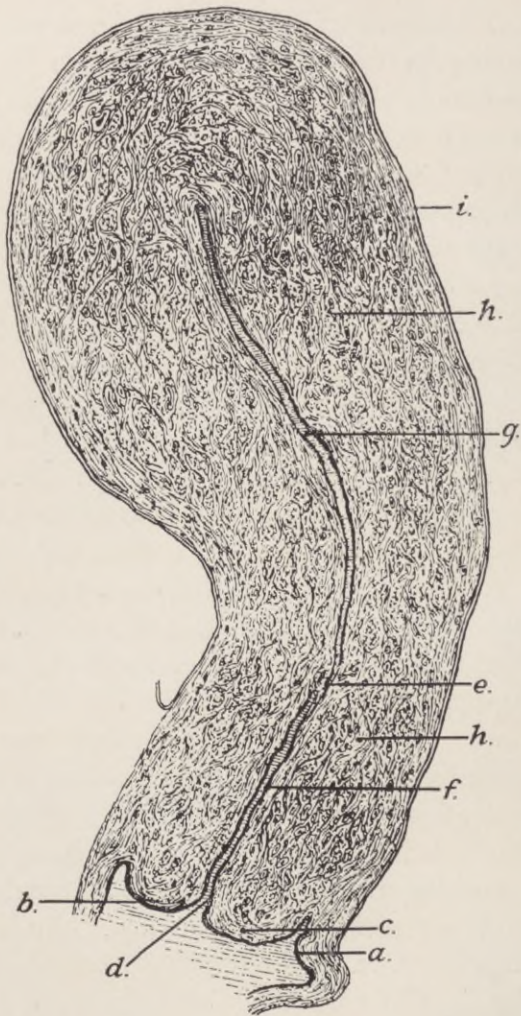


Fig. 13.—Sagittal section of the uterus. *a*, Vaginal mucosa. *b*, Squamous epithelium. *c*, Connective tissue stroma. *d*, External os. *e*, Internal os. *f*, Cervical mucosa. *g*, Endometrium. *h-h*, Musculature of cervix and corpus uteri. *i*, Peritoneal coat. (*Abel*.)

for the uterine muscle such relative fixed points are furnished through its fascicular prolongations in the round and broad ligaments at the pelvic brim.

The rhythmical contractions of the myometrium are necessary, not only in maintaining the nutritional and functional integrity of the uterus as a whole, but they serve the equally essential purpose of drainage. The cervical secretion must find free egress from the normal, and more especially from the diseased, conditions of its mucosa.

In the normal state, such drainage is effected, not merely by a passive outflow through a patent os, but by the active rhythmic expression resulting from uterine contractions.

To comprehend this mechanism, it is necessary to dispel the anatomical myth of a cervical sphinctre. Such a sphinctre would imply the existence of a concentrically contracting muscular ring. The structural design of the cervical musculature precludes any concentric closure of its outlet, which dilates with every uterine contraction, because its fibres, continuous with those of the corpus uteri, do not at any point completely encircle the cervix, but are disposed in serried successions of oblique circle segments, which by contracting spirally upwards necessarily shorten every diameter of the uterine cavity, and, by uncoiling in the cervix, widen the os like an iris diaphragm in a microscope.

Cervical *dilatation* thus becomes an integral part of uterine *contractions* instead of a passive relaxation in a hypothetical sphinctre. Incidentally, this mechanism explains the apparent obliteration of the cervix in labor.

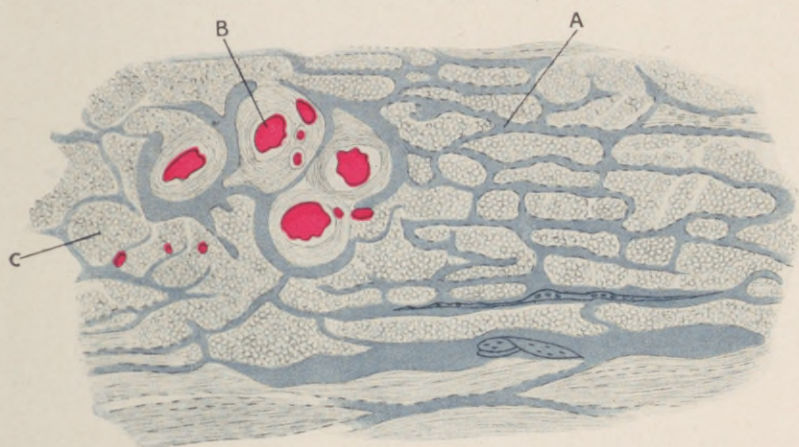
As already emphasized, it is not the laceration as such, but the incidence of its infection that determines the morbidity of a cervical lesion. In the cervix, as elsewhere, every infection incites the greatest reaction in its lymphatic system. The enormous resorptive capacity of the uterus is displayed in its gravid and puerperal state.

It is nearly fifty years since Leopold clearly demonstrated the normal uterine lymphatic circulation. Nevertheless, barring its disseminating rôle in malignancy, the domination of this element in the general pathology of gynecological infections has been practically ignored.

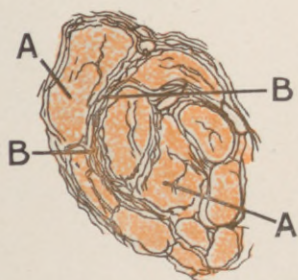
Quoting briefly from Leopold's description, which stands unchallenged to this day, the uterine lymph current may be traced from its lacunar origin in the cervical and corporeal mucosa, through minute funnel-shaped ostia, directly to the myometrium. Here it branches into an extensive capillary net, which, spreading on the perimysium, penetrates and enmeshes every bundle and fascicle of the entire uterine musculature to its subperitoneal surface, whence it drains into two main collecting channels that course parallel to the uterine and ovarian blood-vessels at the base and top of the broad ligament.

It is this normal lymphatic envelopment of the perimysial sheaths and adnexa that determines the course of an infection from the cervical mucosa—*not via the uterine cavity and tubal lumina, but along the intramuscular planes of the uterine and tubal walls to the ovarian tunica albuginea, as an ascending lymphangitis* whose pathological trail impairs normal uterine contractions by infiltrating the myometrial

PLATE II.



Injection specimen, normal nulliparous uterus, transverse section of myometrium. A, Lymphatics running on the intramuscular septa, and enveloping the muscle-bundles. B, Blood-vessels. C, Muscle-bundle. (*Leopold.*)



Transverse section of uterine muscle. A, Muscle-bundles. B, Intramuscular septa carrying blood- and lymph- vessels.

muscle sheaths, occasionally establishing disseminated miliary myometrial abscesses; then progressing to the periadnexal lymphatic ramifications, inhibits tubal peristalsis, kinks the tubes and agglutinates their

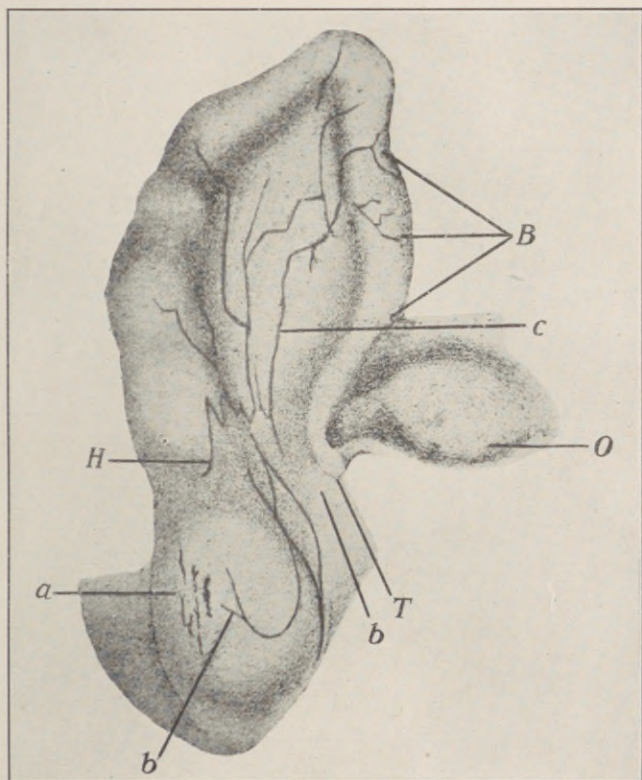


Fig. 14.—Periadnexal lymphatics. Sheep's uterus. H, Left horn. T, Tube. O, Ovary. B, Broad ligament. *a*, Subserous lymphatics. *b*, Collecting lymph tube. *c*, Transit into broad ligament channels. (*Leopold.*)

fimbrial ostia by the production of velamentous bands, which occasionally create tubal diverticuli with ectopic possibilities; finally, reaching the ovaries, the lym-

phatic infiltrate thickens their capsular tunic, impeding the normal rupture and regression of the graafian follicles, with ultimate development of retention cysts. In short, we find a *chronic ascending lymphangitis*, with its resultant impairment of uterine, tubal, and ovarian function—*not an endometritis*—that links the pathology and symptomatology of chronic endocervicitis.

The pathological process as depicted naturally varies in extent and degree, according to the virulence of the infection and the resistance of the tissues. It may remain limited to the racemose tufts of the cervical mucosa indefinitely in one case, while in another it eventuates in an infectious agglomeration of uterus, tubes, and ovaries.

Chronic abscesses in and about the broad ligaments, pyosalpinx, hydrosalpinx, sactosalpinx, tubo-ovarian cysts and abscesses, ovarian sclerosis, uterine fibrosis—all of apparently insidious development and obscure source—will usually reveal their primary focus in a chronically infected cervical mucosa.

The surgical bearing of this is obvious. How often is one of the adnexa removed for periadnexitis, and the other at a subsequent operation, when both could have been saved by a timely attack on the original focus within the cervix? Parallel with the pathological course, the intensity of its symptomatic manifestations will range from a simple but persistent leucorrhœa to complete functional invalidism.

Most important among the derangements resulting from chronic endocervicitis are the disturbances in menstruation, fecundation, and deciduation.

The periodic maturation and rupture of a graafian

follicle, the liberation of its contained ovum, the evolution and involution of the corpus luteum, and the cyclic transmutation of the corporeal endometrium, constitute the cardinal phases essential to normal menstruation, fecundation, and nidation.

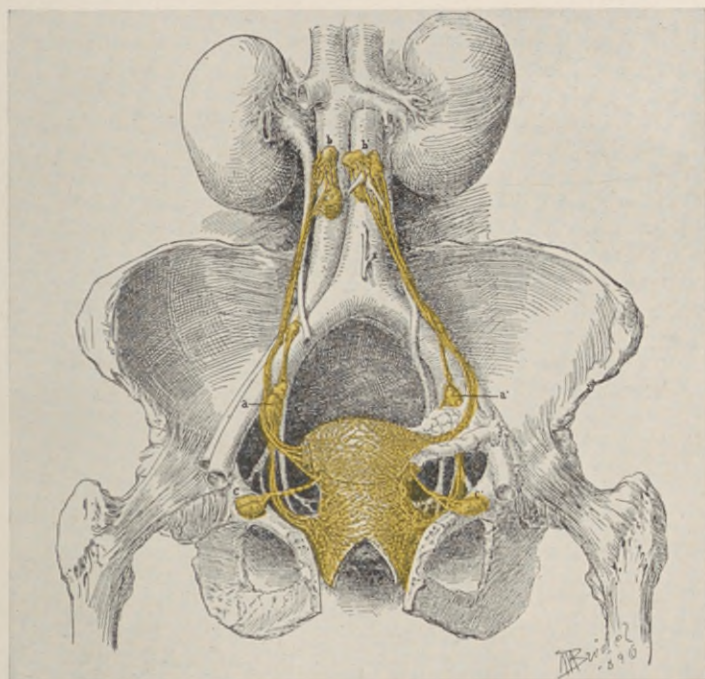


Fig. 15.—Distribution and course of the periuterine and periadnexal lymphatics.

It is of clinical importance to note that in the presence of a normal corporeal endometrium, menorrhagia, metrorrhagia, or amenorrhea occurring in the course of chronic endocervicitis, must be interpreted as an abnormal manifestation *functional* in nature, *i.e.*, a perverted menstruation either augmented, protracted, or inhibited.

Every menorrhagia is obviously a periodical metrorrhagia. The same cause may be productive of excessive menstruation, of intermenstrual hemorrhage, or of both; the "menorrhagia" frequently merging into "metrorrhagia," making a clinical distinction between them impossible.

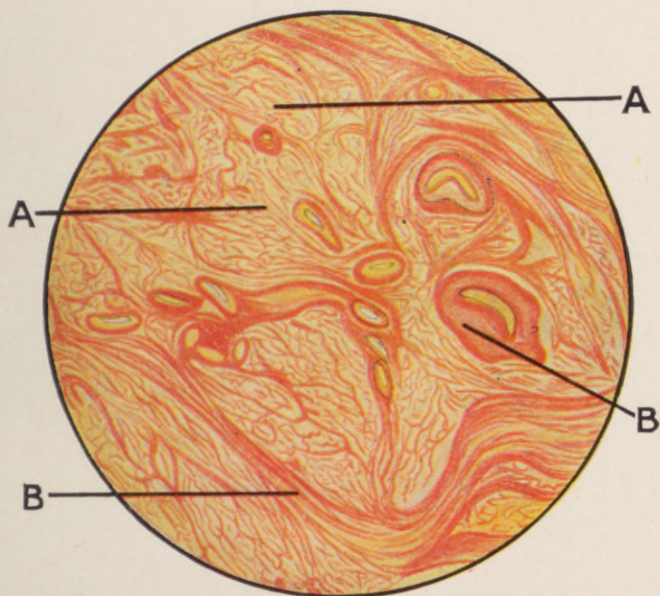
When a bleeding uterus presents a small fibroid, we seek no further for an explanation of the hemorrhage; and yet no one has definitely explained why one uterus harboring a fibrous nodule bleeds excessively, while another bearing enormous masses of a similar nature does not bleed at all.

Still less do we know why there is hemorrhage from some uteri that present no demonstrable evidence of any causative factor whatsoever; and, lastly, we know nothing as to the why and how the uterus bleeds during normal menstruation.

Coagulation is nature's hemostatic. The blood shed from these metrorrhagic uteri, like normal menstrual blood, is *non-coagulable*, and the question naturally presents itself: What induces the normal incoagulability of menstrual blood, and what, if any, is the relation of this incoagulability to the abnormal bleeding under consideration?

The hitherto prevailing theory that attributes the absence of clotting in menstrual blood to the presence of viscid alkaline mucus secreted by the cervical glands is not tenable, for the blood shed from the corporeal endometrium is incoagulable before it reaches the cervical canal. Moreover, no such admixture of alkaline mucus inhibits coagulation in other coagulable fluids of the body.

PLATE III.



Chronic interstitial myometritis—"Fibrosis uteri." From a patient 34 years of age. Chronic endocervicitis. A, Muscle-bundles. B, Fibrous tissue, section made near the peritoneal surface.

Stripped of all intricate laboratory detail, the established premises in the problem are the following:

The general circulating blood during the menstrual period and in the hemorrhagic conditions here considered shows normal coagulative properties.

During menstruation and such uterine hemorrhages the corporeal endometrium receives normally coagulable blood from the general circulation, and sheds this blood in a non-coagulable state.

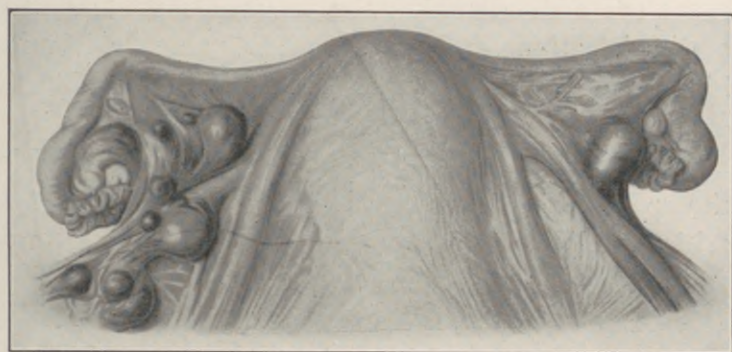


Fig. 16.—Thin periaxial adhesions and phlebectasia in the broad ligament, from chronic myometrial lymphangitis, the result of chronic endocervicitis.

Blood flowing from an experimental puncture or incision of the uterine tissues external to the cervical cavity promptly clots, while the simultaneous menstrual flow from the interior of the uterus fails to coagulate.

The non-coagulability of normal and metrorrhagic menstrual blood discloses an identity in experimental and clinical manifestations, differing only in degree.

Under the given conditions, the corporeal endometrium exercises a function capable of rendering coagulable blood non-coagulable.

This loss of coagulability in menstrual blood is *not* due to the *absence* of any element essential to coagulation, but to the *presence* of an *inhibiting substance* secreted by the corporeal endometrium, from which it may be expressed during the menstrual state.

The endometrium is apparently activated to the secretion of this inhibiting substance by a hormone generated in the ovary.

The evidence of these established phenomena warrants the deduction that the biochemic process thus outlined, pathologically augmented, protracted or inhibited, constitutes an essential link between chronic endocervicitis and its menstrual aberrations.

In the progressive cases of chronic endocervicitis, the ascending myometrial lymphangitis (myometritis) inhibits uterine contractions. The blood-current in the valveless uterine veins, thus deprived of its essential *vis a tergo*, is slowed. The resultant circulatory stasis augments the menstrual flow in the non-pregnant (menorrhagia).

The thickened ovarian tunica albuginea (perioöphoritis) may impede the maturation and rupture of a graafian follicle, with consequent inhibition of menstruation (amenorrhea), or, retarding follicular contraction and involution, protract the menstrual flow (metrorrhagia).

The myometrial sensory nerve filaments penetrate the muscle sheaths; hence the normal uterine contractions, intensified during menstruation, compressing the infiltrated perimyoeal areas, become painful (dysmenorrhea).

It is a marked characteristic of the dysmenor-

rhea resulting from endocervicitis that it subsides after the inauguration of a full flow.

Agglutination and occlusion of the tubal ostia (perisalpingitis) creates a barrier to subsequent fecundity ("one-child sterility"), while the associated *nutritional* derangements induced in the corporeal endometrium disturb or inhibit its specific decidual function, with premature blight of an existing gravidity ("habitual abortion").

The direct spermatocidal effect of a diseased cervical mucosa is vividly depicted by Reynolds, who, utilizing Hühner's postcoital method for the observation of spermatozoa aspirated from the cervical cavity, states: "It is extremely interesting to see how actively mobile spermatozoa progress across the field of the microscope in a cervical secretion of grossly normal appearance, until they come in contact with some clumps of pus-cells, with which the tail of the spermatozoön becomes entangled. The result then is, that it indulges in futile struggles to escape, by the violence of which it becomes exhausted, and in a few minutes gives up the struggle and lies still."

The sterility of women with "conical cervix", "cervical flexion", or "pin-hole os" is *never* due to the cervical malformation as such, but to an existing endocervicitis.

An os that offers sufficient egress for millions of blood-cells during every menstruation will readily afford ingress to a spermatozoön whose diameter measures less than that of a single red corpuscle. We constantly encounter fecundity in cases of "pin-hole os", and sterility in widely gaping lacerated cervices, when the latter are infected.

The cervical mucosa was characterized in the foregoing as the uterine tonsil; this pathogenic parallel finds its applicability when chronic endocervicitis is recognized as a primary infectious focus, and its systemic symptoms as toxic manifestations. The ambiguous category of the "reflex neurosis" accompanying cervical disease is thus brought within the more lucid range of the toxicoses along modern lines of clinical research.

We have learned to recognize systemic manifestations from primary foci in the mouth, the gall-bladder, the appendix, the urethra, etc. Why not from the cavity of the cervix? Why term a symptom toxic there, and neurotic here? Who can continue to believe that "clavus uterinus" is due to "pinching of 'nerve terminals' by cicatrices in the angle of a cervical tear"?

Without extending this detailed analysis beyond the cardinal manifestations enumerated, it would appear sufficiently evident that the whole symptomatology, the complications and sequela of chronic endocervicitis, may be readily predicated from its pathological course as outlined above.

CHAPTER VI.

ETIOLOGY OF ENDOCERVICITIS.

INFECTION of the cervix frequently dates back to a vulvitis in early infancy. This significant fact illuminates many of the gynecological disturbances in virgins.

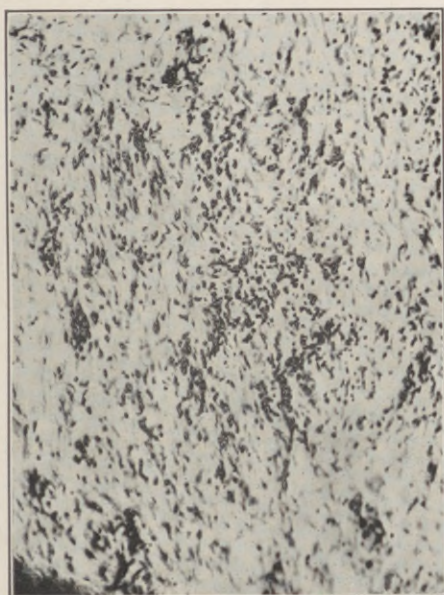


Fig. 17.—Infantile endocervicitis—"Vulvovaginitis." Round-cell infiltration of the intramuscular connective tissue from a case of gonorrheal vaginitis.

Hess reports the *post-mortem* findings in four infants that had the usual non-virulent form of "vaginosis" during periods ranging from "three weeks to one year or more, in all of which the only abnormal

condition and sole lesion was an inflammation of the cervix, with round-cell infiltration of its submucous tissue." On the basis of these findings Hess con-

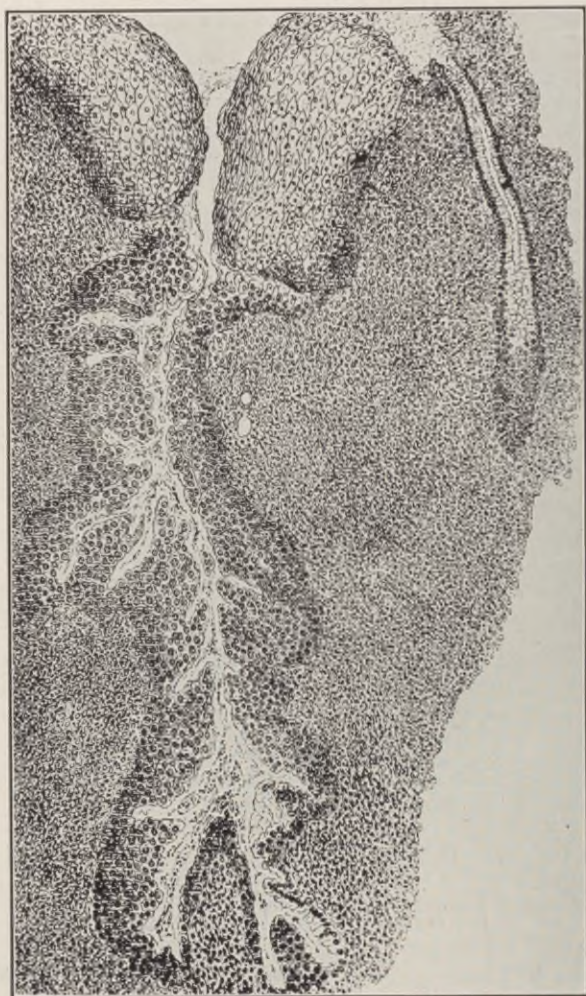

Fig. 18.—Chronic endocervicitis. Section from a cervix after repeated cauterizations. Benign proliferation of the epithelium in the gland lumen, with epidermization of the surface. (*Abel.*)

cludes that "we must regard the average gonococcus infection as involving the cervix rather than the

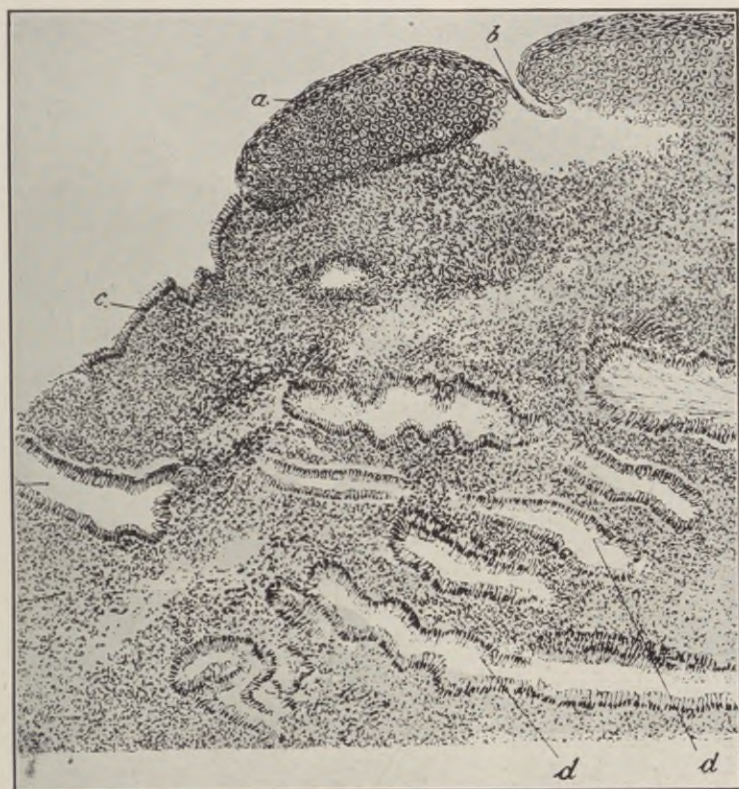

Fig. 19.—Chronic endocervicitis. Section of a so-called "erosion" of the cervix, showing transition from columnar to squamous epithelium. *a*, Squamous epithelium broken at *b* by vulsellum. *c*, Columnar epithelium proliferating over the area normally covered by squamous epithelium. *d*, Glandular depressions extending under the proliferating squamous epithelium. *e*, Stroma infiltrated with round cells. (*Abel*.)

vagina, and must consider the infection a cervicitis rather than a vaginitis."

In adult females, Menge estimates that 95 per

cent. of chronic gonorrhœal infections are located within the cervix.

While the gonococcus is by far the most frequent provocative organism in chronic endocervicitis, streptococcic, staphylococcic, and colon bacillus infections are not at all infrequent findings in the order enumerated.

In infants, the exanthemata—and especially scarlet fever, protracted diarrheas, with probable contamination from soiled diapers, and general debilitating conditions—seem to confer a special susceptibility to cervical infections; while in adults, congenital maldevelopment of the cervix—and more especially when traumatized by cauterizations, dilations, curettage or birth injuries—embodies the

Description of Plate IV.

A, obj. 3, oc. 3, tub. 20. Hæmalaun. Diagnostic excision. An area at some distance from the erosion showing an extension of the round-celled infiltration under the squamous epithelium and a death of the basal layer of cells.

B, obj. 3, oc. 1, tub. 20. Hæmalaun. Uterus removed because of retroflexion with adnex-tumors and adhesions. This patient had a purulent vaginal discharge. Eversion was present, and there was an "erosio-glandularis," with marked round-celled infiltration around the glands. The area shown is at some distance from the erosion and shows what might be interpreted as a beginning erosion, caused by the inflammation and round-celled infiltration excited by an infected gland.

C, obj. I, oc. 4, tub. 15. Hæmalaun. Showing two communications of a gland with the surface. Round-celled infiltration, though slight, is present around the openings of the glands. At one of the orifices there is apparently a destruction of the basal squamous cells.

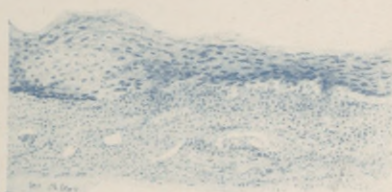
D, obj. DD, oc. 3, tub. 0. Hæmalaun. Drawing from an "erosio-glandularis" which is healing. The basal cells are shown exposed as a form of columnar epithelium. This same preparation showed true cylindrical epithelium on the surface.

E, obj. 3, oc. 1, tub. 15. Hæmalaun and mucicarmine. Nullipara. Myomatous uterus. Shows the squamous epithelium growing under the cervical epithelium, which shows the characteristic staining with mucicarmine.

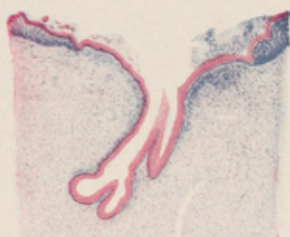F, obj. I, oc. 4, tub. 16. Hæmalaun and mucicarmine. Glandular cells show the characteristic staining reaction for mucin. The squamous epithelium has grown into the openings of the glands underneath their epithelium.

G, obj. I, oc. 4, tub. 18. Hæmalaun. Diagnostic excision. Squamous epithelial plug connected with the surface. Near it is seen a small cyst lined with low cylindrical epithelium. (*Adair.*)

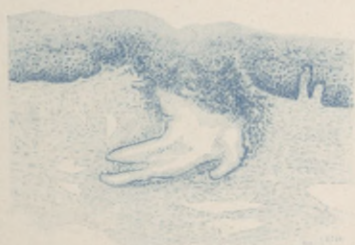PLATE IV.



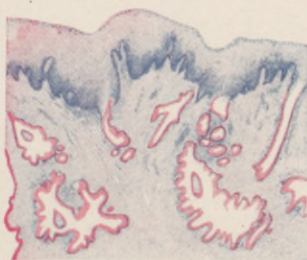
A



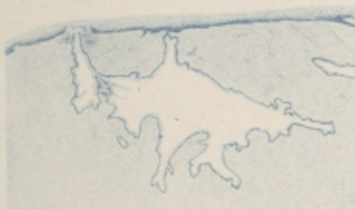E



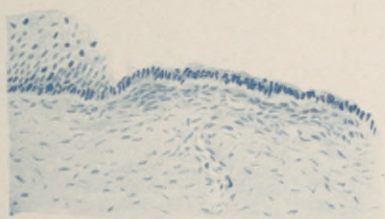
B



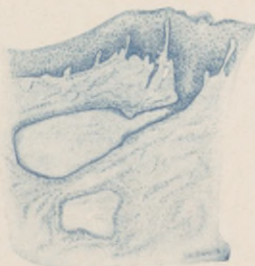F



C



D



G

Histopathology of "cervical erosion."

most prolific predisposing factor to chronic endocervical disease.

The objective features of chronic endocervicitis are typical, and plainly evident on inspection. The nullipara complaining of dysmenorrhea and sterility, with her conical cervix showing its inflammatory halo encircling a small pouting os extruding a ten-

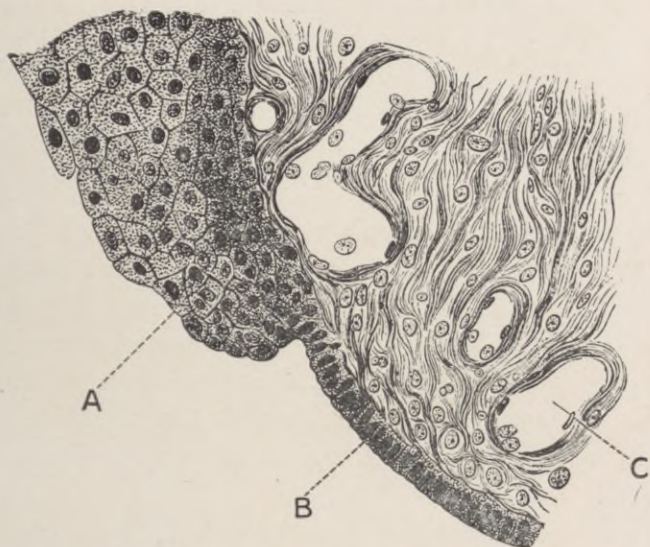


Fig. 20.—“Infantile erosion”—Chronic endocervicitis. Sharp demarcation between proliferating squamous epithelium and columnar cells. A, Squamous epithelium. B, Columnar cells. C, Blood-vessels. (*Chrobak and Rosthorn.*)

acious clump of mucus; or the multipara, with lacerated, eroded hypertrophied lips, honeycombed with nabothian cysts under a granular surface that bleeds on the slightest touch—all of these, in their varying degrees of intensity, constitute a clinical picture so familiar as to call for no detailed delineation.

CHAPTER VII.

TREATMENT OF CHRONIC ENDOCERVICITIS.

THE inadequacy of prevailing therapeutic measures in the treatment of chronic endocervicitis offers the most convincing evidence of misleading fundamental concepts. Who, among the most experienced, does not realize his inability to cure permanently the ordinary leucorrhœa of cervical disease?

Chronic endocervicitis is primarily and essentially an infection of the deeply situated terminal tufts of the endocervical muciparous glands. These glandular saccules harbor the infecting organisms for years or a lifetime. Their distention from duct occlusions may honeycomb the cervical tissues with so-called nabothian cysts, or, becoming purulent, riddle the cervix with chronic miliary abscesses, as shown in Fig. 23.

It is an axiomatic surgical principle, in the control of any infectious process, to direct the therapeutic aim at the primary focus of infection. In general and specialistic practice, the escharotic, the dilator and the curette still hold sway as established routine measures, especially for the chronic endocervicitis in the nulliparous.

Mild escharotics and discriminate dilatation, by promoting drainage, may prove of some benefit in very superficial infections, but *curettage cannot be too emphatically condemned in any case.* The curette does not and cannot reach the deeply situated infected

racemose tufts of the muciparous glands in the cervical tissues. Moreover, it should not injure the utricular tubules of the corporeal endometrium, which is rarely if ever involved in the disease, and whose specific functions in menstruation and gestation have been permanently vitiated by the laceration and inoculation incidental to this time-honored traumatism.

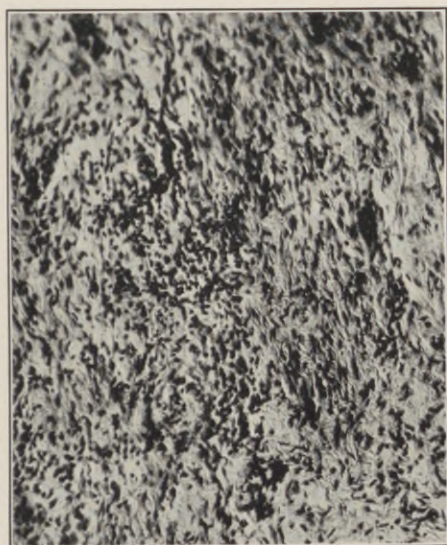


Fig. 21.—Chronic endocervicitis. Dense round-cell infiltrations in the subepithelial layers and muscular stroma of the cervix.

The corporeal endometrium is a highly specialized tissue, to be assiduously conserved, and not to be harrowed and scraped with impunity. The cases of positive corporeal endometritis will be found among uteri that have been cauterized or scraped from one to several times.

In the parous cervixes with infected lacerations, the symptoms emanate from the infection, and not

from the rent in the cervix. Nevertheless, surgeons usually take cognizance of the rent and ignore the infection, with the resulting proportion of ultimate failures tabulated in Leonard's statistics quoted above.

Similar failures have prompted many surgeons to desist from all tracheloplastic attempts during the

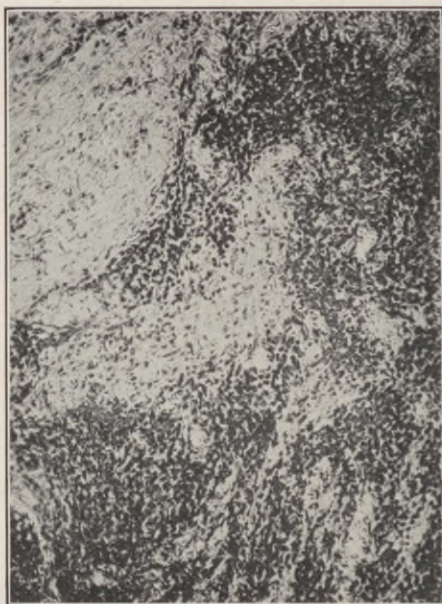

Fig. 22.—Chronic endocervicitis. Dense round-cell infiltration in the subepithelial layers and muscular stroma of the cervix.

child-bearing period, preferring to shut their eyes to the existing condition rather than incur failure to cure, or possible aggravation, by standardized procedures of questioned efficacy.

To cure chronic endocervicitis, we must remove the entire infected area of the endocervical mucosa; as long as endocervicitis persists, so long will its symptoms persist.

The operation of trachelorrhaphy was originally evolved from the misconception that the local and general manifestations following laceration of the cervix are due solely to gaping flaps, with cicatricial dis-

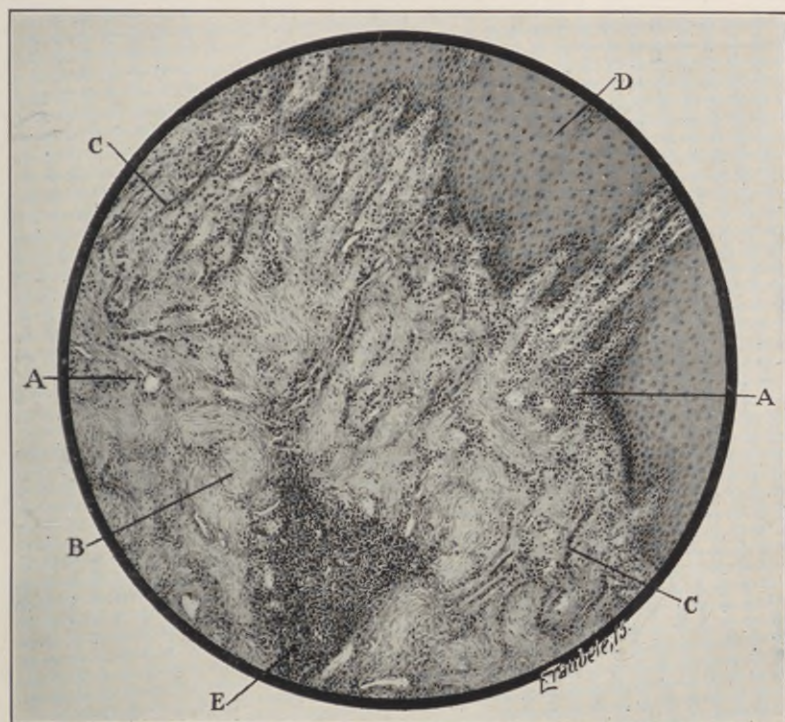


Fig. 23.—Chronic endocervicitis, with miliary abscesses. Section through cervix; subepithelial inflammatory foci; hyperplastic lymph-vessels, with streaks of round-cell infiltration and small inflammatory foci in the cervical musculature. A, Blood-vessel. B, Muscle-bundle. C, Lymph-vessel. D, Squamous epithelium. E, Miliary abscess.

tortion, and that a cure of the condition demanded nothing more than excision of the cicatrix, and sutural closure of the gap. In other words, the operator

aimed to reproduce the original area of laceration and reunite its edges.

It is obvious that *the curative scope of this procedure is necessarily limited to the cases in which the infection has not extended beyond the lines of the*

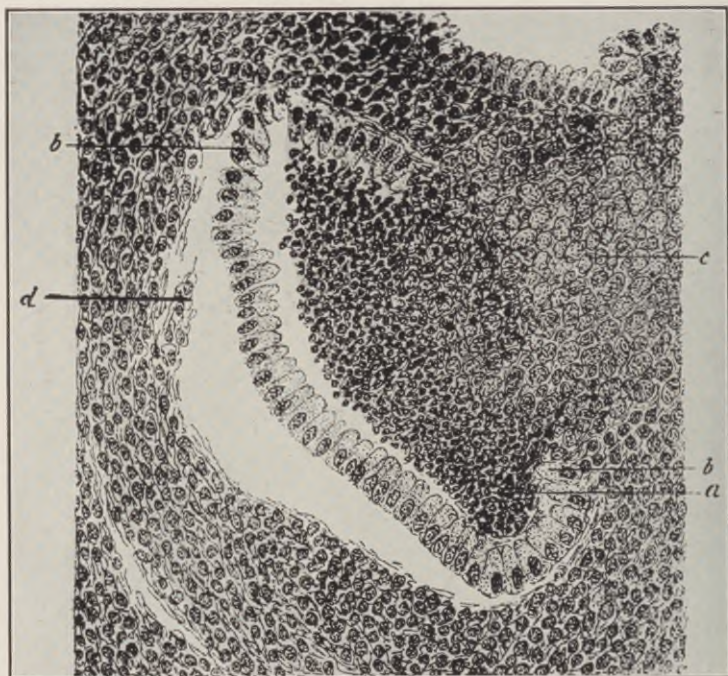


Fig. 24.—Cancerous endocervical gland. *a*, Dark globular cell infiltrate. *b*, Normal columnar epithelium separated from its base at *d*. *c*, Carcinoma involving the right wall of gland. (*Abel*.)

original tear—a rare condition, for we know to-day that the functional disturbances following lesions, which demand surgical intervention—that is, the infected tears—signalize the infectious invasion of the

entire length and breadth of the cervical mucosa, from external to internal os, and that the conservation of the *invaded area* within the cervical canal *beyond the lacerated edges* perpetuates the whole pathological process.

If this is true of single tears, it applies with proportionately greater force to multiple tears. But

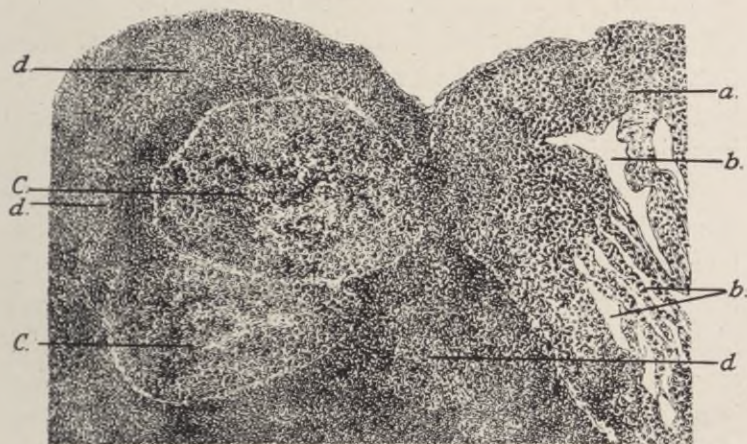


Fig. 25.—Carcinoma of the cervix. Primary stage. *a*, Squamous epithelium. *b*, Artefacts. *C*, Cancer nodules. *d*, Cancer pearls. (Abel.)

whether we accept or reject the foregoing considerations as valid factors in limiting the scope of secondary trachelorrhaphy as a curative measure, a more sinister menace obtrudes itself into this question to-day, namely, the enhanced cancerous potentialities in the chronically inflamed cervical areas beyond the range of the Emmet operation.

A recent publication by Ewing, on precancerous diseases, affirms that "chronic catarrhal endocervicitis precedes cancer in the great majority of cases

. . . and the cervical erosion is the most definitely established lesion known to initiate cervical carcinoma." Polese demonstrated this in 34 out of 48 cases. Beckman carefully observed the development of carcinoma in an erosion which he treated for five years.

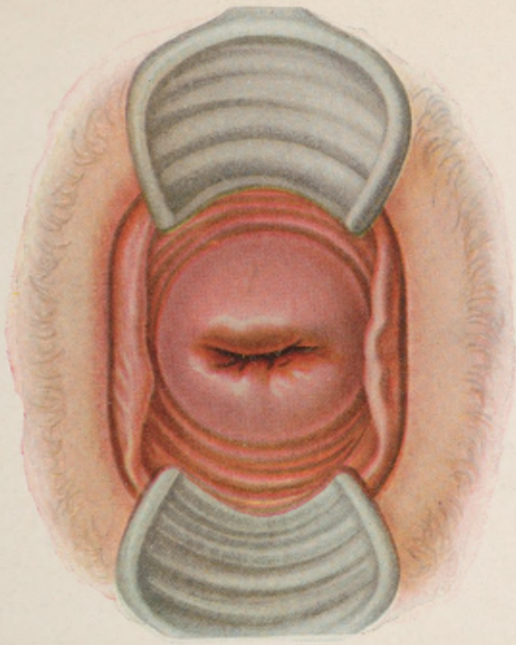
Early stages of carcinoma from such lesions are described by Waldeyer, Ruge, and Veit, by Cullen, Schauenstein, Sitzenfrey, and others. Ewing studied three instances of precancerous polyp in eroded cervixes showing metaplastic overgrowth and beginning invasion of the stroma by adenocarcinoma.

Aside from these clinical considerations, many gynecologists have for a long time discarded trachelorrhaphy in the majority of their cases on purely technical grounds. Thus, Noble declares that "in cervical lacerations of long standing, with marked hypertrophy and nabothian cystic degeneration, amputation is to be preferred, as the conditions left by trachelorrhaphy are far from satisfactory, and, furthermore, that all cervixes deficient in bulk from underdevelopment, irregular multiple tears, or previous sloughing present insufficient tissue for normal reconstruction by trachelorrhaphy."

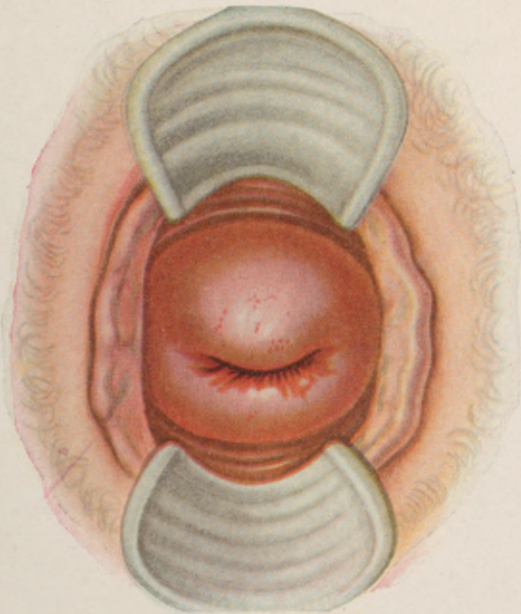
The foregoing arraignment of this procedure, on physiological, pathological, clinical, and technical grounds, forces the conviction that late trachelorrhaphy, whenever indicated, must prove inefficacious as a curative measure, and when apparently curative was probably superfluous.

With the cervical lesion as the established portal of infection, simple trachelorrhaphy should find its cardinal and practically its only sphere early in the

PLATE V.

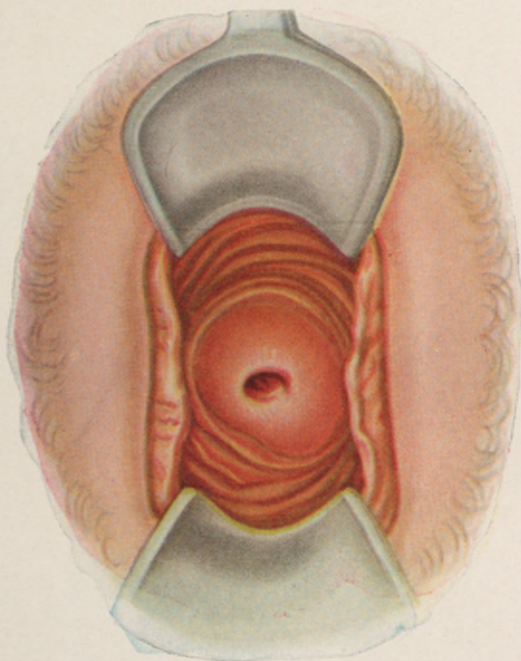


Healed non-infected bilateral laceration.



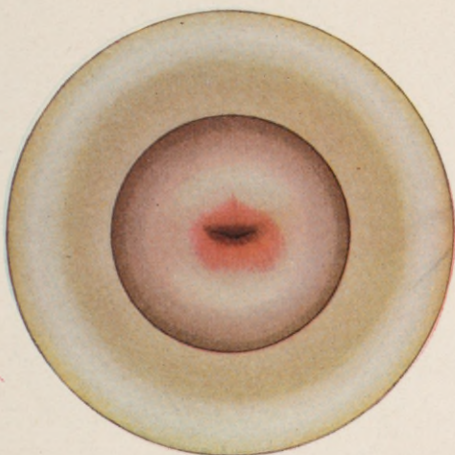
Mild endocervicitis. Bilateral laceration.

PLATE VI.

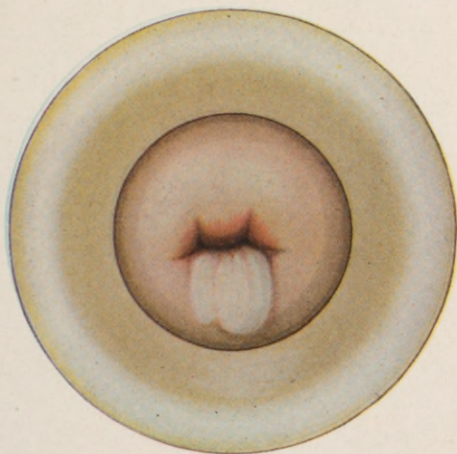


Virginal chronic endocervicitis. Conical cervix.

PLATE VII.

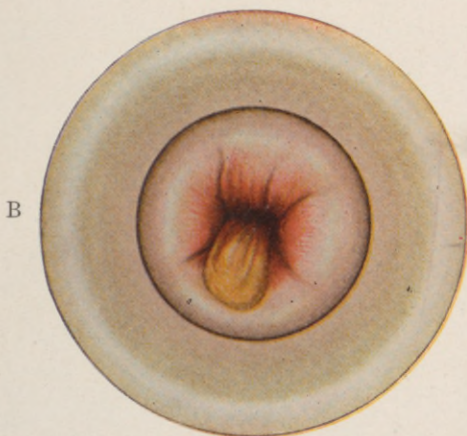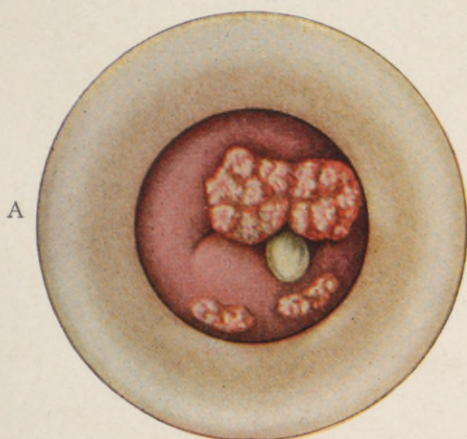


Virginal chronic endocervicitis with "erosion."



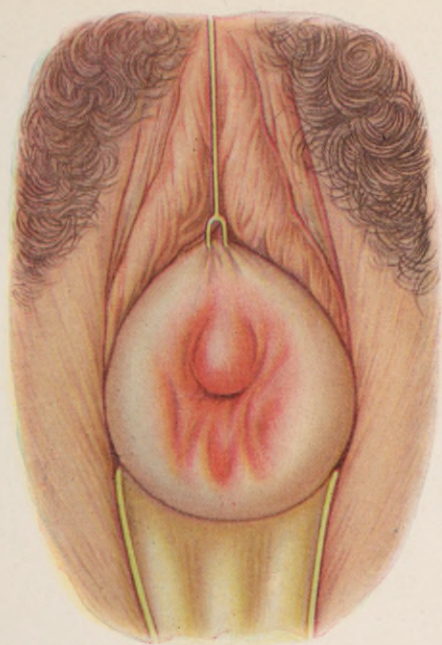
Chronic endocervicitis, with mild manifestation at the external os (leucorrhoea).

PLATE VIII.

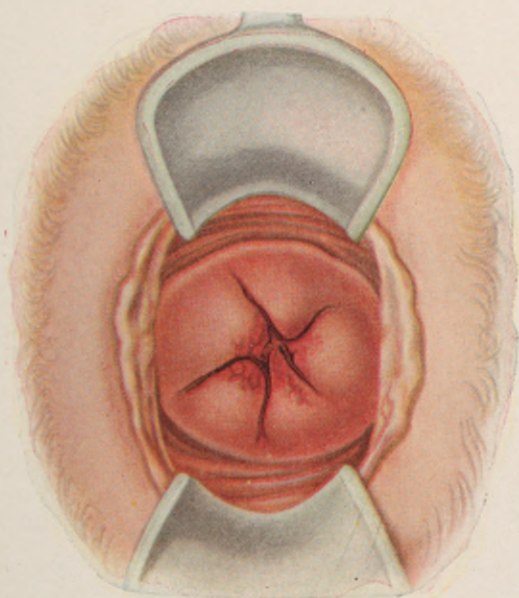


A, Gonorrheal condylomata. B, Gonorrheal endocervicitis.

PLATE IX.

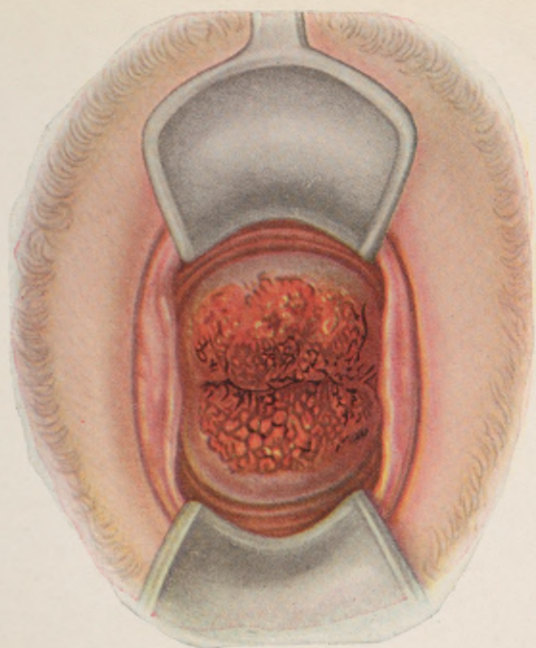


Chronic senile endocervicitis. Infected bilateral laceration, with extreme relaxation—"eversion"—of the cervical wall.

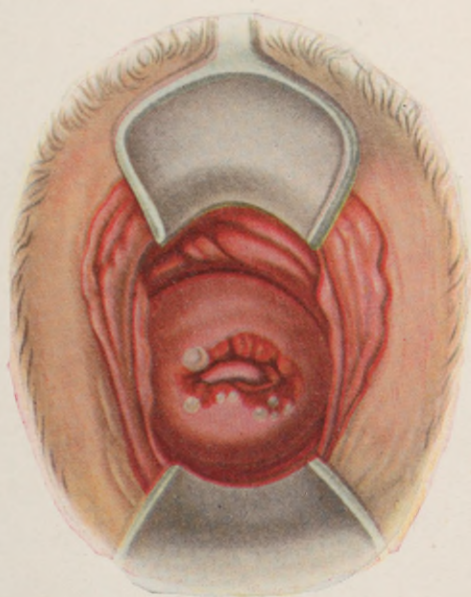


Chronic endocervicitis. Mildly infected. Stellate laceration.

PLATE X.

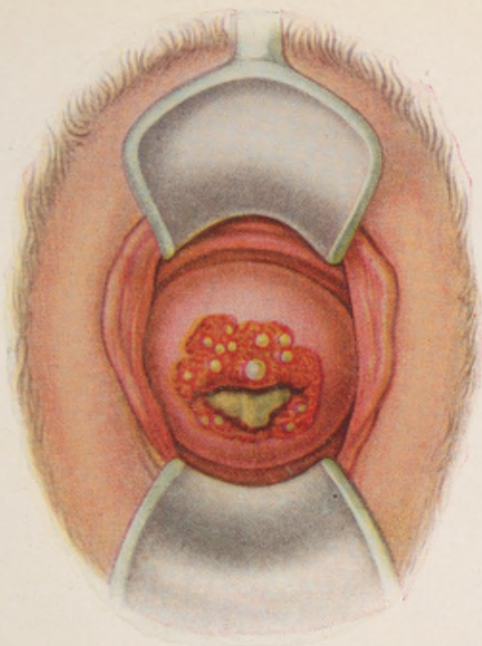


Chronic endocervicitis. Infected laceration—
eversion—"Papillary erosion."

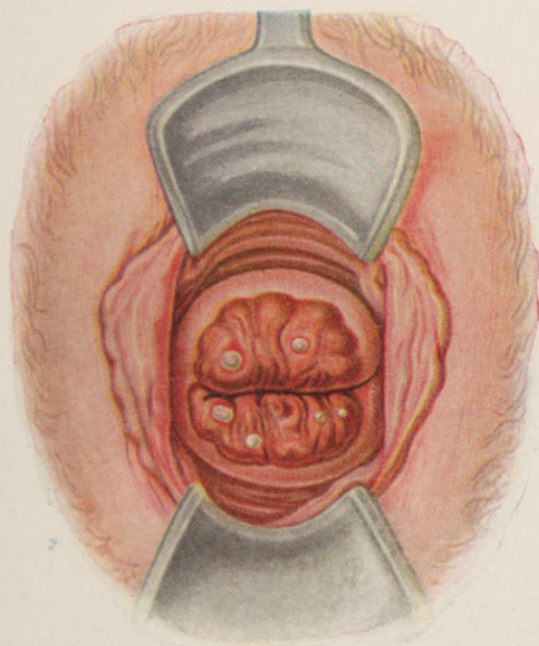


Chronic endocervicitis. Infected laceration, with
"ulceration and nabothian folliculitis."

PLATE XI.

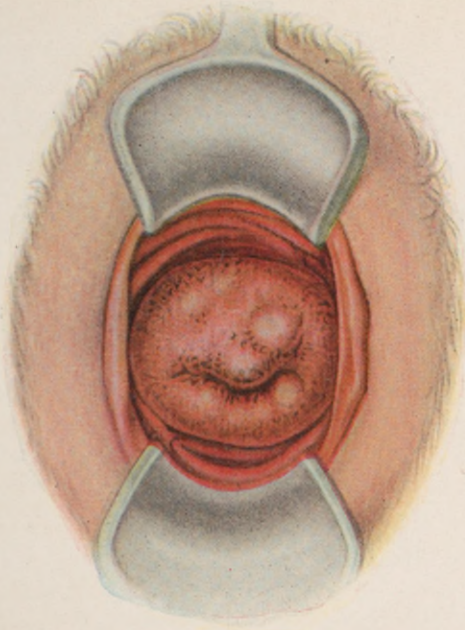


Chronic endocervicitis. Infected laceration with "ulceration and suppurative nabothian folliculitis."

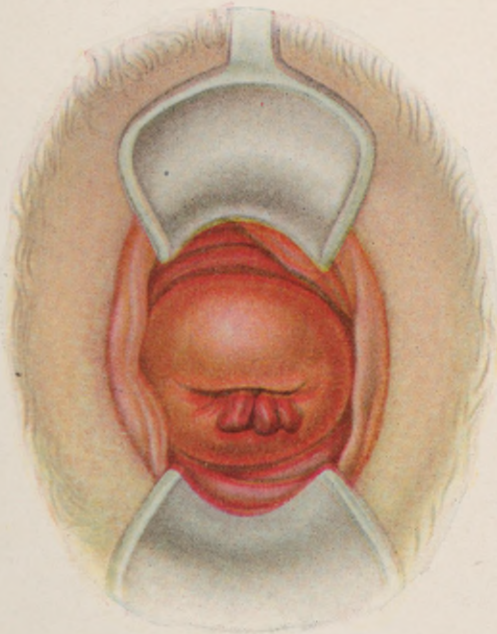


Chronic endocervicitis. Infected laceration. "Ectropium with follicular suppuration."

PLATE XII.

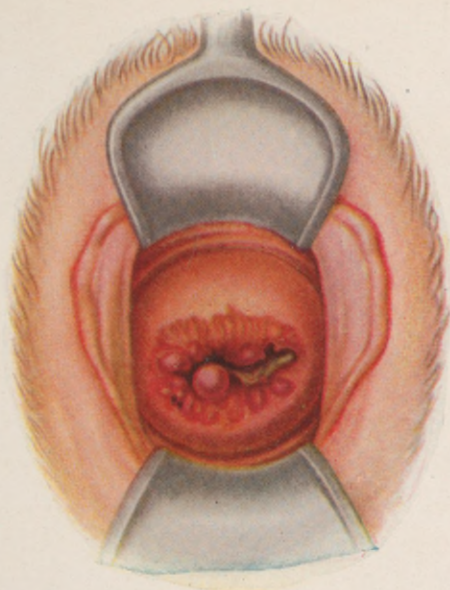


Chronic endocervicitis. Infected laceration, with "granular erosion" and nabothian folliculitis.

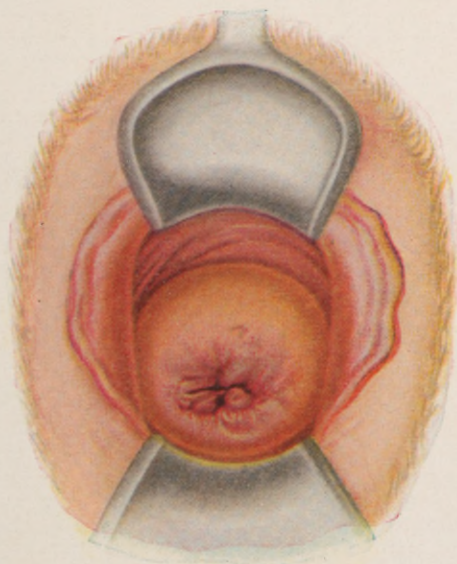


Chronic endocervicitis, with mucous polypi.

PLATE XIII.

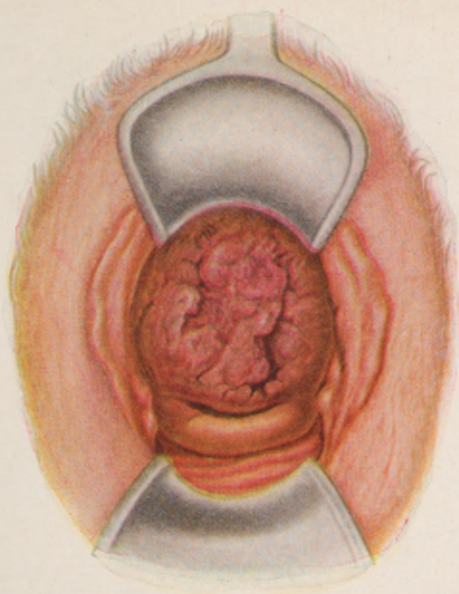


Chronic endocervicitis, with carcinomatous papilloma.

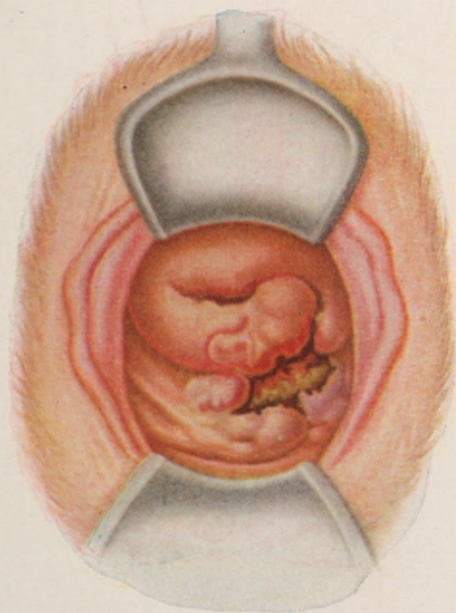


Endocervical carcinoma in the initial stage

PLATE XIV.

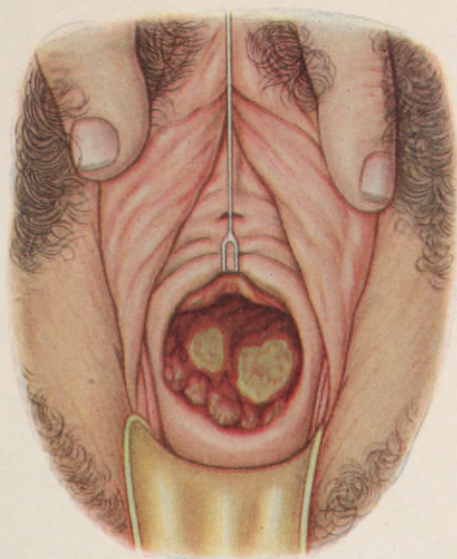


Chronic endocervicitis, with carcinomatous ulceration.

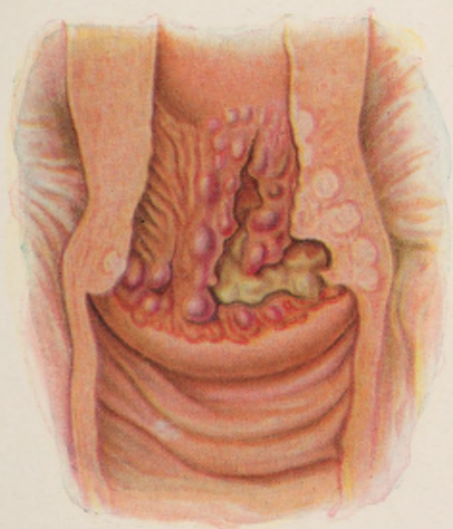


Carcinoma of cervix, with sloughing into the posterior vaginal vault.

PLATE XV.



Carcinoma of cervix, with endocervical necrosis.



Endocervical carcinoma in section, showing its tendency to progress along the uterine musculature, rather than by way of the corporeal endometrium.

puerperium, when "immediate," or, still better, the "intermediate" operation represents an effort of the highest prophylactic potency.

In thus restricting the applicability of trachelorrhaphy to the puerperium, we necessarily augment the

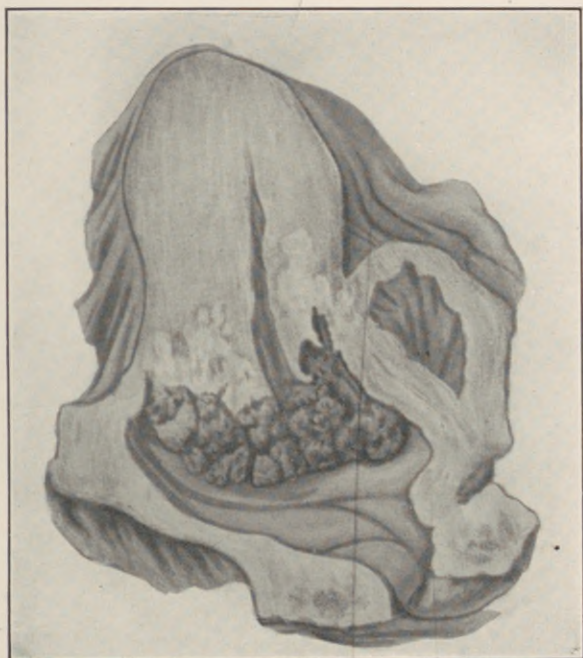


Fig. 26.—Advancing carcinoma of cervix. Note involvement of the uterine musculature.

range of cervix amputation as the reparative method of choice for all chronic cervical lesions; and it now remains to elucidate and obviate as far as possible those derangements noted after this more radical operation.

In the light of the normal and pathological fundamentals at hand, both cause and prevention of these

postoperative disturbances are revealed as inherent in the technique of the prevailing methods of cervix amputation.

A low amputation of the cervix is a partial amputation, and can only eliminate a part of its diseased

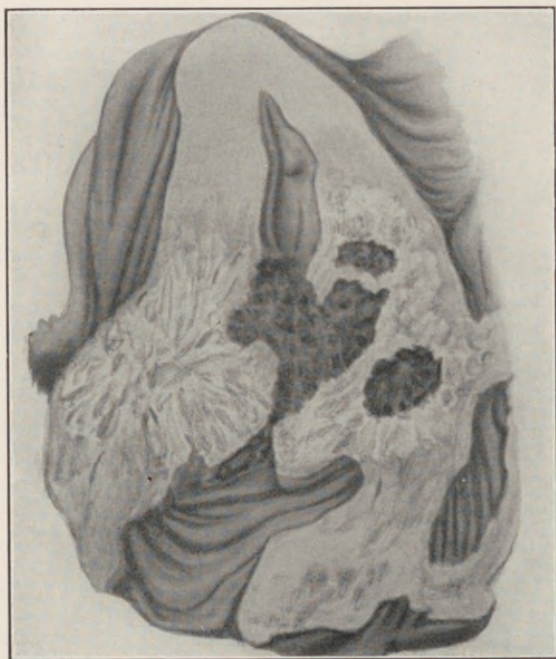
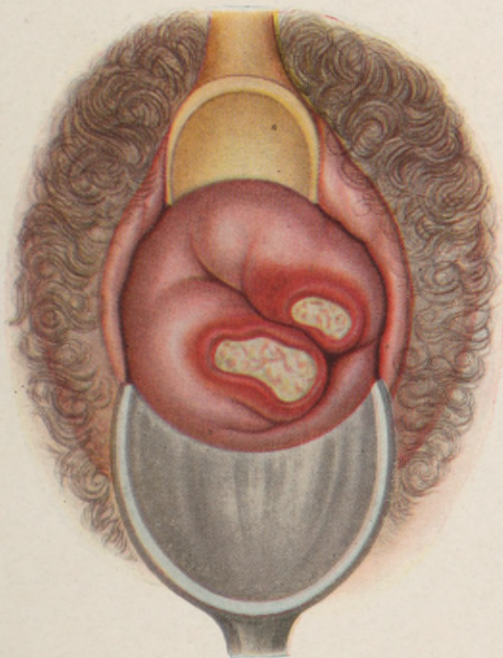

Fig. 27.—Advanced carcinoma.

mucosa, while a complete or high amputation is an unwarrantable mutilation of its muscular mechanism.

When a cervix tears during labor, the rent extends practically in the direction of its muscle-fibres. On the other hand, when the cervix is amputated in the usual manner, the muscle-fibres are severed transversely. The spontaneous tear, unless infected, exercises but

PLATE XVI.



Syphilitic ulcer in angle of laceration.

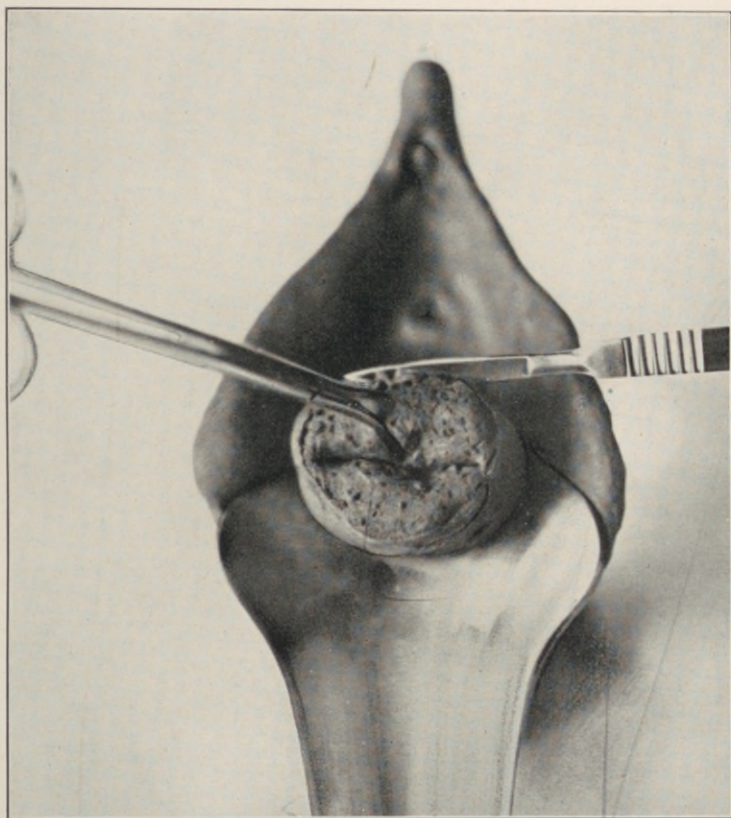


Fig. 28.—Tracheloplasty (author's method). Outlining the edge of the flap on the vaginal sheath of the cervix along the demarcating line between the normal vaginal and diseased endocervical mucosa in a case of infected bilateral laceration.

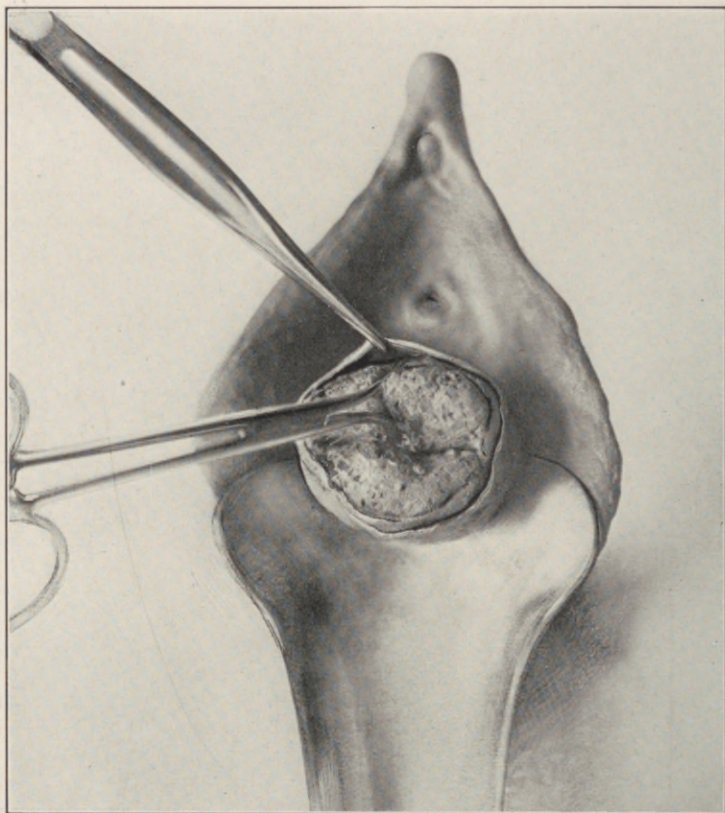
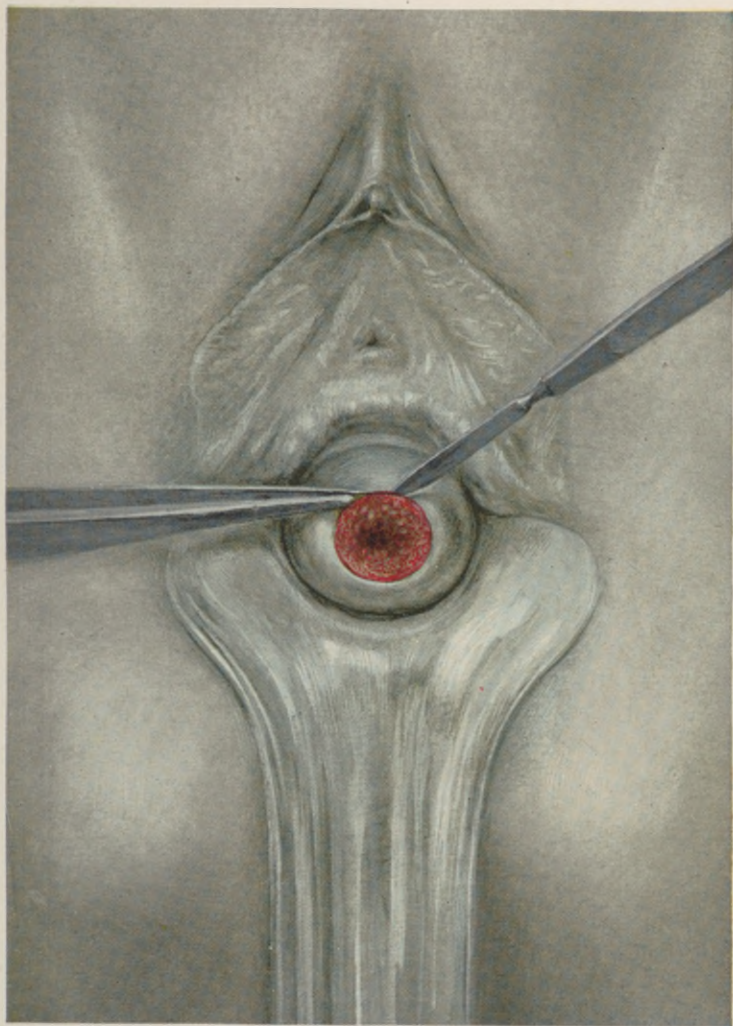


Fig. 29.—Tracheloplasty (author's method). Elevating the flap edge preparatory to its free mobilization by blunt dissection from the subjacent musculature.

PLATE XVII.



Tracheloplasty (author's method). Outlining the edge of the flap of the vaginal sheath of the cervix along the demarcating line between the normal vaginal and the diseased endocervical mucosa in a case of nulliparous chronic endocervicitis.

little influence upon the muscular mechanism of the cervix, while the transverse ablation destroys it completely.

Circular amputation of the cervix, and union of its vaginal and endometrial mucosa, according to standard methods, defeats its own purpose by disregarding the physiological and textural characters of the cervical tissues.

According to an established law in myodynamics—"the extent of contractile shortening in a given muscle depends upon the arrangement and number of its contractile units"—the longer the muscle, the greater the number of its contractile units. Consequently, a long muscle-bundle will contract through a proportionately wider interval than a similarly arranged short one.

In the uterus the peripheral fibres traversing the greater circumferential area are necessarily much longer than the central fibres that entwine the uterine cavity. It follows, therefore, that on ablating the cervix in the usual manner, all the muscle stumps are made to terminate at the same level. The longer peripheral fibres, contracting to a higher plane than the shorter central fibres, tend to pull the vaginal and endometrial margins of the stump asunder. Furthermore, the extreme friability of the endometrial edge renders its sutural retention purely transitory, so that sooner or later the flaps separate and expose a raw beveled cervical stump.

These exposed stump surfaces heal by granulation. Some never heal completely; but when they do, and the patient comes to child-birth, the annular cicatrix, incapable of physiologic retractile expansion, presents

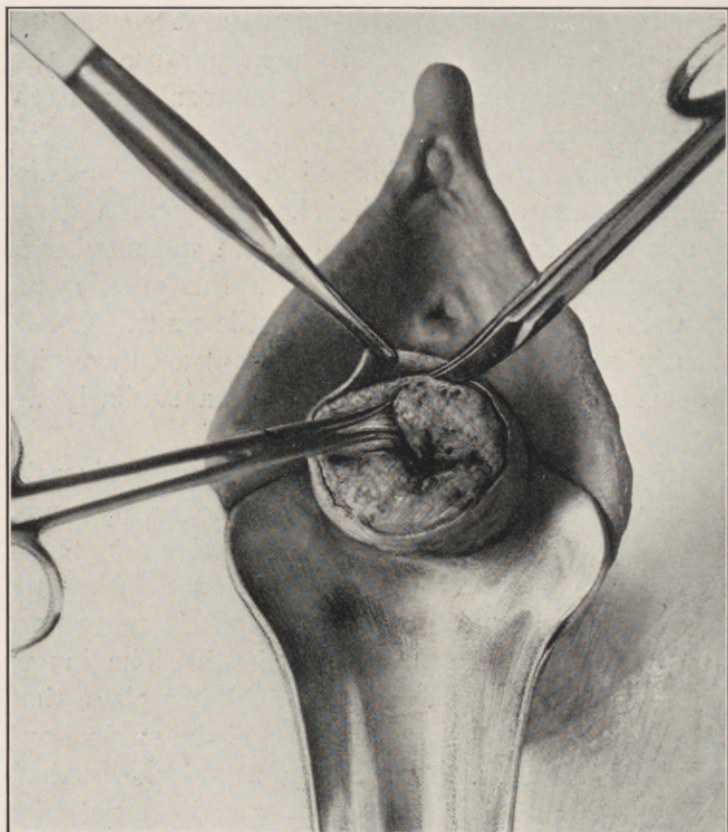


Fig. 30.—Tracheloplasty (author's method). Mobilization of the cylindrical vaginal flap to the vaginal fornices.

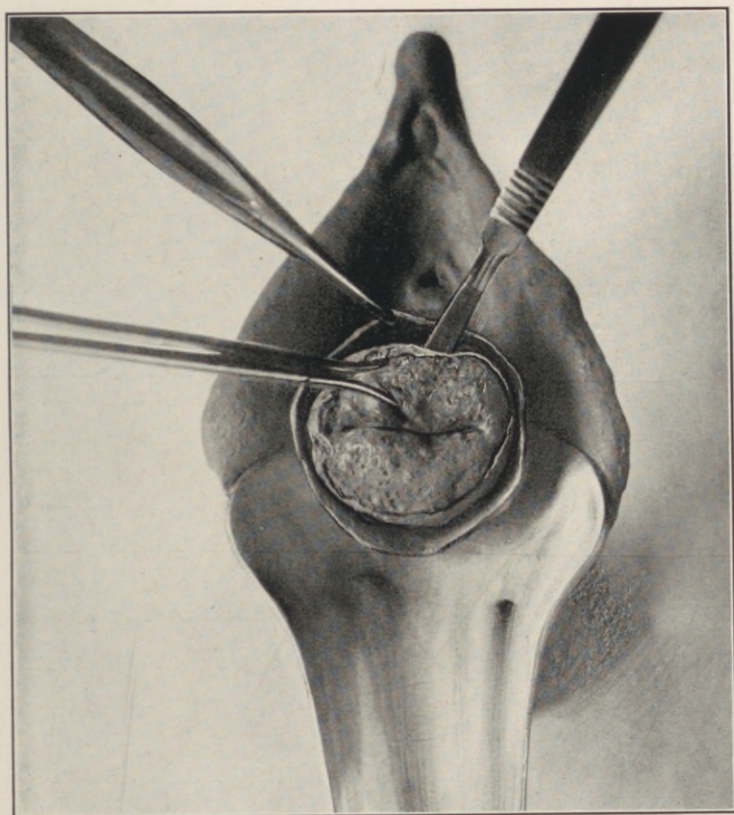


Fig. 31.—Tracheloplasty (author's method). Excision of endocervical cone, the knife directed towards the internal os.

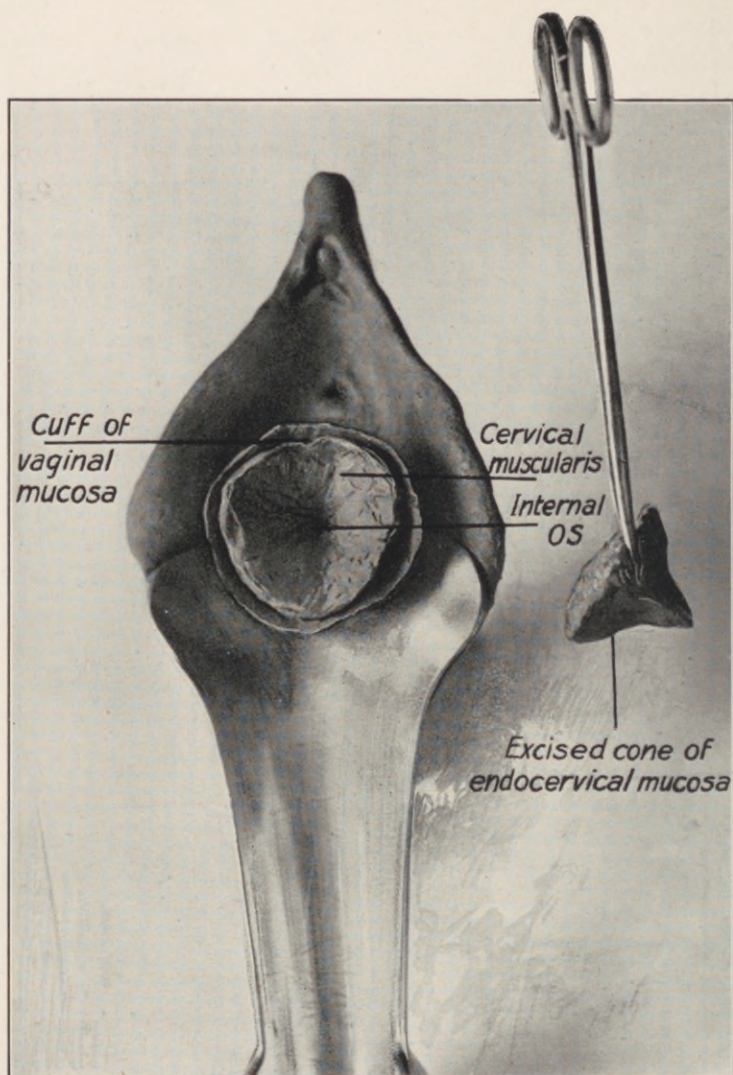


Fig. 32.—Tracheloplasty (author's method). Denuded funnel of cervical muscularis, excised cone of endocervical mucosa, and loose cylindrical flap of vaginal mucosa.

the dystocia noted in Leonard's tedious deliveries. The cases that do not heal present a raw area, which, becoming infected, practically re-establishes the original lesion, with the whole train of objective and subjective disturbances that first prompted our surgical intervention.

Realizing some of these operative shortcomings, Karl Schroeder excised the cervical mucosa separately from the anterior and posterior lip as a transverse wedge. Then he folded each lip upon itself, and sutured its vaginal margin at or near the internal os, while the redundant lateral edges were sutured to each other. Commenting on this modification, Noble states: "Schroeder's operation accomplishes the purpose of removing the glandular portion of the cervix, but it is difficult of performance, and yields inferior results."

Howard Kelly removes a wedge of tissue from each lateral angle after amputating, aiming to produce "a wide, smooth os." The method is comparable to the cupping of the cervix after supravaginal hysterectomy. The ultimate outcome of this method, as already quoted in our introductory statistics, was declared by Leonard as "quite unexpected, and in many ways disappointing."

The difficulty in all the prevailing methods of cervix amputation is encountered when suture of the vaginal to the endometrial edge is attempted, the extreme friability and inaccessibility of the latter frequently rendering accurate approximation and permanent retention quite impossible.

Briefly stated, the cure of a chronic endocervicitis, whether in the nulliparous or multiparous cervix, demands:

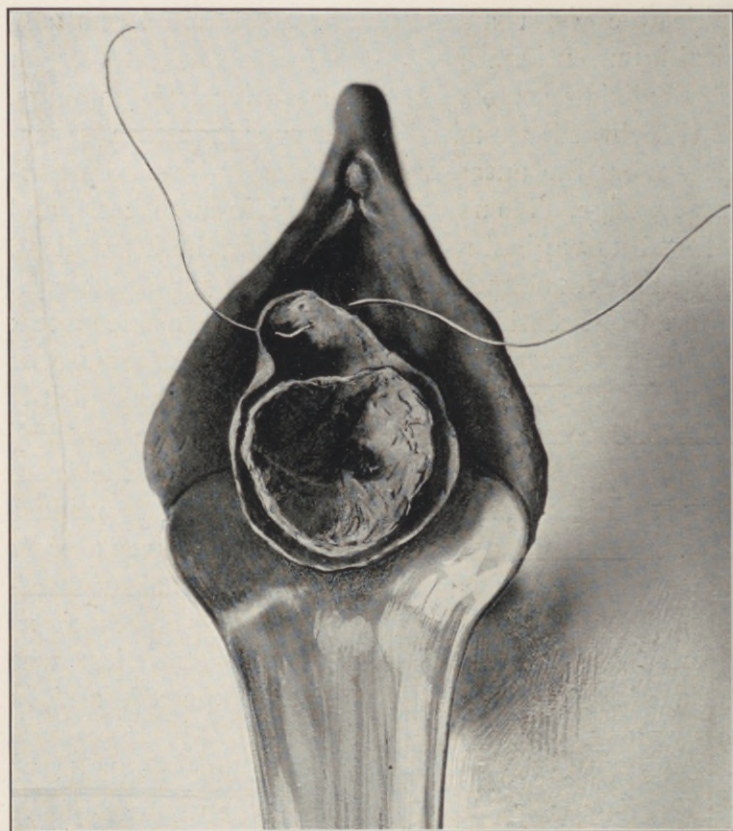


Fig. 33.—Tracheloplasty (author's method). Silkworm strand passed transversely through the vaginal surface of the anterior flap segment, $\frac{1}{8}$ of an inch from the edge, embracing $\frac{1}{8}$ of an inch of tissue.

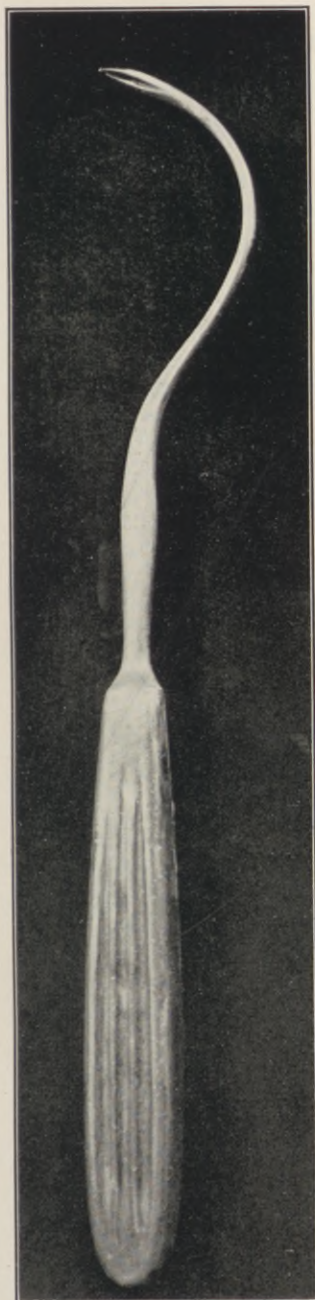


Fig. 34.—Peaslee needle, modified by a double bend, to facilitate the introduction of the silkworm sutures through the denuded cervical musculature to the base of the vaginal cuff.

(1) Complete enucleation of the entire endocervical mucosa, from external to internal os, with preservation of its muscular structure.

(2) Accurate re-lining of the denuded cervical canal by a cylindrical cuff of its vaginal sheath.

The following method fulfills the physiological demands, meets the pathological indications, and obviates the technical shortcomings enumerated. The procedure is applicable to infected nulliparous or multiparous cervixes alike, and comprises:

(1) Outlining and free liberation of an ample cuff of mucosa from the vaginal sheath of the cervix.

(2) Enucleation of the entire endocervical mucosa to the internal os, with preservation of its surrounding muscular layer.

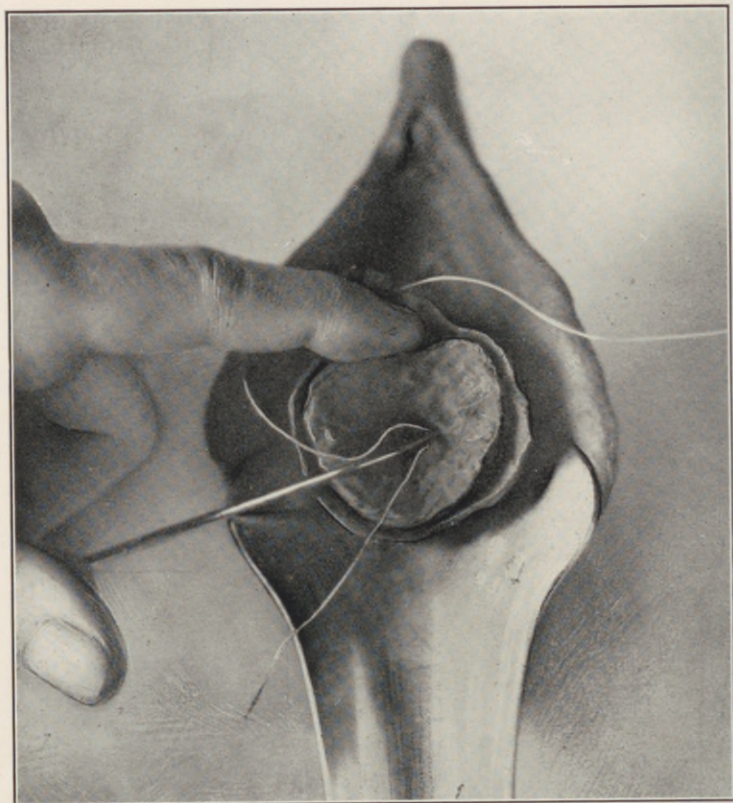


Fig. 35.—Tracheloplasty (author's method). Introducing the right free suture-end into and slightly above the internal os on a double curved needle, whence it is passed upward, forward and slightly to the right through the musculature to emerge at the base of the flap in the anterior vaginal fornix, $\frac{1}{8}$ of an inch from the median line.

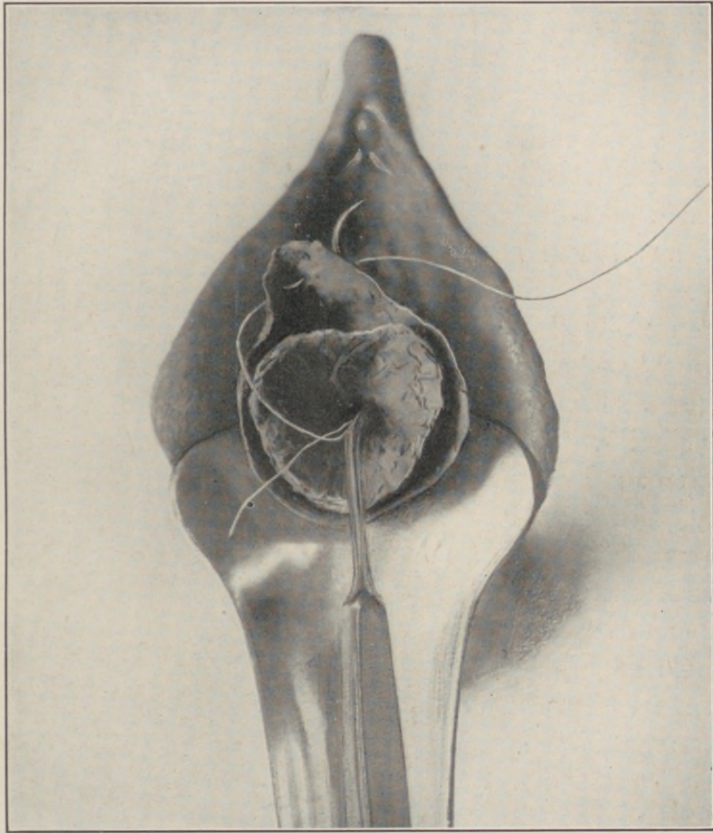


Fig. 36.—Tracheloplasty (author's method). Needle, carrying the right free end of the anterior suture, emerging on the anterior vaginal fornix at the base of the flap.

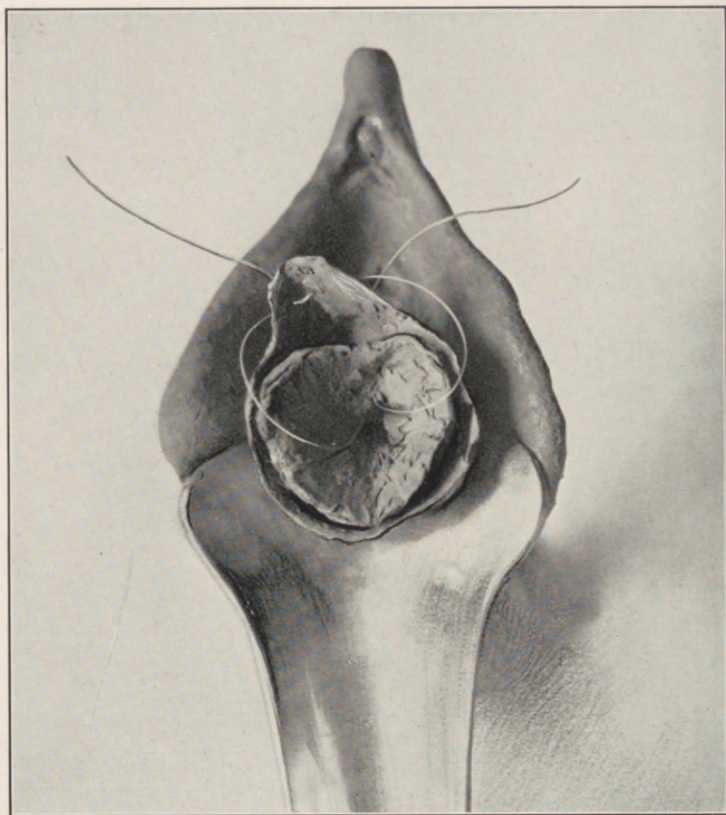


Fig. 37.—Tracheloplasty (author's method). The left free suture-end passed in a direction upward, forward, and to the left. Both ends emerging on the anterior vaginal fornix at the base of the flap, $\frac{1}{8}$ of an inch from the median line.

(3) Sutural inversion of the vaginal cuff into the denuded cervical cavity.

The main object in the first step is the formation of an ample cuff of mucosa from the vaginal sheath of the cervix. With this in view, an outlining incision is made to encircle the eroded area around the external os, closely skirting the demarcation border between the healthy vaginal and the diseased endocervical mucosa, running parallel to any indentations that mark the lines and angles of laceration.

The cylindrical flap thus outlined is freely liberated from the anterior and posterior surface of the cervix to the level of the internal os.

The eroded external os, with its everted hypertrophied lips, and the entire cervical lining up to the internal os, are now cored out of the surrounding muscular bed as a complete cone.

In congenitally deformed nulliparous cervixes, chronically infected, the muscular framework thus exposed may now be advantageously reshaped by appropriate incisions on the lines established by Sims, Pozzi, or Dudley, according to indication or predilection.

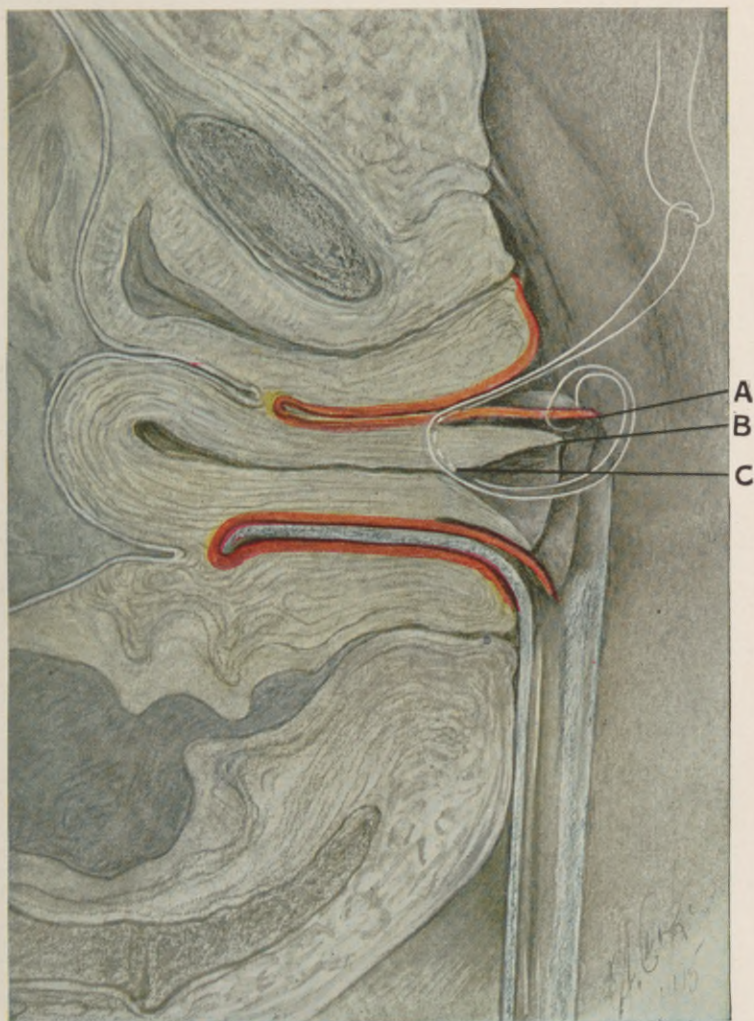
The vaginal flap is not included in any of these muscle incisions, to which no individual stitches need be applied.

The cervix now presents a muscular funnel within a deep cylindrical sheath of vaginal mucosa. The inversion of the cylindrical sheath of vaginal mucosa into the muscular funnel, and its sutural coaptation at the correct level, is accomplished in the following manner: Beginning with the anterior segment of the circular flap, a long strand of heavy silkworm gut is

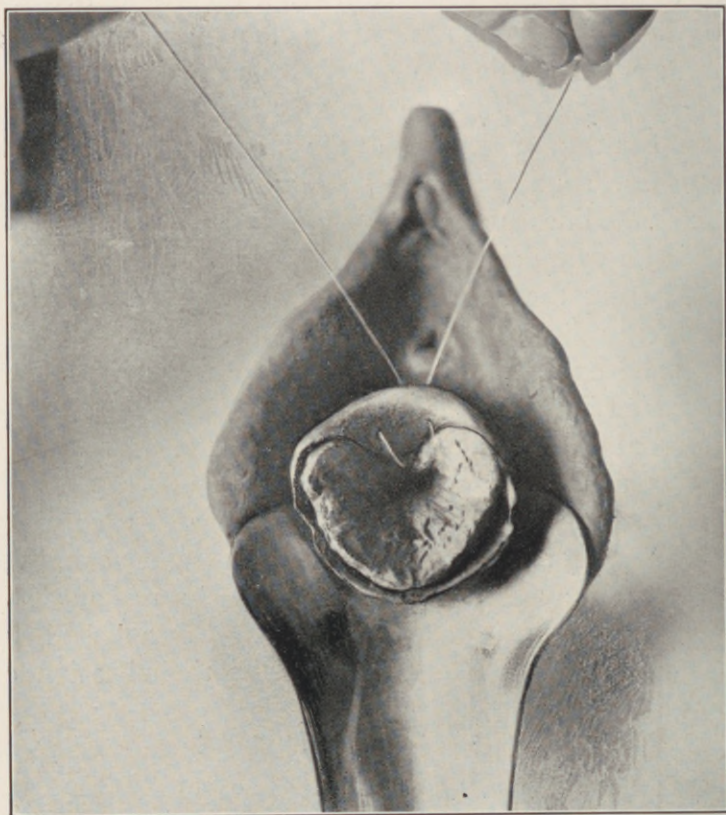

Fig. 38.—Tracheloplasty (author's method). Traction on the two anterior suture ends draws the anterior vaginal flap segment into the cervical cavity, and approximates its edge to the circumference of the denuded internal os.

PLATE XVIII.



Tracheloplasty (author's method). Schematic sagittal view of the suture course in the anterior flap segment. A, Edge of the cylindrical vaginal flap. B, Edge of denuded cervical cavity. C, Course of suture through the musculature to the base of the vaginal flap. The suture of posterior flap segment runs parallel to that of the anterior, but in a correspondingly posterior direction.

passed on its vaginal surface transversely through the free border of its central tip, one-eighth of an inch from the edge, like a mattress suture, the entrance and exit of the strand embracing one-eighth of an inch of tissue.

This suture is permitted to hang free until a like suture is passed in the same manner through the edge of the posterior flap segment.

The right free end of the anterior suture, threaded in a specially bent Peaslee needle, is now carried into the cervical cavity to a level just above the internal os, whence, piercing the cervical musculature in a direction forward, upward, and slightly to the right, it emerges on the vaginal surface at the base of the flap.

The left free suture end is directed in the same manner, forward, upward, and to the left, so that the two suture ends, diverging slightly in their course, reappear in the centre of the anterior vaginal fornix, about one-quarter of an inch apart.

The free ends of the posterior suture are passed in a corresponding posterior direction, and emerge in the centre of the posterior vaginal fornix.

By tightening and tying each individual set of suture ends, the tubular vaginal flap is drawn into the denuded cervical cavity, thus relining its entire raw surface. At the same time it is automatically interposed between the edges of any supplemental incision or excision of the cervical musculature, preventing their reunion, and is approximated to the circumference of the internal os, where it is firmly retained in close apposition until the sutures are removed.

Drawing too short a vaginal flap into the cervical

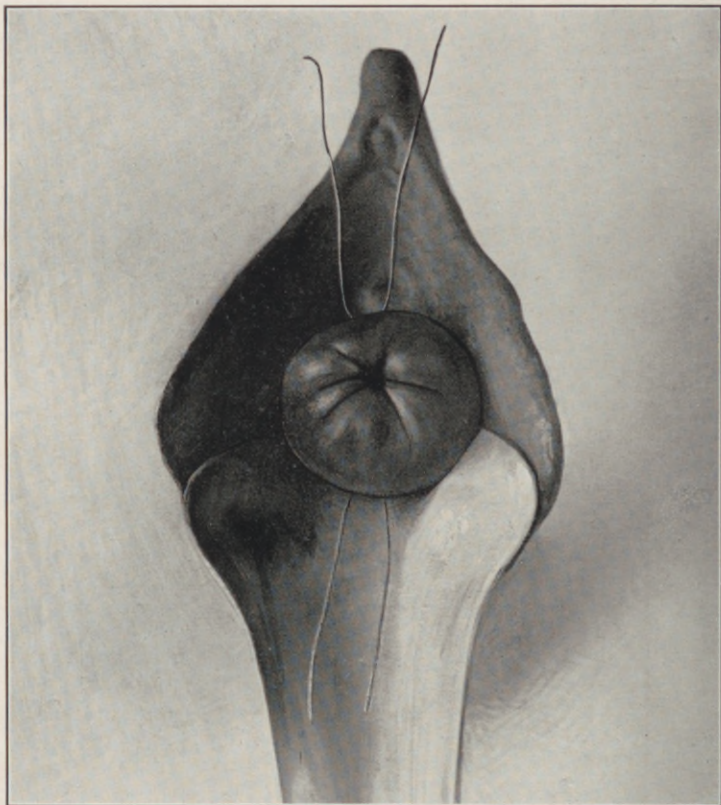


Fig. 39.—Tracheloplasty (author's method). The anterior and posterior sutures drawn taut and tied, flap in place, lining the cervical cavity to the internal os.

cavity will foreshorten the anterior vaginal wall, and tilt the uterus backward.

To lengthen a congenitally foreshortened anterior vaginal wall, as suggested by Reynolds, it is only necessary to incise the anterior flap segment transversely and pull this transverse incision into a longitudinal slit before passing the main sutures, which, emerging at the sides of the slit, coapt and retain its edges in the longitudinal axis.

Additional sutures are usually unnecessary. The silkworm ends are left long to facilitate their removal, and tucked into the vagina.

A narrow strip of iodoform gauze introduced into the cervix, with the object of maintaining flat coaptation of all raw surfaces, completes the operation.

This gauze is removed on the third or fourth day, when the patient is permitted to walk about.

The stitches are removed at the end of the third week, when they will be found loose and accessible.

The specific features of the operative method thus outlined effect the complete elimination of the infectious focus by extirpation of the diseased cervical mucosa; preserve the normal arrangement, contour, and functions of the cervical musculature; obviate the mechanical difficulty, and secure the permanency of accurate sutural coaptation of flap to stump.

I do not claim an ideal restitution to the normal in all cases. So perfectly a balanced mechanism as the uterus, when once deranged, cannot be perfectly restored by surgery. But I may contend that the procedure here advocated obviates in the greatest number of cases the detailed shortcomings in the prevailing tracheloplastic methods and results.

CHAPTER VIII.

THE CERVICOPLASTIC TREATMENT OF STERILITY.

IN its clinical designation, the term sterility is purely relative, necessarily implying in a given case the presence of approximately normal anatomic and physiologic essentials to conception, without the consummation of offspring. Physiologically, every woman who menstruates, ovulates. Biologically, ovulation predicates potential fecundity. The virgin ovary harbors from forty to sixty thousand ova. Ovulation, fertilization, and nidation constitute the chronological cycle of conception, and any perversion in their normal concurrence determines sterility. We cannot create a function; we can only attempt to activate one existing in a dormant state, stimulate one deficient, or, possibly, mobilize one tentatively inhibited. The maturation of a graafian follicle and liberation of its contained ovum, the evolution of the corpus luteum, the endometrial transmutation essential to deciduation, the subtle biotactic elements that dominate ovular fertilization and nidation, are all susceptible to inhibiting influences, temporary or permanent, local or systemic, most of which involve problems far beyond our present diagnostic horizon and therapeutic scope.

Who can explain why the conjugation of a perfectly normal female with an equally normal male proves sterile, while the subsequent union of each with another demonstrates the fecundity of both? To

apply the serological hypothesis of "a selective ovular immunity to certain strains of sperma" in explanation, is mere terminological juggling. Fecundity is a question of seed and soil. We cannot control the seed; we can only enhance its viability by correcting a deficient soil. We cannot control the ovule; we can only aim to correct certain endometrial abnormalities inimical to its fertilization and nidation.

The endometrium must provide a medium conducive to the virility and progression of the spermatozoon in its fertilizing mission, and must respond normally to ovular fertilization, with a concurrent activation of its decidual potentialities essential to normal nidation.

According to established modern conceptions, chronic corporeal endometritis is extremely rare. Our former acceptance of the condition was based upon misinterpretations of the normal endometrial changes characteristic of its menstrual cycle, as already elucidated above. *But for this relative immunity of the corporeal endometrium*, the extreme prevalence of chronic endocervicitis would render the largest majority of women sterile, for *a diseased cervical mucosa is capable of immobilizing and destroying spermatozoa.*

But beyond the direct devitalization of sperma by the diseased cervical mucosa, other factors, of equal and greater potency in the causation of sterility, may be incited through the influence of cervical disease upon the functions of the uterus as a whole, for, *while chronic endocervicitis never extends to the corporeal endometrium by direct continuity*, a sterility accompanying the former *is due in large part to the*

functional derangements induced in the latter. (See chapter on Endocervicitis.)

Crystallized into a concrete postulate, *chronic endocervicitis* presents the key to the therapeutic problem in sterility of cervical origin, and the success of any curative attempt upon the cervix will be proportionate to its elimination of an existing endocervical infection.

The question as an abstract proposition, whether a tracheloplastic widening of the cervical canal cures sterility by facilitating the ingress of spermatozoa, or the egress of deleterious secretions, would appear of more academic than practical interest, but applied to the individual case it acquires the significance that distinguishes between rational procedures and empirical practice.

Every curative attempt should be based upon a correct perception of indications, and a definite realization of its aim and scope. We must know why we operate, in order to determine when and how to operate.

Boldt states: "Next to curetting, dilatation of the cervical canal, principally to overcome sterility, is the operation most frequently done without proper indication. Those who have made observations will probably concede that in 75 per cent. of patients so treated the intervention is unwarranted."

The cervicoplastic operations in vogue for the cure of sterility comprise the so-called discission and amputation—that is, the cervix is either split or ablated.

Many women undoubtedly conceive after one or other of these operation, as they occasionally do after

dilatation and curettage, but to attribute an eventual fecundity to the curative effect of this or that procedure is an obvious "*post hoc*" interpretation; for it must be conceded that, on the one hand, many women presenting operative indications ultimately conceive without any intervention whatsoever, while on the other hand a very considerable number of operations prove utterly futile of results.

One hundred and twenty-eight complete post-operative histories from among 400 recorded cases tabulated by Leonard in Howard Kelly's clinic revealed 80 per cent. of sterility after low amputation for cervical lacerations.

In other words, 8 out of 10 women of established fecundity are sterilized by prevailing methods of cervix amputation; and while we recognize an occasional postpuerperal sterility as a possible sequel of birth injuries ("one-child sterility"), its occurrence never attains to such proportions.

The normal cervical lining is not essential to conception or gestation, but a diseased lining is inimical to both, and should be removed by the method advocated in the chapter on the treatment of endocervicitis.

I would not dogmatically attribute the cure of sterility to this operation any more than to other procedures, for there is too much that is unknown and unknowable involved in the problem; but I may assert, after a very extensive and critical trial, that the method as outlined radically eliminates chronic endocervicitis—*the one established causative factor in the sterility of cervical origin.*

CHAPTER IX.

PERINEORRHAPHY.

THE practice of perineorrhaphy dates from the middle ages. Tradition points to one Trotula, a woman attached to the school of Salerno in the eleventh century, as the first to suture a lacerated perineum: "*Post modum rupturam intra anum et vulvan tribus locis vel quatuor suimus cum filo de serice.*"

From this remote record to the present time, a span of nearly one thousand years encompasses the evolution of perineorrhaphy, every phase of which is linked with names of the most illustrious surgical exponents, and with a literature which offers the most ancient, the most voluminous, and yet the most incomplete theme in modern gynecology.

"To no department of gynecology," wrote Thomas thirty-five years ago, "does there attach more surgical rubbish which needs a thorough clearing away than to perineorrhaphy."

Three years later Emmet inaugurated what may be termed a renaissance in perineorrhaphy, by demonstrating the significance of the musculofascial elements in the nature and repair of perineal injuries. Nevertheless, while thus among the first to recognize correct anatomic essentials for a reparative method, he devised an operation the ultimate results of which have not tended to sustain that prestige among contemporaneous procedures bestowed upon it by the

authoritative name of its advocate, for, after a vogue of nearly three decades, Jewett in 1905 characterizes "the female perineum with its surgical problems" as the "*pons asinorum* of the gynecologist"; adding that "the surgical anatomy, the nature of obstetric injuries and the rationale of their repair, are questions long in dispute, and their solution still remote."

Irving S. Haynes, on "The Anatomic Basis for Successful Repair of the Female Pelvic Outlet," asserts that "the treatment of pelvic lacerations is in sufficient chaos to justify a reasonably careful review of the salient features of the subject."

In the same vein, W. W. Babcock pointedly depicts the practice of perineorrhaphy in 1909 as follows: "The methods of perineorrhaphy that have been chiefly employed for the last twenty-five years suggest more of a mathematical than an anatomic basis for their existence. For the most part, they have consisted of excisions of mucous membrane from the posterior vaginal wall, having geometrical patterns that vary as do the fancies of the different surgeons.

"In support of the various operations, much has been written about the laceration in the muscular and fascial planes, and of the effectiveness of particular operations; yet one who studies the work of various gynecologists will be impressed by the thought that usually the precise anatomic restoration of the perineum occurs only in the theory of the operator, for the operation as a rule consists of little more than the removal of an area of mucous membrane and the union of the wound edges. . . . If at times the operator's needle is made to sweep in various direc-

tions, with the specification that certain muscles are caught in its grasp, the precise evidence that such muscles are included, and especially any evidence that the important fascial planes of the perineum are restored, is rarely observed."

The veteran Henry O. Marcy concludes one year later that "the basic principles of the operation are still in a measure misunderstood."

C. M. Watson tersely epitomizes the sum and substance of the whole problem by stating that "the classic operations for the secondary repair of the torn or relaxed perineum have been successful only to a degree; the more extensive the injury to the levator ani muscle, the less effective these operations."

The recognition of the levator ani as the functional dominant and surgical objective in perineal injuries is not of recent date. In 1884, B. E. Hadra, of San Antonio, Texas, first propounded the operative problem as it presented itself to him at the time, in the following:

"It will be hazardous to cut through the posterior vaginal wall in order to seek the levator muscles and to sew them together; still something of this kind must be done.

"I have in view an operation which was devised by my deceased friend, Dr. Dowell, of Galveston, for hernia. I believe that it will prove to be the correct procedure, as it promises reunion of the separated muscles, and narrowing of the slit, without any injury to the surrounding organs and tissues.

"I will at the proper time report more fully on this point, but for the present would ask the profession to take the whole subject under consideration, and seek

some method to remedy evils which as yet are beyond our control."

Again, in 1887, Hadra, after experimental attempts on the cadaver, and a critical scrutiny of contemporaneous methods, stated: "A little reflection will at once demonstrate that it is not the perineum which the operation aims at, but the posterior vaginal wall. . . . Wylie's operation, like Emmet's, is not a perineorrhaphy. . . . It is only the effect of both operations on the patulency of the vaginal outlet that makes them appear a remedy in a ruptured perineum. . . . Very likely a sewing of the margins of the levator shanks sometimes happens without our knowledge in operations where the sides of the vagina are extensively denuded, so as to lay the muscles bare. . . . I am confident that, in all the colporrhaphies which have given permanent relief, the shanks of the levator were united to each other on the sides of the vagina. When the vaginal wall is fully lifted, these muscles may be fully exposed, and when the corresponding surfaces of both sides are well brought together the brims of the levators must be sewn to each other. I do not doubt that in Hegar's, in a high Tait's or Fritsch's operation, as in all others in which the vagina is posteriorly extensively denuded, the narrowing of the levatoric slit by these processes is the main part of the permanent success."

In 1900, Ziegenspeck first recorded the direct suture of the levator ani in perineorrhaphy on the living, while Duval and Proust published an elaborately illustrated monograph on "Levator Myorrhaphy" in 1902.

These early publications, which practically embody

the origin and principles of all subsequent levator operations, instigated a flood of technical propositions and academic controversy which to the present time display a striking diversity in conceptions of the anatomy, topography, and dynamics of the levator ani muscle.

CHAPTER X.

THE MECHANISM OF INTRAPELVIC VISCERAL SUPPORT.

THE keynote in the clinical significance and surgical indications of perineal lacerations is the loss of gynecic support, and the study of its problems must be centered in the myodynamics of the pelvic floor and its function in the control of intra-abdominal pressure.

Studies of normal visceral support have been confined largely to the limits of anatomical detail. Anatomy, however, has not fully revealed the true *mechanism* of this support. It is a gross misconception of function that attributes visceral support to the textural strength of ligaments or muscles. The ligament or muscle does not exist that can permanently withstand the continuous force of intra-abdominal pressure.

The muscular and ligamentous elements serve to support the pelvic contents, not by virtue of their textural resistance to displacement, but by *deflecting* the displacing force of intra-abdominal pressure.

Moreover, the perineal musculature should not be conceived as a diaphragm, passively bearing the weight of its superposed organs, with a sphinctre action at the pelvic outlet. It is an active integral part in a complicated deflecting mechanism that dominates the topographic stability of all the abdominal viscera.

The influence of pressure and its deflection find familiar exemplification in the mechanism of labor when the initial direction of the expulsive force becomes deflected by the pelvic planes, and thus impels the fetal ovoid through the different axes of the parturient canal.

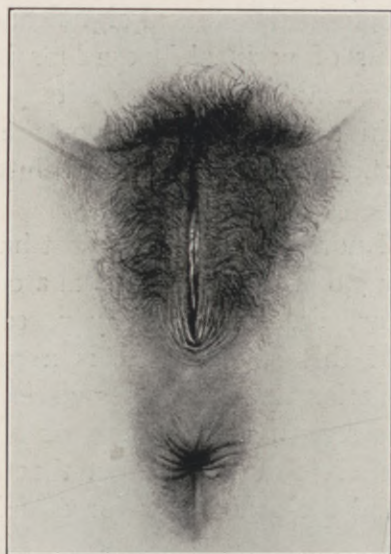

Fig. 40.—Normal nulliparous vulva

The radical cure of inguinal hernia became possible only with the realization of its two essentials, namely, the apposition of *contractile* muscular resistance to the hernial area, and the obliteration of its peritoneal funnel. In other words, the muscular and serous planes are so reconstructed as to re-establish the normal deflection of intra-abdominal pressure, thus causing the intestine to glide *over* instead of *into* the hernial gap.

In inguinal herniotomy, the freely mobilized conjoined tendon with its contiguous muscles is deliberately displaced by suture to Poupart's ligament; and yet the analogous interposition of the mobilized levator, essential to a successful perineorrhaphy (which is practically a vaginal herniotomy), is stigmatized as "unanatomic."

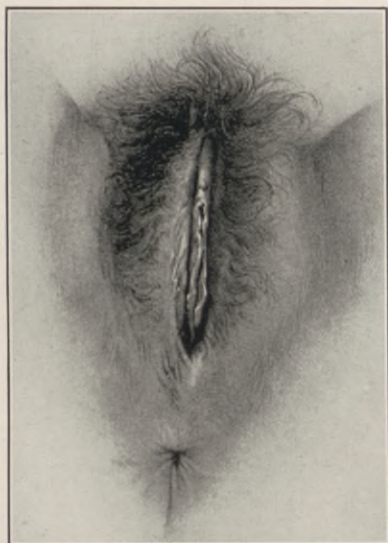


Fig. 41.—Normal parous vulva. Competent levator ani muscle.

The really valid objections to some of the levator myorrhaphies in vogue—namely, the isolation of the muscle "through a slit in its fascial covering," "injuries to the rectovaginal plexus, with possible thrombotic sequela in residual dead spaces"—are inapplicable to a technique which circumvents these deleterious features by approaching the levator bed bluntly along a direct plane of cleavage existing normally between the vaginal mucosa and the levator fascia.

The evolution of levator myorrhaphy, like that of every other surgical procedure, has afforded a fertile field for attempts at originality and modification, some of which, losing sight of fundamental principles, necessarily defeat their own ulterior purpose.

It is a significant fact that the most pernicious of these "simplified" methods emanated from the ranks

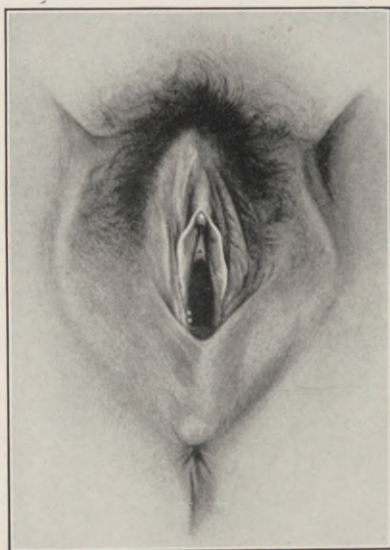

Fig. 42.—Parous vulva, gaping from incompetent lacerated levator ani muscle.

of the general surgeons. To "plunge a scissors" blindly through the perineal tissues, "tease out a few levator fibres on each side and sew them together," all "done within five to six minutes," is levator myorrhaphy in name only, and nothing more.

No corrective procedure in all gynecology exacts a more intimate regional knowledge and greater

technical skill than a properly executed sutural readjustment of the levator ani in perineorrhaphy.

The morbidity of a perineal injury manifests itself by palpable evidences of impaired support at the pelvic outlet. Every perineal laceration that impairs a previously normal intrapelvic support has partly or completely severed the junction of the anterior levator segments on one or both sides of the median raphé; the resultant "relaxed vaginal outlet," the "colpocele," "rectocele," "cystocele," and "descensus uteri," present only different degrees and successive stages in the ultimate development of a complete prolapse, each stage being proportionate to the extent and duration of the muscular lesion in the pelvic floor.

The restoration of the impaired visceral stability within the pelvis demands a readjustment of balance between an expulsive force and its counteracting retentive elements—that is, between intra-abdominal pressure and its deflecting mechanism. Paradoxical as it may appear, both maintenance and disturbance of visceral equilibrium are the resultants of one and the same force, namely, intra-abdominal pressure under the influence of its balanced or unbalanced deflection.

The conditions causing and modifying *intrathoracic* pressures have been the subject of exact research, and the conclusions offered meet general acceptance. This is not the case with *intra-abdominal* pressure.

In the general and special literature, the subject is treated under discussions of splanchnoptosis, ascites, and circulatory conditions. Most of the textbooks on

physiology omit the topic entirely, while the standard works on Obstetrics, Gynecology, and Surgery allude to intra-abdominal pressure so sparsely and inaccurately that very little is to be gleaned from them.

Martin (1885), in discussing the causes of uterine displacement, states that intra-abdominal pressure is the essential factor, and that failure of the pelvic floor induces a diminution of this pressure and a descent of the uterus.

Hegar (1886) asserts that the pelvic viscera are dislocated, not only by relaxed ligaments, but by diminution of intra-abdominal pressure.

The fallacy of these interpretations becomes apparent when it is recalled that the abdominal and pelvic cavities present one continuous chamber, and that pressure recorded at any one point within this chamber is equivalent to the pressure at the same moment at any other point in the chamber; consequently, if diminution of pressure as such induced a descent of the pelvic organs, it should constitute part of a synchronous descent of all superposed abdominal organs, which is contrary to clinical experience.

Much of this confusion is due to the misapplication of hydrostatic principles to intraperitoneal conditions. These principles, when applied to homogeneous fluids under pressure in a retainer of uniform outline and resistance, permit of exact observations and calculation; but the abdominal cavity is neither uniform in outline nor resistance; its walls are bony here and muscular there, while its contents are not homogeneous, but solid, semisolid, fluid, and gaseous.

To quote further from a few of the more extensive treatises on physiology:

Du Bois-Reymond (1908) merely states that there is a variation in intra-abdominal pressure due to the action of the diaphragm.

Hall (1900) considers intra-abdominal pressure at zero when the abdominal muscles are at rest, but illustrates the rise above that on descent of diaphragm and contraction of the abdominal muscles. Although his tracings are probably correct, he gives neither base-line nor statement as to what fluid he used in his manometers to obtain the pressure records. He notes the effect of abdominal pressure on venous and lymphatic flow.

Landois (1900) refers to Hamburger's work of 1895-1896, and makes the curious statement that expiration causes a rise in intra-abdominal pressure in man and dogs, but that inspiration has this effect in guinea pigs. A slight increase in abdominal pressure causes increased heart action and arterial pressure, but excessive pressure in the abdomen decreases both.

Luciani describes the use of rectal and esophageal bougies, and gives tracings of intrathoracic and intra-abdominal pressures, but no figures as to the facts observed in etherized dogs. The essential fallacy of testing such pressures through a contractile hollow organ he does not observe. He finds that the abdominal pressure varies with the descent of the diaphragm and contraction of the abdominal walls.

Schaefer (1900), after noting the effect of abdominal conditions on the circulation, points out the very important fact that the tone of the abdominal wall muscles is maintained by the respiratory centre. The abdominal pressure as maintained by the abdominal walls is of the utmost importance, as it tonic-

ally maintains the calibre of the great veins, and can compress them or allow them to expand.

Tigerstedt (1906): "By abdominal pressure we mean the pressure on abdominal viscera produced by the simultaneous contraction of the diaphragm and the abdominal muscles." He gives no figures or tracings, and considers the pressure of importance only in relation to defecation and in labor.

Briefly stated, intra-abdominal pressure—or, more specifically, intraperitoneal pressure—is the resultant of several components, the most potent of which are muscular contractions, gravity, intravisceral tension, and atmospheric pressure.

Intraperitoneal pressure, while continuous in effect, varies in intensity with the necessarily diverse activity of its muscular component.

For practical purposes, these pressure variations may be defined as presenting a passive and an active phase.

The passive phase is the state of normally balanced minimum intraperitoneal tension which prevails under the ordinary conditions of functional activity. This phase is of physiologic interest only.

The active phase is a superinduced condition of hypertension, resulting from augmented efforts that incite the abdominal and thoracic muscles to sudden or sustained maximum contractions, as coughing, sneezing, straining, lifting, etc. It is this phase of pressure which tends to extrude the pelvic viscera in the direction of least resistance.

When a perineal laceration involves the sphincter ani, prolapse rarely ensues, because every sudden augmentation of pressure in this condition is promptly

reduced by the involuntary emptying of the lower bowel contents through the gaping anal orifice before the increased tension can exercise its displacing force upon the pelvic viscera.

It is a fundamental law in dynamics that the direction of a given force or body impelled by such force, impinging against a resistant plane, becomes deflected in a fixed and definite direction, the degree of deflection being governed by the angle of the resisting or deflecting plane.

The same law is dominant in establishing and maintaining visceral equilibrium against the displacing force of gravity and intra-abdominal pressure. But for the influence of deflecting planes, every erect female would prolapse her abdominal contents into the pelvis and out through the vagina. As the result of normal deflection, a pressure of 80 mm. in the abdominal cavity is reduced to 60 mm. at the cervix, 40 mm. in the vagina, and 20 mm. at the introitus (G. H. Noble), thus resembling a placid pool along the edge of a rapid vortex.

The entire abdominal cavity constitutes a compound deflecting chamber presenting multiple planes, some fixed and others mobile, that deflect pressure at various and varying angles to each other.

In the pelvis, the fixed or bony planes may be designated expulsive planes, inasmuch as they tend to deflect the direction of pressure into line with the axis of the pelvic outlet. They are practically identical with the established obstetric planes, among which, however, the sacral hollow is the most potent, as exemplified in its dominance on the final course of

the fetal head; any viscus that falls into the line of this expulsive plane must eventually prolapse.

In the same sense, the mobile planes are retentive planes, in so far as they deflect or disperse pressure

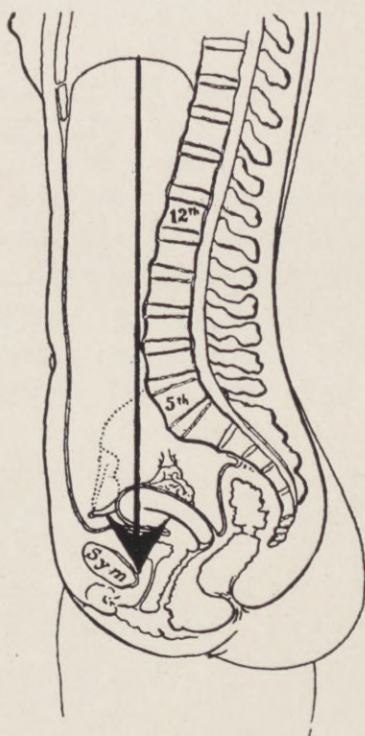


Fig. 43.—In an abdominal cavity of normal skeletal configuration a true vertical in contact with the sacrolumbar angulation will impinge against the inner face of the symphysis pubis at its lower border. This vertical represents the initial direction of intra-abdominal pressure at the pelvic brim.

in directions that tend to preserve the topographic stability of the pelvic contents. These are presented by the mobile uterus, with its broad ligament extensions, and the levator ani in the pelvic floor.

In an abdominal cavity of normal skeletal configuration, a true vertical, in contact with the centre of the sacrovertebral promontory, will impinge against the inner face of the symphysis pubes at its lower border. The sacrovertebral promontory is situated $3\frac{1}{2}$ inches above the symphysis, so that the vertical line which represents the initial direction of intra-abdominal pressure at the pelvic brim passes over, and not into, the pelvic cavity.

In other words, the posterior abdominal wall terminating at the sacrovertebral angle is $3\frac{1}{2}$ inches shorter than the anterior, which ends at the symphysis pubes. Dynamically the pelvic cavity thus presents a separate communicating chamber or elbow, hollowed out of the posterior abdominal wall, with the sacrum as an inclined roof, from which the uterus is suspended by its sacro-uterine ligaments.

Accordingly, under ordinary conditions, the direction of intra-abdominal pressure within the pelvis is such as to fall upon the posterior surface of the uterus and broad ligaments. In deflecting the direction of this pressure to maintain its equilibrium, the normally anteverted uterus may be compared to a lever of unequal arms, poised over a fulcrum presented by the intravaginal crest of the perineum. This intravaginal crest is formed by the junction of the pubococcygeal levator segments to the median raphé.

The longer fundal arm of the uterine lever, which rests upon the subjacent bladder and pubic surface, is movable upwards, extreme movement in this direction being limited by the round ligaments, which, up to a certain point, prevent tilting of the uterus into

the axis of the sacral expulsive plane. The shorter cervical arm of the uterine lever projects free into the vaginal fornix.

By this adjustment intra-abdominal pressure at first tends to depress the normal level of the uterine plane as a whole, until its anterior pole is arrested by the resistance of the subjacent bladder and upper pubic surface; augmentation of the pressure at this stage acts upon the free posterior cervical pole, forcing it upon its perineal fulcrum.

Were this pressure to continue undeflected, the round ligaments would yield, and the progressive descent of the cervical pole, with its corresponding elevation of the fundus, would gradually tilt the uterus into retroversion. In this position it sustains the pressure impact upon its anterior instead of its posterior surface, and is thus crowded into line with the axis of the vaginal outlet. Under normal conditions, it is this last phase of the pressure that is counteracted by the deflecting function of the levator ani muscle.

The stimulus which incites the abdominal musculature into activity, and thereby augments intra-abdominal pressure, induces a simultaneous contraction in the levator ani.

The elements of this muscle are so arranged that their contraction elevates the level and the angle of the pelvic floor. This elevation lifts the intravaginal crest or fulcrum up to the uterine lever, raises the depressed cervical pole of the lever to the level of its fundal pole, thus restoring anteversion; at the same time, the elevation of the perineal plane narrows the essential uterovaginal angle, preserves the potenti-

ality of the vagina by converting its actual canal into a valvular slit, and mechanically closes the pelvic outlet.

Every augmentation of pressure demands a proportionate increase in resistance, which demand is promptly met by a synchronous countercontraction of the levator ani.

Accepting the principle of deflection as fundamentally applicable to the problem of visceral support, it follows as a natural corollary that every deviation from the normal, in the angle and resistance of the perineal deflecting plane, must necessarily induce a corresponding deviation in the direction of intra-abdominal pressure, with resulting topographic disturbance.

The normal contours and topographic arrangement of the pelvic floor and its superimposed organs all conform to subserve this deflecting function.

A sagittal section of the pelvic floor, with the body in the erect posture, shows the cutaneous perineum extending horizontally from the posterior vulvar commissure to the coccyx, while the upper or intra-abdominal surface, conformable with its function as a deflecting plane, slopes obliquely from the pubes, downward and backward, in a line parallel to the axis of the pelvic inlet.

This divergence of the upper from the under surface outlines the triangular configuration of the pelvic floor. Its apex at the coccyx is less than half an inch in thickness; its base at the pubic arch occupies a space of over 3 inches.

The vagina, bladder, uterus, and rectum rest upon and constitute part of this inclined plane, the whole

structure being swung in the muscular hammock formed by the levator ani loops, which, by their contractile response to pressure, maintain its form, level, incline, and topographic relations.

Contrary to general impression, the direction of the vaginal canal is practically horizontal. It is inter-

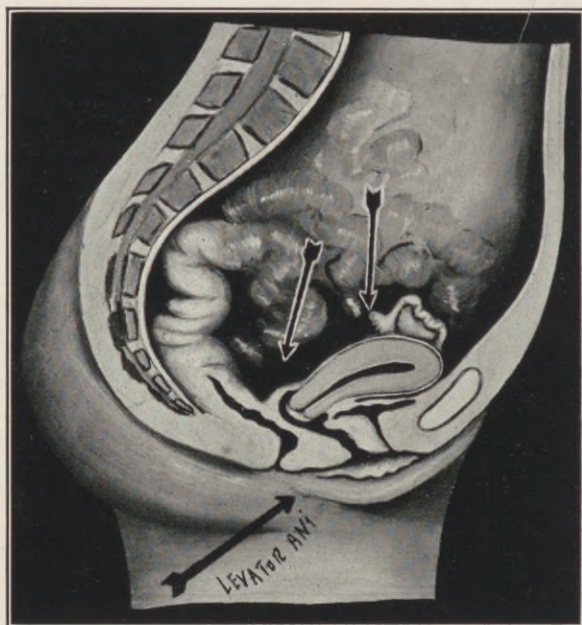


Fig. 44.—Diagrammatic scheme of normal pressure deflection by the intrapelvic planes, and the direction of levator contraction.

posed between the muscular layer in the pelvic floor and the superimposed pelvic viscera, the disposition of its walls being superior and inferior, not anterior and posterior.

Its orifice is held in the most anterior of the levator loops (pubo-coccygens), in a plane just posterior to that of the pubic arch.

Normally, the uterus lies nearly parallel to the puborectal segment of the levator ani, which, on contracting, draws the perineum forward and beneath the bladder, thus covering the outlet like a sliding floor.

Every augmentation of pressure that forces the uterus downward stimulates the levator to lift the vagina upward, constricting its orifice against the pubic arch and closing the uterovaginal angle; the greater the pressure, the narrower the angle and the firmer the resulting vaginal closure.

Concisely stated, the levator ani diminishes the force of intra-abdominal pressure upon the pelvic contents by deflecting the direction of that pressure, augments the resistance to the pressure by closing the uterovaginal angle, and obstructs the pelvic outlet against the pressure by compressing the vaginal canal.

It is the tensor of the pelvic fascia, the antagonist of the diaphragm and abdominal muscles, contracting when these opposing muscles contract, and relaxing when they relax.

When intact, it maintains the equilibrium of the pelvic organs; when its integrity is impaired, equilibrium is disturbed and displacement ensues. Finally, in disorders of the lower spinal segments, especially in *Spina bifida* and *Spina bifida occulta*, involving the fourth sacral nerves, prolapse ensues as the result of levator paralysis, and this notwithstanding that the ligaments and fascia are intact.

Such is the function of the perineum, and such the measure of its importance as a visceral support. It follows that the gravity of perineal lacerations is

proportionate to the resulting impairment of its muscular element, such impairment inducing a tendency to prolapse, *not* because any direct support to the viscera is severed, but because the equilibrium of intrapelvic pressure is deranged and its expulsive force *undeflected*.

CHAPTER XI.

THE LEVATOR ANI MUSCLE.

IN 1889 Robert L. Dickinson wrote: "I venture to affirm that there is no considerable muscle in the body whose form and function are more difficult to understand than those of the levator ani, and about which such nebulous impressions prevail. The drawings of it are complicated, the impressions of its strength and importance are conflicting, and the knowledge concerning it is fragmentary and not readily accessible. . . . One commonly meets with the idea that the levator is a kind of muscular funnel tapering to the anus, and serving to pull it directly upward after defecation. This is absolutely untrue. The muscle rather resembles a horseshoe—a sling attached to the pubes in front, its sweep reacting horizontally backward, to circle like a collar the rectum and vagina. Its action in woman is to drag the lower ends of the vagina and rectum forward, level to the symphysis."

This statement in its entirety holds good at the present time.

The levator ani is not a single muscle, but a radially disposed plexus of flat muscle segments, enclosed and separated by fascial investments, and composed of striped and unstriped muscle-fibres. While its individual segments may be separately demonstrated at their origin, they become intimately and inseparably blended with each other and with the

aponeurotic tissues in the perineal centre and ano-coccygeal raphé.

Functionally, a sharp demarcation characterizes the coccygeal and pubic divisions of the levator muscle.

The coccygeal division comprises the thin posterior semi-membranous segments that are inserted

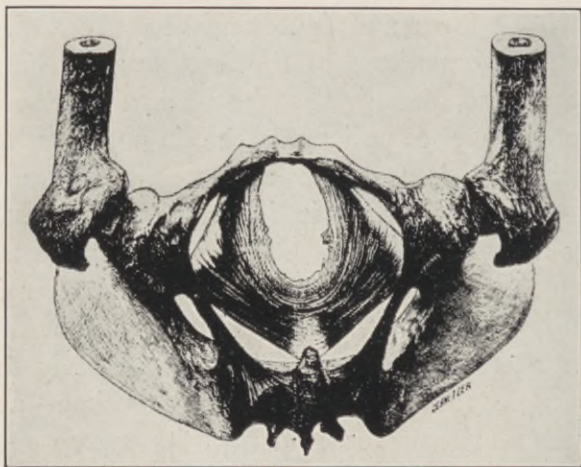


Fig. 45.—The levator ani seen from below. The cut ends projecting upward are those fibres which run into the recto-vaginal septum. (*Dickinson.*)

into the sides and tip of the coccyx. These are devoid of special function, representing vestigial structures, homologous with the caudal flexors in the lower animals, and are of anthropologic interest only.

The functionally essential elements of the levator ani are the pubic bands commonly designated “pubo-vaginalis,” “puborectalis,” or “pubococcygeus.”

The bulk and strength of these muscles are much

greater than current anatomic descriptions and *post-mortem* appearances would indicate.

Their lines of origin extend for 1 and 1½ inches on either side of the posterior surface of the pubic symphysis, thus equalling in width the average sternomastoid; they are twice as thick as the diaphragm,

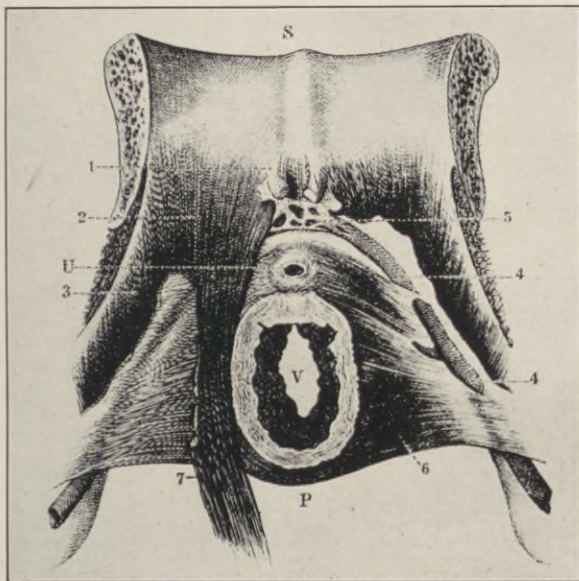


Fig. 46.—Origin of the left anterior (pubococcygeal) loop of the levator ani from the posterior symphyseal surface (the right loop removed). S, Symphysis. U, Urethra. V, Vagina. P, Perineum. 1, Pubovesical ligament; 2, Origin of pubococcygeus; 3, Iliococcygeus; 4, Internal pudic vessels; 5, Urethral plexus; 6, Upper (inner) surface of the pelvic diaphragm; 7, Pubococcygeal loops of the levator ani muscle.

weigh one-fourth as much as the external oblique, altogether presenting a muscular support exceeding that guarding the inguinal ring.

Their dynamic energy, as developed by Dickin-

son's experiments, ranges from 10 to 27 traction pounds.

These pubic segments course almost horizontally backward and inward along the lateral vaginal walls.

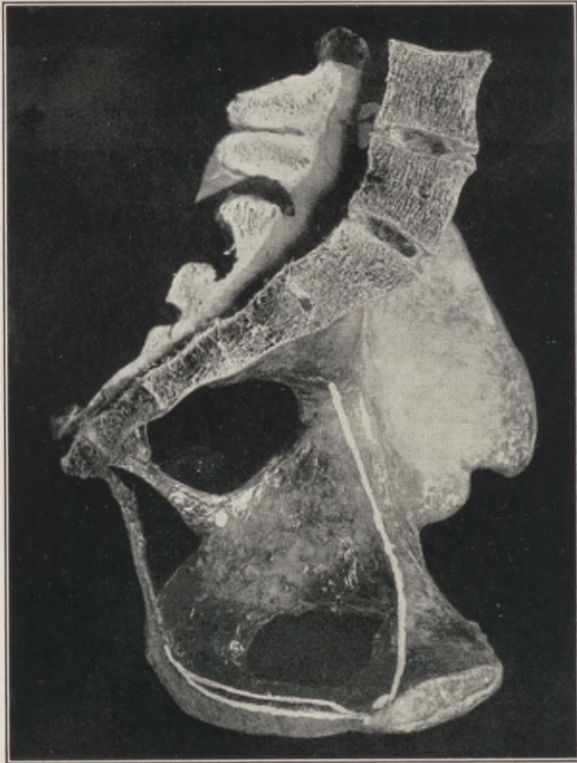

Fig. 47.—The intrapelvic line of origin of the levator ani. (*Haynes.*)

They converge rapidly toward each other to become inserted into the rectovaginal septum, the perineal centre, the rectal walls and the anococcygeal tendon, encircling the vagina and rectum in distinct loops.

Their median borders, which are plainly palpable through the lateral vaginal walls, a half-inch or less behind the plane of the hymen, form a V-shaped interspace which embraces the introitus under the pubic arch, and is termed the levator cleft.

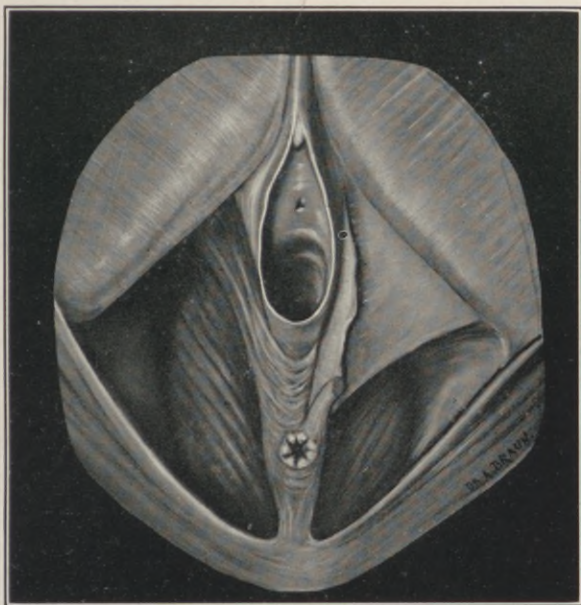


Fig. 48.—Levator ani fibres normally present in the rectovaginal septum.

A study of the vaginal extrusions resulting from perineal lacerations reveal elements closely analogous to those of inguinal hernia.

Both conditions result from muscular insufficiency over a vulnerable intra-abdominal site, tunnelling their outward course along potential channels between the muscular and fascial layers of the abdominal walls.

The levator ani embracing the abdominal floor is as much an abdominal muscle as the obliquus, transversalis, or rectus. Furthermore, the form and nature of the muscular arrangement guarding the inguinal openings above the pubes is the exact counterpart of the levator arrangement beneath the pubes.

The lacerated levator shanks retract upward and outward behind the pubic rami towards their parasymphyseal origin, widening the introitus, with resulting eversion and ultimate protrusion of the vaginal mucosa through the gaping orifice.

The cleft created by the separation of their median borders gives vent to the anterior rectal wall in the formation of rectocele.

The vaginal floor, thus deprived of its muscular crotch, and shortened to the extent of its laceration, exposes the upper vaginal wall and leaves the bladder base unsupported.

The entire vaginal canal, with its superimposed viscera, descends to a lower level. The prolapsed vaginal pouches, with their hernial contents, gradually drag the anteverted cervix toward the yielding outlet. The uterovaginal angle becomes widened, the uterus telescopes the vagina, and the prolapse is complete.

CHAPTER XII.

THE PELVIC FASCIA.

THE levator ani, like all skeletal muscles, is invested with fascial sheaths whose relative function in the mechanism of intrapelvic support presents a topic of unsettled controversy. The study and delineation of this fascia, like that of the levator, aside from its intrinsic difficulties, is encumbered by a diversified terminology, which depicts a confusing multiplicity of subdivided layers.

In the pelvis, as elsewhere, the muscular dominance in visceral support, direct or indirect, accords with the established morphological law, that "all weight-bearing function is essentially muscular in nature, clonic in rhythm, and continuous in effect."

With the assumption of the erect attitude by man, the pubic levator segments developed their supporting function, while the coccygeal or caudal segments degenerated into thin membranous expansions.

In the biological scale, the tailless anthropoid apes present a well defined levator ani, similar in form and function to the human muscle.

This evolutionary transition of the levator, from caudal flexor to perineal contractor, offers a key to the complicated topographic arrangement of the pelvic fascia along the following lines:

The fibres of the primitive pubic muscle-bundles (pubo-coccygens), proliferated around the pre-existing vaginal and anal canals, between the layers of

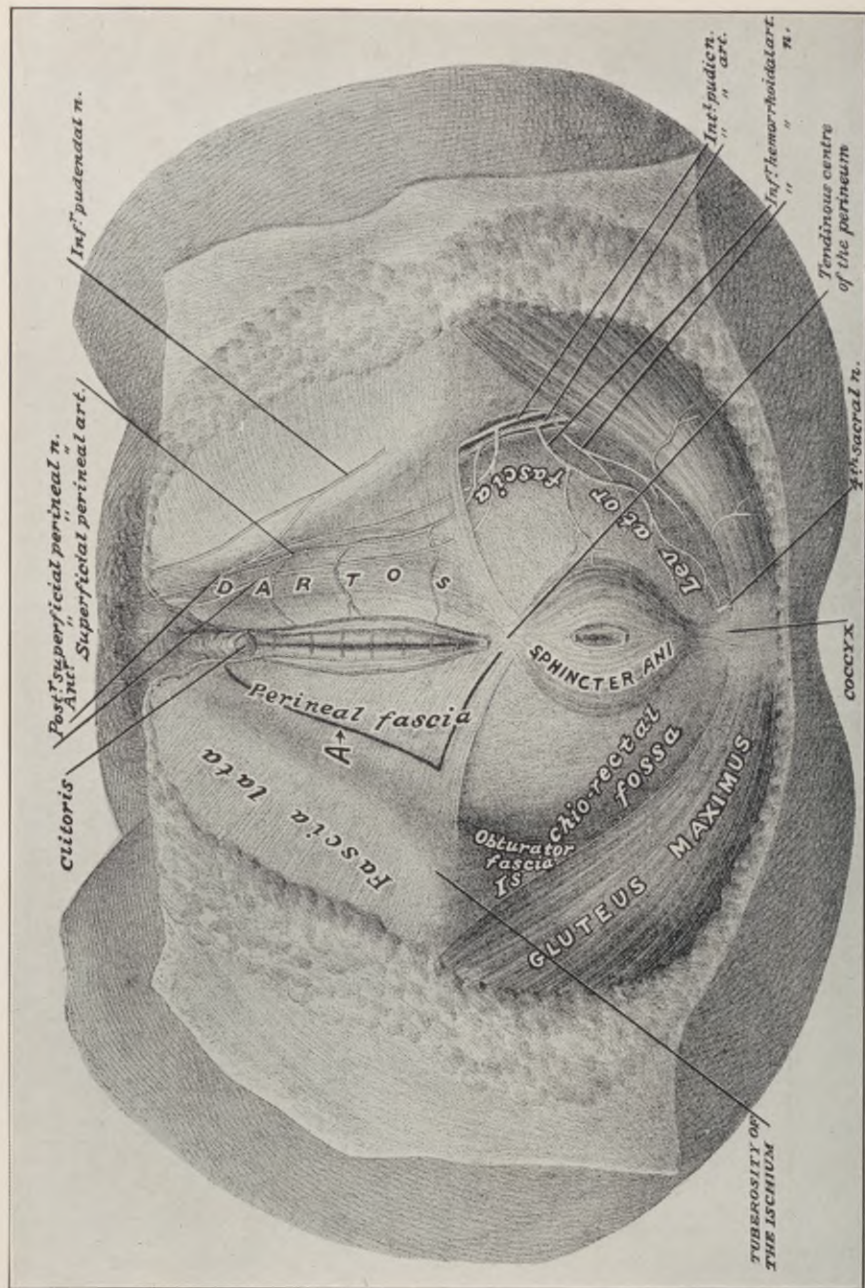


Fig. 49.—Anatomy of the female perineum. Superficial area. At A line of deflection for the exposure of the midarea.

the deep pelvic fascia, which thus constituted the levator sheath; the upper layer of this sheath is known as the "rectovesical fascia", while the lower is termed "levator fascia".

Concisely stated, the pelvic fascia, the rectovesical fascia, and the levator fascia, like the iliac and obturator fascia, are all in reality but one stratified

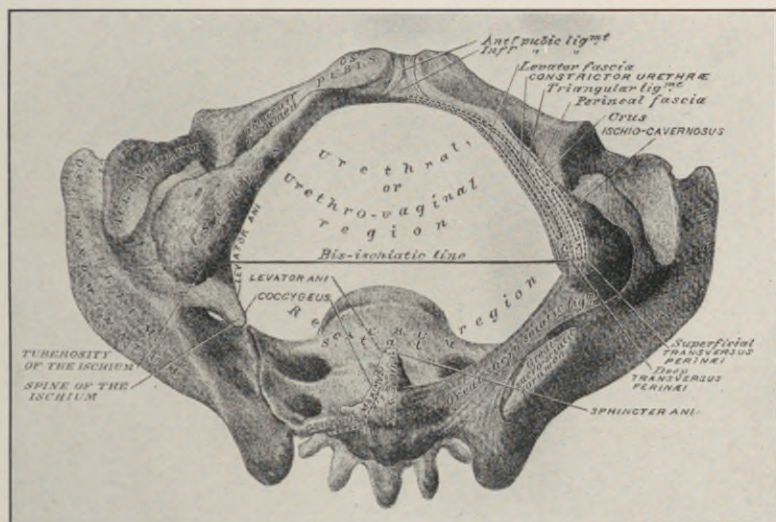


Fig. 50.—The pelvic outlet.

sheath, practically continuous with the transversalis fascia, thus lining the abdominal muscles above and enveloping the levator muscles below. The rectovesical and levator fasciæ fuse in the levator cleft.

Topographically it is essential to note:—

That the origin of the levator ani and its fascial sheath are on a level with the internal or upper surface of the pubic arch.

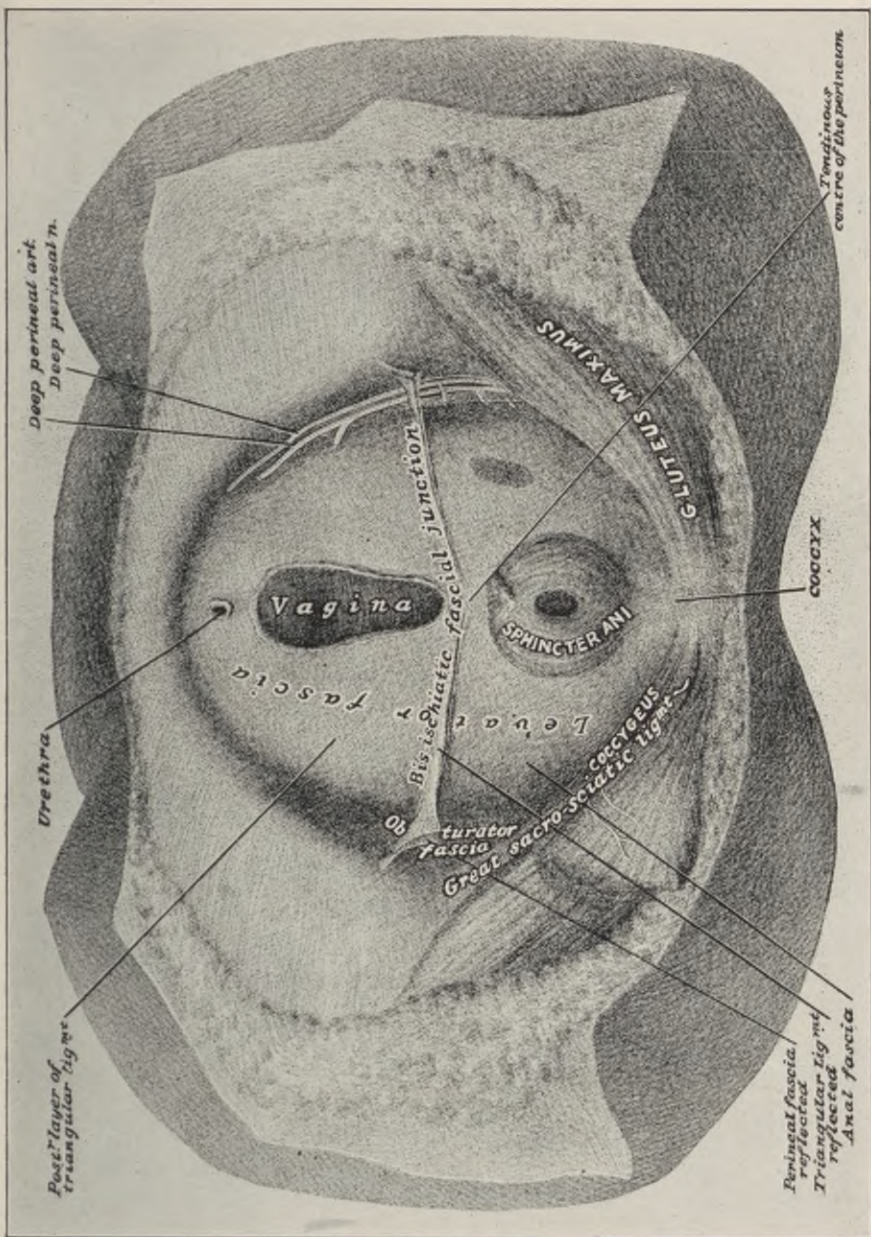


Fig. 52.—The levator fascia.

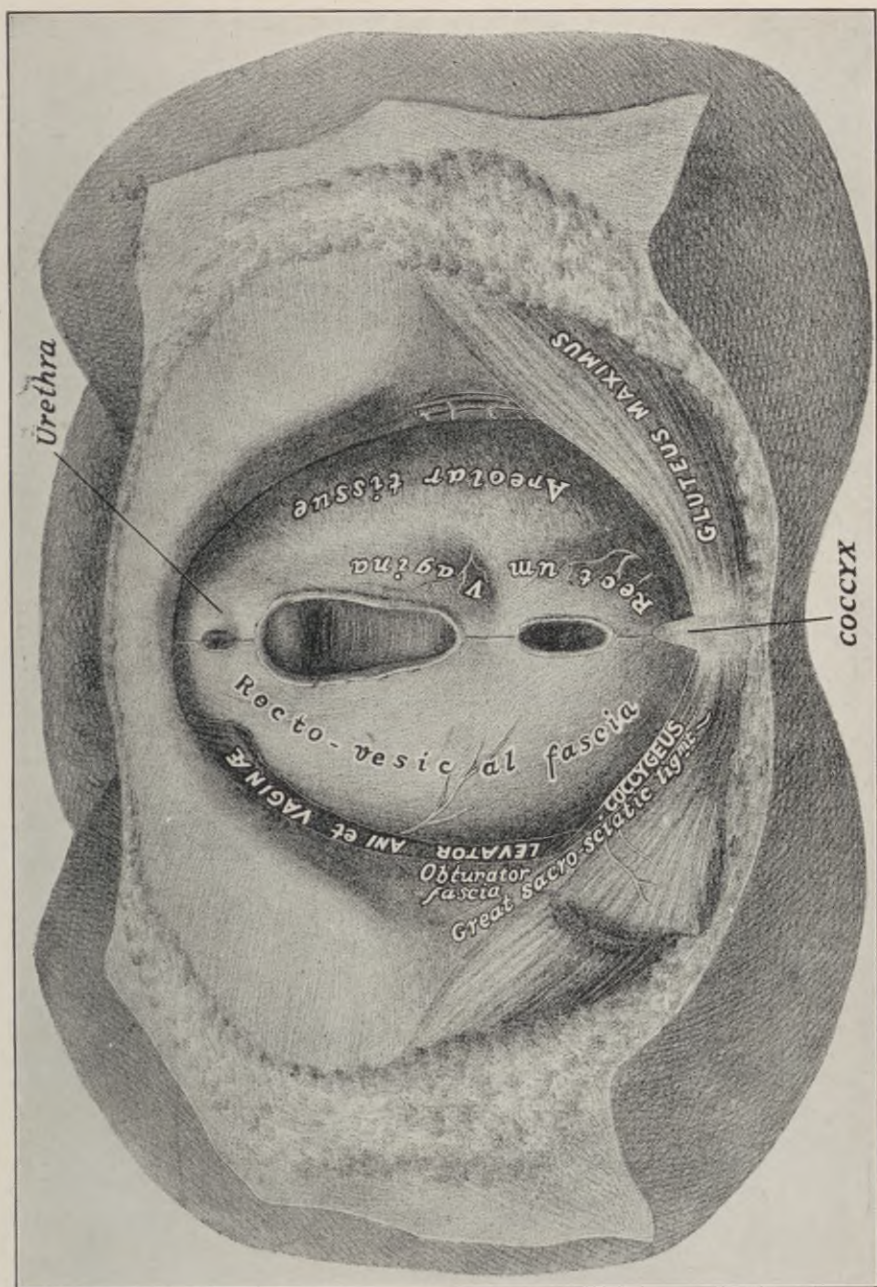


Fig. 54.—Anatomy of the female perineum. Exposure of the rectovesical fascia after removal of the levator muscle.

The pelvic outlet in the lithotomy position is lozenge-shaped, consisting of two triangles, base to base. The apex of the anterior triangle is at the symphysis; that of the posterior at the sacrococcygeal joint.

The anterior triangle presents the vaginal and urethral openings; the posterior triangle presents the anus.

The common base-line between the two extends just anterior to the ischial tuberosities, corresponding to the direction and position of the deep transversus perinei muscle.

The surgical path in the pelvic floor from the vulvar outlet to the levator fascia traverses two thin, indistinct fascial planes—first, the “superficial perineal fascia,” composed of two layers directly continuous with the general subcutaneous fascia, containing a layer of fat only; the second fascial plane is attached to the anterior or lower surface of the pubic arch; it envelops the “superficial transversus perinei,” the “bulbo-cavernosus;” the “bulbus vestibuli,” and the “bartholinian glands.”

The deep transversus perinei occupies the cleft between this second plane and the levator fascia.

These lower fascial planes and their muscles are isolated with difficulty in the cadaver, as they are intimately blended along their lines of contact, while in the living their definition is blurred by cicatricial distortion and attenuation.

Surgically, they are of secondary importance. The two transversus perinei are at best very weak subordinate adjuvants in intrapelvic support, while

the "bulbo-cavernosus," sometimes misnamed "sphinctre vaginae" or "constrictor cuni," simply controls the turgescence of the erectile tissue in the vulva and clitoris, exercising no supporting function whatsoever.

CHAPTER XIII.

LEVATOR MYORRHAPHY.

THE musculofascial elements located in the levator plane, constitute the surgical objective point in perineorrhaphy.

Before denuding the seat of lesion it is essential to locate the two levator shanks, each being distinctly palpable through the lateral vaginal walls, behind the hymenal border, where they converge downward toward the perineal centre, and may be followed upward and outward to their parasymphyseal origin on the posterior plane of the pubes.

The primary laceration separates the tissues at the levator junction on one or the other side of the median line, with subsequent retraction of both muscle shanks. This alters their normal relation to each other and to their surroundings.

Instead of forming an acute angle, with its apex fixed in the perineal centre, they run nearly parallel throughout their course.

The normal intravaginal perineal crest formed by this apex of the two muscle shanks, and constituting a fulcrum to the uterus, is obliterated, while the posterior vaginal wall is foreshortened.

Contrary to general impression, the torn levator muscle is more frequently hypertrophied than atrophied, especially in its upper portion, owing to its augmented compensatory function, due to its malposition.

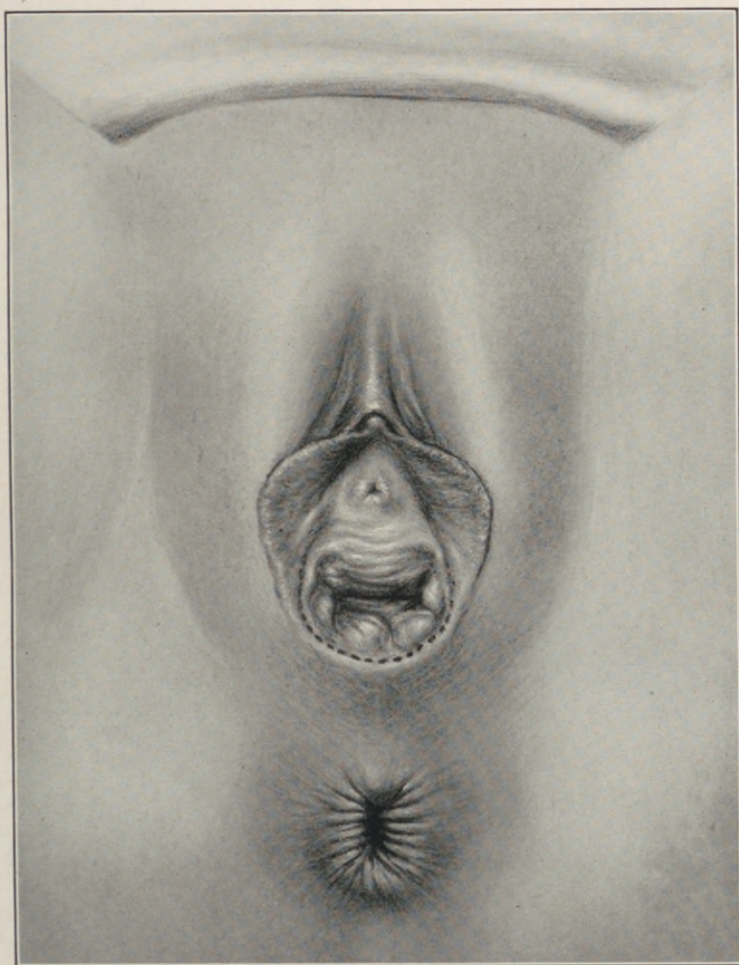


Fig. 55.—Perineoplasty (author's method). Outlining incision on the vulvar mucosa from corresponding points just outside the lateral hymenal edges to the cicatricial mucocutaneous centre of the posterior commissure.

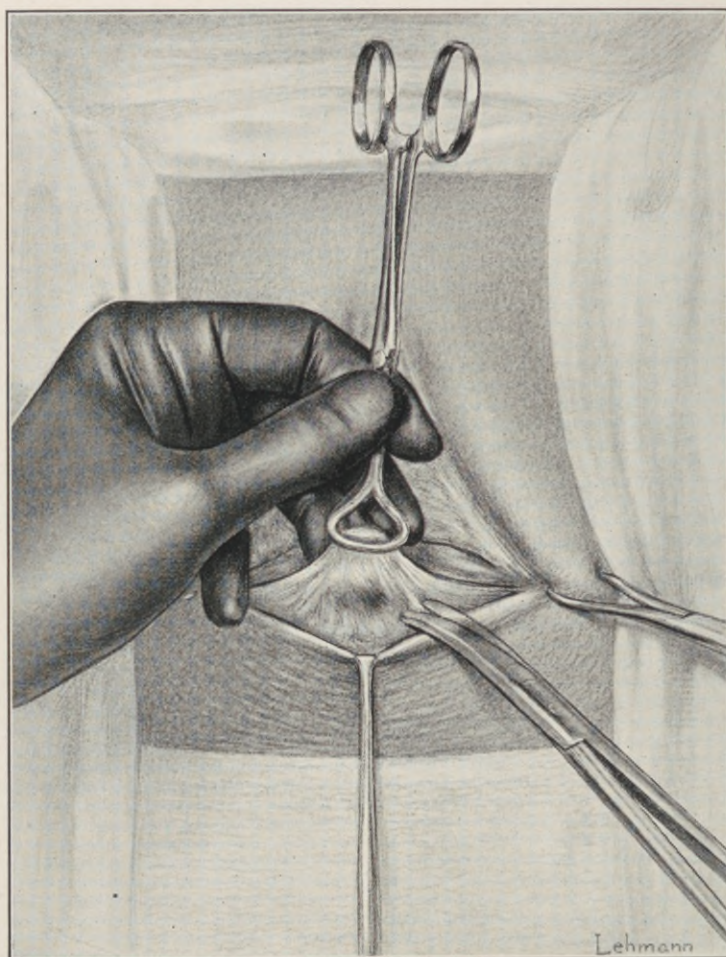


Fig. 56.—Perineoplasty (author's method). The outlined flap is carefully elevated from the underlying cicatricial and fascial layer by feather-edge dissection up to its base, as the thinnest possible (almost translucent) flap consisting of vaginal mucosa only.

Atrophy of either muscle shank occurs only as the result of direct destructive traumatism to the *muscle belly* by crushing with obstetric forceps.

To correctly expose the seat of lesion and the levator shanks, it is necessary to recall that the upper and under fascial sheaths enclosing the levator ani—namely, the rectovesical and levator fascia—

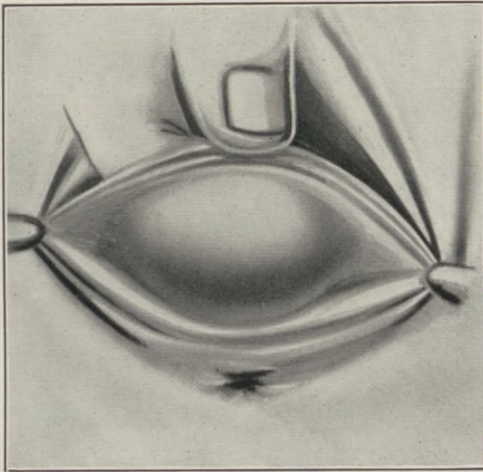


Fig. 57.—In elevating the vaginal mucosa, the flap is steadied by the left hand, the index finger exercising counter-pressure, controlling the course and progress of the denudation.

blend in the median triangular space between the inner muscle borders known as the levator cleft, the contiguous fascial surfaces being held in apposition by a sparse reticular layer, which offers a natural line of cleavage directly to the muscle.

The essential steps in the operative technique that demand detailed elucidation are:—

I. Elevation of a thin, almost translucent triangular flap of mucosa from the posterior vaginal wall.

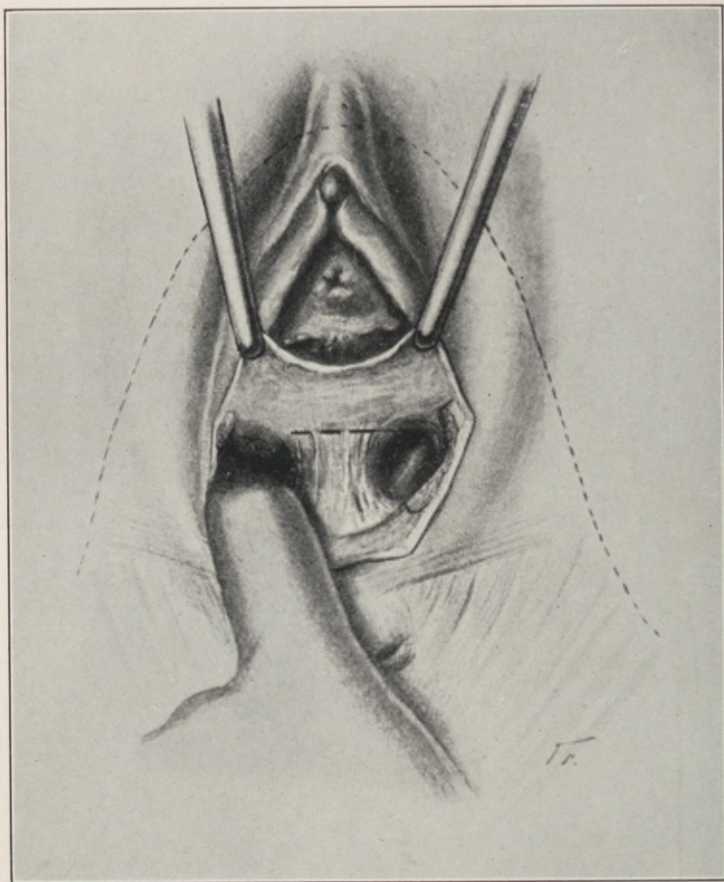
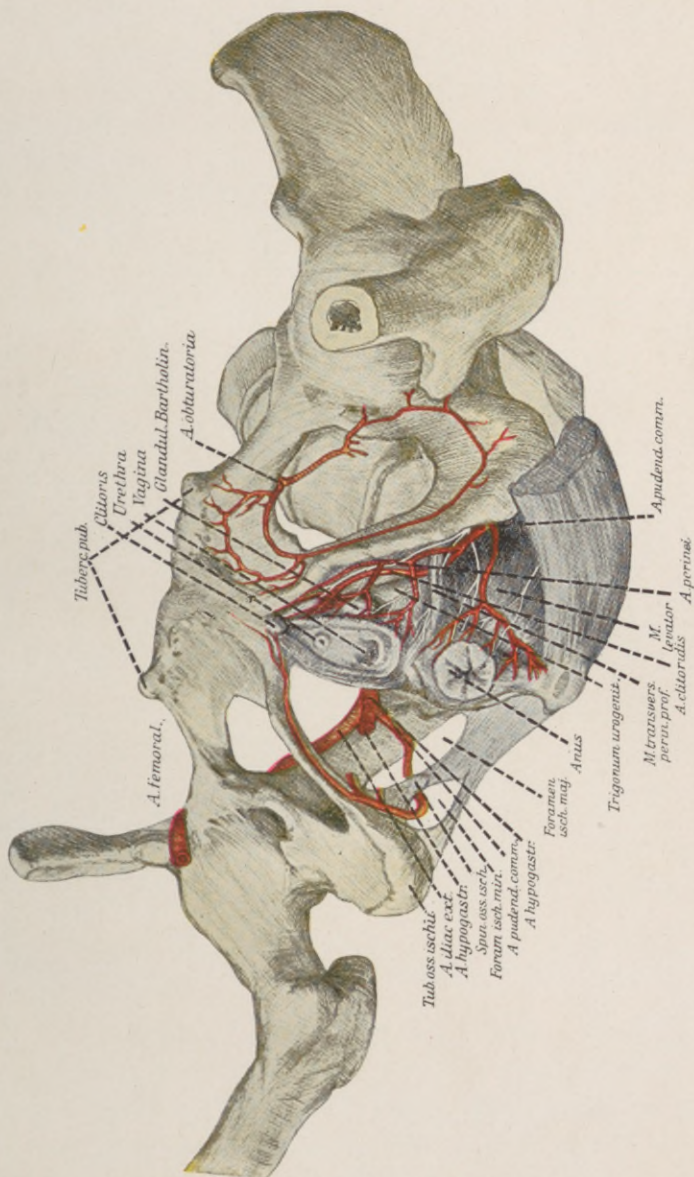


Fig. 58.—The flap dissection is necessarily sharp through the dense cicatrized area, until the uninvolved yielding reticular structure at the lower pole of the rectovaginal septum is reached, whence it is continued bluntly on either side of the centre to the crest of the rectocele.

PLATE XIX.



Arterial supply of the perineal region. Note relation of the internal pudic artery to the course of the levator ani muscle.

- II. Exposure and mobilization of the puborectal levator shanks.
- III. Sutural readjustment of the muscle.
- IV. Coaptation of the vaginal flap.
- V. Closure of the superficial perineal layers.

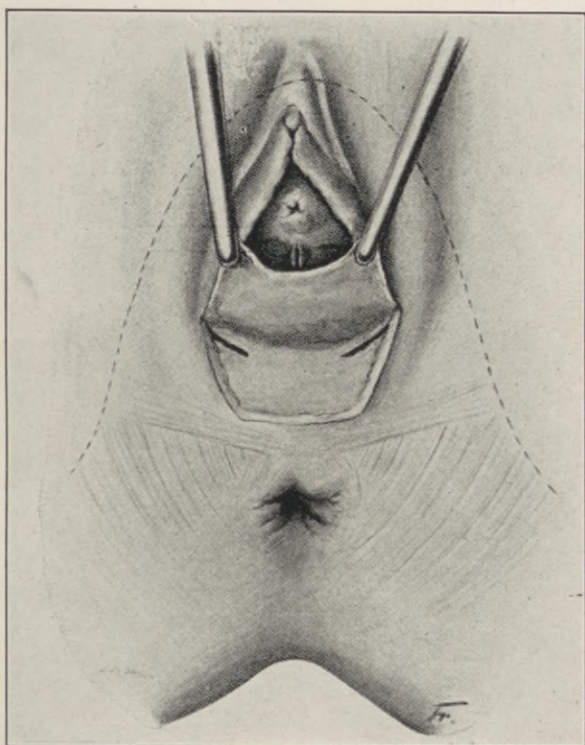


Fig. 59.—Fascial slits for levator exposure, necessitated by improper denudation.

Preliminary to the first step, any concomitant displacement of the uterus or bladder, as well as pathological condition of the cervix, must be corrected by measures which will be considered under their respective captions.

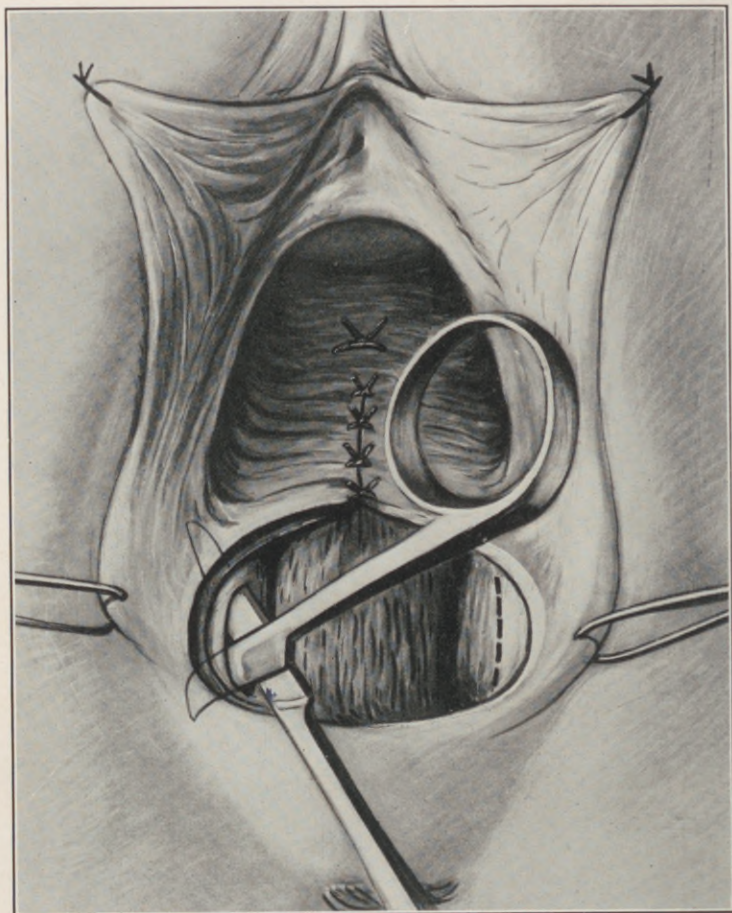


Fig. 60.—Incorrect method of exposing the levator muscle by slitting the fascia.

The delineation of the flap is facilitated by hooking a tenaculum on each side of the vaginal orifice into the labia majora, and a third into the centre of the posterior mucocutaneous margin.

A very superficial outlining incision is carried by light strokes of the knife on the vulvar mucosa from corresponding points just outside the lateral hymenal edges to the mucocutaneous centre of the posterior commissure. This constitutes a triangular area, with its apex and base just the reverse to that of Hegar.

The lowest hymenal caruncles are too frequently situated at different levels to be standardized as fixed starting points in all cases.

The triangular surface thus outlined must be carefully elevated from all underlying tissues by feather-edge dissection up to its base as the thinnest possible, almost translucent flap, consisting of vaginal mucosa only.

The flap dissection at first is necessarily a sharp one, through the dense cicatrized area until the uninvolved yielding reticular tissue in the lowest pole of the rectovaginal septum is reached, when it may be continued bluntly upward to the natural point of contact between the anterior and posterior vaginal wall, commonly designated as the "crest of the rectocele."

Owing to the proximity of the rectovaginal venous plexus, it is neither advisable nor necessary to continue the cleavage of the tissues upward in the *median line* above this point of the rectovaginal septum at this stage of the procedure.

If a sufficiently thin flap of mucosa has been separated from the posterior vaginal wall, at the correct anatomical level, the exposed submucous surface will

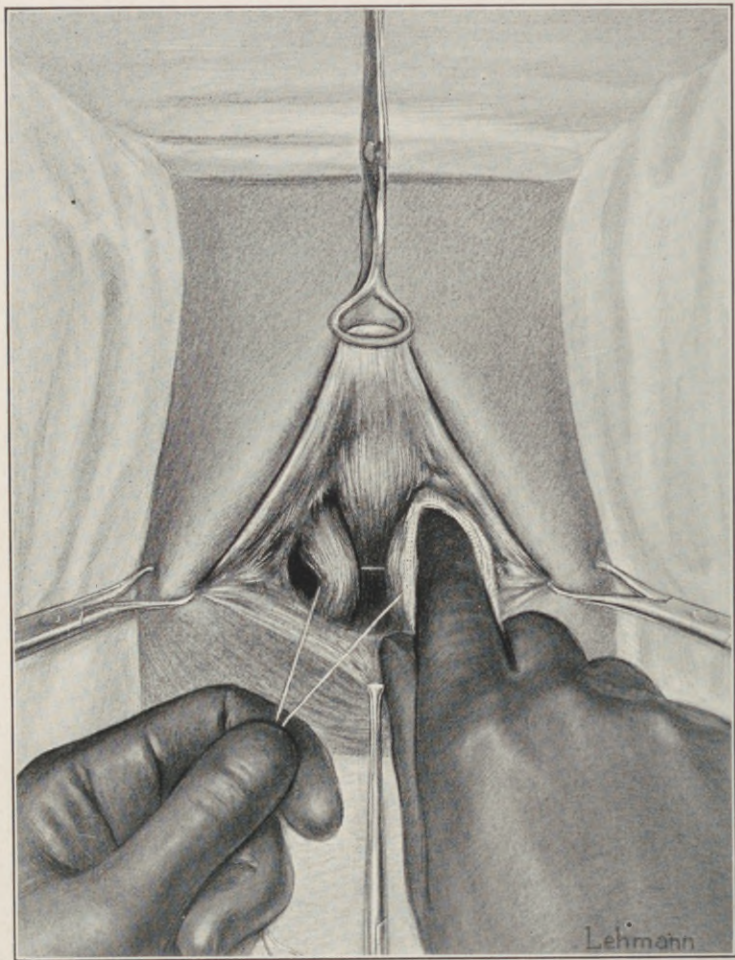


Fig. 61.—Perineoplasty (author's method). Suture traction on the retracted upper part of the levator ani, and blunt mobilization of its left shank by a gauze-covered finger.

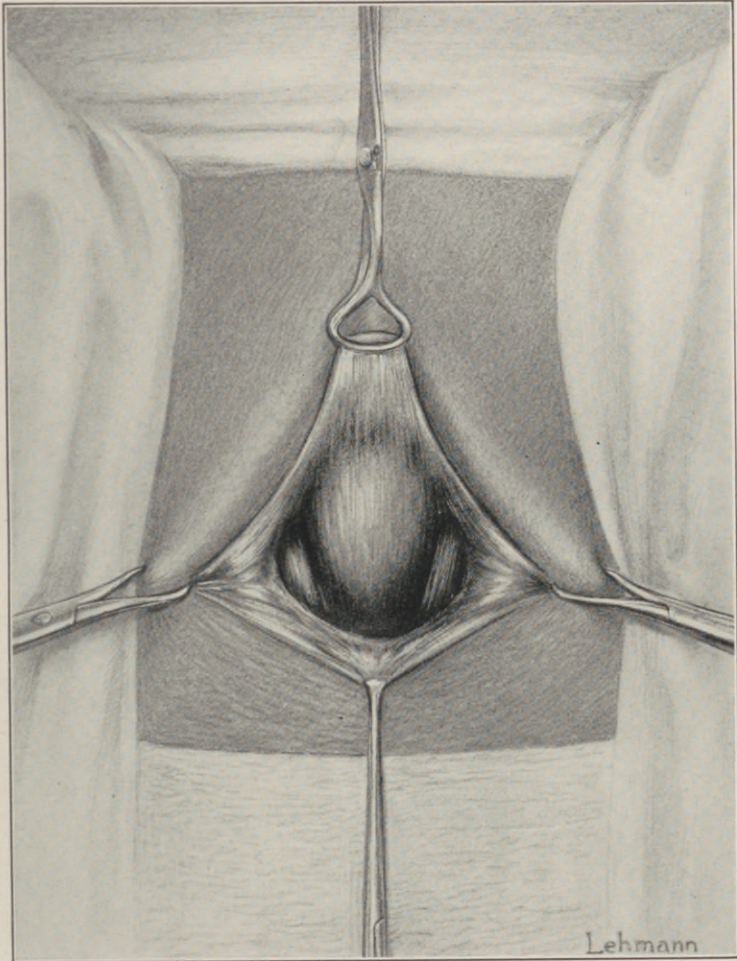


Fig. 62.—Perineoplasty (author's method). The levator ani partly exposed, covered by a thin perimyseal sheath.

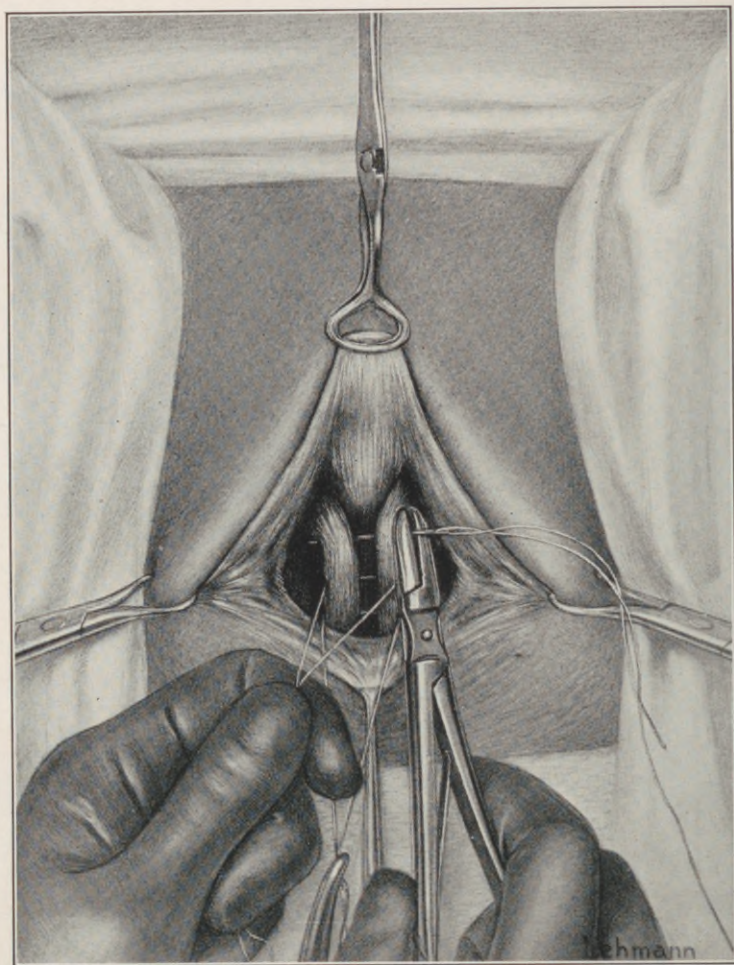


Fig. 63.—Perineoplasty (author's method). The sutures passed entirely round (not through) the muscle-shanks, encircling them so as to secure the broadest possible side-to-side surface contact under the vaginal floor.

lead directly into the normal line of cleavage between the two levator sheaths, where the finger tip may be insinuated and pushed gently in a direction outward and upward, on each side of the median line, toward the posterior surface of the pubic rami, and expose the muscle near its origin.

Here it is necessary to observe that the pull on the flap during its elevation imperceptibly drags the submucous tissues forward in a manner to overlap the essential plane of cleavage to the levator ani. This overlapping tends to divert the further course of dissection into the lower fascial and cicatricial planes, which blurs the definition of the muscle, and necessitates supplemental fascial incisions for its exposure and mobilization, all of which are circumvented by frequently releasing the pull and carefully grasping and clipping all attached reticular meshes with mouse-tooth forceps and scissors, as close as possible to the under flap surface.

Barring the penetration of an occasional traumatic varix in the reticular structure, which is easily controlled by pressure, and a small spurting branch of the internal pudic artery, no bleeding of import is encountered in this procedure.

The *vaginal flap* is *not* excised.

The upper pole of the muscle, exposed by the blunt penetration, with the finger tip between the levator and rectovesical fascia, is found completely enveloped in a hitherto undescribed thin, smooth perimyseal membrane, which for convenience may be termed the surgical sheath. Neither this sheath nor its contiguous fascial coverings should be perforated during any step in the operation. At times

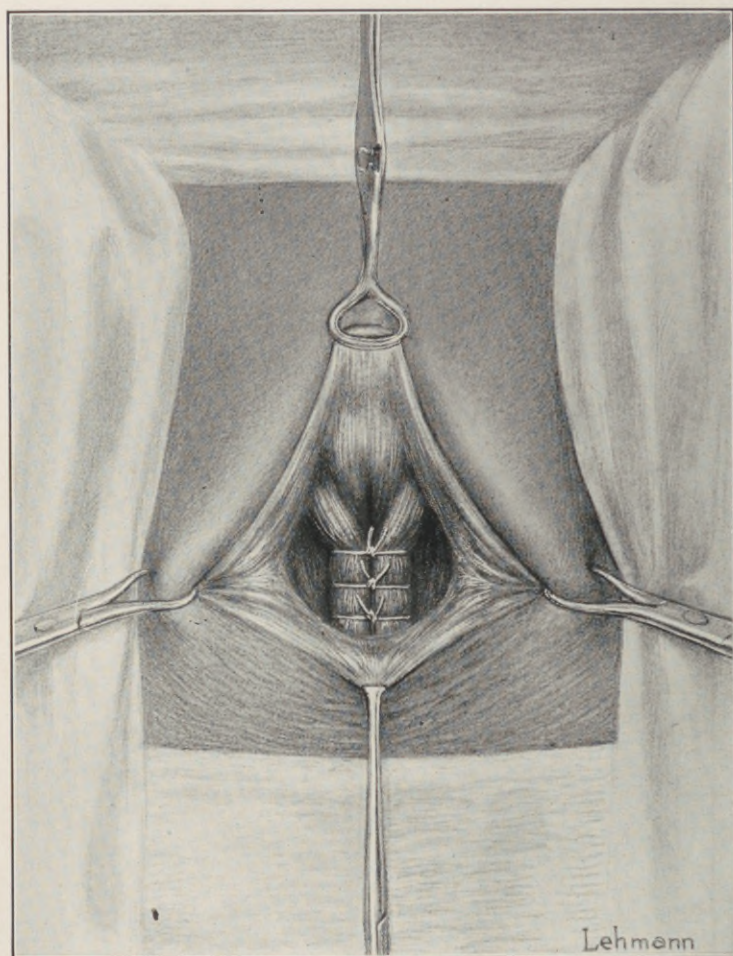


Fig. 64.—Perineoplasty (author's method). Levator sutures *in situ* and tied.

the digital retraction of the wound edges creates deep fascial folds which may simulate the levator shanks so closely as to confuse the operator. This is averted by palpating the exposed muscle to its posterior pubic origin.

The identity of both muscle shanks thus established, their outer borders should be mobilized along their entire length to an extent permitting of their median approximation without tension.

The method practised by a number of surgeons, in which a thin edge of muscle is drawn through a slit in the lateral fascia on each side and sutured without previous mobilization, is not to be commended, as it results in the formation of a thin crescentic diaphragm behind the introitus, productive of disagreeable sequellæ.

On the other hand, the muscle must not be enucleated or dislocated from its normal bed; its natural mobility is simply amplified by gently stretching its connections to contiguous structures.

The operative field, correctly exposed before suture, should present a denuded irregular triangle, with its base line at the junction of vaginal flap and rectovaginal septum, its sides the inner borders of the levator shanks, edged by the furled layer of the levator fascia.

From three to four interrupted, forty-day chromic gut sutures coapt the muscles and close the intermuscular gap in front of the rectocele. Each suture is passed from side to side, *not through* but *entirely around both muscles*, encircling them so as to secure their broadest possible surface contact under the vaginal floor.

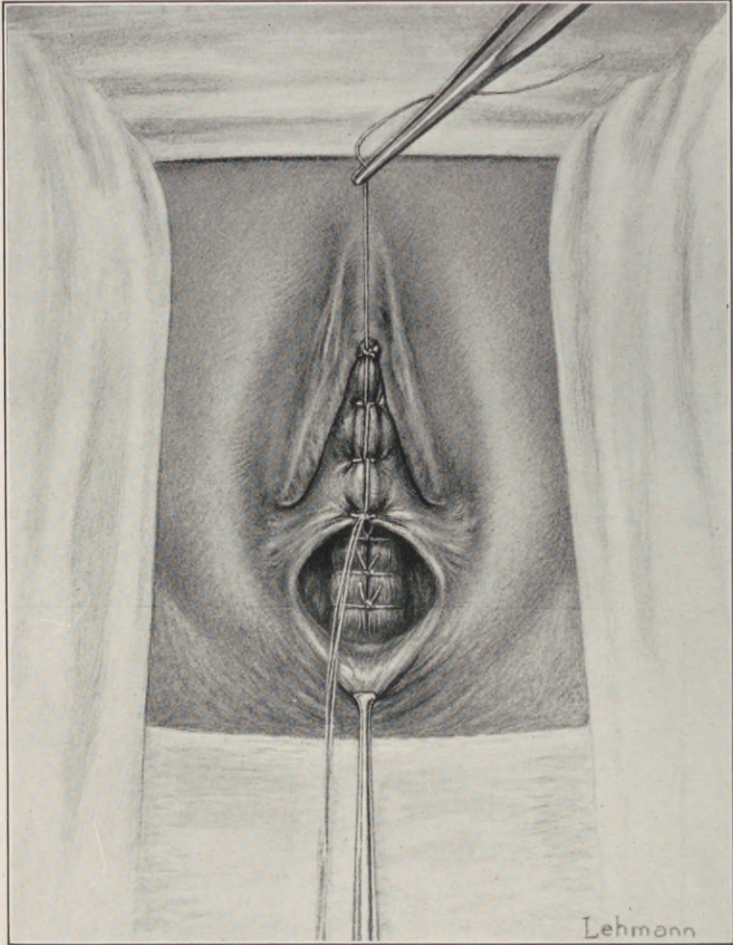


Fig. 65.—Perineoplasty (author's method). The elevated flap of vaginal mucosa is not ablated. Its edges are sutured from its central tip downward to form a hollow cone.

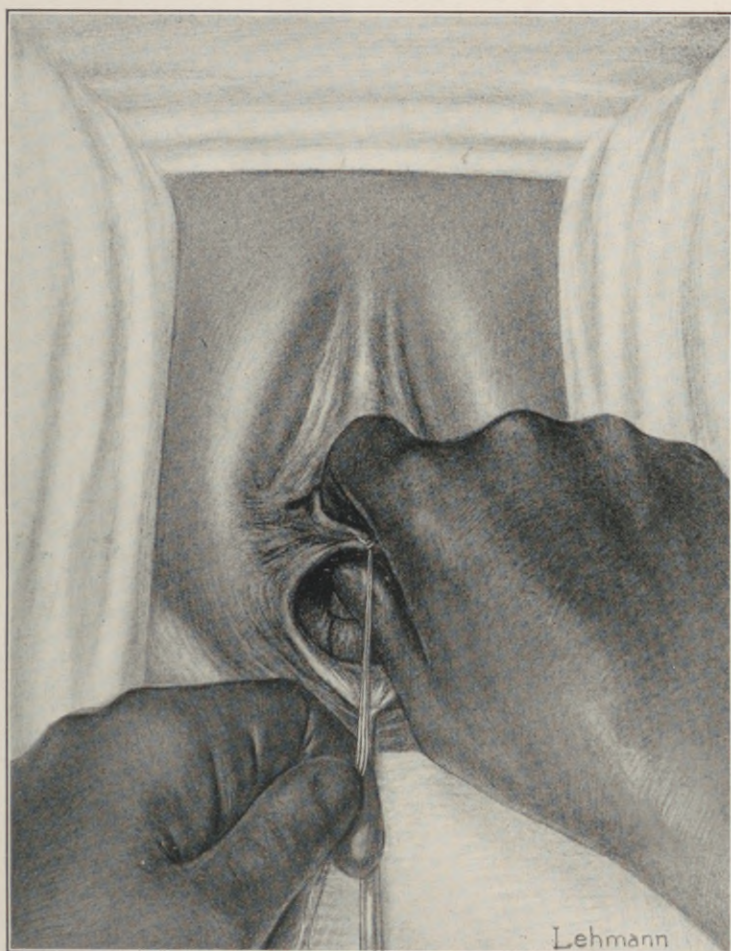


Fig. 66.—Perineoplasty (author's method). The hollow cone of vaginal mucosa is inverted upon itself, tucked into the vagina, and snugly applied to the *posterior* surface of reunited levator ani muscle.

The rectocele should not be caught in the suture nor pinched between the muscles, the uppermost suture being inserted just high enough to normally appose the lower to the upper vaginal wall when the flap is replaced.

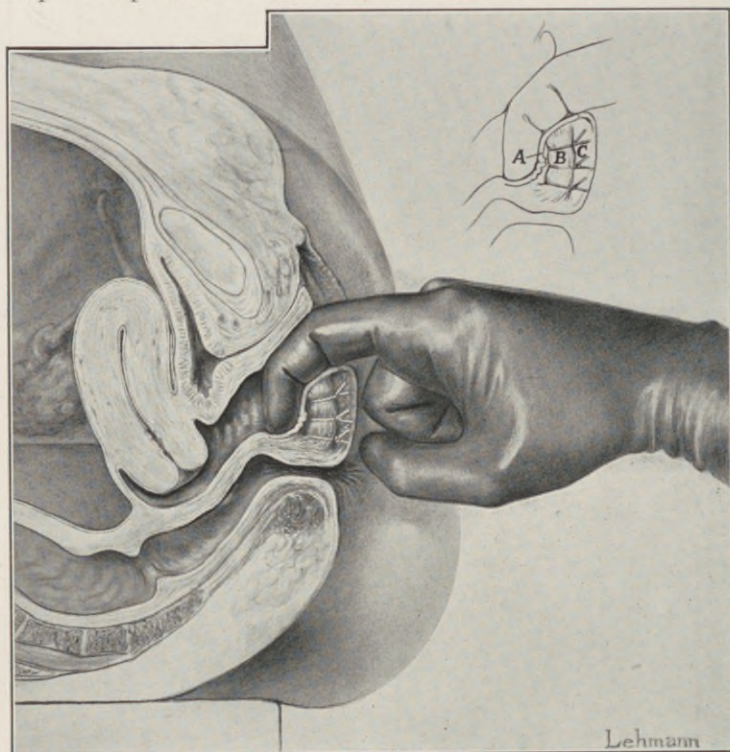


Fig. 67.—Perineoplasty (author's method). Diagrammatic sagittal section, showing the inversion and application of the inverted flap of vaginal mucosa to the posterior surface of the reunited levator ani. A, Inverted flap. B, Levator ani. C, Superficial perineal coverings.

In adjusting the superficial coverings *no vaginal mucosa is removed*. The transverse wound is converted into a perpendicular slit by properly applied

traction, and the edges united side to side by continuous or interrupted suture.

The proper adjustment of the flap is clearly indicated by observing the normal vaginal contours.

In sagittal section, the edge of the posterior vaginal wall presents an undulating line running convexly in front over the eminence of the intravaginal perineal crest, concave posteriorly where it dips into the declivity of the posterior vaginal *cul-de-sac*.

In the lacerated perineum, on the other hand, the intravaginal crest is obliterated by the diastasis of the levator junction, the posterior vaginal wall plus its mucosa is foreshortened, and the undulation is levelled to a flat surface.

The sutural reunion of the levator junction restores the intravaginal crest and the natural undulation of the posterior vaginal wall.

The area of an undulating surface is greater than that of a flat surface. It follows that the vaginal floor thus requires *more mucosa after its restoration* than before. Moreover, the normal vagina is not a canal of smooth bore, but rugous.

To ablate the flap is not only unanatomical, but unsurgical; for, the remaining mucosa, too short to adapt itself in lining the posterior or descending surface of the intravaginal crest, must span the hollow at its base, creating a dead space of variable depth and pathological potentialities.

To secure a normal adjustment of the flap, its median edges are brought together by a thin catgut suture extending from the central tip to the lowermost hymenal caruncles, which are thus brought into their natural apposition, where the suture is tied.

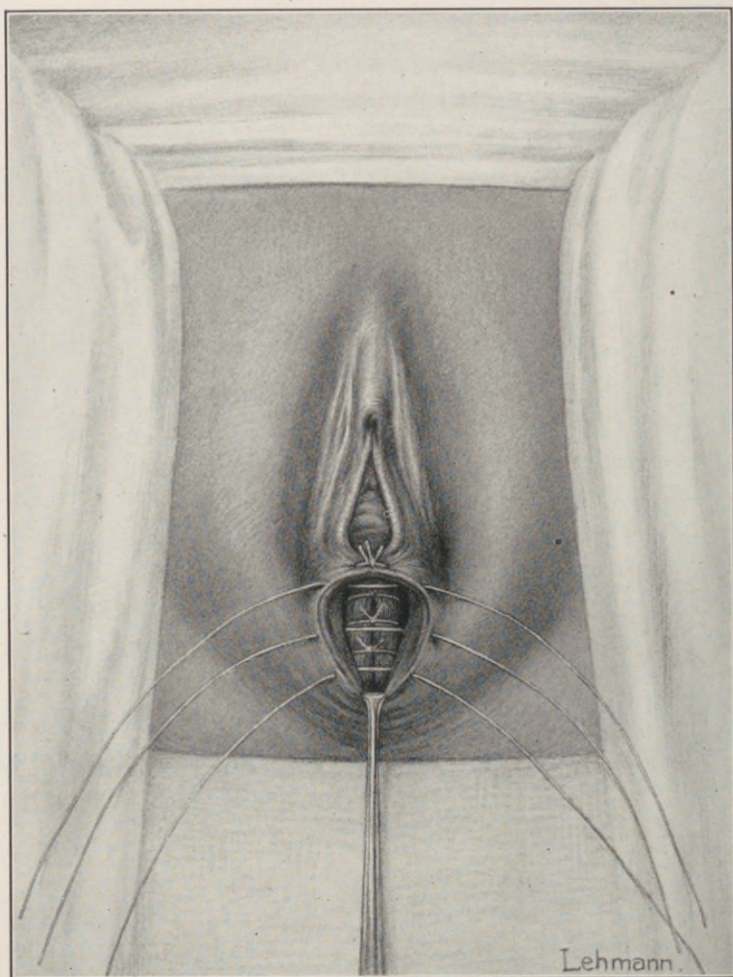


Fig. 68.—Perineoplasty (author's method). Sutures introduced to unite the musculofascial layers superficial to the levator suture. These sutures do *not* include the levator muscle.

The resulting hollow cone of vaginal mucosa is turned inside out, thus inverting its apex and exposing its entire raw surface; this is tucked into the vagina, and snugly applied against the posterior surface of the reconstructed crest down to the hollow at its base,

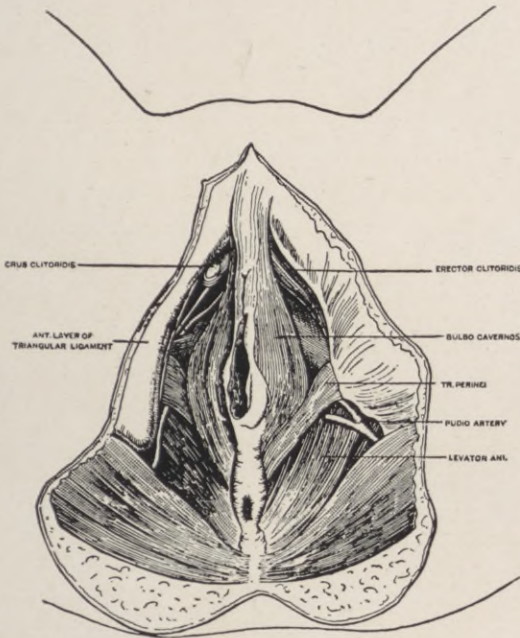


Fig. 69.—Diagram of the vulvoperineal musculature. Note the position, relation, and origin of the transversus perinei as compared with the levator ani.

where it is retained by a small packing of iodoform gauze.

The entire vaginal canal is thus completely restored, and it remains to readjust the levator fascia and superficial layers to the cutaneous perineum.

The very extended controversy on the relative importance of fascia and muscle in gynecic support

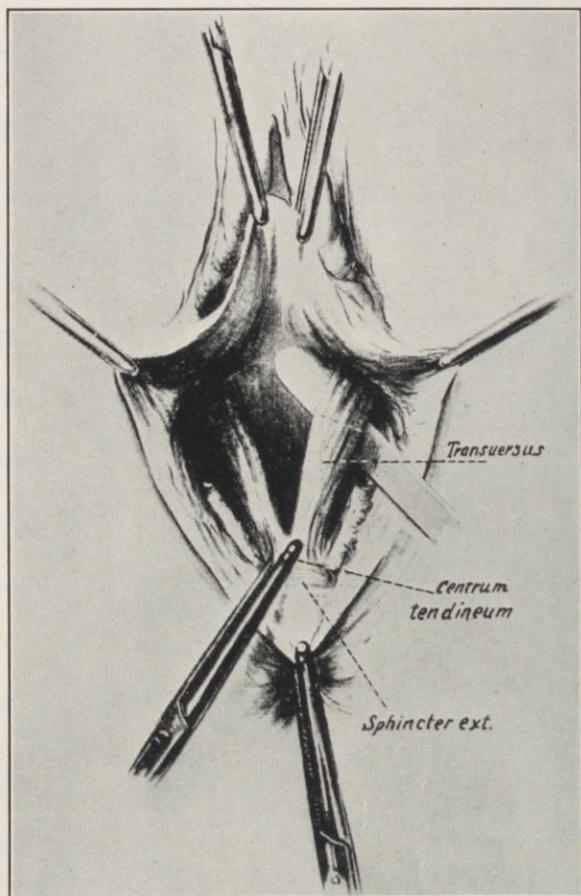


Fig. 70.—The transverse perinei here depicted is often mistaken for the levator edge. Isolated suture of these bundles give a weak, insufficient perineum. (*Doederlein and Kroenig.*)

has only tended to obscure the salient fundamentals of the question.

Physiologically and dynamically, fascia and muscle constitute a functioning unit. The elastic resiliency of the former is complementary to the contractility of the latter.

The direction and arrangement of the muscle-fibres determine and limit the line of muscular con-

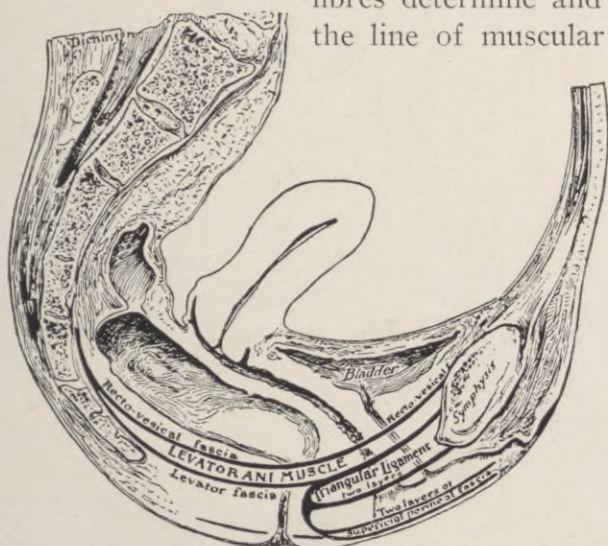


Fig. 71.—The fascial layers in relation to the levator ani.

tractions, which are amplified and extended radially by its fascial sheaths.

The exploitation of the fascia to the exclusion of the direct levator suture in perineorrhaphy on the parallel of its utility in ventral hernia ignores the textural and topographic contrasts presented by the two areas.

The abdominal fascia ordinarily offers the necessary strength and redundancy essential to successful

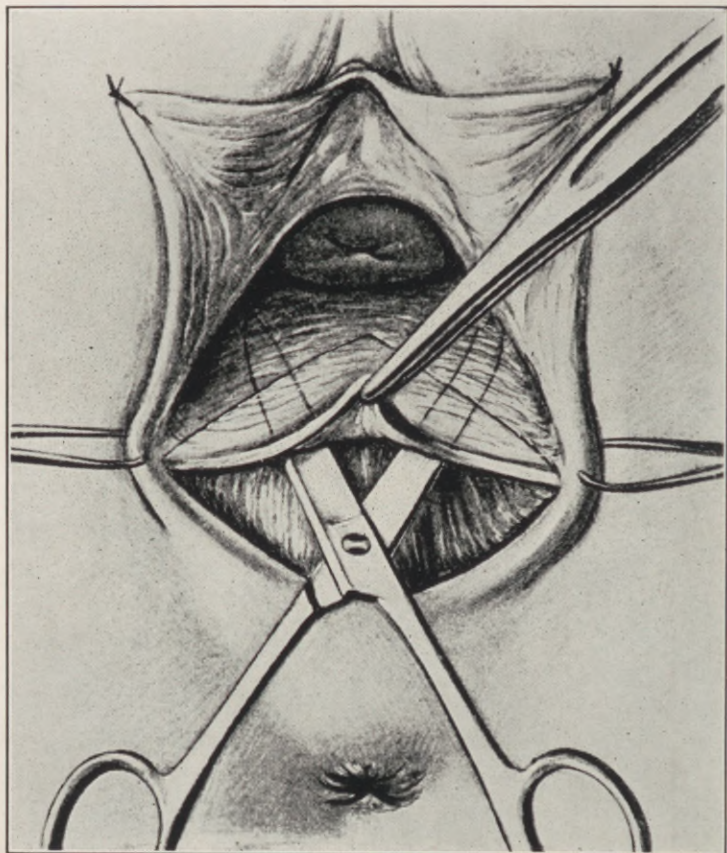


Fig. 72.—Incorrect denudation, leading into wrong cleavage lines, and necessitating additional incisions into the levator fascia to expose the muscle.

overlapping in ventral hernia, while the pelvic floor fascia does not.

The torn levator fascia, limited in extent by its firm attachment to the pubic arch, attenuated by retraction, and partly obliterated by cicatricial fusion, does not offer the reconstructive essentials to permanent support. This is substantiated by the shortcomings in the functional results of the classic fascial perineorrhaphies.

Efficient overlapping is impossible. "A chain is as strong as its weakest link." Fascial suture cannot reproduce fascia, but only an edge-to-edge cicatricial junction at best.

An unbiased criticism of the results following the classic fascial methods of perineorrhaphy in vogue will concede a more or less perfect cosmetic restoration of perineal contours and bulk, in which, however, the all-essential physiologic muscular element in pelvic support is supplanted and immobilized by a vicarious cicatricial plug at the vaginal outlet.

Such result fulfills all the indications for those who continue to see a "perineal body forming a triangular wedge, composed of fascia and areolar tissue," instead of a muscular pelvic floor, and who still adhere to the theory that ascribes the rôle of the perineum in the co-ordination of gynecic support to *form* rather than *function*.

Obstructive retention at the vaginal outlet cannot permanently replace normal physiologic support, and the aim in perineorrhaphy must be the restitution of such anatomic relations as to restore, as far as possible, physiological as well as mechanical support to the pelvic contents.

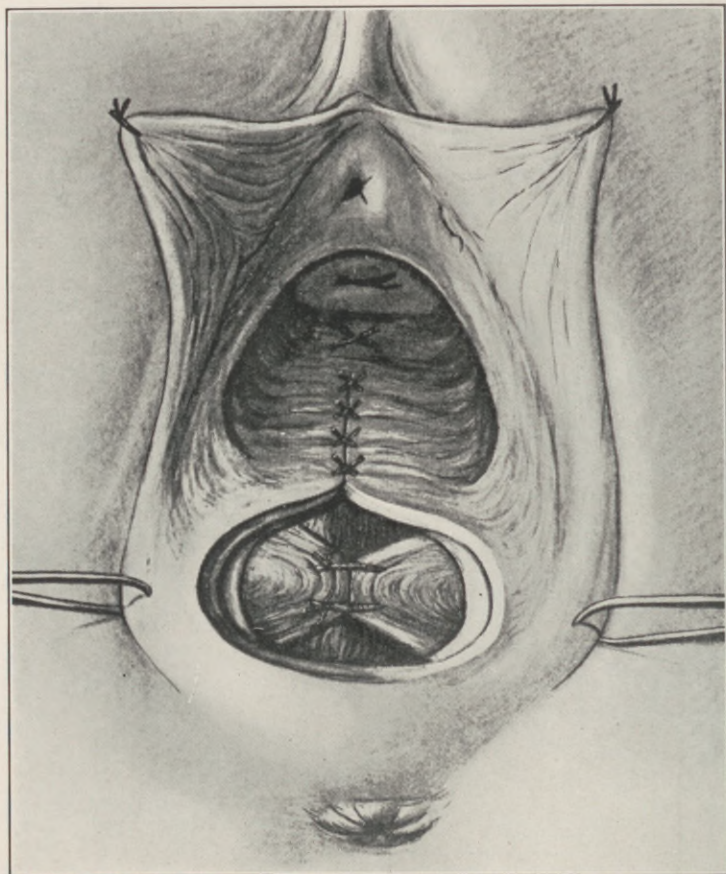


Fig. 73.—Incorrect exposure and improper suture of the levator ani. The levator edges are here drawn through a slit in its fascia, resulting in a thin cicatricial crescentic diagram at the vulvar outlet.

The original perineal rent is anteroposterior. Subsequent levator retraction converts this sagittal rent into a transverse slit. The operative denudation and properly applied anteroposterior traction by tenacula reconverts the transverse wound into a perpendicular slit, which thus restores the original relations of the fascial edges for suture in the median line.

Whether the fascial structures and skin are finally united by one or two rows of interrupted sutures is simply a matter of individual preference, the main object being accurate layer coaptation.

The interposed levator muscle in the rectovaginal septum provides contractile resistance over the two hernial areas in the vaginal canal—namely, the uterovesical above and the uterorectal below—fulfilling its function in gynecic support, and restoring the anatomic contours of the lacerated perineum.

CHAPTER XIV.

THE RETRODISPLACED UTERUS AS A COMPLICATION IN PELVIC FLOOR INJURY.

THE development of uterine prolapse consequent upon a perineal laceration is invariably preceded by a stage of retroversion.

On the other hand, every retroverted uterus does not necessarily prolapse. A concomitant cervical laceration, chronically infected and productive of adnexal disease with peri-uterine adhesions, may suspend the uterus and prevent its ultimate descent.

The treatment of retroversion is the correction of its cause.

The cause may be congenital or acquired.

Our fundamental conceptions of uterine poise, normal and abnormal, have not as yet attained to any concrete finality, and, barring the occasional allusion to the existence of congenital retrodisplacements and their probable dependence upon conditions of general viscerotaxis, the clinical significance of such displacements, and their diagnostic, etiologic, and therapeutic contrast to the acquired form, find no elucidation in the literature on the subject.

The wide diversity in the nature of the two conditions, presenting practically identical symptoms, demands their clinical differentiation. Such differ-

entiation necessitates a differentiating factor of pathognomonic constancy.

A uterus congenitally retroposed before impregnation will resume its retroposition after delivery, whether the pelvic floor is lacerated or not.

Loss of perineal support in the congenital class is more prone to the development of procidentia than in the acquired form.

The correction of congenital retroposition as such is essentially orthopedic, while that of the acquired form is gynecologic. Hence this differentiation is important.

Approximately, 18 per cent. of all gynecological patients present a retrodisplaced uterus.

Barbour and Watson estimate one-fifth of this number as congenital in origin, qualifying their statement, however, by admitting that "it is difficult to establish the congenital nature of these cases; but should a uterus be found retroverted in a nulliparous patient, without any history of inflammation or other cause sufficient to produce retroversion, should it measure only $2\frac{1}{2}$ inches by sound, and on being replaced show a tendency to resume its retroverted poise, we are justified in assuming that it has developed in that position."

These admittedly vague differential criteria embody in their very paucity the crux of the clinical problem presented by uterine displacements in general to-day.

In the first place, a retrodeviated uterus, whether in a nulliparous or multiparous patient, "without evidence of inflammation or other cause sufficient to produce the displacement," would be classified as a

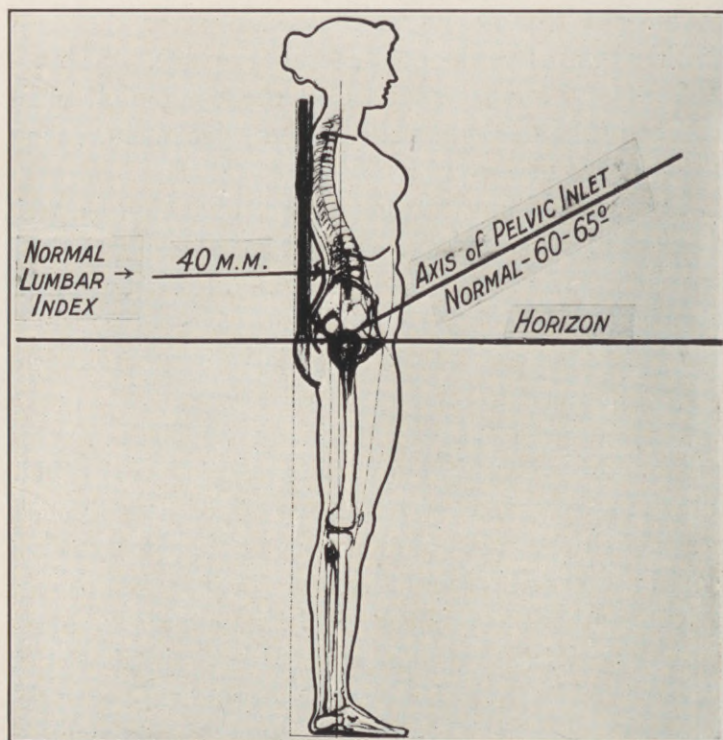


Fig. 74.—Normal or neutral type of posture. Distinguishing features are: (1) Line of gravity of body passes through important pivotal points; (2) the pelvis is balanced in equilibrium on the heads of the thigh bones; (3) this relation of important pivotal points with the line of gravity and this balance of the pelvis prevents muscle and ligament strains; and (4) the rear perpendicular touches the middle back and the buttocks. (Modified from Dickinson and Truslow.)

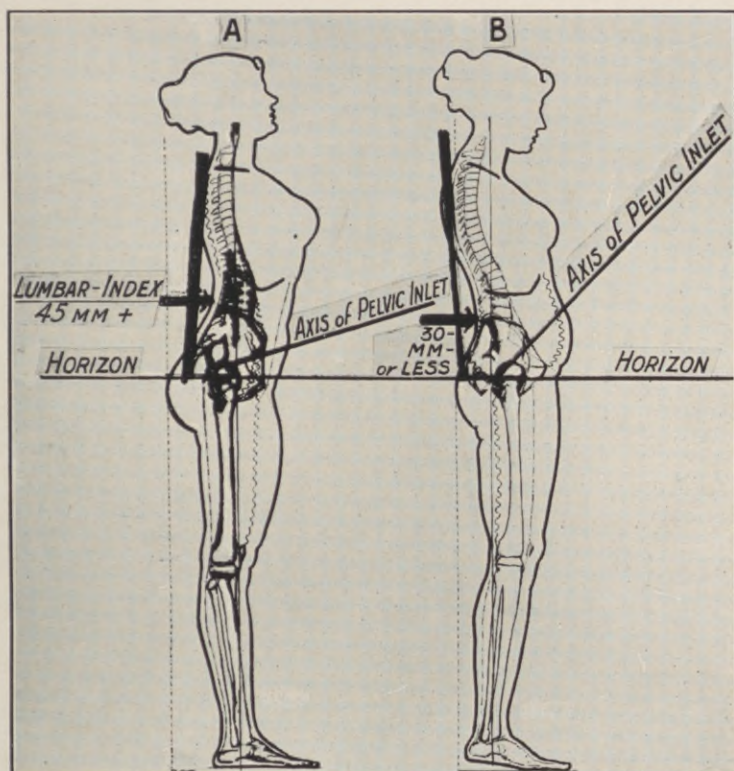


Fig. 75.—A, Kangaroo type of posture. Distinguishing features are: (1) Most pivotal structures of the trunk are carried in front of, and those of the lower extremities behind, the line of gravity; (2) the pelvis rotates forward downward; (3) the forward carried trunk puts strain on the spinal and pelvospinal ligaments and muscles, and tends towards forward displacement of abdominal and pelvic viscera. Wavy lines indicate muscles relaxed; double lines, muscles in action. B, Gorilla type of posture. Distinguishing features are: (1) Most of the pivotal structures of the trunk are carried back of, and those of the lower extremities in front of, the line of gravity; (2) the pelvis rotates backward downward; (3) the backward carried trunk puts its own variety of strain on the spinal and pelvospinal ligaments and muscles, and tends toward backward and downward displacement of the abdominal and pelvic viscera. Wavy lines indicate muscles relaxed; double lines, in action. (Modified from Dickinson and Truslow.)

simple or uncomplicated malposition, regardless of its probable congenital nature.

Such classification has a most significant therapeutic bearing, for, accepting the clinical postulate, that all *uncomplicated* uterine retrodisplacements are devoid of symptoms or clinical significance, it follows that to differentiate the congenital from the acquired retrodisplacements is to exclude any attempt at correction of the displacement as such in over one-fifth of the cases.

On the other hand, a congenitally retrodisplaced uterus is not necessarily "nulliparous," nor immune to "inflammatory and other complications capable of producing retroversion." It may, like any other uterus, measure more than "2½ inches by sound," so that the congenital origin of its retroposition must be established through existing diagnostic factors that are constant and remain unaltered by complicating elements which tend to efface the characterizing syndrome formulated by Barbour and Watson.

As a matter of fact, it is that very class of patients, with their congenital deviations obscured by superposed parturitional and infectious complications, in which differentiation is most essential.

In seeking to establish such a constant pathognomonic factor it is necessary to recognize that the malposition does *not* represent simply a congenital uterine retroversion, but a congenital retroversion of the *entire pelvis*, with resultant *compensatory dys-*topia of its contents.

Dickinson and Truslow characterize the general skeletal poise of these cases as "the gorilla type," in

which "the pelvis is rolled or rotated backward and downward, the plane of its inlet making with the horizon an angle more acute than that of the normal type."

In other words, with normal spinal contours, the axes of the abdominal and pelvic cavities form al-

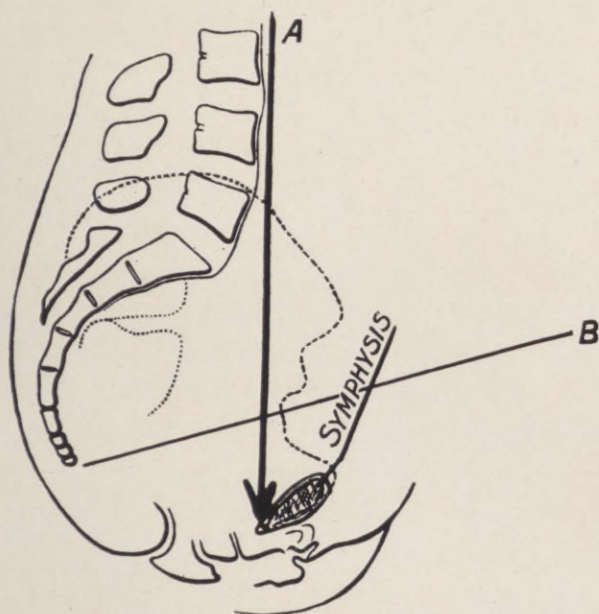


Fig. 76.—*A*, Axis of abdominal cavity. *B*, Axis of pelvic cavity.

most a right angle, while in the stature under consideration there is a marked flattening of the sacrovertebral angle, resulting in an approximation of these axes toward the vertical, so that the thrust of intra-abdominal pressure is expended in a more direct line on the pelvic viscera.

This flattening of the sacrovertebral angle, is

regularly evidenced by a corresponding obliteration of the normal lumbar curve, and the measure of its resultant approximation to the vertical constitutes a diagnostic index in differentiating congenital from acquired retrodisplacements of the uterus.

To obtain this measure, the patient, with back exposed, assumes her natural standing attitude, while the edge of an ordinary 18-inch desk ruler, held vertically in contact with the most prominent spinous processes of the dorsal and sacral convexities, spans the intervening lumbar hollow.

The distance in millimeters from the deepest point of this hollow to the edge of the ruler presents our index.

The spinous processes of the dorsal and sacral convexities are invariably and distinctly palpable under all degrees of adiposity and statural deviations, while the extreme simplicity of the method and means enables anyone to substantiate the uniform accuracy of the index, and elicit the significance and indications of its clinical bearings.

In an extensive series of observations, the index ranged from 12 to 45 millimeters. An excess of 45 millimeters indicates pathological lordosis—a condition the opposite to that under consideration, of more obstetric and less gynecological importance.

An index of 30 millimeters marks the extreme minimum compatible with normal *anteversion* of the uterus. *From 25 millimeters down, the existence of congenital retroversion may be positively predicated in nearly every case prior to its bimanual verification, and this regardless of multiparity*

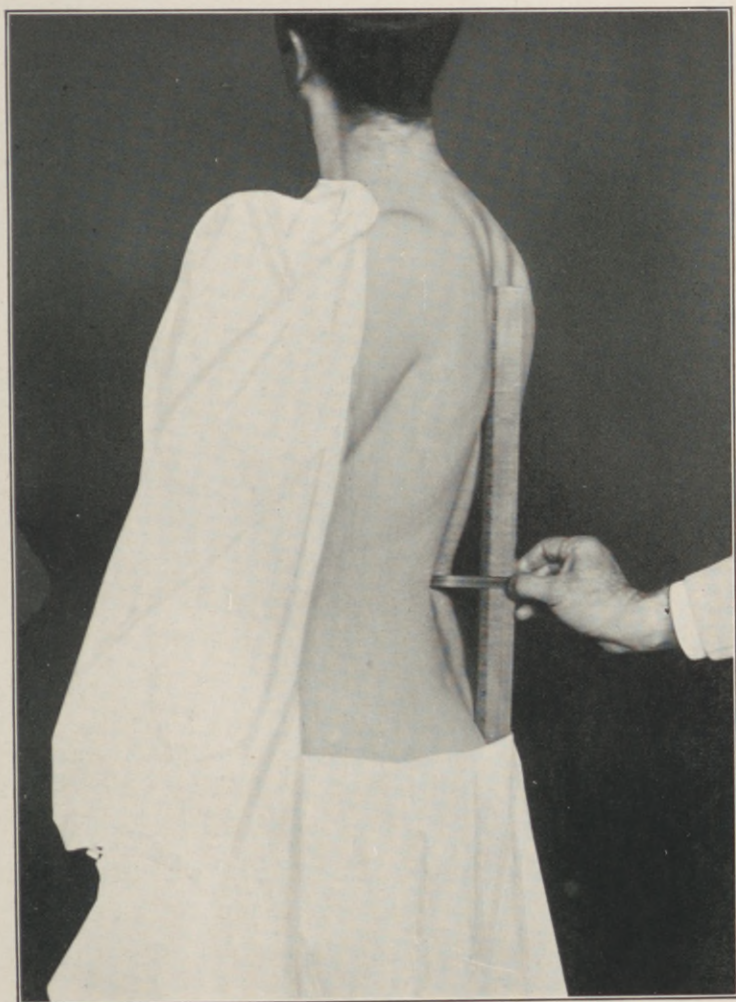


Fig. 77.—The edge of an 18-inch ruler held vertically in contact with the most prominent spinous processes of the dorsal and sacral convexities spans the lumbar hollow. The distance in millimeters from the deepest point of the hollow to the anterior edge of the ruler presents the "lumbar index." (Author's method.)

and the other complicating factors that obliterate the differentiating criteria formulated by Barbour and Watson.

A uterus congenitally retroverted before conception will invariably resume its retroverted position after delivery, when the demonstration of a minus index will reveal the congenital nature of the displacement, to the exoneration of the *accoucheur*.

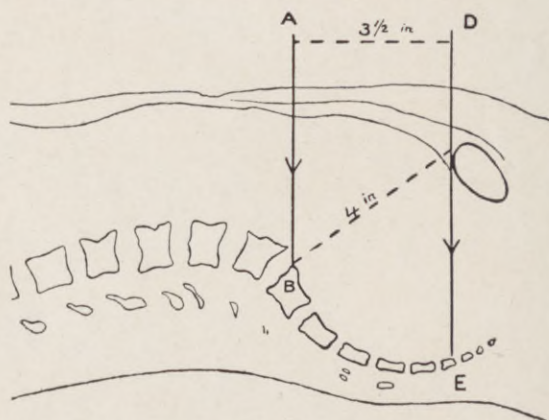


Fig. 78.—Diagram of the relation of pelvis to abdomen. A, Sacrolumbar angle. B, Upper sacral vertebra. D-E, Line extending from the upper symphyseal border to the sacrococcygeal joint.

The application of the lumbar index will establish over one-half of all retroversions, complicated and uncomplicated, as congenital, instead of one-fifth, as hitherto accepted.

The rare exceptions to the rule will, on closer investigation, reveal an exostosis of the sacral promontory; a recession of the pubes which foreshortens the conjugate diameter; a strained and deceptive pose assumed by the patient during measurement, or an

acquired anteversion from pathological concomitants, for it is only reasonable to suppose that, just as a normally poised uterus may be retroverted, so a congenitally retroverted one may become anteverted without invalidating the utility of the index.

It must be emphasized, that congenital retroversion, as such, is essentially only a part of a compensatory adaptation of the pelvic contents to abnormal static conditions through unstable spinal poise; that the depth of the lumbar hollow is the relative measure of the sacrovertebral angle; that the degree of sacrovertebral angulation determines the dip of the pelvis, and that a certain degree of such pelvic dip is essential to the normal topography of its contents.

A flat sacrolumbar angle with vertical pelvis is normal in early childhood, but abnormal in the adult.

If an infant be placed on its back, and its legs be drawn down from their habitual attitude of semi-flexion, it will be noticed that the range of extension is limited by the absence of the lumbar curve and pelvic incline. When gain in muscular development enables the infant to stand, the erector spinæ draws the trunk upward against the resistance of the iliopsoas group and ligaments of the hip-joint, bending the lumbar spine into its physiological curve.

In other words, under normal development, the erect attitude is attained by flexure of the lumbar spine, the pelvis maintaining an incline of 60 to 65 degrees, the tip of the coccyx being on a level with the lower border of the symphysis pubes. Under abnormal developmental conditions, the upright pose is induced principally by an upward and backward rotation of the pelvis on the hip-joints, carrying the axis

of its inlet toward a vertical from a horizontal line.

In such a vertical pelvis, the only tenable position for the uterus is one of retroposition.

The upward and backward rotation of the pelvis elevates the pubes and lowers the sacrum, which latter, thus forming the posterior instead of the upper wall of the pelvic cavity, necessarily alters the mechanism of the sacro-uterine ligaments, their horizontal pull tending to hold the uterus backward against the depressed sacrum, instead of suspending it from above, as in the normal. Furthermore, intra-abdominal pressure, inadequately deflected, thrusts the loose intestinal coils into the pelvic cavity and against the anterior surface of the uterus, crowding it into the space of least resistance offered by the sacral hollow. To put it tersely, every fixed abnormal pelvic tilt must create a correspondingly abnormal uterine tilt.

The whole clinical import of congenital retroversions is centered in their intra- and extra-pelvic complications, not in the uterine displacement as such.

The continuous attitudinal strain on the sacroiliac joints, the erector spinæ and iliopsoas muscles, induces pelvic symptoms that simulate and are generally attributed to the retroversion.

Operative gynecology to date records over 100 detailed methods for the correction of uterine retrodisplacements. Every one of these methods, at the hands of its promulgator, will undoubtedly convert the retroposed into an anteroposed uterus; but notwithstanding their faultless uterine poise, many of

these patients will continue to suffer as before operation—and some more so.

Baldy states: "In my opinion nine-tenths of the operations performed on women for retrodisplacements are uncalled for; and, further, the possible number of retrodisplacement operations performed in this country is limited only by the number of females in existence."

We have already stated that congenital retroversion is a compensatory necessity, and it follows that any procedure which converts such a retroversion into an anteversion converts a compensated into a decompensated visceral equilibrium within the pelvic cavity.

Clinically, the lumbar index will reveal two classes of congenital retrodisplacements, namely, the complicated and the uncomplicated.

Leaving the retroversion, as such, unmolested, the gynecologist should aim to eradicate all coexisting intrapelvic complications, thus converting the complicated into an uncomplicated case.

It cannot be overemphasized that patients with uncomplicated congenital retroversion suffer through a constant attitudinal strain in maintaining their unstable skeletal poise within the lines of gravity, the congenital retrodisplacement of the uterus being an accompaniment and not a cause of the suffering.

These cases must be treated on purely mechanical and orthopedic principles, the details of which find full elaboration in the appended literature.

The normal uterine poise is necessarily oscillat-

ing, the fundus traversing an anteroposterior arc whose normal limits extend from the symphysis pubis to the sacral promontory, with its axis of oscillation at the cervicocorporeal junction, its pivotal fixation secured by the so-called "cardinal ligament."

The round ligaments tend to subserve uterine support only in so far as they limit its essential mobility to a normal range. *They maintain poise, but not support.* They cannot lift the uterus, because their insertion at the fundus is normally above their pelvic attachment; hence their pull on the fundus is downward and forward.

Whether the uterus oscillates from promontory toward symphysis, as in congenital retroposition, or *vice versâ*, as in the normal, is a phenomenon of clinical indifference so long as the elevation of the pivotal point, which is determined by the plane of the levator junction, is at the normal level. *Poise is unimportant; elevation is essential.*

Every uterus freely movable at the normal pelvic level is in normal poise at any point in its arc of transit from the symphysis to the sacral promontory.

Briefly summarized, congenital retropositions should not be corrected.

Acquired retroversions *without* descensus, resulting from levator impairment, are corrected by levator myorrhaphy.

Acquired retroversions *with* descensus should be corrected by levator myorrhaphy *plus* a vaginal shortening of the round ligaments, which pulls the uterus forward out of the sacral hollow and upon its re-established levator fulcrum. Finally, all adherent

retroversions should be attacked through the abdominal route:

As the vaginal shortening of the round ligaments should constitute a part of every cystocele operation, it will obviate repetition to detail the method under the latter caption.

CHAPTER XV.

CYSTOCELE.

CLINICALLY, it is essential to differentiate the simple ectopia of the vaginal wall, known as anterior colpocele, from the condition of true cystocele.

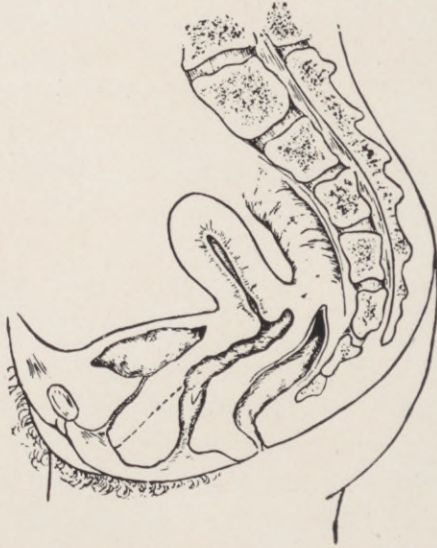


Fig. 79.—Anterior colpocele simulating cystocele. Dotted line indicates the redundant anterior vaginal wall, with the bladder and urethra in normal position.

Anterior colpocele occurs as a result of certain obstetric complications that lead to separation and prolapse of the vaginal wall from the vesical base without disturbing the musculofascial planes that maintain the anatomic position and topographic relations of the bladder.

The abnormality, with but few exceptions, occurs in parous women during the first and second decades of the child-bearing period. A coexisting lesion of the pelvic floor may or may not be present, although a lacerated or relaxed state of these structures always aggravates the condition, and in exceptional cases bears a causal relation to its development.

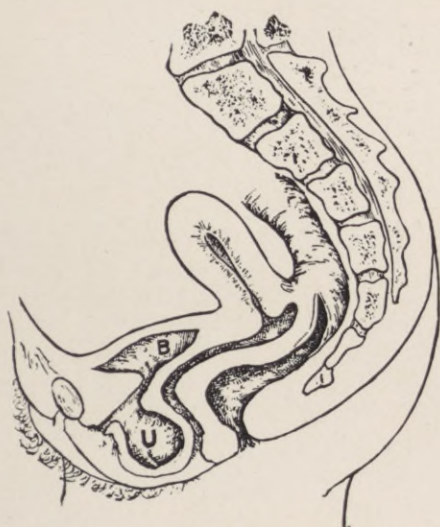

Fig. 80.—Urethrocele. B, Bladder. U, Urethrocele.

First among the distinguishing features between anterior colpocele and true cystocele is the absence of uterine ptosis; in fact, the uterus bears no relation whatever to either the production or maintenance of an existing colpocele, while, on the other hand, a true cystocele without uterine descent is anatomically inconceivable.

Such a uterine descent may not be evident unless the patient is examined in the erect posture.

True cystocele differs from colpocele as a loose fold of hypertrophied skin or relaxed abdominal wall differs from ventral hernia.

The prolapsed vaginal wall is usually hypertro-

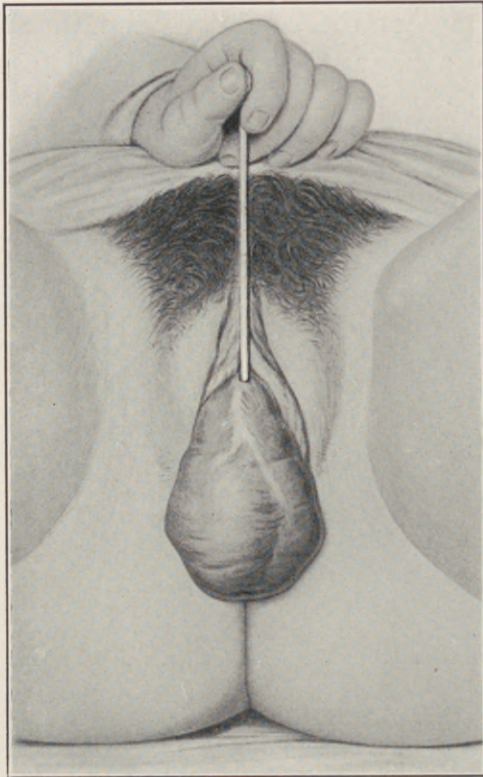


Fig. 81.—Inversion of the vagina, with cystocele and pro-
cidentia uteri. Catheter in bladder.

phied and rugous, while the vaginal covering of a cystocele, especially when distended, is smooth and thin. Furthermore, careful palpation will disclose the mobility of the simple vaginal protrusion on the firm

subjacent vesical floor. In cystocele a catheter passed into the bladder can be directed so that the vesical end of the catheter may be felt in the prolapsed bladder, where it protrudes through the vaginal outlet.

Residual urinary retention and its possible sequella are conspicuously absent in colpocele.

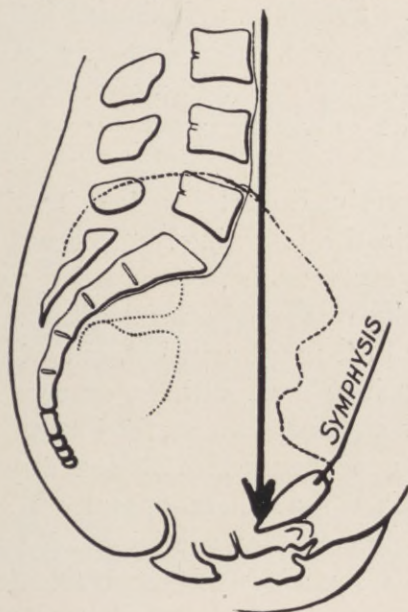


Fig. 82.—Initial direction of intra-abdominal pressure at the pelvic brim.

Anterior colpocele, involving the vaginal mucosa only, is curable by any of the standardized colporrhaphies that simply ablate a varying patch of the vaginal mucosa, and reef the wound edges by suture.

A herniated bladder, however, cannot possibly be restored and retained by any such procedure, which only substitutes a yielding temporary occlusion for the mechanism of physiological support.

Notwithstanding these clinical, pathological, and surgical contrasts between the two conditions, the term cystocele is still generally applied to all protrusions of the anterior vaginal wall regardless of the structures involved. Thus we find (Kelly and Noble's Gynecology) "anterior colporrhaphy or resection of the anterior vaginal wall is indicated for the cure of cystocele, or of cystocele complicated by prolapse of the uterus;" and again, "anterior colporrhaphy is the only satisfactory treatment for cystocele."

More recently, Robert Frank epitomizes the subject to date in the following: "The writer has seen individual operators who, through long years of experience, or by reason of special gifts and dexterity, have acquired the necessary skill, but who were quite unable to teach to the spectator, or even transmit to their regular assistants the method by which they obtained their good results. This inability to teach is due to the fact that these operators, although by nicety of judgment, by precision of execution, by unconscious visualizing of reconstruction, and by proper extent of denudation they obtained good results, did not expose the field anatomically, and did not perform an anatomical repair, such as is done as a matter of course in inguinal herniotomy, for example. . . . For a number of years the so-called interposition operation has been employed in the treatment of cystocele. This procedure is anatomical in so far as its execution is concerned, but the resulting repair distorts natural conditions to a degree which necessitates sterilization, if performed in the child-bearing period, and is unsatisfactory when ap-

plied to cases of prolapse. . . . The majority of operations devised for cystocele and rectocele depend upon ingenious denudation, complicated application of sutures, etc., rather than upon a firm anatomical basis."

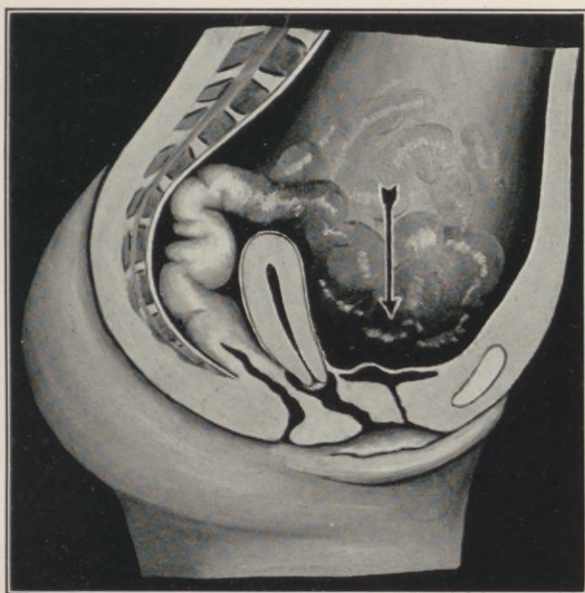


Fig. 83.—Diagrammatic scheme of misdirected pressure deflection by deranged intrapelvic planes, due to incompetent levator contraction resulting from perineal injury. The same occurs as a result of levator paralysis in *Spina bifida occulta*, or lesions of the fourth sacral nerve producing a "virginal uterine prolapse," notwithstanding intact fascia and ligaments. First stage in the development of cystocele and procidentia uteri.

A rational operative procedure for the cure of cystocele must be evolved from a clear conception of the disorder in the supporting mechanism resulting in prolapse.

Although descriptive anatomy enumerates five

“true” and five “false” ligamentous supports, the bladder is actually swung at its base on a thin fascial hammock, which extends from the posterior surface of the symphysis and pubic rami to the cervicocorporeal junction of the uterus.

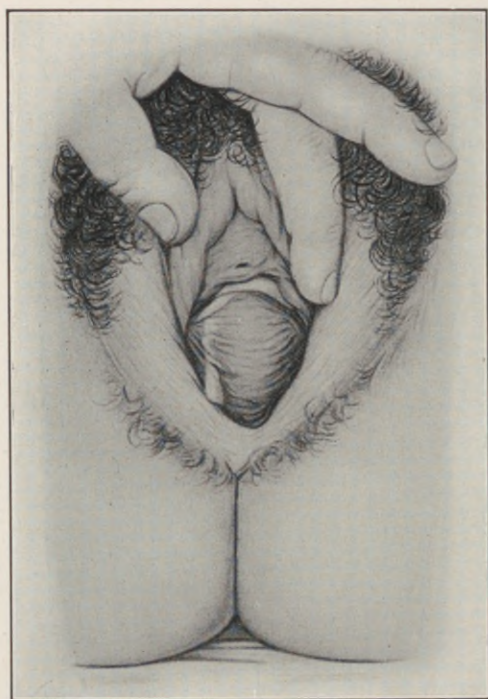

Fig. 84.—Perineal laceration, with rectocele and leucorrhea, from chronic endocervicitis.

The anterior or pubic extremity of the bladder base thus presents a fixed point, while its posterior or cervical segment naturally participates in the mobility of the uterus. Uterine poise thus dominates bladder poise; the free span of bladder base between the pubic and cervical attachment and its subjacent

anterior vaginal wall being supported by the musculofascial mechanism of the pelvic floor.

In applying the principle of deflection to the problem of intrapelvic visceral support, as elucidated

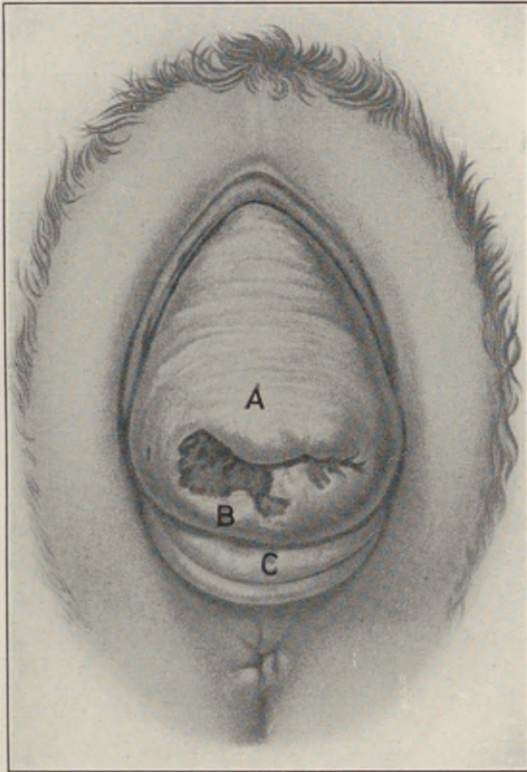


Fig. 85.—Procidentia uteri. A, Cystocele, showing transverse rugæ, the lowermost of which indicate the position of the lower bladder pole. B, Endocervical ulceration. C, Rectocele.

in the chapter on perineorrhaphy, intra-abdominal pressure is defined as the initial force to be deflected, the mobile intestinal coils as the medium through which this force is manifested, and the muscular

mechanism of the pelvic floor *plus* its superposed bladder and uterus as the deflecting plane.

A transverse section of the empty bladder is Y-shaped, due to the cupping of its summit in contraction.

“As the bladder empties, the upper, more movable portion, covered with peritoneum, settles down into the lower and relatively more fixed portion, until it comes to lie within it as one saucer rests in another. During respiration the free upper half may be seen (through the cystoscope) moving on the lower half, as if hinged, the line of demarcation between them being distinctly visible.

“At the edges where the two saucers meet, three folds are formed—the right, left, and posterior. The posterior fold stretches from side to side in front of the uterus; it is gently convex forward, following the contour of the uterus, and ends in front of each broad ligament, where each lateral fold begins and extends horizontally around toward the urethra. These folds represent the physiological hinges on which the bladder moves in expanding and collapsing.

“The apices, where the posterior fold joins the lateral fold in front of the broad ligaments, are called the right and left vesical cornua” (Howard Kelly).

This is significant, for under normal conditions the concavity of its intraperitoneal aspect, induced by this cupping, is filled by the convex uterine fundus like a ball in a socket, which thus maintains the contours and incline of the plane for the deflection of pressure from above. On the other hand, where the uterine fundus is retroverted and prolapsed, the

cupped bladder area affords a potential peritoneal pouch for the herniation of its superposed intestine.

Observing the distorted topography of the pelvic viscera from above in a case of marked cystocele, the first abnormality to obtrude itself is the absence of the uterine fundus from its normal situation, and the presence in its place of intestinal coils. On clearing these coils, the essential incline of the pelvic floor is found converted into a hollow declivity formed by the distended uterovesical space, with the uterine fundus posteriorly, and the bladder at the bottom. The crippled levator ani permits the anterior part of the pelvic floor to sag, levelling its incline; the direction of intra-abdominal pressure, no longer deflected, falls upon the vesico-uterine space, which, deprived of its musculofascial buttress at the perineal crest, becomes pouched and distended with intestinal coils.

Thus the fully developed cystocele represents not merely a prolapse of the bladder, but a complete hernia, equipped with its peritoneal sac containing intestine, differing from an inguinal hernia only in that the *bladder* and *vaginal wall* enter into the *formation of its coverings*.

CHAPTER XVI.

OPERATIONS FOR CYSTOCELE.

THE surgical object in the cure of cystocele and procidentia should not aim to create merely a cicatricial retention of the prolapse at the vaginal outlet, but to reconstruct the mechanism which exercises physiological support from below and deflects pressure from above the pelvic organs.

That this object is not uniformly attained is apparent in the diversity and multiplicity of prevailing methods.

The procedure of Bumm, Liepman, and Martin, which consists of a simple anterior colporrhaphy reinforced by separate suture of the subvesical fascia, after mobilizing the bladder, is advocated and detailed by Frank in the following:—

“The cervix is grasped with a vulsellum forceps, and forcibly pulled downward. A small forceps (Ochsner) is applied to the mucosa $\frac{1}{2}$ centimeter below the urethra. A vertical incision, just penetrating through the vaginal mucosa, is made between the two instruments. Starting from below upward, the vaginal mucosa is separated from the underlying bladder for a distance of only $\frac{1}{4}$ centimeter along the entire edge on both sides of the incision. The vaginal flap is made as thin as possible. To each edge two Ochsner forceps are applied as tractors. At the very bottom of the incision a few snips of a blunt scissors

cut across the so-called 'vesical ligament,' which serves to attach the bladder to the cervix.

"The gauze-covered finger, by stripping upward and backward, strictly in the median line, now frees the lower margin of the bladder from the cervix. As this is done on each side, fascial fibres running upward and inward become apparent. These are the

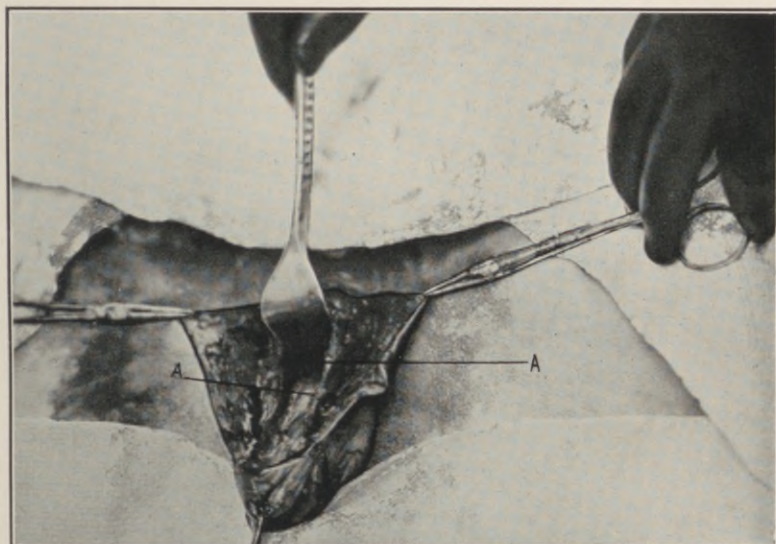


Fig. 86.—"Bladder pillars." A, Pubocervical ligament. (From life.)

'bladder pillars' (the pubovesical ligaments), which are invaluable in the repair.

"Not until this dissection has been completed is it wise to separate the vaginal mucosa to the necessary distance laterally, because it is extremely easy to stray into a deeper layer, and thus either destroy or repeatedly buttonhole the 'pillars' and the thin fascia which covers them, or to detach them from their

continuity with deeper structures (anterior part of cardinal ligament).

“After the vaginal flaps have been reflected, and the bladder pushed up well above the peritoneal reflection, especially at the sides (behind the pillars),

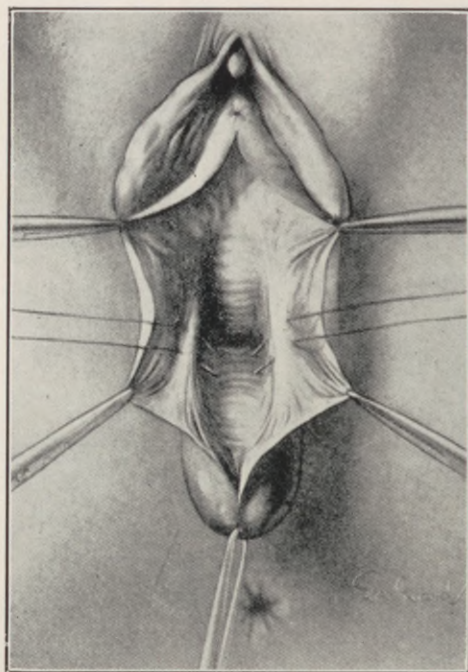


Fig. 87.—Operation for cystocele. Exposure of the “bladder pillars” (pubocervical ligament) and insertion of the cervical sutures. (*Frank.*)

interrupted sutures of chromic gut are passed from side to side, entering one pillar, then catching the cervix, and again taking in the pillar of the opposite side.

“The upper suture must be passed with care, and not too deeply, as the ureters are in close proximity.

“When these sutures are tied, the bladder is held well up and back, and is prevented from descending.

“At the upper end of the denudation, close to the urethra, a strong inverted V-shaped fascia will be noted. This forms part of the anterior layer of

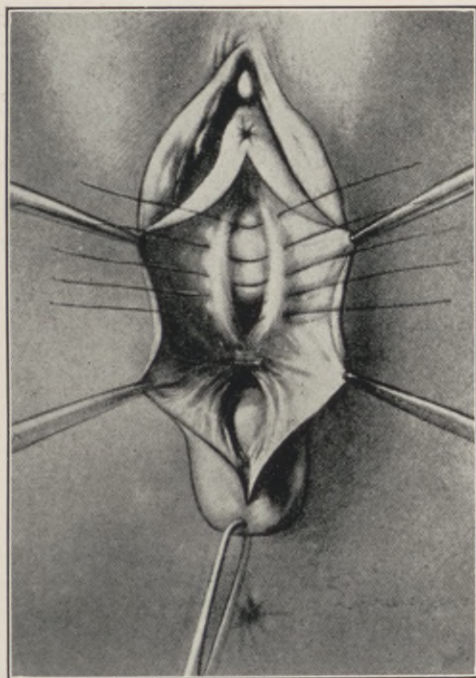


Fig. 88.—Cystocele operation. Cervical sutures tied, holding back bladder. Insertion of more anterior suture. (*Frank.*)

the triangular ligament. When this is approximated by transverse or mattress sutures of chromic gut, only a small portion of the bladder between the upper and lower sutured areas lacks reinforcement. This weak spot can now be closed, as the fascial edges, which have become demarcated far laterally by the

traction of the tied sutures (and which draw the anterior fibres of the cardinal ligament toward the median line), are in turn drawn together by interrupted sutures.

"After resecting a sufficient area of vaginal flap on each side (the amount, if not excessive, is of little importance), so as to leave an oval denudation, the mucosa is approximated with interrupted silk sutures.

"By following the above directions closely, sufficient fascial structures will be found in almost every case, especially in large cystoceles found in conjunction with prolapsus.

"The fasciæ are most often destroyed or lost by operators who form large vaginal flaps or broadly denude, as their first step in cystocele operations. Other gynecologists deliberately cut through the 'pillars' 'in order to free the bladder edges.'

"The bladder can be fully freed behind (*i.e.*, cephalad) to the 'pillars.' These structures are especially valuable, not only because they afford good material for suture, but also as they serve both as guide and tractor to the deeper parts of the anterior portion of the cardinal ligaments."

Frank prefaces the above technique with the claim that it is "applicable to all but very large cystoceles, that it is always the operation of choice, and only to be abandoned if absence of fascial structures is encountered." He concludes by stating that "in the few cases in which no 'pillars' and no fascia can be isolated, large cystoceles may be held back by the operation of vaginal interposition (Schauta, Wertheim), which is simple, but the disadvantages of which (necessity for sterilization, bladder symptoms,

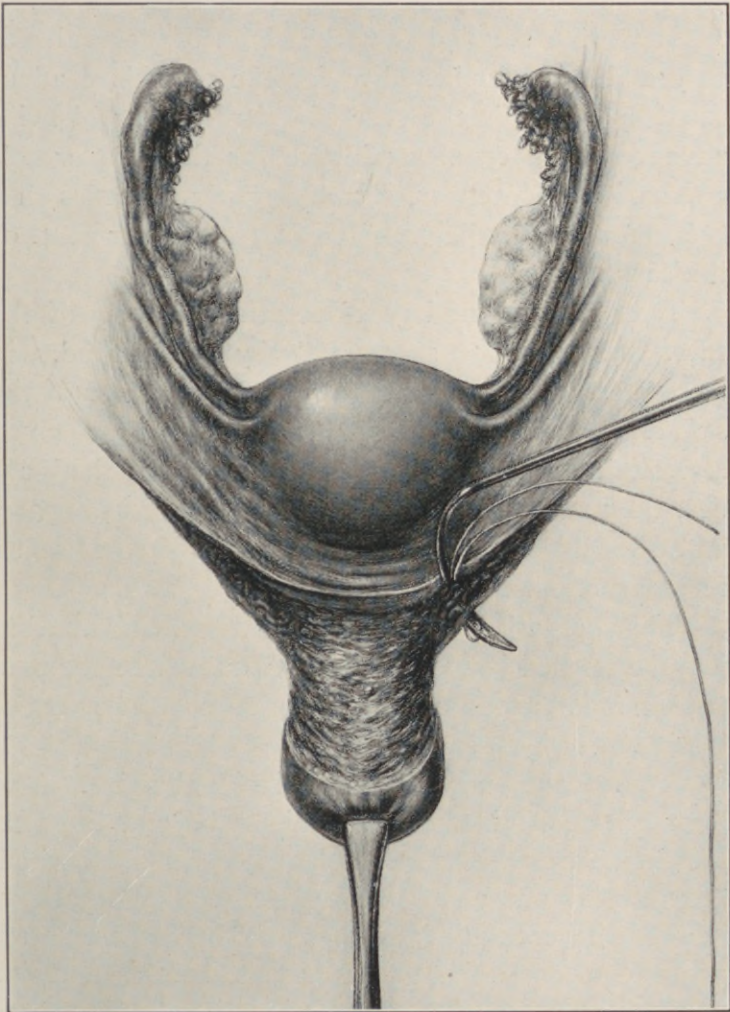


Fig. 89.—Extended operation for postclimacteric cystocele, with complete procidentia. (*Goffe.*) Vaginal hysterectomy—ligature of uterine artery.

recurrence of protrusion after operation for prolapse) have become increasingly apparent."

It will be recalled that the claim of general efficacy and wide applicability for the procedure advocated by Frank in the cure of cystocele was likewise advanced with equal confidence for the simpler colporrhaphy. Moreover, Frank vaguely concedes that "recurrence must be expected in 1 to 10 per cent. of the cases."

A closer pre- and post-operative scrutiny of the cases operated upon successfully by this method, will attribute the curative result, *not* to the *suture* of the *subvesical fascial* "pillars," upon which so much stress is laid, but rather to the elevation of the bladder, the partial obliteration of the uterovesical space, and the efficacy of the concomitant perineoplastic reconstruction.

This operation is undoubtedly beneficial in what may be termed borderline conditions, where the protrusion constitutes a maximum of colpocele and a minimum of cystocele.

These cases never present residual urine. The floor of the bladder never projects beyond the normal plane of the vulvar cleft, in addition to which they display one anatomic feature of almost pathognomonic differential significance not heretofore noted, namely, a deep transverse sulcus in the anterior vaginal wall, at the site of junction between the urethra and vesical neck, directly under the apex of the pubic arch.

This transverse sulcus is due to the competence of the pubovesical fascia. It maintains the normal

direction of the urethra, and is always obliterated in marked cystocele.

The futility of fascial suture as such in pelvic visceral support, and the reasons therefor, have been fully discussed in the chapter on perineorrhaphy. In addition to the arguments set forth there, which apply with equal force here, it must be recalled that, unlike the perineal fasciæ, the subvesical fascia is seldom if ever directly torn. In short, the normal subvesical fascia sags, not because of any direct injury, but primarily as a result of the levator tear in the perineum *plus* uterine descent, the former depriving it of its fundal support, the latter carrying its cervical attachment downward; and it follows as a logical corollary that the reefing of this fascia, more especially in the attenuated condition encountered in advanced cases of cystocele, must prove illusory as an element in the restoration of permanent support to the bladder.

The essential operative phases in the radical cure of cystocele with uterine procidentia demand:—

I. Ample separation of the bladder base from the abnormal uterine and vaginal attachment acquired in its descent.

II. Correction of the uterine malposition by vaginal reefing of the round ligaments.

III. Reattachment of the bladder to the *anterior* surface of the uterus at the normal level (Goffe).

IV. Reconstruction of the musculofascial support in the pelvic floor.

To expose the base of the bladder, the cervix is forcibly drawn down with a vulsellum; its anterior vaginal coat is incised transversely just below the

level and parallel to the lowest of the transverse rugæ, which, in the relaxed state, invariably designates the limit of the vaginocervical attachment of the bladder.

From the center of this transverse slit, a superficial median longitudinal incision is made, extending for a sufficient distance upward toward the external urinary meatus, the junction of the two incisions thus forming an inverted T.

The mobilization of the bladder is begun at the lower extremity of the longitudinal incision by separating the two central flap tips in the angles of the inverted T from the underlying tissues for a distance sufficient to expose and sever the cervical attachment to the bladder base, after which the bladder is readily brushed bluntly from the uterus by a gauze-covered finger, up to the vesico-uterine peritoneal reflection.

The separation of the bladder from the anterior vaginal wall is materially facilitated by attention to certain technical and anatomical details.

In picking up the edge of the flap incision the underlying tissues should be severed with a few strokes of the knife, so that the T-forceps grasps the vaginal tissues only. Then by gauze dissection the bladder is separated on each side as far out as necessary for its free mobilization.

The safety of this rapid blunt dissection lies in rolling the yielding connective tissue from the raw upper surface of the firm vaginal flap by the gauze-covered finger working against counterpressure exercised by the fingers of the opposite hand applied to its under surface.

Furthermore, it is essential to note that there are

two planes of cleavage between the vaginal mucosa and the base of the bladder proper, separated by the pubovesical fascia.

The lower cleavage plane lies between the vaginal mucosa and under surface of the fascia, while the upper separates the bladder from the upper fascial surface.

The longitudinal arm of the outlining flap incision should *penetrate this fascia to the upper plane of cleavage* (i.e., between the bladder base and upper (cephalad) fascial surface), in which the bladder may be readily mobilized without undue traumatism or bleeding.

The lower plane of cleavage must be avoided, as it leads directly to the under surface of the pubovesical fascia, the pubic attachments of which may offer considerable resistance, necessitating their discission in freeing the lateral aspects of the bladder wall.

The freely mobilized bladder is elevated on a flat speculum held against the pubic arch. This stretches and exposes the uterovesical fold of peritoneum, which is gently drawn down by blunt forceps and grasped between the fingers like a hernial sac to exclude the possible presence of omentum or intestine, after which it is opened widely to the base of the broad ligament on each side.

In stout patients, and in those with deep pelves, a slight Trendelenburg incline at this stage of the operation will facilitate the location of the uterovesical fold, and tend to cause the intestines to gravitate from the operative field. No gauze packing should be used for the latter purpose.

Difficulty is sometimes experienced in identifying

the uterovesical fold. It may be recognized by a difference in color from the surrounding tissues, its translucency, smooth surface, and respiratory oscillation.

In the anxiety to avoid injury to the bladder, confusion is sometimes caused by dissecting too close to the uterus. At the cervicovesical junction, it is necessary to hug the cervix closely, carefully brushing all loose tissue with the bladder wall; but once the bladder wall begins to peel freely, and the loose connective tissue between the cervix and bladder is clearly defined, the remaining attachment is simply wiped off the cervix in the line of least resistance, which always carries the separation direct to the uterovesical peritoneum.

In the cure of a complete procidentia the operative aim is not only an elevation of the prolapsed organs to their normal level, but the equally essential restoration and maintenance of normal uterine poise by vaginal shortening of the round ligaments, which is best accomplished by bringing the exposed fundus to the vulva, doubling each ligament upon itself, and sewing the loop to the cornual area at the fundus.

These sutures should be inserted at the correct distance, and in proper alignment, but not tied until after the fundus is replaced within the pelvic cavity; or, each ligament may be caught in a chromic gut loop, introduced one inch from the cornua, the loose strands of each loop passed separately through the respective vaginal flap, one-quarter of an inch apart, and tied. (Vaginal fixation of the round ligaments.)

The fundus uteri should be brought to the vulva by manipulation with a finger hooked behind one

or other broad ligament, and not by traumatizing tenacula, the delivery of the fundus being facilitated by first pushing the cervix far back into the vagina.

Dr. J. Riddle Goffe secures the elevation of the bladder by suturing its base to the anterior uterine wall as follows:—

“Three chromicized catgut ligatures (No. 2) are passed, one through the anterior wall of the uterus at its midpoint, and the other two through the anterior walls of the broad ligaments, just outside the lateral margins of the uterus. These are left long, and protrude through the vulva. A point is now selected in the base of the bladder, at such a distance from the urethra as, when carried up to the point of insertion of the first of these three ligatures, will cause the base of the bladder to make a straight line from the urethra to the uterus.

“Through this point in the bladder wall the suture is passed, catching up in its course the bladder attachment of the peritoneum, where it was separated from the uterus. Two points in the base of the bladder are now selected, at either side of the first selected point, and distant from an inch to an inch and a half. Through these points the lateral sutures are passed respectively. The three are then tied, beginning with the middle one. The first takes up all the slack in the line from the uterus to the urethra, but makes a ridge in the interior of the bladder, with a sulcus on either side. By tying the lateral sutures, however, these sulci are obliterated, and the base of the bladder is spread out upon the anterior face of the uterus and broad ligaments.

“The overstretched fascia and hypertrophied an-

terior vaginal wall are trimmed to fit snugly under the bladder base, then sewed together, and to the lower anterior surface of the uterus."

As an aid in the identification of the round ligaments, when these are not clearly definable as the result of the inverted fundal position, three distinct ridges may be noted, continuous with and extending outward from the uterine cornua. In tracing these ridges backward, the anterior will be found continuous with the round ligament, the middle with the fallopian tube, and the posterior with the utero-ovarian ligament, the tubal ridge being the highest and most prominent, the utero-ovarian the lowest and posterior.

When the round ligaments are identified, they are grasped in holding forceps, and the fundus replaced within the pelvis. This relaxes the ligaments, and enables the operator to estimate the necessary extent of shortening, and to insert the sutures, all of which is impossible with the fundus and ligaments on the stretch at the vulvar outlet.

There are cases in which the round ligaments and tubes, especially near their uterine extremity, occupy practically the same compartment in the top of the broad ligament. Here the looping and suture of the round ligament would necessarily kink the tube with pathological possibilities. This condition may be recognized after reposition of the fundus by observing the outlines of the tube on pulling the round ligament loop before suturing. If tubal kinking is induced, the peritoneal investment along the round ligament should be incised for a distance sufficient to liberate the tube.

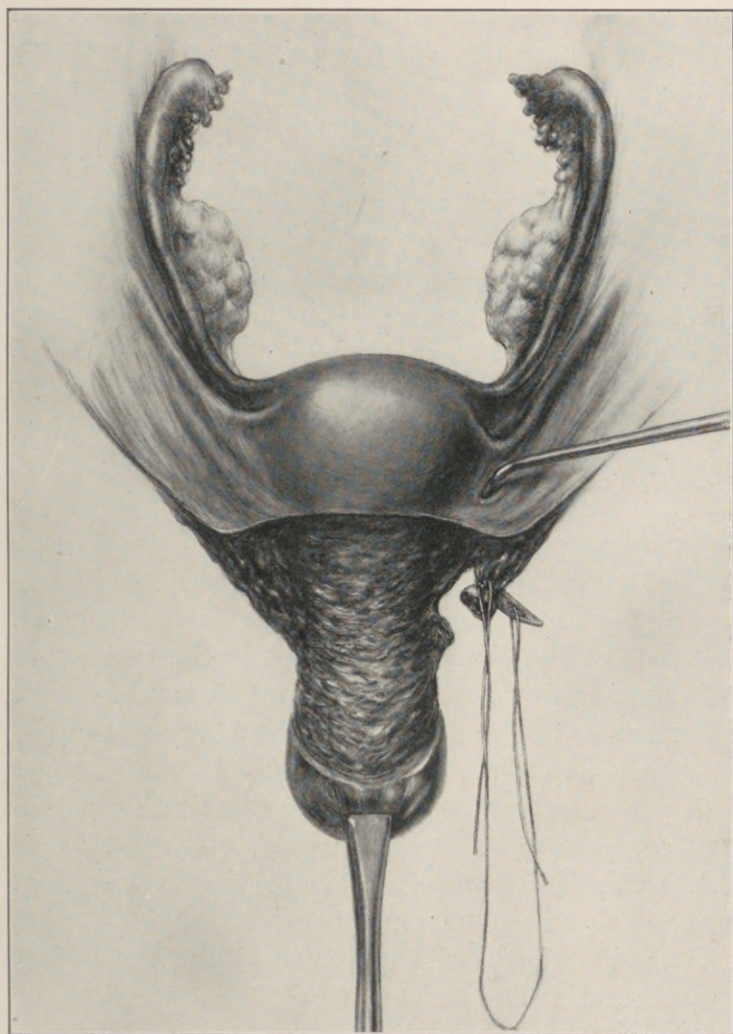


Fig. 90.—Extended operation for postclimacteric cystocele, with complete procidentia. (*Goffe*.) Ligature of broad ligament between the uterine and ovarian artery.

In trimming the redundant vaginal flaps, there is a general tendency to remove too much mucosa rather than too little, with a consequent shortening of the anterior vaginal wall. This will tend to pull the cervix toward the vulvar outlet, and thus promote the possibility of a recurrence.

Vaginal hysterectomy, as a routine measure for the cure of complete procidentia, cannot be too emphatically condemned. The advocacy of this illogical empiricism has been perpetuated in standard publications to the present time. Thus, E. E. Montgomery asserts:—

“Even in women during the child-bearing period, any operation for the successful retention of the protruding uterus and vagina is inconsistent with the continuance of procreation. No operative procedure has been devised for such a condition which will successfully endure the mechanism of a subsequent labor.

“Indeed, the changes produced in the uterus are such as to render conception improbable, and to make the uterus unable to develop in such a way as to offer a reasonable probability that the fecundated ovum shall find a proper soil and secure habitation to ensure completion of the pregnancy. The uterus in such cases is a needless organ—yea, worse than needless, a diseased organ.”

This is fallacious dogma, based upon premises not substantiated by either clinical, pathological, or surgical facts.

In the chapter on the dynamics of intrapelvic visceral support, the uterus is depicted as constituting a lever, with a fundal and a cervical arm, swung upon a fulcrum formed by the projection of the levator

junction, which latter constitutes the "intravaginal perineal crest." Hence, to remove the uterus, or ablate its cervical arm, is to remove an integral part in the mechanism that prevents prolapse by deflecting the course of intra-abdominal pressure. For the same mechanical reason, permanent fixation of either uterine pole is contraindicated.

The *cervix should not be amputated*, its bulk being reduced to normal, when necessary, by the method detailed in the section on "Tracheloplasty."

A prolapsed uterus is a dislocated uterus, and dislocation as such is not an indication for its removal, notwithstanding an existing menopause. Furthermore, hysterectomy does not ensure the permanency of the retention, as the bladder and vagina may eventually protrude in the absence of the uterus—a condition presenting an extremely doubtful prognosis as to the probability of an ultimate cure.

The indications for the removal of the prolapsed uterus should be identical with those in the non-prolapsed organ, namely, irremediable pathologic alteration from chronic infections or neoplasms.

This applies particularly to the aged, who, as a matter of fact, suffer more from anxiety than from the actual discomfort induced by the existence of the prolapse, both of which may be effectually and safely relieved by a properly applied Menge pessary.

In the presence of definite indications, a vaginal hysterectomy should be performed by extending the primary transverse incision on the vaginal mucosa completely around the cervix, severing the vaginal and bladder attachments of the uterus, which is then brought completely to the vulva and removed after

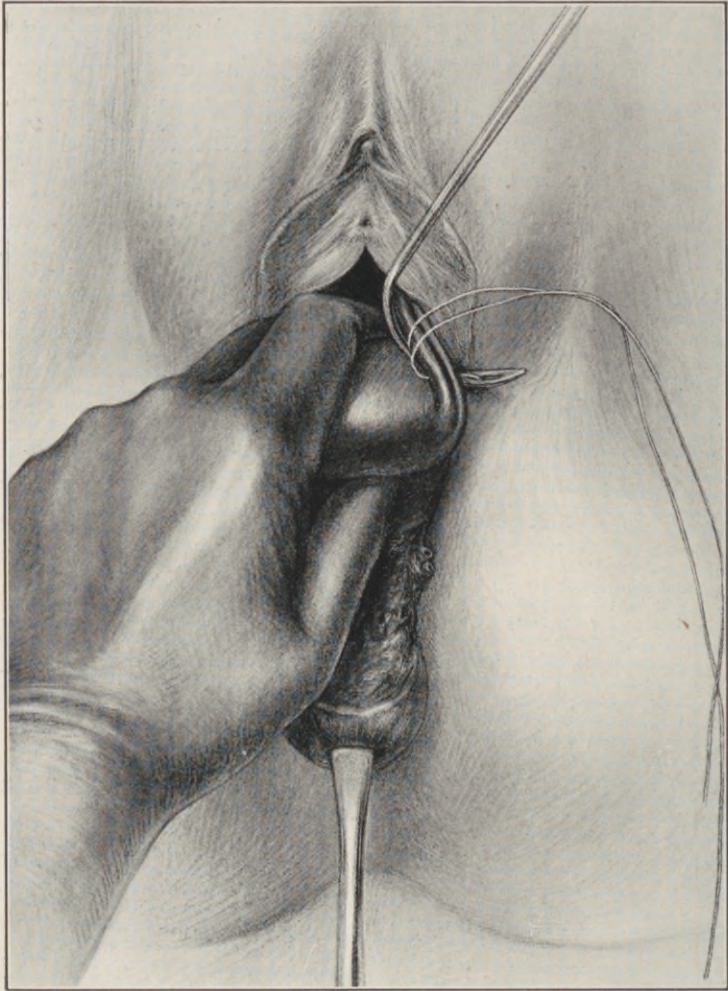


Fig. 91.—Extended operation for postclimacteric cystocele, with complete procidentia. (*Goffe.*) The fundus uteri delivered through the anterior vaginal fornix. Ligature of the utero-ovarian artery and tube.

clamping each broad ligament from top to bottom as far outward as possible, leaving or removing the adnexa according to indications.

A continuous suture or chain ligature controls bleeding from the raw edges of the broad ligaments.

"In order to provide a support for the bladder, and also a surface to act as a deflector of intra-abdominal pressure, the broad ligament edges are sutured to one another, from the round ligaments down to their bases, taking in sufficient slack to make them draw taut across the pelvis" (Goffe).

"The bladder is spread out on the *anterior* (under) surface of the broad ligament plane thus constructed (which takes the place of the uterus), and is attached at three points corresponding to those designated for the cases with the uterus *in situ*, after which the pubovesical fascia and trimmed vaginal walls are sutured in separate layers, or in bulk" (Goffe).

The operation is completed by the method of levator myorrhaphy in the pelvic floor, as detailed in the chapter on the perineum.

It is a significant fact, of direct bearing on the extended controversy as to the relative merits of the numerous procidentia operations and their technical variants, that none omit, and all stress, the importance of an efficient pelvic floor restoration.

The technique, as outlined here, readjusts the normal bladder topography, obliterates the hernial pouch of the distended uterovesical peritoneum, augments the resistance of this area by *superposing* the uterine fundus, and, finally, by restoring the poise and elevation of the uterus essential to its function

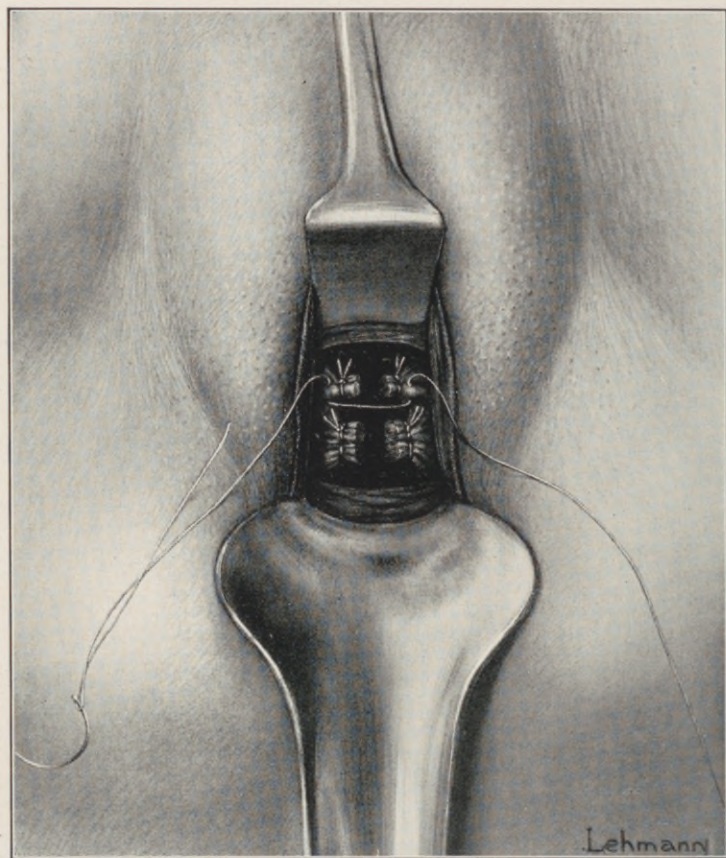


Fig. 92.—The stumps of the broad ligaments, with their respective ligatures, seen in the depth of the vaginal wound. (*Goffe*.) Introduction of broad ligament suture to form a new base of support for the bladder in place of the uterus removed.

as a lever in the deflecting mechanism, it diminishes pressure from above the vesico-uterine space.

This operation does not hazard the result upon the precarious support offered by the subvesical fascia. It creates no malinterposition of the bladder, and demands no sterilization of an otherwise normal woman.

From a prognostic and technical point of view, the preoperative differentiation of three types among procidentia patients is essential, namely:—

I. Procidentia as an ultimate result of birth trauma *in previously* normal women.

II. Procidentia following birth injury in women presenting the skeletal and static deviations pathognomonic of *congenital uterine retroposition*. These cases are recognized by the sacrolumbar index described in the chapter on retroversion.

III. Cases of so-called "virginal prolapse," which may manifest itself before or after parity.

Weinberg asserts "that prolapse of the uterus in the new-born and in nulliparæ constitutes 3.45 per cent. of all cases of prolapse. Nebesky, in a series of 232 cases of procidentia, reports 16 as occurring in nulliparous women."

The majority, if not all, the virginal cases are due to the existence of an unrecognized *Spina bifida occulta*, which involves the fourth sacral nerves, with consequent paralysis of the levator ani.

The bony cleft of *Spina bifida occulta* in the lumbosacral region is usually closed by a dense membrane; a characteristic hairy patch may be the only local indication of its existence. The cleft can usually be felt, but in some cases only the X-ray reveals its presence. The hair has a typical concentric arrange-

ment over the centre of the defect. After puberty it may grow to 25 or 30 cm. in length, resembling a tail. Local hypertrichosis is usual in all *Spinæ bifidæ*.

Cicatricial changes in the skin over the defect are common, and are always present when tumors exist

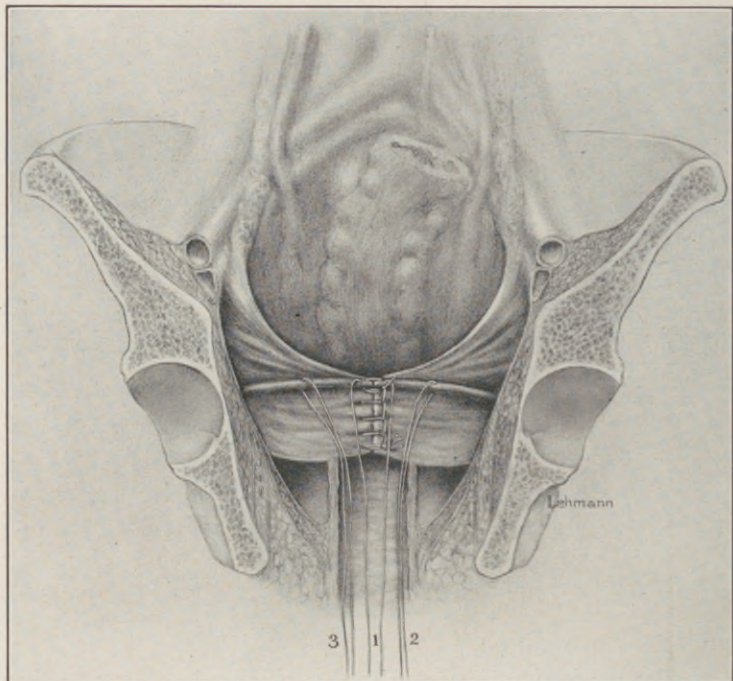


Fig. 93.—Broad ligament stumps sutured across the midline. Suspension ligatures, 1, 2, 3, are passed from the centre and sides of the upper broad ligament border through corresponding points at the centre and sides of the bladder base, and are drawn taut. (*Goffe.*)

within the canal. Lipomata, fibromata, myomata, angiomata and dermoids are frequently found inside or outside the vertebral canal, or occupying the bony cleft.

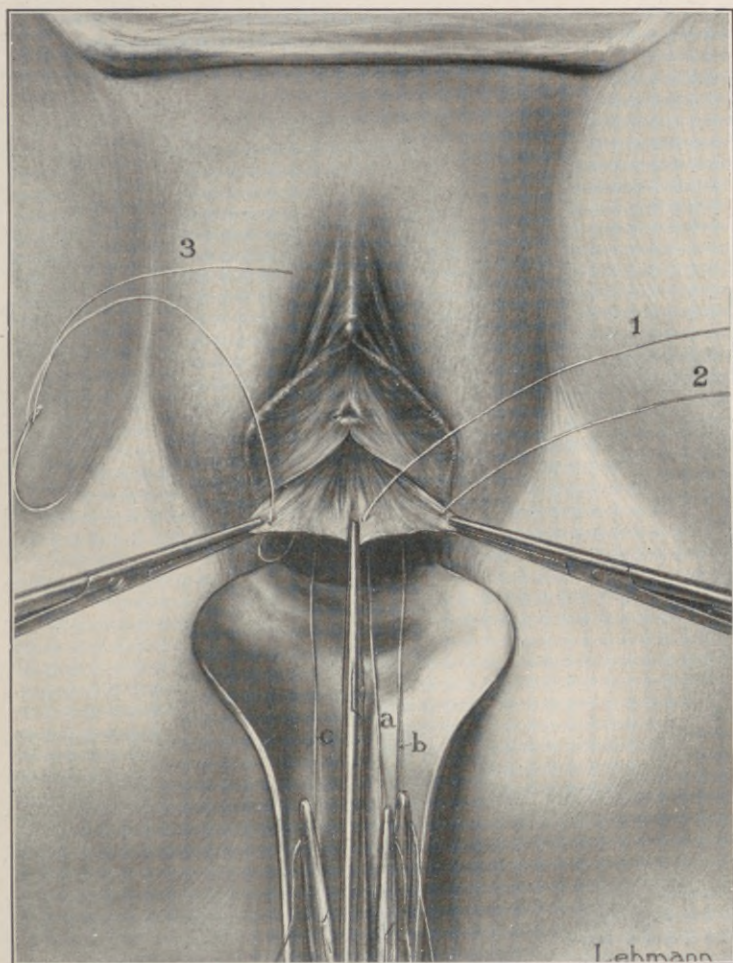


Fig. 94.—The upper free end of each suspension ligature is passed from its insertion in the broad ligament border (Fig. 93) through corresponding points in the subvesical fascia. Each upper free end is then tied with its respective lower free end, c, a, b, and drawn taut, bringing the base of the bladder snugly against the anterior face of the united broad ligaments. (*Goffe.*)

Even in the absence of such tumors, the patients frequently present sensory, trophic, or motor symptoms, such as areas of anesthesia, neuroparalytic ulcers, club-foot, partial paraplegia, or a sphincteric insufficiency not otherwise accounted for.

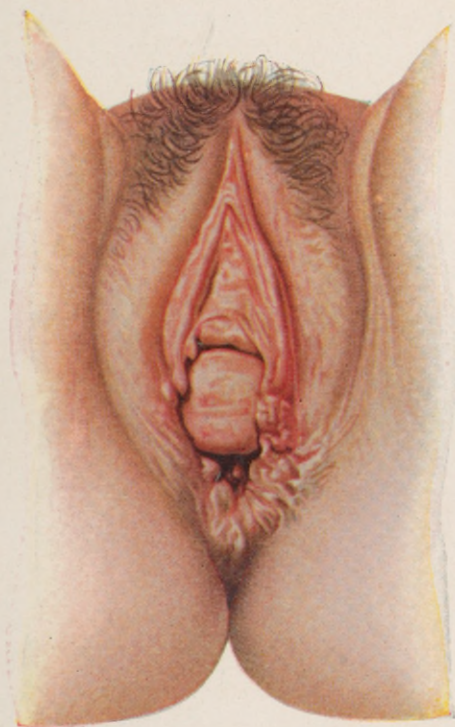
These symptoms vary in intensity, and may not develop until puberty is established. In the absence of tumors, their direct cause is found in the firm fibrous bands, passing through the cleft, with the cord near its lower end. Hence, the treatment of the condition consists in incision or excision of these bands. Good results from this treatment are reported by Katzenstein (who cured bladder symptoms of six years standing), Jones, Milner, and others.

The prognostic and technical bearings of prolapse in cases of congenital retroposition, and those resulting from *Spina bifida occulta*, are manifest in their inherent tendency to eventual recurrence after operation.

Such recurrences will tax the ingenuity and skill of the most experienced operator. Corrective attempts in these two classes of proclivitas, at any time and by any means at our command, can only substitute artificial immobilization of the prolapsed organs by fixation methods for the normal mechanism of intrapelvic support.

A ventro-suspension without undue tension, obliteration of the abnormally deep Douglas' pouch by a spiral suture, in addition to a high reconstruction of the congenitally foreshortened perineum, will accomplish all that is surgically possible. Failing in this, pessary support offers the only recourse.

PLATE XX.



Complete perineal laceration through the anal sphinctre, with exposure of the posterior vaginal and rectal walls. Note the absence of cystocele and uterine prolapse.

Discrimination before operating upon these cases will obviate many difficulties and disappointments. Let the operator fully realize what he sets out to accomplish, and he will readily adopt the simplest, easiest, and surest method to this end. Let him, on the other hand, clog his mind with details and special plans of this and that operator, and he will follow an uncertain mixture of complicated and often futile procedures.

CHAPTER XVII.

LACERATION THROUGH THE ANAL SPHINCTRE.

ONE of the most distressing phases of pelvic floor lacerations is fecal incontinence from injury to the anal sphinctre.

In the immediate operation after injury, the indication to reunite the several tissues is plain. When, however, the repair is to be undertaken, after healing by granulation with subsequent cicatricial distortions, the problem presents technical difficulties.

“Many and varied methods are still advocated that should, by reason of general surgical advance, have been discarded, while those appearing worthy of more extended trial have not been accorded the prominence they are entitled to” (C. G. Child).

The degree of sphinctral incompetence and the technique of the repair vary with the extent of the laceration into the anterior rectal wall.

In all cases of complete tear involving the recto-vaginal septum, lateral cicatricial retraction shortens the anterior rectal wall, and buries the retracted sphinctre ends on either side of the anus. In some cases these ends are caught in a bridge of cicatricial tissue spanning the anterior edge of the anal opening, thus maintaining a partial fecal control. But, as a rule, the sphinctre ends are so widely separated as to expose the eroded rectal mucosa.

The technical dominants in the operative cure of these injuries comprise two objectives:—

I. Elongation of the shortened anterior rectal wall by utilizing an "apron flap" of vaginal mucosa, thus obviating the liability to infection by suture of the anterior rectal wall (Warren, Ristine).

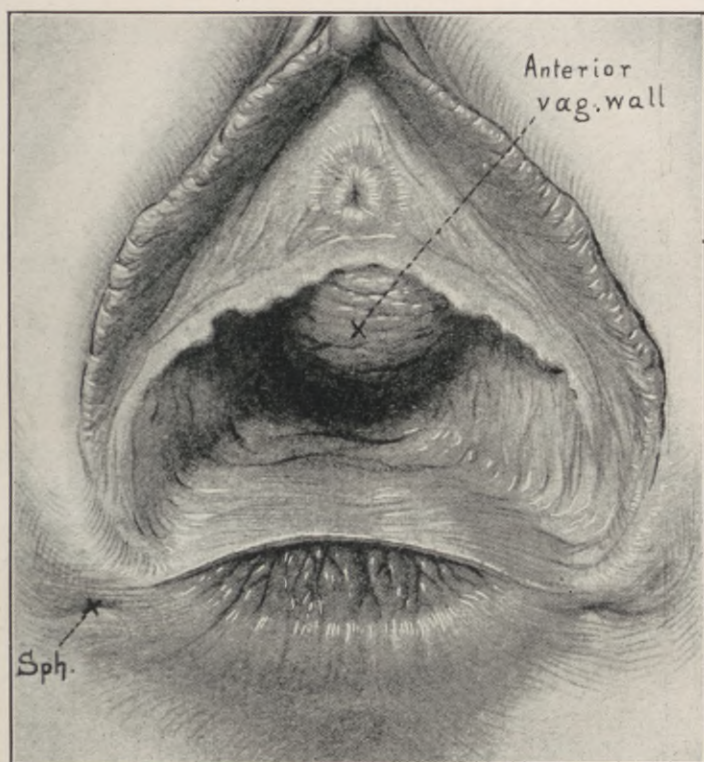


Fig. 95.—Complete laceration of the perineum through the anal sphinctre. Rupture of the rectovaginal septum, with retraction of the anterior rectal wall. Sph, Sphinctre pits over the location of the widely separated sphinctre ends. (Kelly.)

II. Isolation and direct sutural reunion of the retracted sphinctre ends.

Laceration through the sphinctre ani constitutes a complete perineal tear, and the operative cure of

the former comprises an extended procedure for the restoration of the latter in the following order:—

I. Outlining the area of denudation and mobilization of the vaginal "apron flap" from the rectovaginal septum.

II. Liberation and isolated suture of the retracted sphinctre ends.

III. Levator myorrhaphy.

IV. Sutural readjustment of the superficial perineal planes.

With the patient in the lithotomy position, the vulva is retracted laterally by tissue-hooks, inserted as for incomplete tear.

A transverse outlining incision is then carried completely across the posterior vaginal wall, one inch to an inch and a half above its anal margin.

From each lateral extremity of this transverse incision a longitudinal incision is directed to the pits on either side of the anus which mark the location of the retracted sphinctre ends. The three incisions thus outline a square flap on the rectovaginal septum, the vaginal layer of which is carefully dissected downward to the anal margin from the rectal layer, liberating an apron of vaginal mucosa attached at the anovaginal junction.

The base of this apron retracts into the rectum, automatically filling the defect in its anterior wall, thus substituting a curtain of the posterior vaginal wall for the deficient anterior rectal wall.

The apron or flap is liberated from above downward. In this way normal tissue is entered first, cicatricial last, making the dissection easier. As the proper line of cleavage between the rectal and vagi-

nal layer is entered, the splitting of the septum proceeds with little difficulty, until the cicatricial juncture of the vaginal and rectal outlets is encountered. Here the greatest care must be taken not to button-hole the apron or perforate the rectum. As the

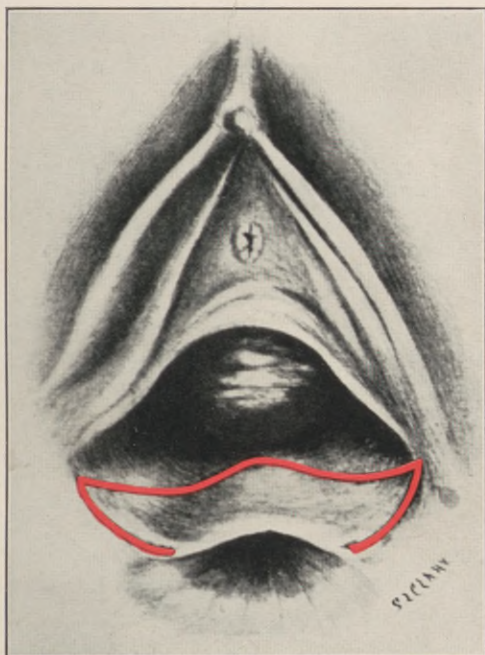


Fig. 96.—Warren-Ristine operation for complete perineal laceration through the anal sphinctre, with retraction of the anterior rectal wall. Outline of apron flap on the posterior vaginal wall.

margin of the septum consists of cicatricial tissue, it requires skillful dissection to preserve a properly nourished flap.

After turning the flap down over the anal orifice like a curtain, the exposed tissues in the sphinctre pits are grasped and drawn forward by small trac-

tion forceps, and the retracted sphinctre ends are freely liberated by clipping their cicatricial envelope with knife-tip or curved scissors. When both sphinctre ends are freely mobilized, they are united by interrupted buried chromic gut or thin kangaroo sutures.

After trimming the apron flap to necessary dimensions, the levator myorrhaphy and the sutural

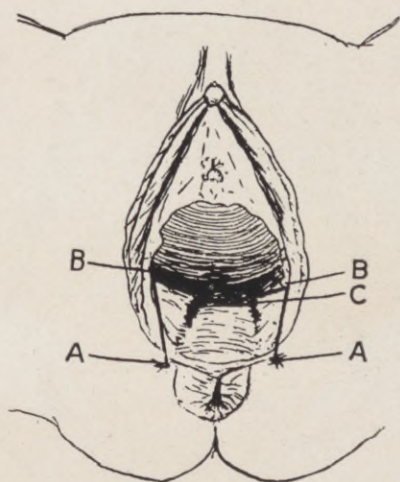


Fig. 97.—Child's outlining apron flap in the Warren-Ristine operation for complete perineal laceration. A, Sphinctre pits. B, Upper extremity of outlining incisions. C, Crest of the rectocele.

readjustment of the superposed perineal tissues is carried out as described under Perineorrhaphy.

Sloughing of the apron edge sometimes occurs, but as a rule does no harm, as the necrosis is superficial.

Child claims 90 per cent. of cures by primary union after the following modification of this method:

“The apron dissected from the posterior and lateral vaginal walls is clamped at three points and allowed to hang down over the anus, where it remains until the completion of the operation. The incision in the vagina is closed with a continuous suture of No. 4

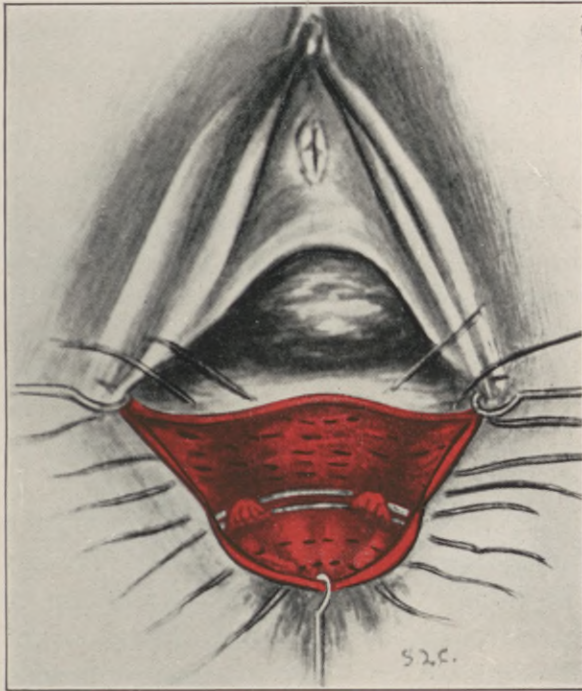


Fig. 98.—Warren-Ristine operation for complete perineal laceration through the sphinctre ani, with retraction of the anterior rectal wall. Suture through the exposed sphinctre ends. Apron flap from the posterior vaginal mucosa drawn over the anal defect by a tenaculum.

forty-day chromic catgut, beginning at the apex of the denuded area on the posterior vaginal wall, and continued down to the outlet, thereby bringing the caruncula together in the middle line to mark the

highest point on the new perineum, as they originally marked the highest point on the old perineum before it was torn.

"In uniting the muscles in the perineum, the method that I first described in 1913 of figure-of-eight sutures of large-size silkworm gut is used. These are introduced as follows: The first suture is passed through the ends of the sphinctre muscle; the free ends are then crossed and introduced in the raw area close to the sheaths of the sphinctre, and brought out through the skin on either side, about one-quarter inch from the wound margin. These are then clamped, but not tied. In like manner three or four figure-of-eight silkworm sutures are passed through the edges of the levator ani muscles, crossed, and made to include in their second bite all intervening tissue. A thorough irrigation of the wound area is now given. All blood-clots that may have formed during the operation are carefully removed, and all bleeding points tied with fine-size kangaroo tendon.

"The sutures are now tied in the following manner: Beginning with the one that unites the ends of the sphinctre, the free ends are drawn on until the first bite of the figure-of-eight is tightened sufficiently to bring together the muscle ends within its grasp. It is then tied by a square knot, just tight enough to snugly approximate the tissues, which it holds. The remaining sutures, uniting the levator muscles, skin, and subcuticular tissues, are tied in the same manner.

"The sutures should never be tied so tightly as to cause cutting or strangulation, and the second knot of each suture should not be tied tight enough to splinter the silkworm, or to interfere with untying it

later, should occasion arise. The wound is now completely closed, and if at its summit, the highest point on the perineum, any gaping is present, an extra silk-worm suture may be introduced.

“A careful survey of the field of operation will

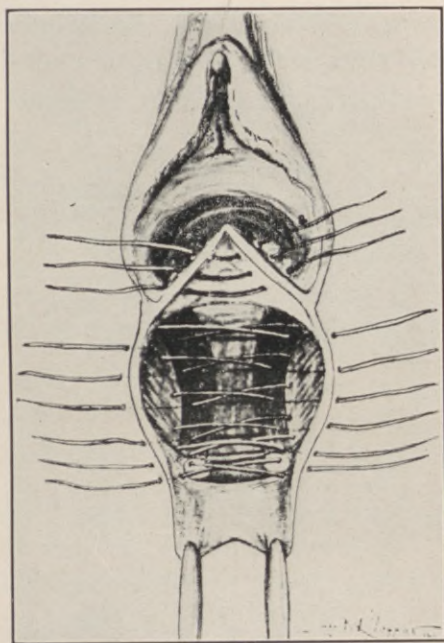


Fig. 99.—Child's method of introducing figure-of-eight sutures in the Warren-Ristine operation for complete perineal laceration.

now show that the apron of Ristine has already to some extent been drawn up into the rectum, thereby lengthening out the previously shortened anterior rectal wall, thus relieving all tension at the anovaginal juncture. A small strip of iodoform gauze is introduced into the vagina to facilitate drainage for the first few days.

“The patient should be catheterized every eight to twelve hours for the first three days, after which the perineum is irrigated during micturition. The wound is inspected daily, and if any of the sutures have been tied too tightly the tension should be relieved. The bowels are moved on the third day, castor oil being the laxative of choice, assisted by an enema when necessary. If an enema is given it should be under the doctor’s supervision, unless the



Fig. 100.—Cross section of figure-of-eight sutures tied. (*Child.*)

nurse is thoroughly familiar with this class of cases. After the third day, when the vaginal gauze is removed, a daily cleansing vaginal douche of normal saline is given. The patient is kept in bed for two weeks. After the fourth or fifth day the apron of tissue over the anus may begin to slough; this will have no bad effect upon the healing of the wound, but the sloughing area should be clipped off with scissors. If the line of demarcation is carefully followed, this will cause no pain.

"The silkworm gut sutures are removed between the tenth day and the end of the second week. As a rule, the end of the second week, when the patient is ready to get up out of bed, is the preferable time. Should infection occur in the wound, the sutures, several or all, are untied and loosened, so as to allow of free drainage and daily irrigation. Later, when the infection is over, and union begun, the sutures are again drawn tight and tied, as at the time of their introduction. During the third week after operation the patient is allowed up in a chair, the bed-pan is discarded, and she may move slowly about her room each day."

Child concludes: "So far as I have been able to determine, the operations for this condition performed by other methods are far from satisfactory, yielding a very small percentage of successful results. By the Warren-Ristine technique, with certain modifications described, I have reported the results of 10 consecutive cases. In only one instance was union by first intention in the least interfered with, and in 90 per cent. the cure was absolute. Once only, in case No. 10, did we fail to restore perfect control of the sphinctre muscle; yet as the patient's condition was very materially improved, even this case cannot be classed as a failure."

In rare instances, the sphinctre ani is torn subcutaneously, causing fecal incontinence without external evidence of the lesion. In such cases, there is also a submucous laceration of the levator ani, with resulting relaxation of the vaginal outlet. Most frequently, however, this condition is due to an unsuccessful operation for complete perineal rupture, in

which union of the perineum is obtained, but with failure to restore the sphinctre ani.

To repair such a sphinctre, Kelly makes a "horse-shoe incision on the perineal surface, extending from one sphinctral pit to the other, parallel to the anterior anal border." The flap of the skin thus outlined is turned down over the anal opening, similar to the apron flap described in the preceding section.

The ends of the incision should extend down on either side to expose the sphinctre muscle, which is readily palpated between index finger and thumb.

After liberation of the sphinctre, its ends are united by two or three interrupted catgut sutures.

It is advisable at this juncture to introduce a retention stitch of silkworm gut, transfixing the skin from just behind the ends of the incision, the sphinctre ends, and the rectovaginal septum. Before tying this stitch, the cutaneous sutures are inserted.

CHAPTER XVIII.

VESICOVAGINAL FISTULA.

IN the entire evolutionary progress of gynecoplastic technology no single phase presents a more striking contrast between past and present methods and results than the operative cure of vesicovaginal fistulæ.

In 1663 H. V. Roonhuysen first suggested the closure of such defects by suture. Following this suggestion, J. Fatio operated successfully upon two cases—one in 1675, the other in 1684—by the method published in 1752: "With the patient in the lithotomy position, a speculum exposed the fistula, the edges of which were freshened with a delicate pair of scissors, and held in apposition by means of a quill suture."

A. J. Jobert de Lamballe (1850-1852) published the first elaborate monograph on the subject, based upon an extensive series of operated cases, many of them successful.

His method consisted in exposing the fistula by speculum and traction on the cervix with forceps, denudation of the fistulous margin, and approximation by suture.

In very extensive defects, he relieved tension by vaginal incisions running parallel to the edges of the fistula, which permitted closure ("*par glissement*"). An incision through the vaginal vault, detaching the cervix for this purpose, is still known as "Jobert's incision."

G. Simon (1854) discarded the lateral vaginal incisions of Jobert, substituting tension sutures at a distance from the wound. The suture securing approximation of the denuded fistula margins he termed "suture of union," and the one relieving tension "suture of detention."

In 1852, J. Marion Sims, working independently of the above, devised the duck-bill speculum and its use in the left semiprone (Sim's) position of the patient for the better exposure of the fistula. He bevelled the denudation of the fistular margin, and closed it with silver wire.

Sims' results in the cure of vesicovaginal fistula had not been equalled in his time, but, notwithstanding the brilliant success following upon his original innovations and manual skill, there still remained a large class of cases that proved intractable to prevailing curative methods, and in which surgery could offer nothing save a complete occlusion of the vaginal outlet, *i.e.*, colpocleisis (Simon).

The first attempts to obviate the necessity for so mutilating a procedure were those of Rydygier (1887), and of A. Martin (1891), who planned to cover the fistulous defects with pediculated flaps from contiguous vaginal mucosa.

Trendelenburg (in 1890) and L. Von Dittel (1893) departed radically from all precedent by approaching the lesion through an abdominal incision, separating the bladder from the uterus, thus exposing and suturing the fistula. The suture included only the bladder wall, and was covered by the utero-vesical peritoneum.

An epochal advance in the operative cure of vesicovaginal fistula was inaugurated by A. Mackenrodt in 1894. This consisted in the *complete* mobilization of the bladder base from its vaginal and uterine attachments, and the separate suture of the vesical and vaginal margins of the fistula.

In very large defects, he interposed the uterine fundus to occlude the opening in the bladder or vaginal wall (vagino-fixation).

Mackenrodt's operation embodies the modern principle of flap splitting and cleavage, the practical application of which has brought the closure of many otherwise intractable fistulæ of all grades, form, size, and position, within the range of curability, and has well-nigh relegated the pioneer work of Sims, Simon, and Emmet, as well as the numerous complex modifications of their denudation methods, to the rear.

This method secures the essential laxity of vesical structure in the immediate vicinity of the fistula, and the free mobility of the vesical base, necessary to effect permanent closure without incurring risk of failure from undue tension. All subsequent contributions present only auxiliary aids and modifications, adapted to isolated conditions, that exercise no dominant influence on the outcome of the procedure in general.

CHAPTER XIX.

OPERATIONS FOR VESICOVAGINAL FISTULA.

THE anterior vaginal wall is fixed and put on the stretch with two tenacula, one catching the cervix and the other the tissues below the external urinary meatus. A straight incision is now made from one tenaculum to the other, across the fistula, through the entire thickness of the vaginal wall to the connective-tissue layer separating it from the bladder.

Mackenrodt splits the edge of the fistulous margin, cleaves the entire bladder base from its vaginal and uterine attachments in all directions, up to the vesico-uterine peritoneum if necessary.

The dissection is carried out with knife, scissors, and gauze brushing. Free mobilization of the bladder, especially its base, is the aim. The edges of the bladder opening are trimmed of scar tissue, and brought together without tension by a Lembertizing continuous or interrupted mattress suture of fine forty-day chromic gut, care being taken not to penetrate the intravesical surface. The vaginal flaps are finally pared and approximated by soft silkworm strands.

In general, it will be found much more expeditious to begin the separation of the vaginal from the vesical wall in the normal tissues at either extremity of the outlining incision, *i.e.*, below the meatus, or at the cervical attachment. The normal line of cleavage is readily located at these points, from which it is

easily extended on all sides toward the cicatrized margins of the fistula, the mobilization and splitting of which is thus facilitated.

In very extensive tissue defects, the uterine fun-

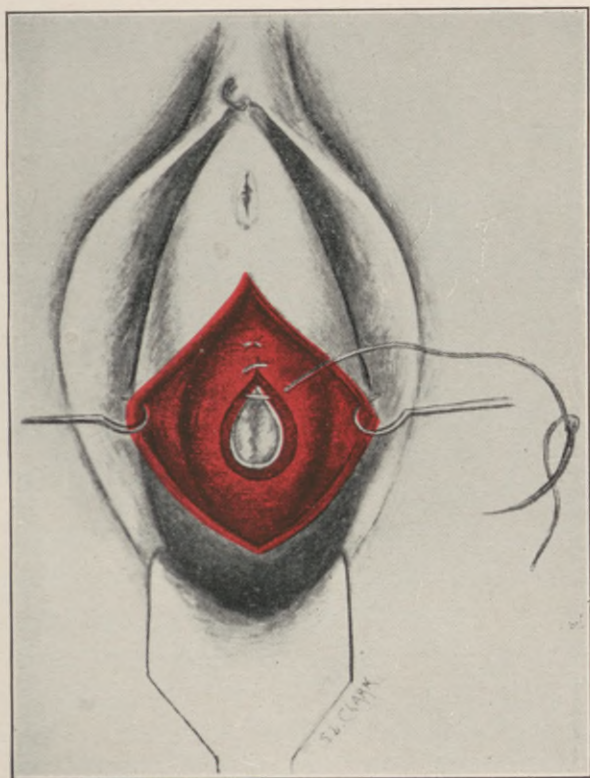


Fig. 101.—Closure of bladder fistula with buried catgut sutures, without penetrating the vesical mucosa. (*Mackenrodt.*)

cus is interposed between the bladder and vagina, its posterior surface thus filling the bladder gap, while its anterior bridges the vaginal opening.

In “vesico-uterine” and “vesico-uterovaginal” fistulæ, the application of Mackenrodt’s principle—

namely, isolation and separate suture of the vesical, uterine, and vaginal tissues—offers the most certain means to successful repair.

Only in those cases, fortunately rare, in which a

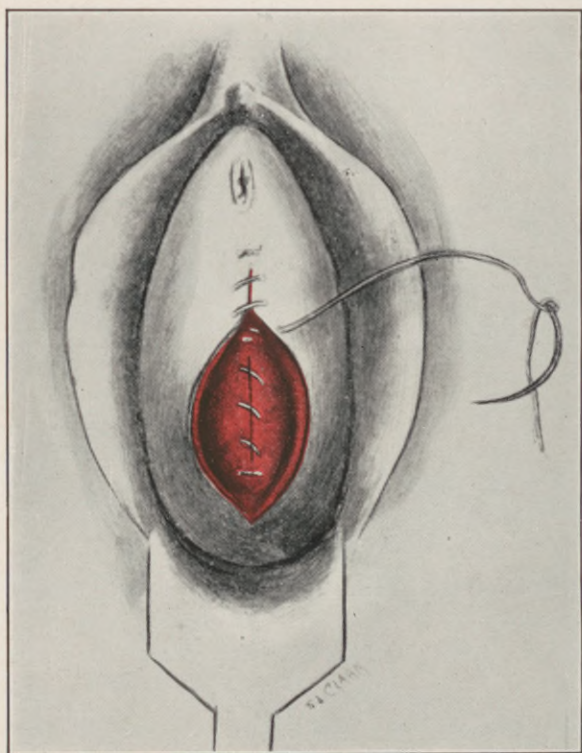


Fig. 102.—Vesicovaginal fistula. Mackenrodt's operation.
Approximation of vaginal flap.

vesico-uterovaginal fistula is complicated by very extensive intrapelvic disease, with firm fixation at the vaginal vault, does an attack by the abdominal route with possible hysterectomy for access to the fistulous tract come under consideration.

Ureterovaginal fistula should be operated intra-abdominally, as a rule. Vaginal plastic efforts to implant the ureter end or the fistulous tract into the bladder, converting the ureterovaginal into a ureterovesical fistula, are not to be commended, as a probable stenotic contraction at the site of union invariably eventuates in destructive degeneration of the corresponding kidney.

In *ureterovesicovaginal* fistula, the simplest and surest course is to implant the ureter into the bladder by the abdominal route, and repair the vesical opening through the vagina.

Exceptionally favorable cases of this class, in which the ureteral and vesical openings are small, very close to one another and imbedded in lax, accessible surroundings, may be operated entirely by the vaginal route in one of several ways.

An oval denudation, at least one-third of an inch wide, is made to encircle, like a ring, a small island of vaginal mucosa, the centre of which presents the fistulous openings of ureter and bladder. The margins of the denuded circle are united by suture in the line of least resistance, thus turning the ureteral orifice into the bladder (Schede).

Where the ureteral orifice is readily located, it may be split on its vesical aspect to the extent of half an inch, making its opening continuous with that in the bladder. The object in either of the above procedures is to eliminate the ureteral opening as a complicating factor, and reduce the condition to one of simple vesicovaginal fistula.

Sampson, in a study of 158 total hysterectomies for carcinoma, performed at Johns Hopkins, records

19 cases, or 12 per cent., of bladder injuries with resulting fistulæ.

These fistulæ usually present a small opening, which is buried in the rigid, firmly adherent vault of an atrophied and contracted vagina.

Every fistulous defect of the bladder, that is freely and completely mobilized from its vaginal and uterine attachments, and properly sutured without tension, will heal promptly.

The technical difficulty presented by postoperative vesicovaginal fistulæ is their inaccessibility.

To overcome this difficulty, Kelly incises the posterior vaginal fornix at the site of the *cul-de-sac*, and opens the peritoneal cavity. This tends to lower and partially liberate the plane of the fistulous area, which may thus be drawn down within reach. But an aid of wider scope, affording much greater accessibility, is offered by the paravaginal incision devised by Schuchardt, to which Ward redirected attention in the following:—

“It is rather strange that in America a correct conception of this incision, and appreciation of its value, is rare. In the minds of many operators confusion exists between Schuchardt’s incision and the ordinary lateral vaginoperineal incision, which is similar to a simple episiotomy. The two incisions are totally different, and there is no comparison as to their effectiveness in procuring accessibility.

The simple straight vaginoperineal incision is superficial, and much less extensive, as compared to Schuchardt’s. Its length is limited by the pelvic wall, and it is usually necessary to make one on each side of the perineum.

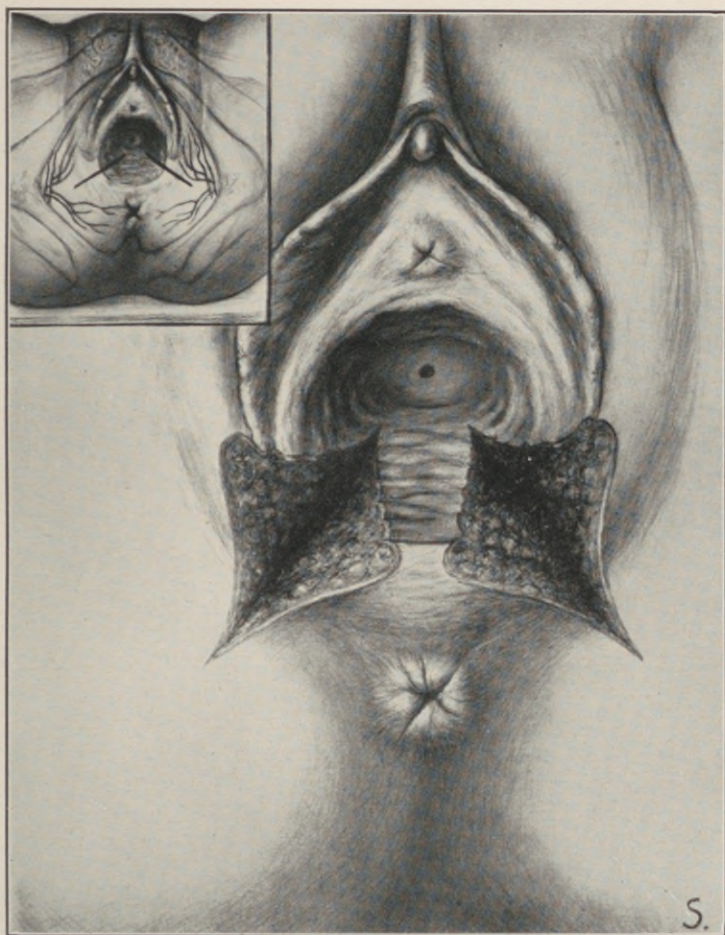


Fig. 103.—Lateral vaginoperineal incision as made by
Duehrsen and others. (*Ward.*)

Schuchardt first described his incision in 1893 for the radical vaginal extirpation of the carcinomatous uterus, and Schauta and others have adopted it in their vaginal operations for cancer.

In 1896 he advocated its employment for other conditions besides carcinoma of the uterus, and reported a case of its successful use in rendering accessible a double vesicovaginal fistula which was fixed in scar tissue high in the vagina. In 1901 he contributed a further study of his incision, with an anatomical report by Waldeyer.

Vaginoperineal incisions have been employed by many operators prior to Schuchardt's description of his operation in 1893, notably Duehrssen, Leopold, Chaput, Picque, and others; but, as Sinclair remarks, it is not fair to speak of Schuchardt's method as a mere extension of these incisions; it is a distinctly beneficial addition to the resources of operative gynecology. Sinclair made Schuchardt's incision on the cadaver, and had the anatomical relations studied by Young.

Gellhorn says: "The effect of the paravaginal incision is surprising. In place of a vaginal tube we have before us a shallow excavation not deeper than one inch."

Duehrssen claimed that he had recommended the same incision three years prior to Schuchardt, but a study of his paper shows that he described the straight vaginoperineal incision, which is directed toward the ischium, and is but 2 to 3 centimeters in depth.

In 1892 Chaput described an incision similar to that of Duehrssen, before the Congrès Français de

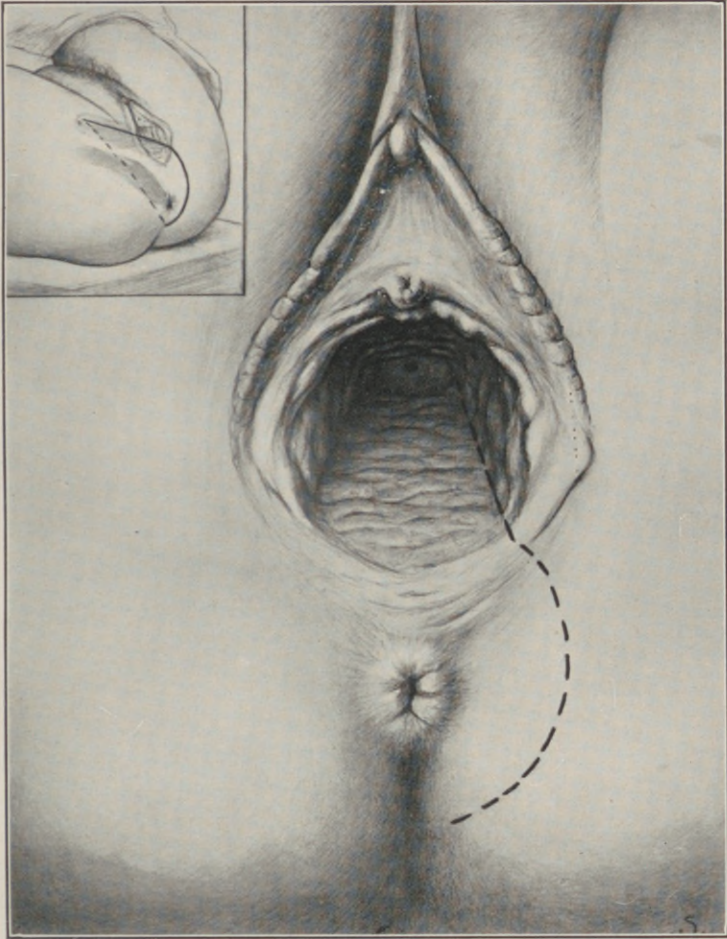


Fig. 104.—Schuchardt's incision outlined. (*Ward.*)

Chirurgie, which he designated as a "colpoperineotomie laterale," and in the discussion Picque stated he had utilized it several times for high vesicovaginal fistulæ.

The vaginoperineal incision of Duehrssen, as described by him in 1889, commenced 6 to 7 centimeters within the vagina, at the junction of the posterior with the lateral wall, and extends in a straight line for a similar distance on the skin toward the ischium.

Schuchardt, in his later description of his operation, describes the site of the incision as a triangle, one side of which is on the vaginal wall, the other on the skin from the junction of the middle and lower third of the labia majora to a point a finger's breadth posterior to the anus, near the middle line, and the base forms a line extending obliquely from the upper end of the incision on the vagina to a point just posterior to the anus. It lies from within outward, partly in paravaginal and in pararectal tissue, the fat of the ischiorectal fossa, and in the subcutaneous tissue. The surface of this triangle is curved on its long axis, with its concavity toward the rectum.

The incision is made preferably on the left side, as it is easier for right-handed operators. The left labium is put on the stretch, and is divided at the junction of its middle and posterior third. The incision is then extended up the whole length of the vaginal tube at the junction of the posterior and lateral walls, completely splitting the vaginal canal. It is next continued on the cutaneous surface in a curve outside of and encircling the sphinctre ani, the integrity of which is preserved, and terminates a finger's breadth posterior to the anus near the median

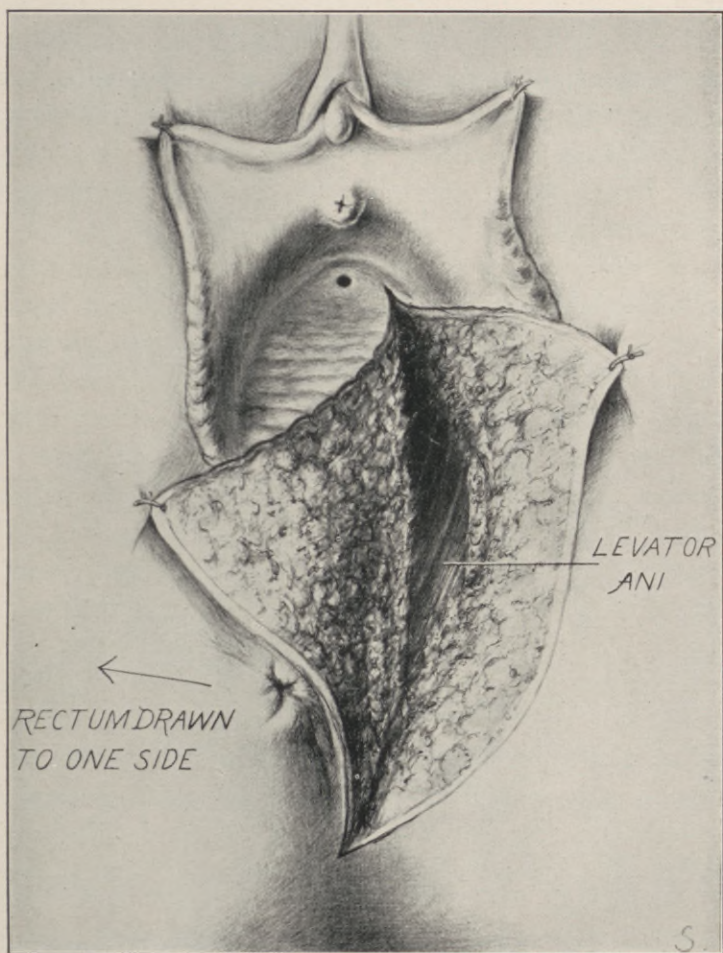


Fig. 105.—Schuchardt's incision completed.
(Drawn from life, *Ward*.)

line. The entire incision is then deepened in a curved direction, enveloping the rectum, without injuring it, until the inner surface of the canal of the levator ani and coccygeus muscle and the depths of the ischio-rectal fossa are plainly exposed. If the incision has been correctly made—that is, with a sufficient curve—the levator muscle will not be cut, except the superficial fibres near their insertion into the coccyx and sphinctre ani.

It will then be seen that the incision, while commencing laterally on the vaginal surface, terminates at its base near the median line, posterior to the rectum, encircling that organ, and consequently mobilizing it, so that it may be displaced to one side. Thus the incision, for all practical purposes, becomes a median one, lying in the longest diameter of the pelvic outlet, thereby obtaining the maximum amount of space. The incision divides the whole vaginal canal, the labium, the skin of the perineum and lateral anal region down to the coccyx, the superficial fascia, the bulbocavernosus and transversus perinei muscles, the lower part of the triangular ligament, the paravaginal and pararectal tissues, the outer fibres of the levator ani near their sphinctre ani and coccygeal attachment, and the cellular tissue of the ischio-rectal fossa. It passes below the vestibular bulb and Bartholin's gland.

Only the superficial branches of the perineal and inferior hemorrhoidal vessels and nerves are divided, and hemorrhage is readily controlled with a few ligatures.

In spite of the extent of the incision, no tissue of importance is injured, and the wound unites readily

if closed with a layer of buried and external sutures. A rubber tissue drain should be placed at the lower angle of the incision, extending into the ischio-rectal fossa.

The wide separation of the bladder from the vagina is practically that of the modern operation for

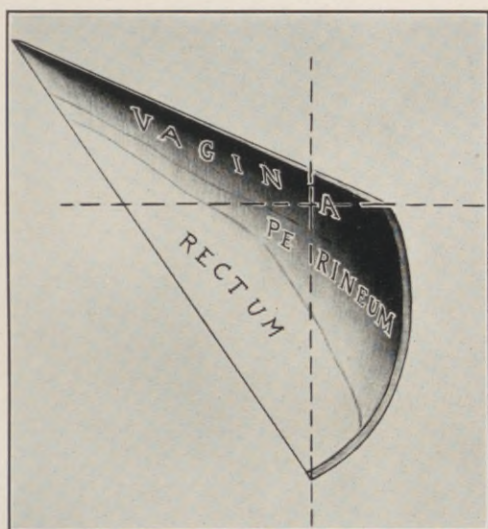


Fig. 106.—Geometrical figure of the plane of Schuchardt's incision. (*Ward.*)

cystocele, with a more extensive dissection at the vaginal vault. In cases in which the bladder is extensively adherent to dense cicatricial tissue, a transverse incision extending the full width of the vault is essential in order to free it sufficiently.

I would not hesitate to freely open the peritoneal cavity, as recommended by Kelly, but so far I have not found it necessary. It is wise to bear in mind

the possibility of the proximity of an adherent loop of intestine where the uterus has been removed.

The point in the technique which I wish to emphasize is, that in separating the bladder base from the vagina the dissection should commence at the outer

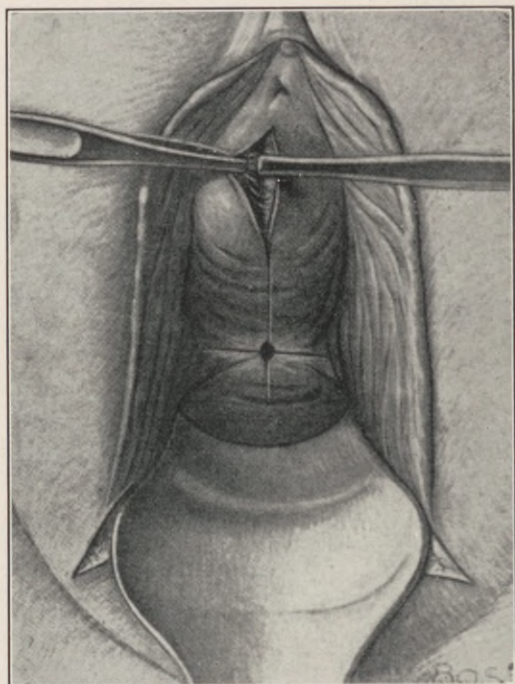


Fig. 107.—Commencement of mobilization of the bladder. (*Ward.*)

end of the anteroposterior incision near the meatus urinarius, where there is an absence of scar tissue, and where it is a simple matter to find the line of cleavage between the bladder wall and the vagina. This having been established, the separation is carried upward and outward until the cicatricial tissue in the region of

the fistula is encountered, when the dissection progresses, partly by the use of the gauze-covered finger, and partly by snipping with round-pointed scissors, with a fair degree of safety, by reason of the line of cleavage having been first determined, and by the use of a sound in the bladder as a guide.

If care and patience are exercised in freeing the bladder laterally to the utmost limit, not only at the vault, but also throughout the length of the anterior vaginal wall, the next procedure (that of dislocating the bladder wall downward so as to bring the site of the fistula within easy reach) will be greatly facilitated.

The employment of an instrument introduced into the bladder through the urethra for this purpose, and to act, as a counterpoint, has been advocated by Pasteau, of France. He has devised a special instrument for the purpose, but I can see little advantage in it over a sound.

I consider that the employment of an instrument in the bladder, used as a lever and counterpoint, is a decided aid, and I have found a straight male sound (No. 28, French scale) to be most satisfactory for this purpose.

Catgut should be used for closing the opening in the bladder wall. I have found No. 1. chromic gut suitable for this purpose. The needles should be very short, curved, round-pointed, and strong. These sutures should penetrate the muscular coat of the bladder only, and have the effect of turning in the edges of the fistula. A second layer may be used to advantage in some cases.

The vaginal incision at the vault should be closed

with silkworm gut sutures, an important point being to catch with each stitch the base of the bladder to one side and beyond the fistula, so that when tied the lines of suturing will be brought in different planes, and will avoid dead spaces.

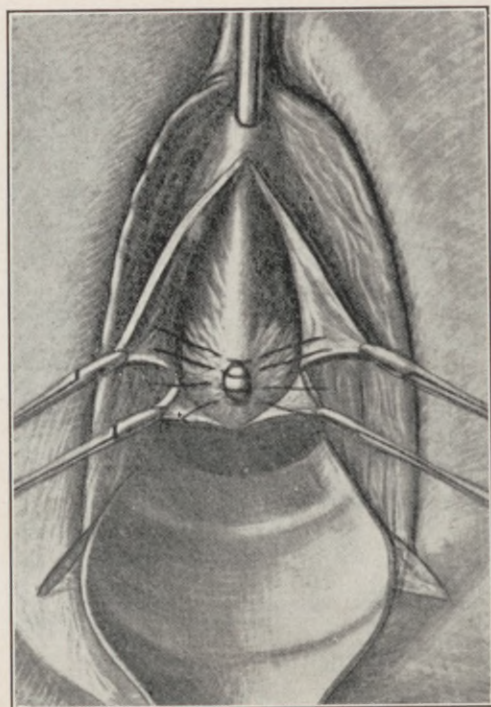


Fig. 108.—Displacement downward of the bladder by means of a sound. Sutures embracing fistular margins in place. (*Ward.*)

The bladder should be drained with a self-retaining catheter, or be frequently catheterized for a period of six days.

Nothing serves more to signalize gynecoplastic progress during the past fifty years, than the state-

ment, that, *not one* of the indications postulated by Simon for colpocleisis, with its morbid sequella, is valid at the present time. No case of vesicovaginal fistula, whatever its extent, should be considered hopeless from a reparative standpoint, provided the vesical sphinctre and adjacent portions of the urethra are intact. Surgery can repair, but cannot create, a sphinctre muscle.

To restore a sphinctre that is partly lacerated or completely severed, as after pubotomy, the bladder should be completely liberated, as for vesicovaginal fistula. The urethra and bladder are then sutured over a rubber catheter with interrupted sutures of chromic gut, which grasp the muscular but not the mucous coat.

At the bladder neck, the sphinctre fibres, together with a delicate but distinct fascia, are caught in the sutures, or sewn separately, just as the sphinctre ani is reunited in complete perineal tears.

The torn and retracted sphinctre ends must be sought and isolated close to the edges of the pubic rami. As an aid in locating these fibres, Frank suggests "passing a traction suture about 1 centimeter from the pubic ramus, at the level of the vesical neck; when this traction suture is pulled upon, the stronger and deeper fibres are brought into view."

Whenever the vesical sphinctre has been completely destroyed in consequence of excessive trauma and sloughing no effort should be expended in plastic attempts to restore the urethral canal, which can at best yield but a cosmetic result, not urinary continence. The only feasible expedient in this lamentable and otherwise intractable condition is the direct

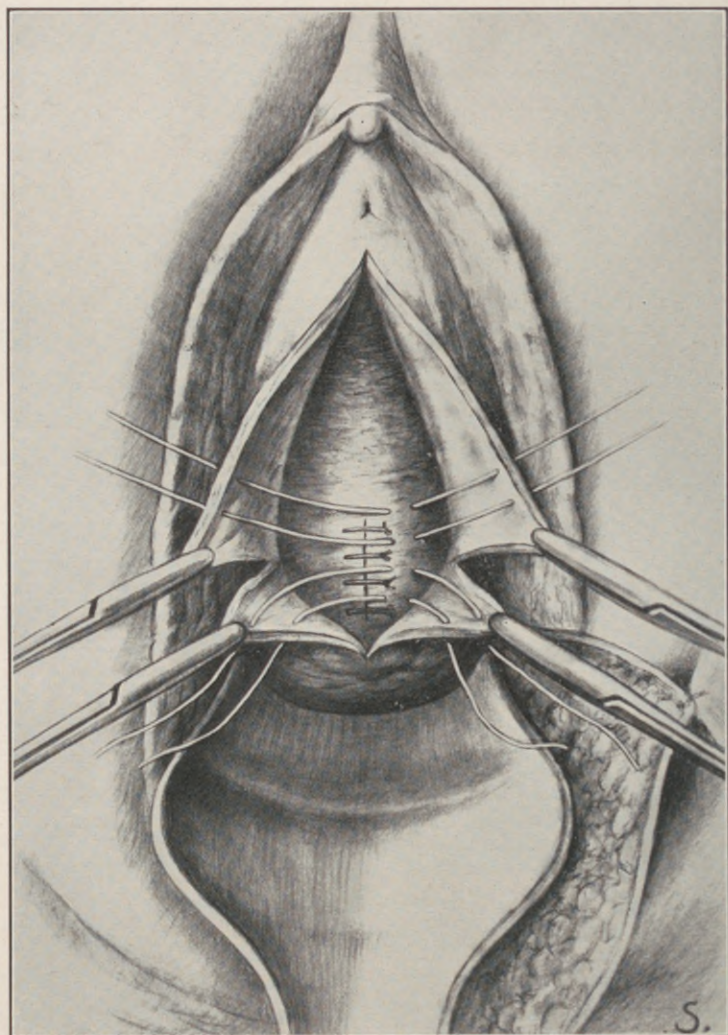


Fig. 109.—Vaginal sutures *in situ*. (Ward.)

drainage of the bladder into the rectum by establishing an ample communication between the bladder and rectum *via* the vagina. This secures a tolerable urinary continence by means of the anal sphinctre.

While this expedient may appear objectionable on theoretical grounds, its practical utility has been

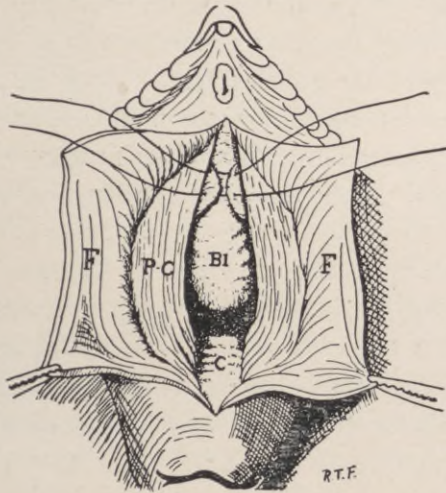


Fig. 110.—Exposure and suture of (lacerated) sphinctre vesicæ. Vaginal flaps (F) have been liberated and retracted. The bladder (Bl) has been freed and pushed upward, exposing the supra-vaginal part of the cervix (C). On each side the pubocervical ligaments (P-C) have been exposed. The sphinctre fibres are shown partly approximated by traction on two untied sutures. (*Frank.*)

amply demonstrated by clinical and experimental results, which tend to prove that the rectum can be used as a substitute for the urinary bladder without giving rise to rectal irritation.

Peterson, in a recent article entitled, "Substitution of the Anal for the Vesical Sphinctre in Certain Cases of Inoperable Vesicovaginal Fistulæ", which embraces the entire literature of the subject to date,

states: "According to Lipinsky, the first utilization of the rectal sphinctre for the control of the urine after the formation of a vesicovaginalrectal fistula and closure of the vagina (colpocleisis) or the vulva (episiocleisis) is to be credited to Maisonneuve. . . . The operation had been suggested, but not practised, by Jobert in 1836, and Bérard in 1845."

Commenting upon 41 recorded cases, inclusive of his own, Peterson concludes: "Most of the operations were performed for conditions where restoration of function—*i.e.*, urinary continence—was hopeless from the start, because of loss of the vesicle sphinctre. In a way, every case of the operation we are considering is a confession of failure. It is not, and never will be, an ideal procedure. At the most, it is merely a way out of a serious difficulty."

As the peritoneal cavity is not invaded by this operation, there should be no primary mortality.

This is borne out by Peterson's study. Maisonneuve's case in 1851 died directly from the operation, but as a result of septic phlebitis. Morisani lost one patient, on the eighteenth day, from pneumonia. One of Rose's patients died ten months after the operation from nephritis, while another operated upon for malignant disease died nine weeks later from metastatic occlusion of both ureters.

Among the successful cases, urinary control was maintained for from one to eight hours.

In 12 cases, the women menstruated through the rectum without apparent inconvenience, while 9 patients ceased to menstruate after the operation without obvious cause. Infection of the uterine cavity from contiguity of rectal contents was not observed.

The most important fact established by these cases is, that ascending renal infection was absolutely excluded, which is undoubtedly due to the preservation of the normal ureteral orifices and ample drainage at the lowest point of the bladder base.

In performing the operation for the establishment of a permanent vesicovaginorectal fistula, it is essential to bear in mind, that the vesical and rectal openings must be made large enough to allow for post-operative contraction, which occurred in 9 out of the 41 recorded cases.

The rectal opening should be made just above the internal sphinctre muscle, large enough to admit two fingers.

The edge of each fistulous opening should be whipped over by a running suture, but the two fistulous openings should not be anastomosed.

It will obviate the tendency to cicatricial recontraction to excise an ellipse from the anterior and posterior vaginal mucosa, and simply incise the underlying bladder base and rectal wall longitudinally for $1\frac{1}{2}$ to 2 inches. The hemming of the fistulous edges thus advantageously everts the vesical and rectal mucosa, which acts as a valvular curtain, preventing the regurgitation of feces into the bladder.

In 15 of the reported cases, the operation was performed in two stages, the fistulæ, vesical, and rectal being made first, and the vulva subsequently closed. In the majority of the cases, however, the operation may be completed in one sitting.

The closure of the vagina (colpocleisis-episiocleisis) is performed by removing a wide collar of tissue

from the circumference of the vulvovaginal outlet, and uniting the denuded surfaces with interrupted silkworm sutures. This converts the perforated bladder and vagina into a common reservoir for urine and menstrual blood, which drains through the rectovaginal fistula into the rectum, from which it is discharged at intervals through the anus. The urethral canal should either be extirpated in denuding the vulvovaginal outlet, or its canal obliterated by a Paquelin cautery.

It is difficult to secure a primary union of the entire vulvar cleft. In only two instances of the series reported by Peterson was this attained. The small resulting fistulæ, however, heal very readily on the application of caustics, only 6 of the 41 recorded cases having proved intractable.

As already indicated, this operation has no direct mortality; there is no danger of renal infection; there is no regurgitation of feces into the vagina; there is no irritation of the rectum. It precludes copulation, which, however, is equally interdicted by the eroded tissues and vaginal defects in the unoperated condition.

It is a mutilation of the genitals, but it substitutes a very tolerable state for an intolerable condition.

Keen, the first among American surgeons to apply this procedure in a case resulting from typhoid sloughing, comments upon the result as follows: "It is an encouraging fact that in any case requiring similar treatment, the later history of the patient shows that for twenty-one years she has only twice had the least trouble—once from a small calculus forming in the vagina, and once from a small abscess

forming in the cicatrix, which abscess spontaneously closed. Instead of being a constant source of disgust to herself and everybody about her, a hospital patient dependent upon charity, and a pariah, cut off from all society, she has been enabled to become self-supporting as a nurse, and to enter freely into her wonted social relations."

CHAPTER XX.

FUNCTIONAL URINARY INCONTINENCE.

THERE is a class of climateric multiparæ, with a record of difficult and prolonged labors, who suffer from a relaxed and incompetent vesical sphinctre.

Their involuntary urinary discharge varies from an occasional ejection on coughing or other sudden exertion to a constant dribble.

In the surgical correction of this condition, various urethroplastic operations are advocated, namely, narrowing, lengthening, twisting, or displacement of the urethral tube, all of which can at best only mitigate the incontinence by establishing an artificial impediment to the urinary escape in the place of its sphincteral control.

The rational operative indication in urinary incontinence, due to widening of the sphincteral opening from relaxation, is to contract such opening by sutural furling of its muscular ring at the vesical neck in the following manner:—

The anterior vaginal wall is divided by a median longitudinal incision extending well over the posterior part of the urethra and vesical neck. The vaginal flap on each side is caught by forceps and separated from the underlying tissues for an ample distance outward.

The vesical sphinctre should be accurately located by a bulbous sound, which is passed into the bladder and withdrawn until its head engages in the vesical

neck. The sphinctre then lies just in front of the bulb, which is identified by palpation.

The muscle may now be exposed by deeper dissection, and furled by direct suture; or the sphincter opening may be narrowed indirectly by the in-

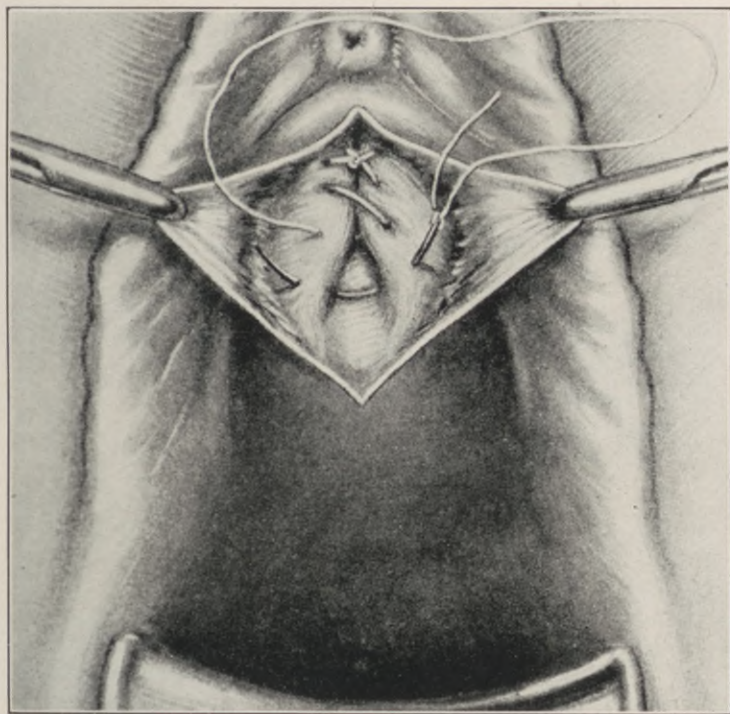


Fig. 111.—Operation for functional incontinence of urine, due to relaxed sphinctre. The vaginal mucosa has been reflected exposing the sphinctre area and the course of the constricting sutures.

folding of its enveloping tissues with mattress sutures of silk or linen thread, after the method suggested by Kelly, as shown in the illustration.

The mattress suture, when correctly placed, embraces the region of the sphinctre muscle, narrows its

opening, elevates the vesical neck, and restores the essential angle of the urethrovesical junction. The vaginal wall is finally reunited in its normal relations.

In the majority of cases a relaxed vesical sphinctre is part and parcel of a generally relaxed pelvic

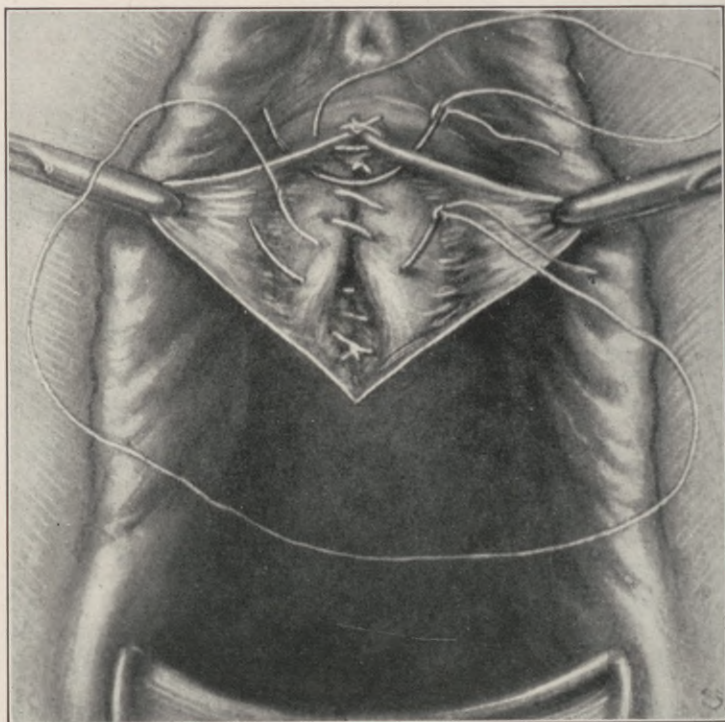


Fig. 112.—Operation for urinary incontinence due to relaxed vesical sphinctre. The second line of buried sutures and union of the vaginal flaps.

outlet consequent upon birth-injury to the levator ani muscle, with partial or complete descent of the bladder, rectal wall, or uterus, all of which must be corrected coincidentally with the above procedure to assure permanency of result.

Incontinence from a Paraurethral Opening of an Abnormal Ureter.—An anomalous type of permanent urinary incontinence, congenital in nature, is due to a minute ureteral opening in the vaginal vesti-

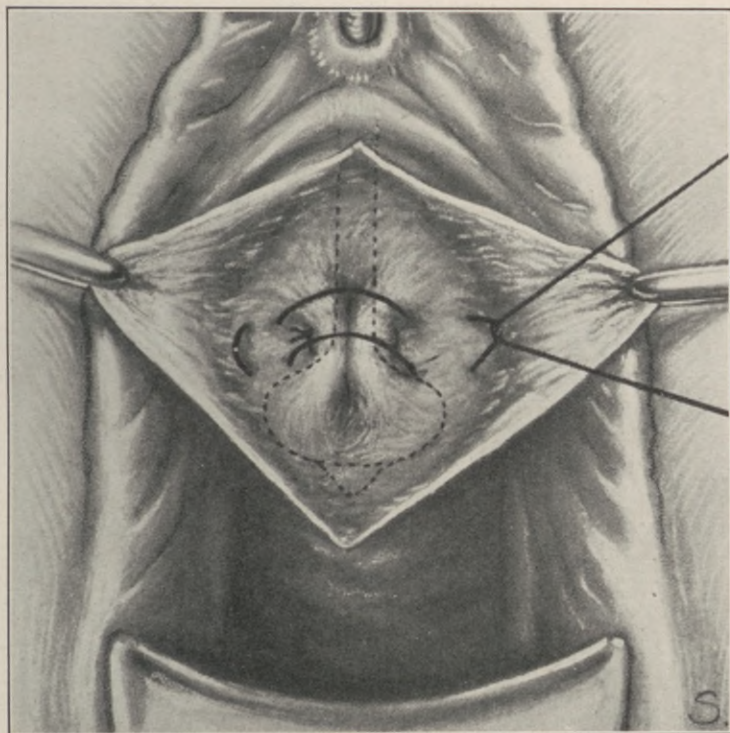


Fig. 113.—Kelly's mattress suture for shortening the relaxed vesical sphinctre. The sphinctre is located by the bulb of a retention catheter drawn into the vesical outlet, as shown by dotted lines.

bule, just lateral to the edge of the external urinary meatus.

The clinical vicissitudes of such a patient are typified by the following case:—

Miss D., nurse, 23 years old, single, suffered from incontinence all her life. During childhood she was treated for "enuresis," then for a "weak bladder." Later in life she was pronounced a "neurotic." One

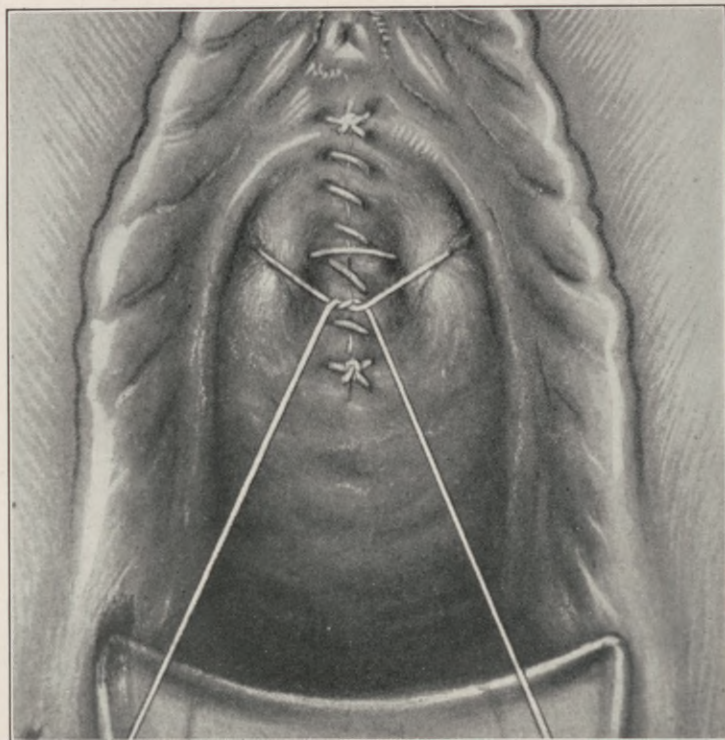


Fig. 114.—Shortening of the vesical sphinctre for functional incontinence. Baldy's re-enforcing suture over the repaired area.

surgeon attributed her incontinence to a "floating kidney," and performed a nephropexy on the right side.

The persistence of the condition prompted another surgeon to remove her left kidney for "tubercular

nephritis." The leak continuing, a third surgeon subjected her to a urethroplastic procedure, four months after which the patient came under the author's observation.

On distending her bladder with methylene blue solution, the total absence of the coloring substance in the leaking urine at once established both the integrity of the vesical sphinctre and the ureteral source of the incontinence.

The anomalous opening was exposed, after a prolonged and tedious search, as a very minute orifice, concealed by a minature contractile valve of mucosa, located just within the right lateral margin of the external urinary meatus. This diminutive opening contracted periodically like a normal ureteral orifice within the bladder.

The patient was cured by dissecting the para-urethral ureter from the para-urethral tissues on an inserted probe, and implanting its free end into the base of the bladder.

These cases are not as rare as the paucity of reports would indicate. Anomalous and supernumerary ureters are quite common, and when such aberrant ureters open into the urethra or vaginal vestibule a permanent incontinence must ensue, which can be corrected only by a ureterovesical implantation, which, in most of the cases, may be successfully accomplished per vaginum.

CHAPTER XXI.

EXSTROPHY OF THE BLADDER.

THIS is a congenital deformity in which arrested fetal development resulted in a diastasis between the two lateral halves of the anterior bladder wall and of all the tissues in front of it, including the abdominal parieties, the pubic bones, and the roof of the urethra, the gap being filled by the forward bulging of the bladder base.

The clitoris is cleft, and the labia majora and minora are widely separated, while the urethra as such is totally absent.

Up to recent years this most deplorable affliction defied all corrective efforts. Much zeal and ingenuity were expended in repeated futile attempts to bridge these extensive defects by various plastic methods, the best results of which were a small urinary sac, chronically inflamed, and subject to recurring calculus formation, demanding constant treatment.

In a number of cases such plastic procedures secured a covering for the protruding vesical cavity, and thus converted the bulging mass of bladder wall into a closed urinary reservoir, but no method had established the sphincteral retentive function essential to the cure of the condition.

The very operations that secured the most complete closure of the defect were farthest from affording relief to the patients, as in just these instances

decomposition of urine, phosphatic incrustations and irritating secretions from the inner surface of the artificial bladder wall, almost invariably necessitated a reopening of the cavity for free drainage and cleansing purposes.

In 1894 Maydl first introduced the modern principle of diverting the urinary flow by transplanting the bladder trigone, with both ureters intact, into the sigmoid, then dissecting out the remainder of the bladder, and closing the abdominal aperture by an autoplasmic method suitable to the case.

He thus preserved the essential controlling mechanism of the ureterovesical orifices.

Hartley collected the results of 46 cases operated upon by this method, with an ultimate mortality of 15 per cent.

The principal danger of Maydl's operation lies in its transperitoneal course. Moynihan obviates this danger by first catheterizing the ureters, then excising the entire bladder wall, and, after stripping the intact rectovesical peritoneum upwards, he incises the rectum and implants the bladder base into the rectal lumen.

As Maydl's original operation and Moynihan's extraperitoneal modification are anatomically impracticable in the female, George A. Peters, of Toronto, elaborated the following method of extraperitoneal transplantation of each ureter into the corresponding side of the rectum, taking with the ureter enough of the bladder wall to preserve the ureterovesical musculature:—

With a guiding catheter in each ureter, the excision of a button of bladder wall is begun on the

lower or pubic side of the ureteral orifices, thus avoiding the peritoneum.

A finger in the cellular space thus opened continues the dissection bluntly to the peritoneal reflection.

When the button of bladder wall is entirely free, the ureter is readily brushed from its loose surroundings and carefully followed back without traction

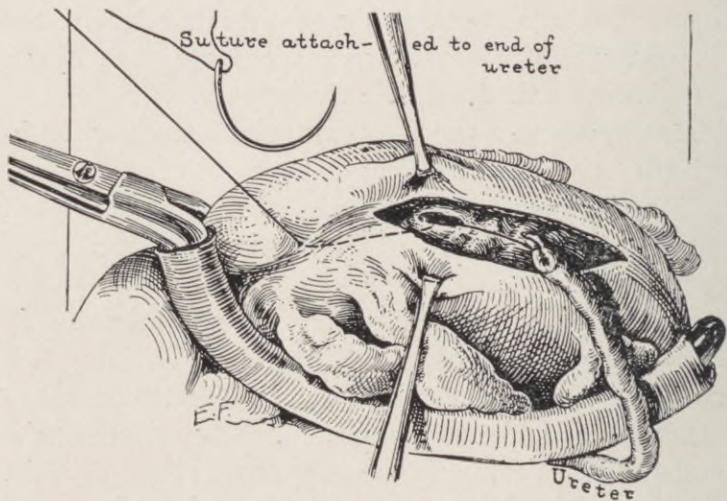


Fig. 115.—Operation for exstrophy of the bladder. Uretero-intestinal anastomosis (Mayo.) Ureter ready to be drawn through incision into the lumen of the large bowel.

until enough is mobilized to secure an approximately straight course from the brim of the pelvis to its new location in the lateral rectal wall.

The transplantation should be made just above the internal rectal sphinctre. A forceps is carried through the anus into the rectum and pressed against the selected spot, where a slight incision enables the forceps to penetrate when it is spread just sufficient

to make an opening that will hold the ureter snugly by means of one or two sutures.

After drawing the button of bladder into the rectal opening, the catheter is removed from the ureter, and when both sides are completed, Peters leaves a small drainage-tube in the rectum. The latter is unnecessary.

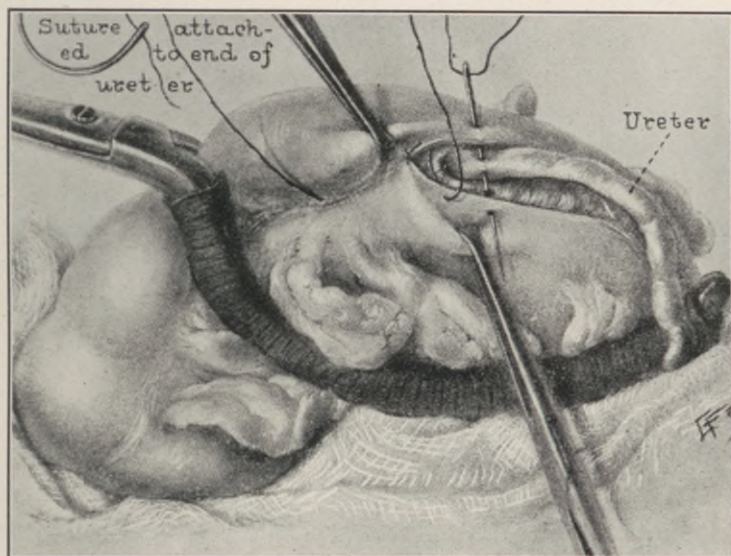


Fig. 116.—Operation for exstrophy of the bladder. Uretero-intestinal anastomosis. (Mayo.) Ureter infolded into large bowel, similar to gastrostomy.

Peters cured each one of his 5 original cases, 4 of which are still living and well. They retain their urine from one to four hours during the day, and from six to eleven hours during the night.

Lendon, of Australia, performed an exactly similar operation May 22, 1899—two months before Peters' first operation—and another in July, 1901,

but his two cases were not published until 1906. In the same issue (*Brit. Med. Jour.*, April 28, 1906) Newland, of Australia, records a case, and in the same journal of May 19, 1906, is the report of a case by Bond, of England.

Sherman, of San Francisco, reports a successful case done by the Peters method, and quotes one of Pye Smith. This makes 10 cases, with two deaths—a record that will be improved upon with greater perfection of technique.

Peters' operation preserves the ureterovesical musculature, as do the Maydl and Moynihan procedures. It is entirely extraperitoneal. Its simplicity and ease of execution result in a minimum of trauma, and therefore in greater likelihood of a proper immediate ureteral function. The infection of the peritoneum is eliminated, and ultimate contractures and strictures about the ureters obviated.

The remainder of the bladder should be removed at a subsequent operation, when cicatricial contraction and the dry state of the tissues offer more favorable conditions for autoplasmic closure of the residual abdominal defect.

In a recent article reviewing the subject to date, Charles H. Mayo discards Peters' operation, and questions the competence of the ureterovesical implant to prevent ascending renal infection.

Mayo contends that "Nature's method of emptying a duct is always by indirection. Thus, the salivary ducts, the common duct of the liver, and the ureters pass through the muscularis, and continue for a distance between the mucous membrane and the firmer outer wall of the cavity. Pressure from within

compresses the ducts, and blocks against dilatation and ascending infection. The fact seemingly was not recognized that the mechanical principle of the passage of the ureter through the wall of the bladder and its mucosa could not be retained after the loss of its innervation. . . . The secret of successfully anastomosing the ureter into the bowel is to tubularize the ureteral entrance for $1\frac{1}{4}$ inches."

On the basis of this contention, he reverts to the transperitoneal implantation of the ureters into the sigmoid. The inherent dangers of this formidable procedure, as compared with the Peters operation, are in no measure offset by the purely theoretical advantage as set forth. Mayo's record of 13 successful cases, with only one operative death, attests the technical skill of the operator rather than the safety of the method employed.

CHAPTER XXII.

FECAL FISTULÆ.

THE fecal fistulæ within the range of gynecoplastic operations comprise:—

- I. Enterogenital.
- II. Enterovaginal.
- III. Rectovaginal.
- IV. Rectoperineal.
- V. Postrectal (congenital cysts).

An *enterogenital* fistula communicates between some part of the intestinal lumen (not including the rectum) and the generative organs. The condition is not common. Lieblein and Hilgenreimer found only 122 cases in the entire literature of the subject.

These fistulæ may be congenital or acquired. The latter result from traumatism during attempted abortion, parturient accidents or injuries, and extra-uterine pregnancy.

In 28 cases of *entero-uterine* fecal fistula collected by Neugebauer, one-half were due to retained necrotic foetal parts; the remainder followed forceps application, or rupture of the uterus during delivery.

The uterus or vagina may be perforated; a loop of intestine protruding through the rent becomes strangulated and sloughs.

The puerperal uterus may be penetrated by the curette or finger in removing placental remnants.

In postpartem sepsis an adherent coil of intestine may be invaded by suppuration of a pelvic exudate,

or punctured by an incision in the posterior vaginal fornix for the evacuation of pus.

Among the established non-puerperal causes of enterogenital fistulæ are forcible dilatation of the cervix; pessaries; clamping and injudicious gauze-packing during vaginal hysterectomy.

Such fistulæ may also originate from primary intestinal conditions, as tuberculosis, syphilis, appendicitis, diverticulitis or malignant growths.

Congenital	Fistulæ of Genital Origin			Intestinal origin	Unknown origin	Total
	Puerperal	Post-operative	Other			
1	47	47	12	5	13	125

The order of frequency in the occurrence is: I., enterovaginal; II., entero-uterine; III., enterotubal. Among 102 cases, 59 were vaginal, 41 uterine, and 2 tubal.

Varieties	No. of Cases	No. of Fistulous Openings			Total No. of Fistulæ
		Small Intestine.	Large Intestine	Large and small Intestine	
Entero-vaginal	57	46	10	3	59
Entero-uterine	37	25	13	3	41
Enterotubal	2	..	2	..	2
Postoperative	26	24	3	..	27
Total	122	95	28	6	129

The location of the fistulæ (as shown in this table, from Lieblein and Hilgenreimer) is in the small bowel, and, as a rule, in its movable segments. It follows that all plastic attempts through the vagina are attended by technical difficulties that jeopardize the outcome by enhancing the possibility of infection and disaster, the abdominal route offering greater access, facility, and safety for any indicated enteroplastic procedure, which, when successful, is invariably followed by a spontaneous closure of the vaginal opening.

While some of the cases may heal spontaneously after a varying period of time, the majority demand operative intervention, as shown in the following table:—

Variety	Non-operated Cases					Operated Cases				
	Cured	Improved	Non-improved	Died	Total	Cured	Improved	Non-improved	Died	Total
Post-operative Fistulæ	11	2	13	3	3
Other Fistulæ	15	12	1	20	48	12	1	3	6	22
Total	26	12	1	22	61	15	1	3	6	25

The mortality in these patients is materially augmented by delay in operating.

Rectovaginal fistula is a direct pathological communication between the vagina and rectum. Surgically, this variety should be classified as follows:—

I. Openings into the upper region of the rectovaginal septum.

II. Openings involving the more central zone.

III. Those presenting in the sphincteral region.

The first and second class are most frequently due to malignant or syphilitic ulceration, more rarely to trauma; while the third class almost invariably results from parturiental or operative injury.

Rectoperineal fistulæ frequently follow unsuccessful attempts at repair for complete perineal laceration extending into the anterior rectal wall.

A fistulous tract connecting the rectum and one of the labia presents an extension of burrowing abscess formation from the ischiorectal fossa, usually tubercular in nature.

Rectovaginal fistulæ of cancerous origin are incurable.

An operation for fistula resulting from syphilitic or tuberculous ulceration will fail unless preceded by appropriate constitutional measures.

The same technical principles that govern operations for the cure of vesicovaginal fistulæ apply to the treatment of rectovaginal fistulæ.

In all cases, when the patient is anesthetized, the anal sphinctre should be incised or properly stretched as an essential preliminary.

To secure ample mobilization and redundancy of the involved tissue layers, the mucosa of the posterior vaginal wall should be incised like that of the anterior vaginal wall in vesicovaginal fistula, and the rectum dissected from the vagina for at least $1\frac{1}{2}$ inches around the fistular margins.

Firm closure of the rectal defect without undue tension should be secured by interrupted absorbable Lembert sutures, introduced from the vaginal aspect,

so as to extend to, but not through, the rectal mucosa. Before suturing the vaginal mucosa, the levator ani should, if possible, be interposed between the vaginal and rectal wall, as described in the chapter on Perineorrhaphy, thus securing an additional barrier against recurrence.

A rectoperineal fistula demands complete division of the perineum through the sphinctre ani along the course of the fistulous tract to its origin in the rectum.

The fistulous tract should be exsected, and the tissues accurately reunited, as in cases of recent complete perineal tear.

Fistulæ situated high between rectum and vagina, like the inaccessible vesicovaginal fistula, may necessitate the paravaginal incision of Schuchardt, already described.

In large rectal defects extending laterally, it is sometimes advantageous to liberate the anterior rectal wall for from 2 to 3 inches above the upper margin of the fistula. This is drawn down and attached to the cutaneous anal margin, and the split sphinctre ani united over it by a buried suture (Noble).

The most frequent cause of failure in rectovaginal as in vesicovaginal fistula is, deficient liberation of the fistular layers from one another.

Postrectal Fistulæ (Cysts; Congenital Fistulæ).—These infected congenital defects result from failure of embryonal occlusion of the neuro-enteric canal. There may be simple pilonidal cutaneous involucre (dermonidal cysts), or postrectal dermoid pockets communicating with the rectum (mucous exclusion),

or a fistula may lead from the skin to the mucosa of the bowel.

The variety which concerns us here is the post-rectal fistula communicating with an epithelium-lined pocket behind the rectum.

A retrorectal dermoid may become infected and rupture into the rectum, discharging pus and dermoid *débris* for months or years. A sinus or opening in the postrectal region discharging pus, hair, or *débris* would, of course, lead to a diagnosis, but the surgeon rarely sees the case in this condition. He finds merely an opening leading to a suppurating cavity, or the patient complains of a periodical discharge of pus from the bowel, the source of which may not at the time be apparent, owing to intermittent closure of the fistulous opening.

The affected parts may be reached by a sacro-iliac incision close to the margin of the sacrum and coccyx, or by a Kraske incision.

On reflecting the bony flap, the wall of the sac can be freed from all of its attachments, severed from the rectum, and removed.

A mural and an extramural double row of absorbable sutures should close the rectal defect; the bony flap is replaced, and the postproctéal space drained.

This class of fistulæ is generally mistreated, since neither simple incision and drainage nor cauterization can effect a cure. The cavity is lined with epithelial cells presenting essentially an organic secreting tissue curable by nothing short of radical extirpation.

CHAPTER XXIII.

CANCER OF THE VULVA.

THE records of primary vulvar cancer to date embrace about 271 reports (Stein).

Among 1177 cases of malignant disease involving the female genitalia, tabulated by Schwarz, 30 were of primary vulvar origin.

While primary vulvar cancer, like cancer in general, is a disease of advanced life, youth is by no means exempt. A number of cases are recorded that developed in women under 30 years of age. Ossing refers to a case in a girl of 20.

Primary cancer of the vulva almost invariably originates from the squamous epithelium of the affected area, and thus presents the clinical and histological features of tegumentary epithelioma, although a few scattered instances of adenocarcinoma originating in the vulvovaginal and Skenes glands are recorded.

The most frequent starting-point of the disease is the inner aspect of the right labium minus, below the clitoris, the other sites of origin in their order of occurrence being: the sulcus, between the labium minus and majus; the anterior and posterior commissures; the clitoris; the urinary meatus; and the vulvovaginal glands.

Papillary excrescences at the mucocutaneous margins, and other local irritative processes in el-

derly women, manifest a decided predisposing tendency to the development of malignant disease, which ordinarily begins as a circumscribed superficial infiltration, gradually developing one of two distinct clinical types in its progress:—

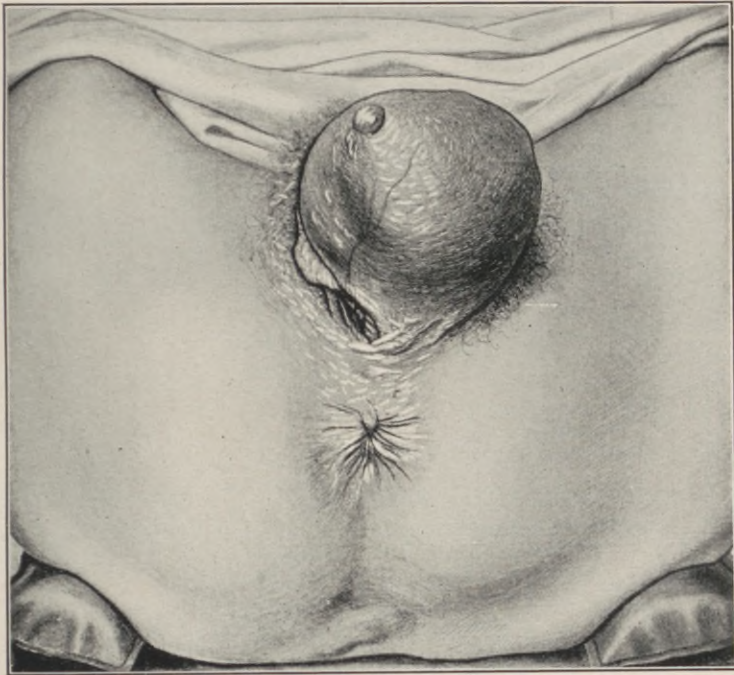

Fig. 117.—Adenocarcinoma of the left vulvo-vaginal gland. (*Kelly.*)

I. A more or less prominent nodular or papillary outgrowth, with a tendency to the formation of “epithelial pearls” and cornification.

The outgrowth may attain the size of an orange; its surface becomes excoriated, and sooner or later breaks into necrotic ulcers.

II. is the more virulent, and presents a diffuse surface infiltration rather than circumscribed tumor formation, characterized by a flat elevation of the deeply infiltrated area, in which early necrobiosis results in sloughing patches, with typical irregular,

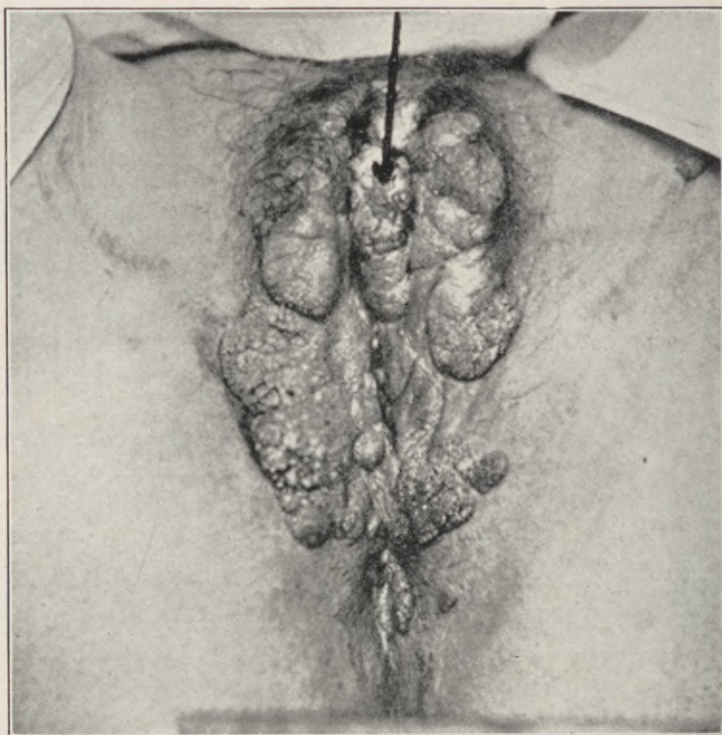
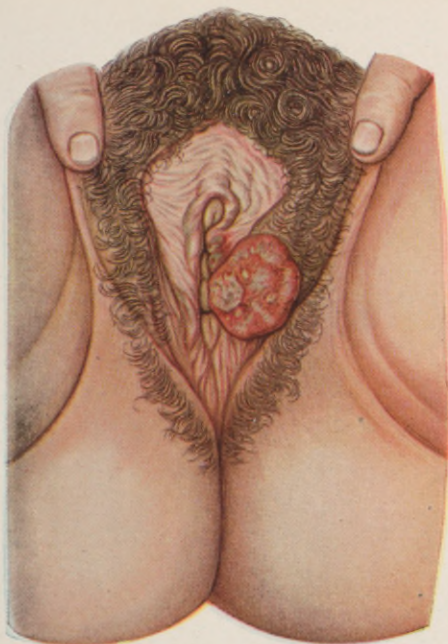
Fig. 118.—Primary carcinoma of clitoris developing on a basis of condylomata acuminata. (Tauszig.)

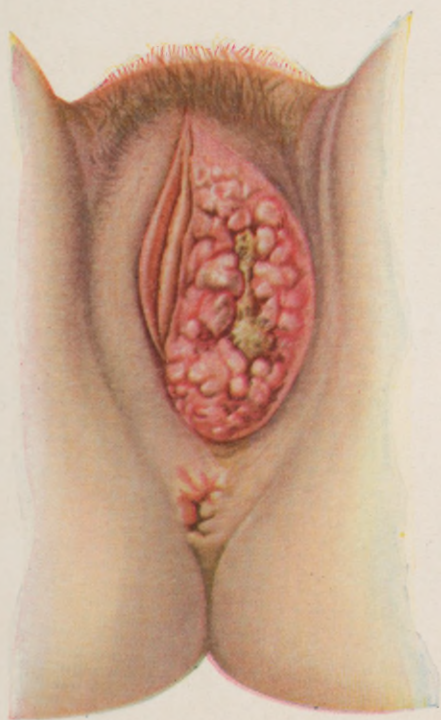
indurated edges, and a grayish, friable, coarsely granular base, exuding a foul discharge.

Involvement of the inguinal lymphatics occurs early in the latter form of the disease, and contact implantations have been noted.

PLATE XXI.



Circumscribed epithelioma of the vulva.



Diffuse ulcerative epithelioma of the vulva.

As a rule, the process extends toward, but not into, the vagina, usually advancing upward into the groin and down over the perineum.

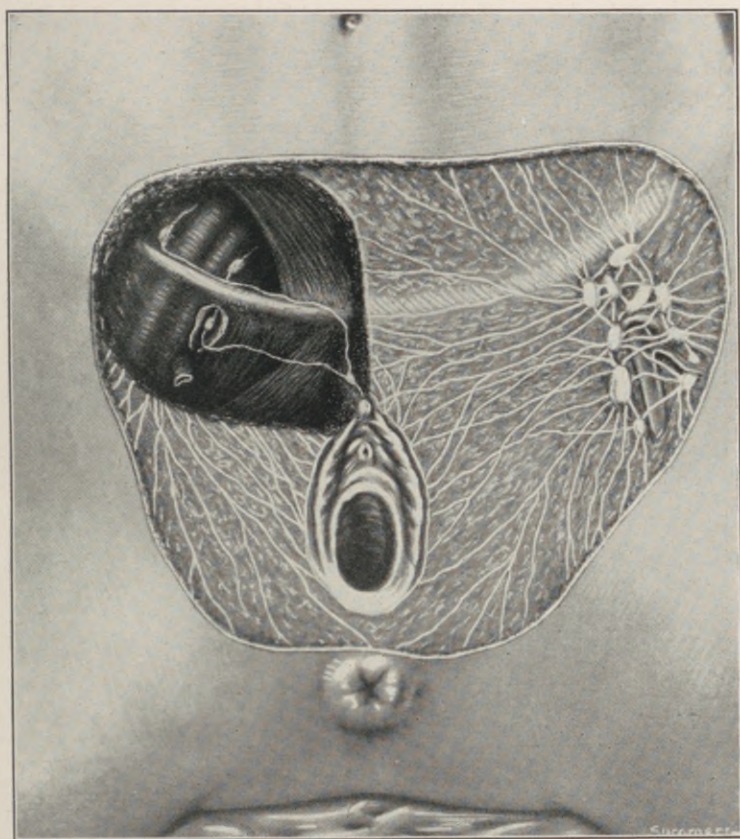


Fig. 119.—The lymphatics of the external genitalia. (*Crossen.*)

The average duration of life in unoperated patients is about two years.

In no class of cancer cases, with the possible exception of primary adenocarcinoma of the corporeal

endometrium, is early radical extirpation so uniformly curative as in primary vulvar epithelioma.

Such an extirpation implies a total exsection "*en bloc*" of all the involved vulvar structures, including the inguinal lymphatics on both sides.

Poirier and Cunéo give the following account of the vulvar lymphatics, quoting in part from Sappey's older work:—

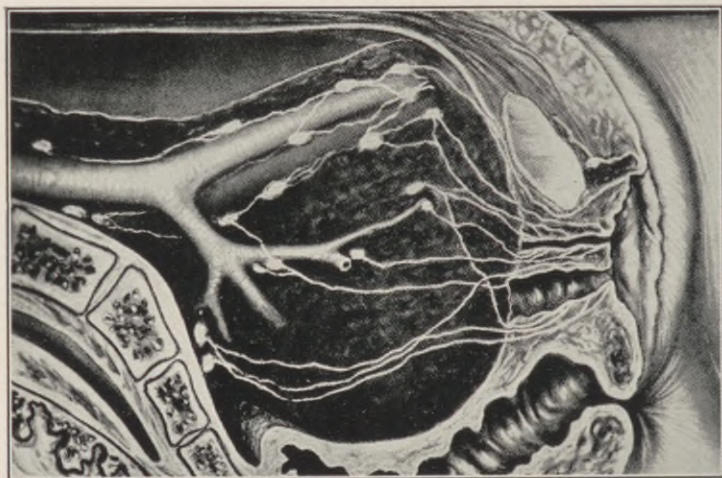


Fig. 120.—The lymphatics of the urethra and anterior part of the vagina pass directly backward to glands in the interior of the pelvis. (*Crossen.*)

“The lymphatics of the vulva arise from a network, the extremely close meshes of which are superposed in several planes. This network covers the fourchette, the meatus urinarius, the vestibule, the clitoris, the labia minora, and the internal surface of the labia majora. It is so loose and close throughout that when it has been well injected it presents at first sight merely an ashy-gray appearance. To dis-

tinguish the innumerable silvery filaments of which it is composed, we must use a magnifying glass. On the external surface of the labia majora the network composed of smaller and larger branches becomes sufficiently distinct to be recognized by the naked eye" (Sappey). "From the periphery of this network of origin run the collecting trunks. The direction of these trunks varies according to their point of origin. Those which come from the anterior third of the vulva run directly upward and forward toward the mons veneris; there they turn sharply and run transversely toward the superficial inguinal glands. The trunks which come from the posterior two-thirds are directed upward and outward, and directly reach their terminal glands. The majority of the lymphatics of the vulva terminate in the glands of the internal-superior group. Some of them may end in the internal-inferior group. It is even possible, though much more rare, to see some of these vessels reach a gland belonging to one of the two external groups. The vulvar lymphatics are far from being confined to a perfectly definite glandular group. When injecting one-half of the vulva the mass may frequently be seen to reach the *glands of the opposite side*. The injection of these glands may take place by a double process. Sometimes it is effected on account of the continuity of the network of origin of the two sides of the vulva in the middle line; at others it is due to the fact that some of the collecting trunks cross the middle line and end in the inguinal region of the opposite side. In all cases, when dealing with an epithelioma of the vulva, the inguinal glands of *both sides* should be regarded as liable to infection.

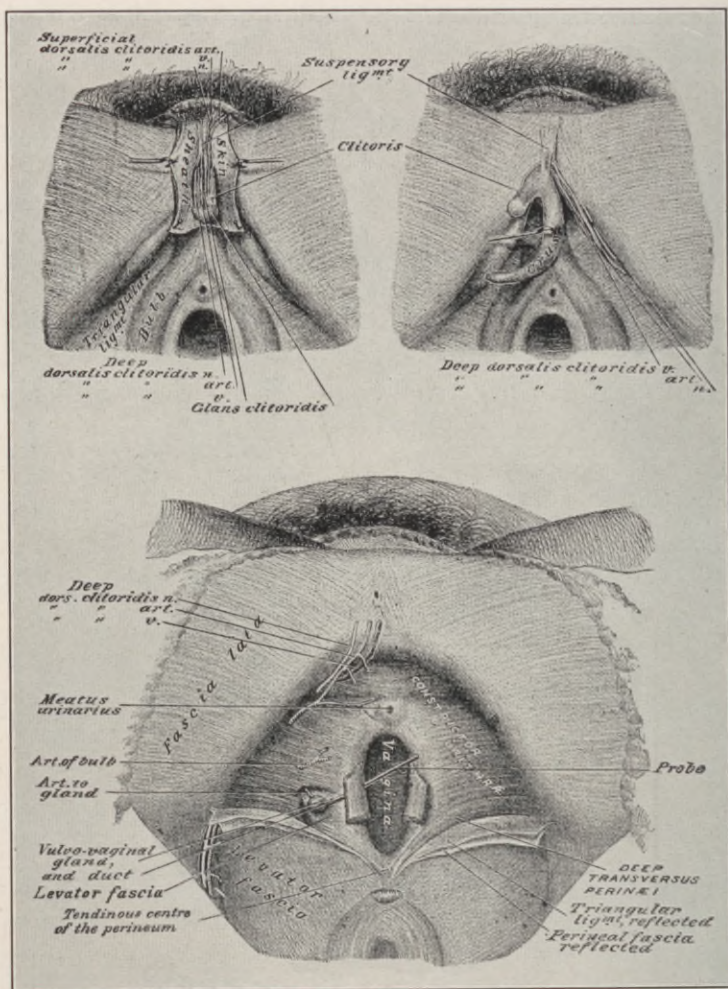


Fig. 121.—Regional layer dissection of vulvar structures.

Surgical interference in epithelial tumors can be efficient only when combined with radical extirpation of the glands, for the lymphatics are invaded from the very beginning, and, although sometimes apparently intact, are always altered histologically."

The lymphatics of the clitoris, instead of passing into the superficial inguinal glands, like the other vulvar lymphatics, pass from the primary plexus in several collecting trunks along the dorsal surface of the clitoris to the front of the symphysis, where they anastomose, forming a plexus which gives off two sets of collecting trunks. One lymph-vessel, passing along the inguinal canal to the external retrocrural gland, is usually encountered beneath the round ligament, while other lymphatics pass toward the crural to their termination in a deep inguinal gland, the internal retrocrural gland and the so-called gland of Cloquet.

The urethral lymphatics in the female drain into the middle and outer chain of the external iliac glands, the hypogastric glands, and the glands of the promontory.

The practical application of these anatomical findings is very clearly and concisely summarized by Crossen ("Operative Gynecology," 1915, p. 476) as follows:—

I. "From a cancer of the labium majus or minus all the lymphatic distribution in the early stage is likely to be to the inguinal glands.

II. "This distribution may extend not only to the side on which the lesion is located, but also to the opposite. Hence the glands on both sides should be removed.

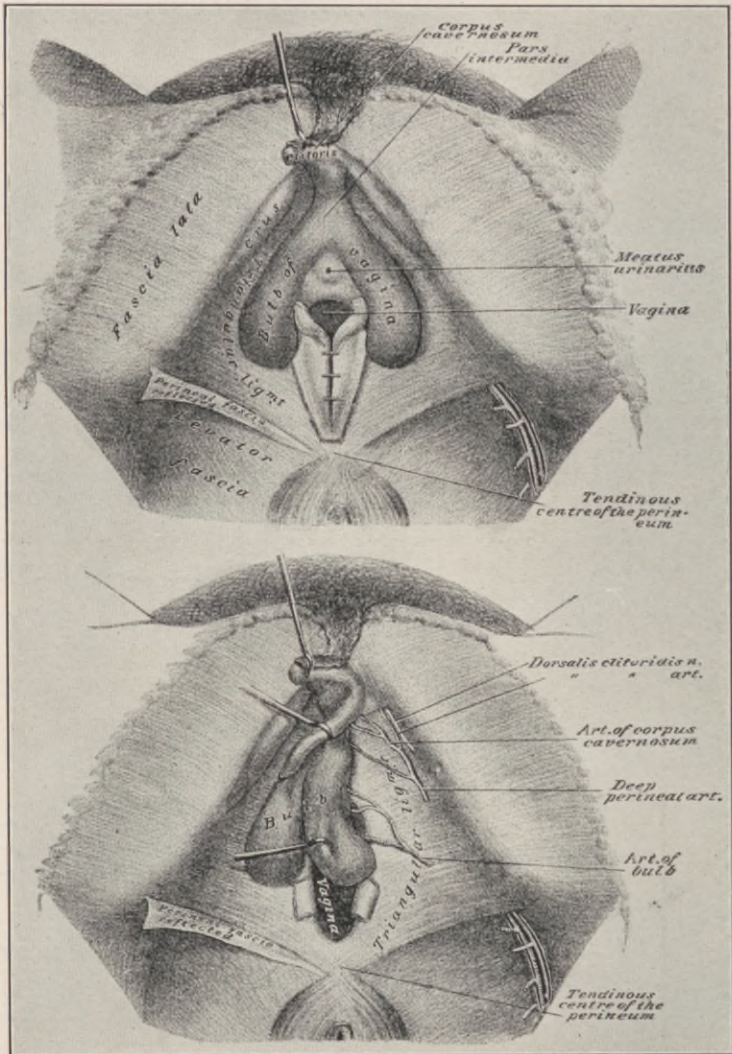


Fig. 122.—Regional layer dissection of the vulvar structures.

III. "In cancer of the clitoris, a very early distribution to the glands *inside* the pelvis is probable.

IV. "In cancer of the urethra also, invasion of the interior of the pelvis is favored by the lymphatic distribution."

Technically, the operation for cancer of the vulva should conform strictly to the established modern

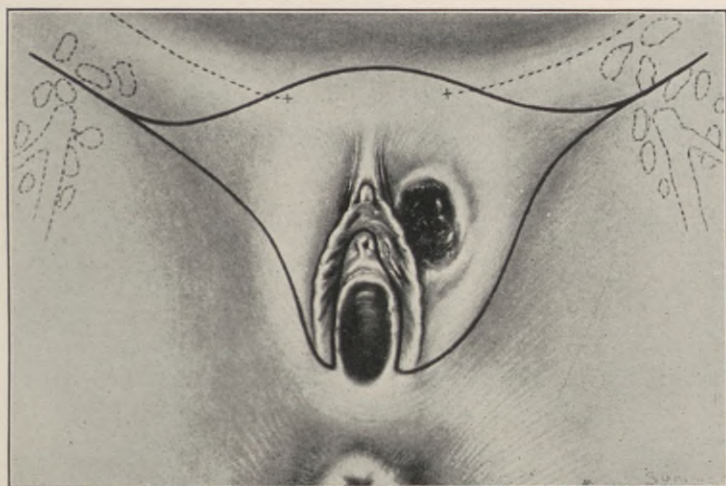


Fig. 123.—Outlines for the "block excision" of the external genitals. (Crossen.)

principles of radical cancer extirpations "*en bloc*", that is, commencing with the excision of the inguinal lymphatics and ending with that of the vulva, the whole involved area is removed from above downwards in its entirety, as one unbroken block, which includes the glands, the lymph-vessels and the vulvar tissues, with an ample margin of uninvolved skin.

To obviate dissemination, this entire dissection is conducted through the surrounding healthy tissues,

as wide of the disease as feasible, and all rough manipulation of the cancerous structures is scrupulously avoided.

In the following adaptation from Crossen, Stein summarizes the stages in the operative technique as follows:—

First step: "Circumferential skin incision of the

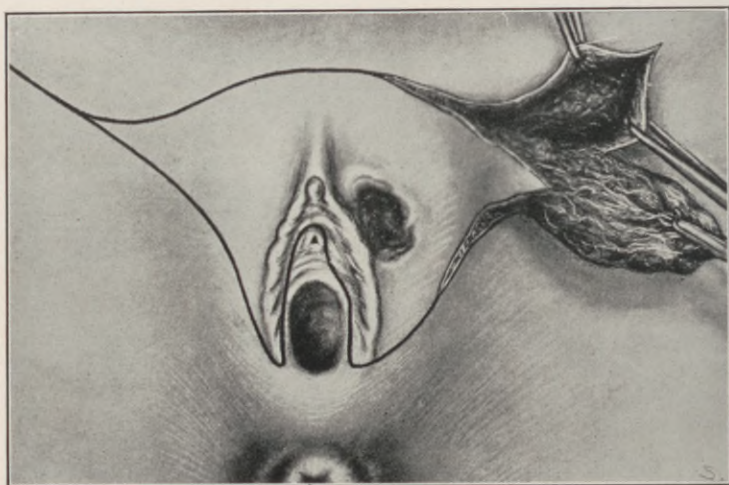


Fig. 124.—First step in the "block excision." The inguinal gland-tissue dissected out. (Crossen.)

surface to be removed, including a wide margin about the lesion, extending outward over the lymphatics on each side. Where the vulvar lymphatics are more deeply situated a linear continuation of the incision and reflection will be sufficient."

As some of the lymph-vessels run upward for a considerable distance before turning outward, while others decussate, it is necessary to excise the superficial tissues well up over the pubes.

Second step: "Block dissection of the gland-bearing area on each side, including the adjoining tissues and the contents of the saphenous opening, where injury to the deep veins must be carefully avoided."

From being skin deep at first over the gland areas, the incision, as it approaches the vulva, penetrates the structures down to the muscles and fascia.

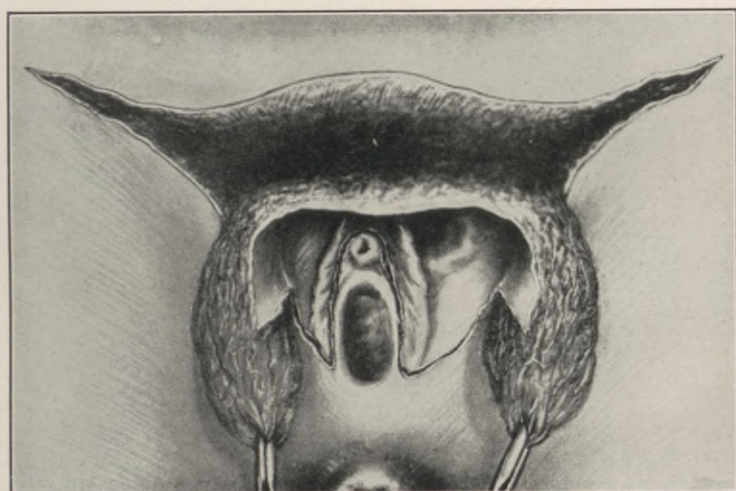


Fig. 125.—The block of tissue partially excised. (Crossen.)

Third step: "Removal of the tissue block '*en masse*,' guarding against injury to the urethra."

Enough of the vestibular mucosa should be left intact to cover the urethra and prevent cicatricial distortion of the urinary outlet. This strip of mucosa may be safely preserved, as its lymphatics terminate in the excised glands of the groin.

Fourth step: "The large raw area left by the excision is covered as far as possible by sliding flaps,

by tension sutures, and relaxing incisions, the details of which will necessarily vary in different cases. It is preferable to leave parts of the wound to heal by granulations than to incur sloughing by overtension. . . .”

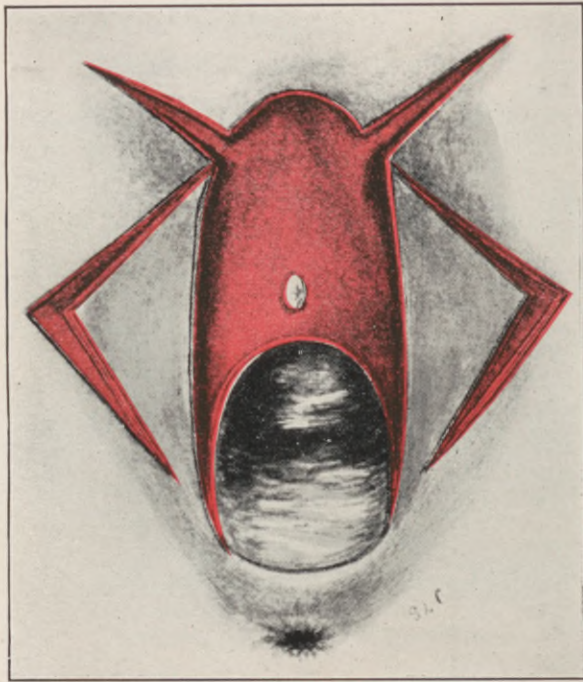


Fig. 126.—Denuded area and flap outlines after the removal of the clitoris, vestibule, anterior part of the urethra, and labia, with extension of the incisions for the removal of the inguinal glands.

The absolutely fatal prognosis in advanced cases should prompt early intervention.

The *inguinal glands must invariably be extirpated on both sides, whether demonstrably involved or not,* and the whole region of the groin thoroughly cleared

of all lymph-carrying structures, similar to the clearing of the axillary space in mammary cancer.

The extraperitoneal extirpation of deep glandular involvement, according to Stoeckel, begins with an incision parallel to Poupart's ligament, extending from the inguinal ring to the anterior-superior iliac spine, and along the anterior third of the pubic crest.

The parietal peritoneum is reflected toward the median line, exposing the ureter in its entire course, as well as the large iliac vessels, when the deep and superficial pelvic lymphatics with their enveloping connective tissue are removed in continuity with the deep and superficial inguinal glands.

A more extended radical operation by an intraperitoneal method was again advocated by Stoeckel in 1912, aiming to extirpate the hypogastric glands in addition to the iliac, the superficial, and deep inguinal. The intra-abdominal glands are removed through a median laparotomy incision, which is then closed, and the inguinal glands removed by way of two oblique incisions above the inguinal ligaments.

At the point where the laparotomy incision and the curved incision from one iliac spine to the other meet, a vertical incision is applied, which passes downward over the symphysis encircling the vulva. Next, the vulvovaginal tissue is detached from the bone, together with the tumor. This is followed by suture of the wound and permanent catheterization of the bladder.

Routine laparotomy, in Stoeckel's opinion, is a very desirable preliminary, and improvement of the operation, and he recommends its performance as a valuable first step in all operations for cancer of the

vulva. A patient recently operated upon by him according to this plan made a good operative recovery. In another case which was operated upon according to the customary method—namely, extirpation of the total lymph gland apparatus from the anterior-superior iliac spines in connection with the entire vulva—

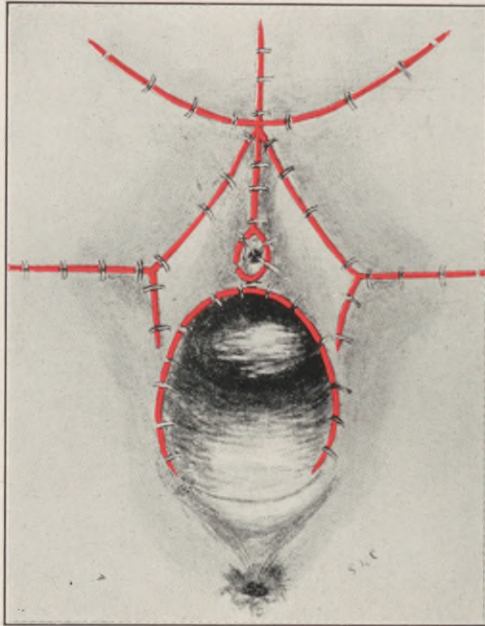


Fig. 127.—Wound closed.

the wound healed by first intention, but a small nodule developed in the vaginal cicatrix on the right side, evidently an inoculation-recurrence, as it was found on examination to be carcinomatous.

It is doubtful whether such extensive and formidable operative invasions are justifiable, more especially as the conviction generally prevails that in

cases where the disease has actually extended to the intrapelvic lymph-nodes the extended radical procedures offer a forlorn hope.

Ordinarily, the neighboring healthy tissues are sufficiently mobile to permit of wound closure by direct suture of the skin and vaginal mucosa.

In very extensive denudations it is necessary to secure sliding skin flaps from the corresponding thighs to cover the defect.

By means of circumferential relaxing incisions, it is usually possible to approximate all the margins without injurious tension. If at any point this cannot be accomplished, the intervening gap may be left to heal by granulation.

A considerable amount of scar tissue is tolerated in this region without disturbance, provided the urethra is not distorted by cicatricial contraction. Hence, accurate coaptation, especially about the urinary meatus, should be secured.

CHAPTER XXIV.

ELEPHANTIASIS VULVÆ.

IN its clinical application, the term *Elephantiasis vulvæ* designates a generic group of local manifestations, linked by a similarity in objective features, but differing in their etiology.

These objective features are characterized by hyperplasia and hypertrophy of the vulvar tegumentary and subjacent connective tissue layers, concomitant with local lymph stasis and dilatation of the lymph-channels.

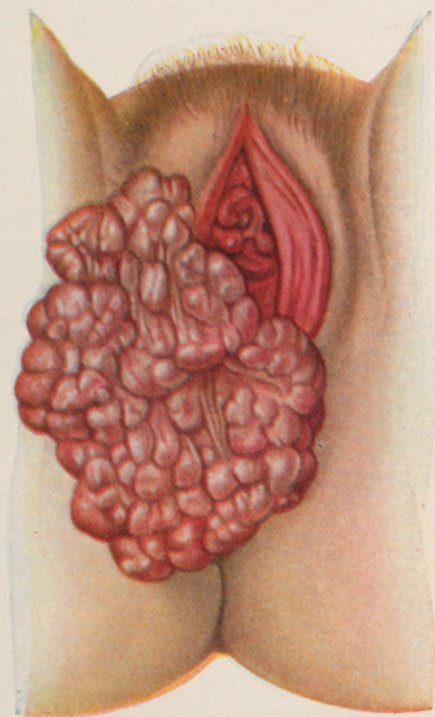
The clitoris, labia minora, labia majora, and perineum, in the order named, present the initial focus from which the process extends, rapidly or slowly, involving the whole or part of the vulvar region in a growth that may reach to the knees and weigh 30 or more pounds.

The surface of such growths may be smooth, rough, warty, polypoid or ulcerated. It presents macules, papules, and cysts, very large masses being invariably fissured and lobulated.

Negresses are more prone to the disease than white women.

The disease is endemic in the tropics, as a result of filarial infection, while the non-parasitic form, which may occur in any climate, is most frequently due to syphilis or tuberculosis. But there are many cases, of obscure etiology, that develop in the course

PLATE XXII.



Elephantiasis of the vulva.

of various chronic inflammatory lesions, productive of local lymph stasis.

In an article on "Esthioméne and Elephantiasis Vulvæ", A. Stein reports a case, and reviews our present knowledge of this indeterminate class as follows (see Fig. 128):—

"During recent years publications upon this subject have been very few. This is probably due to the fact that our knowledge of maladies of the vulva is growing clearer, and we can distinguish ulcerative, tubercular, or luetic processes from those of an indeterminate etiology. Under the latter heading, however, there is a small group of diseases—better, perhaps, a clinical picture—to which we can apply no better appellation than that of 'Esthioméne.' This term was employed for the first time about sixty years ago by Huguier. He, like his contemporaries, knew no methods of differentiation among luetic, tubercular, and simple ulcers of the external female genitalia. Chronic inflammatory processes due to chemical and other non-specific agents could not be separated from those caused by specific organisms. It is possible, however, to reopen this question, and to analyze it more accurately, since our conception of the nature of syphilis and tuberculosis is no longer vague, as in the days of Huguier. . . . It seems clearly established that we are dealing with a condition the etiology of which is still obscure. . . . It may be argued that the overgrowth presents a type of true lymphangioma. It will not be difficult, however, to show that this is not so.

"Our conception of lymphangioma is not a perfectly clear one, for the simple reason that it is

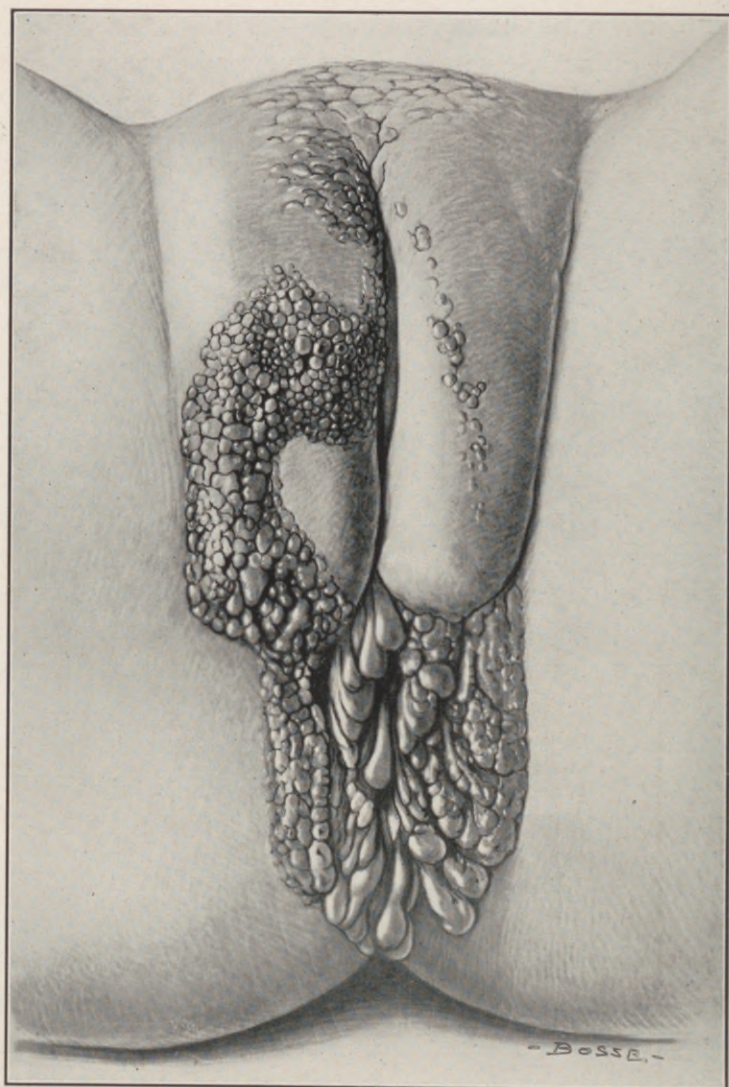

Fig. 128.—Elephantiasis. “Esthioméne” of the anovulvar region. (Stein.)

difficult clinically and pathologically to distinguish between a lymph-vessel new growth and a lymph-angiectasis. Winiwarter, Wagner, and Unna have attempted rather unsuccessfully to clear up this subject, but have succeeded mainly in splitting hairs. One very readily recognized disease coming under this caption, which deserves closer scrutiny, is 'lymphangioma circumscriptum cystoides cutis.'

"Clinically, this is characterized by the appearance upon the skin of small, clear cysts from 1 mm. to $\frac{1}{2}$ cm. in circumference, occurring in groups over an area of from 1 to 4 inches. These cysts contain clear serum, and have non-inflammatory bases. Occasionally in the subjacent skin teleangiectases are found. At times the blood-vessels rupture into the cysts, causing their contents to become hemorrhagic. The disease is one of youth. It is usually found about the neck, shoulders, upper thorax, lips, and even the tongue.

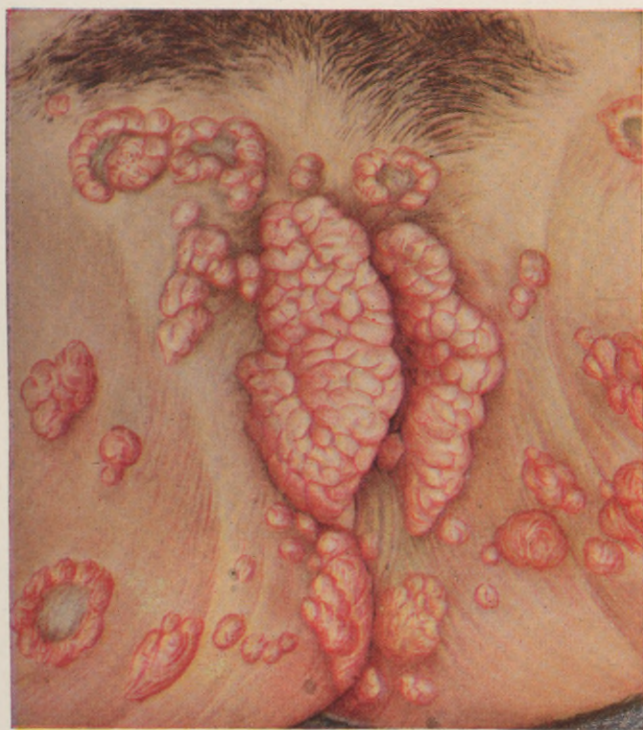"Strange to say, the first case in the literature, described by Tilbury and Calcott Fox in 1879, was one in which the lesions were located upon the perineum and thighs. In no case recorded since then has this been observed. The patient was a young man of about 20. Fox designated the disease as lupus lymphaticus, and we cannot evade the suspicion that this case may serve as a connecting link between the true circumscribed lymphangioma and esthioméne. A further point of similarity is furnished by Freudweiler, whose good fortune it was to observe a case from its inception. The earliest manifestations he noticed consisted of small yellow spots, which, becom-

ing raised, were ultimately converted into cysts. In our patient all of these stages of development were present, the flat lesions being situated upon the mons veneris, the others further backward upon the labia. In no case in the literature was any reference made to ulceration or polypoid formation.

"Histologically, the lesions have been described as clefts corresponding to lymphatic spaces in the connective tissue of the papillary body and cutis. Some were pear-shaped, with the apex pointing downward, and connected by strands of cells with the cutaneous blood-vessels. All contained lymph-cells; all were lined with endothelium, sometimes several layers deep. Freudweiler found no evidence of inflammation. Wäelsch, on the other hand, did. All other investigators agree with Freudweiler.

"Concerning the etiology, opinions are evenly divided as to whether the disease is caused by proliferation of the lymph-vessel endothelium *per se*, or whether it is due to lymph-vessel dilatation. Without entering into this discussion, it seems unlikely that a new growth in the true sense of the word can depend for its origin upon a process commonly regarded as inflammatory. In comparing our case, then, to cystic lymphangiomata, we note the following points of similarity, viz., the presence of macules, papules and cysts. More striking, however, are the pronounced differences. In lymphangioma cysticum, ulcerations, hypertrophies, elephantiasis are entirely lacking, and there are no ascertainable mechanical grounds for cyst formation such as are present in this case. Obviously, then, we must rule out the pre-

PLATE XXIII.



Syphilitic gummata.

sumption that our case is one of lymphangioma cysticum, and seek another diagnosis. This we believe to be the one already mentioned, namely, esthioméne."

While elephantiasis of the vulva is not a malignant disease, the intense pruritus, the painful excoriations, and the eventual impediment to urination, defecation, and copulation, compel the patients to seek relief, which is afforded only by a total extirpation of the tumefied areas.

The operation must be guarded by the strictest aseptic and antiseptic measures, to avoid infection and its rapid dissemination through the dilated lymph-vessels.

Before incising the tissues, all ulcerated surfaces should be thoroughly seared with a thermo-cautery.

The mass should be enveloped in moist bichloride gauze thus securing a firm hold for fixation and traction, while the tissues about its base are incised from above downwards.

In very extensive extirpations, Kelly grasps the gauze-covered mass with the left hand, and by traction "forms a distinct pedicle where none exists naturally." This pedicle is transfixied with successive silkworm ligatures, and the mass excised from above downwards, tying each ligature before incising the next section of pedicle.

The amputation is thus continued, excising and closing area after area, until the whole mass is removed and the wound completely closed.

By this method of sectional successive transfixion and closure, the ligatures serve the double purpose of hemostasis and coaptation.

These hypertrophies should be removed as early as possible, before they have attained to the septic and excessively vascular stage, in which the operation is at best an extremely dangerous undertaking.

CHAPTER XXV.

CONGENITAL MALFORMATIONS.

THE congenital malformations of the female reproductive organs constitute a sharply defined clinical group of anomalies, in which surgical intervention aims to correct defective menstrual and procreative functions.

These anomalies are, almost without exception, instances of arrested development.

The fallopian tubes, uterus and vagina represent the normal end products in the developmental transmutation of the two embryonic Müllerian ducts.

Lying on either side of the Wolffian body, and external to its duct, the Müllerian ducts, consisting at first of solid strands, pass downwards into the allantoic portion of the cloaca. At a later stage each duct acquires a lumen, the lower portion of which, by fusing with its fellow of the opposite side, forms the uterus and vagina, while its upper part, remaining separate, forms the fallopian tube.

Certain deviations from the normal sequence in this developmental chronology, such as irregularities in the fusion of the lower parts of the Müllerian ducts, in their mode of termination, their partial or complete absence, or their imperforate condition, will account for the various congenital atresias, abnormal fistular communications, partial or complete duplications and other defects, that may involve different segments or the entire genital tract.

The development of the vulva and external generative organs is more complicated and less clear than that of the vaginal canal and uterus, with its adnexa.

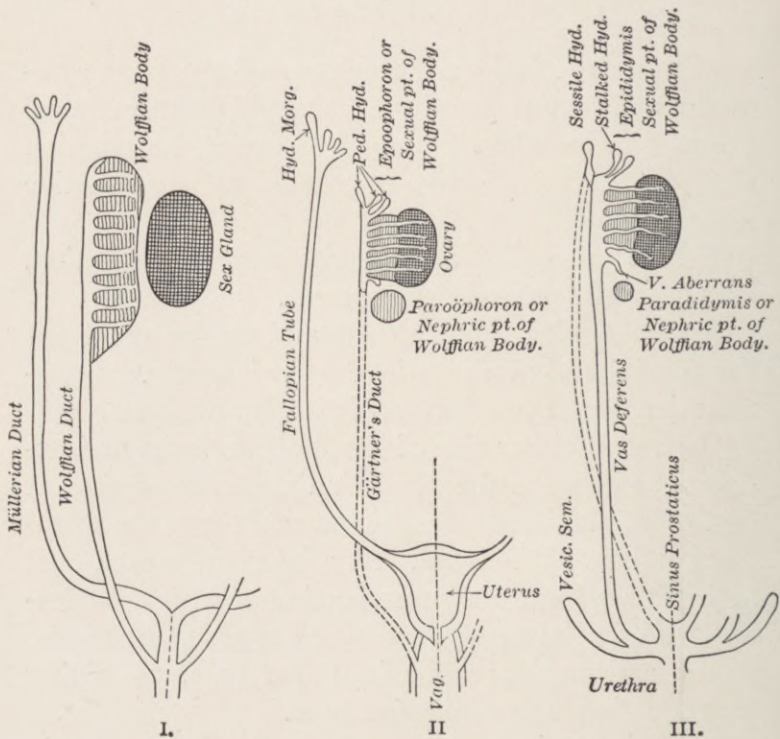


Fig. 129.—Relationship of the sexual ducts and their rudiments in the two sexes. I, The indifferent primary type. II, The differentiation in the female. III, The differentiation in the male (Adami.)

At the posterior or lower end of the embryo an invagination of the ectoderm occurs, by which the cloaca is brought into communication with the exterior, thus forming the cloacal opening or primitive

anus. This is followed by an indifferent stage, during which sex distinction is impossible.

The anterior part of the anal plate becomes thickened, and gives origin to a projection known as the "genital tubercle", which is the "anlage" of the penis in the male, and the clitoris in the female.

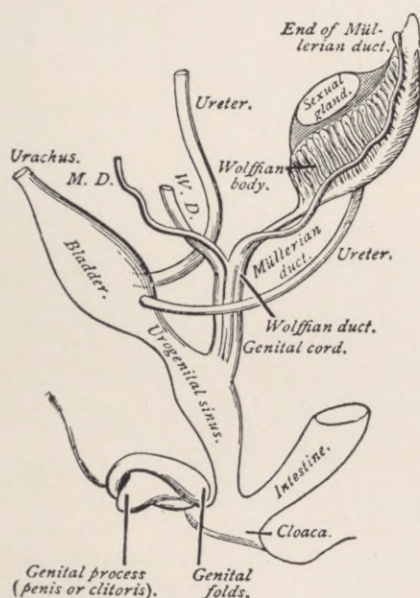


Fig. 130.—The indifferent stage in the development of the generative organs (diagrammatic). (Piersol, after Thompson, "American Textbook of Obstetrics.")

On the under surface of the genital tubercle appears a groove—the "genital groove"—which passes backwards into the cloaca. In the female, the edges of this furrow become the labia minora, and the integument external to these develops into the labia majora. In the next stage, the cloaca is divided by a partition—the rudimentary perineum—into an an-

terior and posterior cavity, the former, termed "the urogenital sinus," gives vent to the urinary and sexual duct terminals, while the latter constitutes the permanent anus.

In the female, the sinus urogenitalis persists, forming the vestibule, the external urinary meatus, the vaginal introitus, and the hymenal fold.

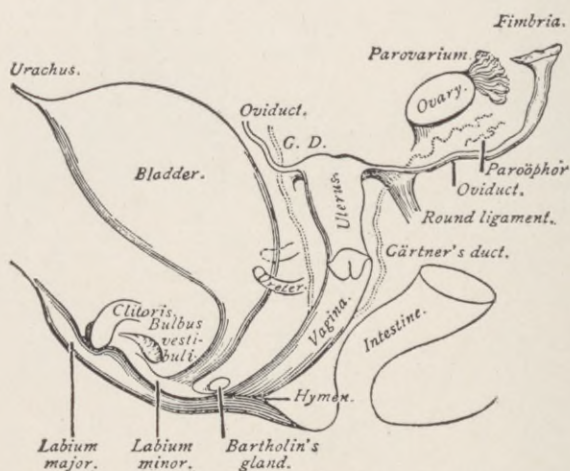


Fig. 131.—Changes that take place in the development of the female generative organs (diagrammatic). (*Piersol*, after Thompson, "American Textbook of Obstetrics.")

Omitting the more involved phases of academic teratology, these brief embryological outlines will serve to reveal the complicated segmental transmutations which must be visualized in the elucidation and attempted correction of any congenital defect. Not all such defects, however, can be satisfactorily explained on the basis of developmental arrest, and in these latter other pathologic factors more or less conjectural, such as amniotic compression, amniotic

adhesions, fetal peritonitis, infantile vulvitis, adhesive colpitis, etc., have been invoked.

While it is generally accepted as a clinical axiom that congenital malformations and defects are usually multiple and diverse, they may for practical purposes be enumerated under the following pathological grouping.

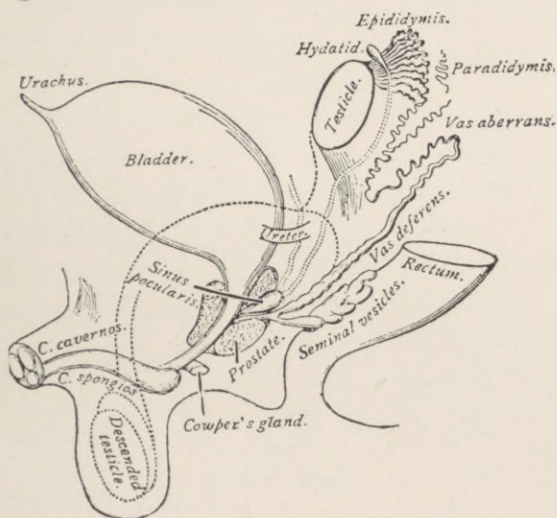


Fig. 132.—Changes that take place in the development of the male generative organs (diagrammatic). (*Piersol*, after *Thompson*, "American Textbook of Obstetrics.")

GROUP A.

APLASIA AND HYPOPLASIA OF THE FETAL RUDIMENTS.

1. Absence of the uterine appendages.
2. Absence of the uterus.
3. Absence of the entire genital tract, with or without—
4. Pseudohermaphroditism.
5. Uterus unicornis.

6. Atresias, which may be cord-like or diaphragmatic, existing in the cervix, vagina, hymen or vulva.

7. Congenital rectovaginal or rectovulvar fistulæ; atresia anivaginalis or hymenalis, cloaca vaginalis, or fistula rectovestibularis.

8. Feminine epispadias or hypospadias.

GROUP B.

HYPERPLASTIC ANOMALIES OF FORMATION.

1. Duplication of entire segments: Uterus didelphys.

2. Uterus et vagina duplex.

3. Duplication of the uterine appendages; ovaries; tubal ostia.

4. Uterus bicornis.

5. Duplication by a septum: Uterus bicornis septus, or bicollis, and subseptus or unicollis, all of which may be combined with vagina septa or subsepta.

GROUP C.

ARRESTED DEVELOPMENT AND ANOMALIES OF INFANCY AND PUBERTY.

1. Uterus foetalis.

2. Uterus infantilis and uterus membranaceus.

3. Anteflexio uteri infantilis.

4. Stenosis cervicis et orificii externi.

5. Stenosis vulvovaginalis or hymenalis.

6. Evolutio præcox.

7. Oligomenorrhœa and amenorrhœa.

8. Dysmenorrhœa.

9. Menorrhagia.

10. Sterility.

Of clinical import in the foregoing enumeration are:—

Absence of the Uterus (“uterus deficiens seu defectus uteri”).—Complete absence of the uterus, its adnexa, and (to some extent also) the external genitals is usually encountered in the acardiac twin and in sympodial fetuses; but its occurrence in the adult and otherwise normal individual is extremely rare. Only *post-mortem* evidences can establish the non-existence of the uterus and its adnexa, and in most of the reported cases such evidence is wanting; hence it is more logical to assume that in the majority of these cases the individual was a male with undescended testicles, not a female without a uterus.

A woman without a uterus, or with merely a rudimentary organ, may present all the secondary characters of her sex. She may have a high-pitched voice, rounded contours, and an absence of facial hair. Amenorrhœa is necessarily constant. Nevertheless, ovulation may occur, and molimina become manifest, which occasionally assume an intensity that demands removal of the ovaries. The shallow vestibular vaginal pouch may be deepened by repeated attempts at coitus, which in most of the cases is unconsciously practiced through the gradually dilated urethral opening.

Uterus unicornis is an organ in which one horn alone is well developed. There are two varieties—that in which the second horn is altogether absent, and that in which it persists as a solid or hollow rudiment. In the first condition there is complete, in the latter partial, defect of one of the Müllerian ducts.

The uterus unicornis has no fundus. The single horn, inclining to one side of the middle line, tapers to a point at which it is continuous with the fallopian tube and the origin of the round ligament. The cervix is usually small, and the vagina narrow, absent, or septate. The single horn may also be solid or partly excavated.

The concomitant defects noted are, absence of the fallopian tube, round and broad ligament on the deficient side, as well as the corresponding ureter and kidney.

Only half of the bladder may be developed, while the ovaries, when present, are rudimentary.

A patient with a uterus unicornis commonly gives a history of amenorrhœa, but it is well to bear in mind that menstruation and fecundation have occurred. Gestation in such a rudimentary uterine horn is practically an ectopic gestation, with all of its attendant dangers and indications.

The uterus didelphys, diductus, or separatus, exhibits the maximum degree of separation between its two laterally placed halves, which normally fuse into the single viscus. There appear to be two single uteri lying side by side, each, however, possessing only one ovary, tube, and round ligament.

There may also be complete or incomplete duplication of the vagina, or this canal may be single.

The two uteri are rarely of equal dimensions, and one of them may be imperforate—a condition giving rise to hæmatometra at puberty.

Not uncommonly this uterine malformation is associated with deformities of neighboring parts, such as ectopia vesicæ and atresia ani.

Since it is impossible to differentiate cases of uterus didelphys from the more frequent uterus bicornis, the two will be considered together.

Uterus bicornis denotes the condition in which the two halves or horns are not entirely separate, as in the didelphous organ, but are united more or less intimately at their lower end, that is, in the region of the cervix or lower part of the corpus uteri.

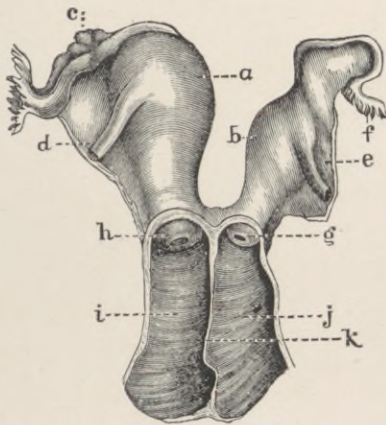


Fig. 133.—Double uterus (uterus didelphys). a, Right cavity; b, left cavity; c, right ovary; d, right round ligament; e, left round ligament; f, left tube; g, left vaginal portion; h, right vaginal portion; i, right vagina; j, left vagina; k, partition between the two vaginæ. (Mann.)

The mid-portions of Müller's ducts had evidently begun to fuse, but coalescence ceased short of the normal limits, and a uterus is produced exhibiting clear external evidences of its two-horned origin.

The bicornate uterus is the connecting link between the uterus didelphys, which presents two un-united halves, and the uterus septus or bilocularis, in which outwardly the organ gives no indication of duplicity.

The uterus bicornis also shows all possible transitions from the form in which the two horns are fused in the cervical area only to that in which the malformation is merely indicated by a shallow depression or notch at the fundus.

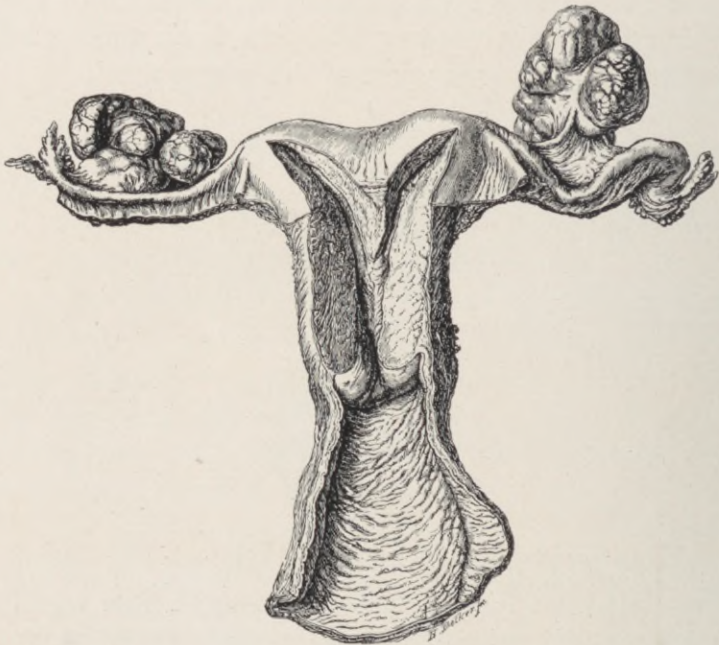

Fig. 134.—Case of bicornate uterus, with carcinoma of both ovaries. Septum seen running down to the single cervical canal. The depression at the fundus is characteristic.

The two horns may be of equal size, or one, being retarded in development, approximates to the type of uterus unicornis.

The extent of bifurcation varies greatly. In the most marked, the two segments present a considerable interval superiorly, bridged by a band or frenum passing from the bladder to the rectum. In less

evident cases the horns lie close together, but are not united. The cervix may be broad and large, showing a double orifice (uterus bicornis duplex; septus or bicameratus); it may be double, with but one orifice, or entirely normal.

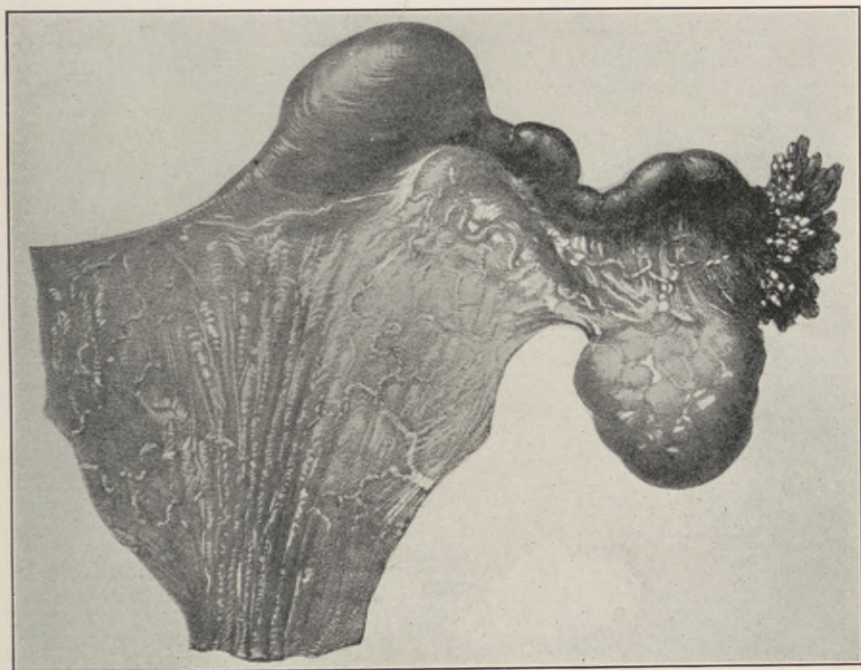


Fig. 135.—Left tube, ovary and uterine nodule. Tube and ovary normal in size. The membrane below, with parallel folds, occupies the position of the uterine body and upper vagina. Natural size. (*Kelly.*)

The vagina may be septate, subseptate, or single, the external genitalia usually presenting a normal appearance.

The menstrual function may be variously affected by the presence of a didelphous or bicornate uterus.

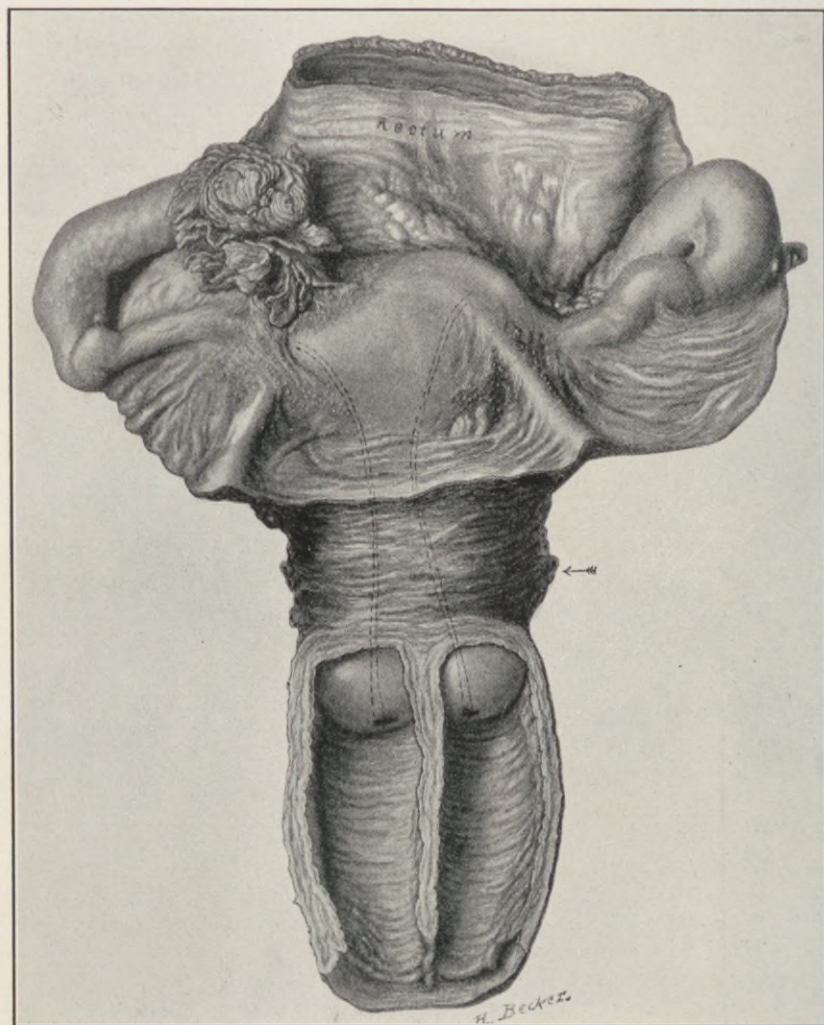


Fig. 136.—Case of double uterus, double vagina and planiform fundus. The uterine cavities are shown in double lines. Natural size. (Kelly.)

Menstruation may occur every two weeks, every month, or once in every two months. In the first instance, the menstrual flow comes from each uterine cavity alternately every two weeks, there being no coincidence of function; each side menstruates independent of the other. In the second case, both sides menstruate simultaneously, or each side functions alternately every other month. In the third instance, there is a bimonthly flow from one half, whilst on the other side there is an imperforate condition of the horn, vagina, or hymen which obstructs the egress of the discharge.

Pregnancy may occur in one horn, and menstruation from the other—a circumstance which possibly accounts for the continuance of menstruation during gestation in many unrecognized cases.

Decidua may form in the empty horn or each horn may harbor an ovum, pregnancy occurring in both horns simultaneously or at different but not far distant dates, thus explaining some instances of anomalous superfetation. The bicornate uterus may abort from one horn, fœtation going to full term in the other. When, as sometimes happens, the pregnant horn is obstructed by a septum, gestation becomes practically extra-uterine. Even in cases in which there is no unilateral atresia, rupture of the uterus, or of the septum between its horns, may occur (see Fig. 137).

Uterus Fœtalis.—The anatomical uterine characters normal to the fœtus may persist as an abnormality in the adult. The cervix is longer than the corpus; its walls are thick, while those of the corpus

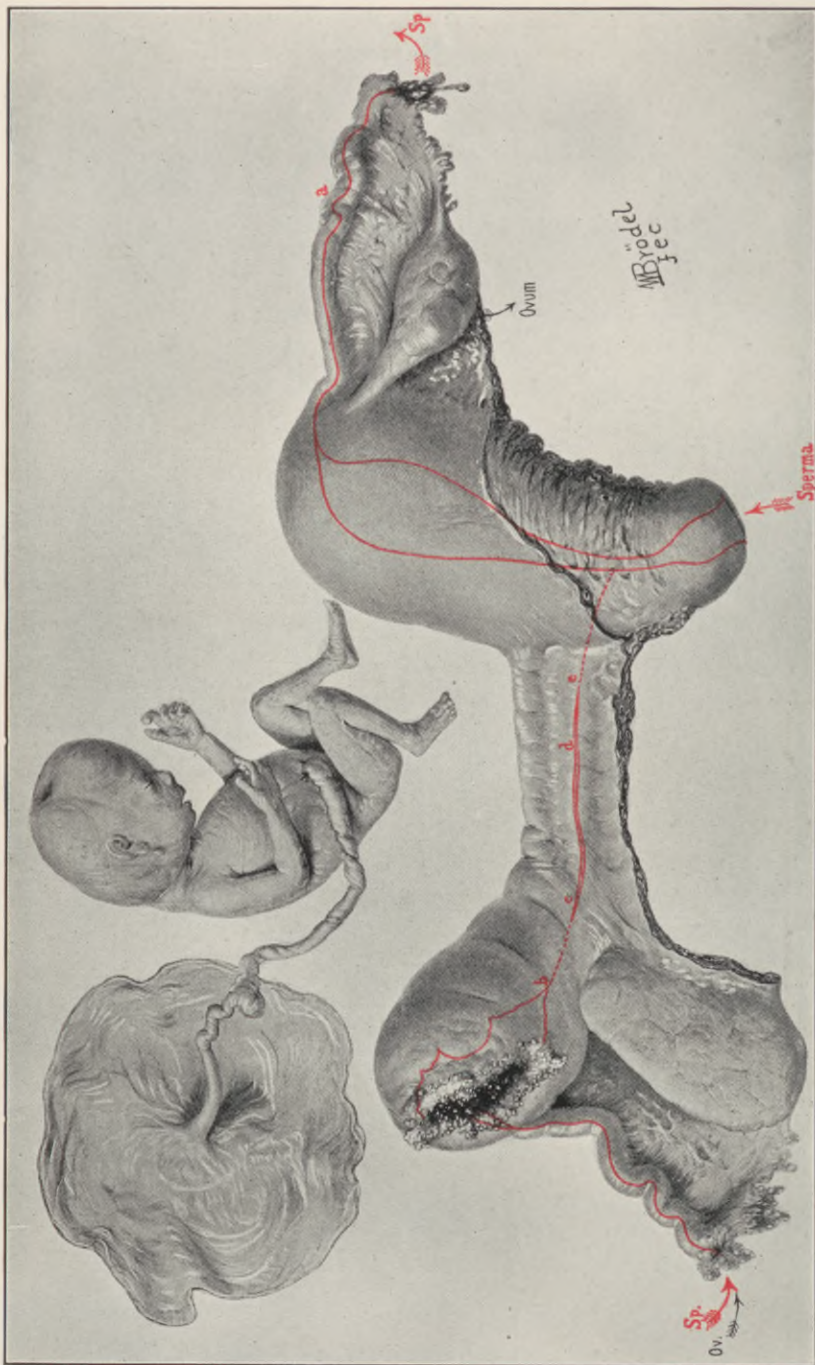


Fig. 137.—Pregnancy in a rudimentary left uterine horn. Rupture. The specimen is viewed from behind. To the right is the well-developed uterus, which, after reaching the internal os, deviates to the right side. Attached to the right tube, which is normal. The ovary is of the usual size, and at its inner and lower portion is the corpus luteum of pregnancy. Springing from the left side of the uterus at the internal os is a muscular band; on tracing this to the left, it merges into the rudimentary uterine horn. On the posterior surface of this horn is a long slit, representing the point of rupture, protruding through the rent are placental remains. The left tube passes off from the outer side of the rudimentary horn. The left ovary is flattened. The red line on the well-developed uterus indicates the size of the uterine cavity. The line b, c, d, e, indicates the course of the left Müller's duct. Between a and d it contains a lumen; where it is represented by dotted lines, it consists of a solid muscular cord. Above the specimen are the placenta and fetus, drawn in normal size. *Nasir, (Kaly.)*

are thin. It is conical in shape, with a so-called "pin-hole os."

The whole organ is cylindrical in form and small in size, the length of its cavity rarely exceeding $1\frac{1}{2}$ inches. The term "infantile uterus" is practically synonymous with foetal uterus. The endometrium is poorly developed, and may present an absence of utricular glands.

The vagina is short, especially its anterior wall, usually narrow, but may be normal. Ovaries, tubes, and external genitalia are infantile in contour, and deficient in function.

With a uterus fetalis there is usually amenorrhea, or at most a scant, irregular, and painful menstruation. Sterility is constant. Chlorosis, a small heart, small aorta, and general hypoplasia of the vascular system are frequent concomitants.

All attempts at treatment of the fetal uterus are futile, while in the pubescent uterus a small proportion attain some approximation to normal functions later in adult life.

Uterine Atresia and Stenosis.—The uterus may be congenitally imperforate—an anomaly which finds its explanation in the originally solid condition of Müller's ducts, from which it is developed. Uterine atresia is not so much an independent malformation as a complication of other defects. The whole cervix may be solid or present a septum at the external or internal os. At puberty hematometra may develop, which may be unilateral in bicornate cases.

The symptoms of uterine atresia are mainly those of hematometra, and as these are also encountered

in vaginal atresia, their further consideration will be deferred to the chapters on the latter anomaly.

Infantile or Congenital Antelexion is in reality an antelexion of the cervix only, which usually is conical in shape with a minute external orifice, and foreshortened anterior vaginal wall.

Dysmenorrhea and sterility are the rule, the more direct cause, however, being a chronic endocervicitis, to which these cervices are especially prone.

CHAPTER XXVI.

MALFORMATION OF THE VAGINA AND VULVA.

VAGINAL malformations present many characters in common with those of the uterus—a circumstance readily understood when we recall that both vagina and uterus are derivatives of the Müllerian ducts.

Moreover, vaginal and uterine defects frequently coexist, and in many instances combine to establish a clinical complex.

While abnormal communications between the uterus and contiguous viscera are rare, the congenital fistulas between the vagina and its neighboring organs are relatively frequent.

Double Vagina (vagina septa).—A double vagina in the literal sense can only be said to exist in certain double terata, such as the pygopagous twins; but it has become customary to apply the term to cases in which the two Müllerian ducts, which normally fuse into one canal, have remained separate, the residual septum persisting along a part or the entire extent of its vaginal course.

In the great majority of cases this septum runs anteroposteriorly, and the vaginæ are situated laterally. More rarely it extends transversely, when the vaginal canals lie in front of one another. In the latter instance, the two unfused ducts must have undergone a partial rotation.

The two canals are never perfectly symmetrical in position or calibre. Ordinarily the left lies a little in front of the right. The septum is composed of muscular tissue covered by mucous membrane, and has the consistency of the rectovaginal septum. It varies, however, in thickness, and may be perforated. It may be absent at the introitus, and present at any point above, and *vice versâ*. Its remnant may be indicated by a ridge or cock's-comb elevation on the vaginal wall. In the majority of cases the uterus is double, *i.e.*, didelphous, bicornate, or septate, presenting one cervical orifice in each vaginal compartment.

In a few recorded cases the uterus was single, its cervix projecting into one or other of the vaginal lumina. In atresia of one or both vaginal tracts, unilateral or bilateral hematocolpos will develop in adult life.

It is claimed that during pregnancy the septum may be absorbed, but should it persist to term, delivery may be impeded. When one canal is imperforate, the condition may simulate a vaginal cyst.

Atresia Vaginæ implies any defect of the vaginal canal, from its complete or partial absence to a simple membranous obstruction or perforated diaphragm existing at some part of its lumen.

When the upper two-thirds of the vagina are occluded, the patulous lower third is not vaginal in nature, but represents an enlarged vestibular canal, the vestige of the sinus urogenitalis. Through the arrest in the downward progress of the Müllerian ducts, the vestibular canal has retained its early dimensions, its depth being increased by coital attempts. When the central vaginal zone is atretic,

it may be assumed that the upper canal is Müllerian or truly vaginal, while the lower part is vestibular.

The uterus, adnexa, and vulva may be normal, rudimentary or absent. If the uterus and ovaries are present, the condition reveals itself at puberty by hematocolpos, hematometra, and hematosalpinx.

The surgical indications will be entirely dominated by the extent and position of the defect, by the presence or absence of the internal generative organs, or by the accumulation of retained menstrual blood.

Patients with extensive defects of the vagina and uterus, in whom severe menstrual molimina indicate the presence of functioning ovaries, may demand oöphorectomy for relief.

Hematocolpos and hematometra invariably call for operative intervention. It is not correct to leave such blood accumulations to nature. Spontaneous rupture, even when it occurs through the vaginal tract, is seldom safe in its immediate, or satisfactory in its ultimate, results.

Dyspareunia, as such, in the absence of uterus and ovaries, and without other subjective manifestations, is a questionable indication for the operative construction of an artificial vagina—a difficult and dangerous procedure, the results rarely justifying the means especially in very extensive cases.

Abnormal Communications of the Vagina.—The vagina may open into the rectum through a developmental defect of the rectovaginal septum, or it may communicate by a small orifice with the urethra.

Most of the abnormal clefts between the vaginal canal and its contiguous viscera are in reality vulvar

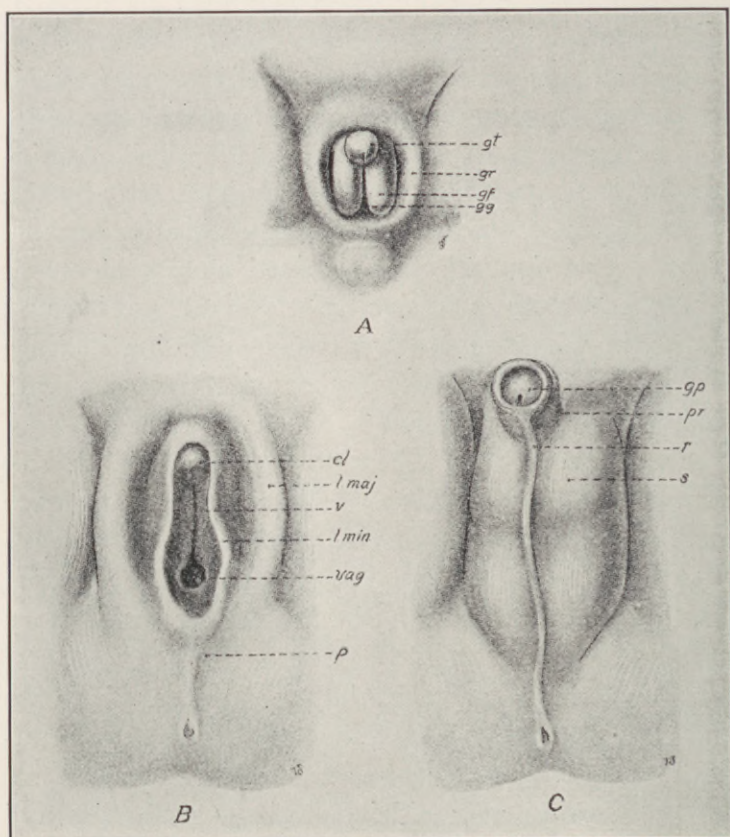


Fig. 138.—Development of the external genitals (after Ecker-Ziegler models). *A*, Indifferent stage (eighth week): *gt*, genital tubercle; *gr*, genital ridge; *gf*, genital fold; *gg*, genital groove. *B*, Female type: *cl*, clitoris; *l. maj*, labia majora; *v*, vestibule; *l. min*, labia minora; *vag*, vagina; *p*, perineum. *C*, Male type: *gp*, glans penis; *pr*, prepuce; *r*, raphé; *s*, scrotum.

anomalies, due to the persistence of the sinus urogenitalis or of embryonic cloaca.

Malformations of the Vulva.—Atresis vulvæ superficialis is applied to the condition in which adhesions of the labia majora or minora obliterate the normal vulvar cleft.

Ordinarily the occlusion is not complete, a small orifice existing near the root of the clitoris through which urine and menstrual fluids escape. The anomaly may be present at birth or may develop in infancy. In both cases it is due to adhesive vulvitis.

In early life there may be discomfort in micturition. After puberty the menstrual flow may be impeded, but hematocolpos does not develop. Coital penetration may be impossible, but not impregnation.

Abnormal Communications of the Vulva.—There is a phase in the developmental period, when the allantois (bladder), Müllerian ducts (vagina), and rectum all open into a common cavity, which drains to the surface of the body, and is called the cloaca. Normally, this condition is transitory. When it persists and becomes permanent, the anomaly known as atresia anivaginalis or vulvar anus results.

Atresia Ani Vaginalis (anus vulvalis).—The term "persistent cloaca" is better adapted to this condition than the cumbersome, inaccurate atresia anivaginalis, in which the normal anus is apparently absent, the rectum emptying through the vagina or vulva, the feces escaping through an opening either in the neighborhood of the vestibule or in that of the posterior commissure.

Hypospadias (persistent urogenital sinus).—In one sense it is incorrect to speak of hypospadias in the woman as an anomaly. There is, however, a malformation of her external genitalia to which this designation has been applied, presenting a persistence of the urogenital sinus. The urethra appears to open into the vagina, but what is regarded as vagina is in reality sinus urogenitalis.

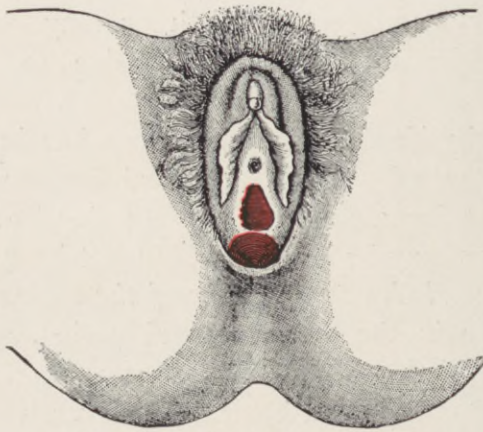


Fig. 139.—Anus vulvalis. (After Dwight.)

Through a common opening at the base of the clitoris, which latter is frequently hypertrophied, both the urine and menstrual blood escape. The perineum and anus are normal. Thus the condition differs from the persistent cloaca of atresia ani-vaginalis.

Pozzi describes two varieties, differing in degree. In the one of minor degree, the vestibular canal is long and narrow, with its urethral opening high up in the vagina. This type is frequently accompanied

by hypertrophy of the clitoris, thus creating some doubt at times as to the sex of the individual.

In the second degree, which may be called hypospadias proper, the urogenital canal has disappeared;

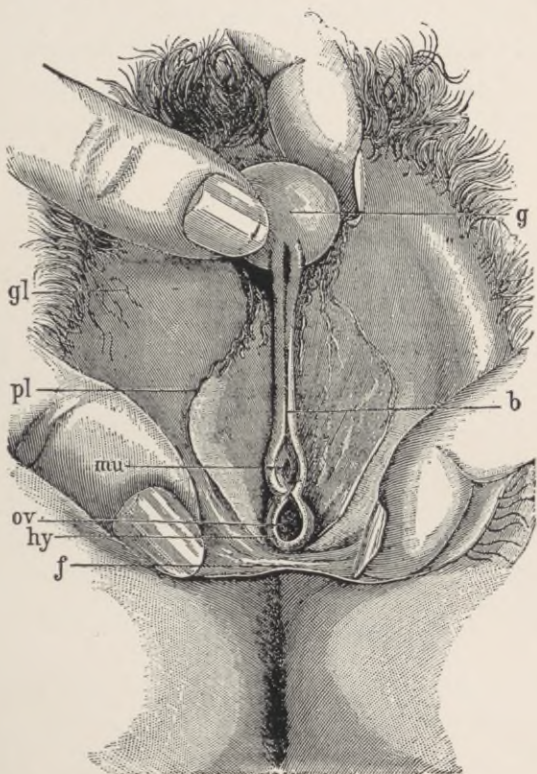


Fig. 140.—Pseudohermaphroditism, perineoscrotal hypospadias, (After *Pozzi*.) g, glans; b, frenum; mu, meatus urinarius; ov, vulvar orifice; hy, hymen; f, fourchette; pl, labia minora; gl, labia majora.

but the lower part of the allantois, which should have developed into the urethral canal, has been included in the formation of the bladder. There is thus an absence of the urethra, while the vagina and bladder

open together into the vestibular canal, with incontinence of urine as a result.

Epispadias is observed as a simple defect in the upper urethral wall, or a part of a similar defect of the bladder, abdominal wall, and pubic bones, *i.e.*, ectopia vesicæ. In the former condition the urethra is seen as an open groove or gutter passing upward in the position of the vestibule, and disappearing under the symphysis pubis, to terminate in the bladder or into an upper normal part of the urethra. On either side of the groove lies one-half of the bifid clitoris, continuous with its apertinent labium minus. (See chapter on Exstrophy of the Bladder.)

The labia majora may unite normally or diverge. Intermediate types between these two are observed.

The most important clinical manifestation of uncomplicated epispadias is incontinence of urine. The incontinence is not usually absolute, but any sudden exertion, change of position, coughing or sneezing, is accompanied by a gush of urine from the bladder, which is usually *abnormally* small in size.

Malformations of the Hymen.—Most of the hymenal malformations are clinically unimportant. There is as yet no general acceptance of any one theory as to the mode of its development, some asserting that it is vaginal, others that it is vulvar in origin. On either hypothesis, it is simply a developmental remnant, not a "fixed organ," and, like all other remnants of a similar nature, presents innumerable anomalies of structure, form, and position.

Cases of double hymen which have been reported are probably errors of interpretation, the upper sup-

plementary membrane usually consisting of a perforated diaphragmatic septum in the vaginal canal, a little above the normal hymen.

Two or three of such septa may exist, some doubtless due to adhesions between the walls of the fetal vagina.

Atresia Hymenalis (imperforate hymen) is not as common as the number of reported cases would

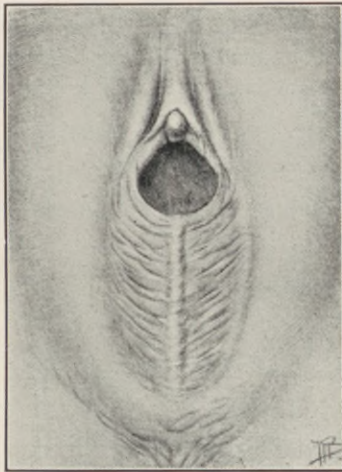


Fig. 141.—Agglutination of the labia in a little girl. There is a distinct raphe in the middle, with a translucent, slightly furrowed membrane on both sides, which conceals the urethra and the hymen.

indicate. In the majority of the cases the supposed hymenal diaphragm is in reality the blind end of the Müllerian vagina.

It is often possible to locate the normally perforate hymen, displaced and covered by the bulging of the vaginal saccular protrusion. Strictly speaking, cases of hymenal atresia are often instances of simple vaginal atresia. In other cases, adhesions of

the labia minora give rise to an appearance resembling atresia of the hymen, and it is only after division of the labial attachment that the true normal hymen is found beneath. The clinical results in all of these cases is the same, namely, retention of mucus in infancy, and menstrual blood in the adult.

Pseudohermaphroditism.—The exact meaning of the word "hermaphrodite," as applied to the human subject, has undergone a change. Whilst the older writers applied the term to individuals whom they regarded as possessing the organs of both sexes, in an anatomical and physiological sense, modern authors use the name rather to indicate subjects whose true sex is doubtful. Malformations of the genital organs, giving rise to doubt as to the true sex of the individual, have attracted the attention of observers from the earliest periods of the world's history, and records of such cases have been found on the brick tablets of the ancient Chaldean libraries. In Rome, individuals of doubtful sex were destroyed. In the East, on the other hand, there is reason to believe that they were deified. According to the Talmud, Abraham was a hermaphrodite, and so, according to many authors, was Adam.

In one sense, the human embryo at a certain period of its existence may be regarded as hermaphrodite. There is a stage in development when it is impossible to state whether the sexual gland will become an ovary or testicle; whether the Müllerian or the Wolffian ducts will atrophy; whether the genital tubercle will become a penis or a clitoris. The embryo is then, so far as is known, potentially of

either sex, and awaits the action of some force to determine which sex is to predominate.

It is easy to understand how morbid influences, brought to bear upon the embryo at or about the time when it is passing from its sexually indifferent stage into one of differentiation, may so upset the normal process of development as to produce an individual with, for example, testicles and a uterus. It is, however, a matter of great difficulty to imagine a condition of affairs which would give rise to the presence of a testicle and an ovary on the same side; for, so far as is known, the sexual gland may become either a testicle or an ovary, but not both. In the Müllerian and Wolffian ducts, on the other hand, we have to do with two sets of structures, one of which normally atrophies, and the other develops; but abnormally both may persist in a more or less fully formed condition. As a matter of fact, it is very doubtful whether a genuine case of the coexistence of testicles and ovaries in the human subject has ever been reported; whilst instances of pseudohermaphroditism, as they have been called, are far from rare. Still, it is never safe to say that the occurrence of any particular teratological combination is impossible; and if we bear in mind that true hermaphroditism has been met with in fish, amphibians, and even in the goat and pig, it may be that some observer will yet record an undoubted case in the human subject.

Cases of pseudohermaphroditism are not uncommon. In many of them the dubiety as regards sex is due to the existence of one or other of the anomalies of the female external genital organs, already

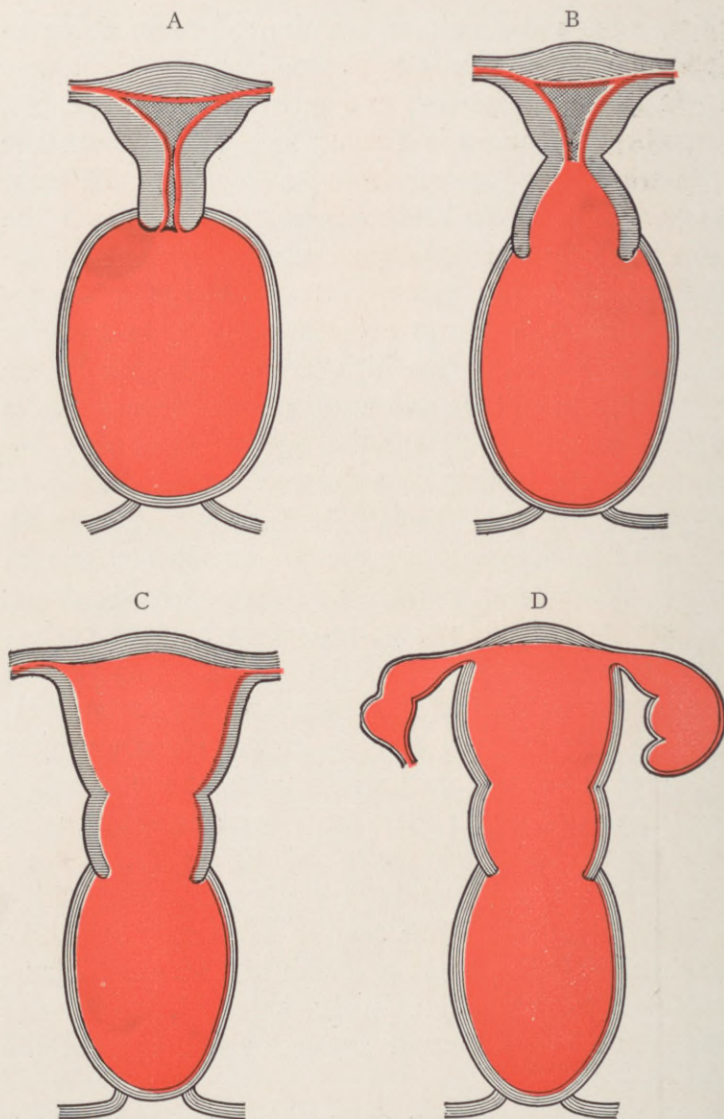


Fig. 142.—Atresia at the vulva first causes distention of the vagina, producing hematocolpos. B, Hematotrachelos has followed hematocolpos. C, Hematometra has followed hematotrachelos. D, In addition to C there is added hematosalpinx. (*Sulton and Giles.*)

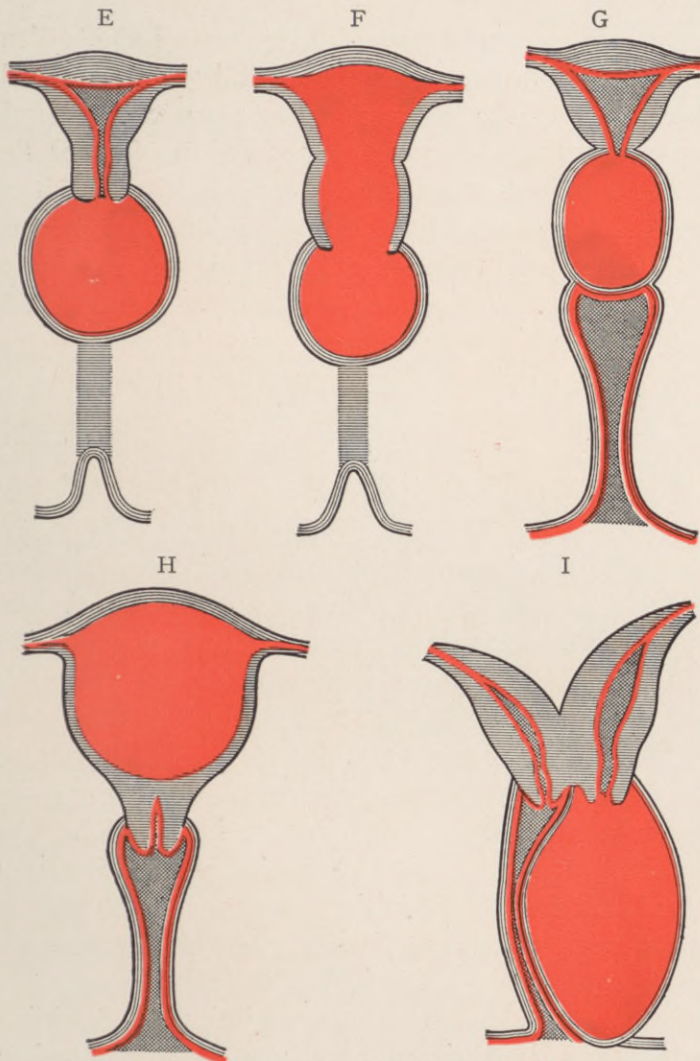


Fig. 143.—E, Atresia in the vagina, midway between the vulva and the os externum, causing hematocolpos on the upper half of the vagina. F, Same as E, except that distention of the whole uterus has followed the partial hematocolpos. G, Atresia of the os externum, producing a hematotrachelos. Corpus uteri not yet distended. H, Atresia of the os internum, producing hematometra. Fallopian tubes may become distended later. I, Atresia of the vulva on one side of a double uterus and vagina, causing a hematocolpos on the affected side. (*Sulton and Giles.*)

described. In many more, however, we have to deal with malformations of the penis and scrotum, which have given to the external parts a somewhat feminine appearance. In the former group of cases the ovaries are present, whatever may be the condition of the other organs, and the individual is therefore really a female in the state known as *pseudohermaphroditismus femininus*, or *gynandry*. In the latter group, the subject, by the possession of the testicles, is a male, however closely he may approach the other sex in appearance—a state known as *pseudohermaphroditismus masculinus*, or *androgyny*. Individuals of the second kind are more numerous than those of the first. Each of these two varieties has been subdivided into three groups—*internus*, *externus*, and *completus*. Thus, in a case of *pseudohermaphroditismus masculinus internus* there are testicles in association with external genitals of the male type, and a uterus, vagina, and even tubes. In *pseudohermaphroditismus masculinus externus* there are also testicles, but the external genitals and the build of the body are feminine. Again, in *pseudohermaphroditismus masculinus completus seu externus et internus* there are testicles, but there is also a uterus with tubes, and the external organs approach more or less closely to the female form. In the same way, in the three varieties of feminine pseudohermaphroditism there are always ovaries; but in the internal type there are also distinct traces of the Wolffian ducts; in the external type the external genitals are of the male form; and in the complete type the external organs are masculine, and the Wolffian ducts and prostate gland are present. The

enumeration of these varieties will have given some idea of the morbid anatomy of pseudohermaphroditism. At the same time it must be borne in mind that some of them are very rare. One of them, on the other hand—pseudohermaphroditismus masculinus externus—is, comparatively speaking, very common.

One of the most usual arrangements of parts to which the name of feminine pseudohermaphroditism

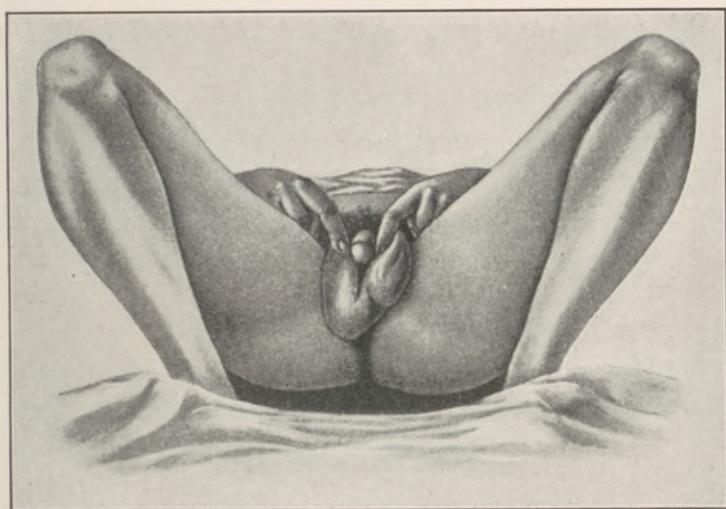


Fig. 144.—Feminine pseudohermaphroditism.

is given is that in which a woman presents an adhesion of the labia along with hypertrophy of the clitoris. When, also, there is a labial ovarian hernia on one or both sides, and a development of hair on the face, the resemblance to the male—at any rate, to the hypospadiac male—becomes very striking. The vulva, however, may be normal, and the subject show simply an enlarged clitoris, a beard, and a masculine arrangement of the pubic hair.

Non-descent of the testicles in the male gives origin to one variety of androgyny. Such men are often the subjects of gynæcomastia (enlargement of the breasts); and since also the penis, although perforate, is sometimes small, and the sexual functions poorly developed (infantilism), it is easy to understand how doubts as to their virility may arise. A more common type of androgyny, however, is that caused by the existence of scrotal hypospadias. In this case the resemblance to the female type of external genitals is very strong, for there is a small imperforate penis often fixed in position under the symphysis by adhesions; the urethra opens externally near the penile root and below it is a sort of vulvar aperture or vestibular canal which may even be of some depth, and may be guarded by a hymen. The external genitals in such a case resemble, as Pozzi graphically expresses it, those of an embryo seen under a magnifying glass. When it is also borne in mind that the testicles are either undescended or at any rate atrophic, and that the individual has probably been mistaken for and brought up as a girl, and has thus acquired feminine habits, it is easy to see how extremely difficult it may be to ascertain the real sex. The difficulty may be still further increased by enlargement of the mammæ, by the absence of hair on the face and chest, and by the occasional discovery of a uterus, although, of course, ovaries are not to be detected. Doubtless most of the cases of supposed true hermaphroditism have been really hypospadiac men.

Clinical Features.—Whilst in the histories of pseudohermaphrodites there are many details which

are peculiar to each case, there are also some which are practically common to all. The error in the recognition of the true sex of the individual is usually made at birth, and confirmed at baptism; and, as a rule, it is not till the period of puberty is reached that doubts arise as to the accuracy of the declaration at birth. In the case of male pseudohermaphrodites, the error may even be perpetuated, and the individual be married as a woman, and live with a husband, an imperfect form of coitus taking place per urethram. Usually, however, suspicions begin to be entertained at puberty when, in the case of hypospadiac males brought up as females, the absence of the menstrual function and the appearance of certain secondary sexual characters proper to the male sex give rise to doubts. At the same time, it must be borne in mind that even in these subjects hemorrhage simulating the menses may take place from the urethra, dilated by coitus, and in a few instances a real catamenial discharge from a uterus has been noted.

Further, the secondary sexual characters cannot be relied upon; for mammary enlargement, rounded outlines, a broad pelvis, a small larynx, and a feminine distribution of the body-hair, may all be met with in male pseudohermaphrodites, while the secondary sexual characters of the male may coexist with ovaries. The habits, also, and the feelings and desires of the subject, will depend largely on the surroundings in early life, and cannot be regarded as diagnostic of the sex.

“The treatment of such cases presents many puzzling problems. Lawson Tait’s rule, that every

infant about whose sex there is doubt should be brought up as a male, is a good one; for male pseudo-hermaphrodites are more common than female; individuals reared as males are not so apt to enter into marriage in ignorance of their sexual inability; and there is less danger in bringing up a girl among boys than a boy among girls. The question as to the advisability of surgical interference is a difficult one. In a case reported by Christopher Martin, the testicles were removed from an individual brought up as a girl, and castration was followed by a development of the breasts and pubic hair; while Péan records the extraordinary operative history of an individual whose abdomen was first opened to discover the sex, then an artificial vagina was made, and finally the abdomen was again opened and the tubes and ovaries removed. The separation of the adherent labia in a gynandrous individual is a minor operation, which may be undertaken without hesitation; but it is doubtful whether we are justified in removing the sexual glands in any case of pseudo-hermaphroditism" (J. W. Ballantyne).

CHAPTER XXVII.

OPERATIVE CORRECTION OF CONGENITAL MALFORMATIONS.

THE clinical range of congenital anomalies, as elucidated in the preceding chapters, affords a very limited scope for legitimate operative intervention, as most of the conditions enumerated are obviously beyond corrective possibilities. Surgical plastic cannot construct organs nor create functions; it can only aim to readjust certain defections of visceral alignment and continuity that bar or impede the normal manifestation of their latent virility.

The phases of genital maldevelopment amenable to operative measures are: imperforate hymen, stenosis of the vaginal introitus, atresia or absence of the vagina, and ectopia vesicæ.

Imperforate Hymen.—Imperforate hymen and vaginal atresia are rarely noticed before puberty. In some instances a protrusion of the septum during violent efforts has directed attention to the condition, while in others a collection of mucus behind the septum has produced a fluctuating protrusion between the labia. Granwell reports the case of an infant, 1 month old, with a tumor filling the pelvis and lower abdomen to the umbilicus. The vulva and perineum were reddened and œdematous. Urinary retention was at first suspected, but disproved on catheterization. Incision of the occluding membrane gave vent

to a small amount of pus, followed by about 400 mils of yellow fluid.

Slight epithelial adhesions between the mucous folds immediately behind the hymen are not uncommon in children, and may be mistaken for imperforate hymen. Spontaneous rupture may occur. In the adult, atresia at any point of the vulvovaginal

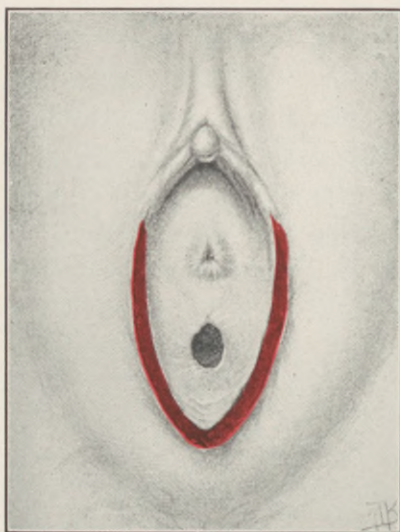


Fig. 145.—Same as Fig. 141, after division of the membrane.
Urethra and hymen exposed.

tract, is followed by an accumulation of menstrual fluid above the obstructed area. If the atresia involves only the hymen, the anterior or mid-portion of the vagina, its upper part becomes distended, forming a hematocolpos.

With increasing distention, the cervix is gradually obliterated, and hematometra and hematosalpinx develop.

If the atresia is not corrected in time, serious consequences may ensue, the two principal dangers being rupture and infection. Spontaneous rupture is the usual sequel of the distention, and may occur either externally or internally.

In external rupture the vaginal wall gives way, but cases of perforation through the base of the labium majus and the gluteal region are on record.

External rupture is sometimes followed by complete recovery; but in many cases the distended cavity became infected, with lethal result from general sepsis.

Internal rupture is more frequent, and perforates the vaginal or uterine wall. The resulting hematoma may be discharged through the rectum or into the bladder. Recovery may follow either, but the spontaneous vent is usually inadequate, producing a recurrence of the condition, or a persistent fistular communication. The gravest of all possibilities is an intra-abdominal rupture of a hematosalpinx, with consequent peritonitis.

The treatment for imperforate hymen is, crucial incision of the obstructive portion, with excision of its central area. The cut edges should be sutured with catgut to check bleeding, and the cavity above gently irrigated with warm normal saline solution. Small adherent particles of inspissated blood invariably remain, and favor the rapid multiplication of any infecting organisms that may find entrance. The great danger of sepsis, particularly when the blood-distended cavity involves the uterus, demands the most rigid aseptic precautions throughout the operative and convalescent stage.

In some cases the vaginal introitus is inadequate, not as the result of any hymenal obstruction, but due to a congenital narrowing or hypercontractility of the levator ani, with consequent vaginismus and dyspareunia.

If such narrowing cannot be relieved by repeated dilatation, it may be permanently overcome by dividing the upper third or half of the perineum in an

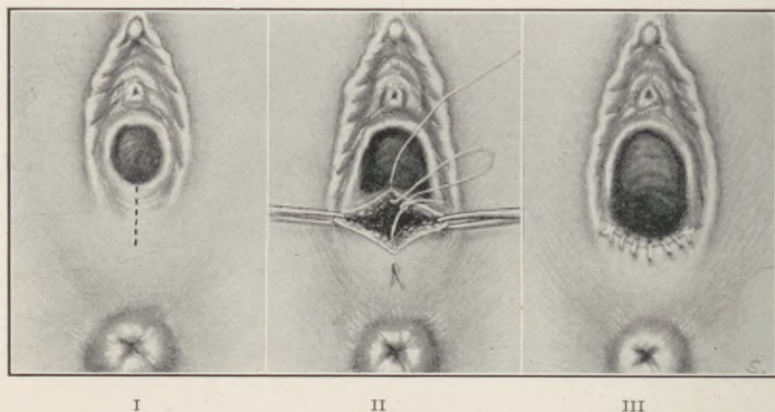


Fig. 146.—Widening the vaginal opening for dyspareunia. I, The perineum is to be excised as indicated by the dotted line, one-half or two-thirds of the distance to the rectum. II, The wound has been spread open, and is being closed so that its length will lie transversely. III, The operation completed. After healing, the vaginal opening will be permanently enlarged, as indicated. There is a marked tendency of the approximated edges to pull apart. If catgut alone is used, it should be well chromicised (40 days). Even that failed to maintain complete approximation in some of the author's cases. It is advisable to put in two or three tension sutures of silkworm gut, or close entirely with same. (*Crossen.*)

anteroposterior direction, converting this longitudinal incision into a transverse slit by proper traction, and suturing it in this position, for which purpose silkworm gut or 40-day chromic gut is used.

Simple membranous atresia of the vagina is treated like an imperforate hymen, namely, by incision and excision of the obstructing tissue under aseptic precautions. In these conditions it is essential to differentiate simple atresia from the condition in which the upper vaginal canal is entirely absent; the distinguishing feature between the two is the presence of fluid accumulation above the obstruction.

In atresia of the vaginal vault and cervix, surgery is of very questionable utility. The technical difficulties and dangers, owing to the usual necessity of attack both from above and below, are not warranted by the precarious functional results in the few successful cases thus far reported.

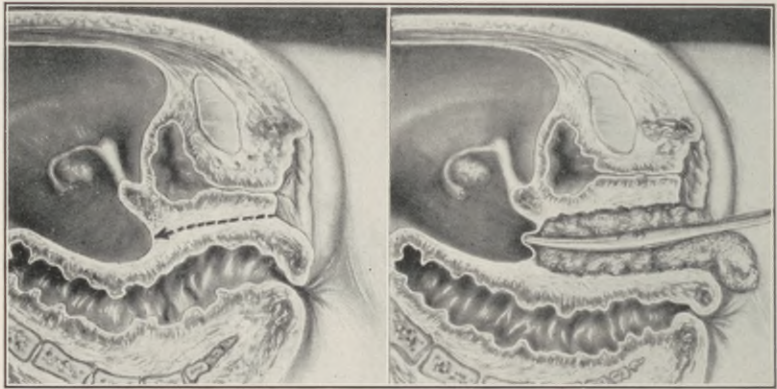
Absence of the Vagina.—Congenital absence of the vagina and complete atresia are at times difficult to differentiate, but the question is not of surgical importance, as both conditions are usually accompanied by other developmental defects of a grade to exclude all corrective intervention. Moreover, if a well-developed uterus should be present, the operative course would be practically similar in either case. The structural difference between the two conditions is the presence of a fibromuscular band between the rectum and bladder in atresia, while in total absence of the vagina the rectum is in direct contact with the bladder.

Atresia affecting a segment of the vaginal lumen, usually the lower part, is comparatively common, and may be congenital or acquired.

According to some investigators, notably Nagel, most cases of atresia, even in the new-born, are not strictly developmental anomalies, but the effect of

prenatal adhesions. In other cases the atresia results from infantile vulvitis due to gonorrhoea or any of the exanthemata. There may be only a superficial epithelial agglutination of the apposed surfaces, or the occlusion may present a membrane of varying thickness and resistance.

It is only within recent years that successful methods for the construction of a permanent artificial vagina have been evolved. All former attempts,



I

II

Fig. 147.—Formation of an artificial vagina from an intestinal loop. I, Deformity (absence of vagina) here shown. The tissues are to be separated along line indicated by arrow, up to, but not through, the peritoneum. II, The canal for the vagina has been completed, and packed with gauze. The forceps pushing against the peritoneum is to be used in a subsequent step of the operation. (*Crossen.*)

which consisted mainly of skin transplantations into the tunneled rectovesical septum, were futile.

In 1907 Baldwin devised and practised the interposition of an intestinal loop as a permanent substitute for the vaginal canal, in the following manner:—

1. The patient, prepared for both perineal and abdominal operation (intestinal resection), is placed in the lithotomy position. A transverse incision is made in the vulvar area between the meatus urina-rius and anus, through the integument and fascia to the areolar tissue, in which discreet blunt dissection, carried upward, separates the bladder and rectum as far as the peritoneal reflection.

When the dissection has reached the peritoneum, the cavity is widened in all directions to an ample degree, without penetrating the abdominal cavity, and is packed with sterile gauze.

2. The patient is now placed in the horizontal position, and the abdomen opened. A loop of ileum, about 12 inches long, is selected to serve as a substitute for the vaginal canal. Its mesentery must be sufficiently long to permit of downward displacement and implantation without tension.

The loop is emptied of its contents by pressure, and severed at both ends, as for intestinal resection, with preservation of its mesentery.

The continuity of the ileum is restored by a Murphy button or suture, while the ends of the isolated loop are securely inverted by the purse-string method.

The peritoneal reflection between the bladder and rectum is now opened, the gauze packing removed from below, where a sponge-holder is introduced, passed upward, and made to grasp the centre of the resected intestinal segment, which is drawn into the artificial canal to the vulvar introitus.

The parietal peritoneal edges covering the ends of the loop are sutured, and the abdomen is closed.

3. For the next stage of the operation, the patient is returned to the lithotomy position, the apex of the bowel loop is opened, and its edges are sutured to the surrounding cutaneous margin.

Each arm of the loop is then cleansed of all mucus, and lightly packed with gauze to secure union of the loop surfaces to the walls of the vaginal cavity.

4. After three weeks, or when the patient has fully recovered from the operation, the septum or

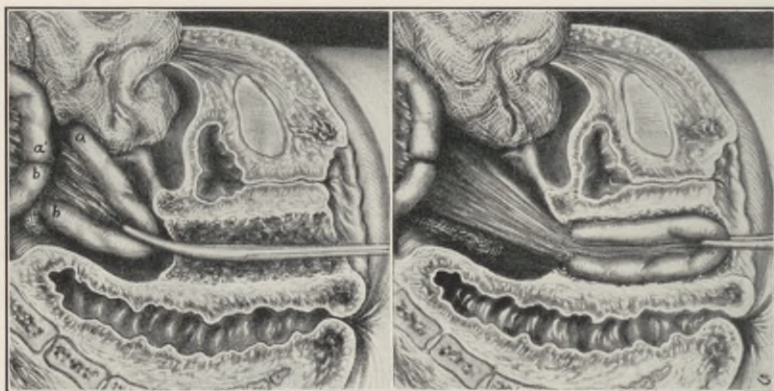


Fig. 148.—I, The intestinal resection has been completed, and the intestinal loop has been grasped with the forceps preparatory to drawing it into the prepared canal. II, The intestinal loop drawn into place. The *cul-de-sac* peritoneum should be closed over the ends of the loop, but not in a way to interfere with the circulation in the mesentery. (Crossen.)

spur between the two arms of the loop is divided, converting their lumina into a single wide channel.

This may be accomplished by inducing pressure necrosis. A long clamp is introduced, one blade into the upper and one into the lower arm of the loop. The clamp is firmly locked, and left *in situ* until its

bite sloughs through, which usually occurs in about five days.

Another method consists in the application of two clamps, a short distance apart, between which the septum is incised, the clamps remaining on the tissues just long enough to insure against hemorrhage, *i.e.*, about twenty-four hours.

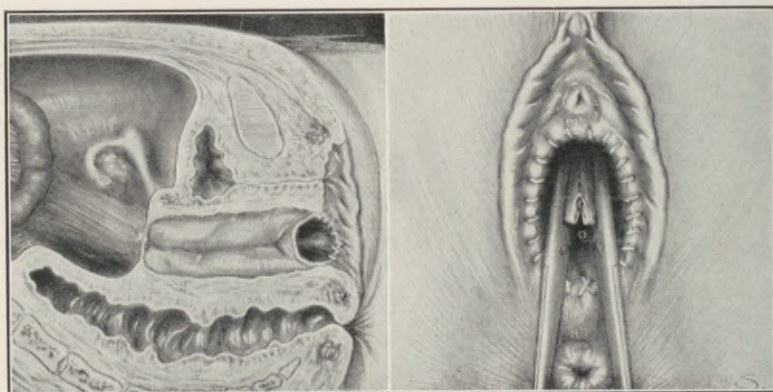
Baldwin, in reporting his fourth case (Journ. A. M. A., vol. 54, 1910), states:—

“While studying the technique of this operation from a theoretical point of view, I took pains to examine the ileum and sigmoid in a large number of patients on whom I was doing ordinary abdominal operations. Several hundred patients were thus examined, and in all I found that there would be no difficulty in drawing down such a loop of ileum into the vagina, or a loop of sigmoid, if for any reason the ileum should not be found satisfactory.

“With either, there would be plenty of mesentery slack, so that the circulation would not be interfered with. I have always used, however, a loop of ileum, because resection of the ileum is safer than resection of the sigmoid. In all of my cases operative recovery was absolutely smooth, and the new vagina seems to take the place very satisfactorily of the natural organ. I was induced to use the bowel for this purpose, because a very extensive study of the literature had shown that all other methods resulted in almost complete failure, although full of promise in many cases when the patient left the operating table. By the use of the bowel a normal mucous membrane is provided, surrounded by normal connective and muscular tissue, and with an ample blood supply.

"The dangers of operation are simply those inherent in any other deliberate resection and anastomosis of intestine, but the operation is one which should certainly not be undertaken by a tyro in surgery. . . . Nevertheless, the danger should be fully explained to the patient, who would then decide whether the risk is worth the while."

Wallace (Buffalo Med. Journ., Feb., 1911) reports a case in which he opened the abdomen, in-



I

II

Fig. 149.—I, The intestinal loop in place and opened; the margins of the opening sutured to the surrounding surface. II, Dividing the septum between the two portions of the intestinal loop. This is carried out some days after the operation. (*Crossen.*)

tending to do the Baldwin operation. Finding, however, that the mesentery of the ileum was too short, he utilized a loop of the sigmoid, resecting 5 inches. One end was turned in and closed, the other was drawn down and stitched to the vulva.

The ultimate result was excellent.

G. Schubert (Surg. Gynec. and Obst., 1914)

devised a method which utilizes a segment of the rectum in the formation of an artificial vagina. It has given excellent results, and there is no invasion of the peritoneal cavity, with its attendant dangers. The steps of this procedure are as follows:—

1. With the patient lying on the left side, the hymen is completely excised, but no deeper dissection is made. The sphinctre ani is then moderately dilated, and a circular incision is carried around the anus at the mucocutaneous junction.

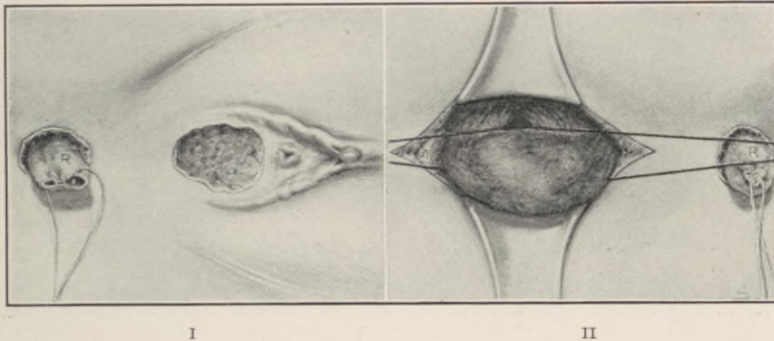
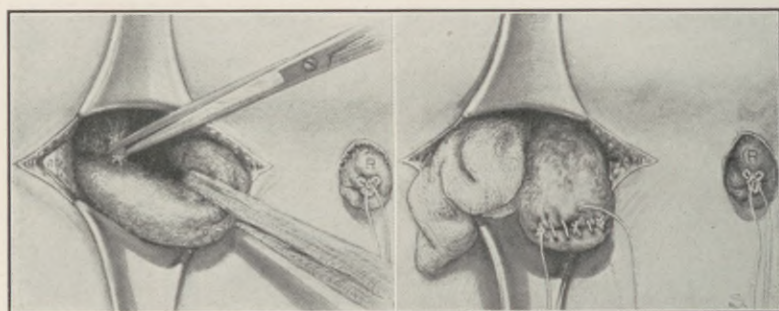


Fig. 150.—Artificial vagina from a section of the rectum. I, The hymenal area has been excised, and the end of the rectum mobilized by dissection around the anus. II, An incision has been made over the coccyx, the bone removed, and a loop of the rectum brought out. A double ligature has been introduced and divided, making two ligatures. By pulling these in opposite directions, an opening is made in the vascular tissue, beneath the rectum. Through the opening a strip of gauze is to be passed for traction on the rectal loop. (*Crossen.*)

The rectal mucosa is then carefully dissected all around from the sphinctre and upward for about an inch. The bleeding is checked, and the rectum closed by a temporary suture. It is well to have this suture long for traction purposes in the subsequent steps.

2. The coccyx is excised through a longitudinal incision, 4 inches long, extending to within 2 inches of the anus. The cut is carried down to the bone, the fascia pushed aside, and the coccyx seized with a bone forceps and disarticulated. The underlying pelvic fascia is divided longitudinally, exposing the rectal wall.

3. The rectum is drawn into the wound, and a long double ligature is passed around it 4 inches above the anus. The ligature is divided, giving two



I

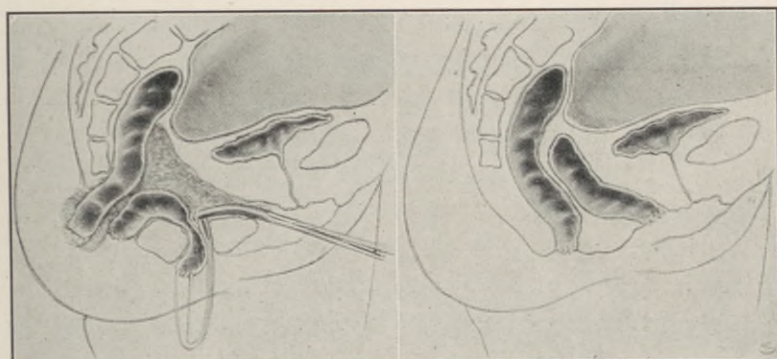
II

Fig. 151.—I, The gauze strip has been placed, and traction is being made. As the loop of rectum is drawn down, all resisting bands of tissue are ligated and divided, as here indicated. II, The loop of rectum has been divided at the point where the double ligature was first passed, 4 inches (12 cm.) above the anus. At the point of division of the rectum the proximal end is closed temporarily, and covered with gauze, while the distal end is closed permanently with sutures, as here shown. (*Crossen.*)

ligatures. By separating and manipulating the ligatures, the rectum is isolated and space obtained for the introduction of a gauze loop, by means of which the rectum may be pulled upon without injury to its walls.

Traction upon the exposed rectum brings its upper part within reach, which is mobilized by severing blood-vessels and any restraining bands after double ligation. This upward liberation is continued until the rectal tube is sufficiently freed to permit the level of its proposed division to reach the anus. The peritoneum should not be opened, but pushed up in advance of the blunt dissection.

The rectum is cut across between two clamps, the



I

II

Fig. 152.—Sectional view, depicting the later steps in the operation. I, The forceps drawing forward the anal end of the rectum has been introduced from the hymenal area along the canal, and is grasping the temporary suture closing the anal end of the rectum. II, Operation completed. (*Crossen.*)

upper cut-end is temporarily closed by suture, and enveloped in sterile gauze; the lower end is permanently sealed by inversion.

4. Blunt dissection tunnels a channel from the hymen upward and backward until it encounters the rectal wall at the upper limit of the dissected area. This artificial canal is widened to the capacity of two

fingers, a forceps is introduced, and the ends of the lowest temporary suture (first introduced and left long for traction) are seized and drawn to the denuded hymenal border, to the circumference of which the rectal stump is sutured after removal of the temporary suture.

The upper cut-end of the rectum is now brought down and united to the anal rim. The first sutures are buried and deeply placed, uniting the sides of the rectal tube to the adjacent sphinctre, the end of the rectum is then secured to the cutaneous margin.

5. Inclosing the coccygeal wound, a drain should be inserted. The new vagina is divulsed by a speculum, cleansed and packed.

G. Schubert, at the time of his report (*Surg. Gynec. and Obst.*, vol. 19, 1914), had operated on four patients. The method was also employed by Floel, Franque, Krömer, Strassman, and Engelman. Nine cases have been under observation to the present time, with extremely favorable results.

CHAPTER XXVIII.

PUDENDAL HERNIA.

SYNONYMS: Levator hernia, subpubic hernia, perineal hernia, ischio-rectal hernia, rectal hernia.

The existing literature on this comparatively rare condition is extremely meagre. In a very recent and most comprehensive publication, Dr. Herbert C. Chase, of New York City, contributes the thirteenth case recorded since the first detailed treatise on the subject by Sir Astley Cooper, in 1807.

The apparent rarity of the condition, the paucity of its literature and the existing confusion in classification, warrant its consideration within the category of gynoplastic procedures.

In reviewing the etiology of pudendal hernia, Chase states "Primarily, of course, all of the factors bearing on the etiology of hernia in general must be considered.

"Pregnancy and parturition are the factors of most import, and we find that the majority began during labor or were noted soon after.

"The incidence of age would thus naturally fall within the child-bearing period.

"The youngest is Cooper's case, 22 years old. The oldest is Winckel's case, 51 years old."

While pregnancy and labor would seem to present potent contributory elements, there must obviously exist a primary, predisposing structural deficiency as the direct causative factor in the development of pudendal hernia.

According to Ebner's investigations (Macready) the principal cause of pudendal hernia is some congenital abnormality in the parietal peritoneum of the

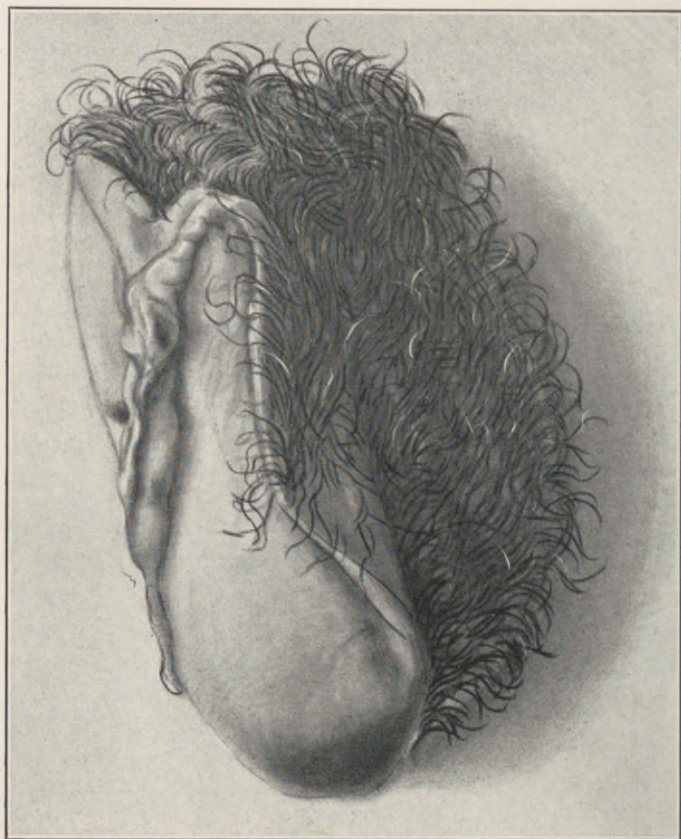


Fig. 153.—Pudendal hernia presenting through anterior and left vaginal wall and labium, simulating cystocele. (*Author's Case.*)

pelvic floor, which extends lower than the normal, especially in the region of Douglas' pouch.

This contention is invalid, the pouch of Douglas may be found abnormally elongated in pudendal

hernia, but the elongation, like the hernia, is the result of a levator muscle deficiency.

The levator ani is not a single muscle, but a radially disposed plexus of flat muscle segments, en-

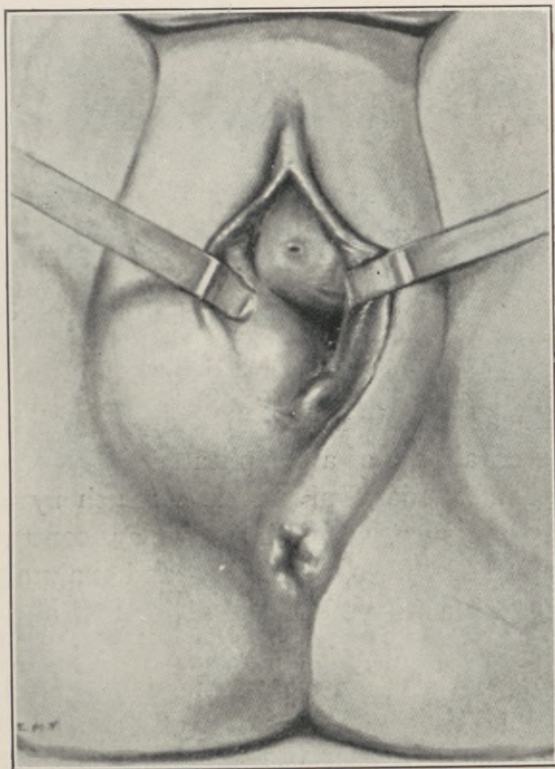


Fig. 154.—Showing the “levator hernia” before operation. Note position of sac (through subpubic triangle) and that its internal surface is covered with mucous membrane and external surface with integument. (*Chase.*)

closed and separated by fascial investments; each segment being, unfortunately, designated by a special term indicating its point of origin and inser-

tion (*i.e.*, pubo-rectalis, ischio-coccygeus, pubo-coccygeus, coccygeus, etc.), thus creating some confusion. While these individual segments may be separately demonstrated at their origin, they become intimately blended with each other and with the aponeurotic tissues in the perineal centre and anococcygeal raphé.

Ebner studied sixty bodies and found that in twenty-five there existed gaps between the coccygeal and ischio-coccygeal segments of the levator ani.

In a consideration of the levator abnormalities productive of pudendal hernia, it is essential to re-emphasize the statement made in the chapter on the mechanism of intrapelvic visceral support, namely—the muscular and ligamentous elements that constitute the perineal floor, should not be conceived as a *passive* weight-bearing diaphragm with a hypothetical sphincter action at the pelvic outlet, but as an *active* integral part of a complicated *deflecting mechanism* of intraabdominal pressure, which by deflecting that pressure, through muscular contractility, within normal planes, dominates and maintains the topographic stability of all the abdominal and pelvic viscera.

The essential deflector of intraabdominal pressure into normal planes at the pelvic outlet is the levator ani muscle; and the primary etiological factor in pudendal hernia is presented by a congenital or acquired deficiency in a segmental area of that muscle.

The herniation occurs either between the muscle fibres or through the interspaces existing between the individual segments constituting the levator ani, thus reaching the ischio-rectal fossa.

Having reached the loose areolar tissue of the fossa, the hernia may remain undiscovered, or advancing along planes of least resistance, presents itself as a so-called "ischio-rectal hernia;" working backward it constitutes the "rectal hernia;" pushing forward it may appear under the skin as a typical "pudendal or perineal hernia."

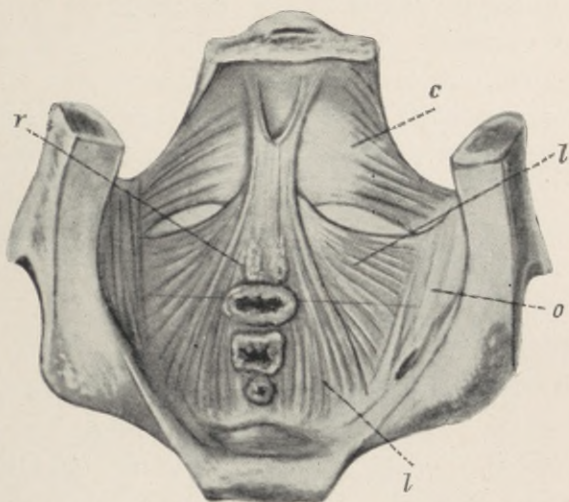


Fig. 155.—Showing the weak points in the pelvic diaphragm seen from above—the beginning of levator herniæ internally. *r*, Rectococcygeus; *c*, coccygeus; *l*, levator ani, and *o*, oblique fascia. (*Chase.*)

Any of these varieties in the course of their progress may appear as "vaginal hernias" which occasionally bulge the vaginal wall through the vulva (see Fig. 153).

The form appearing under the anterior vaginal wall differs in its course of exit from the above, by escaping directly into the vagina through the vesico-uterine connective tissues, without traversing the ischio-rectal fossa.

On the other hand, Hunner claims, that this latter form of the hernia may, after separating the vesico-uterine tissues, bore laterally through the levator ani, reaching the ischio-rectal fossa, appearing in the labium as a pudendal hernia.

Chase suggests the following practical classification based upon the initial site of the hernial exit:—

- a. Anterior to the broad ligament.
- b. Posterior to the broad ligament.
- c. Combined (anterior and posterior).

Chase nevertheless recognizes that, "a sac originating behind the broad ligament may push forward under the ligament and break through the levator anteriorly, thus combining the features and contents of both the anterior and posterior types, a condition which he would term 'combined type.'" He further states, "The point of entrance of the posterior variety or its beginning is at the weak point in the pelvic diaphragm internally.

"From a consideration of the anatomy and formation of the various layers of the pelvic diaphragm it will be seen, that this weak point is at the three posterior divisions of the levator muscle. The lateral portion of the levator (*M. iliococcygeus*) does not overlap the central portion (*M. pupococcygeus*) laterally, but passes onward to fuse directly with the pubococcygeal and rectococcygeal raphé. This leaves a space on each side behind the broad ligament devoid of muscular covering, where the pelvic or rectovesical fascia is separated only by areolar tissue from the ischio-rectal fossa.

"No such condition exists anterior to the broad ligament, where the lateral portions of the levator

(*M. iliococcygeus*) entirely overlap and fuse with the pubococcygeal segments.

“This undoubtedly explains the predominance of the posterior variety (eight out of eleven cases reported)” (Chase).

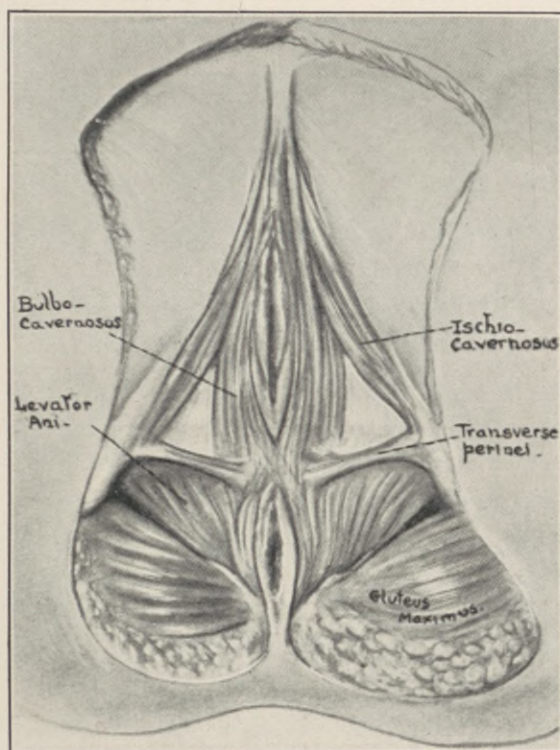


Fig. 156.—Showing the “subpubic” triangle and its boundaries through which all true levator herniæ must emerge.

In the diagnosis of pudendal hernia some fatal errors recorded in the literature should and can be averted by keeping the possibility of the condition in mind.

In one case, “a loop of intestine several inches

in length was cut off; in another, reported by Ganz, the hernia was incised on the supposition that it was a cyst, and the cecum, which afterward protruded, became gangrenous and caused the death of the patient." (Reported by Hunner.)

When the hernia appears in the vagina it is covered with the vaginal mucosa and may thus be mistaken for a uterine polyp, especially as the hernia may find its exit near the cervix.

Michaelson and Lukin report a case from the Kronstadt Hospital, in which a supposed uterine polyp was amputated.

The patient died the following day and the autopsy revealed that about five inches of the transverse colon and a foot of omentum had been excised.

Vaginal, pudendal and Bartholinian cysts should never be incised until the possible existence of a hernia is absolutely excluded.

In the treatment of pudendal hernia as in all herniæ, surgery offers the only means of radical cure. While some form of mechanical support in the shape of a pessary may occasionally retain the hernia, the majority of the patients will remain unrelieved without surgical intervention.

The radical cure of inguinal hernia became possible only with the realization of its two essentials, namely:

I. Apposition or overlapping of contractile muscle at the hernial site of origin.

II. Obliteration of the peritoneal funnel or sac.

In other words, the muscular and serous planes of the hernial canal, must be so reconstructed as to reestablish the normal deflection of intraabdominal

pressure, thus causing the herniated viscera to glide *over* instead of *into* the hernial gap.

For convenience of description the operation may be divided into the following stages:

I. Reduction of the hernial contents.

II. Free exposure of the levator ani on the affected side.

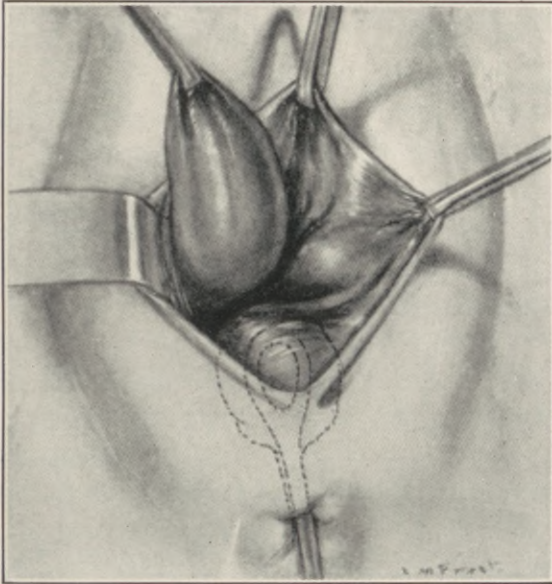


Fig. 157.—Vaginal route. The sac has been separated from edges of split levator, and the inner bundle of split muscle pushed outward to join main body of right levator muscle and sac freed to neck. Sponge in rectum. (*Chase.*)

III. Localization of the hernial defect in the levator muscle.

IV. Complete mobilization, high ligation and amputation of the hernial sac.

V. Levator myorrhaphy.

VI. Closure of the vaginal wound.

The reduction of the hernial contents may demand opening of the sac earlier in the operative procedure for the separation of adherent contents and for purposes of exploration and orientation.

It may occasionally become necessary to secure additional accessibility by a suprapubic incision, as in Dr. Chase's case.

Chase emphasizes, that "The sac is obviously longer and more definitely defined in the posterior variety (*i.e.*, in the herniæ originating posterior to the broad ligament). This is of practical importance, because the surgical principles of high ligation of the sac and closure of the ring are applicable always to this variety. Careful palpation will determine whether a given case of pudendal hernia is of the anterior, posterior or combined variety. With the hernia reduced, the point of entrance internally may be felt and its position relative to the broad ligament and uterus decided."

The levator ani muscle may be freely and easily exposed and its hernial defect located by the method described in a previous chapter on Levator Myorrhaphy; the essential features of which may be summarized as follows:

Before denuding the seat of lesion it is always advantageous, as an anatomical guide, to palpate the levator shanks on either side of the vaginal introitus, where they are distinctly palpable through the lateral vaginal wall, just behind the hymenal border, converging downward toward the perineal centre.

From the perineal centre the muscle may be traced upward and outward to its parasymphyseal origin on the posterior plane of the pubes.

To correctly expose the seat of lesion in the levator ani it is necessary to recall, that the upper and under fascial sheaths enclosing the muscle, namely, the recto-vesical and levator fascia, blend in the median triangular space existing between the inner muscle borders of the two shanks, which is known as the levator cleft; the contiguous fascial surfaces being held in apposition by a sparse reticular layer which on being split offers a natural line of cleavage leading directly to the muscle. (See chapters and illustrations on Perineal Laceration and Repair.)

The levator freely exposed, its hernial defect may be easily demonstrated by slight traction on the hernial sac, which latter may now be completely mobilized, carefully opened, its contents examined and reduced after which the neck of the sac is transfixed and replaced within the peritoneal cavity.

This is followed by a sutural overlapping of the levator ring and the vaginal wound closed in the usual manner.

With clearer conceptions of the anatomical and mechanical elements involved, the application of modern standardized essentials to the surgery of pudendal hernia, should yield results that will parallel those realized in inguinal hernia.

LITERATURE QUOTED.

Abel, Karl: Die Mikroskopische Technik u. Diagnostik in der Gynäkolog. Praxis. Berlin, 1900.

Adair, F. L.: Surg., Gynec. and Obstet., 1910, vol. x, No. 4.

Babcock, W. Wayne: Submucous Perineorrhaphy. Jour. Amer. Med. Assoc., vol. iii, No. 20, 1909.

Baldy, J. Montgomery: The Surgical Treatment of Retroversion of the Uterus. Surg., Gynec., and Obstet., 1915, vol. xx.

Barbour and Watson: Gynecological Diagnosis and Pathology. Edinburgh, 1913.

Beckman: Zeitschr. f. Geburtshilfe and Gynäk., vol. xlv.

Bennett, J. H.: A Practical Treatise on Inflammation of the Uterus, Its Cervix and Appendages. Philadelphia, 1853.

Boldt, J. H.: Discussion and Adjustment of an Intra-uterine Stem versus Dilatation. Jour. Amer. Med. Assoc., 1916, vol. lxvi.

Bum, quoted by E. Martin: Der Haftapparat der Weiblichen Genitalien. Berlin, 1911, 1912.

Byrne, Jno.: Electrocautery in Uterine Surgery, N. Y.

Cathelin: Brilliare et Fils. Paris, 1903.

Chaput: Cong. Franc. de Chirurg, 1892, 6th session, p. 618.

Chase, Herbert C.: Surg., Gynec. and Obstet., 1922, vol. xxxv, No. 6.

Child, Chas. G., Jr.: N. Y. State Jour. of Med., Feb., 1916.

Chrobak and Rosthorn: Die Erkrank. d. Weibl. Geschlechtsorg. Vienna, 1896.

Cooper, Astley: The Anatomy and Surgical Treatment of Crural and Umbilical Hernia, 1807, London.

Crossen, H. S.: Operative Gynecology. St. Louis, 1915.

Curtis, Arthur H.: A Combined Bacteriological and Histological Study of the Endometrium in Health and Disease. Surg., Gynec., and Obstet., 1918, vol. xxvi, No. 2.

Cullen: Cancer of the Uterus, p. 282.

Dickinson, R. L.: Studies of the Levator Ani Muscle, Am. Journ. Obstet., 1889, vol. xxii, No. 9.

Dickinson and Truslow: Averages in Attitude and Trunk Development and Their Relation to Pain. Jour. Amer. Med. Assoc., 1912, vol. lix.

Duehrssen, F.: Zentralbl. f. Gynaek., 1889, p. 530. Arch. f. Gynaek., 1890, xxxvii, p. 27. Charité Annalen., 1889, xvi, p. 513. Arch. f. Gynaek., 1893, v, xlv, p. 413. Neue Folge Chirurg., 1894, xxvi to 1, p. 541.

Duval and Proust: Levator Myorrhaphy, Presse Medical, 1902, p. 1121.

Dittel, von L.: Wiener Allgem. Med. Zeitung, 1891, also Wien. Klin. Wochenschr., 1893, No. xxv.

- Ebner: *Deutsche Zeitschr. f. Chirurgie*, 1887, vol. xxvi, p. 101.
- Emerson, Haven: *Intra-abdominal Pressures*. *Arch. of Int. Medicine*, 1911, vol. vii, p. 754.
- Emmet, T. A.: *Am. Journ. Obstet.*, N. Y., 1874.
- Emmet, T. A.: *A Study of the Etiology of Perineal Laceration, with a New Method for its Proper Repair*. *Trans. A. Gyn. Soc.*, 1883, p. 198.
- Ewing, J.: *Precancerous Diseases and Precancerous Lesions*. *Med. Rec.*, N. Y., lxxxvi, No. 23.
- Frank, Robert: *Uterine Prolapse, Rectocele and Cystocele*. *Surg., Gynec., and Obstet.*, 1917, xxiv, No. 1.
- Frank, Robert: *Principles Governing the Spontaneous Repair and Operative Closure of Vesicovaginal Fistulæ*. *Surg., Gynec., and Obstet.*, 1917, vol. xxv, No. 5.
- Findley, Palmer: *Diagnosis of Diseases of Women*. Phila., 1905.
- Freudweiler: *Arch. f. Klinische Medicin*, 64.
- Freudweiler: *Arch. f. Dermat. u. Syphilis*, xli.
- Gellhorn: *Amer. Journ. Obstet.*, N. Y. 1905, lii, No. 1.
- Goffe, J. Riddle: *An Improved and Perfected Operation for the Relief of Extreme Cases of Procidentia, Cystocele and Rectocele*. *Am. Journ. Obstet.*, 1910, vol. lxii, No. 4.
- Goffe, J. Riddle: *The Treatment of Prolapsus of the Uterus, with Attendant Cystocele and Rectocele*. *N. Y. Med. Jour.*, May, 1912.
- Goffe, J. Riddle: *Intra-abdominal Pressure*. *Trans. Am. Med. Assoc.*, Section Obstet. and Gynecology, 1912.
- Goldthwaite, J. E.: *The Relation of Posture to Human Efficiency, and the Influence of Poise on the Support and Function of the Viscera*. *Boston Med. and Surg. Jour.*, 1909.
- Gynæciorum, hoc est, de Mulierum tum Aliis, tum Gravidarum, etc., Basileæ, per T. Guarinum, 1566, 257, chap. xx. Gynæciorum sive de Mulierum affectibus commentarii Græcorum, etc., Basileæ, 1586, vol. i, chap. xx, p. 104.*
- Hadra, B. E.: *Remarks on Vaginal Prolapse, Rectocele and Cystocele*. *Am. Jour. Obstet.*, 1889, vol. xxii, No. 5.
- Hadra, B. E.: *Lesions of the Vagina and Pelvic Floor*, 1888.
- Hadra, B. E.: *Am. Jour. Obstet.*, 1884, vol. xvii.
- Hall: *Textbook of Physiology*, 1900, London.
- Hartley: *Operative Treatment of Exstrophy of the Bladder*. *Annals of Surgery*, July, 1901.
- Haynes, Irving S.: *The Anatomical Basis for Successful Repair of the Female Pelvic Outlet*. *Am. Jour. Obstet.*, 1908, vol. lviii, No. 6.
- Hegar: *Arch. f. Gynaek.*, 1872, iv, 531.
- Hegar: *Deutsch. Med. Wochenschr.*, 1886, xii, 582.
- Heidenhain: *Arch. f. Gynaek.*, 1908, vol. lxxxviii, p. 432.
- Hertoghe, E.: *Thyroid Deficiency*. *Med. Record*, N. Y., 1914, vol. lxxxvi, No. 12.

- Hertzler, Arthur: *Surgical Operations with Local Anæsthesia*. Surg. Publish. Co., N. Y., 1916, 2nd edition.
- Hess, A. F.: *Provocative Vaccination in Vaginitis of Children*. Am. Jour. Dis. of Children, 1916, p. 476.
- Henricius: *Finska Läk.-Sällsk.-Handl.* Helsingfors, 1889, xxxi, p. 349.
- Henricius: *Zentralbl. f. Gynaek.*, 1889, xiii, p. 676.
- Hilgenreimer: *Deutsche Chirurgie*, 1905, 46 C.
- Hitschman and Adler: *Die Lehre von der Endometritis*, *Zeitschr. f. Geburtshilfe u. Gynaek*, 1907, vol. xl, p. 603.
- Hitschman and Adler: *Monatschr. f. Geburtshilfe u. Gynaek*, 1908, xxvii, No. 1.
- Hühner, Max: *The Practical Scientific Diagnosis and Treatment of Sterility in the Male and Female*. *Med. Record*, May 9, 1914.
- Hunner, Guy L.: *Gynec. and Abdom. Surgery*, Kelly and Noble, Saunders, 1908.
- Jewett, Charles: *Surgery of the Female Pelvic Floor*. Brooklyn Med. Jour., January, 1906.
- Jobert de Lamballe, A. J.: *Traité des Fistules—Vesico-utérines; Vesico-utero—Vaginales, etc.*, Paris, 1852.
- Jones: *British Med. Jour.*, 1891, 1, 173.
- Katzenstein: *Centralbl. f. Chirurg.*, 1901, Beilage, p. 57.
- Keen, W. W.: *Surg. Complic. and Sequels of Typhoid Fever*, 1898.
- Kelly, Howard: *Operative Gynecology*, N. Y., 1906.
- Kelly and Noble: *Gynecology and Abdominal Surgery*, Philadelphia, 1908.
- Kundradt and Engelman: *Med. Jahrb.*, 1873, p. 135.
- Laewen: *Deutsch. Zeitschr. f. Chirurg.*, 1911, cvii, No. 1.
- Landois: *Lehrbuch. d. Physiologie*, Berlin, 1899, p. 218.
- Leonard, V. H.: *Surg., Gynec., and Obstet.*, 1913, p. 390.
- Leonard, V. H.: *Surg., Gynec., and Obstet.*, 1914, xviii, p. 35.
- Leopold, G.: *Die Lymphgefäße, des normalen nicht schwangeren Uterus*. *Arch. f. Gynaek.*, 1874, vi.
- Lendon: *British Medical Jour.*, April, 1906.
- Lewis and Bartels: *Surg., Gynec. and Obstet.*, 1916, vol. xxii, No. 3.
- Lieb, C.: *The Physiology and Pharmacology of the Excised Human Uterus*. *Am. Jour. Obstet. and Dis. Women*, 1915, vol. lxxi, No. 2.
- Lieblein and Holgenreimer: *Deutsch. Chirurg.*, 1905, 46 C.
- Liepman, Wilhelm: *Der Gynäkologische Operations Kursus* Berlin, 1912.
- Lipinsky: *Deux cas de fistules vesicovaginales guéries par l'opération d'épisioclélisis avec fistule rectovaginale artificielle*. *Ann. de Gynec. et d'Obst.*, Paris, 1897.
- Lorentz, von: *Beitrag zur Pathologischen Anatomie der Chronischen Metritis*, 1903, *Arch. f. Gynaek.*, lxx, No. 2.
- Luciani: *Delle oscillazione della pressione intratoracico e intra-abdominale*, 1877. *Turin. Arch. p. Scienz Med.*, 1878, ii, 177.

- Mackenrodt, A.: *Centralbl. f. Gynaek.*, 1894, No. 8, p. 180.
- Marcy, Henry O.: *Plastic Surgery of the Pelvic Structures. Jour. Am. Med. Assoc.*, Sept. 10, 1910.
- Martin, A.: *Frauenkrankheiten*, Vienna, 1885.
- Martin, Ed.: *Zur Anatomie und Technik der Levator, Fasciennaht*, 1912. *Arch. f. Gynaek.*, vol. xcvii, No. 2.
- Maydl, K.: *Ueber die Radikaltherapie der Blasenektomie. Wiener Med. Wochenschr.*, 1894, 25; 1896, 28.
- Mayo, Charles: *Exstrophy of the Bladder. Jour. Am. Med. Assoc.*, 1917, vol. lxi, No. 25.
- Menge, K.: *Handbuch d. Geschlechtskunde*, Vienna, 1912, 2, 323.
- Michaelson and Lukin: *Centralbl. f. Chirurgie*, 1879, vol. vi, p. 303.
- Milner: *Centralbl. f. Chirurg.*, 1905, p. 802.
- Montgomery, E. E.: *Vaginouterine Prolapse and Its Effective Treatment. Jour. Am. Med. Assoc.*, 1913, vol. lxi, No. 14.
- Moynihan, G. A.: *Extroversion of the Bladder. Annals of Surgery*, February, 1906.
- Moynihan, G. A.: *Lancet*, March 2, 1900.
- Neugebauer: *Deutsch. Chirurg.*, 1905, 46 C.
- Newland: *British Med. Journal*, April, 1906.
- Noble, Kelly, and Noble: *Gynec. and Abdom. Surgery.*, Phila., 1908.
- Noble, G. H.: *Intra-abdominal Dynamics and Mechanical Principles Involved in the Cause of Backward and Downward Displacements of the Uterus. Surg., Gynec., and Obstet.*, vol. xx, No. 1, 1915.
- Ossing, J.: *Inaug. Thesis*, Kiel, 1913.
- Paré, Ambroise: *Opera Ambrosii Paré regis primarii et Parisiensis Chirurgi, etc., Parisiis, J. Dupays, 1582, Liber. xviii, chap. xxvii, p. 698.*
- Ibid*: *The works of that famous chirurgion, Ambrose Parey, translated out of the Latin and compared with the French by Th. Johnson, etc., London, R. Cotes, 1649, Lib. xxiv, chap. xxvii, p. 615.*
- Paré, Ambroise: *Oeuvres d'Ambroise Paré*, Lib. xxiv, 1012.
- Pasteau: *Ann. d. Mal.*, 1908, xxvi, 836.
- Peters, G. A.: *British Med. Jour.*, June 22, 1901.
- Peterson, Reuben: *Substitution of the Anal for the Vesical Sphinctre in Certain Cases of Inoperable Vesicovaginal Fistulæ. Surg., Gynec., and Obstet.*, 1917, vol. xxv, No. 4.
- Piquand and Renaud: *The Levator Pubovaginalis and Genital Prolapse, Revue d. Gynec. et de Chirurg. Abd.*, 1908, No. 1.
- Pique: *Discussion of Chaput's paper, Cong. Franc. de Chirurg.*, 1892, 6th session, p. 618.
- Poirier, P.: *Lymphatiques des Organes Genitaux de la Femme*, Paris, Loeresinier, 1890.
- Polese: *Zentralbl. f. Gynaek.*, 1916, p. 284.
- Reynolds, Edward, and Lovett, R. W.: *An Experimental Study of Certain Phases of Chronic Backache. Jour. Am. Med. Assoc.*, March 26, 1910.

Reynolds, Edward: The Etiology of the Ptoses, and their Relation to Neurasthenia. *Jour. Am. Med. Assoc.*, Dec. 3, 1910.

Reynolds, Edward: Prognosis of Sterility. *Jour. Am. Med. Assoc.*, Oct. 2, 1915.

Reynolds, Edward: Forward Fixation of the Cervix as a Predisposing Cause of Some Retrodeviations of the Uterus, and an Operation for Its Release. *Surg., Gynec., and Obstet.*, 1914, vol. xix, p. 588.

Ristine, C. E.: *Am. Jour. Obstet.*, vol. xli, p. 365.

Rosenow, E. C., and Davis, C. H.: The Bacteriology and Experimental Production of Ovaritis. *Jour. Am. Med. Assoc.*, 1916, vol. lxvi, No. 16.

Ruge and Veit: *Zeitschr. f. Geburtshilfe und Gynaek.*, 1881, p. 261.

Rydygier: *Berl. Klin. Woch.*, 1887, No. 31.

Sampson: *Johns Hopkins Bulletin*, 1904, xv, 285.

Sappey, M. P. C.: *Anatomie-Physiologie-Pathologie des Vaisseaux lymphatiques considérés chez l'homme et les vertébrés*, Paris, 1874.

Schaefer: *Physiology*, London, 1900, ii, 44, 162.

Schaeffer, Oskar: *Atlas and Epitome of Gynecology*, Philadelphia, Saunders, 1900.

Schauenstein: *Arch. f. Geburtsh. u. Gynaek.*, lix.

Schauta: *Monatschr. f. Geburtsh. u. Gynaek.*, 1902, xv, 133.

Schwarz, G.: *Inaug. Dissert.*, Berlin, 1893.

Schuchardt: *Arch. f. Klin. Chirurg.*, 1896, liii, 474. *Zentralbl. f. Chir.*, 1893, xx, 1121. *Monatschr. f. Geburtshilfe und Gynaek.*, 1901, xiii, 744.

Schlimpert: *Zentralbl. f. Gynaek.*, 1911, xxxv, 477.

Sherman, H. M.: Exstrophy of the Bladder—Successfully Treated by Peters Method, *Journ. Am. Med. Assoc.*, Sept. 23, 1905.

Simon, G.: *Wien. Med. Woch.*, 1876, xxvii.

Simon, G.: *Ueber die Behandlung der Blasenscheidenfisteln*, Giesen, 1854.

Sims, J. Marion: On the Treatment of Vesicovaginal Fistula. *Am. Jour., Med. Scien.*, 1852, vol. xxiii, p. 59.

Sims, J. Marion: Amputation of the Cervix. *Trans. Med. Soc.*, N. Y., 1861.

Sinclair: *Jour. Obstet. and Gynec., Brit. Emp.*, 1906, ix, 241.

Sitzenfrey: *Zeitschr. f. Geburtsh. u. Gynaek.*, lix.

Stein, Arthur: Esthioméne and Secondary Elephantiasis Vulvæ. *Surg., Gynec., and Obstet.*, 1912, vol. xiv, 345.

Stein, Arthur: Primary Carcinoma of the Vulva. *Am. Jour. of Obstet. and Dis. of Women*, 1916, vol. lxxiv, p. 577.

Stoeckel, W.: *Zentralbl. f. Gynaek.*, 1909, xxxi, 1.

Stoeckel, W.: *Ueber Radikalheilung des Vulvacarcinom.* *Muench Med. Wochenschr.*, 1910, No. 9.

Idem: *Muench Med. Wochenschr.*, 1912, No. 8.

Idem: *Zentralbl. f. Gynaek.*, 1912, No. 34.

- Idem*: Zentralbl. f. Gynaek, 1909, xxi, No. 1.
- Sturmdorf, Arnold: Studies on a Local Hæmatologic Factor in the Causation of Uterine Hemorrhage. N. Y. State Jour. of Med., Oct., 1911.
- Sturmdorf, Arnold: Perineorrhaphy in Principle and Practice. Am. Jour. of Obstet. and Dis. of Women, 1912, vol. lxvi, No. 3.
- Sturmdorf, Arnold: Perineum, Perineorrhaphy and Prolapse. N. Y. Medical Record, April 1, 1905.
- Sturmdorf, Arnold: The Functional Metrorrhagias. Jour. Am. Med. Assoc., 1914, vol. lxii, 507.
- Sturmdorf, Arnold: Tracheloplastic Methods and Results. Surg., Gynec., and Obstet., 1916, pp. 93-104.
- Sturmdorf, Arnold: Congenital and Acquired Retropositions of the Uterus. Am. Jour. of Obstet. and Dis. of Women and Child., 1916, vol. lxxiv, No. 3.
- Sturmdorf, Arnold: The Cervicoplastic Treatment of Sterility. Am. Jour. Obstet. and Dis. of Women, 1917, vol. lxxvi, No. 3.
- Sturmdorf, Arnold: Chronic Endocervicitis. Trans. Amer. Med. Assoc., 1917, Section Obstet. and Gynec.
- Tait, Lawson: Diseases of Women and Abdominal Surgery, Phila., 1889, vol. i, p. 68.
- Taussig, F. J.: Etiologic Study of Vulvar Carcinoma. Am. Jour. Obstet. and Dis. of Women, 1917, vol. lxxvi, No. 479.
- Thomas, T. G.: A Practical Treatise on the Diseases of Women, N. Y., 1880.
- Thompson, J. E.: An Anatomical and Experimental Study of Sacral Anæsthesia. Ann. of Surgery, 1917, vol. lxvi, No. 6.
- Tiegerstedt: Textbook of Physiology, 1906.
- Trendelenburg, F.: Zur Operation der Ectopia Vesicæ-Zentralbl. f. Chirurg, 1885, p. 857.
- Trendelenburg, F.: Samml. Klin. Vortr, 1890, No. 355.
- Veit: Handb. d. Gynaek, 1907, vol. ii.
- Vineberg, Hiram: Complete Procidentia in a Nullipara. Am. Jour. Obstet. and Dis. of Women, 1917, vol. lxxv, 1060.
- Von Winckel: Pathologie der Weiblichen Sexual Organe. Leipzig, 1881, p. 282.
- Waldeyer: Arch. f. Path. Anat., etc., lv.
- Ward, George Gray, Jr.: The Operative Treatment of Inaccessible Vesicovaginal Fistulæ. Surg., Gynec., and Obstet., 1910, xi, 22.
- Ibid*: 1917, vol. xxv, No. 2, 126.
- Warren, C.: Operation for Complete Tear of the Perineum, Trans. Amer. Gynec. Soc., 1882.
- Watson, C. M.: The Anatomic Repair of the Female Pelvic Floor. Surg., Gynec., and Obstet., 1911, vol. xii, No. 6.
- Wertheim, E.: Arch. f. Gynaek, 1914, cii, 201.
- Winiwarter: Chirurg. Krankheiten d. Haut.
- Ziegenspeck, quoted by Ed. Martin: Arch. f. Gynaek, 1912, vol. xcvi, No. 2.

INDEX.

A

- Abdominal cavity, axis of, 155
- Abortion, habitual, 51
- Abscess, of broad ligament, 46
- Absorption, drug from vagina, 11
- Adnexa, absence of, 279
- Adnexitis, 46
- Albumen, 15
- Amenorrhea, 50
- Anemia, secondary, 6
- Anesthesia, general, 5
 - regional, 17
 - sacral, 17
- Anal sphinctre, laceration
 - through, 198
 - repair of, 198
 - suture of, 201
 - plate, 277
- Androgyny, 304
- Anus primitive, 276
- Apron flap, formation of, 200
 - for complete lacerations, 200, 202
- Artery, internal pudic, 135
- Atresia of cervix, 280
 - of hymen, 299
 - of vagina, 292
 - of vulva, 295
- Atresia ani vaginalis, 295
- Axis of abdominal cavity, 155
 - of pelvic cavity, 155

B

- Bladder, cornua, 172
 - exstrophy of, 240
 - hernia of, 97, 164
 - ligaments of, 170
 - pillars, 175
 - mechanism of, 172
 - prolapse of, 164

- Bladder, topography of, 170
- Blood-pressure, 6
- Broad ligament, abscess, chronic, 46

C

- Caffeine, in shock, 14
- Camphor, in shock, 14
- Cancer, uterine, 63
 - of vulva, 252
- Cardiac murmurs, 6
 - dilatation, acute, postoperative, 16
 - hypertrophy, 6
- Casts, 15
- Catharsis, preoperative, 8
- Catheterization, postoperative, 12, 14
- Cervical canal, function of, 32
 - catarrh, 32
 - drainage, 43
 - erosions, 26, 32
 - eversion, 27, 32
 - flexion, 51
 - lacerations, direction of, 66
 - laceration, pathology of, 32
 - mucosa, 32
 - sphinctre, 43
 - ulceration, 26, 32
- Cervix, amputation of, 29, 66, 69, 86,
 - atresia of, 280
 - cancer of, 63
 - congenital deformity of, 79
 - conical, 51
 - course of infection in, 45
 - dilatation of, 43, 86
 - discission of, 86
 - ectropium of, 32
 - flexion of, 290
 - hypertrophy of, 32

- Cervix, lacerations of, 26
 lymphatics of, 44
 musculature of, 41
 stenosis of, 86, 280
- Clitoris, carcinoma of, 261
 cleft, 240
 hypertrophy of, 297
 lymphatics of, 259
- Coagulation, inhibition of, 48
- Coccygeal plexus, 21
- Colon bacillus infection, 56
- Colpocele, 97, 164
- Colpocleisis, 230
- Colpoperineotomie laterale, 220
- Colporrhaphy, 168
- Congenital fistulæ, 280
 malformations, 275
 post-rectal cysts, 250
 uterine displacement, 151
- Curettement, 58
- Cystocele, 97, 164
 operations for, 174
- Cystitis, 10
- D
- Decensus uteri, 97
- Diet, preoperative, 8
 postoperative, 8
- Dilatation, 58
- Dysmenorrhœa, 50
- Douglas's pouch, spiral suture of, 196
- Dressings, 13
- Dyspareunia, 293, 312
- Dystocia, cervical, 73
- E
- Elephantiasis vulvæ, 268
- Endocervicitis, 32, 54, 55
 treatment of, 58
 as a cause of sterility, 51, 84, 87
 etiology of, 53
 infantile, 53
 virginal, 53
 as a precancerous stage, 63
 spermatocidal effect of, 51
 toxemia of, 52
- Endometrium corporeal, 32
 bacteriology of, 35
 glandular hyperplasia, 34
 menstrual cycle of, 38
- Endometritis, chronic, 32
 hypertrophic, 34
- Endotrachelitis, 32
- Enemata, 16
- Entero-genital fistulæ, 246
- Entero-vaginal fistulæ, 246
- Epidural space, 17
- Episiocele, 230
- Epispadias, 298
- Erosions of cervix, 26
- Erosion, glandular, 27
- Escharotics, 58
- Esthiomène, vulvæ, 269
- Ether effects, 5
- Exophthalmic goiter, 9
- Exstrophy, of bladder, 240
- F
- Fascia pelvic, function of, 115
 superficial, 115
 deep, 115
 perineal, 122
 levator, 117
 recto-vesical, 117
- Fascial overlapping, 147
- Fecal fistulæ, 246
 incontinence, 198
- Feces, impacted, 8
- Fistula, congenital, 250
 entero-genital, 246
 entero-uterine, 246
 fecal, 246
 post-rectal, 250
 recto-perineal, 249
 recto-vaginal, 248
- Schuchardt's incision for, 216
- uretero-vaginal, 215
- utero-vesico-vaginal, 215
- vagino-perineal incisions for, 218
- vesico-uterine, 213
- vesico-utero-vaginal, 213

Fistula, vesico-vaginal, 200
 Flap splitting for vesico-vaginal fistula, 211
 Flaps, formation of, 13
 Flatus, 15
 Flexion of cervix, 291
 Fetal rudiments, 275

G

Gastro-intestinal complications, 8
 Genital groove, 277
 tubercle, 277
 Glands, bartholinian, 122
 Glandular erosion of cervix, 27
 Goffe, J. Riddle, 185
 Gonorrhoea, 10
 Gynecomastia, 306
 Gynandry, 304

H

Hematometra, 293, 302, 303
 Hematocolpos, 293, 302, 303
 Hematosalpinx, 302, 303
 Hemorrhage, 3, 10, 13, 48
 Heart, functional capacity of, 7
 Hemorrhoidal, plexus, 21
 Hernia, pudendal or levator, 323
 Hiatus, sacralis, 18
 Hydrosalpinx, 46
 Hymen, atresia of, 299
 Hymen, imperforate, 299, 311
 Hymen, malformations of, 298
 Hyperthyroidism, 10
 Hypertension, 4
 Hypnotics, 10
 Hypospadias, 296
 Hysterectomy, vaginal for pro-
 lapse, 179, 187, 188, 190

I

Imperforate hymen, 299, 311
 Incompetence of vesical sphinctre,
 235
 Incontinence, urinary, 234
 Infection, 3
 Infantilism, 306

Inhibition of coagulability in men-
 strual blood, 48
 Intermenstrual hemorrhage, 47
 Intestinal stasis, 8
 Intra-abdominal pressure, dynam-
 ics of, 97
 deflection of, 101
 Intrapelvic support, 93
 Iodine, tincture of, 12
 Irrigation, vaginal, 11, 13
 Ischio-rectal hernia, 323

K

Kidneys, functional test of, 7

L


Laceration of cervix, 26
 complications, 45
 pathology, 32
 through anus, 198
 Laxatives, 15
 Leucorrhoea, 46
 Levator ani, coccygeal segment,
 110
 exposure of, 127
 hernia, 323
 paralysis of, 107
 pubic segment, 110
 cleft, 113
 interposition, 137
 myorrhaphy, 124
 sheaths, 135
 Ligament, pubo-cervical, 175
 round, function of, 162
 vaginal fixation of, 184
 vaginal shortening of, 184
 uterine, mechanism of, 104
 Lumbar index, 156
 determination of, 156
 Lymphangioma of vulva, 271
 Lymphatics of adnexa, 45
 of cervix, 44
 of clitoris, 259
 in broad ligament, 45
 peritubal, 45
 periovarian, 45

- Lymphatics of urethra, 259
of uterus, 44
- M
- Malformations, congenital, 275, 309
- Menorrhagia, 47, 50
- Menstrual blood, incoagulability of, 48
- Metrorrhagia, 47
- Morphine, 9, 14
- Müllerian ducts, 275
- Muscle, bulbo-cavernosus, 122
bulbo-vestibuli, 122
constrictor cuni, 123
deep transversus perinei, 122
superficial transversus perinei, 122
sphinctre vaginae, 123
- Myodynamics of levator ani, 109
- Myometritis, 49
- Myometrium, arrangement of, 40
contractions of, 40
- N
- Nabothian follicles, 27
- Nephritis, 7
- Neurosis, reflex, 52
- Novocain, 22
- O
- Os, pin-hole, 51
- Ovarian sclerosis, 46
- P
- Papillary erosion of cervix, 26
- Pelvic abscess, 46
cavity, axis of, 155
floor, mechanism of, 93
fascia, 115
overlapping of, 181
outlet, 122
- Pelvis, angle of, 101
planes of, 101
rotation of, 101
vertical, 156
- Periadnexitis, 46
- Peridural space, 22
- Perineal fascia, 122
hernia, 323
lacerations, 124
laceration, complete, 198
plexus, 21
- Perineoplasty, 88
- Perineorrhaphy, 88
- Perineum, rudimentary, 277
- Perioöphoritis, 50
- Perisalpingitis, 51
- Plexus, recto-vaginal, 131
- Poisoning from vaginal irrigation, 11
- Post-rectal cysts, 250
- Precancerous conditions, 63
- Prolapsus uteri, 97, 193
vaginae, 97
- Prolapse, virginal, 107, 193
- Pseudohermaphroditism, 279, 300
- Pubo-coccygeus, 110
- Pubo-rectalis, 110
- Pubo-vaginalis, 110
- Pudendal hernia, 323
plexus, 21
- Pulse, 7
- Purging, preoperative, 8
- Pyosalpinx, 46
- R
- Rectal hernia, 323
- Rectal wall, anterior, laceration of, 199
- Rectocele, 97, 114
- Recto-perineal fistula, 249
- Recto-vaginal fistula, 248
- Retroposed uterus, 150
- Retroverted uterus, 151
- Retroversion operations, 161
- Round ligaments, shortening of, 184
- S
- Sacral anesthesia, 17
blocking, 17
canal, 17, 18
cornua, 18
hiatus, 18

- Sacro-coccygeal ligament, 19
 Sacro-lumbar angle, 159
 Sacro-uterine ligaments, mechanism of, 160
 Sacro-vertebral angle, 155
 Sactosalpinx, 46
 Shock, treatment of, 3, 13, 14
 Septa, vaginal, 299
 Septum, recto-vaginal, 198
 Sexual characters, secondary, 307
 Spermaticidal, effect of, endocervicitis, 51
 Sphinctre, anal, repair of, 203
 laceration, subcutaneous, 207
 vesical, incompetent, 234
 repair of, 227
 relaxed, 234
 Spina-bifida, uterine prolapse in, 107, 193
 Spinal anesthesia, 17
 Splanchnoptosis, 97
 Staphylococcus infection, 56
 Stenosis of cervix, 86, 289
 Stimulants, cardiac, 9
 Stomach, dilatation of, 8
 Streptococcus infection, 56
 Strychnine, 14
 Sterility, 51, 84, 87
 Sutures, 13
- T
- Thyrototoxicosis, 9
 Toxic symptoms of endocervicitis, 52
 Trachelorrhaphy, 61, 63
 Tracheloplasty, 26
 Transversus perinei muscles, 122
 Triangle, anterior, 122
 posterior, 122
 Tuberculosis of vulva, 270
 Tubal ostia, occlusion of, 51
 Tubo-ovarian abscess, 46
 cyst, 46
- U
- Ulceration of cervix, 32
 Urine, 7, 14, 15
 Urinary incontinence, 234, 237, 298
 Ureter, para-urethral, 237
 supernumerary, external, 230
 transplantation, 242
 Uretero-vesico-vaginal fistula, 215
 Uretero-rectal anastomosis, 241
 Urethra, absence of, 297
 Urethral lymphatics, 259
 Urethro-plasty, 227
 Urogenital sinus, 278
 Urotropin, 14
 Uterine atresia and stenosis, 289
 circulation, 40
 contractions, 40
 displacement, congenital, 156
 fibrosis, 46
 lymphangitis, 44
 poise, normal, 162
 poise, abnormal, 162
 musculature, structure of, 41
 myodynamics, 69
 tetany, 41
 ventro-suspension, 196
 Utero-vesical fold, 184
 Uterus, absence of, 279
 bicollis, 280
 bicornis, 280, 283
 contractions of, 40
 course of infection in, 44
 decensus of, 97
 didelphys, 280, 282
 dilatation of, 41
 duplex, 280, 285
 foetalis, 280, 287
 function in menstruation, 40
 infantilis, 280, 289
 lymphatics of, 44
 pessary support of, 196
 prolapse of, 97, 193
 retroposed, 151
 retroverted, 154
 septus, 280, 285
 structure of, 41
 unicornis, 279, 281

- Vagina, absence of, 313
 abnormal communications of,
 293
 artificial, 314
 atresia of, 292, 313
 duplex, 291
 malformations of, 291
 Vaginal contours, normal, 141
 hysterectomy for prolapse, 188
 outlet, relaxed, 97
 septa, 291
 wall, ectopia of, 164
 foreshortened, 83
 Vaginismus, 312
 Vaginitis, 53
 Varix, traumatic, 135
 Vesical sphinctre, incompetence
 of, 234
 laceration of, 227
 relaxed, 234
 repair of, 235
 Vesico-vaginal fistulæ, 212
 fistula, Schuchardt's incision
 for, 216
 Vesico-uterine fistula, 213
 Vesico-uterovaginal fistula, 213
 Visceral support, intrapelvic, 93
 Vomiting, postoperative, 15
 Vulva, abnormal communications
 of, 295
 atresia ani vaginalis, 295
 atresia of, 295
 cancer of, 252
 lymphatics of, 256
 malformations of, 291
 Vulvæ, elephantiasis, 268
 Vulvar dermatitis, 10
 esthioméne, 269
 excoriations, 10
 eczema, 10
 furunculosis, 10
 lymphangioma, 271
 tuberculosis, 269
 Vulvitis, infantile, 53
- W
- Wolffian body, 275





JAN 17 1966

GS



WP 660 S936g 1923

47530560R



NLM 05244398 9

NATIONAL LIBRARY OF MEDICINE