

WN 230 L549d 1923

45510660R



NLM 05232526 9

NATIONAL LIBRARY OF MEDICINE

SURGEON GENERAL'S OFFICE
LIBRARY.

ANNEX —

Section _____

No. 113,
W. D. S. G. O.

No. 259274


3-513

Dental *Stereoroentgenography*

By C. A. LE MASTER, D. D. S.
PROFESSOR OF ROENTGENOLOGY
St. Louis University Dental Department



PUBLISHED BY
THE SOUTHWORTH COMPANY
Troy, N. Y., U. S. A.



WN
230
L549d
1923

filmo. 9922, item 5

Copyright, 1923, by
THE SOUTHWORTH COMPANY, Publishers
Troy, N. Y.

#17. ²/₁

APR 11 1925

©C1A829131

✓
m ✓

Dental Stereoroentgenography

By C. A. LE MASTER, D. D. S.

Professor of Roentgenology, Saint Louis University Dental Department



THE use of the stereoscopic method of roentgen technic in dental examinations is something new. It is something new but not novel, for with simplified methods of technic, it is of practical value. This method of examination has been grossly underestimated by some, and correspondingly exaggerated by others. The indisputable fact remains, that a simple roentgenogram is a flat record of superimposed shadows, while a stereoroentgenogram is a record of those same shadows arranged in their proper perspective planes, from which it follows that stereoroentgenography may be used with great advantage wherever the subject for examination calls for differentiation of structures lying in different planes and depths; we can, therefore, readily see that examinations of this character would be extremely valuable to the dental surgeon, whose technical work demands that he have a clear idea as to the relative positions of the teeth to their surrounding structures.

¶ It is my hope that I may be able to give to the profession a proof of the valuable aid which perspective adds to the dental roentgenogram. To do this it will be neces-

sary to briefly review the fundamental principle involved in taking and viewing stereoroentgenograms; simplified methods necessary to obtain true stereoscopic plates of dental conditions, with both the intraoral and extraoral positions; the proper method of mounting and viewing them, and their value as compared with the flat roentgenogram.

¶ The roentgenogram may be described as a record of shadows cast by objects which are placed between an X-ray tube in action and recorded on a sensitized plate or film. These shadows are recorded on the sensitized surface of the film in simple outline or sketch form and for that reason were at one time called a skiagram or outline. A roentgenogram, therefore, is a record of superimposed shadows one upon the other, which may not only render them difficult to interpret, but very often misleading. The density of these shadows is in direct ratio to the opacity or resistance which the objects offer to the passage of the roentgen ray, and it is often difficult to determine the position of these shadows when substances of different density are to be differentiated.

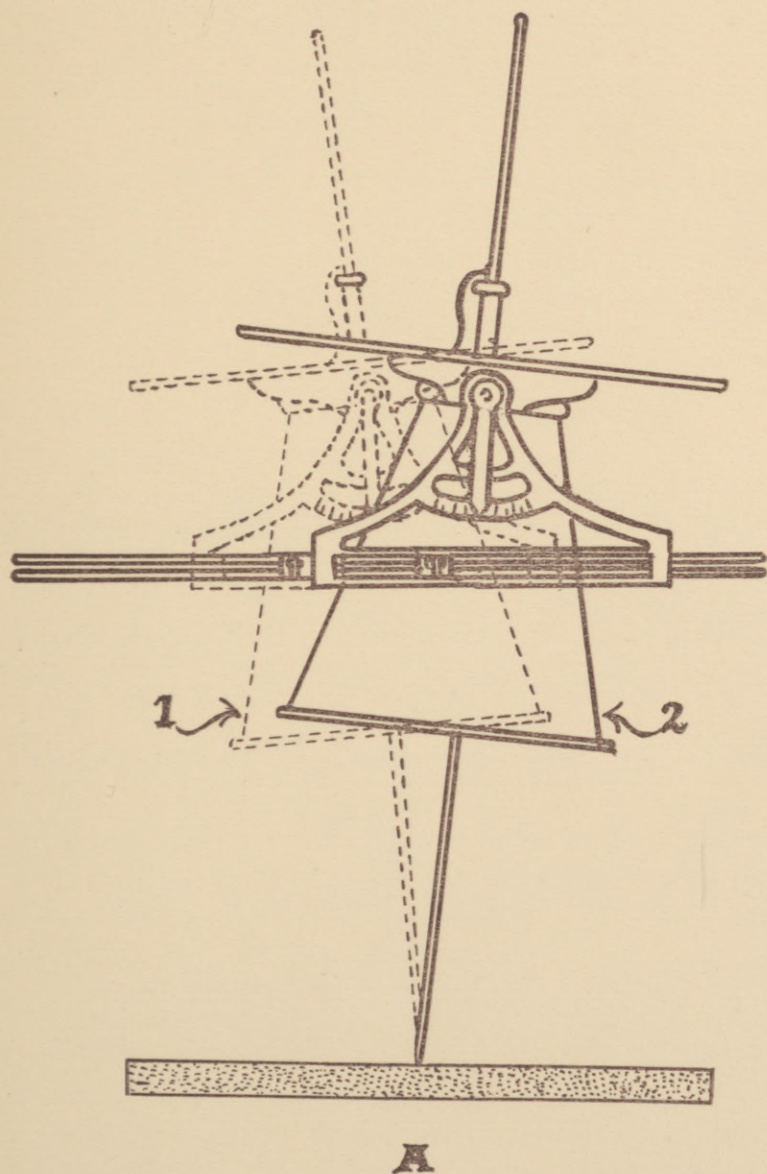
¶ The stereoroentgenogram may be described as a record of shadows cast by objects which are placed between an X-ray tube in action and recorded on sensitized plates or films, two in number. One plate records the shadows cast when the central ray passes from the focal spot of the target of the X-ray tube at an angle corresponding to the angle of vision of one eye. The other plate records the shadows cast when the central ray passes from the focal spot of the target of the X-ray tube at an angle correspond-

ing to the angle of vision of the other eye. We thus have records of shadows from both angles of vision, and when they are viewed through a suitable apparatus, the stereoscope, the two roentgenograms fuse into one giving stereoscopic vision, enabling one to view artificially what our eyes would have seen if the object had been viewed directly.

¶ Figure A illustrates the principle of making stereoroentgenograms.

¶ This method of examination was first suggested by Ilihu Thompson in 1896, with reference to X-ray examinations. Sometime later Sir James Mackenzie Davidson of London, England, further developed this idea, and from that time on it has become a common practice with competent roentgenologists all over the world. This is true with reference to the entire body except the teeth; very little work has been done by the dental roentgenologist on this phase of his work.

¶ Singularly enough stereoroentgenography has been employed very little in its application to dental roentgenography. The extraoral stereos have been made for some time, but these, although valuable, do not give the information that intraoral stereos do for certain dental conditions. The failure of the dental roentgenologist to employ this means of examination may be summed up in the following manner: The technical difficulties encountered in placing the two films accurately in the same positions in the mouth for two exposures; in securing the absolute immobilization of the patient between exposures; in determining the proper angles of the central ray, with the two shifts of the X-ray tube; in properly mounting the roentgenograms for



viewing; and finally the actual difficulties experienced by some individuals in viewing stereoscopic films; all may be reasons for the less extensive use of this method of examination.

¶ It will be the purpose of this work to illustrate and in a general way give the technic required for making dental stereoroentgenograms and to prove the many benefits which the dentist may obtain from the judicious use of the principle of perspective as applied to dental roentgeneology

¶ The technic for making dental stereoroentgenograms must be considered for both the intraoral and extraoral methods. Due to the fact that better detail and usually more satisfactory results can be obtained from the intraoral method, it is advisable to take as many of the teeth and areas of the process as possible this way. The areas which can be best taken with the intraoral method, film within the mouth, are as follows: The maxillary and mandibular anterior teeth; maxillary and mandibular cuspids and bicuspid. The molar regions are best taken with the extraoral method, the film outside the mouth.

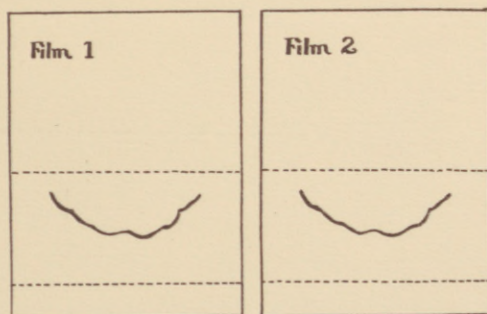
¶ The technic necessary for the production of the intraoral stereoroentgenogram has been the greatest difficulty in the past and it is mainly for that reason that this method of roentgenographing the teeth has been very little employed. There have been numerous film holders and appliances devised to aid in stereoscopic technic, but these in all instances have proven valueless. Many attempts have been made to secure true stereoroentgenograms within the mouth

without practical results. The method which the writer advocates is simple and practical. To secure true stereoroentgenograms and not those of the pseudo type has been the main difficulty. The dental surgeon will rely upon the stereos when operating and if they give him false information his results will likewise be false. Stereos that are to be used for such work therefore must be accurately made and mounted, otherwise they will prove misleading and worse than useless to the operator.

¶ **Intraoral Technic.** The technic may be described as follows and the steps mentioned must be closely followed to secure accurate results:

¶ **A.** Prepare the tube shift with reference to the lateral shift, $2\frac{1}{4}$ inches; tilt the tube by a special tilting device so that the direct rays are at both extremes pointing to a centre on the film. This is done at a given distance, say 21 inches, and this distance must be used later when the exposures are made. The lateral shift of the tube corresponds to the pupular distance, and the tilt of the tube to the angle of accommodation which the eyes would use if viewing the object to be roentgenographed. Figure A illustrates the changes in position of the tube when taking stereoroentgenograms. Position 1, first position. Position 2, second position.

¶ **B.** Prepare the films. The main requisite is a method whereby the films No. 1 and No. 2 may be placed relatively in the same positions in the mouth. Use either the Eastman large dental film No. 2 or if this is too large their special size No. 1 A, may be used. Take two film packets, marking them No. 1 and No. 2 respectively. Place film



B

No. 1 between the maxillary and mandibular teeth as though an occlusal bite roentgenogram were to be made; instruct patient to bite on this film. With a pencil or pen trace the outline of occlusion of the maxillary anterior teeth from left to right cuspid, on their labial incisal aspect on the film. Figure B shows results of drawing on the film packet. It is difficult to trace on the parafin paper which covers the packets, but this difficulty can be overcome by pasting a sheet of white paper over the smooth surface of the cover. These can always be prepared in numbers of a dozen or more and are always ready for use. Transfer the sketch from film No. 1 to film No. 2. This is best done by tracing it off film No. 1 onto a thin piece of paper or celluloid and then using tracing paper to reproduce it on packet No. 2. Care must be taken to reproduce it on the same location on film No. 2 as it occupied on film No. 1. Mark packet No. 1 with a small lead "L" by placing it on a corner of the packet with a piece of adhesive tape. This film then will be for the left shift and will be the one for the left eye to view. To further insure that the stereoroentgenogram is later viewed properly, place a small piece of lead on the lingual aspect of one of the teeth, attaching it with adhesive; this will later show on the stereoroentgenogram and one will be able, knowing where the metal was placed, to determine whether it is being viewed from the labial, lingual or buccal aspect of the teeth, a very difficult and confusing matter.

¶ C. Clamp the patient's head in the headrest so as to immobilize the part as much as possible. Instruct patient as to what is to be done; namely the opening and closing of the mouth, simply by dropping the mandible without

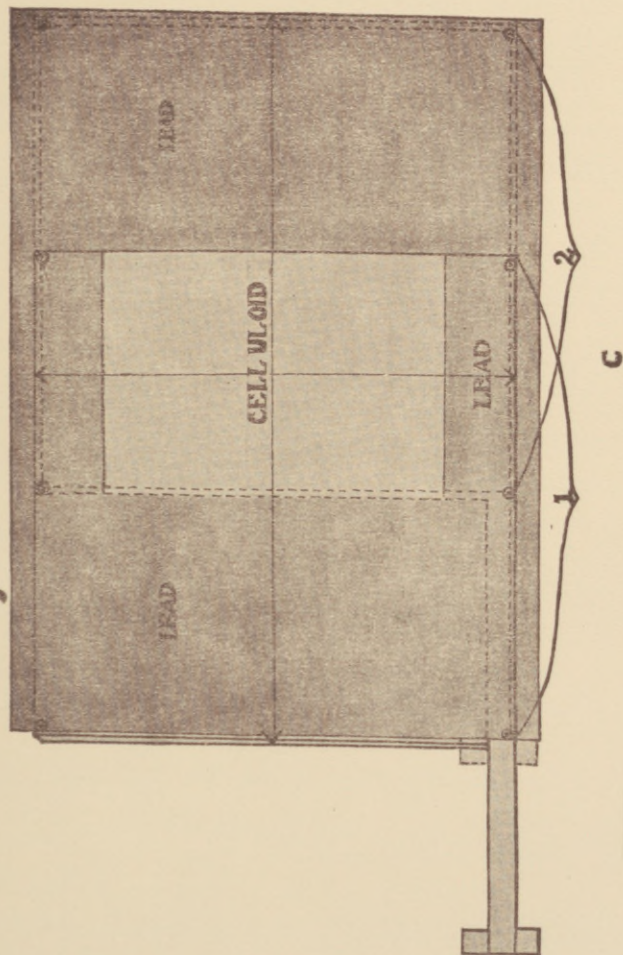
moving the other part of the head; the placing of the films No. 1 and No. 2 into position; the shift of the tube, etc.

¶ **D.** Replace film No. 1 between the teeth in its original position, using the sketch on the packet as a guide. Make exposure using regular technic; as a guide to the angle, namely, the angle of incident of the normal ray shall strike at right angle the plane which exactly bisects the angle formed between film and tooth, a law to which there is no exception. Remove film No. 1, insert film No. 2 using the transferred sketch as a guide to position, shift and tilt tube to the other side and make the other exposure. The above method if followed accurately will give true stereoroentgenograms.

¶ If the maxillary or mandibular teeth are missing from the arch, it is not possible to use the above method. A thin aluminum tunnel can then be used, which will accommodate the packets; this tunnel is placed in the mouth and the patient is instructed to bite upon it. The tunnel is slightly larger than the Eastman No. 2 dental film. It is possible with the use of this tunnel to place the films No. 1 and No. 2 in accurately the same position within the mouth by using one side and corner of the tunnel as a guide to position. The same areas of the mouth can be taken with this method as the other, but the tunnel is rather large and causes considerable discomfort to the patient, and the first or sketch method, is usually the preferred one wherever it can be used.

¶ **Extraoral Stereoroentgenographic Technic.** The technic for making extraoral stereoroentgenograms does not differ from that used for other parts of the body, as

they are taken with the plate or film on the outside of the mouth. This method is used when the maxillary or mandibular molars are desired, and also the maxillae and mandible themselves. The position of the patient may be described as follows: the affected side of the maxilla or mandible towards the plate. Care must be exercised to direct the central ray in such a manner as to project the shadows of the affected jaw without any superimposed shadows. A handy tunnel or shifting device for the film or plate is the following, designed by the writer, and one which meets the requirements for extraoral stereoroentgenograms. It is made to accommodate a 5 x 7 inch film or plate, taking both exposures on one film, which can then be viewed directly through a parlor hand stereoscope, this saves the trouble of mounting and makes the taking of them very simple. Figure C of the top of the tunnel will illustrate. The lead offers a protection for the part of the film unexposed and later, in the other position, for the exposed part. The entire top of the tunnel is covered with a one-quarter inch sheet of celluloid extending over the center of the tunnel, where the patient's face is placed leaving this part of the film for the exposure. Bracket 1 illustrates the film in position for the first exposure, and bracket 2 illustrates the position of the film for exposure two. The tunnel should be mounted on a stand about four inches high and the exposures made with the patient in the prone position. Mark the left shift, and for convenience use position 1, marking that part of the film with the lead "L." A small piece of lead placed on the outside of the cheek might also act as a guide to position of viewing later.



¶ **The Stereoscope.** The stereoscope is a simple optical contrivance by which two flat roentgenograms of an object taken at different angles and from different viewpoints are viewed simultaneously and are fused into one image, giving the actual appearance of relief, showing the relative depths of the objects and their positions.

¶ The stereoscope was invented by Professor Wheatstone in 1838; subsequently Sir David Brewster invented the refracting or lenticular stereoscope. The stereoscope most practical for viewing the dental stereoroentgenogram is the small, hand, parlor stereoscope.

¶ **Mounting the Intraoral Stereoroentgenogram.** Mounting the intraoral stereoroentgenogram is a very necessary and important step and care must be exercised to see that they are mounted accurately. The dental films have an emulsion side and a glossy or glazed surface, the glossy surface must be the one facing the observer. The stereoroentgenogram with the mark L must be for the left eye vision and the other one for the right eye vision. Mount them either upon a clear glass or better a sheet of frosted celluloid, using the lower border as a guide to position of mounting. This is best done by drawing a line across the lower border of the mount about one-half inch from the bottom, placing the lower border of the film directly upon this line. They are thus mounted parallel to one another. Place them about one-half inch from one another from the median line of the mount. Stereoroentgenogram No. 1 will illustrate this. If the positions of the films were accurately in the same positions in the mouth when the exposures were made, one will thus get the

stereoscopic vision without any strain to the eye. If there is a strain this can usually be relieved by taking the stereoroentgenograms off the mount, placing the glossy surface of one on the emulsion surface of the other, superimpose the shadows on the roentgenograms, and cut them both at their lower border so that you have a resulting straight line to use in placing them upon the mount. This should be sufficient to thus correct their faulty position and then should be viewed without strain to the eye.

¶ **Mounting the Extraoral Stereoroentgenogram.** The extraoral stereoroentgenogram if taken with both exposures on the same film, does not have to be mounted, but can be viewed directly through the hand stereoscope. If they are taken on two separate films or plates, they are best viewed through the large stereoscope. If it is desired to view them through the small hand stereoscope they must be either reduced in size or it is possible to cut them down in size to show only a small area of the roentgenograms. This is done by superimposing and cutting them down the same as done to true up the intraoral ones.

¶ **Viewing the Stereoroentgenograms.** The intraoral stereoroentgenograms are viewed with the glossy surface of the films towards the observer, thus is obtained a view within the mouth out or from the lingual aspect of the teeth. The extraoral ones should be viewed the same way, and it is best to mark the sides of the films before developing, indicating which side corresponds to the glossy surface and the emulsion surface. If plates are used, view through the glass side. If the areas X-rayed have been marked with a lead marker so that one is always able to determine

whether he is viewing from the labial, lingual or buccal surface, they can then be viewed in any manner desired since it is always possible to determine which side is being viewed. A diffused light should always be used, it gives better detailed vision. It must be remembered that there are some individuals who find difficulty in accommodating their eyes for stereoscopic vision, while there are some who find it impossible to view stereoscopically. These individuals are comparatively few, however, and no one should place himself in this class until he has tried faithfully to accommodate himself to stereoscopic vision. The observer will know when he is viewing stereoscopically, by the fact that the two roentgenograms fuse into one and give the appearance of depth to the view. To fully appreciate the stereoscopic effect, view and study the stereos in this work first without the stereoscope, then view stereoscopically and compare results. There are regulating devices on all stereoscopes and the settings differ for practically all individuals and must be regulated for all views.

¶ It is my desire to illustrate some of the valuable points in technic, and in order to do so clearly it is best to show some stereorontgenograms of dry specimens. The first few, therefore, will be of the dry specimen.

¶ The usual question asked by the dentist doing general practice is "Of what value is the stereoroentgenogram to me? I do not attempt the difficult extractions such as impacted cuspids or third molars or the removal of foreign substances, etc.; I refer them to the men specializing in these particular branches." Does he really know his limitations; does he not often attempt operations which are

far beyond his ability, probably due to the fact that they appeared on the roentgenogram or flat picture to be very simple; and does he not after an attempt at operating on the case have to finally refer it to the specialist? Had he viewed the case stereoscopically he might have come to the conclusion that the case was not so simple as it had seemed, for the average person viewing the stereoroentgenogram says "Why you can see the condition plainly." For example, if it is a case of an impacted or unerupted tooth which, from the flat roentgenogram appears to be in apposition to the roots of the other teeth, when viewed stereoscopically, however, it can be determined whether this condition is true or not and usually these unerupted teeth are not in apposition to the surrounding teeth; this the stereos will show. The real value therefore to the general practitioner in dentistry is that it gives him a comprehensive view of the field of operation and thus makes him better able to diagnose the true conditions, enabling him to proceed with an operation, where it is contemplated, with considerably more confidence and with a far greater hope of success, or enabling him to properly diagnose the case as one which is beyond his ability to operate upon.

¶ **The Value of the Stereoroentgenogram to the Dentist Specializing in the Extraction of the Teeth.** The exodontist of today is truly a surgeon and his duties are strictly surgical. True the roentgenogram is not absolutely necessary for every case he handles, but it is a valuable aid to him, especially where he is expected to remove the unerupted or impacted tooth or pieces of foreign substances. In cases of this kind he, like the medical surgeon, must first localize the foreign substance or tooth before operating,

since it is necessary to know its location with reference to the surrounding structures so that he may plan his operation and successfully perform it. The methods we have been using to localize such conditions in and around the teeth have proven unsuccessful. Although some very clever operations have been performed without the use of the stereoroentgenogram, I know that they could have been done with greater ease by the surgeon and with probably better results to the patient had he employed its aid, for with it he gets depth to his view and can really see the condition as it exists.

¶ **The Value of the Stereoroentgenogram to the Orthodontist.** The practice of orthodontia is a most scientific and exacting branch of the dental profession, and the Orthodontist, who really obtains results, is the one who carefully diagnoses his case and carefully plans his treatment; this is at times very difficult to do as many unforeseen things may come up during the treatment which are very discouraging. If he had had a clear understanding of, not only the relation of the erupted teeth, but also the unerupted ones with reference to their line of eruption, their position in the process with relation to the surrounding teeth and structures, he could have been able to avoid many of these conditions. It will be easy to determine these conditions if one will study the stereoroentgenograms, for they surely afford an ideal study model of cases.

¶ Bearing these facts in mind, a clear study of the stereoroentgenograms of this book should be evidence of the value of this method and show wherein its application could be of the greatest aid.

Anterior Maxillary Teeth Viewed from the Lingual Aspect.

[Stereo 1.]

- ☐ Dry specimen.
- ☐ Illustrating the Dental Intraoral Stereoroentgenogram.
- ☐ Anterior maxillary teeth, viewed from the lingual aspect.

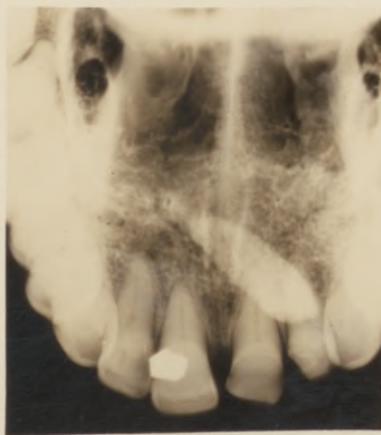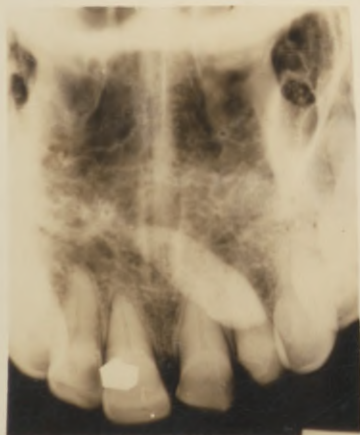☐ Shows a cuspid on the right side decidedly to the lingual of the central and lateral incisors. The cuspid was glued to the hard palate opposite these teeth before the exposures were made. It is not in apposition to the teeth as the stereo shows.

☐ Note white shadow of the lead "L;" stereo for the left eye. Radiopaque object on the lingual surface of the central incisor, was attached to the tooth to act as a landmark. It appears decidedly to the lingual of the tooth proving that you are viewing from the lingual aspect.

- ☐ Line shows position of mounting the stereos.

Stereo 1.

Serial N^o 67



**Duplicate of Stereo 1 with the Roentgenogram for the
Left Eye Placed on the Right Side and the
Right Side on the Left.**

[Stereo 2.]

¶ Intraoral Stereo.

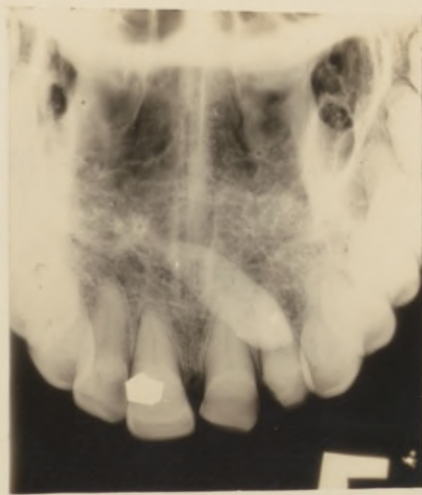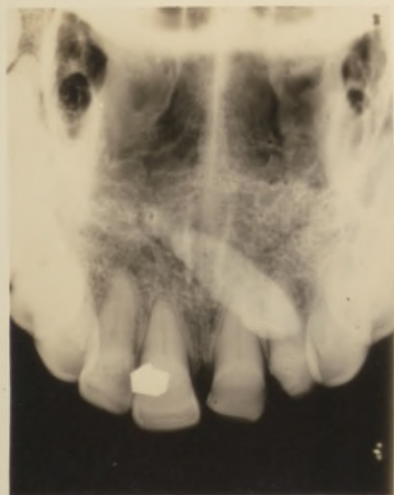Duplicate of Stereo 1 with the roentgenogram for the left eye placed on the right side and the right side on the left.

¶ It can be noted that the cuspid still appears on the right side opposite the right central and lateral incisors but this time labial to them; this reverses the appearance of the case; however, the shadow cast by the small piece of lead now appears on the labial surface of the left central incisor; knowing that this was placed on the lingual surface it immediately checks up as improperly mounted stereos.

¶ It can easily be seen from this example the necessity of following the rules for, it is with difficulty, even with trained eyes to tell definitely whether one is viewing the lingual or labial aspect without some definite guide.

Stereo 2

Serial N^o 67



**Viewed from Buccal Surface, from Without
the Mouth In.**

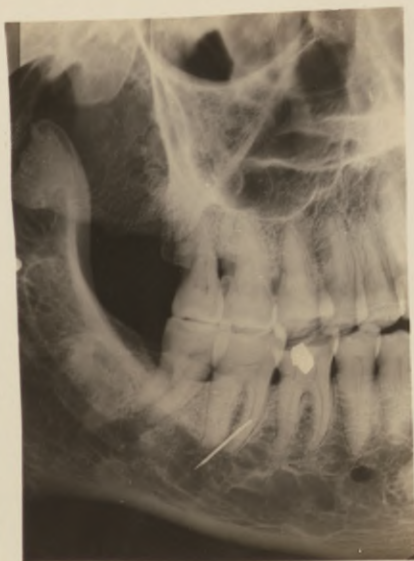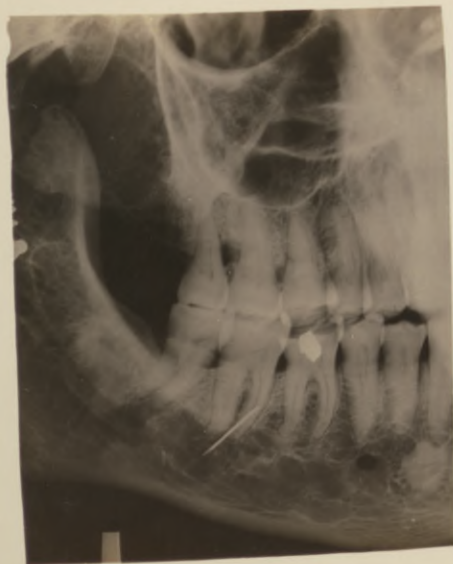[Stereo 3.]

- ☞ Dry specimen.
- ☞ Illustrates the extraoral stereo.
- ☞ Viewed from the buccal surface, from without the mouth in.
- ☞ Broken off hypodermic needle placed opposite the second mandibular molar on the buccal surface.
- ☞ Stereo shows the needle in position as described above.
- ☞ Lead marker was placed on the buccal surface of the crown of the second molar; which is seen between the viewer and the crown of the tooth; proving that you are viewing from the buccal surface.
- ☞ Both exposures made on the same film; size 5 x 7 inches and viewed directly without mounting.

Stereo 3.

Serial ^{No}

67



**Illustrates a Maxillary Cuspid Labial to the Right
Central Incisor.**

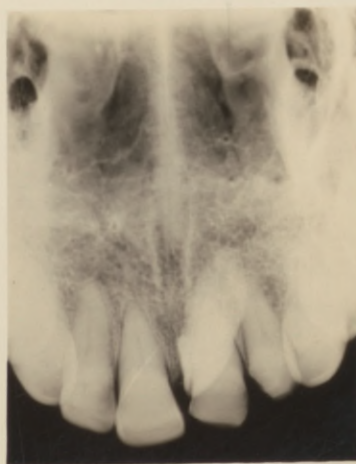
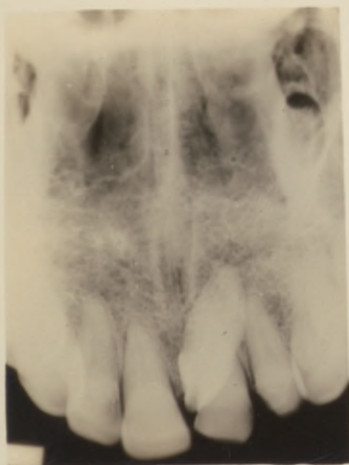[Stereo 4.]

- ☞ Dry specimen.
- ☞ Intraoral stereo.
- ☞ Illustrates a maxillary cuspid labial to the right central incisor.
- ☞ Cuspid was glued to place on the labial surface of the process opposite the central incisor before the stereos were made.
- ☞ Lingual aspect view.

Stereo 4.

Serial

67



Lingual Aspect View.

[Stereo 5.]

- ☐ Intraoral stereo.
- ☐ Dry specimen.
- ☐ Lingual aspect view.
- ☐ Localizes broken off hypodermic needle.

☐ It appears distinctly lingual to the left maxillary central incisor, far removed from the root of the tooth. The needle was glued to place opposite the left central incisor before the exposures were made.

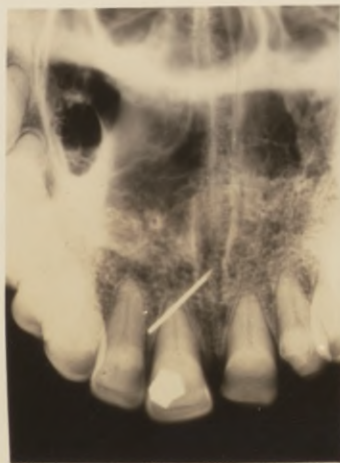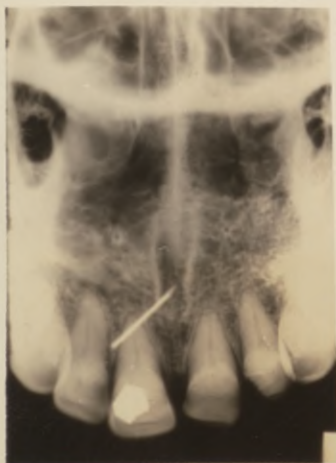☐ Let it be remembered that the needle even if placed on the labial surface would appear lingual when viewed on the flat roentgenogram, for we are all trained from childhood to associate clearness with nearness, and the needle being a very dense substance would appear just as clear in outline as it does on the lingual surface using identical exposures, for distance as a general rule plays little or no part in the roentgenogram when substances of heavy density are to be localized.

Stereo 5.

Serial

Nº

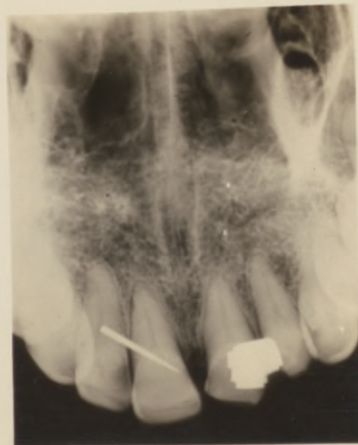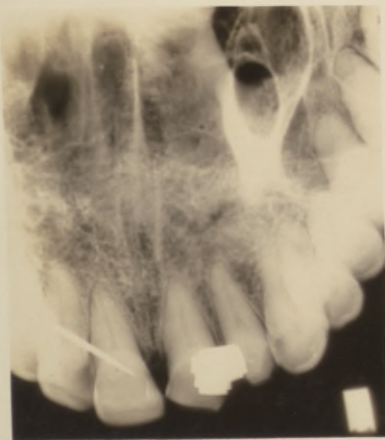67

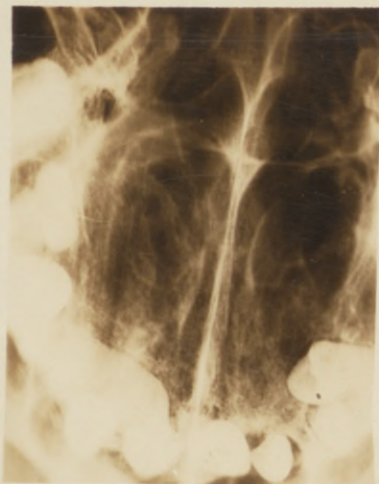


Lingual Aspect View.

[Stereo 6.]

- ☞ Intraoral.
- ☞ Dry specimen.
- ☞ Lingual aspect view.
- ☞ Illustrates a broken off hypodermic needle opposite the left maxillary central and lateral incisors. It appears to be on the labial surface far removed from the crowns of the teeth. It was glued on the labial surface of these teeth.
- ☞ If these stereos are viewed without the stereoscope, as a flat roentgenogram, the needle appears lingual to these teeth.

Stereo 6.**Serial** **N^o****67**



Roentgenogram X

- ☐ Dry specimen.
- ☐ Occlusal bite roentgenogram.
- ☐ Skull has two unerupted teeth, maxillary cuspid on the right and bicuspid on the left.
- ☐ Roentgenogram illustrates a method used to determine whether teeth are lingual or labial in their position. It is the only practical method which will show whether teeth are located lingual or labial to the teeth in the arch, other than stereos. The technic used in making this roentgenogram is similar to the one used to obtain the Sphenoid Sinus within the mouth; it is taken with the film between the teeth and is called the occlusal bite roentgenogram.

It shows the occlusal surface of the teeth and shows the two unerupted teeth as being lingual to the teeth in the arch; it does not give their long axis position in relation to the surrounding teeth or structures.

¶ The exposure to obtain true occlusal roentgenograms of the maxillary teeth are as a rule prohibitive, as the exposure is necessarily very long, due to the fact that the central ray must pass through the thickest part of the skull.

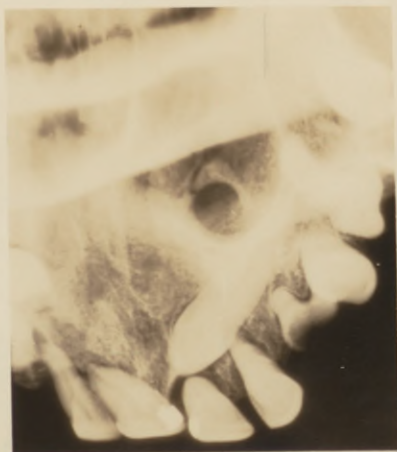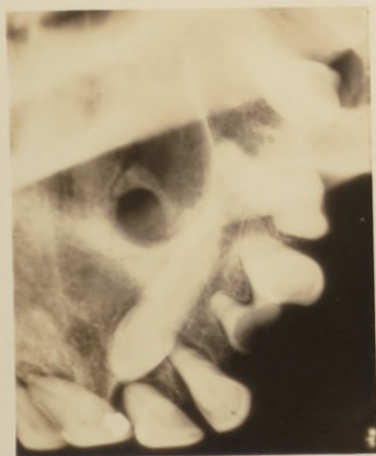¶ The illustration is shown so that a comparison can be made of the same case when the stereos are used.

Lingual Aspect View.

[Stereo 7.]

- ☐ Intraoral stereo.
- ☐ Dry specimen.
- ☐ Lingual aspect view.
- ☐ Same case as Roentgenogram X.

☐ Right maxillary cuspid; unerupted. It is seen to lie on the lingual surface of the right central and lateral incisors and bicuspids. Its cusp is directly opposite the apex of the central incisor, not in apposition to it. Lingual to the apex of the root of the lateral incisor, and superior and lingual to the bicuspid roots. Its root is deeply imbedded in the process more so than the cusp of the tooth. The process was dissected from around this tooth and its position checked up accurately to that described above.

Stereo 7.**Serial N^o 67**

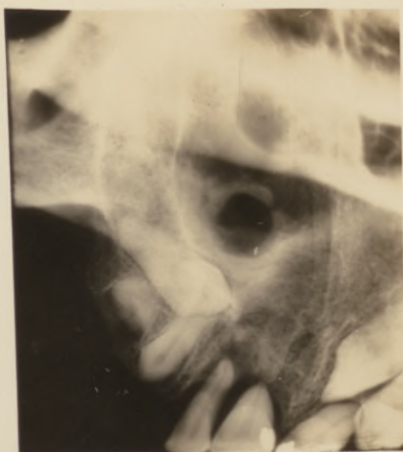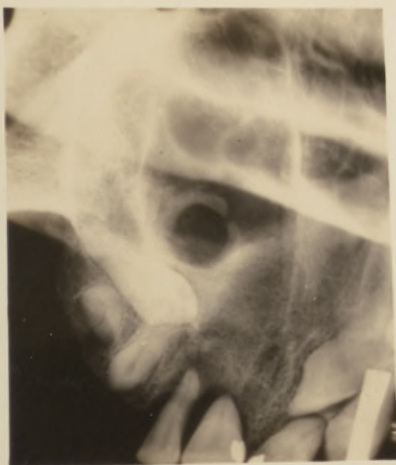Lingual Aspect View.

[Stereo 8.]

- ☐ Intraoral stereo.
- ☐ Dry specimen.
- ☐ Lingual aspect view.
- ☐ Same case as Roentgenogram X.

☐ Localizes the left maxillary bicuspid; Its crown is lingual to the remaining root of the cuspid and its root is superior and lingual to the root of the first molar and is not in apposition to either of these roots. Also note that the apex of the unerupted bicuspid punctures and extends a slight distance beyond the periphery of the process on the buccal side.

☐ The process surrounding this tooth was dissected away and its position checked up accurately as described above.

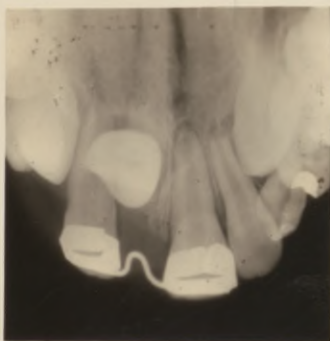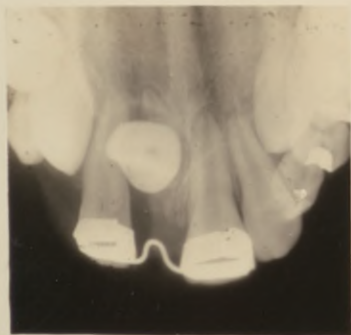Stereo 8.**Serial****Nº****67**

Lingual Aspect View.

[Stereo 9.]

- ☐ Intraoral stereo.
- ☐ Lingual aspect view.

☐ Left maxillary central incisor. Unerupted; rotated with its labial surface towards the lingual. Note its line of eruption, it is erupting directly towards the viewer, lingual to the lateral incisor. The portion of root lingual to its crown was thought from the flat roentgenogram, to be that of a deciduous tooth; by studying the stereo carefully you can see that this is the root of the central itself and that it is a tooth having a decidedly curved root. It was realized after the stereo was made that this tooth would be valueless even if moved to its proper place in the arch and that it would be a difficult work if accomplished, so it was extracted and its position checked up very accurately with the above findings. This is certainly valuable to the orthodontist as it not only saved both he and the patient much inconvenience, but greatly assisted him in his diagnosis of the case.

Stereo 9.**Serial N^o 67**

Lingual Aspect View.

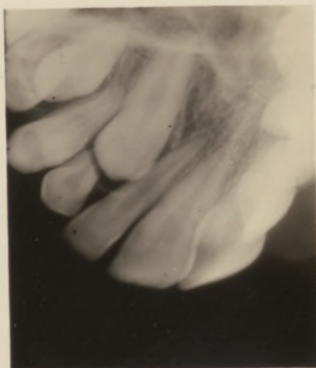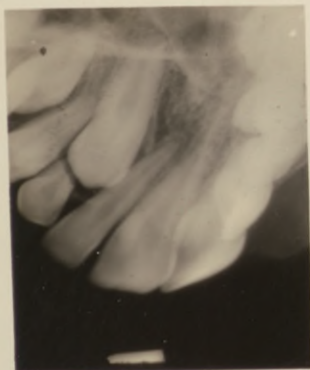[Stereo 10]

- ☞ Intraoral stereo.
- ☞ Lingual aspect view.
- ☞ Left maxillary cuspid; unerupted. Stereo 11 will be the same case but the right side. If viewed without the stereoscope the tip of the cuspid appears to be lingual to the lateral incisor and will erupt lingual to this tooth. No indication of its position could be determined by digital examination.
- ☞ The stereo shows that it is erupting lingual to the lateral incisor.

Stereo 10.**Serial**

No

67



Lingual Aspect View.

[Stereo 11.]

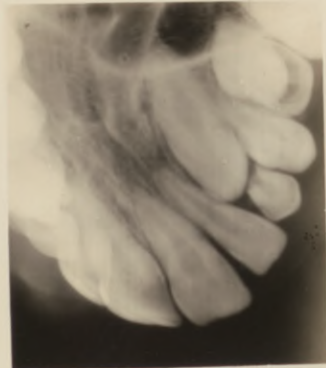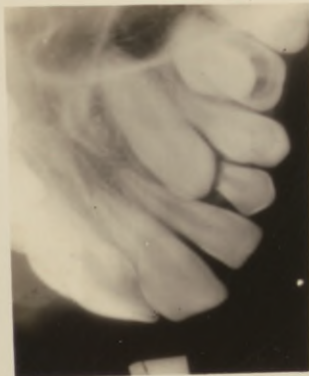- ☐ Intraoral stereo.
- ☐ Lingual aspect view.

☐ Right maxillary cuspid; unerupted. Same case as Stereo 10. This cuspid also appears to be erupting lingual to the lateral incisor if viewed without the stereoscope. The stereo shows it erupting labial to the lateral incisor slightly tilted toward the median line. No indication of its position could be determined by digital examination. This is surely valuable to the orthodontist, as it shows him where these teeth are located and their line of eruption can be seen. He will thus arrange his appliances when he starts the case to take care of these difficulties and obtain quicker and better results with less effort on his part and much less discomfort to his patient.

Stereo 11.

Serial **☐**

67



Lingual Aspect View.

[Stereo 12.]

☞ Intraoral stereo.

☞ Lingual aspect view.

☞ Right maxillary cuspid and second bicuspid; unerupted.

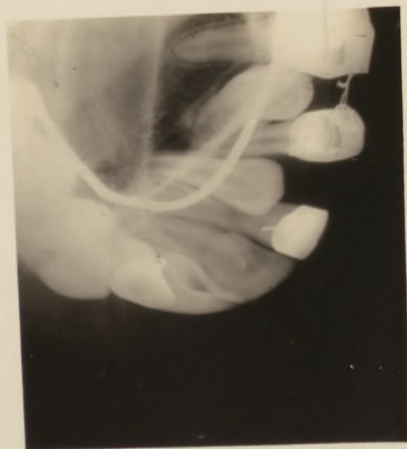
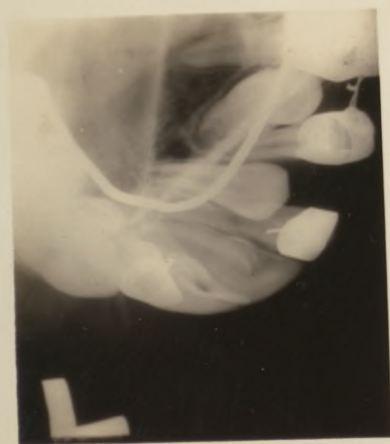The cuspid can be seen to lie labial to the lateral incisor and misplaced slightly towards the median line.

☞ The second bicuspid can be seen erupting slightly lingual and towards the distal, and is impacted against the crown of the first molar. Seeing these conditions the orthodontist can rearrange his appliance to take care of these teeth and thus obtain a uniform result, at the same time, instead of overcoming one difficulty at a time and always having new ones present themselves. Note that the stereo shows the relation of the appliance with the teeth and makes an ideal study model.

Stereo 12.**Serial**

No.

67



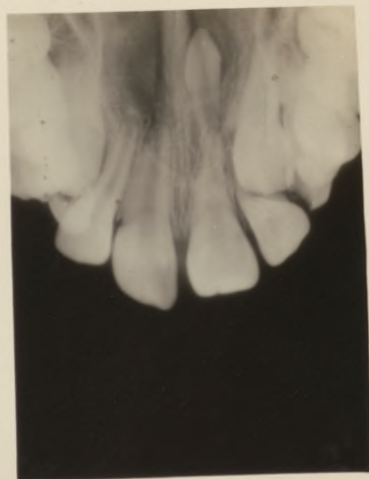
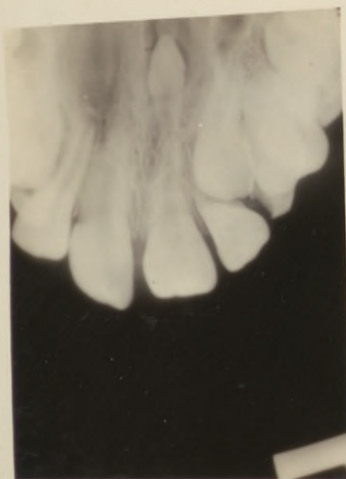Lingual Aspect View.

[Stereo 13.]

- ☐ Introral stereo.
- ☐ Lingual aspect view.
- ☐ To act as study model for the Orthodontist; there is indeed plenty to study in this case.
- ☐ Supernumerary tooth can be noted erupted in the lateral incisor area; lateral incisor unerupted. Right maxillary cuspid unerupted; erupting in its proper position.
- ☐ Supernumerary tooth superior to apex of the root of right maxillary central incisor; note that it lies inferior to the palatal ridge and is not deeply imbedded in the process; its root is lingual to apex of central incisor and will not be a difficult tooth to extract.
- ☐ This stereo is simply a general study model for the anterior teeth. Special ones were made for the cuspid and bicuspid on both sides to determine more accurately their position.

Stereo 13.

Serial N^o 67

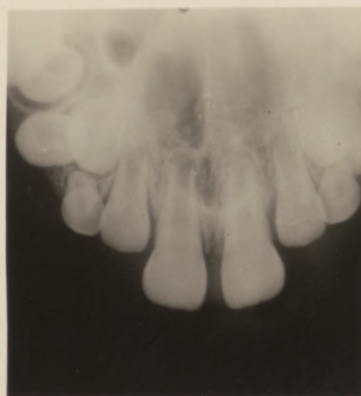
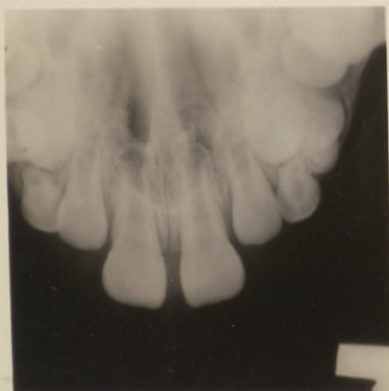


Lingual Aspect View.

[Stereo 14.]

- ☐ Intraoral stereo,
- ☐ Lingual aspect view.
- ☐ Maxillary teeth.

☐ Case taken to act as a study model for the Orthodontist. A study of this case reveals the condition, position and erupting plane of the unerupted teeth. This gives the Orthodontist a definite guide as to the proper method of treatment; it shows the relative position of the erupting teeth; it gives a comprehensive view of what he can expect of the case in the future. Surely this is valuable information.

Stereo 14.**Serial N^o****67**

Lingual Aspect View.

[Stereo 15.]

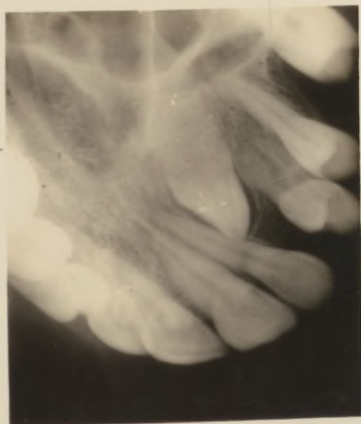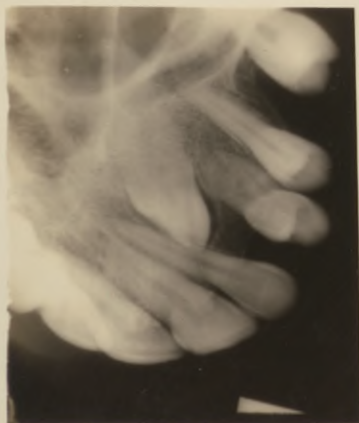☞ Intraoral stereo.

☞ Lingual aspect view.

☞ Right maxillary cuspid; its position from the flat roentgenogram was described as follows:

☞ It appears to lie lingual to the lateral incisor and first and second bicuspid, fairly high in the process. Attempt at extraction failed, for after dissecting the process on the lingual surface of these teeth and the tooth not reached, it was finally decided that the tooth was too high in the process to extract without a great deal of destruction of the process.

☞ The stereo shows the position of the cusp of the cuspid to be labial to the lateral incisor root, its root to be lingual and superior to the bicuspid and molars, with the apex of its root within the antrum. An incision on the labial surface of the lateral incisor verified this position. This tooth can be easily removed by extracting the lateral incisor and thus you will have a direct line of extraction.

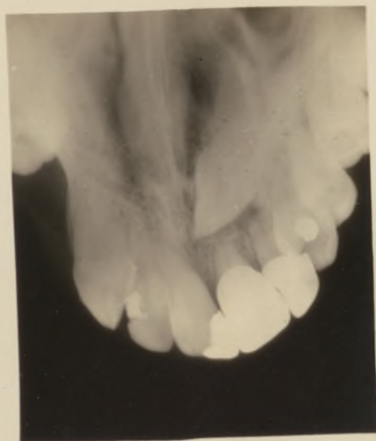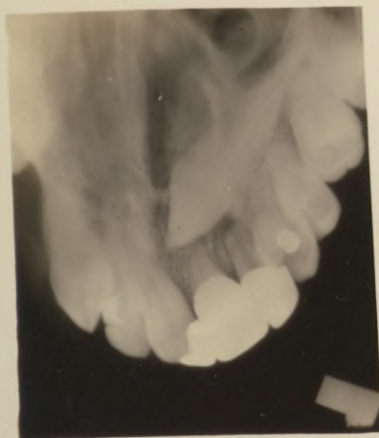Stereo 15.**Serial N^o 67**

Lingual Aspect View.

[Stereo 16.]

- ☐ Intraoral stereo.
- ☐ Lingual aspect view.

☐ Right maxillary cuspid; Its position from the flat roentgenogram may be described as being lingual to the central and lateral incisors, bicuspid and molars. The stereo shows it to be lingual to the central and lateral incisors, with its crown nearly on a level with the apices of these teeth making its position very high in the process. It is superior and slightly lingual to the bicuspid and superior to the molars with its apex apparently within the antrum. Due to the patient's condition it was necessary to extract this tooth. After studying its position by means of the stereo it was removed with but little destruction of the process, from the buccal palate, superior to the molars and bicuspid. Its position checked up very accurately to that

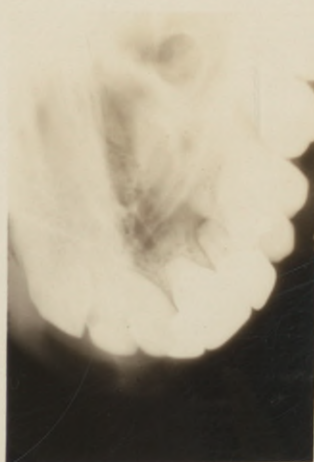
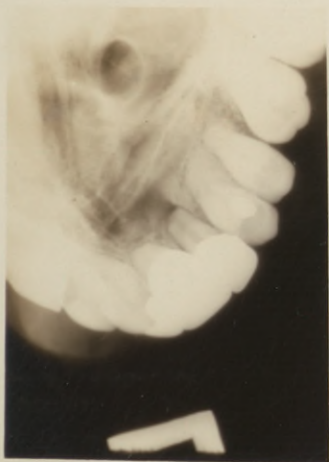Stereo 16.**Serial N^o 67**

shown by the stereo. Suppose that its extraction would have been attempted from the lingual surface by dissecting the hard palate until the tooth could be reached, certainly a great amount of the process would have been destroyed, which would probably have been the procedure if the flat roentgenogram had been followed. From its position as shown by the stereos it might have been taken out through the nasal cavity, but it appears that the procedure followed was a good one as ideal results were obtained.

Lingual Aspect View.

[Stereo 17.]

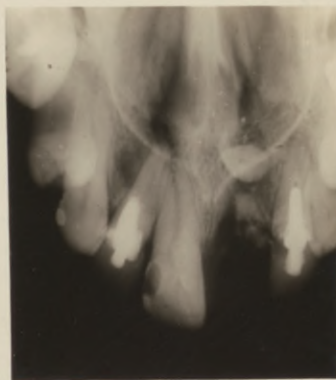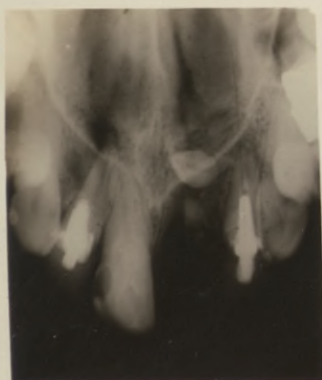- ☐ Intraoral stereo.
- ☐ Lingual aspect view.
- ☐ Same case as Stereo 16, shows case immediately after the right maxillary cuspid was removed.
- ☐ The vitality of the bicuspid was tested repeatedly and they tested as vital teeth, showing how thoroughly and efficiently the operation was performed.

Stereo 17.**Serial N^o 67**

Lingual Aspect View.

[Stereo 18.]

- ☐ Intraoral stereo.
- ☐ Lingual aspect view.
- ☐ Right maxillary central incisor; root remains in the process. A supernumerary tooth can be seen to lie superior and slightly lingual to the apex of this root. It can be removed through the socket left after extracting the root.
- ☐ Right lateral incisor; apex of root is considerably absorbed.
- ☐ Left lateral incisor; large apical and lateral granulomata.
- ☐ Note that the root of the lateral incisor is lingual to the root of the central incisor. Left central incisor appears to be involved in the granulomatous area of the lateral incisor.

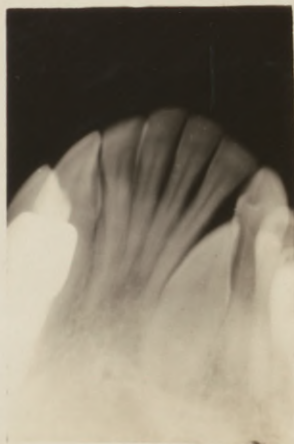
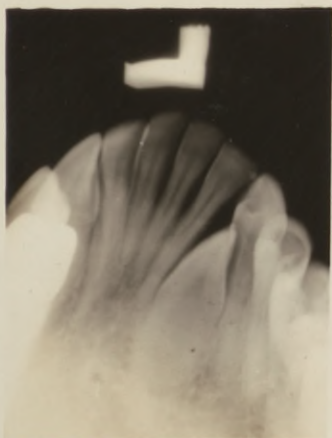Stereo 18.**Serial N^o 67**

Lingual Aspect View.

[Stereo 19.]

- ☐ Intraoral stereo.
- ☐ Lingual aspect view.
- ☐ Right mandibular cuspid; unerupted.
- ☐ Its position is slightly rotated so that its mesio-distal aspect is bucco-lingual. It is erupting buccal to the first bicuspid. Its line of eruption is clearly seen. This is particularly valuable to the Orthodontist to know whether the tooth is erupting buccal or lingual to the erupted teeth.
- ☐ You can state positively when viewed stereoscopically that it is buccal but from the flat roentgenogram one would hesitate to definitely state.

Stereo 19.

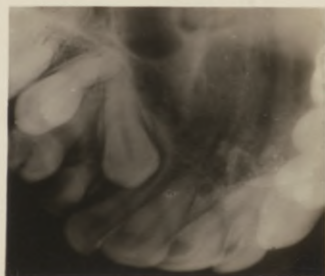
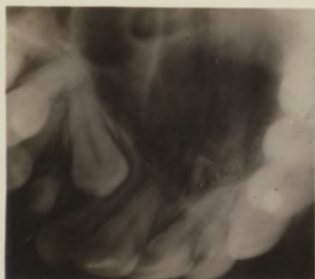
Serial N^o 67

Lingual Aspect View.

[Stereo 20.]

- ☞ Introral stereo.
- ☞ Lingual aspect view.

☞ Left maxillary cuspid; Its position when viewed stereoscopically may be described as follows: Crown is lingual to lateral incisor, is not in apposition to it, the root is buccal to apex of first bicuspid and superior and buccal to apex of second bicuspid. The cuspid is locked in between these teeth and unless carefully removed trouble will be experienced later with the bicuspid. This case is a beautiful example of the value of perspective to the Exodontist. This tooth was extracted without difficulty, and first bicuspid was extracted first, then cuspid. No injury was done to second bicuspid. It tested later as a normal, vital tooth.

Stereo 20.**Serial N^o 67**

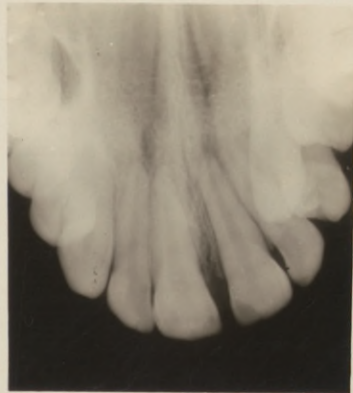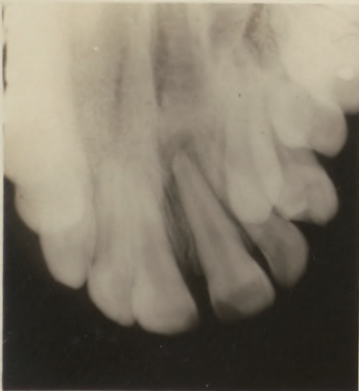Lingual Aspect View.

[Stereo 21.]

- ☐ Intraoral stereo.
- ☐ Lingual aspect view.
- ☐ Right maxillary cuspid; unerupted, showing its position to be decidedly labial to the lateral incisor and buccal to the first bicuspid.
- ☐ The root of the lateral incisor has been moved towards the lingual. Extraction of the cuspid is necessary.

Stereo 21.

Serial N^o 67



Lingual Aspect View.

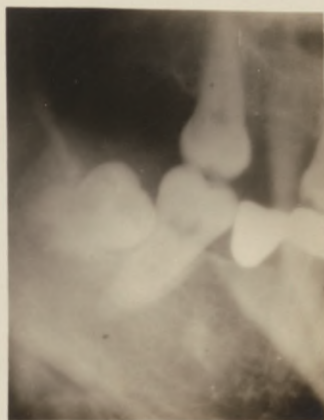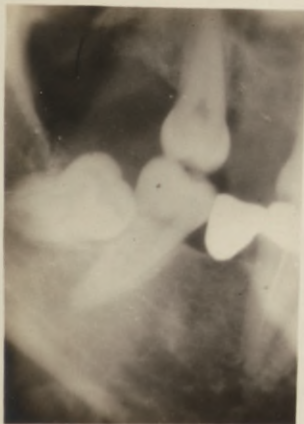
[Stereo 22.]

☐ Extraoral stereo.

☐ Lingual aspect view.

☐ Left mandibular third molar; It is not impacted but is erupting lingual to the second molar. It was extracted without the use of the elevator as it was not in apposition to the second molar, and by simply removing the soft tissue over the occlusal surface of the crown it was easily grasped with the forceps and removed with very little difficulty. This method surely aids the Exodontist in localizing the molar, which is the first step when extraction of such a tooth is contemplated.

Stereo 22.

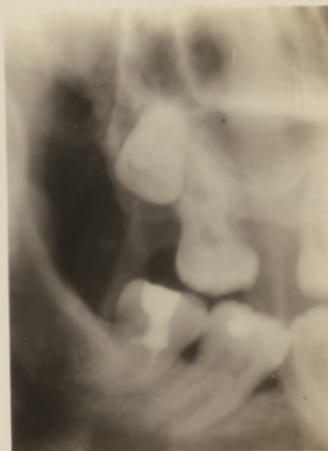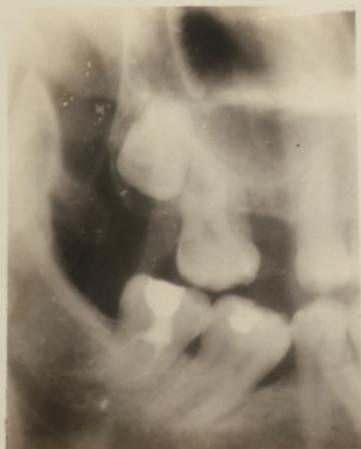Serial N^o 67

Lingual Aspect View.

[Stereo 23.]

- ☐ Extraoral stereo.
- ☐ Lingual aspect view.

☐ Left maxillary third molar; unerupted, erupting decidedly lingual to the second molar. Could this be definitely stated from the flat roentgenogram? You could not with definiteness state whether it is lingual or labial to the second molar. With the aid of the stereo it can be definitely stated that it is lingual. We thus eliminate guess work.

Stereo 23.**Serial N^o 67**

Buccal Aspect View.

[Stereo 24.]

☐ Extraoral stereo.

☐ Buccal aspect view.

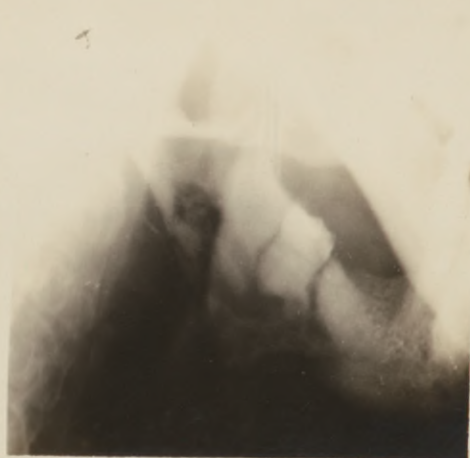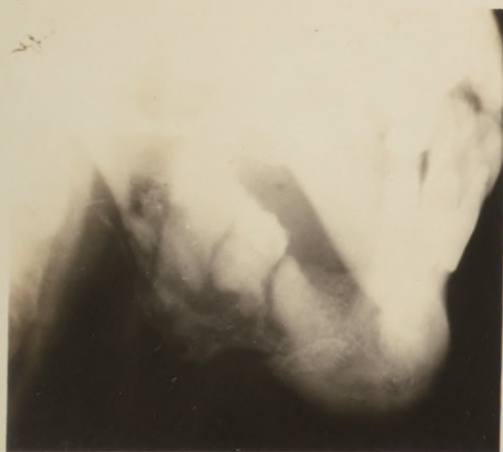☐ Left mandible; Advanced destruction of the mandible with partial destruction of the body and angle. The angle itself is partially destroyed, and a line of fracture can be noted running along the mesial side of the unerupted third molar; this is a pathological fracture without separation of the fragments which the stereo shows. Numerous sequestra are formed and a large one can be seen inferior to the roots of the third molar.

☐ The stereo is valuable in as much as it gives a comprehensive view of the condition as well as showing that there is no displacement of the fragments.

Stereo 24.

Serial N^o

67



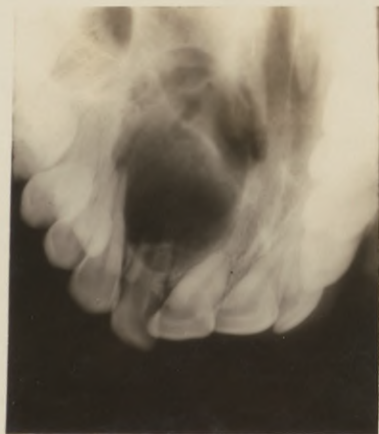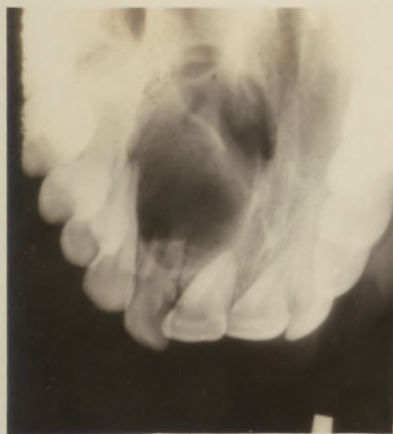Lingual Aspect View.


[Stereo 25.]

- ☐ Intraoral stereo.
- ☐ Lingual aspect view.
- ☐ A cyst involving the hard palate on the left side.
- ☐ The root of the left lateral incisor appears necrotic.

The left cuspid is involved and forms the distal wall of the cyst. The stereo shows that there is a communication with the nasal cavity; a valuable point due to the fact that the mucous lining of the nasal cavity and the periosteum was still in contact and if extensive curretment was performed in this area a puncture might have resulted with a drainage into the nose. Principle point of drainage was posterior to the lateral incisor. No evidence of a communication or involvement of the maxillary sinus can be noted.

☐ Without the stereo the depth of the destruction cannot be followed.

Stereo 25.**Serial N^o 67**



Handwritten signature in cursive script, possibly reading "J. G. L."

MAY 1 2 1976

