



WN 100 C555r 1924

45310340R



NLM 05231122 9

NATIONAL LIBRARY OF MEDICINE

h

SURGEON GENERAL'S OFFICE  
LIBRARY.

Section *Pathology*

No. 113,  
W. D. S. G. O.

No. 257623

8-513







# ROENTGEN DIAGNOSIS AND THERAPY

BY

*Christie*  
ARTHUR C. CHRISTIE, M. D., M. S., F. A. C. P.


PROFESSOR OF ROENTGENOLOGY, GEORGE WASHINGTON UNIVERSITY MEDICAL COLLEGE;  
ROENTGENOLOGIST TO THE GEORGE WASHINGTON UNIVERSITY HOSPITAL;  
COLONEL, MEDICAL OFFICERS' RESERVE CORPS, U. S. ARMY;  
FORMERLY CAPTAIN, MEDICAL CORPS, U. S. ARMY,  
AND PROFESSOR OF ROENTGENOLOGY AND  
OPERATIVE SURGERY, ARMY MEDICAL  
SCHOOL, WASHINGTON D.C.

WITH 144 ILLUSTRATIONS



PHILADELPHIA LONDON MONTREAL  
J. B. LIPPINCOTT COMPANY

*5 19247*





COPYRIGHT, 1913-1917, BY J. B. LIPPINCOTT COMPANY

COPYRIGHT, 1924, BY J. B. LIPPINCOTT COMPANY ✓

WN  
100  
C555r  
1924

PRINTED BY J. B. LIPPINCOTT COMPANY  
AT THE WASHINGTON SQUARE PRESS  
PHILADELPHIA, U. S. A.

DEC 17 1924 ✓

©C1A814248c R

no 2

To  
WILLIAM DAVID COOLIDGE  
IN RECOGNITION OF HIS INVALUABLE CONTRIBUTIONS  
TO THE SCIENCE AND ART OF ROENTGENOLOGY  
THIS BOOK IS RESPECTFULLY DEDICATED





## PREFACE

THIS book is a revision and enlargement of the author's Manual of X-ray Technic. Its object is to furnish to the student and practitioner a concise account of the essentials for the practice of roentgenology. The author's experience as a teacher, both of graduate and undergraduate students, has led him to believe that there is need in this country for such a book. The aim throughout has been to furnish a practical guide, and for that reason theoretical considerations have been for the most part omitted. A special effort has been made to present the facts so simply and in such order that the beginner will find it easy to acquire a knowledge of the essentials of roentgen technic, diagnosis and therapy.

The student of roentgenology must recognize the fact that he is dealing first with an art and that he can hope for success only by perfecting himself in the technic of that art. Good technical work is the very foundation of success in the practice of roentgenology. In addition to this, however, he must realize that this is a special branch of medical science whose data must be interpreted in the light of a broad general knowledge of medicine. He cannot place too great emphasis upon the importance of correlating all the information received through his roentgenological examination with the history, clinical course, and physical signs. This

necessitates not only broad medical training and experience but also a disposition on his part to coöperate to the fullest possible extent with his medical colleagues.

Although we have drawn freely upon the general literature of the subject, for the sake of simplicity specific references are given only when further reading is considered essential to a complete understanding of the matter under discussion.

I wish to acknowledge with grateful thanks the assistance of Dr. Fred O. Coe in the preparation of the chapters on Technic and of my colleague, Dr. Thomas A. Groover, who has written the section on Therapy.

THE AUTHOR.

# CONTENTS

CHAPTER	PAGE
I. ELECTRICITY AND MAGNETISM.....	1
II. THE ROENTGEN RAY. HISTORY AND PROPERTIES.....	8
III. ROENTGEN-RAY TUBES.....	13
IV. APPARATUS AND EQUIPMENT. THE INDUCTION COIL.....	26
V. APPARATUS AND EQUIPMENT. HIGH TENSION TRANSFORMERS ACCESSORY APPARATUS.....	35
VI. ROENTGENOGRAPHIC TECHNIC.....	47
VII. DARK ROOM TECHNIC.....	56
VIII. ROENTGENOSCOPY. LOCALIZATION OF FOREIGN BODIES.....	69
IX. DISEASES AND INJURIES OF BONES AND JOINTS.....	79
X. THE HEAD. NASAL ACCESSORY SINUSES. MASTOID DISEASE. BRAIN TUMORS.....	144
XI. THE CHEST. DISEASES OF THE LUNGS, HEART AND GREAT VESSELS, AND MEDIASTINUM.....	170
XII. THE GASTROINTESTINAL TRACT.....	206
XIII. THE URINARY SYSTEM.....	269
XIV. ROENTGENOTHERAPY. GENERAL CONSIDERATIONS.....	283
XV. ROENTGENOTHERAPY.....	302





# ROENTGEN DIAGNOSIS AND THERAPY

## CHAPTER I

### ELECTRICITY AND MAGNETISM

**NATURE AND PROPERTIES.**—The nature of electricity is known only by its effects. The word is derived from the Greek *elektron*, meaning amber, in which substance Thales, about 600 B. C. first noticed some of the phenomena of electricity. The word “electrics” was first applied by Dr. Gilbert about the year 1600 A. D. to certain substances like amber, sealing wax, etc., which become electrified by friction.

Electricity may be either static or dynamic.

Static electricity is electricity at rest; it is produced by some form of friction or “influence” machine.

Dynamic electricity may be faradic or galvanic.

Faradic electricity, named from Michael Faraday, is a derived (induced) form of electricity, in which there are rapid alternations of direction.

Galvanic electricity is that produced by the galvanic cell, which, in its simplest form, consists of a jar of dilute sulphuric acid in which are dipped a plate of zinc and one of copper (Fig. 1).

According to the theory of Arrhenius the affinity of the zinc for the acid radical  $\text{SO}_4$  starts a chemical reac-

tion which results in the determination of positive ions toward the copper and of negative ions, called electrons, toward the zinc. In consequence of this ionic movement an electrical current is produced from the zinc to the copper through the liquid, and outside of the cell from

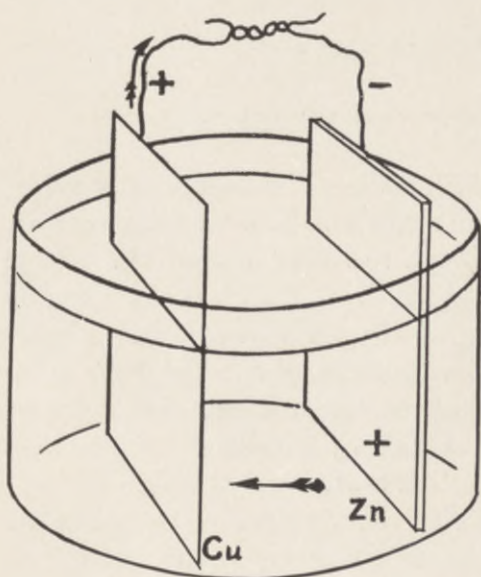


FIG. 1.—The galvanic cell.

the copper to the zinc through a connecting wire. *Electric generators* serve the same ultimate purpose as the galvanic cell, that is, to separate negative from positive ions and to cause them to travel in opposite directions. The idea of the electrical constitution of the atom is now accepted. The atom is made up of positive and negative particles

which may exist by themselves. The negative particles have received various names, among which are cathode rays, corpuscles, beta rays, electric ions and electrons.

**DIRECT CURRENT.**—Galvanic cells, storage batteries, static machines and direct current dynamos produce a current whose flow is in only one direction. Such a current is called a direct current, even though it may be intermittent or pulsating.



**ALTERNATING CURRENT.**—When the current flows for a short time in one direction and then for an equal length of time in the opposite direction, it is called alternating. There is a rise from zero to a maximum and then a fall again to zero when the current immediately flows in the opposite direction and again reaches zero, when the cycle is complete. A current which has 60 such cycles or 120 alternations per second is called a 60 cycle current. Practically the only source of alternating currents are a-c. dynamos.

**DEFINITIONS OF ELECTRICAL TERMS.**—The *ohm* is the unit of electrical resistance and is represented by the resistance of a column of mercury 106.3 cm. long and 14.4521 gm. in mass at 0° C.

The *ampere* is the unit of current strength and is that current which deposits silver at the rate of 0.001118 gm. per second. One milliampere equals 1/1000 ampere.

The *volt* is the unit of electrical pressure or electromotive force; it is that electromotive force which applied to one ohm produces one ampere. A kilovolt equals 1000 amperes.

The *coulomb* is the unit of quantity, being the quantity of electricity conveyed by one ampere in one second.

The *watt* is the unit of power. One ampere with a pressure of one volt produces one watt. One kilowatt equals 1000 watts.

These terms are analogous to certain hydraulic terms. The voltage or electromotive force corresponds to the head or pressure of water. Electrical resistance, the unit of which is the ohm, is analogous to the frictional

resistance to the flow of water in a pipe. The current strength, whose unit is the ampere, is represented by the rate of flow of the water through the pipe. The quantity of electricity per second (coulomb) corresponds to the amount of water delivered per second. In other words, if an electromotive force of one volt is working against a resistance of one ohm it produces a current of one ampere; which, flowing for one second, produces a coulomb of electricity.

**OHM'S LAW.**—Current strength in amperes is equal to the electromotive force in volts divided by the resistance in ohms. If  $C$  represents the current strength,  $E$  the electromotive force and  $R$  the resistance, then

$$C = \frac{E}{R} \text{ or } E = C \times R = \text{ or } R = \frac{E}{C}$$

It is evident from this that the current strength varies directly as the electromotive force and inversely as the resistance.

**KINDS OF ELECTRIFICATION.**—Electrification may be manifested by repulsion as well as by attraction, and is of two kinds, opposite in character, called positive and negative. Bodies similarly electrified repel each other and those oppositely electrified attract each other.

**CONDUCTION.**—Electrification by conduction is the process of charging a body by putting it in contact with an electrified body. The charge thus produced is of the same kind as that of the communicating body.

**INDUCTION.**—This is the process of electrifying a body by bringing it near to, but not in contact with, an electrified body. The charge thus produced is of the

opposite kind to that of the communicating body. A current of electricity in one of two wires placed near each other produces no effect in the second wire so long as the current flows steadily, but whenever the current is increased or decreased in strength a current is "induced" in the second wire. This current in the second wire depends upon the presence of a "field of force" which surrounds every electrically charged body. At the instant when the primary current begins or increases in strength a weak current in the opposite direction is generated in the secondary wire; at the instant when the primary current stops or decreases in strength a strong current in the same direction is generated in the secondary.

**MAGNETISM.**—Magnetism is the property by virtue of which a body attracts iron or steel, and which causes the iron or steel when suspended to take a position pointing approximately north and south.

A magnet may be a natural one, as lodestone, or an artificial one. Artificial magnets are either permanent or temporary.

The ends of a magnet are called the poles. The end which points to the north when the magnet is freely suspended is the north, marked, or + pole; while that which points to the south is the south, unmarked, or - pole.

**MAGNETIC FIELD.**—When a bar magnet is placed beneath a sheet of paper on which are some iron filings, the filings will arrange themselves in lines radiating from each pole of the magnet as shown in Figure 2. The area surrounding any magnetic body is called a magnetic



field; it is the space through which the magnetic force acts. The lines of force are supposed to flow from the north to the south pole outside of the magnet and in the opposite direction inside, making a complete circuit.

**ELECTROMAGNETISM.**—It can be shown experimentally that an electric current has magnetic prop-

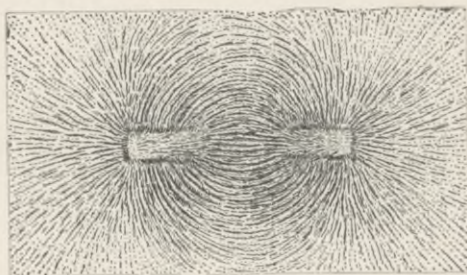


FIG. 2.—Action of bar magnet on iron filings.

erties; it will deflect the magnetic needle and will cause iron filings to arrange themselves as they do when placed in the field of a magnet.

A coil of wire through which a current is passing is called a solenoid and has all the properties of a magnet (Fig. 3). An electromagnet is a bar of iron magnetized by an electric current passing through a coil of wire surrounding it (Fig. 4).

The strength of an electromagnet is directly proportional to the strength of the current passing through the wire surrounding it, and to the number of turns of the wire. Since electric currents may be made very strong and since we may use as many turns of wire as desired, it becomes possible to make electromagnets of enormous strength.



Just as a current may be induced in one of two wires lying near each other by increasing or decreasing the strength of the current in the other wire, in the same

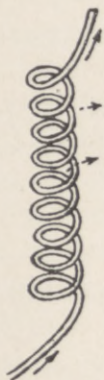


FIG. 3.—Solenoid.

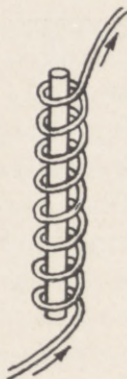


FIG. 4.—Electromagnet.

manner a current may be induced in a coil of wire surrounding an electromagnet but insulated from it. Upon this fact depends the action of induction coils, transformers, and motor generators, all of which are used in *x*-ray work.

## CHAPTER II

### THE ROENTGEN RAY. HISTORY AND PROPERTIES

**HISTORY.**—The first vacuum tubes were made by Geissler about the year 1858. The passage of an electric current through these tubes, which were of low vacuum, caused a faint glow, varying in intensity with the degree of vacuum. Hittorf discovered about 1860 that the stream of discharge in a Geissler tube could be deflected by a magnet. It was in 1879 that Sir William Crookes, experimenting with tubes of very high vacuum, discovered the cathode rays. The glow which is present in the tubes of low vacuum has disappeared in these high-vacuum tubes and is replaced by a greenish fluorescence of the walls of the tube. To this form of “radiant energy” Crookes gave the name *cathode rays*.

The study of the discharge in high-vacuum tubes was continued by many investigators, prominent among whom were Professor Hertz and his assistant Professor Lenard. In 1894 Lenard proved that the rays produced in high-vacuum tubes caused phenomena outside of the tube. Experimenting with a tube having a sheet of aluminum in the end opposite to the cathode he observed that radiation passed through the aluminum and caused fluorescence in such substances as platinum-barium cyanide. The next year, 1895, Professor William Conrad Roentgen at Würzburg, was experimenting with a high-vacuum tube covered with black paper

impervious to ordinary light. He noticed that a nearby paper covered with platinobarium cyanide fluoresced brilliantly while the tube was in action. Roentgen realized that this phenomenon must be caused by some hitherto unrecognized force, differing essentially from the cathode rays. Continuing his experiments Roentgen found that he could obtain shadow pictures on photographic plates of metallic objects in a box which was impervious to light, and also of the bones of the hand. He soon made his discovery public and it was only a short time until the use of the rays became general for diagnosis, and not long until valuable therapeutic effects also were observed.

**ELECTRONS.**—It is now known that the so-called cathode rays are streams of electrified particles which are shot off from the cathode when a high voltage current is passed through a tube of high vacuum. They are simply electrons which have been freed from their atoms and set in motion. They have the following properties: (1) They travel at very high speed, which varies somewhat with the voltage applied to the tube but which is approximately 60,000 miles a second; (2) they travel in straight lines; (3) they have a constant and fixed negative electric charge which they never lose; (4) they have a definite mass which they never lose; (5) they can be deflected from their course by a magnet or by an electric field; (6) they cause fluorescence of certain substances, notably the glass of the vacuum tube in which they are formed.

**RELATION OF ELECTRONS TO ROENTGEN RAYS.**—In a perfect vacuum no current can pass.



Electrons must be present in the tube to carry the current across the vacuum. In "gas" tubes electrons are furnished by the breaking down of the atoms of the gas, and in Coolidge tubes by liberating them from the metal of the cathode by heating the latter. The mere presence of electrons in the tube is not sufficient, however, to produce X-rays. It is necessary that they be put in rapid motion. This is accomplished by the force of the high tension current applied to the tube.

Whenever electrons travelling at high speed in a vacuum tube are suddenly stopped, roentgen rays or X-rays are produced. The two latter terms are synonymous. The sudden stopping of motion is accomplished in modern roentgen tubes by placing a metal target in such a position that the stream of electrons will strike upon it. The roentgen rays are produced at the point of impact and are of an entirely different nature from the cathode rays which produce them. Roentgen rays are analogous to light rays and have the following properties: (1) They are not deflected by a magnet; (2) they are invisible, but cause fluorescence and phosphorescence of certain substances; (3) they affect photographic emulsions like ordinary light; (4) they travel in straight lines, that is, they cannot be reflected or refracted, if we except the slight reflection that takes place when the roentgen ray is passed through crystals; (5) they pass through all known substances with varying degrees of intensity; (6) they cause gases to become conductors of electricity, or in other words they cause the ionization of gases; (7) they have marked effects on living tissue.



**Wave-length of the Roentgen Ray.**—It is now known that roentgen rays are identical in their nature with light except that the wave-lengths of the former are much shorter than those of the latter. The roentgen rays, in fact, occupy a place in a continuous spectrum of electro-magnetic waves, at one end of which are the Hertzian waves, which vary in wave-length from a few millimeters to 25,000 meters, and at the other end the gamma rays of radium which are the shortest waves known. The spectrum is continuous from the Hertzian waves through the infra-red rays, the visible light rays, the ultra-violet rays, and the roentgen rays, to the gamma rays of radium. The roentgen-ray beam, however, is not made up of rays which are all of the same wave-length, some are much shorter than others. The passage of the rays through any substance is directly proportional to the shortness of the wave-length, that is, the shorter the wave-length the more readily they pass through matter. Short wave-lengths are produced only by applying high voltage to the roentgen-ray tube. The higher the voltage, the shorter the wave-length and consequently the greater the penetration of the ray. In passing through matter three things happen to the roentgen beam—some are scattered, some are absorbed and some pass through. Some of the waves are scattered as light is scattered in passing through fog. This scattering renders the shadows made on the photographic plate less distinct than they would be otherwise. The Potter-Bucky diaphragm which will be described in another chapter has been devised to eliminate the evil results of scattering upon the roentgen

picture and the screen image. Some of the waves are absorbed in their passage through matter, the degree of absorption being directly proportional to the density of the material. The remainder of the beam that is neither scattered nor absorbed passes straight through.

The factors necessary for the production of roentgen rays are (1) Some means of obtaining a supply of electrons in a suitable vacuum; (2) a current applied to the roentgen tube of sufficiently high voltage to give the electrons high speed; (3) some means of suddenly stopping the stream of electrons.

The apparatus essential for the accomplishment of these results consists of suitable vacuum tubes and of apparatus for the production of electric currents of high voltage.

## CHAPTER III

### ROENTGEN-RAY TUBES

THE earliest forms of vacuum tubes were the Geissler tubes. These are of low vacuum and transmit electric currents more readily than air. During such passage the tube lights up with a soft luminous glow. As the tube is still further exhausted the current passes with difficulty and the increasing luminous glow is replaced by a greenish fluorescence of the walls of the tube. When it reaches this degree of vacuum it is known as a Crookes tube and in it are produced the cathode rays.

The first roentgen-ray tubes were somewhat conical in shape, the cathode, which was a flat disc, being placed in the small end (Fig. 5). The cathode rays were thus thrown upon the opposite end of the tube, the anode being ring-shaped so as not to obstruct the passage of the rays.

A great advance was made when Herbert Jackson devised a tube with a metallic target fixed within it, at or near the focus point of the cathode stream (Fig. 6). This "focus" tube has undergone many modifications, the most important of which was the addition of an accessory anode and of a device to regulate the vacuum.

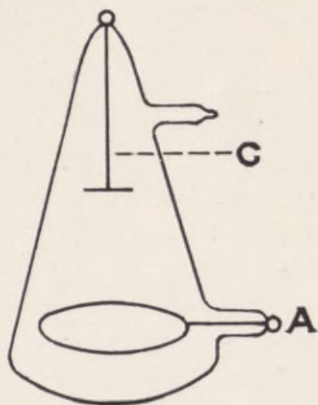


FIG. 5.—Early type of roentgen-ray tube.



A late model roentgen tube is one in which the air has been exhausted by means of mercury pumps to about one-millionth of an atmosphere. The essential parts of the tube are the cathode, the anti-cathode or target, the accessory anode, and some device to regulate the vacuum (Fig. 7).

The cathode of a focus tube is made of aluminum, because this metal does not suffer disintegration with

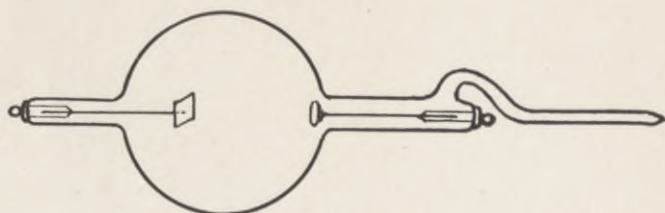


FIG. 6.—Jackson's focus tube.

consequent discoloration of the walls of the tube. The concave form of the cathode causes the cathode rays to be focused upon a point on the target, or anti-cathode, called the focus spot.

In modern tubes the target is an anode of the tube, but it is not necessarily so. Since a high degree of heat is generated at the focus spot the target must be made of a metal which has a high melting point. If the metal is heated to such a degree that it melts the face of the target, the area about the focus spot soon becomes a deep crater; and if the heat is still higher, the metal vaporizes and is deposited upon the walls of the tube. Either of these occurrences interferes with the efficiency of the tube. Formerly platinum, which has a melting point of  $1750^{\circ}$  C., was generally used; but even platinum



is not infusible and often melts under the intense heat generated. Iridium and osmium have been used to some extent but tungsten, with a fusing point of  $3300^{\circ}$  C., has now replaced all other metals. The tungsten disc is set in a solid block of copper which is a good con-

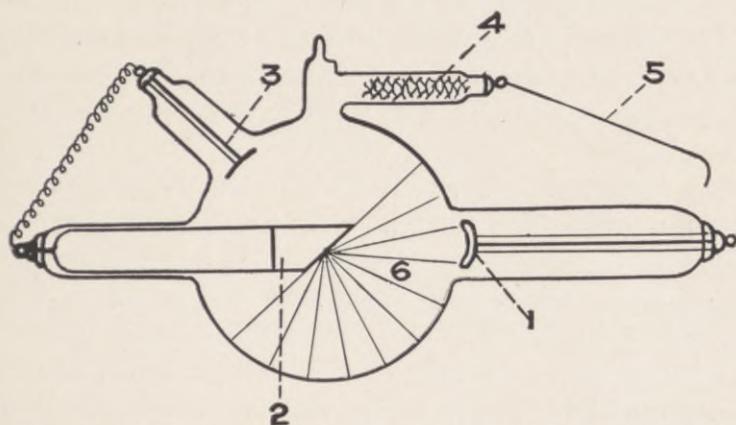


FIG. 7.—Modern type of roentgen-ray or focus tube. 1, cathode; 2, target; 3, accessory anode; 4, vacuum regulator; 5, adjustable wire; 6, X-ray hemisphere.

ductor of heat and as an additional precaution against fusing, the target is placed at a point just beyond the mathematical focus of the electronic stream. Water-cooled tubes are also used successfully. In such tubes water flows through the hollow anti-cathode and comes into direct contact with the target. Another means of cooling the target is by the use of a metal radiator attached to the anti-cathode, outside of the tube. The radiator type of Coolidge tube, to be described later, makes use of this method. The amount of heat generated at the focus point on the target also depends somewhat upon the size of the focus point.

In a "fine-focus" tube, that is, one in which the cathode stream is focused on a very small area, fusing takes place with the application of less energy than is the case with a tube of medium or broad focus. In the latter cases the heat is spread over a larger area.

The accessory anode is made of aluminum. It is connected to the anti-cathode by a wire outside of the tube. Tubes furnished with an accessory anode do not seem to increase in resistance so rapidly as do those of older models.

REGULATING THE VACUUM IN THE ROENTGEN TUBE.—The tendency of the roentgen tube to increase in resistance, that is, to become higher in vacuum, making it increasingly difficult for the current to pass through it, has caused the introduction of many contrivances for lowering the vacuum when it has become too high. One of these was the osmo-regulator of Villard, now obsolete. It consisted of a platinum pin sealed into the tube with one end projecting outside. Heating the projecting end with a flame caused the platinum to become porous and to absorb hydrogen, thus lowering the vacuum of the tube. The same principle was made use of in the palladium tube in which palladium was used instead of platinum.

Baking a tube in an oven at 200° to 300° F. for several hours will also lower the vacuum.

In 1896 Queen's self-regulating tube came into use (Fig. 8). This tube had a relatively large accessory bulb B in which was sealed a smaller bulb *b*, the latter containing some chemical such as potassium chlorate. The smaller bulb connected directly with the main bulb.

When the vacuum in the main bulb was too high the current could no longer pass directly through the tube but sparked across the path of less resistance from the cathode C to the end of the adjustable wire W, causing the potassium chlorate in the small bulb to become heated. The vapor given off into the tube from the potassium chlorate lowered the vacuum in the main

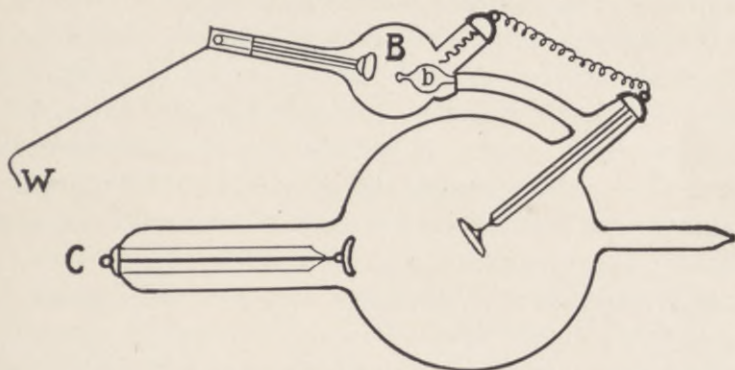


FIG. 8.—Queen's self-regulating tube.

bulb until the current could pass directly through, when the sparking from the cathode to the adjustable wire ceased.

The regulating device most largely used at present is one in which the accessory tube connects directly with the main bulb (Fig. 7). Asbestos is the substance ordinarily used instead of the chemical of the old Queen's tube. When the current sparks across from the cathode to the adjustable wire, air is forced out of the interstices of the asbestos and the vacuum consequently lowered. Instead of using the adjustable wire on the tube the regulating device may be connected by a third



wire to an adjustable spark-gap on the coil or transformer. This is the most convenient method since it enables the operator to regulate the vacuum from a distance.

When new tubes are ordered it is necessary to specify whether they are to be used with a coil or a transformer, since tubes pumped for use with a coil are of too high vacuum for use with a transformer.

When a new tube is received it is usually found to be of relatively low vacuum, but after being used a few times it reaches its point of maximum usefulness. The vacuum then seems to remain about stationary for some time and then gradually increases until it reaches a point where it must be lowered every time it is used. Finally the vacuum becomes so high that it can no longer be lowered sufficiently to allow the current to pass.

**Directions for Regulating the Vacuum.**—If the current cannot pass through the tube on account of the high vacuum it sparks across between the positive and negative terminals of the coil or transformer. An adjustable spark-gap is provided so that the operator may measure the length of the spark. The length of spark that a tube will “back up” is a measure of the resistance of that tube.

If the tube is too high to allow the current to pass when the latter is at its full strength, the end of the adjustable wire should be placed at a distance of about two inches from the cathode (never touching it) and the weakest current possible allowed to spark across to the regulator. The wire is then moved to a distance of five

or six inches from the cathode and the current turned on to its full strength. This process is repeated until the tube lights up properly and there is no sparking at the parallel spark-gap. The same method is followed when the adjustable regulating spark-gap on the apparatus is used instead of the adjustable wire on the tube. Great care must be exercised in this matter of lowering the vacuum of a tube for it is exceedingly easy to lower it to such an extent as to render it valueless until it is repumped. If a strong current is used for regulating, it will cause a thick yellow spark to jump across and probably destroy the vacuum.

To increase the vacuum of a tube a weak current may be run through it in a reverse direction for several times. If this is done every day for considerable time the tube becomes higher. A tube will also increase in resistance by constant use. The best and quickest way, however, to increase the vacuum of a tube which is *soft* is to send it back to the manufacturer to be repumped.

A roentgen tube is said to be *soft* when the vacuum is low, and *hard* when it is high. The penetrative power of the roentgen rays increases with the degree of vacuum and with the strength of the current.

When working well the tube shows a well-marked hemisphere of greenish fluorescence in front of the target, while the part of the tube behind the target is dark.

**THE COOLIDGE TUBE** (Fig. 9).—This tube was invented by Dr. W. D. Coolidge, of Schenectady, N. Y., and constitutes a remarkable advance in roentgen apparatus. It differs fundamentally from the older type of tubes. In the latter the stream of electrons is pro-

duced by the bombardment of the cathode with positive ions which are produced by the passage of the electric current through the gas contained in the tube. The Coolidge tube is pumped to a much higher degree of vacuum than the gas tubes, so high in fact that no current will pass through it unless the cathode is heated. The electrons constituting the cathode stream are thrown out by the heated cathode instead of being pro-

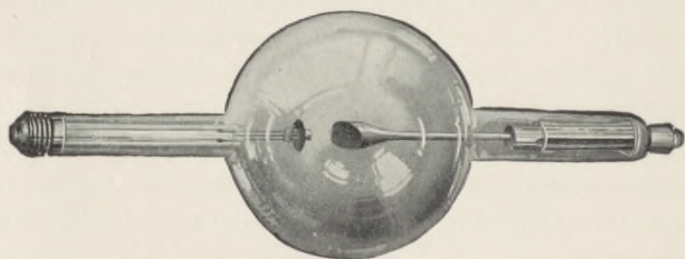


FIG. 9.—The Coolidge tube.

duced by bombardment of the cathode with positive ions. In order to secure a pure electron discharge from the heated cathode it is, of course, necessary to completely exhaust the tube itself and also to entirely free the electrodes from gas. It was known that the rate of emission of electrons from a hot cathode in very high vacuum increases as the temperature of the cathode rises.

The Coolidge tube differs from the ordinary tube in the following particulars:

- (1) The vacuum is as high as it is possible to make it.
- (2) The cathode consists of a cylindrical tube of molybdenum, 6.3 mm. inside diameter. This is supported on two molybdenum wires which are sealed into



the end of the glass tube. This molybdenum ring acts as a focusing device. Inside of the ring is a closely wound spiral of very fine tungsten filament mounted so as to be concentric with the ring. The spiral is welded to two wires which pass out at the negative end of the tube. Through these two wires passes a low voltage current which serves to heat the tungsten filament, the degree to which it is heated being controlled by an adjustable rheostat. The source of the current for heating the filament may be a small storage battery, or the 110 V. alternating current reduced to the proper voltage by a suitable transformer. When only the direct current is available a small motor generator is necessary in addition to the transformer. Whether a storage battery or transformer is used it must be insulated from the ground, since it is connected with the high potential current.

(3) The target, instead of being a platinum- or tungsten-faced copper block, is a solid block of tungsten. The target functions as anode, and there is no accessory anode.

**Radiator Type of Coolidge Tube (Fig. 10).**—The ordinary form of Coolidge tube, described above, requires a unidirectional current, since the target must always be the positive and the cathode the negative terminal of the tube. If the alternating current were applied to the tube without rendering it unidirectional (rectification) the target would be the negative end of the tube during every other alternation. While the target is thus acting as the cathode, electrons are formed upon it and are shot off to form roentgen rays in other parts of the tube,

greatly interfering with its efficiency. A rectifying apparatus operated by a motor must therefore be used to render the current unidirectional when the ordinary form of Coolidge tube is used. It will be remembered,




FIG. 10.—Radiator type of Coolidge tube.

however, that electrons are formed at the cathode of a Coolidge tube only when the cathode is heated. This is true also of the target so that when an unrectified current is passed through the tubes, one wave of the current will be suppressed as long as the target is cool, that is, the tube will itself rectify the current. The radiator tube is so constructed that the target remains cool for

relatively long exposures and the tube is therefore "self-rectifying." The target is a tungsten disc set in a heavy copper block which is continuous with a copper rod extending out of the neck of the tube. On the extension is placed a radiator constructed of several metal discs. Such tubes are now designed to take 30 ma. for heavy roentgenographic work, 10 ma. for lighter work, and 5 ma. for roentgenoscopic work, all to operate at not to exceed a 5-in. gap. Operated within these limits these tubes suppress each alternate half wave of the alternating current and may be operated directly from the high tension transformer without the use of any cumbersome rectifying device.

**Advantages of the Coolidge Tube.**—The great advantage of the Coolidge tube over the older type consists largely in the ability to regulate the penetration of the former by varying the temperature of the cathode. This is of value both in roentgenography and roentgenotherapy, since results may be practically duplicated on different occasions. Another great advantage in roentgenotherapy is the fact that the Coolidge tube can be used for practically any length of time. With the gas tube it is necessary either to have a water-cooled target or to make frequent changes of tubes as they become heated.

There has been considerable objection to the use of the Coolidge tube for roentgenography and roentgenoscopy, good detail being somewhat lessened by the rays from points on the target other than the focus point. Many of the best roentgenologists use the Coolidge tube for roentgenotherapy and gas tubes for all other work. The durability and ease of control of the Coolidge tube



make it desirable to use it for all purposes, and many have found that very satisfactory practical results can be obtained in roentgenography if care is taken to regulate the tube so that it never has a greater resistance than is necessary to enable the ray to penetrate the particular part being roentgenographed. For instance, it has been found that practically all stomach work can be done with a maximum spark-gap of 5 in. and 30 ma. of current, the spark-gap being decreased to  $3\frac{1}{2}$  or 4 in. with thin patients. Good bone detail can be obtained with the Coolidge tube by using a short spark-gap and about 20 to 25 ma. of current, and a relatively long exposure. The author uses the Coolidge tube for all purposes, including roentgenography and roentgenoscopy.

**Care of the Roentgen Tube.**—Certain precautions are necessary to keep roentgen-ray tubes at the point of their maximum efficiency for the longest possible time. In cold weather the tube should be warmed before use. Very sudden cooling of a hot tube is to be avoided. The high tension wires leading to the tube should not come in contact with the walls of the tube or even in close proximity to them when the tube is in action, since a spark may jump across to the glass and cause puncture. Keep tubes perfectly clean; a small particle of dust on the glass may attract the high tension current and cause puncture. New tubes are likely to be rather unstable in vacuum and should be used cautiously with weak currents, and with very short exposures with strong currents, until they become seasoned. Avoid overheating the tube by too long or too frequent use. Always be

sure that the Coolidge filament is lighted before the high tension current is turned on.

**Blackening of the Roentgen Tube.**—The blackening of the tube observed after continued use is due to “sputtering” or disintegration of the cathode and also of the target when there is inverse current. By “sputtering” is meant the breaking off and projection of small particles of metal. Another cause of the blackening is the actual volatilization of the metal of the target when it becomes very hot. To prevent blackening care should be taken not to run the tube so long or with such heavy currents that overheating occurs.

## CHAPTER IV

### APPARATUS AND EQUIPMENT

#### THE INDUCTION COIL

THE apparatus used to excite roentgen-ray tubes may be a static machine, an induction coil, or a high potential transformer.

The static machine is now little used in roentgenology. It gives a very uniform discharge at exceedingly high voltage, but the amperage is so low as to necessitate unduly long exposures.

**THE INDUCTION COIL.**—The induction coil is now used in roentgenology only to a very limited extent in this country, but it is thought advisable to give a brief description of it and of the accessories necessary for its use.

An induction coil consists of a core of soft iron wire upon which is wound a primary coil of coarse wire. Upon the primary coil, carefully insulated from it, is wound the secondary coil. The latter is made up of very many turns of fine wire, while the primary consists of relatively few turns of coarse wire. A current is passed through the primary winding and magnetizes the iron core, thus setting up a strong magnetic field through and around the secondary winding. The current in the primary is made to vary rapidly in strength by means of some form of interrupter, thus producing rapid changes in the intensity of the magnetic field. This reacts upon the windings of the secondary and



induces an electromotive force in each turn of the wire. At each make of the current in the primary coil a weak current flowing in the opposite direction is set up in the secondary; while at each break in the current there is induced in the secondary a strong current flowing in the same direction. This break current is the one used to excite the roentgen-ray tube. If the make current is allowed to pass into the tube, "inverse rays" are produced and the efficiency of the roentgen ray is greatly reduced.

**INVERSE CURRENTS.**—A tube in which the inverse current plays a part does not have the clear-cut hemi-




FIG. 11.—The oscilloscope.

spheres of a properly working tube, but will have one or more green rings back of the target.

The production of inverse currents can also be demonstrated by means of the oscilloscope (Fig. 11). When connected in series with a coil, if the current is unidirectional, a violet band will be seen at the negative end; while if there are inverse currents, bands of equal or unequal length will be seen at both ends.

Inverse currents may be prevented from entering the tube by introducing a spark-gap of such length that the make current is too weak to pass it.

Another method is to use the ventril or valve tube of Villard (Fig. 12). One pole of the Villard tube is made

of a spiral of aluminum giving a large surface. This pole acts well as a cathode and permits currents to pass readily when it is the negative pole.

As stated above, the secondary of the induction coil consists of many windings of very fine wire, sometimes ten miles or more in length. It is usually wound in sections and these subsequently assembled. All the

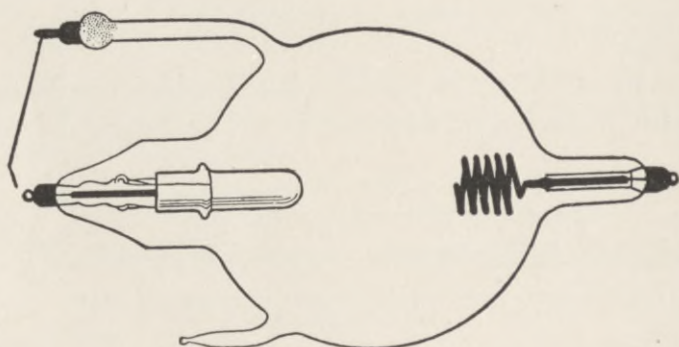


FIG. 12.—Valve tube.

layers of the coil must be thoroughly insulated, each from the other.

The effect of the induction coil is to change a current of relatively low potential (110 volts) and high amperage (5–25) to a current of very high potential (100,000 to 150,000 volts) but of correspondingly low amperage.

**THE INTERRUPTER.**—Some means of interrupting the current must be supplied with the induction coil, for it is only by varying the number of lines of force surrounding the primary winding that a current can be set up in the secondary.

Interruption may be classified as follows:

(1) MECHANICAL.

(a) *Vibrating*. This is the slowest.

(b) *Mercury*. Medium rate.

1. Dipper.

2. Rotary.

3. Jet.

(2) ELECTROLYTIC. Most rapid and therefore gives the strongest current.

1. *Wehnelt*.

2. *Caldwell-Simon*.

VIBRATING INTERRUPTER.—This interrupter operates on the same principle as the electric bell, and consists essentially of a spring carrying at its end a platinum contact point and an armature of soft iron. The armature is close to the end of the induction coil. The instant a current flows through the primary of the coil the core becomes magnetized, and acting upon the armature of soft iron pulls the platinum contact point away from its contact with the general circuit. When this happens the circuit is of course broken and the core becomes demagnetized. The armature is no longer held against the core and the spring carries the platinum contact point back to its contact with the main circuit.

There are many modifications of the vibrating interrupter and in some form or other it has been very widely used with roentgen-ray apparatus, but there are many objectionable features to all of them. The platinum points may become uneven or may fuse, the spring may break, and they are very noisy. They are still used with portable apparatus but practically never with stationary installations. It is quite certain also that



the portable apparatus of the future will be some form of high potential transformer actuated by a gas engine, with which an interrupter is unnecessary.

**MERCURY INTERRUPTERS.**—These give a medium rate of make and break and medium strength of current.

**Dipper Mercury Interrupter.**—The contacts are made by a metallic rod dipping into the mercury. The mercury should be covered with a layer of some non-conducting substance such as paraffin or alcohol so as to effectually prevent sparking. The shaft raising and lowering the metallic rod is operated by a motor connected with a shunt circuit.

**Rotary Mercury Interrupter.**—This consists of a turbine attached to a shaft which is rotated by a motor. There are platinum tips on the turbine and the interruptions are made by these entering and leaving the mercury.

The rate of interruptions with both of these interrupters is regulated by varying the speed of the motor.

**Jet Mercury Interrupters.**—A motor operates a pump which throws jets of mercury in opposite directions. These jets striking the armatures produce the contacts. By raising or lowering the armatures the strength of the current may be increased or decreased.

**ELECTROLYTIC INTERRUPTERS.**—These interrupters depend upon the fact that when a current of electricity is passed through a liquid and one of the metallic electrodes is very small the surface of this electrode becomes covered with a thin layer of gas which stops the flow of the current. As soon as the current stops the gas disappears and the current again

flows. These interrupters give as high as 40,000 breaks per minute.

The Wehnelt Interrupter (Fig. 13).—The fluid in this

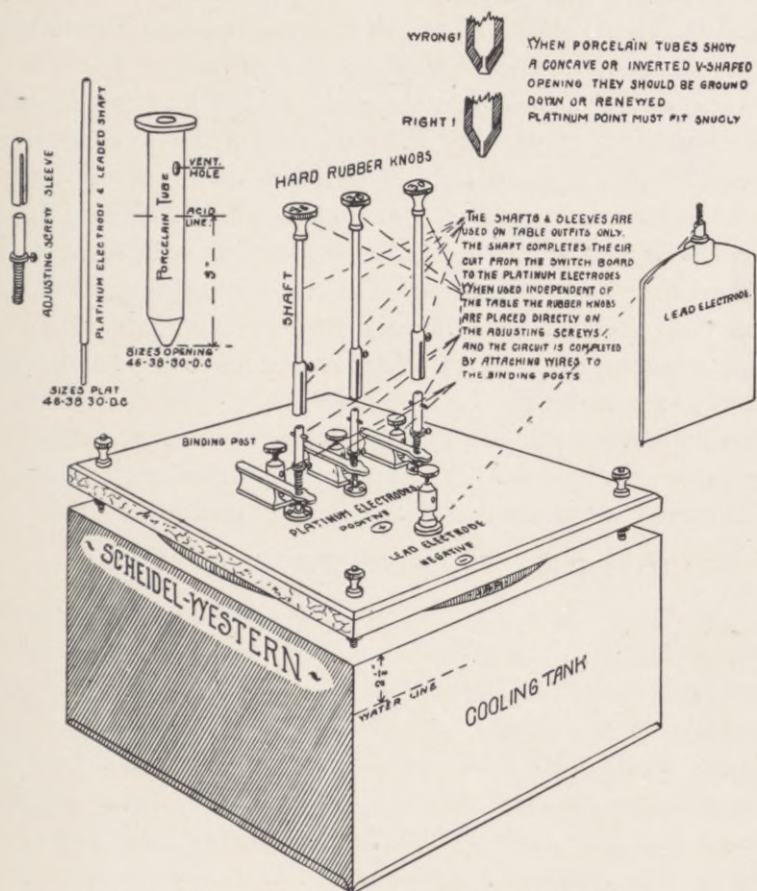


FIG. 13.—The Wehnelt electrolytic interrupter.

interrupter is sulphuric acid diluted with six times as much water. The small electrode is of platinum, and the

large one of lead. The platinum rod is enclosed in a porcelain sheath and by means of a screw a smaller or larger amount of the platinum may be made to project into the liquid. When a small amount projects the impulses are small and rapid, and when a larger amount projects they are heavier and less rapid.

**The Caldwell-Simon Interrupter.**—This has two large lead electrodes dipping into dilute sulphuric acid, the vessel containing which is divided into halves by a vertical partition. There are very small holes in this partition and when the current passes small bubbles of vapor are formed in them. This causes the break in the current. In this form of interrupter either pole may be the positive, while in the Wehnelt the platinum rod must always form the positive pole.

The electrolytic interrupter is the best for roentgenographic work, while a mercury interrupter is better for roentgenoscopy and for roentgenotherapy.

#### SOURCES OF CURRENT FOR OPERATING AN INDUCTION COIL

(1) **ELECTRIC BATTERIES.**—All forms of batteries are objectionable because of the corrosive solutions they contain, and because of their rapid deterioration. They are practically never used in X-ray work.

(2) **STORAGE BATTERIES.**—The storage battery of an electric automobile will operate a coil and interrupter. Small portable storage batteries may also be used. The greatest objections to the use of storage batteries for portable apparatus are their great weight and the difficulties of getting them charged. The latter is now accomplished in the military service by using a



generator connected with the motor of an automobile or with a small portable gas engine.

(3) **ELECTRIC LIGHTING AND POWER CIRCUITS.**—The 110 or 220 volt lighting circuit with direct current is the best available source of power for a roentgen-ray coil. The alternating current of the same voltage is also often used, but requires additional apparatus to render it unidirectional. This is described below. Another available source of energy is the 500-volt-power circuit.

**Use of Coil with Alternating Current.**—When only an alternating current can be obtained to operate a coil some means must be used to render it unidirectional. It is possible to use the Wehnelt interrupter for this purpose, but the platinum pole being the negative during one phase of the current gives it an undesirable polarity and causes its rapid destruction.

The aluminum cell rectifier is the device usually employed to rectify alternating currents for use with roentgen-ray coils. This rectifier transmits about 90 per cent of the current passing in one direction and almost none of that passing in the other. The rectifier consists of four glass jars containing a solution of Rochelle salts (one part water to one part saturated solution of Rochelle salts). Each jar contains a lead and an aluminum plate. The alternating current wires are connected as shown in Figure 14. The wire which delivers the positive current is connected to the aluminum of two cells and the negative wire comes from the lead of the other two cells. The current flows readily so long as it is passing from the lead through the solution to the

aluminum; but not in the opposite direction, polarization preventing the flow in one direction while offering little obstruction to its passage in the other.

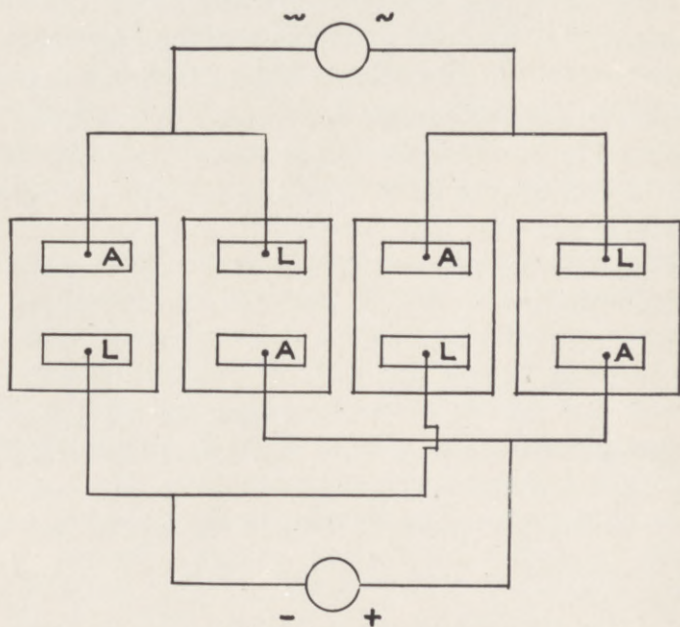


FIG. 14.—Aluminum cell rectifier.

There are other forms of rectifiers for the alternating current, such as the mercury arc and mercury vapor vacuum tube rectifiers, but the one described above is the most commonly used.

The loss of power is so great with an alternating current that the direct current is always used to operate a coil if it can be obtained.

## CHAPTER V

### APPARATUS AND EQUIPMENT. HIGH TENSION TRANSFORMERS. ACCESSORY APPARATUS

**HIGH TENSION TRANSFORMERS.**—The necessity for using some form of interrupter, and also a rectifier in the case of alternating currents, both containing some liquid, are disadvantages always encountered with coil apparatus. Even with the use of these appliances inverse currents often persist and cause rapid deterioration of tubes besides making it difficult or impossible to obtain good pictures. For these reasons and because of its added efficiency, the type of apparatus known as a transformer is at present the most satisfactory for exciting the roentgen-ray tube.

The transformer consists essentially of a primary and a secondary coil, both surrounding a continuous soft iron core. The principle is exactly the same as in the induction coil. With the latter, however, an interrupter must be used, while in the former an alternating current is utilized and the interruptions are supplied directly from the dynamo. The voltage of the secondary current depends upon the proportion between the number of turns of wire in the secondary to the number of turns in the primary. If, for instance, the secondary coil has twice as many turns as the primary then its voltage will be twice as great as that of the primary. It should be remembered that the amperage undergoes opposite variations at the same time. The transformer



is a step-up or step-down transformer, depending upon whether the secondary has a greater or less number of turns than the primary. For roentgen-ray work the

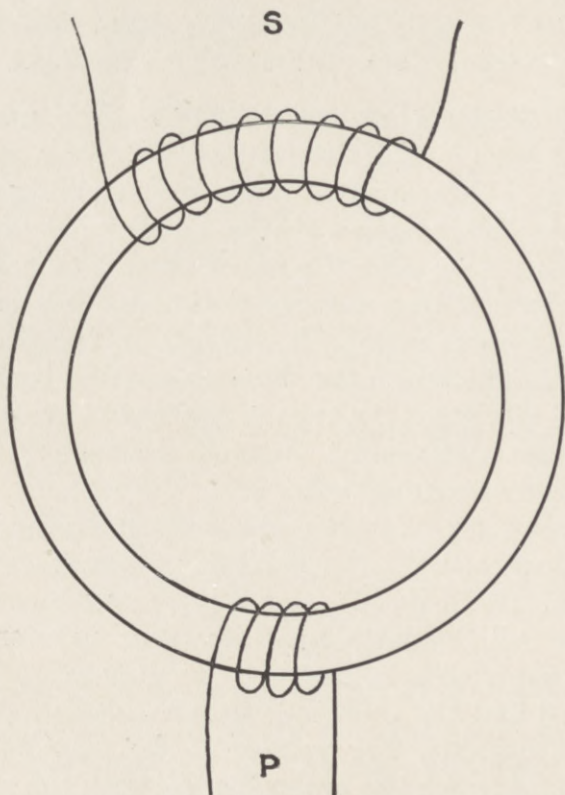


FIG. 15.—Ring type of transformer.

step-up transformer is necessary. The ring type of transformer is illustrated in Figure 15, showing the primary and secondary coils surrounding a ring-shaped core of iron. The transformer may be of the shell or jacket type, in which the primary and secondary coils

are surrounded by laminated masses of iron, which, from an electrical standpoint, constitute the core. Most transformers now in use are called *closed magnetic circuit* transformers and consist of a rectangular metal core with the coils so wound that they slip onto the sides of the rectangle.

The efficiency of the transformer is very high, being about 97 per cent of the energy of the primary. The current furnished to the primary must be an alternating one. If only a direct current is available it must be changed to an alternating one by a motor generator. Operating the generator necessitates a considerable loss of energy, from 30 to 50 per cent being lost in this manner. For this reason an alternating current supply is to be greatly preferred to the direct. It is necessary to use a motor even with an alternating current, for reasons which will be explained later, but this causes very little loss of energy.

The 220-volt alternating current is the ideal one for operating a transformer.

Thorough insulation of the primary and secondary coils is necessary. Some makers bury the coils in oil and others use only wax as insulation. Oil insulation is by far the preferable method. The terminals of the secondary coil must also be insulated or separated to a considerable distance from each other, to prevent sparking across.

**Methods of Rectifying the Current.**—Just as the current passing through the primary of the transformer is an alternating one, so that in the secondary is of the same character. Before this current can be used to excite a

roentgen-ray tube it must be rendered unidirectional by some means. Ventril or valve tubes, previously described, have been used for this purpose, but most high-tension transformers are now provided with some form of mechanical rectifying switches.

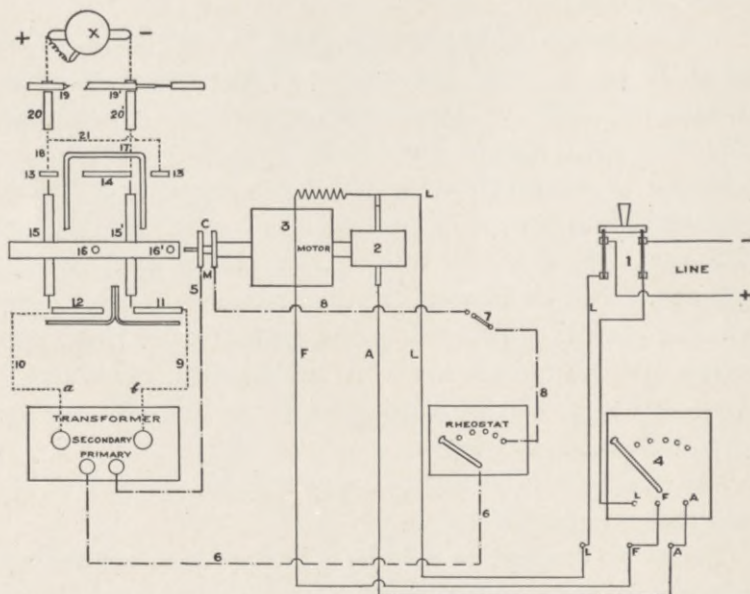


FIG. 16.—Diagram of connections of interrupterless apparatus.

Figure 16 represents diagrammatically the connections of the motor, transformer and rectifying switches of the so-called "interrupterless" apparatus used for roentgen-ray work, when only direct current is available. A direct current is furnished from the line and passes through the switch 1, the line L to the armature 2, and the field 3 of the motor generator. From the generator the current returns through the wires A and

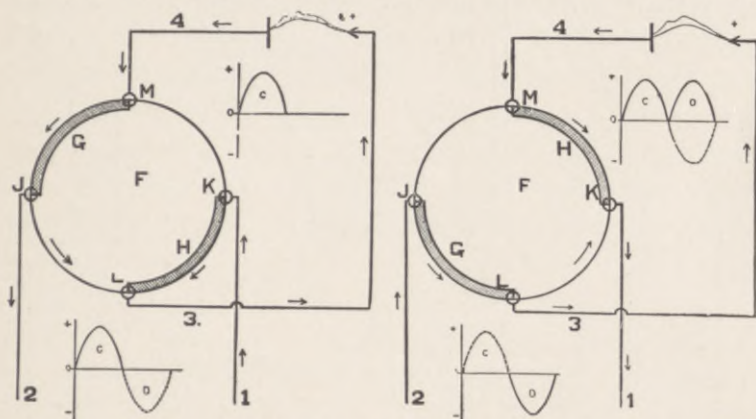


F to the motor starter 4, and thence back through the main switch to the line. The motor starter is simply a resistance box and enables one to start the motor gradually. Automatic motor starters are now furnished instead of the type represented in the diagram which must be operated by hand. In the generator the current is changed to an alternating one, necessitating a considerable loss of power as mentioned above. This alternating current is taken off from the collecting rings C by the brushes M, passes through wire 5 to the primary of the transformer, through the windings of the primary to wire 6, through rheostat to wire 8, and the switch 7, back to the collecting ring on the motor. This complete circuit constitutes the primary circuit. The poles of the secondary coil are marked *a* and *b*. As previously stated, the current is here an alternating one, just as in the primary winding. Before it can be utilized to excite the roentgen-ray tube it must be rendered unidirectional, this being accomplished by means of the four revolving arms 15, 15', 16 and 16'. These arms are mounted on the same shaft as the motor, two of them at right angles to the other two, thus insuring that the revolutions of the rectifying arms are synchronous with the phases of the current from the motor. This is the reason also why a motor is used even with alternating currents, for if the current were taken directly from an alternating light or power circuit there would be no means of accurately synchronizing the revolutions of the rectifying switches with the phases of the primary current. The manner of operation of the revolving arms is as follows: When *a* is the positive pole of the trans-

former the current passes through wire 10 to the metal collecting ring 12, sparks across to the end of the copper wire on the revolving arm 15 which is then in position to transmit it, sparks across from this wire at the other end of 15 to the metal plate 13, and passes through wire 18 to the terminal 20 which is connected with the positive terminal of the roentgen-ray tube. It then passes through the tube to the negative terminal, through 20' and 17 to the metal plate 14, sparks across to 15' and from 15' to the metal plate 11, which is connected with the negative terminal *b* of the transformer. At the opposite phase of the current *b* is the positive terminal of the secondary and the current is conveyed through 9 to the plate 11; the shaft has now made a quarter turn and instead of 15' being in position to convey the current, 16' is now in position; the current therefore passes through 16' to the metal plate 13' and is conveyed through wire 21 to 18 and thence to the positive terminal of the tube, just as it was in the first instance when *a* was the positive of the secondary; the current then returns through 20', 17, 14, and revolving arm 16 to 12 and thence to *a*, which is at this instant the negative terminal of the secondary. Thus both phases of the current are utilized, but it always passes through the tube in the same direction, no inverses being produced.

Instead of using four revolving arms to rectify the current, a revolving disc on which are mounted two metal strips is used in some constructions, to secure a unidirectional current. Figures 17 and 18 illustrate this method of rectification. *F* is a mica disc, *G* and *H* the two metal strips. *J* and *K* are the terminals of the

secondary of the transformer. L and M represent the brushes which receive the rectified current. In Figure 17 if 1 is positive, the current is taken up by the metal strip H and passes out through L to the anode of the tube. At the next alternation of the current the condition is shown in Figure 18. No. 2 is now the positive and the metal strips have assumed the position shown



FIGS. 17 and 18.—Illustrating rectification of current by revolving discs.

by a quarter revolution of the disc; the current again passes through L to the anode of the tube. The arrows show the direction of flow of the current in each instance.

Both the revolving-arm and the revolving-disc system must be kept clean and free from moisture. Collection of carbon, dust or moisture on the shaft, the arms, or the disc causes leakage of current which interferes both with the strength of the current and its synchronization.

Figure 19 is a diagram of the connections of an "interrupterless" apparatus operating on an alternating cur-



rent. The main current flows directly from the line through the primary of the transformer instead of through the rotary converter as in the case of the direct current.

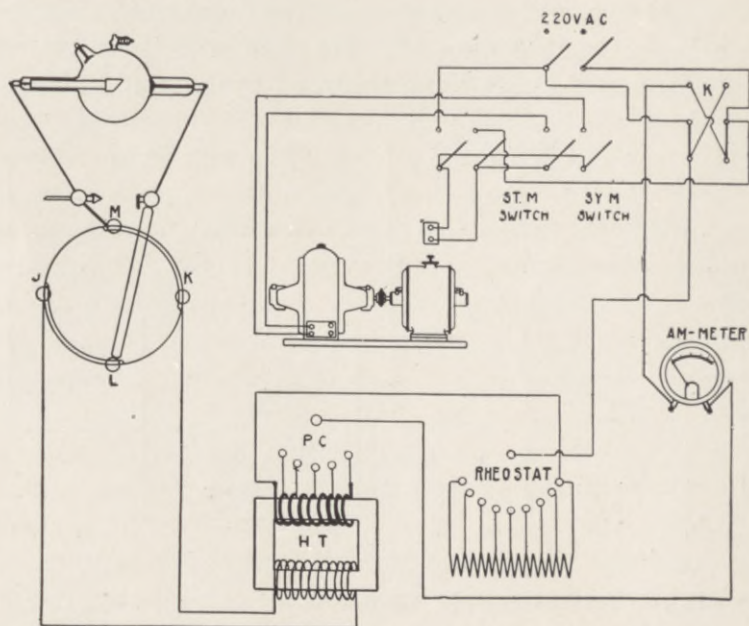


FIG. 19.—Diagram of connections of an "interrupterless" apparatus operating on an alternating current.

The two small motors, the starting motor and the synchronous motor, serve simply to revolve the rectifying disc J M K, the motors and rectifying disc all being mounted on the same shaft. The switch for the starting motor S T M is first closed, and when this motor has reached its maximum speed the switch to the synchronous motor S Y M is closed. The shaft is then revolving at the same rate as that of the dynamo in the

power house which is the source of the current. This insures that the revolutions of the rectifying disc are exactly synchronous with the alternations of the current passing from the secondary of the transformer to the terminals J and K.

Synchronous motors are now so constructed that the use of an additional starting motor is not required.

Rectifying devices are not necessary when the radiator tube is used. The only apparatus then necessary is a high tension transformer, a small transformer for the current to the Coolidge filament, a milliammeter, and a rheostat or auto-transformer by means of which the current may be controlled. The four latter-mentioned instruments are described below. If only direct current is available a rotary converter must be used to render it alternating before it passes into the transformer.

**SURGE.**—It sometimes happens that the current on the main line suddenly rises to an exceedingly high voltage. This is called a "surge." In order to prevent the burning out of the motor when a surge takes place a lamp is put across the main leads to the motor. Similarly, surge may burn through the insulation of the transformer and protection is secured by placing another lamp across the main leads.

**Regulating the Current.**—Electric currents are controlled by means of resistance, the current strength being equal to the voltage divided by the resistance (Ohm's law). Electrical resistance depends upon the material of which the conductor is made, the diameter of its cross-section, its length, and its temperature. Copper wire is one of the best practical conductors,

iron wire not so good, and German silver one of the poorest. The latter is widely used as a resisting medium. The resistance of a conductor is directly proportional to its length and inversely proportional to the area of its cross-section or the square of its diameter.

A *rheostat* is an appliance used to vary the strength of a current by changing the amount of resistance in the circuit. It usually consists of coils of wire connected with each other and with buttons on the switchboard, in such a way that any desired number of coils may be placed in the circuit at will. The rheostat necessarily decreases the voltage as the current strength increases, in accordance with Ohm's law. With an unstable current supply this loss in voltage is very troublesome.

The *auto-transformer* type of control causes practically no loss in voltage and for this reason it has largely replaced the rheostat in roentgenological work. The auto-transformer operates in accordance with the law of transformer ratios, *i. e.*, the voltage applied to the primary is to the voltage drawn from the secondary as the number of turns of wire on the primary is to the number of turns on the secondary. For a given setting on the auto-transformer, therefore, the variations in current are not accompanied by a drop in voltage; while for a given setting on the rheostat any increase in current is accompanied by a corresponding drop in voltage.

Even when the auto-transformer is used as the main control, however, a rheostat also is usually left in circuit because it permits of finer adjustment.

**Polarity.**—When using the “interrupterless” type of machine, which is now almost universal, the alternating



current is always used. It often occurs when the motor is turned on that the current is not passing in the proper direction to the tube, that is, it has the wrong polarity. This is indicated by the current jumping across the parallel spark-gap, or if, as should be done, the first trial was made with a very weak current, it fails entirely to pass. A polarity indicator is furnished with some machines indicating by a hand on a dial in which direction the current is passing. If it is found in any of these ways that the polarity is wrong, it may be rectified by a polarity switch on the control board; or if there is no such switch, by opening and closing the motor starting switch until the flow is in the right direction.

**THE MILLIAMETER.**—This instrument shows the strength of the current in milliamperes and is an exceedingly important part of the apparatus. It should be placed in the circuit between the spark-gap and the tube so that the current does not pass through it when the spark is being tried. The readings of the milliammeter should be checked frequently by placing another milliammeter in the circuit. This is especially important if the machine is used for roentgen therapy. There are usually two scales on the instrument and care must be taken not to throw a heavy current through it when it is set for the lower scale.

**THE COOLIDGE TUBE TRANSFORMER.**—It is necessary to supply a special current of low voltage for lighting the filament of the Coolidge tube. This current has only 12 volts which is secured by means of a specially constructed step-down transformer placed in the tube circuit on the same side as the milliammeter. The primary

current supply to this transformer is 110 volts instead of the 220 V. current which goes to the main transformer. If the only source of current is a direct current, a small rotary converter must be placed in the circuit to supply alternating current to the transformer, or a storage battery may be used to furnish the current direct to the filament. This filament current is controlled by means of a choke coil with a control on the switchboard.

**Timer.**—It is desirable to have on the machine an automatic timing device to insure accuracy in the time of exposure. The timer is usually very delicate and cannot stand heavy currents. A remote control or relay switch is used so that the timer circuit may be operated with only a few volts, sufficient to magnetize the relay switch. The relay may be of the mercury dip type, or of a later type in which heavy pieces of copper wire are brought into contact under oil by a magnet when the timer circuit is closed, and opened by a spring when the timer circuit is opened.

## CHAPTER VI

### ROENTGENOGRAPHIC TECHNIC

A GOOD film for diagnosis is one that shows contrast and detail.

*Contrast* refers to the amount of difference in darkening of the different parts of a film. When difference in density between lightest and darkest parts of a film is great we say much contrast is present; if small, there is little contrast present and the negative is "flat."

To get contrast, films must be used which will show the greatest difference in density or blackness with the slightest differences in exposure, for the soft tissues of the body are in some cases nearly as opaque as the material of which it is desired to obtain an outline. Roentgen films must possess great power of contrast and at the same time be capable of showing fine gradation and detail in the developed image.

Contrast depends on the following factors:

(1) The nature of the object. The contrast seen in a hand film is not seen in a kidney film because in the hand the image is a contrast between bone and muscle while in the kidney film the objects compared are of nearly the same density.

(2) Correct exposure and development. Overexposure or underexposure will each give films lacking in contrast. Overdevelopment or underdevelopment of a normal film will also give a negative lacking in contrast.



(3) Quality of radiation. It has been found that, other things being equal, the contrast in roentgenographic negatives will decrease as the spark-gap increases, that is, the amount of difference in density which the negative will show with a slight increase of exposure is less for a 6-in. spark-gap than for a 3-in. gap. This accounts for the brilliant negatives taken at shorter spark-gaps where it is not necessary to penetrate thick parts.

Since this penetrating power is absolutely essential on thicker parts there is a minimum spark-gap which may be used with certain parts of the viscera. The shortest spark-gap which will yield roentgen rays that will penetrate the object should be used, as it will give the maximum contrast.

The reasons for this are obvious as the radiations from a "hard" tube penetrate both soft and hard tissues and there is not much selective absorption or difference of absorption for soft and bony tissues, while the radiations from a soft tube are much more readily absorbed by the bony tissue than by the soft tissue, and great contrast in the image results.

*Detail* refers to the finer structure that shows in a correctly exposed and developed negative. The points that may be considered as having an important bearing on detail are as follows: //

(1) Focal spot of tube. The finer the focal spot the better the detail.

(2) Distance of object from film and distance of focus from object. The nearer the object to the film the sharper will be the image. The farther the focus of the

tube is from the object the sharper will be its image on the film. This is due to the fact that the rays approach more nearly to the parallel as the distance of the object from the tube increases.

(3) Correct exposure and development.

(4) Complete immobilization of parts by compression, sandbags, bandages or clamps, and by cessation of respiration when parts of the thorax or abdomen are being roentgenographed.

**Effect of Scattered Radiation Upon Contrast and Detail.**—As explained in a previous chapter the roentgen rays undergo scattering as they pass through any solid object. These scattered rays cause a blurring of the image on the film since they arise at points other than the focus spot on the target. They thus lessen both contrast and detail in the image. The effect of scattering is not important when dealing with thin parts of the body, but with thick, and especially with dense parts, it becomes of great importance. A recent addition to roentgen equipment, the Potter-Bucky diaphragm,<sup>1</sup> serves to eliminate a large percentage of the scattered rays and constitutes a most important advance in the technic of roentgenology.

There have been minor improvements in the apparatus since it was first described by Potter, but his original description shows clearly the principle and essentials of construction. "Strips of type metal  $\frac{5}{8}$  in. wide,  $\frac{1}{50}$  in. thick and 2 ft. long are mounted on a form which is shaped to resemble a section of the shell

---

<sup>1</sup> Potter, Hollis, E. The Bucky diaphragm principle applied to roentgenography. *Am. J. Roentgenol.*, 1920, vii, 292.



of a cylinder. All metal strips are parallel and spaced by gutted wooden strips about  $\frac{1}{8}$  in. thick. This makes the strips with the spacers run about five to the inch. The curve put into the complex is such that the rays from a tube target 25 in. above, pass through the spaces without impinging on the sides of the strips, just the edges.

“This complex is mounted on roller bearings made to run on a curved track, so that motion is across the length of the strips, and the distance of movement about 5 in. The power used for movement is the weight of a mass of lead. This weight is hung from an equalizing rod, each of whose ends is attached by cable over pulley to a side of the movable grid. The movement is regulated in speed and made uniform in rate by an oil drag. \* \* \* Above the grid is built a curved support for the patient. This is made of laminated wood and just allows the grid to clear underneath. Below the grid is a space for plates and screen holders. \* \* \* To operate, one places patient and plate in position, sets the oil drag in ‘down’ position by trigger, and sets the value for speed desired for the exposure. Just before starting the exposure the trigger is tripped by a pull on a string and the ‘sieve’ set in motion. The exposure must be complete before the sieve comes to a stop, otherwise the strips cast their shadows.”

The Potter-Bucky diaphragm finds its greatest application in thick and dense parts of the body, notably the urinary tract, the spine, the pelvis, and the hips. The time of exposure is somewhat longer than without the diaphragm. This is not so great as might be expected,



however, because the diaphragm enables the operator to use a longer spark-gap with consequent greater penetration than was possible without the diaphragm.

Another advantage of the Potter-Bucky diaphragm is that it is no longer necessary to use diaphragms just below the tube to intercept the rays arising from the target at points other than the focus spot. This makes it possible to roentgenograph very large fields without sacrificing either contrast or detail.

**Directions for Exposure.**—The time of exposure in making a roentgenogram depends upon the following factors: the voltage and milliamperage of the current, the distance of the tube from the film, the thickness and density of the part, and the speed of the photographic emulsion. The time is increased by the use of filters and decreased by the use of intensifying screens.

**Detailed Directions for Exposure.**—The operator closes the motor starting switch and turns on the light in the Coolidge filament. With the auto-transformer or rheostat control on a low button he closes the operating switch to try the polarity, and if it is the wrong direction he corrects it. He now sets the auto-transformer on the button which he knows by experience will give the spark-gap he desires, the spark-gap being the practical way in which he estimates the voltage. He now manipulates the Coolidge filament control until the milliammeter gives the desired reading and then tries the spark-gap. If the gap is too long, he sets the auto-transformer on a lower button; and if too short on a higher button, until it is exactly the length desired.

With the patient on the table, the tube is now adjusted with its focus point perpendicularly above the center of the film. It must be remembered that the time of exposure varies not inversely as the distance but inversely as the *square* of the distance of the focus point from the film. Eighteen to twenty-eight inches are convenient distances at which to work, but it is well for each operator to choose a particular distance and adhere to it. It is advisable, in fact, to have only one variable factor, which is necessarily the time of exposure. This must vary because patients are not all of the same thickness.

After the tube is adjusted for distance the part to be roentgenographed is carefully adjusted over the film.

The *use of a filter* increases the time of exposure. It should be a rule to use 1 mm. of aluminum as filter for all roentgenographic work. This filters out the softer rays which are of little or no use for roentgenography, but which may furnish the additional dose necessary to injure the skin.

Films for roentgen-ray work have been greatly improved in the past few years. As a rule, the more rapid the film the more readily it fogs in developing, but the double-coated, or duplitized, films now on the market are very satisfactory both for speed and lack of fog.

Excellent *intensifying screens* made of calcium tungstate spread in an emulsion in a gelatin base on cardboard, are now to be had. Screens are now very free from grain and from lag. The latter is the quality which causes the fluorescence to persist for some time after the exposure, and is very objectionable.



A duplitzed film is placed in a cassette between two intensifying screens. It is of the greatest importance that all parts of the screens make close contact with the film over the entire surface; otherwise there will be blurred areas where the screens are not in contact.

The action of the intensifying screen is due to the fluorescence of the calcium tungstate when the roentgen ray strikes it. Good screens shorten the exposure from one-third to one-half of the time that is necessary when they are not used. Screens should be brushed carefully each time before use; any spot of dust or dirt on the screen will make a corresponding mark on the roentgenogram. This is also true of finger prints or abrasions.

It is impossible to give exact rules for all exposures, but it is well to keep in mind the following suggestions:

(1) The penetration of the roentgen ray through solid bodies depends largely upon the voltage. It is, therefore, necessary to have a spark-gap sufficiently long to insure the penetration of the ray through the part being roentgenographed. On the other hand if the ray is of a too penetrating quality, it will pass through even the more solid parts of the body and produce a flat picture without contrast or detail. The ideal is to have the spark-gap just long enough to secure penetration of the part.

(2) A high milliamperage does not necessarily mean a ray of high penetrating power. It may mean just the opposite. Fluctuation in the filament current circuit may cause a rise in temperature in the Coolidge filament and a consequent increase in the number of electrons in the tube. This makes an easier path for the current,



or in other words, lessens the resistance. The result is a rise in the milliamperage but a drop in the voltage. This is corrected by regulating the Coolidge filament current until the milliammeter is giving the proper reading when it will be found that the spark-gap has increased to the original length.

(3) Care must be exercised in centering the tube, not only to insure that the focus is directly over the center of the film but that the tube is centered in the tube-holder.

(4) The part to be roentgenographed must be thoroughly immobilized. This may be accomplished by compression with the cone on the tube-stand, by bricks or sandbags placed about the part, by a strip of cloth thrown over the part and held firmly with weights fastened to its ends and hanging on either side of the table, or in numerous other ways that will suggest themselves.

(5) The marking of the film to identify the patient and also the side of the body is of obvious importance. It should be routine procedure to place a lead R or L upon the cassette to mark the right or left side. This is doubly important since the use of double-coated films has become general; there is no possible way to identify the right or left side on unmarked films.

To identify the patient, either numbers in lead are placed upon the cassette before exposure or the patient's name is written upon the film with lead pencil before it is developed.

The table on page 55 is given simply as a guide for

time of exposure. Every operator must work out his own exposure table upon the particular apparatus with which he is working.

EXPOSURE TABLE. DOUBLE INTENSIFYING SCREENS. SUPER-SPEED FILMS.

Part	P.	Dist.	M. A.	Time	S. G.
Nasal sinuses.....	P. A.	Comp.	30	4	5 in.
Nasal sinuses.....	Lat.	28 in.	30	$1\frac{1}{2}$	5 in.
Sella turcica.....	Lat.	Comp.	30	$\frac{3}{4}$	5 in.
Mastoid.....	Reg.	Comp.	30	$2\frac{1}{2}$	4 in.
Cervical spine.....	A. P.	28 in.	25	$1\frac{1}{2}$	4 in.
Cervical spine.....	Lat.	36 in.	25	2	4 in.
Shoulder.....	A. P.	28 in.	25	$1\frac{1}{2}$	4 in.
Elbow.....	A. P.	28 in.	25	$1\frac{1}{2}$	3 in.
Elbow.....	Lat.	28 in.	25	$1\frac{1}{2}$	3 in.
Hand.....	A. P.	28 in.	25	$\frac{3}{4}$	$2\frac{1}{2}$ in.
Hand.....	Lat.	28 in.	25	1	$2\frac{1}{2}$ in.
Dorsal spine (B).....	A. P.	28 in.	20	4	5 in.
Dorsal spine (B).....	Lat.	28 in.	20	8	5 in.
Chest.....	P. A.	48 in.	30	$\frac{3}{4}$	4 in.
Heart.....	P. A.	60 in.	30	3	4 in.
Gall-bladder (B).....	P. A.	28 in.	20	4	$5\frac{1}{2}$ in.
Kidneys (B).....	A. P.	28 in.	20	4	$5\frac{1}{2}$ in.
Stomach.....	P. A.	28 in.	30	1	$4\frac{1}{2}$ in.
Colon.....	P. A.	28 in.	30	1	$4\frac{1}{2}$ in.
Lumbar spine (B).....	A. P.	28 in.	20	4	$5\frac{1}{2}$ in.
Lumbar spine (B).....	Lat.	28 in.	20	8	$5\frac{1}{2}$ in.
Pelvis and hip (B).....	A. P.	28 in.	20	4	$5\frac{1}{2}$ in.
Knee.....	A. P.	28 in.	30	2	3 in.
Knee.....	Lat.	28 in.	30	2	3 in.
Ankle.....	A. P.	28 in.	30	$1\frac{1}{2}$	3 in.
Ankle.....	Lat.	28 in.	30	$1\frac{1}{2}$	3 in.

P. Position.  
 M. A. Milliamperes.  
 P. A. Posteroanterior.  
 A. P. Anteroposterior.

(B). Bucky diaphragm.  
 Comp. Compression.  
 S. G. Spark gap.  
 Time is in seconds.

## CHAPTER VII

### DARK ROOM TECHNIC

THE roentgen ray acts upon sensitized plates like ordinary light, therefore the making of roentgenograms has much in common with photography. It must always be remembered, however, that whereas the photograph is produced by the action of light which is reflected from the object to be photographed, the roentgenogram, on the other hand, is a record of the penetrability of the different parts of the object to the roentgen ray.

The photographic plate consists of a sheet of glass coated with gelatin containing sensitive silver salts. The salt may be either the bromide, the chloride, or the iodide of silver. The iodide is not often used except occasionally as an addition to the bromide, and the chloride is used only for slow emulsions such as are used on printing-out paper and for lantern slides. The gelatin-bromide emulsion, either with or without the iodide, is the one usually employed. The sensitiveness of the emulsion is governed by the manufacturer by the length of time during which it is subjected to slow heating or other method of "ripening." The increase of sensitiveness is said to be due to the enlargement of the particles, something like the growth of particles by crystallization. The particles as they become larger are able to absorb



more light and consequently a greater amount of silver is reduced, rendering the plate more rapid. A similar explanation is given as to why the amount of emulsion on the plate affects its sensitiveness.

Roentgen-ray plates differ from photographic plates only in their greater sensitiveness, the emulsion being thicker than on photographic plates.

What is said above with regard to photographic plates may also be said of films, which are now largely supplanting plates. The film which is now most commonly used in roentgenography is one coated with the sensitive emulsion on both sides.

The exact effect that light has on silver salts is not yet entirely understood. So far as known, light exerts a reducing effect on the salt, setting free the chlorine, bromine, or iodine. The latent image consists of some modification of the halogen.

In order to bring out the latent image some form of developer is necessary. A developer contains several ingredients known respectively as the reducer, the accelerator, the restrainer, and the preservative. There are a great variety of reducing agents, among which are pyrogallic acid, hydroquinon, metol, amidol, eikonogen, ortal, rodinal, etc. The function of the reducer is to reduce the exposed silver bromide to metallic silver, for it is this metallic silver that produces the lines of the picture. Most of the reducers named, however, will not act quickly enough by themselves, so that an accelerator must be added. Some alkali, usually sodium carbonate, fulfills this function.

The restrainer is added, usually potassium bromide, so that the developing may be more under control and may not take place too rapidly. Sodium sulphite is usually added to act as a preservative, which it does by taking up oxygen and thus preventing oxidation of the reducer.

Following are some formulas for developing solutions:

Hydroquinon or Quinol	
No. 1.	Hydroquinon. . . . . 6 gm.
	Sodium sulphite. . . . . 50 gm.
	Water . . . . . 500 c. c.
No. 2.	Potassium carbonate . . . . . 100 gm.
	Potassium bromide. . . . . 1.5 gm.
	Water . . . . . 500 c. c.

For use take equal parts of No. 1 and No. 2.

The hydroquinon developer may be made in one solution, according to the following formula, but should be made fresh for each day's work:

Hydroquinon . . . . .	36 gm.
Sodium sulphite, dry. . . . .	90 gm.
Potassium carbonate, dry. . . . .	180 gm.
Potassium bromide. . . . .	9 gm.
Water . . . . .	1800 c. c.

Hydroquinon is a reducer which gives great contrast in pictures and since this is a very desirable thing in roentgenograms it makes a good developer in roentgen-ray work. Where softer negatives with greater detail are desired metol is a valuable reducer. Hydroquinon and metol may be used together according to the following formula:

No. 1.	Metol. ....	1 gm.
	Hydroquinon . . . . .	4 gm.
	Sodium sulphite. . . . .	50 gm.
	Potassium bromide, 10 per cent sol. . . . .	4 c. c.
	Water . . . . .	250 c. c.
No. 2.	Sodium carbonate. . . . .	50 gm.
	Water . . . . .	250 c. c.
	Mix No. 1 and No. 2 in equal parts.	

The advantages of having the accelerator, sodium carbonate, in a separate solution are that the developer keeps better and that development is better under control. If the plate is over-exposed then a small amount of No. 2 should be added; if under-exposed, a proportionately larger amount.

After the negative has been developed it is necessary to remove the silver from the unexposed parts of the film. This is known as fixing, and is effected by placing the plate in a solution of sodium hyposulphite, made according to the following formula:

## A

Water . . . . .	4000 c. c.
Sodium hyposulphite . . . . .	1000 gm.

## B

Water . . . . .	1000 c. c.
Sodium sulphite, dry . . . . .	90 gm.
Sulphuric acid . . . . .	15 c. c.
Powdered chrome alum . . . . .	60 gm.

Mix B in exactly the proportions and sequence given above.

Pour B into A while stirring. During cold weather one-half of B is sufficient for the full quantity of A.



Excellent developing powders are now on the market with the ingredients mixed in the proper proportions. They are accompanied by directions which make the preparation of developing solutions very simple.

In a general way the procedure in making a roentgenogram is as follows:

The film is placed in a container which may be an aluminum or wooden cassette, double envelopes, or a cardboard folder. Whatever the folder it must be impervious to light and at the same time readily penetrable by the roentgen ray. The film is placed in its container in the dark room and when taken to the roentgenographic room, this container is placed in a lead-lined box or closet while the roentgen tube is being tried and regulated.

When the tube is ready the film-holder is placed beneath the part to be roentgenographed and the proper exposure made.

After exposure the plate or film is taken to the dark room, removed from its container, and placed in the developing solution. It should be slid into the tray of developer and the solution made to cover the entire plate immediately by a wave-like motion. It is important that the developer be kept at a temperature of about  $65^{\circ}$  to  $68^{\circ}$  F. All air bubbles should be removed from the surface of the plate by rocking the tray. Complete development is judged by the even black appearance of the back of the plate when it is held up to the ruby light. When developed the plate is washed for a moment in running water and placed in the fixer. After it has remained in the fixer for about a minute the light

may be turned on. The plate is fixed when all the dull white film has disappeared from it,—a fact which may be determined by looking at the back of the plate, but it should be left in the solution for about fifteen minutes after this has occurred. When the plate is fixed it should be washed for at least an hour in running water.

Tray development is not practical in laboratories where a large amount of work is done. There it is necessary to use tanks in which plates are set in grooves, or films are hung in film-holders. The tanks are made of soapstone or porcelain. The developing and fixing tanks should be some distance apart to avoid getting fixing solution in the developer.

It is not only important to keep the developing solution at about 68° F. but the water used for washing must also be kept below 70°. Ice packed into an adjacent tank will serve to keep the developer cool but water should be constantly flowing through the washing tank and it is therefore more difficult to cool it.

A practical method that has been used by the author for several years is to run the water through a coil of pipe in a water-cooler before it enters the washing tank. The cooler has now been replaced by a refrigerator in which the coil is installed.

Films should be dried in a room or box free from dust and in which there is a free circulation of air provided by a suction or blower fan.

**CARE OF DARK ROOM.**—The dark room should be kept perfectly clean and in order. If the solutions of developer or hypo are allowed to drip on the floor and dry, small particles of chemical will be constantly in the



air. These settling on the plates will cause black spots. If chemicals are spilled on the floor, they should be mopped up at once. Tanks, trays, graduates, etc., should be washed thoroughly immediately after use. The stain that gathers on the inside of the developer tank can be removed by a liberal application of scouring powder and scrub brush or more easily by using an acid solution. All benches, developing tanks, cupboards, etc., in the dark room should be at least one foot from the floor so that the floor can be mopped underneath. The floor should be kept as clean and dry as possible. Provision should be made for envelopes, plates, both exposed and unexposed, cassettes, etc. Each of these materials should be kept in its proper place so that the dark-room man can easily find everything needed and not be inconvenienced by having to look for misplaced material. The dark room is oftentimes used as a storage room for any material that the roentgen department cares to have out of sight. Only that material that is to be used in the dark room should ever be kept there.

**Over-Exposed Plates.**—A plate on which the image flashes up almost immediately upon placing it in the developer is usually over-exposed, and if developed in the usual way would be so dense that the picture could scarcely be seen. It may be taken from the developer immediately and the process finished in a weaker developer, or a few drops of 10 per cent solution of potassium bromide may be added to restrain the development. If after development the plate is still found to be too black and dense, it may be greatly improved by treating it



with a reducer. For this purpose the following solution may be used:

Potassium permanganate . . . . .	.5 gm.
Sulphuric acid . . . . .	1 c. c.
Water . . . . .	1050 gm.

Before treating with this reducer the plate should be washed but does not require to be entirely free from hypo. Rock the dish continually while the plate is in the reducer. If a stain is left by the permanganate, it may be removed by a 1 per cent solution of oxalic acid.

Potassium cyanide is often used as a reducer according to the following formula:

Potassium cyanide . . . . .	1 gm.
Potassium iodide . . . . .	.5 gm.
Mercuric chloride . . . . .	.5 gm.
Water . . . . .	300 c. c.

The plate must be well washed to remove the poisonous chemicals in the above formula.

**Under-Exposed Plates.**—Plates that have had insufficient exposure will need to be developed for a long time in a strong developer. Leaving them in too long, however, will often fog them. Under-exposed plates may be much improved by treating them with an intensifying solution such as the following:

Mercuric chloride . . . . .	11 gm.
Potassium bromide . . . . .	6 gm.
Water . . . . .	210 c. c.

Leave the plate in this solution until it looks white, then wash it in running water for about one-half hour. The plate is then placed in the following solution:

Sodium sulphite .....	45 gm.
Water .....	180 c. c.

until it has turned black, and is then thoroughly washed.

Of course the ideal is to give the correct exposure and to develop to the proper density, but this is not always attained, and otherwise valueless plates may be saved by reduction or intensification.

**Defects on Plates or Films.**—There are numerous types of markings which will be found on photographic plates and films which have been subjected to careless handling. Unless the source of trouble is identified in the finished negative, it will lead to confusion not only in interpretation but in upsetting the routine of the dark room in order to attempt to locate the trouble. By examination of a simple set of negatives which illustrate most of the defects met with in the ordinary roentgen-ray dark room, the operator will gain experience which will afterwards save him much time and material.

These markings or plate troubles may be listed as follows:

(1) *Fog*.—The presence of reduced silver in the negative other than that produced by the exposure. It may come from careless exposure to roentgen rays or light or from defective chemicals in the developing solutions. It will present an even black deposit usually over the entire negative, or in some cases be local in nature. There is no remedy for this condition, but it may be avoided by seeing that the plates or films are in light-proof containers while exposed to white light and never exposed to roentgen rays, even indirectly, except when the roentgenogram is made.

(2) *Finger Marks*.—In most cases these develop up black in the negative, although in the case of grease or hypo on the fingers, they may develop up as clear spots. They are always due to unclean fingers. Such marks are practically impossible to remove from the negative without destroying it. They may be avoided by making it a habit to keep the hands clean at all times.

(3) *Scratches or Abrasions*.—These usually show up in the negative in the exposed parts as clear lines or marks and in the unexposed parts as dark deposits. They are due to a rupture of the emulsion surface. If they are not at all dense, they may be removed by a ferricyanide reducer without greatly injuring the negative.

(4) *Dust, Dirt or Grease Adhering to the Plate or Film*.—Where such contamination exists, the silver will be undeveloped, leaving a clear spot. There is no remedy, this being another type of mark which may be easily avoided by brushing the plates or films before developing.

(5) *Air Bells During Development*.—These leave a dark circle surrounding a clear patch and are due to a bubble resting on the plate during development. These marks cannot be removed but may be avoided by agitating the developer for a few seconds after the plate has been wet.

(6) *Uneven Development*.—This will show in the negative as uneven patches of density, usually bordered by a sharp dividing line. It is generally caused by the plate being unevenly wet when slid into the developer.



To avoid it in the case of tray development the plate or film should be slid rapidly into the developer with no pause in its flow across the surface. In the case of tank development the plates or films should be slid at a constant rate into the tank.

(7) *Dichroic Fog*.—This is one of the most troublesome types of marking and shows in the negative as a stain which is a reddish-yellow by transmitted light and green by reflected light. It may be due to any of the following causes: Hypo in the developer, lack of rinsing between development and fixing, lack of acidity in the fixing bath. All three of these actions may be primarily traced to the presence of developer and fixer in the gelatin at the same time. It may be easily avoided by using fresh solutions, particularly developer which is not badly oxidized and a fixing bath which is distinctly acid in action, the acid having the effect of immediately checking the action of the developer. In a number of cases this fog exists only on the surface and may be wiped off with absorbent cotton or taken off with ferricyanide reducer. In cases, however, where it is deep in the emulsion, it is practically impossible to remove it.

(8) *Undissolved Chemicals*.—In this case the plate will present a mottled appearance showing local unevenness of development. Such a condition cannot be remedied but may be avoided by dissolving the chemicals in warm water when mixing the developing solutions.

(9) *Black Spots*.—These are usually small dense deposits of silver and are caused by the presence of chemicals on the plate which produce the same effect as

exposure. Some of these chemicals are hydrogen peroxide, all kinds of turpentine, iron, iron rust, etc. It is impossible to remove these spots but they may be avoided by clean methods.

(10) *Water Spots*.—These show as dense circles surrounding areas of lesser density and are due to water being spattered on the plate while drying. Their effect may be greatly reduced by soaking the plate thoroughly in water, and redrying. The excessive moisture should be carefully wiped off the plate or film before drying is started and this operation done in a place which is free from the possibility of spattering.


(11) *Reticulation*.—This shows up in the negative as a fine network of lines and is due to the developing solutions being of too high a temperature, causing the gelatine to swell to such an extent that it is impossible to dry it back to its original form. It is obvious that such marks may easily be avoided but not remedied.

(12) *Hypo Crystals on Negative*.—Crystalline surface. Where a negative shows a greasy surface which is full of shiny crystals, one may be sure that the hypo was not sufficiently washed out after fixing. These crystals may be easily removed by thoroughly washing the plate or film again.

(13) *Scum*.—This is usually a brown stain on the surface of the plate or film due to extreme oxidation of the developer. It may be avoided by using a proper developer or thoroughly stirring an old one before development is started. It may be removed to a great extent by rubbing with absorbent cotton.

(14) *Crimp Marks*.—This is a trouble peculiar only to films and is usually evidenced by crescent-shaped clear patches in the exposed portions. It is due to a crumpling of the film before exposure which causes an image to be formed which is subsequently reversed by the exposure. These marks cannot be removed but may be easily avoided by following instructions for handling films.

(15) *Peacock Green*.—This is usually due to use of old plates.





## CHAPTER VIII

### ROENTGENOSCOPY. LOCALIZATION OF FOREIGN BODIES

ROENTGENOSCOPY or fluoroscopy is the method of making studies of opaque objects by means of shadows on a fluorescent screen. The latter consists of a cardboard upon which is spread an emulsion containing some fluorescent substance such as platino-barium-cyanide or calcium tungstate. This screen may be fitted into a light-tight box or simply mounted in a frame. In whatever way it is mounted it must be covered by lead glass equivalent in absorbing power to sheet lead  $\frac{1}{32}$  inch in thickness. This is to prevent the rays from reaching the operator. The roentgenoscopic method is especially dangerous to the operator because of the prolonged exposure necessary for the examination of many patients each day.

When a part of the body is held between the roentgen tube and the fluorescent screen the rays pass with varying degrees of penetration. Around the part where there is no obstruction there is brilliant fluorescence; under the soft parts the fluorescence is less brilliant; and if the degree of penetration is correct there is very little fluorescence beneath the bones, and they appear black.

APPARATUS.—Dessane's fluoroscope was designed for use in a lighted room. When open (Fig. 20) the operator can see what goes on in the room through a ruby

glass which preserves the sensibility of the retina. When the roentgenoscope is closed and ready for use (Fig. 21) the ruby glass rises automatically out of the field of vision. This roentgenoscope is of special value when the work must be done at the patient's bedside, either in the hospital or the home. It has found its greatest field of usefulness, however, in

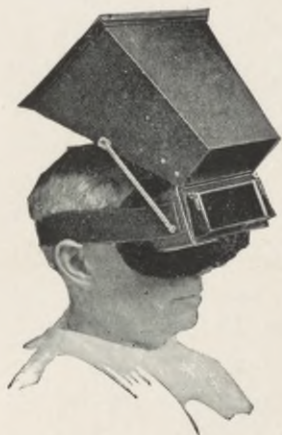

FIG. 20.—Operating roentgenoscope (Dessane bonnet) open.

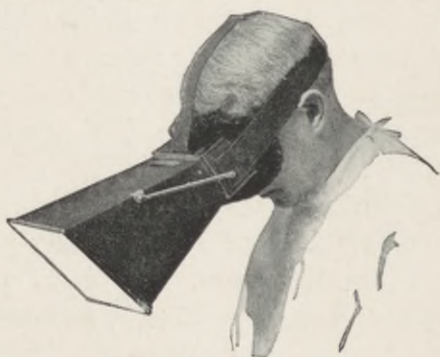

FIG. 21.—Operating roentgenoscope (Dessane bonnet) closed.

the operating room for the removal of foreign bodies or of renal calculi under direct roentgenoscopic control.

The upright roentgenoscope (Fig. 22) is invaluable for examination of the chest and the gastro-intestinal tract. The horizontal roentgenoscope (Fig. 23) is also of great value to furnish additional information in chest conditions and for examination of the stomach and duodenum and of the cecum, appendix and colon.

The radiator type of Coolidge tube designed for 5 ma. is very satisfactory for roentgenoscopic work.

Transformers so designed that the filament trans-




FIG. 22.—The upright roentgenoscope.



former is wound as a part of the main transformer have simplified the apparatus necessary for this work. The Coolidge tube filament lights up when the foot switch is closed. The only other apparatus necessary are a milliammeter and some type of control that makes it




FIG. 23.—The horizontal roentgenoscope.

possible to vary both the milliamperage and the voltage. Roentgenoscopic work should usually be done with about 2 ma. of current and should never exceed 4 ma. The spark-gap may be varied from 3 in. to 5 in. Roentgenoscopic units are now constructed with the roentgen tube immersed in oil in the same tank as the high tension and Coolidge filament transformer. They are especially valuable for use in the operating room to obviate

the danger of fire or explosion caused by ignition of vaporized ether by sparks from exposed high-tension wires.

The *roentgenoscopic room* should be well ventilated but it is essential absolutely to exclude all white light. A ruby lamp giving a dim, diffused light is the best means of illumination. It is so wired that it is extinguished when the foot switch is closed to operate the roentgenoscope.

There are certain conditions essential to the best roentgenoscopic work. The retina must be sensitized by remaining in the darkened room illuminated only by the ruby light for at least ten minutes before beginning the roentgenoscopy. This is an essential which is often disregarded resulting in failure to see the screen image well and in prolonged exposure of the patient. Goggles with ruby glass or celluloid should be worn if it is necessary to leave the dark room. The tube used must be of fine focus and the distance from the tube to the screen should not be less than 24 in. The sharpness of contrast on the screen depends very largely on the degree of penetration of the ray, in other words, upon the equivalent spark-gap of the tube. It should be a rule to make every examination with as short a gap as possible, since the contrast increases as the penetration of the ray decreases. Increasing milliamperage serves only to increase the illumination of the entire screen and does not increase the definition of the shadows. Scattered rays from the patient's body, the edges of the shutters, etc., and rays emitted from the target outside of the focus spot serve to obscure the screen image just as they do the image on the photographic film. To



minimize the amount of radiation reaching the screen from points other than the focus, metal shutters are placed in front of the tube so that the operator can decrease the size of the illuminated area and thus secure better definition. Scattered radiation is greatly lessened by the use of the Potter-Bucky diaphragm. The principle of this is the same as in roentgenography except that no means has yet been devised to secure movement of the diaphragm during exposure.

**LOCALIZATION OF FOREIGN BODIES.**—This subject is dealt with in this chapter because it was demonstrated in the World War that roentgenoscopy is the most practical method of locating and assisting in the removal of foreign bodies. In the military service this is particularly true because of the difficulty of transporting plates or films, and the absence of dark-room facilities at the forward hospitals where most of this work must be done so rapidly when there are large numbers of wounded that no delay can be made for the development of films. There are additional and important reasons why roentgenoscopy should also be the method of choice in civil practice. (1) It can be done with less manipulation of the injured part than is necessary when a sufficient number of films are made for accurate localization. (2) It is available for use when the surgeon is attempting removal of the foreign body. (3) A rapid survey can be made of parts far removed from the entrance wound for the possible presence of fragments or of other foreign bodies. (4) There is a chance that the foreign body may not be in the same location at operation as it was when the films were made.



In any roentgenoscopic method the roentgen tube must be mounted in its holder so that the focus spot is perpendicularly beneath the center of the opening in the diaphragm. The operator can then be certain that when he reduces the diaphragmatic opening to a very small area the illuminated area on the screen is perpendicularly above the focus spot on the target of the tube.

*A very simple method of localization* is to proceed as follows: The patient lies on the horizontal roentgenoscope; survey is made of the suspected part with the diaphragm wide open; when the shadow of the foreign body is seen the diaphragm is reduced in size and the tube is moved until the shadow appears in the illuminated area on the screen; the end of a metal pointer is then placed upon the skin so that its shadow coincides with that of the foreign body, or a metal ring may be used to surround the shadow; the position of the pointer or ring is then marked on the skin with indelible ink. This mark will be perpendicularly above or below the foreign body. By rotating the part containing the foreign body or by ascertaining where pressure by a pointer causes the greatest movement of the shadow one can find the point on the skin where the foreign body is nearest to the surface. This point is also marked. The surgeon may now be able to find the foreign body readily but if not, it may be removed under *direct roentgenoscopic control*. The latter is carried out as follows: After the surgeon has made his incision to the approximate depth indicated by the previous examination he places a curved metal pointer in the wound, holding it by a long handle so that his hand

is not in the field of vision. The roentgenologist wearing a Dessane fluoroscope then locates the shadow and directs the surgeon as he gently moves the pointer. The image on the screen is of course in only one plane, but it is usually possible by noting the movement of the shadow or by gently rotating the part to tell when the pointer is in contact with the foreign body. The lights are then turned on and with the pointer in position it is possible in the majority of cases to locate the foreign body very quickly. A great number of instruments and devices have been used to assist in the localization and removal of foreign bodies under direct roentgenoscopic control but space cannot be given here to their description.

In general it may be stated that the apparatus should be as simple as possible and that it is of the utmost importance to work out the details of any method with the greatest care. The dangers attendant upon prolonged exposure of the patient, the surgeon or the roentgenologist to the roentgen ray must not be forgotten. The smallest current that will give a good screen image should be used and the time of exposure made as short as possible. When the examination is made while the surgeon is operating, the ray should be turned on only when necessary. The opening in the diaphragm should be as small as possible and there should be the usual thickness of lead glass over the screen. The surgeon's hands will be out of the field of the ray if he uses a long-handled pointer but the roentgenologist should wear the usual protective gloves.

When direct roentgenoscopic control at time of opera-



tion is not feasible the foreign body must be localized as accurately as possible in relation to fixed body landmarks, or to marks made upon the skin. Stereoscopic films made in two directions at right angles to each other are often of great assistance.

A method described by Dr. Hernaman-Johnson which utilizes the ring localizer is simple and efficient. The general position of the foreign body is ascertained by examination on the screen with a wide open diaphragm. The diaphragm is then gradually reduced to about one inch in diameter, keeping the shadow of the foreign body in the center of the illuminated area. The image on the screen is then vertically above the body itself. A metal ring about  $\frac{3}{4}$  inch in diameter, fixed to the end of a wooden handle about one foot in length, is placed under the screen so that its shadow encircles that of the foreign body. The screen is removed without displacing the ring and a mark made with silver nitrate or indelible ink in the center of the ring. The same procedure is repeated with the ring between the patient and the table, and a second mark made on the lower aspect of the patient's body. The part is turned at right angles and the above procedure repeated so that there are in the end four localizing marks on the patient's body. The point of intersection of lines connecting the opposite skin points can be estimated with fair accuracy. This method is, of course, applicable only to parts which can be examined in two different directions.

When the examination can be made in only one direction the above described method may be used to



localize the foreign body in one direction and its depth may be obtained by a very simple application of the parallax method. This method depends upon the fact that the shadow of a foreign body on the screen moves when the roentgen tube is moved and the distance it moves depends upon its distance from the screen. The farther away it is from the screen the greater will be its movement. Now if we place an opaque body like the end of a metal pointer or a tack in the end of a stick against the patient's body, we can move it up or down until its shadow on the screen shifts with the movement of the roentgen tube the same distance as the shadow of the foreign body. It will then be at the same distance from the screen as the foreign body itself and this position can be marked on the patient's skin.

Localization of foreign bodies in the eye must be made with great accuracy and for this it is necessary to have special apparatus. The Sweet apparatus or its modification known as the Sweet-Bowen apparatus have been found perfectly satisfactory in practice. Complete directions for using the apparatus are furnished by the manufacturer and will not be included here.

## CHAPTER IX

### DISEASES AND INJURIES OF BONES AND JOINTS

THERE seems to be little necessity for insisting upon the importance of roentgen examination of bone and joint lesions, for this is the field in which roentgenography first proved its value.

It should be an invariable rule to secure roentgenograms, not only in cases of undoubted fracture or dislocation, but in every case of suspected injury to the bones. This is especially important when the injury is near to a joint. The necessity for this is demonstrated by the great number of cases in which no clinical diagnosis could be made other than contusion or sprain, and in which the roentgenogram revealed a fracture or dislocation. Roentgenograms are especially valuable in bone and joint injuries to establish the presence or absence of a complicating lesion, such, for instance, as a fracture of the greater tuberosity or head of the humerus in shoulder-joint dislocations, dislocations of the carpal or tarsal bones in injuries about the wrist or ankle, or disease of the bone which may accompany or be the predisposing cause of fractures.

In examining bones either for injuries or diseases it is essential, where practicable, to make roentgenograms from two different angles. The target of the tube should be centered directly over the lesion to avoid the distortion which occurs if the picture is taken obliquely,

and which may give an entirely erroneous impression of the amount of overriding or separation of the fragments in fractures.

Stereoroentgenograms are invaluable in determining the correct relation of the fragments in fractures and of the articular surfaces in dislocations.

The following practical suggestions are made for roentgenography of the bones and joints in various parts of the body.

The *spinal column* in the dorsal and lumbar regions should be roentgenographed in both the anteroposterior and lateral directions. The lateral view is of especial value in cases of fracture of the bodies of the vertebræ. The dorsal spine can be shown very well with the patient turned obliquely so that the ray enters about two inches outside of the right nipple. This prevents superimposing the shadow of the heart and great vessels upon that of the spine. When taking the lumbar spine and sacroiliac region in the anteroposterior position, it is best to have the knees drawn up so that the lumbar region is flat against the table. Immobilization is very important in pictures of the spine, as indeed it is in all bone pictures. The use of a large rubber bag on the patient's abdomen against which the cone or the tube-holder is pressed very snugly has been found of great value in roentgenographing the lower spine and sacroiliac regions. This bag may also be used to advantage for bone and joint pictures in other parts of the body. A liberal use of sandbags also aids in immobilization.

The Potter-Bucky diaphragm is a valuable aid in securing good roentgenograms of the spine.



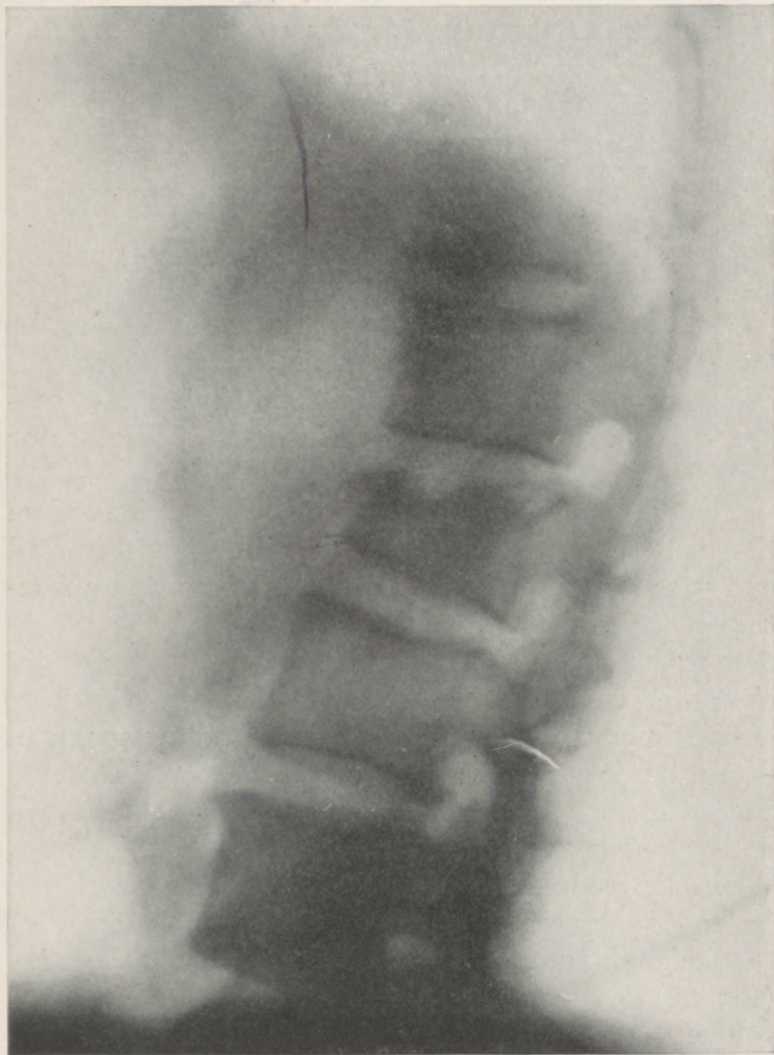

FIG. 24.—Compression fracture of the third lumbar vertebra.

Fractures of the bodies of the vertebræ are much more common than is generally supposed (Fig. 24). They occur most frequently in the lower dorsal and upper lumbar region and diagnosis is often impossible without roentgen examination. It occurs not infrequently that such a fracture is not even suspected and may be discovered a long time after the injury, upon roentgen examination to discover the cause of pain in the back.

The *shoulder* should be roentgenographed with the target centered over the glenoid cavity, the patient being in the supine position. Stereoscopic roentgenograms should always be made in cases of fracture or dislocation of the shoulder.

The shoulder should be taken in two positions when this is possible, that is, with the arm rotated inward and with it rotated outward. If this is omitted a fracture of the greater tuberosity (Figs. 25 and 26) or exudate in the bursae about the greater tuberosity may not show well in the film. In fractures of the surgical neck of the humerus one of the most important points to determine is whether or not there is rotation of the head (Fig. 27), and if so, to what degree. This will determine the angle at which the humerus is to be fixed. When the shoulder is dislocated examination should be made for the presence of impacted fracture of the surgical neck or fracture of the greater tuberosity (Fig. 28).

The *elbow*, *wrist*, *knee* and *ankle* should be roentgenographed both anteroposteriorly and laterally. The side with the lesion should be placed nearest to the plate.

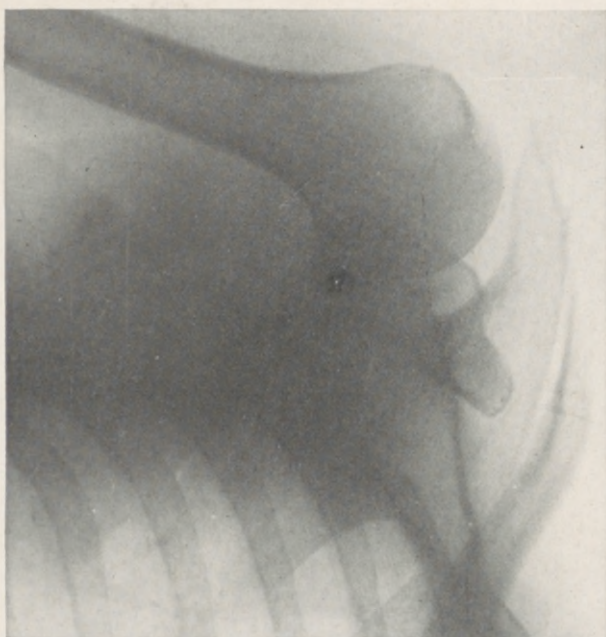


Fig. 25.—Shoulder taken with hand prone and arm rotated inward. Shows no evidence of abnormality.

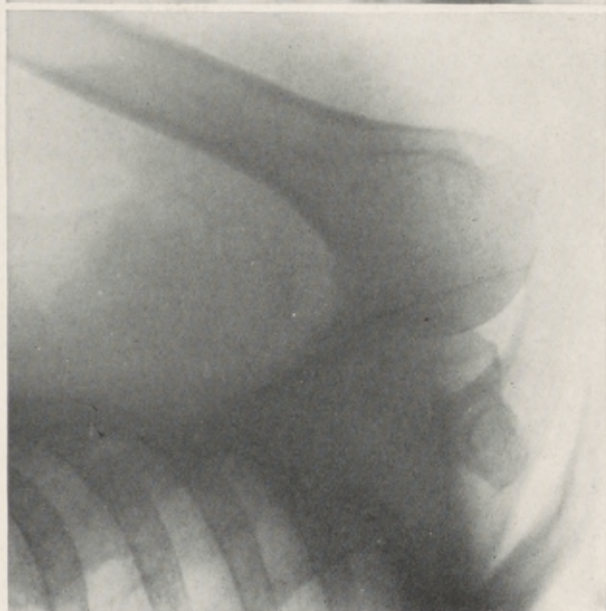


Fig. 26.—Same shoulder as Fig. 25, taken with hand supinated and arm rotated outward; shows fracture of greater tuberosity.



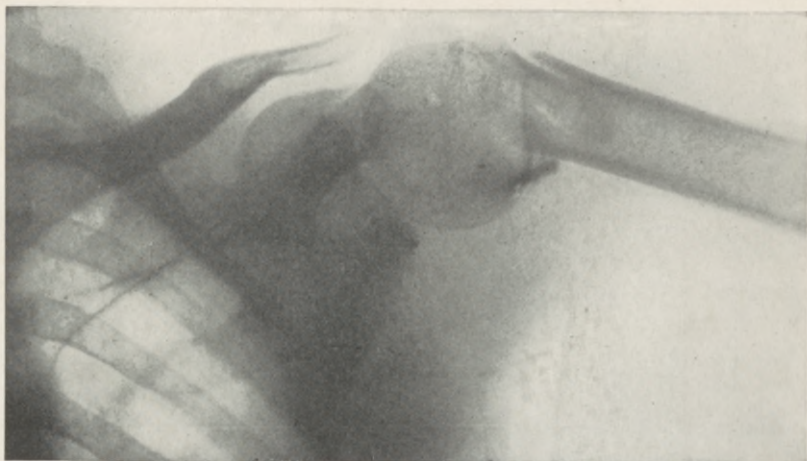

FIG. 27.—Fracture of surgical neck of humerus with upward rotation of head.

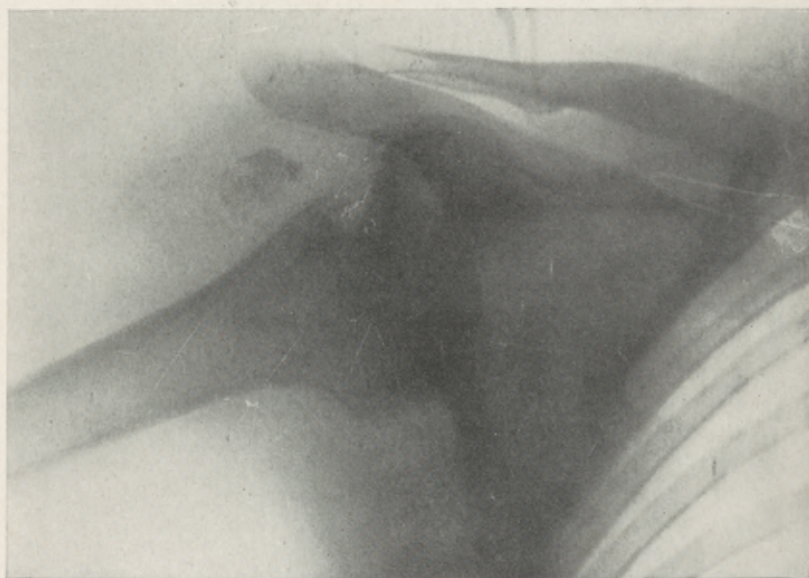

FIG. 28.—Subcoracoid dislocation of humerus with fracture and displacement of greater tuberosity.

It is important to distinguish between epiphyseal displacements and fractures in all localities, but especially about the elbow-joint. In injuries about this joint examine the roentgenograms, especially for dis-

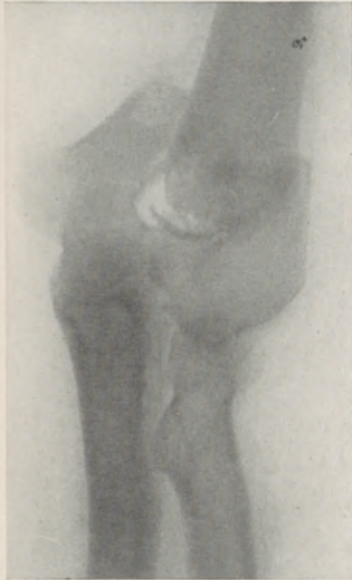

FIG. 29.—Supracondylar fracture of humerus, anteroposterior view.

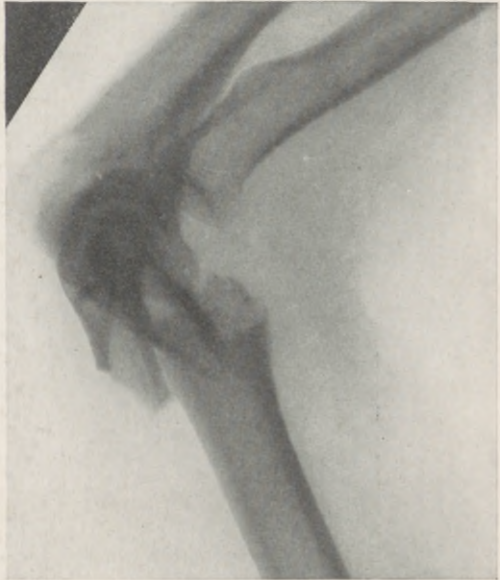

FIG. 30.—Supracondylar fracture of humerus, lateral view.

location of the head of the radius or fracture of its neck. In fracture of the upper third of the ulna always examine for dislocation of the head of the radius as this is a quite constant finding (Fig. 32). In Colles' fracture (Figs. 34 and 35), one of the most important points to settle is the degree of angulation of the distal fragment of the radius. Even backward displacement of this fragment is

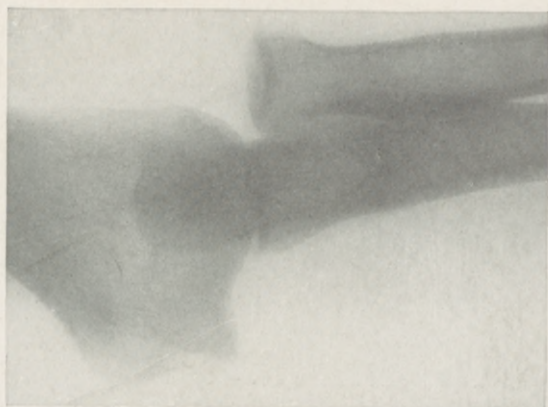


FIG. 33.—Lateral dislocation of both bones at the elbow.

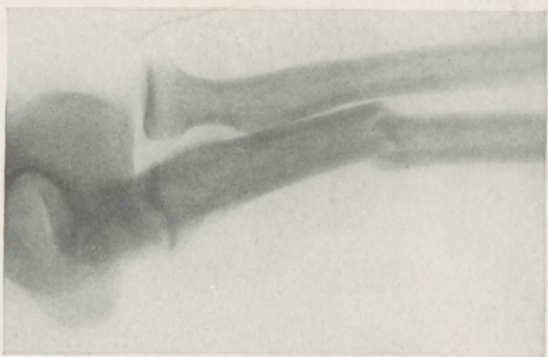


FIG. 32.—Fracture of upper third of ulna with dislocation of radial head.

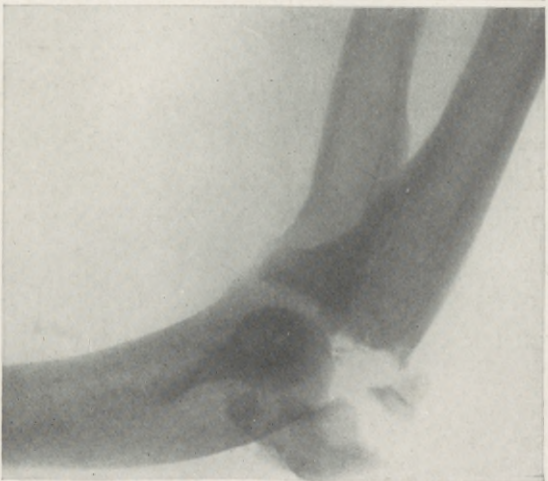

FIG. 31.—Fracture of olecranon.



not so important as backward tilting. It should be remembered that the surface of the radius which articulates with the carpus is normally directed toward the

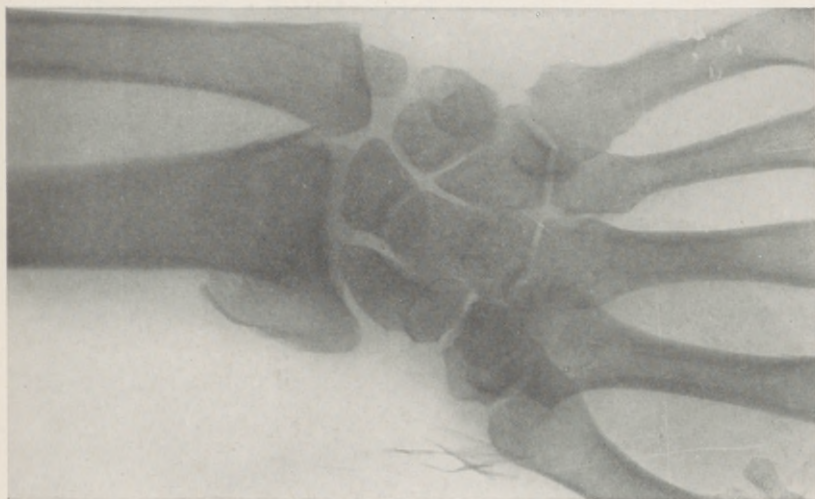


FIG. 34.—Colles' fracture; dorso-palmar view.

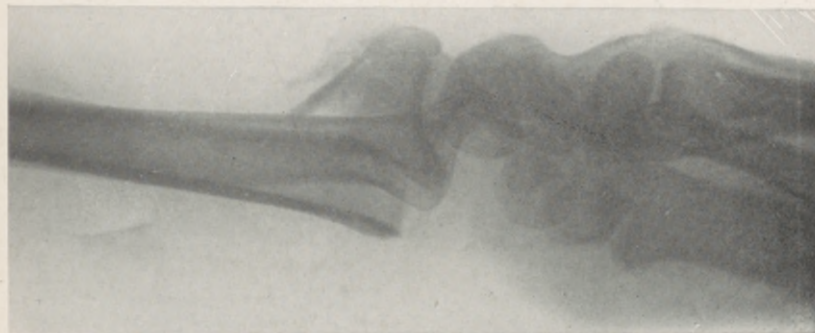

FIG. 35.—Colles' fracture; lateral view.

palm. If it is tilted so as to be directed in any degree toward the dorsal surface considerable deformity and

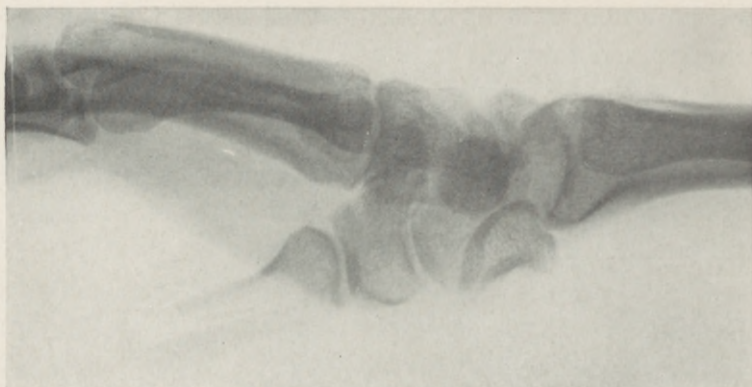

FIG. 36.—Dislocation of semilunar bone.

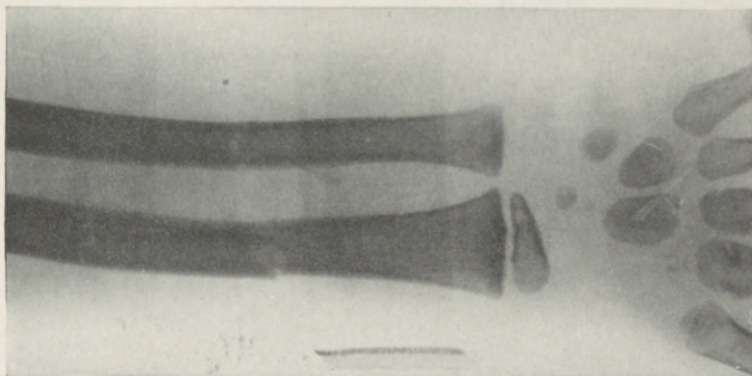


FIG. 37.—Fracture of both bones of forearm; no lateral displacement. Shows the normal epiphysis of the radius; that for the ulna has not yet formed. The carpal bones are only partly ossified.

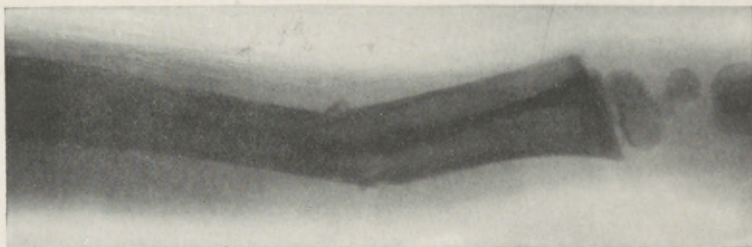

FIG. 38.—Lateral view of same case as Fig. 37; shows angulation at site of fracture.

disability is likely to result. Roentgenograms made for injuries of the wrist should be carefully studied for the

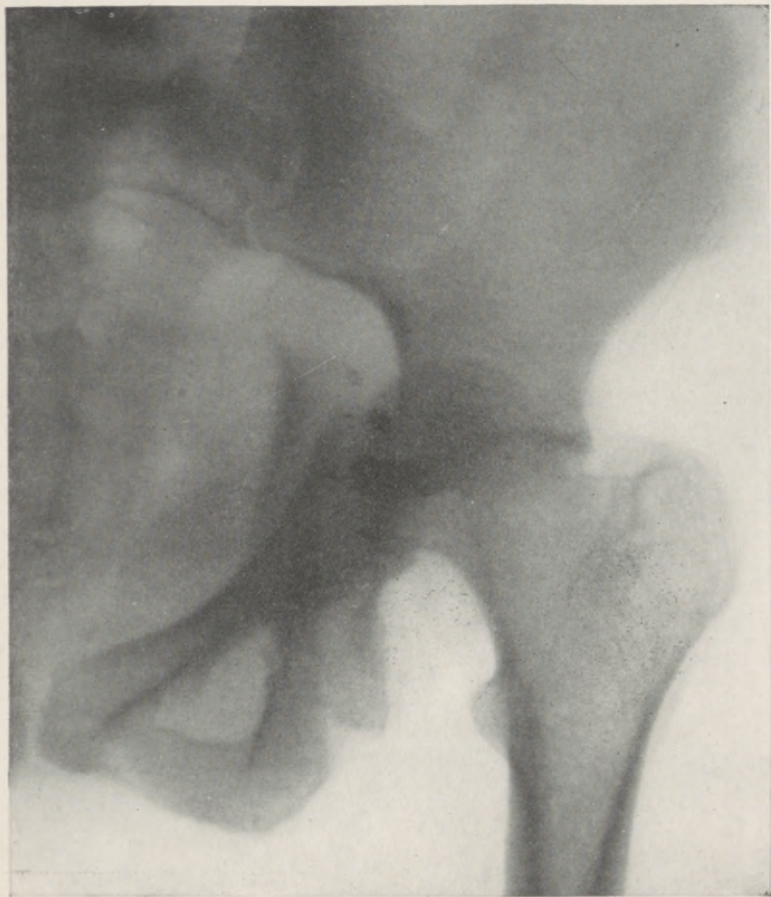

FIG. 39.—Injuries of the hip and pelvis : Fracture through the acetabulum with central dislocation of hip, and fracture of the body of the ischium.

possible presence of fracture of the scaphoid and for anterior dislocation of the semilunar bone (Fig. 36).



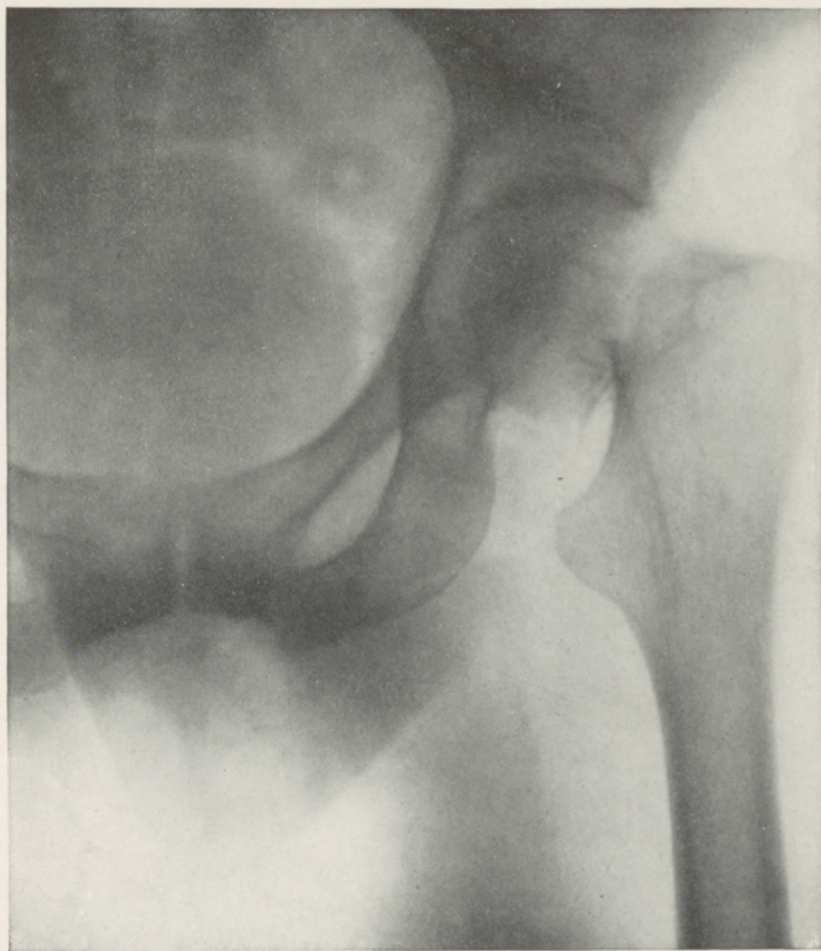


FIG. 40.—Old fracture of neck of femur with absorption of neck.

Roentgenograms of the *hip* are made with the target directly over the center of the acetabulum, the patient usually lying upon the back. In interpreting roentgeno-

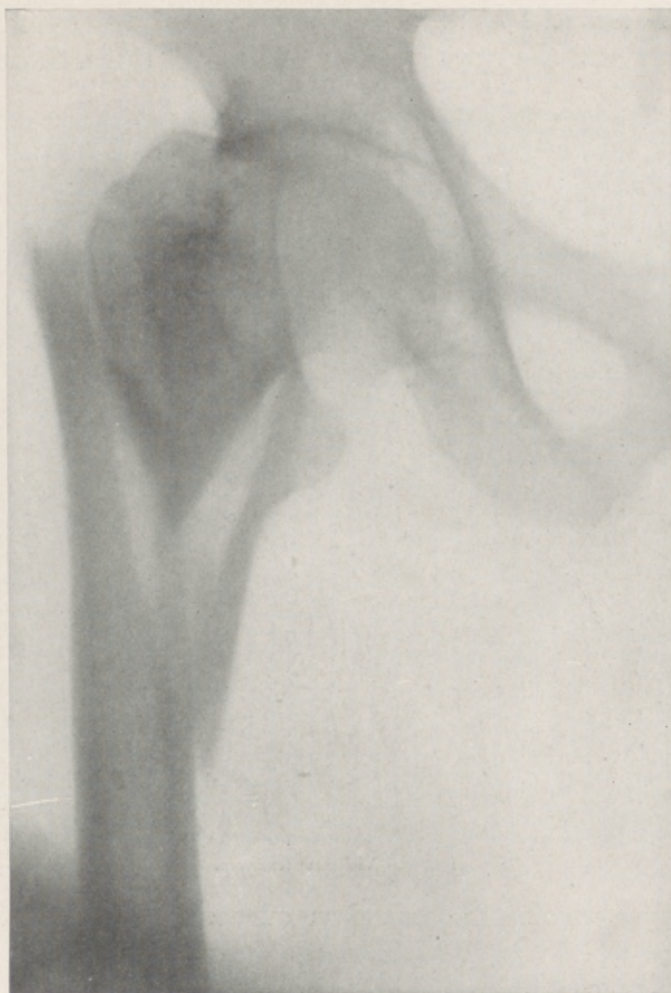

FIG. 41.—Fracture through base of neck of femur and splitting off of a large fragment with the lesser trochanter.

grams of the hip it is important to remember that the arch formed by the under surface of the neck of the femur and the upper border of the obturator foramen

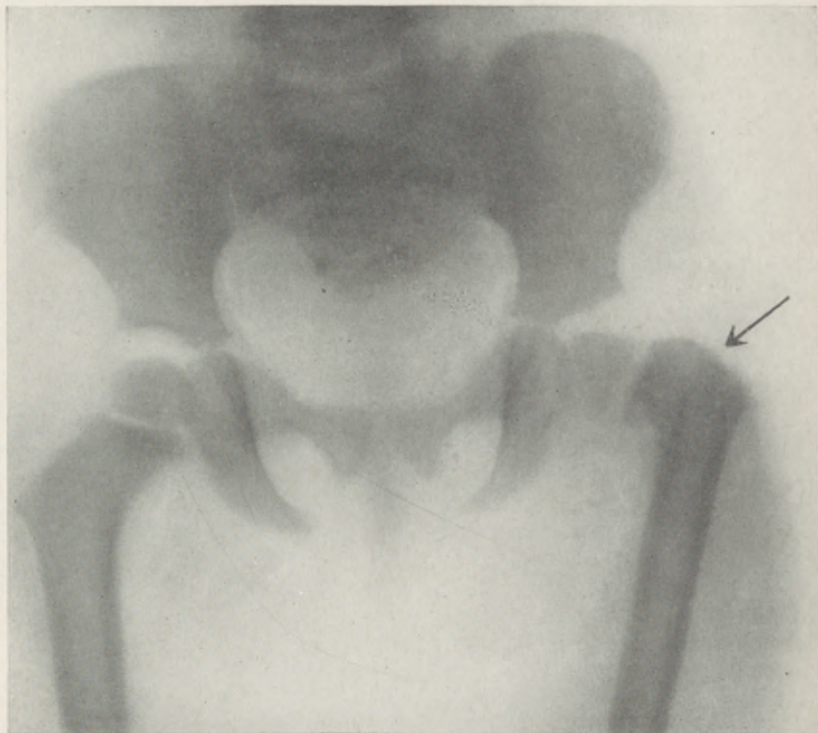


FIG. 42.—Adolescent coxa vara.

normally make an unbroken curve. Good roentgenograms of the hip should show the posterior border of the acetabulum through the head of the femur.

Fractures of the neck of the femur may be overlooked if they are impacted. Any apparent change in the usual angle of the neck and shaft should be carefully scruti-



nized. Here again displacement of the epiphysis (traumatic or adolescent coxa vara) (Fig. 42), should be distinguished from fracture.

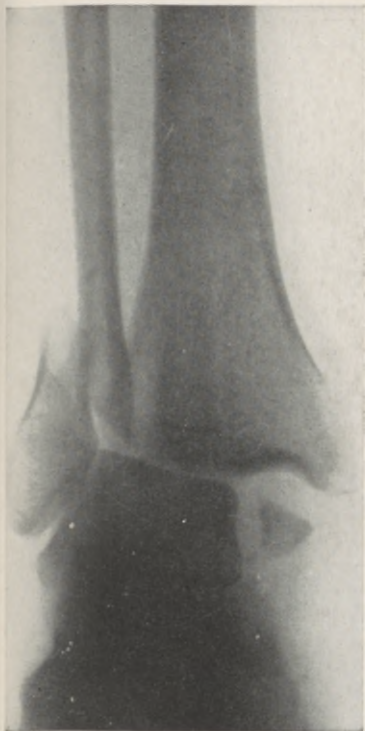

FIG. 43.—Pott's fracture with lateral dislocation of the ankle joint. There is over-riding of the fragments of the fibula and fracture of the internal malleolus.

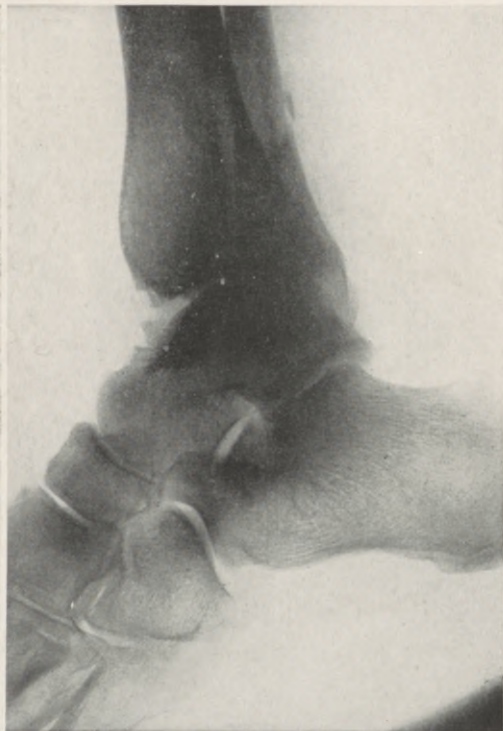

FIG. 44.—Lateral view of same case as Fig. 43.

The normal epiphysis and epiphyseal lines are often causes of incorrect diagnosis of fracture. The roentgenologist must thoroughly familiarize himself with the appearances of the developing bones at different ages

in order to avoid these mistakes. The sesamoid bones in the feet and hands and anomalous bones in all parts of the body may be causes of error.<sup>1</sup>

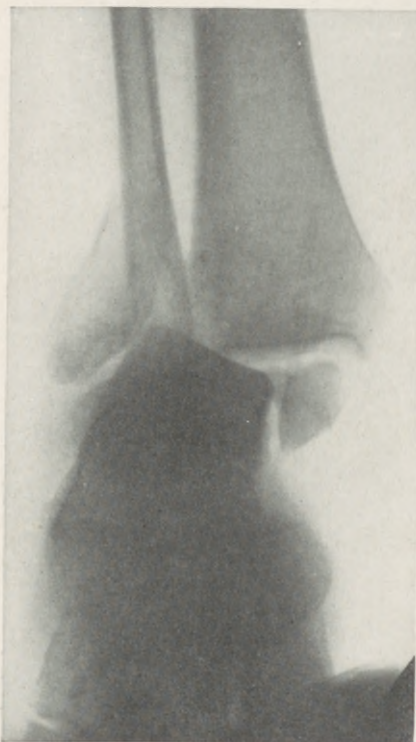


FIG. 45.—Pott's fracture with dislocation. The external malleolus is angulated and displaced upward and there is fracture and outward displacement of the internal malleolus.

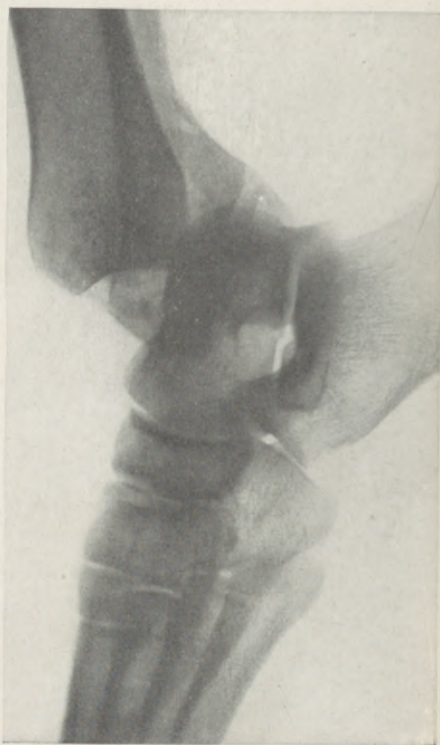
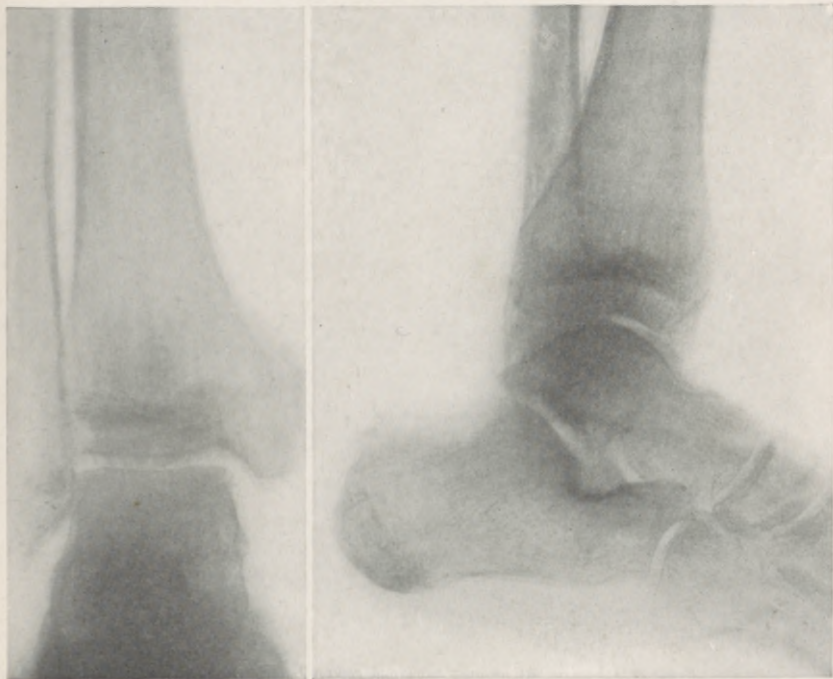


FIG. 46.—Lateral view of same case as Fig. 45, shows the anterior dislocation of the tibia.

Diagnosis of fracture should always be made from plates or films and *never* from the appearance on the

<sup>1</sup>Cohn, Isidore. Normal bones and joints roentgenologically considered. *Annals of Roentgenology*, iv.

roentgenoscopic screen. It is sometimes permissible to attempt reduction under the roentgenoscope, but great care must be exercised not to over-expose the patient or



FIGS. 47 and 48.—Syphilitic periosteitis of the tibia and fibula.

the operators to the roentgen ray. During the pre-occupation of reducing the fracture the time of exposure may be under-estimated and disastrous burns result.

#### DISEASES OF THE BONES AND JOINTS

*Periosteitis* and *osteitis*, whether of traumatic or infectious origin, are usually associated. Early in the disease when there is only periosteal involvement the



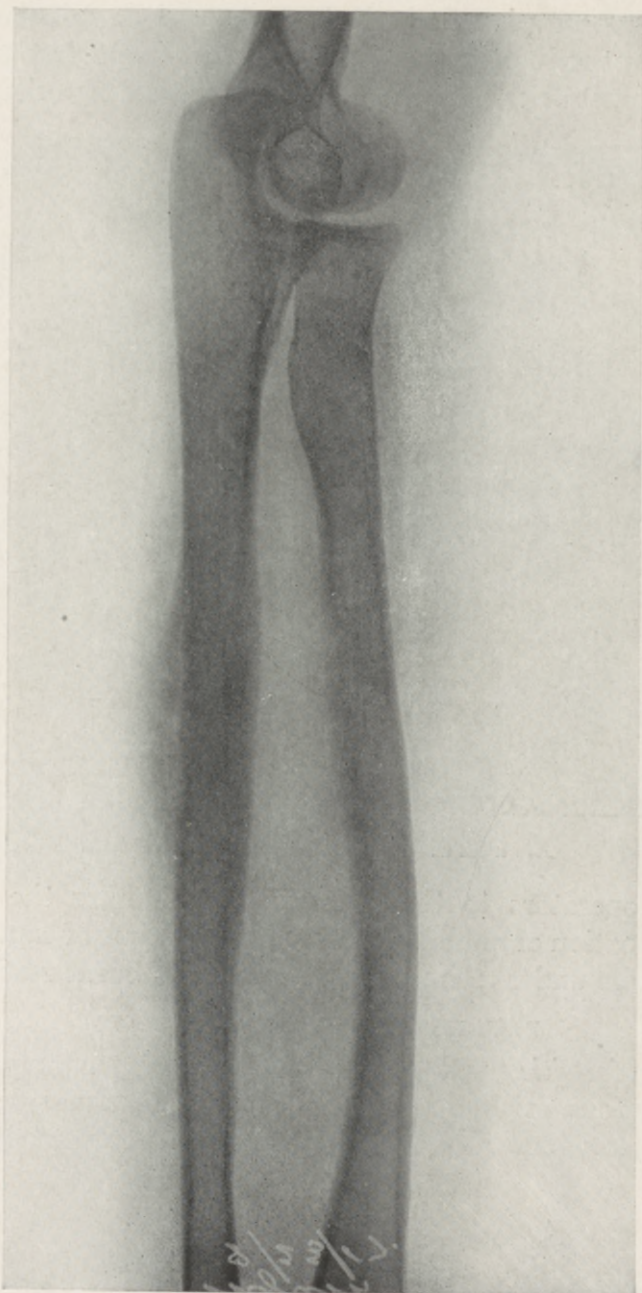


FIG. 49.—Syphilitic periosteitis of the ulna.

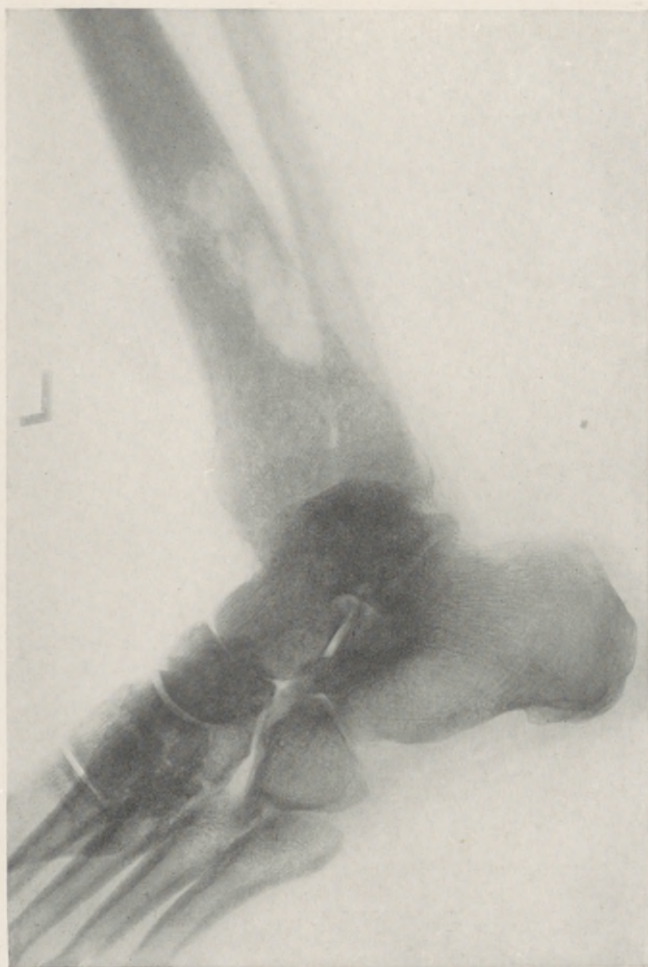

FIG. 50.—Osteomyelitis of the tibia showing periosteal thickening and extensive destructive changes in the bone.

only thing to be seen in the roentgenogram is a fine line outside of the cortex and parallel to the shaft (Figs. 47 and 48). Later there may be a bulging in the contour

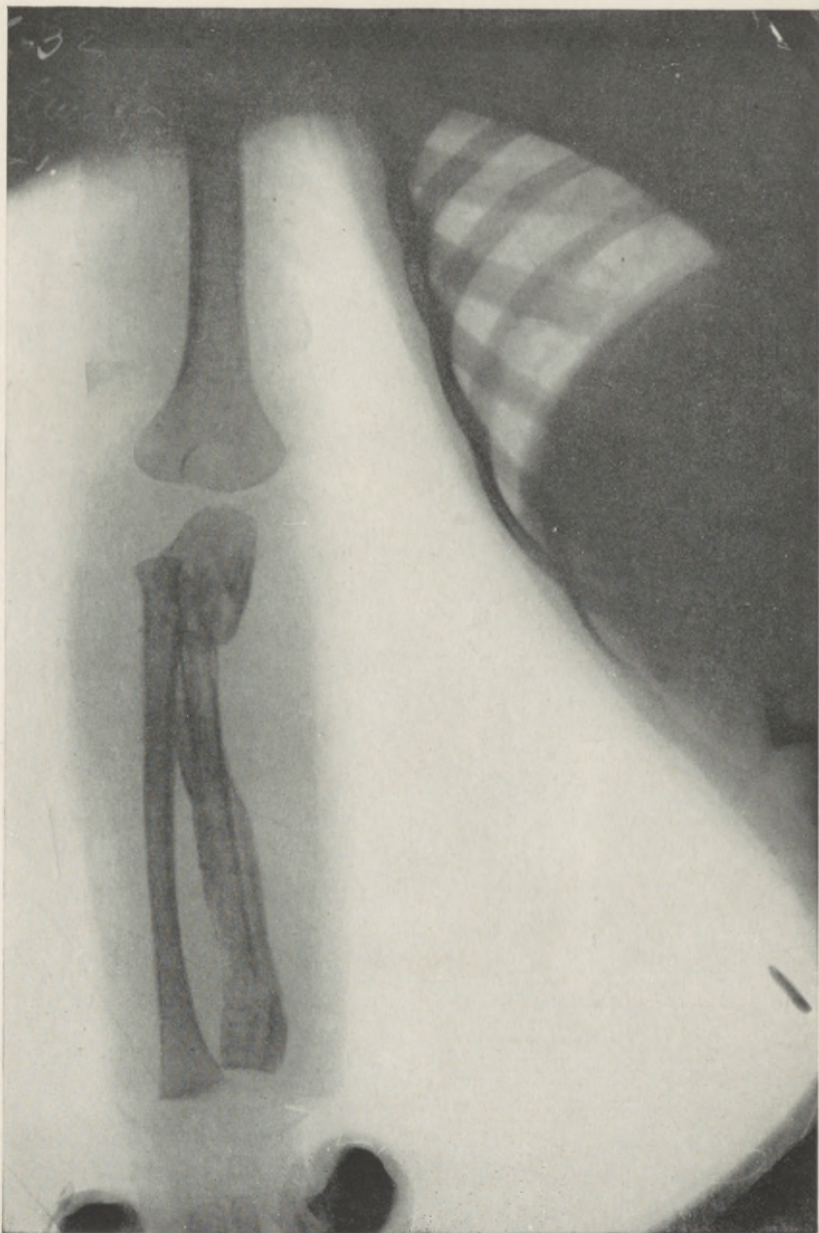


FIG. 51.—Osteomyelitis of the entire ulna. Almost the entire shaft is a sequestrum surrounded by an involucrum.



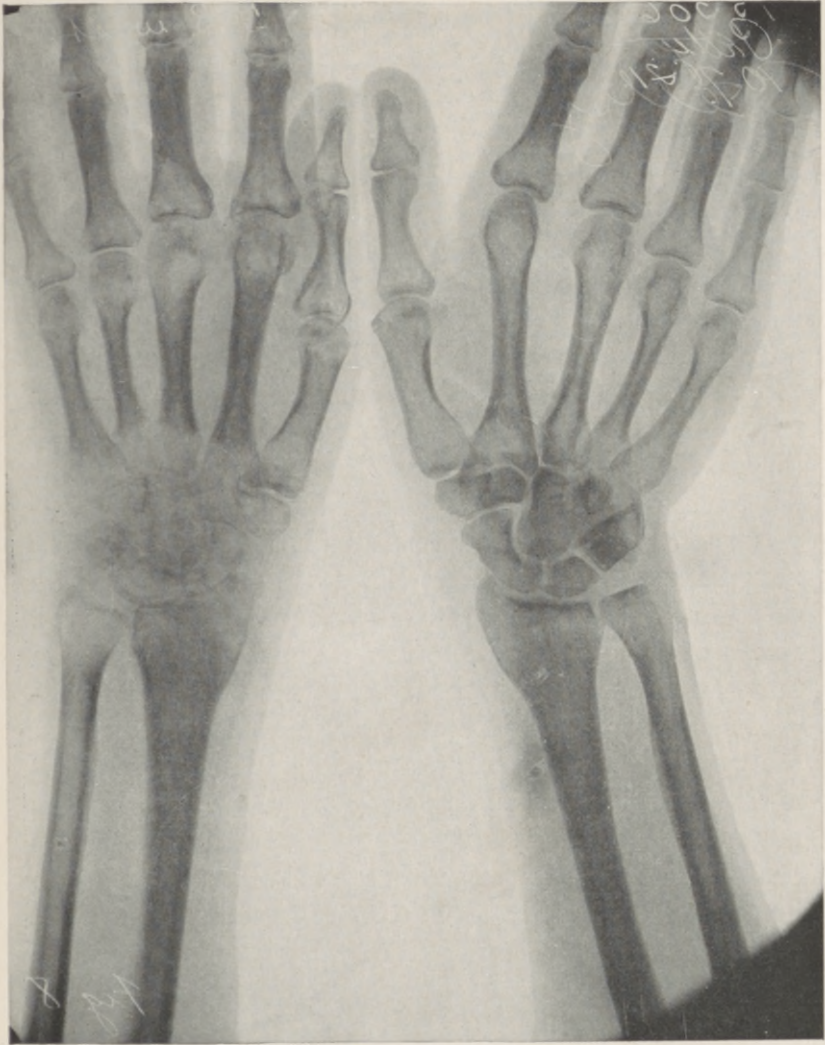

FIG. 52.—Tuberculosis of the left wrist, involving the heads of the radius and ulna, the carpal bones and bases of the metacarpals.

of the bone at the site of the lesion (Fig. 49). Later, a distinct shadow is produced by the exudate thrown out; and later still the dense shadows due to sclerotic changes are seen. Periosteitis occasionally occurs alone as a result of trauma, but it is often associated with osteomyelitis of infectious or syphilitic origin.

*Osteomyelitis* (Fig. 50) shows the exudative and sclerotic changes of periosteitis and osteitis, but in addition, changes due to bone destruction are evident. Well-marked abscesses and cavities due to necrosis are present. In older cases sequestra are seen (Fig. 51). The course of sinuses through the bone and soft tissues may be marked out by injecting bismuth paste. To show the exact course and relations of the sinus stereoroentgenograms should be made. In chronic osteomyelitis new bone formation takes place with the production of areas of bone that are much denser than normal. Areas of bone destruction and of new bone formation may alternate, giving the bone a ragged or "moth-eaten" appearance. A point of great importance in diagnosis is that there is a period early in acute osteomyelitis when the medullary and Haversian canals may contain pus but when no bone destruction has occurred. The roentgenogram at this time will show no noticeable departure from the normal. A statement that osteomyelitis is absent should therefore not be made on the evidence of the roentgenogram alone. //

**TUBERCULOSIS.**—The distinguishing characteristic of tuberculosis of bone is the absence of lime salts, causing the shadow of the bone to appear faint and indistinct (Fig. 52). It usually attacks the epiphyses and

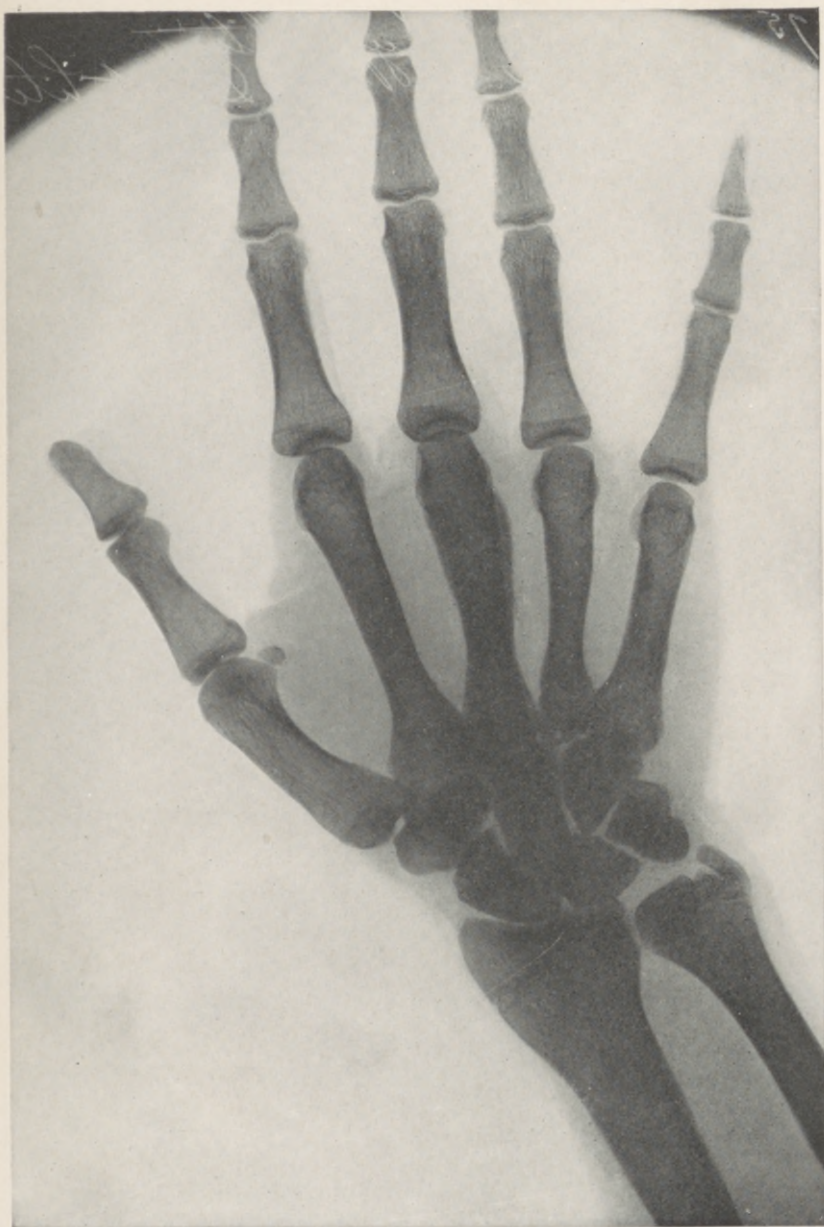

FIG. 53.—Syphilitic dactylitis—an osteo-periosteitis.



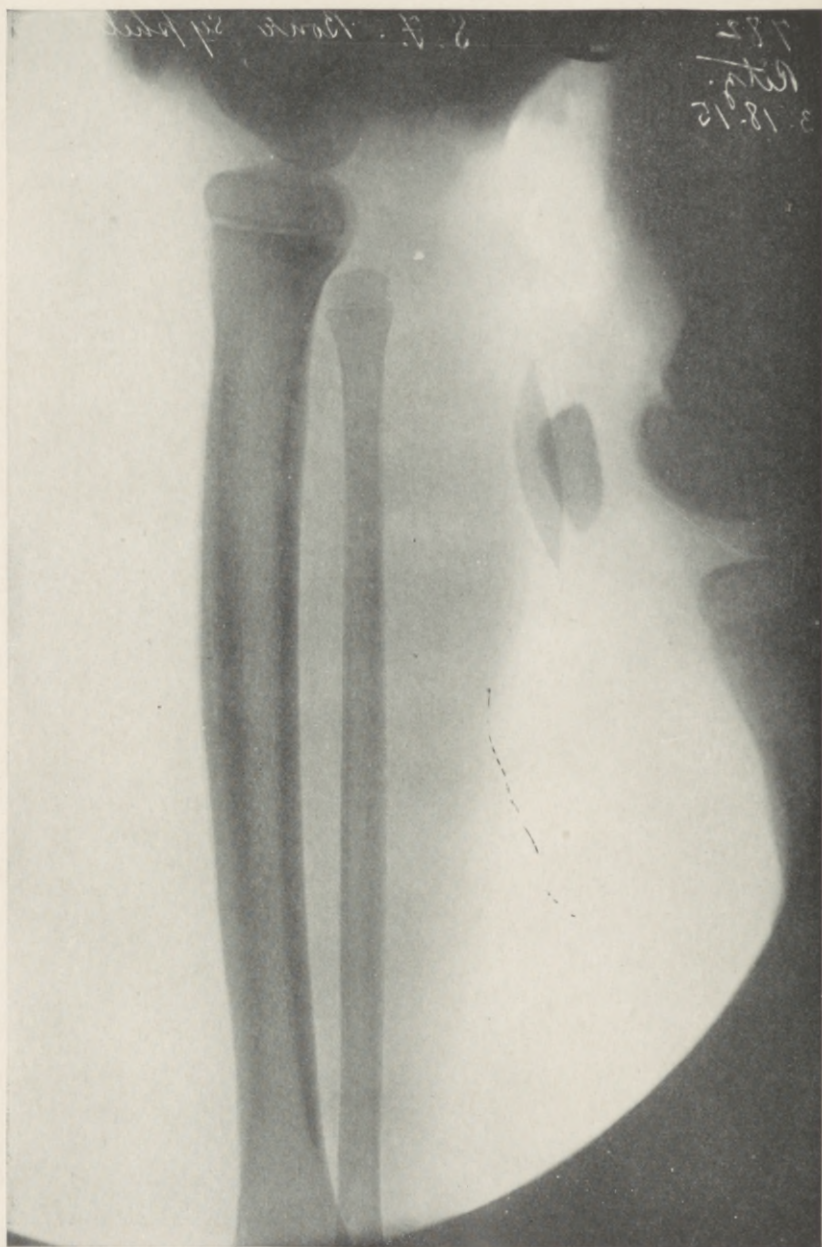


FIG. 54.—Bone lesion of congenital syphilis; typical thickening of cortex of tibia.

seldom involves the periosteum, the contrary being the case with syphilis. When the disease begins in the joint there are at first no changes that can be shown in the roentgenogram. Later the presence of fluid or periarticular thickening may give an indistinct, hazy appearance in that joint as compared with its fellow on the opposite side; but this is not peculiar to tuberculosis. Cartilage destruction may later take place and evidence of this may be seen on the roentgenogram, in that the articular surfaces are closer together than they are on the normal side. Cartilage itself is not opaque to the roentgen ray and therefore casts no shadow. When the tuberculous disease attacks the bone there is bone destruction and the joint surfaces become rough and uneven. The disease rarely involves the shafts of long bones and when it does the roentgenogram is not characteristic. Tuberculous dactylitis sometimes occurs and is identical in appearance with syphilitic dactylitis (Fig. 53).

Tuberculous spondylitis produces first a general haziness in outline of the affected vertebræ; later areas of erosion occur, and finally, collapse of the bodies. The shadow of tuberculous abscess of the spine sometimes shows on the roentgenogram

**Syphilis.**—Periosteitis resulting in permanent thickening of the cortex is the most common bone lesion of congenital syphilis (Fig. 54). There are also in some cases marked changes in the diaphysis close to the epiphyseal line (Fig. 55). It is distinguished from rickets by the absence of flaring of the bone at the epiphyseal line, and from scurvy by the fact that subperiosteal hemorrhages are not present.

Syphilitic osteomyelitis (Fig. 56) cannot be distinguished on the roentgenogram from osteomyelitis of

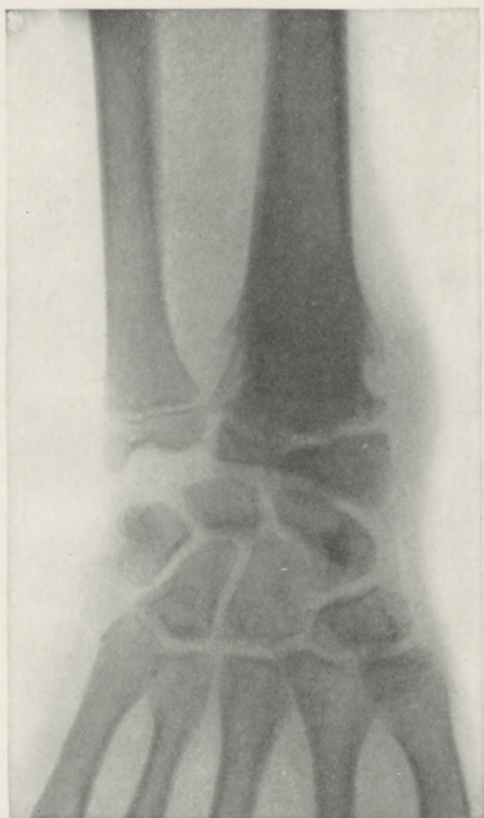

FIG. 55.—Bone lesion of syphilis. Changes in diaphysis of radius near to epiphyseal line.

infectious origin. In the syphilitic type, however, several bones may be involved and the disease is usually painless and is not accompanied by the usual signs of an inflammatory process.



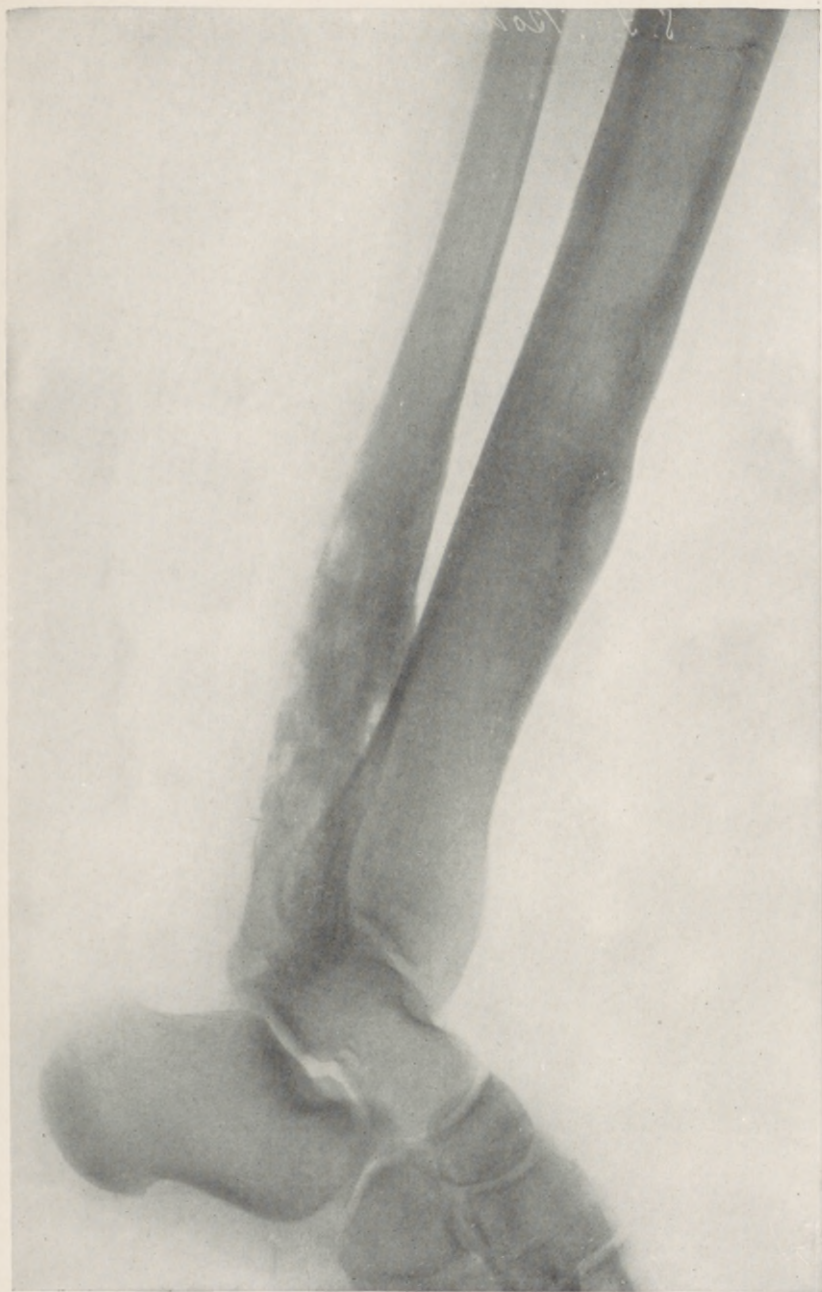

FIG. 56.—Syphilitic osteomyelitis of the tibia and fibula.

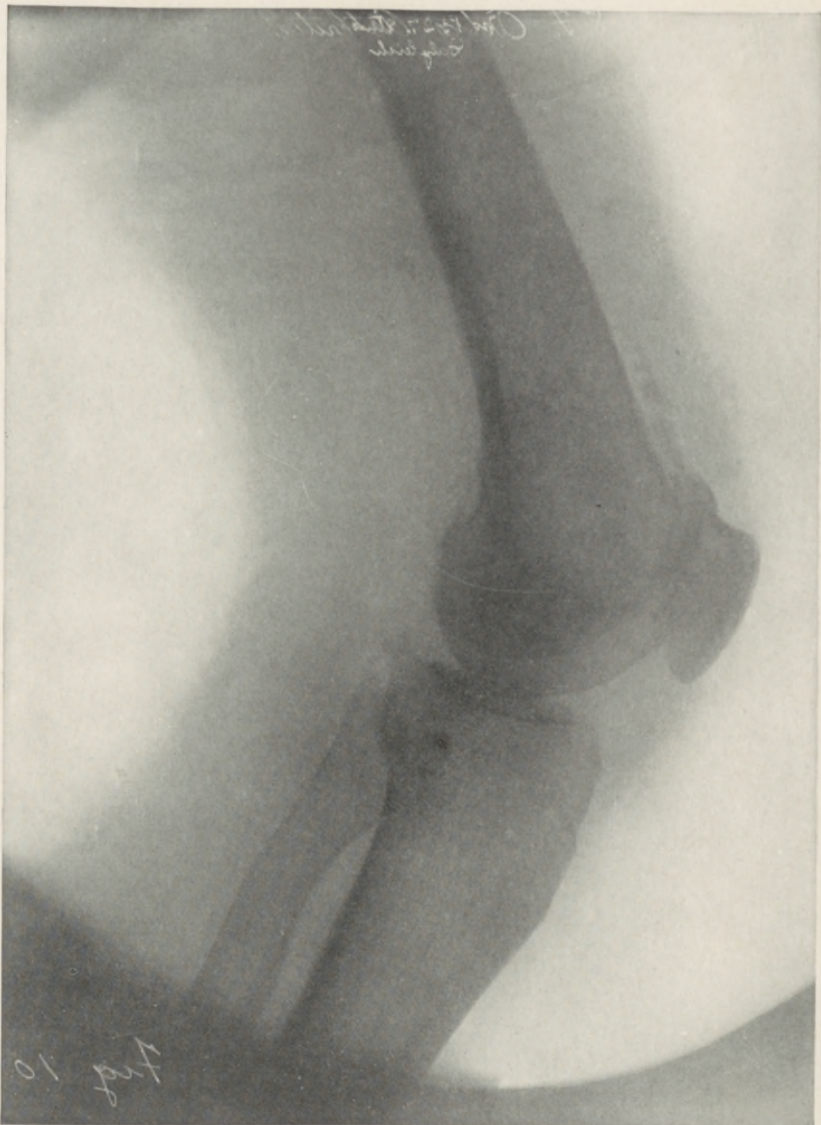


FIG. 57.—Hypertrophic osteo-arthritis of the knee.

**Chronic Arthritis (Arthritis Deformans).**—The roentgenographic appearances of the bones and joints in this disease vary greatly, from almost no change whatever to evidence of extensive atrophic and hypertrophic alterations in the cartilages and bone, resulting often in great deformity. Goldthwaite recognizes an infectious, a hypertrophic and an atrophic type of this disease. The infectious type produces both atrophic and hypertrophic changes and may thus at times simulate either the atrophic or hypertrophic type of the disease. The infectious type begins with the presence of exudate in the joint, and the only change to be seen in the roentgenogram is a blurring of the joint outlines. Destruction of cartilage is the next stage, evident on the roentgenogram by the fact that the bones are closer together than on the normal side. When the articular surfaces of the bones become involved there is actual bone destruction producing an irregular, ragged appearance. Subsidence of the infectious process brings on the hypertrophic stage when the destroyed areas are replaced by fibrous tissue or bone and considerable bony overgrowth takes place about the joints, resulting in exostoses (Fig. 57), “lipping” at the edges of the articular surfaces or actual ankylosis.

It is not certain that there is a distinct atrophic type of chronic arthritis. It seems more probable that it is a stage of an infectious process (Fig. 58).

There is, however, a distinct type of the hypertrophic form, which occurs in people at or beyond middle life and which does not run the course of infectious arthritis. It is characterized by localized cartilage destruc-



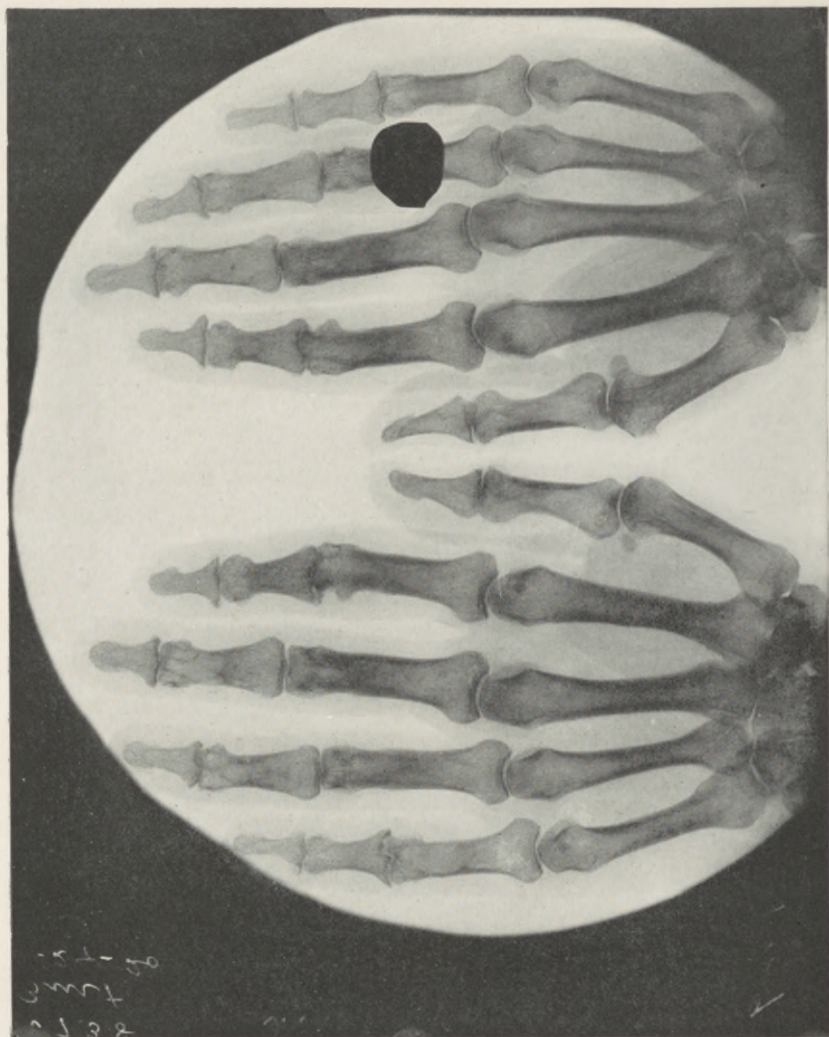


Fig. 58.—Atrophic osteo-arthritis, involving many joints of the hands and accompanied by cystic changes in the phalanges.

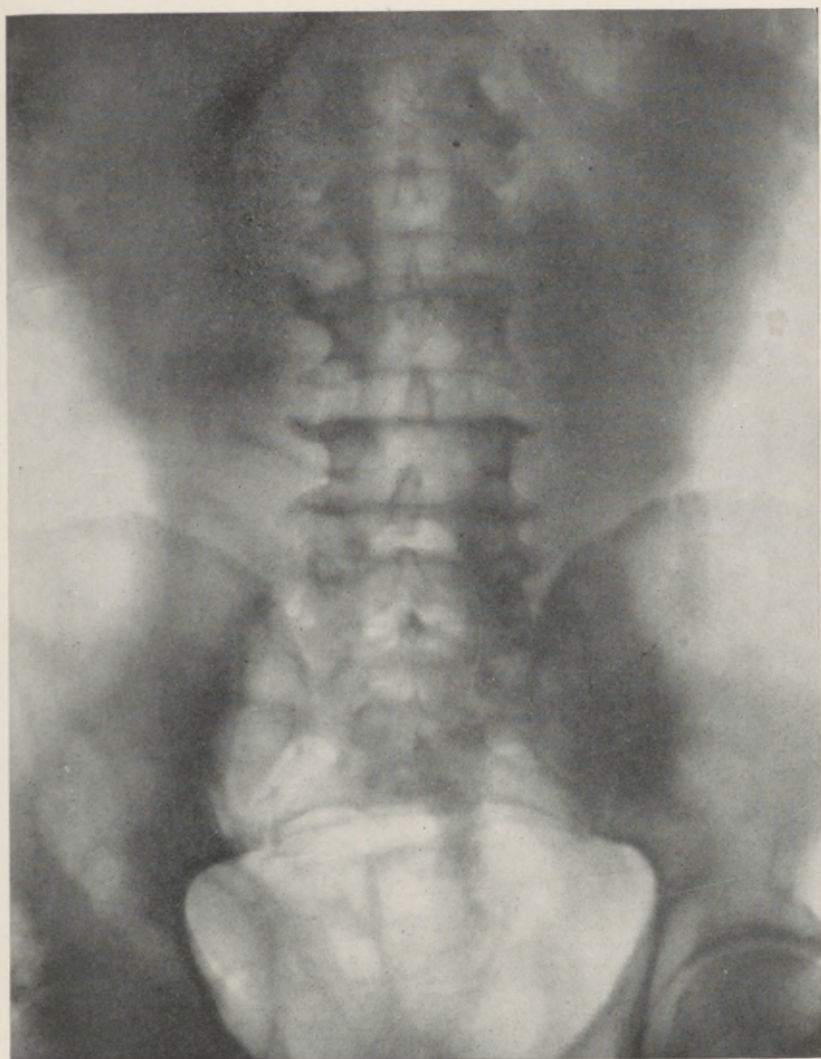

FIG. 59.—Hypertrophic osteo-arthritis of the spine.

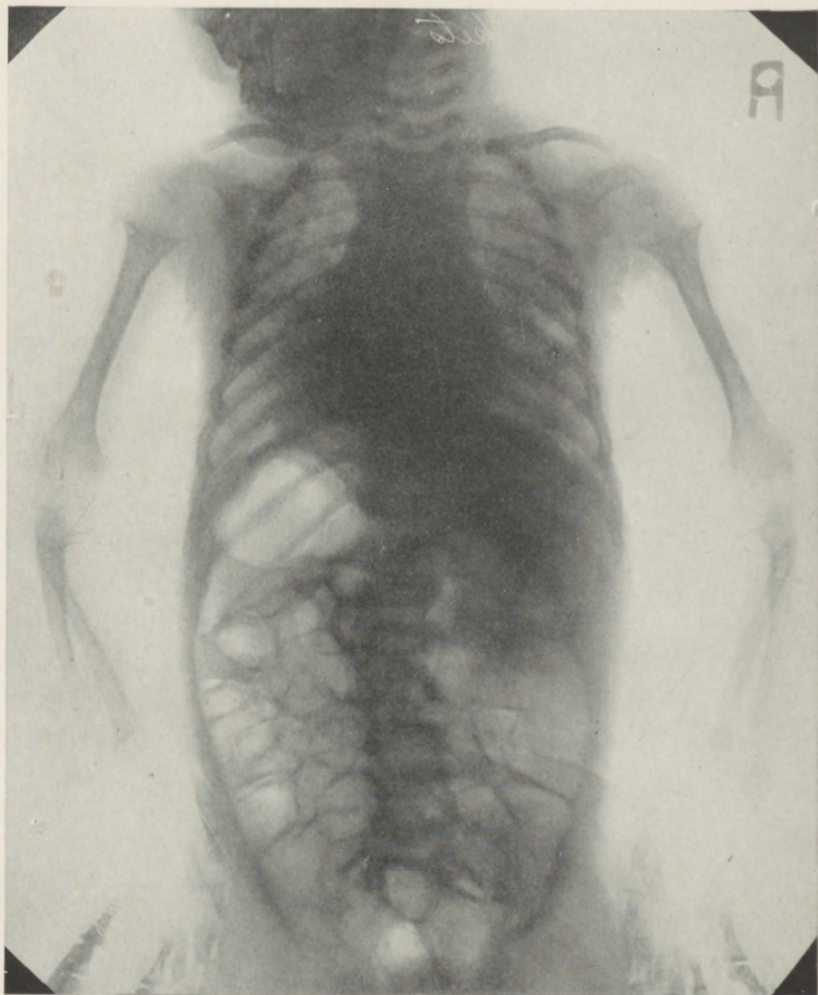

FIG. 60.—Rickets. Note the flaring of the bones at the epiphyseal lines.



tion and formation of new bone. It results in exostoses and formation of free calcified nodules in and about the joints (Fig. 59).

**Rickets.**—This is a disease of early life which involves

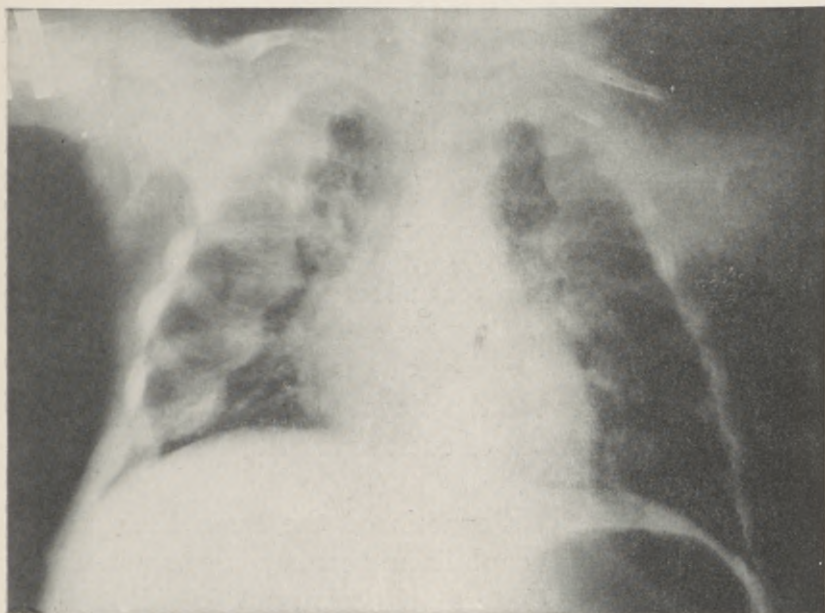


FIG. 61.—Atelectasis along inner margin of each lung, due to pressure at the costochondral junction in rickets.

both the bones and joints. The lesions are multiple. The most characteristic change occurs at the epiphyseal lines and results in a widening or flaring of the bones at those points (Fig. 60). There is general deficiency of calcium salts in the bones resulting in the characteristic bowing of the long bones and in the frequent occurrence of fractures. The expansion and concave deformity at the epiphyseal line occurring at the ends of the ribs pro-

duces a characteristic appearance known as the "rachitic rosary." In rickets there is usually no evidence of periosteitis as in congenital syphilis, and in the latter disease there is no expansion at the epiphyseal line as in rickets. A common change in infants and young children is the occurrence of an atelectatic strip in each lung parallel to and adjoining the mediastinum. It is due to pressure upon the main bronchial trunks by the swelling at the costochondral junctions (Fig. 61).

**Scurvy.**—The bone changes of scurvy consist of a sharply localized area of bone destruction accompanied by periosteitis and often by subperiosteal hemorrhage. These changes take place at the epiphyseal line but unlike those of rickets they are entirely on the side of the diaphysis. The subperiosteal hemorrhage may become organized and lead to the diagnosis of new growth. The roentgen appearance of such hemorrhages is, however, quite characteristic.

The differential diagnosis of the bone changes of rickets, congenital syphilis and scurvy, are summarized by Baetjer and Waters<sup>1</sup> as follows: "In rickets the changes are confined to the epiphyseal line; in lues the epiphyseal line and bone behind it are involved while in scurvy the epiphyseal line is intact and all the changes, comprised in a zone of destruction, take place just behind the epiphyseal line. In rickets there is seldom periosteitis; in lues there is marked periosteitis, while in scurvy the periosteitis is frequently accompanied by

---

<sup>1</sup>Baetjer, Frederick H., and Waters, Charles A. *Injuries and Diseases of the Bones and Joints. Their differential diagnosis by means of the roentgen rays.* 1921 New York.

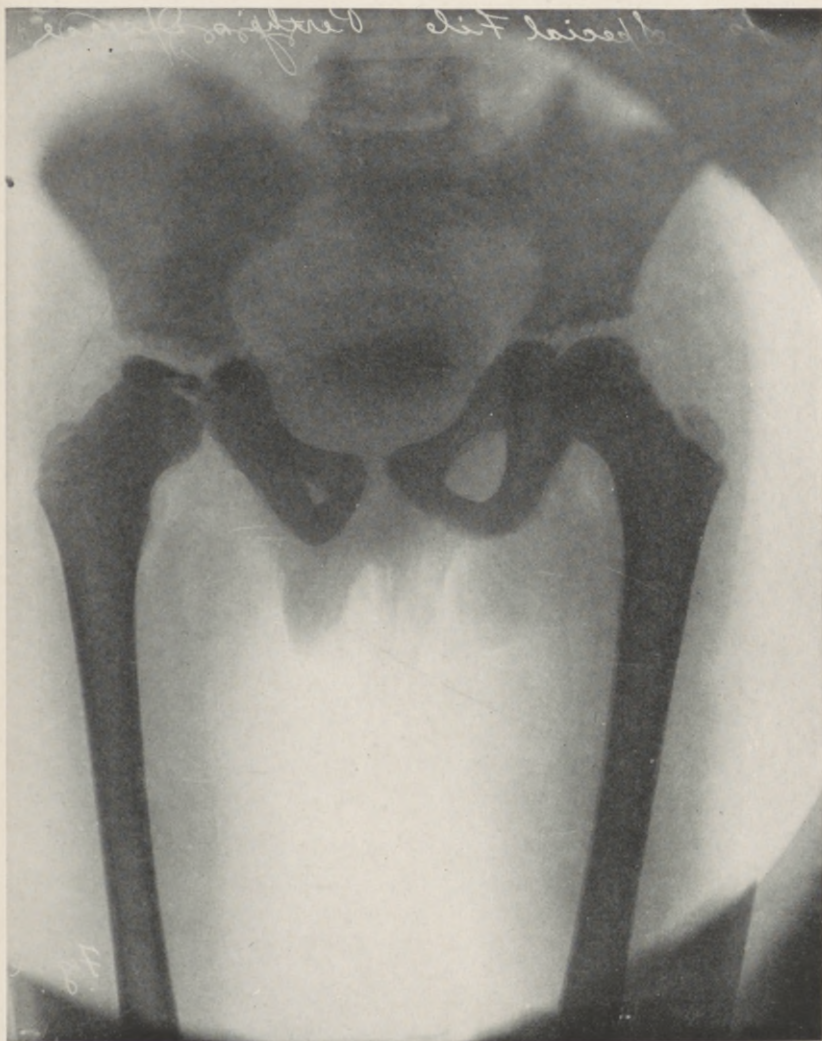


FIG. 62.—Perthes' or Legg's disease.



subperiosteal hemorrhages. In rickets we have atrophy and frequently multiple fractures, while in lues and scurvy there is generally but slight atrophy and there are no fractures."

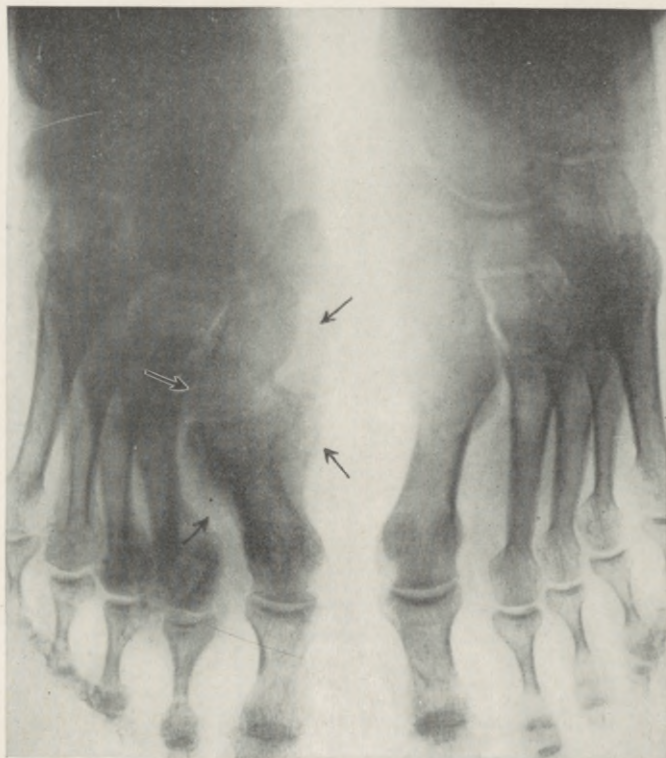

FIG. 63.—Charcot's joint.

**Perthes' or Legg's Disease (Fig. 62).**—This is a disease of the head of the femur which is practically always mistaken clinically for tuberculosis. The disease is a destructive process confined to the epiphysis of the head

of the femur. It does not produce the great destruction often seen in tuberculosis, and recovery is more rapid. The roentgenogram shows a characteristic flattening of the head of the femur and there is often slight coxa vara.

**Charcot's Joint.**—This disease is due to changes in the nervous system which are a late manifestation of syphilis. It is most frequent in the knee, ankle and hip but has been seen by the author in the spine, shoulder, tarsal and metatarsal bones (Fig. 63), and in various other localities. The disease causes extensive destruction of all the joint structures including the bones. None of the parts of a normal joint may be recognizable in the roentgenogram, the entire area being filled with bony detritus and calcified material.

**Paget's Disease (Osteitis deformans).**—This is a disease of middle or late adult life. It appears to be a chronic inflammatory process and goes through stages of destructive and proliferative osteitis. The disease sometimes involves only a single bone but on the other hand nearly all the bones in the body may be affected. The roentgenogram shows areas of rarefaction, of proliferation and of cyst-like cavities, all of which may be present at once in the same bone. The proliferative changes in the long bones are very characteristic, consisting of longitudinal striæ and areas of sclerosis (Fig. 64). The latter are often marked in the tibiæ and especially in the skull (Fig. 65), where they form knob-like projections. The irregular proliferative changes in the tibiæ often cause marked bowing of the legs.

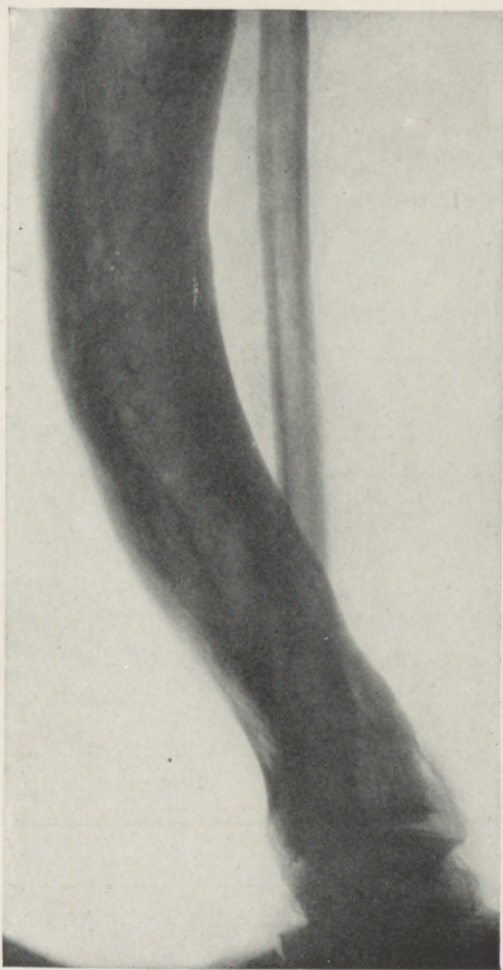

FIG. 64.—Paget's disease, showing the typical bowing and trabeculation of the bone.



**Osteitis fibrosa cystica** (Figs. 66, 67 and 68).—This disease causes bone changes which are in many cases

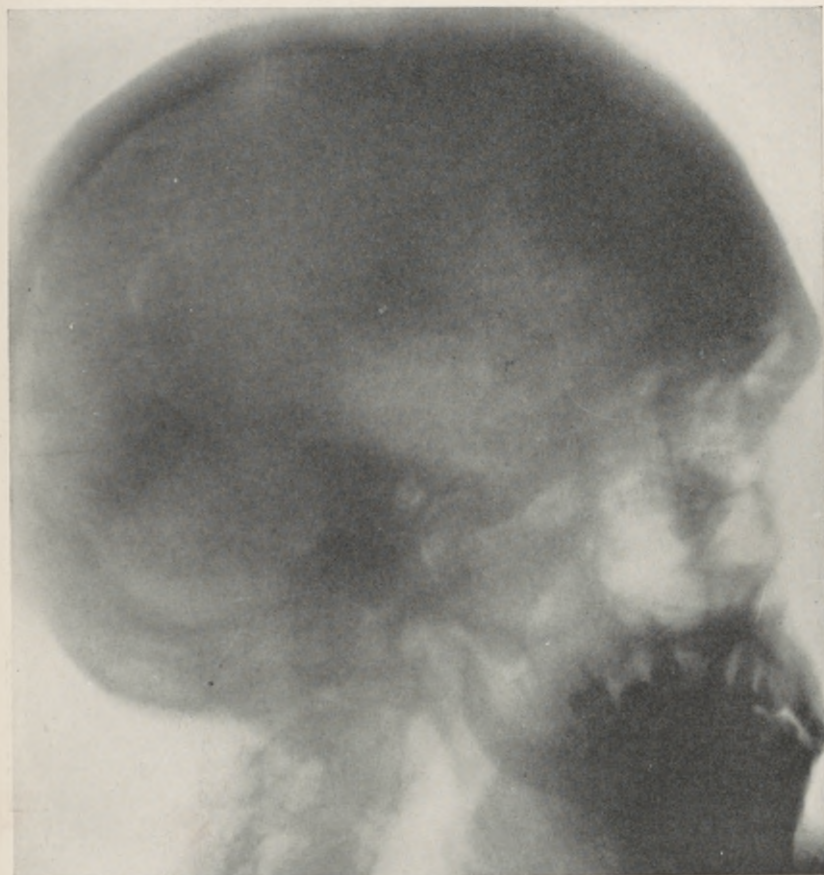


FIG. 65.—Paget's disease, showing the thickening of the cranial bones.

characteristic. There is usually a general expansion of the involved area of the bone and the bone structure is replaced by longitudinal trabeculæ, enclosing cystic

areas of various sizes. The shafts of the long bones are involved more often than other localities. When the disease attacks many bones of the body it has been called von Recklinghausen's disease.

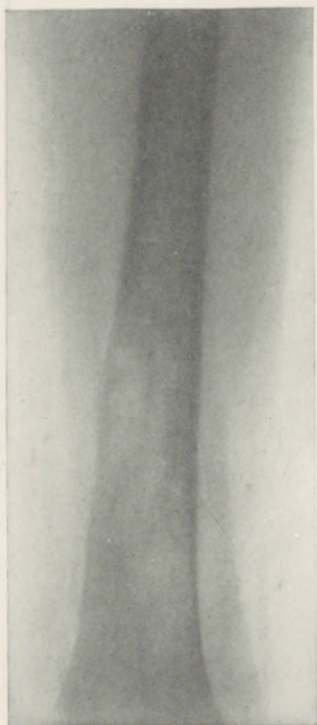


FIG. 66.—Osteitis fibrosa cystica of the femur.

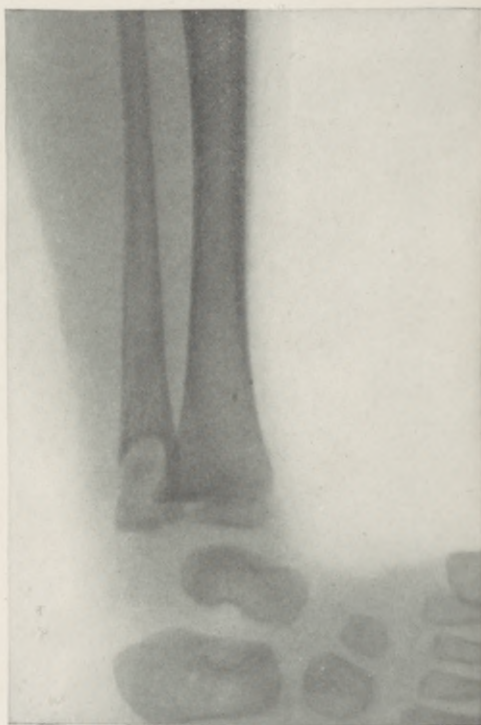

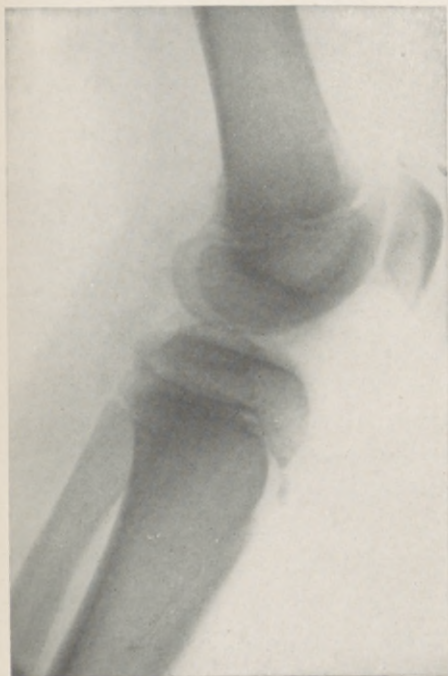FIG. 67.—Osteitis fibrosa cystica involving the extremity of the diaphysis of the fibula.

Schlatter's Disease (Figs. 69 and 70) occurs in adolescents as a result of trauma and consists in an enlargement and deformity of the tibial tubercle. It is accompanied by pain and localized tenderness.


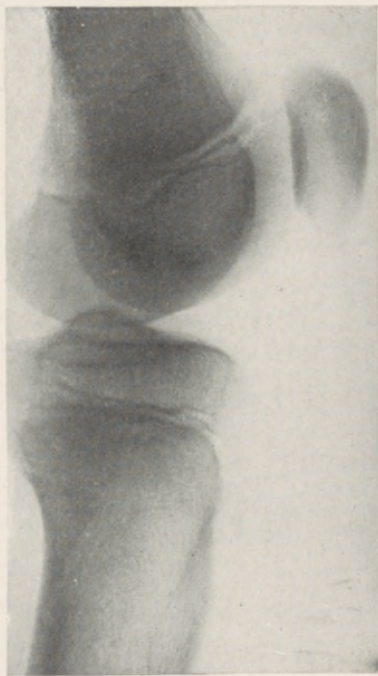


FIG. 68.—Osteitis fibrosa cystica with fracture through cyst of humerus.



FIGS. 69 and 70.—Schlägler's disease.



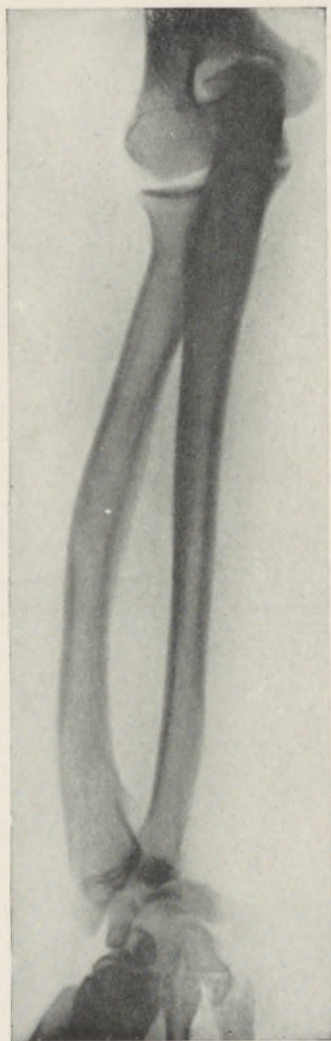


FIG. 71.—Madelung's deformity.

**Madelung's Deformity** is a subluxation of the wrist which comes on spontaneously. The roentgen appearance is characteristic (Fig. 71).

**Sprengel's Deformity** (Fig. 72) is a unilateral, or rarely bilateral, elevation of the scapula, of developmental origin. The scapula is often deformed, the clavicle shortened and there may be associated abnormalities such as exostoses and abnormal articulations in the spinal column.

**Osteogenesis Imperfecta.**—This is a rare condition occurring during fetal life or in early childhood. It is characterized by deformities of the long bones and multiple fractures (Fig. 73).

**Bursitis.**—The bursæ in various parts of the body are subject to inflammatory processes, the results of which may give a characteristic appearance in roentgenograms.

This is a shadow produced by a deposit of lime salts in the bursa. The sub-acromial bursa is one of those most commonly involved.

Figure 74 shows the characteristic roentgen appearance. The shoulder should always be roentgenographed in the two positions previously described in order to make

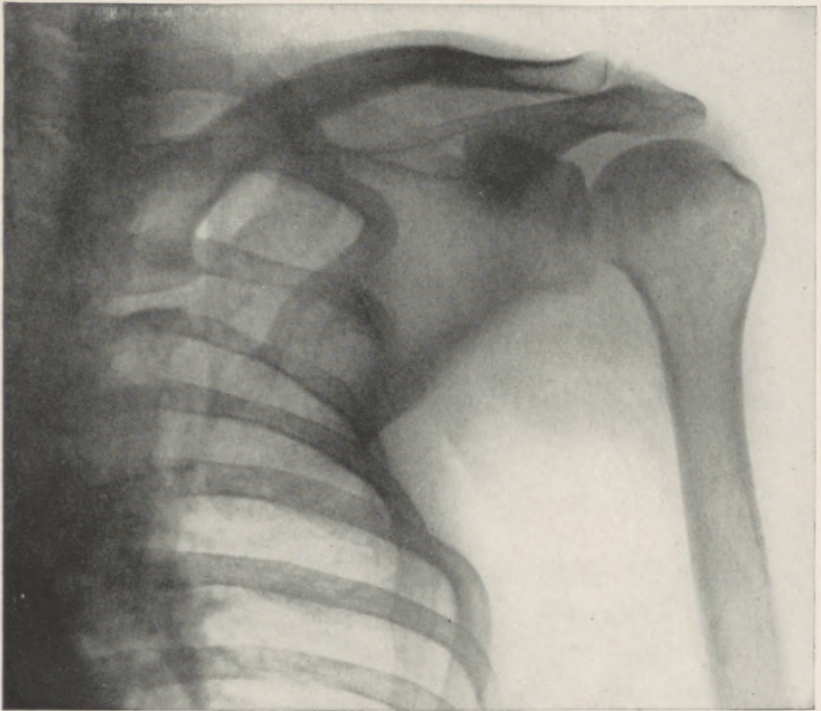


FIG. 72.—Sprengel's deformity.

certain that the shadow of the lime containing bursa is not superimposed upon the head of the humerus.

It should not be assumed that pain in the shoulder is always due to disease or injury in the shoulder itself or in the adjacent bursæ. There are many causes of reflex pain in the shoulder. One of the most common, to

which attention has not been sufficiently directed, is apical tuberculosis. When the roentgen examination of

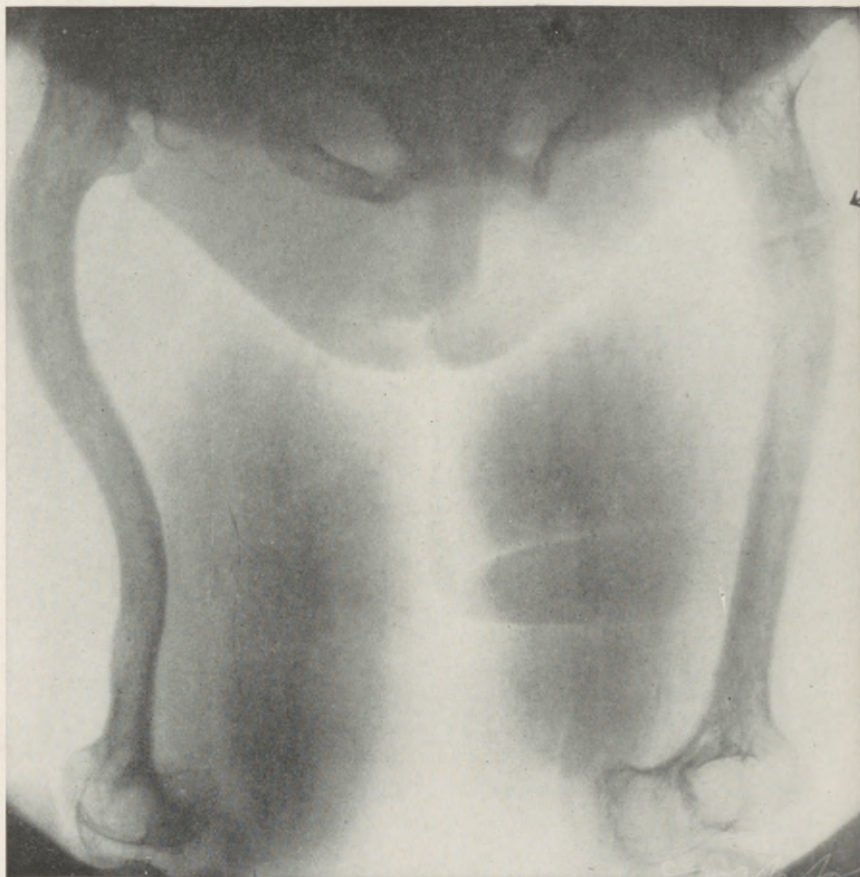


FIG. 73.—Osteogenesis imperfecta. Arrow points to fracture with callus formation.

the shoulder fails to show cause for the pain it is advisable to examine the lungs for the presence of a tuberculous lesion.



**Myositis Ossificans.**—This condition usually follows trauma and consists in the deposition of calcium salts in lines parallel to the long axis of the bone. The most

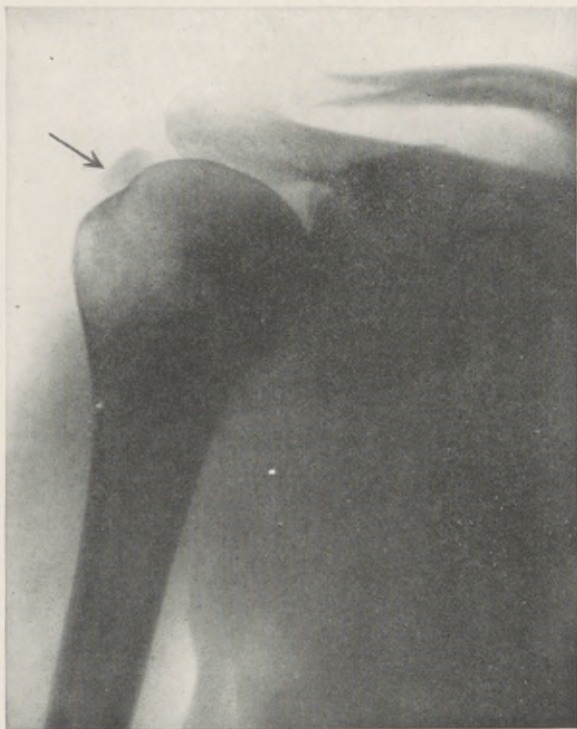

FIG. 74.—Subacromial bursitis.

common location is the thigh. The roentgen appearance is typical (Fig. 75).

**Ossifying Hematoma.**—This condition is due to calcification of a sub-periosteal hemorrhage. Its clear-cut edges, its lines of calcium salts parallel to the bone and the absence of bone destruction, serve to differentiate it

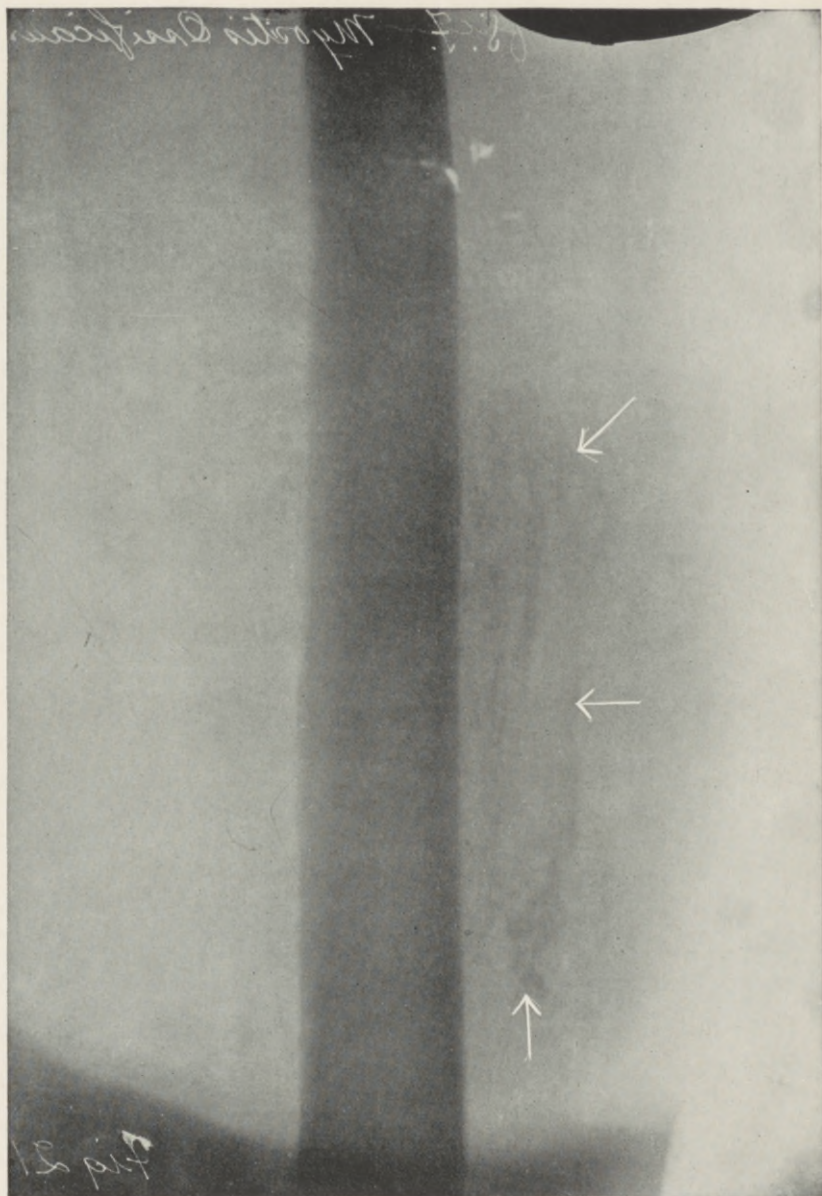


FIG. 75.—Myositis ossificans; bone laid down in lines parallel to the long axis of the femur as designated by the three arrows.

from the malignant tumors. It is distinguished from myositis ossificans by its rounded periphery, due to the fact that it is limited by the periosteum.

#### BONE TUMORS

Tumors of bone, like those of soft parts, may be classified as benign or malignant, and may be of connective-tissue or of epithelial origin. Malignant tumors are much more common in bone than benign ones and since epithelial cells are not normally found in bone, epithelial tumors must be secondary to tumors elsewhere and are more rare than those of connective-tissue origin.

An *osteoma* (Fig. 76) is a tumor composed entirely of bone. *Endostoma* is a rare tumor arising in the center of bone. Exostoses of fibrous origin usually occur in the auditory canal, jaws, or skull. They arise from periosteum and are rare.

Cartilaginous exostoses arise from pre-existing islands of cartilage and are important because of their frequency. When single they arise from the epiphyseal cartilage by a lateral growth, or from the diaphysis near to the epiphyseal line. The upper end of the tibia is the most common site.

Multiple cartilaginous exostosis is a disease characterized by the presence of multiple exostoses with marked deformity of the skeleton. It often occurs in several different members of the same family or in individuals of several generations. Its diagnosis depends upon the presence of multiple hard tumors near to the epiphyses,



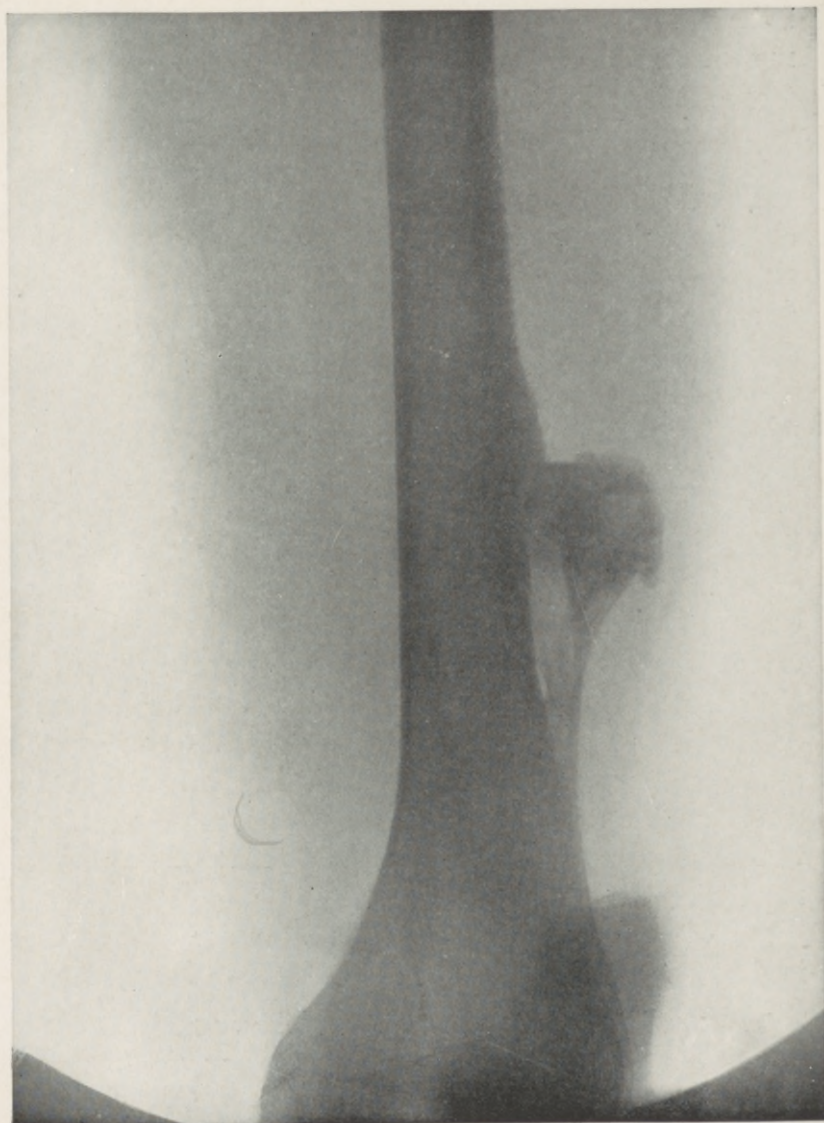

FIG. 76.—Osteoma arising from the femur.

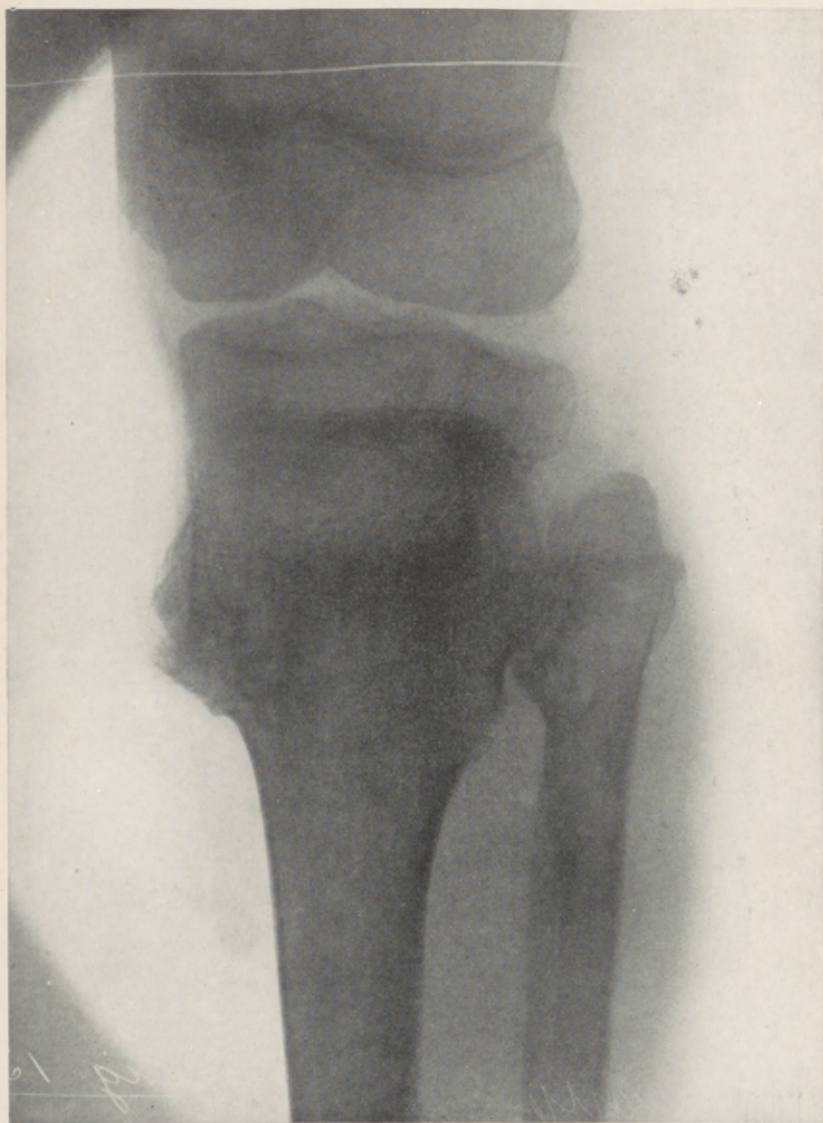

FIG. 77.—Multiple cartilaginous exostosis. The rectangular shape of the head of the tibia is characteristic.

with more or less deformity. The roentgenogram gives a typical appearance and serves to exclude chondroma (Figs. 78 and 79).

Chondroma is a tumor composed of cartilage and may

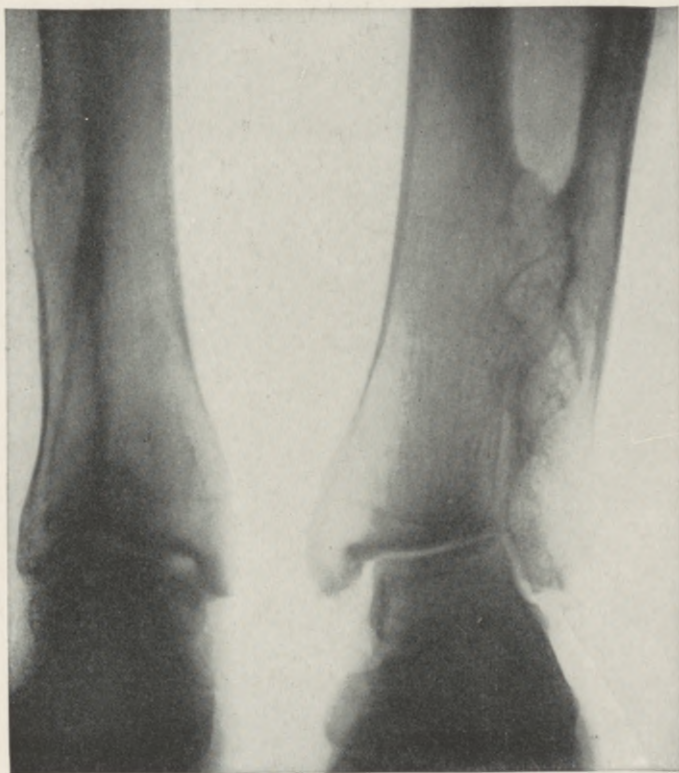

FIG. 78.—Multiple cartilaginous exostosis. Bony union of tibia and fibula.

be single or multiple. The single chondroma growing laterally from near the epiphyseal line has a typical roentgen appearance. Multiple enchondroma is also easy to identify because of the occurrence of the tumors



in the long bones of the hands and feet and their typical roentgen picture. Single chondroma developing

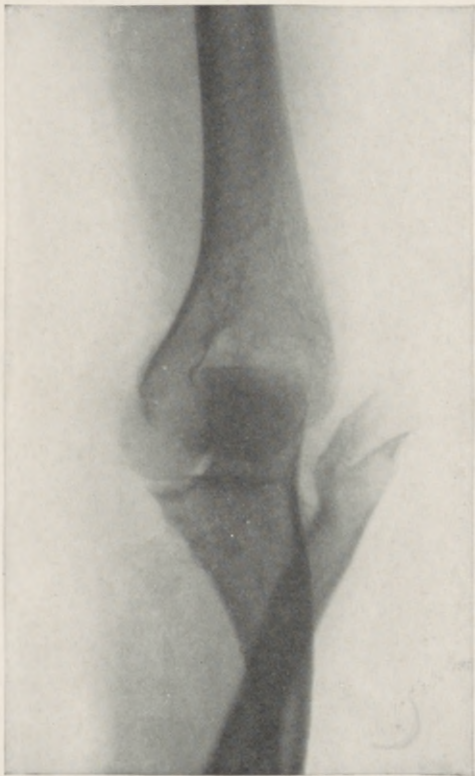

FIG. 79.—Multiple cartilaginous exostosis. Dislocation of radius at elbow due to failure of growth of ulna.

centrally in bone is very difficult to distinguish from bone cysts and from giant-cell sarcoma.

Osteochondroma (Fig. 80), osteochondromyxoma and other tumors of mixed structure are occasionally seen. They are benign in that they do not metastasize but

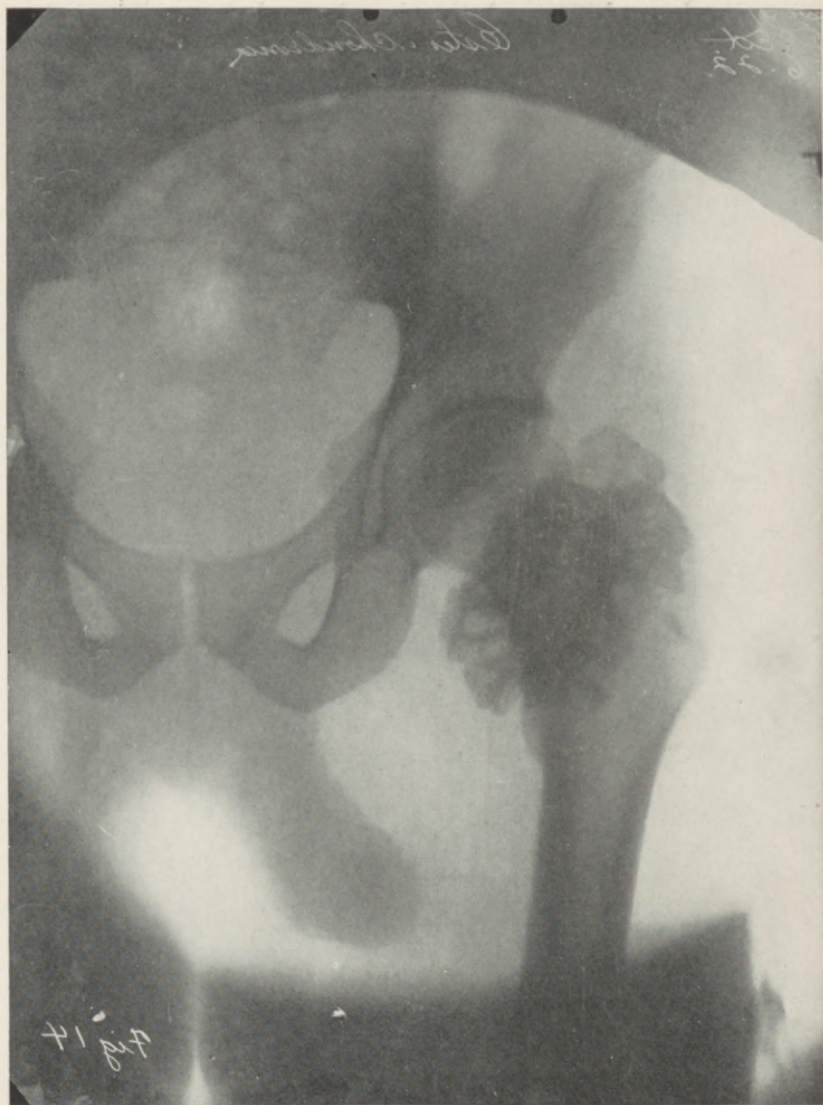


FIG. 80.—Mixed tumor arising from the neck of the femur; probably osteochondroma.

they are prone to recur locally unless they are removed with the utmost thoroughness.

Sarcoma is the most frequent and most important tumor originating in bones. The jaws and long bones of the extremities are the most frequent sites. They are of three main classes, periosteal, medullary and osteosarcoma. The early diagnosis of *periosteal sarcoma* offers great difficulty. Early roentgen examination may show only a slight roughening or dissecting up of the periosteum, or very slight irregularity of the cortex. The roentgen appearance a little later is so characteristic that mistake should never be made. It consists in a trabeculation or spiculation at right angles to the bone due to the laying down of calcium salts in the tumor itself. These lines of calcium salts are always perpendicular to the long axis of the bone and never parallel to it (Fig. 81).

*Medullary sarcomata of bone* of the round or spindle-cell type are usually located near the epiphysis, but the round-cell variety is not infrequently found in the shaft. Pain usually precedes the appearance of tumor in medullary sarcoma, while the opposite sequence occurs in the periosteal type. The pain is referred to the neighboring joint in many cases and may lead to a diagnosis of arthritis. It is not increased by motion, however, nor relieved by rest or fixation. The roentgen appearance of central round and spindle-cell sarcomata in the early stages is not characteristic. Practically the same picture is given by cyst or chondroma. A diagnosis may be arrived at only by frequent examinations to show the rapid destructive effect with breaking down of the



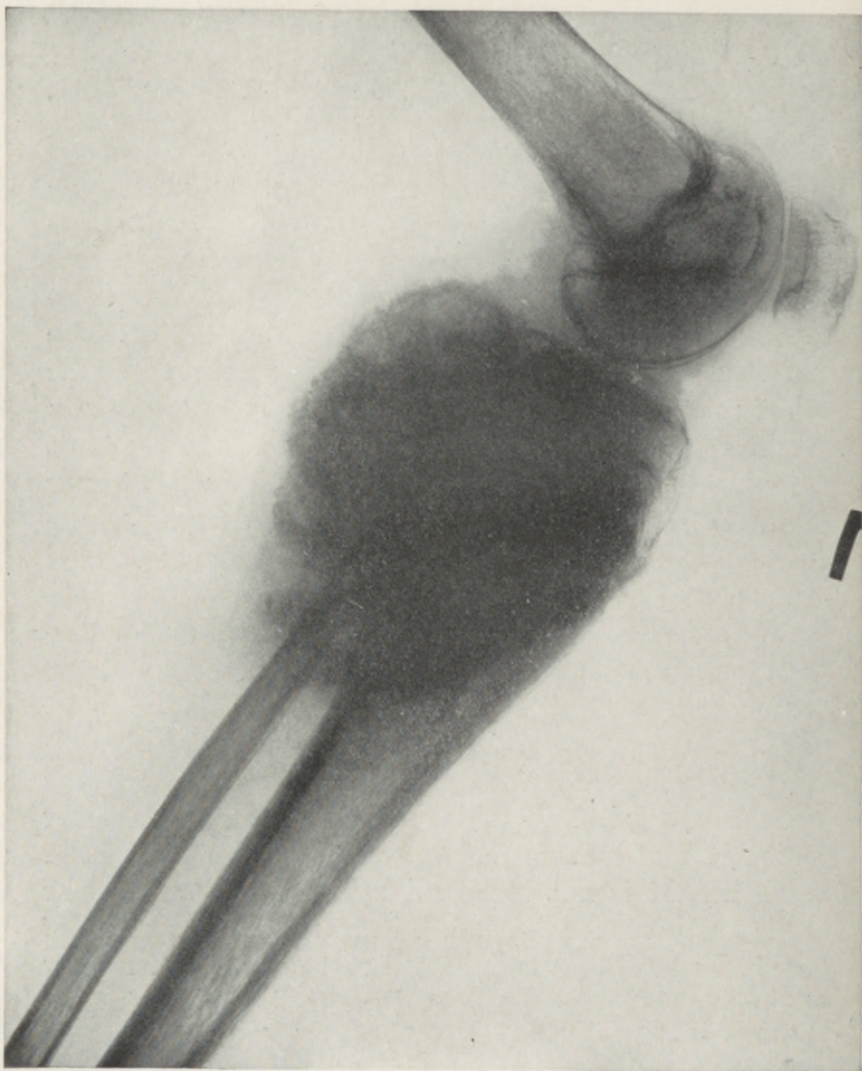


FIG. 81.—Periosteal sarcoma of the head of the tibia.

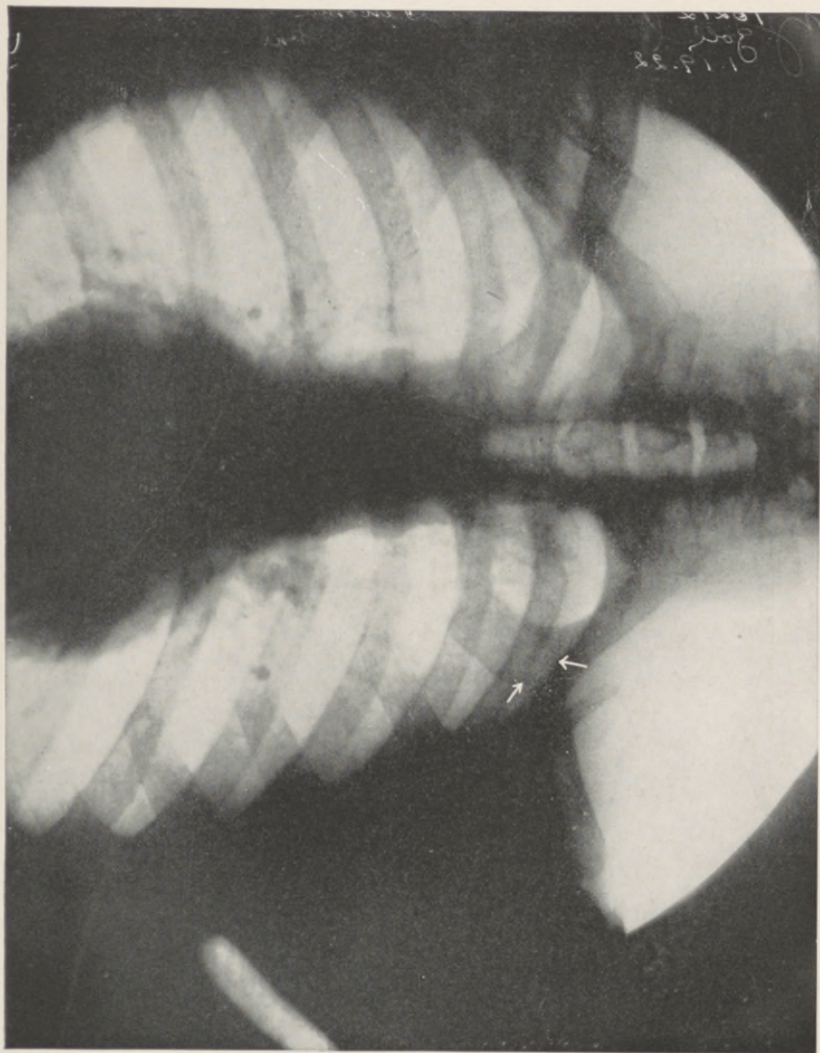

FIG. 82.—Medullary sarcoma, which has caused destruction of about half of the left clavicle.

cortex. These tumors extend by invasion and destruction of the bone and not by expanding the cortex. The round-cell variety is much more rapidly destructive than the spindle-cell type (Figs. 82 and 83).

*Osteosarcoma* arises from the cortex and extends both

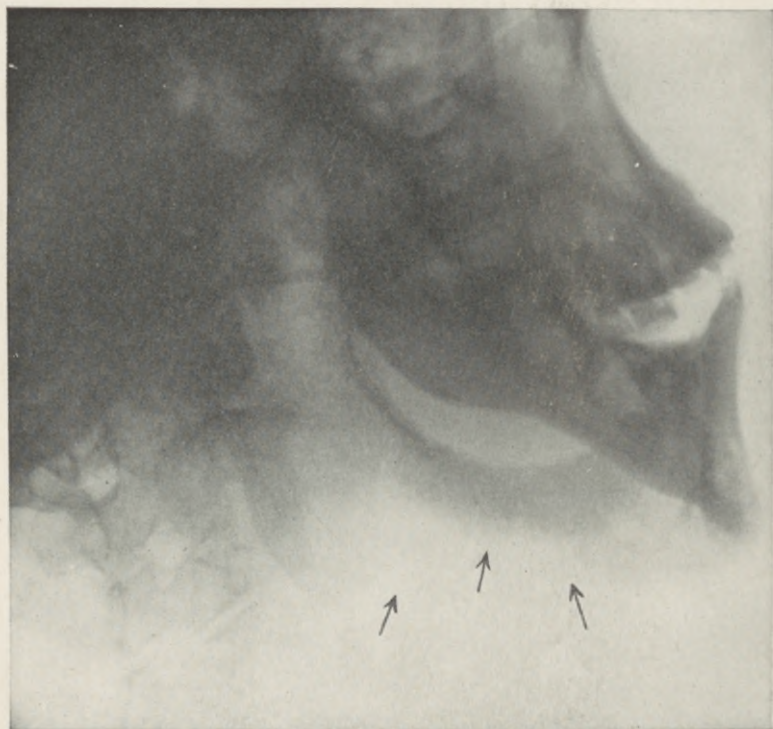


FIG. 83.—Rapidly growing sarcoma of mandible.

outward into the soft tissues and inward to destroy the bone. Baetjer and Waters call attention to the fact that periosteal sarcoma and osteosarcoma are the only two malignant tumors that produce bone within themselves.



**Giant-cell Tumor (Fig. 84).**—These tumors have long been known as “giant-cell sarcoma” but this term is misleading since the condition is essentially benign. It does not metastasize and is usually cured by local removal. It has its origin in the medullary canal and grows equally in all directions, but it simulates a cyst rather than sarcoma in that it expands instead of destroys the cortex. It is most commonly found in the extremities of long bones or in the lower jaw, the favorite sites being the head of the tibia, lower extremity of the femur, lower end of the radius, and the lower jaw. It is distinguished from sarcoma by its slow growth, by the fact that the cortex remains intact, and by absence of invasion into the soft tissues. Cyst and enchondroma may both be mistaken for giant-cell tumor. Cysts are more common in the bones of the hands and feet and in the shafts of long bones. Enchondroma is not usually so symmetrical in its growth as giant-cell tumor and although it occurs near the ends of the bones it does not involve the epiphyses.

**Bone Cysts (Fig. 67).**—The majority of bone cysts are now believed to be a phase of the disease known as osteitis fibrosa. They usually occur near the ends of long bones but do not involve the epiphysis, and are even sometimes near to the middle of the shaft. The cyst is a clear-cut area of bone destruction, somewhat circular or oval in shape, and expanding but not destroying the cortex. Its roentgen appearance is identical with that of enchondroma but the latter are more likely to be multiple and to involve the bones of the hands.

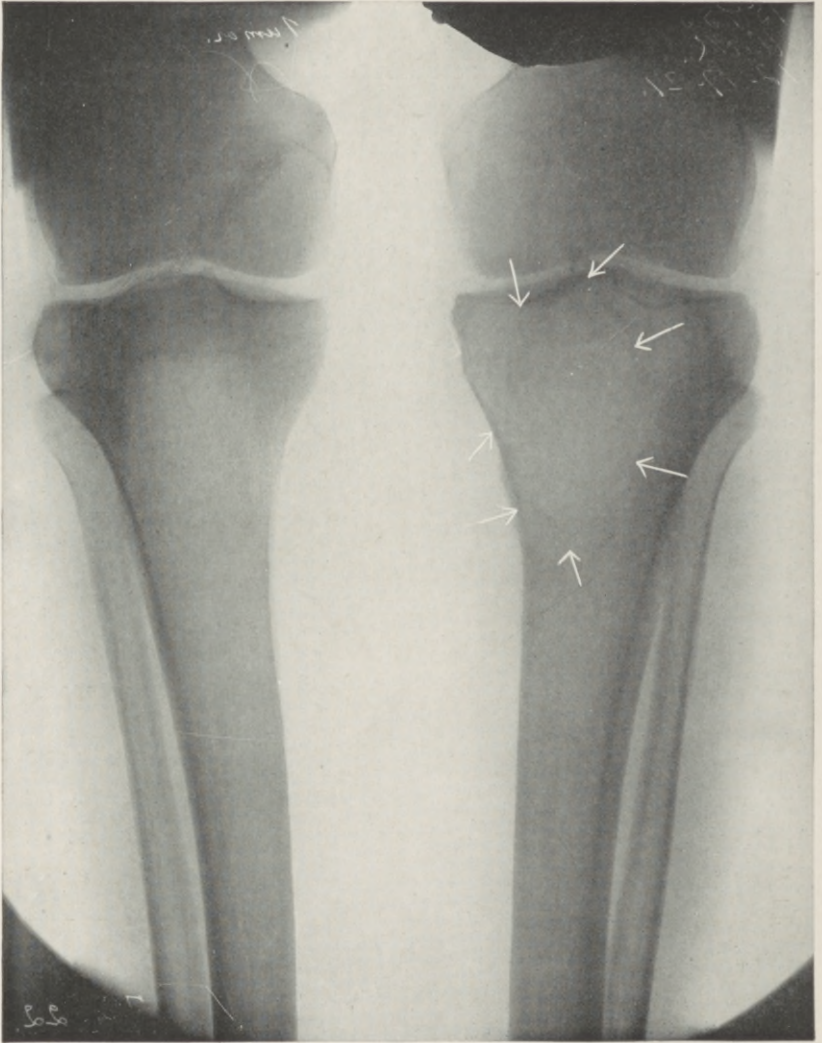


FIG. 84.—Giant-cell tumor, head of left tibia.

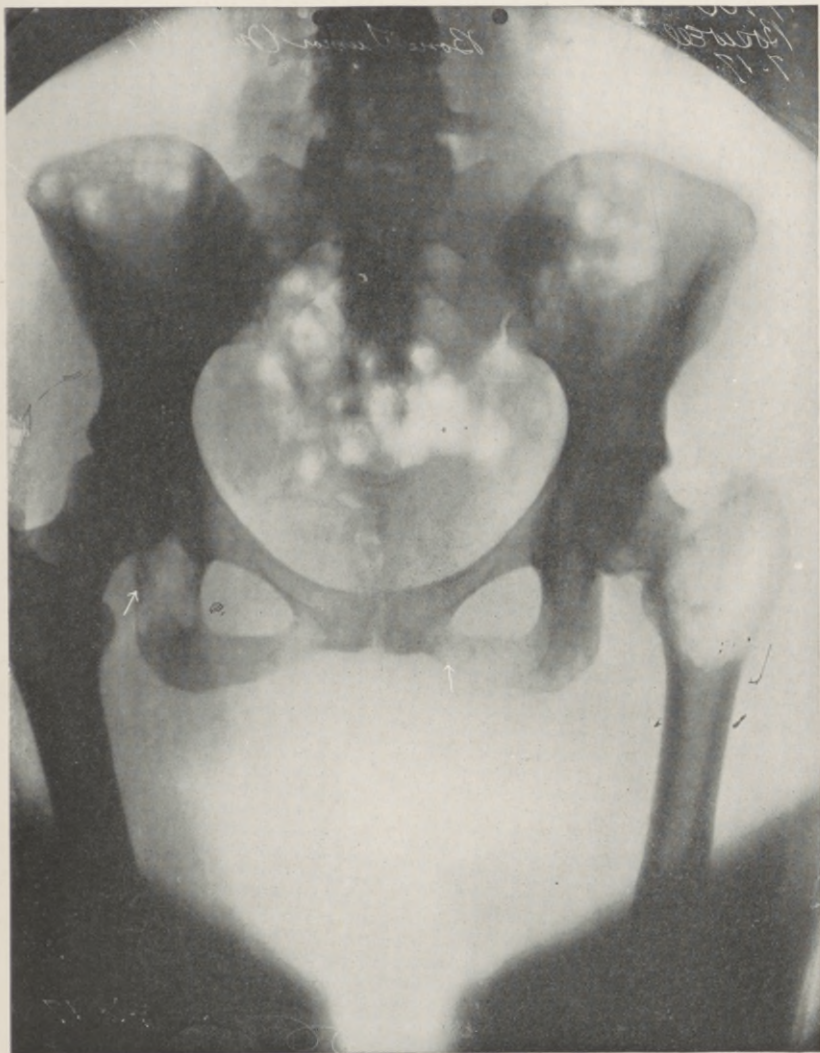


FIG. 85.—Multiple myeloma, areas of bone destruction in the left femur and bones of the pelvis.



Fractures of the long bones are common through areas weakened by cyst or enchondroma.

**Multiple Myeloma** (Figs. 85 and 86).—This is a primary, multiple, malignant tumor of bone which involves more frequently the sternum, vertebræ and skull, but may attack any bone in the body. The roentgen appearance is that of clear, punched-out circular or oval areas of bone destruction. The cortex is not usually expanded but is occasionally destroyed. The diagnosis depends upon the roentgen appearance and the presence of albumose in the urine.

**Endothelioma** is a rare malignant tumor of bone which it is clinically impossible to differentiate from sarcoma.

**Carcinoma**, or **epithelioma**, as a secondary disease, is not uncommon in the bones. Bone may become involved either by metastasis or by direct extension. Metastases occur in women most frequently from the breast and in men from the prostate, but carcinoma anywhere in the body may produce secondary involvement. The roentgen appearance of bone carcinoma is fairly characteristic. According to the common view, the disease enters the bone through the nutrient canal and is therefore often first seen about the middle of the shaft of long bones.

Handley's view, which he supports with much evidence, is that carcinoma spreads from its primary source by direct growth along the lymphatics of the deep fascia and passes directly into the bone from the fascial attachments.

The tumor destroys the bone as it advances, in a very irregular manner, giving to it a worm-eaten appear-

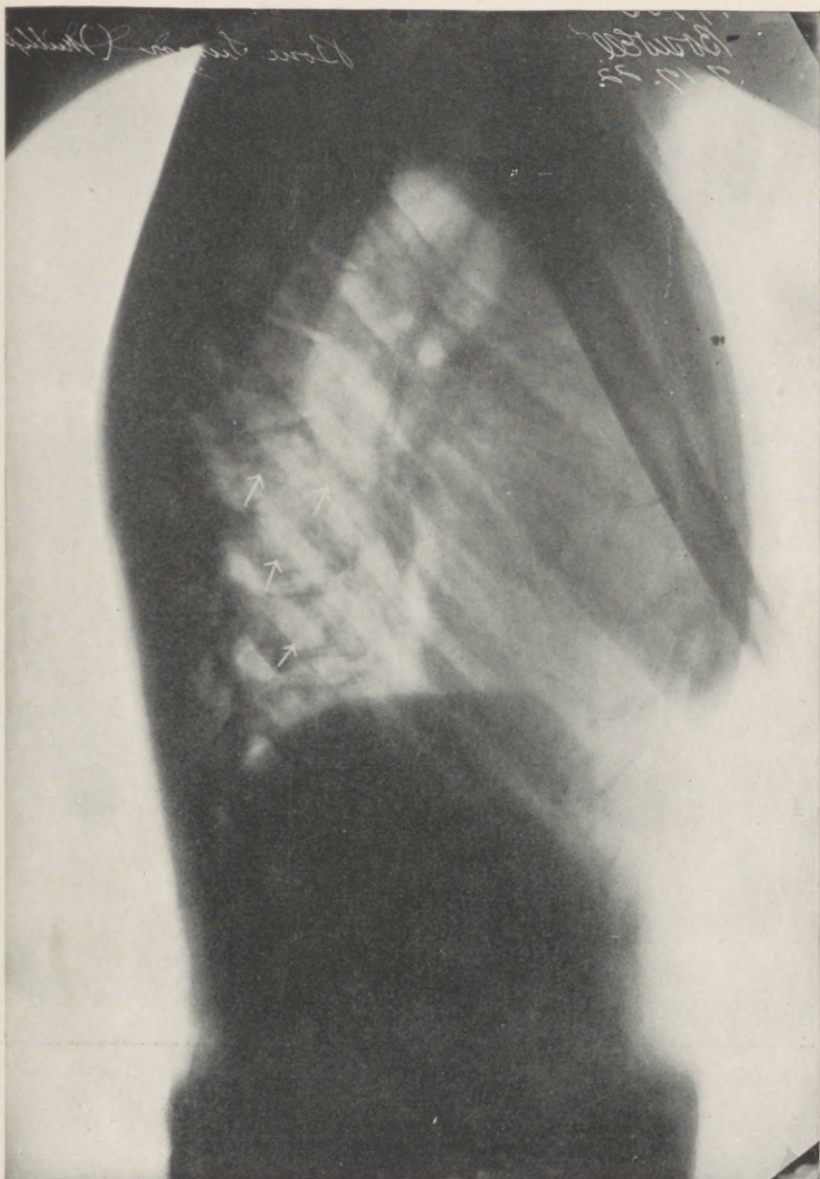

FIG. 86.—Multiple myeloma. Lateral view of the spine showing areas of bone destruction in several vertebrae. (Same case as Fig. 85.)

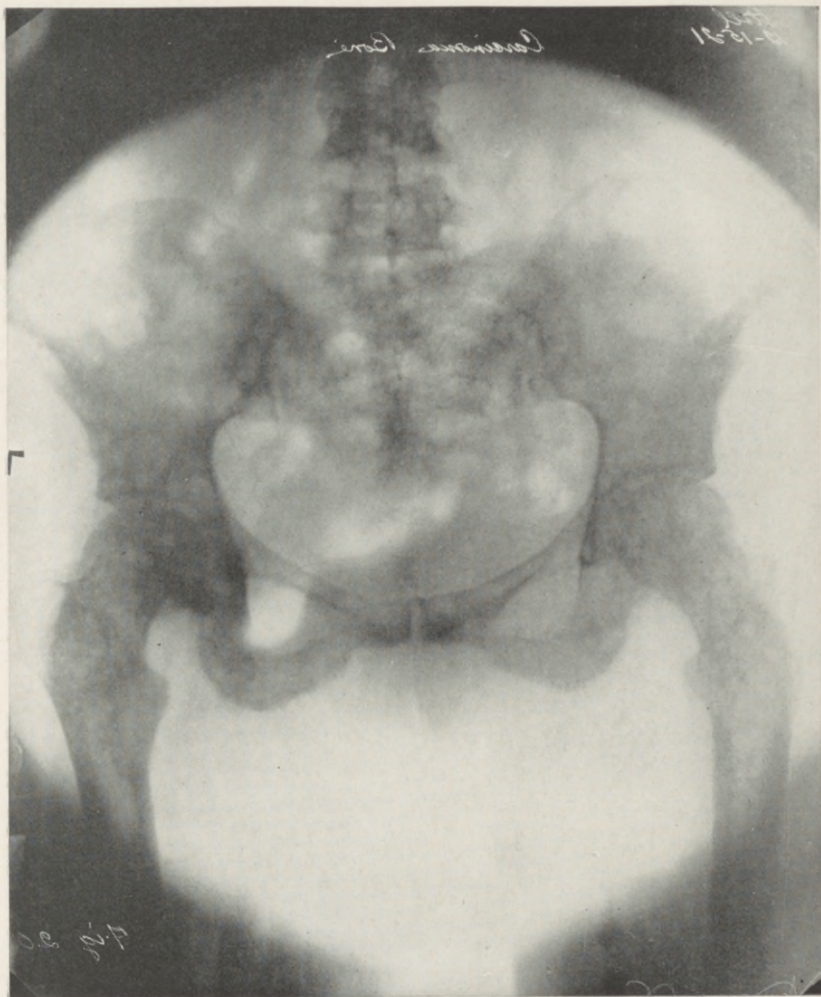

FIG. 87.—Carcinoma involving vertebræ, bones of pelvis, and both femora, secondary to carcinoma of the breast.



ance which sometimes simulates osteomyelitis (Figs. 87 and 88). *Hypernephroma* occasionally metastasizes to bone but there is no way to differentiate it from carcinoma.

The *differential diagnosis* of bone tumors may be summed up shortly as follows: Exostoses may be accurately diagnosed by their roentgen appearance. Chondroma when growing laterally from the epiphysis gives a typical roentgen picture, and multiple enchondromata are readily recognized. Single chondroma occurring centrally may be mistaken for benign cyst or giant-cell sarcoma, but the treatment is practically identical for all three. Periosteal sarcoma gives a typical roentgen picture, the spiculation at right angles to the bone. The round or spindle cell medullary sarcoma may be confused with tuberculosis or Charcot's joint, and the greatest care is necessary to differentiate them.

It is especially in the spine that tuberculosis and sarcoma may be confused. Both cause destruction of the vertebral bodies. The most important point in the differential diagnosis is the failure of immobilization to relieve the pain due to sarcoma. Roentgenograms taken at frequent intervals will show much more rapid bone destruction in sarcoma than is the case in tuberculosis. Charcot's joint may also be mistaken for sarcoma but the fact that the former is a disease of long duration, that it is painless, and that the roentgenogram shows involvement of several bones, and that there is a large amount of bony detritus about the involved joint, all serve to establish the diagnosis.

It is not always possible to distinguish carcinoma

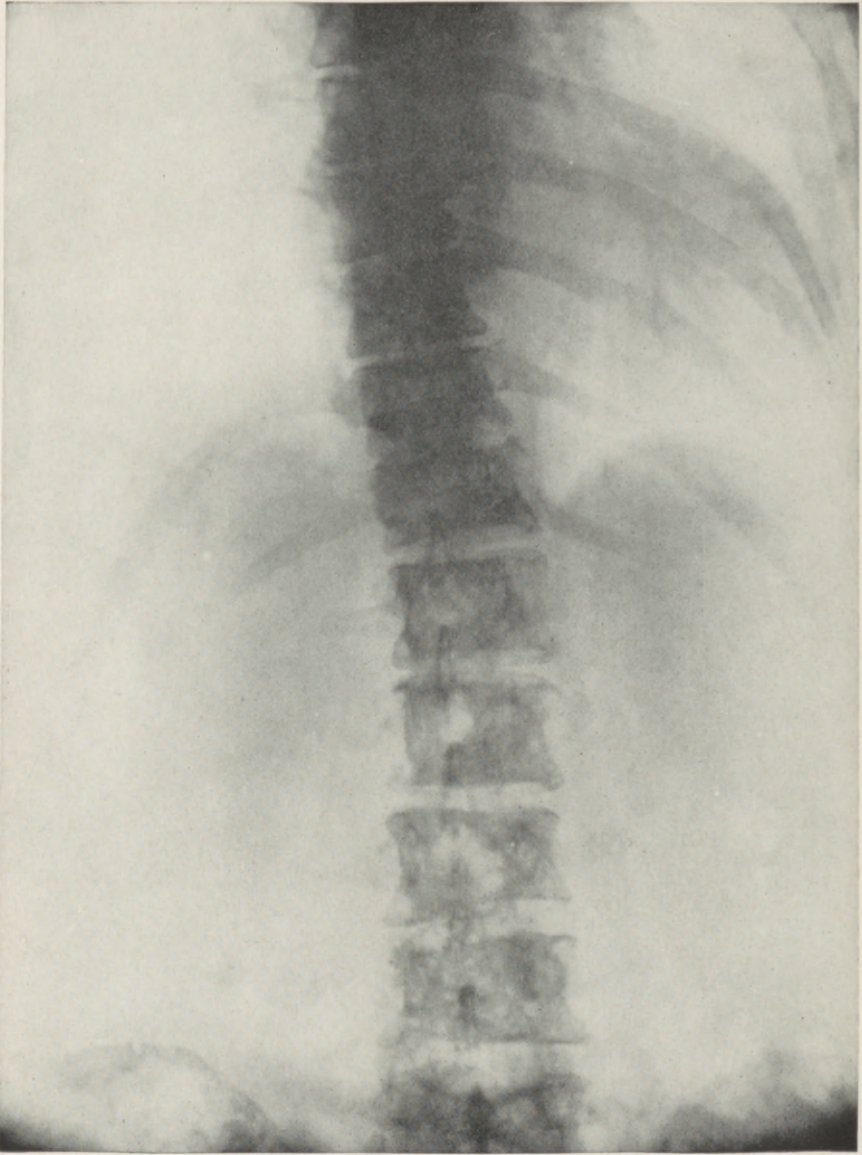


FIG. 88.—Metastatic carcinoma of bone involving ribs and spine.

from sarcoma but if it is kept in mind that sarcoma usually occurs in early life, that it is usually localized to a single area in only one bone, and that in carcinoma a primary cancer is always present, a mistake will not often be made.

Myositis ossificans should never be mistaken for sarcoma. In the former calcium salts are laid down in lines parallel to the long axis of the bone, giving a typical roentgen appearance.

Multiple myeloma and endothelioma are rare. The former can usually be recognized but the latter cannot be distinguished clinically from sarcoma. Benign cysts are likely to be confused only with chondroma or giant cell sarcoma. Carcinoma of bone may be confused with tuberculous disease, especially in the spine, but if care is taken in examining for involvement of other bones and in discovering the primary cancer, a mistake is usually avoided.



## CHAPTER X

### EXAMINATION OF THE HEAD

**FRACTURES.**—Lateral roentgenograms of the head show fractures of the vault of the skull very well, but it is only rarely that fractures of the base can be shown. The lateral views should always be taken stereosci-

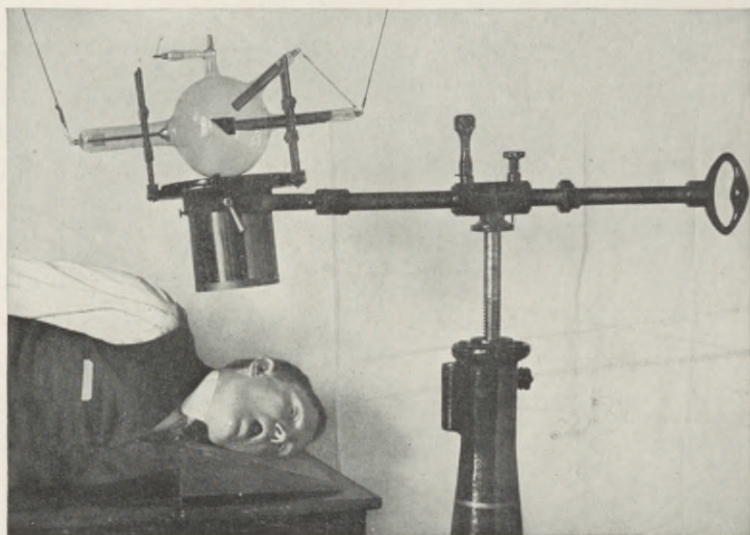


FIG. 89.—Position for lateral roentgenography of head.

cally and the supposedly normal side should be taken for comparison. Care must be exercised to secure true lateral views in order to avoid distortion. It is very important to secure complete immobilization by pressure of the cone or other means. The slightest movement may completely obscure the image of a linear fracture. Care must be exercised in interpretation not to mistake the

normal suture lines or the markings of the diploic veins for fractures. Posteroanterior views are often of value to determine whether or not the fracture is depressed.

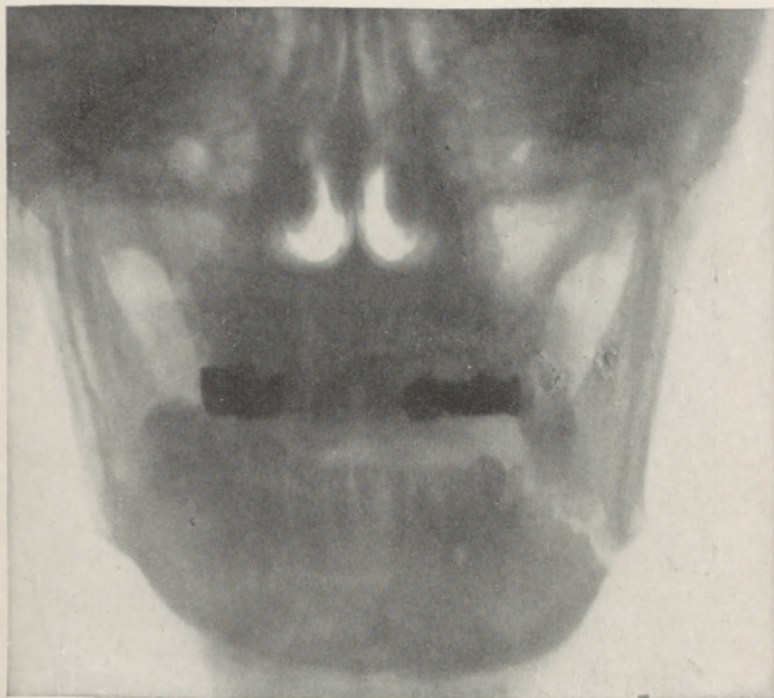

FIG. 90.—Fracture of mandible taken in position described on page 144.

Fractures of the mandible, especially about the posterior two-thirds of the body, the angle, the ramus, the neck, the condyle, and the coronoid process, are best shown by centering the tube a little below and behind the angle of the jaw (Fig. 89) and directing the ray slightly upward. Figure 90 showing fracture of the mandible, is from a roentgenogram taken in what has

been found a very useful position, especially valuable to show lateral displacement. The patient's chin and tip of the nose touch the film, which is *horizontal*, and the

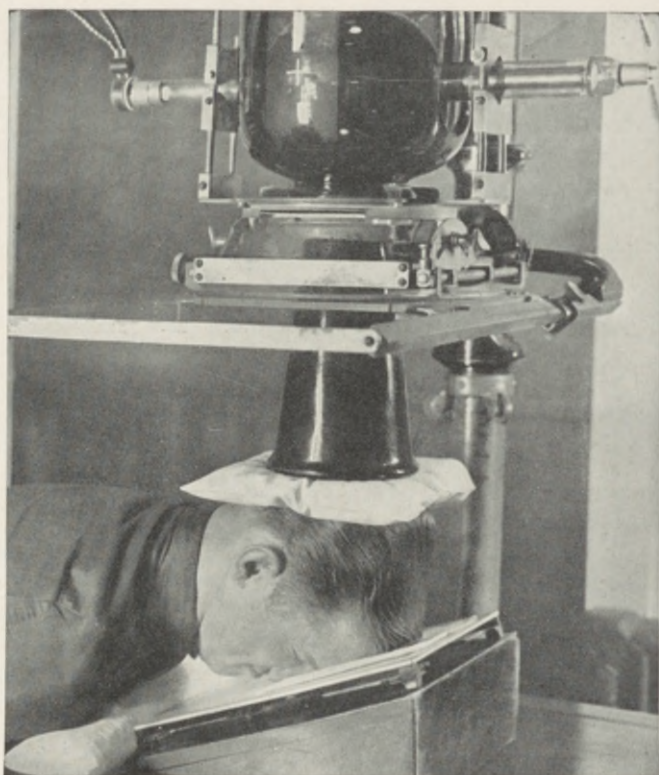


FIG. 91.—Posteroanterior position for roentgenographing the accessory nasal sinuses at angle of  $25^{\circ}$ .

target of the tube is centered about an inch below the occipital protuberance, the ray being directed at right angles to the film. The lateral views should be taken stereoscopically and both sides should always be taken for comparison.



**The Nasal Accessory Sinuses.**—It is necessary to make films of the nasal accessory sinuses in two different directions, the posteroanterior and the lateral. The

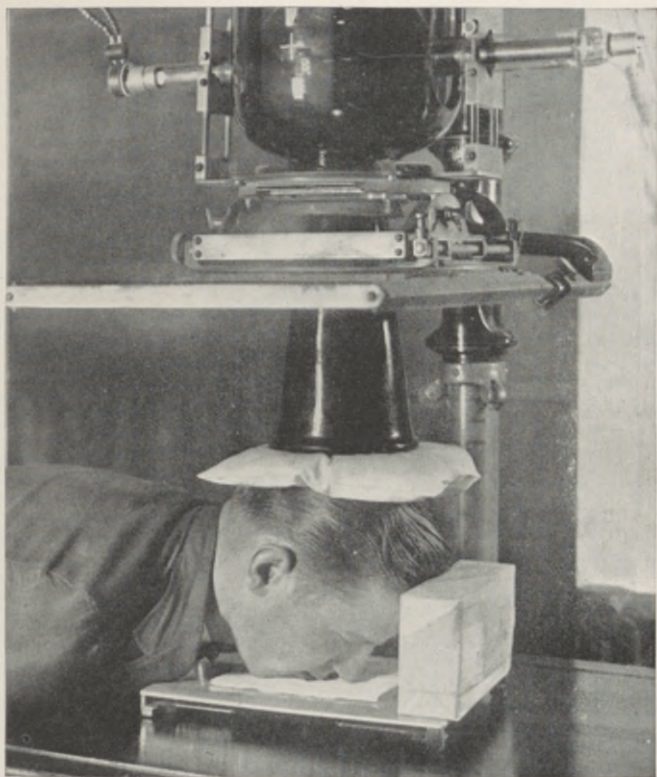


FIG. 92.—Waters' position for roentgenographing the maxillary antra.

position that has long been accepted as the best to obtain a general view of all the sinuses is one made with the patient prone upon the roentgenographic table with the forehead and tip of the nose in contact with the film-holder (Fig. 91).

The film-holder is placed upon a wedge-shaped block giving it an angle of  $25^{\circ}$ . The target of the roentgen tube is centered over a point midway between the occip-




FIG. 93.—Lateral view of the skull taken stereoscopically. The second view is taken after shifting the roentgen tube three inches horizontally.

ital protuberance and the vertex, the central ray passing in a direction perpendicular to the table upon which the patient is lying. The shadows of the petrous portion of the temporal bone are thus projected upon the uppermost portions of the maxillary sinuses and the

lower part of the orbits. In this position the frontals are shown better than any of the other sinuses. The *Waters' position* (Fig. 92) gives an unobstructed view

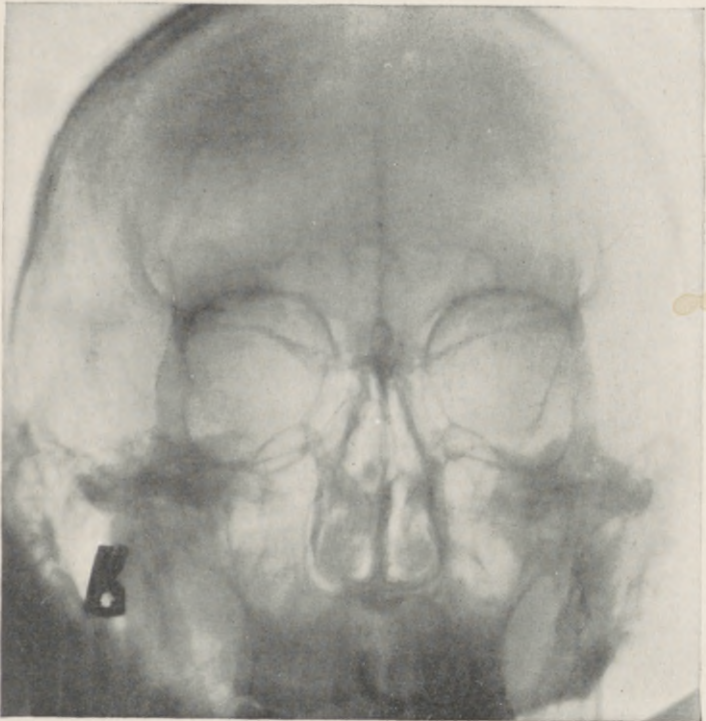

FIG. 94.—Normal sinuses : Twenty-five degree position.

of the maxillary sinuses. For this position the film is placed horizontally upon the table and the patient lies prone with the chin resting upon the film and the tip of the nose  $\frac{1}{2}$  to  $1\frac{1}{2}$  cm. from the film.

The lateral view of the skull should be taken stereoscopically (Fig. 93). The patient lies upon his side with



the plate exactly parallel to the sagittal plane of the head. The target of the tube is centered over a point one inch in front of and one inch above the level

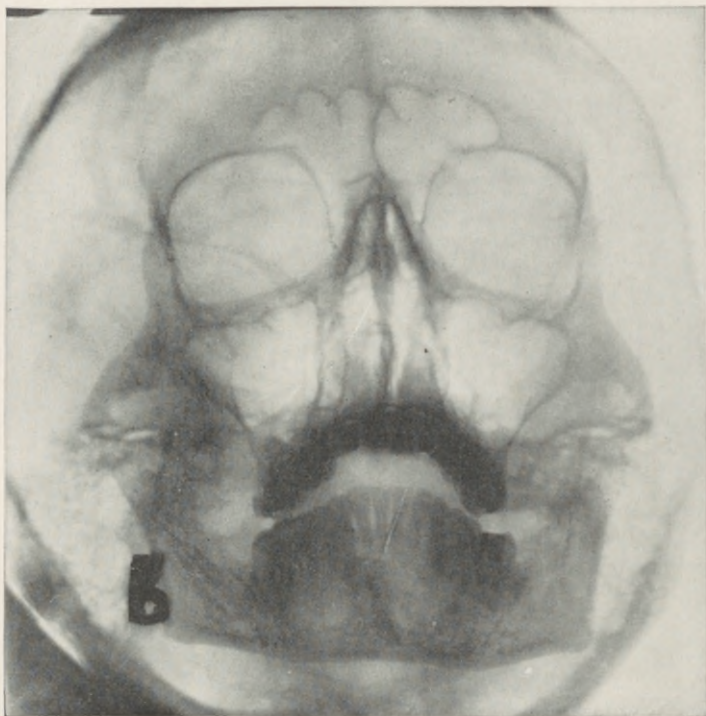

FIG. 95.—Normal sinuses: Waters' position.

of the external auditory meatus. The central ray thus passes transversely through the head.

The sphenoidal sinuses are seen in the lateral views but the two sinuses are superimposed. They may be seen separately by placing the plate under the chin with the neck well extended and the tube centered over the

vertex of the skull, or by placing a large film well back in the mouth against the palate. For routine examination of the sinuses it will usually suffice to take one plate

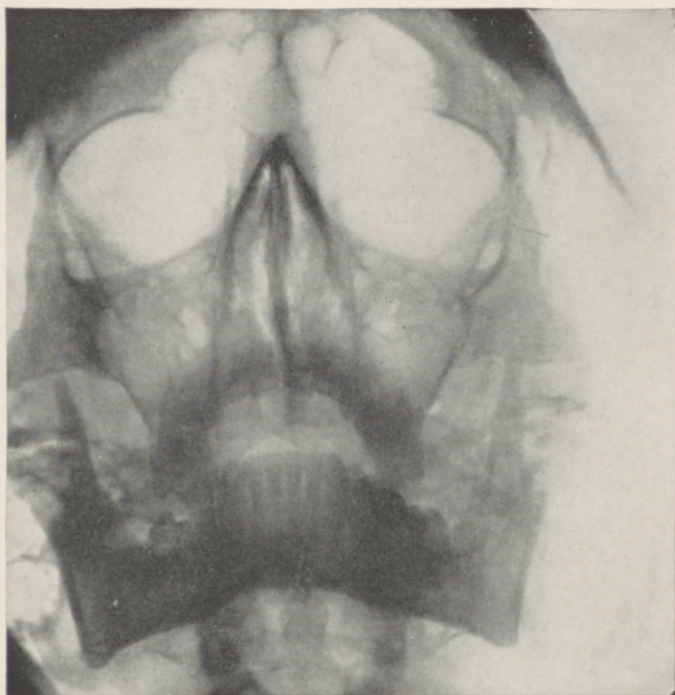

FIG. 96.—Empyema of all the accessory nasal sinuses, showing opacity over both antra :  
Waters' position.

in the posteroanterior position at the  $25^{\circ}$  angle; one in the Waters' position, and a lateral stereoscopic pair.

**Interpretation of Sinus Plates.**—The sinuses being air-filled cavities normally allow the roentgen rays to pass readily and their shadows on the plates are much blacker than the surrounding structures (Figs. 94 and 95). When fluid or other pathological material is

present they become more dense and the shadows are consequently whiter. The thickness of the bone, which may be estimated in the lateral views, must be taken into account when interpreting the relative densities of shadows. This is particularly true of the frontal sinuses which may be very shallow and the walls very thick. Sometimes one or both of the frontal sinuses is completely absent. The cause of opacity of the sinuses cannot be stated from the roentgen appearance. It can only be stated that the sinus is occluded, but whether the occlusion is due to the presence of pus, granulations or new growth can be decided only by opening the sinus. Interpretation of the findings is also modified by previous operation upon the sinuses. A sinus that has been opened and drained and perhaps irrigated over a long period is likely to have a greatly thickened mucous membrane which increases its opacity to the roentgen ray. Figures 96 and 97 illustrate the roentgen appearance in pathological conditions of the nasal accessory sinuses.

**The Mastoids.**—Roentgenological study of this region is of little value in children under five years of age because of lack of development of the mastoid cells before that time. The technical difficulties are also increased in children, due to the difficulties of immobilization.

The mastoids should always be taken stereoscopically and it should be an invariable rule to take both mastoids for purposes of comparison. The patient lies upon his side with the head so supported as to bring its sagittal plane parallel to the film-holder. The tube is so



placed that the central ray enters the head above and behind the external auditory meatus and emerges at the opposite auditory meatus, and is so tilted as to

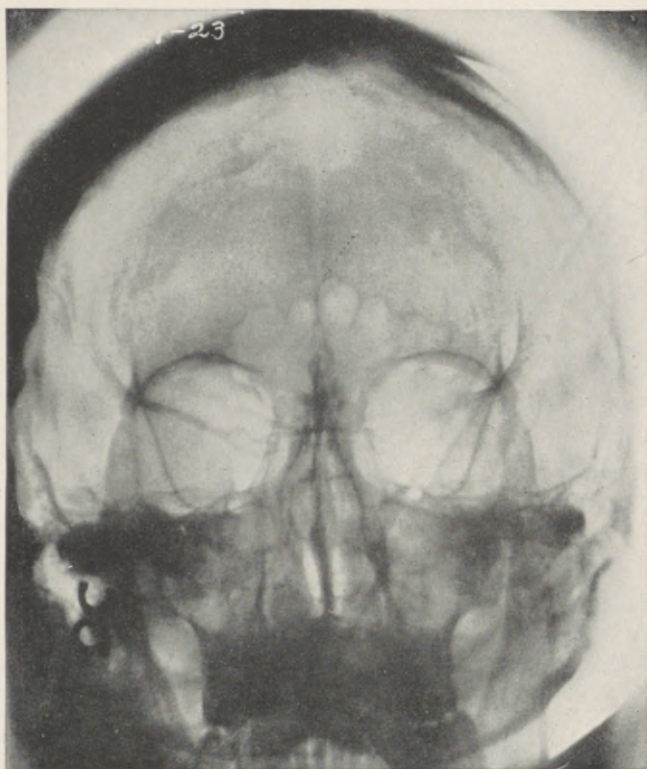

FIG. 97.—Empyema of all the accessory nasal sinuses, showing opacity over both frontal sinuses: Twenty-five degree position. (Same patient as Fig. 96.)

form an angle of  $15^{\circ}$  from above downward (Fig. 98).

The parts shown on a good roentgenogram of the mastoid region are the external and internal auditory meati, with the mastoid antrum just above and behind

them. There is a wide groove in the occipital bone for the lateral sinus. Below and in front of the auditory meatus is the temporomandibular articulation.

There are two general types of mastoids, the non-

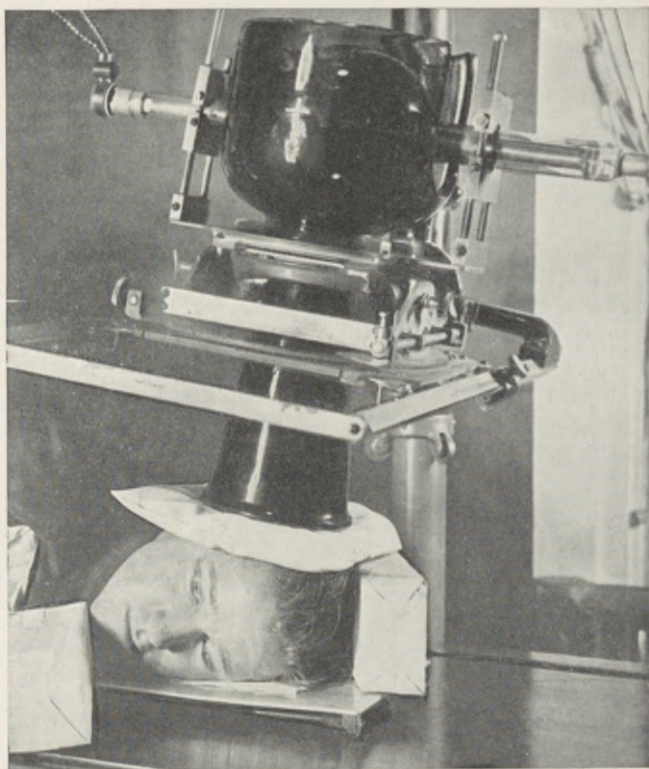


FIG. 98.—Position for roentgenographing the mastoid region.

cellular and the pneumatic or cellular. The latter may contain very large cells and may extend well forward into the zygoma, upward into the squamous portion of

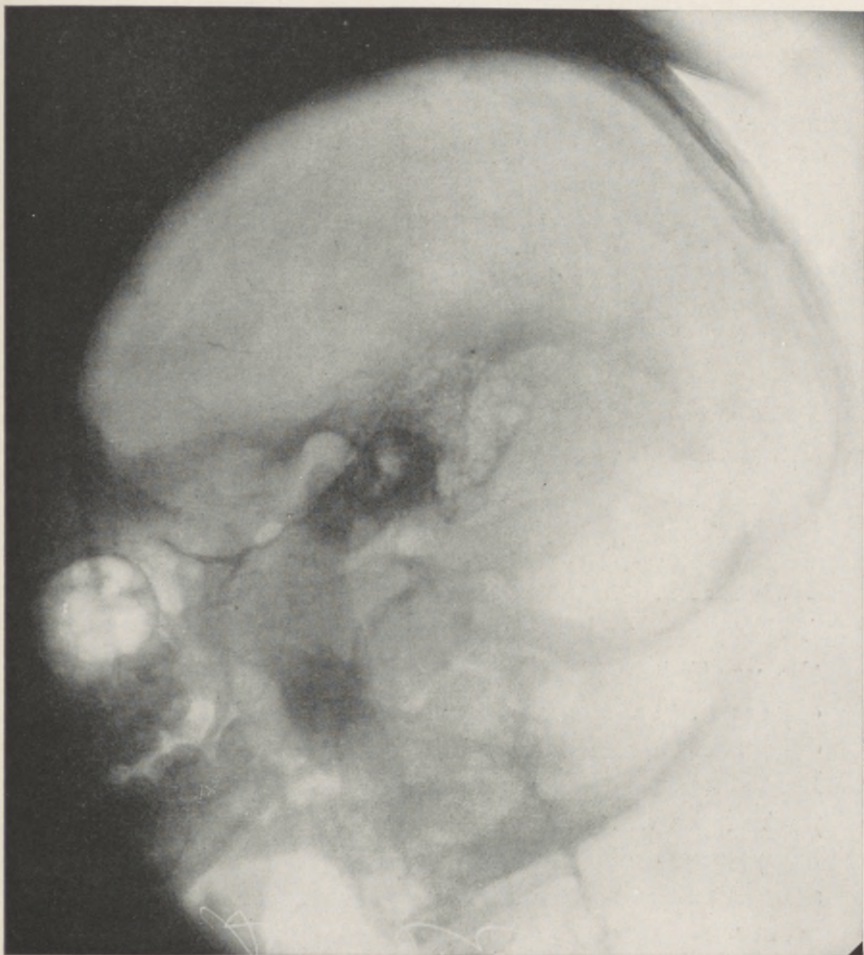

FIG. 99.—Normal mastoids.



the temporal bone and far backward into the occipital bone. Figures 99 and 100 show the appearance of normal mastoids.

**Mastoiditis.**—In acute stages of this disease (Fig. 101) the roentgenogram shows a haziness or lack of sharpness in the outline of the cells as compared with those of

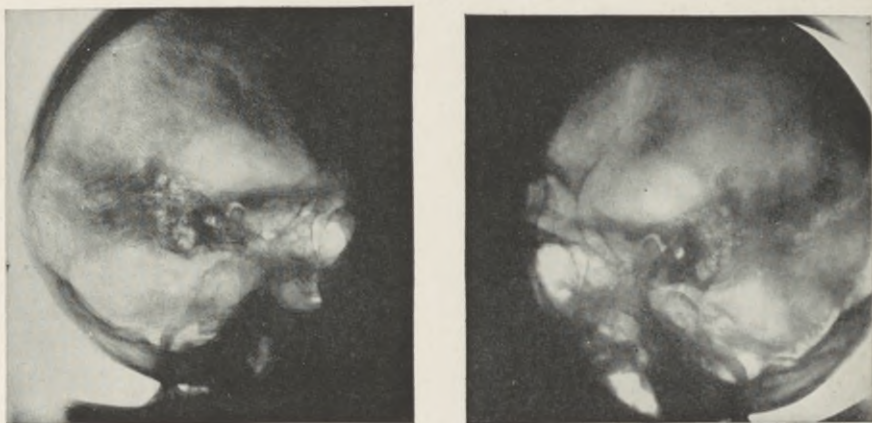


FIG. 100.—Stereoscopic views of normal mastoids.

the unaffected side, but the cells are not completely obscured. In chronic mastoiditis (Fig. 102) the air-cells are completely obscured in the roentgenogram. It is often possible to demonstrate destruction of some part of the wall of the lateral sinus. Besides indicating the presence of disease the roentgenogram is useful in showing the extent of the cells that are involved, thus giving the surgeon an indication of the extent of the operation before he opens the mastoid. The cells in the zygoma may become involved and infect the temporo-mandibular articulation. This is probably the most

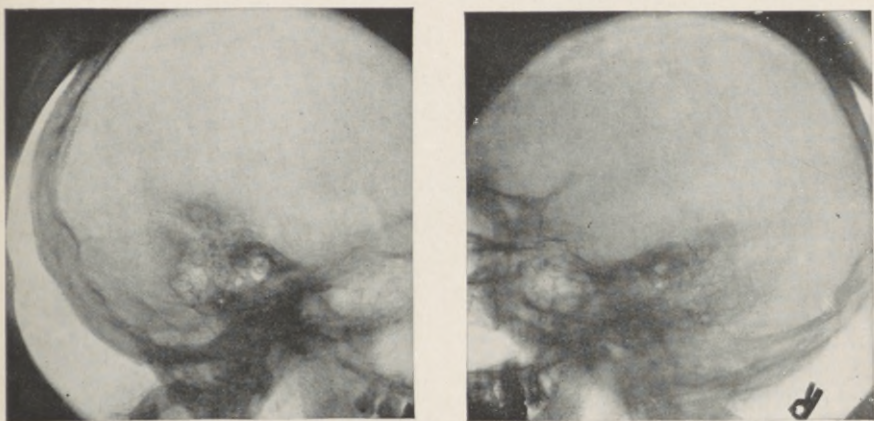


FIG. 101.—Stereoscopic views of acute mastoiditis, the involvement being on the right side marked R where the cells show indistinctly as compared with the other side.

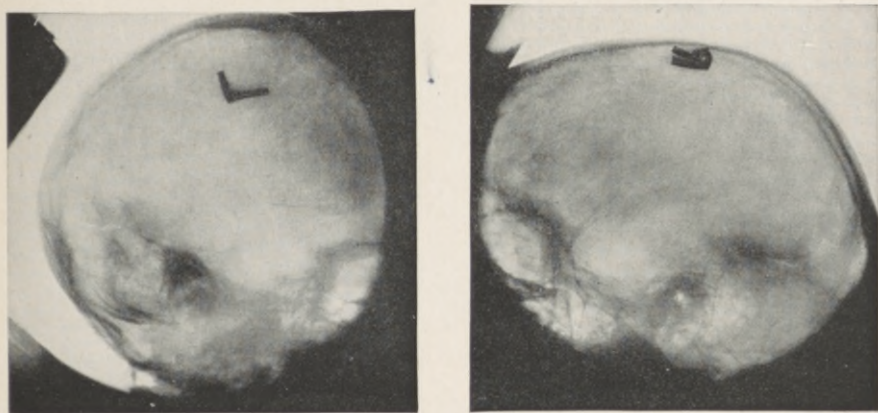


FIG. 102.—Stereoscopic views of chronic mastoiditis of the left side: The cells are completely obliterated on the left side, which is the side involved.

common cause of pain in this joint, accompanied by limitation of motion.

**Intracranial Tumors.**—It is only rarely that tumors within the skull can be directly demonstrated roentgenologically, that is when they have undergone extensive calcification. There are two means, however, that have become of great value in diagnosing the presence, location and size of intracranial tumors, namely, the changes visible in the bones of the skull and the changes in the size and location of the ventricles of the brain after introduction of air into them.

The changes produced in the bone may be either in the nature of general changes due to increased intracranial pressure or of local destruction of the inner table of the skull. The former is manifested by the appearance of smooth, oval-shaped excavations on the inner surface, usually appearing first in the frontal region. The convolutional depressions become deepened and there is a gradual sharpening of all the ridges and bony points inside the skull. The local effect of a tumor is bone destruction due to pressure. In this connection, the roentgen examination is very valuable for the diagnosis of hypophyseal tumors. The normal sella differs widely in different individuals in its contour and size, and allowance must be made for normal variations within very wide limits. A tumor of the hypophysis causes gradual destruction of the sellar structures (Figs. 103 and 104), including the dorsum sellæ, the anterior clinoid processes and the floor. In addition to the sellar changes there may also be present the general changes due to acromegaly such as thickening of the bones,



increase in size of the sinuses, and enlargement of the mandible. Schuller<sup>1</sup> differentiates tumors arising within the sella from those arising from the hypophysis just

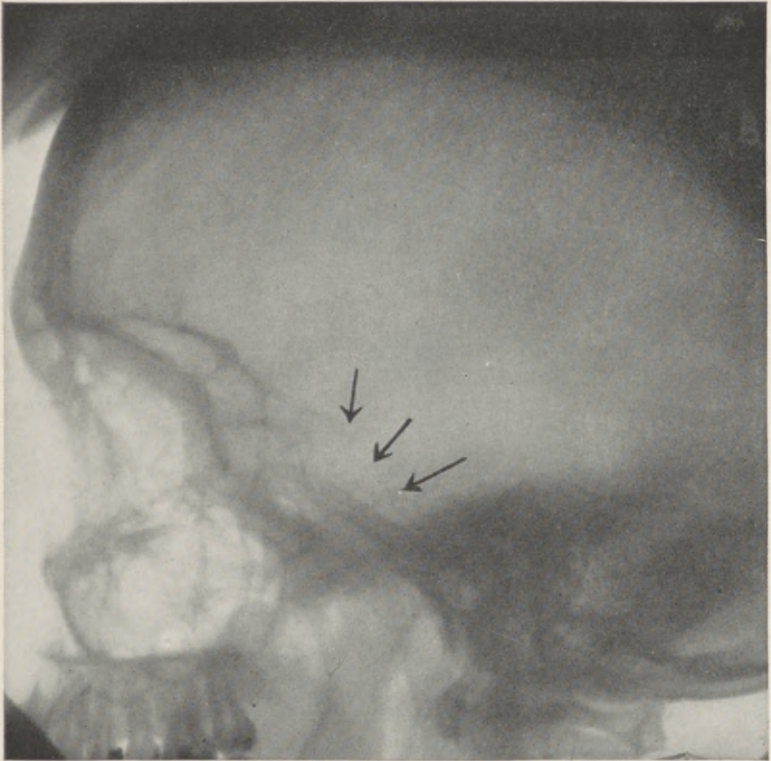


FIG. 103.—Pituitary tumor. The posterior arrow points to what remains of the dorsum sellæ, and the anterior one to the partially destroyed anterior clinoid processes.

above the sella in the following way: “Hypophyseal tumors arising intrasellar widen and deepen the sella in such a way that its floor is thinned and brought

<sup>1</sup> Roentgen diagnosis of diseases of the head. Stocking Schuller. C. V. Mosby Co., St. Louis, 1918.

closer to the floor of the middle cranial fossa, that the dorsum sellæ appears thinned, pushed posteriorly, tipped backward, and elongated. The angle formed by

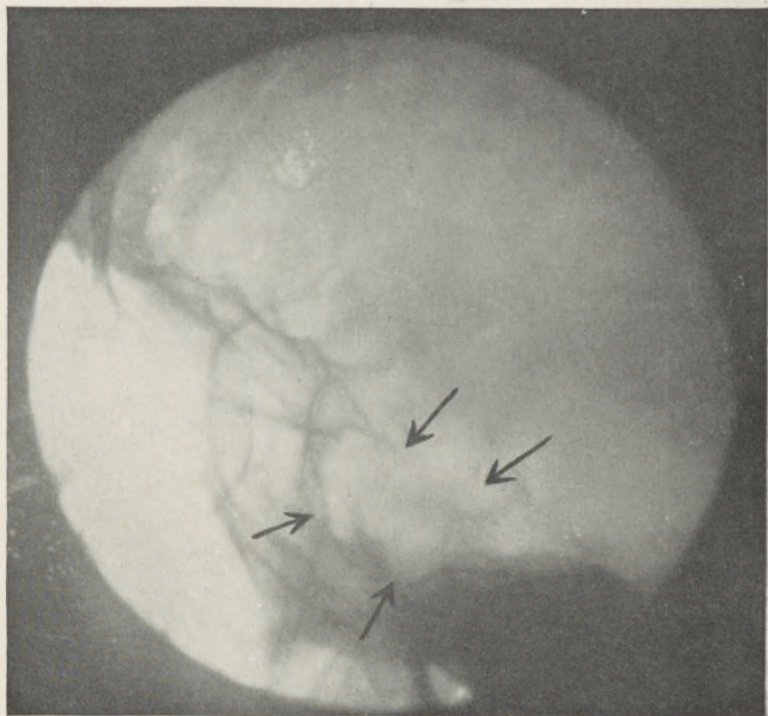


FIG. 104.—Pituitary tumor. The upper arrows indicate what remains of the anterior and posterior clinoid processes. The lower arrows indicate the lower limit of encroachment of the tumor. The fossa is greatly deepened and encroaches upon the sphenoidal sinuses.

the projection of the dorsum sellæ and the planum sphenoidal becomes more acute. The anterior clinoid processes seem normal or pushed upward and their under surface hollowed out or strikingly plump. Acromegalic changes are frequently found in the rest of the

skull, as shown by thickening of the wall and the bony ledges, and enlargement of the accessory sinuses.

“Hypophyseal tumors arising extrasellar produce a flat, saucer-like widening of the sella in which the dor-

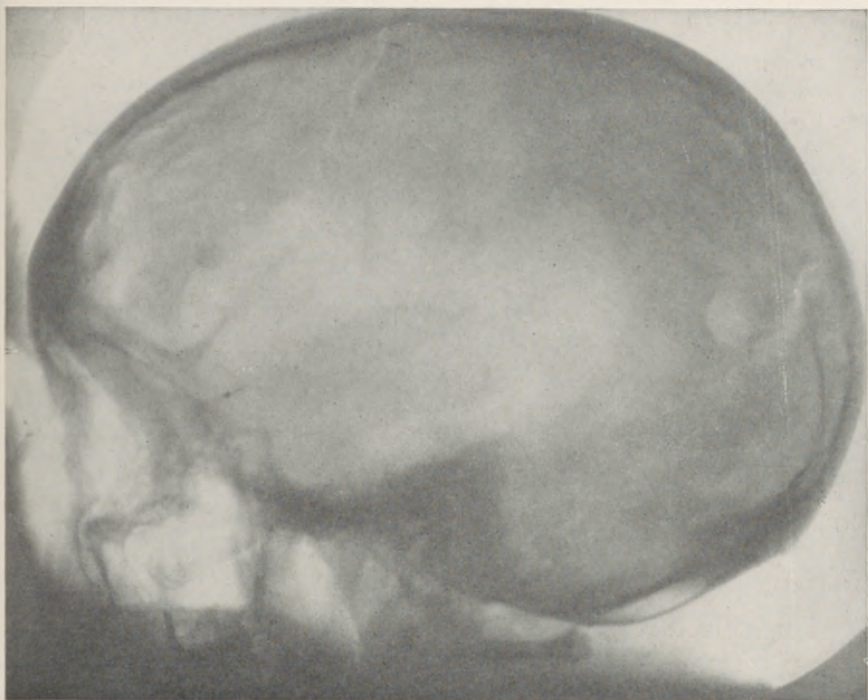


FIG. 105.—The normal lateral ventricle as shown by pneumography.

sum becomes thinned, shortened; the anterior clinoid processes are pointed or shortened. The floor of the sella is not pushed much closer to the floor of the middle cranial fossa and forms an obtuse angle with the planum sphenoidal. In the rest of the skull are found no acromegalic changes but rather a thinning of the wall in consequence of increased intracranial pressure.”



The method of localization of brain tumors by injection of air into the lateral ventricles—*cerebral pneumography*, has been developed by Dandy<sup>2</sup> to a point of great practical value. To carry out this method, air is substituted for the cerebrospinal fluid in the ventricles through small openings made on each side of the skull over the posterior horn of the lateral ventricle. The needle is inserted through the opening in the skull into the posterior horn of the ventricle and the cerebrospinal fluid withdrawn. Air is drawn into the syringe and injected into the ventricle equal in amount to the fluid withdrawn (Fig. 105). By turning the head in various directions the air can be shifted to different parts of the ventricular system. A tumor in either hemisphere of the brain will modify the shape, size or position of the corresponding lateral ventricle (Fig. 106) or even of the ventricle in the opposite side.

Roentgenograms are made in both lateral projections and in the anteroposterior and the posteroanterior.

The procedure is one that should be undertaken only by an experienced brain surgeon and much experience is required for a proper interpretation of the roentgen findings.

**DENTAL ROENTGENOGRAPHY.**—There are two methods of making roentgenograms of the teeth, the intraoral and the extraoral method.

In the intraoral method a small photographic film wrapped in paper impervious to light is placed inside the mouth, as nearly as possible against the teeth that are under investigation. In the extraoral method the pic-

---

<sup>2</sup>Localization or elimination of cerebral tumors by ventriculography. *Surg. Gynec. Obst.*, Oct. 1920, xxxi, 340.

ture is taken upon a film placed beneath the patient's head, the central ray being directed as shown in Figure 89.

In both methods the important point is to have the

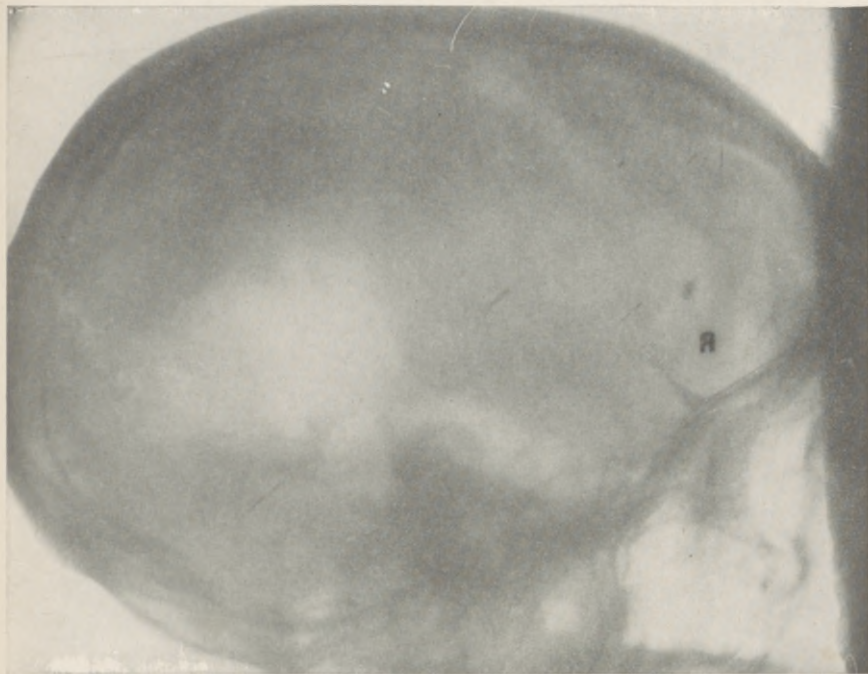


FIG. 106.—Obliteration of the anterior horn of the lateral ventricle by a tumor of the frontal lobe.

correct angle of incidence of the roentgen rays upon the film or plate. This is especially true of the intraoral method. It is readily seen that in roentgenographing the teeth of the upper jaw the film cannot be placed parallel to the teeth. Its position depends upon the slant of the roof of the mouth. If the roentgenogram is made with the direction of the rays at right angles to

the teeth they will appear elongated and distorted, while if the angle is too small the shadow of the teeth will be foreshortened. Figures 107 to 111 illustrate the



FIG. 107.—Hand holding film in mouth for the X-raying of upper incisors and adjacent teeth.

proper positions for the majority of cases for roentgenography of the teeth.

The intraoral method is the best for all cases in which it is desired to secure detail about the teeth, but for fractures of either jaw, and in cases where it is necessary



to show the relations over a wider area than can be covered by a film, the extraoral method is applicable.

Good roentgenograms of the teeth and jaws give



FIG. 108.—Left hand holding film in mouth for the roentgenographing of the right upper cuspids and bicuspid.

much valuable information in various abnormal conditions. Among these may be mentioned periapical infection, including pericementitis, granuloma, abscess, and cyst formation; the presence and position of unerupted teeth; the condition of root-fillings and pivot teeth; and the shape, position, length, etc., of roots of teeth upon which bridges or crowns are to be placed.

Interpretation of dental roentgenograms should be attempted only by those who have a knowledge of the anatomy, both normal and pathological, of the teeth

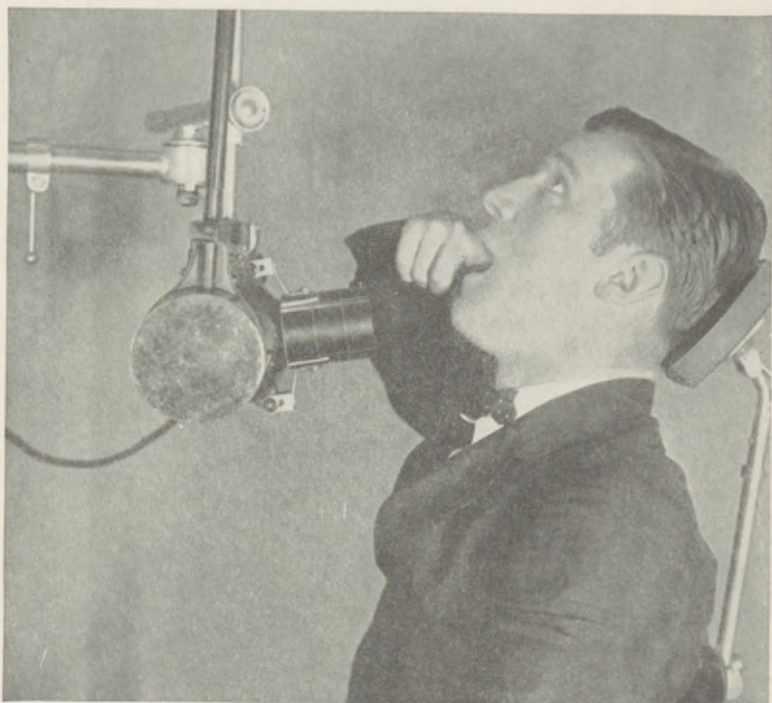


FIG. 109.—Position of film and tube for roentgenogram of lower incisors.

and jaws. It is the duty of the medical roentgenologist to describe as accurately as possible all departures from the normal shown by the roentgenogram, and to state, if possible, his opinion of the underlying pathological condition responsible for such changes. He is precluded in most cases from making a complete diagnosis because of his lack of knowledge of the clinical manifestations.

The diagnosis must be made and the treatment decided upon by the dentist who receives the roentgenologist's report or by a dental roentgenologist who, in addition



FIG. 110.—Left hand holding film in mouth for the X-raying of the right lower molars.

to the information obtained from the roentgenogram, is also in possession of that obtained from a careful clinical examination.

Crane<sup>3</sup> describes in a clear and simple way the proper

<sup>3</sup>A practicable root canal technic. Arthur Barton Crane, D. D. S., Lea & Febiger, 1920.



method of interpreting dental roentgenograms. "In reading a dental X-ray film, the teeth known to be normal should first be studied. The use of a good



FIG. 111.—Left hand holding film in place for X-raying of the right lower cuspids and bicuspids.

reading glass, or denticope, will be of great help. It will be noted in the case of a normal tooth that the pericementum can be traced around the root as a continuous radiolucent line. Adjacent to and surrounding this will be seen the lamina dura or radiopaque line.

It will also be noted that the trabeculæ of bone about the apex are homogeneous with the bone which lies adjoining.

“Infection is microscopical and cannot be radiographed. What we look for in the film is not infection, but the results of infection. Thus it may happen that a tooth recently infected or one long the habitus of organisms of low virulence may present a radiographic record in no way differing from the normal. Again, in the entire absence of infection there may be a rarefying process in the adjacent bone sufficient to cause a most decided radiolucent area. This latter picture is caused by over-stimulation, as in traumatic occlusion or orthodontic procedure, and may also be observed about the forming roots of adolescence. Bearing these points in mind, the suspicious tooth should be examined to see in what manner it differs from the normal.

“The first thing to look for is a thickening or break in the line of the pericementum at the apex of the root. Next, the bone about the apex should be examined for radioparency or radiolucency, and the presence or absence of the lamina dura noted; thence the periphery of the apex should be studied for roughness. When any or all of these signs are recorded in the radiograph of a tooth which the clinical examination has shown to be non-vital, we may safely conclude that the tooth is infected, and that we are dealing with periapical disease.”

## CHAPTER XI

### THE CHEST

THE *technic* of roentgenography of the chest is not difficult, but considerable care and experience are necessary to secure roentgenograms which give the greatest possible detail.

Stereoscopic roentgenograms are of immense value in diagnosing intrathoracic conditions, so much so that it is rarely advisable to make single roentgenograms of the chest. In the stereoroentgenogram every structure appears in its true relation to other structures, making it possible to avoid those mistakes in interpretation unavoidably caused by the superimposed shadows of the flat picture.

Roentgenograms of the chest should be made with the patient in the erect position, either sitting or standing, in order to avoid the blurring of the lung markings caused by upward displacement of the diaphragm and congestion of the blood-vessels present when the patient is prone. For the same reason the distance from the tube to the film should not be less than 40 in., and 60 in. is even better. The 30 ma. self-rectifying tube may be used with spark backup not to exceed 5 in. This will enable one to produce satisfactory roentgenograms at 60 in. distance with rapid double-coated films placed between good intensifying screens. It is absolutely essential that the screens make perfect contact with the film on all parts of its surface. The slightest lack of con-



tact will produce blurring of the roentgenogram which will render it valueless.

To make the stereoscopic pair of roentgenograms, the target of the tube is centered over the spine on a level with the spines of the scapulae, and the cassette containing the film is placed against the front of the chest. The patient takes a moderately deep breath and holds it in inspiration while the exposure is made. The tube is shifted 3 in. toward the patient's feet, a second film substituted for the first, and the second exposure made, all while the patient holds his breath. The entire procedure need occupy only a very few seconds.

The *roentgenoscopic examination* is also made with the patient erect and the screen against the front of the chest. A rapid survey is made to note any apparent limitation in the movements of the diaphragm or unusual fixation at any point by adhesions. Any apparent lack of aeration or any unusual density in the lungs is noted. The screen examination is especially valuable when fluid is present to note its upper level and whether it seems to be free or encapsulated. When air is present with the fluid the contrast is so great that the upper level of the fluid may be seen to move upon any sudden movement of the patient. The screen examination is invaluable for examination of the heart and great vessels, and of the posterior mediastinum. For the latter the patient is rotated to the right anterior oblique or the lateral position.

The first essential for the study of roentgenograms of pathological conditions in the chest is experience in interpreting the shadow cast by the normal chest

(Fig. 112). The dense shadow extending down through the middle of the roentgenogram is cast by the sternum,

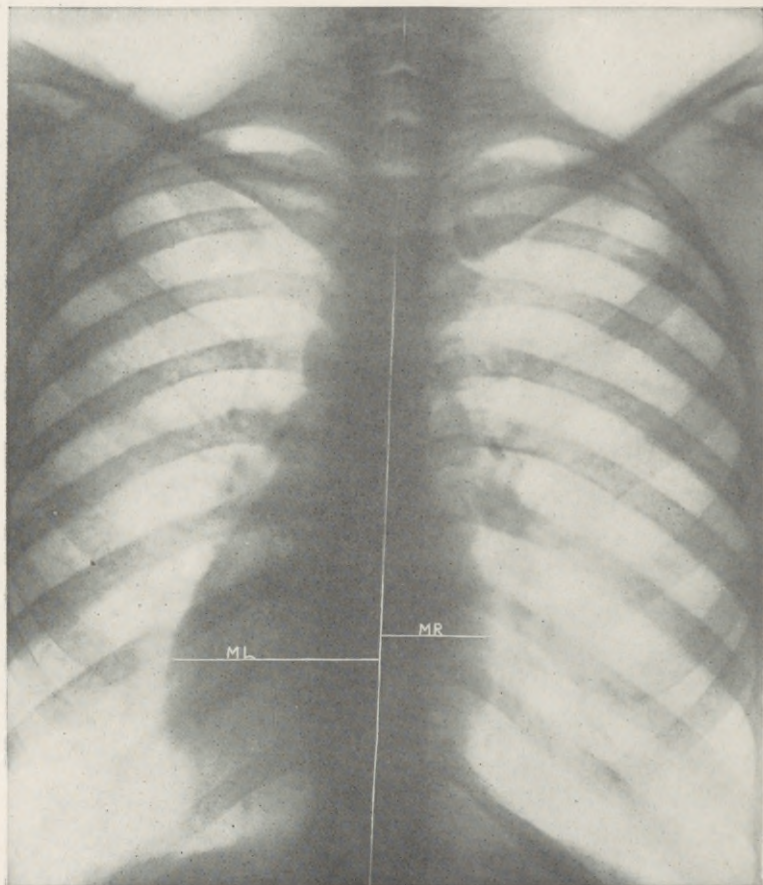


FIG. 112.—The normal heart and aorta.

spinal column, heart and great vessels, esophagus, trachea, lymphatics, and connective tissue. On either

side of this central shadow is an irregular shadow of less density, that of the hilum. This is cast by the primary branches of the pulmonary vessels with their contained blood, the walls of the primary bronchi, and the lymphatic and fibrous tissue surrounding these structures. Inflammatory processes in early life produce such changes in the lymph-nodes at the hila that the roentgen appearance of this region is very unreliable as a basis for opinion as to the presence of a pathologic process.

Radiating from the hila are seen linear shadows which subdivide as they extend through the lung field. It has been quite definitely proven that these shadows are produced by both the bronchi and the blood-vessels with their accompanying connective tissue. These linear markings gradually disappear as the periphery of the lung is reached.

**THE HEART.**—This organ should be studied both by roentgenoscopy and roentgenography. The screen examination notes the apparent size, shape and position of the heart, variations from the normal in its pulsation, and the presence of adhesions between the pleura and pericardium or the pericardium and diaphragm.

The roentgenogram of the heart should be made at a distance of 6 ft., and when so made there will be very little distortion and practically no enlargement. The exposure is made with the patient standing with his chest pressed against the cassette and the target on a level with the ninth dorsal spine.

The shape of the heart varies even in healthy individuals, but there are certain constant characteristics.



These are shown in Figure 112. The configuration of the heart varies with the obliquity of its long axis. The axis is more nearly horizontal in broad-chested people and quite vertical in the narrow-chested. A high diaphragm caused by adiposity, gaseous distention of the stomach or colon, ascites or abdominal tumor causes the heart to rotate into a horizontal position and makes it appear larger than normal.

The size of the heart<sup>1</sup> has been computed in a large number of healthy individuals based on the area of the roentgen shadow. Bardeen<sup>2</sup> has constructed a table giving the approximate area for individuals of either sex at various ages and of various heights and weights. The reader is referred to Bardeen's articles for description of the method.

The dimensions of the heart most commonly used are indicated in Figure 112. ML and MR indicate respectively the distance of the left and right borders from the mid-line. The sum of ML and MR equals T the transverse diameter. A practical working rule is that the heart is enlarged if T exceeds one-half the greatest diameter of the chest, the roentgenogram being made at a distance of 6 ft. The relation of MR to ML is approximately 1 to 2. Dilatation or hypertrophy of the heart results in an increase in size of the entire heart shadow and in an increase of both MR and ML.

Displacements of the heart are readily recognized by the roentgen examination. They are commonly due to

---

<sup>1</sup> Bardeen, C. R. Determination of the size of the heart by means of the X-ray. *Am. J. Anat.*, 1918, xxiii, 423-4.

<sup>2</sup> Bardeen, C. R. Tables for aid in the determination of size of the heart by means of the roentgen ray. *Am. J. Roentgenol.*, 1917, iv, 604-610.

adhesions accompanying tuberculosis, the presence of large tumors or pleural effusion, or to deformities of the thoracic cage.

Valvular lesions produce more or less characteristic changes in the contour of the heart. Mitral insufficiency causes a general enlargement of the heart shadow which is somewhat globular in shape. Mitral stenosis causes an unusual prominence of the left auricular shadow. Aortic insufficiency causes increase in size of the shadow of the left ventricle, and moderate widening of the aortic arch. The transverse position of the heart is the most noticeable feature of this lesion.

Atheroma of the aorta accompanying renal disease causes moderate widening of the aortic arch which is sometimes mistaken for aneurysm, but this mistake can be avoided by noting the diffuse character of the dilatation. There is also prominence of the shadow of the arch in old people that must not be confused with aneurysm. Syphilitic aortitis causes a general widening of the arch which is more marked in the early stages of the disease about the origin of the aorta. This is best seen with the patient in the right anterior oblique position.

**Aneurysm of the Aorta.**—Roentgen examination is of great value in the diagnosis of aortic aneurysm, since a large number of aneurysms fail to give any clinical signs at all or only those that are inconclusive. In many cases the roentgen appearance of aneurysm is typical. The two varieties are the fusiform and the sacculated. The fusiform type is usually seen as a general dilatation of the entire aortic arch. As aneurysms of

this variety increase in size a sacculated aneurysm may be formed at some especially weak point.

Sacculated aneurysm is most common in the ascending portion of the arch. It is sometimes of very slow growth and usually extends out into the right lung field. Sacculated aneurysms are often multiple and are sometimes of enormous size. Aneurysms may usually be recognized by their roentgen appearance but occasionally it is very difficult to differentiate them from mediastinal tumors. A positive Wassermann is, of course, a very important help in arriving at a diagnosis. Aneurysm is usually smooth and clear cut while tumors may be lobulated and the edges irregular and hazy. The shadow of the normal aorta may sometimes be distinguished from a tumor shadow. Tumors are usually of more rapid growth than aneurysm and repeated examinations may reveal this. Pulsation when present is of some value for diagnosis, but some tumors pulsate and a considerable number of aneurysms do not.

The screen examination is invaluable. The oblique positions are likely to give more information than any others.

The conus of the pulmonary artery is enlarged in mitral disease and in congenital heart disease, notably in persistent ductus Botalli. Aneurysm of the pulmonary artery is rare but does occur.

**Pneumothorax.**—This condition is readily diagnosed either by screen examination or by roentgenography. The space filled by the air offers but little resistance to the passage of the ray, so that it appears very bright on the screen and perfectly black on roentgenograms.



Another important point, and one which distinguishes pneumothorax from emphysema, is the absence of the lung markings over the area occupied by the air. The size and shape of the pneumothorax depends largely upon the presence or absence of pleural adhesions. If no adhesions are present, the lung is compressed more or less symmetrically and forms a dense mass in the region of the hilum. The apices most commonly remain uncompressed because adhesions are most common in that region, but occasionally the pneumothorax will occupy only the apical region and leave the lower part of the lung uncompressed. The heart and mediastinal structures are often displaced by the pressure of a pneumothorax. Sometimes several separate areas of pneumothorax may be present, separated from each other by pleural adhesions.

**Pleurisy.**—Acute pleurisy without effusion gives practically no roentgenologic evidence of its presence, except perhaps slight limitation of movement of the diaphragm. Free effusions in the pleura are readily recognized by their roentgen appearance. They produce a dense shadow which first obliterates the costophrenic angle, and later extends upward until it may cause opacity over the entire lung field. Change of position will show a change of level of the fluid which will be particularly noticeable if air is also present in the pleural cavity. Wessler and Jaches<sup>3</sup> call attention to the fact that a very early fibrinopurulent exudate complicating lobar pneumonia may be recognized by a dis-

---

<sup>3</sup> *Clinical Roentgenology of Diseases of the Chest.* H. Wessler, L. Jaches. The Southworth Pub. Co., 1923.

tinctive shadow—a narrow band in the axilla extending from apex to base. This is followed in a few days by a true fluid exudate with characteristic picture. Encap-

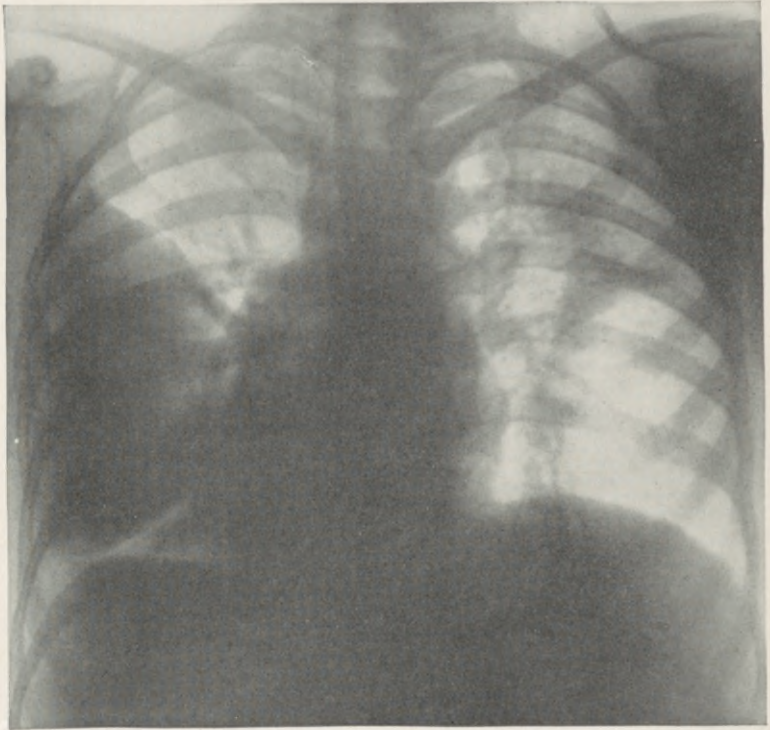


FIG. 113.—Encapsulated pleural exudate.

sulated effusions are often very difficult to diagnose by clinical means and the roentgen method is of great value. The effusion may be encapsulated by adhesions along the periphery of the lung (Fig. 113), between the diaphragm and the lung, in the interlobar fissures, or between the mediastinum and the lung. It is not unus-

ual to have two separate sacculations of fluid having no connection with each other. Tuberculosis of the pleura is not infrequent and manifests itself by pleural effusion, by thickening, and by calcification of the tubercles.

The study of the conditions present in *chronic empyemata* which have been opened and drained, is greatly facilitated by roentgen examination. Usually there is an area of pneumothorax along the lateral chest wall limited mesially by the retracted lung. The pleura may be greatly thickened over the lung and there may be extensive adhesions. The size of the cavity and its ramifications may be demonstrated by roentgen examination after injecting the sinus with Beck's bismuth paste. Occasionally a rubber drainage tube or other foreign body is discovered in the cavity.

**THE MEDIASTINUM.**—In acute mediastinitis a widening of the mediastinal shadow occurs that may be of assistance in diagnosis but which is not typical.

Abscess of the mediastinum causes a localized bulging into the lung filled which cannot be distinguished from an encapsulated pleural effusion in that region.

Chronic mediastinitis resulting in adhesions is usually the result of tuberculosis or syphilis. The adhesions may occur between the pericardium and pleura and cause irregularities in the cardiac shadow. The mediastinum may be greatly distorted as a result of adhesions accompanying pulmonary tuberculosis in the upper lobes. Wessler and Jaches call attention to the occurrence of strictures and distortions of the esophagus caused by chronic inflammatory processes in the mediastinum.



**Tumors of the mediastinum** produce an increase in the width of the mediastinal shadow. The increase in width is usually bilateral although not equal. They are usually smoother in contour than lung tumors and can often be distinguished from the latter by examination in the oblique positions.

**Lymphosarcoma** is a common mediastinal tumor which, by its rapid growth, often causes extreme dyspnoea and cyanosis from pressure upon the bronchi and blood-vessels at the roots of the lungs. It can usually be diagnosed by the presence of the large bilateral shadow. Primary carcinoma is rare in the mediastinum but metastatic carcinoma is not infrequent. The latter involves the lymph-nodes and may be so extensive that the shadow produced by it may entirely overshadow a primary carcinoma of the bronchus from which it has arisen.

**The thyroid gland**, when enlarged, may be partly intrathoracic. It may be centrally situated in the upper part of the thorax but usually extends outward to either side, more often to the right than to the left. The trachea is usually displaced and often narrowed by the pressure. These enlargements of the thyroid may extend only into the upper aperture of the chest, but on the other hand, they may extend downward to the arch of the aorta and even to the base of the heart.

**Enlarged thymus gland** is often the cause of asthmatic attacks in children. The roentgen shadow of the thymus gives somewhat the appearance of a keystone with the base at the root of the neck, the sides converg-

ing slightly down to the base of the heart. In children beyond early infancy care must be taken in interpretation of supposed thymic shadows because of the fre-

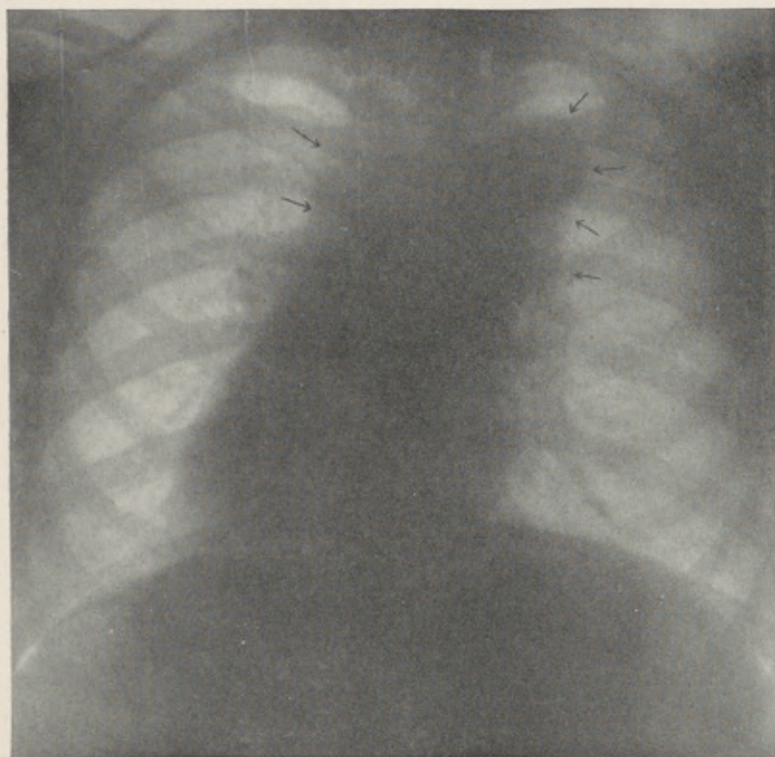


FIG. 114.—Hodgkin's disease.

quency of masses of tuberculous glands which produce a picture which it may be impossible to distinguish from enlargement of the thymus.

Benign tumors such as dermoid cysts, teratomata and fibromata occasionally occur in the mediastinum.

The roentgen appearance does not enable one to distinguish them from each other but their smooth rounded

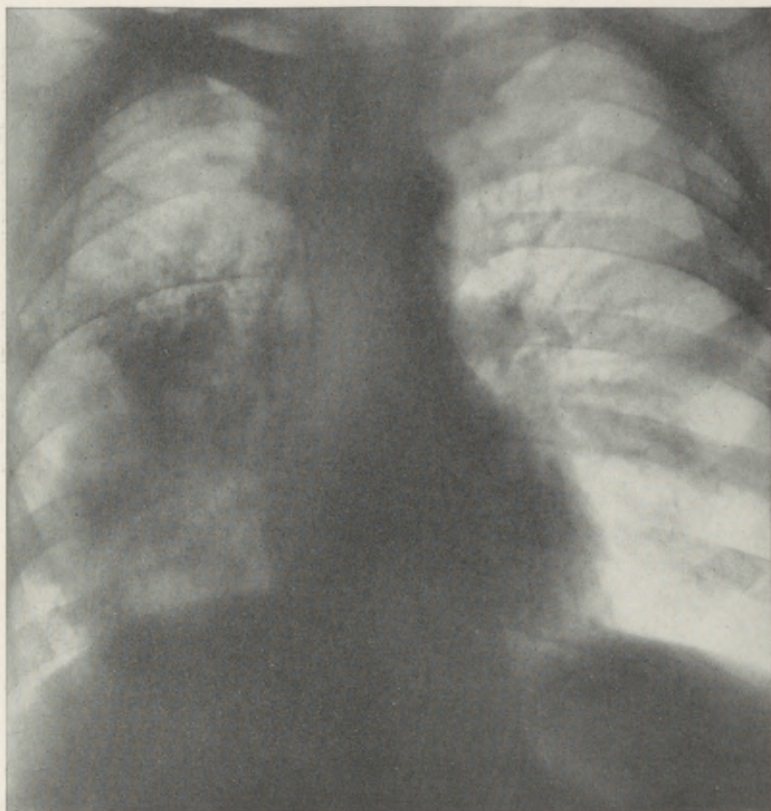


FIG. 115.—Abscess of the lung involving the right lower lobe.

appearance and slow growth will usually differentiate them from malignant tumors.

Hodgkin's disease (Fig. 114) with intrathoracic involvement may give a roentgen picture resembling



lymphosarcoma or other malignant disease of the mediastinum. Sometimes circular or lobulated masses due to Hodgkin's disease are seen scattered through the lung

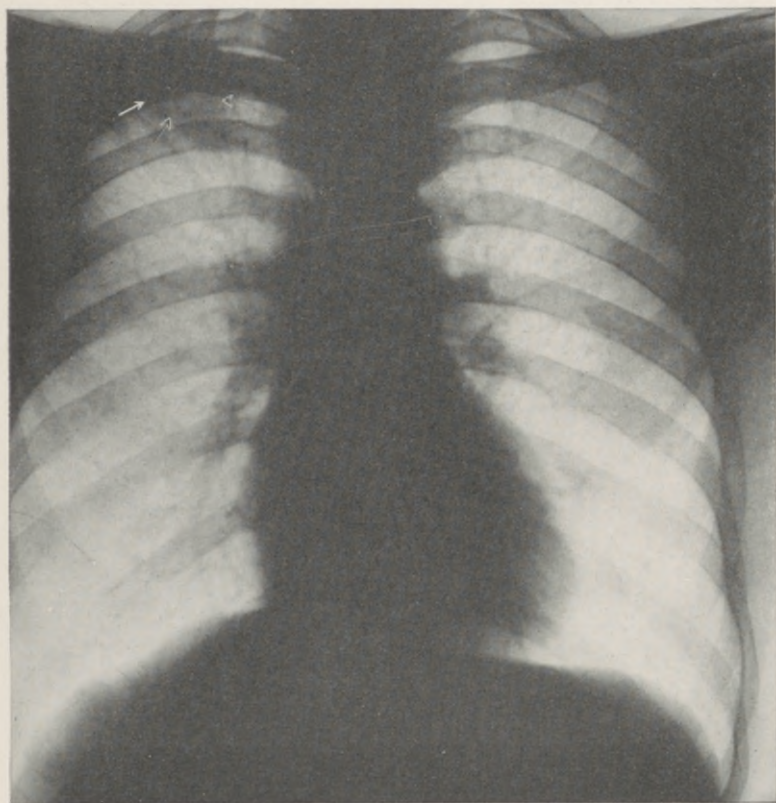


FIG. 116.—Abscess of the lung, of long duration. There is a cavity with a dense fibrous wall.

parenchyma and have the appearance of metastatic malignant tumors. There is, however, a rather typical appearance in many cases of Hodgkin's disease consisting in great enlargement of the bronchial and para-

tracheal lymph-nodes. These glandular masses are very soft and therefore cast a much fainter shadow than tuberculous lymph-nodes, which are usually caseous or calcified.

**Abscess of the lung** (Fig. 115) has a somewhat typical roentgen appearance. The areas involved, being denser than the surrounding lung structure, are more opaque to the ray and therefore appear white on the plate. The abscess cavity itself may sometimes be distinguished (Figs. 116 and 117), if it is partly empty and contains some air, but usually the appearance is that of a more or less oval area, densely opaque in the center, gradually thinning out toward the periphery, and with irregular edges.

This is the picture in the stage of the disease when there is a surrounding pneumonic process. The latter may involve an entire lobe. The patient may die during this acute pneumonic stage or the condition may continue to necrosis and excavation and finally, if the patient survives, to the formation of multiple cavities, extensive fibrosis and pleural adhesions. Complete resolution of the abscess takes place in a certain percentage of patients and when it does the roentgen examination may show a lung completely restored to normal.

In cases of **lobar pneumonia**, the roentgenogram always shows the areas of infiltration and consolidation, sometimes even before there are any physical signs. The roentgen examination is therefore of great value to demonstrate the extent of involvement, the presence of pleural exudate, and the course of resolution.

In bronchopneumonia the roentgen appearance varies from that of small discrete areas of infiltration scattered

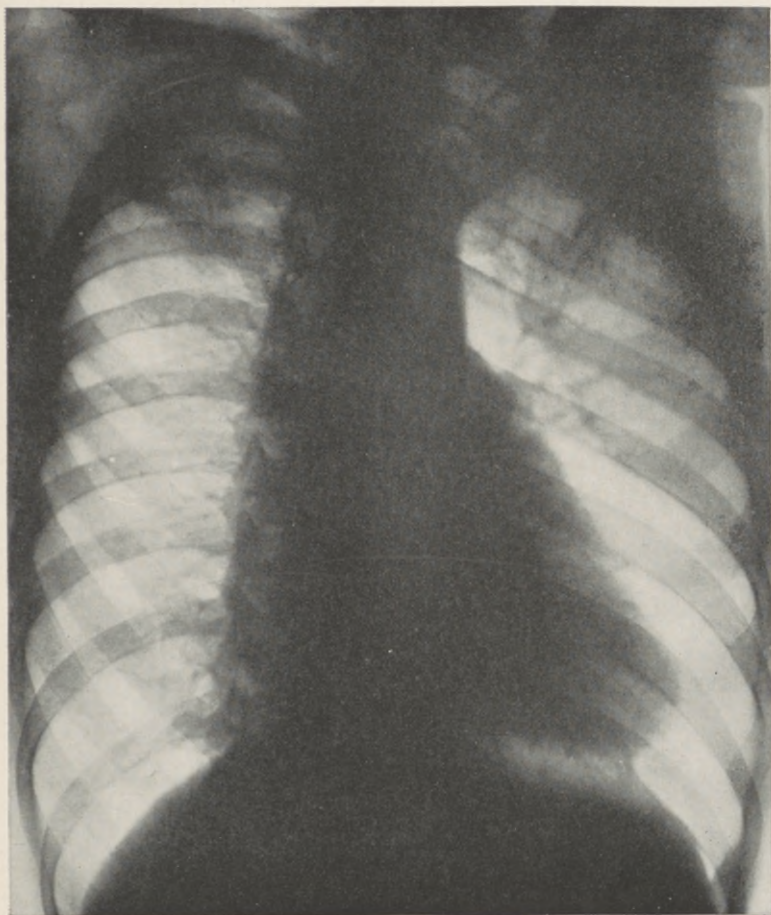


FIG. 117.—Same case as Fig. 116 in an oblique posture which demonstrates the abscess cavity with its dense fibrous wall much better than the anteroposterior view shown in Fig. 116.

throughout the lungs to consolidation of an entire lobe or even an entire lung. There are cases of broncho-



pneumonia accompanying influenza that cannot be distinguished by their roentgen appearance from pulmonary tuberculosis. The only way to be sure that such cases are not tuberculosis is to make repeated examinations as the process clears up.

**Bronchiectasis.**—Roentgen examination is important in all cases of suspected bronchiectasis since clinically this disease is very difficult to differentiate from abscess and tuberculosis. The roentgen ray does not always suffice to differentiate these conditions but it assists greatly in doing so, and in addition gives valuable information about the position, extent, and operability of the lesion.

Moore<sup>4</sup> in an unusually good presentation of the value of the roentgen ray in diagnosis of this condition classifies bronchiectasis as infiltrative, cylindric, and sacculated. He states that these three forms probably represent different stages of the disease. The infiltrative stage is characterized in the roentgenogram simply by increased density along the trunks at the base of the lung, the roentgen appearance not being at all characteristic.

The cylindric stage shows a somewhat fan-shaped shadow extending outward from the root of the lung with small areas of decreased density scattered through the area of shadow. These areas are dilated bronchioles and their presence is pathognomonic of the disease. They may be demonstrated more certainly by having

---

<sup>4</sup>Moore, Alex B. Roentgen Diagnosis of Bronchiectasis. *Am. J. Roentgenol.* 1916, iii, 524-531, and republished in coll. papers of the Mayo Clinic, viii, 1916.

the patient discharge the secretion from them by forced coughing.

The sacculated stage shows distinct pseudocavitations surrounded by dense fibrous tissue.

Moore also states that the disease "may be differentiated from chronic bronchitis by the greater increase in density along the bronchial trunks in bronchiectasis, the tendency to localize at the base of the lungs, the extension of this increased density to the periphery of the chest even as far as the costo-phrenic angle, and the presence of bronchiectatic pseudocavitation or sacculataion. Bronchiectasis is usually differentiated without difficulty from abscess of the lungs by its location, and the fact that the walls of its cavity are relatively thin and small. The cavities are multiple and there is absence of a fluid level within them."

**Pneumoconiosis.**—This condition is found in individuals who inhale a large amount of dust, notably miners, stone-cutters and metal grinders. The roentgen appearance of the lungs in pneumoconiosis often simulates certain types of tuberculosis and care must be taken to differentiate them.

The principal pathologic change in pneumoconiosis is a fibrosis which begins about the root of the lungs, gradually becomes peribronchial, then involves discrete, localized areas in the parenchyma, and finally becomes diffuse. The stage of root and peribronchial thickening cannot be distinguished from other conditions which produce like changes such as passive congestion, chronic bronchiectasis, etc. The second stage, in which there is diffuse mottling, is quite characteristic in the roentgen



picture. The third stage, that of diffuse fibrosis, shows very extensive changes throughout the lungs and pleura. In this stage there are always localized areas of emphysema, especially at the bases. The diaphragm is always restricted in movement because of the inelasticity of the fibrosed lungs but also because of extensive pleural adhesions.

A complete description of the pathologic changes and the roentgen findings in pneumoconiosis may be found in an article by Pancoast.<sup>5</sup>

**Pulmonary Tuberculosis.**—It is necessary to employ both roentgenoscopy and roentgenography in the study of this disease. The screen examination can show only the coarser markings in the lungs but it is invaluable for the study of the diaphragmatic movements, the change of level of fluid in cavities, the degree of aeration of different parts of the lung, etc. It should never be stated, however, from the roentgenoscopic examination that tuberculosis is absent. The final opinion of the roentgenologist must be based on the evidence furnished by good plates or films, preferably stereoscopic.

The lesions of very early tuberculosis are usually in the infraclavicular regions and apices and occur as small circumscribed areas of infiltration. Sometimes these areas are composed of groups of miliary tubercles, and often the area is rendered hazy or irregular by a surrounding pneumonic process (Fig. 118). Just how early pulmonary tuberculosis may be diagnosed by roentgen examination it is difficult to state, but the

---

<sup>5</sup> Pancoast, Henry K. Roentgenologic studies of pneumoconiosis and other fibrosing conditions of the lungs. *Ann. of Clin. Med.*, July, 1923, ii, 8.



general opinion now held is that the disease is susceptible of demonstration roentgenographically as soon as it can give clinical symptoms. These early lesions often

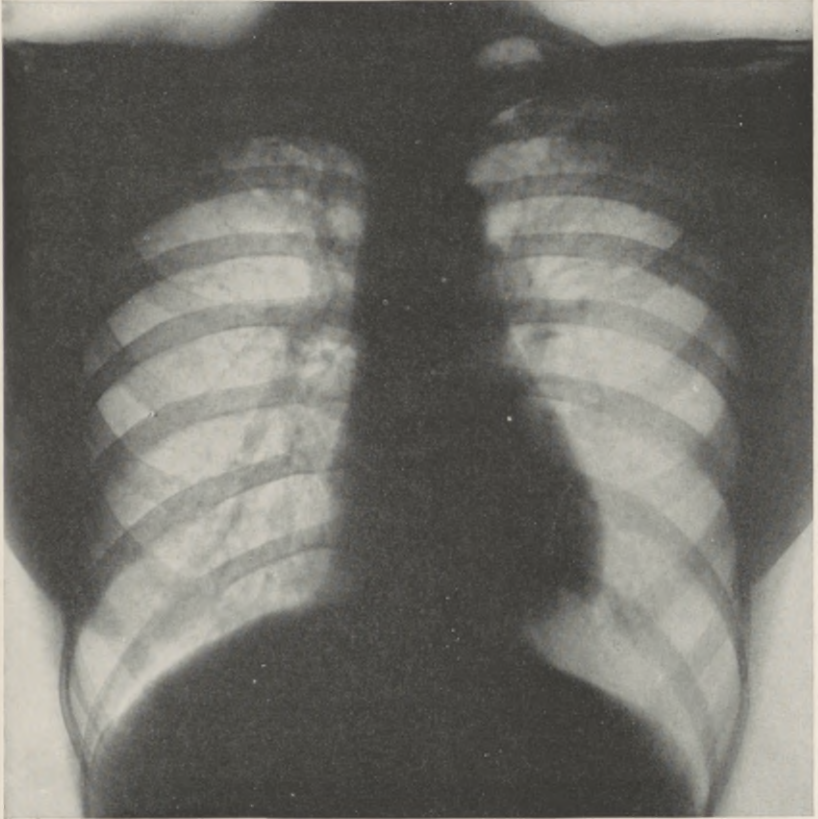


FIG. 118.—Apical tuberculosis.

heal without further extension. The area of infiltration disappears and the tubercles become caseous and their outline much sharper on the roentgenogram. If the original area involved was of considerable extent the

healing process is accompanied by fibrosis, which the roentgenogram plainly shows. The final stage in healing is calcification. If healing fails to take place during this incipient stage of the disease and it continues to a stage where it may be described as moderately advanced the roentgen appearance is not unlike that already described except that the areas of infiltration are much more extensive. The tubercles are more numerous and the entire area involved may be occupied by a pneumonic infiltration. There are likely to be other areas of the lung where fibrosis and calcification show that healing has taken place.

Advanced tuberculosis may be of the bronchopneumonic type with extensive infiltration and wide dissemination of tubercles (Fig. 119). Within the involved area may be seen numerous small cavities due to caseation and softening. Large cavities may also be seen surrounded by dense walls of fibrous tissue as the process becomes older, and entire areas may be replaced by fibrous tissue. Numerous calcified nodules or large calcified plaques are also seen. In the same lung may be seen all the stages of the disease from the tubercle surrounded by an infiltrated area, to tuberculous bronchopneumonia, and in other parts of the lung there may be excavation and fibrosis. The picture varies in different patients and in the same patient at different times according to the degree of caseation with destruction and cavity formation, or fibrosis with healing. If caseation predominates, the disease is called fibrocaseous tuberculosis, and if the fibrosis predominates it is called fibroid tuberculosis.

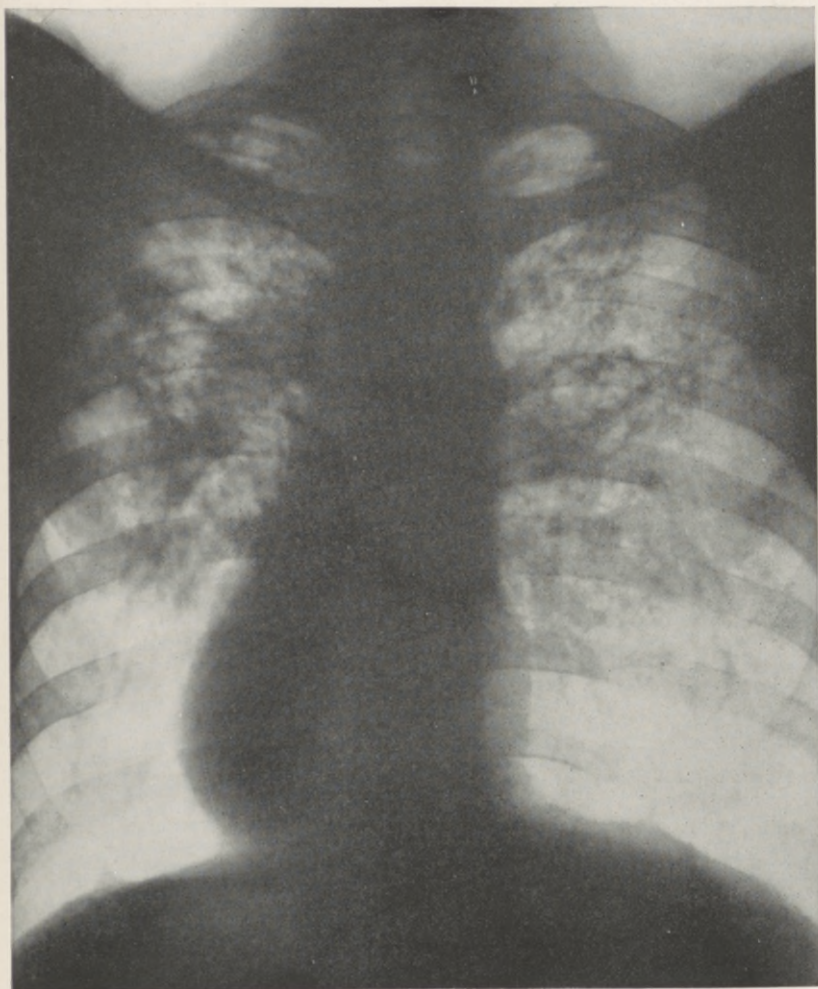


FIG. 119.—Advanced pulmonary tuberculosis of the bronchopneumonic type.



Acute pulmonary tuberculosis may be of the general miliary type or that of a tuberculous pneumonia.

Miliary tuberculosis of the lungs gives a typical roentgen picture. The lungs are studded throughout with fine nodules, so close together that it may have a general hazy appearance. When the miliary disease is purely pulmonary and not a part of a general miliary infection the picture is different and the prognosis not necessarily fatal as in the general disease. In the pulmonary form there are disseminated miliary tubercles secondary to an old fibro-caseous process.

Pneumonic tuberculosis may involve one entire lobe in which caseation takes place, when it is called *caseous pneumonia* (Fig. 120), or it may involve different areas throughout both lungs. The disease is in the majority of cases fatal.

*Hilum tuberculosis* (Fig. 121) is a rare condition and the diagnosis should be made only when there are distinct infiltrative changes in the lung extending outward from the hilum. Much harm has been done and discredit has been cast on the roentgen method by diagnosis of hilum tuberculosis, because of the presence of enlarged glands or thickening at the roots of the lungs. The same may be said of diagnosis of "peribronchial tuberculosis" because of the presence of exaggerated markings radiating from the hila. These markings are usually caused by the blood-vessels and not by the bronchi at all.

The activity of tuberculous lesions cannot be judged from the roentgen appearance. The roentgenologist should content himself by stating that the "roentgen

appearance is that of a recent infiltration," or "the appearance suggests a remote origin of the process," or

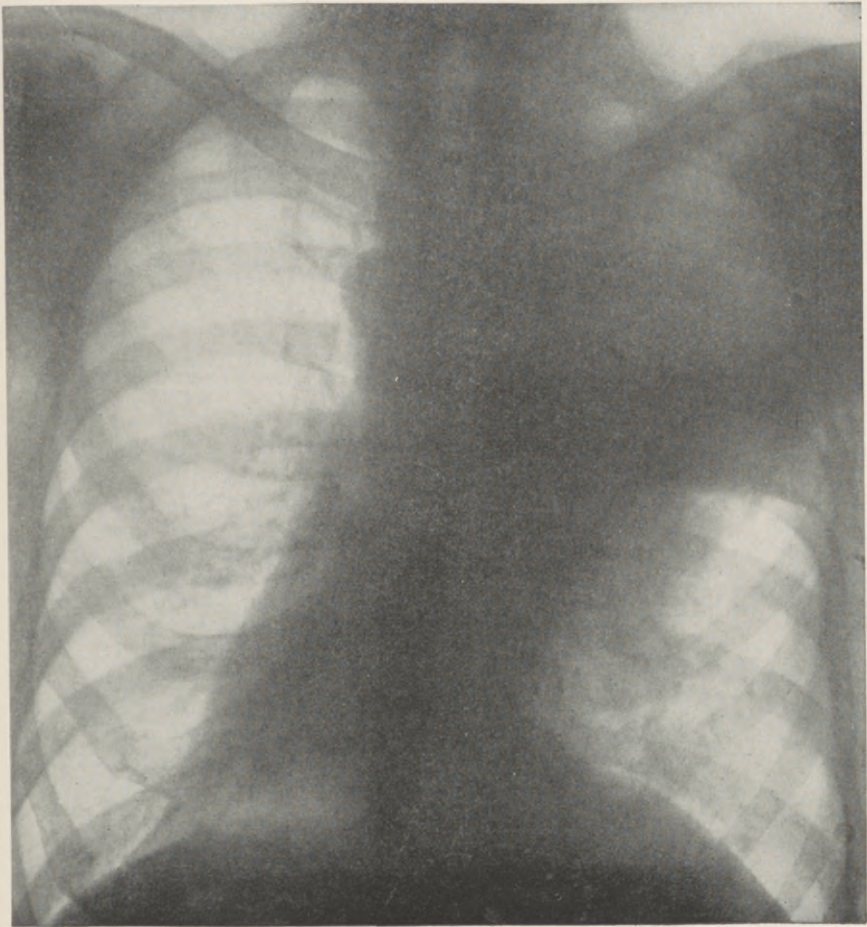


FIG. 120.—Acute pneumonic tuberculosis (caseous pneumonia) involving the right upper lobe.

that it appears to represent an acute or a chronic process as the case may be.

Pulmonary tuberculosis in children must be considered separately from the disease as it occurs in adults because of its quite different manifestations in

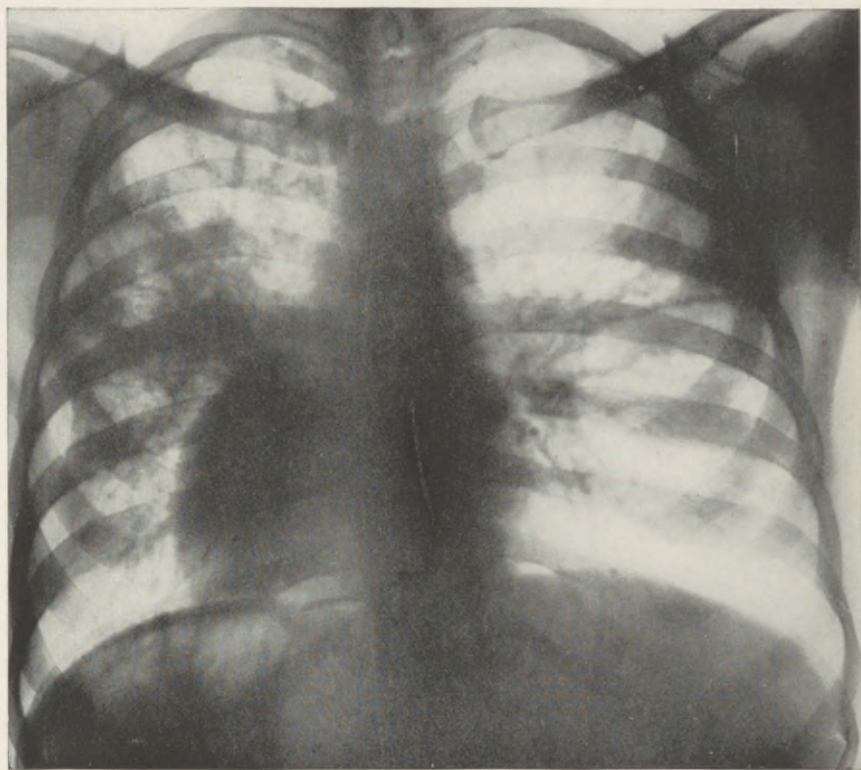


FIG. 121.—Hilum tuberculosis. The apices are not involved. Note the thickening of the interlobar pleura on the right side.

early life. The first adequate consideration of this subject from a roentgenological standpoint is found in the recent admirable work of Wessler and Jaches.<sup>6</sup> They

<sup>6</sup>Wessler, H. and Jaches, L. *Clinical Roentgenology of Diseases of the Chest*. The Southworth Pub. Co., Troy, N. Y., 1923.



summarize the sequence of events when a child's lungs are infected by the tubercle bacillus as follows: "If the attack is a massive or virulent one, the child is overcome by an acute, caseous and often rapidly fatal disease. If the invasion is mild, there results a primary lesion of small extent, situated anywhere in the lung, which usually goes on to cure by fibrosis or calcification. Coincidentally there is a tuberculous adenopathy, which may remain latent or may manifest itself clinically some time after the primary focus has healed. Finally, toward puberty, or more commonly in early adult life, there may be a tertiary infection of the lung from the mobilization of tubercle bacilli in the bronchial nodes or by massive infection from without. This tertiary form of the disease which is found nearly always in the upper lobes, because of the altered reactivity of the lung, is a chronic indurative one and is characteristic of the disease in adults." The authors then give the following classification of tuberculosis in infants and children:

"I. Primary Tuberculosis:

(a) Focal primary lesion.

(b) Caseous pneumonia, infantile phthisis.

II. Tuberculosis of the intrathoracic lymph-nodes.

III. Hilum tuberculosis.

IV. Recurrent hilum pneumonia.

V. Miliary tuberculosis.

VI. Apical tuberculosis and other adult forms."

Several of these types, *viz.*, caseous pneumonia, hilum tuberculosis, miliary tuberculosis, and apical tuberculosis and other adult forms, do not differ essentially in their roentgen appearance from types of the

disease seen in adults. The characteristic feature in children is the greater frequency of involvement of the intrathoracic lymph-nodes and the roots of the lungs. There may be such extensive disease of the tracheal and bronchial lymph-nodes that the shadow of the mass resembles a new growth and the appearance has often been mistaken for enlarged thymus. Lesions at the hila and in the lower lobes are much more common in children than in adults.

**Tumors of the Lungs.**—Benign tumors of the lungs are exceedingly rare.

**Carcinoma** is the most common of the primary tumors. There are two varieties—the bronchial and the lobar. The former arises in the mucous membrane of a bronchus and its roentgen appearance is often fairly characteristic. A roughly circular shadow will be seen extending outward from the hilum. The periphery of this shadow is not sharply circumscribed but shades off into the surrounding lung field and has projecting from it processes that radiate out into the lung. Surrounding the tumor there is likely to be an area of poorly aerated lung due to partial obstruction in the bronchus, and there is sometimes actual infiltration caused by an accompanying inflammatory process. Lobar carcinoma presents itself as a complete consolidation of a part or the whole of a lobe. It is often very difficult to distinguish it from an inflammatory process, and from caseous pneumonia.

Diagnosis of primary carcinoma of the lungs is often difficult and every means must be used in addition to the roentgen examination. Gradually increasing dys-



pnoea; a sense of tightness in the region of the hila; a dry, unproductive cough and blood-tinged sputum are suggestive signs.

Primary carcinoma must be distinguished from numerous other intrathoracic conditions. Benign tumor is usually smooth in contour and its slow growth is a distinguishing characteristic. Mediastinal tumor can usually be recognized by the fact that in the anteroposterior projection the shadow is directly continuous with the mediastinal structures and in the oblique view its mediastinal origin may be recognized. Gumma of the lung has much the same appearance as malignant tumors. The diagnosis depends upon the Wassermann test and disappearance of the lesion under anti-syphilitic treatment. Caseous pneumonia may readily be mistaken for primary carcinoma. The early symptoms may be quite indefinite just as they are in malignant disease and the roentgen picture may not be distinctive. The irregular temperature, gradually becoming higher as the disease progresses, the finding of tubercle bacilli in the sputum, and the character of the sputum, may serve to differentiate this disease from carcinoma.

Metastatic tumors of the lungs are of frequent occurrence and the roentgen examination is of great value in their diagnosis. The tumor may be carcinoma (Fig. 122), sarcoma, or hypernephroma, and it is usually impossible to differentiate them by their roentgen appearance. The early metastases give small circular shadows that are quite characteristic; they may be seen scattered throughout the lungs. Sarcoma often attains great size and may involve nearly the whole lung. The meta-



static tumors are sometimes so numerous that the appearance simulates that of extensive tuberculous involvement. A differential point is the fact that the

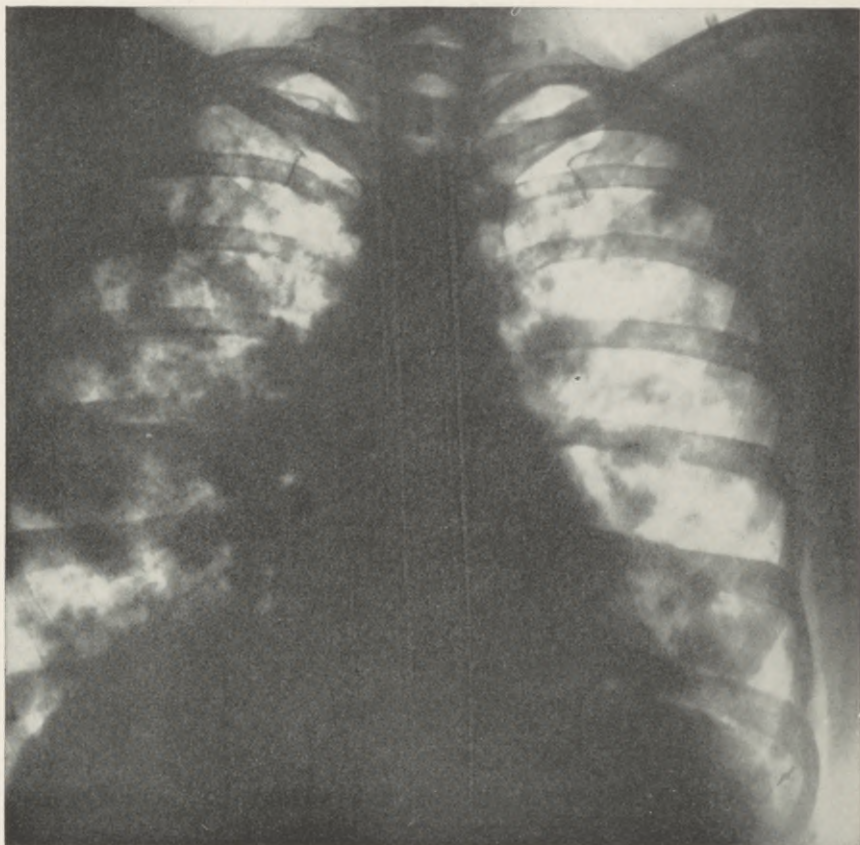


FIG. 122.—Metastatic carcinoma of the lungs.

apices are not usually involved, since the metastases usually begin in the bases. The only distinguishing characteristic between metastatic carcinoma and sar-

coma are that the latter often occurs as a very large, single tumor with smooth edge while the former is usually multiple and with an irregular edge. Metastatic carcinoma from the prostate, however, is often large and single and thus resembles sarcoma. There is a miliary form of carcinosis which may be mistaken for tuberculosis, but a careful study of the roentgenogram should avoid this error.

SYPHILIS OF THE LUNGS gives rise to such diverse pathological processes that there is no typical roentgen appearance to be described. The disease may manifest itself as a localized tumor mass—a gumma (Fig. 123); as an interstitial pneumonic process resulting in fibrosis; or as a diffuse infiltration resembling lobular tuberculosis. It must not be supposed that a case is necessarily syphilis because there are present lung changes and a positive Wassermann; many people with syphilis may also have pulmonary tuberculosis in one of its various manifestations. The only reliable test to prove that a condition is really lung syphilis is to show by roentgen examination that the shadows have disappeared after anti-luetic treatment.

FOREIGN BODIES IN THE RESPIRATORY PASSAGES are of such frequent occurrence and the results of their presence so grave, that the roentgenologist should thoroughly prepare himself to give all the assistance possible for their location and removal. When the foreign body is opaque to the roentgen ray it can often be demonstrated on the screen and nearly always on the film. Whenever a foreign body is suspected, careful examination should be made of all parts of the respiratory tract, beginning

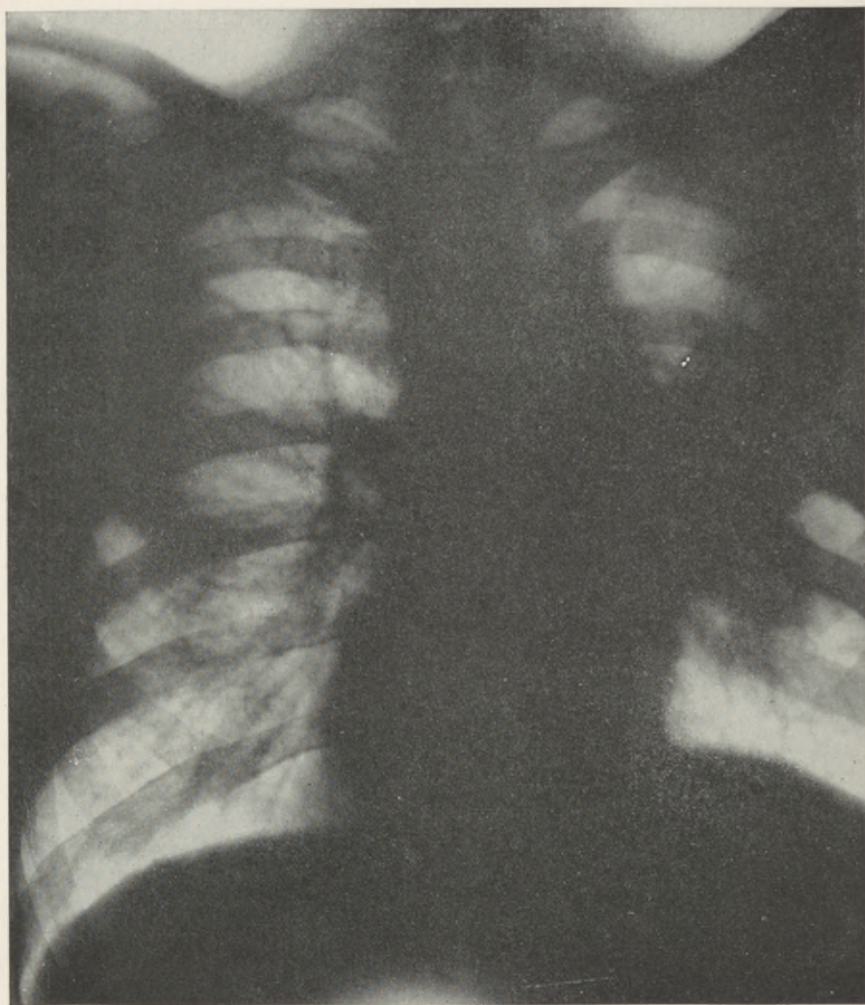


FIG. 123.—Gumma of the lung.



with the pharynx. If it is not found in the respiratory tract the digestive tract also should be examined. The screen examination is made in the posteroanterior position and in the anterior oblique positions. Films should be made in whatever positions the screen examination indicates as the best. It is important for the exposure to be short, and there must be complete immobility on the part of the patient. The slightest movement of respiration or otherwise may so blur the shadow of the foreign body as to completely obscure it. In the roentgenologist's report it is important to indicate the exact location of the foreign body; as nearly as possible its nature, shape and size; and whether there is any evidence of complications such as inflammatory reaction. The presence of non-opaque foreign bodies may often be inferred from the lack of aeration of a portion of the lung due to obstruction of a bronchus or from the presence of an inflammatory process. Manges<sup>7</sup> has described a type of case in which the non-opaque foreign body is in a bronchus, and so situated that it permits air to pass freely into the lung but offers obstruction to its escape. This produces an obstructive emphysema which gives the following signs:

- “ 1. Increased transparency of the affected lung.
2. Depression and partial fixation of the diaphragm on the affected side.
3. Displacement of the heart and mediastinal structures away from the affected side.
4. Increased excursion of the diaphragm on the unaffected side, due to compensatory emphysema.”

---

<sup>7</sup> Manges, W. F. The Roentgen-ray Diagnosis of Non-opaque Foreign Bodies in the Air Passages. *Am. J. Roentgenol.*, May, 1922, ix, 288.

**The Diaphragm.**—There is much variation within normal limits in the shape and position of the diaphragm.

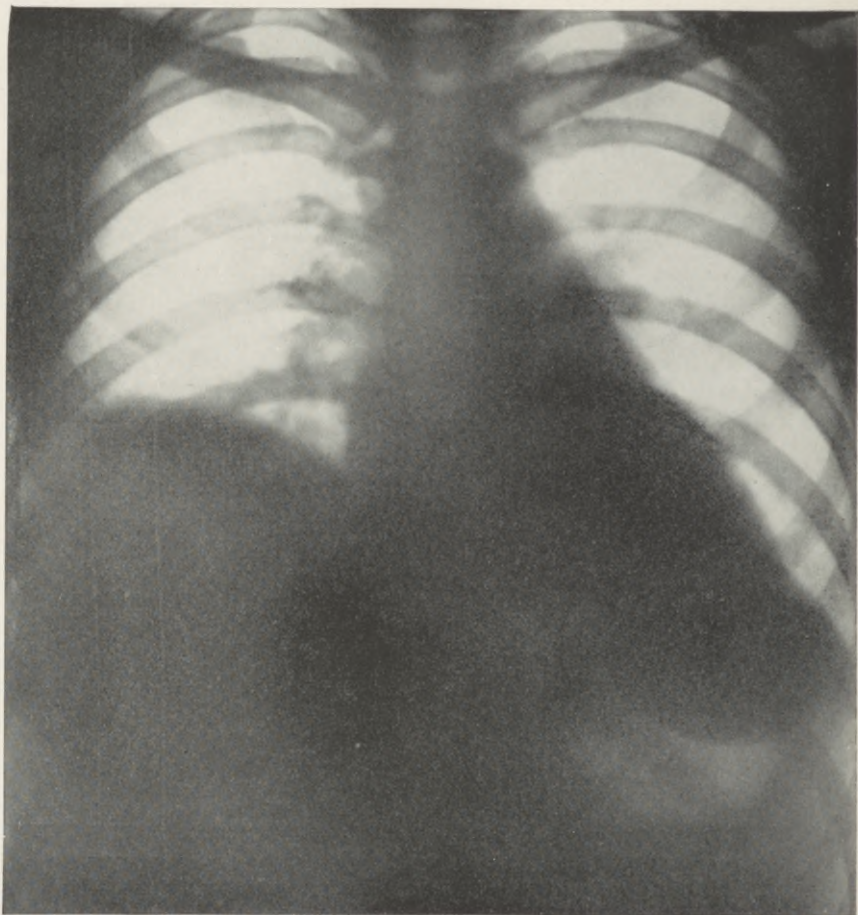


FIG. 124.—High position of diaphragm due to subphrenic abscess.

In stout, short-chested individuals the diaphragm is high and the costophrenic sulcus, deep; while in long, narrow-chested persons the reverse is true. Much ab-

dominal fat or even an excessive amount of gas in the stomach or colon may displace the diaphragm upward.

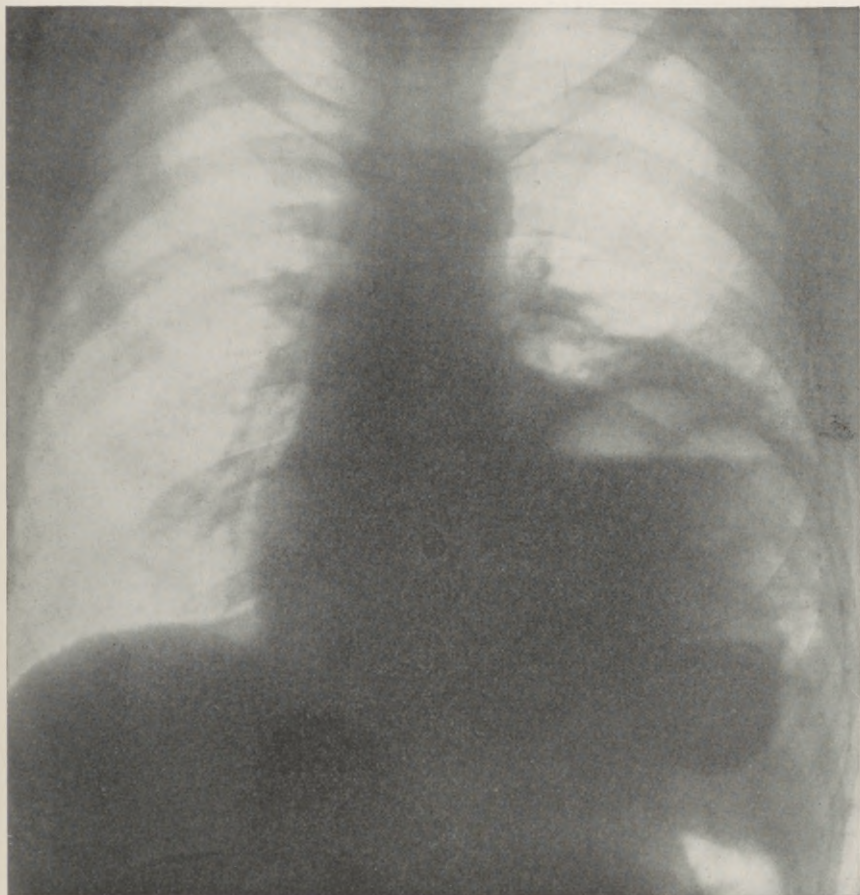

FIG. 125.—Eventration of the diaphragm. Note the high diaphragm on the left side with the bubble of gas in stomach just beneath it.

The right leaf is usually higher than the left, but gas in the stomach may elevate the left leaf so that it may be as high or higher than the right.



Both leaves are usually smooth and convex and move uniformly with respiration.

Subphrenic abscess causes an elevation of the dia-

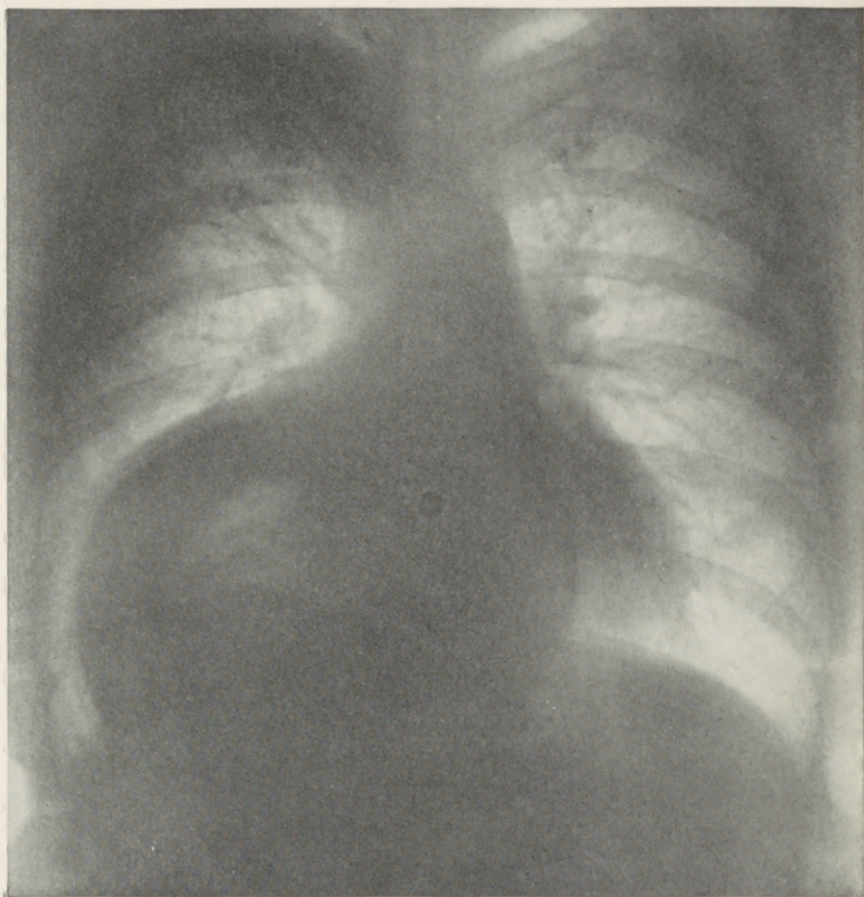


FIG. 126.—Hernia of stomach through the right leaf of the diaphragm. No history of injury.

phragm, usually on the right side. Roentgenoscopic examination will show fixation or limitation in motion,

in addition to the high position of the diaphragm. Great care must be exercised to differentiate this condition, which is below the diaphragm, from pleuritic effusion or lower lobe pneumonia with effusion. Sometimes in subphrenic abscess there is gas in the abdominal cavity which enables one to recognize the condition instantly upon the screen. The gas rises to a position under the diaphragm and above the fluid where it is plainly seen.

New growths in the abdomen and conditions which cause enlargement of the liver, such as gummata or abscesses (Fig. 124) may also cause elevation of the diaphragm.

*Eventration of the diaphragm* (Fig. 125) is not a very common condition and the only accurate means for its recognition is the roentgen examination. It may occur on either side. The diaphragm is seen as a thin, smooth, convex shadow. The upward displacement may be to almost any degree, sometimes to the level of the second rib.

*Hernia of the diaphragm* (Fig. 126) can, in many cases, be differentiated from eventration by demonstrating the shadow of the smooth, intact diaphragm in the latter condition.

Paralysis of the diaphragm on one side may be due to pressure on the phrenic nerve. The diaphragm on the affected side is immobile and occupies a high position.

## CHAPTER XII

### EXAMINATION OF THE GASTROINTESTINAL TRACT

THE gastrointestinal tract may be studied both roentgenoscopically and roentgenographically by filling the lumen of the organs with some substance opaque to the rays. The opaque substance now in general use is barium sulphate. This must be especially prepared for use in roentgen diagnosis so that it is free from all soluble barium salts. It has the advantage of being much cheaper than bismuth subcarbonate which was formerly in general use.

The opaque meal is prepared by mixing three ounces of barium sulphate with eight ounces of buttermilk, either natural or artificial, or with one ounce of malted milk in eight ounces of water. If buttermilk is used, the barium is readily incorporated with it simply by stirring with a spoon, but if malted milk in water is the vehicle it is necessary to use a mechanical mixer. Numerous other vehicles have been employed such as apple-sauce, cream of wheat or a pap made of potato-starch or corn-starch. The author prefers malted milk or buttermilk because of the ease of preparation, the fact that they are palatable to most people and that they make an even, smooth suspension of the barium.

The *preparation of the patient* for the examination consists in administration of a laxative, preferably an ounce of castor oil, on the evening preceding the examination. It is very important that the stomach be



free from food at the time of the examination because the presence of food or secretion in the stomach may simulate a deformity in its contour. The evening meal on the day preceding the examination should be light and no breakfast is to be taken on the morning of the examination. It has been found especially satisfactory if the patient comes for the roentgen examination directly after removal of the test meal and gastric lavage. This, however, is not essential. When the patient is undergoing examination not more than one layer of thin cotton clothing should cover the chest and abdomen, and this should be entirely free from buttons, fasteners or pins. Before the gastrointestinal examination is begun roentgenograms are taken of the gall-bladder region because examination of this region is an essential part of an examination of the gastrointestinal tract. This is described in detail later.

**THE ESOPHAGUS.**—Examination of the esophagus is made both roentgenoscopically and roentgenographically. Roentgenoscopic examination is carried out by having the patient stand with his chest against the screen, the ray passing from behind. He is then rotated slightly so that the right breast is against the screen, the ray passing obliquely through the chest from left to right. This is the right anterior oblique position. He now places his right hand back of his head, holding the elbow well up, and holds the glass of barium mixture to his lips with his left hand. The ray is then turned on and the roentgenologist observes the shadow of the barium in its passage from the pharynx into the stomach as the patient slowly drinks it. Normally the barium passes

down the esophagus with a slight backward deflection behind the arch of the aorta, and with slight delay at the

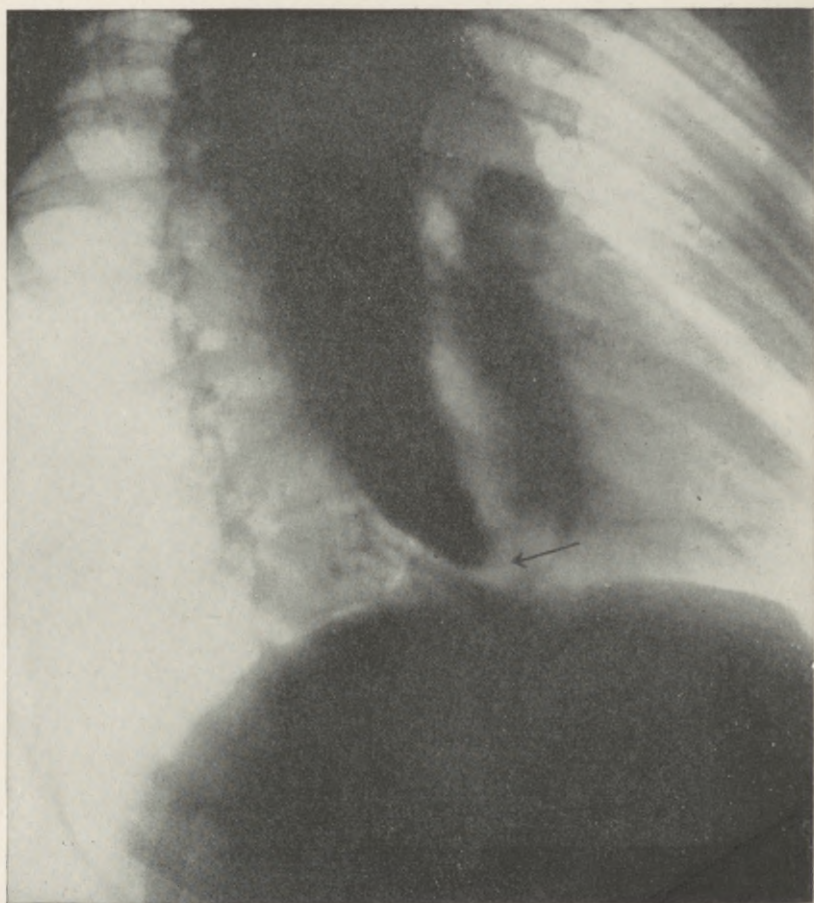


FIG. 127.—Cardiospasm with great dilatation of the esophagus.

cardiac orifice. If a stricture is suspected and none is demonstrated by the use of barium in a liquid vehicle, it is advisable to mix some crusts of bread with the

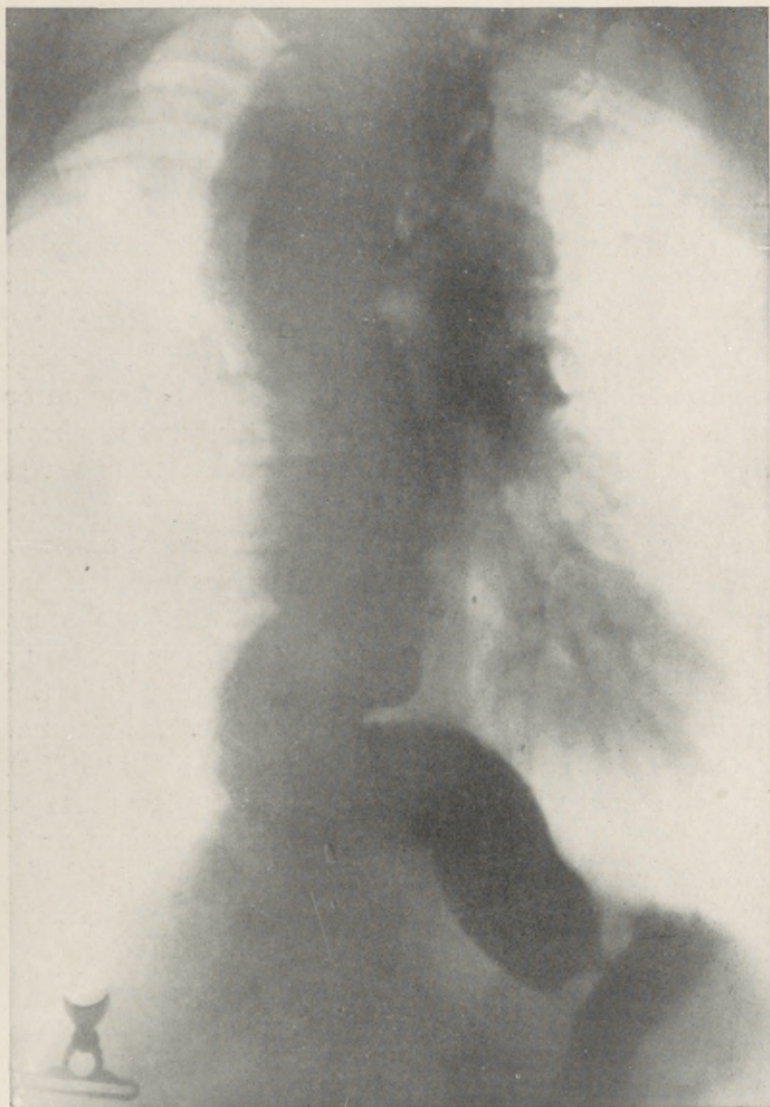

FIG. 138.—Cardiospasm with dilatation and reduplication of the esophagus.



barium and buttermilk, or to give a very thick barium paste. The passage of this will sometimes reveal a stricture which is not shown by the liquid meal.

The portion of the esophagus below the diaphragm, which is three to five centimeters in length, is normally much narrower than the portion above the diaphragm. This sub-diaphragmatic portion is directed sharply to the left to enter the stomach and is better seen in the anteroposterior position than in the right oblique.

Cardiospasm produces obstruction either at the point where the esophagus passes through the diaphragm or at the cardiac orifice (Fig. 127). The esophagus above the point of obstruction may be greatly dilated and even reduplicated (Fig. 128). The appearance, roentgenoscopically or on plates, is that of a smooth conical shadow. This is the characteristic that distinguishes it from carcinoma and benign organic stricture. Care must be taken to exclude the presence of food particles in the sac since the latter may produce irregularity in the barium shadow, simulating the defects due to carcinoma.

Carcinoma of the esophagus (Figs. 129, 130 and 131) is characterized by the ragged, irregular appearance of the barium-filled lumen. The obstruction may vary from none at all to almost complete blocking of the lumen. It may be difficult or impossible to differentiate carcinoma from benign organic constriction.

Diverticula of the esophagus usually occur near its upper end and appear in the roentgenogram as smooth rounded sacs either at one side or behind the esophagus. The most common location is at the level of the cricoid cartilage (Fig. 132).

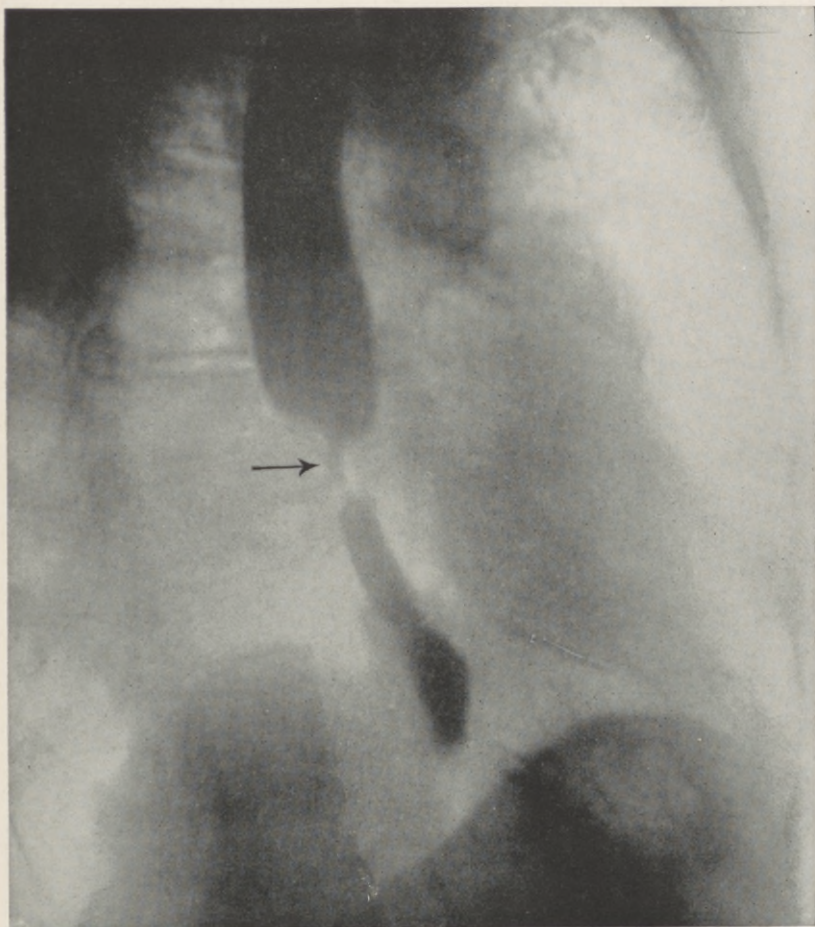


FIG. 129.—Annular carcinoma of esophagus with moderate dilatation above.  
(Arrow points to place of constriction.)

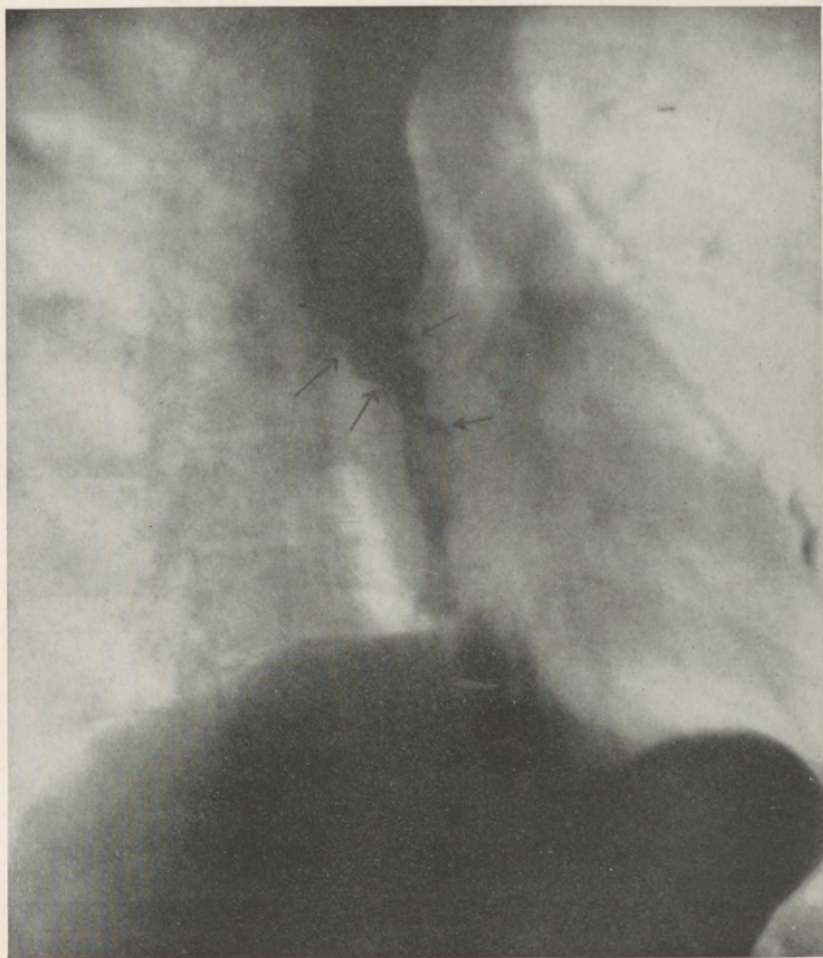


FIG. 130.—Carcinoma of the esophagus with a high degree of obstruction.



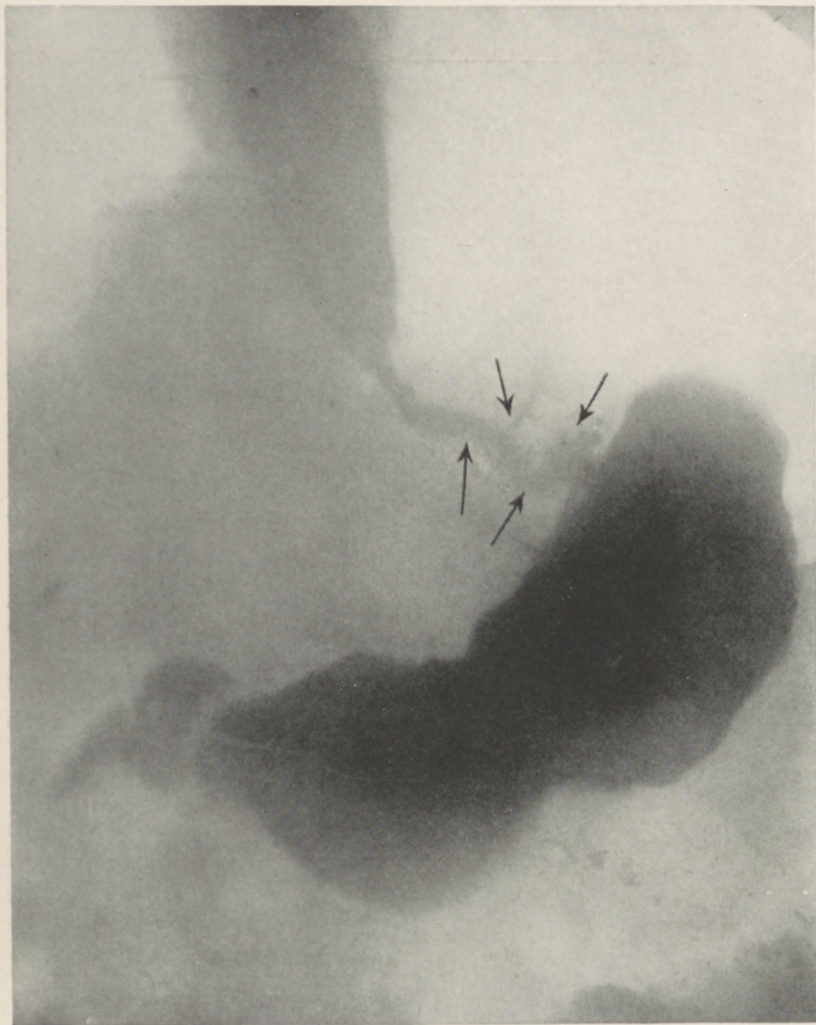

FIG. 131.—Carcinoma of esophagus close to cardia.

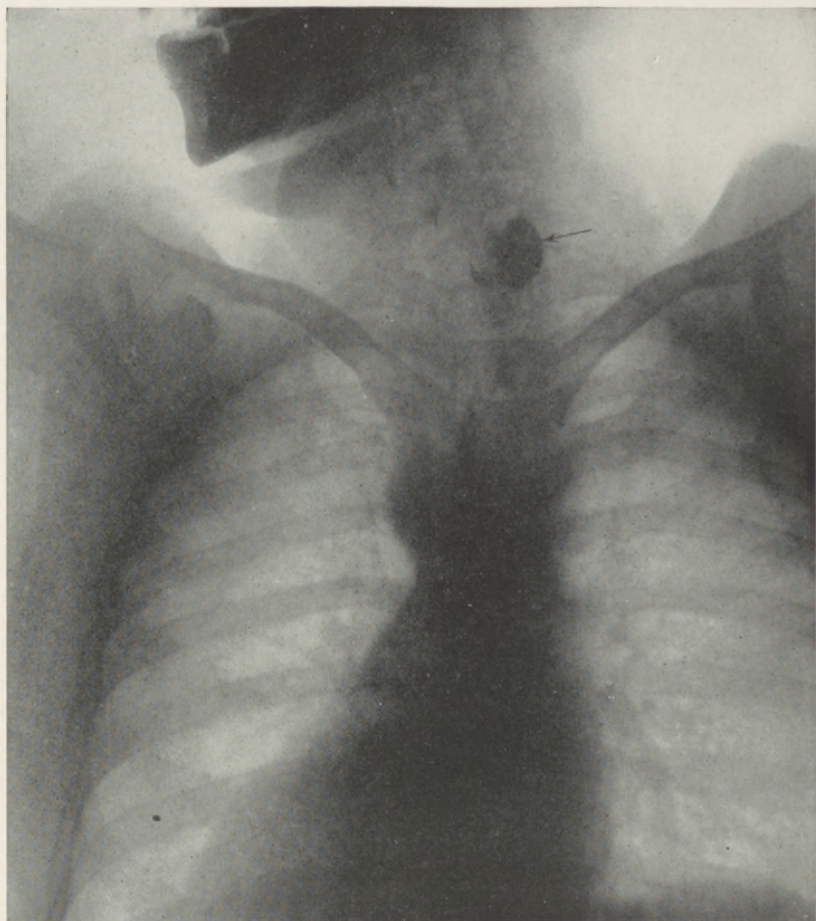


FIG. 132.—Diverticulum of esophagus. (The arrow points to the sac which is filled with barium.)

Benign stricture of the esophagus may be due to cicatricial contraction following ulceration, the cause of which

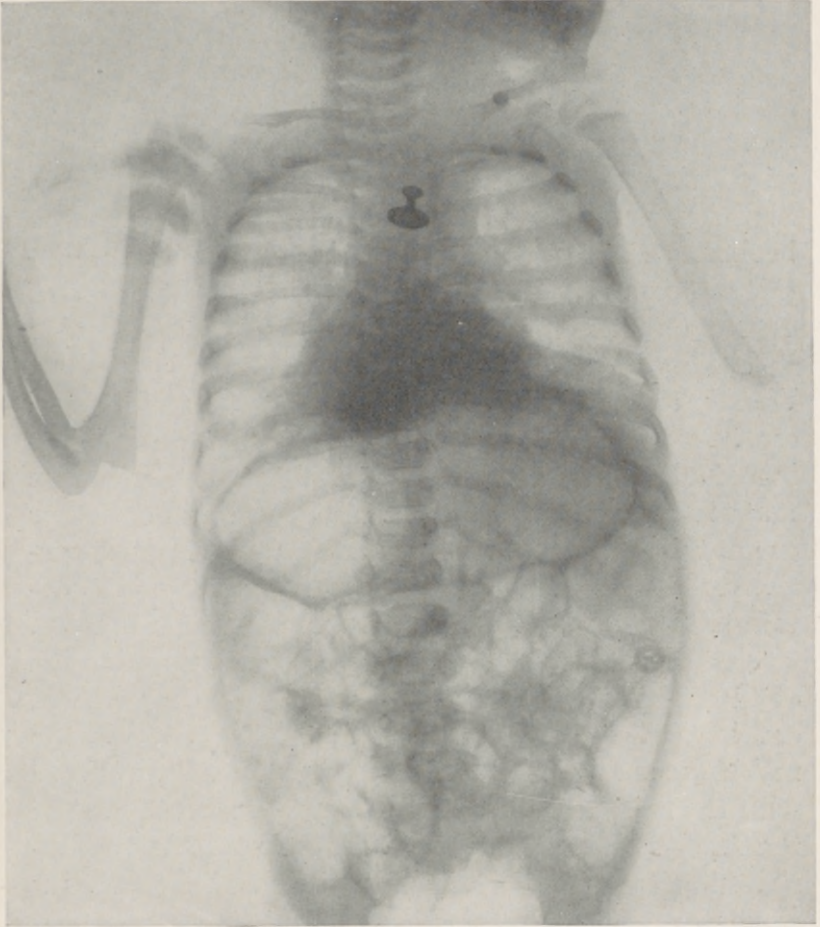

FIG. 133.—Collar button in esophagus.

may be syphilis, tuberculosis, the swallowing of caustics, etc. They may occur at any point in the esophagus



and cannot be distinguished by the roentgen appearance from carcinomatous strictures.

**Foreign bodies in the esophagus** (Figs. 133 and 134) usually lodge at the narrow point on the level of the cricoid cartilage or behind the aortic arch. If the foreign body is metallic or of other substance opaque to the roentgen ray it may be localized by the roentgenoscope or on the film. The location of non-opaque foreign bodies may sometimes be determined by giving a barium mixture and noting the point of partial or complete obstruction or unusual deviation. It must of course be definitely determined whether the foreign body is in the esophagus or in the trachea or a bronchus. Usually the air-filled shadow of the trachea and bronchi can be seen on the plates. If there is doubt the swallowing of a barium mixture and observation of its passage on the screen will usually permit one to decide whether or not the body is in the esophagus. It is sometimes possible to locate a non-opaque foreign body by the obstruction to the passage of large capsules filled with barium.

**THE STOMACH.**—The roentgenoscopic examination of the stomach takes note of the size, shape, position, contour, the rapidity and character of peristalsis, the mobility and the rate of evacuation. Pressing upward with the right hand assists in filling the highest part of the fundus. The examination is first made in the upright position with the abdomen against the screen. By gradually rotating the patient to the right anterior oblique and finally to a straight lateral position the posterior wall of the stomach is brought into profile. The examination carefully notes any delay or deformity

about the pylorus. The first portion of the duodenum known as the "cap" or duodenal bulb is very important

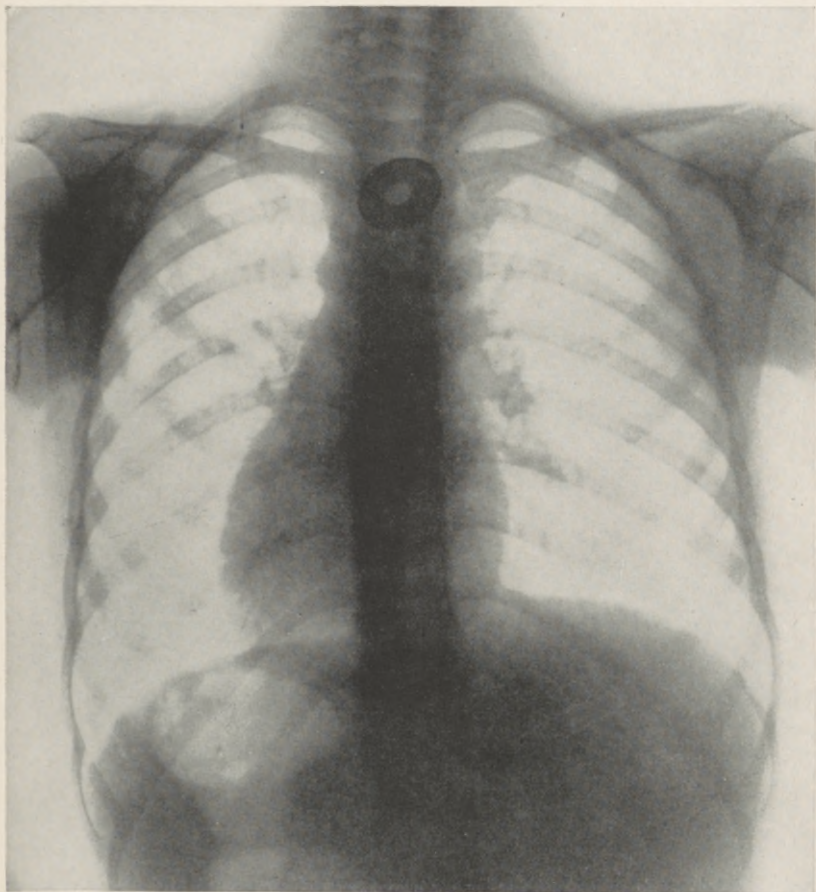


FIG. 134.—Iron washer in esophagus.

from a roentgenologic standpoint, and should be examined as the stomach empties. The roentgenoscopic examination is completed on the horizontal roentgeno-

scope. The stomach and duodenum are examined not only in the prone and supine positions but in the anterior and posterior oblique and lateral positions as well.

The patient now lies upon a table in the prone position and a film is placed beneath the abdomen. The tube is centered over the film at a distance of 24 in. and the exposure made while the patient holds his breath. It is well to place a pillow under the patient's hips to prevent defect in the barium shadow of the stomach caused by pressure of the spine. It is the custom of the author to examine this film as it is coming up in the developing solution in order to be sure that the image of the stomach is well centered on the plate, and whether or not all parts of the stomach and duodenal bulb are well filled with the barium mixture. If the duodenal bulb has not filled, the patient is made to turn upon the right side and pressure made with the hand over the epigastrium in such a manner as to assist the filling of the bulb. The patient now lies prone again and three or four pictures are taken at intervals of about one minute. The patient is then turned to the right anterior oblique position, and the same procedure followed as for the prone position. If the first picture taken in this position shows no defect in the contour of the cap no others are taken, but if there is deformity it is necessary to take several more in order to determine whether or not the deformity is constant. Usually one or two roentgenograms are then taken with the patient erect. Of course, the above procedure is often varied to suit different cases. In patients having much abdominal fat, or in those having a very hypertonic stomach most



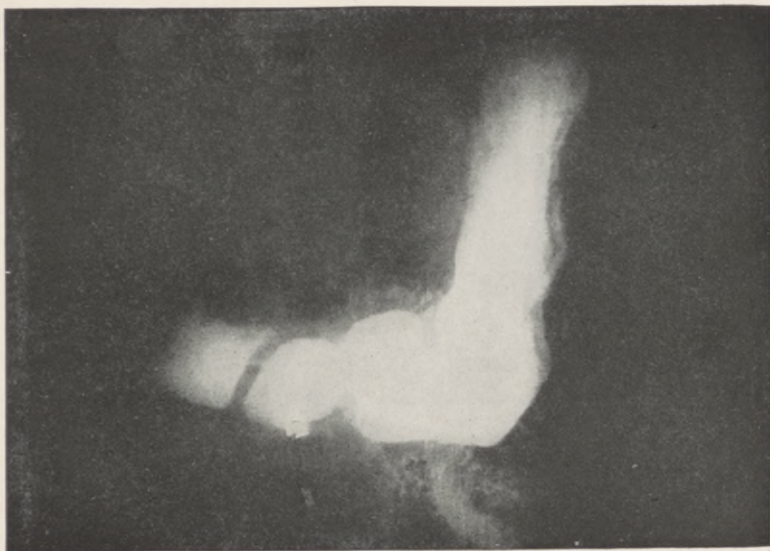


FIG. 135.—Type of normal stomach and duodenal cap.

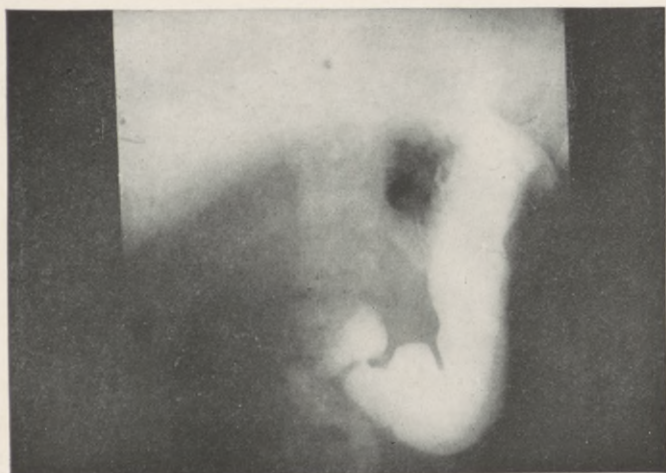


FIG. 136.—Type of normal stomach and duodenal cap.

of the examination is made in the erect posture, since the duodenal cap does not show so well in these individuals when the examination is made in the prone position. The right anterior oblique position with the patient prone is especially valuable in the hypertonic type of stomach.

The appearance of the normal stomach varies greatly in different individuals and in the same individuals as a result of different postures, pressure, nervous influences, etc. The best classification is probably that based upon muscular tone. The orthotonic stomach grasps its contents and maintains its tubular shape with the patient erect (Fig. 138). The hypertonic variety is the so-called "steer-horn" stomach (Fig. 139), lying high in the epigastrium and more or less horizontally. In the atonic stomach the meal gravitates to the most dependent portion, little or none remaining in the vertical part (Fig. 140).

The following terms are in use to designate certain parts of the stomach. The *pars cardiaca* is that part of the stomach above the esophageal entrance. The *incisura cardiaca* is the angle formed above the esophagus at its junction with the stomach. The *pars media* is the middle part of the stomach extending from the *pars cardiaca* to the *incisura angularis*. The latter is the indentation found on the lesser curvature at the junction of the vertical and horizontal portions of the stomach. It is not well marked in the hypertonic type of stomach. The *pars pylorica* is that portion of the stomach between the *incisura angularis* and the pylorus.

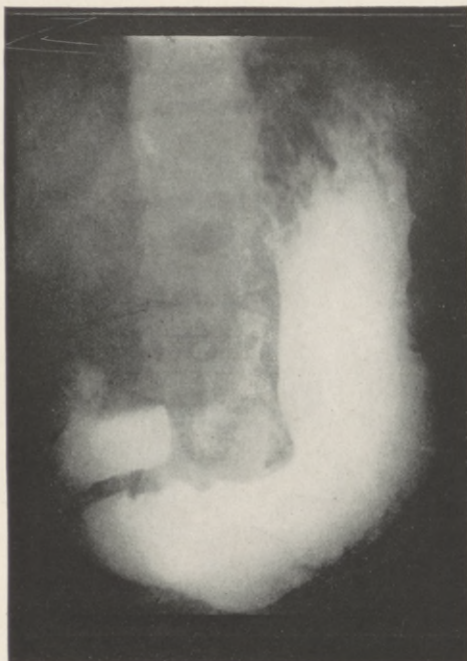

FIG. 137.—Type of normal stomach and duodenal cap.

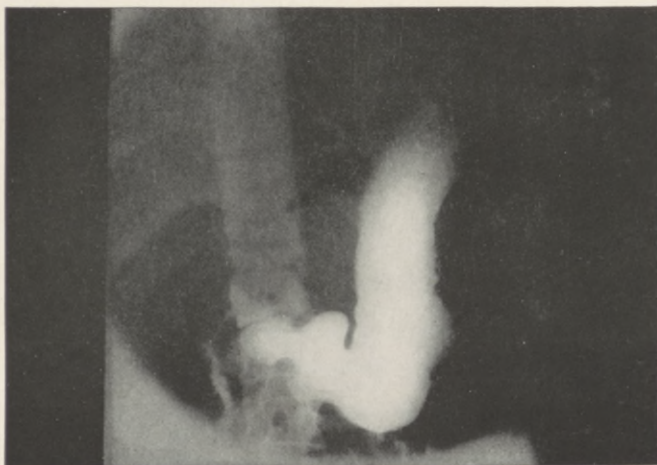

FIG. 138.—Orthotonic stomach.



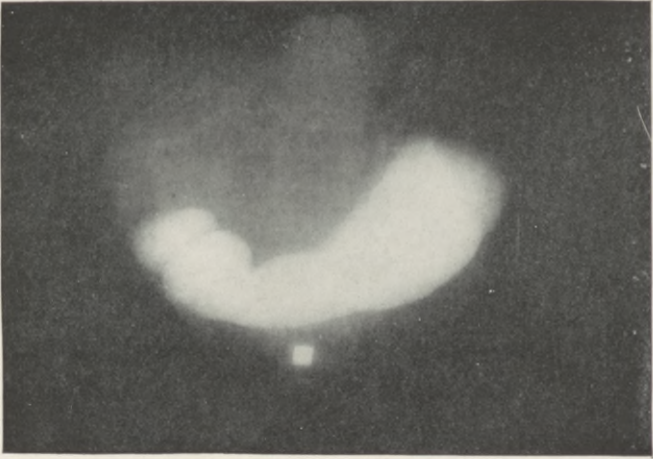

FIG. 139.—Hypertonic stomach.

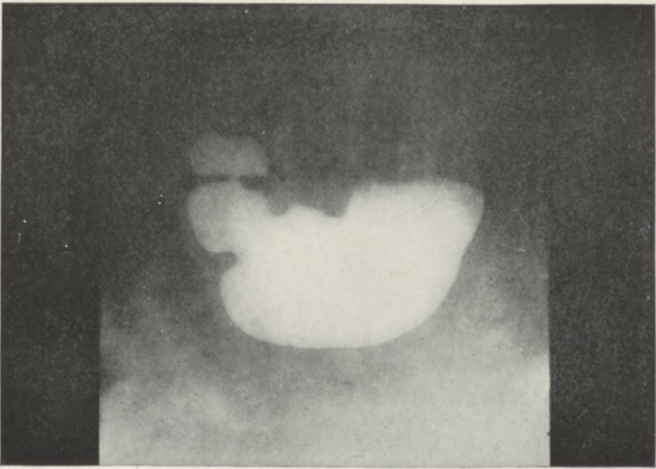


FIG. 140.—Atonic stomach.

**GASTRIC ULCER.**—The roentgen examination has become the best single means of diagnosis of the presence and location of gastric ulcer. In experienced hands this method will yield at least 90 per cent. of correct diagnoses. The findings should, of course, always be correlated with the information gained from the history, the analysis of gastric secretions, and the physical examination.

Carman<sup>1</sup> classifies the roentgenologic signs of gastric ulcer as follows:

- “1. Primary and practically pathognomonic signs.
  - (a) Niche.
  - (b) Accessory pocket.
  - (c) Organic hour-glass stomach.
2. Secondary and corroborative but not absolutely diagnostic signs.
  - (a) Spastic manifestations.
    - (1) The incisura.
    - (2) Spasmodic hour-glass stomach.
    - (3) Diffuse gastrospasm.
      - (b) Retention from the six-hour meal.
      - (c) Gastric hypotonus.
      - (d) Acute fish-hook form of the stomach.
      - (e) Alterations of peristalsis.
      - (f) Localized tenderness.
      - (g) Lessened mobility of the stomach.”

The *niche* is the shadow of the barium-filled crater of a penetrating ulcer (Figs. 141 and 142). If favorably situated it may be seen even though it is very small. Ulcer is most common on the lesser curvature or on the posterior wall near to the lesser curvature, and in this

<sup>1</sup>Carman, Russel D. *The Roentgen Diagnosis of Diseases of the Alimentary Canal*, 2nd ed., W. B. Saunders Co., Philadelphia, 1920.

locality the niche may usually be demonstrated. Sometimes a niche may be seen while the patient is drinking the barium mixture and then fail of demonstration when

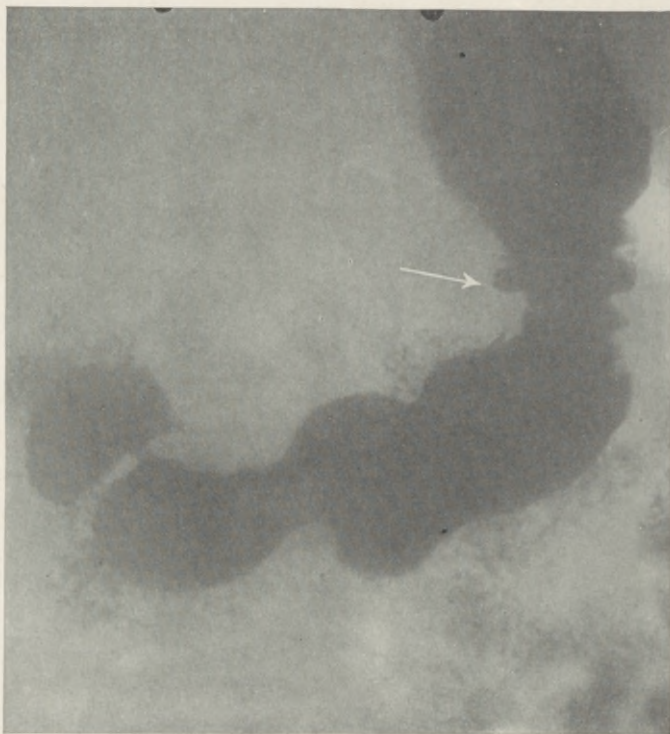


FIG. 141.—Gastric ulcer on lesser curvature; niche indicated by arrow.

the stomach is filled. In other cases the crater can be filled by careful palpation while watching the shadow on the screen, but does not remain filled when the pressure is removed. Since a certain percentage of ulcers occur on the posterior wall it is essential to take oblique or lateral views and to observe the stomach on the screen



in these positions. To secure good films of ulcer craters on the posterior wall the best procedure is to watch the image on the screen or the horizontal roentgenoscope

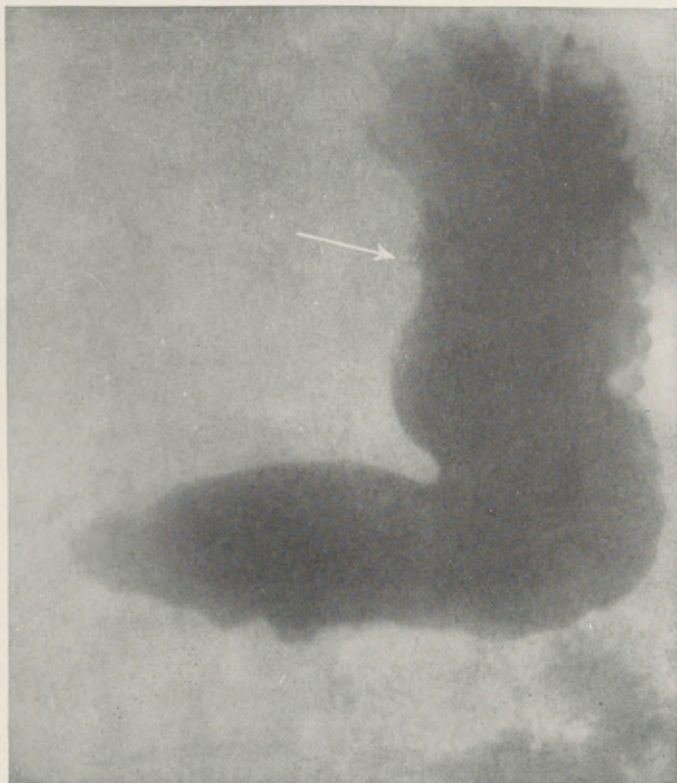

FIG. 142.—Gastric ulcer on lesser curvature; niche indicated by arrow.

while the patient is slowly rotated until the best view is obtained. The films are then made in that position.

*The accessory pocket* is caused by a perforated ulcer and the roentgen shadow is that of the barium-filled

cavity outside the stomach (Fig. 143). Not all perforating ulcers have such a cavity since it may be oblit-

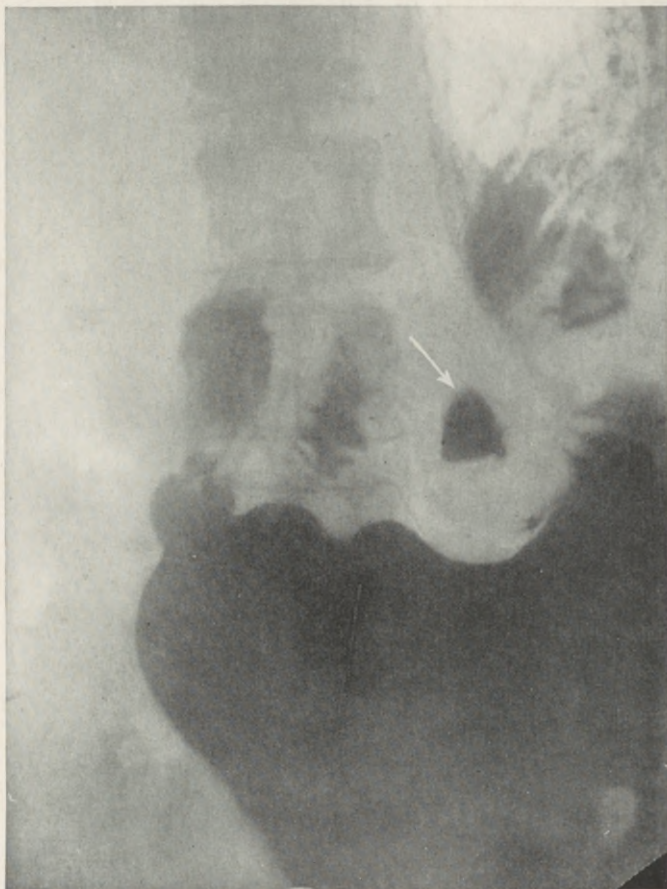


FIG. 143.—Perforated gastric ulcer, accessory pocket indicated by arrow.

erated by the products of inflammatory reaction, and in such a case the deformity is not typical. When viewed in the upright roentgenoscope the pocket may

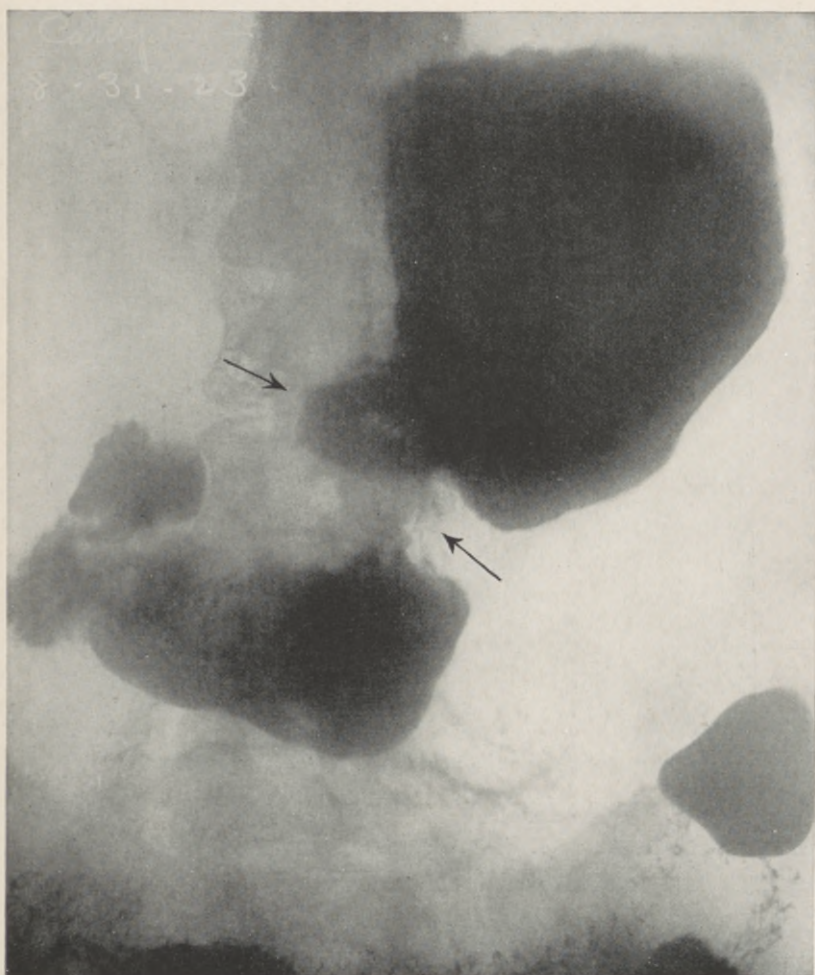

FIG. 144.—Perforated gastric ulcer with accessory pocket and organic hour-glass stomach.

show several layers, the barium at the bottom, translucent fluid above and air-bubble uppermost. The pocket is often best seen at the six-hour period when the



stomach is partially or completely empty, since the pocket often remains partly filled with barium when the stomach is empty. It is the author's experience that all perforated ulcers are tender to pressure. A diagnosis of perforated ulcer in the absence of such tenderness should be made only after the most careful considera-

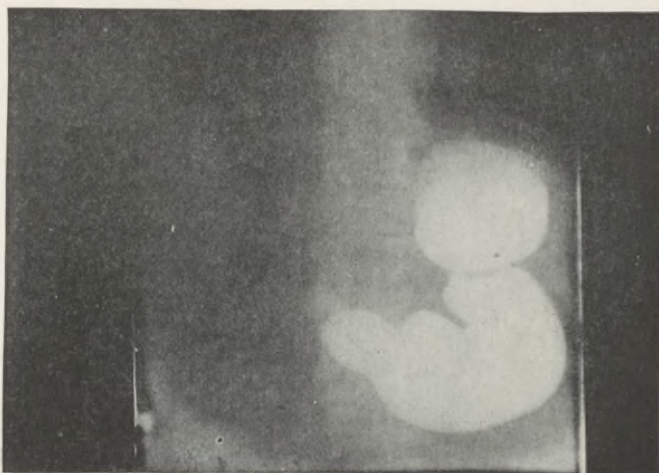


FIG. 145.—Incisura, producing hour-glass stomach, caused by ulcer of lesser curvature.

tion. The ulcer may perforate either into the liver or into the pancreas. The former cavities move with respiration while the latter do not.

*Organic hour-glass stomach* may be seen with either penetrating or perforating ulcer and is due either to the presence of adhesions, scar formation or inflammatory infiltration of the gastric walls (Fig. 144).

*Spastic contractions* (Fig. 145) of the stomach often accompany gastric ulcer but they are not sufficiently constant in their occurrence to be of definite diagnostic

value, and to add to the uncertainty such spastic manifestations may occur in conditions other than ulcer. The spastic condition may be in the nature of a general

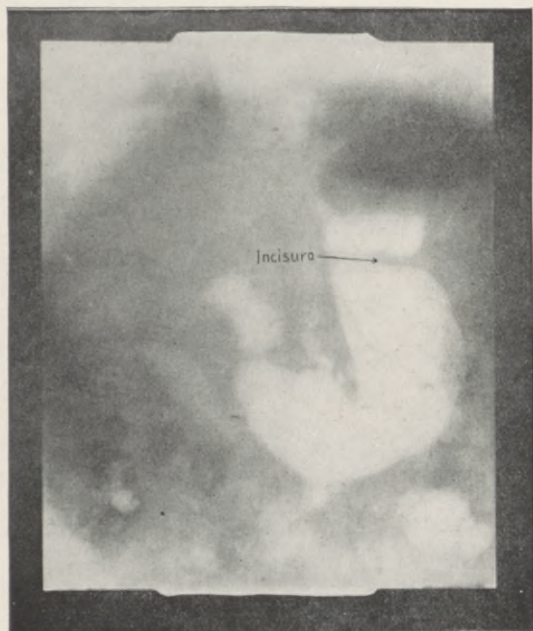


FIG. 146.—Incisura opposite ulcer of lesser curvature.

gastrospasm or a more localized spasmodic contraction called incisura or spasmodic hour-glass.

*The incisura* (Fig. 146) is an indentation of the wall of the stomach occurring opposite to an ulcer. It practically always occurs on the greater curvature opposite to an ulcer of the lesser curvature. Care must be taken not to confuse the incisura cardiaca occurring in the normal stomach at the esophageal entrance, or the incisura angularis occurring in the angle of the lesser curvature,

with true incisuræ. Typical looking incisuræ may be caused by reflex irritation, such as that from appendix disease, gall-bladder disease or duodenal ulcer. To be of value as a diagnostic aid, the incisura must be constant in position and accompanied by other signs of ulcer, and must persist after the patient has taken tincture of belladonna to physiologic effect. The cause of the incisura is thought to be the contraction of the circular muscular fibres of the stomach due to the irritation of the ulcer. The edges of a true incisura are smooth and the end is bluntly rounded. The occurrence of two ulcers together, however, may give it a ragged appearance.

*The spasmodic hour-glass stomach* has about the same value in the diagnosis of ulcer as the incisura since it usually has the same cause—a spasmodic contraction due to irritation.

*General gastrospasm* or spasm of a considerable portion of the stomach may also be due to gastric ulcer but it is more likely to have an extrinsic cause. In the author's experience disease of the gall-bladder is a very common cause of gastrospasm.

*A marked residue* in the stomach at the end of six hours is considered a confirmatory sign of the presence of gastric ulcer. The increased acidity in the duodenum which interferes with the normal pyloric reflex is thought to be the cause of retention in cases of gastric ulcer in which there is no actual pyloric stenosis. There are, however, other causes of retention which must be taken into account, such as obstruction due to neoplasm, obstructive adhesions due to cholecystitis, and reflex spasm of the pylorus resulting from conditions



elsewhere in the abdomen. It is obvious that the tone of the stomach must be taken into consideration in judging

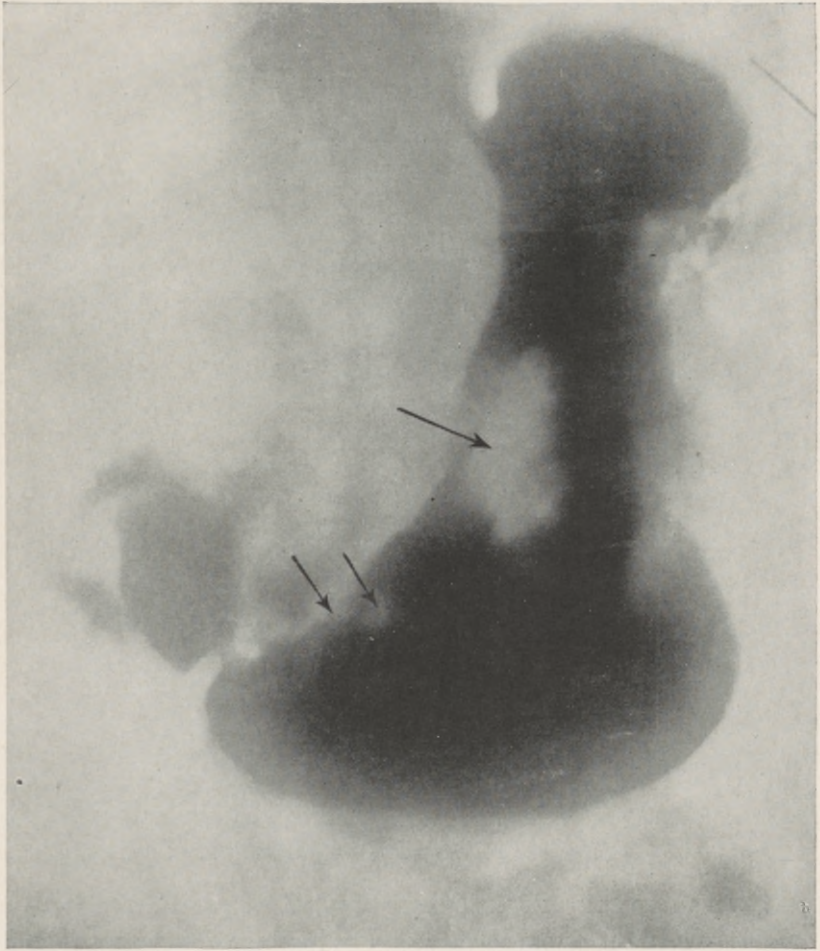


FIG. 147.—Carcinoma of stomach. Arrows indicate filling defects.

the significance of a six-hour residue. A residue having no significance at all in an atonic stomach may be of

importance in one that is hypertonic. If interpreted in the light of other findings the six-hour residue is of value as a diagnostic sign. The presence of a well-marked

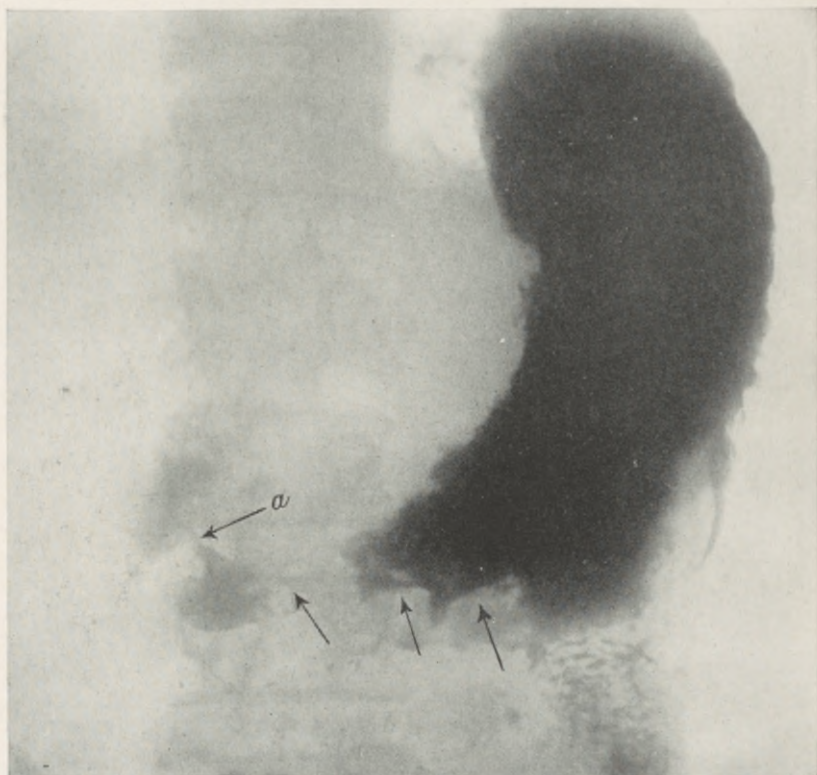


FIG. 148.—Carcinoma of pyloric end of stomach. Arrows indicate filling defects. Pylorus at *a*.

incisura for instance, accompanying a good sized six-hour residue is considered good evidence of the presence of ulcer.

**CARCINOMA OF THE STOMACH** gives a very characteristic picture in advanced cases. Even in early

ones it is usually possible to make a diagnosis of the presence of an organic lesion with probable beginning malignancy. The diagnosis is based upon the presence of filling defects, abnormal peristaltic action, and rapid

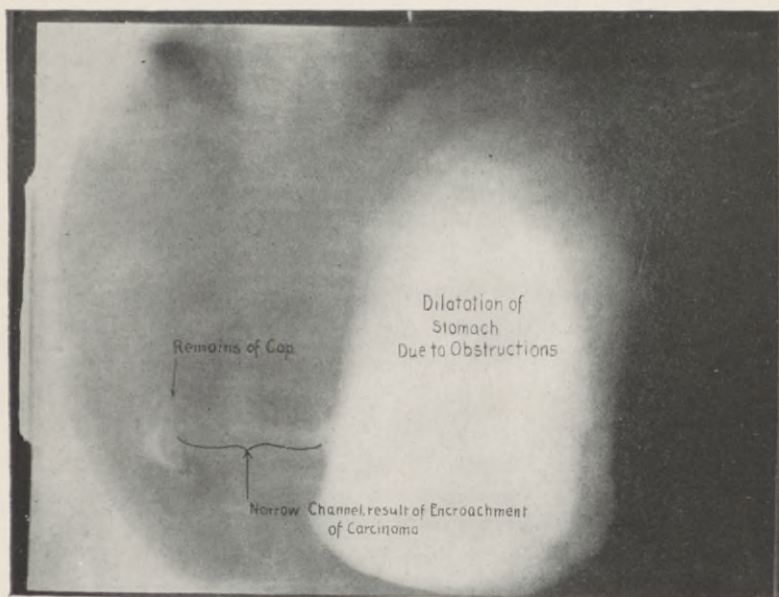


FIG. 149.—Large carcinoma of pyloric end of stomach.

or delayed evacuation caused respectively by gaping or obstruction at the pylorus.

If the growth is a nodular one, the defects in the shadow may be small circular areas—the so-called “finger-print” defects (Figs. 147 and 148). The area involved may have a ragged, worm-eaten appearance due to the irregular nature of the growth (Fig. 149), or it may progress in the shape of a cone (Fig. 150). The latter appearance is frequently seen\* in the antrum



pylori, the constricted pylorus forming the apex of the cone. Carcinoma may, by a general infiltration, cause fixation and stiffening of the walls of the entire stomach (Fig. 151). Great care must be taken to demonstrate

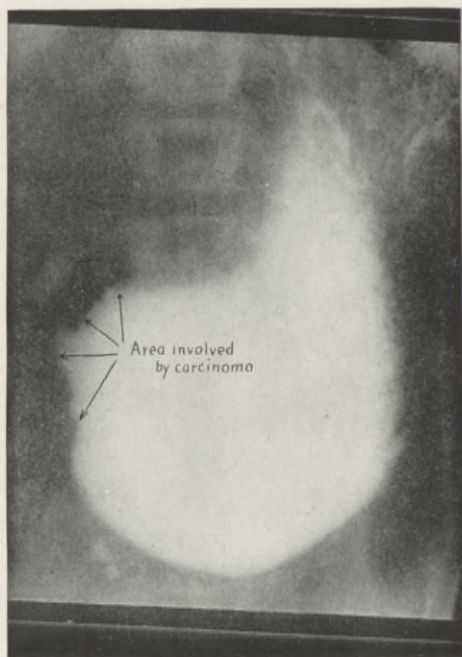


FIG. 150.—Large carcinoma at pylorus, causing high degree of obstruction.

the presence of true filling defects and to differentiate those due to cancer from those due to other conditions. Roentgenoscopic examination should be made in both upright and recumbent positions. It is often possible to see small defects on the screen by pressing the barium with the hand into different parts of the stomach and

by turning the patient to the oblique, lateral and indeed to every possible position. It is especially important to fill the pars cardiaca which can be best accomplished when the patient is lying upon his back. An annular

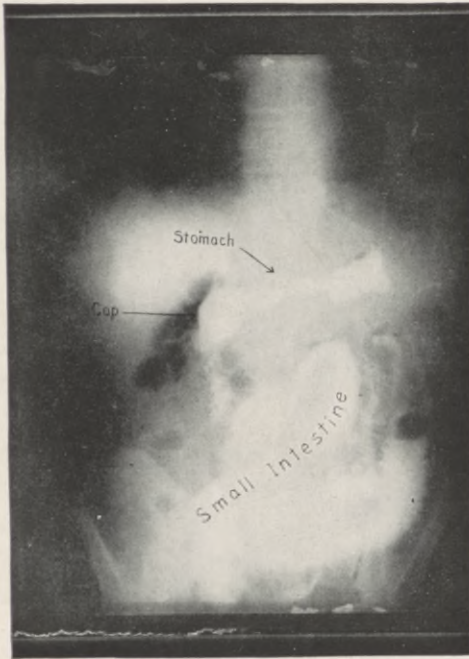


FIG. 151.—Large infiltrating carcinoma of the stomach.

carcinoma directly at the pylorus (Fig. 152), may cause an apparent lengthening of the pylorus so that the duodenal bulb appears farther away from the stomach than usual. Carcinoma may produce organic hour-glass deformity of the stomach. This is usually irregular in outline and its lumen central in position, while that caused by ulcer is smooth in outline and its lumen near

to the lesser curvature. Spasm due to extragastric conditions often cause deformities of the stomach that simulate cancer. They can usually be relieved by giving the patient tincture of belladonna until the physiological effects are produced.

Deformities of the stomach caused by extragastric

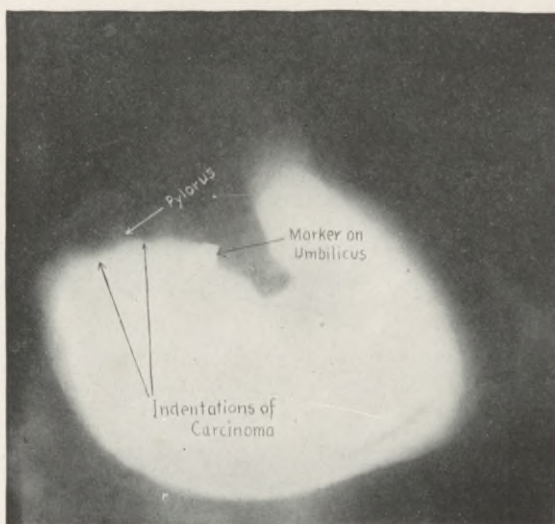


FIG. 152.—Annular carcinoma of pylorus.

tumors can generally be differentiated by the fact that in certain positions the stomach may be seen to have a normal contour. Roentgenograms made in the erect, prone and lateral positions and palpation while the stomach is observed on the screen aid in ruling out tumors outside of the stomach. Cysts of the pancreas cause changes in the contour of the stomach, their nature depending upon the location of the cyst. A cyst of the head of the pancreas often produces a smooth,



rounded deformity in the pyloric end of the stomach and in the duodenal bulb, at the same time displacing them toward the left. Syphilis of the stomach often causes deformities having the appearance of carcinoma. It should therefore be a rule to have a Wassermann test made in all cases giving a roentgen picture of carcinoma, but it should be kept in mind that patients with syphilis may also have carcinoma.

Changes in peristalsis are often caused by gastric cancer. The cancerous area may show a complete absence of peristalsis or the waves may be very weak. Sometimes the entire stomach shows no peristaltic action at all. Not much reliance for diagnosis can be placed on the changes in peristalsis since the same changes may take place in other pathologic processes.

Evacuation of the stomach contents may be either very rapid or very slow. Rapid emptying is often due to a widening and stiffening of the pylorus caused by the cancerous infiltration. It is often present in those cases that involve the entire stomach, when the whole organ appears to be a stiff, non-contractile tube. Rapid emptying is also seen in some cases when the cancer is not located at the pylorus, a result caused by some interference with the normal pyloric reflex. Very rapid evacuation, simulating that seen in cancer, is sometimes present in achylia and in certain extragastric conditions such as gall-bladder disease, duodenal ulcer and even appendicitis.

The roentgen examination is of value not only to enable one to recognize the presence of cancer but also for the assistance it gives in deciding the question of

operability. The latter depends not so much upon the size as upon the position of the cancer. In a very general way it may be stated that cancers of the pars cardiaca are inoperable; those in the pars media either operable or inoperable, depending upon their extent toward the cardia; and those in the pars pylorica are operable. Of course other considerations such as metastases, involvement of contiguous organs, etc., must be taken into account when considering the question of operability. Study of the roentgen appearance, however, will often enable one to decide that a cancer is either operable or inoperable so far as the possibility of resection is concerned.

Fibromatosis of the stomach (cirrhosis, fibrosis, leather-bottle stomach, linitis plastica) is a condition characterized by the presence of a large amount of fibrous tissue in the gastric walls. The stomach is reduced in size, peristalsis is very weak or absent, and evacuation is rapid. Since Brinton first described this condition there has been a fairly general opinion that there is a true cirrhosis of the stomach characterized by the presence of connective tissue and the products of every stage of inflammation. Many cases have been described, however, with the characteristics of this disease but in which after prolonged search the pathologist has found carcinomatous changes. The opinion is held by some that the process is due to a very slow growing infiltrating type of scirrhous carcinoma in which the carcinomatous elements are gradually replaced by connective tissue. The roentgen examination gives an appearance identical with that of the infiltrating form

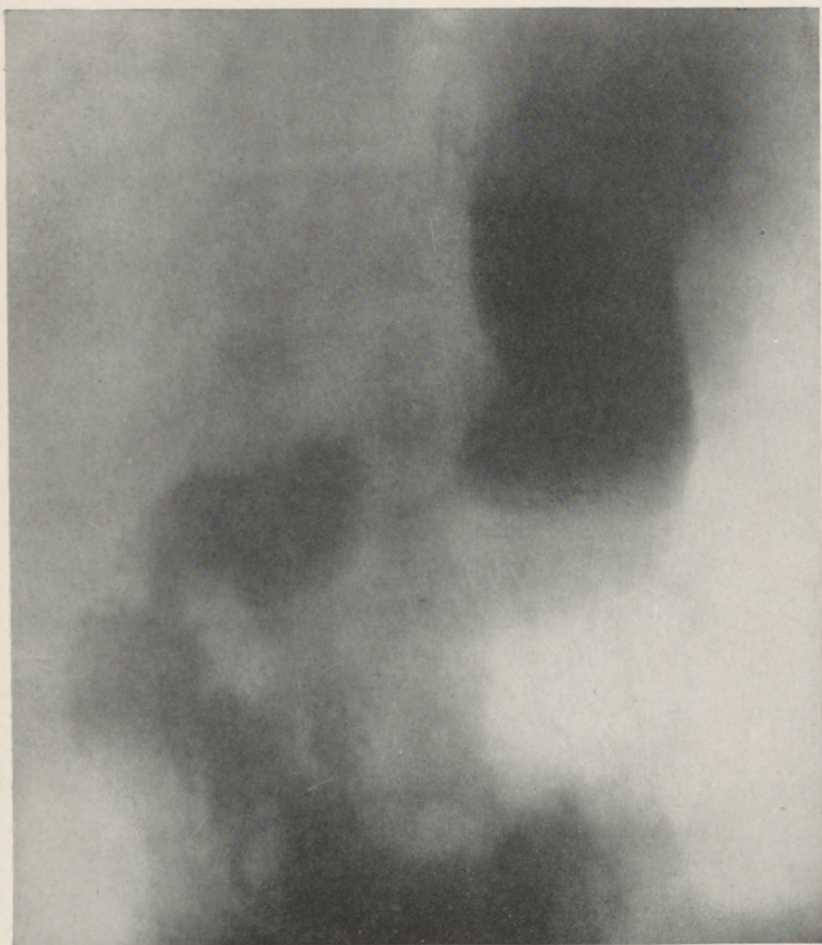


FIG. 153.—Syphilis of stomach. Extensive defect caused by infiltration and fibrosis.  
Diagnosis established by autopsy.

of cancer with diminution in the size of the gastric lumen, absence of peristaltic action and rapid evacuation of the barium meal.



**Syphilis of the Stomach.**—This disease is usually characterized by infiltration in the gastric walls followed by fibrosis (Fig. 153), occasionally by the presence of shallow ulcers of the mucous membrane, and rarely by the presence of gummatous masses (Fig. 154). The

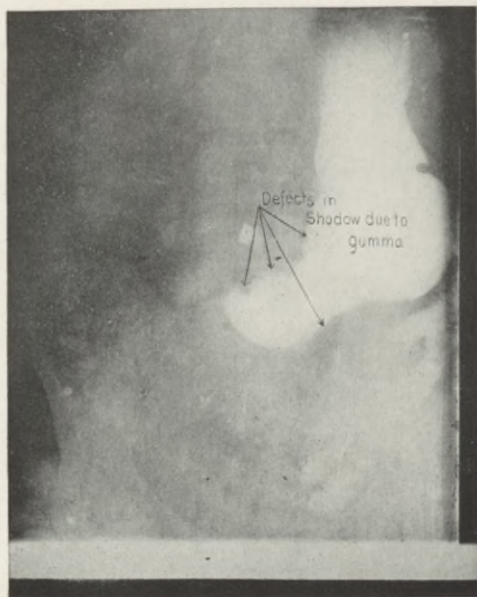


FIG. 154.—Gumma of stomach.

roentgen examination shows filling defects that cannot be distinguished from those of carcinoma. Suspicion may be aroused that the condition is not cancer by the fact that the patient is young, or that he has no cachexia or loss of weight.

**Benign Tumors of the Stomach.**—Myomas, fibromas, adenomas and various other less common benign tumors are sometimes found in the stomach. They often project

into the gastric lumen and this causes filling defects in the roentgen picture. Such defects can often be distinguished from those due to carcinoma by the fact that they are usually sharply circumscribed and their edges are smooth. Polyposis of the stomach is a rare multiple tumor formation. It gives a diffuse mottled effect to the roentgen picture that is fairly characteristic.

**THE DUODENUM.**—The first portion of the duodenum known as the bulb or “cap” is normally of a smooth rounded outline but varies greatly in size and shape. It appears to become very narrow at its junction with the second portion of the duodenum. If the patient is turned to the oblique or lateral position it will be seen that the narrowing is only apparent and that the appearance is due to the fact that the duodenum turns sharply backward and outward at that point. The second or vertical portion of the duodenum descends with a curve to the right around the head of the pancreas. It is not so well seen as the bulb because of the rapid passage of its contents, and when seen it is irregular in outline due to the presence of the *valvulæ conniventes*.

The third or horizontal portion terminates at the ligament of Treitz. The duodenum is examined along with the stomach, first in the upright and then on the horizontal roentgenoscope and in all the positions which are found useful in stomach examinations.

**Duodenal ulcer** is much more common than gastric ulcer—three or four to one. It is of prime importance to the roentgenologist that more than 90 per cent of these ulcers occur in the first portion of the duodenum, that portion best seen in the roentgen picture.

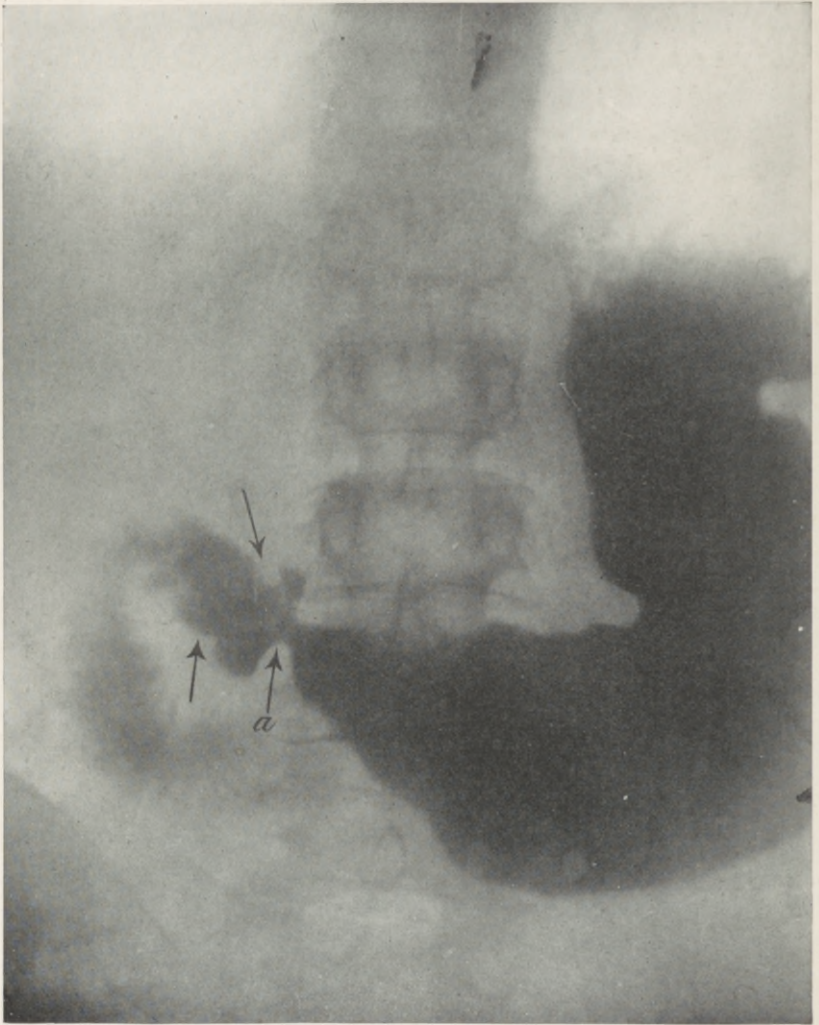


FIG. 155.—Duodenal ulcer. Deformed duodenal bulb indicated by arrows. Pylorus at *a*.



The roentgenologic signs that can be depended upon in duodenal ulcer are deformities of the bulb, and changes in the time of evacuation, peristaltic action and

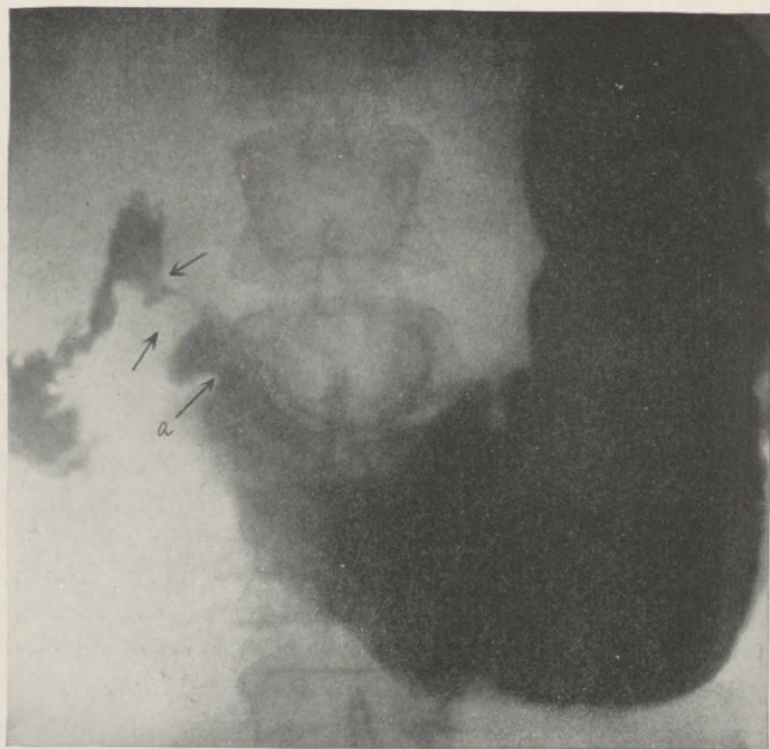

FIG. 156.—Duodenal ulcer. Deformed duodenal bulb indicated by arrows. Pylorus at *a*.

tone of the stomach. Deformities of contour may assume many different shapes and may be slight or great in extent (Figs. 155 and 156). They may be due to distortion by scar formation, to penetration or perforation, and to spasm. The latter is a large element in the production of the deformity in nearly all cases.

Great distortion of the bulb is often produced, giving it a branched appearance, while in other cases there may be a simple indentation or a small niche. Usually the deformity is of the rounded portion of the bulb, but

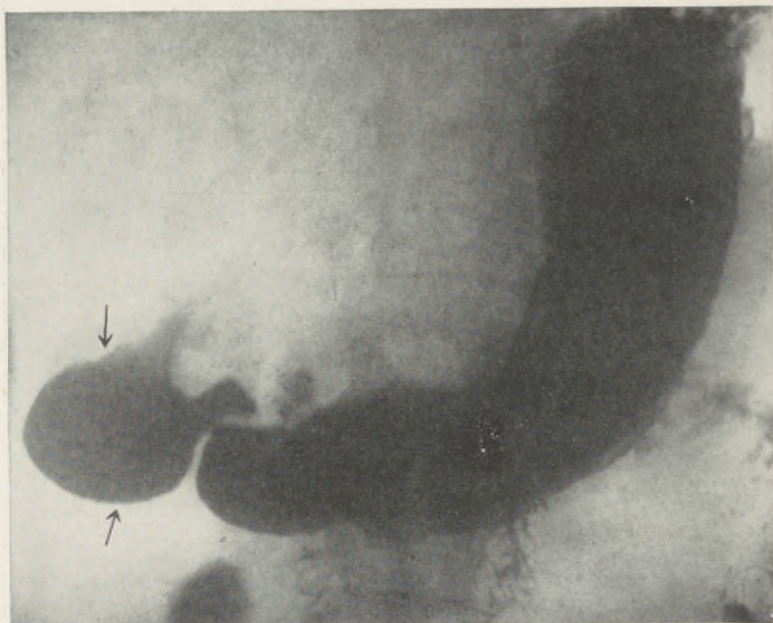


FIG. 157.—Diverticulum of the second portion of the duodenum.

occasionally it is seen on the base. There is sometimes an incisura-like deformity opposite to a distinct niche. An accessory pocket is sometimes seen in perforating ulcers. Deformity of the duodenal bulb as a sign of ulcer was first recognized by Lewis Gregory Cole and it has been thoroughly demonstrated that deformities of the bulb are in the majority of cases due to ulcer and that it is only very rarely that ulcer is present without

producing deformity. There are occasionally typical cases in which the observer must be content to report the presence of deformity indicative of a pathological process which may be due to ulcer or to disease of the gall-bladder with adhesions to the duodenum. It is necessary sometimes, when the bulb does not have a typical deformity, to eliminate spasm by examination after administration of tincture of belladonna and to take a number of films in all possible positions.

There are certain other roentgenological signs of duodenal ulcer which are of some value but only in a confirmatory way. In the majority of ulcers of the duodenum there is hypertonus, hyperperistalsis and hypermotility of the stomach. The latter results in rapid and early evacuation of the barium meal. The exaggerated peristalsis is often very noticeable. When the ulcer has produced obstruction, however, the stomach may become distinctly reduced in tone and evacuation is slow because of actual organic obstruction. In some cases there are reflex spastic manifestations in the stomach such as an incisura, spasmodic hour-glass or general gastrospasm. Carman calls attention to the fact that it is difficult or impossible to relieve the gastrospasm produced by duodenal ulcer by the administration of antispasmodics. Of course, the final diagnosis of duodenal ulcer is made by correlating the roentgen findings with all other information obtainable about the case. At the present time there is scarcely any region of the body where the roentgen examination is more valuable than in the region of the pylorus and first part of the duodenum.



The second and third portions of the duodenum, and the jejunum and ileum do not lend themselves so readily to roentgen examination because of the rapidity with which the barium mixture passes through them. Some-

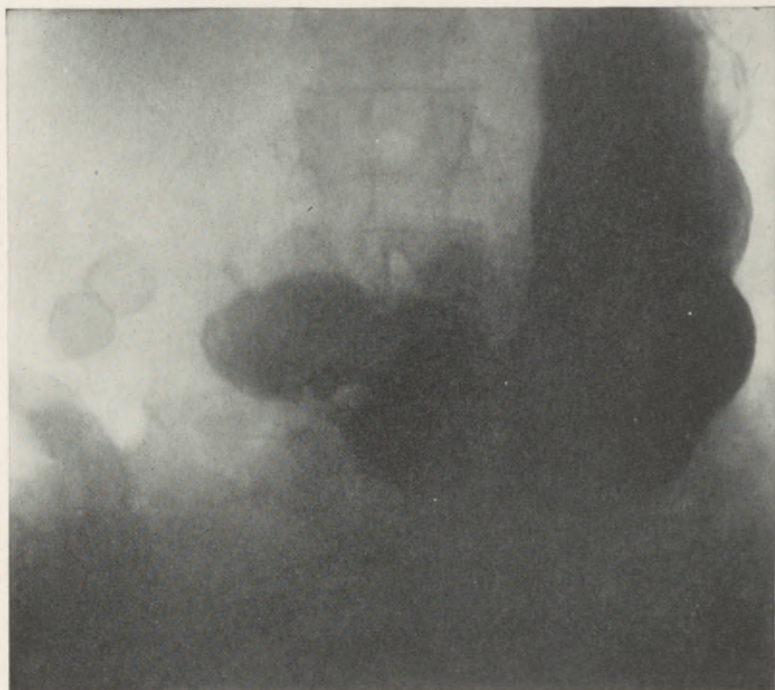


FIG. 158.—Two gall-stones on the level of the fourth lumbar vertebra.

times a dilated ampulla of Vater or a diverticulum (Fig. 157) is demonstrated.

Ulcer of the second and third portions of the duodenum are only rarely recognized by roentgen examination. They may produce some of the indirect signs of ulcer such as gastric hypermotility or retention but

their presence can only be inferred. Gastrojejunal ulcer at or near the stoma of a gastroenterostomy sometimes produces six-hour retention in the stomach and there is occasionally seen a small sac-like barium shadow at the site of the ulcer. Marked localized tenderness to pressure at or near the stoma is also a sign of some value.

Cancer of the small intestine is not a common condition and its presence can only be inferred from the roentgen examination if it produces obstruction. If the tumor is high up it may produce a six-hour retention in the stomach and if lower down, the distention of the bowel with fluid and gas and the delay in the progress of the barium meal are rather typical.

Obstruction at any point in the small intestine may be determined by delay in passage of the barium meal.

The terminal ileum is usually well seen at the six-hour period when the presence of any unusual fixation, kinking, or obstruction may be determined by palpation in front of the roentgenoscopic screen.

**The Gall-Bladder.**—As technic has improved and accuracy in interpretation has advanced, the roentgen examination has become increasingly valuable for diagnosis of pathological conditions about the gall-bladder. Improvement in technic has made it possible to demonstrate shadows of gall-stones more often than was formerly the case. The possibility of showing such a shadow depends upon the density of the stone and upon the density of the bile, the gall-bladder, the liver and other surrounding structures. The density of the stone depends upon the amount of lime it contains. Pure cholesterin stones are less dense than the bile

which may surround them and can rarely be shown on roentgen films. The mixed stones usually cast ring-shaped or irregular polygonal shadows with a dark

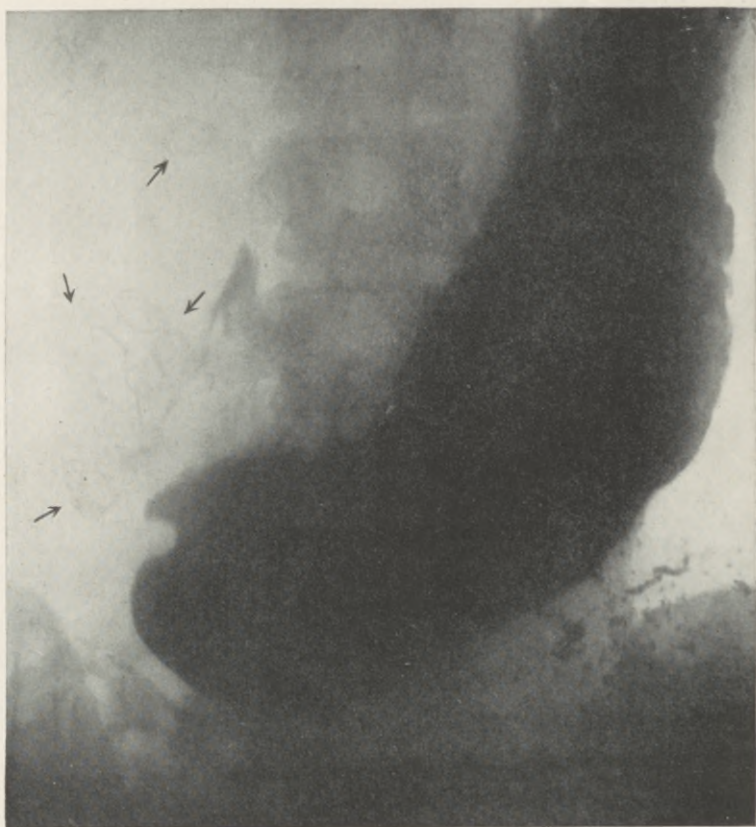

FIG. 159.—A large number of gall-stones in the gall-bladder and a single stone higher up in one of the ducts.

center (Figs. 158 and 159). If the stone contains a large proportion of lime, it casts the homogeneous shadow of a solid body (Figs. 160-161).



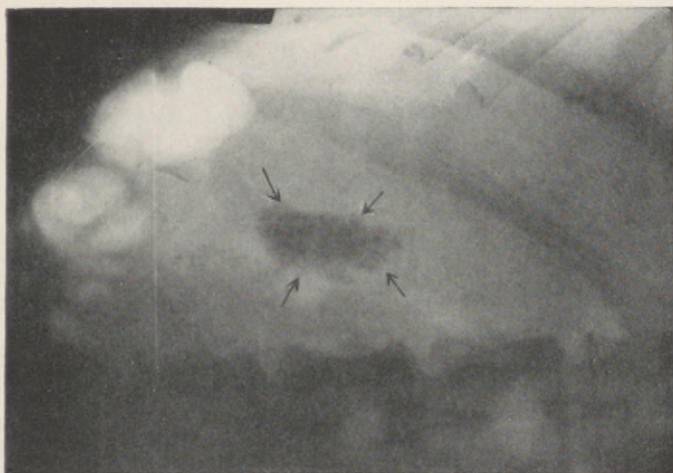


Fig. 160.—Various types of gall-stones.

The technic of gall-bladder examinations adopted by the author is as follows: The patient takes two ounces of castor oil on the evening previous to the examination and abstains from food on the morning of the examina-

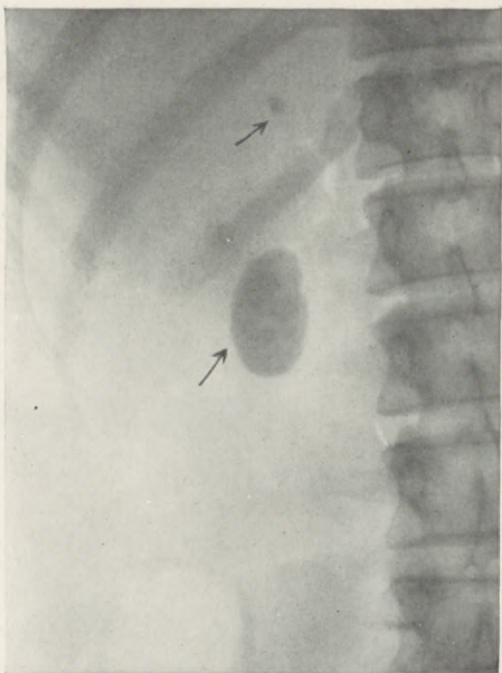


FIG. 161.—Various types of gall-stones.

tion. The essential points are to make a number of films of different densities, to make the exposures short and to secure as complete immobility as possible. The patient lies prone, the film is placed beneath the abdomen and the tube centered vertically above the first lumbar vertebra. Exposures are made both in full inspiration and in full expiration. The use of the Potter-

Bucky diaphragm has not been found especially valuable in this work. The reason for this is probably that the longer time of exposure permits of a greater blurring effect because of intra-abdominal movements of blood-vessels and viscera. Double-coated films and intensifying screens are used.

The films must be very carefully examined with good illumination and the entire right side of the abdomen from the eleventh rib down must be scanned for suspicious shadows. It is well known that the gall-bladder may occupy positions far removed from its usual place near the costal border and it is a very common occurrence to find shadows of stones below, or below and to the left of the location where they are usually supposed to be. Any suspicious shadows must be distinguished from renal calculi. If the shadows are characteristically ring-shaped, a definite opinion based upon their appearance alone can often be given that they are due to gall-stones. When doubt remains it can often be removed by making films that show the kidney outline and demonstrating that the shadows are distinctly within or outside the kidney shadow. Roentgenograms with a ureteral catheter in position or a pyelogram may be of assistance in differentiating renal and biliary calculi. Roentgenograms made with the film against the patient's back show renal calculi more sharply than do those placed against the abdomen, while the opposite is true of biliary calculi. Calcified glands may be mistaken for biliary calculi but the former usually have a lobulated appearance that is quite characteristic. Calcification of the costal cartilages has a rather typical



appearance but in rare cases where there is doubt such calcified nodules can be distinguished from gall-stones by taking films in inspiration and then in expiration. Gall-stones move downward when the patient inhales while calcified areas in the cartilages move upward. Suspicious shadows due to material in the intestinal canal can be removed by a second examination after the patient has taken another laxative.

It must always be kept in mind that the failure to show shadows of gall-stones on the roentgenograms does not exclude their presence. It is also important to remember that cholecystitis or other disease of the gall-bladder may be present without giving any roentgen evidence of its presence.

The roentgen examination may be of value, however, in such conditions through certain secondary manifestations. Gastrosplasm has already been mentioned as a result of gall-bladder disease. It is, of course, only corroborative evidence but if the stomach and duodenum are demonstrated to be free from organic disease, this sign is of some value. Distortion and fixation of the pylorus, the pyloric end of the stomach or the first or second portion of the duodenum can sometimes be fairly interpreted to be due to gall-bladder disease with adhesions. Quite often pressure of an enlarged gall-bladder produces a rounded, smooth deformity of the duodenal bulb or of the stomach that is fairly characteristic. The shadow of the gall-bladder itself is now very often seen on roentgenograms and some consider this evidence of the presence of a pathological condition. It may be said with certainty, however, that it is still

unproven that only the pathological gall-bladder casts a shadow on the film.

Recently a new method of roentgen examination of the gall-bladder has been devised by Graham, Cole and Copher.<sup>2</sup> It consists in the intravenous injection of a solution of the sodium salt of tetrabromphenolphthalein which is excreted through the gall-bladder and is opaque to the roentgen ray. Five grams of the salt is dissolved in 40 c.c. of distilled water, sterilized and injected in two equal doses, five minutes apart, into the median basilic vein. The large vein is chosen because the salt is irritating if injected into a small vein, and for the same reason the injection should be made very slowly, about five minutes being consumed for injection of the 20 c.c. To avoid irritation and resulting necrosis due to extravasation into the tissues at the site of injection, it is well to insert the needle with a syringe attached full of normal saline solution and to inject a small amount of this to make sure that the needle is in the vein. The syringe is then replaced by one filled with the opaque medium.

The normal gall-bladder begins to cast a shadow from 3 to 5 hours after injection, will show a tendency to change in shape and size and will cast its heaviest shadow between 16 and 24 hours. Pathologic gall-bladders do not cast so heavy a shadow and fail to show the elasticity and distensibility of the normal.

**THE COLON.**—The colon is examined twenty-four hours after the administration of the barium meal,

<sup>2</sup>Graham, Evarts A., Cole, Warren H., and Copher, Glover H. Visualization of the gall-bladder by the sodium salt of tetrabromphenolphthalein. *J. Am. M. Asso.*, Chicago, May 31, 1924, lxxxii, 1777-1778.



when the cecum, transverse colon, sigmoid and rectum usually contain barium. Examination is first made with the roentgenoscope to determine the presence or absence of any unusual fixation of the cecum or other parts of the colon. In a certain percentage of cases the appendix will be found filled with barium at this time, and any unusual fixation or kinking may be determined by palpation.

A roentgenogram is made after the roentgenoscopic examination to serve as a record of the condition at the end of twenty-four hours. The patient then lies upon the table on his left side and a barium enema is administered. The enema consists of five ounces of barium sulphate in one and one-half liters of warm water, with the addition of about a teaspoonful of gum arabic to hold the barium in suspension. This is placed in a fountain syringe connected by a rubber tube with a hard rubber rectal tip. When the tip is in position the patient turns on his back and the roentgenologist observes the passage of the enema on the screen until it has completely filled the colon. The patient then turns on his abdomen and roentgenograms are made.

The above routine is usually sufficient for a complete study of the colon, but in some cases further study must be made. To determine the presence and extent of obstruction it is sometimes necessary to make examination forty-eight and even seventy-two hours after ingestion of the barium meal. In some cases it is found necessary to rid the colon of the barium present from the meal and to give the enema with the colon empty, watching the shadow on the roentgenoscope as the colon



fills. The receptacle is then lowered and the enema permitted to run out and further examination is then made with the colon partially empty. Defects in the barium shadow, which are completely obscured when the colon is well filled, can be demonstrated sometimes by this method.

The colon varies greatly in different patients, within normal limits, in size, position and mobility. The only portions constantly fixed in position and which cannot be moved by palpation are the hepatic and splenic flexures, the lower-most part of the sigmoid, and the rectum. The barium meal usually reaches the cecum in about four to six hours, and is in the rectum by the end of twelve hours. The complete evacuation of the colon varies within very wide limits of time. The most noticeable thing about the contour of the colon is its division into segments by haustra. These show best when the colon is filled by the ingested meal rather than by the enema.

Dilatation of the cecum may be due to the presence of adhesions or pericolonic membranes which cause obstruction, or simply to an atonic condition. A small contracted cecum may be caused by adhesions following appendicitis or by cecal inflammation independent of the appendix, or by investing membrane. The cecum is often abnormally fixed by adhesions or congenital membranes, the fixation tending to produce cecal stasis. On the other hand it is sometimes abnormally movable (cecum mobile). In the latter case it is also dilated and atonic. Other parts of the colon may also be fixed or reduplicated in such a manner as to offer obstruction to the passage of its contents. Ptosis of the transverse

colon is very common, especially in the tall, thin individual. In nearly all patients the transverse colon makes a considerable downward curve when the patient is erect, but in cases of marked ptosis both the hepatic and the splenic flexures may descend below the iliac crests, and the transverse colon may be well down in the pelvis. The colon is a very movable viscus and it is often of great importance to determine whether some seemingly abnormal position is a fixed one. This may be done by palpation while observing the colon on the roentgenoscope, and sometimes additional evidence may be obtained by making roentgenograms in the erect, prone and Trendelenburg positions.

The cause of constipation may be found in a kink or constriction; in a large, dilated, atonic cecum; in atony of the entire colon; or in a spastic condition.

The sigmoid is sometimes long and redundant, and may be adherent in the region of the appendix or in almost any other part of the abdomen. Case reports a patient in whom the sigmoid was adherent to both a diseased appendix and to the gall-bladder.

**Neoplasm of the colon**, especially carcinoma (Figs. 162 to 166), can usually be diagnosed by roentgen examination. Great care must be exercised in studying the region of the sigmoid and rectum for suspected carcinoma. Examinations should be made twenty-four and forty-eight hours after the meal, and more important still, the barium enema as it enters, should be watched carefully on the screen.

The carcinoma is usually represented by an annular defect in the barium shadow with the narrow stream of

barium passing through the more or less centrally placed lumen. The disease produces various degrees of obstruc-

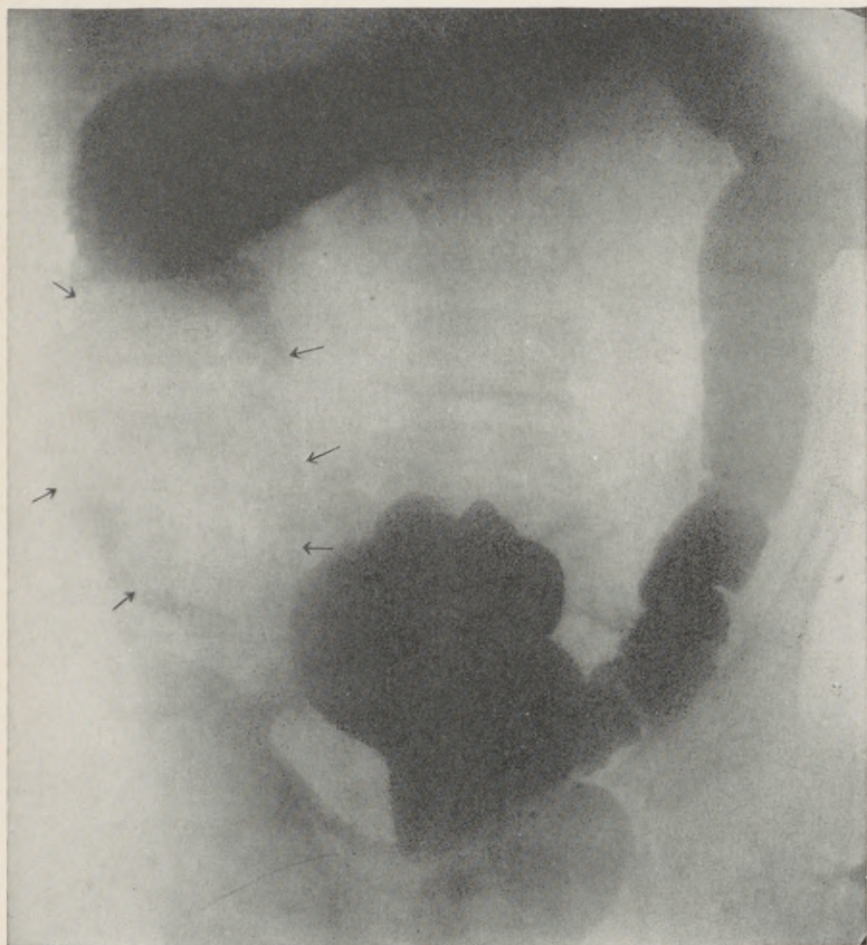

FIG. 162.—Carcinoma of the cecum and the ascending colon.

tion, sometimes almost complete, resulting in dilatation of the proximal portion of the bowel.



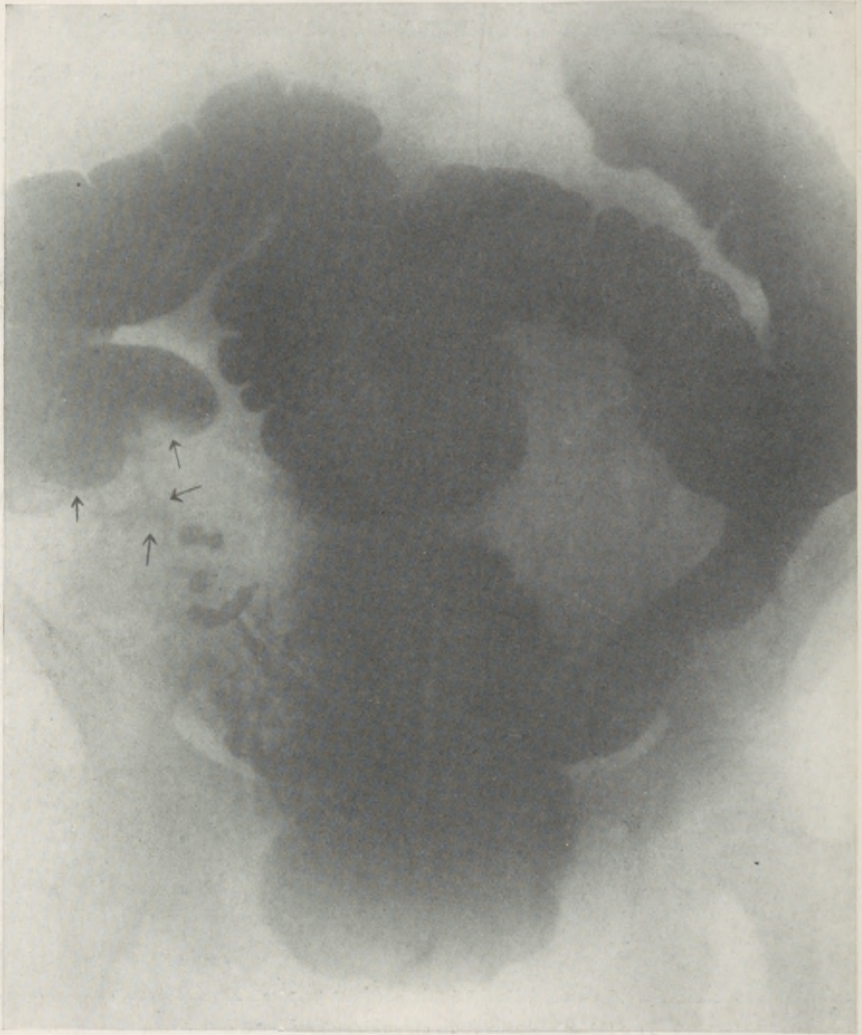

FIG. 163.—Carcinoma of cecum.

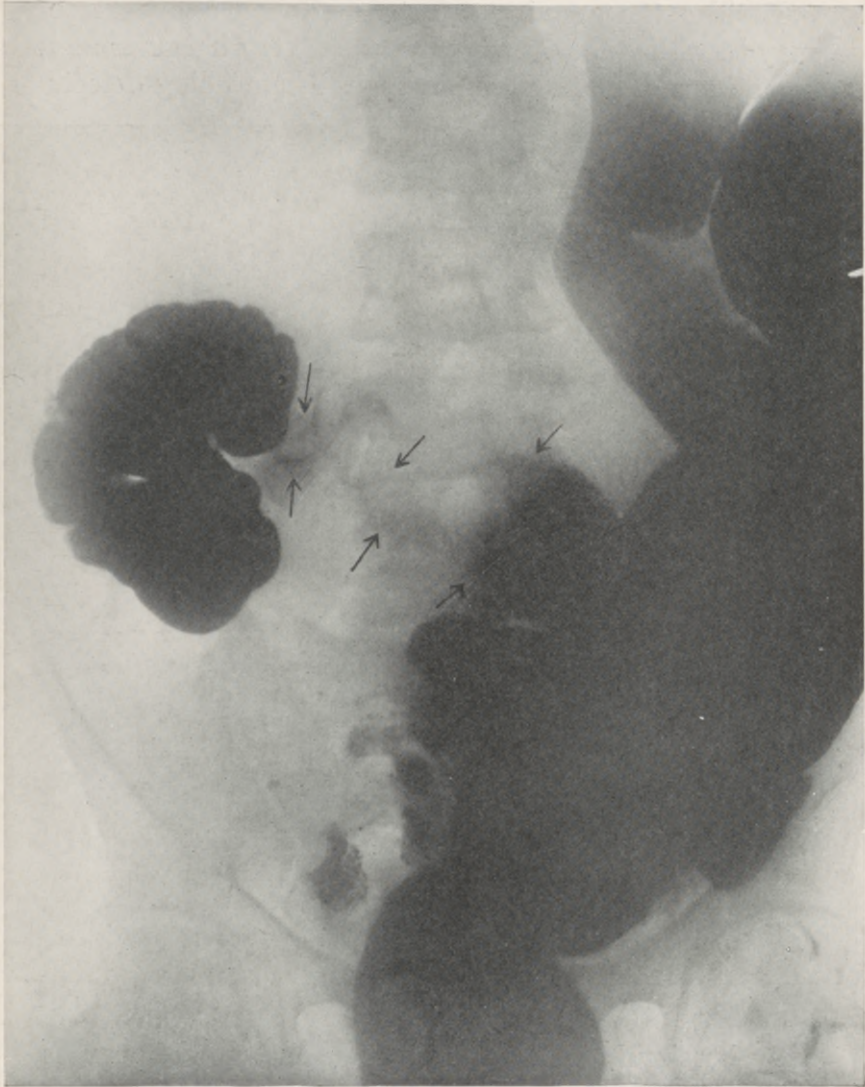


FIG. 164.—Carcinoma of transverse colon; extent indicated by arrows.

Besides the annular defect mentioned above there may be filling defects of other types, very irregular and sometimes of considerable extent. These filling defects

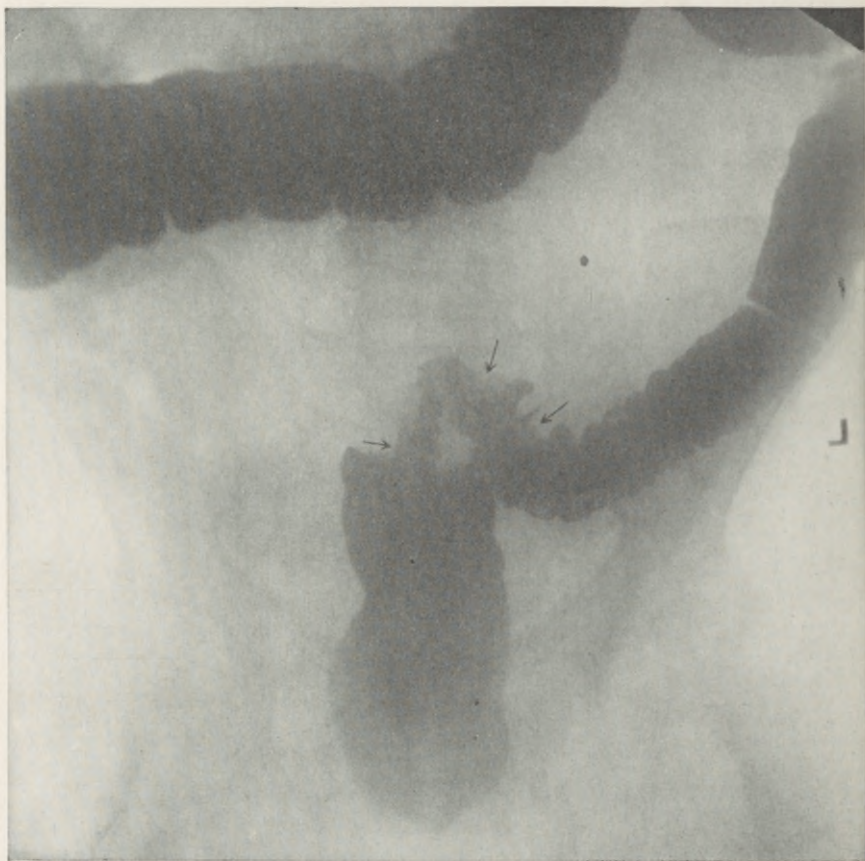


FIG. 165.—Carcinoma of sigmoid.

may be simulated by those produced by other causes such as the presence of gas or fecal matter in the bowel, the distortion due to adhesions, the pressure of tumors



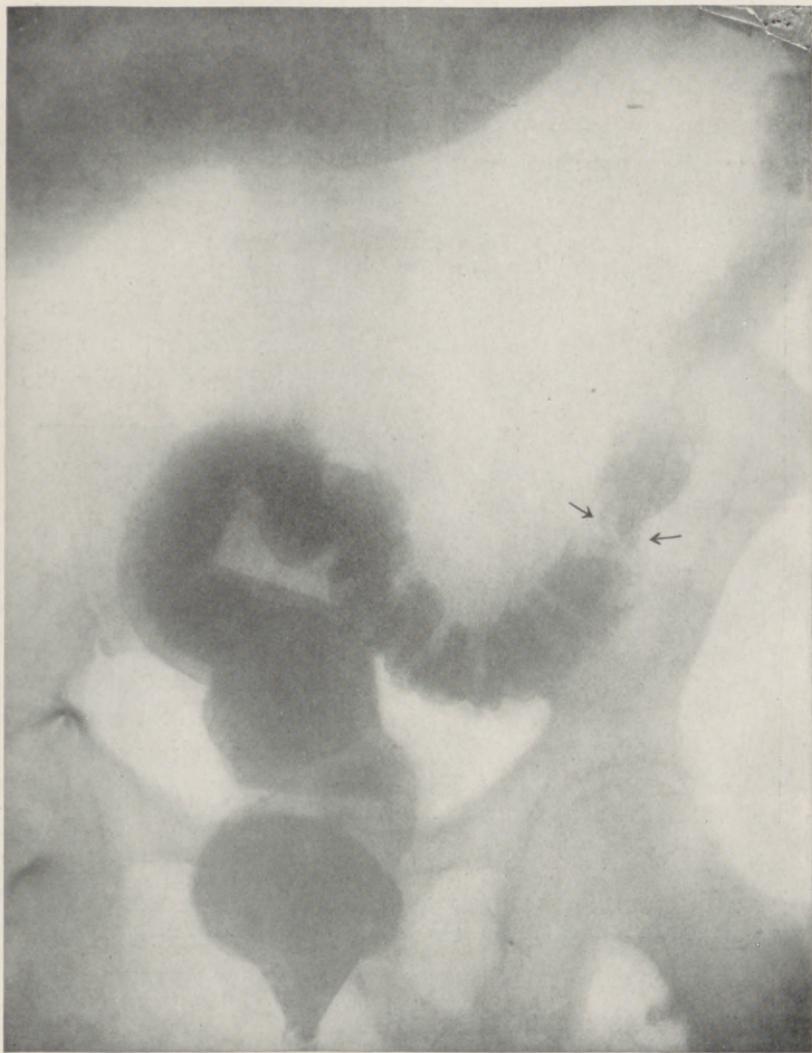

FIG. 166.—Annular carcinoma of sigmoid.

outside of the bowel (Fig. 167), local spasm, and effects of diverticula, tuberculosis, localized inflammation, etc. Whenever a filling defect is found a confirmatory examination should always be made and this will practically

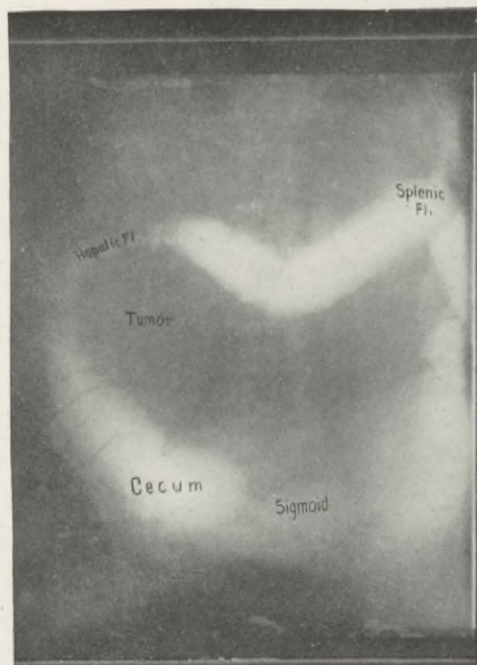


FIG. 167.—Pressure of large tumor (cystic kidney) upon hepatic flexure.

always serve to eliminate the effect of the presence of gas, fecal matter or spasm, since they are not at all likely to cause defects in the same place the second time.

The effect of pressure from tumors outside the bowel is usually to produce a smooth rounded defect which is not difficult to assign to its true cause. The defects produced

by adhesions cannot always be distinguished from those due to carcinoma. Diverticula may produce filling defects exactly simulating those of cancer but may sometimes be distinguished by the presence of the barium filled, extra-luminal sac.

Diverticula of the colon (Fig. 168) occur most often in the sigmoid, less frequently in the descending colon,

and rarely in other portions. The roentgen diagnosis depends upon the presence of small, or sometimes large, barium-filled sacs outside the lumen of the bowel. They

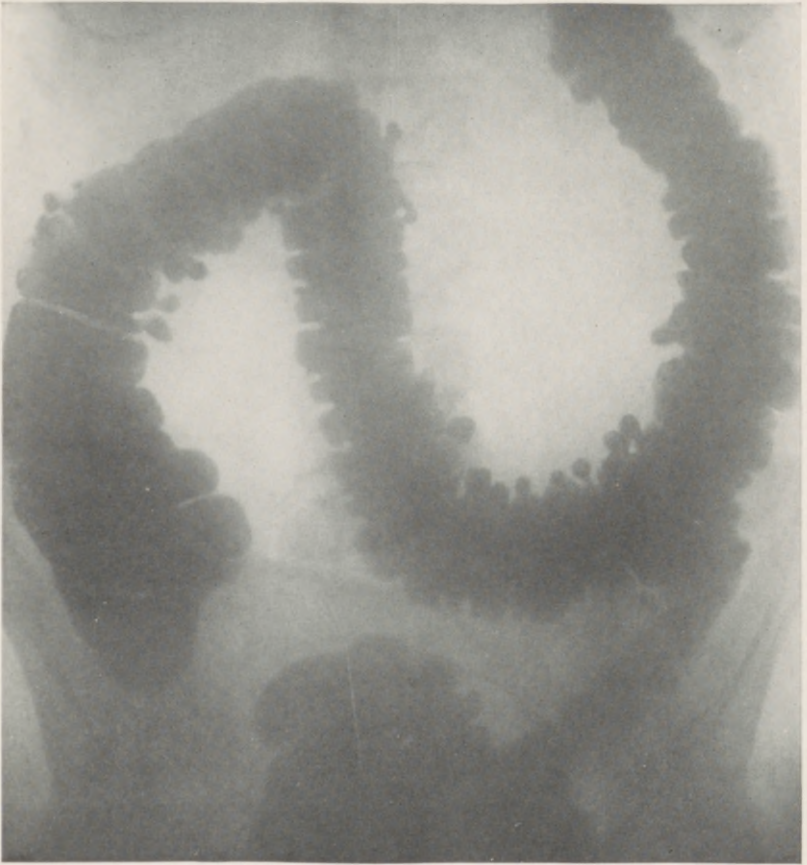

FIG. 168.—Multiple diverticula of the colon.

can usually be well seen twenty-four to forty-eight hours after ingestion of the barium meal and they often remain filled for several days after the colon itself is completely



free from barium. They can be shown particularly well by filling the bowel with a barium enema at the twenty-four hour period when the diverticula are filled with the barium from the meal. Sometimes a diverticulum may be present but its connection with the lumen of the bowel so occluded that barium cannot enter it. The defect produced in the barium shadow in such a case may not be distinguishable from that caused by carcinoma. The presence of other diverticula which the barium does fill and a history of repeated attacks of pain and fever due to diverticulitis may assist one in arriving at a diagnosis.

Tuberculosis of the colon may produce filling defects in the barium shadow difficult at times to distinguish from those of carcinoma. It most often occurs in the cecum where the roentgen findings are quite characteristic. They consist in a lack of filling of the cecum both with the barium meal and the enema. This lack of filling is due almost entirely to spasm set up by the tuberculous ulcers or to lack of tone caused by diffuse infiltration of the cecal walls. The filling defect is produced, not by encroachment of a mass upon the bowel lumen as in carcinoma, but by abnormal rapidity of passage of the bowel contents through the diseased portion of the bowel.

Chronic ulcerative colitis (Fig. 169) gives a typical roentgen appearance. This consists in a general narrowing of the bowel but especially in a disappearance of the normal haustral markings. The entire colon in these cases, or that part of it which is involved, has a smooth, sausage-like appearance.

**Chronic Appendicitis.**—The roentgen examination is of some value in the diagnosis of abnormalities in the

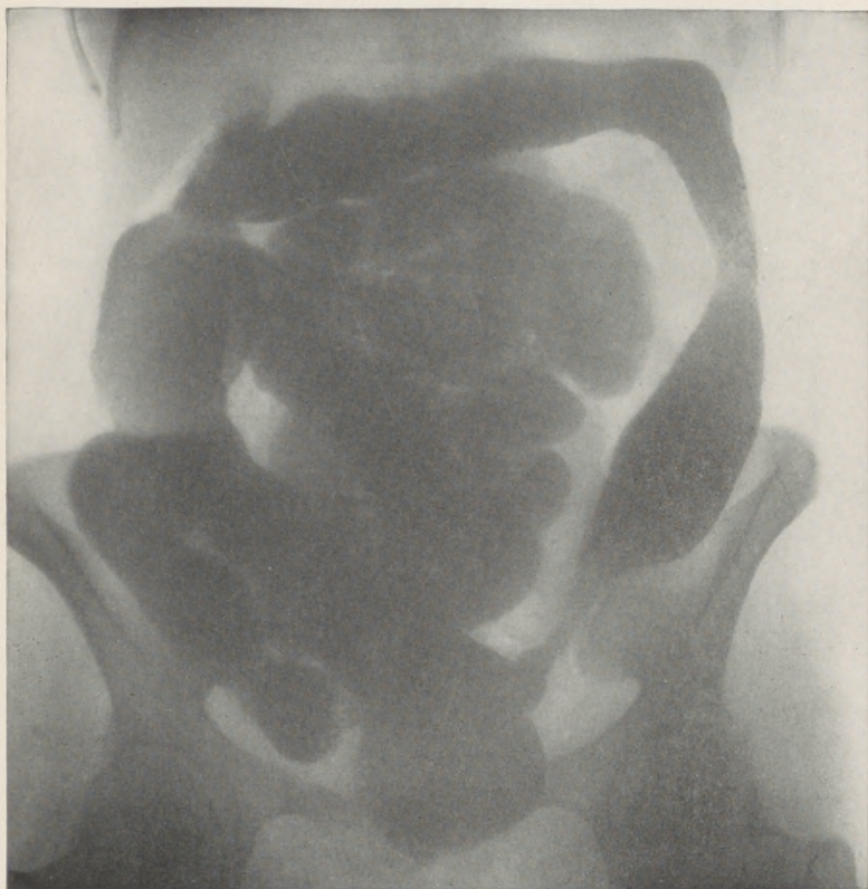

FIG. 169.—Chronic ulcerative colitis.

appendix region but its findings must be interpreted with much caution. The examination is made as a part of the gastrointestinal study at six and twenty-four

hours after ingestion of the barium meal. Fecaliths can sometimes be demonstrated in the appendix and foreign bodies such as pins have occasionally been found. The fecalith is often well outlined when the barium enters the appendix. The fact that the barium enters and fills the appendix is not evidence in itself of the presence of disease. When the appendix is thus seen, however, one may be able to demonstrate a fixed kink, abnormal fixation of a part or all of the appendix, or abnormal position. A retrocecal location is well seen in the oblique or lateral position. If a tender point can be definitely located over the appendix it is of some value for diagnosis. The presence of adhesions can sometimes be inferred by failure to move the cecum by palpation, but great care must be exercised to exclude muscular rigidity or a very low position of the cecum as causes of the failure. Incompetence of the ileocecal valve resulting in the passage of a portion of the barium enema into the ileum sometimes occurs in chronic appendicitis but it is probably of no diagnostic value. There is no doubt that it occurs in many other conditions and it has been seen in many cases in which no lesion could be demonstrated.

**Artificial Pneumoperitoneum.**—The injection of air, oxygen or carbon dioxide into the peritoneal cavity in order to secure better contrast for the roentgen examination has been in use in this country for several years.

Carbon dioxide is, perhaps, preferable to air or oxygen since it is much more rapidly absorbed.

The technic for the introduction of the gas is as follows: The gastrointestinal tract is thoroughly cleared and the bladder emptied. The point selected for the



puncture is about 2 in. below the umbilicus. This is sterilized with iodine and a needle of the type of that used for lumbar puncture is inserted into the peritoneal cavity. The needle is then connected with a rubber tube to the oxygen or carbon dioxide tank and the gas allowed to flow very slowly. From 2 to 4 liters of gas are necessary, the amount used depending upon the size of the patient and the discomfort produced. The needle is withdrawn and roentgenograms made in various positions, including the lateral positions with the film against the patient's back.

The use of this method is necessary only in a selected class of obscure abdominal conditions where it seems very important to make an accurate diagnosis and where other means have failed. It has been found valuable for the location of foreign bodies in or near the diaphragm and for other pathological conditions in that region. The differentiation of tumors of the kidney from other post-peritoneal conditions is sometimes possible by this means. The excellent detail to be obtained on roentgenograms made with the Potter-Bucky diaphragm render the use of the pneumoperitoneum method less necessary than it formerly was. There is some discomfort connected with the introduction of gas into the peritoneal cavity and in a certain percentage of the cases the discomfort is great.

Besides the discomfort there is also a certain amount of danger of unpleasant accidents and even of fatalities. Case<sup>3</sup> reported in 1921 that there had been four deaths

---

<sup>3</sup>Case, J. T. A review of three years' work and articles on pneumoperitoneum. *Am. J. Roentgenol.*, 1921, viii, 714.

reported in this country which were directly associated with artificial pneumoperitoneum. Possible dangers that may attend the use of the method are infection, puncture of the intestine or other viscus, puncture of a blood-vessel causing intra-abdominal hemorrhage or air embolism, rupture of malignant adhesions, and precipitation of cardiac failure.

## CHAPTER XIII

### THE URINARY SYSTEM

**TECHNIC OF EXAMINATION.**—The most painstaking care in technic is necessary in roentgenography of the kidneys, ureters and bladder.

The first essential is the thorough preparation of the patient, without which roentgen examination is valueless. A very light diet should be taken for twenty-four hours previous to the examination, and the bowels should be thoroughly cleared by means of castor oil,  $1\frac{1}{2}$  to 2 ounces. If, for any good reason, castor oil cannot be taken, a vegetable cathartic such as compound licorice powder may be substituted. Saline cathartics tend to produce gas, which may obscure the region under examination. The cathartic is taken in the evening and the patient comes the next morning without eating breakfast. Fecal shadows greatly interfere with interpretation and for this reason it is best not to attempt the examination until the bowels are thoroughly cleared, even if it entails a delay and another laxative.

The examination should include a roentgenogram of each kidney region, one covering the course of each ureter, and a stereoscopic pair of the pelvis, six in all. This is always necessary because it has happened that the roentgenogram showed the stone in the opposite kidney from the one suspected, while in other cases there may be calculi on both sides. The pelvis must be



included because the stone which has caused the renal symptoms may have passed into the bladder.

Films 8 x 10 in. in size have been found the most satisfactory because their area can be completely covered by the ray with the use of a rather small cylindrical diaphragm. The 10 x 12 in. size is best for the pelvis.

A soft tube with sharp focus should be used. A tube which is too hard fails to give the detail in the soft structures essential to a good roentgenogram of the kidney regions, and may fail to show the softer calculi.

Compression by means of some form of compression diaphragm, rubber bag or other apparatus is a valuable aid in securing good detail, because it displaces the abdominal contents over the kidney.

The film for the kidney should be so placed that the last two ribs and the first three lumbar vertebræ will show upon it. The target is adjusted over the center of the plate at a distance of about 18 in. and the exposure made while the patient holds his breath.

The essential features of a satisfactory roentgenogram of the kidney region are that it shall show clearly the last two ribs, the three upper lumbar vertebræ including the transverse processes, the outline of the psoas muscle and the crest of the ilium. It is now usually possible to show the outline of the kidney itself. It is important to use every effort to do this, for if a roentgenogram gives sufficient detail to show the kidney, a negative diagnosis of calculus can be based upon it with only very slight probability of error. Even in very fat patients, with thorough preparation and the use of good compression, the kidney shadow may be shown.

The film for the ureter should show the third, fourth and fifth lumbar vertebræ and the sacroiliac synchondrosis, while that of the pelvis should include both sacroiliac synchondroses, the sacrum and the coccyx to its tip.

Since the Potter-Bucky diaphragm has come into use the procedure for examination of the urinary tract is somewhat simpler than that described above. When using the diaphragm it is not often necessary to use compression. It is the author's custom now to use 14 x 17 in. films and to make one pair of the renal regions, including the upper two-thirds of the ureters, and one pair of the entire pelvis, at a distance of about 28 in. The patient lies upon the table on his back with the knees drawn up in order to straighten out the spine so that the back comes into contact with the cassette or the top of the Potter-Bucky diaphragm.

**Calculus.**—The greatest value of roentgenography of the urinary tract has been in the diagnosis of calculus. Formerly it was thought that only a positive finding was of value, but with improved technic such fine detail can now be obtained that the errors in negative diagnosis are very few.

The positive diagnosis of renal calculus is based upon the presence of a definite shadow over the kidney region. If the shadow of the kidney itself shows on the plate no difficulty is experienced in locating the stone in the pelvis, in a calyx or in the cortex of the kidney. The shadow is sometimes between the eleventh and twelfth ribs but more often below the twelfth rib. If the kidney is in its normal position, the shadow is always internal



to a line erected perpendicularly from the middle of the iliac crest.

A stone in the ureter produces a shadow somewhere along the line of the tips of the transverse processes of the lumbar vertebræ or over the sacroiliac synchondrosis. In the great majority of cases it lies below the pelvic brim.

The composition of calculi determines their degree of opacity to the ray. Oxalates and calcium carbonate form the densest stones and therefore give the most distinct shadows; the phosphates are next in density, and the urates are the least dense. The latter show very faintly or not at all, but fortunately they are found only rarely in the kidney or ureter, and in the bladder they may be located by cystoscopic examination.

Calculi are found most frequently in the ureters, next in the kidneys and least frequently in the bladder.

Renal calculi are often of very large size, occupying the entire pelvis and sometimes most of the kidney. They are not infrequently bilateral and are often multiple.

Unless the shadow has a typical appearance a second examination should always be made for confirmation. If the shadow is small and lies upon that of a rib or transverse process or is below the pelvic brim, stereoscopic films with a ureteral catheter in position are of great value.

**Differential Diagnosis.**—Calcareous glands resemble urinary calculi but may be distinguished from them by their more irregular outline and by the fact that they are not usually over the course of the ureter.

Small calcareous bodies called phleboliths sometimes



appear along the lower part of the ureter, but they are usually multiple and may be arranged in a line at an angle to the course of the ureter.

Fecal concretions or foreign bodies in the intestine are distinguished from calculi by the fact that they change position or disappear entirely.

A concretion in the appendix is easily mistaken for calculus if it happens to be directly upon the ureter. It may, however, not have its long axis in the line of the ureter and it may not occupy the same position at different examinations.

Gall-stones only rarely throw dense enough shadows to be seen on the roentgenogram taken for the kidney and when they do they usually have a fairly characteristic appearance. Because of the greater density of the outer layer of the stone the shadow has a ring-shaped appearance with a dark center. Gall-stones may also be distinguished from renal calculi by the fact that they show much better when the patient lies with the abdomen next to the plate, while renal calculi cast their sharpest shadow with the patient on the back. There are cases, however, in which the gall-stones are very dense and have not their typical ring shape, or in which they occupy a position much lower than usual, or in which there may be both gall-stones and renal stones present. Such cases greatly increase the difficulties of diagnosis and every means must be used to differentiate them. In addition to those mentioned above a valuable means of differentiation is by making lateral roentgenograms. In a true lateral view kidney stones are practically

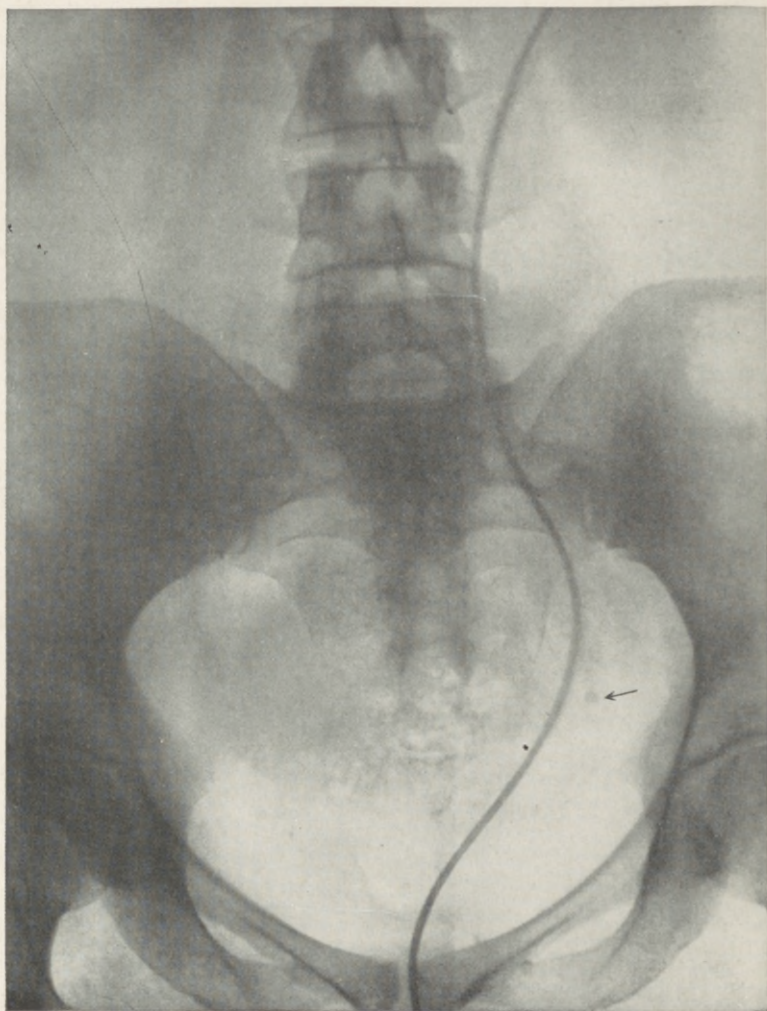


FIG. 170.—Shadow of calcified body outside of ureter as demonstrated by its relation to the ureteral catheter.

always posterior and gall-stones anterior to the plane of the anterior surface of the bodies of the vertebræ.

Difficulty in the diagnosis of renal calculus may arise because of displacement of the kidney from its normal position. The kidney may then be located by the passage of a ureteral catheter.

Sometimes a calcareous gland or other calcified body may throw a shadow directly on the line of the ureter. It then becomes necessary to take other roentgenograms with the ureteral catheter in position (Fig. 170). It must not be inferred, however, that a shadow is not that of a ureteral calculus simply because the catheter can be passed beyond it, for this has frequently happened when there is sacculation or dilatation of the ureter. Roentgenograms at different angles and also stereoroentgenograms will need to be taken to establish the exact relation of the shadows.

There are still other conditions that have at times led to erroneous diagnosis of urinary calculus. Among these are warts and pigmented moles on the patient's skin, adhesive plaster or material in a dressing, calcifications in the aorta or other vessels and calcified dermoid cyst or uterine myoma.

Only by experience and careful work can the roentgenologist avoid frequent mistakes in this field. One error that has been made, and which of course seems inexcusable, is a mistake in the side on which the stone is located. The greatest of care must be exercised in placing a mark upon the film to identify the right and left sides and if there is any question at all that a mistake has been made, the patient must be reëxamined.



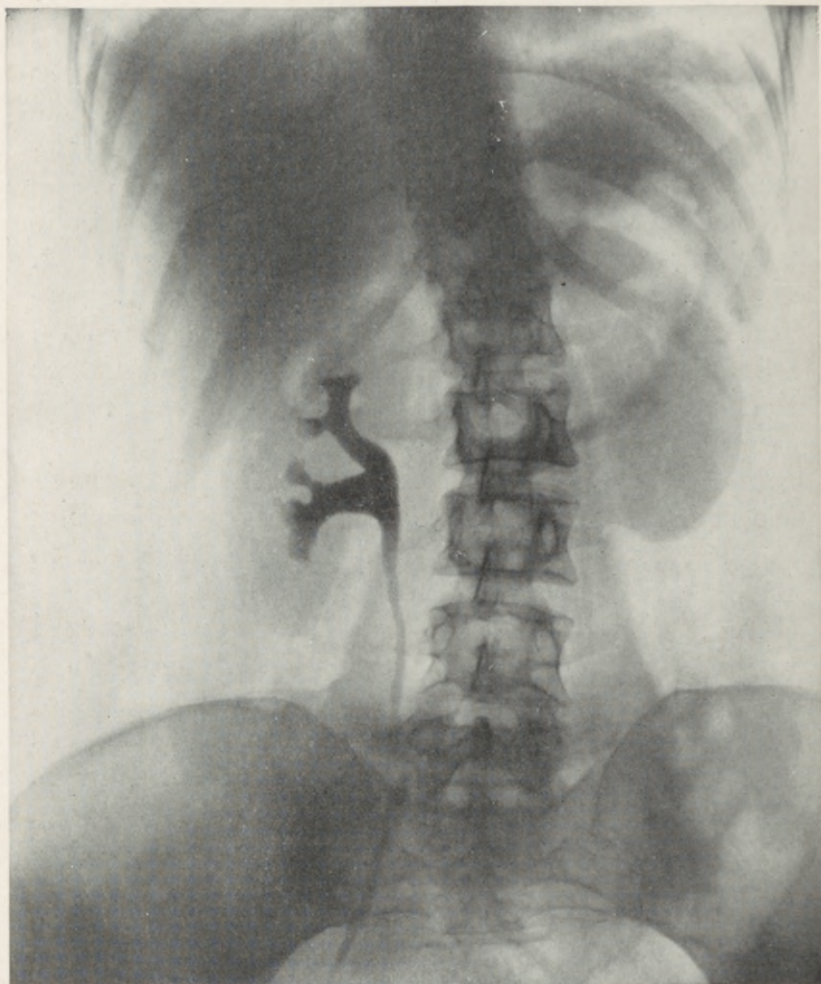

FIG. 171.—Pyelogram of normal kidney pelvis.

The author has found an additional safeguard in attaching a small lead arrow to the under-surface of the

aluminum support on which the patient lies, on the Potter-Bucky diaphragm. Patients are always placed

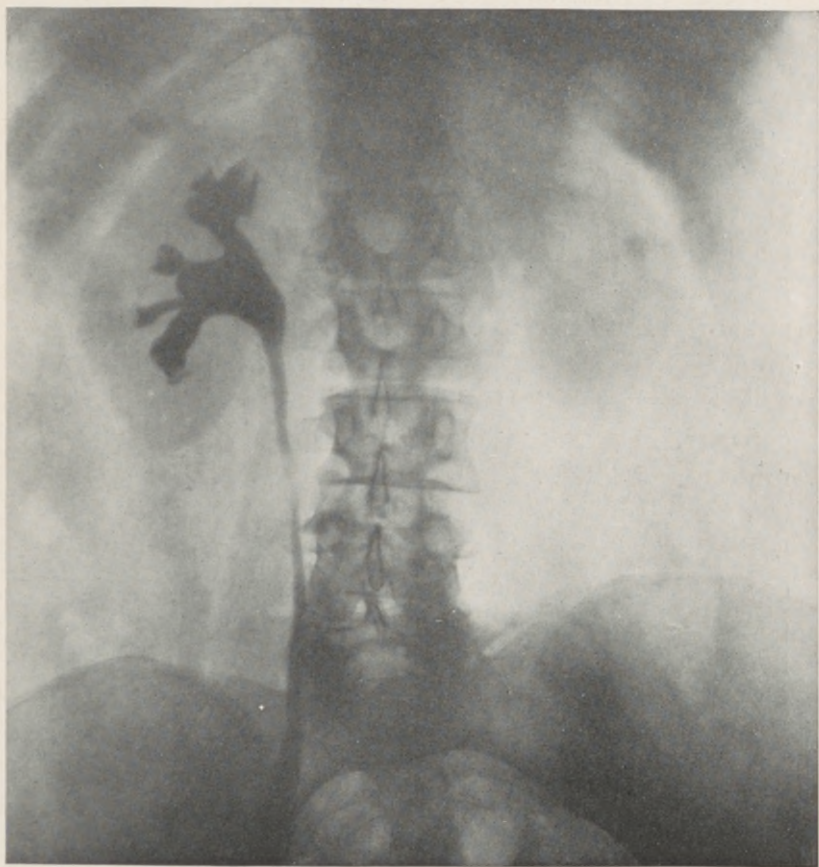


FIG. 172.—Pyelogram of normal kidney pelvis.

on the table in the same position for kidney examinations and it is then known that the shadow of the arrow on the film always points to the patient's right side.

**Pyelography.**—This is the method of demonstrating the pelvis of the kidney on roentgenograms after it has been filled with some opaque substance through the ureteral catheter. Formerly some silver preparation such as collargol, argyrol or silver iodide emulsion was used but these were later largely replaced by thorium nitrate in 10–15 per cent solution, and lately sodium iodide in 12–15 per cent solution is widely used. The solution is allowed to flow into the pelvis of the kidney from a receptacle elevated about 2 ft. above the patient. Pain due to overdilatation is the signal to stop. The amount necessary to fill the pelvis varies from 4 to 10 c.c.

The normal kidney pelvis varies greatly in size and contour. It usually has three major calyces, the upper, middle and lower. Figures 171 and 172 show types of the normal pelvis.

Pyelography gives much information in abnormal conditions that it is difficult or impossible to obtain by other methods. An abnormal *position* of the kidney becomes apparent and if accompanied by a kink in the ureter, this may be shown. Fused or horseshoe kidney, duplication of the renal pelvis and double or bifurcated ureter may be shown by this method.

**Hydronephrosis and pyonephrosis** manifest themselves, according to the degree of distention, as a flattening of the calyces with slight distention of the pelvis, to a large oval or irregular sac with complete absence of calyces (Fig. 173).

**Tumors of the kidneys** cause deformities of the pelvis according to their size and position (Fig. 174).



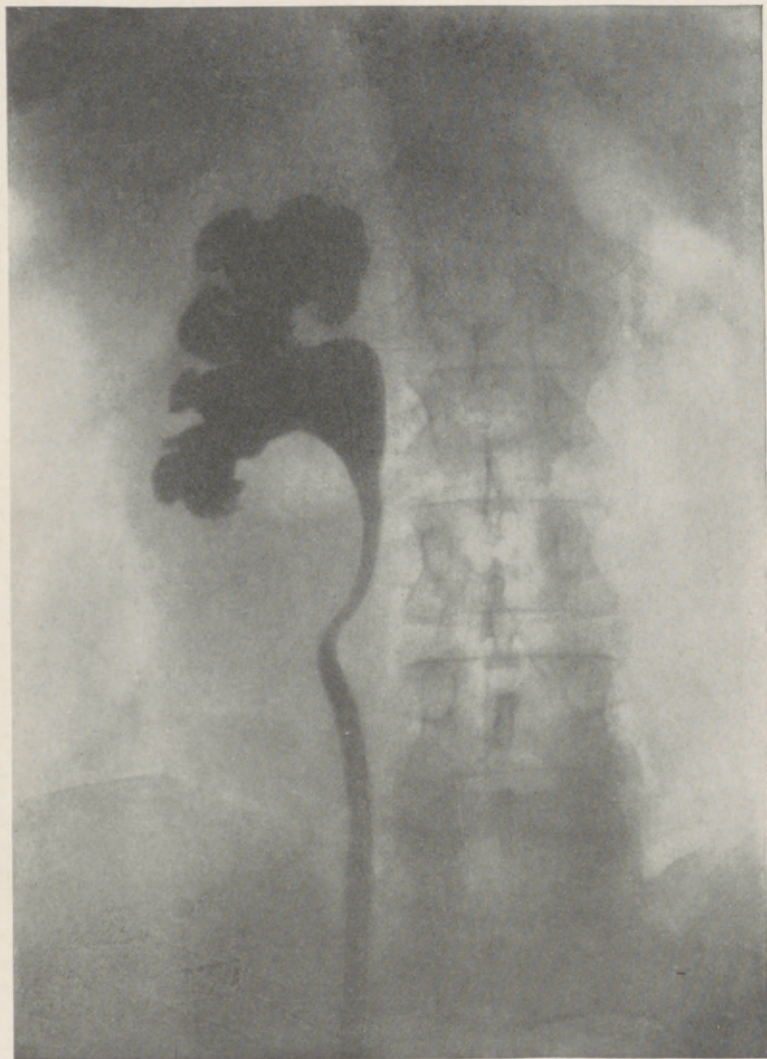


FIG. 173.—Pyelogram showing dilatation of pelvis due to pyonephrosis.

Polycystic kidney produces pelvic deformities not to be distinguished from those produced by tumors (Fig.

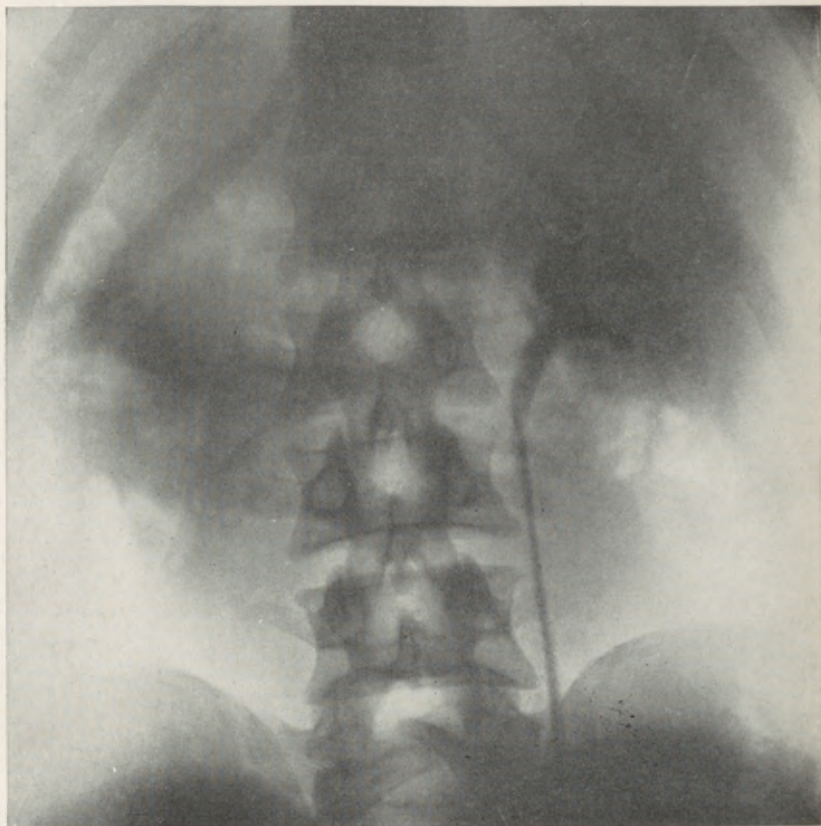

FIG. 174.—Deformity in pyelogram due to tumor of kidney.

175). When the cystic areas become calcified a characteristic appearance results (Fig. 176).

Renal tuberculosis may produce dilatation of the pelvis and stricture and dilatation of the ureter. Necrosis in the cortex connecting with the calyces may give the in-

jected pelvis a very irregular appearance, with circular or oval areas entirely separate from the pelvis itself. When the kidney becomes caseous the variations of

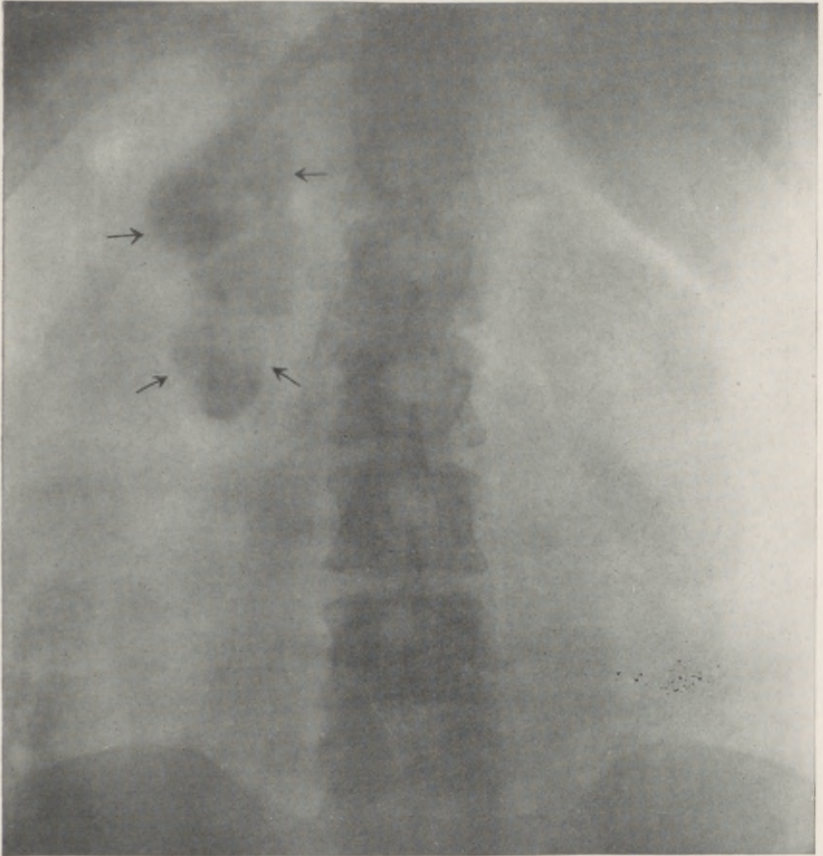


FIG. 175.—Calcified polycystic kidney.

density may be demonstrated in the shadow of the kidney itself.

Roentgenography is of value in cases of vesical cal-



culus, not only to reveal stones but also to show other abnormalities such as diverticula and fistulæ.

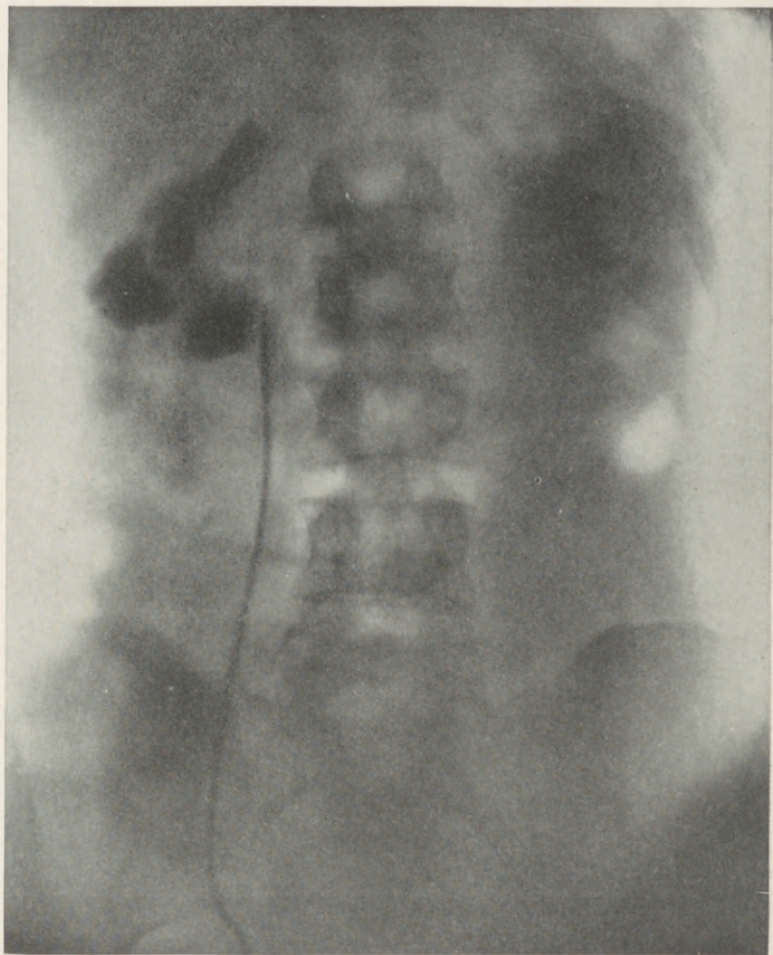


FIG. 176.—Cystic kidney causing deformity of the pelvis.

Prostatic calculi are best demonstrated in roentgenograms made with the patient lying prone.

## CHAPTER XIV

### ROENTGENOTHERAPY

#### GENERAL CONSIDERATIONS

THERE are many problems in connection with the subject of roentgenotherapy which are more or less abstruse and highly technical. It is not within the scope of a manual of this character to discuss these in detail, but only to set forth some of the more important facts that come within the purview of the student, rather than the trained roentgenologist or physicist.

**APPARATUS.**—The high tension transformer is the most satisfactory exciting apparatus for roentgenotherapy. Very much higher voltages are used for roentgenotherapy than for roentgenography, and it is desirable to use separate units for the two. It is also desirable, but not essential, to employ two separate units for roentgenotherapy, the one to be operated at relatively low voltages and the other at a relatively high and constant voltage. The apparatus must be so constructed as to maintain a constant given maximum of potential for several hours of continuous operation. The apparatus itself and all accessories should conform to the highest standards of construction and precision.

**Tubes.**—The Coolidge tube is almost universally used by American roentgenotherapists. The tube selected should be of the appropriate design and construction for the potential at which it is to be operated.

**Quality of Ray.**—The term “quality” as applied to roentgen rays refers to their power of penetration. The roentgen beam is not homogeneous. It is made up of a bundle of rays varying greatly in penetrative power. The penetrative power is believed to be dependent on wave-length—the shorter the wave-length the greater the penetration. The terms “hard” and “soft” are also used to denote rays of high and low penetration respectively. The quality of roentgen rays is to a certain extent governed by the voltage at which they are produced; the higher the voltage the greater the penetration. Voltage is contingent upon the capacity of the exciting apparatus, and its transformation into effective radiant energy is in turn dependent upon the capacity of the roentgen tube. The maximum capacity of apparatus at present available is approximately 250,000 volts.

Many methods have been devised for measuring the quality of roentgen rays, but the most practical is that which concerns itself with the measurement of voltage. The most practical method of measuring voltage is by means of the parallel spark-gap between points or spheres. Measurement between spheres is somewhat more accurate than between blunt points especially for the higher voltages, but the latter will be adopted as a basis of measurement in the following pages because of its more general use in the literature of roentgenotherapy.

**Intensity of Roentgen Rays.**—The intensity of roentgen rays is defined as “the energy falling on one square centimeter of a receiving surface passing through the point and placed at right angles to the rays.” Many



methods have been devised for measuring intensity, by making use of various properties of rays such as the photographic, heating, chemical, fluorescing and ionizing effects. These are of value and interest to the research worker and physicist but are of doubtful practical utility in the every day work of the roentgenotherapist.

It is essential, however, that the mean current passing through the roentgen tube be accurately measured. This is done by placing a carefully tested milliammeter of approved type in the tube circuit. It is of advantage to have two milliammeters in the circuit in order that one may be used as a check against the other. It is accepted as a fact that "for a given voltage the intensity of the general radiation is proportional to the current passing through the tube," hence voltage and milliamperage are important factors in the estimation of dosage.

There is another factor governing roentgen ray intensity that has an important bearing on dosage, namely, the distance of the target of the tube from the body surface. This is known as the focal distance, or the skin-focus distance. Roentgen pointed out the fact that the intensity of a beam of X-rays falls off as the inverse square of the distance from the target. This is known as the inverse square law. Its application will show that comparatively slight differences in the focal distance will make a great deal of difference in the intensity at the body surface, and indicates the necessity for its accurate measurement.

**Filtration.**—By filtration, as the name implies, is meant the interception or absorption of some of the rays of

relatively low penetration. This is accomplished by interposing certain substances between the tube and the patient. Aluminum and copper are the substances most commonly used for this purpose, being placed in sheets of uniform thickness over the aperture of the tube stand. Leather or chamois is sometimes placed next to the body surface to protect it from secondary radiations from the filter itself. The thicker the filter and the greater its density the more rays it will absorb.

Copper is commonly used as a filter material when operating at the higher and aluminum when operating at the lower voltages.

The reason for using filters in roentgenotherapy is to enable the operator to obtain a maximum effect at a depth with a minimum effect on the surface of the body. When roentgen rays strike an object physical phenomena of a highly complex character occur. It is known that under certain conditions rays are given off that are peculiar to the object struck. These are known as characteristic rays. A certain amount of scattering of the primary beam also occurs. Both the characteristic and scattered rays are often spoken of as secondary rays, but the two are quite different. It is probable that some scattering of the primary beam always occurs on striking anything in its path, but characteristic rays are produced only when the primary beam is of shorter wavelength than are the rays that are peculiar to the object struck. Filters then screen out some of the rays of longer wave-length and promote the production of secondary rays, both of which phenomena contribute to a maximum depth intensity with a minimum surface effect.



**Measurement of Dosage.**—The multiplicity of methods and devices for measuring the dosage of roentgen rays is evidence of the fact that there is no entirely satisfactory means of estimating it. Many "direct" methods of measurement based upon the chemical, photographic and other properties of roentgen rays have for one reason or another been abandoned. In general it may be stated that in view of the fact that there is no standard method of measuring dosage, it is preferable for the operator to thoroughly understand one good method and work constantly with it, rather than to combine a number of methods all of which are susceptible to error.

The iontoquantimeter, which makes use of the ionizing property of the roentgen ray, has been widely used during the past few years. Although this instrument has been very valuable in the hands of physicists and research workers and for checking up at times the output of a machine, it is not looked upon by the author as a dependable method for routine use in the hands of the majority of roentgenologists.

The most generally useful method for estimating dosage is the so-called "indirect" method. The essential factors governing the estimation of dosage by this method are voltage, milliamperage, distance and filtration, which have previously been discussed, and to these a fifth factor must be added, namely, the time of exposure. If all of these factors could be accurately known there would be no difficulty in an operator duplicating dosage repeatedly, or in duplicating the dosage of another operator. Unfortunately, this is not entirely possible with respect to voltage and milliamperage, as



these are conditioned by the construction of the generative apparatus, mode of installation, current supply, etc. Although the results of different operators are in close accord, it would be somewhat hazardous to lay down inflexible rules for the student to follow with respect to the exact combination of the various factors required, to produce a given biologic reaction. It is, therefore, incumbent upon each operator to formulate a technic with due regard to the equipment with which he is working.

**Skin Unit. Erythema Dose.**—The amount of radiation required to depilate scalp hair without producing erythema is known as a skin unit. A skin unit will cause a slight erythema on the flexor surfaces of the body of young fair-skinned individuals, but approximately 25 per cent more is required to produce a definite erythema on most parts of the body of older individuals with dark skin. MacKee and his coworkers have shown that with proper combinations of milliamperage, voltage, time and distance, the biologic reaction of unfiltered radiation on normal skin is remarkably constant. They have established a formula representing surface intensity on the basis of the following computation:

$$\frac{\text{Milliamperage} \times \text{voltage} \times \text{time}}{\text{Distance} \times \text{Distance}} = \text{Intensity at surface.}$$

The time factor in subsequent formulæ based upon the above is expressed in minutes, and the distance factor in inches.

By repeated experiments the following formula was established as representing the so-called skin unit:

$$\frac{3 \times 3 \times 4}{8 \times 8} = \frac{36}{64} = 1 \text{ skin unit.}$$

These factors may be varied to produce the same surface effect provided the proper ratio is maintained. For example:

$$\frac{3 \times 6 \times 2}{8 \times 8} = \frac{36}{64} = 1 \text{ skin unit.}$$

It is apparent, therefore, that the biologic effect of unfiltered roentgen rays so far as the skin is concerned is in conformity with the following physical laws:

1. Intensity varies directly as the voltage.
2. Intensity varies directly as the milliamperage.
3. Intensity varies directly as the time.
4. Intensity varies inversely as the square of the distance.

These laws may also be expressed as follows: (1) Doubling the spark-gap doubles the dose. (2) Doubling the milliamperage doubles the dose. (3) Doubling the time doubles the dose. (4) Doubling the distance gives one-quarter of the dose.

There are certain theoretical objections both from a biological and physical standpoint with respect to the application of the above laws when the factor of filtration is introduced. They are, however, *practically* applicable both to unfiltered and filtered rays. With filtered rays a skin unit must be established with due regard to the composition and thickness of the filter employed. This would be a complex procedure if filters varying greatly in composition and thickness were used. This, however, is neither necessary nor desirable. It is of importance, especially for the novice in roentgenotherapy to do his work with the fewest possible variations of physical factors consistent with the biological

effect intended to be produced or therapeutic aim to be accomplished. The author does nearly all of his work, either without filtration or with an aluminum filter five millimeters thick, or with a copper filter one-half millimeter thick. Exclusive of certain dermatological lesions practically all diseases amenable to roentgenotherapy can be effectively treated by using the following formulæ, each representing a so-called erythema dose as applied to most parts of the body surface of the average individual:

- (1)  $\frac{5 \times 8\frac{1}{2} \times 1}{8 \times 8}$  without filter = Slight erythema.
- (2)  $\frac{5 \times 8\frac{1}{2} \times 5}{8 \times 8}$  with 5 mm. of aluminum filter = Slight erythema.
- (3)  $\frac{4 \times 14 \times 100}{20 \times 20}$  with  $\frac{1}{2}$  mm. of copper filter = Slight erythema.

When it is desired to increase the dose beyond that necessary to produce a "slight erythema" the time of exposure is, as a general rule, the only factor that is changed. It is, of course, well recognized that there may be a wide difference of opinion as to what constitutes an erythema, and in actual practice it is frequently desirable to give a dose much in excess of that necessary to produce a slight erythema. These formulæ, therefore, simply form a convenient working basis. A "dose" as applied to roentgen rays is quite as flexible in its application as a "dose" of many other medicinal agents, and is conditioned by many different circumstances. The guiding principle with respect to dosage should be to accomplish a maximum amount of good with a mini-



mum amount of harm. To do this requires clinical sense and judgment as well as a knowledge of the physical factors governing its administration. This can only be acquired by patient study and practical experience.

It is highly important that a full and accurate record be made of all roentgen treatments. Dosage is conveniently expressed by the formula above described, with, of course, specifications as to filtration. Dosage is also often expressed in terms of milliamperere minutes, which is calculated by multiplying the milliamperage by the time. When this is done the record should be amplified by specifying the voltage, distance, and filtration. Example:

$\frac{5 \times 8\frac{1}{2} \times 5}{8 \times 8}$  Filter 5 mm. of aluminum, is equivalent to 25 milliamperere minutes, with  $8\frac{1}{2}$  inch spark-gap, 8 inch focal distance, using 5 mm. of aluminum filtration.

**Repetition of Dosage.**—No area of the body surface which has received a full erythema dose should be exposed again to the roentgen ray before the lapse of at least three weeks. Ordinarily, it is advisable not to repeat the exposure under five or six weeks, and in no event should the exposure be repeated until all evidences of active skin irritation, due to a previous exposure, have disappeared. Skin that has received an erythema dose is more susceptible to the effects of subsequent exposures, which fact may at times make it desirable to decrease the dose if repetition is necessary. As a rule the erythema due to a therapeutic dose of roentgen rays reaches its maximum in about two weeks. There are

rare instances, however, of delayed reaction where the erythema does not reach its maximum before the lapse of several weeks.

There is a limit to the number of doses that the skin will tolerate even when spaced by longer intervals than has been recommended. If treatment is continued for too long a time there is danger of establishing a chronic dermatitis or indurative edema with possible ulceration, that may be incurable. The latter may not manifest itself until long after the treatment has been abandoned. It is advisable, therefore, not to unduly prolong roentgen treatment. If the therapeutic aim is not accomplished in a reasonable time, it would be better to abandon the treatment altogether, or at least to greatly prolong the intervals between exposures. A single erythema dose may cause telangiectasia of the skin. This is a fact well worth remembering, particularly where the final cosmetic result is a matter of importance. The dilated cutaneous vessels do not as a rule appear until after several months. They may follow a mild erythema but are more apt to develop after marked reactions. They may or may not be associated with atrophy of the skin. Why telangiectasia develop in some individuals and not in others is not known.

**Cross-Firing.**—Cross-firing is a procedure employed where it is desired to give a maximum dose to a deeply-seated lesion with a minimum effect upon the skin. Its practice is based upon the well-known fact that the rays diverge from the focal point on the anode of the tube, the roentgen beam thus assuming the shape of a cone, the base of which becomes larger as the distance from

the anode increases. For example, if an area of the body surface an inch in diameter is exposed, with a skin-focus distance of eight inches, the area through which the rays emerge on the opposite side of the body will be considerably larger, the degree of enlargement, of course, depending upon the thickness of the subject. A thorough understanding of this principle makes it apparent that a deep-seated lesion may be exposed or "cross-fired" through a number of different portals, care, of course, being taken not to duplicate the exposure over any single portal.

Cross-firing through a large number of portals is not practiced as extensively as formerly since it has been learned that with proper voltage, filtration and distance, more secondary radiation occurs in the deeper structures when comparatively large areas are exposed. This secondary radiation within the tissues serves to increase the total dose to the deep structures.

**Protective Measures.**—In the treatment of disease by the roentgen ray it is usually necessary to limit the exposure to restricted areas of the body surface. This is accomplished by having the diaphragm of the tube-stand of appropriate size, by the use of suitable specula, or by placing sheet lead or other material opaque to the rays over the body surface to be protected. In treating areas in close proximity to each other special care is necessary to avoid overlapping.

The importance of complete protection of the operator and attendants from the roentgen ray cannot be too strongly emphasized. The danger is particularly great in roentgenotherapy because of the highly pene-



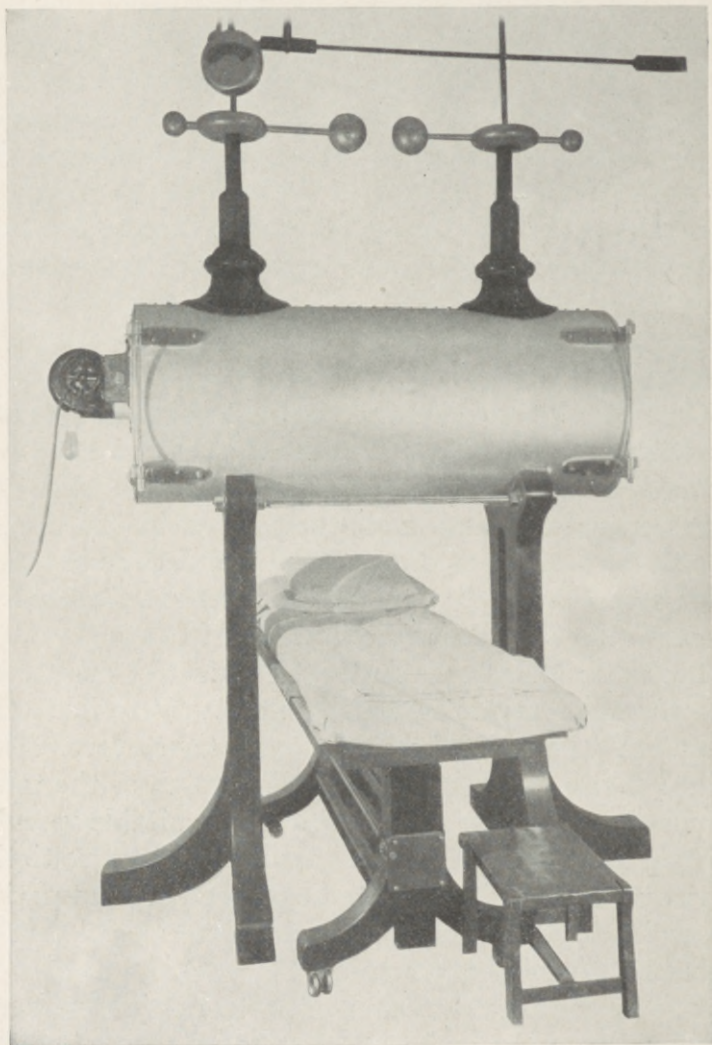


FIG. 177.—Lead cylinder enclosing Coolidge tube designed for voltages of 200,000 and upward. The table is adjustable in height.

trating quality of the rays frequently employed, and the large amount of secondary radiation which occurs under such circumstances. It is recommended that the

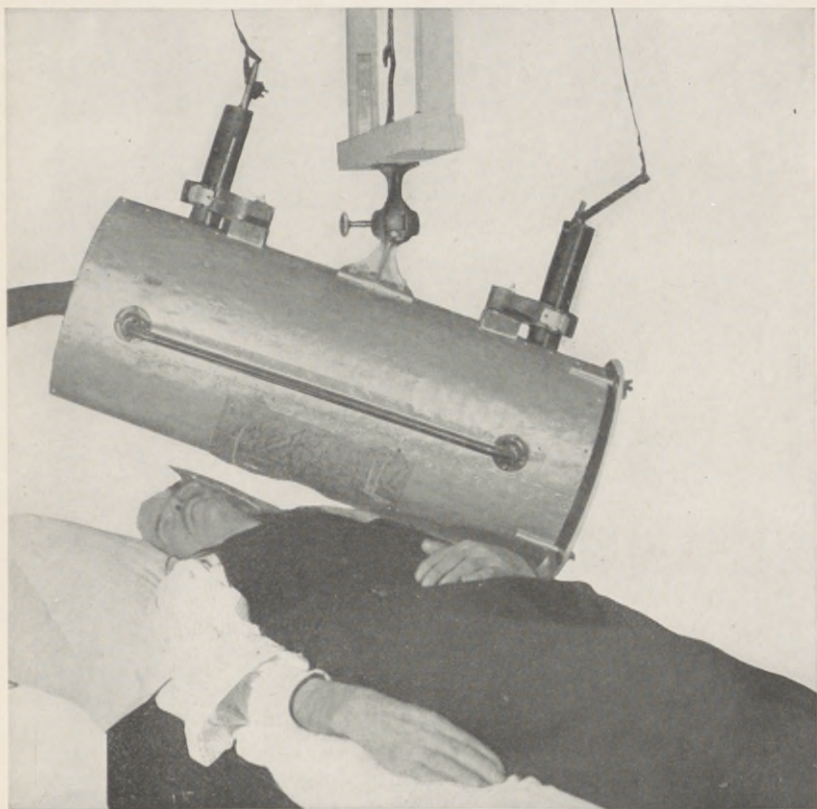


FIG. 178.—Lead cylinder, hung from the ceiling; designed for voltages up to 140,000. The height and angle are adjustable.

entire tube be enclosed in a lead chamber (Fig. 177-179), leaving an aperture for the escape of only such rays as are intended to strike the patient.

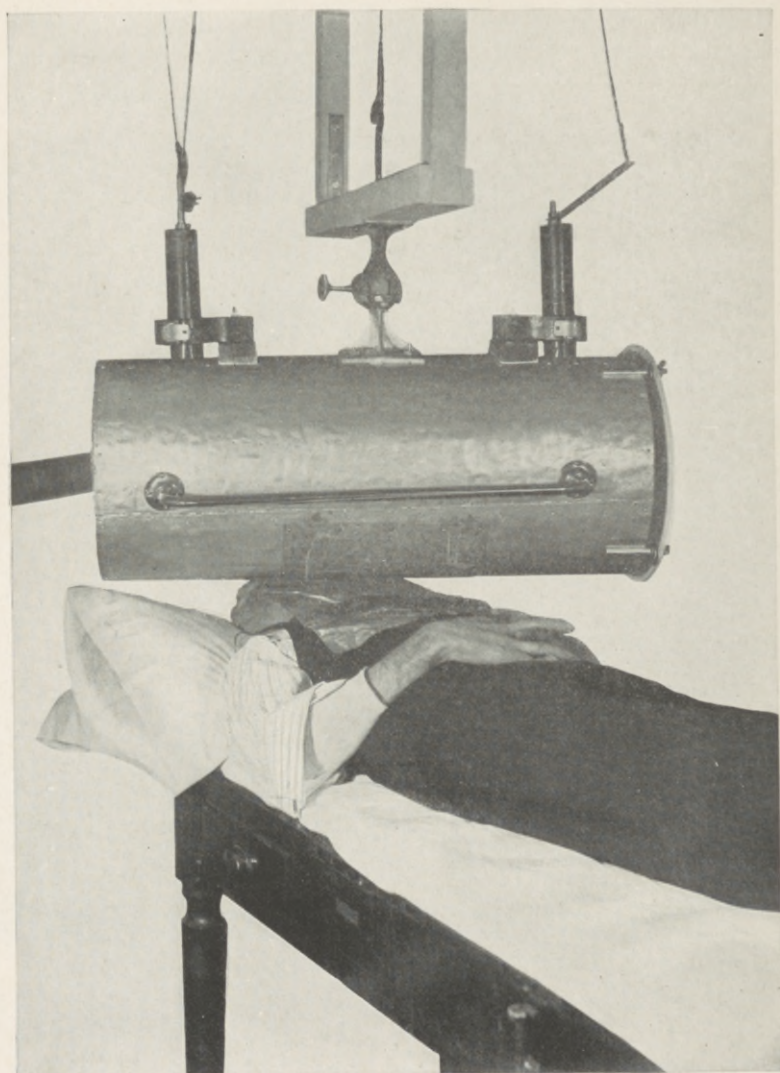


FIG. 179.—Lead cylinder in another position. See Fig. 178.



In addition an appropriate screen or booth should be provided to protect the operator from secondary radiations. The operator can readily test the efficiency of his




FIG. 180.—Perineal treatment stand.

protection by carrying photographic films on his person. If they remain free from fog over a prolonged period of operating the protection may be considered adequate.

Apparatus should also be so designed as to avoid as far as possible the danger of electrical shock. Particular attention should be given to the design of the tube container to remove as far as possible the danger of accidental contact with the high tension terminals (Fig. 179).

**Roentgen Sickness.**—Many patients after the administration of large doses of roentgen rays exhibit a train of symptoms that are often distinctly annoying. They are depressed, prostrated, have headache, distaste for food, nausea or vomiting, and often state that they “taste or smell the ray” for several days. The symptoms vary greatly in intensity in different individuals and some appear to be entirely immune in this particular even to very large doses. It is not known how these symptoms are produced. They can be minimized by having the treatment room well ventilated.

**Idiosyncrasy-Hypersusceptibility.**—There is a difference of opinion as to the existence of a true idiosyncrasy to roentgen rays. That there are variations in susceptibility is, however, undoubted. Reference has already been made to the very great variation in the intensity of the systemic phenomena known as roentgen sickness. Variations in skin reaction, independent of known contributing factors, are not nearly so common. Instances occur, however, where no satisfactory reason can be assigned for the intensity of the reaction in a given case. The color and texture of the skin influences the intensity of the reaction. The skin of young, fair individuals is more susceptible than that of the dark-skinned or aged. The flexor surfaces are more sensitive than the extensor, and the face is more sensitive than most other parts of the

body. The axillæ and perineal regions are relatively sensitive, which is probably due to the contributing factors of moisture and friction. A hyperemic or congested skin is more sensitive than one that is anemic. Extraneous influences may greatly intensify skin reaction. Exposure to the sun, friction, the application of heat, moist dressings and chemical irritants such as iodine, mercury, tar, etc., may contribute greatly to the intensity of the reaction, thereby causing much suffering and perhaps permanent disfigurement.

**Biological Effects.**—Sufficient has already been said to indicate that roentgen rays are capable of producing marked changes in the skin. These have been emphasized because they are easily observed and for that reason have been chosen as a biologic index of surface intensity. It is not to be inferred, however, that other structures of the body are not also affected. Indeed it is important to remember that the dosage of roentgen rays that may be safely given therapeutically is not necessarily limited by skin tolerance but by the tolerance of deeper structures. A great deal of experimental work has been done in an effort to determine their effects on the various organs, and cellular elements of the living organism. While these experiments are not uniform in their results, and much remains to be learned, it appears that roentgen rays are not in a true sense selective in their action. While certain organs and certain cellular elements are more sensitive than others, none are entirely immune. Only a few of the outstanding biologic phenomena will be noted in this connection.

It is a well-known fact that embryonic structures and



cells of embryonic type are peculiarly susceptible to the effects of roentgen rays. In general the effect is to retard development or to kill the cell, the result, of course, depending on the dosage, as well as on the nearness in approach to the embryonic type.

Bergonié and Tribondeau from extensive studies upon adult and embryonic cells, and upon cells in a state of rest or of active division were led to the following generalization which is known as the Law of Bergonié and Tribondeau: Immature cells and cells in an active state of division are more sensitive to roentgen rays than are cells which have already acquired their fixed adult, morphological or physiological characters. This law succinctly states in a general way their known biological effects.

In general it may be stated that bacteria in cultures or suspensions are highly resistant to the action of the rays. It is, however, a matter of common clinical observation that certain infections are favorably influenced by therapeutic doses, indicating that some change is induced in the host which is inimical to the growth and activity of the invading organisms.

That large doses of roentgen rays may have a profound influence on the blood has been definitely proven. The white blood cells, particularly the lymphocytes, are more sensitive than the red cells, but all of the elements may be affected. In general it may be stated that the effects are destructive. Whether this is due to effects on the blood itself or on the blood forming organs has not been definitely determined. Changes in the blood-vessels may also be produced by roentgen rays. Oblit-

erative changes in the vessels are conspicuous in cases of chronic radiodermatitis.

Lymphoid structures are peculiarly susceptible to the effects of roentgen rays. The lymph glands, thymus, spleen and lymphoid tissue wherever located are perhaps the most sensitive of all the structures of the body. The testicles and ovaries are also comparatively sensitive, and the fact that the function of these organs could be arrested by a comparatively small dose of roentgen rays was among the earliest of the physiological phenomena noted with respect to the action of the rays. The salivary glands are also particularly susceptible to radiation. A temporary swelling of the gland with arrest of salivary secretion are phenomena frequently noted following their exposure even to small doses.

Many other biological and physiological effects of roentgen rays have been observed, and it is now definitely known that they are capable of profoundly influencing all organs and tissues of the body. The student is referred to the work of Colwell and Russ for a more detailed account of experimental data relative to their biological and physiological effects.<sup>1</sup>

---

<sup>1</sup>Colwell, Hector A., and Russ, Sidney: *Radium, X-rays and The Living Cell*. London, 1924.

## CHAPTER XV

### ROENTGENOTHERAPY

**DISEASES OF THE SKIN.**—Practically all dermatologists bear testimony to the value of roentgen rays in diseases of the skin. The list of skin diseases in which roentgen rays are useful is a long one. Among the more important are acne vulgaris, sycosis vulgaris, recurrent boils, carbuncles, ringworm of the scalp, favus of the scalp, ringworm of the beard, actinomycosis, blastomycosis, certain types of eczema, psoriasis, lichen planus, pruritus, hyperidrosis, lupus vulgaris, scrofuloderma, verruca, keloid, rhinoscleroma, and keratoses. The technic and results of roentgen treatment of various skin lesions are described in modern textbooks on dermatology and will not be discussed here.

**Basal Cell Epithelioma.**—Probably about 90 per cent of basal cell epitheliomata can be permanently cured by roentgen rays. A small number of relapses will occur but these as a rule respond to further treatment. If the disease involves cartilage, as not infrequently happens in lesions of the ear and nose, it is apt to prove refractory to roentgen treatment. It is difficult to obtain healing over exposed cartilage. The technic of treatment will depend somewhat on the size, location and character of the lesion. Undoubtedly good results can be obtained with marked variations in technic. The author prefers to cure these lesions if possible with one treatment. Many of the more superficial lesions are



given a dose as follows:  $5 \times 8\frac{1}{2} \times 6 / 8 \times 8$ , without filtration. If there is much exuberant tissue, or if the lesion is deeper, a like amount with filtration through 5 mm. of aluminum is given in addition. This, of course, produces an intense reaction which does not entirely disappear for four or five weeks. It is rare that further treatment is necessary and recurrence is very uncommon. Treatment of lymphatic drainage areas is unnecessary in this type of lesion as they rarely metastasize.

**Prickle Cell Epithelioma.**—This is a much more serious lesion than basal cell epithelioma, and the results of treatment much more unsatisfactory. It is frequently of rapid growth and may metastasize early. The technic of treatment will depend on the location, extent and character of the lesion. Specific rules for treatment cannot be given. Each case must be considered in all of its aspects and the plan of attack decided upon accordingly. The treatment must be as intensive as possible, without doing irreparable damage to healthy structures, and requires as much skill and judgment in its application as a radical surgical operation. Lymphatic drainage areas should be actively treated. This can often be done advantageously by use of the higher voltages (14 in. parallel spark-gap) and copper filtration. Radium also has a definite field of usefulness in the treatment of these lesions. Frequently the treatment by radiation can be combined advantageously with electrocoagulation or the intelligent use of the actual cautery. The author is of the opinion that the results of such treatment are superior to those obtained by cutting operations.

*N* Deep-Seated Malignancies.—The treatment of malignant neoplasms of all types with roentgen rays has steadily grown in favor not only among roentgenologists, but among the medical profession as a whole. To what extent it will ultimately supplant or supersede other methods of treatment is at present largely a matter of conjecture. Hardly any one at the present time would deny it an important place in the treatment of this group of neoplastic diseases.

It has in the past been used almost exclusively as an adjunct to surgical treatment, or restricted to inoperable or recurrent lesions. Used as a surgical adjunct it has probably contributed to the prolongation of life and to increase in the number of clinical cures. It is impossible to estimate its degree of usefulness when used in conjunction with surgery. In inoperable cancer it undoubtedly tends to lengthen life in properly selected cases, and there have been many undoubted clinical cures in this otherwise hopeless group. This is also true with respect to recurrences following surgical excision, but generally speaking such recurrences are more refractory to treatment by radiation than are primary growths. It is impossible to state at the present time how the results of treatment by radiation alone would compare with the results of treatment by surgery alone or in combination with roentgenotherapy. There is, however, a growing tendency, which seems to be justified by experience, to treat by radiation alone cases in which surgical treatment is known to be unsatisfactory or markedly hazardous, and to combine the two agents in cases where the percentage of cures by surgery alone is known to be relatively high.



Certainly it is a mistake to operate on malignant lesions where the prospects of cure are slight. The average longevity and well-being would undoubtedly be increased if such cases were treated by radiation alone. Belonging to this group are cancers of the cervix uteri, prostate, and many other lesions where there are metastases quite beyond the reach of surgery. It also needs to be pointed out in this connection that it is worse than useless to treat by radiation cases that are markedly cachectic.

Clinical experience has demonstrated that there is a wide variation in the susceptibility of malignant tumors to radiation. Among the more susceptible are lymphomata, or embryonal tumors such as carcinoma of the testis or ovary. Among the more resistant are osteosarcoma and neurosarcoma. There is a large intermediate group including adenocarcinoma, carcinoma simplex, squamous carcinoma, etc.

With respect to the technic of treatment of these various groups by roentgen rays no fixed rules can be given. Dosage should be adjusted to the individual case with due regard to the age and condition of the patient, type of tumor, its size and relation to other organs, its rate of growth and channels of metastasis. Treatment with the higher voltages (14 in. spark) and copper filtration, at a skin focus distance of 20 in. is as a rule the appropriate procedure. Cases may require an aggregate exposure of 1600 ma. min. or more, depending on the number of areas treated. It is the author's practice not to give more than 400 ma. min. daily and as a rule not more than half that amount. It is as a rule unwise to repeat such a cycle for at least three months.



Roentgenotherapy can be advantageously combined with the use of radium in certain cases. This is particularly applicable to the treatment of malignant neoplasms of the uterus. Electrocoagulation or removal of the growth with the actual cautery is also to be commended in certain cases.

**Hodgkin's Disease.**—Roentgen treatment causes marked and rapid reduction of the enlarged glands of Hodgkin's disease, and often a marked improvement in the general condition of the patient. While the initial improvement is often spectacular it is very rarely or perhaps never permanent. The initial dose should always be small, and the condition of the patient is the only safe guide to its subsequent size or frequency of repetition. Treatment with moderate voltages and aluminum filtration is perhaps quite as satisfactory as with high voltages and copper filtration.

**Leucemia.**—Leucemia is favorably influenced by roentgenotherapy, but it is doubtful if permanent cures are ever attained. Life can, however, often be greatly prolonged, and long periods of comparatively good health maintained in true leucemia as well as in the pseudoleucemias. There is as a rule a marked improvement in the blood picture and in the general well-being of the patient.

No definite standard of technic for the treatment of leucemia can as yet be laid down. Both the spleen and the epiphyseal ends of the long bones should be exposed. The blood-picture and general condition of the patient afford the best guide to dosage and to the frequency of its repetition.

In both leucemia and Hodgkin's disease caution

should be observed in regard to dosage. Large doses may cause such a rapid breaking down of tissue as to induce an alarming or even fatal toxemia.

/// **Tuberculous Adenitis.**—In tuberculous adenitis roentgenotherapy is believed to be the most efficacious of all methods of treatment. By its intelligent use, in combination with appropriate hygienic measures, radical excision of tuberculous glands will very rarely be necessary. Certain types of cases are more favorable for treatment than others, but there are none in which roentgenotherapy is not well worth a trial. If possible, treatment should be instituted before breaking down of the glands has begun. If breaking down has already commenced, roentgenotherapy will likely hasten the process. The pus may then be evacuated through a small incision. The most refractory cases are those with extensive sinuses and an abundance of scar tissue, such cases often having been subjected to repeated operations. Even in the latter the results of treatment are often most gratifying. Coexistent tuberculosis of the lungs is by no means a contra-indication to treatment, but renders the prognosis less favorable. //

There is no technic for the roentgen treatment of tuberculous glands that has been universally adopted. Good results are doubtless obtained by widely different methods. Many operators administer a comparatively small dose at frequent intervals, while others give a fairly large dose less frequently. The author commonly gives the following:  $5 \times 8\frac{1}{2} \times 4\frac{1}{8} \times 8$  with

<sup>1</sup>In this and other formulæ the author has for obvious reasons chosen to indicate *minimum* doses, and doses administered in excess of those indicated would not necessarily be regarded as inadvisable.



5 mm. of aluminum filter. This may be repeated at intervals of ten days, the intervals between treatments being gradually increased as improvement occurs. Where there is a large amount of scar tissue, caution should be observed as to dosage, as such tissue is comparatively easily damaged by roentgen rays. Often it is necessary to continue the treatment of these cases for a prolonged period, a sufficient interval being allowed between exposures to safeguard against a chronic roentgen dermatitis. Treatment should not be abandoned too soon as the sinuses will often heal only after many months of patient effort. Small fibrous or calcified nodules may remain permanently at the site of the diseased glands. These are seemingly innocuous.

**Tuberculous Peritonitis.**—The results of roentgenotherapy in tuberculous peritonitis are often highly satisfactory. If there is much fluid in the peritoneal cavity, it should be evacuated before beginning treatment. The dosage is essentially the same as for tuberculous adenitis. From two to four portals may be required to cover the entire abdomen.

**Non-Malignant Diseases of the Uterus. Uterine Fibroids.**—The indications for the roentgen treatment of fibroids may be conservatively stated as follows:

1. All cases, regardless of the age of the patient, in which an operation is contra-indicated either by the association of some other disease, or by a high grade anemia in consequence of hemorrhage.

2. All patients over forty years of age who present no contra-indication to roentgen treatment.

The contra-indications to roentgenotherapy are as follows:



1. Small tumors causing no symptoms and not requiring treatment of any character.
2. Submucous polypoid growths.
3. Rapidly growing tumors in patients below forty years of age, where the symptoms are of such urgency as to necessitate prompt relief.
4. Gangrenous or infected tumors, or where there is an associated disease of the adnexa.

In addition to the above the age of the patient should be considered in deciding upon the course to pursue. In women of child-bearing age roentgenotherapy may cause permanent sterility. In such cases a myomectomy if feasible, may be the treatment of choice. In this group roentgenotherapy may be resorted to later if surgery fails to give relief.

The results of roentgenotherapy are also more satisfactory in tumors of small or medium size in which excessive bleeding is the predominant symptom than they are in very large tumors or where the predominant symptoms are due to pressure. In the latter group surgery may be resorted to if roentgenotherapy fails to give relief. In deciding on the choice of treatment it is to be remembered that roentgenotherapy is without mortality, whereas the surgical treatment of uterine myomata is attended by an average mortality of more than 5 per cent.

A competent gynecological examination should, of course, precede treatment in all cases, but the author believes that a curettage for diagnostic purposes is not only unnecessary as a routine procedure, but is a practice to be condemned.

The following technic has given satisfactory re-

sults in the author's experience:  $5 \times 8\frac{1}{2} \times 5/8 \times 8$ , 5 mm. al. filter, over each of four areas of the lower abdomen, and one area over the sacrum.

As a rule three such treatments are given at intervals of three to five weeks. Exceptionally only two treatments are needed and rarely four are necessary. Bleeding is not infrequently arrested after the second treatment and menstruation almost invariably ceases after the third. There is a coincident improvement in the anemia and general well-being of the patient. The tumor decreases in size and frequently disappears entirely. There is relief of pressure symptoms coincident with the decrease in size. The diminution in size continues for some time, and a maximum reduction is frequently not attained for several months. Symptoms common to the normal menopause may be present.

Practically the same results may be obtained in uterine fibroids and metropathic hemorrhages by the use of radium as are obtained with roentgen rays.

**Metropathic Hemorrhages.**—Included under this head are that group of cases characterized by menorrhagia or metrorrhagia in which no tumor or other gross pathological defect is present. Although commonly classified as "metritis" or "endometritis" there is often no discoverable pathologic basis. The so-called climacteric hemorrhages belong to this group. In the latter the results of roentgenotherapy are very gratifying. In general it may be stated that the nearer the climacteric age is approached, the more suitable the case for roentgen therapy. Good results are, however, often obtained in younger subjects. The ideal result in the latter would be to check excessive bleeding without perma-



nently abolishing the menstrual function, but such is by no means always possible, which facts should be explained to the patient before instituting treatment.

The technic of roentgen treatment of uterine fibroid and metropathic hemorrhage are essentially the same.

**Benign Hypertrophy of the Prostate.**—Roentgenotherapy in prostatic hypertrophy will often give very marked relief of symptoms and at times produces a complete clinical cure. Its general applicability as a method of treatment has not as yet been established, but it may be resorted to with considerable hope of success in cases where surgical interference is contra-indicated or is likely to be extremely hazardous. The soft glandular type of hypertrophy responds to treatment more readily than the hard cirrhotic type. Symptomatic relief is frequently marked within a few days following treatment. Nocturnal frequency, pain, urgency and the amount of residual urine are all lessened, and there is also a coincident improvement in the general health and well-being. The size of the prostate decreases rapidly and may return to normal.

Benign prostatic hypertrophy is conveniently and effectively treated by directing the rays through the perineum. The patient sits on an appropriately designed seat having the Coolidge tube beneath it (Fig. 180). The following dose may be given:  $5 \times 8\frac{1}{2} \times 5/8 \times 8$  with 5 mm. of aluminum filtration. A similar dose may be given through the pubic region. This dose may be repeated at intervals of three weeks. It is possible that the high voltage technic may be found to be superior, but this is not yet proven. Certainly it is to be preferred if there is any suspicion of malignancy.



**Hypertrophy of Tonsils and Adenoids.**—It is quite well proven that roentgenotherapy will frequently cause a shrinkage of hypertrophied lymphoid structures of the upper air passages, with a coincident relief of the symptoms which they occasion. There is a wide difference of opinion as to the general applicability of this method of treatment, but it is well worth a trial in cases where surgery is contra-indicated. The rays are directed behind the angle of the jaw through an aperture about two inches square. The following dose may be given:  $5 \times 8 \times 4/8 \times 8$  using 5 mm. of aluminum filtration. This dose may be repeated at intervals of two weeks. From four to eight such treatments may be required. The treatment may cause temporary swelling of the parotid gland and lessened salivary secretion.

**Hyperthyroidism.**—Roentgenotherapy is coming more and more to be recognized as a valuable therapeutic aid in the treatment of hyperthyroidism. Evidence is rapidly accumulating which tends to show that the results of such treatment are on a par with its surgical treatment. In addition the operative risk is eliminated.

True exophthalmic goitre is more amenable to roentgenotherapy than toxic adenoma. Both, however, respond to treatment. It is highly important that a basal metabolism determination be made before beginning treatment.

The technic of treatment is as follows: Each lobe of the thyroid and one area over the thymus are exposed to the following dose:  $5 \times 8\frac{1}{2} \times 5/8 \times 8$  using 5 mm. al. filter. This dose is repeated at intervals of three weeks. Usually after the third or fourth treatment (sometimes sooner) there is beginning improvement characterized

by a decrease in the nervous and emotional phenomena; decrease of tremor; and slowing of the pulse rate. At this time a second basal metabolism determination is made, the result of which, in conjunction with the clinical manifestations determines the advisability for further treatment. It is exceptional that more than six or eight treatments are required. Repeated basal metabolism determinations are advisable to avoid the danger of unduly prolonging treatment which might possibly cause hypothyroidism.

Improvement when once begun is usually progressive. The nervous symptoms, agitation and tremor disappear; the heart and metabolic rates return to normal and the weight, strength and endurance increase. The size of the thyroid is decreased but some enlargement may persist. The exophthalmos also decreases, but is usually the last symptom to show improvement, and some prominence of the eyes may persist indefinitely. It is not to be expected that patients with marked myocardial degeneration or extensive visceral changes, the result of prolonged toxicity, will be restored to normal, but many such will become relatively symptom free when the hyperfunction of the thyroid has been corrected.

It is highly important that patients with hyperthyroidism in addition to roentgen treatment have appropriate general supervision, and that proper rest be insisted upon. The psychic manifestations of the disease should not be disregarded, and to combat these every effort should be made to gain the patient's confidence and coöperation.





# INDEX

- Abscess of lung, 184  
Accessory pocket as a sign of gastric ulcer, 225  
Adenitis, tuberculous, treatment of, 307  
Air bells on negatives, 65  
Aluminum as filter, 286  
Ampere, unit of current strength, 3  
Aneurysm of aorta, 175  
    differential diagnosis of, 176  
Ankle, fractures about, 94, 95  
Aorta, aneurysm of, 175  
Apparatus, roentgen ray, 26, 35  
Appendicitis, chronic, 265  
Argyrol for pyelography, 278  
Arrhenius, theory of, 1  
Arthritis, chronic, 107  
    deformans, 107  
Atom, electrical constitution of, 2  
Auto-transformer, 44  
  
Barium sulphate as opaque medium for roentgen study of gastrointestinal tract, 206  
Bergonié and Tribondeau, law of, 300  
Biological effects of roentgen rays, 299  
Black spots on negatives, 66  
Blood, effect of roentgen rays upon, 300  
Bones and joints, diseases and injuries of, 79  
Bone tumors, 125  
    differential diagnosis of, 141  
Bronchiectasis, 186  
Bronchopneumonia, roentgenographic findings in, 185  
Bursitis, 120  
    about shoulder joint, 82  
  
Calculus, prostatic, 282  
    urinary, 271  
    differential diagnosis of, 272  
Cancer of small intestine, 247  
  
Carcinoma, metastatic in lungs, 197  
    of bone, 138  
    of the colon, 256  
    of the esophagus, 210  
    of the mediastinum, 180  
    of the stomach, 232, 233  
    primary, of the lungs, 196  
        differential diagnosis of, 197  
Cardiospasm, 210  
Carman, Russel D., 223, 245  
Case, James T., 267  
Caseous pneumonia, 192  
Cathode rays, discovery of, 8  
    identity with electrons, 9  
    relation of, to roentgen rays, 9  
Cecum, dilatation of, 255  
    tuberculosis of, 264  
Cerebral pneumography, 162  
Charcot's joint, 115  
Chest, normal appearance of, 172  
    roentgenography of, 170  
    roentgenoscopy of, 171  
    stereoscopic roentgenograms of, 170, 171  
Chondroma, 128  
Cirrhosis (fibromatosis) of the stomach, 238  
Cole, Lewis Gregory, 244  
Colitis, chronic ulcerative, 264  
Collargol for pyelography, 278  
Colles' fracture, 85  
Colon, carcinoma of, 256  
    diverticula of, 262  
    examination of, 253, 254, 255  
    tuberculosis of, 264  
Constipation, some causes of, 256  
Contrast in roentgenograms, 47  
Coolidge tube, advantages of, 23  
    description of, 19  
    differences from gas tube, 20  
    methods of heating filament of, 21

- Coolidge tube, radiator type of, 21  
in roentgenoscopy, 70
- Coolidge, W. D., 19
- Cooling of developing solutions, etc., 61
- Copper as filter, 286
- Coulomb, definition of, 3
- Coxa vara, adolescent, 92  
in Perthes' disease, 115
- Crimp marks on negatives, 68
- Crookes, Sir William, 8
- Cross-firing, 292
- Current, alternating, 3  
direct, how produced, 2  
sources of, for roentgen-ray work, 32, 33
- Cysts of bone, 135
- Dark room, care of, 61  
technic, 56
- Dental roentgenography, 162
- Depilation, dosage necessary to produce, 288
- Dessane's bonnet operating roentgenoscope, 69
- Detail in roentgenograms, 48
- Developing in tanks, 61  
in trays, 60, 61  
solutions, 57  
formule for, 58  
powders for preparation of, 60  
temperature of, 60
- Development, uneven, 65
- Diaphragm, eventration of, 205  
hernia of, 205  
paralysis of, 205  
roentgenologic study of, 202
- Diverticula of the colon, 262, 263  
of the esophagus, 210
- Dosage, measurement of, 287  
by "indirect method", 287  
by iontoquantimeter, 287
- Dose, repetition of, 291
- Duodenal ulcer, 241
- Duodenal, roentgenological signs of, 243, 245
- Duodenum, roentgenography of, 241
- Electricity, and magnetism, 1  
faradic, 1  
galvanic, 1  
nature and properties, 1  
static or dynamic, 1
- Electromagnetism, 6
- Electromotive force, volt as unit of, 3
- Electrons, formation of, in Coolidge tubes, 10  
formation of, in gas tubes, 10  
properties of, 9  
relation of, to roentgen rays, 9
- Empyema, chronic, 179
- Emphysema, obstructive, due to foreign body in a bronchus, 201
- Enchondroma, 128
- Endostoma, 125
- Endothelioma, 138
- Epithelioma, basal cell, treatment of, 302  
prickle cell, treatment of, 303
- Erythema dose, 288
- Esophagus, benign stricture of, 215  
carcinoma of, 210  
diseases of, 207  
diverticula of, 210  
foreign bodies in, 215, 216  
method of examination, 207
- Eventration of the diaphragm, 203
- Exostoses, 125  
cartilaginous, 125
- Exposure, directions for, 51  
effect of voltage upon, 53  
effect of milliamperage upon, 53
- Fibromyoma of uterus, treatment of, 308
- Filament, Coolidge tube, current for, 46
- Filtration, importance in roentgenotherapy, 285, 286

- Finger marks on negatives, 65  
 Fixing solutions, 59, 60  
 Fluorescent screen, description of, 69  
 Fog defect on roentgenograms, 64  
   dichroic, 66  
 Foreign bodies in the respiratory passages, 199  
   localization of, 74  
     direct roentgenoscopic control in, 75  
   Hernaman-Johnson's method of, 77  
   in the eye, 78  
   parallax method of, 78  
   precautions to be observed in, 76  
   roentgenoscopy in, 74  
   simple method of, 75
- Gall-bladder, examination of, 247, 250  
   tetrabromphenolphthalein in, 253  
 Gall-stones, differential diagnosis from stones in urinary tract, 273  
   shadows of, 247, 250, 251, 252  
 Galvanic cell, 1  
 Gastric ulcer, 223  
   perforation of, 228  
 Gastrointestinal tract, examination of, 206  
   preparation of patient for, 206  
 Gastropasm, as sign in gastric ulcer, 230  
 Geissler tube, 8  
 Giant-cell tumor, 135  
 Graham, Evarts A., Cole, Warren H., and Copher, Glover H., 253  
 Gumma of the lungs, 199
- Handley, theory of dissemination of carcinoma, 138  
 Head, examination of, 144  
 Head, fractures of, 144  
 Heart, roentgenography of, 173  
   size of, 174  
 Hematoma, ossifying, 123
- Hemorrhages, metropathic, treatment of, 310  
 Hilum tuberculosis, 192  
 Hip, fractures of, 90, 91  
 Hodgkin's disease, diagnosis of, 182  
   treatment of, 306  
 Hour-glass stomach, organic, as sign of gastric ulcer, 228  
   spasmodic, as sign of gastric ulcer, 230  
 Humerus, fracture of surgical neck, 82  
 Hydronephrosis, 278  
 Hydroquinon in developing solutions, 58  
 Hypernephroma, 141  
   metastatic in lungs, 197  
 Hyperthyroidism, treatment of, 312  
 Hypophyseal tumors, 158
- Idiosyncrasy to roentgen rays, 298  
 Immobilization, importance of, in roentgenography, 54  
 Incisura as a sign of gastric ulcer, 229  
 Induction, 4  
   coil, 26  
 Intensifying screens, 52, 53  
 Intracranial tumors, 158  
 Ions, movement of, in galvanic cell, 2  
   separation of, by generators, 2  
 Interrupter, electrolytic, 30  
   Caldwell-Simon, 31  
   Wehnelt, 31  
   mercury, 30  
   dipper, 30  
   jet, 30  
   rotary, 30  
   types of, 29  
   use of with induction coil, 28  
   vibrating, 29  
 Inverse currents, effect of, upon roentgen rays, 27  
   methods of eliminating, 27  
   production of, 27  
   and Villard tube, 28



- Inverse square law, 285  
 Iontogram, 287
- Jachcs, L., and Wessler, H., 177  
 Jackson, Herbert, 13
- Kidney, calculus of, 271  
   normal pelvis of, 278  
   polycystic, 280  
   tuberculosis of, 280  
   tumors of, 278
- Kilovolt, definition of, 3  
 Kilowatt, definition of, 3
- Legg's disease, 114  
 Leucemia, treatment of, 306  
 Linitis plastica, 238  
 Lobar pneumonia, roentgenographic findings in, 184  
 Lungs, abscess of, 184  
   syphilis of, 199  
   tumors of, 196  
 Lymphoid structures, effects of roentgen rays upon, 301  
 Lymphosarcoma of the mediastinum, 180
- Madelung's deformity, 120  
 Magnetism, 5  
 Magnetic field, 5  
 Malignancies, treatment of deep seated, 304  
 Mandible, fractures of, 145  
 Manges, W. F., 201  
 Mastoid processes, disease of, 152  
 Mediastinitis, 179  
 Mediastinum, abscess of, 179  
   diseases of, 179  
 Mediastinum, tumors of, 180, 181  
 Metal in developing solutions, 58, 59  
 Metastatic tumors of the lungs, 197  
 Millimeter, 45  
 Milliamperes, definition of, 3  
 Myeloma, multiple, 137, 138  
 Myositis ossificans, 123
- Niche as a sign of gastric ulcer, 223
- Ohm, unit of resistance, 3  
 Ohm's law, 4  
 Opaque meal for gastrointestinal study, 206  
 Oscilloscope, 27  
 Osteitis deformans (Paget's disease), 115  
   fibrosa cystica, 117  
 Osteochondroma, 129  
 Osteogenesis imperfecta, 120  
 Osteoma, 125  
 Osteomyelitis, acute, 100  
   chronic, 97, 98, 100  
 Osteomyxoma, 129  
 Osteosarcoma, 134  
 Over-exposure, 62
- Paget's disease, 115  
 Pancoast, Henry K., 188  
 Pancreas, cysts of, 236  
 Peacock green on negatives, 68  
 Periosteitis, 95  
   syphilitic, 96  
 Peritonitis, tuberculous, treatment of, 308  
 Perthes' disease, 114  
 Pleurisy, acute, 177  
   with effusion, 177  
   with encapsulated effusion, 178  
 Pneumoconiosis, 187  
 Pneumoperitoneum, artificial, 266  
 Pneumothorax, 176  
 Polarity, 45  
 Polycystic kidney, 280  
 Position, right anterior oblique, 207  
 Potassium bromide as a restrainer, 62  
   cyanide as a reducer, 63  
   permanganate as a reducer, 63  
 Potter-Bucky diaphragm, 11  
   and scattered rays, 49  
   construction of, 49  
   use of, 50  
 Prostate, treatment of hypertrophy of, 311  
 Protective measures, 293

- Pyelography, 278  
 Pyonephrosis, 278
- Radius, dislocation of head, 85
- Rectification of current from high tension transformers, 37  
   by radiator type of tube, 21
- Rectifier, aluminum cell, 33
- Residue of barium meal as sign of gastric ulcer, 230
- Resistance, electrical, means of controlling, 43  
   ohm as unit of, 3
- Reticulation of negatives, 67
- Rheostat, description of, 44
- Rickets, bone changes in, 110, 111  
   lung changes in, 112
- Roentgenoscope, horizontal, 70  
   operating, 69  
   upright, 70
- Roentgenoscopic room, 73
- Roentgenoscopy, 69  
   apparatus for, 69  
   conditions essential for the best, 73  
   in localization of foreign bodies, 74  
   protection during, 69
- Roentgen rays, absorption of, 11  
   factors necessary for production of, 12  
   history of, 8  
   intensity of, 284
- Roentgen rays, methods of measuring, 285  
   properties of, 8, 10  
   relation of, to light, 11  
   scattering of, 11  
   spectrum of, 11  
   wave-length of, 11
- Roentgen-ray tubes, 13  
   accessory anode of, 16  
   care of, 24  
   cathode of, 14  
   cause of blackening of, 25  
   Coolidge, 19  
   early type, 13  
   Roentgen-ray tubes, Jackson type, 13  
     late model, 14  
     radiator type of Coolidge, 21  
     regulating the vacuum of, 16  
     "sputtering" of target in, 25  
     target of, 14  
     water-cooled, 14
- Roentgen sickness, 298
- Roentgen, William Conrad, 8
- Roentgenography, and photography, 56  
   description of procedure, 60
- Roentgenotherapy, apparatus for, 283  
   Coolidge tube for, 283  
   general considerations, 283  
   quality of ray for, 284
- Salivary glands, effects of radiation upon, 301
- Sarcoma, differential diagnosis of, 141  
   medullary, 131  
   metastatic in lungs, 197  
   of bone, 131  
   periosteal, 131
- Scattered rays, 11  
   effect of, upon contrast and detail, 49  
   Potter-Bucky diaphragm for elimination of, 49
- Scattering, importance of, in roentgenotherapy, 286
- Schlatter's disease, 118
- Scratches or abrasions on negatives, 65
- Scum on negatives, 67
- Scurvy, bone changes in, 112
- Semilunar bone, dislocation of, 88, 89
- Shoulder, dislocation of, 82  
   roentgenography of, 82
- Sinuses, nasal accessory, 147, 148
- Skin, diseases of, 302  
   -focus distance, 285  
   unit dose, 288
- Skull, fractures of, 144
- Small intestine, cancer of, 247
- Sodium carbonate in developing solutions, 57, 58, 59

- Sodium hyposulphite in fixing solutions, 59  
 iodide for pyelography, 278  
 sulphite in developing solutions, 58, 59  
 in fixing solutions, 59
- Solenoid, 6, 7
- Spastic contractions in gastric ulcer, 228
- Sprengel's deformity, 120
- Stereoscopy of chest, 171
- Stomach, benign tumors of, 240  
 carcinoma of, 232, 233  
 cirrhosis of, 238  
 roentgenologic examination of, 216, 217, 218  
 syphilis of, 240
- Storage batteries as source of power, 32
- Surge, 43
- Subphrenic abscess as a cause of elevation of the diaphragm, 204
- Syphilis of bone, 103  
 of bone, congenital, 102, 103  
 of the lungs, 199  
 of the stomach, 240
- Syphilitic osteomyelitis, 104
- Technic, roentgenographic, 47
- Teeth, roentgenography of, 162
- Telangiectasis, 292
- Temporo-mandibular joint, cause of pain in, 157
- Tetrabromphenolphthalein for examination of gall-bladder, 253
- Thorium nitrate for pyelography, 278
- Thymus, enlarged, 180
- Thyroid gland, intrathoracic, 180
- Tonsils, treatment of hypertrophied, 312
- Transformer, Coolidge tube filament, 45  
 high tension, advantages of, 35  
 alternating current and, 37  
 description of, 35  
 oil insulation of, 37  
 rectifying current from, 37
- Tuberculosis of bone, 100  
 of the colon, 264  
 pulmonary, 188  
 apical, 189  
 bronchopneumonic type, 190  
 cavitation in, 190  
 fibrosis in, 190  
 hilum, 192  
 in children, 194  
 classification of, 195  
 miliary, 192  
 pneumonic, 192  
 renal, 280
- Tuberculous dactylitis, 103
- Tumor, giant-cell, 135
- Tumors of bone, 123  
 of the lungs, 196  
 metastatic, 197
- Tungsten, as material for target, 15
- Ulcer, gastric, 223
- Under-exposure, 63
- Undissolved chemicals, effect of, on roentgenograms, 66
- Ureter, calculus of, 271, 272
- Urinary calculus, 271  
 system, examination of, 269, 271  
 preparation of patient for, 269
- Vacuum in roentgen-ray tubes, regulation of, 16, 17, 18
- Ventriculography, 158, 162
- Vertebra, fracture of, 81, 82
- Villard tube, 28
- Volt, unit of electromotive force, 3
- Von Recklinghausen's disease, 118
- Waters' position, 149
- Water spots on negatives, 67
- Watt, definition of, 3
- Wave-length and penetrating power, 284
- Wessler, H., and Jaches, L., 177
- X-ray (see roentgen-ray)







DEC 23 1924



WN 100 C555r 1924

45310340R



NLM 05231122 9

NATIONAL LIBRARY OF MEDICINE