



ISABELLA JOHNSON.

6

CASES
OF
FUNGUS HEMATODES
OF
THE EYE.

WITH AN ATTEMPT TO CHARACTERIZE TWO SPECIES
OF THAT DISEASE AND OF CANCER OF THE EYE.

BY ALEX. H. STEVENS, M.D.

SURGEON TO THE NEW-YORK HOSPITAL, CONSULTING PHYSICIAN TO THE NEW-
YORK DISPENSARY, AND LECTURER ON CLINICAL SURGERY.

CASE I.

March 3, 1818.

ISABELLA JOHNSON, a coloured woman, aged 37 years, was brought to the New-York Hospital on account of a fungous tumour proceeding from the orbit of the left eye. It projects over the greater part of the cheek, and extends laterally from the left alæ of the nose to the left temple; its most prominent point is about three and a half inches from the edge of the orbit. Its circumference, measured as near the face as possible, is nine inches. The tumour is moderately hard, and not painful to the touch; on the outer side it is covered with skin greatly distended, but not diseased: the inner side is smooth, shining, transparent, and studded with

small prominences about the size of a shot, apparently covered by the conjunctiva: numerous blood vessels are seen ramifying beneath it: the nose is excoriated by its pressure. The anterior and most prominent part of the fungus is in a state of ulceration; a coat of a light straw colour, resembling dried pus, covers it partially, and where this is abraded, dark purple spots are seen beneath. The tumour is irregularly tuberculated, its edges are reverted; it does not easily bleed: the eye-ball, partly covered by the upper eye-lid, and protruded without the orbit, is very much flattened before and behind, but not enlarged: it occupies the upper and outer part of the tumour, into which it is partially imbedded; notwithstanding which, it is susceptible of slight voluntary movements. The upper half of the cornea, which alone is visible, is flattened, but almost transparent. The retina and iris discover no organic alteration; the former, however, is insensible of light, the latter motionless. The diameter of the pupil is equal to about half that of the cornea. The secretion of tears is uninterrupted. The submaxillary glands on the left side are much swollen. There is also a glandular tumour over the left articulation of the lower jaw; these knots are quite moveable, and like the principal tumour, not painful to the touch. The patient is slightly comatose. She suffers at night especially from a pain shooting

backwards through the left temple, for which she has taken Tinct. Opii. She has become emaciated of late. The menstrual discharge has been regular. The right eye is entirely free from disease. She states that her left eye became weak about six years ago, after an attack of measles; that it began to swell about a year since; that six months ago, (the tumour then being as large as a pullet's egg,) her eye still retained the power of vision. Being informed that an operation for the removal of the tumour would be hazardous, and that its ultimate success would be very uncertain, she says she prefers it to the prospect of certain death.

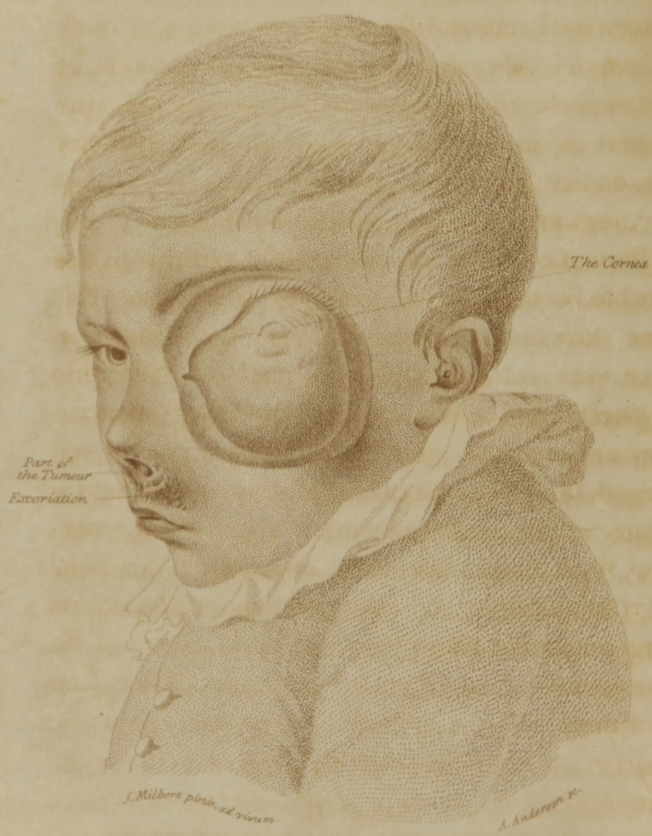
March 7th.—The tumour has sensibly increased since the last report: the cornea is more opaque, and the ulcerated portion greater in extent than on the 3d inst.: a few drops of blood oozed from the part to which the dressings had adhered.

An operation having been agreed on in consultation of the surgeons, I commenced it by a free incision backwards from the external edge of the orbit; from the termination of this incision the scalpel was carried around the lower part of the base of the fungus to the internal canthus, thence under the roof of the orbit to the external canthus, dividing the palpebral conjunctiva of the upper lid, and leaving the latter untouched. In separating the tumour from the cheek,

several arteries sprung, which bled so freely as to render it necessary to accelerate the operation; at the same time, the prodigious extent of the disease showed the impossibility of a nice removal of the morbid parts. The tumour was therefore quickly detached from its further connexions within the orbit, by carrying the scalpel around its posterior part. A ball of lint was placed upon the bleeding vessels, and the cavity of the orbit was filled with it. The patient being now in a state of syncope, was laid upon the floor, and took wine; as she recovered, the upper eye-lid was brought down, and the dressings kept perfectly tight to the divided surface by a monocolus bandage.

Dissection of the tumour.—Several portions of bone were removed with the tumour. The humours of the eye, all its tunics, and the optic nerve, were apparently natural. The mass of the tumour, since its removal, consists of a light yellow soft compact substance, partaking of the qualities of the medullary portion of the brain, and the intervertebral substance. There are several cavities filled with a soft straw-coloured unorganized substance not unlike custard, which has been baked too much. A lateral section through the dark coloured spots on the anterior part of the tumour discovered a congeries of blood vessels, livid on the outer edge, and gradually becoming more florid to the depth of

N^o 1.



MR G'S SON.

three quarters of an inch, where they terminate in the yellow portion of the tumour.

2d day.—A slight bleeding occurred since the operation; it was readily stopped by pressure.

3d day.—The patient is somewhat feverish; otherwise comfortable.

30th day.—She has been comfortable since the last report: the discharge has been good: the wound is diminishing in size: the submaxillary glands are smaller.

Afterwards the woman's health became greatly improved, and she passed six months in tolerable comfort. At the expiration of this time, however, it was evident that the disease was returning, though she was still able to pursue her ordinary business: the submaxillary and parotid glands had considerably enlarged, and she complained of pain in the tumour, which was increasing in size. At the present time (Oct. 1818) the condition of this poor creature is truly frightful; the tumour is quite as large as before the operation, and enormous tumours have formed on the left side of the face and neck.

CASE II.

A SON of Mr. G. aged three years, complained of pains over the orbit of the left eye, which

were accompanied with moderate constitutional irritation. A seton was introduced into the neck, and mercurial and antimonial preparations were exhibited, under the idea that his disease was hydrocephalus; and this opinion was strengthened soon afterwards by the falling of the eye-lid of the left eye, the dilatation of its pupil, and gradual loss of sensibility in the retina.

On the 10th of April, when I first saw him, the globe of the eye was entirely hid from view by the upper eye-lid, which was distended, inflamed, and slightly œdematous. On raising the eye-lid the globe appeared somewhat enlarged; in other respects, except the dilatation of the pupil, the eye was perfectly natural, but it was evidently protruded; the angle formed by the nose and cheek, from the inner canthus half the distance to the inferior part of the septum, was partly obliterated; an acrid fluid oozed from the left nostril, which was impervious to air. All medicines were now suspended, and the seton was withdrawn. The left eye-lid was kept moist by an emollient application.

On the 17th of April, all the morbid appearances having increased, and the coats of the eye being distended, it was deemed adviseable to evacuate the aqueous humour. A small puncture was accordingly made through the cornea,

about a line from the ciliary ligament; the side of the instrument rested in contact with the iris. During the discharge of the aqueous fluid, that membrane contracted, and after the operation the pupil was contracted to half its former diameter.

On the following day the wound in the cornea was not visible, and the globe of the eye and the pupil had acquired their former magnitude.

On the 22d, the protrusion of the eye had become so great, that the upper eye-lid, though it had yielded much, no longer covered the globe, which had protruded to a distance equal to its natural diameter. A grayish silvery substance, seen through the cornea, seemed to occupy the anterior part of the posterior chamber of the eye, and to incline forward, pushing the iris before it, so as to threaten to rupture the upper part of the cornea. I believed it to be the chrySTALLINE lens, rendered slightly opaque by inflammation, consequent to the pressure of a tumour, and by the same cause displaced anteriorly. With a cornea knife, introduced behind the ciliary ligament, brought out at the opposite point, and made to divide half the circumference of the cornea, the lens and all the humours of the eye were evacuated; the lens was perfectly transparent. A tumour protruded through the left nostril, beyond the septum, inclined to the

right side; the upper lip was excoriated; the velum pendulum palati seemed to be pushed forward; the parotid and submaxillary glands were swollen.

The accompanying plate, No. 1, exhibits a very accurate view of the parts on the 23d of April. The retina of the right eye is dilated, but otherwise natural. The diameter of the tumour was judged to be equal to two inches. It is moderately soft, and not very sensible to the touch.

5th May.—The right eye has lost its power of vision; the pupil has become dilated, as was the case with the other eye, and a grayish silvery body is seen. Some difficulty of respiration is experienced, especially in a recumbent posture. The tumour in the nose and that from the orbit have bled several times, to the amount of half an ounce.

On the 9th the child became unable to breathe while lying down; and on the 13th it expired, without exhibiting evidences of great pain, though greatly emaciated and exhausted.

Immediately after death, the tumour shrunk considerably, and lost its florid colour. It was removed in the same manner as in the preceding case, the friends not being willing to permit an examination of its connexion with the internal parts of the head. The consistence of this tumour was by no means so great as that

of the black woman, and it communicated to the hand the same soapy feel as the medulla of the brain,—more especially that part of it which lay within the orbit. The texture of the eye was totally disorganized. Small portions of the bones of the orbit face adhered to it. An opening through the lower and inner part of the orbit had afforded a passage for the adjacent portion of tumour into the left septum nasi. Except in the circumstances above stated, the organization of the tumour was similar to that of the black woman.



CASE III.

I WAS requested by the physician of the Alms-House, to visit a middle aged woman, who had suffered several years from a tumour proceeding from the left orbit. It had destroyed vision in the corresponding eye. The size of the tumour was less than that of a pullet's egg. A portion of it had been separated by the sloughing process. It was not particularly painful. The external appearances were very similar to those in the case of Isabella Jackson. An operation was proposed, but deferred on account of the patient's pregnancy. This was happily terminated about four

months afterwards. She nursed her child six months, then weaned it, and underwent an operation for the removal of the tumour, which had in the mean time increased in magnitude about one half: the operation was performed by Dr. B. H. Akerly.

Dissection of the tumour.—Beneath the external portion of the tumour, it did not present the purple spots formed by a congeries of vessels, and resembling a part of an animal severely bruized immediately before its death, as did that of Jackson. But the mass of it consisted of the same custard-like substance. In the posterior part were two coagula of blood, about the size of a hazelnut: the membranes of the eye were distinct. Of the pigmentum nigrum, or some similar black substance, the product of disease, an unusual quantity existed, not only on the retina and contiguous parts, but within the optic nerve to an extent of $\frac{3}{4}$ of an inch from its termination. In other respects this nerve appeared natural.

No untoward circumstance occurred, and the woman enjoyed tolerable health for six months. During the latter part of this period, however, a small moveable tumour, free from discolouration and pain, formed just below the inner edge of the orbit of the left eye. The poor creature's health became gradually worse: she became emaciated, and her countenance assumed a leaden co-

lour. She was not hectic, but suffered from the usual symptoms of cancerous cachexia. Tumours agreeing in external character with that on her face, formed in the axilla and groin. They acquired a prodigious size previous to her death, which occurred eight months after the operation.

From these gloomy details not one ray of consolation can be derived. The occurrence of disease in parts distant from the primary affection, in the two last cases, is too remarkable to pass without notice. It naturally tends to the conclusion that the disease is not local, and offers a strong inducement to the surgeon to limit his views to the smoothing of the avenues to the grave, from which he can neither free nor respite his unhappy patient*.

It will appear evident from the foregoing cases, that *Fungus Hematodes* affects the eye under different forms. The same is true of cancer. Not having met with any attempt to classify these affections, I would offer the following:—

Fungus Hematodes. 1st species.—The eye-ball is smooth, covered by its conjunctiva: the tu-

* In each of these cases the disease was in the left side. Was this accidental?

mour is smooth, and not ulcerated—exemplified in Case II. 2d species.—The surface of the tumour is tuberculated; its edges reverted; its most prominent part is covered with dark livid spots, partially concealed by the dried secretion of the surface—exemplified in Case I.

Cancer. 1st species.—Cauliflower excrescence with reverted edges, arising from the conjunctiva; if carefully examined, its base will be found small. This tumour may be successfully amputated in most instances. 2d species.—Cancerous affection originating near the eye, and extending to it.