

RANDALL (B. A.)

[Reprinted from the Transactions of the College of Physicians of Philadelphia, 1890.]

THE CORROSION METHOD IN THE STUDY OF THE ANATOMY OF THE EAR.

By B. ALEXANDER RANDALL, M.D.,

PROFESSOR OF DISEASES OF THE EAR IN THE PHILADELPHIA POLYCLINIC, ETC.

[Read November 5, 1890.]

THE method of filling the cavities of an organ with a congealing mass and then corroding away its tissues to leave free the cast thus formed, has been long and profitably employed by anatomists; and most beautiful and instructive preparations have been thus gained. Various drawbacks and difficulties have limited its application, however, and the number of fine results by the older methods which may now be found in the museums is not great. Following the lead of Lieberkuhn, Meckel, and others, Hyrtl made especial use of the method, and a fine series of his casts in wax is preserved in the Mütter Museum. He modified the injection-mass so as to free it from much of the crumbling fragility which had brought to nought most of the finest work of his predecessors, and gave the casts a protective coating which has greatly increased their durability. Yet only by scrupulous care and preservation under glass can such preparations be kept intact; they must be perfectly supported, lest even at ordinary temperatures they should become distorted by bending of the material of which they are composed. Their delicacy is not as great as may be obtained in metal, and the protective coating somewhat obscures and falsifies the finer details.

The ear, with its elaborate intricacy, is one of the organs in which the method can be most advantageously employed; and



while much was done in its study in this manner by Hyrtl, who used the procedure for comparative as well as human anatomy, as the specimens in the Mütter Museum show, it was by Bezold, of Munich, whose valuable brochure was published in 1882, that the subject received its fullest elaboration. Yet the method with wax masses was but a step toward the attainment of the best results; and the return to the use of fusible metal and the improvement of the *technique* have furnished casts far more delicate, yet durable, than were before obtainable. A number of excellent casts made in metal by Dr. Góddard, in 1831, and by Horner a little later, are preserved in the museum of the University of Pennsylvania, so the credit of first successfully employing metal belongs, perhaps, on this side of the Atlantic. Yet much credit for the recent advances is due to Siebenmann, of Basle, who presented exquisite examples of his work at the International Otological Congress at its meeting in Brussels in 1888, and has since published an elaborate monograph upon the revelations thus made in the internal ear.

The writer was much impressed with the beauty of Siebenmann's specimens, which he then studied with the greatest interest, and at once made preparations to follow his example; but press of other work and lack of adequate material have long delayed the undertaking, and the preparations now presented form only a beginning of the series planned. It is hoped, however, that they will serve to bring the method into deserved notice, and that others will find how invaluable an aid it can be to them, and will widen its applications to many other fields. Surely in America, where perhaps fusible metal was first thus employed with success, it ought to yield results second to none elsewhere obtained.

It is hardly necessary to point out that in this instance, contrary to what obtains in vascular injection-preparations, the results gained are negatives, which represent the cavities, not the structures, of the organs, and need for their full comprehension to be supplemented by preparations of the structures themselves. The important point is that they furnish tangible

expressions of the details that are otherwise hardest to grasp; and as illustrating the value of such negatives, I can refer to the magnificent series of preparations by a similar, but far more difficult and tedious, method with which Dr. Piersol captivated the Anatomical Congress in Würzburg some three years ago. The specimens presented will also, it is hoped, speak for themselves; and while revealing many defects, as well as wide gaps in the series necessary for an adequate demonstration of the subject, will also show points that are somewhat new.

The essentials of the method are well known, but its minute details are noteworthy, since upon these refinements depend the perfection of the modern results. The preliminaries vary with the organ to be moulded. If a macerated bone, such as the temporal, it is thoroughly dried and cleaned, and inclosed in linen so pasted on as to bridge the sulcus of the lateral sinus and other grooves and to close all openings except the distal end of the carotid canal, into which a long paper funnel is glued. The whole is then embedded in a large block of plaster-of-Paris, is thoroughly dried for several days, and then warmed to about 200° F. Wood's metal—a fusible alloy melting at about 150° F.—is melted upon a water-bath and poured into the funnel in a full stream until the level ceases to sink. Quick cooling in water is followed by the removal of the plaster and linen envelopes, and the preparation is placed in a warm ten-per-cent. solution of caustic potash. Disintegration of the bone rapidly proceeds, and will be largely accomplished in about two weeks. The older method of picking away the remaining calcareous masses is too dangerous for the delicate portions of the cast, and is to be wholly avoided. The preparation, after washing, is to be placed in a cold ten-per-cent. solution of muriatic acid, which dissolves away the lime particles without injury to the metal beyond an occasional tarnishing, and even this may be avoided by coldness of the solution and the exclusion of daylight. Return to the alkaline solution may be needed to complete the corrosion; the most rapid results being gained by frequent alternation.

The specimen is finally given a prolonged washing in running water, superfluous metal is sawed or filed away, and the cast is mounted for preservation. While the material is fairly strong and possessed of some flexibility and elasticity, careful handling is essential to the preservation of the extremely fine details which it is capable of reproducing, and my specimens already show numerous fractures as the result of rough treatment.

In preparations of the soft parts, injection with the syringe may be sometimes needed, since it is not easy to warm the organ sufficiently to facilitate free flow of the metal without undue drying or maceration; and the closure of the few openings may be readily accomplished without the elaborate embedding. Putty or modelling clay, or even a cold, damp cloth will generally suffice to prevent the escape of the metal when it appears; and until it has thoroughly penetrated, the openings should remain free as exits for the air or fluid filling the cavities. For the lungs, or other closed organs, the whole preparation may be immersed in boiling water, and by prolonged action the air displaced by the metal, even in the alveoli.

Some remarks as to the specimens presented seem in place. They have been obtained both from the recent cadaver and from the macerated temporal bone. As to the former, my only material has been the head of a child, left forgotten for six months in Müller's fluid, and apparently in very bad condition when freed from the thick layer of mould which covered it. Casts were made by pouring the metal into both external auditory canals; but, as they seemed to have failed, an effort was made to withdraw them and repeat the procedure. By the exercise of all the traction which I was able to exert through a strong loop of cords, the cast was extracted from the left canal; but on the right, although quite movable as it lay *in situ*, the cast could not be dragged out, and broke short off at the isthmus. The left drum-head was found to have been well moulded (Fig. 2), and through a perforation in its upper posterior portion the metal had penetrated into the tympanum,

FIG. 1.

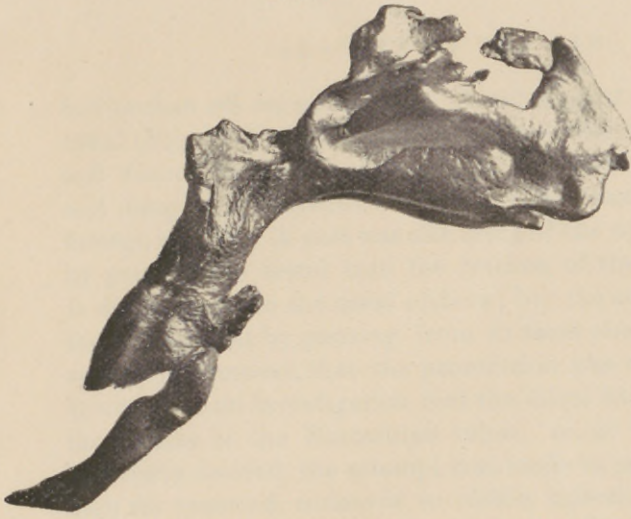

FIG. 2.



FIG. 3.

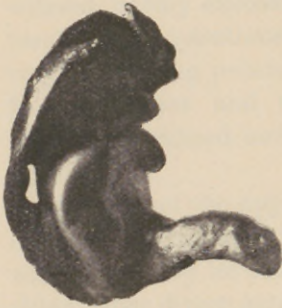

FIG. 4.

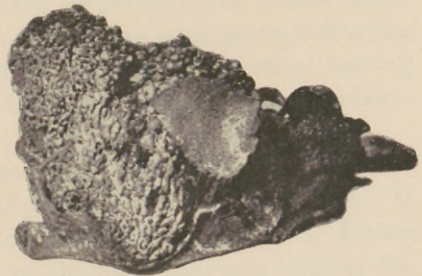
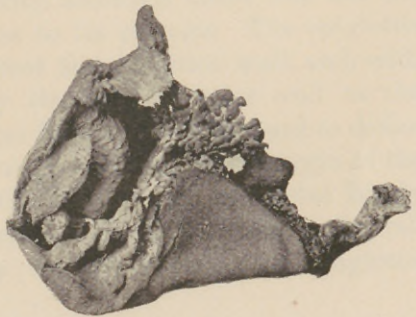


FIG. 5.

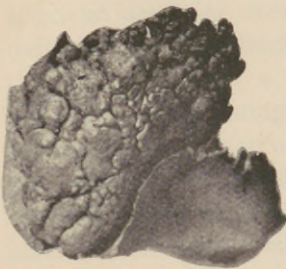

FIG. 6.



but broken off on extraction. A subsequent cast of the same canal (Fig. 3) shows that grave violence had been done to the soft tissues, and gives additional evidence as to the difficulties and dangers of extraction efforts for the removal of impacted foreign bodies. A cast was also made of the upper air-passages by pouring the metal into the trachea of the inverted head. It did not pass to the nasal orifices; but the attempt to supplement the result by pouring from in front showed, as does the cast upon removal, that the penetration was really very good. It was seen on investigation that the metal had hardly entered the orifices of the Eustachian tubes; so, as these casts were especially desired, the attempt was made to preserve the specimen for renewed endeavor to obtain injections of the tubes. The head was sawn asunder, and the specimen removed without corrosion—a decided mistake, as several fractures bear witness, hardly excusable even in my dearth of material. The resulting preparations are very imperfect, yet reveal some very interesting points. The metal was later poured into the frontal sinuses and the antra of Highmore—none having previously gained entrance through the very narrow infundibulum.

The cast of the upper air-passages (Fig. 1) is, probably, the most interesting and practically valuable in its teachings. It will be seen by its examination that not only are the Eustachian tubes direct extensions of the naso-pharynx, linking the tympana into direct continuity with it; but that, on the other hand, the mouth is not legitimately an air-passage at all. Poured freely into the trachea, the metal had almost no tendency to enter the oral cavity, although there was not the slightest artificial obstruction to its passage. The epiglottis deflected the flow back against the posterior wall, and, with the uvula, formed a nearly complete anterior wall to the pharynx. Only enough metal found its way forward to define the location and size of the uvula and the lower margin of the soft palate. The glottis, with the laryngeal ventricles faintly marked above it; the pharynx, with its granular back wall and its anterior limitation by the meeting of epiglottis

and uvula; the posterior nares, with the fossæ of Rosenmüller, the large pharyngeal tonsil, and the slit-like Eustachian tube mouths; the nares, with good impressions of the three turbinal bodies—these, and many points of minor importance, are fairly well shown. The specimen gives promise of far more beautiful and probably instructive results under more favorable circumstances; and it shall be my earnest endeavor to obtain a cast showing in one continuous mass all of this, together with the tubes, tympana, mastoid cells, and the accessory sinuses of the nose—a complete and tangible demonstration of the essential relation of aural and nasal disease.

The remainder of my preparations are casts of the macerated temporal bone in infant and adult life, none of them quite perfect, yet each showing some point of beauty or anatomical importance. The extreme variations in the extent to which the mastoid is occupied by pneumatic cells is well illustrated—one of the finest casts (Fig. 4) showing only a few such cells continuous with the tympanum, while its remainder is of diploic structure; another (Fig. 5), a mass so dense and full as naturally to raise a question as to where there was any room for bony walls and septa. Still another (Fig. 6) answers, in great part, the objection which might be urged against this method of study as contrasted with that by sections, in cases where pathological process is present. A single chain of pneumatic cells reaches down to the tip of the process, while the rest of the mastoid is vacant, except for some still undissolved calcareous masses. This is from a case of inflammatory sclerosis of the bone, where the entire mastoid was converted into a solid eburnated mass, which the corrosion showed to consist of hypertrophied septa inclosing still more compact and almost structureless nodules. Much can be learned as to the structure and density of the bone by thus watching the progress of the corrosion; and under proper precautions it is probable that the method can furnish evidence, distinct though negative, where sections would leave the question of the mastoid condition still in doubt.

Of the casts of the bony labyrinth it is hardly necessary to

speak; for, while they probably surpass any which I have seen, they fall decidedly short of the exquisite delicacy which is revealed by some of the recent results figured by Siebenmann. They are offered simply as the first attempts of a beginner, and their shortcomings are due rather to blunders and defective material than to the method which they but imperfectly illustrate. It is significant to note that such experts as Bezold speak of frequent failures by the wax-mass injection, while their highest successes hardly attain the beauty, and fall far short of the durability, of those here presented.

