

Veasey (C. A.)

al

**Binasal Hemianopsia, with the  
Report of an Additional Case.**

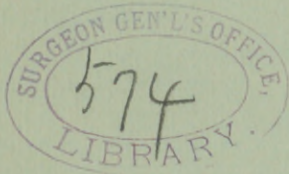
— BY —

CLARENCE A. VEASEY, A. M., M. D.,

PHILADELPHIA, PA.

*Reprint from Ophthalmic Record, February, 1897.*

presented by the author —





\*BINASAL HEMIANOPSIA, WITH THE REPORT OF AN  
ADDITIONAL CASE.

By CLARENCE A VEASEY A.M., M.D.

Adjunct Professor of Diseases of the Eye, Philadelphia Polyclinic; Chief Clinical Assistant to the Ophthalmological Department, Jefferson Medical College Hospital; Consulting Ophthalmologist, Philadelphia Lying-in Charity, etc.

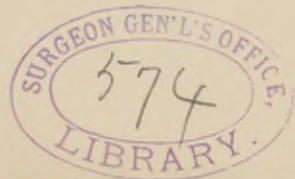Cases of binasal hemianopsia are of such infrequent occurrence that a report of the following may be of interest.

Mrs. L. L., widow, aged 54 years, consulted me concerning the condition of her eyes in April, 1896. She had first noticed that her vision began to fail five months before this time but the failure had been gradual and at no time had there been any severe headache or neuralgia. She recalled that seven months before I saw her she had a spell of nausea and vomiting that lasted about three weeks, the vomiting occurring always in the afternoon or early in the evening and never accompanied by any headache. During this period she sometimes vomited daily; sometimes every second or third day. There was occasionally a slight dull feeling in the temples, or over the brows, but this was never present in the morning. She had had her glasses frequently changed by an optician within a few months but was able to see with each pair for a short time only. Three weeks before consulting me, according to her statement, her eyes suddenly became very much worse as she had been able to do some sewing until this time. When she was first seen there was present the characteristic stare and facial expression of a partially blind person and she complained that there had been some numbness and heaviness in the left leg for two weeks, although an examination at this time failed to show anæsthesia of any portion of the body. There was also some tremor of the head and limbs and occasionally slight vertigo. No family history of syphilis or tumors of any kind could be elicited, and there was no perceptible impairment of memory, speech or hearing.

Examination showed both pupils equal in size,  $6\frac{1}{2}$  millimetres in diameter and reacting to light when reflected directly upon them from the front, to convergence and accommodation though the response was exceedingly sluggish. The bulb was not congested and there were no external evidences of inflammation, although at times there had been attacks of photophobia. The vision of the right eye equalled light perception; that of the left eye equalled  $\frac{1}{10}$  M. The tension was normal in each eye. An ophthalmoscopic examination revealed the following conditions:

O. D. The cornea was clear; the vitreous was filled with cholesterin crystals which moved swiftly about upon each movement of the eye-ball forming the condition known as *synchisis scintillans*. The disc was oval; its edges everywhere veiled. There was a large stellate-shaped arrangement of glistening white streaks and spots surrounding the macula, and a few smaller spots between the macula and the disc. The latter was decidedly pale as seen through the hazy media and there were two small flame-shaped hemorrhages on its surface, one on the upper and inner, the other on the lower and inner quadrant. The arteries were markedly diminished in size, some of them being mere threads, those on the nasal side of the disc being much smaller than those on the temporal side. There

\* Read, by invitation, before the January, 1897, meeting of the Section on Ophthalmology of the College of Physicians of Philadelphia.



were three small hemorrhages down and out from the disc along the course of the inferior temporal vein.

**O. S.** There were no cholesterol crystals in the vitreous but the latter was slightly hazy, the disc oval and very pale. In the macular region there was no such disturbance as existed in the other eye, though a few small buff colored spots were seen in various portions of the fundus. There was a small flame-shaped hemorrhage on the lower outer quadrant of the disc. The arteries were smaller than normal, though not so markedly as in the other eye and those on the nasal side were also smaller than those on the temporal side.

An examination of the urine showed the total quantity passed in 24 hours to be two pints, the specific gravity 1018, the color pale amber, but no albumin, sugar or casts could be found though several specimens were examined.

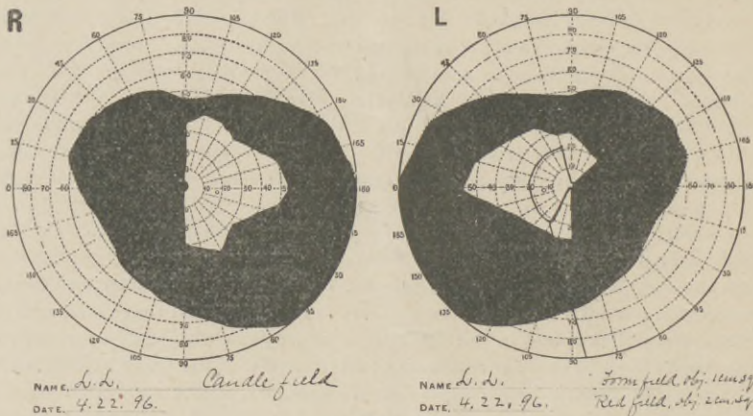


Fig. 1.

The blood examination revealed no parasites but the amount of haemoglobin was only 58% of normal.

The fields of vision, as seen in Fig. 1, showed binasal hemianopsia. That of the right eye was taken with candles, the point of fixation being  $4^{\circ}$  to the temporal side and the macula being included in the blind half. The line of demarcation between the blind and the remaining portion of the field was distinctly vertical. That of the left eye was taken with a grayish-white object, 1 centimeter square, and the preserved portion of the field extended in the upper part, some on the nasal side. The macula was included in the preserved half. The color field for red, taken with an object 2 centimeters square, presented a somewhat different form, being fan shaped, including the macula and here the blind part encroached slightly above and below, on the temporal side. No other color could be recognized. The preserved fields in each eye were concentrically contracted. There were no scotomata. Wernicke's hemianopic pupillary inaction was present and the knee jerk was diminished.

Dr. George E. de Schweinitz very kindly saw the case in consultation, and we decided the best treatment to be pursued was to administer mercury in the form of inunctions, to give rapidly increasing doses of potassium iodide and in addition small doses of nitro glycerin.

The patient remained under observation for one month at the expiration of which time the vision of the right eye equalled the counting of fingers at twelve inches excentrically, while that of the left eye equalled  $\frac{2}{40}$  M. Despite the increase in the visual acuity the fields of vision were gradually becoming more and more contracted still preserving their hemianopic shape, as can be seen in Fig. 2. She insisted upon returning to her home in the South, notwithstanding the gravity of her case had been pointed out to her, where she died three weeks later. No autopsy was obtained. but her attending physician wrote me that she was going around in about the same condition as when I saw her until four days before her death. At this time she became extremely nauseated and there were frequent attacks of hard vomiting and severe muscular twitching in various parts of the body. Two days before death she entered a semi-comatose condition which became complete twenty hours before death and during which there were involuntary evacuations of the bowels.

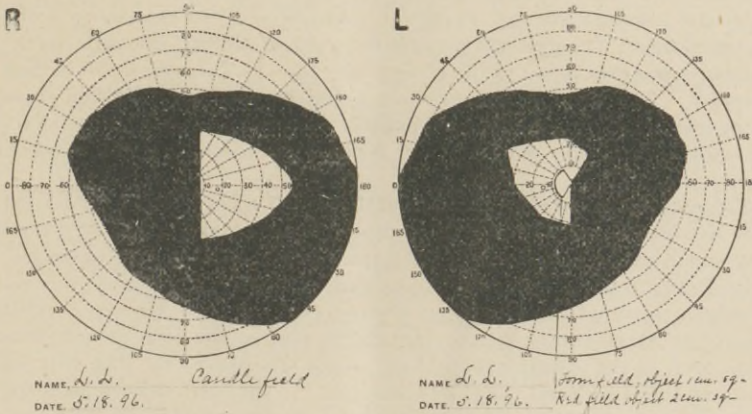


Fig. 2

The literature of binasal hemianopsia has been partially gone over very recently by Fridenberg (1) who added a case to those already recorded.

His patient was a man who eighteen months before consulting him had struck his head in coming up the stairs from a cellar. The blow was severe enough to cause him to stagger but he did not lose consciousness. Six months later he noticed that he could only see "toward the outside". The patient was red-green blind. Ophthalmoscopic examination showed grayish-white discoloration of both discs, without noticeable excavation, and contracted vessels. His hemianopic condition did not improve.

In his paper the author reviews one case that had been reported by von Graefe<sup>2</sup>, four by Mandelstamm,<sup>3</sup> six by Daa,<sup>5</sup> occurring in members of the same family, and two by Knapp,<sup>6</sup> The other recorded cases are one by Schmidt and Wegner<sup>7</sup>, one

by Herschel, <sup>8</sup> one by Ole Bull, <sup>9</sup> one by Eskridge, <sup>10</sup> one by Lang and Beevor, <sup>11</sup> and one by Eales, <sup>12</sup>.

The case recorded by Schmidt and Wegner was a female, aged 23 years. Slight edema of the ankles had existed for one year but prior to this the general health had been excellent. During this year there had developed headache, dizziness and vomiting and there was some disturbance of the visual acuity. The patient was anaemic. An examination of the urine showed the specific gravity to be 1009, the total quantity passed in 24 hours being 2600 c. c., but there was no albumin. Some disturbance of menstruation also existed, this having been regular in all respects up to the beginning of the series of symptoms one year before. The pupils were widely dilated and the reactions sluggish. Ophthalmoscopic examination showed what was presumed to be the typical picture of albuminuric retinitis. The papillæ were swollen, the edges veiled, and there were numerous hemorrhages and whitish spots throughout the fundi. O. D. V. equalled the reading of Jaeger 17 at 5½ inches. O. S. V. equalled the reading of Jaeger 21 at 6 inches. There was binasal hemianopsia and excentric contraction of the remaining portion of each visual field. The case was thought to be one of albuminuric retinitis though no albumin was ever found in the urine at any time. There was no cardiac hypertrophy. The memory and intellect remained good but the vision gradually became less acute. There was an epileptiform attack lasting ten minutes a short time before death, the patient later becoming unconscious and attacked by excessive vomiting.

The autopsy revealed a tumor about the size of a pear situated in the middle of the left ventricle extending to the upper and external portion of the roof of the ventricle and lying loosely on the large ganglia. The optic thalamus was flattened and atrophied. The growth extended into the third ventricle involving the septum lucidum, the fornix and the external layers of the corpus callosum. In the right lateral ventricle from the middle part of the anterior horn down to the entrance of the posterior horn there was a tremulous cyst that very loosely pressed on the large basal ganglia of this side. The latter showed no change in shape, but the anterior corpora quadrigemina was markedly thinned and flattened. The aqueduct of Sylvius was so widely dilated that a large sound could be passed through it. The fourth ventricle was also dilated and the superficial blood vessels, as in the lateral ventricles were larger than normal and contained blood.

The dura mater on both sides was somewhat oedematous. In the optic nerves there was some increase of fibrous tissue and some of the fibers were atrophied. The retinae were swollen and contained numerous irregular ecchymotic spots, none, however, being found in the macular regions. The tumor proved to be a telengiectatic gliosarcoma.

The case of Herschel was a female, aged 30 years, who a short time before had fallen and remained unconscious for awhile. Consciousness returned, however, so that she was able to understand when spoken to and the following day she attended to her housework. From this time on she suffered from periodical pains in the arms and legs which at times were so severe that she was obliged to go to bed. There was also some pain in the head. Sensation and co-ordination were normal. The visual fields showed binasal hemianopsia, the line of demarcation passing vertically through the macula. The pupils reacted promptly and

the ophthalmoscope revealed atrophic discoloration of both discs, especially on the outer halves. O. D. V.  $\frac{2}{20}$ ; O. S. V. equalled  $\frac{1}{60}$ . There was red-green blindness in both eyes. The author assumes that the hemianopsia is due to the apoplectic attack, though not noticed for some time afterwards, the hemorrhage being much greater on the left side. As the patient was exceedingly dull intellectually it was thought that the condition existed immediately after the attack but remained unnoticed until later.

Henschen,<sup>12</sup> records a case in which nasal hemianopsia existed in the right eye, the left being totally blind, where the pathological examination revealed a gummatous exudate surrounding the chiasm, and this to a certain extent is analogous to the case of von Graefe where there was found a gumma extending from the base of the brain into the optic foramina.

Bull's patient was 44 years of age and had been in good health until three years before. Since then had been having headache which increased in intensity. In addition there was great bodily weakness. There was present a congenital defect of the fingers of each hand and the patellar tendon reflexes were absent. The patient swayed when standing with eyes closed, but the gait was not ataxic. Ophthalmoscopic examination showed atrophy on both sides. O. D. V. equalled  $\frac{1}{18}$ ; O. S. V. equalled  $\frac{1}{18}$  (dull day). The green and red were recognised as gray, though red was properly recognised through a glass of this color. Injections of strychnia were employed for a time and the vision was somewhat improved, in O. D. equalling  $\frac{1}{24}$ ; and in O. S. equalling  $\frac{1}{24}$ . This lasted for short time only and the patient became so weak that permanent confinement in bed was necessary, during which time the visual acuity gradually decreased and the visual fields became more and more contracted. Death ensued in a few weeks.

The autopsy revealed nothing abnormal macroscopically. Microscopically the tracts as well as the optic nerves were degenerated, and this degeneration had progressed to a greater degree in the former. In the optic nerves there were no fibers visible peripherally, but there was a bundle found 2 centimeters behind the eyeball, near the middle which was larger on the left side where it amounted to about half the diameter of the normal nerve; on the right being only  $\frac{1}{3}$  or  $\frac{1}{4}$  the normal size. At the same time the trabecular tissue had degenerated peripherally, especially on the temporal sides, In each tract there was found a small bundle of preserved nerve fibers, much smaller in circumference than the bundle in the nerves, and these were situated, not in the centre, but peripherally. The author thinks that these bundles correspond with the bundles in the nerves themselves and concludes from this that the macular bundle does not lie, as some observers claim, in the middle of the tract.

The same author states that he has observed two incomplete cases, both with disease of the spinal cord.

The case of Eskridge was a male Swede, aged twenty-three years, whose occupation was that of a track-walker. He had suffered from headache off and on for nine months, and for two months before the examination had very severe attacks, lasting for more than a week at a time, preventing sleep, and occasionally being accompanied by a vomiting spell that occurred usually in the morning. It was understood that a short time before he had been unable to walk or stand without assistance but after taking large doses of potassium iodide and mercuric bichloride he had been greatly improved.

The vision of O. D. equalled faint object perception on the temporal side, the nasal side being blind. The pupil was widely dilated and the ophthalmoscope showed marked papillitis, with narrowing of the arteries, distended veins and abundant exudate which completely covered most of the vessels as they passed over the disc. The swelling was about 7 dioptries. Vision O. S. equalled faint light perception on the temporal side, the nasal side being blind. The pupil was about the same size, or a little larger than the right. Ophthalmoscopic examination showed marked papillitis and beginning atrophy, with arteries very small and veins less distended than in the right eye, and considerable exudate, the swelling being equivalent to 6 dioptries. Wernicke's hemianopic pupillary inaction was present.

The patient continued rational most of the time preceding his death which occurred about six months after the examination was made. For a few weeks before this occurred there had been noticed dysphagia, weakness of the entire body, almost continuous bleeding from the gums, congestion of the left eye, and marked retraction of the head. He first lost control of the sphincters of the bladder and rectum during the night, but for two months before death the loss of control existed during the day as well.

The autopsy showed a tumor in the left lobe of the cerebellum, which had extended forward and toward the median line, and evidently before death had exerted pressure upon the pons and medulla. The pia surrounding the optic chiasm was greatly thickened, and had pressed upon the optic nerve and chiasm. The tumor was encapsulated, and proved to be a gliosarcoma."

Lang and Beever's case was a female, aged 33 years. The vision had been failing for two years and she had been unable to read for eight months. For several weeks there had been rheumatic pains in the legs.

The patient could not walk toe and heel along a straight line. No incoordination in the hands. The sphincters were not affected and the knee jerk was absent. The pupils would not react to light but did react to accommodation. Movements of the eyeball were normal; O. D. V. equalled  $\frac{5}{2}$ ; O. S. V. equalled  $\frac{5}{6}$ . There was optic atrophy of both discs, binasal hemianopsia and the patient was red-green blind.

The vision gradually became worse.

The case recorded by Eales more resembles my own case than any of the others.

A male, aged seventy-five years, had been having gradual failure of vision for eighteen months following a long period of ill-health. There had also been failure of hearing for two years. There was no history of syphilis, and there had been no headache or vomiting. The vision of O. D. equalled  $\frac{5}{8}$ ; that of O. S. equalled  $\frac{1}{2}$ , with + S. 1 D. Both discs were filled in and presented a grayish yellow appearance. There was loss of definition of the margins as if an interstitial neuritis of a chronic, not very severe type had been going on for some time. There was no swelling, the retinal vessels were practically normal, and around each disc there was an irregular ring of choroidal atrophy confined to the superficial layers. The optic nerves showed no evident signs of atrophy. A mitral systolic murmur and a chronic cystitis were found to exist. An examination of the ears revealed disease of the labyrinth. The visual fields showed binasal hemianopsia a large portion of the upper part of the temporal half being included



in the blind half. Wernicke's hemianopic pupillary inaction was present in both eyes. The patient received treatment for two months, during which time the visual acuity improved somewhat and the visual fields gradually grew smaller. There was some concentric contraction of the temporal fields from the beginning but this steadily increased.

In commenting upon this case Gowers says "The case suggests to me a bilateral inflammation of the trunks of the optic nerves in front of the chiasma, extending to this, and chiefly intense symmetrically at each side of the chiasma. The symmetry of interstitial inflammation in the nerves and nerve-centres is remarkable. I think that nasal hemianopsia has never been due to disease behind the chiasma, and I cannot conceive that it could be thus produced. That the disease is there is strongly supported by the extension of the loss across the middle line above, while the fact that this extension is greater on one side is what we should expect since inflammation, although symmetrical, is seldom exactly so.

The progressive diminution in the field is what would be expected from cicatricial contraction of the new tissues—it is quite unlike the effects of a growing tumor."

These remarks from so eminent a neurologist, seem to me to apply equally well to my own case so that further extended comment is unnecessary.

It is interesting to note, however, that in my case the macular region in the right eye was included in the blind portion of the field, while in the left eye it was included in the preserved portion, a circumstance which it seems to me would indicate that on the right side the inflammation had extended sufficiently far to involve the macular fasciculus while on the left, the latter had not yet become attacked, a view further supported by the fact that in the right eye the line of demarcation between the preserved and blind portions of the field was a vertical line while in the left eye this was not the case, a small portion of the preserved field extending beyond the median line into the nasal portion thus showing that a few of the fibers supplying the temporal side of the left retina were yet uninvolved.

#### BIBLIOGRAPHY.

1. P Fridenberg. A Case of Binasal Hemianopsia Following Cranial Traumatism, New York Eye and Ear Infirmary Reports, January, 1896, Vol. IV., Pt. 1. (One case.)
2. A. von Graefes, Ueber die Untersuchung des Gesichtsfeldes bei amblyopischen Affectionen. Archiv f. Ophthalmol. II. 2 p 87. (One case.)
3. E. Mandelstamm. Klin. Beobacht. 1866, Vol. III. p. 70, (Two cases)

4. E. Mandelstamm. Ueber Sehnervenkreuzung und Hemiopie. *Archiv f. Ophthalmol*, XIX, 2, p. 39. (Two cases.)
5. A. Daa. Hemiopi Det 6 Tilfaelde i samme Slaegt (Case of hemianopsia the sixth in the same family.) *Norsk. Magazin f. Lægevidenskab*, Bd. 23., p. 615. (Six cases.)
6. H. Knapp. Hemiopic and sector-like defects in the field of vision and their connection with diseases of the heart and brain. *Brown-Sequard's Archives of Scientific and Practical Medicine*, p. 293-310. New York, 1873. (Two cases.)
7. Schmidt u Wegner: Aehnlichkeit der Neuro retinitis bei Hirntumor und Morbus Brightii. *Archiv f. Ophthalmol* XV., 3. (One case.)
8. Herschel. Hemianopsia Nasalis. *Deutsche med. Wochenschr.* 1883 (One case.)
9. Ole Bull. *Perimetrie*, 1895 p. 191. (One case.)
10. J. T. Eskridge: Tumor of the Brain with Double Nasal Hemianopsia. *International Clinics*, Vol I., Sixth series, p. 176 (One case.)
11. Lang and Beevor. Binasal Hemianopsia in a case of Tabes Dorsalis. *Trans Ophthal Soc., Unit King.* 1894, p. 246.
12. Eales. A Case of Binasal Hemianopsia. *The Ophthalmic Review*, Vol. XIV., July. 1895, p. 203. (One case.)
13. Henschen. *Klinische und anatomische Beitrage zur Pathologie des Gehirns*, Upsula, 1890-1895.

CLARENCE A VEASEY, A. M., M. D.,

47 N. 17th St., Philadelphia, Pa.

FEBRUARY 1897.

••• THE •••

# OPHTHALMIC RECORD

EDITED BY

GEO. E. DE SCHWEINITZ, M. D.  
Philadelphia.

F. C. HOTZ, M. D.  
Chicago.

G. C. SAVAGE, M. D.  
Nashville.

H. V. WÜRDEMANN, M. D.  
Milwaukee.

CASEY A. WOOD, M. D.  
Chicago.

W. E. HOPKINS, M. D.  
San Francisco.

JOHN E. WEEKS, M. D.  
New York.

HAROLD GIFFORD, M. D.  
Omaha.

---

T. A. WOODRUFF, M. D.  
Editorial Secretary.

1102 Reliance Building, Chicago, Illinois.

---

PUBLISHED MONTHLY. \$3.00 per annum, in advance;  
Great Britain, 14 Shillings.

---

L. D. PIERCE, Publisher,  
214 South Clark Street, Chicago.

