

PHELPS (A. M.)

A NEW OPERATION
FOR HERNIA.

BY

A. M. PHELPS, M. D.,

Professor of Orthopædic Surgery in the University of the City
of New York and the New York Post-Graduate Medical
School and Hospital; Professor of Surgery in the
University of Vermont; Surgeon to the City
Hospital; President of the American
Orthopædic Association.

REPRINTED FROM THE
New York Medical Journal
for September 8, 1894.



*Reprinted from the New York Medical Journal
for September 8, 1894.*

A NEW OPERATION FOR HERNIA.*

BY A. M. PHELPS, M. D.,

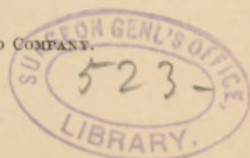
PROFESSOR OF ORTHOPÆDIC SURGERY
IN THE UNIVERSITY OF THE CITY OF NEW YORK AND
THE NEW YORK POST-GRADUATE MEDICAL SCHOOL AND HOSPITAL;
PROFESSOR OF SURGERY IN THE UNIVERSITY OF VERMONT;
SURGEON TO THE CITY HOSPITAL;
PRESIDENT OF THE AMERICAN ORTHOPÆDIC ASSOCIATION.

RELAPSE in oblique hernia takes place at the internal abdominal ring. The external abdominal ring and the abdominal parietes between the external and internal rings may be ever so well closed, yet if the internal abdominal ring has not been fortified and well secured, relapse will quite likely occur.

And then again, if the internal abdominal ring has been well fortified and the canal between the external and internal abdominal rings improperly closed, a relapse is almost sure to result. Therefore I am of the opinion that our efforts in hernia to prevent relapse should be directed particularly to the internal abdominal ring, for the purpose of as strongly fortifying and adding to the strength of this portion of the inguinal canal as is possible.

* Read before the Section in Surgery of the New York Academy of Medicine, April, 1894.

COPYRIGHT, 1894 BY D. APPLETON AND COMPANY.



Secondly, the total obliteration of the inguinal canal, and thirdly, the formation of an artificial inguinal canal for the cord external to the muscles. These are the important points in the method which I have followed in the operative treatment of hernia.

It is to these points that I more particularly wish to call your attention this evening. It is a fact that the operations for hernia which have been industriously followed by our best surgeons in the past have resulted, in a very large percentage of the cases, in lamentable failures. These failures have been more noticeable in the hernias attended with large openings in the abdominal wall, and in my opinion they can always be traced to improperly fortifying the internal abdominal ring; failure to obliterate the inguinal canal and change the course of the cord; and, in large hernias with large openings in the abdominal wall, the failure to fortify these openings either by properly stitching together the tissues *or introducing between the tissues a foreign body which would become encysted*, thereby adding to the strength of the abdominal walls over the opening.

To carry out these ideas so far as possible and correct the errors that have led to failures, I have come to the conclusion that the following methods should be adopted:

A long incision should be made, extending at least two inches beyond the internal ring, through the muscles down to the transversalis fascia. The sac should be opened and the intestine replaced. In the thin sac the suture should be passed with a needle around its neck like the puckering string of a pouch, and two thirds of the sac, or a little more, cut away, the stump inverted with forceps into the abdominal cavity, and the ligature tightened. This secures the stump within the abdominal cavity and prevents dimpling of the peritonæum. A single stitch or two across the neck of the sac is now necessary. The muscles should be care-

fully dissected up from the transversalis fascia a distance of an inch and a half either way from the internal ring. The internal ring is a hole in the transversalis fascia. This hole is enlarged by the pressure of the intestine. In order to sew up this internal ring the edges of the fascia should be denuded, and then for half an inch to an inch on either side of the ring two parallel longitudinal incisions should be made (or, in cases where the fascia is thick and adherent to the sac, it can be included with the ligature and inverted with the sac into the abdominal cavity). It will then be easy to bring the fasciæ together over the stump. The fascia should be stitched with interrupted fine wire sutures. Over this fascia should be placed loops of silver wire if the opening is large. The silver wire should be knotted in several places to prevent slipping. Four or five of these loops, two to three inches in length, will suffice. The cord should be raised from the canal and the loops passed underneath the cord from the internal to the external abdominal ring. Over these loops of silver wire or catgut the transversalis muscle is carefully stitched with interrupted sutures, the cord being brought through the muscle direct. The first layer of wire or catgut should run transverse to the inguinal canal. Over the transversalis muscle another layer of wire loops is passed, extending at right angles to the deeper layer between the transversalis fascia and the internal oblique. Each one of these loops of wire is stitched to the muscle to prevent it from slipping. Over this layer of wire the internal oblique is carefully stitched with interrupted sutures. The cord should be brought through the internal oblique muscle. The external oblique is stitched together, and if there is a thick layer of superficial fat of two or more inches, the wound is dressed open; if there is but little adipose tissue, the wound is closed. A small drainage tube or two strands of catgut should be

inserted down into the sac when the sac has been inverted into the abdominal cavity; but when the sac has been cut away a few strands of catgut passing to the deeper layers of muscle will suffice for drainage.

Dressings should be performed at the end of the third day. Usually but little tumefaction is seen, and thus far I have seen no suppuration. In those cases of thick, large sacs which have been inverted into the abdominal cavity (the second method of dealing with the sac), and puckered together by means of the silk ligature (see Figs. 11, 12, 13, etc.), it is necessary to introduce a small drainage tube or strands of catgut to the bottom of the cavity, which drainage tube should be removed at the end of three days. In these cases, the sac should be thoroughly scarified on its peritoneal surface. This will stimulate adhesions to the abdominal peritonæum. In cases where a thick, large sac is drawn up behind the peritonæum (see Figs. 19, 20), by means of a catgut ligature (the third method of dealing with the sac), a drainage tube or strands of catgut should be inserted in this sac for two or three days, and the scarification of the peritoneal surface before the sac is stitched up, and before its introduction into the abdominal cavity, should be very thorough and extensive. Adhesions will then rapidly form between the sac and the abdominal peritonæum. It is very easy to pass a ligature from within this large sac to the small opening which has been made in the abdominal cavity above. The incision in the sac before its introduction into the abdominal cavity should always be closed by means of catgut sutures. The mouth of the sac should be stitched together with one or two interrupted sutures, not sufficient to cut off the circulation of the sac. When the sac is treated in this manner, the wound is treated precisely as has already been described.

I have devised a curved cannula and needle to pass the catgut ligature through the abdominal walls from within the peritoneal cavity out, thus avoiding an incision and saving time. It is a long curved needle inside of a curved cannula carrying the catgut.

I will now briefly explain the illustrations which are appended to this paper.

Fig. 1 shows the position of an oblique inguinal hernia.

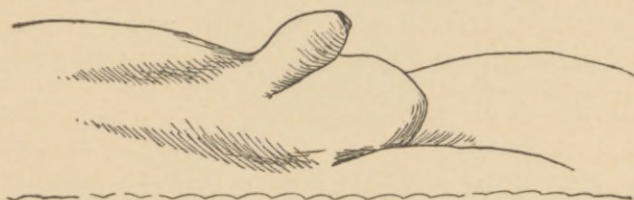


FIG. 1.

Fig. 2, an incision which has been made over this tumor—the sac being in full view. This is the usual in-

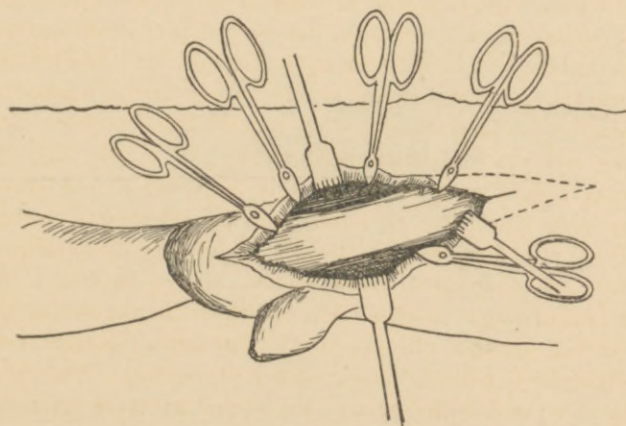


FIG. 2.

cision made. The dotted lines in Figs. 3, 4, and 5 represent the incision as I make it.

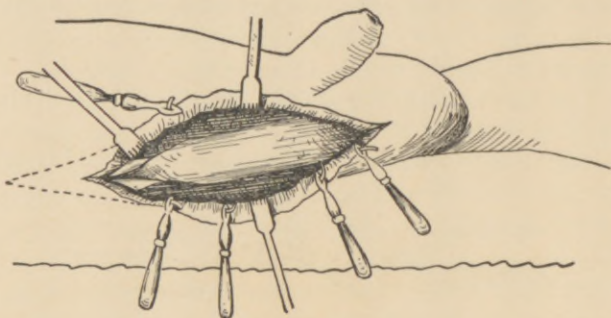


FIG. 3.

Fig. 3 shows the canal split up to the internal abdominal ring in the ordinary operation. This incision should be extended as far as the dotted lines, or nearly to the anterior superior spinous process.

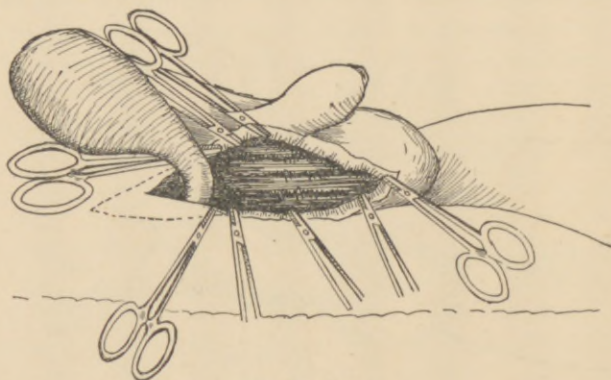


FIG. 4.

Fig. 4 shows the sac raised from its bed to the internal abdominal ring. Now it can be seen that the incision, if

it is extended as far as the dotted lines, will allow the operator plenty of room to perform his work.

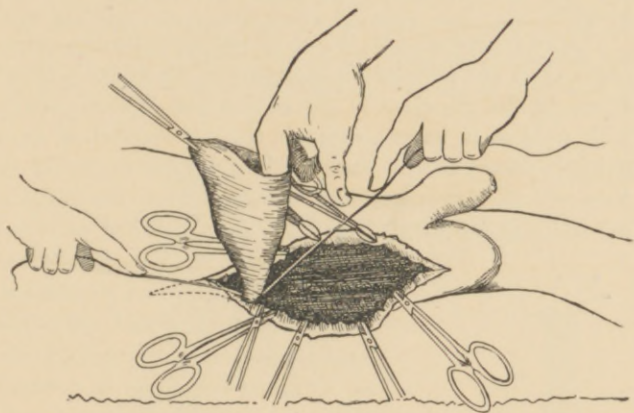


FIG. 5.

Fig. 5 represents the ordinary way of ligating the sac, which I believe to be wrong, because it leaves a dim-

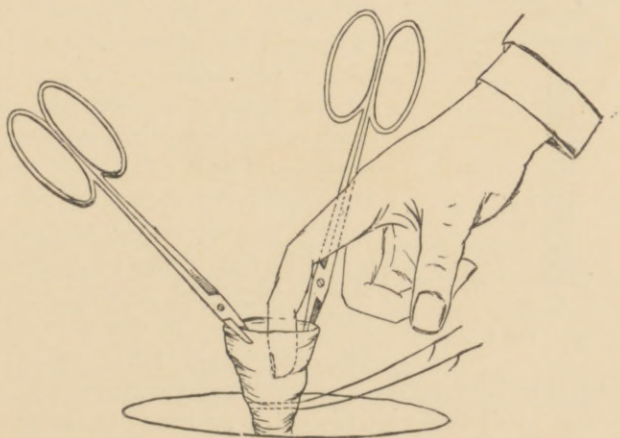


FIG. 6.

pling of the peritonæum, and is not an effective way of dealing with the sac. The following procedure should be adopted.

Fig. 6 represents two thirds of the sac cut away. The edges of it are seized with forceps and the finger is introduced in the sac close to the neck. The ligature, armed with needles, is passed through the sac around it, as a string is passed around the mouth of a purse to pucker it. Now with the forceps the sac is inverted into the abdominal cavity as represented in Fig. 7 (*a*, abdominal parietes;

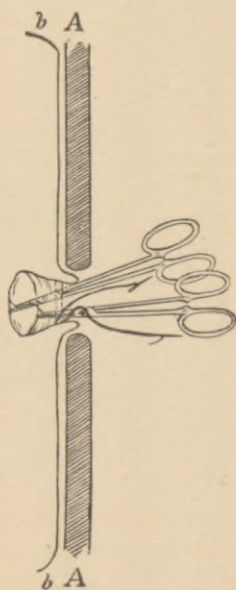


FIG. 7.

b, peritonæum). This brings the ends of the ligature within the sac. These ligatures, armed with the needle, are transfixed through the sac as is shown in Fig. 8, *a*, which brings them externally to the neck of the sac. Now these ligatures are tightened down upon the finger and forceps and gradually the finger the withdrawn as the ligatures are tightened; this prevents the possibility of ligating the intestine. After the ligature has been tied, a stitch is taken across the stump as is seen in Fig. 9, *d*. This is tied firmly, and the stump will then present the appearance as represented in Fig. 10, the peritonæum being straight and the stump projecting into the peritoneal cavity.

The transversalis fascia and abdominal parietes are firmly stitched over the stump. This method of dealing with the sac is applicable to the thin and moderately thickened variety.

The second manner that I have found advantageous in dealing with the sac is represented in Fig. 11. This sac has been opened and the intestine returned to the abdominal cavity, after which the opening is stitched up with catgut. Now a suture armed with needles is passed longi-

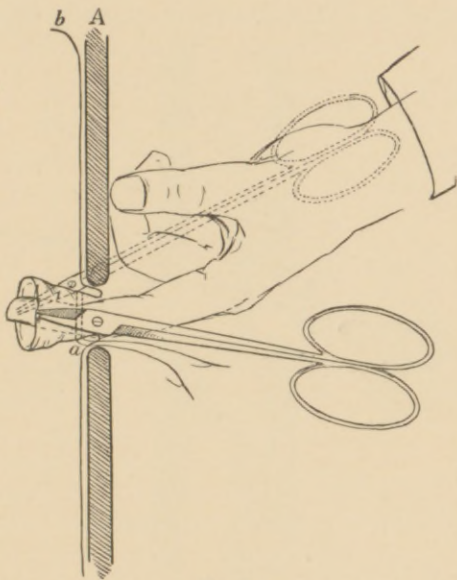


FIG. 8.

tudinally around the sac, threading it in and out like a puckering string. When this ligature is drawn down tightly the sac presents the appearance as seen in Fig. 12. The sac is inverted into the peritoneal cavity as illustrated in Fig. 13. This brings the ligatures on the inside of the sac; they are thrust through the sac as in Fig. 14, *d d*, and tightened and tied across the mouth of the sac as shown in Figs. 15 and 16; another suture or two may be put in across the mouth

of the sac, when it will present the appearance of Fig. 17. Finally the transversalis fascia is stitched together over the sac which has been inverted into the abdominal cavity, as is shown in Fig. 18, and two or three strands of catgut are inserted into the sac for drainage purposes. This man

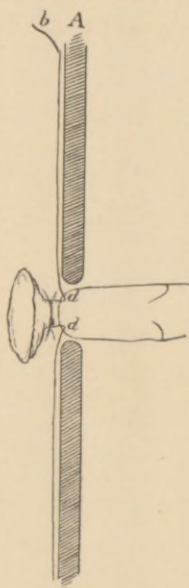


FIG. 9.

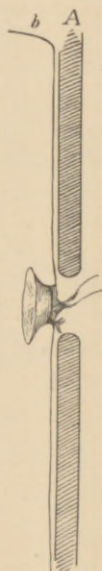

FIG. 10.

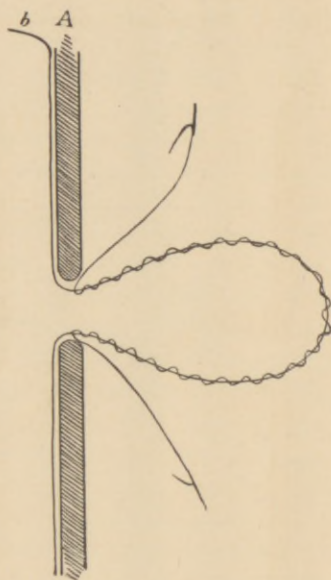


FIG. 11.

ner of dealing with the sac is applicable to the moderately thick and large sacs, and the object is to place within the abdominal cavity a considerable mass of tissue over the part of the weakened abdomen. The manner of sewing up the abdominal ring, which is the hole in the transversalis fascia, will be described a little later.

The third way of dealing with the thick leathery sacs in old hernias is illustrated in Figs. 19 and 20. After the

intestines have been returned to the abdominal cavity the inside of the sac is thoroughly scarified and a catgut ligature is attached to the fundus of the sac (Fig. 19). The opening in the sac which was made to reduce the intestine is now carefully sutured with fine catgut, as in the preceding sac, and upon a probe the end of the ligature is carried upward into the abdominal cavity behind the abdominal parietes as

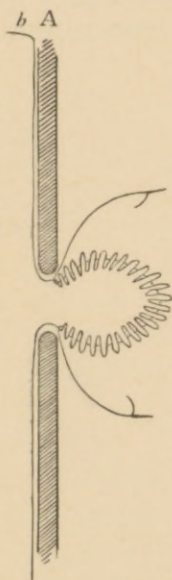


FIG. 12.

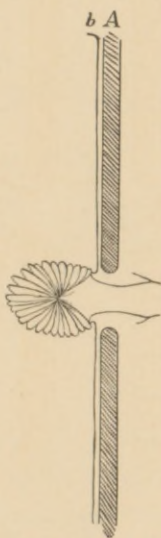


FIG. 13.

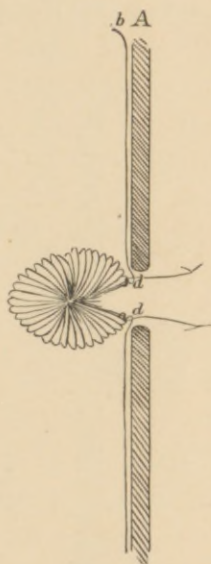


FIG. 14.

far up as the sac is long. At this point, through a small incision, the ligature is drawn out through the opening and the sac inverted into the abdominal cavity and drawn well up behind the abdominal wall. The ligature is attached to a piece of iodoform gauze (see Fig. 20) after being drawn through the small opening. The peritoneal opening is

closed with a single stitch and each one of the muscles is carefully stitched together. The second incision in the ordinary individual need not exceed an inch and a half in length on the surface of the body, and at the peritonæum only the size of the probe. This small incision adds nothing to the hazard of the operation. Finally, a stitch is taken through the neck of the sac, as figured in Fig. 20, *b*. Catgut drainage is inserted into the sac. The sac being well scarified before its inversion into the peritoneal cavity,

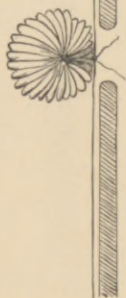b A

FIG. 16.

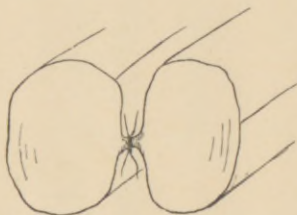


FIG. 15.

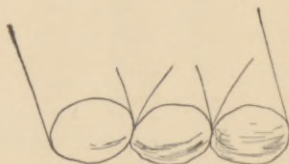

FIG. 17.

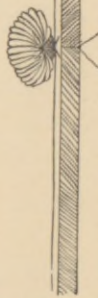
b A

FIG. 18.

at once adheres to the peritonæum, the omentum, and the intestines, the inside of the sac being a raw surface. This forms a large mass of material directly over the weakened point of the abdominal cavity and is a very effective agent in preventing a relapse of hernia.

I have briefly given the method of dealing with these varieties of hernial sacs. In the first the sac is cut away

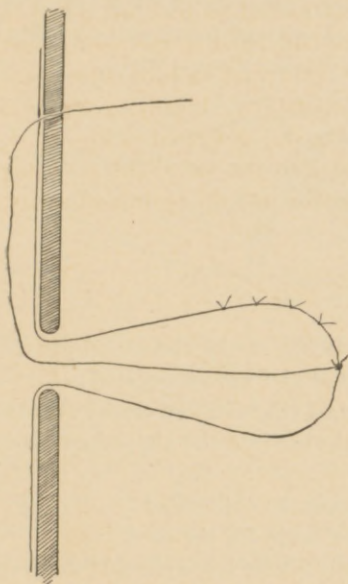


FIG. 19.

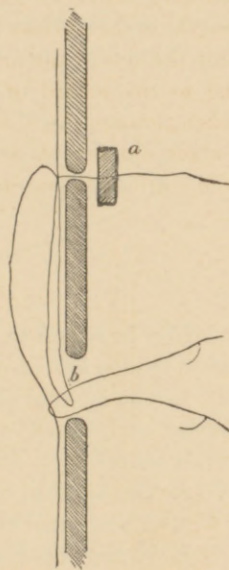


FIG. 20.

and the pedicle ligated in the abdominal cavity. In the second variety of *moderately thickened large sac* it is inverted

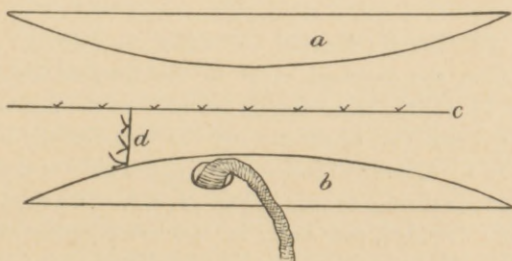


FIG. 21.

into the peritoneal cavity and puckered well down and over the internal abdominal ring. In the third method, *applicable only to the thick, leathery, large variety*, the sac is inverted into the abdominal cavity and drawn well up behind the abdominal wall for the reasons already given.

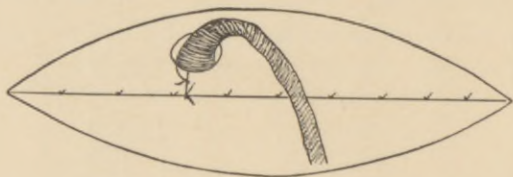


FIG. 22.

Now in regard to the closing of the abdominal parietes after the sac has been treated as I have suggested :

1. The internal abdominal ring must be closed over the stump or inverted with the sac into the abdominal cavity when adherent.

2. The inguinal canal must be obliterated.

3. A new canal must be made for the cord.

4. In large openings, silver-wire loops should be adjusted between the layers of muscles crossing the inguinal canal at right angles, which will be described later.

If these steps are taken and the work is effectively done, the relapses seen after other operations, I believe, will not occur.

1. *To close the internal abdominal ring*, dissect up the cord from the inguinal canal to the internal abdominal ring. Isolate the transversalis fascia from the peritonæum when not adherent to the sac and the transversalis muscle. Make two longitudinal incisions on either side of the internal abdominal ring, as seen in Fig. 21, *a, b*. The ring, which has been denuded, can easily be stitched together at *c*, the cord through an incision can be transferred to the inferior

longitudinal incision. Over the transversalis fascia the transversalis muscle should now be stitched, the cord being brought out directly through the muscle above the line of incision, as seen in Fig. 22. The internal oblique muscle

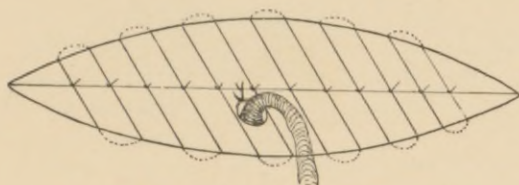


FIG. 23.

is now carefully stitched together and the cord brought directly through that muscle, as is seen in Fig. 23. Finally, the external oblique is stitched together, and if the opening is large in the abdominal wall the cord can be brought through the external oblique, and finally the skin and cellular tissue are stitched over the cord. This forms a new canal for the cord between the external oblique and the skin, and one muscle in this arrangement overlaps the opening in the other.

Now in the large hernias with a large opening in the abdominal cavity, which variety very frequently relapsed from any operation, and in the hernias which have relapsed from other operations, with very large openings in the abdominal walls, I place wire between the layers of muscles in the following manner :

After the transversalis fascia has been stitched together over the stump, loops of silver wire are introduced at right angles to the inguinal canal, between the transversalis fascia and the transversalis muscle, as figured in Fig. 24. The transversalis muscle is now stitched over this layer of wire, the cord brought through the muscle, and another layer of

silver-wire loops is placed between the transversalis muscle and the internal oblique, as illustrated in Fig. 23. This last layer of wire is placed almost at right angles with the first.

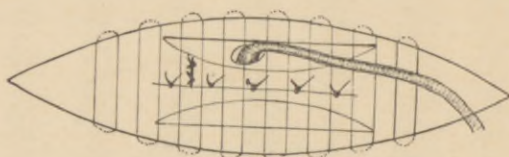


FIG. 24.

The internal oblique is now stitched over these wires and the other tissues are stitched together, as has been already described. These wire loops are fastened in their place, to prevent their slipping during the healing process, with needle sutures. *They are all knotted or run in with loops, to prevent their slipping in the tissues and to more thoroughly facilitate their encysting.* All of the stitching done after the ligation of the sac is with fine wire, with the exception of perhaps the superficial sutures and the needle sutures, to hold the wire loops in place. I have seen no irritation resulting from the use of the wire as I have suggested. When it is introduced into the wound, it comes from an alcohol lamp at a red heat. My conclusions are these:

1. That relapses occurring in hernia are due to the improper way of treating the sac.
2. The use of catgut and other absorbable materials in the closing of the abdominal parietes.
3. The improper treatment of the inguinal canal.
4. The dimpling produced in the peritonæum by the ligation of the sac externally.

To remedy these causes of relapsing in hernia:

1. The sac should always be either cut off and ligated within the peritoneal cavity;

2. Puckered together and inverted into the abdominal cavity ; or

3. Inverted into the abdominal cavity and drawn up well behind the abdominal wall.

4. The inguinal canal entirely obliterated by being stitched up with fine silver wire.

5. Changing the inguinal canal by bringing the cord out through the different layers of muscles at different points, thus making one layer of muscle act as a guard against the opening in the layer underneath.

6. In large openings and in relapsed herniæ, the introduction of wire loops, as already described. *Strangulation of the sac when treated in this manner never occurs, because the circulation is not interfered with.* When the stump of the sac, however, is ligated in the peritoneal cavity, it unites with the adjacent tissue precisely as the stump does following an ovariectomy.

I have seen no unpleasant results in five cases treated as described either from the sac or wire.

I desire to present the following case for your examination :

City Hospital, B. I. Fourth Record.—M. J., aged twenty-seven years, single, sailor ; admitted December 31, 1893 ; discharged March 5, 1894 ; visiting physician, Dr. Phelps ; house physician, Dr. Greenway.

The patient says that ten years ago he fell from the mast of a ship and struck the deck with his buttocks. The next day after the fall he noticed a small tumor in the right inguinal region, about the size of a marble. This tumor gradually enlarged until now it is about the size of a cocoanut. The patient wished to have it operated on, as it caused him considerable discomfort and pain.

Examination shows the tumor to be an oblique inguinal hernia on the right side, with an opening in the abdominal walls that the hand could be passed through.

On January 8, 1894, he was operated on by Dr. Phelps for the radical cure of his hernia, a new method being employed—loops of silver wires were placed in the incision and allowed to remain and become encapsulated. The wound healed by first intention, and the hernia has shown no tendency to recur.

He went to sea March 9, 1894, perfectly cured. No inconvenience from the wire.

40 WEST THIRTY-FOURTH STREET.

The New York Medical Journal.

A WEEKLY REVIEW OF MEDICINE.

EDITED BY

FRANK P. FOSTER, M.D.

THE PHYSICIAN who would keep abreast with the advances in medical science must read a *live* weekly medical journal, in which scientific facts are presented in a clear manner; one for which the articles are written by men of learning, and by those who are good and accurate observers; a journal that is stripped of every feature irrelevant to medical science, and gives evidence of being carefully and conscientiously edited; one that bears upon every page the stamp of desire to elevate the standard of the profession of medicine. Such a journal fulfills its mission—that of educator—to the highest degree, for not only does it inform its readers of all that is new in theory and practice, but, by means of its correct editing, instructs them in the very important yet much-neglected art of expressing their thoughts and ideas in a clear and correct manner. Too much stress can not be laid upon this feature, so utterly ignored by the “average” medical periodical.

Without making invidious comparisons, it can be truthfully stated that no medical journal in this country occupies the place, in these particulars, that is held by THE NEW YORK MEDICAL JOURNAL. No other journal is edited with the care that is bestowed on this; none contains articles of such high scientific value, coming as they do from the pens of the brightest and most learned medical men of America. A glance at the list of contributors to any volume, or an examination of any issue of the JOURNAL, will attest the truth of these statements. It is a journal for the masses of the profession, for the country as well as for the city practitioner; it covers the entire range of medicine and surgery. A very important feature of the JOURNAL is the number and character of its illustrations, which are unequaled by those of any other journal in the world. They appear in frequent issues, whenever called for by the article which they accompany, and no expense is spared to make them of superior excellence.

Subscription price, \$5.00 per annum. Volumes begin in January and July.

PUBLISHED BY

D. APPLETON & CO., 72 Fifth Avenue, New York.

