

GARCEAU (E.)

Compliments of
the Writer.

Vaginal Hysterectomy as Done
in France

BY

EDGAR GARCEAU, M.D.

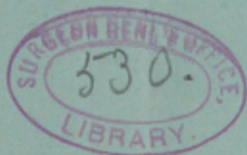Electro-Therapeutist to the Free Hospital
for Women, Boston; Visiting Physician
to Convalescent Home, St. Eliza-
beth's Hospital, Boston, Mass.

REPRINTED FROM

THE AMERICAN JOURNAL OF OBSTETRICS
Vol. XXXL No. 3, 1895.

NEW YORK

WILLIAM WOOD & COMPANY, PUBLISHERS
1895



VAGINAL HYSTERECTOMY

AS DONE IN FRANCE.¹

IN 1886 Péan removed the uterus through the vagina from a patient who had undergone celiotomy at his hands four years previously. The primary operation was done for inflamed appendages and was unsuccessful in relieving pain. The hysterectomy was brilliant in its results. This incident led him to think that perhaps too much attention had been bestowed upon the appendages, and that the uterus might be quite as much responsible for pelvic pains as the ovaries and tubes. Reasoning that the uterus was diseased as well as the appendages, and frequently more so, though perhaps not appreciated as such, he came to the conclusion—certainly a logical one—that, in cases of pelvic inflammation involving the female organs of generation, not only should the appendages be removed, but likewise the uterus as well. As his observations extended and his experience grew larger, he found that even in those cases in which the uterus was removed and the appendages abandoned a cure resulted which proved to be permanent in the vast majority of cases. A convincing argument in favor of the new method was that the mortality was very much lower than that of celiotomy, *ceteris paribus*. His first sixty cases all recovered; among them were some severe types of pelvic inflammation with dense adhesions matting the intestines together to such an extent that celiotomy would have been dangerous had it been attempted.

The new operation met with great disfavor. For a while Péan was alone in upholding his views. Ségond was the first con-

¹ Read before the Gynecological Section of the Massachusetts Medical Society, December 27th, 1894.



vert. He saw Péan operate and cure a patient who had the worst kind of pelvic inflammation. It was clearly a desperate case: the uterus was firmly embedded in dense adhesions; the induration of the viscera extended almost up to the umbilicus. To remove the appendages by celiotomy was not to be thought of. To remove the uterus vaginally under such conditions seemed impossible. Péan demonstrated the feasibility of doing this and cured the patient besides.

Gradually the operation gained a foothold, mainly through the able writings of Ségond, who defended it with extraordinary energy, until now even its bitterest opponents are forced to admit that vaginal hysterectomy has a place in surgery.

At the present time the question when to do vaginal hysterectomy and when to do celiotomy is far from settled. There are some who do the vaginal operation in all cases of double salpingitis, associated or not with purulent collections, and others who do it only when celiotomy is contraindicated; still others occupy a middle ground. As in all questions of this kind, the future will decide.

The operation.—The instruments should be: three knives with long handles, one straight, two curved on the flat with edges right and left respectively; five vaginal retractors of the Péan model; two pairs of scissors, straight and curved, with blunt points; two three-toothed traction forceps; two bullet-traction forceps; a plentiful supply of hemostatic forceps having a bite of different lengths—a half-dozen of one and a quarter inches, a half-dozen of three inches, a few, curved on the flat, of three inches, and about a dozen ordinary small ones; uterine sound; needles, etc., in case the bladder is opened; two hooks for everting the uterus; self-retaining catheter; reflux catheter; sponge holders; uterine curettes and dilators.

The Péan retractors require special mention. They are long, flat blades gently curved at the very end, mounted on strong aluminum handles. In the middle of the instrument, at the junction of the blade and the handle, is a sharp angle which increases the efficiency of the instrument, for it makes it easier for the assistant to manage. Each blade is four and a half inches long and one and a quarter inches wide; the handles are of about the same length. Four of the retractors are of the same size and are used to separate the vaginal walls and expose the

cervix. The fifth retractor is only seven-eighths of an inch wide, though of the same length; it is very useful to slip into a small opening in the peritoneum, and serves as a guide to a larger retractor.

The hooks may also be mentioned; they are eleven inches long and have each two hooks at their extremities, three-eighths of an inch apart. They are very useful at times in everting the fundus.

The self-retaining catheter is very ingenious. It is an ordinary flexible soft-rubber catheter, having opposite its eyelets two rubber shoulders projecting one-quarter of an inch from the shaft, one on each side. These prevent it from slipping out of the bladder unless considerable traction is made; if this is done the rubber shoulders straighten out and the catheter is removed. To introduce the instrument a long whalebone sound is passed into the canal of the catheter as far as its tip. By drawing the mouth of the catheter toward the free end of the sound its shoulders straighten out and it can be easily passed.

Preparation of the patient.—For eight days before the operation the patient has vaginal douches of corrosive sublimate 1:2000. The day before she is well purged, and this is followed by a rectal enema at least six hours before the operation; if this is not done, and the enema given just before operation, there may be great annoyance caused by the discharge of fluid which has not wholly escaped. It is unnecessary to comment on the details of cleansing and shaving; soap, brush, and corrosive are freely used, both externally and in the vagina. The urine is now drawn and the limits of the bladder determined by the finger in the vagina.

In these as well as in celiotomy cases the French surgeons have their patients' lower limbs wrapped in cotton wool and bandaged; this remains on three days; it lessens shock.

The patient being on the back, the operator now examines the pelvic organs in order to determine what his line of action shall be. In the majority of cases it is most convenient to operate the patient in the dorso-sacral position; it is easier for the assistants, the patient remains stationary, her breathing is not interfered with, and fewer assistants are needed. When, however, on examination the uterus is found to be firmly adherent, surrounded by masses, and high up, the left-lateral position of Péan will be preferred, for more room will be gained. But this cannot be

said to be a hard-and-fast rule, for the majority of French operators, except Péan, never under any circumstances use the left-lateral position, believing that there is no uterus which cannot be attacked to advantage in the dorso-sacral position. The left-lateral is practically Sims' position, except that the left limb is extended and the right one sharply flexed on the patient's chest.

SIMPLE VAGINAL HYSTERECTOMY WITHOUT COMPLICATIONS, *the uterus being removed en masse*.—Most surgeons, particularly the

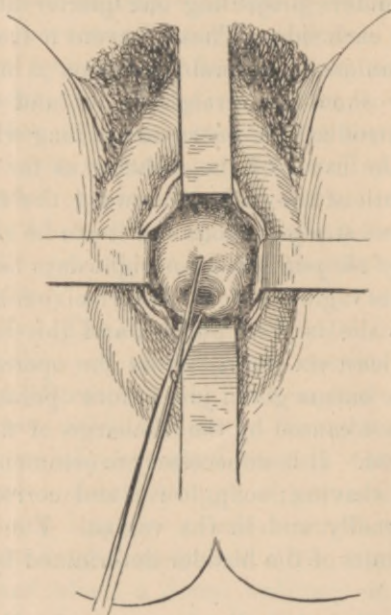


FIG. 1.—The retractors are in position and the bullet forceps draws down the cervix.

Americans, prefer to use ligatures instead of forceps for controlling hemorrhage. This method is certainly much more comfortable for the patient, but when it is necessary to do an operation quickly it is perhaps better to employ forceps. The objections to forceps are their alleged insecurity, the possibility of wounding the viscera, and the difficulty of maintaining asepsis. A careful operator will avoid all these mishaps. The advantages are: they are easily applied; they are easily removed; they control hemorrhage perfectly; there is no subsequent fistula

(from suture); and, lastly, they shorten the operation. In the descriptions which follow it will be assumed that forceps are used.

In all cases in which endometritis is present it is well to dilate and curette the uterus; some operators inject it with iodine after curetting.

The operation begins by placing the four large retractors in position, one on each side and one anteriorly and posteriorly. The assistant on the left of the patient, the more important position, manages the anterior and left-lateral retractors, while the right assistant manages the other two.

The cervix is now seized with traction forceps and the uterus lowered as much as possible (Fig. 1).

Ségon's incision is infinitely the best, for by using it he has never clamped the ureter (four hundred cases). It is made with a knife. He keeps somewhat close to the os externum anteriorly. Posteriorly, however, he allows the knife to cut a little further away (about a third of an inch more). Having done this, he makes two additional incisions, one on each side, parallel to the lower border of the broad ligament; each is two-thirds of an inch long. The advantage is twofold: it gives more room and it protects the ureter. The distance of the circular incision from the os externum varies, of course, with the size of the cervix and the attachments of the bladder. Care should be taken not to cut too far out for fear of wounding the bladder, nor too near the os; in the latter case, the line of "cleavage" between the bladder and the uterus not being hit, the operation would be laborious and slow.

Directly the incision is made the tip of the anterior retractor is forced into the wound and pulled upward and backward along the cervix (Fig. 2). The sectioned tissue yields a good deal—surprisingly so, in fact—and it is just this manœuvre that makes the Péan instrument of so great value. While the retractor is pulling back the tissue the blunt-pointed curved scissors are used to separate the attachments between the bladder and the cervix; the concave curve of the scissors should point toward the uterus. Now short snips are taken from left to right, the greatest care being taken to keep as close to the uterus as possible in order to avoid the bladder. With each snip of the scissors the retractor takes a fresh hold, being introduced into

the part just cut by the scissors. It is truly astonishing to witness for the first time the wonderful help given by the retractors; without them morcellation would be impossible. Unless the attachments between the bladder and the uterus extend high up, which is rare, the peritoneal cavity will soon be opened; it may be recognized by its bluish coloration and smooth surface. The large anterior retractor is now discarded and the narrow one thrust into the opening made; the finger completes the

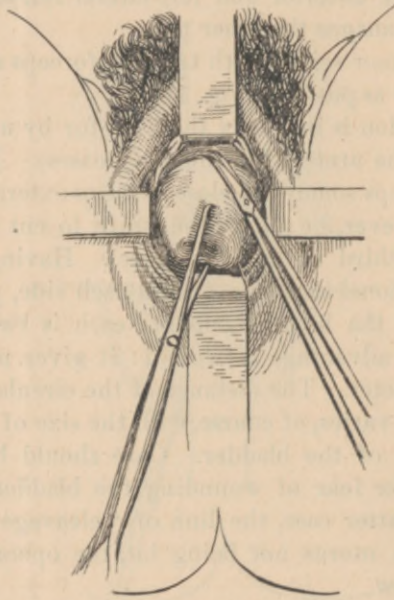


FIG. 2.—The Ségond incision has been made and a large part of the cervix denuded. The anterior retractor pulls up the divided tissue, and the bullet forceps pulls down the uterus. The scissors are shown.

separation. Some operators prefer to use the finger instead of the scissors in separating the anterior attachments; this is not necessary, for if the retractor is properly used there is no danger of wounding the bladder or ureters. However, when the peritoneal cavity is being neared it is well to explore with the finger occasionally; if the tissues give at any one point, this point is probably nearest the peritoneal cavity.

Having opened anteriorly, the same process is performed pos-

teriorly; here, however, the finger will prove of greater service than the scissors. Sometimes it will be best to work in front and behind simultaneously. The hemorrhage up to this stage is insignificant and may be disregarded.

Everting the uterus.—Anterior method. Traction downward should be made as much as possible by means of the forceps still on the cervix. Now the long-handled hook is dug into the anterior wall as high up as possible, and traction made; the uterus yields and begins to evert; the other hook is placed higher up and traction again made. By repeating this process the uterus suddenly pops out, sometimes unexpectedly.

Posterior method. When the uterus is retroflexed, and also in cases in which the anterior attachments are unusually high, the posterior method is to be preferred. By using this method it is not necessary to complete the separation of the anterior attachments. The finger introduced into the posterior cul-de-sac explores the back of the uterus. Using the finger as a guide, a pair of bullet forceps is introduced and seizes the uterus high up on its posterior surface. The organ is now pulled down and out in such a way as to evert the fundus through the vulva. By this movement the broad ligaments are twisted on themselves; their lower borders look up and in front, their upper borders down and behind. If the vesico-uterine attachments have not been separated entirely, this may be done now; the finger is passed up behind by the side of the uterus over the broad ligament, and serves as a guide to complete the separation.

Hemostasis.—A hemostatic forceps is now placed on the left broad ligament from above downward (with relation to the patient), whether the posterior or the anterior method has been used. To do this the index finger seeks the top of the broad ligament, and guides the forceps, preventing it from seizing the intestines; when the tip of the forceps strikes the palm of the hand it is locked. The ligament is now cut close to the uterus, so as to leave some tissue protruding from the forceps, for this might slip if this were not done. The same is done on the opposite side and the uterus removed.

Sometimes there is a little oozing from the vaginal wound, as well as from the prerectal tissue. It should be controlled by clamping the peritoneal and the vaginal edges together with small forceps.

Dressing.—Drainage is not required; the forceps assure complete drainage. The dressing consists of small tampons of gauze well saturated with iodoform powder; each tampon has a string attached to it so that it can easily be removed. Care should be taken to place the tampons above the tips of the forceps, if this is possible, in order to prevent the intestines from lying on these, thus producing pressure necrosis. Other tampons are placed between the forceps and the vaginal walls, while a strip of gauze is placed between them and the vulva. The patient is catheterized again, and the dressing completed by covering the handles of the forceps with aseptic cotton; a bandage is then applied. The patient is put to bed and her knees flexed and supported by a cushion. Pain is controlled by subcutaneous injections of morphine. In forty-eight hours the forceps are removed and the vulva and vagina douched. It is only after the sixth day that the upper tampons are removed; this is in order to allow the peritoneal wound opportunity to contract down. Fresh tampons are at once replaced after douching. The dressing may now be done every day. In three weeks the patient is up and about.

Details.—Many surgeons employ a self-retaining catheter. If the instrument is aseptic there is no danger of cystitis; it is not, however, absolutely necessary to use one.

In incising the vagina the greatest care must be taken to keep close to the uterus, which serves as a guide. Experiments on the cadaver have shown that by using Ségond's incision there is less danger of wounding the ureter. If the simple circular incision was made it was found that the ureter was one-half inch (1.5 centimetres) from the uterus, whereas with Ségond's incision the distance was increased to five-sixths of an inch (2.5 centimetres). The explanation is perhaps to be found in the greater freedom of motion downward accorded the uterus, the ureters at the same time slipping outward and upward.

If a fistula is made it is sewed at once; the natural contraction of the tissues will do much to closetese fistulæ.

During the eversion of the uterus a bullet-traction forceps should pull down the cervix and prevent it from being carried up into the peritoneal cavity; the uterus is flexed on itself in doing this.

If the uterus cannot be everted, but can be lowered, the fol-

lowing manœuvres should be performed: The cul-de-sacs being opened, the index finger of the left hand is introduced into the anterior opening in front of the uterus and seeks the top of the left broad ligament; then taking a long hemostatic forceps, one jaw is introduced into the posterior opening and the other into the anterior; before locking, the index finger explores behind and pushes aside intestines if they prolapse; this has already been done anteriorly. The ligament is clamped and cut and the uterus delivered. It is now a simple matter to clamp the right broad ligament.

If the uterus will not descend progressive clamping must be done. The lower part of the ligament is seized with a forceps having a bite of one and a quarter inches on each side; the ligament is cut up to the tip of the forceps, and the uterus, thus liberated, is lowered; progressive clamping is done until the organ is out. If the uterus will not descend, and the operator is obliged to introduce his forceps directly into the pelvic cavity, the forceps must never be locked until the finger has explored anteriorly and posteriorly. Richelot passes his index and middle fingers into the anterior and posterior cul-de-sacs respectively and guides his clamps in the most perfect manner. Care should be taken that the forceps do not nip the vagina, rectum, or bladder; sloughing would ensue (Mauclair).

VAGINAL HYSTERECTOMY WHEN THE UTERUS IS ADHERENT (*hysterectomy for pelvic suppuration*).—This operation is perhaps the most difficult of any on the pelvic organs. Various expedients have been devised since Péan's first operation; they bear the names of their originators, but the credit belongs entirely to Péan, for it was he who took the initiative, and his operation to-day is applicable to all cases, even the most difficult. The others are merely modifications, and they bear a striking resemblance to the Péan operation. Quenu and Müller remove the uterus by median section; Doyen removes it by hemisection of the anterior wall, and everts it by traction.

The best operation is perhaps a combination of the Péan and the Doyen. Briefly it may be described as having three stages: first, removal of the inferior segment of the uterus; second, removal by morcellation of the anterior wall of the uterus; and, third, eversion anteriorly of the stump. Probably no one operates better than Richelot by this method. He operates

as follows: The patient being on the back, the retractors are introduced and the cervix seized (Fig. 1). The Ségond incision is now made and denudation effected of the cervix proper exactly as described in the preceding operation (Fig. 2). As much of the anterior and posterior attachments is freed as possible, using the retractors to pull back the liberated tissue. The finger, as well as the scissors, should be used to separate the adhesions, which are frequently exceedingly dense, especially posteriorly; the finger will prove to be quite as serviceable as the

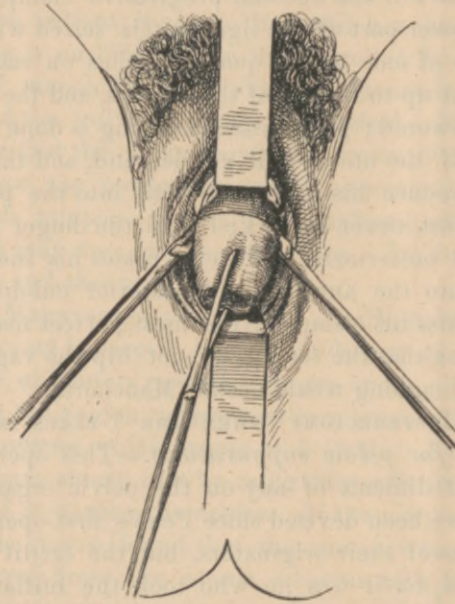


FIG. 3.—The lateral retractors have been removed and their places taken by the clamps which have seized the uterine.

scissors, and some operators prefer it to the scissors. In most instances as much as an inch or more can be liberated anteriorly and posteriorly; every effort should be made to do this, because the uterine artery is to be clamped, and to secure it the first forceps should seize the broad ligament for at least an inch above its lower border. The forefinger of the left hand is now placed on the anterior surface of the cervix and glides along outward toward the base of the broad ligament; it penetrates between

the anterior peritoneal fold and the ligament proper and pushes aside the ureter, which is not far distant; the same is done behind. Then two fingers grasp the broad ligament and serve as guides to the first forceps, which seizes the ligament at least an inch from its lower border and one-third of an inch from the uterus at the level of the external os (Fig. 3). The ligament is now cut the whole length of the forceps close to the uterus.

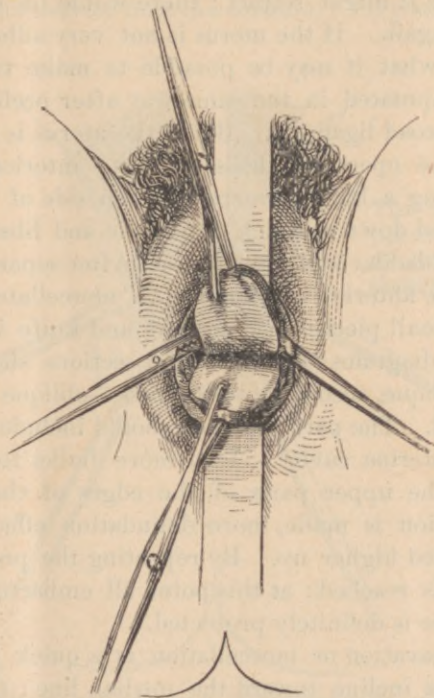


FIG. 4.—The cervix has been split transversely into two flaps, which are seized by bullet forceps. The uterine clamps are shown.

The same is done on the opposite side. The forceps now take the place of the lateral retractors, which may be discarded, but they must be handled with care. As a matter of fact, the lateral retractors have but little to do. The cervix is now split transversely from side to side, through and through, up to the point of the forceps; two flaps are thus made, an anterior (pubic) and a posterior (rectal) (Fig. 4). The posterior flap is now

amputated obliquely from below upward, in order to remove as much as possible; strong forceps seize the anterior flap and pull it downward; the uterus begins to roll anteriorly, thanks to the void which has been made behind; at the same time the scissors denude and separation is effected between the uterus and bladder; the retractor holds the ground gained; some progress is made. The anterior flap is then amputated, but before cutting it off entirely a bullet-traction forceps is fastened into the stump above, because it might retract; there would be some difficulty in getting it again. If the uterus is not very adherent and will descend somewhat it may be possible to make two more flaps, which are amputated in the same way after preliminary hemostasis of the broad ligament. But if the uterus is very adherent the rest of the operation deals with the anterior wall of the organ. Placing a bullet forceps on each side of the canal, the stump is pulled down as much as possible and liberation effected between the bladder and the uterus. After separating as much as possible, the anterior uterine wall is morcellated in the median line in small pieces with scissors and knife in the manner shown in the diagrams (Fig. 7). The sections should be either vertical or oblique, according to the case—oblique if the uterus does not yield. The part removed should include all the tissue down to the uterine cavity. Two more bullet forceps are now inserted on the upper parts of the edges of the excavation; renewed traction is made, more denudation effected, and morcellation carried higher up. By repeating the process the peritoneal cavity is reached; at this point all embarrassment ceases, for the bladder is definitely protected.

Central excavation or morcellation is a quick process. The uterine cornua incline toward the median line; the fundus descends in the form of a V, which allows of its being hooked with the finger and pulled down and out. If there are adhesions behind the uterus they may be separated under the eye with the greatest ease. Having done this, a strong clamp seizes the upper part of each ligament down to the clamp which has been placed in position from below (Fig. 6), and the rest of the stump amputated. Should there be any difficulty about everting the organ when once the peritoneal cavity has been reached, the uterus is bisected antero-posteriorly in the median line and each half clamped separately.

In all these procedures there is little hemorrhage and it may be disregarded.

Details.—Very rarely is it impossible to remove all of the uterus by this method. When there are numerous extensive adhesions the operation is laborious and slow, requiring extraordinary patience; the uterus is immovable and refuses to descend; in these cases it is necessary to proceed with care, for the tissue is friable and is apt to tear. Sometimes the long knife will prove of greater service than the scissors. Very seldom does the

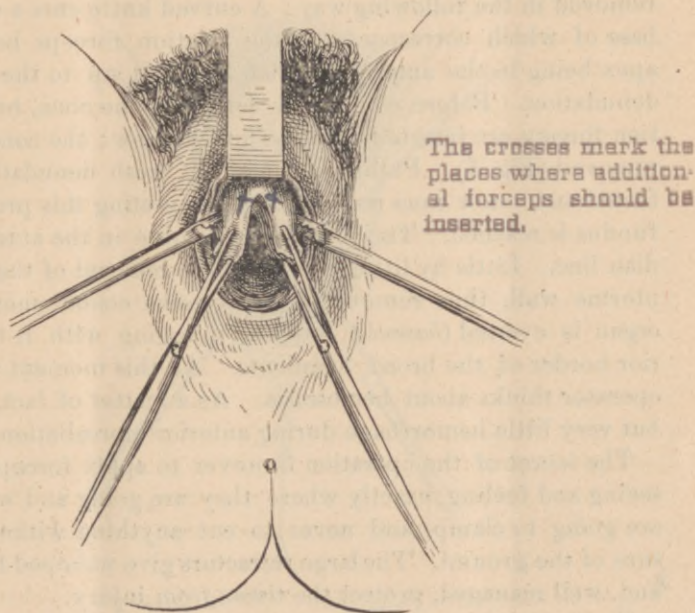


FIG. 5.—The cervix has been amputated. The uterine clamps are seen on the sides. A cone has been morcellated from the anterior uterine wall. Two bullet forceps should be shown as seizing the upper edges of the excavation. The two lower ones are not absolutely necessary. This figure illustrates Ségond's morcellation.

fundus of the uterus have to be abandoned. The final result, however, is said to be quite as good, provided the stump does not offer an obstruction to the flow of the pus, if there should be any.

It is absolutely necessary to apply at least four forceps to the broad ligaments, one for each uterine and one for each ovarian. Some operators neglect this if these arteries do not bleed; it is

unsafe to do so, on account of the possibility of secondary hemorrhage. Sometimes the adhesions may temporarily occlude these arteries and they bleed afterward.

Ségon's method of morcellation is worthy of description because it is so easy. It commends itself to one who has had little experience with the operation. He calls it *central conoid excavation* ("evidement conoïde central"). Since he has used this method he has never had to leave the fundus behind. The excavation begins after the cervix has been amputated, the uterines having been clamped. The next denuded portion is now removed in the following way: A curved knife cuts a cone, the base of which corresponds to the traction forceps below, the apex being in the anterior median line and up to the point of denudation. Before completely detaching the cone, bullet-traction forceps are inserted into its upper edges; the cone is then removed (Fig. 5). Pulling down again, fresh denudation is effected and a new cone removed. By repeating this process the fundus is reached. The point is to operate in the anterior median line. Little by little, thanks to the removal of the anterior uterine wall, thus removed by successive conoid morsels, the organ is everted (*bascule*) forward, dragging with it the superior border of the broad ligaments. At this moment only, the operator thinks about hemostasis. As a matter of fact, there is but very little hemorrhage during anterior morcellation.

The secret of the operation is never to apply forceps before seeing and feeling exactly where they are going and what they are going to clamp, and never to cut anything without being sure of the ground. The large retractors give unhoped-for room, and, well managed, protect the tissue from injury.

There should never be any hemorrhage. The operator should always see what he is doing. It is not a blind operation.

When it seems easier to do morcellation of the posterior wall of the uterus, as in retroversion, it should be done. The conoid excavation or Doyen's median section (to be described later) should be employed, or simply Richelot's method of morcellation.

The management of pus pockets.—The operation described is applicable not only to cases in which there are no pus pockets—*i.e.*, to cases in which there are simply inflammatory adhesions—but likewise to cases in which there are one or more pus cavities around the uterus. If, during the operation of mor-

cellation, such a cavity is opened, the operator is not disturbed. He waits until the flow of pus ceases, enlarges the opening with his finger, washes out the cavity with the reflux catheter, and proceeds exactly as though nothing had happened.

These pockets are situated in the broad ligament, in the tubes, in the ovaries, or in cavities formed by adhesions (encysted peritonitis); in the latter case they may be in close connection with the uterus. Large pockets need not be considered formidable; Péan has done vaginal hysterectomy in a case in which

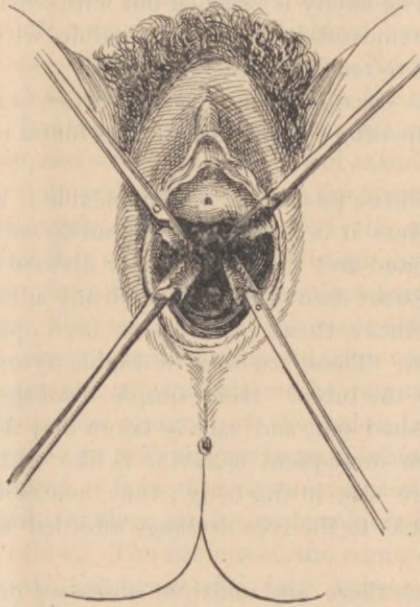


FIG. 6.—Showing the clamps seizing the broad ligaments; two above and two below. The uterus has been removed.

the abscess reached up to the umbilicus. When it is evident, before operation, that pus exists on one or both sides of the uterus, it is well to proceed cautiously. It is possible in these cases that the uterus is fairly movable, and there is a temptation to remove the organ entire; this should not be done, because in placing a long clamp on the broad ligament a pocket might be opened, and if this should happen the operation field would be obscured. But in morcellation the operator sees exactly what is being done, step by step, and there is no embarrassment (Ségond).

If the cavities have not been opened during the operation they may be searched for now after the removal of the uterus. Sometimes the tubes appear as large, congested coils filled with pus. They should be incised methodically, in order not to soil the peritoneum. A mounted sponge or two are placed beside and above the tube; these steady it and make it bulge into the vagina, at the same time shutting off the serous cavity. Then a cut with the knife opens the tube and the contents flow into the vagina, while a pair of forceps at the same time seizes the mouth of the incision and prevents the sac from retracting upward. The cavity is washed out with corrosive and the tube sac now removed in so far as possible with the fingers, taking care not to tear the viscera.

If the pus has escaped during the operation, search should be made for the opening; it will usually be found under the uterine cornu.

Sometimes all the pus sac is not enucleable. After opening one or two pockets it is found that the cul-de-sac of Douglas is entirely obliterated and the pelvic cavity divided into two sacs, back to back against each other, and so firmly adherent that it is impossible to remove them. They have been opened and their contents drained. These are cases of double pyosalpinx and all of the pus is in the tubes. Here simple drainage suffices; the pockets are washed out, and care is taken that there shall be a free exit. Their subsequent behavior is like that of an abscess cavity anywhere else in the body; they contract and become obliterated, thanks to the free drainage afforded by the removal of the uterus.

In some cases there are multiple abscesses on one or both sides. The greatest care should be taken to search for them with the finger and open and drain them; if left behind they will cause further trouble. To be sure, it is possible, and quite probable, that they will open spontaneously in a day or two, but it is not safe to count upon this event.

The treatment of adhesions and the appendages.—The matter may be summed up in a few words. When the appendages can be separated from the adhesions it is proper to remove them, otherwise they may remain behind. They will atrophy and give no further trouble. The inflammatory deposit disappears in an incredibly short space of time. The following case which came under my personal observation illustrates this

point: M. J., 29, Ilpara, was admitted to the Broca Hospital (Pozzi's) August 12th, 1894. Ever since her last confinement, three years before, she had been suffering from inflammatory pelvic trouble which had confined her to bed most of the time. The longest period of quiescence was three months; the rest of the time she had been practically bedridden from pain and prostration. She had had four attacks of pelvi-peritonitis, which had been severe, the last one eight days before entering the hospital. Examination showed a uterus which was fixed, immovable, and surrounded by inflammatory adhesions; on the right a mass the size of a good-sized fist filling the pelvis and impinging on the rectum, on the left a smaller mass. Vaginal hysterectomy was done by Dr. Jayle, Pozzi's first assistant. No pus was found. There was no shock to speak of, although the operation lasted over an hour. In three weeks the patient was completely well, suffering no pain, and walking about. I had examined the woman before the operation and easily made out the large masses; when I examined her again, three weeks after the operation, I was astounded to find that on the left side almost nothing remained, and that on the right side there was only a mass the size of a small hen's egg. She told me that she was perfectly well, and she looked so. And yet both ovaries and tubes were left behind!

When, however, the appendages can be removed it is proper to remove them. The contents of the pelvis, when inflamed, may be compared to an arch the keystone of which is the uterus; this being removed, it is in most instances easy to remove the sides of the arch, for they can be undermined, as it were, and attacked from below. The forceps on the cornu of the uterus is pulled gently and the ovary and tube appear in the vaginal vault; care should be taken not to pull too hard. When the ovary and tube appear the finger is passed in and explores; adhesions are separated and the appendages pulled into the vagina; the pedicle is clamped and they are excised. This is a simple case. Sometimes the tubo-ovarian mass is high up and strongly adherent; the finger scarcely touches it and traction on the cornu effects nothing. The index and middle fingers are now passed in and explore; the tactile sense tells what is ovary, what intestine, what omentum, and what tube wall; the line of "cleavage" is found and efforts made to free the mass. Things are very much as in a difficult celiotomy. There are cases in which the fingers do not suffice to pull down the ovaries; in these cases a fenestration

trated forceps is often useful to seize the organ and cause it to descend. Gentleness is requisite for success, and no harsh measures should be adopted. When persistent, careful efforts have been made without avail, the appendages must be abandoned and Nature allowed to complete the cure (Richelot).

Dressing.—This is the same as in simple vaginal hysterectomy, except that the pus pockets should be filled lightly with iodoform gauze, which is removed with the tampons six days later. Care must be taken at this first dressing to place the fresh tampons as high as possible in the vaginal vault, because if placed too low the contraction of the wound might shut off the openings of the pus pockets and a secondary abscess result. Should such an occurrence happen it is easy to open the abscess per vaginam. The forceps are removed in forty-eight hours. It is extremely rare* that a hemorrhage occurs on their removal. If it should happen the patient should be taken to the operating room and placed in Sims' position. The tampons are removed, the retractors inserted, and the bleeding points seized with forceps again (Richelot).

During the days following the operation it is wonderful to witness the change in the patient. The temperature drops, the pulse becomes steady, the bladder and rectum regain their functions, and the patient makes rapid strides to recovery. The peritoneum has not been handled except in the pelvic cavity, and that very little; the intestines have not been touched; everything has been done in the vagina outside the peritoneal cavity. There is really not more shock than after an operation for a bad perineal laceration.

After-treatment.—The patients take nothing by mouth for four or five hours after the operation, then they may have iced champagne in teaspoonful doses; this and other stimulants is the only nourishment taken until the forceps are removed. The vomiting ceases now and the patients may have milk and Vichy water or cold bouillon. They may have nourishing food from the third day.

An ice bag is to be placed on the lower abdomen immediately after the operation; it diminishes pain and may be allowed to remain four to six days. Severe pain is controlled by subcutaneous injections of morphine. On the third day a rectal injection of glycerin one part and wine two parts is given (Pozzi), a few hours after the removal of the forceps. On removing the

upper tampons on the sixth day no immediate vaginal injection should be given; it is best to wait a few hours before doing so, to avoid violent colic which has sometimes been caused. Now the patient may have a daily injection of carbolized water, one per cent. A strip of gauze may take the place of the tampons from this moment. In ten to fifteen days, in non-suppurative cases, the liquid returns clear. The patients sit up in bed toward the eighth day, and get up on the eighteenth or twenty-first day. Sexual relations should not be resumed until cicatrization is perfect; it generally takes two months.

OTHER METHODS OF VAGINAL HYSTERECTOMY. *Péan's original method.*—The patient being in the left-lateral position (or dorso-sacral), the retractors expose the cervix, which is seized and pulled down. The circular incision is made, the ligaments clamped and cut, and the two flaps, pubic and rectal, made and amputated, care being taken to fasten bullet forceps into both flaps before amputating them. Securing a good hold again, denudation is effected anteriorly and *posteriorly* for as great a distance as possible. Two fresh pairs of hemostatic forceps now grasp more of the ligaments above the first ones; the ligaments are cut, new flaps are made, and the process continued until the uterus is removed. Each stage comprises four manœuvres: 1st, liberation of the anterior and posterior surfaces of the uterus; 2d, section of the broad ligaments; 3d, division into two flaps of the portion of the uterus liberated; 4th, excision of the two flaps thus obtained. The whole organ is removed without losing a drop of blood, and seeing exactly what is being done. The first principle of the operation is never to apply forceps, nor to cut anything, without having seen the region on which the forceps are to be applied or the knife carried.

The solution of the operation is to be found in the retractors and in the division of the uterus into flaps. The retractors give unhoped-for room and, well managed, protect the tissues from injury. The division into segments allows the uterus to descend, even when it seems at first sight impossible for it to do so.

This method is applicable to all cases, and has been employed with success when other methods have failed. It is the parent operation and has held its ground well.

The rules already given in regard to the management of pus and the appendages apply to this method as well as to those about to be described.

Doyen's method of hemisection and eversion, patient on the back.—This process is applicable to cases in which the uterus is not too firmly adherent and can be somewhat lowered; also to cases in which the uterus is not more than twice its normal size. It is particularly to be selected when the uterus is very movable.

The great advantage of the method is that preliminary hemostasis of the broad ligaments is *unnecessary*. The ligaments are not clamped until the uterus is everted through the vulva.

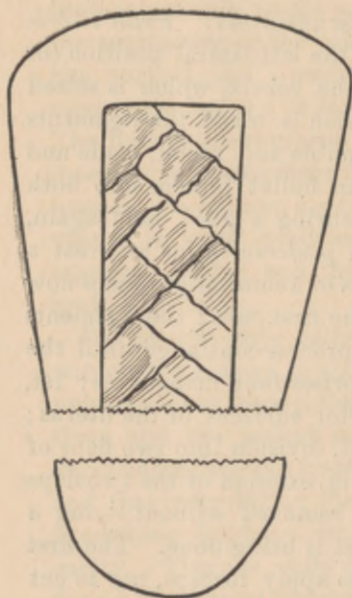


FIG. 7.

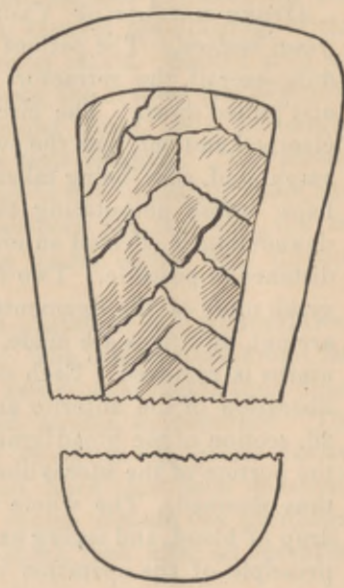


FIG. 8.

FIGS. 7 AND 8.—Diagrams showing the Richelot vertical or oblique morcellation of the anterior uterine wall.

The anterior lip of the cervix is seized with two pairs of bullet-traction forceps, one on each side, to the right and left; they remain here until the end of the operation. The circular incision is made and as much denudation effected as possible with scissors, retractor, and finger, both in front and behind. Now the anterior wall of the uterus is split in the median line between the two pairs of bullet-traction forceps, with the straight scissors, up to the point where denudation ceases (Fig. 9). Two more pairs of traction forceps seize the upper edges of the incision near the angle; traction downward is made, fresh denudation

effected, and the median splitting carried higher up; two more pairs of traction forceps are inserted as before and the process continued until the uterus is everted. The anterior cul-de-sac has been opened during the operation of hemisection.

The central section is a very quick way of reaching the peritoneum. The cornua incline toward the median line; the fundus descends in the form of a V and can be seized with the finger and pulled down. If necessary the median section is carried over the fundus to the posterior wall, splitting the uterus in two halves. Adhesions behind are easily attacked and separated. The appendages are separated and drawn out. If possible a single large clamp seizes the broad ligament from above downward and external to the appendages, thus controlling the hemorrhage (Fig. 11). Doyen applies a lighter forceps, just inside the large one, in order to be more sure; the uterus is then amputated. In cases in which the appendages cannot be lowered enough to be included in the large clamp, it is necessary to clamp them higher up with another pair of forceps. When the uterus is retroverted the hemisection may equally well be performed on the posterior wall.

The advantages of the method are: first, preliminary hemostasis of the broad ligament is unnecessary; second, the operation field is not obstructed by clamps; third, removal of the appendages is easier, there being no clamps in the way.

The median incision is not attended with much hemorrhage; it may be disregarded.

The method of Müller and Quenu, patient on the back.—The steps are the same up to the completion of the cervical denudation. The uterines are either ligated or clamped. The essential feature of the operation is the splitting of the uterus antero-posteriorly into two lateral halves progressively from below upward, denuding as the operation proceeds; otherwise it does not differ from Doyen's, and, like his, it is applicable to cases of fairly movable uteri, or to cases of only moderate enlargement of the organ.

The choice of methods.—As to the choice of methods, this must be left to the operator; what is simple for one is difficult for another. Personal equation must be considered. Everything depends on the skill of the operator and his readiness to take advantage of circumstances as he finds them. To formulate special rules which would be applicable to special cases is impos-

sible. In general, Richelot's method, which is really a combination of methods, will give the best results. I have never seen Ségond operate, but I believe that his central conoid excavation is a most excellent procedure, because it preserves the relation of the parts more perfectly, perhaps, than the vertical or oblique excavation of Richelot.

There are three possibilities in vaginal hysterectomy: either the uterus descends easily, or descends with difficulty, or not at all. ⁴In the first instance any method is applicable; perhaps

There should be two forceps instead of one the crosses mark places where forceps should be.

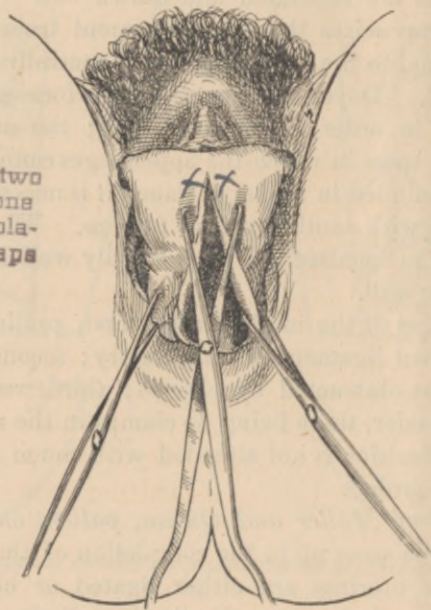


FIG. 10.—Doyen's method of hemisection. Preliminary hemostasis not required. A bullet forceps to the right and left below, and others above on the edges of the median section near the angle.

Doyen's hemisection is the best. A cautious surgeon will perhaps prefer to clamp his uterines first. In the second instance the cervix is amputated first and the body removed next, either by anterior eversion after hemisection or conoid excavation of the anterior wall, or by posterior eversion after similar treatment of the posterior wall. If the uterus is absolutely immovable there are but two methods, the flap method of Péan and the central excavation. Sometimes a combination succeeds—*i. e.*, of the flaps and the central excavation. Here the operator takes

advantage of circumstances; if the uterus cannot be everted, both anterior and posterior walls are attacked by the Péan flap method, and it is most exceptionally the case that the skilled operator is obliged to consider himself vanquished.

VAGINAL HYSTERECTOMY WHEN THERE IS ENLARGEMENT OF THE UTERUS.—The operation may be divided into two heads, cases in which the uterus is not more than twice its normal size, and cases in which the uterus is much larger. Richelot has removed tumors which have weighed three and a half pounds (thirteen hundred grammes). Péan removes all fibroids vaginally which do not extend above the umbilicus, or even higher.

Cases in which the uterus is not more than twice its normal size.—Here any of the preceding methods already described is applicable, the choice being determined, to some extent, by the shape of the tumor and the preference of the operator. Doyen always employs his method of hemisection without special regard to shape. If the tumor refuses to come down he morcellates in the anterior median line by the oblique method (Fig. 10). He does not clamp his uterines, relying on the downward traction to stop hemorrhage by compression; the hemorrhage is never considerable in any event.

The method of Müller and Quenu is also a good one. As the uterus is bisected the uterine cavity is touched with a solution of chloride of zinc (1:10) as an antiseptic precaution. If the uterus is not adherent this method is perhaps as quick as any. The operation is begun by preliminary hemostasis of the uterines by clamps or ligatures.

But the best of all is the method of Richelot. Again it is merely a combination of methods. Richelot seems to have taken the best features of all the processes and to have combined them in such a way as to give the most satisfactory results. His skill is wonderful. He makes the circular incision, denudes the cervix, and endeavors at once to enter the posterior cul-de-sac, generally an easy matter in the absence of adhesions. In incising the vagina he takes care to cut not far distant from the external os, because the bladder frequently descends well down on the cervix in fibroids. The anterior cul-de-sac will probably be opened later for the same reason. The uterines are now clamped, the ligaments cut, flaps made, the posterior one amputated, traction forceps applied to the anterior one, and renewed efforts

made to enter the anterior cul-de-sac. Having entered this, the anterior flap is in turn amputated. Now the rest of the broad ligament is seized with a single clamp, which is guided in such a way, by the index and middle fingers, as to avoid clamping the intestines. The hemostasis being assured, the uterus is removed by morcellation in pieces of varying size, no special care being taken about making flaps. The forceps used in morcellation of fibroids are of a special type (Fig. 13). In the process of morcellation care should be taken to secure the stump of the uterus with forceps before removing a morsel. The appendages are removed in the usual way. But the operation does not

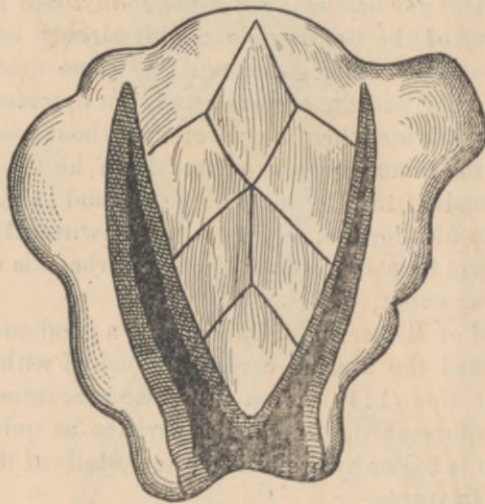


FIG. 10.—Oblique morcellation of the anterior uterine wall in a case of fibroid.

always proceed as smoothly as this. Sometimes the uterus refuses to descend and the ligaments cannot be clamped *in toto*. In these cases, if the flap method of morcellation is attempted (Péan's), it will be found that the stump gives a poor hold owing to the size of the uterus and its height in the pelvis. It is better to do median or oblique morcellation of the anterior wall; Ségond's central conoid excavation is particularly to be recommended. The uterines have been clamped and there is no fear of hemorrhage. Having reached the fundus, the organ is everted anteriorly and the ligaments clamped from above.

Details.—The relations of the uterine arteries, whatever the

volume and the position of the tumor, always remain the same with regard to the cervix; the same procedures are always to be followed in securing them. Sometimes there are dilated vessels, branches of the uterines, in the vicinity of the main artery; occasionally an extra pair of forceps will be required to secure these. Even if the cervix is partially effaced by the hypertrophy of one of its lips or hidden behind the symphysis, it

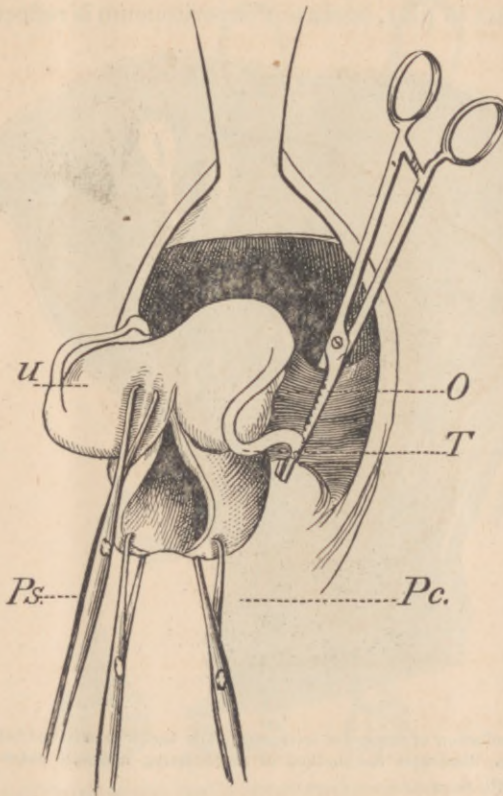


FIG. 11.—Doyen's method of hemisection. The uterus has been everted and a clamp seizes the broad ligament.

is generally possible to seize it and bring it down gently. Only once has Richelot had to attack the body of the uterus in the posterior fornix before making the circular incision; it was a large tumor. If suppuration of the appendages complicates the fibroid the operation is rendered more difficult. Here the rules already given apply.

Cases in which the uterus is of quite large size.—The operation begins as usual by clamping the uterines and cutting the ligaments up to the points of the forceps. The cervix is now split transversely and the mouth of the uterus laid wide open; uterine tissue in the way is removed by morcellation. The cervical flaps must be preserved, if possible, for they serve as traction points; if they cannot be saved they must be amputated and forceps put higher up. The anterior retractor often has a hard part to play, because the peritoneum is reflected higher

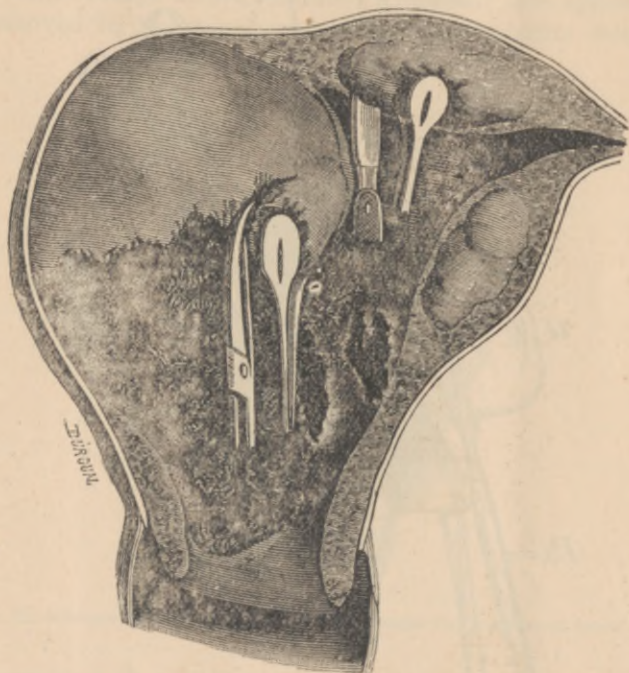


FIG. 12.—Morcellation of tumors of large size. The tumor is removed before attacking the uterus. Also illustrates the method of morcellating a simple submucous fibroid, sparing the uterus.

than usual and is opened later; besides, the bulging of the fibroid in front may hinder its progress and even prevent it from entering deeply when the anterior cul-de-sac is opened. The object now is to empty the fibroid contents of the uterus by morcellation. Tumors of small size may be met with, which are gently enucleated, cut out with the knife or scissors, or simply torn out with the forceps or hooks (Fig. 12). Some uteri are literally crowded with these small fibroids. After some progress has been made, the uterus, already much diminished in size,

may be seized right and left by its muscular walls (the flaps have been amputated) while the operator attacks the main tumor; this is removed in the same way by morcellation, until finally the uterus is transformed into a flabby sac, which is in turn morcellated or which can be everted with ease. Should the tumor be very large it may be necessary to do progressive clamp-

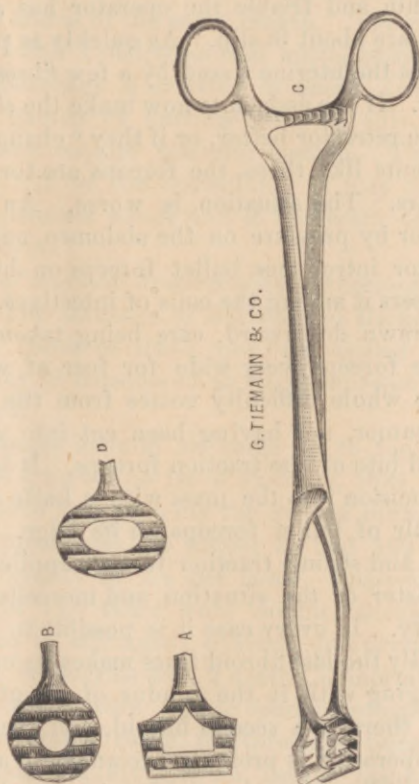


FIG. 13.—Traction forceps used in morcellating fibroid tumors of the uterus.

ing of the broad ligaments and remove the lower portions of the muscular walls, so that the upper parts of the tumor may be made accessible. Almost all the work, long and tedious, has been done outside the peritoneal cavity, which is opened at the end. It will be seen that the object is, not to remove uterus and tumor at the same time, but to morcellate the tumor before attacking the uterus. Sometimes the operation is exceedingly difficult, and profound conviction and great coolness are requisite

for success. The white, rounded tumor appears in the depth of the wound. Traction is made on the cervical flaps to make the tumor more accessible; but the anterior surface of the organ is arrested by the beak of the retractor, which cannot be dispensed with as it prevents the anterior vaginal wall from falling on the forceps. Between the retractor, which elevates, and the forceps, which pull, there is a struggle, and if the edges of the cervix or uterus are thin and friable the operator has a premonition that the forceps are about to slip. As quickly as possible a bullet forceps grasps the uterine tissue by a few fibres, and another seizes the tumor. If the assistants now make the slightest movement to hold the retractor better, or if they "change their grip" at critical moments like these, the forceps are torn out and the tumor disappears. The situation is worse. An assistant depresses the tumor by pressure on the abdomen, and at the same time the operator introduces bullet forceps on his finger as a guide, which steers it among the coils of intestines. The tumor is seized and drawn downward, care being taken not to open the jaws of the forceps very wide for fear of wounding the intestines. The whole difficulty comes from the fact that the surface of the tumor, not having been cut into yet, cannot be seized by a good bite of the traction forceps. It is well now to make a small incision into the mass with a knife and to introduce another pair of bullet forceps on its edge. The incision is now enlarged and strong traction forceps applied. The operator is now master of the situation, and morcellation proceeds without difficulty. In every case it is possible to succeed with patience. Finally the last fibroid mass makes its exit in a lump, frequently dragging with it the fundus of the uterus. Sometimes, however, there is a second fibroid, and even a third; in these cases the operation is prolonged to an hour and a half or even two hours. The ureter has not been injured, even if it is displaced by the fibroid of the lower part of the uterus, because morcellation proceeds from the *centre to the periphery* (Riche-lot). In conclusion it may be said that Ségond attacks even these large fibroids by his process of central conoid excavation.

The most remarkable feature of the operation, which has been long, is the little degree of shock attending it. The peritoneum has not been touched. The day after the patient has no pain and is comfortable. She does not look like a person who has undergone a severe operation the day before. (The descrip-

tion of the operation for large fibroids has been copied almost word for word from Richelot's book.¹)

Incision of the vagina to gain room.—In certain cases when the vagina is small it is necessary to incise the perineum. On the external surface the portion sectioned is represented by a line which begins about half an inch from the middle of the fourchette and extends down and out toward the ischium for about an inch and a half. In the vagina the incision has the same direction and is of the same length. The cut is best made by transfixion with a sharp-pointed knife, cutting from below upward. Hemorrhage is arrested at once. Generally enough room will be gained by cutting one side only, but there are cases which may require bilateral section. The incisions are sutured at the end of the operation. It may be said that the most skilful operators never find it necessary to resort to cutting the perineum.

The results of vaginal hysterectomy performed for pelvic inflammation.—The statistics of Jacobs and Richelot are the latest published. Both of these men are skilled operators, and their results may be considered as fairly representing the merits of the operation.

Jacobs' statistics include all cases up to the 1st of March, 1894; Richelot's, up to the 1st of January, 1894.

Jacobs has done hysterectomy for double inflammatory affections of the appendages 166 times; he had 162 recoveries and 4 deaths, a mortality of 2.4 per cent. Analyzing these cases we find that in 113 there were double purulent collections, which were due to salpingitis, ovaritis, or encysted peritonitis; there were 111 recoveries and 2 deaths, a mortality of 1.8 per cent. The 2 deaths were due to cardiac complications. The bladder was perforated twice, the intestines once; the opening was sutured immediately and no fistula resulted. In 98 of these recoveries the patient was followed for a period varying from 1 to 4 years; the others were lost sight of: 5 or 6 complained of vesical pain due to adhesions; 1 died from dementia 8 months after the operation; 1 had an incurable intestino-vaginal fistula; 2 have had and now have severe pelvic pains, which, however, are intermittent; 88 of these cases were absolute cures. Analyzing the 43 cases of non-purulent inflam-

¹ "L'Hystérectomie vaginale contre le Cancer de l'Utérus et les Affections non-cancéreuses." Paris, 1894. O. Doin, Éditeur.

matory troubles, we find that 1 died during the operation (renal case); 35 were absolute cures; there were some rebellious gastritis complications; the rest were lost sight of. In 10 cases of tumor complicated with bilateral inflammation of the appendages, 1 died from embolism soon after the operation; 7 were followed for a year and were completely cured.

He gives his abdominal work by way of comparison. There were 165 cases with 4 deaths, giving a percentage of 2.4, the same as by the vaginal method; yet it is to be remarked that in 56 of these cases the lesion was unilateral, and it is to be taken into consideration that many of the cases operated on vaginally were desperate ones and inoperable by the abdominal route. All of these patients had inflammatory affections of the appendages.

The distant results of his celiotomies are as follows: Out of his 10 unilateral pyosalpinx cases there were 4 permanent cures; the remaining 6 had subsequent inflammation on the opposite side. The results in the cases of bilateral pyosalpinx are especially noteworthy: there were 3 deaths and 28 operatory recoveries; 25 were seen later; 17 of them had uterine or peri-uterine affections which required curetting in 11 instances, with or without amputation of the cervix; 4 of them had to have a hysterectomy performed to relieve them of their pains; in 5 there was rebellious parametritis. Among the 44 cases of non-purulent bilateral salpingitis many suffered from chronic uterine affections; vaginal hysterectomy was required once; in many other cases some kind of local treatment was needed. He had 34 cases of bilateral ovaritis; many of these had some kind of local treatment subsequently. The unilateral affections of the ovary (46) in general did well. In many instances operation for hernia following the celiotomy was required (number not given).

Richelot had 103 cases of strictly inflammatory diseases of the appendages, 61 of which were associated with pus; there were 7 deaths, a mortality of 6.7 per cent. Analyzing these cases we find that cures were obtained in almost all. In some there were heat flashes and nervous symptoms of various kinds, which disappeared in a short while; a few had a tender vaginal cicatrix, but it was temporary. Richelot states, however, that in some instances when the appendages are left *in situ* subsequent inflammation may be possible from the lighting up of the smouldering fire. Sexual appetite was not diminished.

Landau's work is remarkable. He regards celiotomy as the operation of choice, but in certain cases he thinks vaginal hysterectomy infinitely superior. He says: "There is a category of cases of suppurative disease of the pelvic cavity which are not amenable to the usual forms of treatment; in these celiotomy is extremely dangerous and puts the life of the patient in peril. These cases are those which are complicated with rupture of the tube into the bladder, rectum, or intestine; reference also is made to multiple abscesses which are intra- or extraperitoneal. In these the best treatment is that inaugurated by Péan—vaginal hysterectomy *with removal* of the appendages." He has had 30 cases of this kind without a single death.

Péan's results are phenomenal. From the time of his first operation until December 31st, 1892 (later statistics not found), he had done the operation 150 times with 1 death. He states that 145 were completely cured. The patient who died was exhausted at the time of the operation and succumbed on the sixth day; of the remaining 4, who died during the year following the operation, death in 2 was caused by pulmonary phthisis, in 1 by cerebral hemorrhage, and in the remaining 1 by syphilis. Most of the cases were serious and of long standing; life was insupportable from suffering; almost all were pale and wretched-looking. In two only were there post-operative symptoms referable to the bladder; they were finally cured. In almost all the disease was bilateral.

The following table shows at a glance the results of various operators:

	Cases.	Deaths.
Jacobs.....	166	4
Landau.....	30	0
Péan.....	150	1
Ségon.....	128	11
Routier.....	12	0
Terrier.....	59	7
Pozzi.....	14	0
Michaux.....	25	2
Richelot.....	103	7
Rouaffert.....	21	1
Dewandre.....	3	0
Sutton.....	5	0
Henrotin.....	8	1
	<hr/> 724	<hr/> 34

This gives a mortality of 4.6 per cent. Considering the nature

of the disease—inflammation of the appendages—the mortality is not high. In cases of pelvic suppuration Jacobs' results have hardly been excelled by any celiotomist; it is questionable if they have been equalled. He had 113 cases of double purulent tubes with 2 deaths, a mortality of 1.8 per cent!

The results of vaginal hysterectomy performed for fibroids of the uterus.—The table is striking. The benignity of the method is apparent when it is considered that the cases represent the first efforts of the individual operators in almost every instance. The low mortality is to be explained by the insignificant shock. The tumors were of all sizes, some reaching to the umbilicus. Forceps were always used.

	Cases.	Deaths.
Mayer.....	1	0
Péan	200	4
Jacobs.....	22	2
Mangiagalli.....	8	0
De Ott.....	100	0
Carle.....	22	0
Calderini.....	1	0
Bockel.....	3	0
Routier.....	6	0
Richelot.....	43	1
	<hr/> 406	<hr/> 7

This gives a mortality of 1.7 per cent.

In Richelot's case of death the circumstance was due to his removing the upper tampons too soon. The woman had some irritation of the stomach; he feared iodoform poisoning and removed the dressing on the fourth day; she died the next day of peritonitis. He always waits until the sixth day before disturbing the tampons.

The claims of superiority of vaginal hysterectomy in cases of inflammatory diseases of the appendages.—In the first place, the statistics are favorable. They are, on the whole, better than those of celiotomy. Jacobs' results are wonderful. Landau's, Pozzi's, and Péan's speak for themselves. Landau's were all difficult, as well as Pozzi's. Celiotomy is always preferred by Pozzi when he thinks there is a chance for success. All his 14 cases recovered; they were desperate and inoperable by the abdominal route. As Jacobs says, the statistics of vaginal hysterectomy are derived from desperate cases. To quote Jacobs: "Let us now review the indications for vaginal hysterectomy, beginning with the most difficult cases of suppuration com-

plicated with adhesions. There is pus in the dilated tubes, in the ovaries, in the adjacent cellular tissue. The uterus is fixed and the coils of intestines are glued together above these lesions like a solid roof. In such a case celiotomy displays the adhesions, which cannot be separated without opening the bowels, with a chance that we may reach the purulent focus limited by them, open, empty, and drain it; and the result may be a slow recovery or an intractable fistula. Often we are confronted by a similar condition in which the pelvis is occupied by adhesions, in the middle of which the uterus is imprisoned, and yet without the presence of purulent foci. In such cases, owing to fear of accident, the surgeon is induced to relinquish the operation as an exploratory incision. It is of course always possible to finish the operation, but we have to consider the life of our patient. In just these cases vaginal hysterectomy gives results little short of marvellous—not wholly without danger, but with a security far greater than the abdominal. The collections of pus are opened into the vagina without infecting the peritoneal cavity; the adhesions are severed, if possible, but should the finger encounter too great resistance they are abandoned, and in a few days they will soften and become absorbed. In pelvic suppuration and with extensive complicated adhesions, both equally formidable for the celiotomist, vaginal hysterectomy is triumphant.”

The most wonderful result after these operations is the immediate disappearance of the inflammatory masses. There is no doubt whatever about this. The explanation is probably to be found in the excellent drainage and in the removal of the cause. There is no reason why cicatrization should be any different from that in any other part of the body. An almost analogous condition is to be found in appendicitis. Before operative methods were in vogue in treating this disease, its frequent recurrence was its most distressing feature. The appendix removed, the patient got well.

The starting point of pelvic inflammatory disease is the uterus. Endometritis is the first lesion. Pathological changes may reasonably be supposed to take place in the uterus. A parenchymatous metritis enlarging the organ and giving rise to pain and leucorrhœal discharge, or a chronic interstitial metritis with hypertrophy of the fibrous tissue, certainly demands as much attention as a purulent ovaritis or salpingitis. To neglect the

uterus in such a condition is not logical. Once removed, even if the appendages are left behind, the reservoir of germs is no longer present to cause reinfection. Whether or not leaving behind the appendages, when they cannot be extracted, influences the final result has not yet been definitely determined. The question is perhaps *sub judice*. Those who have had most experience with the operation say that only exceptionally is there any further trouble. At all events, there can be no fresh infection. It is, however, rarely the case that they have to be left behind. One thing is certain, the immediate results are most excellent.

Another point greatly in favor of the operation is the management of pus. The drainage is perfect. The pus and secretions flow down a natural incline and the peritoneal cavity is not contaminated. In celiotomy the pus tubes frequently burst and the contents spread over the peritoneum. In case the pus is foul and fetid, such as is met with after abortions and childbirth, the accident is alarming and gives the operator great uneasiness.

In cases in which pelvic suppuration is complicated with rectal, vesical, or intestinal fistulæ, vaginal hysterectomy is the operation of choice. A celiotomy under such circumstances is fraught with danger. But by the vaginal method the peritoneum is not soiled, the discharges flow into the vagina, and the fistula closes of itself. The conditions are favorable for such a result, the natural healing being aided by cicatricial contraction of the pelvic contents *en masse*; it is rare that a secondary operation is needed.

The post-operative shock of vaginal hysterectomy is infinitely less than that of celiotomy. The reason is apparent. The intestines have not been manipulated. Special emphasis must be made on this point, for it is one of the strongest arguments in favor of the operation. The pelvic cavity seems to have far greater tolerance for operative measures than the great serous cavity.

The cicatrix, which is often tender, to say nothing of hernia, is not a factor in the vaginal operation; nor does the patient have to wear an abdominal support, so disagreeable to sensitive women.

Vaginal hysterectomy removes the possibility of subsequent cancer of the uterus. Tubercle bacilli are found in twenty per cent of all cases of pus tubes; the inference is that they may be present in the uterus.

The objections made against vaginal hysterectomy are: the danger of hemorrhage during the operation; the danger of secondary hemorrhage; the possibility of wounding the bladder and ureter and intestines; the difficulty of maintaining asepsis.

The same accidents may happen in celiotomy, probably not less often. Statistics on celiotomy show this. As to the frequency of clamping the ureter, it may be said that Ségond in 400 consecutive cases never clamped it once. Ségond has never lost a patient from hemorrhage (up to 1893); he has had secondary hemorrhage five times, which was in every case easily controlled—it happened on removing the forceps; he opened the bladder three times—it was sutured and the patient recovered; he opened the rectum nine times—three times it was accidental, six times there was a pre-existing fistula: of these, two died several months after the operation from pulmonary tuberculosis; a third still had a small fistula, but it was a recent case; the other six recovered spontaneously without interference, notably a woman who had passed all the feces per vaginam before operation. Richelot in 219 cases opened the rectum twice, the bladder once. In the first case of opening the rectum the fistula closed in a year—it was small and gave little trouble; in the second the closure was accomplished in two years—it had given little trouble during the second year; in his bladder case the wound was sutured and the patient got well at once. He has had one case of severe hemorrhage on removing the clamps; the patient recovered, but she came near dying. He has had three secondary hemorrhages which took place several days after removing the clamps; tamponing controlled it. Never, with Richelot, did the clamps become unclamped. As to the question of asepsis, with proper care it can be maintained. Sutton has taken pains to make examinations for bacteria in the dressings removed seventy-two hours after vaginal hysterectomy. In his five cases no germs were found.

The greatest objection to the operation is the difficulty of making a correct diagnosis before operation in doubtful cases. The celiotomist who sees what he is doing has a great advantage in feeling as well as seeing. Péan, however, says that in such cases, which must in most instances be simple ones, it is easy to open the posterior cul-de-sac and explore with the finger. In severe affections involving both sides it is seldom that the diagnosis cannot be made beforehand. Another objection is the dif-

faculty of performing the operation. This is certainly valid. It is difficult, and sometimes very difficult. A mere description, however well presented, gives but an imperfect idea of the details which are absolutely requisite for success; a verbal description is not much better. As Ségond says, "one must see the operation performed a number of times by a skilled operator who has done it many times himself, in order to learn it and be able to do it afterward." It is unique in its way and cannot be compared with anything in surgery. The instruments, too, must be suitable; the Péan retractors are almost a *sine qua non* of success.

It has been said that removal of the uterus induces nervous troubles. Ségond has never seen this result, and he follows all his cases (400 up to November, 1894).

The indications for vaginal hysterectomy.—It is natural that American surgeons who have not, perhaps, witnessed the results of vaginal hysterectomy should be somewhat sceptical about it. But here it may be said that Péan's most bitter opponents are to be found in France, and that they have been forced to admit that in selected cases it is the operation of choice. This admission has not been brought about by theoretical reasoning, but by actual results obtained in desperate cases. It is easy to understand opposition to vaginal hysterectomy. Abdominal methods have been perfected to such an extent that celiotomy to-day may be said to be at the very acme of perfection; to replace it by a method which at first sight seemed blind and hazardous appeared out of reason. But the way to convince is by logic and fact. Vaginal hysterectomy has come to stay.

In Paris there are two camps, the hysterectomists and the celiotomists; the former never do celiotomy if they can help it, the latter never do vaginal hysterectomy under any circumstances. But there is likewise a middle camp, that of the unbiassed surgeon who is ready to accept an innovation provided it can be proved to merit recognition. To this Pozzi belongs. His views appeared in *Annales de Gynécologie et d'Obstetrique*, 1893, page 504; they have not changed since then, for vaginal hysterectomy was repeatedly done at his hospital last summer.

Pozzi does vaginal hysterectomy for the following conditions:

1. "Diffuse suppuration of a chronic nature involving all the tissues around the appendages and giving rise to such disorders that ablation of a limited pocket would seem to be of little value or impracticable."

2. "Non-suppurative, very adherent, chronic conditions forming a mass in the pelvis. In these instances the chronicity of the affection, as well as the exacerbations of pelvic peritonitis, should be considered. The surgeon should not diagnosticate invincible adhesions without due reflection. It is perfectly possible that an erroneous idea of the condition may be obtained from examining the patient during an acute attack; here the edema of the deeper tissues deceives the examiner."

3. "Continually discharging fistulæ of the abdominal wall or vagina succeeding celiotomy (with or without drainage), and not yielding to curetting, to dilatation, nor to operation, with a view of finding the suture which causes the fistula. This must not be construed into an argument against celiotomy, for I have had to open the abdomen to extirpate appendages in a suppurative state, complicated with fistula, after vaginal hysterectomy."

4. "Persistence of adnexial tumors which are painful, existing after celiotomy. I have had to do the same thing after vaginal hysterectomy." Pichevin practically admits the same, but admits as an additional reason,

5. Fistulæ opening into the rectum or bladder and communicating with a pus cavity.

To complete the list we might add :

6. Incurable disease of the uterus persisting after removal of the appendages by celiotomy.

We might even add to these conservative indications that of Landau, which is,

7. Extensive disease of the uterus, such as parenchymatous metritis, etc., complicated with double purulent salpingitis. He insists on removing the appendages, however, even if he is obliged to do a celiotomy at the same sitting to accomplish this result.

These, then, are the indications which are recognized by the conservative surgeons. Perhaps it would be better to say by surgeons who prefer to do celiotomy when this method seems to offer any chance for success.

But there are many operators, and their number is rapidly increasing, who think vaginal hysterectomy has a far wider range. Among them Richelot stands pre-eminent. His book, which has lately appeared, contains a most excellent *résumé* of the indications for vaginal hysterectomy. The whole subject is treated in a masterly way, and there is an absence of theoretical discussion

which, added to the simplicity of the style, makes the book most readable. All his cases (219) are given in full. He speaks from profound conviction, and such is his eloquence that one is impressed by what he says.

Richelot, Ségon, Péan, and others operate all cases by vaginal hysterectomy in which the bilaterality of the inflammatory trouble can be demonstrated. This includes the lighter forms of salpingitis and ovaritis, provided operation is imperative. They believe the results are better than in celiotomy. When, however, the bilaterality of the affection has not been demonstrated, and particularly if the patient is young, celiotomy is to be preferred.

Richelot operates complicated cases of retroversion by the vaginal method. By complicated cases are meant those in which the uterus is firmly bound down in Douglas' cul-de-sac and gives rise to severe metrorrhagia; in these conditions the ovaries are prolapsed and diseased. The symptoms calling for the operation are severe pains in the thighs and back, and a condition of nervous debility which makes the woman unfit for anything. He has operated 21 times under these circumstances, with complete cure in all cases.

The social condition of a patient has to be taken into consideration in deciding the question of radical operation. A woman who has to work for a living, and who perhaps has been undergoing so-called *treatments* at various hospitals and receiving absolutely no benefit from them, will frequently accept an operation which will free her from the pains from which she has suffered months and months. On the other hand, a woman who has nothing to do, and who can devote a proper amount of time and care in following out a course of treatment which is intended to be palliative only, may by so doing be made so comfortable that it would be unwise to recommend any radical procedure.

Richelot does not hesitate to do vaginal hysterectomy under circumstances like the following: The woman belonged to the working class; she was 42 years old and had had thirteen children at term. Ten months before entering the hospital she had a miscarriage. She was curetted one month after this mishap, and four months later Schröder's operation was performed. The hemorrhages continuing and becoming grave, vaginal hysterectomy was done in November, 1893; three months later she was seen and was in perfect health.

In cases of pelvic neuralgia resisting all forms of treatment,

vaginal hysterectomy gives remarkable results. Richelot's description of this disease is concise. He says: "The surgeon should operate with extreme caution. The severe forms of pelvic neuralgia are to be called manifestations of true hysteria without painful localizations in the pelvis. There is pain, but there is no pathological lesion. The diagnosis is to be made as follows: Local examination should be negative; the uterus should be normal in position, the cervix of normal size; the cul-de-sacs should have preserved their normal suppleness and should not be hard or indurated; but there is, with rare periods of lull, an exquisite sensitiveness on touching the cervix and cul-de-sacs and on moving the uterus while palpating bimanually; pressure on the iliac fossæ is also painful, and sometimes the surface of the abdomen can scarcely be touched even lightly without exciting exquisite pain. The patients suffer horribly; they walk bent double; some have to stay in bed all the time. During an acute exacerbation all the symptoms of pelvic peritonitis may be present, but on examination after the attack is over nothing abnormal is found. The length of the disease may be from one to thirty years or more. These patients are miserable and go from one gynecologist to another without receiving benefit. At last they become bedridden and they *die*." It has been said that simple celiotomy without doing anything whatever will cure these cases, the cure being mental. Richelot cites a case in which he did this without the least effect; nothing was done but simple exploratory incision. He has also met with cases in which the appendages were removed, there being slight lesions; in these, also, the neuralgic pain persisted after the operation. He now treats both conditions by vaginal hysterectomy with success. The following case happened in Richelot's practice: The woman was 38 years old. She had had three children and had been married twenty-one years. She had been ill twenty years. Her second confinement, seventeen years before, during which she was taken care of by Budin, proved to be severe. She had a rheumatic history and often suffered pains in the arms and shoulders. Her children were all nervous and had neuralgias. She had never had any hysterical attacks. Her stomach was irritable and she had to be careful about her food. For seventeen years she had attacks of severe pains in the pelvis; the accompanying symptoms were excessive tympanites, nausea and vomiting, anorexia, constipation, and filiform pulse—in fact, all the

symptoms of pelvi-peritonitis. The last attack lasted five weeks. When seen by Richelot she was in a moribund condition. His diagnosis was double pyosalpinx with peritonitis. When the attack subsided, however, a movable uterus slightly anteverted was found, and small appendages which could be easily felt; there was no induration whatever. She had been through an attack of pelvic neuralgia with a condition of peritonismus. Vaginal hysterectomy was done. The uterus was somewhat large, but the appendages normal. Seen five months later she reported herself perfectly well. Richelot has had sixteen similar cases, which were all cured with but one exception.

In cases of prolapse of the uterus vaginal hysterectomy is gaining many adherents, even though in many cases it proves to be a preliminary operation, a plastic one being required subsequently.

If a mistake in diagnosis has been made, and the operator finds a hematosalpinx or a cystic ovary when he expected to find tubal inflammatory disease, no embarrassment need be occasioned, for it is quite easy to treat these affections by the vaginal method. Hydrosalpinx and extrauterine pregnancy come under the same heading. Jacobs and Péan have reported many such cases.

Chronic endometritis deserves special mention. Reference is made to those cases which have resisted all forms of treatment, electrical and other. The patient suffers pain, constant leucorrhœal discharge, and is exhausted by repeated hemorrhages. Curetting has been tried without avail. In such cases vaginal hysterectomy is justifiable. Sutton has done it for a suppurative endometritis. The uterus was infiltrated with pus, but the appendages were not involved. The case was gonorrhœal. She recovered. During the past nine weeks Sutton has done the operation twice in cases in which a celiotomy with removal of appendages was unsuccessful in curing the patient. He has done it in another instance in which there was general inflammation of the uterus and appendages, and in still another in which the inflammation was complicated by cataleptic convulsions—all with success.

The operation has not been received with universal acclamation in America, and will doubtless meet with much resistance at first. But Sutton, Thomas, Engelmann, Lusk, and Coe, as well as others, believe that it is a decided advance in gynecology.

Mann, of Buffalo, believes that it is "the question of the day in gynecology, and its decision demands our best thought and our closest observation."

Illustrative cases.—*Picqué*:¹ A case of vaginal hysterectomy done for pelvic abscess with dense inflammatory adhesions filling the pelvis. The patient was 34 years old. She entered the Broca Hospital November 11th, 1891. Married at 19; eight months after marriage had a miscarriage, which was followed by pelvic pain in the region of the appendages. This subsided and for fourteen years she was well. Intrauterine instrumentation for sterility brought on chills and fever, and an abscess on the left side of the uterus which discharged into the vagina. She then had an extension of the inflammation on the right side. Vaginal examination showed a uterus which was impacted in the pelvic cavity and surrounded by inflammatory masses. Vaginal hysterectomy on November 19th, 1891. Twenty-five days later was discharged well. Seen January 20th, 1893, she reported herself perfectly well. The appendages were not removed.

Picqué:² Vaginal hysterectomy done subsequent to celiotomy; removal of the appendages did not cure the patient. The woman was 24 years old, and entered the Broca Hospital (Pozzi's) June 5th, 1891. She had gonorrhœa at 16 and an abortion six years later. Pozzi examined her and found on either side of the uterus a mass, that on the left as large as a small hen's egg, on the right as large as a mandarin orange. On June 20th the appendages were removed by celiotomy. On the right there was a simple non-purulent inflammation; on the left there was a little pus. Discharged July 29th. Returned in November of the same year on account of profuse leucorrhœa. Curetting done twice without result. Vaginal hysterectomy performed. Discharged well in December.

Terillon:³ A case of vaginal hysterectomy done eight days after celiotomy, it not having been possible to complete the latter operation owing to dense adhesions. The patient was 23 years old and had been sick three years following abortion. The uterus was immobilized by adhesions which extended up to the umbilicus. A celiotomy was done, but no attempt was made to remove the appendages, as it seemed impossible to remove them. Eight days later vaginal hysterectomy was done and the

¹ *Annales de Gynécologie et d'Obstétrique*, 1893, p. 176.

² *Id.*, p. 176.

³ *Id.*, 1891, p. 381.

patient got well. She had no more pain. The lesions were tuberculous.

Dewandre:¹ A case of vaginal hysterectomy done for general purulent inflammation involving uterus and appendages. The woman was 34. Married at 26 and pregnant eight times. Last confinement April 20th, 1893. In 1891 had a child at eight months. Since then has been ill. The uterus is imprisoned and immovably held between two masses. Vaginal hysterectomy June 3d, 1894. Uterus, tubes, and ovaries removed; all purulent; adhesions between tubes, omentum, and intestines separated with ease by the fingers. The cure was perfect.

22 HIGHLAND STREET.

No references have been given in this paper, because it was thought unnecessary. The statistics have been gathered from the leading French medical journals, notably *Annales de Gynécologie et d'Obstétrique*. The operation is a new one, and the references may be easily obtained from the "Index Medicus." The most prolific writers on the subject are Richelot, Ségond, Péan, Quenu, and Doyen.

¹ Bulletin de la Société Belge, 1894, No. 5.

