

TUBERCULOUS PERICARDITIS.

BY WILLIAM OSLER, M.D., F.R.C.P. LOND.,
PROFESSOR OF MEDICINE IN THE JOHNS HOPKINS UNIVERSITY AND PHYSICIAN-IN-CHARGE
TO THE JOHNS HOPKINS HOSPITAL.

TUBERCULOSIS follows hard upon rheumatic fever as a cause of pericarditis. The affection is usually overlooked clinically, and possibly in some cases anatomically. In 1000 autopsies, the majority of which were made at the Montreal General Hospital, there were 275 cases with tuberculous lesions, in 7 of which the pericardium was involved. Its relative frequency may be gathered from the following figures, furnished by Dr. Welch's records at the Pathological Laboratory of the Johns Hopkins Hospital. Of instances of pericarditis, 6 were tuberculous. Of late years attention has been called to the frequency of its occurrence, and yet the records in the literature are not very numerous; thus, the *Index-Catalogue* contains only thirty references, and the *Index Medicus* to July, 1892, only twenty-seven. The *Transactions* of the Pathological Society of London include but five cases to date.

The following is a brief summary of the cases which have come under my observation in Montreal, Philadelphia, and Baltimore:

CASE I.—Female, aged forty-three years; sixteen ounces of dark exudate in pericardium; general miliary tuberculosis.

CASE II.—Male, aged five years; caseous masses and fresh villous exudate; miliary tubercles on the peritoneum and in lungs; bronchial and mediastinal glands caseous.

CASE III.—Female, aged thirty-eight years; chronic pulmonary tuberculosis; fresh tuberculous pericarditis.

CASE IV.—Male, aged sixty-four years; acute tuberculous pericarditis; acute tuberculous pleurisy; chronic pulmonary tuberculosis.

CASE V.—Male, aged fifty years; chronic pulmonary tuberculosis; recent tuberculous pericarditis.

CASE VI.—Male, aged forty-five years; chronic pulmonary tuberculosis; chronic tuberculous pericarditis.

CASE VII.—Male, aged twenty-eight years; chronic pulmonary tuberculosis; tuberculosis of pleura; acute tuberculous pericarditis.

CASE VIII.—Mary B., aged thirty-six years; tuberculous pyelitis; fibro-caseous changes at the apices; sixteen ounces of turbid hemorrhagic serum in pericardium; thickening of the layers.

CASE IX.—John G., aged fifty years; tuberculous mediastinal

abscess; tuberculous infiltration of parietal layer of pericardium; acute pericarditis.

CASE X.—Max S., aged forty-five years; primary tuberculosis of bowels; chronic tuberculous pericarditis, the membranes from three to four lines in thickness; bronchial glands caseous.

CASE XI.—Male, aged seventy-two years; death from pneumonia; heart hypertrophied; pericardium adherent, greatly thickened, and tuberculous; calcification of bronchial glands; no other tubercles in body.

CASE XII.—John T., aged sixteen years; tuberculous cerebro-spinal meningitis; tuberculosis of mediastinal glands; old tuberculous pericarditis.

CASE XIII.—Moses B., aged twenty-four years; tuberculosis of mediastinal glands; chronic tuberculous pericarditis; dilatation of heart; a few tubercles in lung.

CASE XIV.—Wm. H. T., aged fifty-two years; dropsy; hypertrophy and dilatation of heart; chronic tuberculous pericarditis; fibroid tubercles in lungs; miliary tubercles in viscera.

CASE XV.—John P., aged thirty-eight years; dropsy and dyspnoea; tuberculous pericarditis with effusion; tuberculous pleurisy; old foci in lungs.

CASE XVI.—Emma B., colored, aged thirty-nine years; dyspnoea, cough, and anasarca; tuberculous pericarditis, with effusion; tuberculosis of mediastinal and bronchial glands; scattered tubercles in lungs, liver, and spleen.

CASE XVII.—John C., aged sixty-five years, admitted with cough, fever, and signs of consolidation at left base. Death on second day after admission. Chronic pulmonary tuberculosis; fresh tuberculous pneumonia; arterio-sclerosis; patch of recent tuberculous pericarditis.

ETIOLOGY.—Tuberculous pericarditis is not limited to any age. The youngest of my cases was a child of five years; the oldest a man of seventy-two years. Parrot, Duckworth, Rolleston and Letulle have reported cases in infants under a year. In Brackmann's Göttingen Thesis, of 65 cases collected from the literature 19 were in children. It does not seem to be at all uncommon in old men, and there are two cases on record in octogenarians. Males seem more prone to the disease than females; there were only four women on my list.

Tuberculous pericarditis is due in a majority of instances to infection of the membrane from caseous mediastinal lymph glands. The disease may be confined to these glands and to the pericardium; thus, in Case XI. of my series, the patient, an old man, aged seventy-two years, died of pneumonia after a short illness. There was no tuberculosis of the lungs or other viscera; the pericardium was thickened, both layers adherent, and presented cheesy masses and gray nodules. The heart was enlarged, weighing seventeen ounces. The mediastinal glands were calcified, particularly the bronchial group. Case IX. is of special interest, showing the mode of extension from the anterior mediastinum to the pericardium. The patient, a man aged fifty years, had pulmonary

tuberculosis, and died of acute tuberculous pleurisy with sero-purulent exudate. Upon the external layer of the pericardium, three and a half inches in extent, was a flattened tuberculous abscess with cheesy and purulent contents. The subjacent pericardium was much thickened, and was itself cheesy, and inflammation had extended through and produced an acute fibrinous inflammation of both layers with very little fluid exudation. Tubercles could not be seen. This association of disease of the mediastinal lymph glands with pericarditis has long been recognized. Zenker laid special stress on it in his paper on the traction diverticula of the œsophagus, caused by diseased lymph glands, and of his 54 cases there were 9 instances of total and 1 of partial synechia of the pericardial layers. Of the 101 instances of disease of the lymph glands of the mediastinum, collected by Beréty, the glands were caseous in the 18 cases in which the pericardium was involved. Kast, who quotes these figures, reports an instance (*Virchow's Archiv*, Bd. xcvi.) of acute tuberculous pericarditis due to perforation of a purulent mediastinal lymph gland into the pericardial sac. In children the affection is in all probability most commonly transmitted in this way from mediastinal and bronchial glands. In Case II., a child aged five years, the bronchial glands were greatly enlarged, projected deeply into the lung tissue, and presented on section a uniform caseous appearance. Both layers of the pericardium were greatly thickened; their adjacent surfaces roughened and irregular; not covered with the usual false exudation, but presenting strands of firm tissue, and flat, slightly elevated caseous masses, which were yellow-white in color, and equally distributed on both layers. There were scattered miliary tubercles in the lung, on the peritoneum, in the kidneys, and in the liver, and these were in all probability entirely secondary to the advanced bronchial and pericardial disease.

A second, less common, mode of extension is from the pleura or from the lung. A very good illustration of this was recently met with in Case XVII., a man aged sixty-five years, who was admitted to ward F of the Johns Hopkins Hospital with acute tuberculous pneumonia, and died on the following day. There was old disease of the lungs, and both acute and chronic tuberculous pleurisy. The left lung was strongly adherent to the pericardium, the cavity of which contained a small amount of clear fluid. The inner surface of the parietal layer was smooth, and presented a number of ecchymoses. At the superior reflection, where it was adherent to the underlying thickened and infiltrated pleura, there was an eruption of fresh gray miliary tubercles.

And, lastly, there are instances in which the pericardium appears to be involved with the pleura and peritoneum in a general tuberculosis of the serous membranes. In some of these cases the extension can be shown to have been directly from the pleura and pericardium into the

peritoneum, while in others it would appear that the extension was from the peritoneum into the serous membranes of the thorax.

MORBID ANATOMY.—The picture is extremely varied. Practically there are two groups of cases: those with firm adhesions between the pericardial layers, usually with great thickening; and those with recent exudation, fibrinous, sero-fibrinous, hemorrhagic, or purulent. The cases with adhesions are the most numerous. Of the 17 cases in my series, 2 cases, Nos. IX. and XVII., may be excluded, as in the first there was only tuberculous infiltration of the parietal layer, and in the other an eruption of fresh miliary tubercles alone. Of the remaining 15 cases, in 6 only was there thickening of the layers without exudation. The statistics, however, of Rousseau (Paris Thesis, 1882) and Lancereaux show that the chronic adhesive form is most common. Of the 35 observations analyzed by the former, in 21 there was adherent pericardium; while in 12 of Lancereaux's 14 cases there were adhesions.

Both layers are, as a rule, uniformly thickened, and in the extreme instances it is impossible to separate them at any point. In other cases the process is more local, and the synechia may be limited to the front of the heart, leaving large portions of the base and of the left auricle free. The reflection of the pericardium at the great vessels and the adjacent mediastinal tissues may be uniformly infiltrated and the vessels surrounded by a solid mass. In Case X. "the layers of the pericardium were adherent and measured six to ten mm. in thickness, and showed groups of tubercles, many of which had fused together in uniform cheesy masses. The tubercles and caseous masses can be readily distinguished in each layer, since between them there is an infiltrated connective tissue which is free from tubercles. At the base of the heart the thickened pericardial layers formed a solid cheesy mass surrounding the aorta."

The membranes may reach a thickness of from three to ten millimetres, the increase being due to the growth in the leaves of tubercles, the development of caseous masses, and to the new growth of connective tissue. Frequently it can be seen that the two enormously thickened layers are united by a clear, infiltrated tissue, which may itself not present any tubercles. In the earlier stages of this process the membranes are little, if at all, thickened, the tubercles are seen just beneath the endothelial layer, and there may or may not be a fresh exudate of yellowish fibrin. In other instances the contiguous surfaces of the thickened layers are covered with flat, yellowish caseous masses, as noted in Case II. Collections of thick cheesy pus are occasionally found between the layers.

The condition of the heart in this chronic adhesive form is most interesting. As is usual in adherent pericardium, particularly when the layers are very thick, there is enlargement of the organ, which may

reach an extreme grade. In Case XIV. the heart with the thickened pericardial membranes weighed thirty-six ounces. At the time of death the cardiac muscle is more or less degenerated, and may show fatty or fibroid changes. The tuberculous process rarely invades the ventricular muscle, though the thin auricle may be much infiltrated, as in Case XV., in which the appendix was converted in great part into cheesy material, only a thin film of muscle substance remaining.

In the cases with effusion there may be—(a) a simple plastic exudate similar to that of ordinary rheumatic pericarditis, with little or no serous effusion, and with scarcely any thickening of the membrane, the eruption of miliary tubercles alone indicating the nature of the process. More commonly there is (b) extensive sero-fibrinous exudate, consisting of flakes of lymph and a turbid serum. When the process lasts for any length of time, the membranes, as in Cases XV. and XVI., may be very greatly thickened and the anatomical picture may resemble very closely that of a fatal case of rheumatic pericarditis. The tubercles, however, can be seen with distinctness in the membranes, and there are usually flat areas of cheesy infiltration beneath the fibrinous layers. (c) In some cases the exudate is hemorrhagic, as in Cases I. and VIII. of my series. The membranes here may be deeply engorged, and hemorrhagic foci may be seen in them. The color of the effusion may be bright red, but is more commonly a reddish-brown or chocolate color. The amount of the effusion may be large, ranging from 500 c.c. to 2000 or 3000 c.c. An instance of most extensive effusion has been reported by Musser, with whom, when his colleague at the Philadelphia Hospital, I had an opportunity of seeing the case. The patient, a colored man, aged twenty, was admitted to the Philadelphia Hospital on the fifth week of an illness characterized by cough, dyspnoea, and irregular chills. There was extreme orthopnoea. There was absolute dullness over the greater part of the left chest from the second rib in front and from the middle of the scapula behind. There was an area of modified tympany along the vertebral column in the infra-scapular region. Thirty-seven ounces of a bloody fluid were aspirated, presumably from the pleural cavity. A distinct friction sound was heard after the aspiration, and it was thought that he had both pleurisy and pericarditis. At the post-mortem the pericardial sac contained sixty-four ounces of bloody serum. There were tubercles in both layers of the pericardium, also in the left pleura. The bronchial glands were enlarged and caseous. And, lastly, (d) the effusion may be purulent, and this, too, apparently from the outset and not following paracentesis. The exudation may be enormous, and the cases have been diagnosticated as left-sided empyema. In Kast's case, already referred to, the inflammation was due to perforation of a softened mediastinal lymph gland into the pericardium. No instance of purulent exudate has come under my direct care.

CLINICAL HISTORY.—We may recognize four groups of cases.

First group: Latent tuberculous pericarditis. A considerable number of all the cases on record belong here. The disease is discovered accidentally in individuals who have died of other affections, or of chronic pulmonary tuberculosis. An interesting illustration of this was Case XI., a well-nourished old man of seventy-two years, who was admitted to my wards in the Philadelphia Hospital with pneumonia, of which he died. There was no suspicion whatever that the pericardium was involved. As already mentioned there was found an adherent, greatly thickened, tuberculous pericardium; calcification of the bronchial glands, but no tubercles in other parts of the body.

In Cases VI., XII., XIII., and XIV. the disease was also latent, and there was no suspicion of pericarditis during life.

Second group: With symptoms of cardiac insufficiency following the dilatation and hypertrophy consequent upon chronic adhesive pericarditis. The clinical features are really those of cardiac dropsy.

CASE XIV.—W. H. T., aged fifty-two years, admitted to ward F of the Johns Hopkins Hospital, June 27th, 1889, complaining of shortness of breath, swelling of the legs, and incontinence of urine.

Family history good. Father died of acute pleurisy, mother of old age, two brothers died when young.

The patient has had scarlet fever, measles, and malaria; denies syphilis. Has had rheumatic pains, but has never been in bed with acute rheumatism. Has used tobacco freely, alcohol in moderation. He was well and strong until two years ago, when he had a "bilious attack," and was in bed three weeks. He was well last winter until February, when he began to be short of breath and had a cough, which has lasted until the present time. About four weeks ago the shortness of breath increased, and his feet became swollen.

Present condition: An emaciated man, with dry, harsh skin; legs and scrotum œdematous; abdomen not swollen. Pulse, 104, tension increased; temperature, 102°.

Heart: Apex beat faintly visible in the fourth interspace; palpable in the nipple line; feeble. Cardiac dullness begins as high as second left interspace, near sternum. To the right it extends 2.5 cm. beyond the sternum; there is no thrill. The sounds are feeble; the second louder, more marked than the first. At the apex the diastolic pause is shortened—the sounds succeed each other at equal intervals of time; the second, at the left margin of sternum, is reduplicated.

Careful examinations of the heart on the 1st and 2d of July showed as a special feature the flatness extending into the second left interspace; the impulse was extremely feeble; the sounds were clear, and in the third and fourth interspaces quite loud; the second was accentuated. At the aortic cartilage the second was feeble.

Lungs: Clear anteriorly; resonance defective at right base. There were numerous râles at base and cracking râles over the left mammary region.

Abdomen: Soft; liver and spleen normal.

Urine clear; no albumin, no casts; sp. gr., 1010.

The case was regarded as one of cardiac hypertrophy and dilatation without valve disease. He was given tincture of digitalis every four hours, and saline purges.

He failed rapidly; the heart became very feeble; Cheyne-Stokes breathing developed, and he died on the morning of the 5th.

On admission the temperature was 102°, but after this did not rise above 99°, except on the evening of the 30th.

Abstract of autopsy (by Dr. Welch). Peritoneum smooth. In the thorax there were extensive adhesions on both sides. The pericardial sac was obliterated. The heart occupied an unusually large area. The surface was everywhere covered by a yellowish-white opaque layer, consisting of firm connective tissue and caseous matter, containing, especially on the surface, numerous gray and cheesy miliary tubercles. These exudations averaged 1 cm. in thickness over the whole surface, the thickest being over the outer surface of the ventricle. The heart, including the thickened pericardium and the base of the aorta, weighed thirty-six ounces. The myocardium was pale yellowish-brown, soft, with mottled fatty degenerations beneath the endocardium. In the apex of the left ventricle there were a few parietal thrombi. The thickness of the wall of the left ventricle was 18 mm.; of the wall of the right, 6 mm. The cavities were dilated; the aortic valves slightly thickened, but competent. The mitral orifice admitted three fingers. The valve segments were a little thickened. There were small gray tubercles on the endocardium of the right auricle about the orifice of the superior cava.

The lungs were œdematous and deeply pigmented; they contained many gray, fibroid, not cheesy tubercles.

There were abundant miliary tubercles on the omentum. The spleen contained a few miliary tubercles. The kidneys presented a number of opaque caseous masses, many in streaks. The liver also presented a few tubercles. In the intestines there were a few scattered miliary tubercles in mucous and submucous layers, but no ulcers. There were no tubercles in the brain.

In the chronic adhesive form of tuberculous, as of simple, pericarditis, the clinical features may be those of cardiac dropsy, and a diagnosis is made either of simple hypertrophy and dilatation of the heart when, as in the case just given, there are no special auscultatory signs, or of mitral insufficiency when there is at the apex a loud blowing murmur. The diagnosis of adherent pericardium, always uncertain, is doubly so in cases admitted with dyspnoea, dropsy, and the signs of cardiac dilatation, since under these circumstances it is almost impossible to make a satisfactory physical examination.

Third group: Acute tuberculous. The clinical picture may be that of an acute tuberculous, either general or with cerebro-spinal manifestations. The following is a good illustration of an acute miliary tuberculous, the primary disease being in all probability in the mediastinal glands and pericardium:

CASE XIII.—Moses B., aged twenty-four years, admitted to ward F of Johns Hopkins Hospital, January 25, 1890, complaining of cough and loss of strength. Owing to mental dulness and apathy it was difficult

to get any satisfactory information from the patient as to his family or personal history. He states that his present illness began only three weeks ago, though he has had a slight cough all winter. Since the onset of the illness he has been in bed and has had fever, cough, and night-sweats. There has been loss of appetite and great weakness.

Present condition: Temperature, 100.8°. Patient looks very heavy and dull; there are sordes on the lips, and the tongue is covered with a brownish fur. The skin shows traces of a squamous syphilide and there are well-marked nodes on the shins. The respirations are 37. The expectoration is muco-purulent and is at times blood-tinged. The physical examination of the lungs gives clear percussion resonance, the note perhaps a little higher in pitch at both bases behind. Anteriorly there are numerous piping and moist râles on the left side below the third rib; behind, the râles are universal.

Heart: Apex beat in fifth interspace below the nipple. The area of dulness does not appear to be increased. The first sound is very feeble and muffled at the apex, and possibly accompanied with a soft murmur. The second sound is well heard at the base, and both sounds are unusually loud to the right of the sternum in the sixth intercostal space. The examination of the abdomen is negative.

During the three days the patient was in the hospital there was irregular fever (from 101° to 103°), increasing debility, with hurried respirations, tremor of the extremities, and gradual failure of the heart. The bubbling râles were so numerous with inspiration and expiration, that it was impossible to hear the heart sounds. The examination of the sputum was negative. The urine was dark-yellow in color, acid, trace of albumin, and there were several casts seen. The diagnosis of acute tuberculous was made.

Autopsy (by Dr. Welch). Abstract: Body of a large, strongly built, well-nourished, muscular man; macular eruption present on the skin; large node on the left tibia.

No special changes in the brain.

The deep cervical glands slightly enlarged, containing numerous small tubercles and caseous areas. Extensive pleural adhesions on both sides. Both layers of the pericardium were adherent over the entire heart, greatly thickened, and contained in the membranes numerous miliary tubercles. The anterior mediastinal lymph glands were enlarged and presented numerous miliary tubercles and caseous masses. The heart was enlarged and dilated. The length of the left ventricle from apex to edge of aortic valve, 13 cm.; thickness of wall of the left ventricle, 16 mm.; the columnæ carneæ in the left ventricle were extremely prominent.

The lungs were congested throughout, œdematous, and contained scattered tubercles surrounded by areas of pneumonia. No caseation except in the tubercles themselves. The mesenteric glands were enlarged and those near the spleen were caseous. The kidneys showed much fatty degeneration in the convoluted tubules.

In the following case the tuberculous was chiefly manifested in the cerebro-spinal meninges, and the clinical picture was that of ordinary tuberculous meningitis:

CASE XIV.—John T., aged sixteen years, admitted to ward F of Johns Hopkins Hospital, November 5, 1889, complaining of pain in back and head. Patient is well-nourished, not emaciated.

His mother is dead; father, five brothers, and six sisters living and well; does not know of what his mother died; says he has been ill for three weeks with headaches, tired feelings, pains over the body. He has been obstinately constipated for ten days; has been in bed for two weeks; says he had a chill a week ago. When admitted he looked very ill; temperature, 95°. After having been in bed for two hours with hot bottles to his feet, temperature rose to 98°. He passed a quiet night; temperature rose to 101° at 8 P.M.; pulse, 72.

On the 6th, the examination revealed the following: Tongue heavily coated, white. Patient is rational, answers questions well, but shows a great dislike to be moved in bed; lies on the left side with the head a little drawn back, and when an attempt is made to move him he resists, saying that it is painful. There is no paralysis; pupils are of medium size and active. Abdomen not swollen, not tender. Spleen not enlarged. Heart sounds are clear at apex and at base. Examination of lungs negative.

On the 7th and 8th he was much worse; became apathetic; rambled; the temperature ranged from 97° to 102°. Heart was examined again on the 8th, and the note reads: "Sounds at apex and base are quite clear."

On the 9th and 10th the meningeal symptoms were more pronounced; he became unconscious and the discharges were passed involuntarily. At times the arms and legs seemed a little stiff, resisting flexion. Pupils moderately dilated; convergent squint in left eye; the retinal veins slightly distended and engorged; no swelling of the disks, but the physiological cupping was absent.

On the 11th there was a good deal of rigidity of the arms and of neck. Abdomen retracted. Death took place on the morning of the 12th.

The case was regarded as one of meningitis, probably tuberculous. There were no features calling special attention to the heart.

Autopsy (by Dr. Welch). Abstract: In thorax, glands at root of neck and in mediastinum enlarged and caseous. A very large caseous gland lay just beneath the ensiform cartilage. One was closely adherent to the pericardium. Some of these glands were full of miliary tubercles. The external surface of the pericardium was thickly studded with small tubercles. The two layers of pericardium were adherent, and between them was a mass of partly caseous, partly gelatinous-looking tissue from two to fourteen millimetres in thickness. Over the left ventricle was a small cavity filled with cheesy pus. The heart weighed 542 grammes. The muscle substance was firm. Wall of left ventricle, 14 mm.; of right, 3 mm. Valves were normal.

The lungs presented numerous irregular areas of hemorrhage, chiefly beneath the pleura. There were no tubercles. On the pleural surface of the diaphragm, extending from the pericardium on the right side, there were a few miliary tubercles. No special changes in liver, spleen, and kidneys. The brain and spinal cord presented a typical picture of tuberculous meningitis.

Fourth group: Cases with symptoms of acute pericarditis. This group, the most important in many respects, includes cases in which the pericarditis is acute and accompanied with more or less exudation of a sero-fibrinous, hemorrhagic, or purulent character. Here,

too, the process may be latent, as in Case VII., a young man aged twenty-eight years, who died under my care, of hæmoptysis. There was chronic tuberculosis of both lungs with extensive pleural adhesions. "The layers of the pericardium were united by soft adhesions, which could be readily torn through. On each membrane were innumerable small granulations, and here and there a nodular tubercle from one to two millimetres in diameter." This case is of special interest, as it shows the first stages of the process which ultimately causes enormous thickening of the pericardial membranes with universal adhesions. The tubercles, when small, may be readily overlooked. Acute plastic pericarditis in chronic tuberculosis is not, however, always due to the eruption of miliary tubercles. In two recent autopsies on patients with chronic pulmonary tuberculosis dying in my wards there was simple pericarditis without a trace of tubercles, and with little or no exudation. The following case, which was admitted to ward E under the care of Dr. Thayer in my absence, illustrates the mode of onset and the clinical features of a tuberculous pericarditis which came on in a strong, well-developed, muscular man, and proved fatal within three weeks:

CASE XV.—John P., aged thirty-eight years, admitted August 18th, with swelling of the legs and dyspnoea. The family history is good. He has been, as a rule, healthy, though in his childhood and youth he had many of the infectious diseases. He has been a moderate drinker. He denies syphilis. The present illness began about two weeks ago with pain in the left shoulder and about the heart. Feet began to swell ten days ago, and he has had cough and shortness of breath for about the same length of time. He has had no nausea; his appetite has been fairly good. Within the past few days he has become much worse.

On admission the patient had intense orthopnoea; pulse 130, but moderately full. He had a distressing cough, with clear watery expectoration. There was great oedema of the lower extremities and of the scrotum. The finger-tips and mucous membranes were bluish in color. In the examination of the heart at the time no murmur could be detected, but the second sound was accentuated at the pulmonary cartilage.

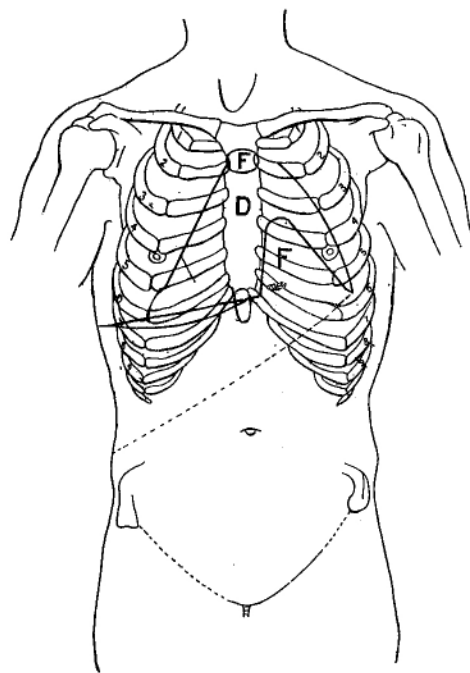
On the following morning the patient was quiet; respirations 28 to the minute; pulse 84, the beats irregular both in rhythm and force, the volume fair, and tension not diminished.

Thorax apparently symmetrical, but the manubrium very prominent, expansion equal. In front, resonance on both sides good, though on the left side flatness begins at the fifth rib midway between the nipple and axillary line, and the dulness seems here to be somewhat movable. There are numerous sibilant and sonorous râles to be heard in front. Passing down the left side and into the axilla, the breath-sounds become more feeble and fine moist râles are heard. Pitch of resonance at the extreme left base is higher than at the right, and the vocal resonance is somewhat diminished.

On auscultation there are numerous coarse and medium fine râles to be heard at both bases. At the extreme left base the respiratory murmur is almost absent.

Heart: Point of maximum impulse difficult to localize; slight general heaving over the whole præcordial area; relative dullness begins above at second rib and extends well to the right of the sternum. The prominence above noted is just at the junction of the manubrium and gladiolus, and just at this point there is dullness over a very limited area. Relative dullness extends outward to a point nearly 5 cm. outside

CHART I.



D. Dull area. F. Flat area.

the nipple. (Chart I.) The heart-sounds are heard with the greatest intensity at the fifth space a little inside of the nipple line. There the first sound is full and booming; the second not so loud. Passing inward toward the sternum the sounds become associated with a superficial, soft, squeaking sound, diastolic in time, heard loudest over the mid sternum, and pericardial in character. This is heard faintly all over the base. The murmur is more distinct in forced expiration than during inspiration. The second pulmonic is a trifle louder than the second aortic sound. The radial pulses are equal in volume, and there is no pulsation in the upper sternal notch; there is no tracheal tugging. The examination of the abdominal organs is negative. The urine is yellow-colored, acid, sp. gr. 1024, distinct trace of albumin; several hyaline casts were found. Throughout the 20th and 21st the patient remained in much the same condition. On the 22d there was a slight rise in temperature to 100.5°; the pulse varied greatly in rate and character; at noon was slow, regular, and full, from 70 to 90 per minute,

and again was as rapid as 140. The patient, in many respects, was better. The œdema of the legs had disappeared. The urine had increased in quantity. On the 19th only 180 c.c., and on the 20th 350 c.c. had been passed. On the 21st and 22d the amounts were 700 and 1100 c.c.

23d. The temperature has been between 97° and 98°; at the morning visit the pulse was 148, regular in force and rhythm; the respirations 32. The patient was lying quietly on left side. The physical signs practically those noted above with the exception that there is an extension of the œdema at the bases of the lung. The patient died suddenly at 4.30 P.M. to-day.

Autopsy (by Dr. Flexner). Large, muscular man; moderate œdema of the legs and of the subcutaneous tissue of trunk. Fat well retained, both beneath skin and in omentum and mesentery.

Pericardium is adherent to the left pleura; the sac thickened and contains a considerable amount of clear serum. Both layers are covered with a thick fibrous deposit, looking like a hairy coat. The thickness of the pericardium over the heart is 3 mm. When incised the thickened layer is grayish in color, with many opaque or yellowish points scattered here and there, often continuous, and having the well-recognized characteristics of tubercles of this membrane. The heart was greatly enlarged. The valves were normal. The thickness of the left ventricle was 17 mm.; length of ventricle, 8½ cm.; mitral orifice, 10½ cm. in circumference. Thickness of right ventricle, 6 mm.; tricuspid orifice, 12 cm. in circumference. The walls of the auricular appendix are almost completely converted into a grayish-white material with only a thin internal film which appears like muscle. In the endocardium of the left ventricle are numerous ecchymoses. There are also a few small ones on the right ventricle and in the auricles, and on the endocardium of the auricles are a few small, round, whitish miliary tubercles.

The left pleura is much thickened; parietal and costal layers adherent in places, but where not in actual contact there is clear serum between them. The costal pleura strips up with difficulty, and is very hard and cuts like cartilage. The diaphragmatic pleura is especially thickened, and on section it is seen to be composed of a dense, almost cartilaginous, grayish tissue, containing yellow, opaque, caseous masses. The apex of the left lung is retracted, hard to the touch, and on section contains a dense, deeply pigmented connective tissue, and old areas of caseation; no calcification. There are a few small foci of miliary tubercles, and scattered fibrous tubercles elsewhere in the lung.

The right lung is voluminous, and in the greater part of its extent free from adhesions, but the pleural surfaces present numerous grayish-white elevated masses, single and conglomerate, which can be scraped off with difficulty. The costal pleura presents similar tubercles. About these there are, here and there, fresh fibrin. In the apex the upper lobe presents a few foci of fibrous miliary tubercles.

The spleen contains a few scattered tubercles. Nothing of note in the abdominal viscera; the intestines did not present tubercles.

Here there was no suspicion before death that the process was tuberculous, nor in reality was there any clew to indicate that this was the possible nature of the trouble.

The following instance is the only one which has come under my

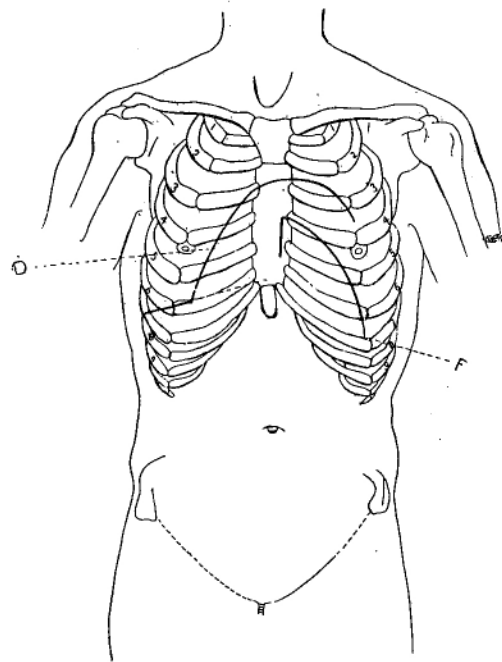
notice, in which the diagnosis of tuberculous pericarditis was made with reasonable degree of probability.

CASE XVI.—E. B., aged thirty-nine years, washerwoman, colored; admitted to ward G of the Johns Hopkins Hospital, July 18, 1892, complaining of pain and swelling in the abdomen, swelling of the feet, and cough.

So far as could be gathered the family history is good. She has two brothers and four sisters living and well.

The patient is a married woman, has had two children, one miscarriage. Has had uterine trouble at times, but has been quite regular until

CHART II.



D. Dull area. F. Flat area.

two months ago. Since childhood, during which she had the ordinary infectious diseases, she has enjoyed very good health.

Her present illness began early in May, when she had shortness of breath, nausea, loss of appetite, and pain in the abdomen. The symptoms which she narrated are indefinite, and she speaks of headache and attacks of diarrhoea. The main points are that she has, during the past three months, been in bad health, has lost in weight, has had difficulty in digestion, and shortness of breath. About a month before admission she noticed some swelling in the abdomen, and about the same time the face became puffy. The feet began to swell four days ago. She has sometimes had attacks of coughing at night, but no expectoration. On

admission, the note made by Dr. Thayer was as follows: Rather sparsely nourished woman; dorsal decubitus; lips and mucous membranes somewhat pale; tongue slightly coated; respirations 30 per minute; pulse 104, regular in force and rhythm, tension not increased; temperature on admission 98.2°.

Expansion equal on both sides of the thorax. Percussion everywhere clear. On auscultation the only abnormal signs are fine moist râles during inspiration at both apices.

Heart: There is slight heaving in the cardiac area; the point of maximum impulse is hard to determine. The area of cardiac dullness, as indicated on Chart II., begins about the second rib and extends far to the right of the sternum. Flatness begins at the third. The general outline of the area as indicated is triangular, and it extends to the left, far down into the seventh interspace. This flatness in the cardiac region is distinctly movable.

On auscultation the sounds are feeble at the apex, become louder in the fourth and fifth interspaces, and are still more distinct at the base, where the second aortic sound is accentuated.

Abdomen: The abdomen is full, generally tympanitic, and the walls are a little tense. The liver flatness begins at the seventh rib in the nipple line, and extends five fingers' breadth below the costal margin. The edge is not distinctly palpable.

The spleen is not palpable.

There is now no swelling of the legs, but she states that they were swollen four days ago.

The urine was cloudy, acid, sp. gr. 1012; slight trace of albumin, no sugar, numerous leukocytes.

During the first ten days in hospital the patient improved. The temperature chart shows a great irregularity. The morning register was at 98° or 98.5°, and in the afternoon, between four and six o'clock, rising to 101°, sometimes to 103°. An ice-bag was placed over the heart and she was given stimulants. For the second ten days, from July 29th to August 8th, there was distinct improvement; the temperature was lower and only once reached 102°. On August 1st it was noted that the area of dullness was diminished, and there was a friction rub heard in the mid-sternal line—synchronous, however, with the respiratory, not with the cardiac movements. On the 3d it was noted that there was a well-marked rubbing friction heard in the second and third left interspaces, and heard as far out as the nipple line and over the sternum adjacent to these spaces. This was the first time since her admission that there was a well-marked friction sound. The pulse has been very variable, ranging from 98 to 112. The patient is brighter and seems to be improving.

Between August 8th and 20th the irregular fever persisted, and on several occasions rose in the afternoon to 103°. She complained at times of pain in the præcordial region and of general abdominal pain. The pulse has ranged from 100 to 125. The note on the 17th was as follows: "There is moderate heaving over the lower sternum and the epigastrium; the point of maximum impulse is rather difficult to determine. Relative dullness begins at the second rib and extends well to the right of the sternum. The absolute flatness, however, scarcely exceeds the normal limit. The heart-sounds heard at the outer limit of the dullness are very feeble, and the first is followed by a short systolic puff. Passing inward the murmur becomes louder, and it disappears above the fourth rib. In

the lower sternum there is a well-marked double friction murmur, soft, close to the ear, and resembling in this respect a pericardial murmur. The murmurs are more intense on forced inspiration."

From September 1st I saw the case daily.

September 11th. Note to-day was as follows: "The intermittent type of fever has persisted, temperature in the evening rising to 102.5°, and occasionally, as on September 6th, to above 103.5°. The pulse has been more rapid, frequently over 120. There has been a good deal of tenderness over the fourth and fifth costal cartilages on the right side.

"On percussion the flatness does not begin until the fourth rib, but extends beyond the right border of the sternum. The sounds at the apex are feeble, and there is heard here a slight pericardial friction murmur which becomes more distinct toward the ensiform cartilage. No endocardial murmur is heard. Of late the cough of which the patient complained on admission has become much more troublesome, but there is no expectoration. The percussion note at the left base is somewhat higher than at the right, and the breathing is feebler, and toward the axilla somewhat tubular in character. There are numerous râles at both bases. The abdomen is a little full and she complains of pain in it."

On the 13th a small quantity of muco purulent sputum was obtained which did not contain tubercle bacilli. During all this time, although the fever has persisted, she has, curiously enough, steadily gained in weight; thus on August 8th she weighed 104 pounds; on the 16th the same; on the 29th, 109 pounds; September 5th, 110; and September 13th, 114 pounds.

September 22d. The abdomen has become more swollen. On examination there was distinctly movable dulness, though fluctuation could not be readily obtained. There was tenderness in the region of the liver, but no nodular masses could be felt. The friction murmur up and down the sternum was more marked, and there was also heard on inspiration a creaking, leathery, friction sound. The physical signs in the lungs show increase in the râles which are heard over the whole of the right back. The tactile fremitus is a little increased, and resonance is defective at the right base. There is no pleural friction.

On the 25th it was noted particularly that the pitch of the percussion toward the outer side between the scapula and the axilla was higher, but without any trace of tympanitic quality. The pericardial murmurs are loud. During the past week the patient has been worse. There is more pain in the epigastric region, the cough is very worrying at night, and there is increasing œdema about the legs and the skin of the back.

At her own desire the patient was taken to her home on September 27th.

Up to September 1st the patient had been under the care of my first assistant, Dr. Thayer, and the case was regarded as one of pericarditis with effusion, and when he left for his vacation she seemed to be improving. During the time she was under my care I made her the subject of several very careful examinations, and repeatedly demonstrated the condition to the class of graduate students, and discussed frequently the probable nature of the trouble. The persistence of the fever and the marked involvement of the lungs suggested to my mind the possibility of the existence of tuberculosis. We could not, however, for some time obtain any sputa for examination, but after September

1st, on several occasions she brought up a muco-purulent, and once an almost purulent expectoration, which was very thoroughly examined with negative results. Notwithstanding, it seemed to me that the case was unlike any ordinary rheumatic or septic pericarditis, and I felt justified in dictating, the last morning I saw her, "that the protracted course of the illness, the signs of pulmonary trouble, and swelling of the abdomen, make it probable that the patient has tuberculosis." Three days after her return home she died, and we were fortunate enough to secure an examination, which was kindly made by Dr. Flexner. The following is an abstract of his report:

Autopsy. There was a considerable quantity of clear serum in the peritoneum, both layers of which were smooth. There were no pleural adhesions, no tubercles on either layer. The pericardial space uncovered by lung unusually large, measuring 15 by 20 cm. The parietal pericardium is everywhere free. The outer surface shows numerous white elevations, many of which are confluent and more massed in some places than in others. On incision the layer is greatly thickened, in places as much as 6 mm. About 300 c.c. of turbid serum escaped. The visceral layer was everywhere covered with flaky, yellowish-white fibrin. On section this layer is greatly thickened and contains numerous yellowish, caseous masses; thus the thickness of the wall of the left ventricle is 3 cm., nearly one-half of which is the thickened pericardium. At the root of the aorta are masses of caseous glands, adherent to the pericardium. The weight of the heart with the thickened sac was 1110 grammes. The chambers were dilated. There was no valvular disease.

The lungs were voluminous, contained many scattered and conglomerate tubercles, many of which were just beneath the pleura. There was diffuse bronchitis, but there were no cavities. The bronchial glands were caseous. Liver, spleen, and kidney contained tubercles; those in the spleen were large and caseous. There were a few small tuberculous ulcers in the small intestines. The mesenteric glands and the glands about the pancreas were caseous.

DIAGNOSIS.—The diagnosis of tuberculous pericarditis is extremely uncertain. In the large group of cases in which the membranes are thickened and united, the difficulties are those which pertain to the recognition of adherent pericardium, difficulties which are enormously enhanced by the state of cardiac insufficiency with which these cases usually come under observation for the first time. In children with a history of repeated attacks of rheumatism, the bulging præcordium, systolic retraction at the apex, the fixation of the upper limit of cardiac dulness, and the diastolic rebound, speak for adherent pericardium; and if in a case of this sort there has been no history of rheumatism, and if, on the other hand, there are indications elsewhere of tuberculosis, a probable diagnosis may be made. In the cases which set in as acute pericarditis, unless there are evidences of tuberculosis in other parts, as, for instance, in the left pleura or in the peritoneum, or there are signs of local disease in the lung and tubercle bacilli have been found in the expectoration, the diagnosis can rarely be made. The effusion may be

equally as great in tuberculous as in rheumatic pericarditis. If paracentesis be performed, the presence of a bloody exudate is decidedly in favor of tuberculosis; once, at least, tubercle bacilli have been found (Kast). The clinical features themselves offer no criteria, though it would seem probable that in the acute cases with sero-fibrinous exudation the course is more protracted and the fever more irregular than in the ordinary forms of pericarditis; and in such a case, as in XVI. in my series, the development of diffuse signs in the lungs may lead to a strong suspicion that the process is tuberculous.

TREATMENT.—It is not improbable that tuberculosis of the pericardium may, as a similar process in the peritoneum, recover completely. Possibly some of the cases of simple adherent pericardium are instances of healed tuberculosis. The chronic adhesive form persists in all likelihood for years, producing few if any symptoms until the compensation fails in the hypertrophied and dilated heart.

It is highly probable that a majority of cases which terminate in general synechia of the membranes present no clinical features; the process is slow, insidious, essentially chronic, and not associated with definite symptoms. A case which has set in acutely must be dealt with as any other form of pericarditis, the indications being, first, to limit, if possible, the intensity of the inflammation; and, secondly, to prevent the evil consequences of the presence of a large amount of fluid in the sac. We have no medicinal agents at our command which have any positive influence in controlling the ordinary inflammation of serous membranes. In *Guy's Hospital Reports* of a year or two ago, *propos* of the treatment of pericarditis, there is a story told of Sir William Gull which is worth quoting in this connection. "He once met a practitioner on a case of rheumatism, in which he detected a pericardial rub. He said nothing of this to the patient's friends, but approved the general treatment, and they came away together. 'Ob, Dr. Gull, it was very good of you not to let them see I had made that dreadful oversight. I cannot think how I can possibly have failed to detect the pericarditis.' 'Never mind,' said Gull, 'it is just as well; for if you had detected it, perhaps you might have treated it.'" There is one measure in the utility of which we may have great confidence, namely, the ice-bag applied continuously over the præcordium. It allays the pain when present, and appears to check the tendency to effusion, while under its use an exudate may be absorbed with rapidity. It is very much to be preferred to blisters or the thermo-cautery. In some instances the patients complain very much of the intensity of the cold of the ice-bag, and in such I was in the habit, in Philadelphia, of using Leiter's coil, through which the water flowed continuously, and it could be arranged to have any temperature thought necessary.

A second indication holds good in tuberculous as in other forms of

pericarditis—when the effusion reaches a certain grade, and the pulse is irregular and feeble, the color becoming bad, the respirations hurried, paracentesis should be performed, or, if necessary, the sac freely incised and drained.