

Hypothermia in the Surgical Treatment of Aortic Aneurysms (**)

Denton A. COOLEY, M.D., and Michael E. DE BAKEY, M.D. (*).
(Houston)

During recent years the treatment of aortic aneurysms by surgical excision has been established as the method of choice wherever conditions permit its satisfactory application (1, 5, 10). However, a number of factors primarily concerned with the nature and location of the lesion determines the operative method to be employed. In general, two types of procedures may be used for this purpose depending upon whether the aneurysm is fusiform or sacciform in type. In the treatment of sacciform lesions, for example, the procedure consists in tangential excision with repair by lateral aortorrhaphy. This is accomplished by isolating and clamping the neck of the aneurysm with a large minimal trauma clamp, excising the sac and repairing the wall of the aorta with multiple mattress sutures. This method is particularly well suited to syphilitic aneurysms of the ascending thoracic aorta and aortic arch. In these cases the aortic wall adjacent to the neck of the aneurysm is usually of leathery consistency and holds sutures well. Furthermore tangential clamping of the aneurysm does not interrupt circulation through the aorta itself, a factor of considerable importance at this high level.

For fusiform aneurysms involving the entire aortic circumference temporary cross clamping of the aorta is necessary in order to excise the lesion and replace the diseased segment of aorta with an aortic homograft or plastic prosthesis. During the period of occlusion ischemic damage to tissues located distally may occur and prevent a success-

(*) From the Department of Surgery, Baylor University College of Medicine, and the Jefferson Davis, Methodist, and Veterans Administration Hospitals, Houston, Texas.

(**) Supported in part by a grant from the Houston Heart Association, and the Cora and Webb Mading Fund for Surgical Research.

ful outcome. The level and duration of occlusion and length of the segment to be excised are important factors influencing the success of this method of treatment. Thus, in our experience with 140 consecutive cases of aneurysms of the abdominal aorta in which the aorta was clamped below the level of the renal arteries for as long as 126 minutes there has not been a single instance of serious ischemic effect upon tissues below the point of occlusion. Above this level the tissue most vulnerable to periods of temporary ischemia is the central nervous system. Based upon our experience with abdominal and thoracic aneurysms damage to other organs has not occurred following occlusion distal to the left common carotid artery. On the other hand, occlusion of the descending thoracic aorta at this level for 20 to 30 minutes will produce significant and often fatal spinal cord damage in a high percentage of cases. Thus in the removal of lesions involving the distal aortic arch and proximal descending aorta the prevention of this complication constitutes the principal problem.

To overcome this difficulty a number of approaches may be used including the use of temporary shunts around the excluded segment of aorta, general body hypothermia, and certain steps in the operation designed to minimize the period of circulatory occlusion. We have employed all of these methods and believe that each is of vital importance. This presentation, however, is concerned primarily with a consideration of the usefulness of hypothermia in the surgical treatment of aortic aneurysms.

At reduced body temperature oxygen demand of the tissues may be significantly diminished (3, 4). Experimental studies have demonstrated that hypothermia provides a definite protective influence upon the spinal cord during periods of high aortic occlusion (2,11). Thus, in our own experiments there was a striking reduction in the incidence of paraplegia after 60 minute periods of thoracic aortic occlusion just distal to the left subclavian artery. For example, 65 per cent of normothermic animals, but none of the hypothermic animals, developed paraplegia (11). These observations have been confirmed by our clinical experience. Among 5 cases of aortic aneurysm which involved the proximal descending thoracic aorta where the operation consisting of excision with homograft replacement was performed at normal body temperature, there were 3 survivors and all had manifestations of spinal cord injury although the symptoms were transient. Moreover, in one of the patients who died soon after operation there was evidence at autopsy of ischemic necrosis of the spinal cord. Thus spinal cord damage occurred in 4 of the 5 cases operated upon at normothermic levels (Table I). On the other hand, among 10 patients who underwent

resection of aneurysms of the proximal thoracic aorta under hypothermic conditions, none developed neurologic sequelae after operation (Table II). Moreover, in those who succumbed in the postoperative period there was evidence of normal motor function in the lower extre-

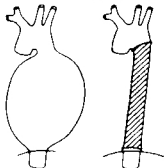
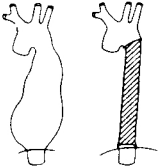
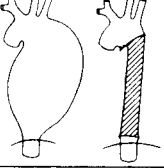
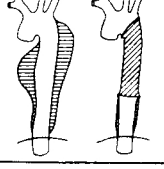
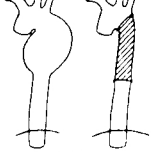
Case	Etiology	Date of Operation	Period of Occlusion	Location and Technic	Result
1. O.J. 50 ♂ C.	Syphilis	6-11-53	48 min.		Transient paraplegia
2. T.M. 58 ♂ W.	Syphilis	11-9-53	77 min.		Died -12 hrs. later Shock ?
3. M.W. 48 ♂ C.	Syphilis	11-23-54	88 min.		Died -30 min. later Heart failure
4. M.F. 40 ♀ W.	Dissection	1-11-55	34 min.		Transient paresthesias
5. M.H. 28 ♀ W.	Traumatic	1-21-55	41 min.		Partial paraplegia

TABLE I.

Patients undergoing excision of aneurysms of proximal descending thoracic aorta without hypothermia.

mities before death. In 4 patients in whom the aneurysm was located in the terminal thoracic aorta operation was performed under normothermic conditions and in none were neurologic sequelae encountered (Table III). From this experience it appears that hypothermia provides significant protection to the spinal cord during temporary occlusion

of the proximal thoracic aorta and that hypothermia may not be necessary in instances of temporary occlusion of the terminal thoracic aorta.

Fusiform aneurysms which involve the ascending and proximal

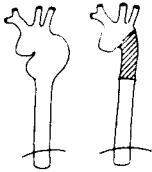
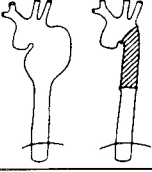
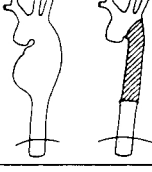
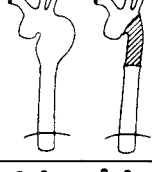
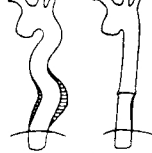
Case	Etiology	Date of Operation	Period of Occlusion	Location and Technic	Result
1. D.J. 18 ♀ W.	Congenital	1-1-54	53 min.		Died - 1 week later Septicemia
2. M.M. 31 ♂ W.	Traumatic	2-5-54	62 min.		Recovered
3. J.B. 66 ♂ C.	Syphilis	3-4-54	54 min.		Died - 8 hrs. later Secondary hemorrhage
4. F.V. 52 ♂ W.	Syphilis	7-5-54	58 min.		Recovered
5. P.M. 58 ♂ W.	Dissection	7-7-54	54 min.		Recovered

TABLE II.

Patients undergoing excision of aneurysms of proximal descending thoracic aorta with hypothermia.

portion of the aortic arch provide an even more difficult problem. Obviously clamping the ascending aorta would be instantly fatal unless the strain on the left ventricle were relieved by means of a shunt to conduct the flow of blood around the occluded point. If both the proximal and distal portions of the aortic arch are occluded, an extravascu-

lar shunt from the ascending to descending thoracic aorta might provide adequate circulation to the spinal cord and lower part of the body. Prevention of cerebral damage under such circumstances could then be achieved by placing additional shunts into the carotid vessels.

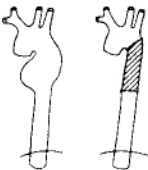
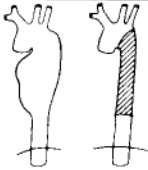
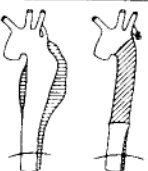


Case	Etiology	Date of Operation	Period of Occlusion	Location and Technic	Result
6. A.M. 63 ♀ C.	Syphilis	7-29-54	31 min.		Recovered
7. G.C. 43 ♂ W.	Syphilis	10-11-54	65 min.		Recovered
8. W.C. 46 ♂ W.	Dissection	11-23-54	65 min.		Died-18 hrs. later Ventricular fibrillation
9. C.B. 55 ♂ W.	Syphilis	4-8-55	35 min.		Recovered
10. M.B. 59 ♀ W.	Arterio- sclerotic	6-28-55	40min.		Died-3 days later Cardiac failure

TABLE II (continuation).

Cerebral tissue is much more sensitive to ischemic damage than is the spinal cord and irreparable damage may occur within four to six minutes of circulatory arrest. With general hypothermia, however, this period of temporary arrest of circulation to the brain may be increased. This is indicated by our experiments upon animals with complete temporary interruption of cerebral flow for periods of one hour. Thus,

among the control group of normothermic animals the incidence of fatal brain damage was approximately 50 per cent, whereas among the hypothermic group this figure was zero (12). It may be advisable, therefore, to employ both hypothermia and temporary shunts in the excision of aneurysms involving the aortic arch in order to provide the widest margin of safety possible in preventing cerebral damage.

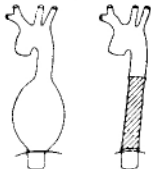

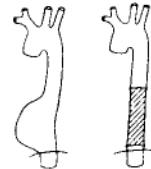
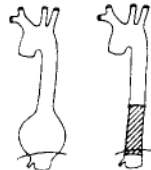
Case	Etiology	Date of Operation	Period of Occlusion	Location and Technic	Result
1. R.A. 47 ♂ W.	Syphilis	1-5-53	45 min.		Recovered
2. E.M. 50 ♀ C.	Syphilis	11-19-53	38 min.		Recovered
3. G.B. 57 ♂ C.	Syphilis	8-9-54	24 min.		Recovered
4. G.W. 63 ♂ C.	Syphilis	10-21-54	70 min.		Died-8 days later Hemorrhage

TABLE III.

Patients undergoing excision of aneurysms of lower descending thoracic aorta without hypothermia.

We have used combined general body hypothermia and external shunts in one case of aneurysm involving the entire aortic arch (7) (Fig. 1). Unfortunately, a thrombus formed in one of the carotid shunts during replacement of the arch with a Polyvinyl sponge (Ivalon) prosthesis and cerebral damage occurred which led to the patient's death one week later. Nevertheless, the patient tolerated clamping of the ascending aorta for 53 minutes. Although hypothermia may not have been vital in this case it probably limited the extent of cerebral damage that

resulted from the period of temporary carotid occlusion. During the period while the proximal aorta was occluded and the shunt was delivering blood to the descending thoracic aorta, the systolic blood pressure in the legs dropped only 10 mm. Hg. and the pulses were easily palpable. This case illustrates the advantage of combining the various methods of preventing central nervous system damage during operation on the upper reaches of the aorta.

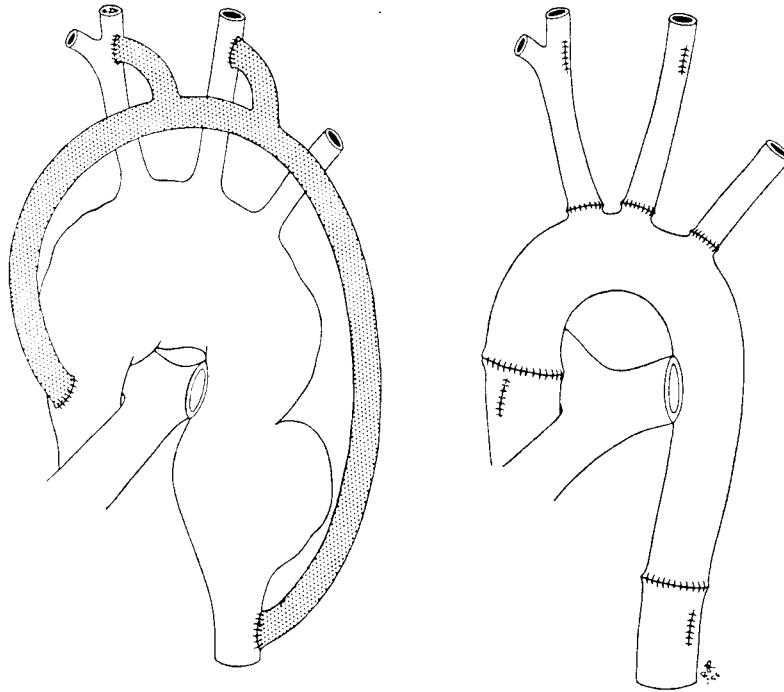


FIG. 1.

Drawing showing method of resection of entire aortic arch for aneurysm with the use of temporary by-pass shunts.

The optimum hypothermic level for such operative procedures has not been established but for most cases a rectal temperature between 88-92 degrees seems to be satisfactory. These levels of hypothermia may be readily obtained by means of a refrigerating blanket or ice water alcohol baths. General anesthesia is first induced with intravenous barbiturates following which one or two intravenous injections of Chlorpromazine 25 mg each are made to promote smooth induction of hypothermia. When the patient's rectal temperature is 92 degrees F., the hypothermic procedure is discontinued, and the operation is begun. During the operative procedure the body temperature may decrease another 4 to 8 degrees and remain at this level throughout. After com-

pletion of the operation rewarming is accomplished in a Hubbard hydrotherapy tank with warm water circulating at 110 degrees F. and usually normal body temperature is restored in less than 1 hour.

Complications related to the hypothermic state have been largely eliminated recently by rapid rewarming. Previously where rewarming was done over a prolonged period of several hours secondary hemorrhage was noted in several patients, but this has not occurred following the present technique. Another patient developed ventricular fibrillation secondary to a tension pneumothorax during gradual rewarming and although cardiac resuscitation was temporarily successful he died 18 hours after operation. Cardiac irregularities under hypothermia are relatively frequent and disappear upon return to normothermic levels. Ordinarily, however, at the mild levels of hypothermia employed in aortic operations in contrast to those used for open cardiac procedures, arrhythmias are not serious.

BIBLIOGRAPHY.

1. BAHNSON, H. T. — Definitive Treatment of Saccular Aneurysms of the Aorta with Excision of the Sac and Aortic Suture. *Surg. Gynec. and Obst.*, 96 : 383, 1953.
2. BEATTIE, E. J., Jr., ADOVASIO, D., KESHISHIAN, J. M., BLADES, B. — Refrigeration in Experimental Surgery of the Aorta. *Surg. Gynec. and Obst.*, 96 : 711, 1953.
3. BIGELOW, W. G., CALLAGHAN, J. C., HOPPS, J. A. — General Hypothermia for Experimental Intracardiac Surgery. *Ann. Surg.*, 132 : 531, 1950.
4. BIGELOW, W. G., LINDSAY, W. K., HARRISON, R. C., GORDON, R. A., GREENWOOD, W. F. — Oxygen Transport and Utilization in Dogs at Low Body Temperatures. *Am. J. Physiol.*, 160 : 125, 1950.
5. COOLEY, D. A., DE BAKEY, M. E. — Surgical Considerations of Intrathoracic Aneurysms of the Aorta and Great Vessels. *Ann. Surg.*, 135 : 650, 1952.
6. COOLEY, D. A., DE BAKEY, M. E. — Resection of the Thoracic Aorta with Replacement by Homograft for Aneurysms and Constrictive Lesions. *J. Thor. Surg.*, 29 : 66, 1955.
7. COOLEY, D. A., MAHAFFEY, D. E., DE BAKEY, M. E. — Total Excision of the Aortic Arch. *Surg. Gynec. & Obst.*, 101 : 667, Dec. 1955.
8. DE BAKEY, M. E., COOLEY, D. A. — Surgical Treatment of Aneurysm of the Abdominal Aorta by Resection and Restoration of Continuity with Homograft. *Surg. Gynec. and Obst.*, 97 : 257, 1953.
9. DE BAKEY, Michael E., COOLEY, Denton A. — Successful Resection of Aneurysm of Distal Aortic Arch and Replacement by Graft. *J.A.M.A.*, 155 : 1398, 1954.
10. DE BAKEY, M. E., COOLEY, D. A., CREECH, Oscar, Jr. — Treatment of Aneurysms and Occlusive Disease of the Aorta by Resection : Anal. 87 Cases. *J.A.M.A.*, 157 : 203-208, Jan. 15, 1955.
11. PONTIUS, R. G., BROCKMAN, H. L., HARDY, E. G., COOLEY, D. A., DE BAKEY, M. E. — The Use of Hypothermia in the Prevention of Paraplegia Following Temporary Aortic Occlusion, Experimental Observations. *Surgery*, 36 : 33, 1954.
12. PONTIUS, R. G., BLOODWELL, R. D., COOLEY, D. A., DE BAKEY, M. E. — The Use of Hypothermia in the Prevention of Brain Damage Following Temporary Arrest of Cerebral Circulation : Experimental Observations, *Surgical Forum of the Amer. College of Surgeons*, 1954. W. B. Saunders, Co.

SUMMARIES.

Depending upon the level and extent of the lesion, temporary occlusion of the descending thoracic aorta during resection of aneurysms may result in spinal cord damage from ischemia and paraplegia. In order to prevent this complication hypothermia was used in ten cases with no neurologic sequelae. Among five other cases with aneurysms of the proximal descending aorta, manifestations of cord damage occurred in four and one was fatal. In one patient the entire aortic arch was resected and replaced with an Ivalon prosthesis using hypothermia and temporary by-pass shunts. Hypothermia is unnecessary in excisional therapy of abdominal aneurysms and aneurysms of the terminal thoracic aorta.

* * *

Abhängend vom Grad und Ausmass der Schädigung kann ein zeitweiliger Verschluss der absteigenden Brustschlagader während der Resektion eines Aneurysma zu Schädigungen des Rückenmarkes durch Ischaemie und zu einer Paraplegie führen. Um diese Komplikationen zu verhindern, wurde die Hypothermie in 10 Fällen ohne neurologische Folgen durchgeführt. Bei fünf anderen Fällen mit Aneurysmen der oberen absteigenden Aorta kam es in vier Fällen zu Erscheinungen von Rückenmarksschädigungen, von denen eine tödlich war. Bei einem Patienten wurde der ganze Aortenbogen reseziert und durch eine Ivalonprothese ersetzt, dabei wurden Hypothermie und zeitweilige Shunts angewandt. Die Hypothermie ist nicht nötig bei der operativen Beseitigung abdominaler Aneurysmen und von Aneurysmen der unteren Brustschlagader.

* * *

La oclusión provisional de la aorta descendente durante las operaciones de resección o de aneurisma aortico puede determinar, segun el nivel de la lesión, trastornos de la médula espinal en forma de isquemia o paraplejia. A fin de evitar estas complicaciones ha sido utilizada la hipotermia en 10 de estas operaciones sin observarse ninguna secuela neurológica. Por el contrario, en otros cinco casos con aneurisma del segmento proximal de la aorta descendente, se observaron alteraciones medulares en cuatro de ellos, uno de los cuales fue seguido de muerte. En un paciente se hizo una resección entera del arco aortico con remplazamiento del mismo con una protesis de Ivalon, actuandose bajo hipotermia y oclusión temporal. La hipotermia es innecesaria en los tratamientos de excisión de los aneurismas abdominales o los aneurismas del segmento distal de la aorta torácica.

* * *

Pendant la résection d'un anévrisme, l'occlusion temporaire de l'aorte thoracique descendante peut entraîner, par ischémie, des lésions médullaires d'importance et d'étendue variables, avec paraplégie. Pour prévenir cette complication, nous avons, dans dix cas, opéré nos malades sous hypothermie: dans aucun cas nous n'avons observé de séquelles neurologiques. Par contre, dans 5 autres cas d'anévrisme, localisé très haut sur l'aorte descendante, nous avons eu 4 lésions médullaires, avec un décès. Chez un malade, nous avons réséqué toute la crosse

aortique, et l'avons remplacée par une prothèse en Ivalon: l'opération fut faite sous hypothermie et en utilisant des court-circuits artériels. L'hypothermie est inutile pour l'excision des anévrysmes abdominaux et pour ceux de l'aorte thoracique basse.

* * *

In dipendenza del livello e del grado della lesione, la temporanea occlusione dell'aorta toracica discendente durante la resezione di aneurismi, può provocare un danno del midollo spinale da ischemia e talvolta paraplegia. Al fine di prevenire questa complicanza, in 10 casi fu usata l'ipotermia senza alcun postumo neurologico. In altri 5 casi con aneurisma del tratto prossimale dell'aorta discendente le manifestazioni di danno midollare avvennero in 4 casi e in un caso l'esito fu letale. In un caso l'intero arto aortico fu asportato e sostituito con una protesi di Ivalon usando ipotermia e temporaneamente by-pass shunts. L'ipotermia non è indispensabile nella terapia chirurgica degli aneurismi addominali e del tratto terminale dell'aorta toracica.

* * *

В зависимости от уровня и величины поражения, временное выключение нисходящей грудной аорты во время операции резекции аневризмы может повести к поражению спинного мозга из-за ишемии и паралигии. С целью предупреждения этого осложнения у 10 больных применяли гипотермию без всяких нейрологических последствий. Из 5 других больных с аневризмами проксимального отрезка нисходящей аорты, у 4 развились симптомы поражения спинного мозга, причем один из больных умер. У одного больного была произведена резекция всей дуги аорты с зашемлением ее протезом из Айвелона при гипотермии и временном выключении кровообращения. Гипотермия не нужна при резекции аневризм брюшной и нижней части грудной аорты.