

Patterns of Atherosclerosis and Rates of Progression

Michael E. DeBakey

*Cora and Webb Mading Department of Surgery, Baylor College of Medicine,
Houston, Texas 77030*

Although the precise cause of atherosclerosis remains elusive, much progress has been made in the past several decades toward development of better understanding of the insidious pathologic and anatomic changes that occur in the arterial wall. This knowledge has evolved not only from experimental studies but particularly from medical and surgical experience, which has provided the opportunity to follow the course of the disease by means of periodic arteriographic examinations of patients over a period of more than two decades. These studies, based on our experience with more than 15,000 patients over the past several decades, have led to a number of interesting and highly informative observations concerning the various patterns of arterial occlusive disease and the natural course of atherosclerosis.

It is now well established that arteriosclerosis or atherosclerosis has a tendency to assume certain characteristic anatomic, pathologic, and clinical patterns. Particularly important is the fact that the disease often tends to be segmental, with relatively normal proximal and distal arterial beds. In other forms the distribution is more generalized. Recognition of the different clinical patterns of atherosclerosis is essential not only for a better understanding of the disease but also for institution of rational therapy.

PATTERNS OF ATHEROSCLEROSIS

The sex and age distributions of the various patterns of atherosclerosis described in this presentation are not much different from those generally recognized except in the patterns specifically indicated. Thus, there is an overwhelming predominance of male over female patients except after the menopause, when the ratio decreases progressively to approach an equal incidence. Whereas the disease may occur at any age, its clinical manifestations are observed rarely in the first or second decades, infrequently in the third, and predominantly in the fifth to seventh decades of life.

One of the most important patterns consists in the predominant anatomic

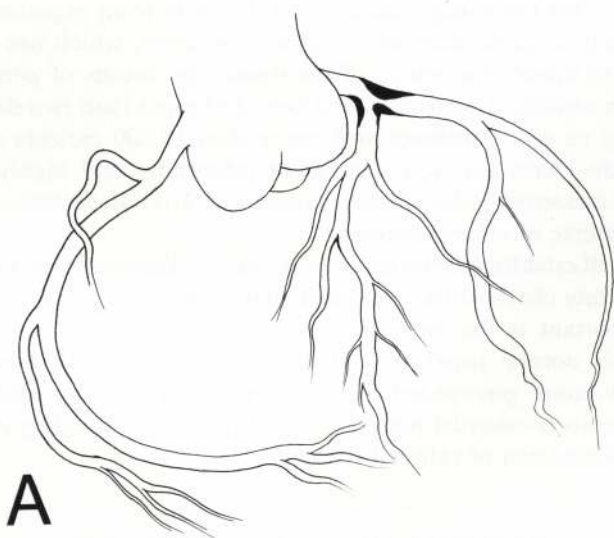
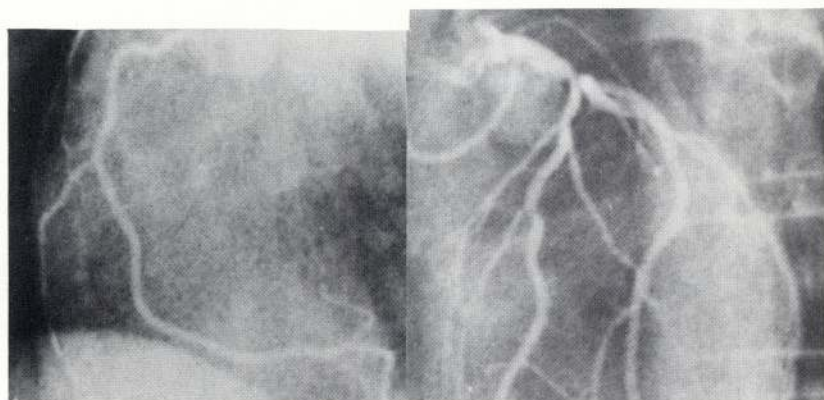


FIG. 1.A. Drawing and photograph of coronary arteriograms showing localized stenotic lesion in main left coronary artery at origin of left anterior descending branch in a 45-year-old white man with chief complaint of severe angina.

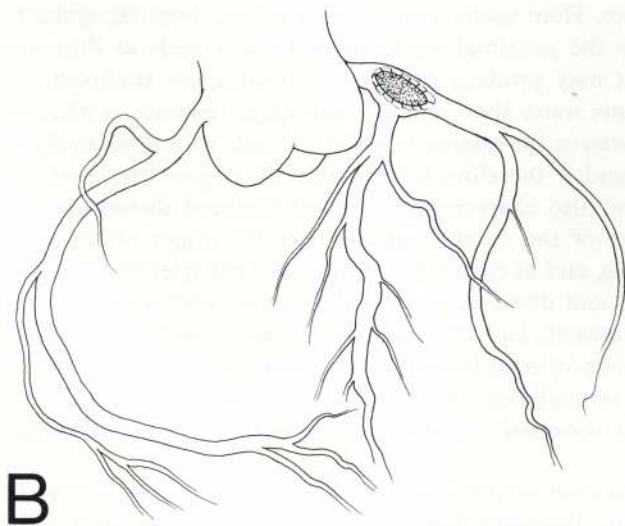
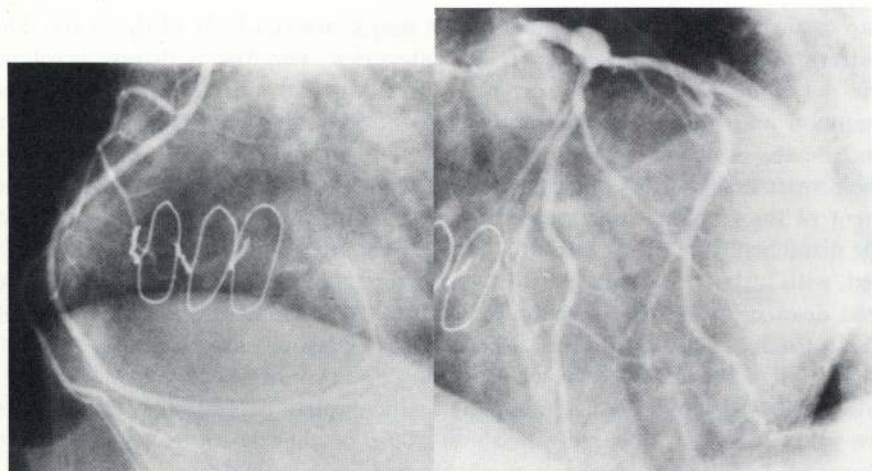


FIG. 1.B. Drawing and photograph of coronary arteriograms 11 years after endarterectomy and patch graft angioplasty showing correction of previous stenotic lesion with restoration of normal flow in left coronary artery and no evidence of recurrence or progression of atherosclerosis in either right or left coronary arterial beds. Patient has remained asymptomatic with completely normal activity. Lipoprotein levels before and after operation have been consistently normal (cholesterol 148; triglycerides 91).

site or distribution of the disease in the major arterial beds of the body. This pattern may be classified into certain categories. The first is disease involving the major branches of the ascending aorta and aortic arch. One of the most common and grave patterns in this region, from the standpoint of disability and death, is atherosclerosis of the coronary arterial bed. Characteristically, the disease assumes one of three patterns of anatomic distribution: first, involvement of the proximal portions of the arterial bed, with little or no disease of the distal bed (Figs. 1, 2); second, predominant involvement of the distal arterial bed, with little or no disease of the proximal portion (Fig. 3); and third, generalized disease of both the proximal and distal portions of the arterial bed (Fig. 4). In the more proximal sites, atherosclerosis may be extremely well-localized to a small segment of the artery, involving one or more of the major coronary arteries, and it may produce complete or incomplete occlusion. These patterns are fairly common, occurring in about 50%, or slightly more, of the patients observed; fortunately, they are amenable to surgical correction.

The next pattern of anatomic distribution is one that affects the major branches of the aortic arch—the innominate, carotid, and subclavian arteries, and their major branches. Here again several patterns have been recognized. In one, the disease affects the proximal segments of these vessels as they arise from the aortic arch; it may produce complete or incomplete occlusion, and in about 50% of patients more than one of these major arteries is affected. In almost all of these patterns the disease is well-localized, with a relatively normal distal arterial bed, and it therefore is amenable to surgical treatment (Fig. 5). The second pattern, also characterized by well-localized disease, tends to occur at the bifurcation of the carotid arteries and the origin of the internal carotid arteries (Fig. 6), and at the origin of the vertebral arteries (Fig. 7). The arteries both proximal and distal to these well-localized atherosclerotic lesions tend to be relatively normal, and thus this pattern is amenable to surgical treatment. The third pattern of distribution in this region is characterized by involvement of the distal arterial bed or intracranial portion, with relatively little or no disease of the proximal segments and therefore is not amenable to surgical treatment.

Although in most of these patterns the atheroma encroaches on the lumen, with consequent localized stenosis, in some patients the lesion is ulcerative in character, with little or no stenosis (Fig. 8). On the surface of the ulcerative lesion, fibrin and thrombi develop, portions of which may break off and be swept up by the bloodstream, producing emboli; when this occurs, the patients may have repeated episodes of transient ischemic attacks.

An important clinical consideration of these anatomic patterns of occlusive atherosclerotic disease is the fact that they tend to produce characteristic cerebrovascular manifestations and neurologic disturbances. In a number of patients, however, these symptoms do not reflect the exact site and extent of disease because of the high incidence of multiple arterial involvement and the development of collateral circulation. For example, in some patients with characteristic

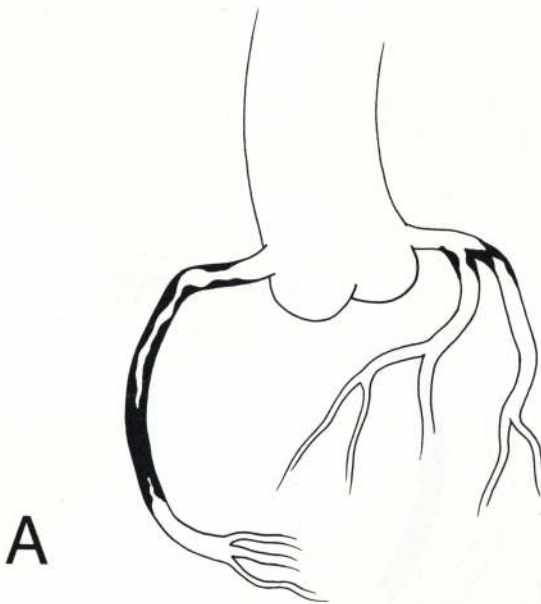
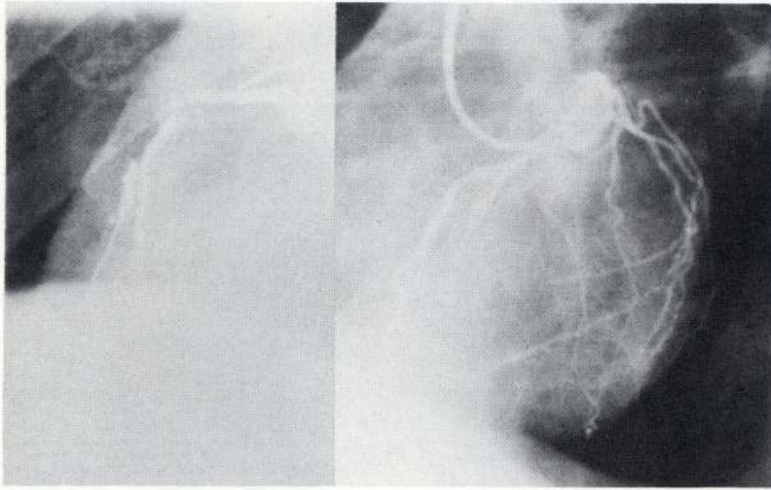


FIG. 2.A. Drawing and photograph of coronary arteriogram showing well-localized stenotic lesion in right and left anterior descending, and circumflex coronary arteries in a 50-year-old white man with severe angina.

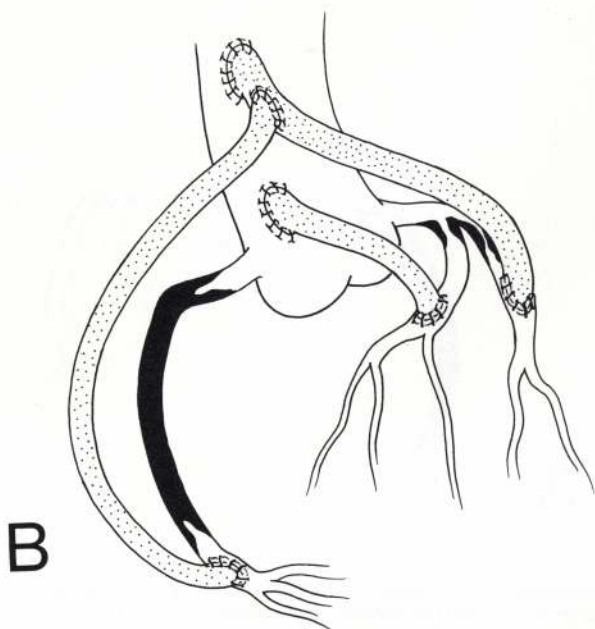
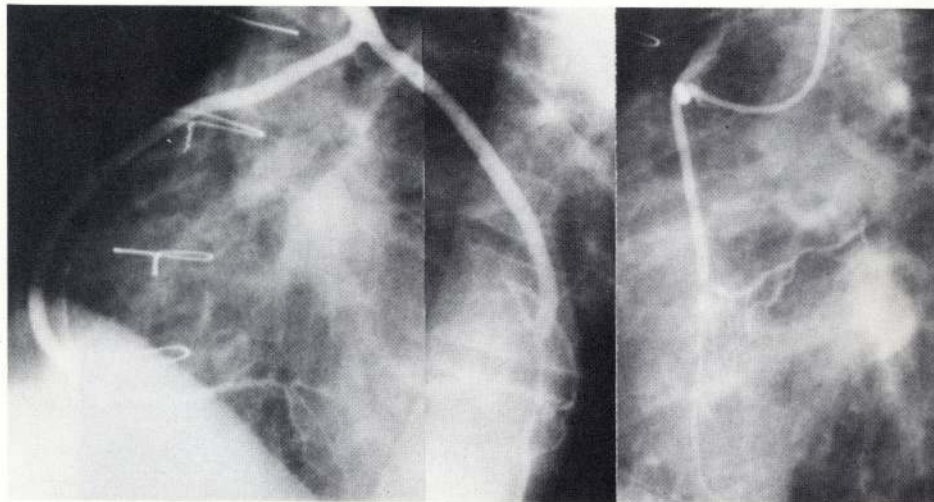


FIG. 2.B. Drawing and photograph of coronary arteriogram 6 years after autogenous vein bypass from ascending aorta to right and left anterior descending, and circumflex coronary arteries. Patient has remained asymptomatic with completely normal activities. Lipoprotein levels have been normal (cholesterol 266; triglycerides 135).

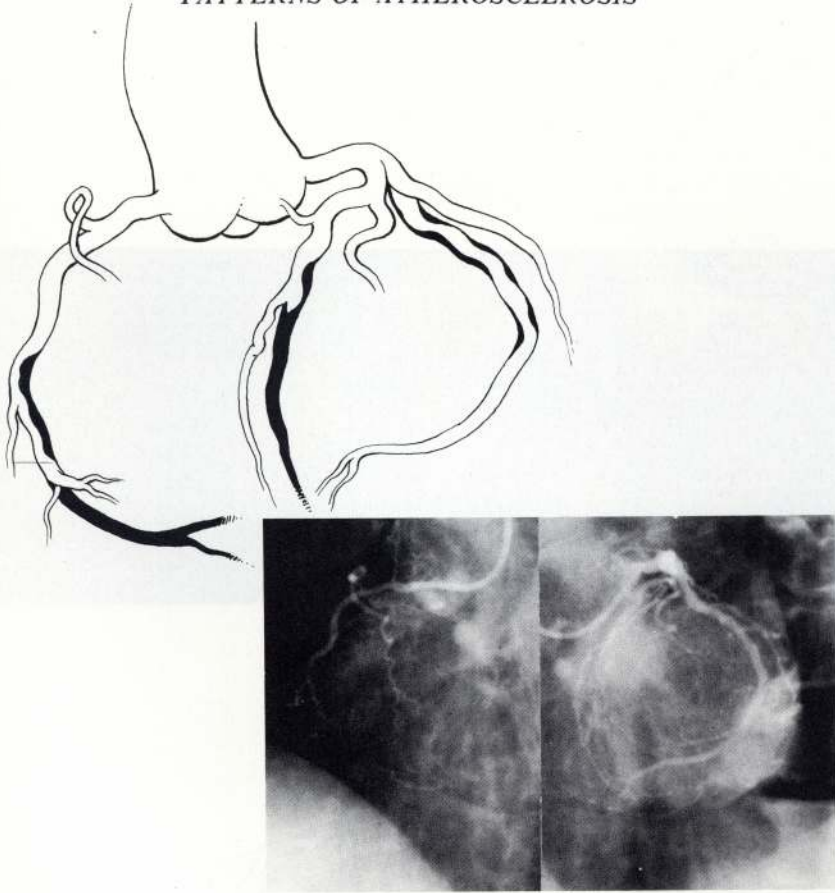


FIG. 3. Drawing and photograph of coronary arteriogram in 59-year-old white man with severe angina and heart failure showing extensive atherosclerotic occlusive disease of distal arterial bed producing dyskinesia and poor left ventricular function, as indicated by a left ventricular end diastolic pressure of 30 mm Hg. (cholesterol 208; triglycerides 104).

ischemia due to occlusive lesions involving the internal carotid arteries, arteriography may disclose the responsible, and surgically correctable, lesion to be in the proximal segment of the innominate, common carotid, or vertebral arteries. In other patients with characteristic manifestations of basilar arterial insufficiency, the responsible, and surgically correctable, lesion may be in the internal carotid arteries or in the proximal segments of the innominate, common carotid, or subclavian artery.

The third pattern of anatomic distribution of occlusive disease is one that affects the visceral branches of the abdominal aorta—the celiac axis, the superior mesenteric, and the renal arteries. This pattern tends to be characteristically well-localized at or near the origin of these arteries from the aorta, with relatively normal distal arterial beds, and hence, it is surgically correctable. Ischemia

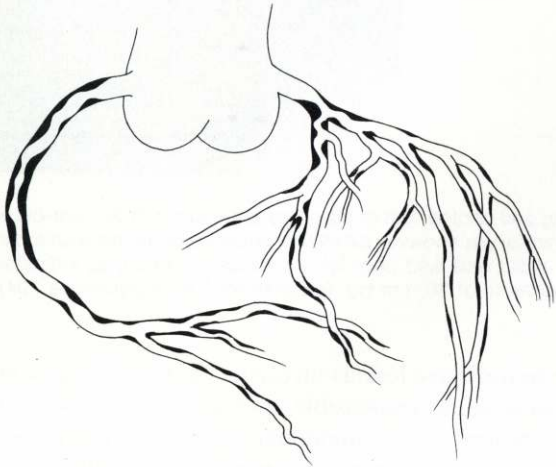
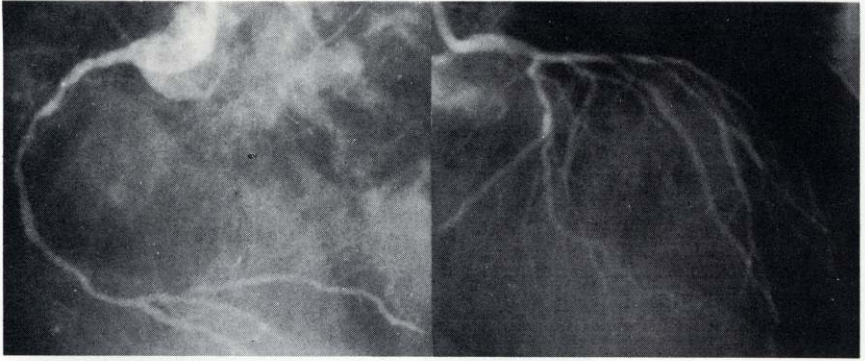


FIG. 4. Drawings and coronary arteriograms in 61-year-old white man with severe angina showing diffuse atherosclerotic occlusive disease throughout entire coronary arterial bed (cholesterol 265; triglycerides 106).

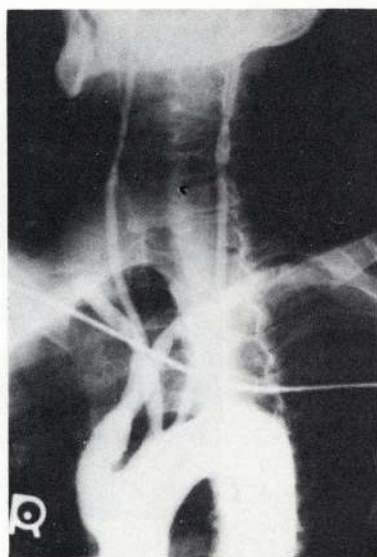
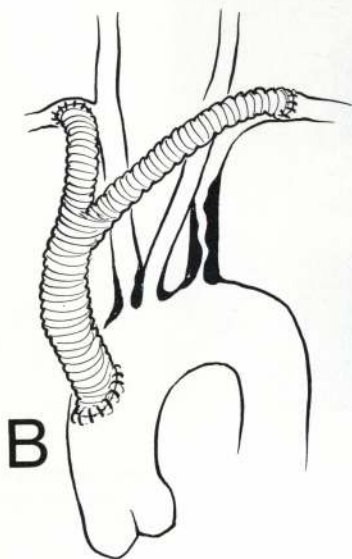
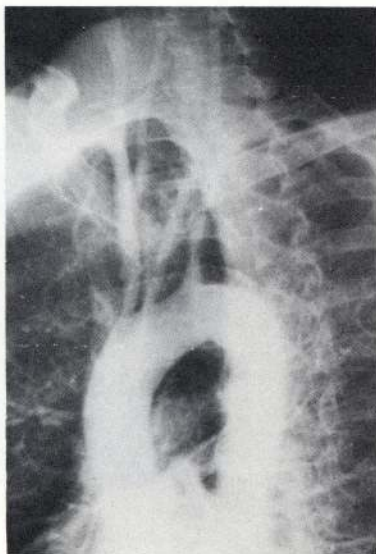



FIG. 5.A. Drawing and photograph of aortic arch aortogram in 54-year-old white man with vertigo and intermittent claudication of arms showing localized atherosclerotic occlusive disease involving proximal segments of innominate and left subclavian arteries. B. Drawing and photograph of aortic arch aortogram made almost 20 years after insertion of bypass graft from ascending aorta to both subclavian arteries. Patient has remained asymptomatic with normal activities (cholesterol 286; triglycerides 133).

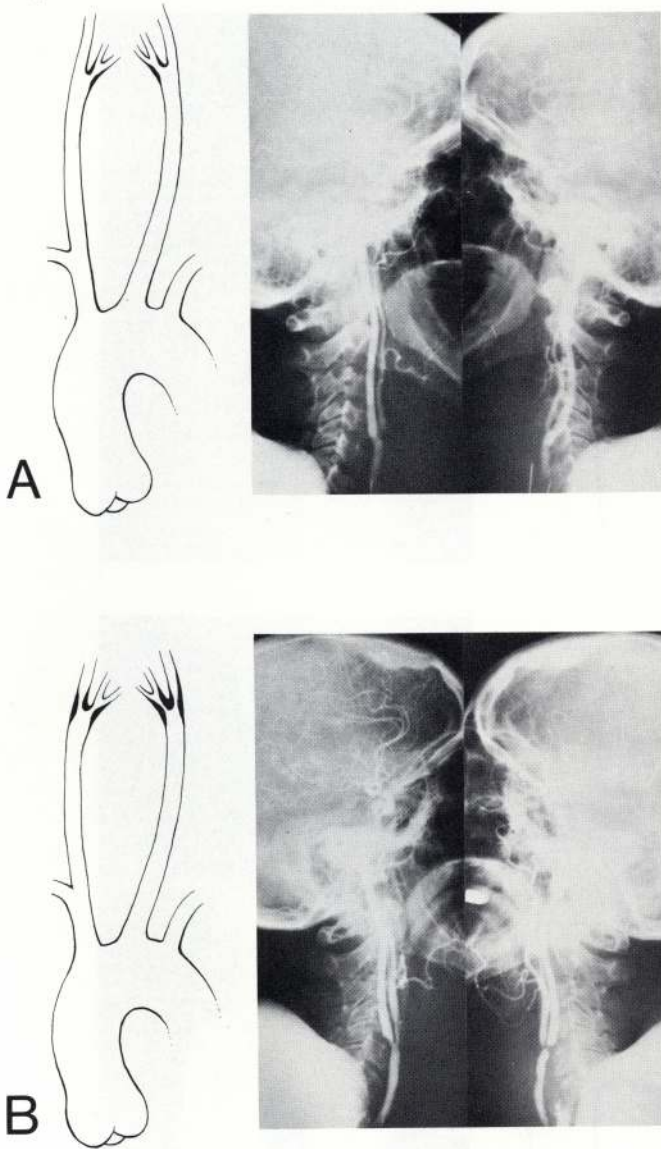


FIG. 6. A. Drawing and photograph of bilateral carotid arteriograms in 47-year-old white woman with mild, intermittent dizziness, showing only mild atheromatous disease without significant stenosis of carotid arteries. B. Drawing and carotid arteriograms made 16 years later, when significant symptoms of cerebrovascular insufficiency developed, showing severe, well-localized atherosclerotic occlusive disease involving bifurcation of common carotid and origin of internal carotid arteries. Bilateral carotid endarterectomy with patch graft angioplasty resulted in complete relief of symptoms (cholesterol 159; triglycerides 109).

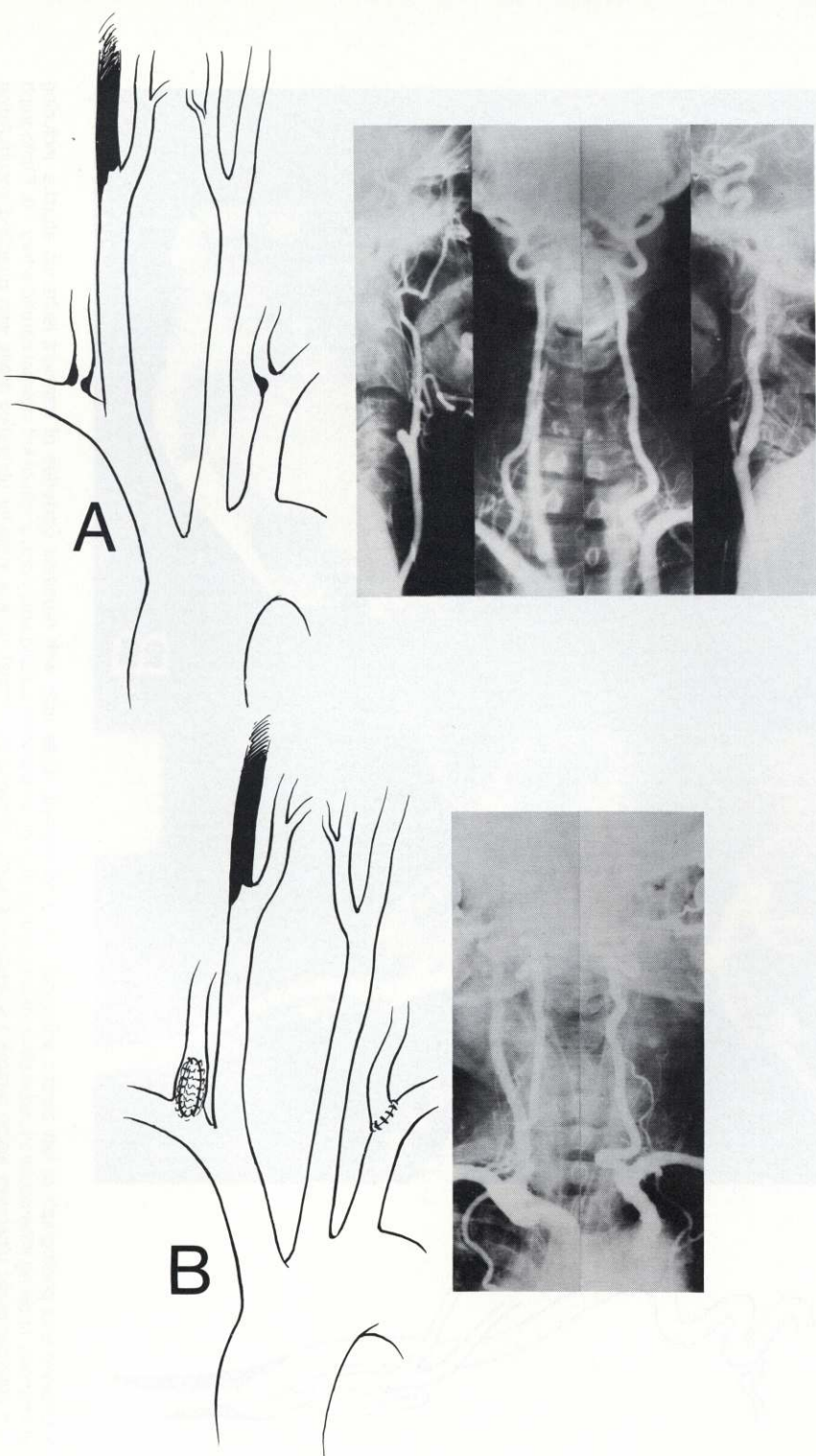


FIG. 7.A. Drawing and photograph of preoperative carotid and subclavian arteriograms in 55-year-old white man with symptoms of vertebral basilar insufficiency showing complete occlusion of right internal carotid artery and well-localized severe atherosclerotic occlusive disease involving origin of both vertebral arteries. **B.** Drawing and photograph of subclavian and vertebral arteriograms made 18 years after endarterectomy showing restoration of normal lumen and circulation. Patient has remained asymptomatic (cholesterol 195).

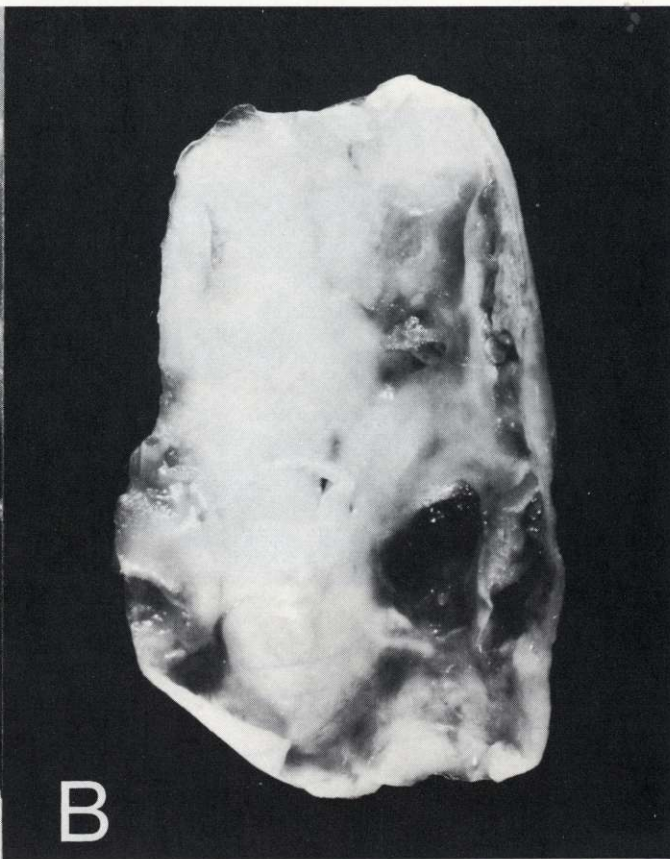
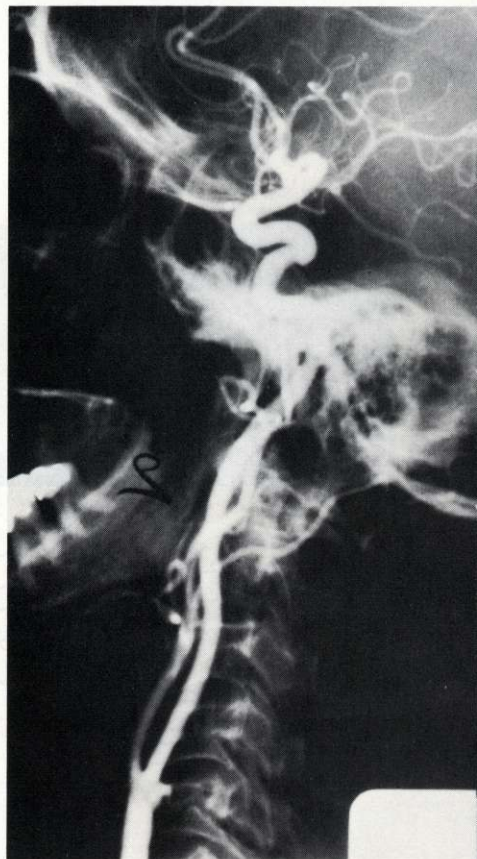
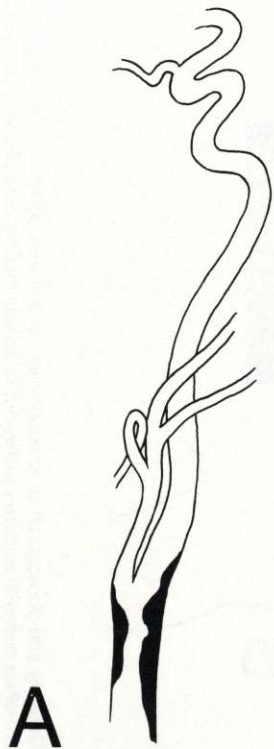


FIG. 8. **A.** Drawing and photograph of left carotid arteriogram in a 65-year-old white man with repeated episodes of transient ischemic attacks, including visual disturbances, showing atherosclerotic ulcerative lesion at bifurcation of left common carotid artery and origin of left internal carotid artery. **B.** Photograph of localized atherosclerotic ulcerative lesion removed at endarterectomy, showing on luminal surface irregular ulcerative areas with attached accumulation of fibrin and thrombi from embolization. Patient has remained asymptomatic for past 7 years since operation (cholesterol 236; triglycerides 113).

resulting from these occlusive patterns produces two characteristic but widely different clinical entities. One is abdominal or intestinal angina caused by occlusion of the celiac and superior mesenteric arteries (Fig. 9), and the other is renovascular hypertension caused by occlusion of the renal arteries (Figs. 10,11).

The final category of patterns of anatomic distribution of atherosclerotic occlusive disease is one that affects the terminal abdominal aorta and its major branches. Here again, several distinctive and characteristic patterns may be observed. One of the most common is disease localized to the aorto-iliac segment. In this pattern the occlusive process usually begins at or near the origin of the common iliac arteries. The incomplete occlusion of one or the other common iliac artery gradually enlarges to complete occlusion of both, and later thrombosis of the abdominal aorta spreads up to the origin of the renal arteries and produces intermittent claudication and sexual impotence, first described by Leriche and known as the Leriche syndrome (Figs. 12,13). The distal arterial bed beyond the aorto-iliac segment is usually relatively normal, so that this pattern is also amenable to surgical correction.

The next most common pattern in this category is characterized by disease of the superficial femoral artery in the region of the adductor canal. This form is also usually well-localized, with a relatively patent distal segment in the popliteal artery and its major branches, and it is therefore surgically correctable (Fig. 14). Here again, the occlusion may be complete or incomplete, depending on its stage of development. Combinations of these two patterns, that is, aorto-iliac and superficial femoral arterial occlusive disease, with some variations as to side of involvement, are also fairly common (Fig. 15).

One of the most interesting and somewhat unusual patterns is observed most frequently in relatively young women, between 30 and 50 years of age. In this pattern the atheroma is localized in the abdominal aorta a few centimeters above the bifurcation, usually on the posterior wall (Fig. 16). The atheroma itself is often no more than 2 to 4 cm. long, involving most of the posterior half of the circumference of the aorta. At endarterectomy, the atheroma may be easily separated from the remainder of the aortic wall by a cleavage plane at the site of attachment.

The final pattern in this category of occlusive atherosclerotic arterial disease involves the distal arterial bed, that is, the popliteal artery and its major branches, but relatively little or none of the proximal arterial bed is affected (Fig. 17). Patients with this pattern of occlusion are often diabetics, but non-diabetics are sometimes also affected. This form of distal atherosclerotic occlusive disease is unfortunately not amenable to surgical correction.

Although the patterns of the anatomic distribution of atherosclerotic occlusive disease that have been described are fairly characteristic, extensive clinical experience would suggest some selectivity in their occurrence in different categories of patients. Some patients, for example, are prone to cerebrovascular occlusive disease, with little or no evidence of involvement of other major arterial beds.

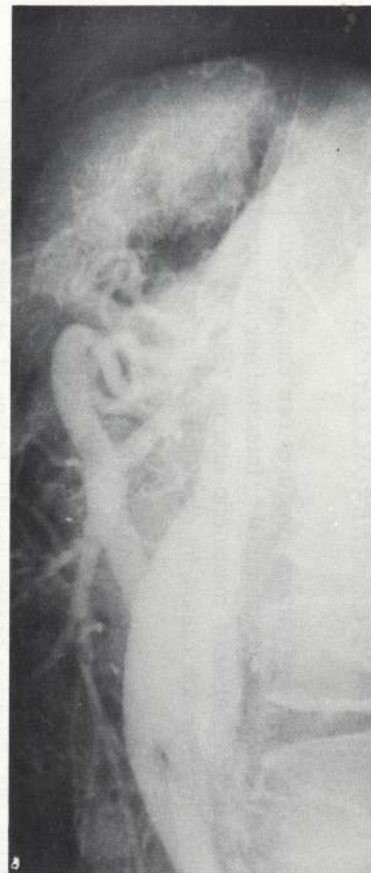
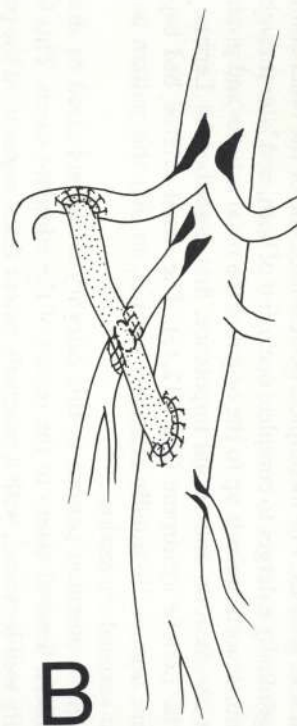
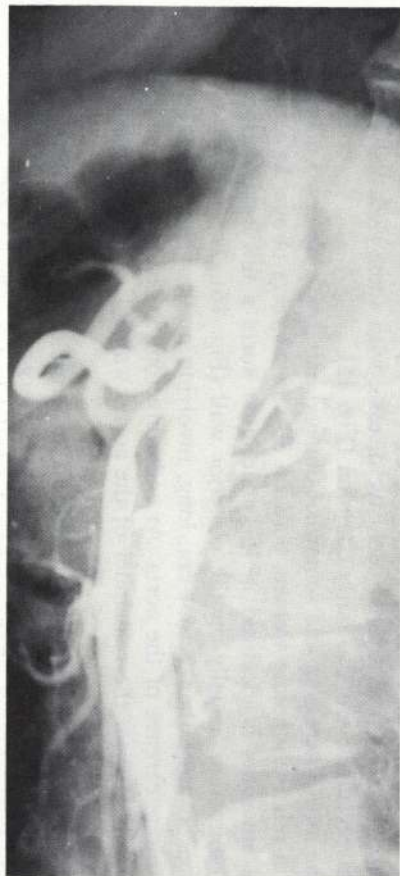
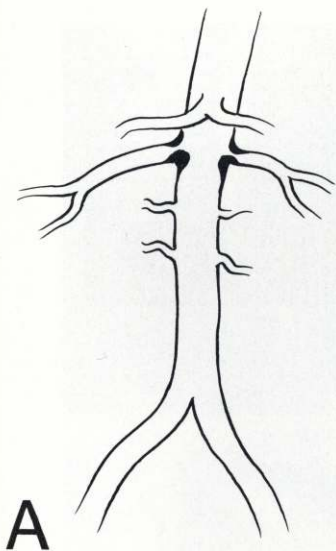
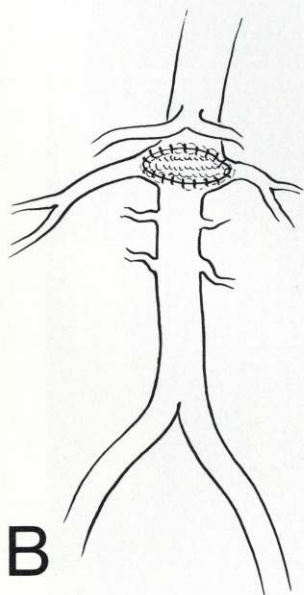
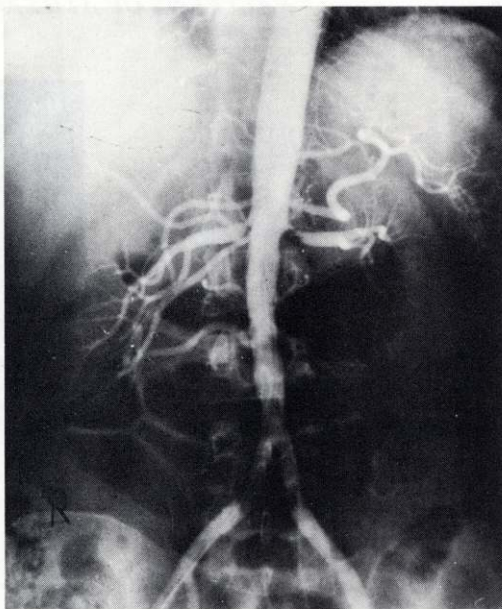


FIG. 9.A. Drawing and preoperative abdominal aortogram in a 57-year-old white woman with abdominal angina, showing well-localized atherosclerotic occlusive lesions involving origin of celiac axis and superior mesenteric arteries. **B.** Drawing and photograph of abdominal aortogram made 5 years after operation showing functioning bypass graft from abdominal aorta to superior mesenteric and hepatic arteries distal to occlusive lesion. Patient has remained asymptomatic (cholesterol 205; triglycerides 98).



A



B

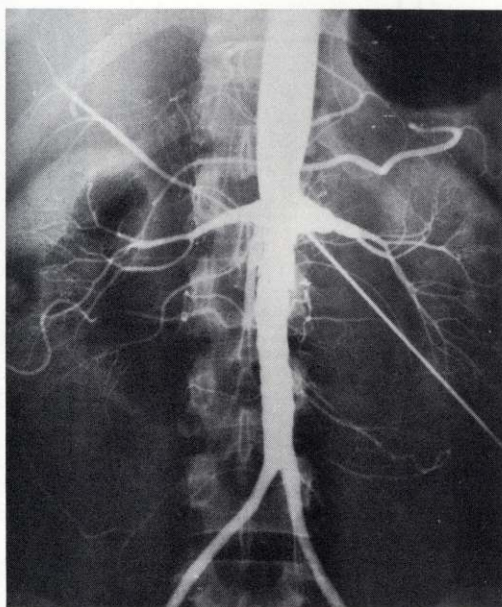


FIG. 10. A. Drawing and photograph of preoperative abdominal aortogram in a 38-year-old white woman with severe hypertension showing well-localized atherosclerotic occlusive lesions of both renal arteries. B. Drawing and abdominal aortogram almost 15 years after endarterectomy and patch graft angioplasty showing restoration of normal lumen and circulation in renal arteries. Patient has remained asymptomatic and relatively normotensive since operation (cholesterol 342).

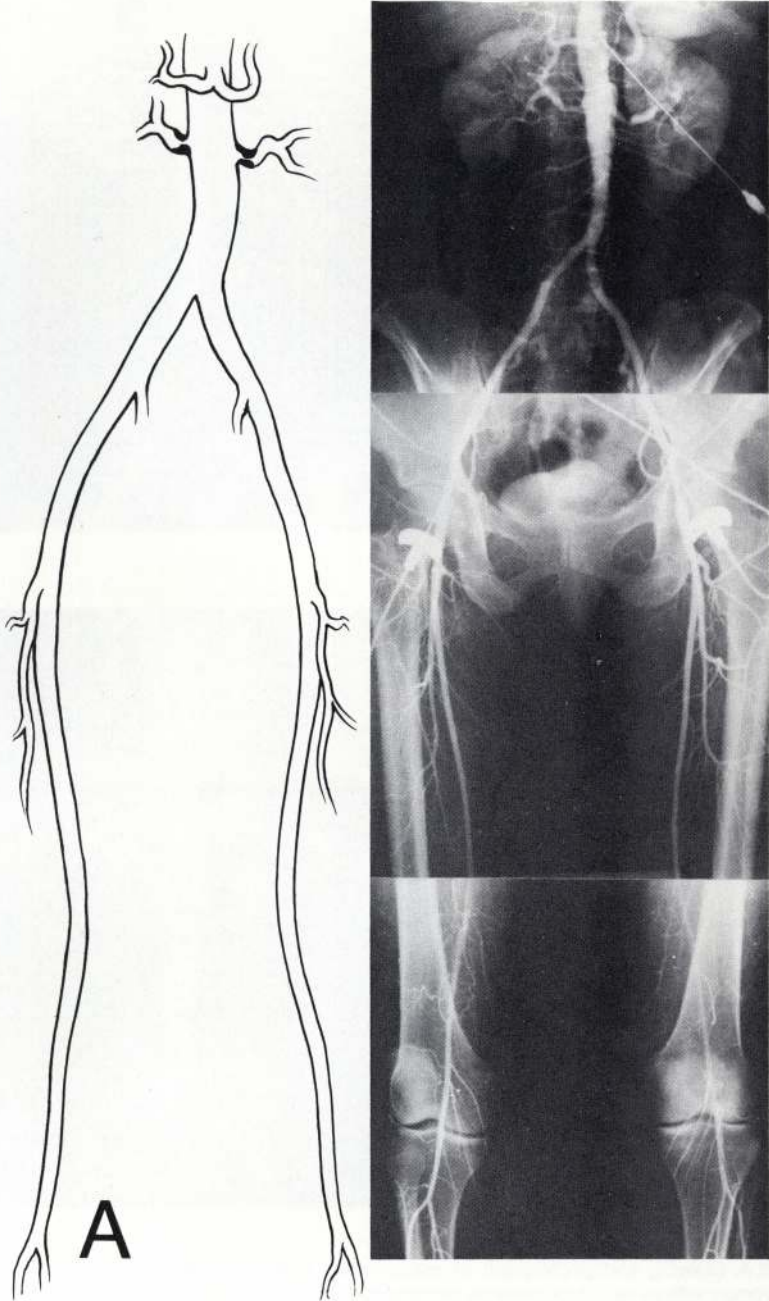


FIG. 11. A. Drawing and photograph of arteriograms of abdominal aorta, and iliac, femoral, and popliteal arteries in a 56-year-old white woman with severe hypertension, showing severe, well-localized atherosclerotic occlusive lesions near origin of both renal arteries. Surgical treatment consisted of Dacron aorto-renal artery bypass bilaterally with good results. Note that there is little or no evidence of atherosclerotic disease in the superficial femoral and popliteal arteries.

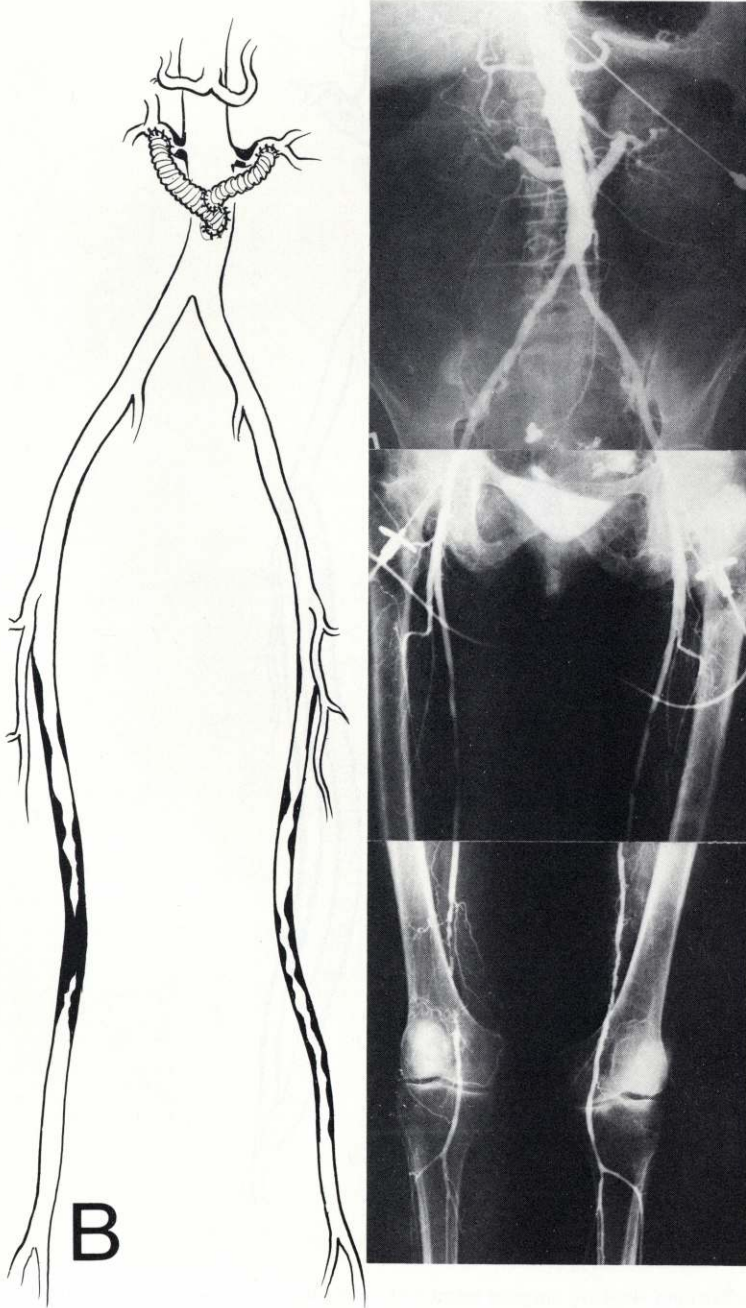


FIG. 11.B. Drawing and photograph of arteriograms of abdominal aorta, and iliac, femoral, and popliteal arteries 17 years later in same patient in whom intermittent claudication of lower limbs had recently developed, now showing severe, well-localized atherosclerotic occlusive lesions in both superficial femoral arteries. Note well-functioning bypass grafts to both renal arteries.

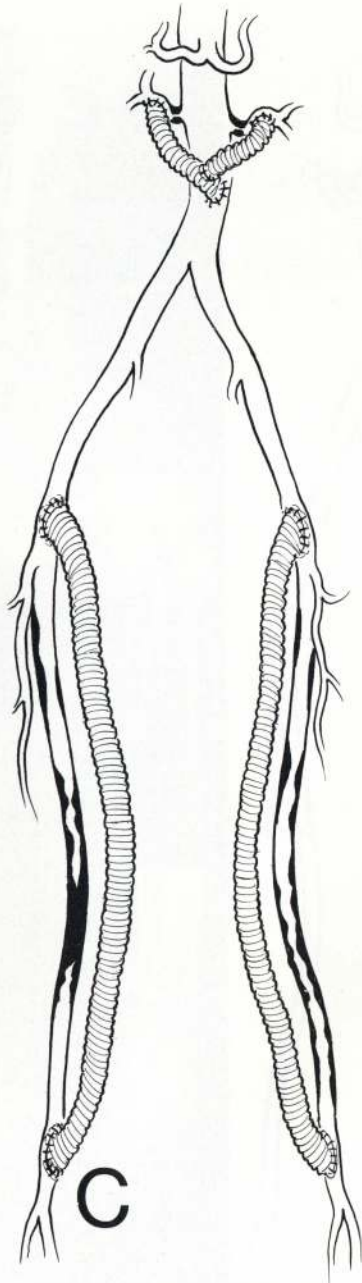


FIG. 11.C. Drawing showing surgical treatment by means of bilateral Dacron femoro-popliteal bypass grafts. Patient has since remained asymptomatic (cholesterol 218; triglycerides 225).

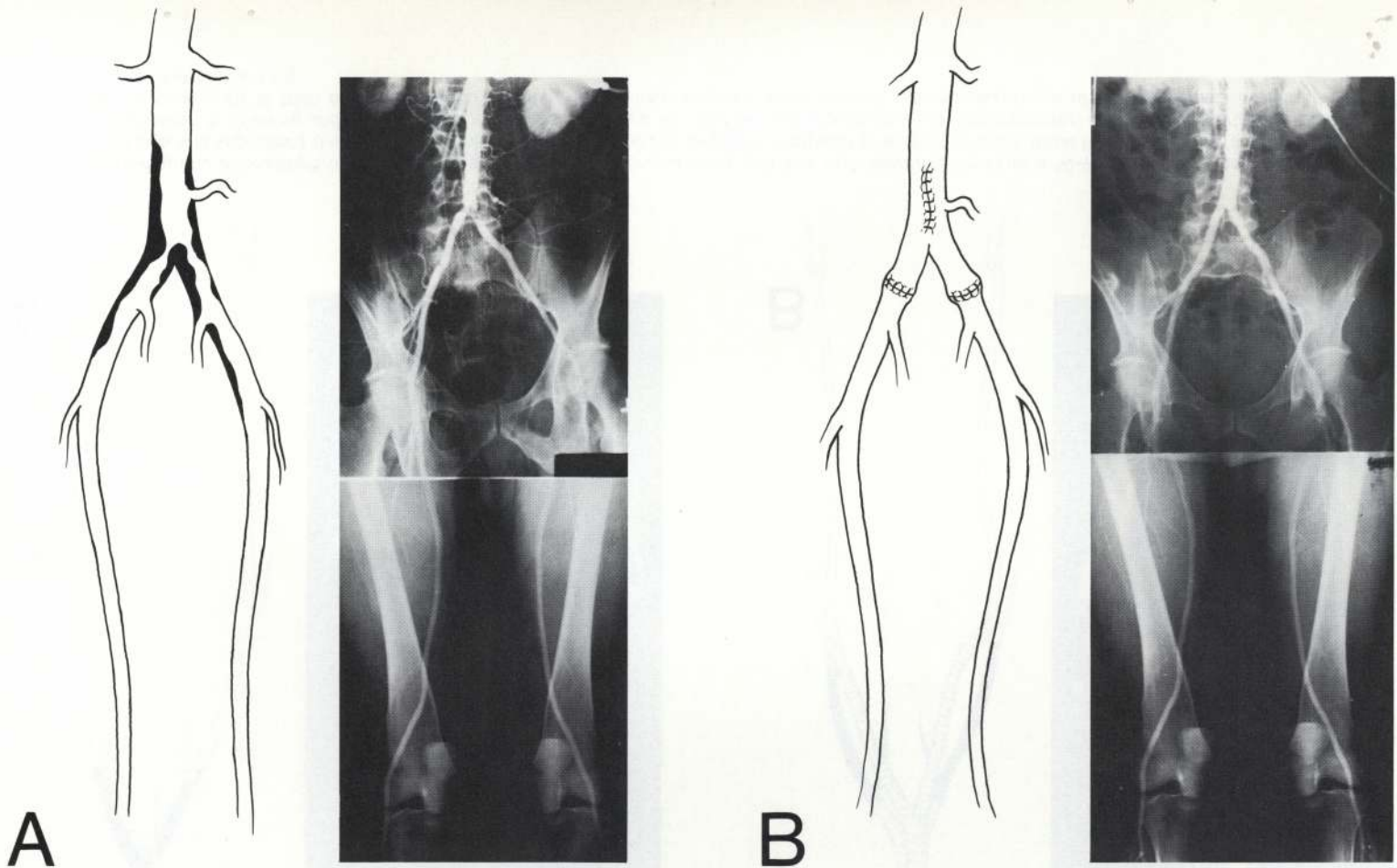


FIG. 12. A. Drawing and preoperative arteriogram of abdominal aorta, and iliac and femoral arteries in a 55-year-old white man with intermittent claudication showing well-localized atherosclerotic occlusive disease of aorto-iliac segment. **B.** Drawing and arteriogram of abdominal aorta, and iliac and femoral arteries 23 years after aorto-iliac endarterectomy showing restoration of normal lumen and circulation to legs. Atherosclerotic disease has not recurred in this arterial bed. Patient has remained asymptomatic (cholesterol 235; triglycerides 345).

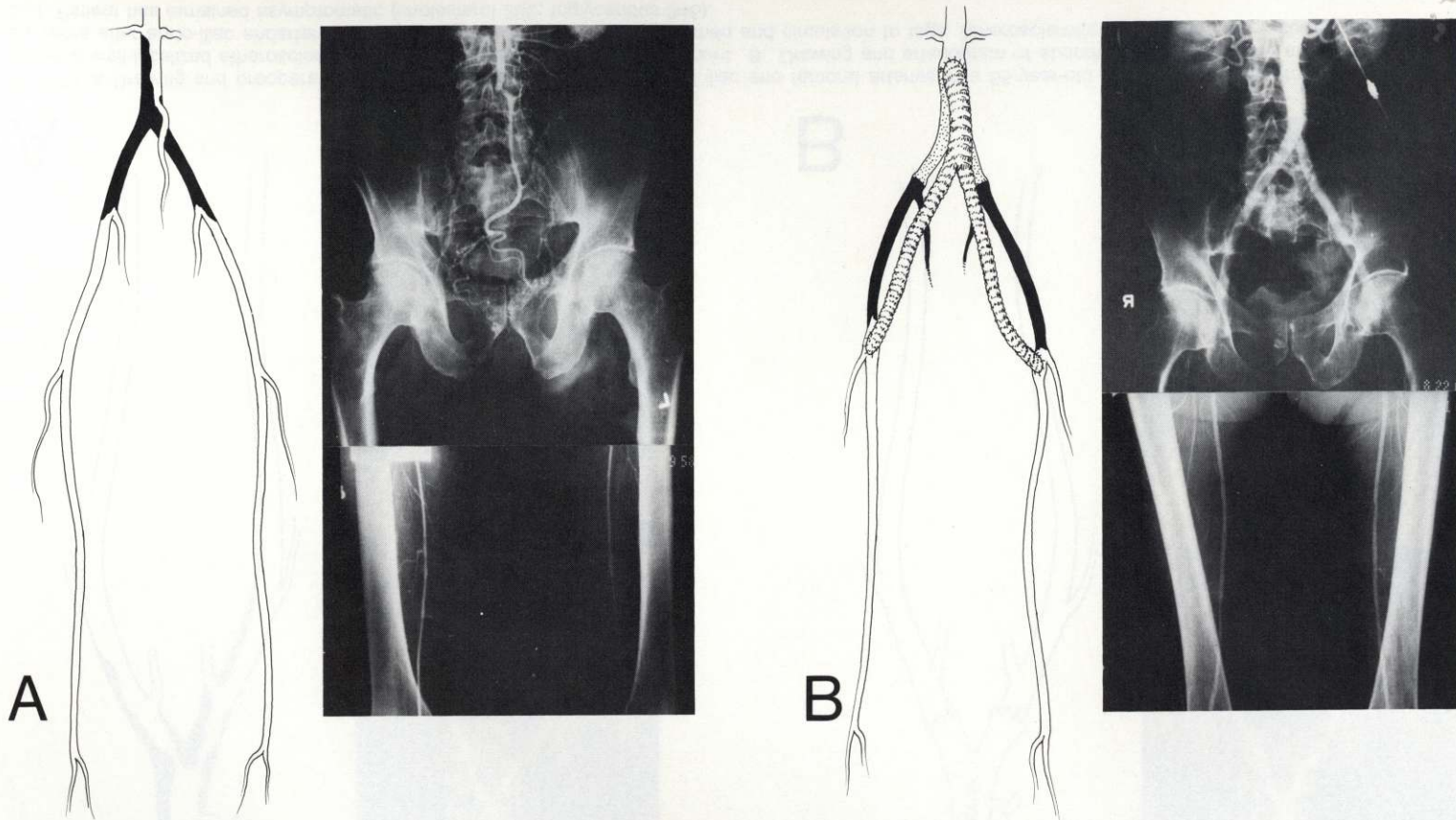


FIG. 13. A. Drawing and photograph of preoperative aortogram of abdominal aorta and iliac and femoral arteries in a 59-year-old white man with intermittent claudication of legs and impotence (Leriche syndrome) showing well-localized complete occlusion of abdominal aorta distal to origin of renal artery and including common iliac arteries. B. Drawing and arteriogram of abdominal aorta and iliac and femoral arteries 23 years after resection of abdominal aorta and replacement with graft and bypass graft to both common femoral arteries. Patient has remained asymptomatic with no recurrence of atherosclerosis in this arterial bed (cholesterol 223; triglyceride 110).

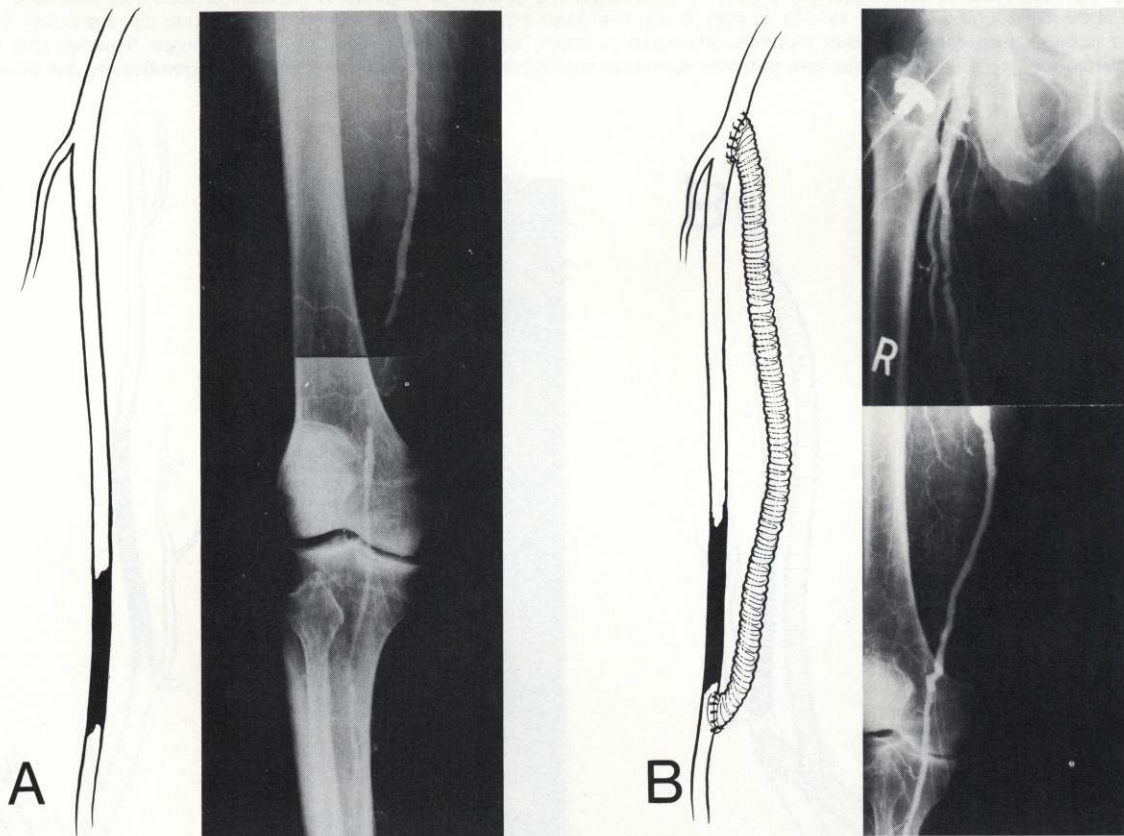

FIG. 14.A. Drawing and preoperative right femoral arteriogram in a 62-year-old white man with intermittent claudication of right leg show well-localized atherosclerotic occlusive lesion of right superficial femoral artery with patent distal popliteal artery. **B.** Drawing and right femoral arteriogram 21 years after insertion of Dacron bypass graft from right common femoral to popliteal artery showing restoration of circulation through functioning graft. Patient has remained asymptomatic (cholesterol 151; triglycerides 115).

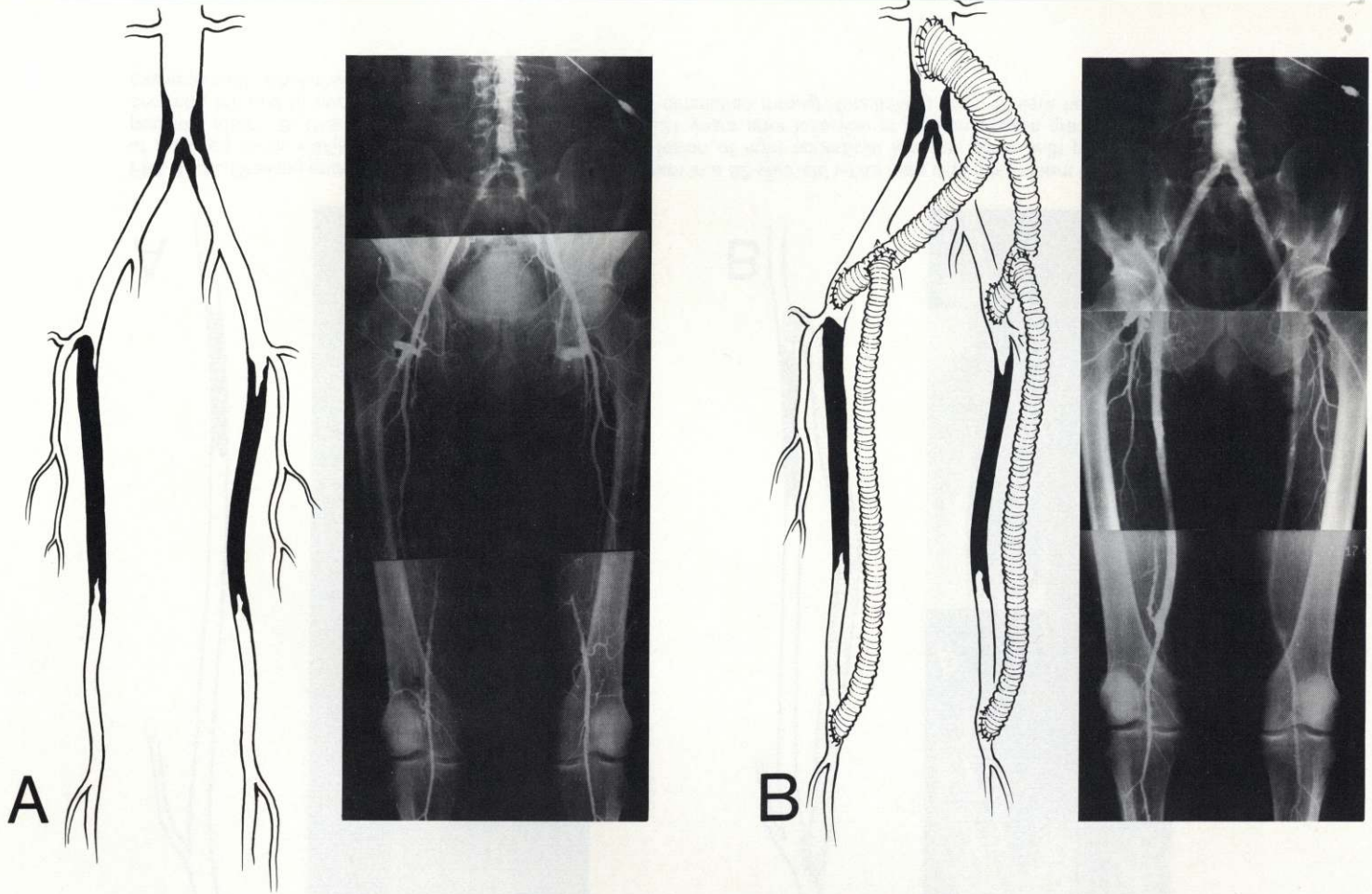


Fig. 15. A. Drawing and photograph of preoperative arteriogram of abdominal aorta and iliac and femoral arteries in a 65-year-old white man with intermittent claudication of legs showing well-localized atherosclerotic occlusive lesion of aorto-iliac segment and both superficial femoral arteries. B. Drawing and arteriogram of abdominal aorta and iliac and femoral arteries 11 years after insertion of Dacron bypass graft from abdominal aorta to both common femoral arteries and to both popliteal arteries showing restoration of normal circulation to legs. Patient has remained asymptomatic (cholesterol 144; triglycerides 122).

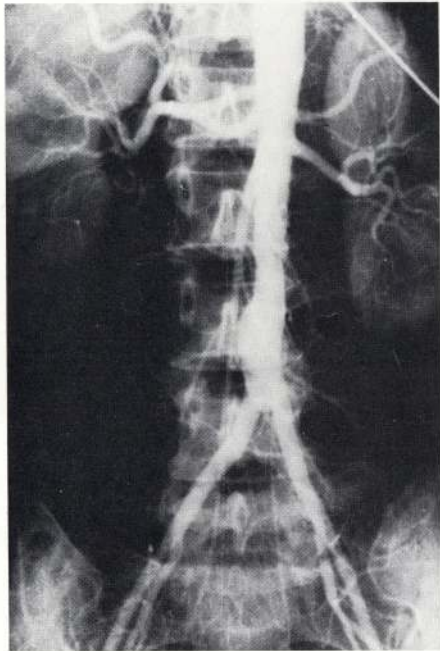
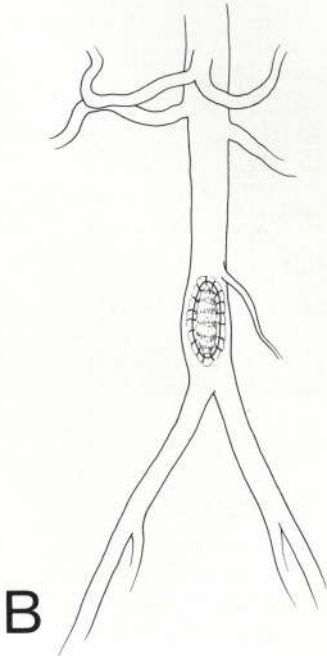
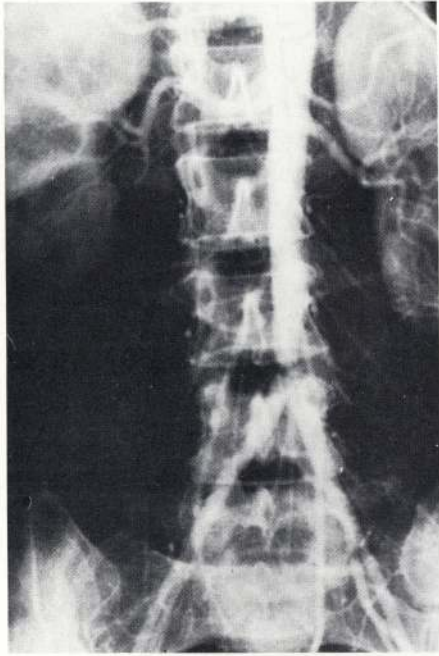
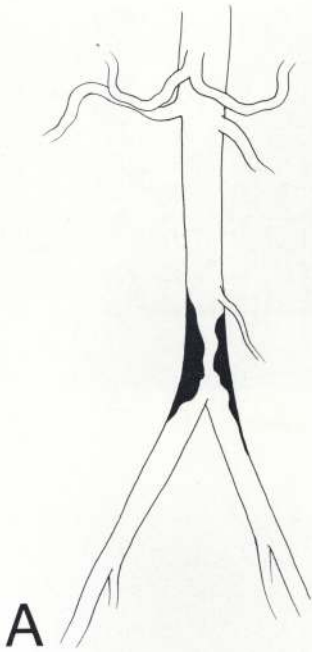


FIG. 16. A. Drawing and preoperative abdominal aortogram in a 48-year-old white woman with intermittent claudication of legs showing well-localized atherosclerotic occlusive disease in abdominal aorta above bifurcation. **B.** Drawing and abdominal aortogram 5 years after endarterectomy and patch graft angioplasty showing restoration of normal lumen and circulation to legs. Patient has remained asymptomatic (cholesterol 283).

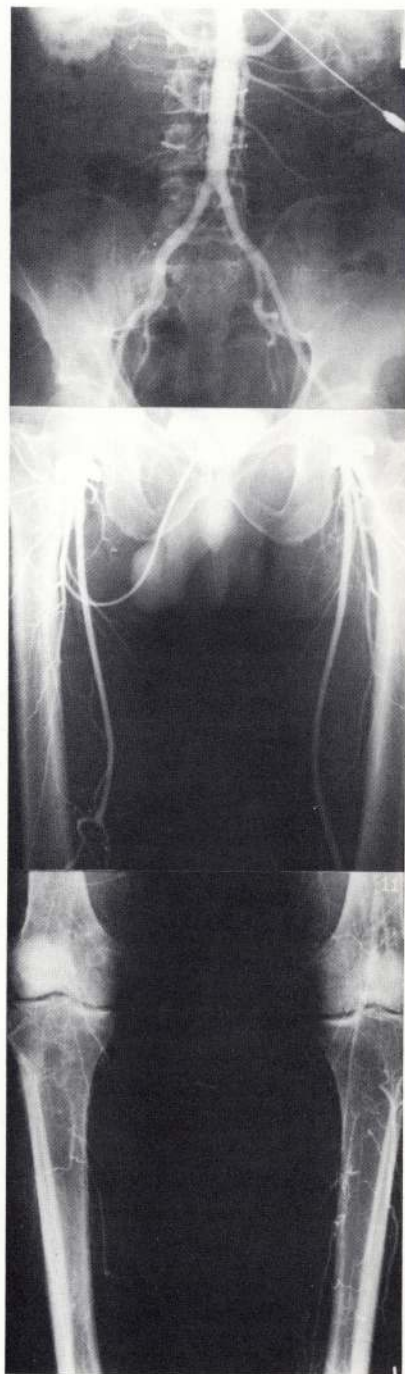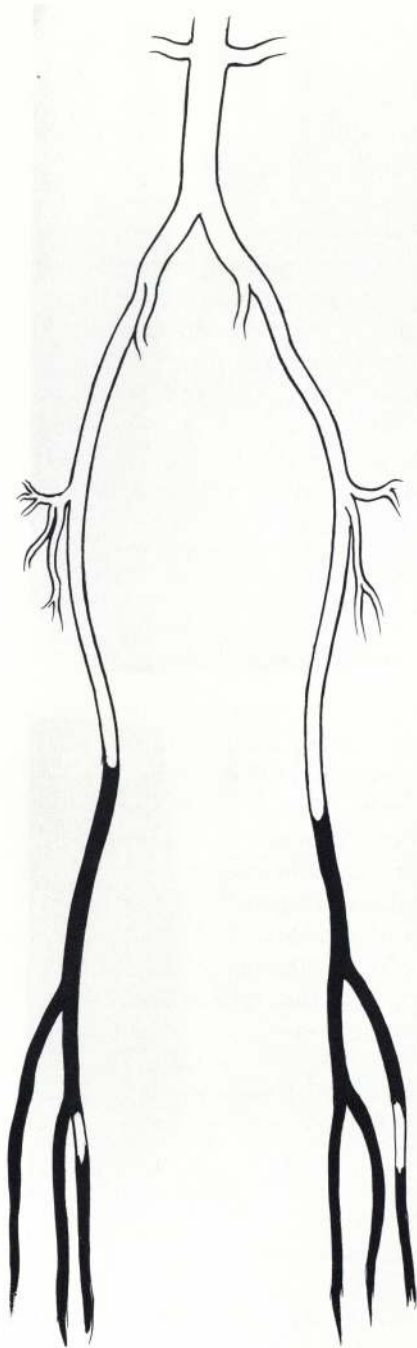


FIG. 17. Drawing and arteriogram of abdominal aorta and iliac and femoral arteries in a 40-year-old white man with severe intermittent claudication of legs showing complete atherosclerotic occlusive disease involving distal arterial bed, lower portion of superficial femoral, and all of popliteal arteries and their major branches.

Even in this group, patients with proximal disease of the major arteries arising from the aortic arch tend to be younger than those with disease of the carotid arteries at their bifurcation and of the vertebral arteries. This is true for both male and female patients, and the sex ratio is about 3 to 2. An interesting and curious difference in Negroes is the prevalence of the distal occlusive patterns and the significant uncommon occurrence of the proximal patterns. In still other patients, the patterns of occlusion are predominantly in the coronary arterial bed, with little or no evidence of disease elsewhere. In this group the disease tends to develop in both sexes at an earlier age than in those with involvement of the carotid arterial tree. Similarly, in patients with predominant aorto-iliac occlusion, the disease tends to develop at an earlier age than in those with the more distal femoro-popliteal pattern, but the sex ratio here is about 10 males to 1 female. The various patterns of anatomic distribution of the disease may also occur simultaneously in some patients (Figs. 18-20), whereas in others this may take place over a period of time that may extend from several years to as much as 15 to 20 years (Figs. 21-23).

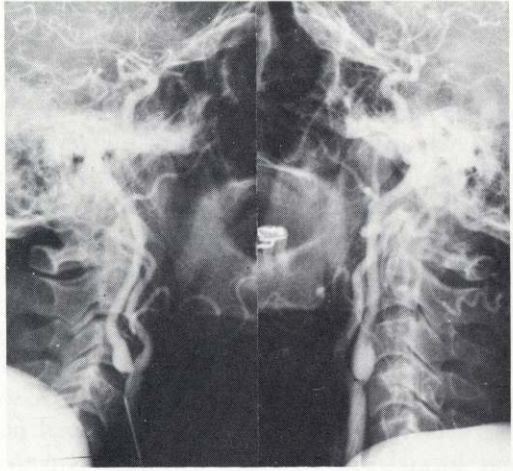
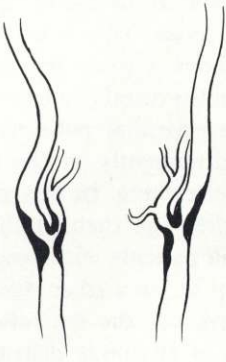
RATES OF PROGRESSION

One of the most interesting, and perhaps one of the most important, observations derived from our long-term follow-up studies, including arteriography, is concerned with the different rates of progression of atherosclerosis. In general these rates may be categorized into three groups. Group 1 is characterized by a rapid rate of progression, usually within a period of one to three years. When first observed clinically and arteriographically, the atheroma in patients in this group appears to be relatively insignificant, but in a few years it becomes clinically significant, and arteriography discloses the atheroma to be producing severe stenosis or complete occlusion of the lumen. These atherosclerotic plaques may be well-localized to a small segment of the artery, or they may be more extensive. They have been observed at most of the anatomic sites of distribution previously described, with some evidence that they occur more frequently in the carotid (Fig. 24), coronary (Figs. 25,26), and femoral arterial beds (Fig. 27). There is also some reason to believe that patients of both sexes in this group tend to be younger than in other groups.

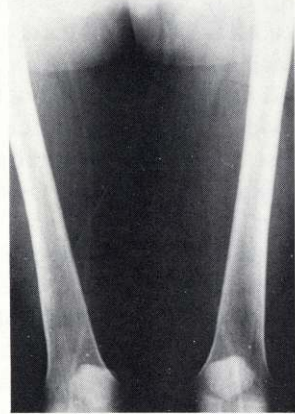
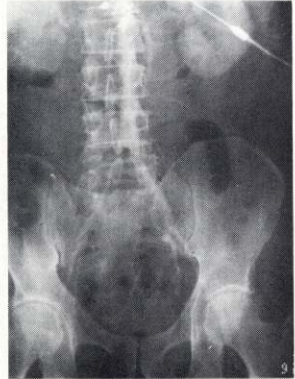Group 2 is characterized by a more moderate or intermediate rate of progression, usually over a period of five to eight years. Both in regard to clinical manifestations and arteriographic evidence, the atheroma in this group of patients proceeds from relative insignificance to severe encroachment on the lumen with consequent ischemic changes. Here again the disease in this group has been observed at most of the anatomic sites previously described (Figs. 28-30). There is no particularly significant sex or age factor in this group. A higher proportion of patients falls into this group than in the others.

Group 3 is characterized by very slow development, usually over a period of 10 years or more (Figs. 6,11,32). Indeed, some patients in this group have

from
 on of
 are in
 am to
 stant
 up the
 many
 I will
 letters
 going
 both
 third
 going
 thing

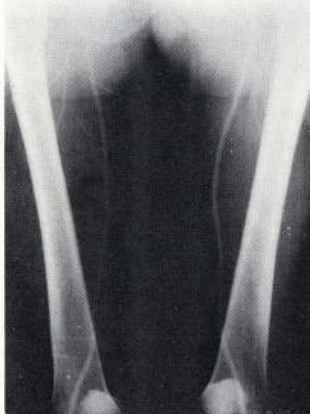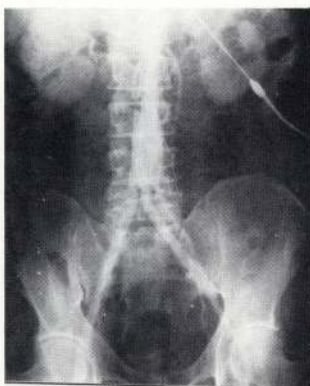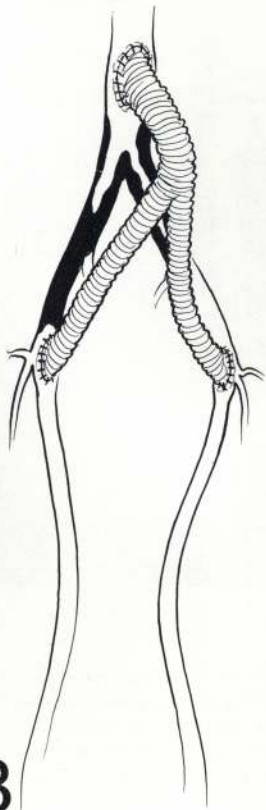
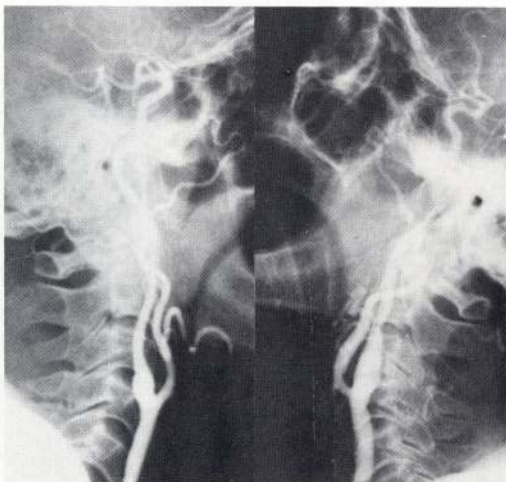


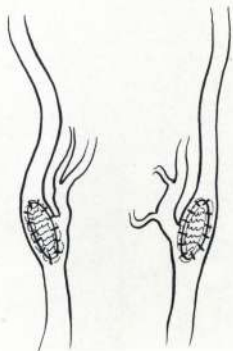all to
 of the
 what
 with
 and by
 could
 they
 have
 from



A

FIG. 18.A. Drawing and photograph of preoperative arteriogram of carotid arteries, abdominal aorta, and iliac and femoral arteries in a 53-year-old white man with intermittent claudication of legs and mild transient ischemic attacks of cerebrovascular insufficiency showing severe well-localized atherosclerotic disease involving both common carotid arteries at the bifurcation and origin of the internal carotid arteries and well-localized severe atherosclerotic occlusive disease of aorto-iliac segment.



B

FIG. 18. B. Drawing and photograph of arteriogram 17 years after endarterectomy with patch graft angioplasty of both carotid arteries and Dacron bypass graft from abdominal aorta to both common femoral arteries showing restoration of normal lumen and circulation in both carotid arteries and to legs with no evidence of progression of atherosclerosis. Patient has remained asymptomatic (cholesterol 226; triglycerides 172).

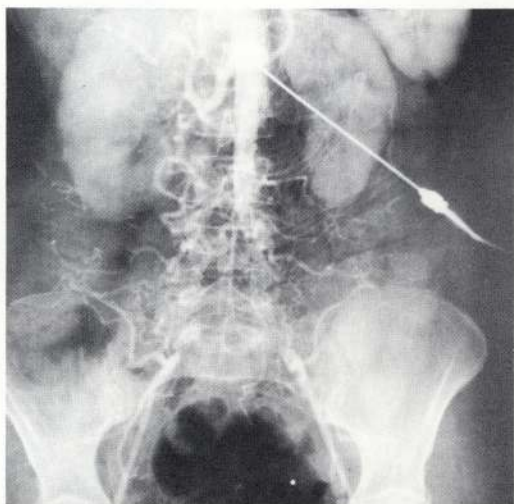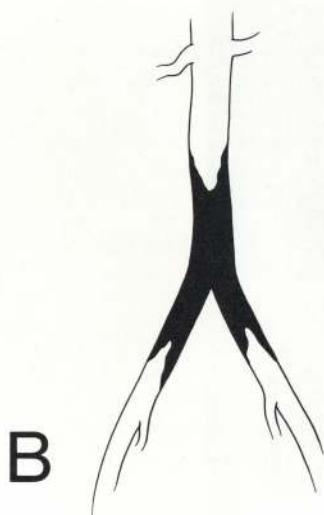

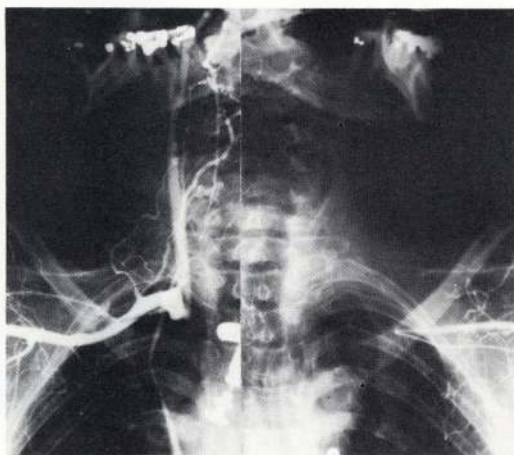

FIG. 19. A. Drawing and photograph of preoperative arteriogram of aortic arch in 55-year-old white woman with symptoms of cerebrovascular insufficiency and intermittent claudication of arms showing well-localized atherosclerotic occlusive disease of innominate and left subclavian arteries. B. Drawing and photograph of abdominal aortogram in same patient with intermittent claudication of legs showing atherosclerotic occlusive disease of aorto-iliac segment.

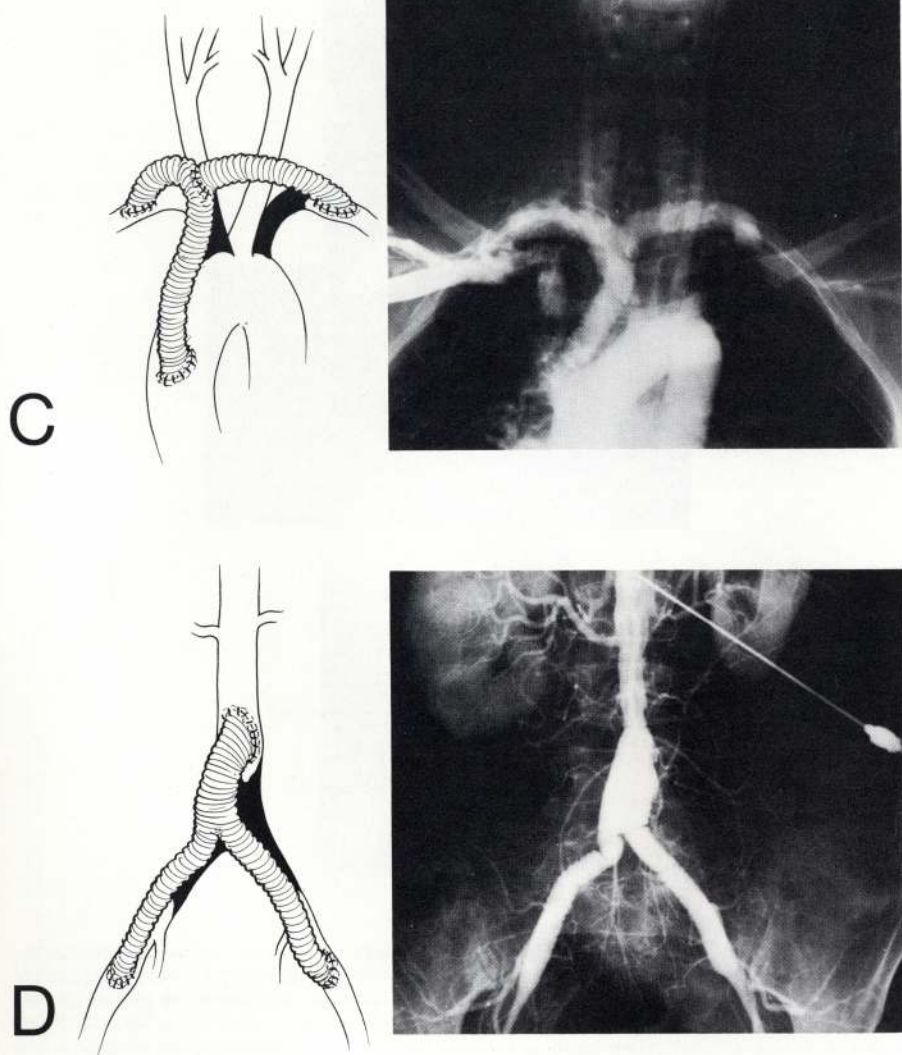


FIG. 19. C. Drawing and arch aortogram almost 15 years after insertion of Dacron bypass graft from ascending aorta to both subclavian arteries distal to occlusive disease showing restoration of normal circulation. D. Drawing and abdominal aortogram in same patient almost 15 years after insertion of Dacron bypass graft from abdominal aorta to both external iliac arteries showing restoration of normal circulation to legs. Patient has remained asymptomatic (cholesterol 240; triglycerides 227).

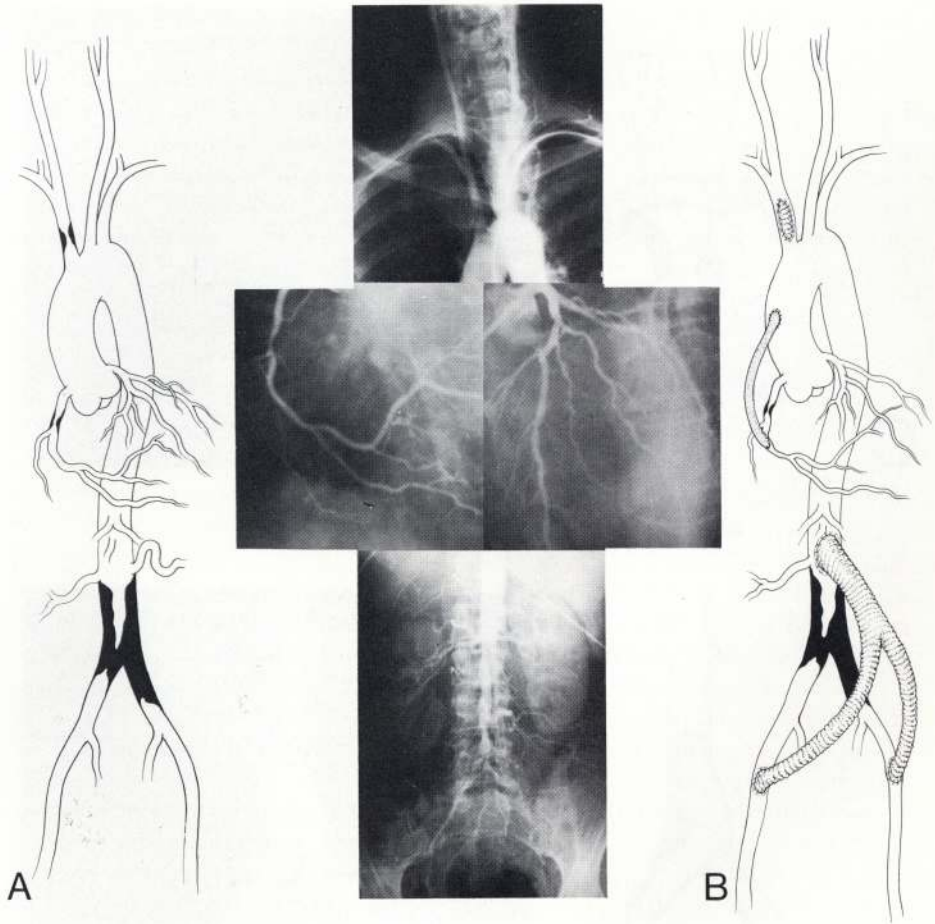


FIG. 20. A. Drawing and photograph of preoperative arch aortogram, coronary arteriogram, and abdominal aortogram in a 40-year-old white woman with manifestations of syncopal attacks, severe angina, and intermittent claudication of legs, showing well-localized atherosclerotic occlusive disease in innominate artery, right coronary artery, and aorto-iliac segment. B. Drawing showing corrective endarterectomy and patch graft angioplasty of innominate artery and saphenous vein bypass from ascending aorta to right coronary artery distal to occlusive lesion performed a few months before second-stage insertion of Dacron bypass graft from abdominal aorta to both external iliac arteries. Patient has remained asymptomatic for 7 years since operation (cholesterol 247; triglycerides 181).

been observed for periods of up to 20 years after surgical correction of the atherosclerotic disease and showed no evidence of further development or progression of the disease (Figs. 1,5,7,10,13,14,18,19,31). Here again there is no particularly significant sex or age factor in this group. In other patients there may be no progression of the disease at the original site in the arterial

bed, but, later, disease appears at another site in the same arterial bed. Thus, for example, a patient with aorto-iliac occlusive disease that has been surgically corrected may be found to have significant atherosclerotic occlusive disease in the superficial femoral arteries 10 years later (Fig. 32). In still other patients progression may take place in different arterial beds, as exemplified by the occurrence of the disease first in the carotid arterial bed, later in the aorto-iliac or femoral arteries, and still later, in the coronary arterial bed, but with little or no progression of the disease in the arterial bed of the original site of involvement (Figs. 11,21-23,33).

CLINICAL SIGNIFICANCE

On the basis of these observations derived from our experience with more than 15,000 patients during a period of more than 25 years, including documentation by follow-up arteriography, it is apparent that the syndrome complex referred to as arteriosclerosis or atherosclerosis represents several or more different entities, each having distinctive anatomicopathologic and clinical characteristics. Whereas it has long been known that an atheroma may develop insidiously, enlarge continuously, and produce clinical manifestations when it encroaches sufficiently on the lumen to impede circulation, either by its actual size or by ulcerative changes with superimposed thrombosis, it is now apparent that these atherosclerotic lesions vary considerably in their anatomicopathologic characteristics and have a distinctive tendency to assume well-defined patterns of involvement, in regard to both their sites of distribution in certain arterial beds and to their rates of progression.

As previously indicated, they may be classified into four major categories according to their occurrence in certain arterial beds, with a distinctive tendency to assume predominantly proximal or distal involvement or to be highly segmental or more diffuse with multiple sites of involvement. Although the presenting and predominant clinical manifestations of patients usually reflect one of these categories, various combinations of these categories may occur in some patients either simultaneously or sequentially.

Also of considerable clinical significance are the patterns characterized by the different rates of progression that are classified into three categories: (1) slowly progressive, (2) moderately progressive, and (3) rapidly progressive. Of particular significance, and not generally appreciated, is the fact that in some patients after surgical correction of the original well-localized process, there is no evidence of further progression of the disease in other parts of that arterial bed (Figs. 1,5,7,10,13,14,18,19,31). These observations would suggest that, at least in some patients, the disease tends to progress slowly up to a certain point, beyond which its progression is greatly retarded or even arrested. Indeed, they would further suggest that atherosclerosis in some patients is not necessarily a continuously progressing disease, but may even be self-limited.

Another curious and significant observation concerning the rate of progression

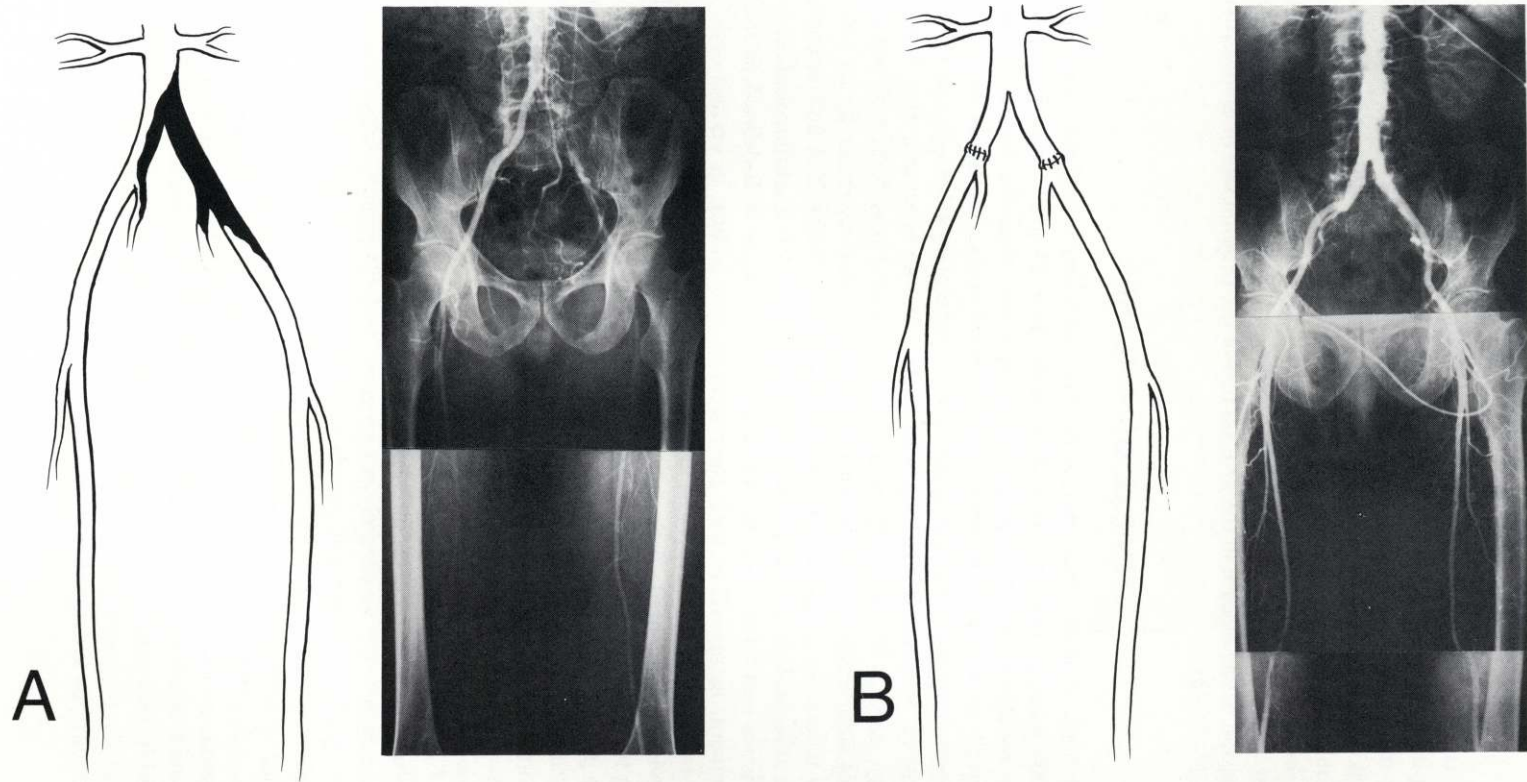
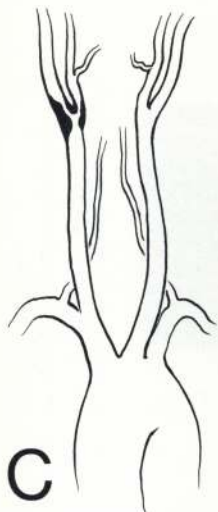
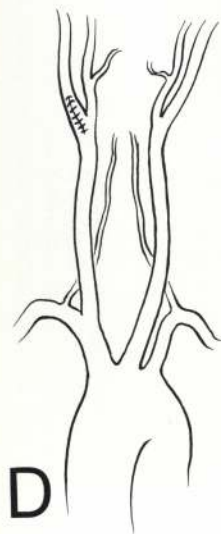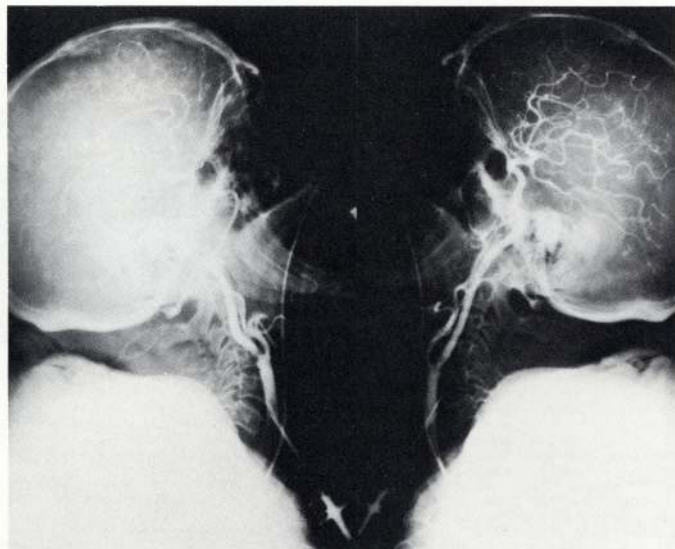


FIG. 21. **A.** Drawing and photograph of preoperative abdominal aortogram in a 46-year-old white man with intermittent claudication of legs showing well-localized atherosclerotic occlusive disease of aorto-iliac segment. **B.** Drawing and photograph of abdominal aortogram 21 years after aorto-iliac endarterectomy showing restoration of normal circulation to legs with no recurrence of atherosclerosis in this arterial bed.



C



D

FIG. 21.C. Drawing and photograph of preoperative arteriogram of carotid arteries in same patient with cerebral transient ischemic attacks showing well-localized atherosclerotic disease involving bifurcation of right common carotid artery and origin of internal carotid artery 16 years after the aorto-iliac operation. **D.** Drawing showing endarterectomy with patch graft angioplasty of right common and internal carotid arteries. Patient has remained asymptomatic (cholesterol 154; triglycerides 131).

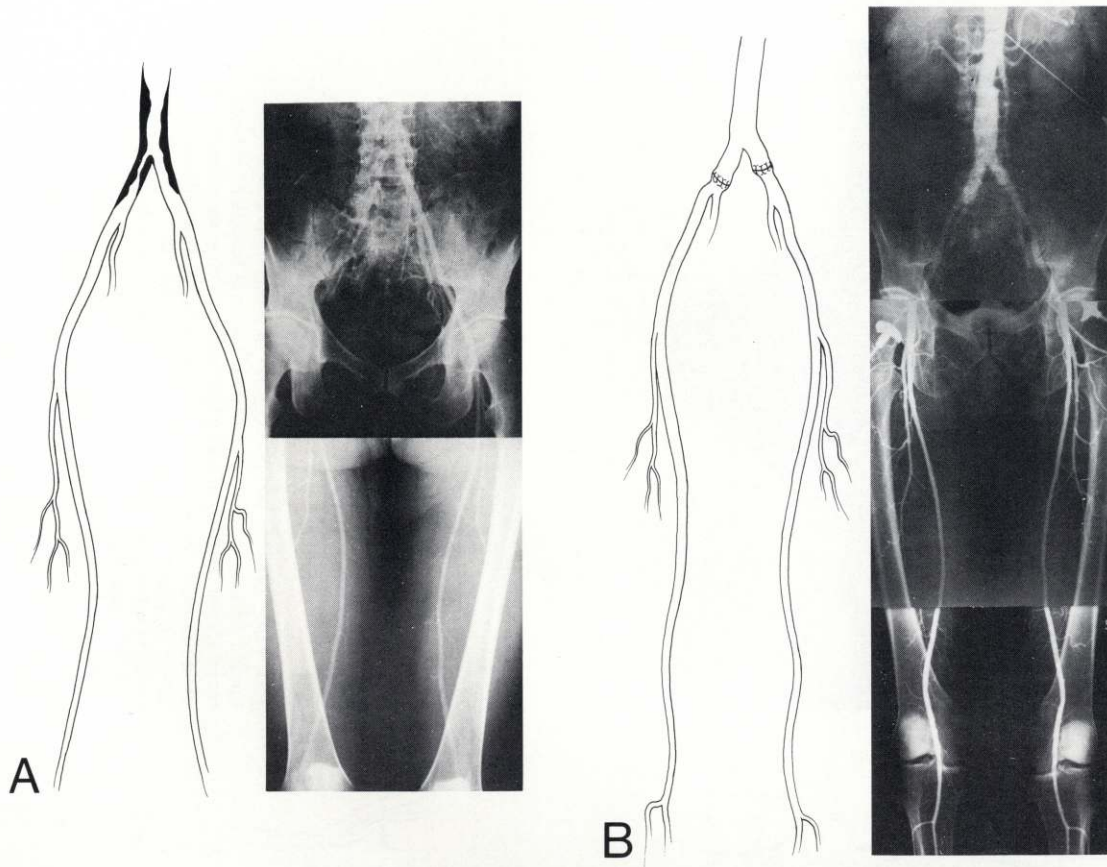


FIG. 22. A. Drawing and photograph of preoperative abdominal aortogram in a 40-year-old white man with intermittent claudication of legs showing well-localized atherosclerotic occlusive disease of aorto-iliac segment. B. Drawing and photograph of abdominal aortogram 20 years after operation showing restoration of normal lumen and normal circulation to legs with no evidence of recurrence or development of atherosclerotic disease in this arterial bed.

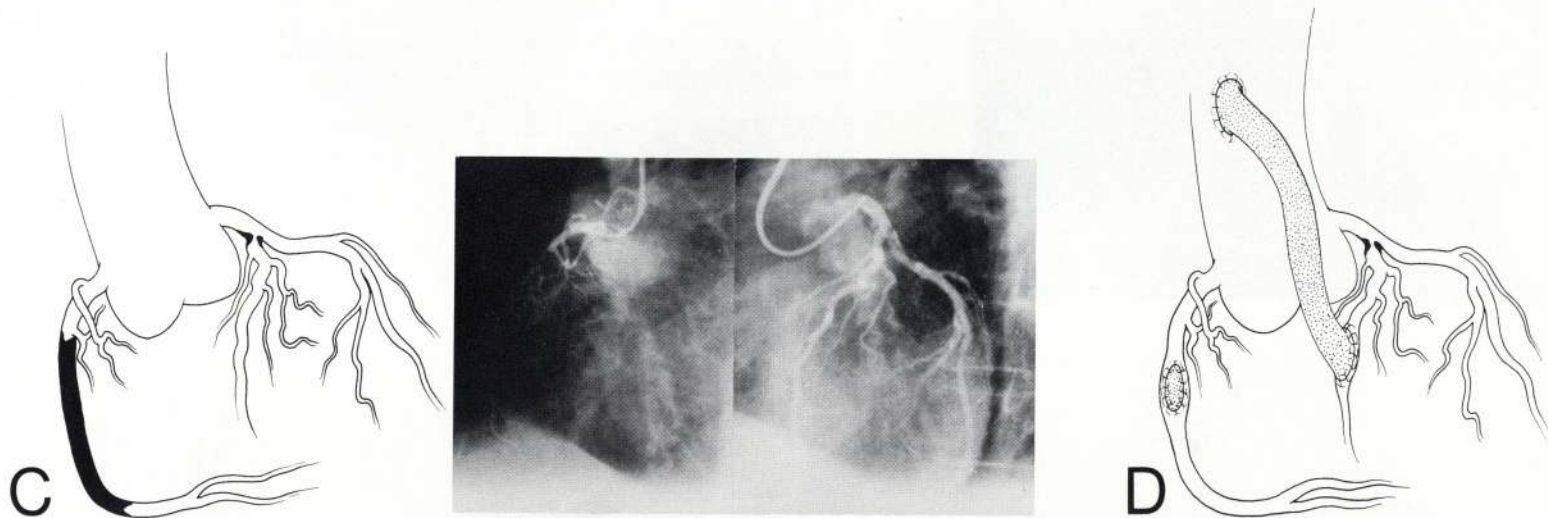


FIG. 22. C. Drawing and photograph of coronary arteriogram in same patient with severe angina 15 years after operation on aorto-iliac disease showing atherosclerotic occlusive disease of right coronary artery and left anterior descending coronary artery. D. Drawing showing endarterectomy with patch graft angioplasty of right coronary artery and saphenous vein bypass from ascending aorta to left anterior descending coronary artery. Patient has remained asymptomatic since both operations (cholesterol 177; triglycerides 87).

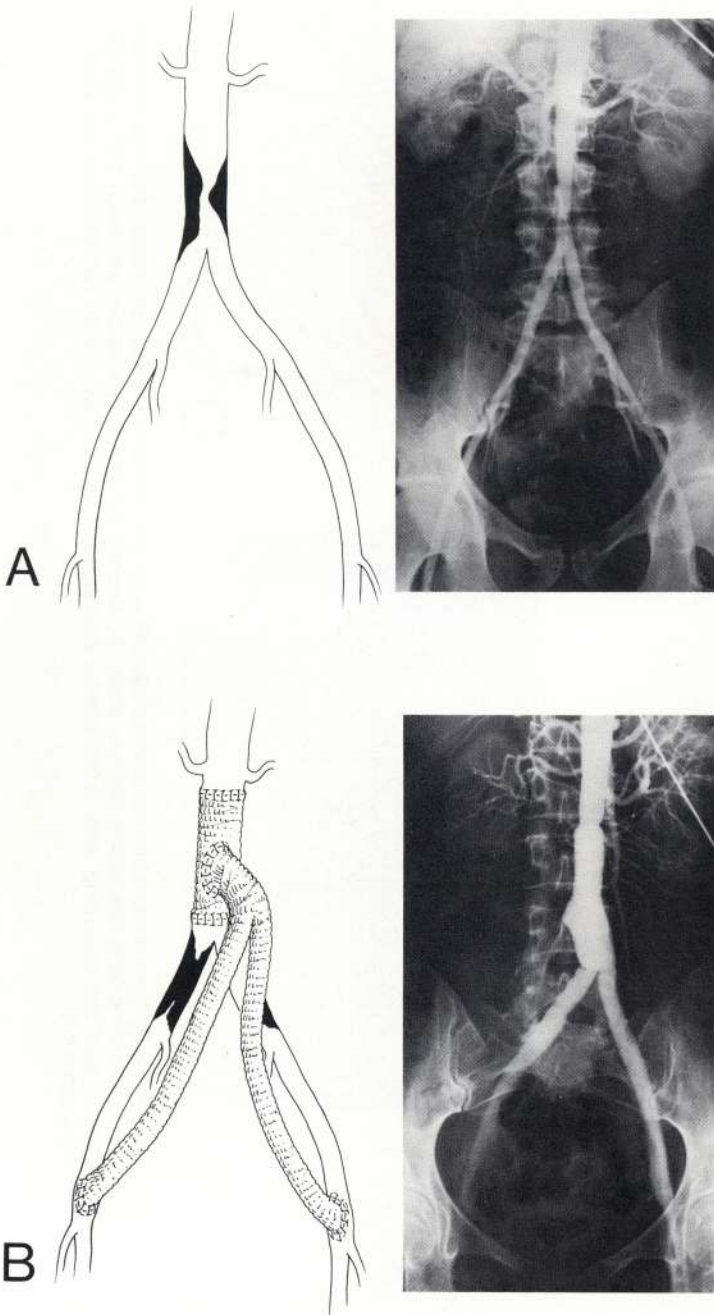


FIG. 23.A. Drawing and photograph of preoperative aortogram in 46-year-old white woman with intermittent claudication of legs showing well-localized atherosclerotic occlusive disease in lower segment of abdominal aorta just above bifurcation. **B.** Drawing and abdominal aortogram 21 years after excision of lower abdominal aorta with Dacron graft replacement and bypass graft to both common femoral arteries showing restoration of normal circulation to legs.

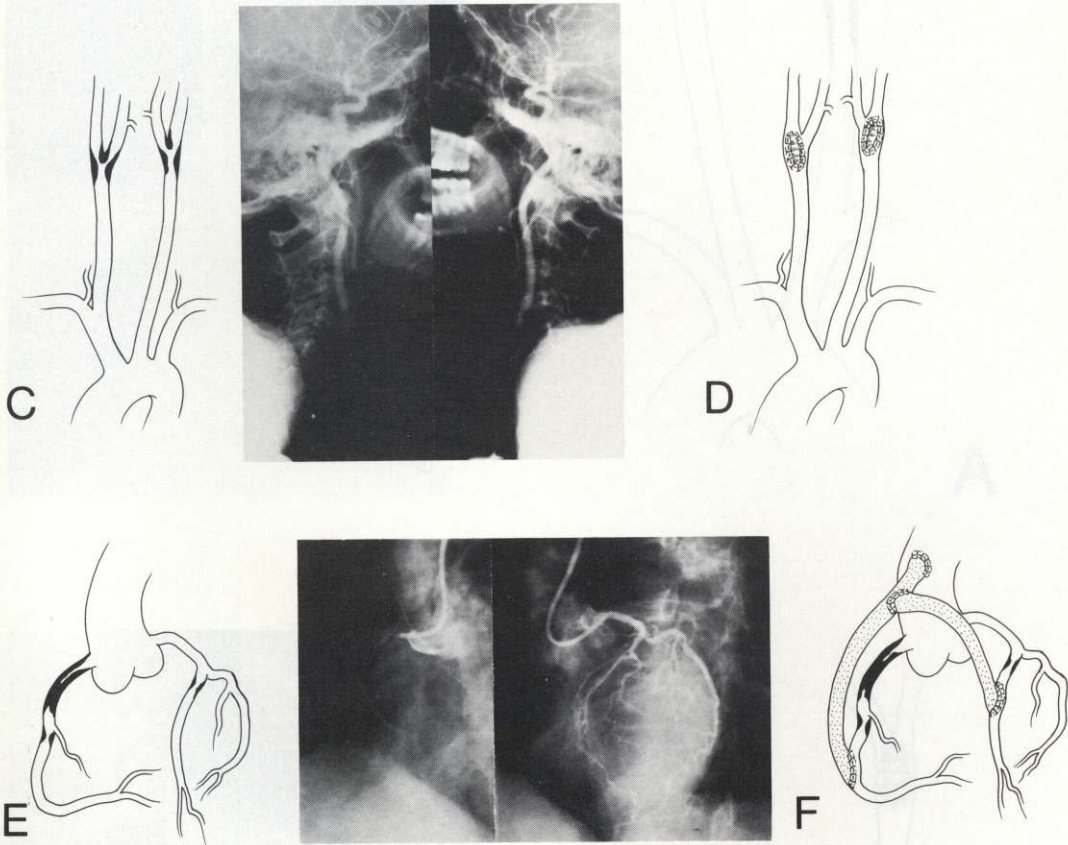
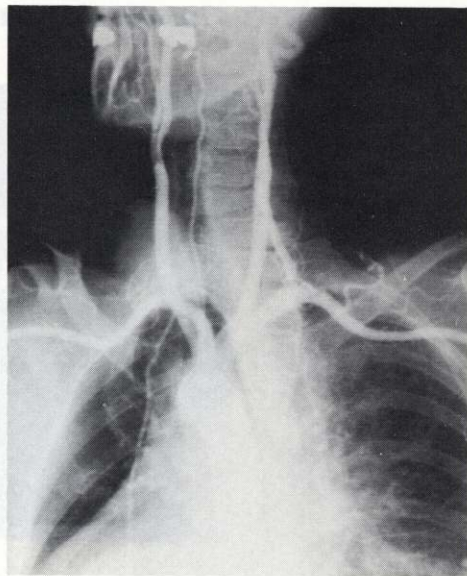
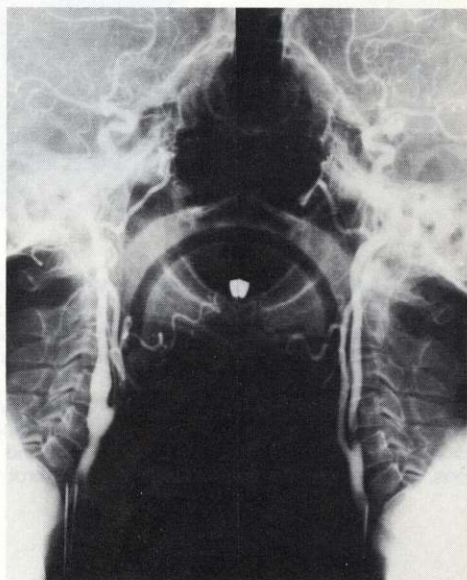
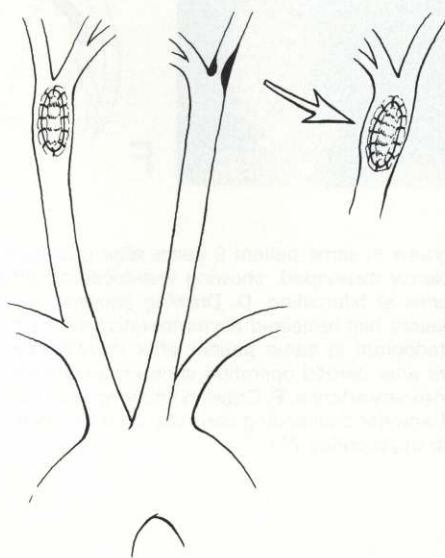


FIG. 23. C. Drawing and photograph of carotid arteriograms in same patient 9 years after previously described operation when symptoms of cerebrovascular insufficiency developed, showing well-localized atherosclerotic occlusive disease involving both common carotid arteries at bifurcation. D. Drawing showing endarterectomy with patch graft angioplasty of both carotid arteries. Patient has remained asymptomatic from cerebrovascular standpoint. E. Drawing and preoperative coronary arteriogram in same patient after development of severe angina 19 years after aorto-iliac operation and 10 years after carotid operation showing severe atherosclerotic occlusive disease of right and left anterior descending coronary arteries. F. Drawing showing treatment by autogenous vein bypass from ascending aorta to right and left anterior descending coronary arteries distal to occlusive lesions. Patient remains asymptomatic (cholesterol 138; triglycerides 76).



A



B

FIG. 24. A. Drawing and photograph of preoperative carotid arteriograms in a 59-year-old white woman with cerebral transient ischemic attacks showing well-localized atherosclerotic occlusive disease involving bifurcation of right common carotid artery and origin of internal carotid artery treated at that time by endarterectomy and patch graft angioplasty. Note that left carotid artery showed no significant disease at that time. B. Drawing and photograph of carotid arteriogram in same patient a little more than 2 years later, when symptoms of cerebrovascular insufficiency involving left carotid system had developed, showing restoration of normal circulation in right carotid artery but development of severe, stenotic, well-localized atherosclerotic disease involving bifurcation of left common and internal carotid arteries. This was treated by endarterectomy and patch graft angioplasty, and patient has since remained asymptomatic for past 4 years (cholesterol 249; triglycerides 93).

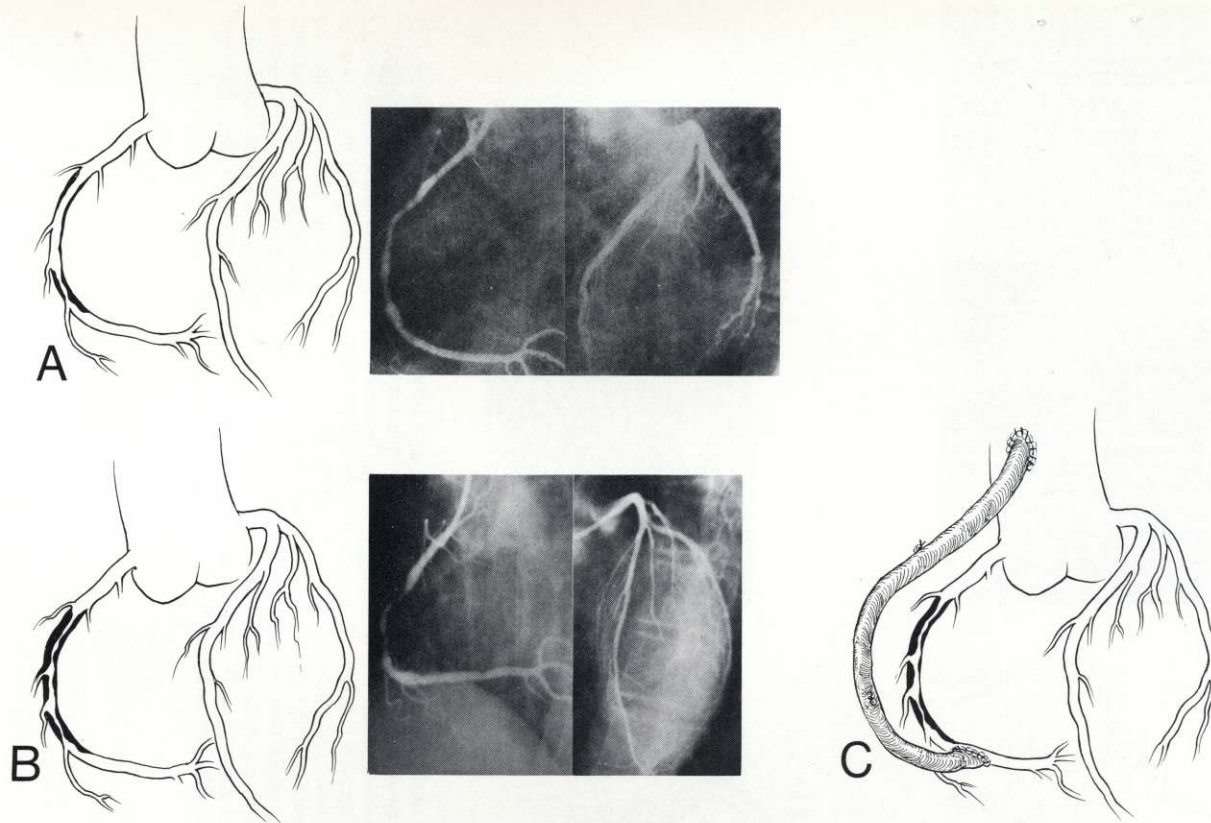


FIG. 25. A. Drawing and photograph of coronary arteriograms in a 61-year-old white woman with mild angina showing mild and relatively insignificant atherosclerotic occlusive disease in midportion of right coronary artery. Patient was treated by medical regimen. B. Drawing and photograph of coronary arteriogram 2 years later in same patient, now with severe angina, showing significant progress of atherosclerotic occlusive disease in right coronary artery producing severe stenosis. C. Drawing showing autogenous vein bypass from ascending aorta to right coronary artery distal to stenotic lesion. Patient has remained asymptomatic (cholesterol 239; triglycerides 191).

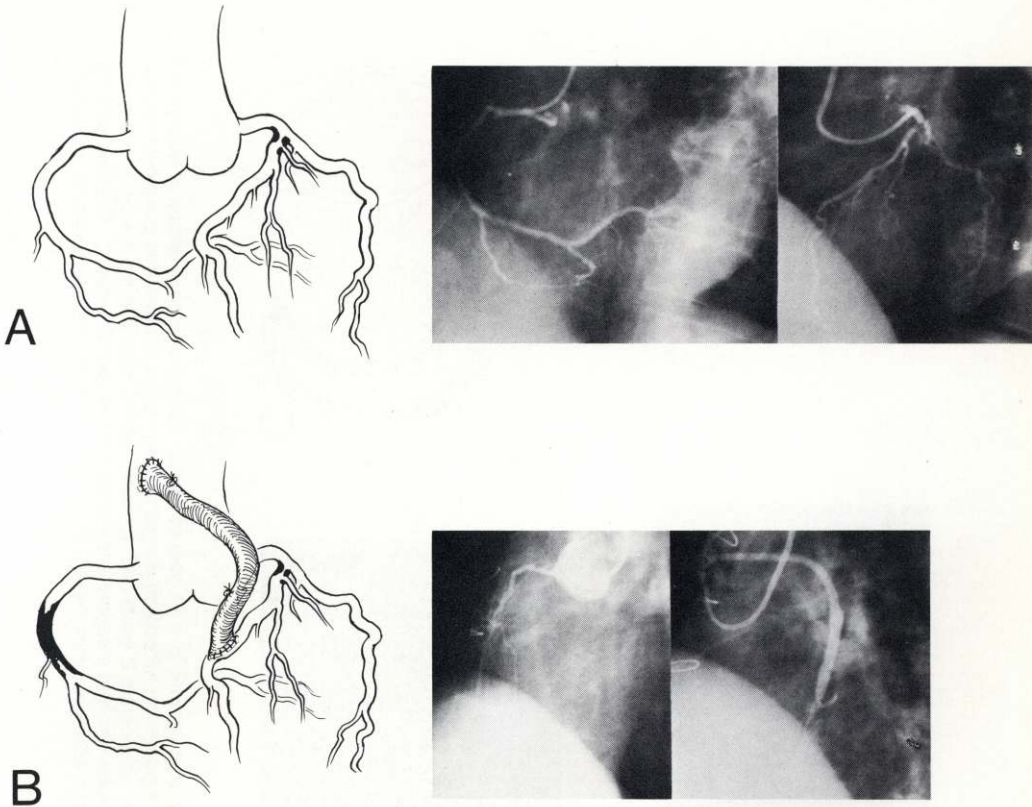


FIG. 26.A. Drawing and photograph of coronary arteriograms in a 66-year-old white man complaining of severe angina, showing well-localized stenotic atherosclerotic occlusive lesion at origin of left anterior descending coronary artery. Treatment, consisting of autogenous vein bypass from ascending aorta to left anterior descending coronary artery, was followed by complete relief of symptoms. **B.** Drawing and photograph of coronary arteriograms in same patient made about 14 months after operation described in **A**, now showing extensive complete occlusion of right coronary artery and well-functioning bypass graft to left anterior descending coronary artery. The patient had resumed work and was asymptomatic for approximately 13 months after the operation when angina suddenly developed about 3 weeks prior to present admission. As may be observed, recurrence was caused by the rapid development and progression of the disease in the right coronary artery. A medical regimen was instituted (cholesterol 193; triglycerides 107).

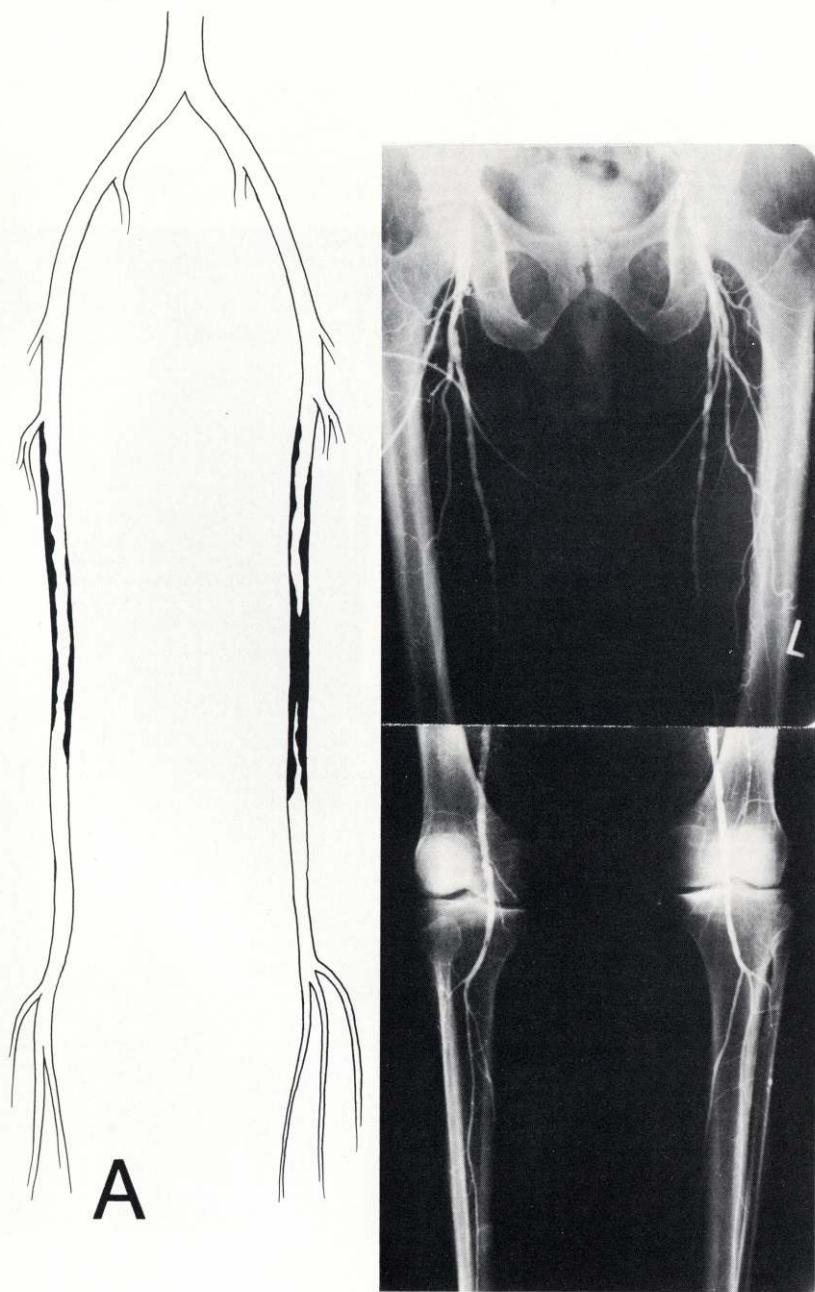


FIG. 27.A. Drawing and photograph of preoperative femoral arteriograms in 69-year-old white man with intermittent claudication of left leg showing well-localized atherosclerotic occlusive disease producing complete occlusion of left superficial femoral artery with patent distal popliteal artery treated by Dacron femoro-popliteal bypass graft. At this time he had only mild, insignificant atherosclerotic disease of right superficial femoral artery.

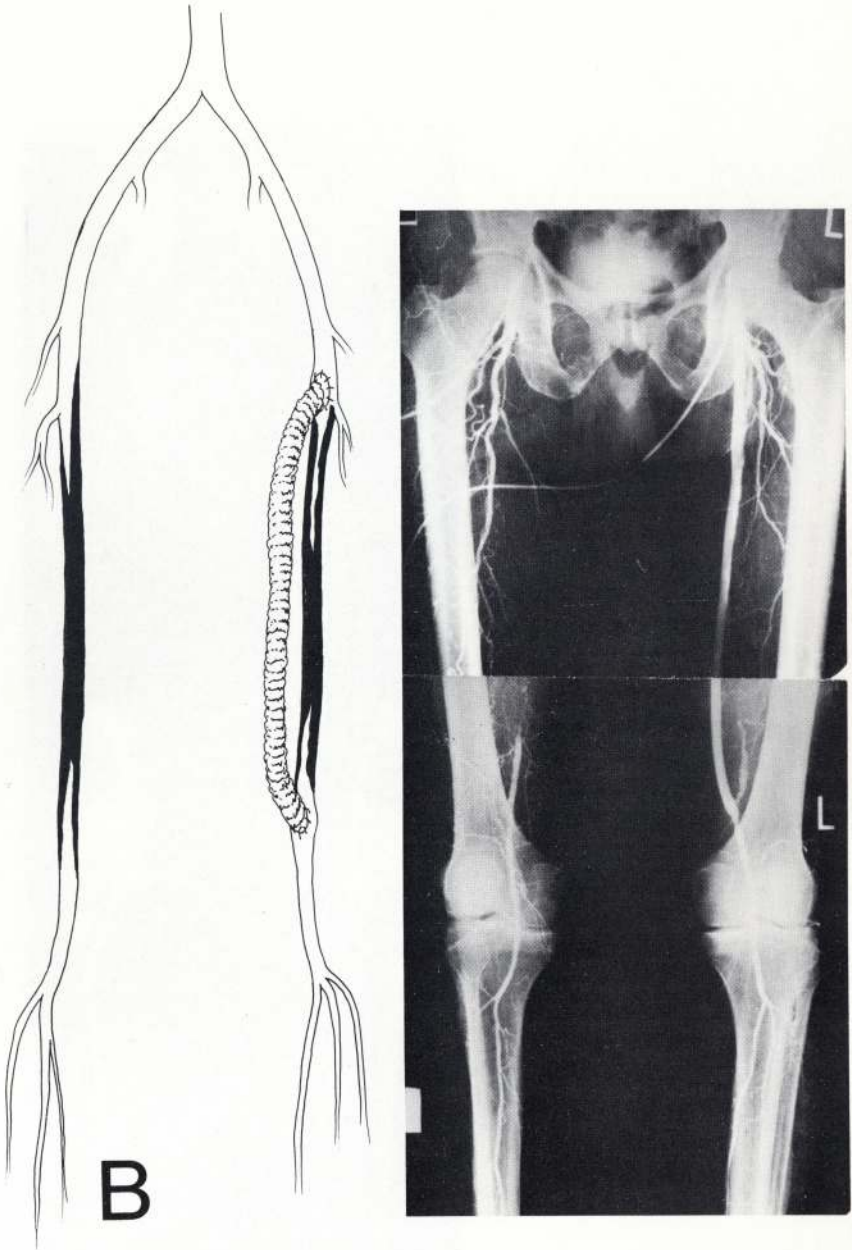


FIG. 27.B. Drawing and femoral arteriogram in same patient made a little more than 1 year later when intermittent claudication of right leg had developed, showing well-localized complete occlusion of right superficial femoral artery. Note restoration of normal circulation in left leg through functioning femoro-popliteal bypass graft.

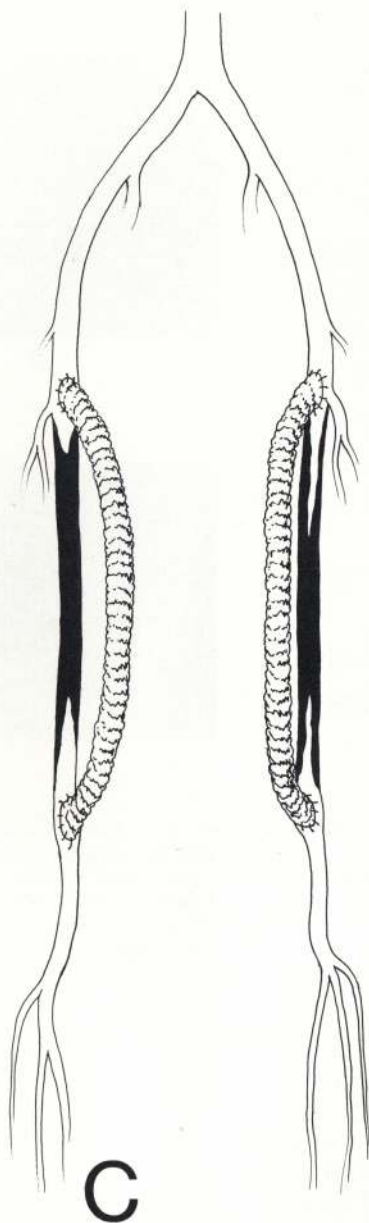


FIG. 27.C. Drawing showing treatment of left side by Dacron femoro-popliteal bypass graft. Patient has remained asymptomatic for past 2 years (cholesterol 190; triglycerides 224).

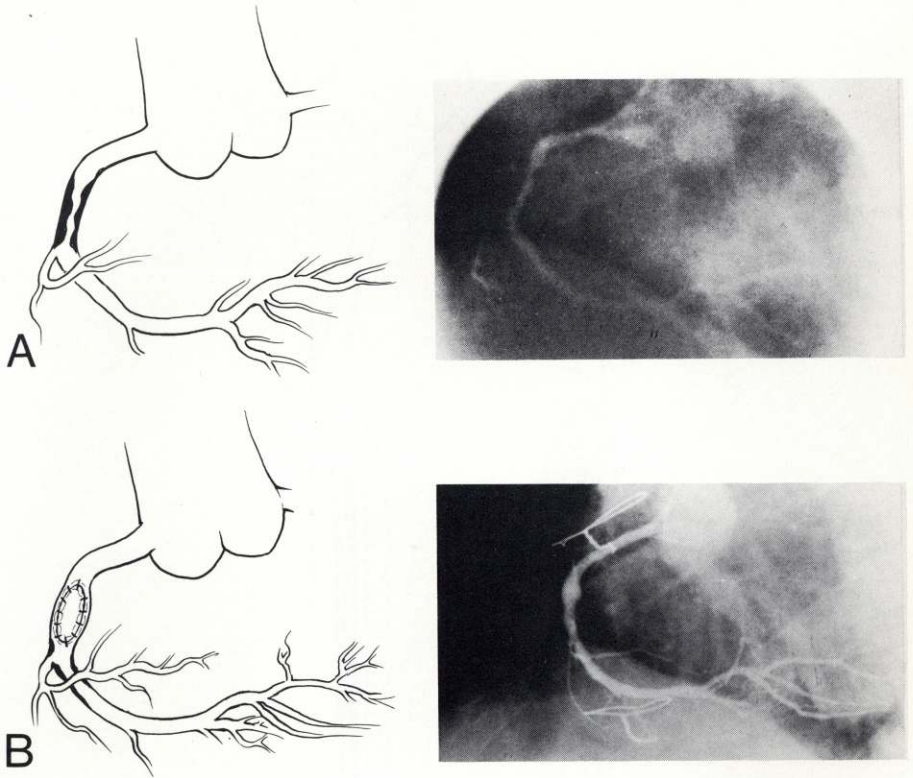


FIG. 28. A. Drawing and preoperative coronary arteriogram in a 46-year-old white man with severe angina showing well-localized atherosclerotic occlusive disease in midportion of right coronary artery treated by endarterectomy and patch graft angioplasty with relief of symptoms. B. Drawing and right coronary arteriogram in same patient 7 years after previous operation, when mild angina recurred, showing well-localized moderate stenosis of right coronary artery just distal to previous endarterectomy. Because patient's symptoms were mild, a medical regimen was instituted.

is the fact that although there may be no further progression of the disease in the arterial bed in which it was originally manifested, for periods up to 10 to 20 years, the disease may develop in another arterial bed many years later (Figs. 11,21,22,23,33). Moreover, the pattern of the atheromatous process often assumes similar characteristics in the new arterial site.

The various patterns of the disease and rates of progression have great significance from both prognostic and therapeutic standpoints. The main therapeutic objective for these various forms of atherosclerotic occlusive disease is restoration of normal circulation. The surgical procedures designed for this purpose based on the various patterns of the disease include thromboendarterectomy, excision with graft replacement, the bypass graft, and patch graft angioplasty. Both the feasibility of surgical treatment and the selection of the appropriate procedure

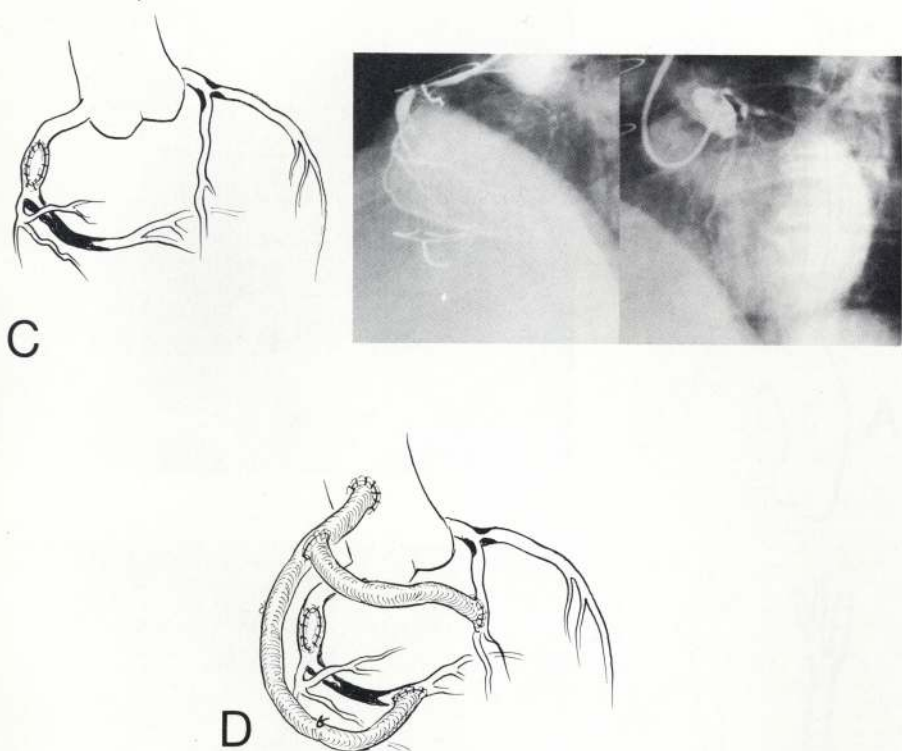


FIG. 28. C. Drawing and coronary arteriogram made 2 years later and 9 years after first operation in same patient, now having severe angina, showing progression of atherosclerotic disease in right coronary causing severe stenosis and development of another well-localized atherosclerotic lesion at origin of left anterior descending coronary artery. Patient had autogenous saphenous vein bypass from ascending aorta to right and left anterior descending coronary arteries distal to occlusive lesion and has been asymptomatic for past 4 years (cholesterol 199; triglycerides 116).

depend on the pattern of the disease. In general, surgical treatment is amenable to those patterns of the disease characterized by well-localized or segmental disease in which the distal part of the arterial bed is relatively normal, whereas those patterns characterized by extensive diffuse involvement throughout most of the arterial bed or predominantly affecting the distal part of the arterial bed are not amenable to effective surgical treatment.

Perhaps the most important factor influencing the prognosis in patients with atherosclerotic occlusive disease is the rate of progression of the disease. Its overriding importance is indicated by the fact that this statement would seem to be true irrespective of the pattern of the disease as originally manifested. To be sure, there are some reasons to believe that those patterns characterized by well-localized disease in the more proximal segments of the arterial bed tend to assume a slower rate of progression than those characterized by more

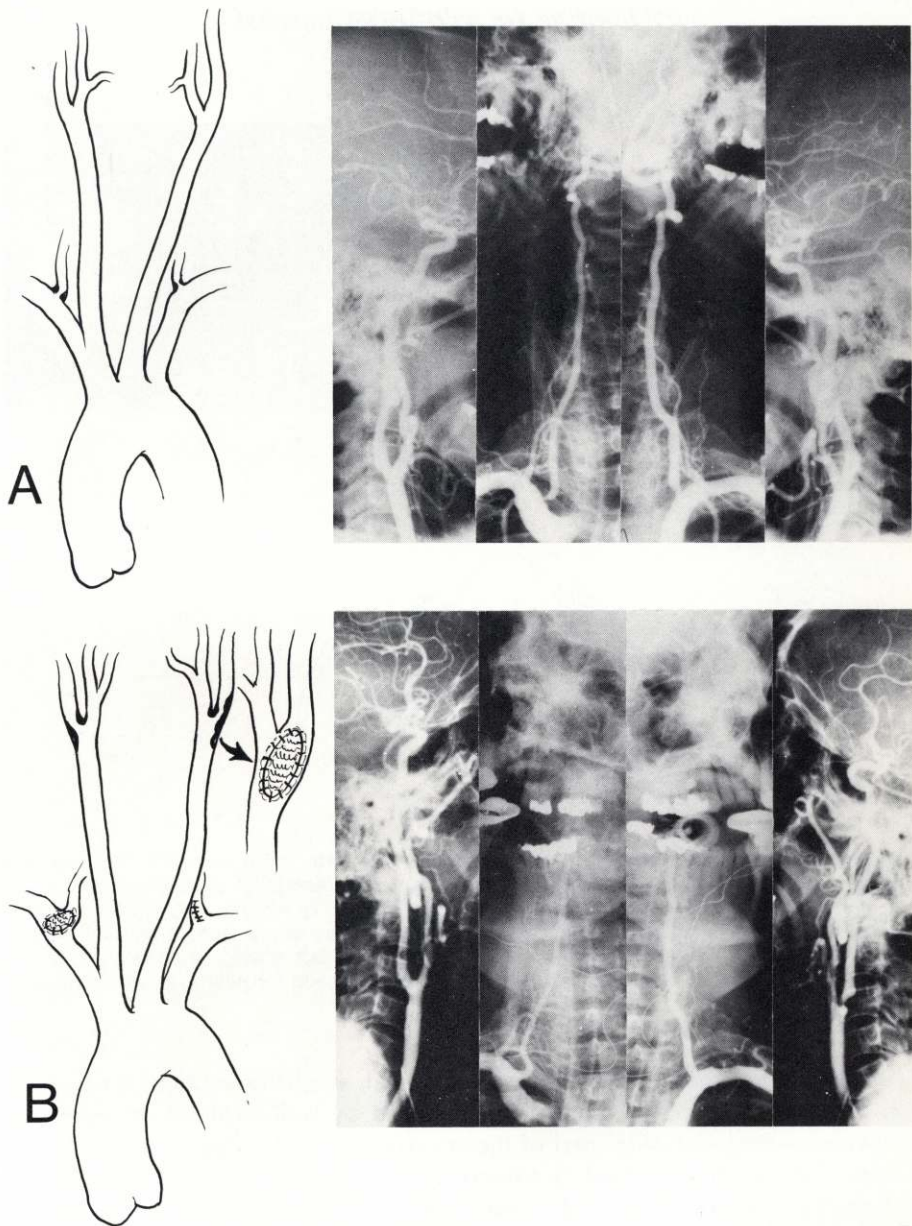


FIG. 29. A. Drawing and bilateral carotid and vertebral arteriograms in a 63-year-old white man with manifestations of basilar vertebral artery insufficiency, showing well-localized, severe atherosclerotic occlusive lesions at origin of both vertebral arteries, treated by endarterectomy and patch graft angioplasty with relief of symptoms. There is little or no involvement of carotid arteries at this time. B. Drawing and bilateral carotid and vertebral arteriograms 6 years later on same patient in whom manifestations of transient cerebral ischemic attacks involving left carotid system had recently developed, now showing development of severe, well-localized atherosclerotic occlusive lesion in left carotid artery with almost complete obstruction of left internal carotid artery requiring endarterectomy and patch graft angioplasty. Note correction of previous stenotic lesion of vertebral arteries. Patient has remained asymptomatic for past 3 years (cholesterol 175; triglycerides 258).

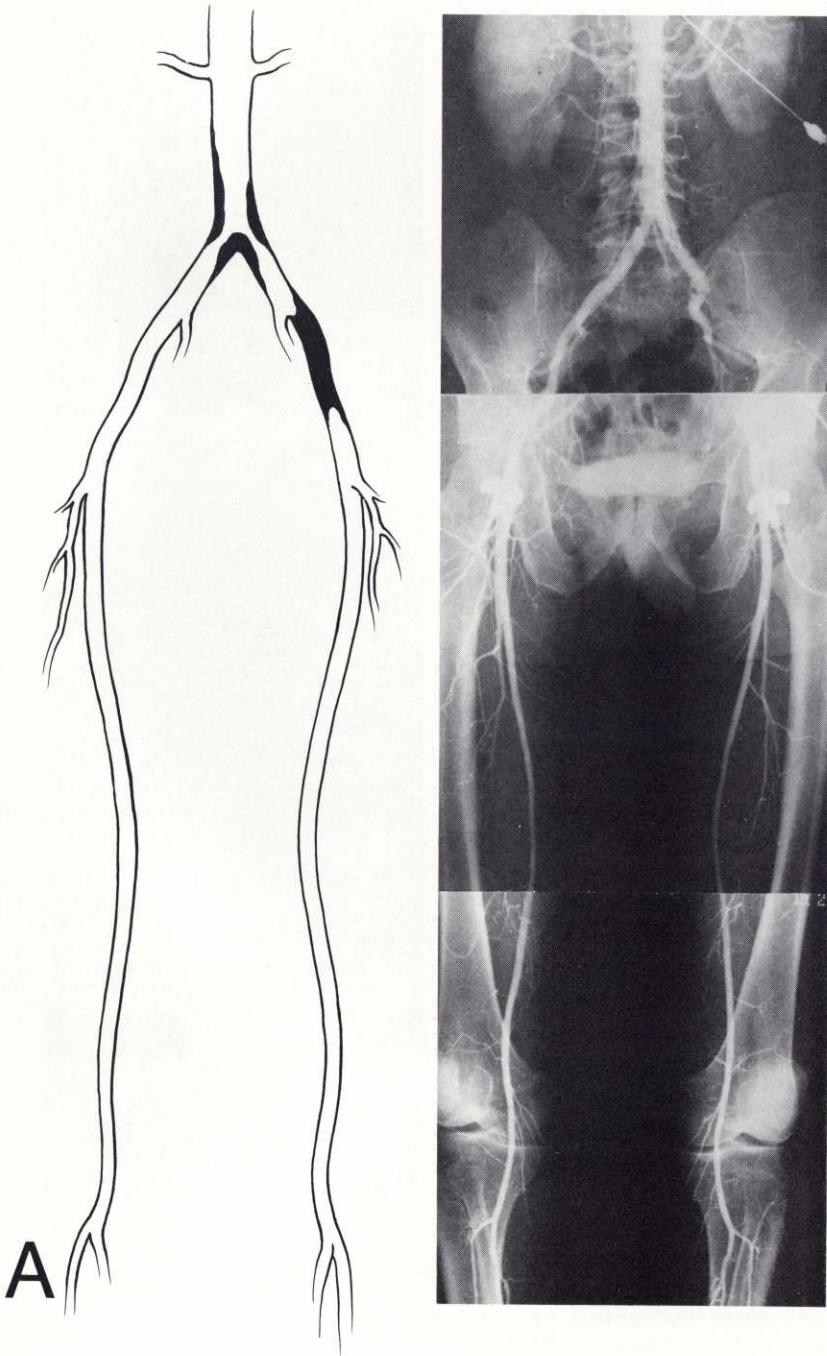


FIG. 30.A. Drawing and photograph of arteriograms of abdominal aorta and femoral and popliteal arteries in a 52-year-old white man, complaining of intermittent claudication of lower limbs, showing well-localized atherosclerotic occlusive lesions involving lower abdominal aorta and iliac arteries. Note that the femoro-popliteal arterial bed is free of disease. Treatment consisted of Dacron bifurcation bypass graft from abdominal aorta to right external iliac artery and left common femoral artery with relief of symptoms.

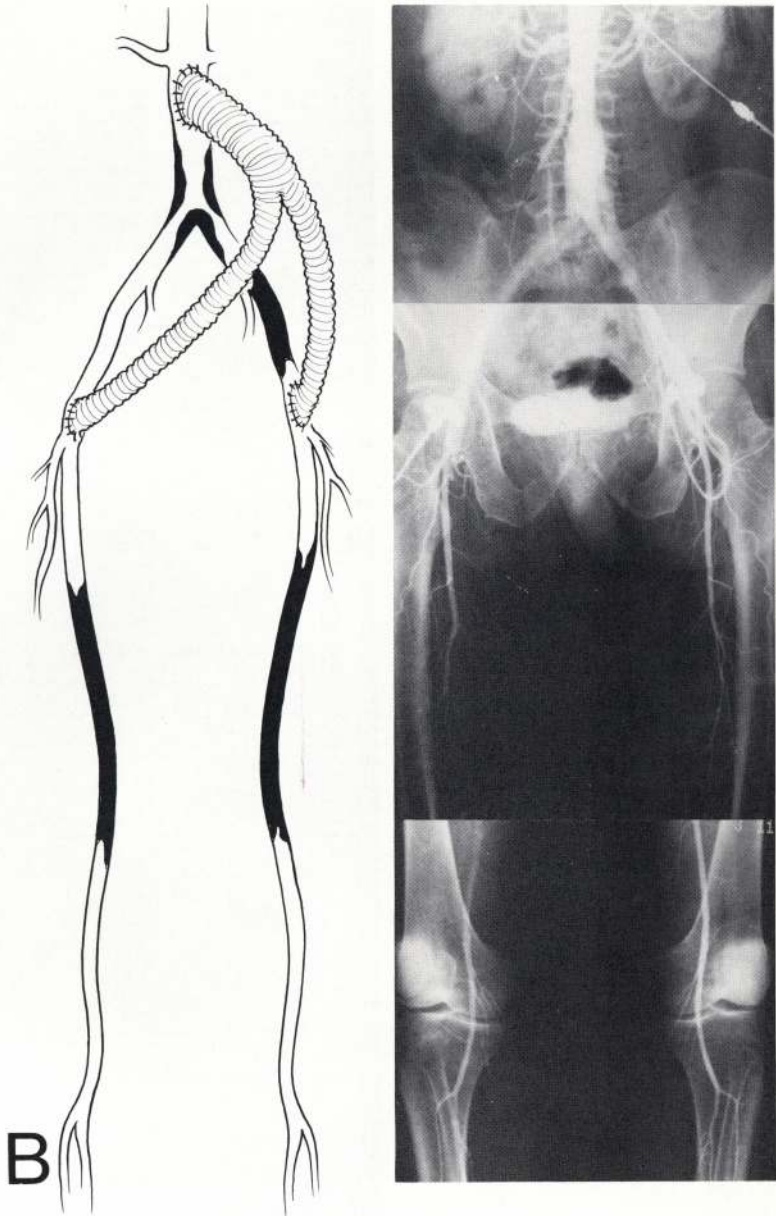


FIG. 30.B. Drawing and photograph of arteriograms of abdominal aorta and femoral and popliteal arteries made 7 years after previous operation in same patient in whom, during the past year, intermittent claudication of lower limbs developed, now showing well-localized occlusive lesions involving both superficial femoral arteries. Treatment consisted of Dacron bypass graft from common femoral to popliteal arteries bilaterally with complete relief of symptoms during past 6 years (cholesterol 200).

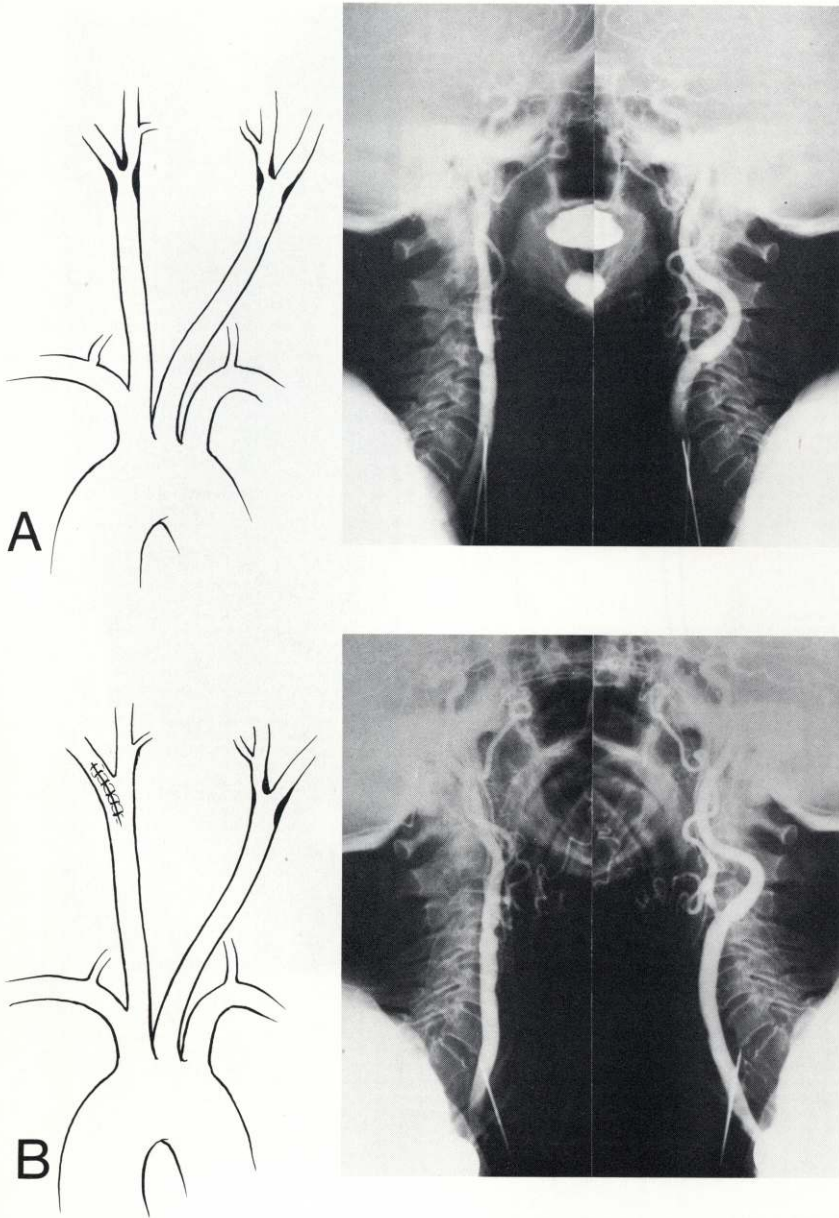


FIG. 31. A. Drawing and preoperative carotid arteriograms in a 69-year-old white woman with manifestations of cerebrovascular insufficiency of right carotid arterial system, showing well-localized, severe atherosclerotic occlusive lesion at bifurcation of right common and origin of internal carotid arteries, which was treated by endarterectomy. There was only very mild evidence of atherosclerotic disease in the left carotid artery. B. Drawing and bilateral carotid arteriograms in same patient 18 years later showing restoration of normal lumen and circulation in previously operated right carotid artery with no change in left carotid artery. Patient, who is now almost 88 years old, has remained asymptomatic (cholesterol 235; triglycerides 234).

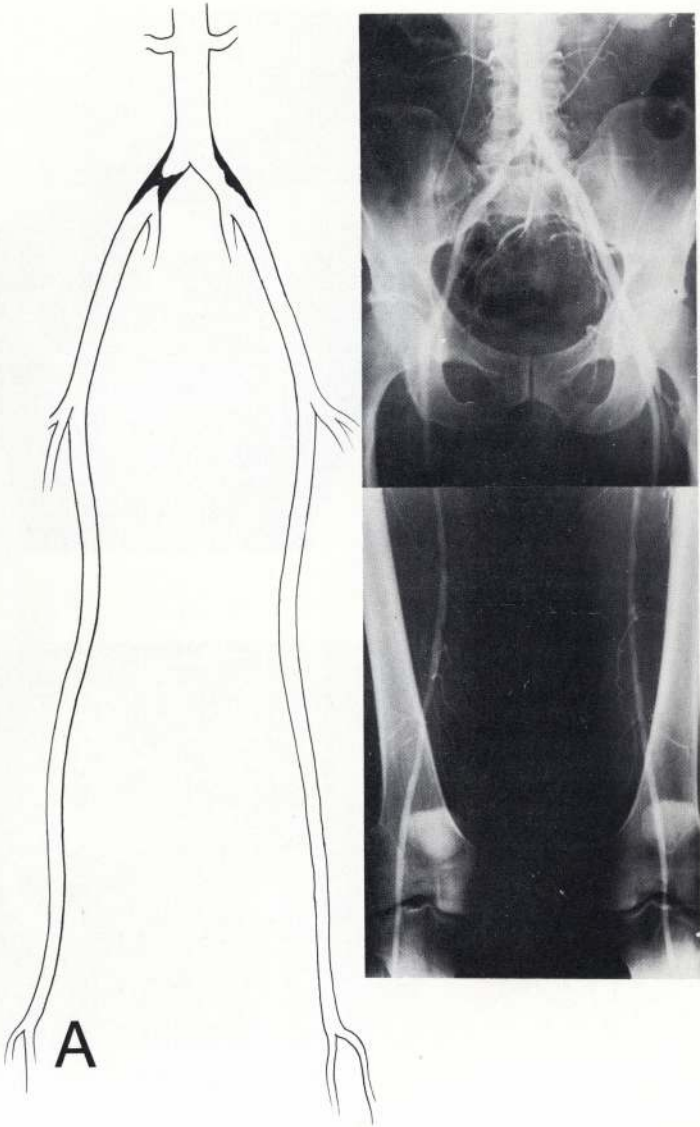


FIG. 32.A. Drawing and preoperative abdominal, iliac, and femoral arteriogram in a 42-year-old white man with intermittent claudication of legs showing well-localized, severe atherosclerotic occlusive disease of aorto-iliac segment with patent distal external iliac, femoral, and popliteal arteries. A Dacron bifurcation bypass graft was inserted from abdominal aorta to both common femoral arteries.

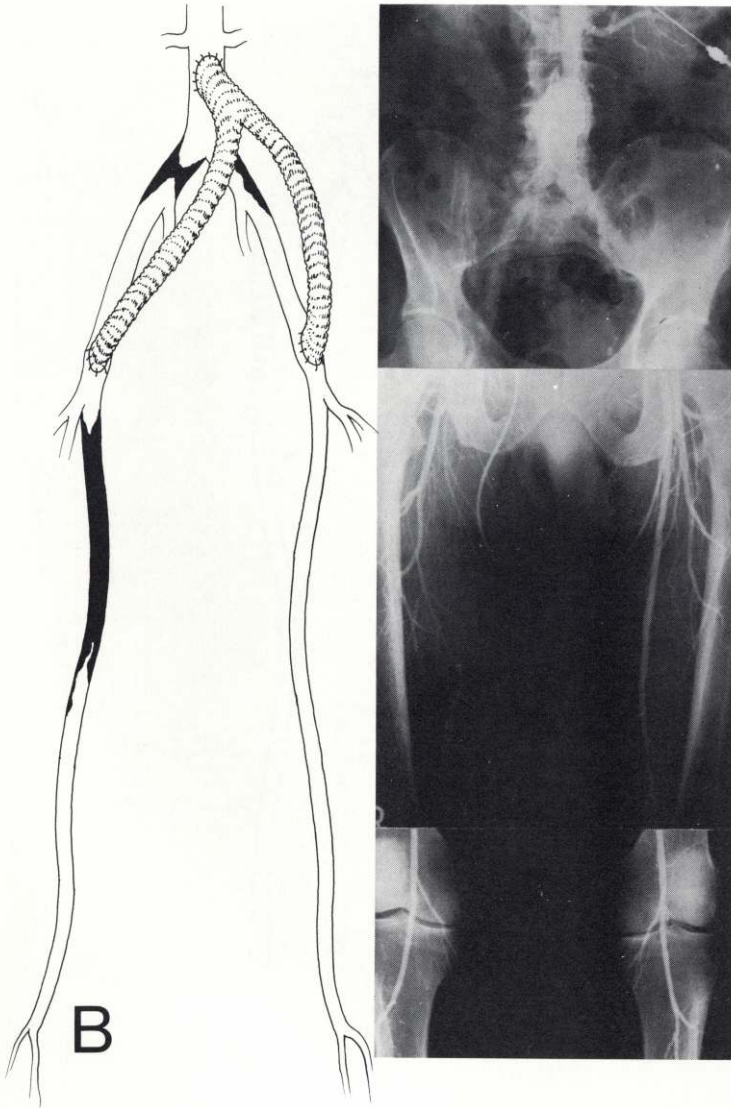


FIG. 32. B. Drawing and preoperative abdominal, iliac, and femoral arteriogram in same patient 17 years after bypass graft. Intermittent claudication had recently developed in right leg. Arteriogram now shows well-localized complete atherosclerotic occlusive disease of right superficial femoral artery with little or no involvement of left superficial femoral artery.

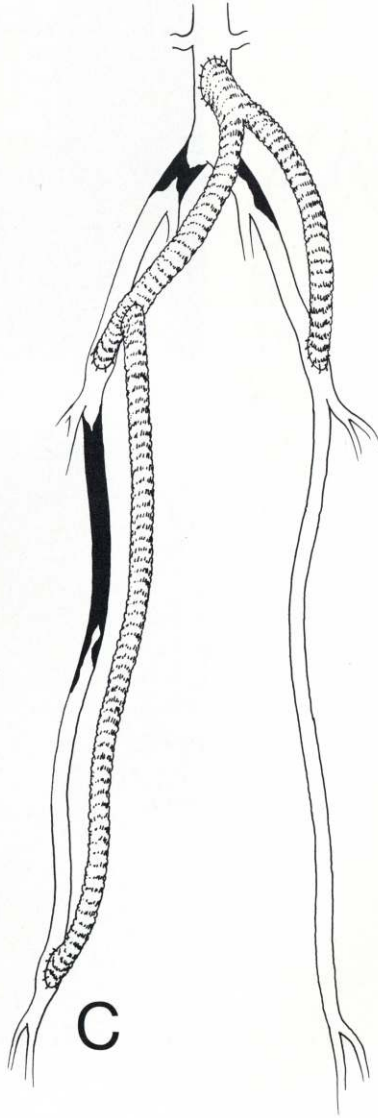


FIG. 32. C. Drawing showing Dacron femoro-popliteal bypass graft. Patient has remained asymptomatic during the 2 years since last operation (cholesterol 172; triglycerides 189).

diffuse involvement, especially in the distal arterial bed, but the fact remains that a certain proportion of the former will show a rapid rate of progression. Indeed, recurrence of ischemic disturbances and failure within a few years after surgical treatment are in most patients caused by the rapid rate of progression of the atheromatous occlusive process distal to the site of surgical correction, whether this be by endarterectomy or the bypass graft. This is well exemplified by a number of cases illustrated in this presentation in which long-term excellent results followed operation with arteriographic evidence of little or no progression of the disease, whereas other patients with recurrence of manifestations within a few years after operation exhibited progression of the atheromatous process.

Obviously, it would be extremely desirable to determine the susceptibility of the individual patient to the various patterns and rates of progression at the onset of the disease or even before. It must be admitted, however, that in our present state of knowledge, this has not been possible to accomplish. Much emphasis in recent years has been placed on certain risk factors, including particularly hypercholesterolemia, hypertension, and cigarette smoking as primary factors, and heredity, sex, age, hypertriglyceridemia, obesity, diabetes mellitus, physical activity, stress, and personality types as secondary risk factors. In our experience, it has not been possible to establish a strong correlation between individual risk factors and the various patterns and rates of progression of atherosclerosis that have been described and illustrated in this presentation or even between risk factors and individual susceptibility. Indeed, perhaps one-fourth or more of the patients observed have no identifiable risk factor. To be sure, one or more of the primary risk factors and some of the secondary risk factors may be present in a certain proportion of the patients observed, but their presence does not show a strong correlation with the different patterns of the disease or with the various rates of progression of the disease.

Finally, it is our firm conviction that the disease complex referred to as arteriosclerosis or atherosclerosis represents a number of distinctively different clinical and anatomicopathologic patterns with various rates of progression. Much of the confusion about etiology, diagnosis, treatment, and prevention is believed to stem from the failure to recognize these widely different patterns, which may indeed represent different entities. This is particularly true in certain epidemiologic studies that tend to represent all forms of arteriosclerosis or atherosclerosis as a single entity without regard to their distinctly different patterns or rates of progression. Even in such studies concerned with clinical manifestations of one arterial bed, such as coronary artery disease so often used for this purpose, there has been a failure to recognize the widely different patterns and rates of progression. Results of such studies, in the absence of precise definition of the patterns involved or their relative incidence in the sample population being studied, can only lead to further confusion. It is not inconceivable that when the precise cause is ultimately discovered, it will be found that each of the several or more different patterns of these arteriopathies has a specific etiologic agent or set of etiologic factors.

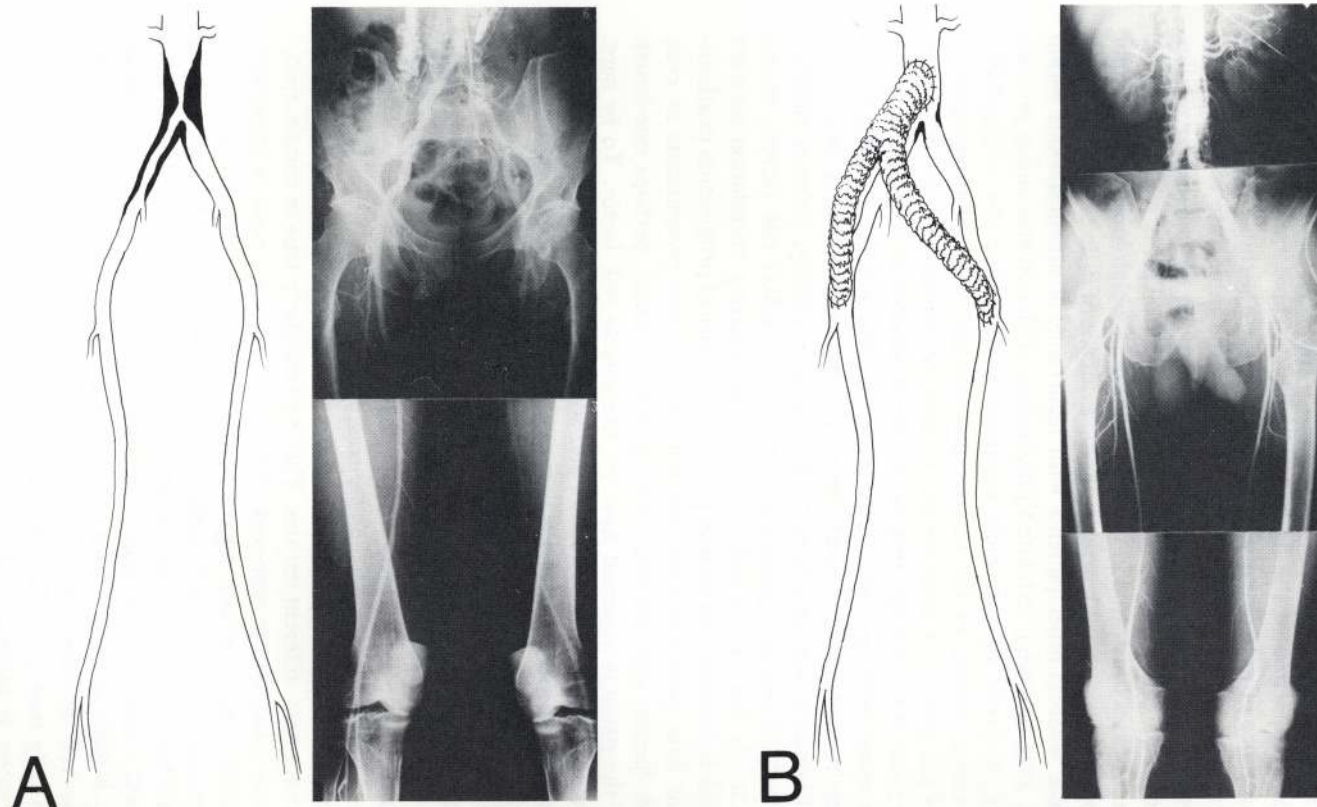


FIG. 33. A. Drawing and preoperative abdominal, iliac, and femoral arteriograms in a 45-year-old white man with intermittent claudication of legs showing well-localized severe atherosclerotic occlusive disease in aorto-iliac segment. Treatment consisted of Dacron bypass graft from abdominal aorta to both common femoral arteries as shown in drawing (B). **B.** Drawing and abdominal aortogram made in same patient 16 years later showing restoration of normal circulation in legs with no evidence of development of atherosclerosis in this arterial bed.

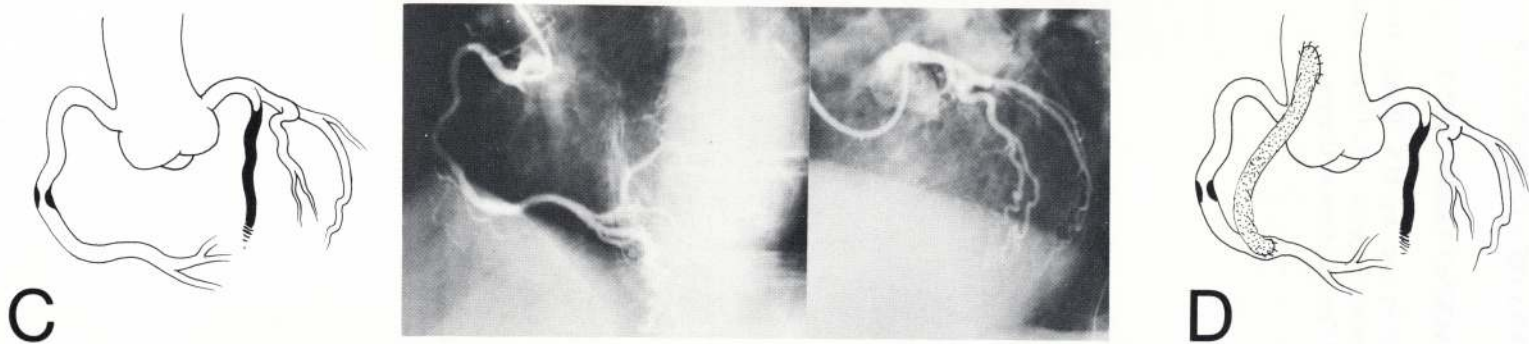


FIG. 33. C. Drawing and coronary arteriogram in same patient with recent onset of progressively severe angina developing 16 years after previous aorto-femoral bypass operation showing well-localized severe atherosclerotic occlusive disease in midportion of right coronary artery and complete extensive occlusion of left anterior descending coronary artery. D. Drawing showing autogenous saphenous vein bypass from ascending aorta to right coronary artery distal to occlusive lesion. Patient has remained asymptomatic 19 years after first operation for intermittent claudication of legs and 3 years after second operation for angina (cholesterol 266; triglycerides 207).

ACKNOWLEDGMENT

This work was supported in part by U.S. Public Health Service, National Heart, Lung and Blood Institute Grant HL-17269, The National Heart and Blood Vessel Research and Demonstration Center.