

HOMOTRANSPLANTATION OF
THE AORTIC VALVE

ARTHUR C. BEALL, JR., M.D.

GEORGE C. MORRIS, JR., M.D.

DENTON A. COOLEY, M.D.

and

MICHAEL E. DE BAKEY, M.D.

Houston, Texas

From the Cora and Webb Mading Department
of Surgery, Baylor University College
of Medicine

Reprinted from

THE JOURNAL OF THORACIC AND
CARDIOVASCULAR SURGERY

St. Louis

Vol. 42, No. 4, Pages 497-506, October, 1961

(Copyright © 1961 by The C. V. Mosby Company)

(Printed in the U. S. A.)

HOMOTRANSPLANTATION OF THE AORTIC VALVE

*Arthur C. Beall, Jr., M.D., George C. Morris, Jr., M.D.,
Denton A. Cooley, M.D., and Michael E. De Bakey, M.D.,
Houston, Texas*

CARDIAC valve homotransplantation came as a logical evolvement of the successful use of vessel homografts. Cusp homografts have been used in both the tricuspid and the aortic valves. From such studies have come conflicting reports.^{26, 26, 39} Many attempts to homotransplant the entire aortic valve have met with failure due to hemorrhage^{6, 20} or to degeneration of the cusps over a period of time.^{6, 7, 20, 25} However, in only one of these studies was a need for the valve created, and here the aortic insufficiency produced was only temporary in the majority of the animals.²⁵ Such an experiment cannot be considered conclusive.²⁴

Hemorrhage from aortic valve homografts can be prevented by various technical maneuvers.²⁵ Murray has shown experimentally that aortic valve homografts will continue to function in the presence of permanent aortic insufficiency,³⁴ and has utilized such valves successfully in several human patients.^{32, 33, 34} As yet no one has attempted to confirm these findings.

The fate of valve homografts is not clear. In such a valve are many inherent advantages. Although vessel grafts of various synthetic materials are now being used with increasing frequency in arterial reconstruction, no *entirely satisfactory synthetic* valve is available. In an effort to clarify the usefulness of aortic valve homografts in a hemodynamic environment which requires the presence of a valve, the following study was undertaken.

METHOD

Mongrel donor dogs, similar in weight to recipient animals, were sacrificed, and the hearts removed under sterile conditions. The aortic valve was excised in such a manner as to include 1.0 cm. of ascending aorta and a small amount of proximal myocardium. A 1.0 to 1.5 cm. segment from the ascending aorta was meticulously sutured as a cuff to the myocardial side of the valve with simple, running 5-0 arterial silk. The coronary orifices were oversewn with 5-0 arterial silk. The valve was then refrigerated from 2 to 48 hours in an antibiotic containing electrolyte solution similar to that described by Gross.¹⁸

From the Cora and Webb Mading Department of Surgery, Baylor University College of Medicine, Houston, Texas.

Supported in part by grants from the Houston Heart Association and the U. S. Public Health Service (H-3137) and under a research fellowship grant from the Houston Heart Association.

Received for publication Sept. 6, 1960.

Mongrel recipient dogs, varying in weight from 11.3 to 29.5 kilograms, were anesthetized with Nembutal sodium, 30 mg. per kilogram. Intermittent positive pressure oxygen was administered through an endotracheal tube. In the lateral position the chest was entered through the fourth left intercostal space, utilizing aseptic technique. A 4 to 5 cm. segment of the proximal descending thoracic aorta was freed, ligating one or two pairs of intercostal arteries. The aorta was occluded proximally and distally with arterial clamps, and a segment of the same length as that of the valve to be inserted was excised. A previously prepared aortic valve homograft was then sutured in place using simple, running 5-0 arterial silk (Fig. 1). Neither hypothermia³⁷ nor pump bypass³¹ was used, as the period of aortic occlusion was only 20 to 25 minutes and no difficulty was noted from aortic occlusion of this duration. After the valve was in place, clamps were slowly released, and stored blood was given as indicated. For a brief period there was often some bleeding from the myocardial suture line, but this readily stopped if the clamps were released slowly. Only one operative death could be attributed to hemorrhage, and this was the first animal in which the procedure was carried out.

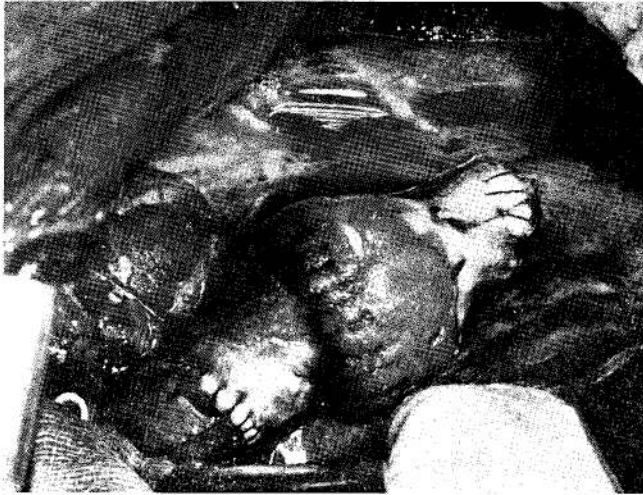

Fig. 1.—Aortic valve homograft sutured into descending thoracic aorta.

After allowing sufficient time for the animals to stabilize from this procedure, generally 10 to 15 minutes, aortic insufficiency was created by a technique previously reported.¹¹ The left subclavian artery was divided 2 to 3 cm. from the aortic arch, and the distal cut end ligated. Under control of a tourniquet, a bent crochet hook was introduced into the aortic arch through the proximal cut end of the subclavian artery. This was passed into the sinus of the posterior cusp of the animal's own aortic valve, guided by a finger along the outer posterior wall of the intrapericardial aorta. The hook was punched through the cusp, and the cusp grasped and avulsed. The hook was removed, and the subclavian artery ligated.

The chest was closed, drainage catheters were removed, and the animals returned to their cages. Penicillin and streptomycin were given for 5 days. At intervals of 1, 3, 6, 9, and 12 months after operation, arterial pressure tracings were taken simultaneously proximal (right brachial artery) and distal (femoral artery) to the homograft valves, utilizing Statham strain gauge manometers and an Electronics for Medicine recorder. At the time of sacrifice, the animals' own aortic valve was examined for the presence of insufficiency. The homograft valves were tested for competence to water pressure, the leaflets examined, and slides made for microscopic study.

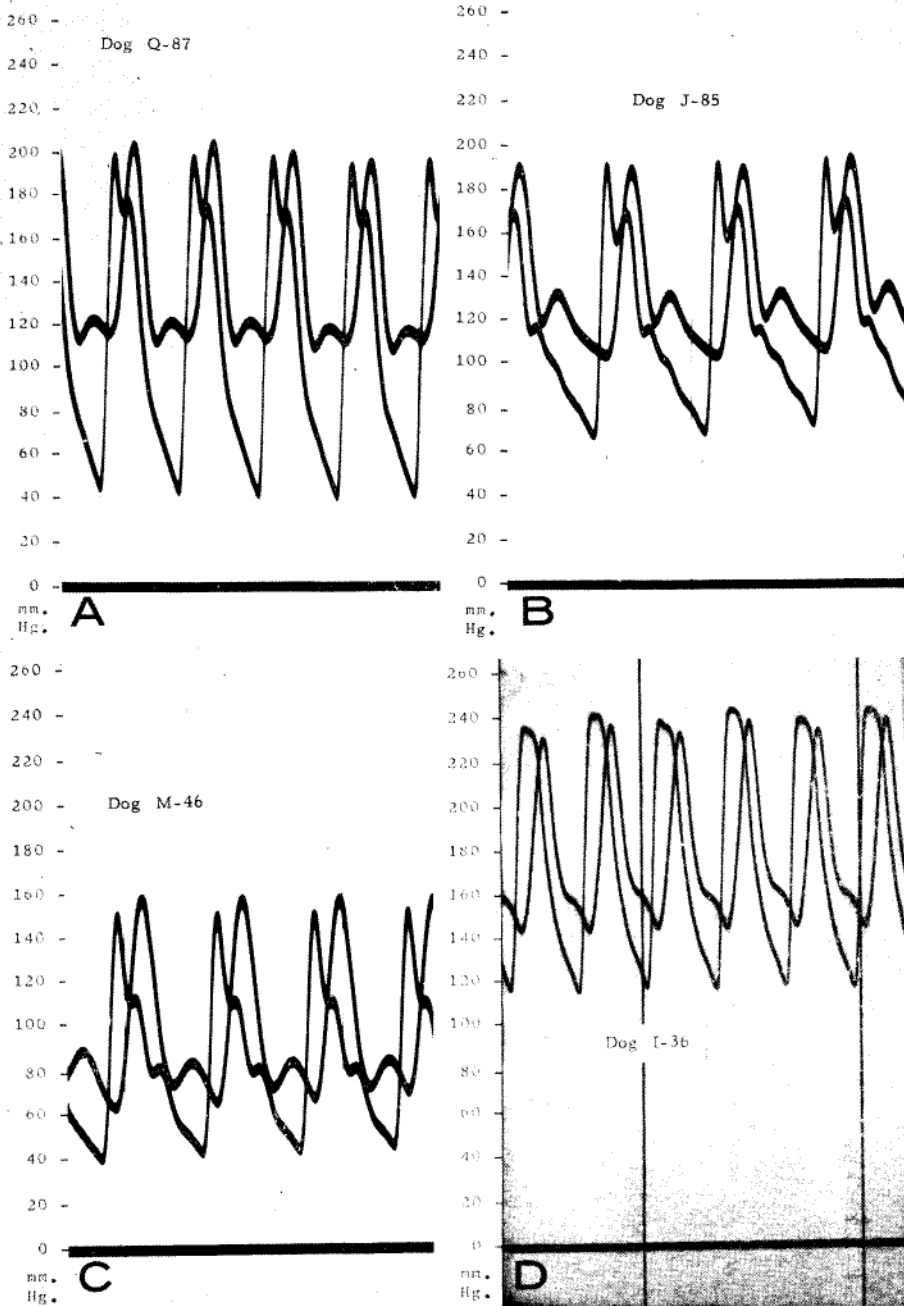


Fig. 2.—A. Simultaneous arterial pressure tracings proximal and distal to aortic valve homograft 3 months after operation.
B. Simultaneous arterial pressure tracings proximal and distal to aortic valve homograft 13 months after operation.
C. Simultaneous arterial pressure tracings proximal and distal to aortic valve homograft 6 months after operation.
D. Simultaneous arterial pressure tracings proximal and distal to aortic valve homograft 13 months after operation.

RESULTS

Twenty-five animals underwent this combined procedure with only four operative deaths. As previously mentioned, the first was due to hemorrhage. Another was associated with progressive heart failure following valvotomy. The other deaths were secondary to irreversible ventricular fibrillation, which occurred at the time of valvotomy. Five animals died during the first month after operation: 2 from heart failure, 2 from pulmonary complications, and 1 from empyema.

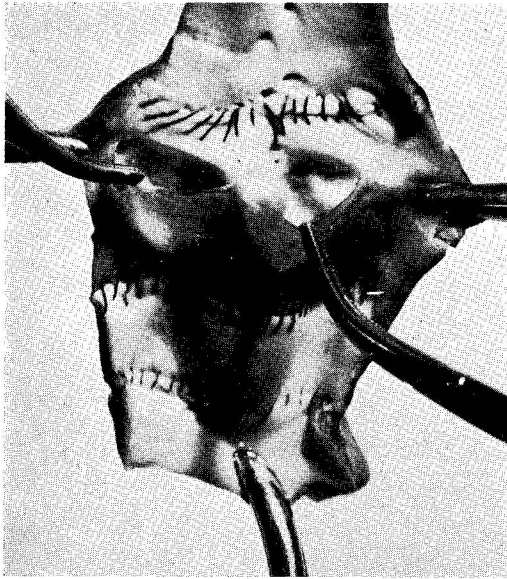


Fig. 3.

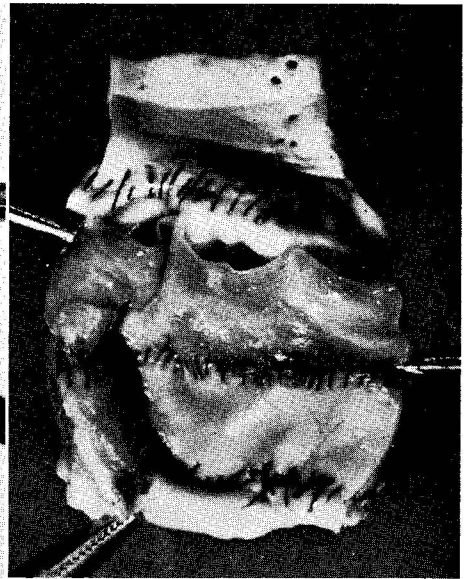


Fig. 4.

Fig. 3.—Aortic valve homograft 3 months after operation. Competence to water pressure proved at time of sacrifice.

Fig. 4.—Aortic valve homograft 13 months after operation. Cusps have become somewhat thickened but remain pliable and competent to water pressure.

Sixteen animals were available for study 1 to 13 months after operation. Five of these died from various causes during the second and third months after surgery, and 1 was killed in a fight. Seven were sacrificed at intervals up to 13 months, and 3 are still alive and well, 3, 8, and 13 months after the insertion of a homograft valve and the creation of aortic insufficiency.

In 3 animals still being followed, simultaneous pressure tracings reveal typical curves of aortic insufficiency proximal to the homograft valves with normal curves distally (Fig. 2, *A* and *B*). Similar pressure tracings were seen in 9 of the other 13 animals (Fig. 2, *C* and *D*), and competence of these homograft valves was confirmed by water pressure at the time of death or sacrifice. Examination of the cusps revealed slight thickening, but they remained pliable, and quite capable of function (Figs. 3 and 4). Microscopically valvitis with polymorphonuclear and lymphocytic infiltration was seen during the first month

Fig. 5.

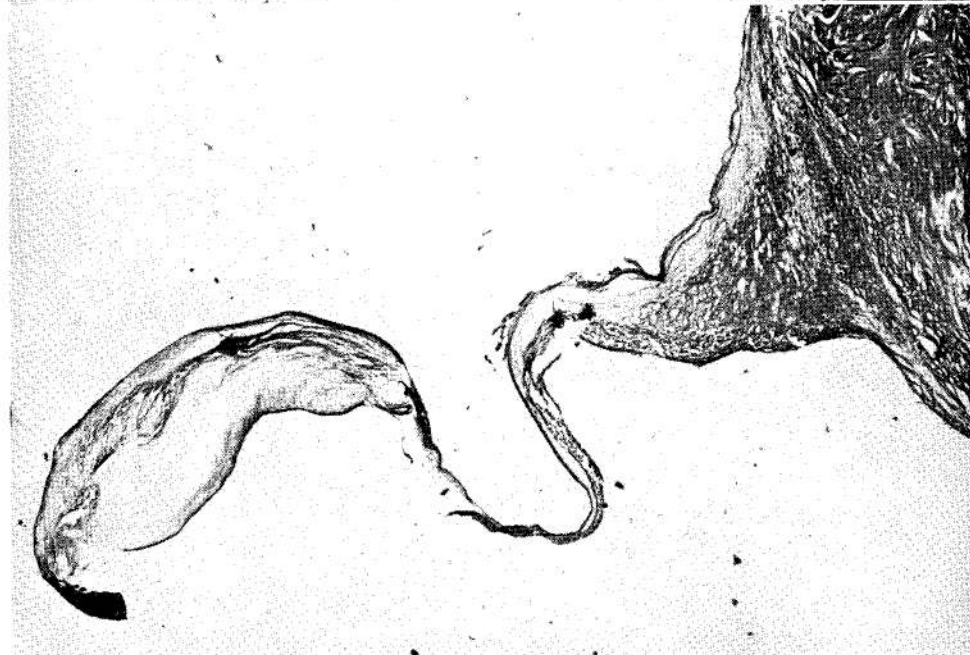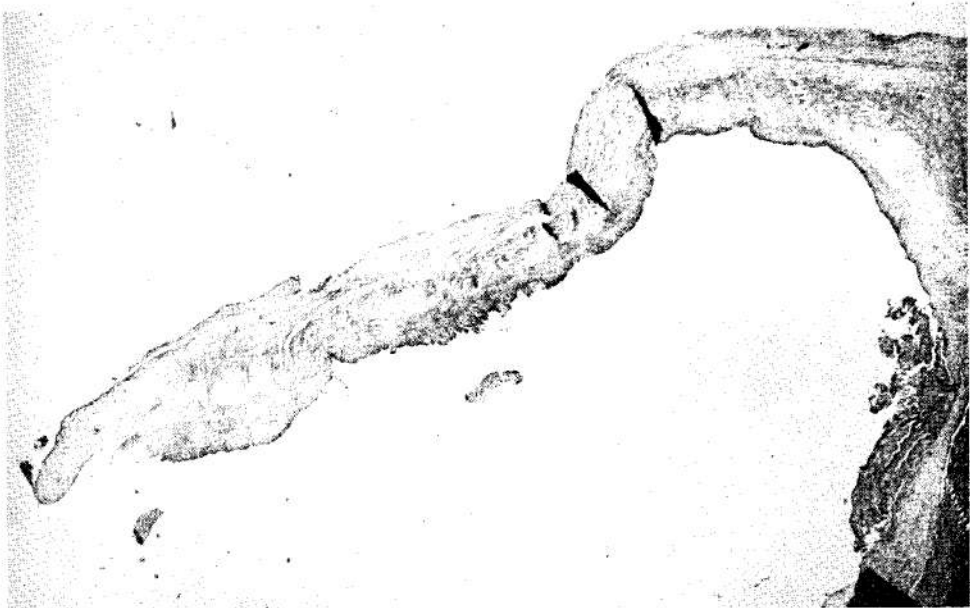


Fig. 6.

Fig. 5.—Photomicrograph of homograft cusp 1 month after operation. Minimal inflammatory response is present.

Fig. 6.—Photomicrograph of homograft cusp 13 months after operation. Cusp acellular and hyalinized with ground-glass appearance, but valve remains competent.

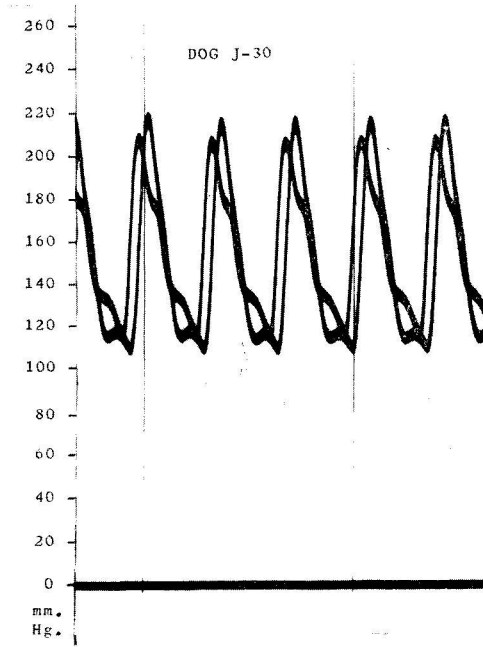


Fig. 7.—Simultaneous arterial pressure tracings proximal and distal to aortic valve homograft. Proximal and distal tracings similar throughout period of study.

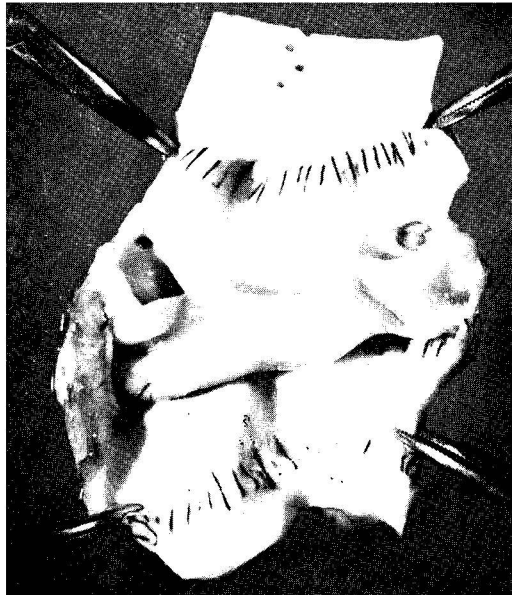


Fig. 8.—Aortic valve homograft 11 months after operation. Valve not competent to water pressure, but appears distorted at myocardial suture line.

after insertion, but was seen only rarely thereafter. Over a period of months, the cusps developed an acellular, hyalinized, ground-glass appearance (Figs. 5 and 6).

Competence could not be proved in the 4 remaining animals; in 2, pressure tracings proximal and distal to the homograft valves were similar throughout the period of study (Fig. 7). At the time of sacrifice, the homograft valves were not competent to water pressure, but the cusps were in good condition and capable of function (Fig. 8). One cannot help but speculate that these valves were distorted when the disproportionate myocardial anastomosis was made and were never competent. In the other 2 animals, marked sclerosis with shrinking of the cusps was noted at the time of death at 3½ months in 1, and at the time of sacrifice at 11 months in the other. Pressure tracings in these 2 animals revealed progressive loss of insufficiency proximal to the homograft valves, and examination of their own aortic valves suggested that the torn posterior cusp had been compensated for by the right and left coronary cusps as previously noted by Lam.²⁵ It would appear that loss of function in these two homograft valves was associated with the spontaneous disappearance of aortic insufficiency in the animals' own aortic valves.

DISCUSSION

Many ingenious techniques have been developed for the treatment of valvar lesions of the heart. Autogenous tissue has been used experimentally for both the atrioventricular and aortic valves.^{1, 3, 6, 11, 16, 17, 30, 35, 38, 42, 44, 45} The entire pulmonic valve has been transplanted into the descending thoracic aorta.²⁸ In recent years numerous foreign materials have been used both experimentally and clinically in cardiac valve surgery.^{2, 4, 5, 8, 9, 10, 12-15, 19-23, 27, 29, 40, 41, 43, 46, 47} Although many of these valve substitutes have shown considerable promise, none has been entirely satisfactory.

The ideal location for an aortic valve replacement would be proximal to the coronary orifices. The descending thoracic aorta was chosen for the present investigation, as this location allowed pressure tracings to be taken proximal and distal to the valves without re-opening the chest. Clinically many gratifying results have been obtained from the placement of plastic ball valves in the descending thoracic aorta.^{21, 41} Until a satisfactory subcoronary valve replacement is available, it would seem advisable to continue to use the descending thoracic aorta without interfering with the function remaining in the patient's own aortic valve. This does not allow excision and replacement of a stenotic and destroyed valve, but does offer palliation to patients with aortic insufficiency until such time as the valve can be replaced in its entirety.

As with vessel homografts, valve homografts, if successful, will eventually be replaced by a more satisfactory material. Even now, the final answer in vessel grafts has not been found. No human data are included in this series, but Murray has reported clinical success with aortic valve homografts in patients with aortic insufficiency for periods up to more than 4 years.^{32, 33} This type of procedure is contemplated in the near future, and should alleviate some of the

problems seen with plastic ball valves, such as noise, destruction of formed elements of the blood, emboli, and complications resulting from the insertion of a rigid tube into the pulsatile aorta.

Attempts are now being made to transplant aortic valve homografts into a subcoronary position in the dog. With technical advances made in recent years, present techniques of total cardiopulmonary bypass allow adequate exposure of the aortic valve area. Total excision and subcoronary replacement of the aortic valve awaits only the development of a satisfactory valve and a method of adequately securing it in place.

SUMMARY

Previous attempts to homotransplant aortic valves have generally met with failure, due to hemorrhage or to loss of cusp function in experiments in which no aortic insufficiency was created or the insufficiency produced spontaneously disappeared. Encouraged by occasional reports of successful cardiac valve homografts, a study was carried out in which an aortic valve homograft was inserted into the descending thoracic aorta of the dog. Aortic insufficiency was then created, and the animals were followed at intervals by pressure tracings taken proximal and distal to the homograft valves. At the time of death or sacrifice the valves were tested for competence to water pressure and examined grossly and microscopically.

Sixteen animals were studied from 1 to 13 months after operation. In 12 the homograft valves remained functional. In 2 the valves did not appear competent throughout the period of study, but the cusps remained in good condition and appeared capable of function. In 2 animals in which aortic insufficiency spontaneously disappeared, the homograft cusps underwent degenerative changes, and the valves became functionless. It would appear from these findings that homotransplantation of the aortic valve is technically feasible, and that such a valve will continue to function if a need for the valve exists.

ADDENDUM

Feb. 18, 1961. Since this experimental study was submitted for publication, aortic valve homografts have been sutured into the proximal descending thoracic aorta of 3 patients with severe aortic regurgitation. Pump bypass from the left atrium to the femoral artery was utilized during the period of aortic occlusion. These patients have shown definite clinical improvement with decrease in heart size, 7, 6, and 5 months after operation. There has been no evidence of regurgitation in any of these homograft valves.

REFERENCES

1. Absolon, K. B., Hunter, S. W., and Quattlebaum, F. W.: A New Technique for Cardiac Valve Construction From Autologous Diaphragm, *Surgery* **46**: 1078-1083, 1959.
2. Akutsu, T., Dreyer, B., and Kolff, W.: Polyurethane Artificial Heart Valves in Animals, *J. Appl. Physiol.* **14**: 1045-1048, 1959.
3. Bailey, C. P., Jamison, W. L., Bakst, A. E., Bolton, H. E., Nichols, H. T., and Gemeinhardt, W.: The Surgical Correction of Mitral Insufficiency by the Use of Pericardial Grafts, *J. THORACIC SURG.* **28**: 551-603, 1954.
4. Benichoux, R., and Chalnot, P.: A Method for the Surgical Correction of Mitral Insufficiency, *J. THORACIC SURG.* **30**: 148-158, 1955.

5. Berg, E. H., Goodman, S. E., Stuckey, J. H., and Newman, M. E.: Total Replacement of the Mitral Valve, *S. Forum* 8: 363-367, 1957.
6. Berwin, E. G.: The Use of Tissue Transplants in the Surgery of Cardiac Valvar Disease: An Experimental Study, *Guy's Hosp. Rep.* 105: 328-340, 1956.
7. Bill, A. H., Jr., Pierce, E. C., II, and Gross, R. E.: Experimental Production of an Extracardiac Shunt Around the Mitral Valve. Preliminary Report, *Arch. Surg.* 60: 1114-1121, 1950.
8. Braunwald, N. S., Cooper, T., and Morrow, A. G.: Complete Replacement of the Mitral Valve. Successful Clinical Application of a Flexible Polyurethane Prosthesis, *J. THORACIC SURG.* 40: 1-11, 1960.
9. Campbell, J. M.: An Artificial Aortic Valve. Preliminary Report, *J. THORACIC SURG.* 19: 312-318, 1950.
10. Carter, M. G., Gould, J. M., and Mann, B. F., Jr.: Surgical Treatment of Mitral Insufficiency. An Experimental Study, *J. THORACIC SURG.* 26: 574-581, 1953.
11. Castro-Villagrana, B., Sisteron, B., and De Bakey, M. E.: An Experimental Surgical Treatment for Aortic Insufficiency, *S. Forum* 8: 371-375, 1957.
12. Denton, G. R., Seymour, T., and Wiggers, H.: A Follow-up Report on the Development of a Plastic Prosthesis for the Atrioventricular Valve, *S. Forum* 4: 83-87, 1953.
13. DeWall, R. A., Warden, H. E., Lillehei, C. W., and Varco, R. L.: A Prosthesis for the Palliation of Mitral Insufficiency, *Dis. Chest* 30: 133-140, 1956.
14. Edwards, W. S., and Smith, L.: Aortic Valve Replacement With a Subcoronary Ball Valve, *S. Forum* 9: 309-313, 1958.
15. Ellis, F. H., Jr., and Bullulian, A. H.: Prosthetic Replacement of the Mitral Valve. I. Preliminary Experimental Observations, *Proc. Staff Meet. Mayo Clin.* 33: 532-534a, 1958.
16. Glenn, W. W. L., and Turk, L. N., III.: The Surgical Treatment of Mitral Insufficiency: The Fate of a Vascularized Transchamber Intracardiac Graft. A Preliminary Report, *Ann. Surg.* 141: 510-518, 1955.
17. Glover, R. P., Henderson, A. R., Margutti, R., and Gregory, J.: The Fate of Intracardiac Pericardial Grafts as Applied to the Closure of Septal Defects and to the Relief of Mitral Insufficiency, *S. Forum* 3: 178-185, 1952.
18. Gross, R. E., Hurwitt, E. S., Bill, A. H., Jr., and Pierce, E. C., II.: Preliminary Observations on the Use of Human Arterial Grafts in the Treatment of Certain Cardiovascular Defects, *New England J. Med.* 239: 578-579, 1948.
19. Harken, D. E., Black, H., Dexter, L., and Ellis, L. B.: The Surgical Correction of Mitral Insufficiency, *S. Forum* 4: 4-7, 1953.
20. Hufnagel, C. A.: Aortic Plastic Valvular Prosthesis, *Bull. Georgetown Univ. M. Center* 4: 128-130, 1951.
21. Hufnagel, C. A., Vilkgas, P. D., and Nahas, H.: Experiences With New Types of Aortic Valvular Prostheses, *Ann. Surg.* 147: 636-645, 1958.
22. Johns, T. N. P., and Blalock, A.: Mitral Insufficiency: The Experimental Use of a Mobile Polyvinyl Sponge Prosthesis, *Ann. Surg.* 140: 335-341, 1954.
23. King, H., Su, C. S., and Jontz, J. G.: Partial Replacement of the Mitral Valve With Synthetic Fabric, *J. THORACIC SURG.* 40: 12-16, 1960.
24. Lam, C. R.: Personal communication.
25. Lam, C. R., Aram, H. H., and Munnell, E. R.: An Experimental Study of Aortic Valve Homografts, *Surg. Gynec. & Obst.* 94: 129-135, 1952.
26. Litwak, R. S., Gadboys, H. L., Scott, G. B., and Ferrara, J. F.: Surgical Approach for Stenotic Lesions of the Semilunar Valves by Excision and Cusp Replacement Under Direct Vision, *J. THORACIC SURG.* 24: 165-189, 1952.
27. Long, D. M., Jr., Sterns, L. P., DeRiemer, R. H., Warden, H. E., and Lillehei, C. W.: Subtotal and Total Replacement of the Aortic Valve With Plastic Valve Prostheses: Experimental Investigation and Successful Clinical Application Utilizing Selective Cardiac Hypothermia, *S. Forum* 10: 660-665, 1959.
28. Lower, R. R., Stofer, R. C., and Shumway, N. E.: Autotransplantation of the Pulmonic Valve Into the Aorta, *J. THORACIC SURG.* 39: 680-687, 1960.
29. Malette, W. G., Summers, W. B., and Eiseman, B.: Experimental Problems in the Construction of Subcoronary Prosthetic Aortic Valves, *S. Forum* 7: 233-237, 1956.
30. Moore, T. C., and Shumacker, H. B., Jr.: Unsuitability of Transventricular Autogenous Slings for Diminishing Valvular Insufficiency, *Surgery* 33: 173-182, 1953.
31. Morris, G. C., Jr., Witt, R. R., Cooley, D. A., Moyer, J. H., and De Bakey, M. E.: Alterations in Renal Hemodynamics During Controlled Extracorporeal Circulation in the Surgical Treatment of Aortic Aneurysm, *J. THORACIC SURG.* 34: 590-598, 1957.
32. Murray, G.: Personal communication.
33. Murray, G.: Aortic Valve Transplants, *Angiology* 11: 99-102, 1960.

34. Murray, G., Roschlau, W., and Longheed, W.: Homologous Aortic-Valve-Segment Transplants as Surgical Treatment for Aortic and Mitral Insufficiency, *Angiology* 7: 466-471, 1956.
35. Murray, G., Wilkinson, F. R., and MacKenzie, R.: Reconstruction of the Valves of the Heart, *Canad. M. A. J.* 38: 317-319, 1938.
36. Pollock, A. V., and Thomas, V.: Replacement of a Tricuspid Valve Cusp by a Homologous Cusp in Dogs, *Surg. Gynec. & Obst.* 103: 731-735, 1956.
37. Pontius, R. G., Brockman, H. L., Hardy, E. G., Cooley, D. A., and De Bakey, M. E.: The Use of Hypothermia in the Prevention of Paraplegia Following Temporary Aortic Occlusion: Experimental Observations, *Surgery* 36: 33-38, 1954.
38. Rappaport, A. M., and Scott, A. C.: Valvular Anastomosis of the Heart Cavities, *Ann. Surg.* 131: 449-465, 1950.
39. Robicsek, F.: Cardiac Valve Transplantation, *Acta med. hung.* 5: 81-91, 1954.
40. Roe, B. B., Owsley, J. W., and Boudoures, P. C.: Experimental Results With a Prosthetic Aortic Valve, *J. THORACIC SURG.* 36: 563-570, 1958.
41. Rose, J. C., Hufnagel, C. A., Freis, E. D., Harvey, W. P., and Parteno, E. A.: The Hemodynamic Alterations Produced by a Plastic Valvular Prosthesis for Severe Aortic Insufficiency in Man, *J. Clin. Invest.* 33: 891-900, 1954.
42. Ryan, E. P., Johnson, G., Jr., and Beal, J. M.: An Experimental Aortic Valve, *Proc. Soc. Exper. Biol. & Med.* 94: 372-374, 1957.
43. Sarnoff, S. J., and Case, R. B.: Experimental Bypass of the Aortic Valve by Valvular Anastomosis Between Apex of the Left Ventricle and Thoracic Aorta, *Henry Ford Hosp. International Symposium on Cardiovascular Surgery, Philadelphia, 1955, W. B. Saunders Co., pp. 304-315.*
44. Silen, W., Mawdsley, D. L., Miller, E. R., and McCorkle, H. J.: The Experimental Production of a Competent Aortic Valve, *Surgery* 40: 78-83, 1956.
45. Templeton, J. Y., and Gibbon, J. H., Jr.: Experimental Reconstruction of Cardiac Valves by Venous and Pericardial Grafts, *Ann. Surg.* 129: 161-176, 1949.
46. Trout, R.: Discussion of Roe et al.⁴⁰
47. Wible, J. H., Jacobson, L. F., Jordon, P., Jr., and Johnston, C. G.: Spring Valve Prosthesis for the Control of Valvular Insufficiency, *S. Forum* 7: 230-232, 1956.