


Bettman (B.)



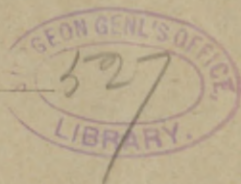Subvolution — A New Pterygium Operation.

BY BOERNE BETTMAN, M.D.

CHICAGO.

PROFESSOR OF OPHTHALMOLOGY AND OTOTOLOGY IN THE COLLEGE OF PHYSICIANS AND SURGEONS; PROFESSOR OF OPHTHALMOLOGY IN THE CHICAGO POST-GRADUATE MEDICAL SCHOOL; OCULIST AND AURIST TO THE MICHAEL REESE AND GERMAN HOSPITALS; ATTENDING SURGEON TO THE ILLINOIS CHARITABLE EYE AND EAR INFIRMARY.

REPRINTED FROM THE
JOURNAL OF THE AMERICAN MEDICAL ASSOCIATION,
MARCH 24, 1894.



CHICAGO:
PRINTED AT THE OFFICE OF THE JOURNAL OF THE ASSOCIATION.
1894.

SUBVOLUTION—A NEW PTERYGIUM OPERATION.


Many theories have been advanced to explain the origin and mode of growth of pterygium. Arlt ascribes it to an erosion of the cornea at the scleral margin, which in healing pulls the conjunctiva into the cicatrix. Poncet found micrococci in some of his pathologic preparations, and regarded them in the light of etiologic factors. Theobald concluded that the long-continued action of the recti muscles, usually the interni, was the responsible cause. Mannhardt regarded episcleritis as the promoting element.

None of the explanations, however, are entirely satisfactory. A thorough and critical examination of this subject has recently been made by Fuchs, of Vienna, who after long-continued clinical and microscopic investigation concluded that a pterygium results from a pinguecula; that the hyaline degeneration which occurs in this pathologic product is continued on the adjoining corneal tissue over which the conjunctiva is pulled.

As many methods of operation have been introduced for the successful eradication of pterygium, as there have been theories advanced for the elucidation of its growth and pathology. These may be all grouped under the following heads:

Transplantation of the pterygium; excision; strangulation, and evulsion.

The simplest, and according to Arlt, the most efficient operation is that of excision as first practiced by Coccius. It consists in separating the pterygium from the underlying cornea, and excising it with a triangular piece of conjunctiva. The conjunctival



wound is closed by a suture placed a few millimeters from the cornea-scleral margin.

In the following diagram, Fig. 1, *a*, represents the pterygium; *b*, the triangular piece of conjunctiva to be removed; and *c, c*, the sutures which are to unite the cut.

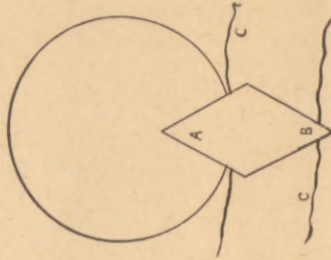


Fig. 1.

Wright, of Columbus, and Prince, of Springfield, report favorable results following evulsion. The former tears the pterygium with a forceps. The latter loosens it from the cornea with a strabismus hook, and then proceeds as in the operation of excision.

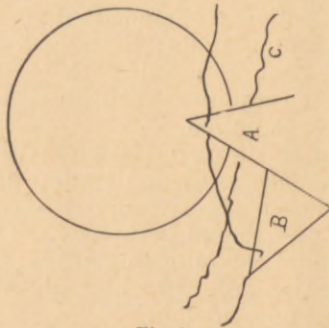


Fig. 2.

Demarres (Fig. 2,) practiced transplantation as early as 1855. After dissecting loose the flap on the cornea and on the sclerotic, he makes a conjunctival incision downward, commencing from the lower bor-

der of the base. Into the lower edge of the triangular gaping wound, the apex of the pterygium is sewed.

Knapp's modification consists in dividing the pterygium when large from apex to base, into two flaps. The ends are cut off and each flap is transplanted into its corresponding upper and lower conjunctival wound. The exposed surface of the sclerotic is covered by first dissecting up and then drawing together the conjunctiva.

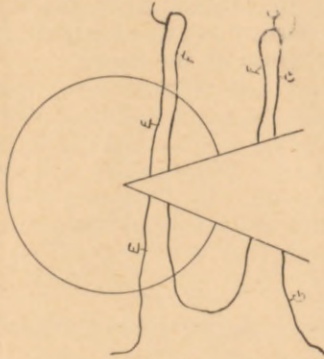


Fig. 3.

Strangulation is advocated by Szokalski and Galozowski. The first (Fig.3,) passes a thread, armed with two needles, under the corneal and sclerotic portions of the pterygium. The thread is cut close to the needles leaving three threads. The ends of each are

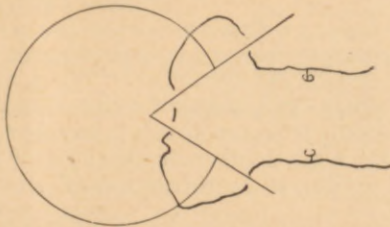


Fig. 4.—Thread in position; both ends are knotted, thus strangulating the pterygium.

tied, a knotting of the middle one puckers the pterygium and all three of them cut off its circulation.

Galozowski (Fig. 4,) separates the pterygium from the cornea, passes both needles at either end of the thread through the apex from above downward, leaving a loop on the upper surface. The needles are again entered at either border of the base through its under surface. It will be observed that the flap is turned downward upon itself its upper surface being brought in contact with the sclerotic. The two ends of the suture are tied together, thus strangulating the pterygium at the base.

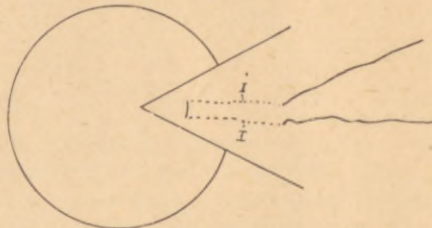


Fig. 5.—I I, Sutures under pterygium.

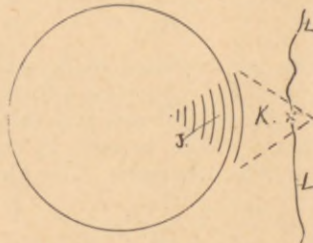


Fig. 6.—J, Denuded surface of cornea; K, pterygium turned under its base, dotted lines its edges; L L, suture knotted.

Hotz recently read a paper before the AMERICAN MEDICAL ASSOCIATION, recommending transplantation of a Thiersch's graft taken from the arm to replace the defect produced by retraction of the dissected pterygium.

Most of these procedures are frequently followed by a renewal of the growth. There are two funda-

mental principles involved in all these operations. One is destruction of tissue; the other is its preservation and growth in a new direction. None of the authors, however, take into consideration the salient feature involved in all plastic operations of the conjunctiva, namely, the prevention of contact between two raw surfaces. In excision, strangulation, and transplantation, the cut edges of the conjunctiva must necessarily be apposed to the denuded surface of the cornea. To me, this accounts for the relapses which so frequently occur.

Fuchs has shown that with the growth of the pterygium there is associated a fibrillar degeneration of the cornea, which involves Bowman's membrane and even the superficial layers of the cornea proper. In dissecting off the wing-shaped formation, a raw uneven surface is exposed. If now the cut surface of the conjunctiva comes in contact with this, or the proliferation at the cornea-scleral margin, it will unite with it and is liable to be again drawn over the cornea.

During the last six years I have followed my own method which satisfactorily overcomes the objection just stated. Its underlying principle is to prevent re-adhesion by placing a mucous surface in contact with a raw one. To do this, I turn the triangular flap underneath, which action can be best described by the term, subvolution, (turning under). In order to carry out this rule I have made the operation in the following manner:

The pterygium is gathered up by the two branches of a fine forceps serrated at the ends. A knife is passed underneath it close to the cornea, and the triangular membrane is dissected off toward the apex. A suture with a needle at each end is passed through the apex. Both needles are inserted from above downward, thus leaving a loop of thread on its outer surface. The needles are now passed through the base from below outward. The points of puncture being the ends of parallel lines drawn from the

punctures in the apex, and just far enough back, so that when the flap is turned upon itself underneath the base, the roll will correspond with the cornea-scleral margin.

The two ends of the suture are now firmly tied. We have induced a condition similar to gumming the flap of an envelope to its body. The under surface of the pterygium is brought in contact almost throughout its entire extent and adheres. A re-adhesion to the cornea is prevented by the roll of mucous membrane at the cornea-scleral margin.

This operation to a casual observer is similar to Galozowski's, of whose method I only recently learned while looking through ophthalmic literature. But the principle involved is entirely different. He aims at destruction of tissue. I, at its preservation and the prevention of the renewal of the growth, by apposing a smooth surface to a raw one.

The only seeming drawback to this procedure is the temporary unsightly thickening produced by the folding. This, however, disappears in a few days, and after a week or two flattens and settles down to the *niveau* of the adjacent parts of the eyeball. It adheres to the sclerotic. The raw surface of the cornea is covered with scar tissue and regenerated epithelium.

No matter how much the base of the pterygium contracts after dissection from the cornea, sufficient allowance can always be made by stitching the apex more or less forward.

The apex may be cut off, or not, depending entirely upon the degree of thickness. It is hardly necessary to state that the eye is bandaged and cleaned daily with a boric solution, and that the thread is removed after two or three days.

My operation is especially in large pterygia. Even in smaller ones, where the growth contracts considerably after having been separated from the cornea, it is followed often by good results. In these cases, adhesions will form, which will draw the turned

flaps over the sclerotic up to the cornea-scleral margin.

My friend, Dr. Beard, informed me only two days ago that he had seen Dr. Landolt, of Paris, turn the pterygium under as I do, and then sew the dissected conjunctiva from above and below over the denuded sclerotic. This latter act, however, I regard as an objectionable feature, since it defeats the very object of my operation by placing the cut edge of the conjunctiva in contact with the raw corneal surface.

