

WAGNER (H.L.)

Seropurulent Maxillary Sinusitis
in Chronic Lead-Poisoning.

BY

HENRY LEWIS WAGNER, M. D., Ph. D.,

Professor of Rhinology, San Francisco Polyclinic
(University of California);

Fellow of the American Laryngological Association;

Membre Correspondant de la Société Française d'Otologie,
de Laryngologie et de Rhinologie.

REPRINTED FROM THE

New York Medical Journal

for August 15, 1896.



SEROPURULENT MAXILLARY SINUSITIS IN CHRONIC LEAD-POISONING.*

BY HENRY LEWIS WAGNER, M. D., PH. D.,
PROFESSOR OF RHINOLARYNGOLOGY, SAN FRANCISCO POLYCLINIC
(UNIVERSITY OF CALIFORNIA);
FELLOW OF THE AMERICAN LARYNGOLOGICAL ASSOCIATION;
MEMBRE CORRESPONDANT

DE LA SOCIÉTÉ FRANÇAISE D'OTOLOGIE, DE LARYNGOLOGIE ET DE RHINOLOGIE.

THE advancement made in the study of ætiology in diseases of the nasal sinuses has greatly improved the methods of treatment. The results in this study are obtained not only by histological and bacteriological analyses, including post-mortem examinations, but also depend upon a careful examination of the whole system.

The following case fully illustrates the views on this subject:

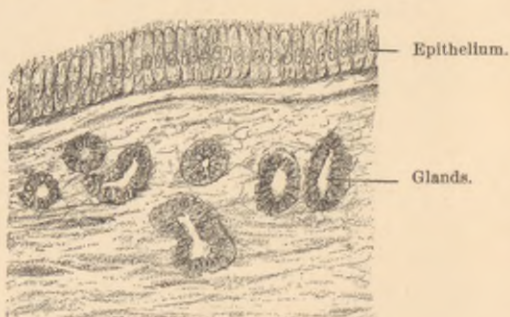
H. M. (aged thirty-two years; occupation, carriage painter for twelve years; parents healthy) consulted me a year ago for severe neuralgia of the right supra-orbital region. These neuralgic pains had existed for three consecutive years, occurring daily at intervals of from one to twelve hours, and consequently the patient was obliged to relinquish all work. He was afflicted with hyper-

* Read before the American Laryngological Association at its eighteenth annual congress.



osmia, strong odors of any kind producing pain. Opiates and various coal-tar derivatives were prescribed by his former physicians without any result, and the resection of the right supra-orbital nerve even failed to bring relief. All teeth in the upper jaw—some of them decayed and discolored—had been extracted, the source of trouble being located there, but no relief followed.

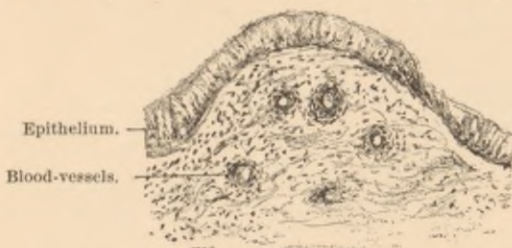EXAMINATION.—Patient a well-built man, skin yellow in color, flesh lacking in firmness, no syphilis, eyes and ears normal, throat showed slight pharyngitis sicca. Nose: Left side normal; right, slight hypertrophy of the middle and lower turbinated bodies. At the entrance of the hiatus semilunaris a crust formed daily, which could easily be removed, and a slight seropurulent discharge, containing *Staphylococcus aureus* and a few non-pathogenic cocci, could only be observed every second



Normal antrum of Highmore.

or third day. Face: Transillumination showed little difference between the two sides. No external swelling of face. Pressure on the supra-orbital region produced no pain. Mouth: Hypertrophy of the right upper gum; no blue lead line could be detected. Pressing upon the region of the right first molar produced severe neuralgic pain. This assured me that the cause of the trouble existed in the right antrum. Being unable to probe or irrigate the antrum through the hiatus semilunaris, I

entered the cavity through the hard palate under cocaine anæsthesia with the aid of a spearhead drill—this method, which is quick and painless, I employ frequently—and by injecting sterilized warm water a slight seropurulent discharge was observed coming from the right nostril. Shortly after the patient was somewhat relieved, and I decided to open the antrum through the canine fossa. This was accomplished under chloroform with a large trephine drill. The antrum showed in the lower and side walls a peculiar bluish-gray hypertrophy of the mucous membrane. Probing did not reveal any caries of bone, but touching certain places produced severe pain. Microscopical examination of the hypertrophy, made by



Seropurulent maxillary sinusitis in chronic lead-poisoning.

Dr. D. Montgomery, showed "loose connective tissue infiltrated with much serum and a fair number of round cells of inflammation; the piece of tissue had a covering of columnar epithelium. There were some micrococci in the tissue." After thorough removal of the hypertrophied tissue, dry treatment with borated gauze gave no relief, and also other methods of treatment were unsuccessful. I then decided to examine the urine for albumin, sugar, and lead, none of which were found; but, on examining fresh tissue, removed from the antrum, I found with sulphide of sodium the characteristic lead reaction. I placed the patient at once under iodide treatment, and in a few days he was relieved of all pain; the seropurulent discharge then ceased, and with it the formation of crusts.

Traces of lead were now detected in the urine. The patient has steadily improved, and has remained ever since free from pain.

In this case we must assign the diseased condition of the antrum, including the neuritis of various nerves, to the deposit of lead, perhaps as an albuminate. Similar conditions have been observed in a few eye cases (Stood), where optic neuritis, accompanied by severe headaches, was produced by chronic lead-poisoning.

NO. 506 SUTTER STREET.

The New York Medical Journal.

A WEEKLY REVIEW OF MEDICINE.

EDITED BY

FRANK P. FOSTER, M.D.

THE PHYSICIAN who would keep abreast with the advances in medical science must read a *live* weekly medical journal, in which scientific facts are presented in a clear manner; one for which the articles are written by men of learning, and by those who are good and accurate observers; a journal that is stripped of every feature irrelevant to medical science, and gives evidence of being carefully and conscientiously edited; one that bears upon every page the stamp of desire to elevate the standard of the profession of medicine. Such a journal fulfills its mission—that of educator—to the highest degree, for not only does it inform its readers of all that is new in theory and practice, but, by means of its correct editing, instructs them in the very important yet much-neglected art of expressing their thoughts and ideas in a clear and correct manner. Too much stress can not be laid upon this feature, so utterly ignored by the "average" medical periodical.

Without making invidious comparisons, it can be truthfully stated that no medical journal in this country occupies the place, in these particulars, that is held by THE NEW YORK MEDICAL JOURNAL. No other journal is edited with the care that is bestowed on this; none contains articles of such high scientific value, coming as they do from the pens of the brightest and most learned medical men of America. A glance at the list of contributors to any volume, or an examination of any issue of the JOURNAL, will attest the truth of these statements. It is a journal for the masses of the profession, for the country as well as for the city practitioner; it covers the entire range of medicine and surgery. A very important feature of the JOURNAL is the number and character of its illustrations, which are unequalled by those of any other journal in the world. They appear in frequent issues, whenever called for by the article which they accompany, and no expense is spared to make them of superior excellence.

Subscription price, \$5.00 per annum. Volumes begin in January and July.

PUBLISHED BY

D. APPLETON & CO., 72 Fifth Avenue, New York.

