

10.13)

ON  
THE "LACUNÆ TONSILLARUM"

BY

D. BRYSON DELAVAN, M.D.

NEW YORK

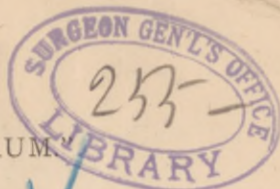
SECRETARY, AMERICAN LARYNGOLOGICAL ASSOCIATION; SURGEON TO DEMILT  
DISPENSARY, DEPARTMENT DISEASES OF THE THROAT; ATTENDING  
SURGEON, WORKHOUSE AND ALMSHOUSE HOSPITALS, ETC.



[Reprinted from the TRANSACTIONS OF THE AMERICAN LARYNGOLOGICAL  
ASSOCIATION, 1883]







THE "LACUNÆ TONSILLARUM"

By D. BRYSON DELAVAN, M.D.

TO the casual observer the surface of the normal tonsil presents a number of depressions, so slight in extent and so unobtrusive in appearance that they hardly seem to call for more than a passing glance. That most writers consider them as unimportant is evident from the hasty manner in which, in articles upon the subject, they are generally dismissed. Believing, as we all doubtless do, that the cavities of which these indentations are the orifices, constitute a prominent element in the anatomical structure of the tonsil, and play an important rôle in its general economy, it has seemed desirable to call especial attention to them, to the end that certain points in their gross and minute anatomy might be prominently brought forward, and that the facts thus suggested might be utilized in the practical treatment of diseased conditions of the part.

These depressions, the lacunæ tonsillarum, as is well known, are a series of follicles formed by the reduplications of the oral mucous membrane and their contained adenoid tissue, which constitute the organ known as the tonsil. Their number is variously estimated at from eight to eighteen. Many of them are spacious in extent, and they commonly penetrate deeply into the substance of the gland, sometimes almost reaching to its hilum. There are, also, in the interior of the tonsil, single larger cavities, each one of which includes several follicular folds, and procures their common discharge at the periphery. By this ingenious arrangement the actual superficial extent of the tonsil is greatly increased.

To this fact attention is particularly directed.

In examining under the microscope a section of human tonsil, we find that, in common with the rest of the buccal cavity, its surface is invested with a thick covering of pavement epithelium, which rests upon a delicate endothelioid basement membrane. Following this is a tolerably compact

mucosa, formed of interlacing bands of connective tissue, and containing many connective-tissue corpuscles. Occasionally, the adenoid tissue extends so near to the surface of the organ that it penetrates the mucosa, and, here and there, actually encroaches upon the epithelial layers. In the walls of the crypts this encroachment is especially marked, the more plainly so as the bottom of the lacuna is approached. In other words, the epithelial and sub-epithelial layers, thick at the periphery, become rapidly more delicate the deeper we trace them down the crypt wall, until, toward the lowest depth of the lacuna, they generally disappear, by reason probably of the attenuation of the mucous membrane in this locality, and its consequent liability to rapid post-mortem decomposition and to mechanical injury in the preparation of the microscopical section.

This unusual destructibility is another point worthy of attention, for it, together with the point before mentioned, namely, the increase in the superficial extent of the tonsil caused by the crypts, constitutes a factor of the greatest importance in the pathology and the treatment of diseased conditions of the gland.

First, in its pathology, it is evident that any morbid condition which may affect the surface of the tonsil will also, in all probability, extend into the crypts, and thus add greatly to the amount of irritation apparently present in a given case. Moreover, the delicate nature of the lining of the crypt wall would facilitate the absorption of matters retained in the crypt, and this, together with the intimate connection of the tonsil with the lymphatic system would, manifestly, expose the patient to the danger of general infection in conditions attended with the presence of local sepsis, as, for instance, in diphtheria, and in inflammatory affections giving rise to purulent discharge.

The effect of irritation of the lacuna upon the whole tonsil is a matter of common observation in cases where it has been distended by cheesy accumulations, by tonsillar calculi, or by retained pus.

The writer has recently seen a case in which the latter



condition was unquestionably accountable for a well-marked swelling and tenderness of the cervical lymphatics, and a similar case has been reported to him by Dr. Albert H. Buck; while in diphtheria the same symptom is so common as almost to be pathognomonic.

Turning now to the consideration of the matter of treatment, however, these very anatomical conditions before mentioned offer possibilities for the relief of disease which have, by the majority of practitioners, but rarely been appreciated or utilized. Instead of merely painting the medicament over the well-protected surface of the tonsil, let it be applied thoroughly to the delicate wall of the interior of the crypt. Then, not only will a far greater extent of surface be reached, but, also, the effect upon the gland will be much more profound, from the greater ease with which the application will be absorbed.

The objection may be urged, that to make such an application to the tonsil of a child, or even to an adult tonsil of normal size, would be impracticable. It should be remembered, however, that morbid conditions of the tonsil are almost invariably accompanied by hypertrophy, and that the larger the tonsil the larger will be the crypts; and this, together with the insensitiveness of the organ, which exists in many instances, will render the operation easier than might be supposed. By this plan three general varieties of treatment may be employed, namely: the disinfectant, the astringent, and the cauterant. The lacuna should first be cleansed by means of a bit of absorbent cotton upon a fine probe, or by a stream of water from a curved syringe, and the application then made by an appliance similar to the one used for cleansing.

My friend, Dr. Lincoln, has for a long while advocated the use, in this manner, of a strong solution of iodine and chloride of zinc, and he and others have also used nitrate of silver, fused upon the end of a probe. For this purpose the writer has found it exceedingly convenient to apply the fused nitrate to the end of a small splinter of wood. This can readily be grasped in any good forceps, and when once used it can be thrown away.

The measures here suggested can probably nowhere be so well utilized as in those troublesome cases of hypertrophy of the tonsil in which excision is for any reason impracticable. No stronger argument could be brought forward, however, in favor of excision of an hypertrophied tonsil than the anatomical points referred to in this article. The conditions in which the general measures referred to will be applicable, will suggest themselves so readily, that to enter into details concerning them seems unnecessary.





G. P. PUTNAM'S SONS, PRINTERS  
NEW YORK