

ILL. (ED. J.)

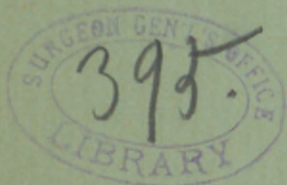Desmoid (Fibroid) Tumor of  
the Abdominal Walls.

BY

EDWARD J. ILL, M.D.,  
NEWARK, N. J.



REPRINT FROM TRANSACTIONS,  
VOL. I, 1888.





# DESMOID (FIBROID) TUMOR

OF THE

## ABDOMINAL WALLS.

BY

EDWARD J. ILL, M.D.,

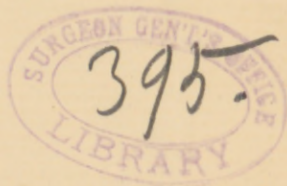NEWARK, N. J.

---

REPRINTED FROM TRANSACTIONS OF  
AMERICAN ASSOCIATION OF OBSTETRICIANS AND GYNECOLOGISTS,  
SEPTEMBER, 1888.

---

PHILADELPHIA:  
WM. J. DORNAN, PRINTER.  
1889.





## DESMOID (FIBROID) TUMOR OF THE ABDOMINAL WALLS.

By EDWARD J. ILL, M.D.,  
NEWARK, N. J.

---

THE conclusion of the medical man naturally follows his experience. Let me, therefore, relate two cases of desmoid tumors which have occurred in my practice within the past year, and then I will ask your indulgence as to what my experience and reading have taught me.

CASE I.—Mrs. L. T., American, aged twenty-three, married four and a half years, mother of two children, last child three weeks ago, was brought to my notice on February 12, 1887, through the kindness of Dr. Brumley, of Newark, N. J. The history, as was kindly given by the doctor, was this: For some time during the earlier part of the patient's pregnancy, she noticed a swelling situated in the upper portion of the left lumbar and umbilical regions. No special notice was taken of it, however, although there was a pricking pain occasionally experienced. The doctor discovered it during the confinement of the patient. While the child was still in utero it was taken for a uterine myoma. When the child was expelled, however, it was noticed that the tumor still remained in its former position.

The patient was a woman of small stature, pale, nervous, and slender build. On uncovering the patient's abdomen a hard, very smooth, laterally and, within a certain limit, freely movable tumor was noticed about ten centimetres in length by seven centimetres in width, reaching from the lower border of the ribs in the left hypochondrium downward into the left lumbar and umbilical region, remaining about two centimetres from the median line. It was prominent above the surface of the abdominal walls surrounding the tumor, and seemed to dip into the abdominal cavity about as far as it was above the abdominal walls. It was moderately tender to the touch, there was dulness all over it, and tympanitic resonance around its border. The spleen was made out easily by percussion, in its proper place, as was also the liver, both being separated readily from the tumor by an intestinal resonance. There was no difference in the percussion sounds over the region of the kidneys, from which it was inferred that those organs were in their proper place. The spleen and liver dulness were normal. During

deep inspiration and expiration it remained stationary, or, rather, there was a forward and backward movement.

The fundus uteri, which was felt just above the pubes, had no connection with the tumor, nor was there any evidence of the tumor having any connection with the pelvic organs generally.

After finding this condition of things, I felt very certain that I had to deal with a desmoid (possibly sarcoma) of the abdominal walls, and recommended its removal. At this time the patient objected to any interference, and pressure was not brought to bear upon her, since a prolonged observation was deemed advisable to satisfy any doubt as to the diagnosis. On October 12, 1887, was the next date when the patient was seen by me. This was eight months after I had first seen her. Her general health seemed as good, if not better, than it was on February 12th, though the woman nursed her baby during this time. The tumor had grown almost double in size, and was situated in the same position. It had grown more laterally than downward, so that it reached the median line, and extended to near the quadratus lumborum; below, it was near the crest of the ilium, gave the patient great uneasiness, simply from its pressure, and some dull, aching pain. She was now willing to have it removed, but wanted to have it seen by some prominent surgeon for his unbiassed opinion. Her doctor selected a most distinguished and prominent gynecologist in New York to see her, and it was in his office where I saw her for the second time on the date above stated.

The doctor rather nonplussed us (Dr. Brumley and myself) by calling it an enlarged spleen, and, when that was shown to be an impossibility, a displaced and enlarged kidney. This diagnosis was also objected to, and an exploratory abdominal section was advised as the only means for getting at a correct view of the case. The doctor did not commit himself to any positive diagnosis, saying that desmoids of the abdominal walls were too rare to make a positive diagnosis. As will be seen further on, this doubt of so prominent and so highly esteemed a surgeon rather changed my plan of operation, and possibly made it more complicated.

The patient was admitted into my service of the Woman's Hospital of this city on November 1st, for operation.

The usual treatment as to diet, bowels, and baths, such as we are accustomed to use in this institution in all cases where the peritoneal cavity is opened, was given. The plan of the operation was clearly laid out and followed in all its details, as the gentlemen present at the operation can testify.

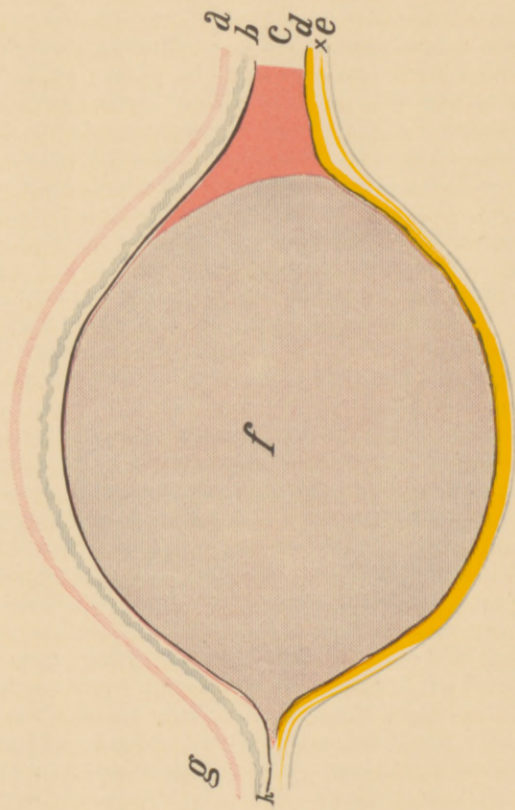
In the main, I followed the method of Dr. M. Säger, of Leipzig, to whose excellent article in the *Archiv für Gynäkologie*, Band 24, Erstes Heft, I am highly indebted, and will frequently make reference to in the detailed history of my case and *résumé*.

*Operation* November 5, 1887. The patient was anesthetized. I was ably assisted by Dr. Balleray, Dr. Bennett, and the house staff; Dr. Brumley and many of the gentlemen of the staff of St. Michael's Hospital being present.

After proper antiseptic preparation of the abdomen, dry carbolized towels



PLATE I.



- a.* Skin.  
*b.* Superficial fascia.  
*c.* Abdominal muscles.  
*d.* Fascia transversalis.  
*z.* Subperitoneal cellular tissue.  
*e.* Peritoneum.  
*f.* Tumor.  
*g.* Median line.  
*h.* Anterior sheath of the rectus.



were laid all over the patient except the field of operation. Since such a strong doubt as to the diagnosis was expressed by our New York consultant, I first made an exploratory incision to the right of the tumor in the median line, about five centimetres in length. When the incision had been carried into the peritoneal cavity there was no longer room for a doubt in the diagnosis. The tumor could be taken between the fingers in the peritoneal cavity and the hand outside, and the posterior surface of the tumor was seen to be covered with peritoneum. It now also appeared that the tumor dipped into the abdominal cavity as deep as it arose above the abdominal walls. A transverse section of the tumor and relative position of its covering and surroundings would appear as shown in Plate I. (which I would say is a modified drawing from Sanger's article). (I should say that the subperitoneal cellular tissue should have been drawn much thinner.)

A transverse section of the skin was now made, reaching from the middle of the exploratory incision to nearly the outer edge of the tumor in the lumbar region. The upper portion of the flap was now dissected backward far enough to allow the finger and the needle carrying the suture to enter between the costal cartilages and the tumor. Two ligatures were thus carried, one near the tumor and the other near the costal cartilage, and the tissue intervening cut. It now became impossible to continue the ligatures on account of the proximity of the tumor to the cartilages.

The lower portion of the tumor was now attacked, and double ligatures were carried, one near the tumor, the other about two centimetres from the first, and the tissue between was cut. The ligatures were carried about two centimetres apart, with a strong needle fastened to a handle similar to a perineum needle, except that its edges were dull. The succeeding ligature always caught up some tissue of the foregoing, so that there was complete prevention of hemorrhage. As soon as the opening was large enough to admit the introduction of a flat sponge, this was done, and all fluid, blood, etc., kept from entering the cavity of the abdomen.

While separating the skin and superficial fascia from the tumor there was a great loss of blood from the tumor side, and nothing but a sponge or the fingers pressed firmly on the tumor prevented bleeding. The openings made by a needle, to stop the flow by ligature, even proved a source of annoyance and worry. Thus it occurred that the skin was dissected off by successive steps only so far as was necessary to get at the edge of the tumor. Fifty-six ligatures were thus inserted, twenty-eight on the tumor side and a like number on the distal side. The portions ligatured near the crest of the ilium and the costal cartilages proved to be the most troublesome, and in the latter place it occurred that a ligature slipped and hemorrhage took place from a very large artery, which I took to be the internal mammary or one of its branches. All these ligatures were made of strong silk. The visceral organs which appeared in the wound were the left portion of the greater curvature of the stomach, a portion of the left lobe of the liver, the transverse and beginning of the descending colon, omentum, and small intestine. We now had a large opening in the abdominal wall about twelve by fourteen centimetres in size, and nothing to cover it except skin and

superficial fascia. There was no chance of bringing the peritoneum together, since the opening extended from the border of the ribs to the crest of the ileum and from the linea alba to near the quadratus lumborum. The intestines were now cleared from all coagula, the omentum carefully spread over the whole surface exposed to the superficial fascia. The skin was now raised in a fold and five silver wire button-sutures were placed at the base of this mass. Above this, eight deep silver wire sutures and a like number of superficial silk sutures were inserted. Then the wound in the median line was closed by five deep silver wire sutures, taking in the peritoneum from the healthy side; absorbent cotton, iodoform, and a tight bandage finished the dressing. No drainage tubes were used, and the patient was put to bed. The operation lasted three hours. Plate II., Fig. 1, will explain the arrangement of the sutures, and Plate II., Fig. 2, the appearance of this fold of the skin. Plate III. is a photographic view of the abdomen just before removal of the stitches.

The tumor measured twelve centimetres in width by fifteen in length, and twelve in diameter, and weighed 750 grammes, was perfectly solid, and cut like a very hard myoma of the uterus, only it appeared much more dense and no bloodvessels were seen on its cut surface. The anterior sheath of the rectus was inseparably connected with the tumor tissue.

Dr. T. M. Prudden, who kindly examined the tumor for me, sent the following report:

The tumor is a *fibroma*, one of those fibromas which look translucent to the eye *en masse* because of the large amount of interfibrillar fluid. The outer layers of the tumor, on the side covered with peritoneum, were tolerably firmly attached to the latter, but structurally there was a distinct line of demarcation between them.

Nov. 5, 3 P. M. An hour after the operation the patient's pulse was 130; resp. 24; temp. 101°. Complained of some pain during respiration. Later in the day the temp. rose to 102°.

6th, 7 A. M. Temp. 101°; pulse 120; resp. 16. Still some pain in the wound, for which five drops of solution of Magendi are given hypodermatically. There is no tympanites and she perspires freely. Vomited at noon of this day. At 6 P. M. temp. was 102°; resp. 19; pulse 124. During the night she passed flatus for the first time.

7th, 7 A. M. Temp. 101½°; pulse 124; resp. 18. At 8 P. M. pulse 116; resp. 18; temp. 100½°.

8th, 7 A. M. Pulse 112; resp. 18; temp. 100½°. 6 P. M. Pulse 108; resp. 18; temp. 100°.

9th, 7 A. M. Pulse 108; resp. 18; temp. 100°. 6 P. M. pulse 108; resp. 18; temp. 100½°.

10th, 7 A. M. Pulse 100; resp. 18; temp. 99°; after which there was no longer any rise of temperature.

13th. Bowels were moved by an enema, and then removed all except the button sutures, which were removed three days later.

There was union by first intention of the whole large surface of the wound, and the patient left the hospital, with a well-fitting truss, on the 29th of

PLATE II.

FIG. 1.

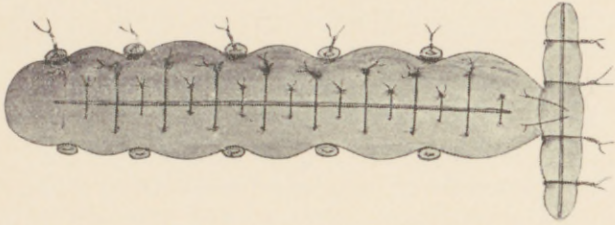
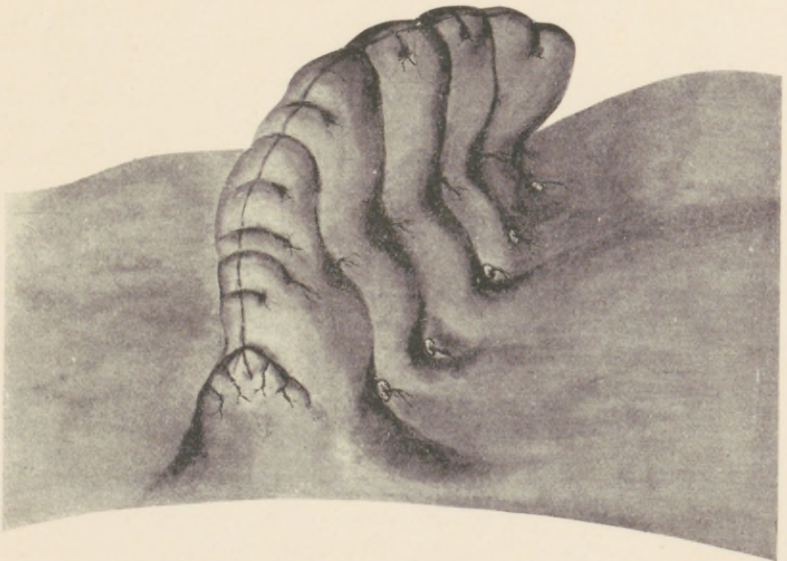


FIG. 2.





## DESMOID TUMOR OF THE ABDOMINAL WALLS.

November. Six months later an abscess formed at the lower margin of the rectus muscle, from which the tumor was removed, and a ligature removed by incision.

Up to the present time there has been no difficulty experienced by the patient from the want of so large a piece of the abdominal muscles. Her breathing is perfectly regular, and only on forced coughing is there be a slight protrusion at the site of the tumor.

CASE II.—Mrs. R. H., married, aged twenty-eight, of good family history, three children, last child fifteen months ago, presented herself on May 28, 1888. She has been ailing more or less for five or six years with pain across the abdomen, dragging-down pain, backache, and some premenstrual pain, otherwise was healthy. Two weeks ago she noticed a pain just above the pubes when leaning against some hard object or when lifting a heavy weight.

Physical examination revealed a deeply lacerated cervix; uterus movable, anteflexed; to right of uterus, not connected with it, was a hard, broad, laterally slightly movable tumor reaching eleven centimetres above the upper edge of the middle of the pubes, and eight centimetres in width. The ovaries could not be made out, and the patient was directed to present herself again for the purpose of anesthesia. She again presented herself on June 30th for the above purpose. The physical examination then showed the following: A tumor, beginning exactly in the median line about two and a half centimetres above the middle of upper portion of the pubes and extending eight centimetres further up, and also five centimetres to the right, is found to be smooth, laterally quite freely movable and with but little motion in an up-and-down direction. The tumor can be grasped by the hand and slightly raised. Respiration does not affect it. Uterus is freely movable and has no connection with the tumor. Right ovary is lodged in Douglas's cul-de-sac and enlarged. Left ovary is normal and in normal position. A very tense and short cord (tendon of the rectus) runs from the tumor to the crest of the right pubic bone. A sound in the bladder indicates that the tumor is outside of that organ. The tumor has no connection with the pelvic organs. The diagnosis is a *desmoid* tumor (sarcoma) in the right rectus muscle, probably originating in its posterior sheath. The operation for its removal was undertaken on July 18th, no particular increase in its size having been noticed at that time. An incision about five centimetres in length was made about two and a half centimetres to the right of the median line and directly over the site of the tumor. After opening the external sheath of the rectus and separating its fibre, the tumor was struck and showed itself of a grayish color, covered on all sides by muscular fibres. The tumor was separated on both sides from the muscular fibres, the tendon cut across and the tumor raised by a vulsellum, and now it became evident that its origin was the internal sheath of the rectus. Knowing that the peritoneum was very loosely attached to the deep fascia, I hoped to separate it without much trouble; but the tumor was so closely adherent to the peritoneum that an opening two by four centimetres broke into the peritoneum at that place where the diameter of the tumor was largest. The enucleation

was carried on, however, until the upper portion was reached. The rectus muscle was here transfixed, doubly ligated, and the tumor removed. In separating the outer portion of the tumor the deep epigastric was cut and retracted, so that it became quite difficult to secure and ligate it. Hemorrhage at times was very free, and several ligatures were used in different portions of the wound. The torn portion of the peritoneum was closed by continuous catgut suture. The rectus retracted very much, leaving a large opening in its sheath, into which a drainage tube was inserted. The wound was closed by deep silver wire sutures, which carried with them the lateral portion of the cut rectus muscle, the fascia and the skin, and by superficial sutures. I hardly need say that the operation was carried on under the most careful antiseptic precautions. The operation lasted one hour and a quarter. The drainage tube and superficial stitches were removed on the fourth day, no notable rise of temperature having taken place. The patient made a speedy recovery. Plate IV. explains the relative position of the tumor, with its surroundings.

The microscopic examination revealed the tumor to be a true desmoid.

In comparing the experience of these two cases I should say that Case II. was the most difficult to diagnosticate, both on account of the stoutness of the patient as well as its proximity to the pelvic organs, and, unless ether had been administered, would not have been satisfactory.

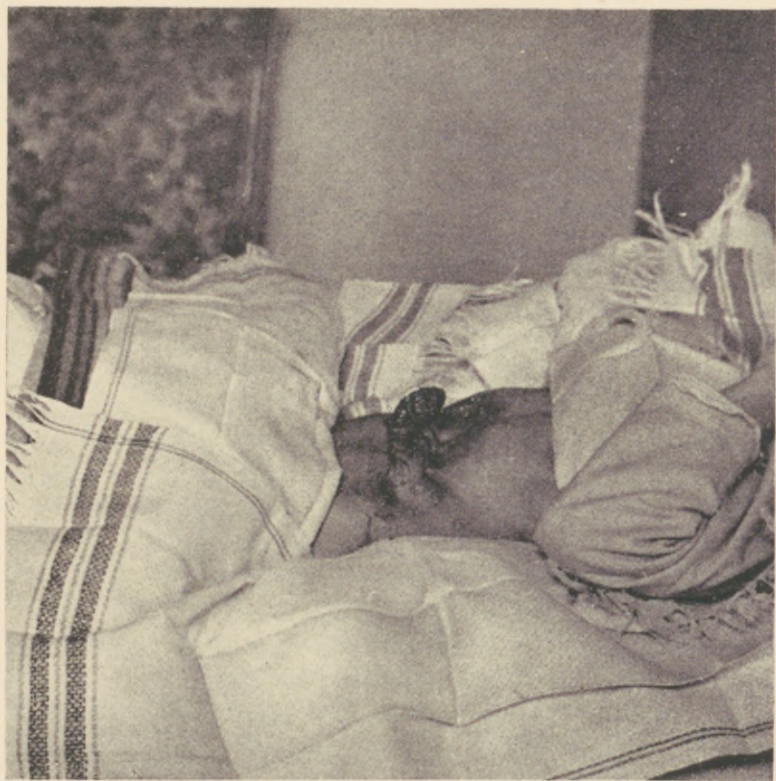Concerning the method of operation, there was so much difficulty experienced in separating the tumor from the peritoneum that I would henceforth much rather extirpate portions of the peritoneum as I had done in the first case. The removal will be more complete and there will be less liability to recurrence.

In my studies on desmoids I have remarked the following :

With rare exceptions the tumor originates from the posterior sheath of the rectus abdominis muscle. Continuing to grow, it separates and absorbs the muscular tissue. They therefore naturally produce an elevation in the abdominal walls; but on account of the large deposit of fat on the abdomen, rarely affect the skin. As a rule, however, they also grow toward the abdominal cavity. Thus they may be found to have gone as far as the loose subperitoneal cellular tissue, or they may become closely and inseparably adherent to the peritoneum, and even may break into and through that membrane (Volkman). The latter ones are, however, most apt to be sarcomatous.

Laterally they may grow to take in the muscles of the loin

PLATE III.







and above or below become adherent to the bone of the pelvis or the cartilage of the ribs. The form of the tumor is usually round or oval; at times that portion of the tumor which is connected with the fascia transversalis becomes contracted, and then the form of a shirt-stud results.

The size of the tumor, of course, varies. Commonly a patient will not seek the advice of a physician until the tumor has reached a considerable size, or because of the pain it produces. The smallest in my record of cases was reported by Dr. Heitzmann, of the size of a walnut; the largest by Dr. Weir, of New York, reaching the enormous weight of eleven pounds.

They are fed by the deep epigastric, which enters the rectus at about eight centimetres above the ossa pubes; also the superior epigastric, internal mammary, and lumbales.

ANATOMY.—The tumor itself, as a rule, is quite dry and not very bloody. In my first case, however, the quantity of blood which came from the outer portion of the tumor through the torn veins was amazing, and the blood lost in my second case was large, though it came from outside the tumor.

The tumors have invariably been found to originate in the fibrous sheaths of the muscles, and never lie loose between them. Structurally, they are composed of dense fibrous tissue. The growth of the tumor takes place by the production of intercellular fibrous substance. In this way it appears that the cellular tissue is in some portions of the tumor larger than in others, and therefore it will often be difficult to tell whether one portion of the tumor is sarcomatous or still purely fibroid. At times the fibrous tissue will accept (by metamorphosis) a colloid or mucoid appearance. Never, however, has a calcareous or fatty degeneration been observed. A sphacelated, ulcerated, and gangrenous condition, however, is not infrequent (see Parks' case), and hemorrhage of deadly character has occurred. Very frequently the growth begins during a pregnancy and continues with more or less slowness. Suadicani<sup>1</sup> (Esmarch) has observed a cessation of the growth after confinement in two cases. The female seems to be more prone to suffer from this form of tumor. In my own collection of cases eighty-two per cent. were women.

<sup>1</sup> Inaugural Dissert., Kiel, 1875.

In males they are most apt to be recurrent; thus in four cases in men reported by Volkmann, only one case remained without recurrence. In these cases the recurrent tumors were of a soft sarcomatous character.

Metastases are not mentioned, nor do any speak of glandular infiltrations.

Concerning the *etiology* very little is known. Graetz (Cohnheim)<sup>1</sup> considers that its foundation is laid in the embryo. It seems doubtful, however, whether the origin of these homologous tumors can be explained by his theory. Nor does it seem likely that an injury to the muscles, to which Herzog<sup>2</sup> attributes his case, can be charged with this form of tumor; since no one else ever heard of this form of tumor being the result of injury.

**SYMPTOMATOLOGY.**—As a rule, patients will not present themselves to the doctor until the tumor has reached a large size, or unless it is in such portion of the body where pressure is exerted upon it. We can, therefore, consider that they produce but little trouble in the early stages. When they become large they become troublesome by compression of the abdominal organs, by the disfigurement of the patient, or by the inconvenience produced by the pressure of the clothing, as in my own cases. When they become still larger, gangrene of the skin over the most elevated portion of the tumor, and thus septic infection or deadly hemorrhage may take place. It has been observed that these tumors are more sensitive during menstruation than at any other time. Under ordinary circumstances they are but slightly sensitive to touch. The tumor in my Case I. could be moved about freely without producing any real pain. In Case II. it was more painful on pressure.

**DIAGNOSIS.**—The fact that between eighty and ninety per cent. of all cases will be women must be taken into consideration when a diagnosis is made; also that the tumor rapidly increases during a pregnancy, though it may have been present before and of very slow growth. From the cases I have collected you will see that the tumor grows two or three times its size in about a year.

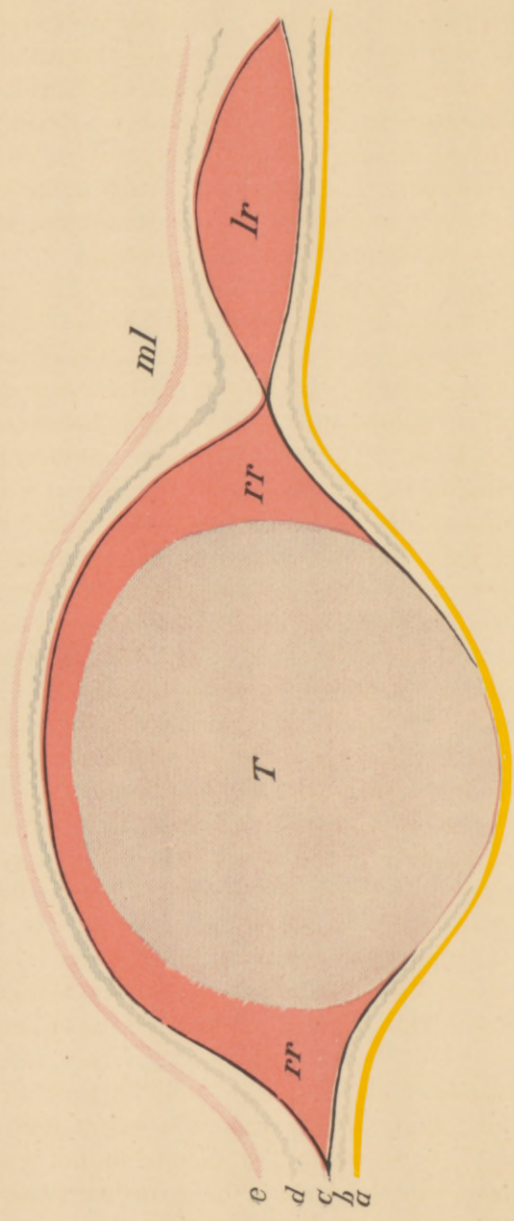
By *inspection* the tumor will appear above the surface of the

<sup>1</sup> Cohnheim, Allg. Pathologie, p. 634.

<sup>2</sup> Ueber Fibroma der Bauchdecken, München, 1883.



PLATE IV.



- a. Peritoneum.
- b. Subperitoneal cellular tissue.
- c. External and internal layer of deep abdominal fascia.
- d. Superficial fascia.
- e. Skin.
- lr. Left rectus muscle.
- ml. Median line.
- rr. Right rectus muscle.
- T. Tumor.

abdominal walls, if it has reached any large size and the patient is not over-fat. The skin, possibly, is covered by large veins. This will be more so the larger the tumor appears. During respiration the tumor will be lifted forward and backward only, the patient being on her back. When the tumor is of excessive size, forced respiration might cause an upward or downward movement of the growth. There will be no lifting up of the abdominal walls from the tumor on deep inspiration, as is so often seen in intra-abdominal growths.

By *palpation* the tumor will be found to be very circumscribed, at times perfectly smooth (uni-lobular), at others uneven and nodular (multi-lobular), and generally of solid, board-like feel. Occasionally fluctuations will be noticed, as was observed in Dr. Weir's<sup>1</sup> case, and probably accounted for the mistaken diagnosis. If not too large, and occurring in a multipara, the fingers of both hands can almost pass around the tumor and the posterior smooth or nodular surface distinguished. This, however, will not be the case when the patient is directed to contract the abdominal muscle, when the tumor will appear immovable. This must be an important point in the differential diagnosis between a tumor situated within or outside of muscles and fascia. For when the tumor is situated in the subcutaneous cellular tissue it will be movable no matter what condition the muscles are in. If the tumor is intra-peritoneal, any contraction of the muscle will not send the tumor back to its place, as would be the case with a tumor situated in the muscular or fibrous layers of the abdominal walls. If the tumor were in the deep layer of the abdominal muscles, any contraction would tend to throw the tumor into the abdominal cavity; if in the outer layer, the tendency would be to raise the tumor above the level of the abdominal walls. The tumor will not often be sensitive to pressure.

The percussion note, of course, will be dull all over the region of the tumor. Percussion will often help us out in differentiating between tumors of the abdominal walls and an enlarged spleen, especially when the growth is situated in the

<sup>1</sup> Medical Record, Dec. 3, 1887.

left hypochondriac region. Thus there was a distinct tympanitic resonance between the tumor and the location of the normal spleen-dulness in my Case I.

Thus it was, also, that the tympanites between the left lobe of the liver and the tumor could be noticed only when the patient made a deep expiratory effort. While the dulness over the liver rose and sank by inspiration and expiration, the dulness over the tumor remained stationary. Whether there would be resonance between the kidney and the tumor, if the tumor were situated in the flank, would depend upon the size which the tumor had reached and how far it was pushing itself into the abdominal cavity. In my Case I. there was a distinct and unmistakable resonance between the tumor and the dulness of the region of the kidney. In case of a tumor of the kidney the percussion over the lumbar region of the affected side would be dull, while if it were a desmoid the percussion sound would be normal. The dulness between the tumor and a full bladder could only be mistaken if the bladder was not carefully emptied of its contents. The same might be remarked about a large amount of feces in the colon.

If the tumor were in the lower part of the abdominal wall, possibly closely connected with the ilium and very large, the diagnosis becomes more difficult, and the examination under an anesthetic would probably give the required result. This had to be done with my Case II. before any decision could be obtained. When the tumor is in this region and becomes very large, its differentiation from uterine fibroids, solid tumors of the ovary or round ligament might become impossible, and exploratory incision becomes the proper procedure. A case of localized peritonitis, which originated during pregnancy in the left hypochondrium and simulated a desmoid in many respects, was only understood after aspiration and careful thermometric observation. It seems to me hardly possible that there could be any difficulty in differentiating between malignant tumors of the intestine or omentum and a desmoid.

An adherent displaced kidney might be taken for a tumor in the abdominal walls. But the form of the kidney and resonance over that portion of the lumbar region where the kidney was missing, and the muscular symptoms of which I

have just spoken, would probably give the necessary information.

The sense of touch given by adipose tissue, whether as a lipoma of the omentum or sub-peritoneal or subcutaneous fatty tissue, is so much different from that of a desmoid that they could hardly be confounded with each other. Thus, also, an umbilical hernia containing a lipoma of the omentum would present a *soft*, lobulated condition, which is never the case in the desmoids.

A ventral or umbilical hernia could, if strangled, produce a tumor which is very hard, but the symptoms of strangulation and the outer appearance of the tumor, and other points in the history of the case, would leave no doubt as to its nature.

Cysts of the urachus cannot possibly be confounded with desmoids; since these cysts commonly empty themselves by the navel or bladder, thus producing a disappearance of the cyst temporarily.

Desmoids of the abdominal walls are rare, since only one case, by Nélaton, has been described, and very possibly it came from an ovary, as did the myoma of Dr. Marcy's case come from the uterus.

The *treatment* is extirpation, and the sooner this is done the better for the patient.

While the tumors are still small and in a location where the peritoneum is not closely adherent to the deep fascia, extirpation without opening the peritoneum may be resorted to, and must be our aim, but it will rarely succeed. As a rule, however, extirpation with resection<sup>1</sup> of the peritoneum will be, under careful antiseptic precautions, the safest by guarding against recurrence, should the tumor prove to be sarcomatous.

The prognosis of the true desmoid after removal is good so far as its benign character is concerned. The prognosis without extirpation must be almost fatal unless we consider such fortunate cases as those reported by Suadiciani. Thus, also, will partial removal result disastrously, as Esmarch's second case would prove.

<sup>1</sup> Sänger, Archiv für Gynäkologie, Band 24, p. 20.

## DESMOID (FIBROID) TUMORS OF THE ABDOMINAL WALLS.

No.	Reporter.	Age	Family history as to tumors generally.	Sex	Length of time the tumor was known to exist.	Location.	Size when first noticed.	Size when last seen by the operator.	Length of time intervening.	Reporter's opinion of the origin of tumor.	Probable or possible cause.	Treatment.	Result.	Anatomical character of tumor.	Remarks.
1	T. G. Richardson, New Orleans.	30	.....	F.	.....	Right iliac.	.....	Goose egg.	.....	.....	.....	Excision.	Cured.	Strictly fibrous.	"The peritoneum was closely attached to the posterior surface, covering about a square inch. In endeavoring to dissect off the serous membrane the peritoneal cavity was opened, but as no blood entered irrigation was not practised. Drainage tube used, but not entering the peritoneal cavity."
2	C. Heitzmann, New York.	45	.....	M.	.....	Left lower iliac region.	Hazel-nut	.....	.....	.....	.....	Excision.	Cured.	Dense, fibrous connective-tissue bundles freely inter-lacing.	
3	D. W. Cheever, Boston, Mass.	25	.....	F.	.....	Between umbilicus and pubes.	.....	Size of ostrich egg.	.....	.....	.....	Removal.	Cured.	Solid.	No recurrence. Involved peritoneum on under surface by contiguity. Peritoneum was opened at time of removal.
4	R. F. Weir, New York.	41	.....	F.	4 years.	Both iliac and umbilical region.	.....	11 lbs.	.....	Transversalis fascia.	.....	Extirpation.	Cured.	Purely fibrous tissue.	Reported in the Medical Record, Dec. 3, 1887. Peritoneum as large as two hands was removed with the tumor, and peritoneum brought together by nature. Peritoneum was not opened. Report in Medical Record, December 3, 1887.
5	C. K. Briddon, New York.	27	None.	F.	9 mos.	Right inguinal	.....	.....	.....	Fascia transversalis.	.....	Extirpation.	Cured.	.....	Peritoneum not opened.
6	J. A. McGraw, Detroit, Mich.	23	None.	F.	Not recorded.	Right iliac fossa.	.....	Double fist.	Several years.	None.	.....	Extirpation.	Cured.	Fibroma.	Peritoneum not opened.
6	" "	30	None.	F.	Not recorded.	Right iliac fossa.	.....	Double fist.	Several years.	None.	.....	Extirpation.	Cured.	Fibroma.	Peritoneum not opened.



7	Chris. Fenger, Chicago, Ill.	20	None.	F.	6 mos.	Lower part of left hypo- gastric region.	Walnut $3\frac{1}{2} \times 2\frac{1}{2}$ inches.	6 mos.	Tendon of the internal oblique abdo- minal muscle.	None.	Extirpa- tion Jan. 31, 1880, in Cook Co. Hospital	Cured.	"Firm fibroma" micro- scopical appear- ance of a ute- rine fibroid" "Macro- scopical charac- ter of a uterine fibroid perhaps less dense."	"Firm Peritoneum was not opened since "the fascia transversalis could be peeled off the abdominal sur- face of the tumor."
8	Reeves Jackson, Chicago, Ill.	8	None.	M.	Not known.	Umbilical, right hypo- chon- driac, lumbar, and hypo- gastric regions.	..... Probably $3 \times 5$ inches.	.....	Not given.	.....	Enucle- ation.	Cured.	"Macro- scopical charac- ter of a uterine fibroid perhaps less dense."	Enucleation and very slight loss of blood; peritoneum not open- ed. Recovery prompt.
9	D. Prince, Jacksonville, Ill.	?	None.	F.	.....	.....	4 inches in diam- eter.	.....	.....	.....	Extirpa- tion.	Cured.	Macro- scopical appear- ance of a fibroid.	Peritoneal cavity was not opened.
10	R. S. Sutton, Pittsburg, Pa.	23	None.	F.	2 years.	Right inguinal and un- bilical region.	Small. Size of orange.	2 years.	Fibres of inter- nal ob- lique.	.....	Extirpa- tion.	Cured.	Macro- scopical appear- ance that of a fibro- myoma.	The tumor never returned; peri- toneum not opened; the wound healed by first intention. <sup>1</sup>
11	Edward J. Ill, Newark, N. J.	28	None.	F.	16 mos.	Above the left lumbar and un- bilical region.	7-10 centi- metres.	9 mos.	Fascia trans- versalis, i.e. pos- terior sheath of rec- tus ab- dominis	.....	Extirpa- tion.	Cured.	Purely fibrous tissue.	Case I. of my paper. Peritoneal cavity was opened and about 100 square centimetres of peri- toneum removed.
12	" "	30	None.	F.	6 w'ks	Right illac in rectus abdo- minis.	5-8 centi- metres.	6 mos.	Poste- rior sheath right rectus abdo- minis.	.....	Extirpa- tion.	Cured.	Purely fibrous tissue.	Case II. of my paper. Peritoneal cavity was opened.

<sup>1</sup> Very probably this was a true fibroma and is reported under this heading for that reason, no microscopical examination having been made.

## OTHER FORMS OF TUMORS OF THE ABDOMINAL WALLS.

No.	Reporter.	Age	Family history as to tumors generally.	Sex	Length of time the tumor was known to exist.	Location.	Size when first noticed.	Size when last seen by the reporter.	Length of time intervening.	Reporter's opinion as to the origin of the tumor.	Probable or possible cause.	Treatment.	Result.	Anatomical character of tumor.	Remarks.
1	J. W. Gouley, New York.	30	.....	M.	.....	Left flank and lumbar region.	.....	.....	.....	.....	.....	Removal of tumor and its recurrence at five different times.	Recurrence a few months after last operation, and death.	Spindle-celled sarcoma	
2	R. Park, Buffalo, N. Y.	36	None.	F.	Difficult to say as there was a hernia of congenital origin.	Umbilical region.	.....	258 lbs	.....	Tumor arose from the sac wall.	.....	Complete excision of tumor and hernial sac in July 1885.	Cure.	Fibrosarcoma	Had given particular trouble since two years. No return after operation. Sac and all was so large that when she sat down the tumor touched the chair before the buttocks did.
3	H. T. T. Hanks, New York.	27	None.	F.	6 mos.	Right inguinal in diameter.	1 inch	2x3 inches.	6 mos.	?	.....	Extripation.	Cure(?)	Recurrent fibroid.	A year after the first operation the reporter removed a second one on the opposite side, and after two years more two further tumors appeared in other parts of the walls of the abdomen. (Partly reported in the American Journal of Obstetrics, 1884, partly by personal correspondence.)

4	H. O. Marcy, Boston, Mass.	...	Not given.	F.	.....	.....	.....	.....	Uterine.	.....	Extirpa- tion	Cure.	Calcar- eous myoma.	The tumor was removed by the late Dr. H. A. Martin, of Rox- bury, Mass., and is said to have been in the abdominal wall. Whether it formed part of the abdominal muscles is not spoken of. The tumor was removed without opening the abdominal cavity. Dr. Marcy thinks it a uterine myoma that became detached from the uterus.
5	R. S. Sutton, Pittsburg, Pa.	70	None.	M.	Some weeks.	Below navel to right side.	Walnut.	Walnut.	A few weeks.	.....	Extirpa- tion.	Recov- ery.	Not known.	Patient died, seven or eight years later, of sarcoma in the corre- sponding groin.
6	" "	40	None.	F.	1 year.	Right groin.	Small.	Goose egg.	1 year.	.....	None.	Death.	Sarcoma	Growth of the tumor very rapid.
7	" "	22	None.	F.	More than a year.	Above Pou- part's ligament on left side.	Small.	Goose egg.	1 year.	Blow.	None.	Death.	Sarcoma	Patient declined extirpation.

I have for my instruction collected as many cases of desmoids and other tumors of the abdominal walls (see Tables), as I was able to reach by correspondence with American surgeons and reference to American medical literature. I wish to draw your attention to a few of the following points:

Among the desmoids all but two were females. Among these the ages ranged between twenty-three and forty-one years. The ages of the males were eight and forty-five years. The longest time any of the tumors was known to exist was four years. (Dr. Weir.)

In five cases the origin of the tumor was given as the fascia transversalis; in one, the fibres of the internal oblique muscle. The knife was the treatment in every case. In six cases the tumor was so *closely adherent* to the peritoneum that this cavity was opened by rupture of that membrane, and in two of these by excision of large portions. And, lastly, that they all have recovered. From personal correspondence I know that Dr. Thomas has removed four such tumors, and that he will publish the results himself.

Of the other forms of tumors, five were females and two males. Five cases were denominated sarcoma, one each a recurrent fibroid, and one calcareous myoma.

Five of the tumors were removed by operation. They all recovered, but recurrences are noticed in three of these.

#### BIBLIOGRAPHY.

- S. GRAETZER. Inaugural Dissertation. Breslau, 1879.  
 E. SUADICANI. Inaugural Dissertation. Kiel, 1875.  
 W. BILLROTH. Die Allg. Chirurg. Path. und Therapie. v. Pitha und Billroth. Handbuch der Allg. und Spec. Chirurgie, iii. 2.  
 COHENHEIM. Allgemeine Pathologie.  
 GROSS. Surgery.  
 R. F. WIER. A Huge Fibroma, etc., Medical Record, December 3, 1887, p. 703.  
 M. SÄNGER. Ueber Desmoid der Bauchdecken, etc., Archiv für Gynäk., Band 24, Erstes Heft.  
 C. ROKITANSKY. Path. Anatomie, 1856.  
 RINDFLEISCH. Lehrbuch der Path. Gewebslehre, 1875.  
 WAGNER. Handbuch der Pathologie, 1872.  
 FORSTER. Path. Anat., 1865.  
 GOULEY. Diseases of Man, etc., 1888.  
 HERZOG. Ueber Fibroma der Bauchdecken. München, 1883.



