

Burnett (S. M.)

ac

Compliments of

Swan M. Burnett

A CASE OF GREAT SWELLING OF THE EYELIDS
AND FACE FOLLOWING AN UNSUCCESSFUL
ATTEMPT TO EXTRACT THE UPPER CANINE
TOOTH ON THE LEFT SIDE; ABSCESS OF THE
ORBIT; TOTAL BLINDNESS; ATROPHY OF THE
DISC; OBLITERATION OF THE RETINAL VES-
SELS.

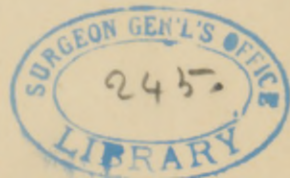BY DR. SWAN M. BURNETT, WASHINGTON.

(With one wood-cut.)

John H. Davis, a colored man, aged thirty-five, was operated on for cataract of the right eye by extraction, in 1874, with partial success only. The left eye continued to have perfect vision until the 28th of January, 1884. At that time the upper canine tooth on the left side began to ache, and he went to a dentist for the purpose of having it extracted. This the dentist attempted to do, but failed after many persistent efforts. He told Davis that the jaw-bone was broken from the violence of the pulling. That same evening the left side of the face began to swell and be painful, and soon the left eye was closed. As it could not be opened for nearly two months, he was not able to tell whether there was any protrusion of the ball or what its condition otherwise was. At the end of twenty-one days, during which time there was fever, but no chill nor mental disturbance, a discharge set in from the region of the inner canthus, and afterward from the forehead and the cheek near the lower orbital ridge. When the swelling subsided so as to enable him to open his eye, he found that vision was abolished, not even perception of light remaining.

On the 20th of May, 1884, when I examined him for the first time, I found the eye in proper position and its movements perfect. There was a depression at the outer portion of the lower orbital ridge extending two *cm.* downward into the cheek, caused

Reprinted from the ARCHIVES OF OPHTHALMOLOGY, Vol. xiv., Nos. 2 and 3, 1885.



by exfoliation of bone. There was no scar either in the skin or conjunctiva near the inner canthus. Exophthalmus was not present. There was no perception of light.

An ophthalmoscopic examination revealed a condition of the fundus shown in the accompanying sketch (fig. 1). The disc-surface is sharply outlined, dead white, and not excavated. From its lower edge there ran three white lines downward, one almost directly, one deviating inward, and one running downward and

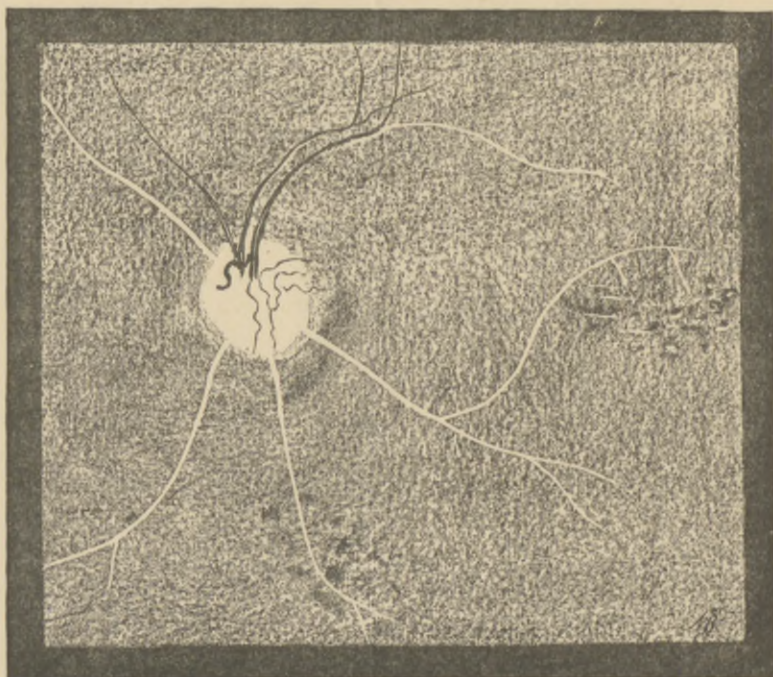


Fig. 1.

outward. This latter divided and sent a branch which ran the unusual course shown in the figure, passing upward to the level of the centre of the o. d., becoming nearly horizontal, and sending at the same time two short branches downward. The other branch passed diagonally downward and outward, and became forked, as did the other two white bands running downward.

From the upper edge of the disc one white band ran inward and upward for about the same distance as its companion on the same side below, but was not forked at the end. Proceeding from

a point somewhat above the centre of the disc and towards its inner edge there ran upward two vessels filled with blood, one smaller and lighter in color than the other. The lighter one curved slightly outward, sending one branch directly upward, and another, very fine, almost horizontal. The larger, darker vessel ran a course almost parallel to this one, but gradually diverged slightly to the outer side. It sent off no horizontal branch, but just where this branch should be given off there was a white band which ran outward and curved slightly downward. A very delicate light vessel ran upward and inward between the upper white band and the larger light vessel. On the surface of the disc several dark and very tortuous vessels were seen, all of them, except one, very delicate and fine; three of them ran outward and two downward to the edge of the disc, but none of them could be followed over the border. None of the lines, either red or white, were broken—they were either red or white throughout,—but to the outer side of the smaller red vessel there was a distinct white line about $\frac{3}{4}$ of an o. d. in length, and the same thing was observed on the outer side of the larger dark vessel, just where it was joined by the large white line running horizontally. The fundus was even in tint, with the exception of two places: one above the bifurcation of the middle lower white band, and the other a little beyond the macula-lutea region and under the curve of the white line taking the unusual course. These alterations consisted in dark or black dots and larger masses, together with perfectly white and glistening dots and lines, which ran for the most part horizontally. These last alterations were found almost exclusively in the yellow-spot region as shown in the figure.

The interest of this case lies in the striking resemblance—the exact identity, in fact—of the ophthalmoscopic appearances to those found in blindness after facial erysipelas. If one will take the trouble to compare the drawing of our case with the fine chromo-lithographic plates of Knapp's case of blindness from erysipelas of the face in vol. xii. of *These ARCHIVES*, and Carl's case in *Zehender's Monatsbl. f. Augenheilk.* for April, 1884, it will be seen at once how all three agree in essential particulars. The question of the connection between erysipelas affecting the face and the orbital and ocular changes associated with it has been too recently discussed to render any further comment on the

subject necessary. Knapp has, from his careful observation of a case from the beginning, clearly shown, I believe, that all the intra-ocular changes are due to mechanical pressure within the orbit, and that none are due to the specific poison of the disease. Our case lends support to that view, for the clinical history does not warrant a diagnosis of erysipelas. On the contrary, it is almost certain that there was an abscess of the antrum of Highmore caused by a fracture of its walls from the forcible but unsuccessful attempt to extract a tooth, which led to the inflammation in the orbit. Further evidence of this is the destruction of a part of the maxillary bone at the lower edge of the orbit.

It has been known for a long time that abscesses in the antrum were attended by inflammations of the orbital tissues, followed by blindness. In 1862, Mr. James A. Satler, surgeon-dentist to Guy's Hospital, reported such a case in the *Medico-Chirurgical Transactions*, vol. xlv.; and he alludes in his paper to an article by A. Th. Brück on "Repeated Inflammations in the Antrum of Highmore and Amaurosis," published in *Caspar's Wochenschrift f. d. gesam. Heilk.*, March, 1851.

Reference to some of the more recent literature of orbital and ocular disease associated with dental caries can be found in an article by Vossius in *Graefe's Archiv* xxx., p. 157. Vossius' case, however, differs in many essential particulars from mine.

It can be readily understood how such abscesses of the antrum lead to inflammations and abscesses within the orbit. The wall of bone separating the two cavities is extremely thin, and will give way easily to the increased pressure within the antrum; or the inflammation might be propagated along vessels which may happen to pass from the one to the other.

