

Brown (Buck.)

CASE OF TALIPES VARUS.

By Buckminster Brown, M.D.

TALIPES VARUS.

BY BUCKMINSTER BROWN, M.D.

Read before the Boston Society for Medical Improvement.

THE lad who is here this evening, to be examined by the members of the Society, was born with double talipes varus. He is from Detroit, Mich., and is now 9 years of age. The efforts of his parents, from the time of his birth to the present, have been unwearied to obtain a cure of the deformity, and no expense or pains have been spared. The following extracts from a letter written by the boy's mother, previous to his coming to Boston for treatment, give a brief history of the case up to that time.

“Our boy was born with both feet very badly misshapen. At the age of eight months he was operated upon by a surgeon, who divided the tendon of the heel and the ligament in the hollow of the foot, * * * * * but the feet remained the same as at first. At the age of two years and four months, the child was operated upon again, by a surgeon who was confident of success, and he remained under his care two years, during which time the tendo-Achillis and the ligament on the inside of the foot were cut five times each, making ten incisions in the two feet. All sorts of apparatus were used, from a single splint to a harness reaching from the waist to the toes, weighing not much less than five pounds. Chloroform was administered during the cutting, and paregoric and opium without stint given to enable the little sufferer to bear his torture. At the end of two years his health seemed to be giving way, and we released him from the stocks. That he lived through all, seems a wonder; that his temperament should be nervous and his disposition irritable, seems but natural. He is now eight and a half years old; his feet are as bad as ever they were, I think—and notwithstanding our hard experience, we are anxious

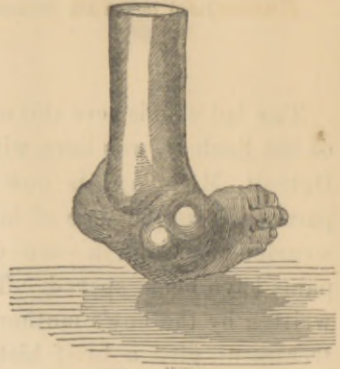
to place him under your care, in case you could encourage us to believe that he could be made better."

The plaster casts which I have now in my hand are from the moulds of this boy's feet, taken when he first came under my care. (See Figures 1 and 2.) It will be seen that they present some unusual peculiarities, consisting chiefly in the rounded, marble-like prominences standing out upon the dorsum or top of the feet, and in the marks of the cicatrices and adhesions which were formed

Figure 1.

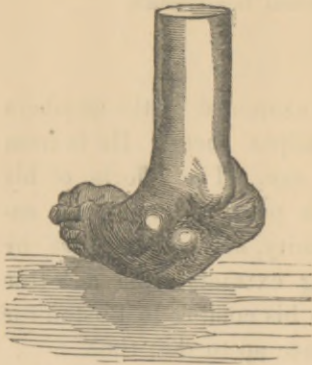

Figure 2.



Copies of casts taken when the patient came to Boston.

between the skin, fascia, tendons and cellular tissue at the place of the early operations, all of which are well represented by the casts. The feet were completely turned inward, and rotated on their own axes, and the patient in walking threw one over the other, as is usual in such cases.

Figure 3.

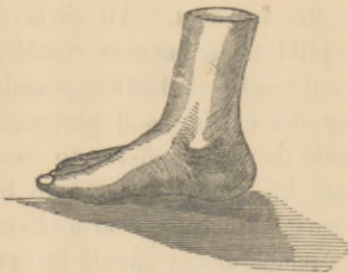
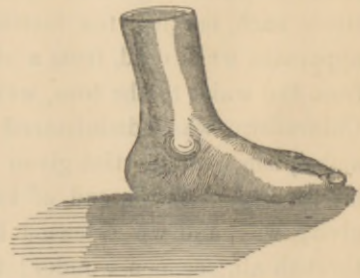
Figure 4.



Copies of casts taken after treatment.

The left foot was cured, or nearly in the condition you now see it, in about six weeks. (See Figures 3 and 4.) In the right, how-

ever, the cicatrices and adhesions above referred to were far more rigid and unyielding.

The free and persevering use of strong mercurial ointment appeared to have a decided effect in producing absorption and softening of these results of inflammation, and the member was gradually brought to its present state, which it will be seen is that of a perfect foot. The appearance and shape of the members, and the action of the joints (which last is in all these cases the most difficult to acquire), will be found, upon examination, to be equal to that of feet which have never been malformed.

Boston, July, 1859.

