

*Goodwillie (D.H.)*

TREATMENT OF ARTHRITIS  
OF THE  
TEMPORO-MAXILLARY ARTICULATION

BY ✓

D. H. GOODWILLIE, M.D., D.D.S.

NEW YORK CITY

LATE CLINICAL ASSISTANT TO THE METROPOLITAN THROAT HOSPITAL; PERMANENT  
MEMBER OF THE AMERICAN MEDICAL ASSOCIATION; HONORARY MEMBER OF  
THE CANADA MEDICAL ASSOCIATION; MEMBER OF N. Y. NEURO-  
LOGICAL SOCIETY; OF THE MEDICAL SOCIETY OF THE  
COUNTY OF N. Y., ETC.

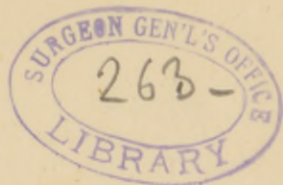(READ BEFORE THE AMERICAN MEDICAL ASSOCIATION)

[Reprinted from the ARCHIVES OF MEDICINE, June, 1881]



NEW YORK  
G. P. PUTNAM'S SONS  
27 & 29 WEST 23D STREET  
1881





## ARTHRITIS OF THE TEMPORO-MAXILLARY ARTICULATION.\*

By D. H. GOODWILLIE, M.D., D.D.S.,  
NEW YORK.

**A**RTHRITIC inflammation may be of a local or constitutional character.

The former may be excited by dislocations, blows, luxations, or any lesion in neighboring parts.

In the latter by some blood poison, viz.: syphilis, rheumatism, gout, scrofula, etc., and as such must have disease medicines that are antidotes or specifics to the particular blood poison.

It is my desire, in the following cases, to call attention to my method of producing *extension* in acute inflammation of this joint from either of the above causes.

CASE I.—*Gouty arthritis of the temporo-maxillary articulation.*  
A. P. B., of Hanover, N. H., 60 years of age, was brought to me by the late Prof. A. B. Crosby, M.D.

He had been a man of very robust constitution, but for the past two or three years had suffered with attacks of gout, and was now certainly an object of pity to look upon.

The gout from which he had suffered came with terrific violence into both temporo-maxillary articulations, and when he came into my office his teeth were chattering, like one in a malarial chill, from excessive irritation and spasm of the muscles of the jaw.

This caused great pressure on the inflamed articular surfaces,

---

\*Read before the American Medical Association at Richmond, Va., May, 1881.

Reprinted from the ARCHIVES OF MEDICINE, Vol. v, No. 3, June, 1881.

and gave him excruciating pain, so that he got no relief except from the effects of morphine, hypodermically administered.

The arthritis was preceded by neuralgia of the inferior maxillary nerve. On examination of the mouth, I found that his teeth had no decay in them, but some were very much worn by mastication upon the crowns, and some pulps (nerves) were exposed, and in consequence he had pulpitis, causing neuralgia that was followed by acute arthritis.

In the treatment nothing could be done with him except under the effects of morphine and an anæsthetic. On entering my office, a hypodermic dose of morphine was administered, and when under the effects of the drug, he was given nitrous oxide as an anæsthetic.

This relieved him from pain, while consciousness to some extent remained.

The pulpitis, the exciting cause of the facial neuralgia, was removed by protecting the exposed dental pulps (nerves) from the air and attrition by means of gutta-percha and an interdental splint.

The principle of the treatment of arthritis in these joints is the same as in others, differing only in the method of application.

I do not know that any extension appliance has ever been used for the relief of arthritis of this joint.

The method that I employ is as follows: In this case the patient was under the anæsthetic effect of morphine and nitrous oxide. If there is any rigidity of the muscles, cautiously force open the mouth and take an impression of either the upper or lower teeth, and a rubber splint is made from the cast to cover over all the teeth in one jaw. Upon the posterior part of this splint is made a prominence or fulcrum, (D) so that when the mouth is closed the most posterior teeth close upon it, while all the anterior teeth are left free. The next step is to take a plaster of Paris impression of the chin, and from this make a splint. (A) On each end of

the splint is made a place for fastening elastic straps (B) that pass up on each side of the head to a close-fitting skull-cap (C). See fig. 1.

When the apparatus is in place and the elastic straps tightened so as to lift the chin, then pressure is brought to bear on the fulcrum at the posterior molar tooth, and so by this means extension is made at the joints, and the inflamed surfaces within the joints are relieved from pressure: then immediate relief is experienced.

FIG. 1.



As soon as this apparatus was put on this patient his pain stopped instantly, and he took no more morphia.

He continued for a time his anti-gout remedies, and after some manipulations of the lame muscles of the jaws under elec' ...y perfect motion was restored.

CASE 2.—*Arthritis from septic poison.* Miss Clara B., of Iowa, 21 years old, was sent to me by Dr. J. C. Hutchinson, of Brooklyn. Her history, in a few words, was as follows: Six years before had exposed dental pulps (nerves) of the inferior molars of both sides. A liberal supply of arsenic was used to de-vitalize the nerve, and this was left in many days.

Soon after teeth became very painful, jaw swelled, extending also to the submaxillary gland and tonsil of left side.

Necrosis of cellular portion of the jaw containing the teeth followed, and they were all removed with the necrosed bone. The submaxillary and tonsillar glands suppurated, and opened externally with a great discharge of pus.

With this great amount of swelling in jaw and glands, she suffered much from dyspnœa. Her vital powers became very much exhausted from want of food, and septic poison.

When she came under my care in June, 1879, she was quite anæmic and very despondent—troubled with insomnia, loss of appetite, and vomiting.

No menstruation for the past 18 months. Complained of great pain on left side of the head, at the temporo-maxillary articulation; partial ankylosis. At times there was a discharge from the ear and also into the naso-pharyngeal cavity where she had quite an abscess.

No teeth in the lower jaw, while the upper set was quite perfect.

Two large scars, as the result of the suppurating submaxillary and tonsillar glands; one about an inch and a half anterior to the ramus, and the other made by the suppurating tonsil on the anterior border of the sterno-cleido-mastoid muscle, one and a half inches long by one-half inch broad.

Treatment consisted in applying an extension apparatus in the same manner as in the first case. Her alimentation consisted in a teacupful of warm milk to which was added one teaspoonful of maltine, pepsine, and pancreatine every three hours. Vomiting stopped and digestion immediately improved, and then tonics were added. Warm sponge baths of salt water and bay rum every night and morning, and a mild current of electricity.

She continued to improve, and in Feb., 1880, menstruation returned. In March the apparatus was given up and a lower artificial denture inserted, and now her mastication was restored. In June, 1880, one year after treatment was begun, she had gained 24 lbs. in weight, and has been perfectly well up to the present time.

CASE 3.—*Arthritis from impacted wisdom-tooth.* D. L., aged 18 years, had an impacted right inferior wisdom-tooth that produced extensive swelling with partial ankylosis. Great pain in the joint.

Administered an anæsthetic, forced open the mouth, and removed the impacted tooth lying in the ramus. Extension apparatus applied; muscles were manipulated under electricity every day, and at the end of two months' treatment he was well.

CASE 4.—*Arthritis from tonsillitis.* Miss Mary H. had a severe attack of tonsillitis which extended into left temporo-maxillary articulation. Had been suffering some time before I saw her. Unable now to open her mouth. Contracture muscles very stiff from misuse.

An apparatus was worn, and every day the mouth was cautiously opened so as not to stir up any new inflammatory process in the joint. She made a good recovery.

In all cases of arthritis the muscles suffer more or less, according to the extent of the inflammatory process. Contracture muscles get stiff from the products of inflammation, while in the depressor muscles may be expected some degenerative changes from want of exercise.

I will not further trespass on your time but only say that from experience it will be found:

(1) That arthritis of this joint, like all other joints, the result of local or constitutional causes, requires proper and prompt treatment, as it may pass in a very short time from its most incipient stage to one of suppuration and destruction.

(2) That arthritis without proper treatment more often results in fibrous ankylosis, and that bony ankylosis is the exception.

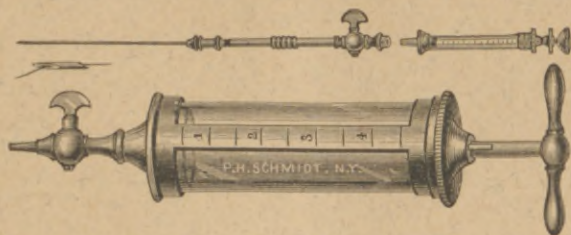
(3) That the highly developed muscles of the jaw, from pathological changes, the result of inflammation, or even from misuse, have always more or less impaired motion, and in some cases require more treatment than the joint trouble.

(4) Cases do sometimes occur in which the poisonous effects of overdoses of mercury have had a disastrous result.





# MUNDE'S PELVIC ASPIRATOR.



PHILIP H. SCHMIDT,

*(Twenty-five years with Geo. Tiemann & Co.),*

MANUFACTURER AND IMPORTER OF

SURGICAL AND ORTHOPÆDIC INSTRUMENTS,

TRUSSES, SUPPORTERS, ELASTIC STOCKINGS,  
SPLINTS, AND BRACES. Repairs promptly attended to.

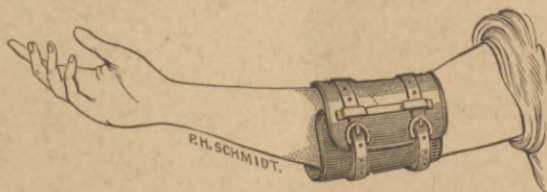
No. 1311 BROADWAY, Up Stairs,

S. W. Cor. 34th Street,  
Over Drug Store,

(OLD NO. 1275.)

NEW YORK.

Mrs. Schmidt will be in attendance to wait upon Lady Customers.



GOODWILLIE'S ELBOW PAD for Preventing the Hand  
Getting into the Mouth in STAPHALORAPHY or THUMB-SUCKING.

