

copy
TILDEN (G. H.)

with Dr. Fildes's Comments

SO-CALLED

MYCOSIS FONGOIDE.

BY

✓
GEORGE H. TILDEN, M.D.,

*Physician, Department of Diseases of the Skin, Boston City
Hospital.*

[*Reprinted from the Boston Medical and Surgical Journal
of October 22, 1885.*]



BOSTON :
CUPPLES, UPHAM & CO., PUBLISHERS,
Old Corner Book Store.
1885.



SO-CALLED MYCOSIS FONGOÏDE.¹

BY GEORGE H. TILDEN, M.D.,

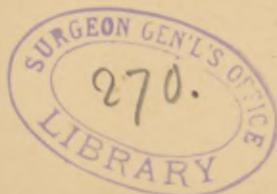Physician, Department of Diseases of the Skin, Boston City Hospital.

Syn., Beerschwamähnliche multiple Papillargeschwülste der Haut, Inflammatory fungoid neoplasm, Granuloma sarcomatodes cutis, Granuloma fungoides cutis, Sarcoma cutis, Lymphadénie cutanée.

ONE of the twigs on the topmost branch of Alibert's arborescent classification of cutaneous diseases bears the name Mycosis Fongoïde, employed by that Dermatologist to designate an uncommon affection of the skin, which has since been described by various authors under half a dozen different titles. An instance of this disease came under my observation at the Boston City Hospital, in August of last year, having been sent to me by Dr. Vincent Bowditch.

The patient was twenty-eight years of age, a man of robust build, whose family history gave no information of importance in connection with his malady, and whose condition had always been one of uninterrupted good health until his twenty-fifth year, when the first manifestations of the disease appeared. These consisted in the development of several small, red and desquamating spots, situated about the elbows and attended by intermittent attacks of pruritus, which affected principally the outer sides of the arms, and were a source of much annoyance. The skin, in general, however, retained its normal aspect for several months, at the end of which time there appeared, irregularly distributed over the face, abdomen and arms, many

¹ Read at the Annual Meeting of the American Dermatological Association, August 27, 1885.



erythematous spots and patches of various sizes and individually of a fugitive character, which were attended and followed by desquamation and severe itching, the latter being aggravated by any exposure of the skin to the air, by the influence of perspiration and by indulgence on the part of the patient in alcoholic liquors. According to his account, there was never anything like the formation of vesicles in connection with these lesions, which always retained their dry and scaly character.

This condition of the skin obtained with periods of remission and relapse, for about a year and a half, the general condition of the patient, meanwhile, remaining perfectly good. It was not until nearly two years after the beginning of the disease that there appeared several small cutaneous nodules of a red color, situated upon the left cheek and throat, the attention of the patient being first called to them by their interference with the act of shaving. Some of these nodules spontaneously disappeared and no others became manifest until two or three months later, when there appeared upon the inner and lower part of the right thigh, a small red papule, which increased with slow and constant growth until it was represented by a cutaneous tumor the size of an orange. In consistence this tumor was moderately firm and its upper surface was denuded of epidermis, of a dirty yellowish color, and exuded a thin fluid, which, upon exposure to the air, readily dried to a thin crust.

Shortly after the first appearance of this growth, there showed themselves in both groins, many papules of a like nature, which remained quiescent for several months, but eventually those in the left inguinal region developed with great rapidity, forming a mass of thickly crowded fungous excrescences of a reddish brown color, irregular shapes, lobulated and fissured in

appearance, and covered with epidermis, the largest of them being the size of an English walnut. During the six months previous to the time I first saw the patient, numerous lesions in the shape of papules of various sizes had appeared on different parts of the body, more abundantly in and about the axillæ and upon the neck and scalp than elsewhere, and many of them had developed into tubercles and some into tumors.

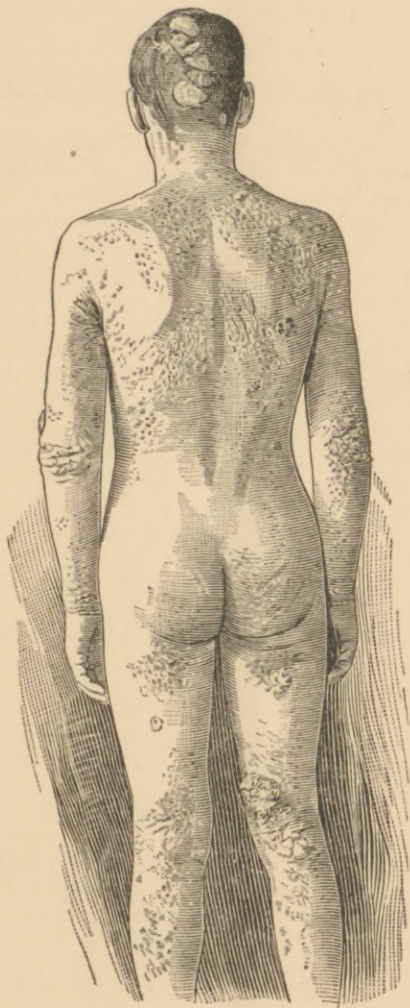
Upon the back of the head there was a large oblong patch of irregular outline, composed of flat tumors, measuring five by three inches in extent, and elevated nearly one-half an inch above the cutaneous level, the surface, uneven, fissured and covered for the most part with epidermis. The color of this patch was pale red and its consistence soft and doughy, although at the time of their first appearance, these tumors were, according to the patient's account, much harder than when I saw them. The scalp, with the exception of the area taken up by this group of tumors, was thickly covered with hair.

The forehead presented a collection of several large, flat, red papules, which were combining to form a large circular lesion of slight elevation and covered with epidermis, but of harder consistence than those upon the scalp. Upon the right cheek, near to the angle of the mouth, was a tumor, circular in outline, elevated nearly an inch above the level of the surrounding skin and somewhat larger than a silver half dollar. Its upper surface was slightly convex, deprived of epidermis, of a pink color with shadings of yellow, studded with numerous red points and covered with a thin glaze, which was easily removed by friction or by the influence of warmth and moisture, thus allowing the escape of a reddish fluid, which upon exposure to the air again dried to a thin crust. In consistence this tumor was firm, being much more dense than those

upon the scalp, the softness of which approached fluctuation.

Almost surrounding the neck of the patient was a broad collar of a dusky red color and nodulated surface, formed by the coalition of papules and tubercles, extending upwards, as far as the jaw, and below, draping itself with irregular outline upon the breast and shoulders. Just above the elbow joint, on the outer side of the left arm, was a moist tumor, similar to but smaller than the one upon the cheek, and immediately below it was a patch of combined papules and tubercles resembling those upon the neck. Upon the upper part of the back over the apex of the right scapula, on the right thigh below the fold of the nates, on the back of the left thigh and in the right popliteal space, were flattened tumors and groups of tubercles of various grades of consistence and covered with epidermis of a pale red color. There were many papules and tubercles isolated and in groups, in and about the axillæ and groins, while the abdomen, thighs and arms were covered with erythematous spots and patches, interspersed with papules and tubercles, which varied in size from that of a small pea to that of a filbert. None of these lesions were pedunculated or connected with the skin by a narrow neck, but all were attached by a base as large or larger than their tops. On the right thigh and in the left groin were tumors which have already been described.

Although they presented much diversity in size and appearance, these lesions began as erythematous spots from which were gradually developed papules, at first of small size, of pale red color and covered with smooth epidermis. Simple increase in the size of these lesions had transformed many of them into tubercles the size of a filbert, and several of them into veritable tumors. Wherever large numbers of such papules



This plate is merely intended to show in a general way, the distribution of the eruption on the back.

and tubercles came into contact with one another, they coalesced, forming patches of greater or less extent, irregular outline, with nodulated and fissured surface, and of a darker, more violaceous color than the primary and isolated nodules. For the most part these patches of conjoined lesions were covered with epidermis and only here and there were they excoriated and oozing. In none of the cutaneous lesions was there any retrograde change represented by the formation of pus or by deeply destructive ulceration, although the softness of some of the tumors suggested a fluid or semi-fluid contents, and one of them having been incised, discharged a dark red, almost black, grumous fluid. The large and protuberant tumors were luxuriant growths, from the surface of which, in some instances, the epidermis had been cast off, exposing to view the pathological tissue of which they were composed, and from some of these excoriated tumors there had been occasional hæmorrhage of moderate amount. They resembled very much in appearance, although they greatly exceeded in size, the moist, fungous, oozing tubercles, which are sometimes met with in connection with parasitic sycosis. When exposed to the air the thin, slightly bloody fluid exuded from their surface, dried to a thin crust, which was easily removed by friction or moisture. Decomposition of this fluid caused the patient to oftentimes emit a strong and peculiar odor, which resembled the united smells of sour cabbage and Parmesan cheese, being exceedingly offensive.

Within two years there had been apparent to the patient painless enlargement of the lymphatic glands in the groins and axillæ. The inguinal glands of both sides were much enlarged, having attained the size of large almonds, while along the outer edges of the pectorales muscles and behind the ears over the mastoid

processes, lymphatic glands were to be felt as large as good sized peas. This enlargement of the lymphatic glands was of indolent and painless nature and they were unattached to the surrounding tissues, forming subcutaneous tumors over which the skin was freely movable.

The patient suffered no pain, and the cutaneous lesions were not sensitive to pressure but were, however, attended with severe and widely spread itching, causing him to scratch vigorously, secondary lesions due to energetic use of the finger nails being manifest in several parts of the body. The patient was anæmic, the skin and mucous membranes being pale and the skin in general dry and rough. He complained of an unwonted feeling of weakness and easy loss of breath from slight exertion, together with violent beatings and palpitation of the heart, and the most trivial occurrence was oftentimes sufficient to throw him into a state of nervous excitement. There had been a loss of thirty pounds from the normal weight of one hundred and eighty pounds, but there was no emaciation, the patient's appetite was good, and there was fairly good performance of the digestive and excretory functions of the body. There were nowhere any cicatrices or atrophic spots on the skin, no cutaneous anæsthesia, no deafness nor failure of vision, and there had been no hæmorrhages from any of the mucous membranes, and no cough nor hæmoptysis. The result of the physical examination was as follows:

The ophthalmoscope detected nothing abnormal. The heart presented a systolic murmur heard over its base which was probably caused by anæmia, and there was sometimes irregular and rapid action of the organ, very likely due to the same cause.

* The lungs were normal and the liver and spleen were not enlarged. The urine was found to be nor-

mal. Examination of the blood by Dr. Gannett showed the number of red globules in a cubic millimeter to be 3,722,000, and the number of white corpuscles 23,333, that is, moderate anæmia together with increase in the number of white corpuscles, giving a ratio of one white corpuscle to one hundred and fifty-five red, the normal ratio being about one white to five hundred red.

August 6th. The patient entered the hospital on the surgical side in the service of Dr. G. W. Gay, who kindly turned the case over to me. He was placed in one of the hospital tents, given the tincture of the chloride of iron, extra diet and received subcutaneously once a day, four minims of Fowler's solution of arsenic. Under this treatment he gained fourteen pounds in weight and rapidly improved as to his general condition, although no noteworthy change took place in the state of the skin. The liberal use of an ointment containing one per cent. of carbolic acid gave him the most relief from the intolerable itching with which he was afflicted, more especially during the night. He left the hospital August 18th, but remained under observation until November.

August 30. Since leaving the hospital many of the erythematous spots which were upon the abdomen, thighs and arms had developed into papules.

September 5. Much of the diffuse erythematous redness about the chest had entirely disappeared, the restored whiteness of the skin contrasting in a striking manner with the red and violaceous color of the numerous papules and tubercles which were scattered about.

September 18. There was some improvement in the general condition, but no marked change on the part of the skin.

November 3. The patient complained of increasing

weakness and shortness of breath upon exertion, which constrained him to remain quiet. A most striking change had taken place in several of the cutaneous lesions. The large tumor on the cheek near the corner of the mouth had entirely disappeared and its original site was covered with epidermis, while the largest tumor of all, that upon the right thigh, was also covered with epidermis and had diminished in size by nearly one-third. There was excessive desquamation all over the body and the inner surface of the thighs had assumed an eczematous condition, oozing in places and covered with yellow, honey-like crusts. There was also remarkable alteration in the appearance of the face which within a week had become extensively infiltrated, the skin being of a dull copper color and the countenance one of swollen rigidity, with effacement of the lines of expression.

This was the last time I saw the patient, as he afterwards disappeared, probably on account of the fatal and hopeless prognosis which he received in reply to a request for information as to his prospects. I afterward heard indirectly that he died in March of the present year, that is, about three years and eight months after the beginning of the malady. Before death he had been affected with gradually increasing exhaustion and diarrhœa. Two of the smaller nodules were excised while he was in the City Hospital and given to Dr. W. W. Gannett, pathologist to the hospital for examination, and the following is his report of their histological structure:

“Report on two nodules sent for examination by Dr. G. H. Tilden, August 13, 1884.

“Both nodules were hardened in Müller’s fluid and later in strong alcohol. After the hardening process had been completed, the larger nodule measured 14 mm. in diameter, and was elevated 5 mm. above the

level of the surrounding skin; the smaller nodule had a transverse diameter of 10 mm. and an elevation of 5 mm. The epidermis was intact upon them.

"A series of vertical sections was made with the microtome and then examined, stained and unstained, in various media. Sections were also brushed.

"Sections of the smaller nodule showed the following appearances:—

"All the layers of the epidermis, from the horny layer to the rete, were intact and showed no variation from the normal.

"The superficial parts of the corium, including the papillæ, showed the presence of masses of small round cells arranged in groups of varying size and form, some being nearly circular, others irregular, others branching. In the centre of many of them a blood-vessel was to be made out. After brushing, these masses were found to be made up of a very delicate connective-tissue stroma, in the form of a fine mesh-work of connective-tissue fibres enclosing spaces. Each of these spaces enclosed one or two small round cells, having a large distinct nucleus with very little protoplasm about it.

"These cells correspond, morphologically, to lymph-corpuscles; their arrangement in the mesh described, makes this a cytogenous or lymphoid tissue.

"Where the above described patches were small and isolated the interlying connective-tissue of the corium showed nothing unusual. Where they were larger and in closer proximity, the intervening tissue of the corium was found to be converted into bundles of well-marked spindle-cells lying parallel to one another.

"In the deeper layers of the corium nothing remarkable was observed beyond a slight degree of round-cell infiltration of the adventitiæ of some of the blood-vessels. In the sub-cutaneous connective-tissue no appearances varying from the normal were discovered.

“Sections of the larger nodule showed appearances varying from those in the smaller nodule as follows:—

“The epidermis was intact.

“The papillæ on the peripheral parts of the nodule were distinct; those in the central part, however, were very small; the rete Malpighi presenting a wavy line. This change was undoubtedly due to the pressure of the growing tissue beneath.

“The upper half of the corium was at least three times the usual thickness and was wholly occupied by a cytogenous tissue like that described in connection with the smaller tumor.

“This large area of lymphoid tissue was subdivided into smaller ones by narrow bundles of parallel-lying spindle-cells, which by anastomosis formed a coarse reticulum, having much the same relation to the lymphoid tissue that the reticulum of a lymph-gland has to its follicles.

“In parts of the lymphoid tissue were to be seen numerous red blood-corpuscles which from their arrangement were evidently contained in vessels, that is, in capillaries.

“The lower half of the corium, that portion bordering on the subcutaneous connective-tissue, showed many patches of lymphoid tissue, large and small, and of the greatest variety of form. Where this tissue was not present in patches one could make out round-cell infiltration in the spaces between the larger connective-tissue bundles and elastic fibres.

“In the subcutaneous fat-tissue the adventitia of the blood-vessels showed here and there round-cell infiltration.

“The process in the larger nodule is evidently the same in character as in the smaller one, only more advanced. One has to do in both nodules with the development of a true lymphoid tissue in the corium; that is, a lymphoma.

"In neither of the nodules was any evidence of a necrotic or degenerative change discovered.

"Several months after the histological examination of the above specimens had been made, Rindfleisch and Auspitz announced their discovery, in lymphomata like the above, of micrococci, which they claim are the specific micro-organisms of this affection.

"Although the nodules now described had been hardened in Müller's fluid and alcohol and were consequently much less adapted than fresh specimens or those hardened in absolute alcohol for demonstrating micro-organisms, yet the attempt was made to find them.

"Thin microtome sections were stained in Ehrlich's gentian-violet solution, then treated by Gram's method and examined in benzol balsam with an Abbe illuminating apparatus and a Zeiss 1-12 oil-immersion, but with a negative result.

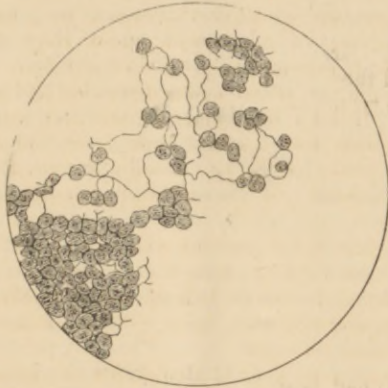
"Sections were kept in alcohol for two months, then stained with an aqueous solution of methyl-blue, partially decolorized in alcohol and examined as before, but with a like negative result.

"Of course no special weight is to be attached to negative evidence in specimens hardened as the above were."

W W. GANNETT, M.D.

The first description of this disease by Alibert, was published more than fifty years ago, and since that time a sufficient number of cases have been placed on record to furnish us with a good picture of its clinical aspects. There is no instance of the malady having occurred in more than one member of the same family, and as a rule, the sufferers therefrom have been healthy individuals, free from venereal disease and of good family history, so that the elements of heredity, contagion, and syphilis may be eliminated from consideration.

In addition to the case reported in this paper, I have been able to find accounts more or less complete, of twenty-nine instances of this malady. The deaths of



Portion of brushed section showing the fine network of connective tissue fibres present in the tumors, and the character of the cells of which the latter were composed. Drawn with the help of a camera lucida, Hartnack ocular iii, objective vii.

sixteen of these cases have been recorded, and the results of eleven autopsies have been published. One case of recovery is mentioned by Bazin as having taken place after an attack of migrating erysipelas, the patient remaining well for several years afterward, and the other cases were lost sight of, many of them in a condition which gave no hope of recovery.

Of these thirty instances of this disease, twenty-three occurred in males and seven in females, a remarkable disproportion in the matter of sex. The malady shows a tendency to develop in late adult life, more than one-half of the whole number of patients being forty years of age or over, at the time of the appearance of the dis-

ease. Of the remaining cases, one-half occurred in individuals of over thirty years of age, so that in only about one-quarter of all the cases, has the affection developed before the thirtieth year. The most advanced age at which the disease has been known to occur is sixty-eight years, which was the age of Demange's patient; and there is no instance of its having developed before the twentieth year, if we exclude the case of an infant, reported by Landouzy to the Soc. de Biologie, which case has not been included in the above collection on account of its doubtful and exceptional character. The duration of the disease is usually from two to four years, with the extremes of two, four and five months in the cases reported by Galliard, Naether, and Debove, respectively; and of eight years, in one of Hardy's cases, mentioned by Köbner, and twelve years, in a case of Bazin's, reported by Guerard and Lorda. In a remarkable instance of this malady published by Port, there had been for thirty years, beginning with the fifth year of life, an almost continual manifestation of various kinds of inflammatory, cutaneous lesions, and it was not until the patient's thirty-fifth year, about six months before his death, that the characteristic fungous excrescences of mycosis fongoïde began to show themselves.

The disease usually begins with the appearance on any and all parts of the body, of cutaneous lesions, which present no special characteristics by which they may be distinguished from changes which are met with in other and common affections of the skin. They may either be erythematous and urticarial in nature; may resemble eczema in being vesicular, moist, and covered with crusts, or may simulate psoriasis and lichen, by reason of their dry, infiltrated, and scaly character. At first, of a more localized and temporary nature, these lesions in the course of time, become more numerous

and more tenacious of place, attended with greater thickening of the skin, and accompanied by pruritus of extreme severity, which is the only subjective symptom of which the patients complain. There are, however, exceptions to the above general rule, and the affection may begin with the immediate appearance of the tumors which are peculiar to it. Such was the case in the instances of this affection published by Demange, Galliard and Debove, which seem to have been of more acute development and shorter duration than usual. In two of these three cases, the tumors appeared first upon the breast, in the other upon the head; and in two of them there took place very early in the malady, extensive infiltration of the skin of the face, giving to the countenance the so-called leonine expression, seen in leprosy and scleroderma. After a longer or shorter period of time, during which the patients suffer from these apparently inflammatory changes in the skin and the attendant pruritus, and during which time there not infrequently occurs temporary cessation of symptoms, there appear the strange growths which are peculiar to mycosis fungoïde, which foreshadow its fatal termination, and before the arrival of which, a diagnosis is impossible.

These tumors may arise either from preëxisting pathological patches in the skin, or they may develop in cutaneous regions which have hitherto been unaffected by disease. They consist in well-defined, rounded elevations of the skin, at first moderately firm and elastic in consistence, covered with smooth epidermis, of a pale red color, and their attachment to the skin by a pedicle or narrow neck is very exceptional. They remain confined to the skin and are always movable with it, even in the most advanced stage of their development. After they have attained a certain size, which, as in the present case, may be considerable, they remain un-

changed for a long period of time; but there takes place in some of them, sooner or later, a change which is one of the most notable features of the disease, namely, their disappearance by absorption, which may coincide with the appearance and growth of similar tumors in other parts of the body. When these growths have reached a large size, the epidermis may be cast off, as in several tumors of the present case, and superficial erosion occur; this process, however, not being inconsistent with the integrity of the tumors affected by it, which retain their size and shape, constituting the moist, fungous excrescences peculiar to mycosis fungoïde. This form, characterized by superficial loss of substance, is the more common variety of retrograde change, but there may also occur rapid and extensive destruction of these tumors, in which case they soften and open externally, thus forming large, suppurating, cutaneous ulcers.

In most of the cases, there has been painless enlargement of many of the lymphatic glands to a greater or less extent, and like the cutaneous tumors, this lymphatic enlargement may disappear by absorption. As a rule, the general condition of the patient is unaffected until after the appearance of the tumors; but eventually they become anæmic and debilitated, toward the end appear fever and diarrhœa, which together with increasing exhaustion, and in some cases, the formation of extensive and suppurating ulcers of the skin, close the scene, death generally taking place from marasmus.

Such is the clinical course of a malady, the pathological nature of which has given, and still offers sufficient opportunity for speculation, and the information furnished by the microscopic and post-mortem examinations remains to be considered. The results of microscopic examination of these tumors agree in showing the epidermal layers of the skin to be in a normal

condition, but sometimes thinner than usual; the papillæ flattened and broadened, but well defined in most cases; and an infiltration of the connective tissue of the corium with round, granular, nucleated cells, resembling leucocytes in appearance. These cells may be disposed in groups and gathered around the blood-vessels, an arrangement which is more apparent in sections taken from tumors before they have reached an advanced stage of development, in which latter event, the cellular infiltration may extend as deep as the subcutaneous fat-tissue, in some cases replacing entirely the normal structure of the corium. Blood-vessels, hair follicles, and cutaneous glands may sometimes be seen imbedded in this collection of cells, and their sheaths infiltrated with similar elements. Ranvier was the first to detect and call explicit attention to the existence in these tumors of delicate, connective-tissue fibres, anastomosing so as to enclose spaces nearly circular in form, in which lie the lymphoid cells, a structure such as was found by Dr. Gannett in the specimens from the present case, and which is considered to be characteristic of cytogenous tissue. The existence of this meshwork has been remarked by all of the French observers, and the fact that careful brushing of thin sections is necessary to determine its presence, may account for its having been overlooked by several investigators.

The most noteworthy fact to be derived from the autopsies is the negative one of the absence in any of the internal organs, of metastatic growths similar to those in the skin. The nearest approach to such a condition of things was found in the autopsies reported by Duhring and Galliard, in each of which was detected in the walls of the bladder, beneath the mucous membrane, round-cell infiltration resembling that in the skin, while in addition to this Galliard describes the

presence in the heart, lungs, liver and testicles, of small circumscribed collections of leucocytes, "apoplexies lymphatiques," the character of which was determined by the microscope. In one case only, that of Debove, were the tonsils the seat of ulceration, following an enlargement of these glands which had been apparent during life. In the great majority of cases there was found increase in size of the lymphatic glands in various parts of the body, a change which the microscope has shown to be of the nature of hyperplastic enlargement. In two instances some of these enlarged glands were found to contain small collections of pus and there was also purulent infiltration of the surrounding connective tissue. In only two cases was the spleen notably enlarged, in three cases it was slightly increased in size, and in the rest, of normal dimensions. The details with regard to changes in the other internal organs are slight and possess no special significance.

The theories with regard to the pathological nature of mycosis fungoïde are three in number:

- I. That it is generalized sarcoma of the skin.
- II. That the new formation of lymphoid tissue in the skin renders the disease a variety of pseudo-leukæmia.
- III. That the new growths are so-called infective granulomata of the skin, that is, young connective-tissue tumors associated with the presence of special microorganisms.

As to the first hypothesis, the weight of evidence is against the disease being sarcomatous in nature. The clinical course of the disease and the appearance of its cutaneous lesions are unlike the same factors in the cases of multiple sarcoma of the skin as described by Köbner and Kaposi. The curiously unstable character of the pathological products of mycosis fungoïde,

their comparatively rapid appearance and subsequent disappearance by absorption and by necrosis, are conditions not usually observed in connection with sarcomata which, generally speaking, are permanent and stable growths. The microscopic structure of the tumors of mycosis fungoïde is that of a lymphoid tissue rather than that of typical sarcoma, while the absence of so-called metastatic growths is the absence of what is one of the most marked tendencies of some varieties of sarcoma.

With regard to the affection being leukæmic or pseudo-leukæmic in nature, this theory is based solely upon the microscopic structure of the tumors of mycosis, more particularly upon the presence therein of a finely-meshed cell-holding reticulum, such as is found in lymphatic glands and in cytogenous tissue, generally so called. So little is known as to the true nature of leukæmia and pseudo-leukæmia that speculation as to their possible relationship with mycosis fungoïde is rather barren of definite conclusions, but it may be said that something more than a knowledge of the minute structure of pathological products at any one stage of their development, is necessary to render evident their pathogenesis. In none of the very few cases of mycosis fungoïde, in which the blood has been examined, has there been found sufficient increase in the number of the white corpuscles to constitute typical leukæmia, while in only two of the autopsies has there been found notable enlargement of the spleen, an enlargement which together with that of the lymphatic glands is an essential feature in pseudo-leukæmia.

A remarkable case, which demands attention in this connection, has recently been published by Kaposi, as a hitherto unrecognized form of disease, under the name "Lympho-dermia perniciosa." Up to a certain point the features of this case bear some likeness to

those of mycosis fungoïde. There was the same preliminary manifestation of chronic inflammatory changes in the skin attended with pruritus and lasting a year, followed by the development of numerous cutaneous tumors and enlargement of the lymphatic glands. The tumors in this instance, however, did not disappear by absorption or form the typical, moist, fungous excrescences of mycosis fungoïde, but simply softened, opened and formed suppurating ulcers.

In addition to the above phenomena, these ultimately developed undoubted evidence of leukæmia, which was confirmed by the autopsy.

There was marked increase in the number of the white blood corpuscles, the spleen was found after death to be four times its normal size, and nodules were detected in the lungs, pleura and medullary cavities of the bones, which together with the cutaneous lesions were shown by the microscope to be composed of cytogenous tissue. The only other instance in which the development of lymphoid tumors in the skin accompanied the course of typical leukæmia was in a case reported by Biesiedeck, in which case there is no mention of retrograde change in any of the tumors, the appearance of which was preceded by the development of the general leukæmic condition, and not as in Kaposi's case, followed by it.

Within the year Rindfleisch and Auspitz have each described the existence in the pathological products of mycosis fungoïde, of microorganisms, the presence of which is considered characteristic of the so-called infective granulomata, represented by tubercle, lupus, leprosy, rhinoscleroma, and most recently of all, syphilis. Rindfleisch describes them as streptococci, which he expressly states are to be seen *only* within the blood vessels, the plugging of whose calibre by these microorganisms is sufficient in his opinion to give rise

to the cellular infiltration of the surrounding tissues, while their removal by the force of the blood current, is supposed to account for the peculiar disappearance by absorption of the lesions of mycosis fongoïde. Auspitz, on the other hand, using the same methods of staining, states that there exist large numbers of micrococci in the pathological tissue outside of the blood vessels. It is impossible to avoid the suspicion that the presence of these micrococci, mentioned by Auspitz, is simply accidental. There is nothing to be said concerning the latest theory, except to remark the discrepancy between these observations, and bearing in mind the prevalent rage for the detection of microorganisms, to await further developments. It is possible that these observations point in the wrong direction; it is not impossible that therein may eventually be found the answer to the naïve question of Demange with regard to mycosis fongoïde. "*N'y a-t-il donc pas là quelque chose de spécial qui nous échappe encore ?*"

LITERATURE OF THE SUBJECT.

- Alibert. — Monographie des Dermatoses. Tome ii, p. 423. Paris, 1835.
- Hardy. — Maladies de la peau. 1862.
- Bazin. — Leçons théoriques et cliniques sur les affections cutanées artificielles, etc. p. 375. Paris, 1862.
- Lorda. — Mycosis fongoïdes accompagnés d'une eruption généralisée, par plaques rougeâtres. Gaz. des hopitaux. No 61, 1862.
- Guerard. — Du mycosis fongoïde généralisé. Paris, 1863.
- Köbner. — " Ueber Beerschwamähnliche multiple Papillargeschwülste der Haut." Klinische und experimentelle Mittheilungen aus der Dermatologie und Syphilidologie. p. 37. Erlangen, 1864.
- Virchow. — Die Krankhaften Geschwülste. p. 538. 1864-5.
- Kaposi. — " Ueber die sogenannte Framboesia." Archiv für Dermat. und Syph. 1869.
- Gillot. — Etude sur une affection de la peau, décrite sous le nom de mycosis fongoïde. Thèse de doctorat. Paris, 1869.
- Landouzy. — Mémoires de la Soc. de Biologie. Dec., 1871. p. 184.
- Charpy. — De la nature du lichen hypertrophicus. Annales de Derm. et de Syph. Vol. iv, p. 27. 1872-73.
- Debove. — Société Anatomique, p. 420. Oct., 1872.
- Ranvier. — Bull. de la Soc. Anatomique, p. 477. Paris, 1872.
- Demange. — Du Mycosis fongoïde ou Lymphadénie cutanée. Annales de Derm. et de Syph. No. 2, p. 121. 1873-1874.
- Port. — Ein Fall von multiple Sarcombildung der Haut unter dem Bilde der Mycosis (Alibert) Deutsches Archiv für Klinische Med. Band xii. s. 134. 1874.
- Hebra. — Artztliches Bericht des K. K. Allg. Krankenhauses zu Wien vom Jahre, 1874, s. 213. Wien, 1875.
- Hebra. — Archiv für Derm. und Syph. 1875.
- Biesiadecki. — " Ueber einen Fall von leukämischen Tumoren in der Haut " Mittheil. des Ver. der Aerzte in Nieder-Oesterr. 1875-1876. Band ii, p. 30.
- Bazin. — " Mycosis " Dictionnaire Encyclopédique des sciences Médicales. 2m Série, Tome xi. 1876.
- Tanturini. — " Tre casi clinici nuovi di mycosis fongoïdes di Alibert " Il Morgagni. 1877. Nos. 1 and 2, p. 1 and p. 81.
- Brachet. — " Observation de mycosis fongoïde " Mem. de Med. et de chir. Militaires. 3d Série, vol. 33, p. 626. 1877.
- Geber. — " Ueber eine entzündliche fungöse Geschwulstform der Haut." Deutsches Archiv für Klin. Med. Band xxi, Heft, 2 w. 3 März. 1878.
- Duhring. — " A case of inflammatory fungoid neoplasm." Archives of Dermatology. Jan., 1879 and Jan., 1880.
- Fabre. — " Des manifestations cutanées de lymphadénie cutanées à propos d'un cas de mycosis fongoïde." Bulletin de l'acad. Med. No. 44, p. 1135. Nov., 1879.

- Hillaret. — Un cas mycosis fongoïde debutant pas un urticaire. Acad. de Med. Paris, Dec. 7, 1880.
- Besnier. — Annales de Derm. and de Syph. Tome ii, No. 4, p. 637. Oct 25, 1881. "Sur un cas de tumeurs de la peau, etc."
- Vidal. — Lymphadénie cutanée, Transactions of the International Medical Congress. London, 1881.
- Hillaret. — Ditto.
- Oscar Simon. — Ditto.
- De Amiciis. — Contribuzoine clinica ed Anatomico-patologica allo studio del Dermo-linfoadenoma fungoïde micosi, fungoïde di Alibert Naples. Tipografia Trani, strada Medina, 25. 1882. Ref. in Annales de Derm. et de Syph. Tome iii, No. 7, p. 452. 1882
- Galliard. — "Contribution a l'étude de la lymphadénie cutanée." Annales de Derm. et de Syph. Tome iii, No. 3, p. 145 1882.
- Mannino. — "Sur le Mycosis Fungoïde d'Alibert Giorn. Ital. delle mal. vener. p. 348. 1882.
- Naether — "Granuloma sarcomatodes cutis" Deutsches Archiv für Klin. Med. 1883, xxxiii. 470-584.
- Köbner. — "Beerschwamähnliche multiplen Papillargeschulste der Haut" Berlin Klin. Wochenschrift. No. 27, p. 417. 1883.
- Hyde. — Study of a case of multiple sarcoma of the skin. Edinburgh Medical Journal 1883-1884. xxix, 592-606.
- Auspitz. — Vierteljahreschrift für Derm. and Syph. 1885. Heft. 1, p. 123
- Rindfleisch. — Deutsche Med. Wochenschrift. No. 15, p. 233. 1885.
- Kaposi — Ueber eine neue Form von Hautkrankheit, Lymphodermia perniciosa, etc. Separat-abdruck aus der Med. Jahrbücher der K.K. Gesellschaft der Aertze in Wien, 1885.

