

Souchon, (Ed.)

REPRINT

OF

Papers from the TRANSACTIONS of the Texas State Medical Association, entitled

RECAPITULATION OF SURGICAL CASES

Treated and Operated on in Wards 2 to 8 and 10, Charity Hospital, of New Orleans, La., from October 1, 1885, to March 31, 1886, with Remarks.

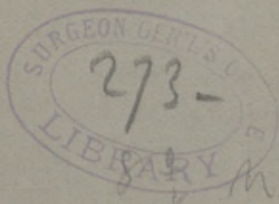and

A CASE OF RESECTION OF THE SUPERIOR MAXILLARY BONE, FOR CANCER.

By EDMOND SOUCHON, M. D., NEW ORLEANS, LA.,

Professor of Anatomy and of Clinical Surgery, Tulane University of La., in charge of Wards.

Read before the TEXAS STATE MEDICAL ASSOCIATION, at its meeting at Dallas, Texas, April 27, 28, 29 and 30, 1886.



Con Am: Re


35- -

RECAPITULATION OF SURGICAL CASES.

Treated and Operated on in Wards 2 to 8 and 10, Charity
Hospital, of New Orleans, La., from October 1,
1885, to March 31, 1886, with Remarks.

By EDMOND SOUCHON, M. D., NEW ORLEANS, LA.
*Professor of Anatomy and of Clinical Surgery, Tulane
University of La., in charge of Wards.*

The total number of patients, including the out-door patients, treated in those wards during the time mentioned, was 471—all accessible to the students of the medical class, who were not only allowed, but pressed to examine them for themselves, and follow them throughout. Of that number, 65 underwent more or less serious operations—all performed before the class in the operating amphitheatre, after explanation of the cases.



The following are the diseases treated:

Abscesses, sundries, 10; abscess (acute) of mammary gland in male, 1; abscess (chronic), 2.

Adenitis of various glands, 16; adenitis of submaxillary, 2.

Adenoma of wrist, 1; ankylosis of elbow, following dislocation, 1; aneurism of femoral artery, 1.

Arthritis of elbow, 1; arthritis of knee-joint, 1.

Bite, of nose, 1; buboes, 17, burns, 11.

Cancer of tongue, 1; cancer of superior maxilla, 1.

Cancer of rectum, 1; cancer of elbow-joint, 1.

Cancer of penis, 1; cancer of lower lip (epithelioma), 1.

Cancer of cheek (epithelioma), 1; carbuncles, 2.

Chancres, 3; chancroids, 11; concussion of the brain, 2.

Conjunctivitis, 1; contusions, 24; contusion of epigastrium, 1.

Cystitis, chronic, 4; circumcision, 2.

Deformity of toes, 1; dislocation of elbow, 1.

Dislocation of outer extremity of clavicle, 1.

Eczema, 4; erysipelas, 6.

Fracture of base of skull, 4; fracture of inferior maxilla, 5.

Fracture of superior maxilla (alveolar process), 1; fracture of humerus, 1.

Fracture of radius and ulna, 5; fracture of radius alone, 2.

Fracture of radius (the head), 1; fracture of ribs, 5.

- Fracture of femur, 2 ; fracture of tibia and fibula, 6.
Fracture of tibia alone, 1 ; Pott's fracture, 1.
Frost bite of fingers and toes, 6 ; fistula in ano, 11.
Gonorrhœa, 15.
Hernia, reducible inguinal, 2 ; hernia, irreducible inguinal, 1.
Hemorrhoids, 12 ; herpes, 1 ; hip-joint disease, 1.
Hydrocele, 1.
Impetigo, 1.
Keloid tumor of ear, 1.
Lymphadenoma of parotid region, 1.
Mercurial salivation, 1 ; medical cases, 4.
Necrosis of inferior maxilla, 1 ; necrosis of bones of forearm, 1.
Necrosis of phalanges, 1.
Necrosis of ischium, 1.
Necrosis of femur (invaginated), 1.
Necrosis of tibia, 1.
Necrosis of tarsal bones, 1.
Necrosis of os calcis, 1.
Needles, splinters, etc., in body, 3.
Onanism, 1 ; orchitis, 8 ; otitis, 1 ; ozena, 1.
Paronychia, 6 ; perineal infiltration of urine, 6.
Phlebitis (long saphena and femoral), 1.
Phlegmon of the hand, 5 ; Pott's disease, 1.
Prostate, hypertrophy, 1.
Rheumatism (acute), 1.
Rheumatism (chronic), 1.
Sprain of elbow, 2 ; sprain of wrist, 3.

- Sprain of knee joint, 5 ; sprain of ankle, 4.
Stone in the bladder, 1 ; stricture of urethra, 8.
Syphilis (secondary), 10 ; syphilis (tertiary), 7.
Tonsillitis, 1.
Ulcers (indolent), 20 ; ulcers, serpiginous, 2.
Ulcers, syphilitic, 3 ; ulcers, varicose, 27.
Ulcerations of the mouth, 3 ; undiagnosed cases, 14.
Varicose vein, 2 ; varicocele, 1.
Wounds, abdomen (penetrating), 1. (Cured).
Wounds, thorax (penetrating), 1. (Cured).
Wounds, contused and lacerated, 50 ; (1 died of erysipelas).
Wounds, contused and lacerated, of scalp, 1. (Cured).
Wounds, incised, 28.
Wounds, punctured, 5.
Wounds, gunshot, nose, 1 ; inferior maxilla, 1 ; nose and eye, 1 ; hand, 3 ; neck and shoulder, 1 ; sundries, 3.
Total, 471.
The following are the operations performed :
Abscesses in dangerous regions, 4 ; axillary region, 1 ; illac fossa, 1 ; liver, 1 ; submaxillary region, 2.
Autoplasty of face, 1.
Epithelioma of lower lip, 1.
Fistula in ano, 8.
Gunshot wound of leg—erysipelas, 1.
Grafting, 1.
Hemorrhoids, 5.
Hernia, strangulated, 1.
Hydrocele, 3.

Lithotripsy, 1.

Necrosis of bone, 5. Lower maxillary, 1; foot, 1; tibia, 1; thigh, 2.

Perineal operations, 11, for chronic urinary fistula, 1; for infiltration of urine, 10.

Tumors, 3. Lymphadenoma of parotid, 1; adenoma of wrist, 1; adenoma of testicle, 1.

Total number of operations, 65.

The following are the points of interest connected with these operations :

The Abscess in the Axillary Space had originated in one of the glands, and was as large as an ordinary hen's egg. It presented a deep and vague sense of fluctuation; but the hypodermic syringe confirmed the presence of pus. The patient was placed slightly under the influence of chloroform—just enough to deaden the pain, since one thrust of the knife, only, was contemplated. To avoid injuring any of the large vessels and nerves of the space, the arm was placed at right angles with the body; the back of the knife was turned against the vessels, the blade parallel with these vessels, and the point over the abscess, directed towards the walls of the chest. One firm and quick stroke drove the knife through about one inch of tissue, of which one-third was formed by the substance of the gland not yet destroyed. About one tablespoonful of pus escaped. At this moment, took place an incident which might have proved very dangerous to those situated around the operating table. No sooner had the knife penetrated into

the flesh, than the patient gave such an unexpected start that he got loose from those who were holding him down, and, jumping to his feet, in a wild, excited and unconscious manner, rushed to the case of instruments, which was near by, and had half opened a drawer, and was about seizing one of the instruments, when one of the students bravely caught him. He very soon quieted down. It lasted, at most, fifteen seconds. The next day, in the ward, he told us that he had just come from the grinding on a sugar plantation, where a number of Chinese were employed; that he was always quarrelling with them; and that, as he was going under chloroform, the students around him became gradually transformed, in his mind, into Chinese; and that, as the knife penetrated him, though he felt no pain, he was satisfied that it was one of the Chinese who had stabbed him. Hence the rush he made to what he thought was his armory, for a weapon to defend himself. He made a good recovery.

The Abscess of the Left Iliac Fossa was transferred from a medical ward. It was remarkable from the vast amount of swelling and œdema it created all around, the length of time the pus was in forming, and the small quantity it presented, when at last detected. The swelling and pain were all over the iliac region; also in the lumbar, and, later, in the gluteal region. There was a great deal of œdema of the whole of the left limb, and corresponding part of the abdominal walls on the left, and a small amount of serous effusion in the peritoneum.

Four times, at least, at a week's interval, was the patient placed under the influence of chloroform; and a good, long, and pretty large, exploring hypodermic needle, with syringe, inserted at all suspicious places—above Poupart's ligament, below it, along the inside of the iliac crest, behind it—but all in vain. However, at the last sitting, the needle struck pus in the ilio-costal space, near to the ilium. The knife was then driven along the track of the needle, and, at a depth of two inches and a half, struck the focus of the abscess. Very little pus flowed through the opening, however, which was enlarged to the extent of one inch and a half, and kept open. The patient's strength had been so reduced, by pain and fever, that he derived but some relief from his pain, and died within the following ten days. Upon making a post-mortem examination, it was found that the whole iliac muscle, together with the pelvic portion of the psoas, were thoroughly infiltrated with lymph. There was but a small pus cavity, about the size of a large hen's egg, situated at the terminal portion of the crest of the ilium, between it and the last lumbar vertebra. The plastic lymph also surrounded the iliac vessels, and so compressed the vein as to diminish its caliber to about one-third. This was the cause of œdema of the limb. There was a tract of pus about one-third of an inch in diameter, which went into the true pelvis, and, following the course of the gluteal and ischiatic vessels and nerves, was reaching the buttock.

The Abscess of the Liver was also transferred from

a medical ward. The abscess was an acute one, when it had been diagnosed, and had been located to the right of the median line. Upon placing the patient gently under the influence of chloroform, we could examine him more thoroughly. There was no special bulging on the right of the median line, and, by percussion, a clear sound was returned. We thought it useless to thrust the hypodermic needle and syringe there, since we believed that no abscess, of such a size as to require and justify surgical interference, could exist, without some bulging and some dullness upon percussion. Considering the great frequency of abscess of the right lobe, we made two punctures in that region, but no pus was struck. The case ran a rapid course, and the patient died within some ten days. The post-mortem revealed an abscess, of the size of a hen's egg, situated in the *left lobe* of the liver, to the *left*, therefore, of the median line; where the patient had never complained of any pain in particular, at any time. There was, also, a good deal of peritonitis in the epigastric and both hypochondriac regions. As operations for acute abscess are of little good, we did not much regret the anomalous symptoms which led us off the track.

The Abscesses of the Sub-Maxillary Region were situated in the lymphatic glands, lying over the salivary gland, and were due to bad teeth. They were in their second stage, but the inflammation was threatening to invade all that side of the neck; they were causing much pain, and determined a great deal of difficulty in

swallowing, and of feeding properly. There was no evidence of fluctuation; but there was so much redness and œdema over all that region that it was evident there must be pus, deeply seated, and that we were justified in using the hypodermic needle and syringe. It struck pus at the depth of one inch and a quarter. The knife was then introduced, making an opening of about a quarter of an inch. About one drachm of pus was liberated, and the disease was checked. One of those cases gave us some annoyance, for a moment, in this, that, after the needle had shown the presence of pus, yet, when the knife was driven in to the depth indicated by the needle, no pus came. As the opening was over the internal and external carotids, just where they are crossed by the large thyroid and lingual veins, opening into the internal jugular, which itself lies there, on the outside, and, also, somewhat over the arteries, we dared not cut any deeper. We then used the end of a blunt grooved director, and, by careful, gradual working, finally broke what little lamina of tissue separated the terminal end of the incision from the focus of the abscess; this barely contained more than half a teaspoonful of thick pus. It was then very plainly visible that the throbbing of the deeply seated vessels was communicated to the blood on the tract made by the knife.

The Case of Anchylosis of the Elbow Joint was due to organized plastic adhesions, which had taken place between the articular surfaces, after the reduction of the dislocation of that joint, the limb having been al-

lowed to go too long without being exercised. The case was rendered much worse by the fact that the physician who attended him at the time made the too often repeated mistake of placing the limb in the extended position, instead of placing it in the not quite semi-flexed position. The patient being placed under the influence of chloroform, the forearm was gradually, gently, slowly and most carefully flexed upon the arm. As this was being done, the adhesions were felt and heard giving way; as we neared the right angle position, though, the skin over the olecranon became so tense that, lest we might rupture it, we desisted from further efforts. The arm was bandaged in that position, and cold water applied to the parts. A very moderate amount of swelling followed, but the patient complained of a great deal of pain. On the third day, however, this subsided, and the joint was exercised with care. At the end of ten days, he was sent back home, after being instructed how to exercise his limb; of course, he was taught how to bend it, more and more, as the skin over the olecranon permitted it.

The Case of Facial Autoplasty was necessitated by a gunshot wound, which had destroyed the left half of the lower maxilla, horizontal as well as ascending ramus, and the tissues above and below the bone; leaving there a gap, extending from the middle line to the ear, and from the alveolar process of the superior maxilla to within a half inch of the hyoid bone at its greatest height; it measured about three inches and a quarter in

length, and about two and a quarter inches vertically. The skin over the cheek and over the neck was movable enough, and it was thought that, by dissecting it, it would slide, and the edges come in contact. Dr. Miles, the house surgeon, kindly examined him, at my request, and encouraged me to operate. Of course, all this could only be determined, positively, by actually performing the operation. No particular difficulty was experienced in approximating the edges at the two extremities of the gap; but, at the center, though the edges did meet, there was so much tension on the sutures, and the edges of the flaps of skin were so thin, that no union was expected there, and it was evident that it would require a second plastic operation to close the gap, more or less large, which was going to be there. The patient did well for the first twenty-four hours; but, after that, the edges of the wound showed signs of erysipelas, which extended over all that side of his face and neck, bursting most of the sutures, and destroying a good deal of the union which had already taken place. He was immediately transferred into the erysipelalous ward. Ten days afterwards, the erysipelas had disappeared, leaving the gap, however, smaller, since about an inch and a half of union had persisted at the angle of the mouth. He says he finds some benefit from that much of union. He was then returned into Ward 8; but he had scarcely been there a few days when the erysipelas showed itself again, and again he was transferred to the erysipelalous ward. We will

attempt nothing more on him until fall, giving his system time to improve. I rather think it may be necessary, in this case, to resect, on the right side, the horizontal ramus to the anterior border of the masseter, so as to have all the tissues as loose, almost, as they are in cases of resection of the horizontal portion of the bone; and thus be enabled to bring the pared edges together thoroughly, and without straining the sutures. As far as he is concerned, he will consent to anything to close that gap.

The Removal of the Left Eye-ball was necessitated by a gunshot wound, which had struck the patient from the right side, fracturing the bridge of the nose, laying open the nasal cavities, the lachrymal sac, the frontal sinus, and destroying the left lid and eye-ball. The pieces of bone were removed as they became detached, and the remnants of the eye might have been detached by nature, but considering that the other eye might become sympathetically attacked, it was thought best to remove it. This was done with a few clips of strong, slightly curved scissors. the hemorrhage was rather slight, and was easily controlled with lint and pressure. A small piece of the outer part of the upper lid, about an inch square, was hanging from the first by a small pedicle; it was preciousely preserved, so as to assist in the closing of the big gap. It had to be stitched up repeatedly, and gave some little trouble because the small portion of the orbicular muscle intering into its structure would constantly contract and pull on the

sutures, and cause them to cut through. In course of time, it is almost incredible how the bottom of that deep gap has been filled by granulation so as to raise it on a level with the surface of the sound eye. It has also very much contracted around the margins.

The Case of the Resection of the Superior Maxilla and of the Eye-ball was rendered imperative by the development of a sarcomatous growth. It is the subject of a separate paper.

The Amputation of the Arm was performed for a spindle-cell cancer of the lower extremity of the left humerus. It was as large as the head of an eight year-old child, and was ulcerating. The infiltration extended higher up than the deltoid insertion. The whole of the axilla was filled with engorged cancerous lymphatic glands. The Esmarch bandage was applied, and the arm amputated above the deltoid insertion, in healthy tissues. As soon as the vessels were secured, and the constricting band removed, an incision was then made, about two and a half inches long, in the axilla, over the most salient of the glands; and, as soon as the gland itself was struck, the knife was dropped, and the glands were enucleated, and torn out with the fingers. Of course, they proved to be larger than might have been judged from examining them through the skin, the first, and largest, being about the size of a small hen's egg. Of course, again, as soon as the first ones were removed, still more, though smaller, were found, and in greater number than would be expected by one who had not

“been there before.” The more we removed, the higher we penetrated into the axillary space, and the closer to the vein and artery we got. Fortunately, none of the glands were attached to any of those dangerous structures. All were removed that could be felt, whether diseased or not, and however small. The wound in the axilla filled up almost altogether within a few days, and far faster than that of the amputation. The patient, upon leaving the hospital, was particularly instructed to report occasionally, so as to have the axilla explored, and have the glands removed at once, as soon as they can be even suspected.

The Hand was Amputated for a lacerated wound. The thumb and little finger were preserved, and the bones sawed through were the second, third and fourth metacarpal bones, through their upper third. There was a good deal of trouble in securing the small vessels, and nothing short of plugging and pressure by bandage controlled the hemorrhage after the operation. The next day, the pressure was removed, so as not to endanger the vitality of the flaps, and the blood started during the day. In spite of all efforts, and the use of styptics, the hemorrhage could not be controlled, and both the radial and the ulnar had to be ligated by Dr. Jamison, then the assistant house surgeon. Professor Richardson thought the case one of hæmophilia, to some extent, at least.

Of the Two Amputations of the Thigh, one was performed for painful stump. He had been first operated

upon twenty years previously, and had always suffered more or less from the stump ; but, within the last two years, the pain had increased very much, and he was clamorous for relief. The operation afforded it.

The other amputation of the thigh was on account of too short a flap, which ulcerated. Hence the advice given to the class to make long flaps, especially near joints.

Of the Three Foot Amputations, the only interesting one is the one performed on a colored boy, for frost-bite of the toes, extending to the head of the metatarsal bones. The line of demarcation had formed. From apprehension of sloughing, from the appearance of the parts, long flaps were dissected and the bones sawed through below the upper extremities of the metatarsal bones. After the removal of the Esmarch, the blood returned with great slowness into the flaps, and it was thick, black blood. It was quite a while, perhaps three or four minutes, before the blood reached the end of the flap ; quite in contrast with what usually takes place in ordinary cases. This condition of the circulation caused me much apprehension for the safety of the flaps, and so much the more so, as, recently, in somewhat similar case, in private practice with Dr. J. H. Lewis, the flaps had sloughed to such an extent that a second amputation had to be performed. In order to prevent any similar thing, if possible, in this case, I decided to make provision for the sloughing, which seemed imminent, and I removed another inch or

two of the bone. Dr. Becton, President of the Texas State Medical Association, and Dr. R. Matas, my chief of clinic, were present, and both entertained the same apprehensions. In operating through the foot, I made no attempt to disarticulate and perform either Lisfranc's or Chopart's operation; but simply sawed the bones through transversely between the two lines. Any pieces of bone, too thin and too loose to have a chance to heal, were then removed. Thus, I considered the tarsus as a single solid bone, and sawed it through, thereby simplifying the operation very much. The flaps were brought together gently, without tying the sutures tight, or applying the bandage tightly in dressing it. Some little sloughing occurred at the outer part of the flaps, but, fortunately, was soon limited. The little patient, finally, made a good recovery, in spite of an attack of sub-chronic diarrhœa, which, at one time, reduced him very low.

Such a course, in such cases, is supported by Gross, Agnew, Holmes and Erichsen. Those standard authorities do not treat of frost-bite at length; but consider it as a species of mortification from local cause, and, under the head of amputation in cases of mortification from local causes, they all say that, as soon as the line of demarcation is established, amputation should be performed. However, Gassalin and Denouvilliers and Prof. T. G. Richardson, in regard to frost-bite of the toes and metatarsus, take a decided stand against operating, thinking that, by leaving the process of elimi-

nation, even to the elimination of the bones, to nature, less loss of tissue ensues than has to be sacrificed by amputation, though it may require three or four weeks for nature to eliminate the mortified parts. There is now in one of Prof. Richardson's wards, a Negro patient with frost-bite of the toes, not extending beyond the first phalanges, who has been there four months, and is not yet well. In the case of the amputated boy, it was the condition of the soft parts remaining attached to the foot that called, we thought, for extensive flaps, to save him from a second amputation; but under ordinary circumstances, flaps of half the length would have been plenty long. The difference between the two courses would be the loss of about one inch of foot and a gain of two months or more of suppuration; whereas, by non-interference, there would have been a gain of about one inch of foot at the expense of two months or more of suppuration. The choice of the surgeon lies between the two.

The Case of Epithelioma of the Lower Lip occurred in a young man, and such occurrences are so rare in young subjects, that a small particle of the tumor was examined under the microscope, so as to eliminate all slim possibility of removing a syphilitic ulcer for an epithelioma.

Of the Eight Anal Fistulas, two were superficial, and did not extend to the upper border of the sphincter-muscle. After introducing a grooved director through the tract and internal opening, some cocaine was injected

into the bridge of tissues to be divided, and the cutting was done without any pain at all. In one case, where the fistula extended too high up to be able to so thoroughly overcome the spasmodic contraction of the muscle as to reach the upper part of the fistula, the incision of the first was quite painful; whereas, the incision of the lower part, which had been well injected, was cut through without the patient noticing it. One of these fistulæ extended as high as three inches into the rectum. The division of the parts was followed by much bleeding, but this was checked by systematic plugging of the tract, then of the rectum, and by the application of a T bandage over lint and folded towels, placed over the anus and perineum. This case is to this day troubled with some incontinence of fœcal matter when these are fluid, or soft, and has to keep his bowels costive. If this persists, we may, later, attempt some surgical operation to remedy this. Another interesting one of these fistulæ, is one with a tract of some seven inches long, extending from the side of the rectum, through the perineum, into the root of the scrotum. It was incised throughout, and its whole course explored with care, to find any opening leading into the rectum. None was found, and the tract being superficial, it was thought that this was an exception to the rule, which wants every tract around the anus to communicate with the gut. The exception was only apparent, though, for three weeks later, an opening showed itself at the posterior extremity of the tract, running into the rec-

tum. The regular operation for fistula in ano was then performed, and the patient finally got well.

One Gunshot Wound of the Leg was attacked by phlegmonous erysipelas, which destroyed the subcutaneous and subaponeurotic areolar tissue of the anterior region of the right leg. The muscles, also, of the anterior region were partly destroyed, and there existed a long cavity, bounded by the tibia and fibula, laterally, the inter-osseous membrane behind, and the strong fascia of the leg in front, all unyielding structures, which kept the walls of the cavity from coming together and uniting. Upon making an incision from the upper third of the leg to the foot, through the flesh of the leg, under the skin which laid over it, the bottom of the cavity was exposed. The outer surface of the tibia was partly denuded, but being still white and smooth, we did not scrape it. The healing proceeded rapidly, but the patient left the hospital too soon to enable us to judge how much use of the injured muscles he recovered.

The Case of Grafting was performed on an old man of 63, weak and debilitated, who, after a bruise of his right leg, was taken with erysipelas. It terminated by sloughing of the skin; but a narrow strip of skin of about an inch in breadth remained on the anterior and posterior aspects of the leg, extending from the knee to the ankle. At first sight, when he was admitted into the hospital, the limb looked so bad and ugly, the first impression was that amputation was necessary. Fortunately, though, the fascia was not broken through,

and the subaponeurotic structures were uninjured. After a few days, the sloughs dropped off, and were clipped off, and the parts began to look more promising. The general condition, also, of the patient improved under the influence of rest and good food and tonics. The parts became covered with granulations, the strips of skin stretched, and the loss of substance soon seemed to be half repaired. But there it slacked, and at places, stopped entirely. It was then that grafting was resorted to. Some eight small pieces of cuticle, not extending deeper than the mucous layer of the skin, were cut from the thigh, by making a small fold with the forceps, and cutting the base of the fold with sharp scissors. Each piece was carefully unraveled, and its cut surface laid on the surface of the granulations. After they were all in position, they were covered by a piece of dry lint, and a moderately tight bandage applied. This was removed some three days afterward, when it was found that all but one or two of the grafts had taken. The healing of the parts was much accelerated by this procedure, which was repeated two or three times by the expert resident student, Mr. J. F. Schmittle.

Of the several Cases of Hemorrhoids, three were injected with a solution of equal proportions of glycerine and carbolic acid. The process proved almost as painful as the ligature, both as regards the injection and the pain which followed, for twenty-four hours, or more. The cases, however, finally got rid of their trouble.

The only Case of Strangulated Inguinal Hernia was

ably operated on, when brought in, during the night, by the assistant house surgeon, Dr. Parkham; but it was so far gone that he died within thirty-six hours.

All the Cases of Hydrocele of the Vaginal Tunic were operated on by incision and packing of the cavity thoroughly with carbolized lint. A good deal of swelling of the testicle followed, but it soon subsided, and the cases got well without any particular trouble.

The Case of Stone in the Bladder was presented by an old man of 58 or 59. It was easily diagnosed. The urethra was free, and easily dilated; the bladder and kidneys unaffected, and the general condition good. We operated by lithontripsy, after Bigelow's method. Though the hospital is provided with Bigelow's lithonriptor, we prefer to use the fenestrated lithonriptor, because it presents a *whole* opening through the female blade, whereas, Bigelow's presents but a small opening, thereby more exposed to such clogging of the blades that the withdrawal of the instrument is rendered so difficult and dangerous as to wound the urethra in its course outward. In fact, one of the gentlemen present remarked that that very thing had happened before him, with that very instrument of Bigelow's. Besides, the fenestrated lithonriptor, with the pinion, is lighter in hand, and more easily managed, than the heavy Bigelow. The lithonriptor was introduced without difficulty, and withdrawn eight minutes afterward. The largest evacuating sound was then introduced, also, without difficulty, and the rubber ball, modified by Thomson, ad-

justed to it. The proper working of the ball soon sucked all the fragments, very few of which were larger than a small cow-pea. The stone was friable, and had been almost entirely pulverized. The patient was up and about in a few days afterward, relieved of all his symptoms.

The Case of Necrosis of the Tibia formed a kind of tunnel, which ran through the upper part of the shaft, forming a canal of about half an inch in diameter. By sawing and gouging the anterior wall of this tunnel, the bottom was exposed. It soon became covered with granulations, and filled up rapidly.

Of the two Necroses of the Thigh, the first was seated at the upper part of the shaft, at the junction with the great trochanter. It had been operated on the summer before with partial benefit, and it did not suppurate a very great deal. It was thought that but little gouging would be necessary; but, upon cutting down upon the bone, it was found that the whole thickness of the shaft had been reduced to about one-third of an inch in thickness, and, besides that, the necrosis had extended through the whole thickness, there being, then, in fact, a solution of continuity in the bone, a sort of spontaneous fracture. The extremity of the lower fragment was gently forced to the surface, and a half inch sawed off; the other end, which corresponded to the greater trochanter, was chiseled and gouged so as to remove all the dead surface. The parts were immobilized by a long axillary splint, a portion of which was

removed opposite the seat of the wound, and replaced by two arched rods of iron, which kept the parts in proper position, at the same time giving free access to the wound, above, below and between them, a contrivance which reflected much credit upon the ingenuity of the resident student, Mr. Bloom, now Dr. Bloom. The parts healed rapidly, without any complication. A small piece of dead bone came out through one of the orifices. At the latest date, one or two openings were still discharging, showing that the case was not thoroughly cured.

The other case of necrosis of the femur was one of the lower extremity, with an invaginated sequestrum. The lower extremity of the femur, together with the lower part of the shaft itself, was twice as large as the bone of the opposite side. There was a good-sized fistulous opening on the inside and the outside of the thigh, about one inch and a half above the tuberosities of the condyles. After the application of the Esmarch, an incision four inches long was made on the outer side of the region and down to the bone, which was gouged and chiseled to the extent of three inches by one and a half. This was done with some difficulty, as the new bone was very hard. Upon penetrating into the cavity in the center of the bone, a sequestrum was found of about three inches in length by one inch in diameter. It was removed in several pieces, and the cavity was thoroughly scraped. It proved to be quite large—about four and a half inches in length by about three in diameter. It was

filled with carbolized lint, and a bandage firmly applied, before the Esmarch was removed. Some ten days after the operation, the leg became œdematous, and was threatened with erysipelas; but it did not develop into anything serious, and the healing of the wound progressed most satisfactorily. The whole of the interior became covered with granulations, leaving no exposed bone, and filled up rapidly. At the time my service expired, four-fifths of the cavity was filled already, care having been taken all along to keep the opening leading into the central cavity well opened.

One of the Perineal Operations was for numerous chronic urinary fistulæ, running through the thickly indurated perineum. It was an old Negro, who was lingering in the hospital, gradually losing ground, and soon to die. I hesitated some time before operating on him, on that account; but, several times my students drew my attention to his declining condition, and I determined to try something for him. His canal would admit a number 8 sound, but the fistulæ showed no signs of healing. I knew, from past experience, that simply incising through the perineum, even in its whole length, in cases with so thick and hard an induration, would result in no good, as the induration prevented the walls of the fistulæ from coming together and closing. I decided, in that case, to incise the perineum, and then to cut out—dissect out—as much as possible of this indurated tissue. This course had been suggested to me, some years ago, by Professor Richardson, when I was his chief of clinic.

However good I may think the principle is, the operation was more than the old man could stand, and he died of exhaustion some ten days after.

All the other cases of perineal operations were performed for acute urinary infiltrations. Some two or three were performed by the surgeons of the house, as soon as the patients came in, after my daily round. Those infiltrations formed but small, circumscribed tumors, and the timely and well performed operations cut their development short. Three or four others were operated on by myself, having acquired the size of a hen's egg. The others were more extensive. In one of them, the infiltration had extended to the scrotum, and to the hypogastric region. The penis and scrotum showed signs of mortification. Some ten or twelve incisions through the parts gave free drainage to the urine and pus, and stopped the further progress of the disease. The sloughed parts were eliminated, having exposed the testicles, covered over by the fibrous and vaginal tunics. The granulations healed rapidly; and the skin of those parts is so thin and loose that whoever saw the case for the first time, towards the end of its course, never could realize that all the scrotum and the skin of the perineum had sloughed off.

Another case—this one a Negro—was also very extensive. The course pursued consisted in laying the tracts freely open, and exposing the bottom of them; such being the rule laid down by standard authorities, and emphatically insisted upon by Erichsen, especially.

The tracts soon granulated, and presented a healthy enough appearance; but the patient gradually lost strength, and finally died. In all cases of acute urinary infiltration, the incision through the infiltrated parts, and the laying open of the tracts, was the first and most urgent part of the treatment; but no case was allowed to recover from the chloroform before a good-sized metallic sound was introduced through the meatus and down the urethra into the bladder. When necessary, the strictures, or obstacles to the introduction of the sound, should be cut, externally or internally, or be divulsed. By passing the instrument daily, afterwards, it compels the granulations to heal over it, as it were, and insures a good canal by the time the perineal wounds are healed. By neglecting this part of the treatment, much trouble is experienced later—when the treatment of the stricture begins—to introduce even a small instrument through the strictural and irregularly coursed canal; besides, the patient has to go through all the grades of dilatation. In one case, we failed to get an instrument through the vesical end, in spite of all our efforts to find that end; but, after the parts had healed, it became easy to pass a number 4 through, and the gradual dilatation went on.

The Two Cases of Circumcision for Elongated Prepuce were sent to us for operation by Professor Elliott, who thought the operation of circumcision was the proper treatment, in these cases, to cure them of peculiar general reflex symptoms, referable to no other cause.

Cocaine was injected into the prepuce some little time before operating, and they stood the operation without any pain.

None of the Tumors Operated presented any difficulty, and healed well and quick. The case of adenoma of the testicle presented an abscess in the inguinal canal, but, as soon as the matter was liberated, it got well. The patient, however, ultimately died of sub-chronic diarrhœa, after the wound had healed thoroughly.

All the operations were performed without the use of the spray; but none but carbolized sponges were used; all the instruments were kept in carbolized water, and the operator and assistants cleaned and disinfected their hands before operating. The lint used was also carbolized lint.

Five of the sixty-five patients operated on took erysipelas. They were all transferred to the ward set apart in the hospital for that special purpose. They all got well but one, who died. This is rather an unusually large percentage of erysipelas this year, following operations here.

Of the sixty-five operated patients, seven died, from the following causes: One from amputation of the finger, followed by phlegmonous erysipelas; one from abscess of the liver; one from iliac abscess; one from strangulated hernia; two from perineal operations, followed by exhaustion; one from tumor of the testicle, of sub-chronic diarrhœa.

The following are the points of interest presented by

the other classes of patients, which required no operation:

The Case of Femoral Aneurism showed how easily and unexpectedly aneurisms will sometimes get well. It was in Scarpa's triangle, and was as large as a hen's egg. In order to demonstrate to the students the effects of compression of the artery above the tumor, the external iliac was compressed three or four times each week, and for about five minutes each time. Upon coming to his bed one morning, he greeted us with the news that the tumor had ceased beating, was hard and much smaller. Such was the fact. It was only upon firm pressure that a slight, deep pulsation could be detected. The student of the ward continued compressing the external iliac artery above Ponpart's ligament, and the patient himself was taught how to do it; this was continued for some two weeks—even after all deep pulsations had disappeared. The tumor diminished rapidly in size, but it was a good while before he was allowed to get up and walk about. This did not cause the pulsation to return, and, finally, the patient left the hospital with the promise of reporting immediately, if any beatings returned. We never saw him after that; and thus was accidentally and unexpectedly cured an aneurism which has required the ligature of the external iliac, and which has been known to resist even that heroic treatment.

The Case of Arthritis of the Elbow Joint was of traumatic origin. It gave him a great deal of pain, with

some fever; but, after a few days, the fever abated. At the same time, though, he became more and more drowsy, with a kind of hemiplegia on the opposite side, and finally died in a comatose state. The post-mortem showed a thick, almost pseudo-membranous effusion, in the arachnoid cavity, and in the sub-arachnoid space.

The other case of arthritis affected the knee joint. It was also traumatic. It resisted all the usual local and general means, and gradually grew from bad to worse. At one time, we thought there was some pus in the joint; but the hypodermic syringe showed that the fluctuation was delusive. Finally, he was placed under the influence of chloroform, and a liquid glass bandage applied, but loosely, simply to prevent motion; and an opening was cut over the knee. This procedure was followed by a marked diminution of all the symptoms, and the case kept on improving. Later on, there occurred, over the patella, a small abscess, through which a small piece of bone from the patella was eliminated. Upon probing the tract, it was calculated that it extended to the cartilage lining the deep surface of the patella; and, lest it might ulcerate through and penetrate the joint, the bandage was re-applied, and the patient kept quiet until the tract healed. He finally got well; but the tendons around the joint are stiff—more so than the joint itself.

The Case of Pernicious Anemia, as it is called by some, was a marked one. The largest glands were on the sides of the neck, where they bulged like turkey's

eggs; they extended into the chest and supra-clavicular region; there were also some under the arms. He had had the tumors cut into by some one, but the physician who attended him last, a gentleman from Texas, fearing that some one might not recognize the disease, and might attempt a bloody, dangerous and useless operation, gave the patient a letter of some twenty lines, in which he so nicely, clearly and pointedly, described the course and nature of the disease, and the danger and uselessness of operating, that I read the letter to the class, and said that it so covered the ground, in such few words, that I found nothing to add to this "clinical letter." Of all the remedies tried in his case, Fowler's Solution gave the best result. At one time the glands had almost disappeared, but they afterward regained almost their former size, in spite of the use of the arsenic.

Most of the cases of *Buboes and Chancroids and Chancres* were on colored subjects, since the white patients have special syphilitic wards prepared for them. The students have full access to this ward, where they are always welcomed by the surgeon in charge, Dr. Underhill. The two professors of Clinical Surgery also take the students through that ward, and teach them the diagnosis and treatment of venereal diseases. Iodoform was the basis of treatment locally.

The Cancer of the Tongue was not operated upon, because of the cachectic condition of the patient. He finally died, exhausted.

The Cancer of the Rectum was a limited one, and a good case for operation, had not the patient, prior to his entrance into the hospital, lost so much blood as to be in such anæmic condition as to render him unable to stand such an operation.

The Cancer of the Penis was not operated upon, because he left the hospital.

All of the cases of *Concussion of the Brain* recovered.

The Case of Contusion of the Epigastrium presented remarkable symptoms of a cataleptic appearance, but recovered completely after thirty-six hours.

The Cases of Eczema and Impetigo were treated with oil of chaulmoogra, with marked satisfactory results.

All the cases of *Fracture of the Skull* died.

We have abandoned the use of the interdental splint in the *Fracture of the Lower Maxilla*; we simply immobilize the bone with a liquid glass bandage, passing under the chin and over the top of the head.

The Fractures of the Limbs, not too close to the body, were reduced *at once* under chloroform, and a plaster bandage immediately applied, moderately tight. When the skin was injured, an opening or more was cut through the bandage. This treatment was followed by good results in all of the cases.

The Fractures of the Femur above the Lower Third were treated by the long splint, or, oftenest, by the

weights and pulley, and by short splints around the fracture.

One Case of Fracture of the Upper Part of the Humerus was also treated with weights and pulley. When up and about, the weights were allowed to hang down. We think that the result was better, as regards the following deformity, than when the ordinary plan of treatment is used.

The Case of Mercurial Salivation was attributed by the patient to Tutt's pills.

The Case of Curvature of the Spine was one of the extreme kind. He was much relieved by the application of the plaster jacket.

The Case of Phlebitis began by the internal saphenous vein, and was a marked and typical case. He was a rather unruly patient, and thought he was uselessly kept in bed after the symptoms had disappeared, so he got up and walked about. Three days afterward, he had to go back to bed, his whole limb having swelled considerably, from the fact that the femoral vein had also been inflamed. However, rest and mercurial frictions pulled him through.

The several cases of *Phlegmon of the Hand* were due to callosities over the palmar aspect of the root of the fingers. The cases were remarkable at first by the great amount of swelling and redness on the *back* of the hand, quite in contrast with the absence of any or much swelling and redness on the palmar aspect. The temptation was to lance the back of the hand, whereas, the cut

should always be made over the palmar aspect, where the disease first begins, and where the puss is located. The cut was always made as early as possible, and arrested the spread of the disease at once; any delay might have resulted in phlegmon of the whole hand and limb, and even death.

The same applies to phlegmon of the fingers, and particularly of the last phalanx. The cut always extended down to the bone, which the knife scraped. Thus bone felons were often prevented.

One Case of Articular Rheumatism was treated by the application of a liquid glass bandage, loosely applied. It afforded much relief, and was applied to the joints successively as they became painful. If the case be a particularly acute one, morphine or chloroform should be administered before applying the bandage.

All the Uncomplicated Cases of Stricture of the Urethra were treated by gentle and gradual dilatation; no force or violence was ever used, even when it felt as though hard pressure would drive the instrument through. No metallic instruments were used in masked strictures, until the soft instruments had prepared the way for them. No lengthy, harsh or bloody attempts were made to pass an instrument through a stricture, when the patient had just entered into the hospital. Preference was given to emptying the bladder with the aspirator, if necessary, and giving an opiate. Twenty-four hours did much towards relieving congestion and

spasmodic contraction of the parts, and, the next day, allowed the passage of a small instrument.

Ulcers of all kinds were treated in a general way, by rest, iodoform, strapping and bandaging of the limb. When the edges were high and hard, they were incised in several places, and this assisted the case very much.

Of the Various Wounds of the Scalp, one was followed by a phlegmonous erysipelas, which destroyed all the areolar tissue under the pericranial fascia. The pus was fusing towards the eyebrows, and back towards the occiput. The insertion of several drainage tubes arrested the disease, and the patient was finally cured, though after a long time.

The Penetrating Wounds of the Abdomen were all diagnosed at the moment of the accident by the able ambulance surgeons. Two died and one recovered.

A CASE OF RESECTION OF THE SUPERIOR MAX- ILLARY BONE, FOR CANCER.

By EDMOND SOUCHON, M. D., NEW ORLEANS, LA.,
*Professor of Anatomy and of Clinical Surgery, Tulane
University of La., in charge of Wards.*

On January 8, 1886, Alex. Dykes, a colored man of 41 years, from Providence, La., entered ward 8 in the Charity Hospital. He is a strong, well built Negro, and applies for relief or cure of a tumor of the left side of the face.

There is nothing special in the history previous to the appearance of the tumor, some eighteen months ago, as far as we can ascertain from his dull understanding, except that some four months or so ago the tumor was operated upon, or simply cut into, of which he bears the mark.

On the left side of the face, exists a tumor extending from the upper lip to the lower lid, which is pushed up so high as to close the eye, and from the nose to the malar bone. The surface of the tumor is ulcerated to the extent of a half-dollar silver piece. The tumor is rather hard to the touch, and is painless, both upon

pressure and spontaneously. By examining through the mouth, it is found that the tumor does not extend beyond the beginning of the pterygoid process.

The patient was shown to the class on the regular clinic day. All the above features were explained to them, and the case diagnosed one of malignant disease of the superior maxillary bone, having originated, most likely, on the antrum.

The bulging of the tumor on the face, it being on a level with the free border or back of the nose, together with its reaching in the mouth to the pterygoid process, convinced us that it had extended so deep, also, toward the apex of the orbit that to operate on him at that stage would have been a bloody, dangerous and useless operation. I therefore declined to operate.

During the week that followed, I examined him often. He seemed much disappointed at seeing that nothing was being done for him, since he had come quite a distance, he thought, to find some one who would attempt something for him. At my request, Prof. Richardson was kind enough to examine him, and we came to the conclusion, since it was the man's only shadow of a chance, especially since the success depended upon how deep the cancer actually extended, if perchance it did not extend beyond the danger zone of the deep regions, an operation might be successful in saving his life, or in prolonging it, or in affording him an easier death ultimately than would be if the tumor was allowed to go on ulcerating, develop

ing, spreading and involving the mouth, throat or cranial cavity.

The patient was given a good drink of whisky before getting on the operating table, and he was put under the influence of chloroform. He took it very well, and it was determined that after the removal of the towel, when the operation would begin, the anæsthesia would be kept up by the use of a throat atomizer, containing chlorotorm, which would be atomized, mixed with air and thrown in his throat by means of a long metallic tube, which would not be in the way.

As it was known the operation would be bloody, dangerous and tedious, all precautions were taken to operate quickly, and to have at hand most skillful assistants, who were Dr. R. Matas, my chief of clinic, and my efficient resident students, M. M. Beckham, Bloom and Schmittle, together with some other students of the staff and class. The knives, saws and chisels had all been freshly sharpened.

As soon as the patient was fully under the effects of the chloroform, an incision was made over the malar bone, on a line with the speno-maxillary fissure, extending down to the bone, and the bone was sawed; immediately, a dry-pressed carbolized sponge was applied over the wound, and kept there firmly, to stop the bleeding.

A second incision was made over the nasal process of the superior maxillary, directed from the lachrymal sac to the anterior nasal orifice, and down to the bone,

which was also sawed through. The upper lip was then cut through, opposite the left middle incisor tooth, which was extracted, and then the palatine process of the superior maxillary bone was sawed through, without previously incising the mucous membrane of the palate.

The next step was the detaching of the upper lip from the tumor, as far back as the ascending ramus of the lower jaw. All this had been done without difficulty, and is usually done quicker than might be supposed, when the instruments are good and the operator has the anatomy of the parts well present to his mind, and is determined not to mind the blood, and to go on quickly. As fast as an incision was completed, it was covered with a sponge, like the first.

Here some little trouble and delay were experienced in opening the mouth fully, so as to be able to reach the articulation of the tuberosity of the superior maxilla with the pterygoid process. As soon as the mouth was well opened, a sharp chisel was placed between the two bones, and, by hard pressure in the right direction, the maxilla was finally loosened from its last hold. Quickly the soft palate was detached from the hard palate, and the lower lid was separated from the tumor. The whole mass of tumor and bone was felt to be loose, and was quickly removed with the knife, severing whatever points resisted. In doing this, no attention was paid to the limits of the tumor, the point in view, at this time, being swiftness, as the bleeding was more considerable than at any previous time. The cavity was at once

firmly packed with several dry-pressed carbolized sponges, and the patient given a moment's rest, during which time the hemorrhage would stop. Though all this had occupied but little time, yet the patient was beginning to show signs of shock and the effects of the loss of blood, which, in spite of all care and attention, would trickle down from the table into the pail placed on the floor for the purpose of receiving it.

As soon as the hemorrhage had ceased, the sponge nearest the eye was removed, and that organ examined. It was found healthy, but the parts around were diseased, and it was without any support of any sort, either bony or fibrous, all having been destroyed by the tumor. The eye was accordingly removed with clips of strong curved scissors.

Now began a most careful review of the field of the operation, for the purpose of removing all pieces and particles of tissue which looked or felt suspicious. On this account, all the degenerated adipose tissue normally situated between the ascending ramus and the superior maxillary bone was removed with scissors and scrapers, as also that of the zygomatic fossa, to the internal and external pterygoid muscles; it was all invaded by the cancer. In doing this, the middle portion of the internal maxillary artery was cut; it bled freely, and had to be ligated.

At this stage of the operation, the patient's pulse, which had gradually become weaker, disappeared at the wrist; his breathing was weak and distant; his

limbs limp. Here a halt was imperative, to revive the patient, who was fast sinking. The cavity of the wound was packed with sponges, the head was hung down, whisky was injected freely into his limbs, the right side of his face and the pericordial region were slapped hard with the end of a wet towel, and his weak respiration was assisted by artificial means. At the end of some ten minutes, the pulse had returned, and the operation was continued by removing all the degenerated adipose tissue and structures in the cavity of the orbit, to its very roof and apex; the sphenoidal sinus being exposed. Upon reaching the apex of the orbit, it was seen that some suspicious particles still remained; but they were so near the internal extremity of the sphenoidal fissure, where the ophthalmic vein—then and there very large—opens into the anterior extremity of the cavernous sinus, that, for fear of wounding these structures, it was decided to stop. Besides, at this time, the patient was again sinking, and it was impossible to proceed without running the risk of the patient dying on the operating table. We desisted, therefore; intending to attempt, later, to destroy the remaining cancerous nodules with chloride of zinc applications and injections, if deemed safe.

By using the same means as above, the patient was revived a second time. The wound was packed closely with carbolized lint, and the lip was stitched to its fellow. He was carried back to his bed, but more dead than alive.

For the next thirty hours, he remained between life and death; and it took all solicitude and care, especially of Mr. Beckham, the dutiful resident student, to keep him in this world. He was laid flat in bed, with his head without a pillow, on a level with the bed. He was surrounded by bottles of hot water; received all over his limbs hypodermic injections of whisky, digitalis and ammonia, was heavily covered with warm blankets, and the door and transom near his bed closed. As soon as possible, he was given warm milk punch by the teaspoonful, which was allowed to trickle down on the sound side of his mouth. From this moment, he began to rally, and he improved rapidly, and, three weeks later, was sitting up. It could be seen then that some little cancerous growths were projecting slightly from the apex of the orbit, but to this day they are easily controlled by repeated applications of chloride of zinc on a piece of lint or cotton. Another small growth had arisen near the nares, but was easily destroyed by the scoop, followed by the application of chloride of zinc. Such vigorous measures would also dispose, we think, of the small growths near the apex; but the close proximity of the cavernous sinus and cranial cavity and brain has kept our hand back. When we last saw him, he was in as good health as he ever was. He walks briskly all over the grounds all day, subsisting on fluid. The cavity has contracted by one fifth, at a rough guess. It is evidently much smaller than would be supposed, having filled up by healthy granulations,

and by the contraction of the skin over the edges. There still remains a pretty large gap, through which the side of the tongue will occasionally protrude.

The teachings of this case are : First, how much human nature can stand ; second, that, if the patient had applied sooner, all the disease could have been eradicated, thus increasing very much the chances of cure.

The whole question of the operation turns upon this point: Does the disease extend beyond the danger zone, or not? And this is impossible to ascertain, except by operating. The following are some of the interesting points connected with the history of the resection of the superior maxilla: It was John Lizars, of Edinburg, who, in 1826, first planned and proposed the removal of the whole of the superior maxillary bone ; but it was Gensoul, of Lyons, France, who, without having had any knowledge of Lizars' ideas, first operated, in May, 1827. Lizars operated on his first case in December, 1827. The hemorrhage during the operation is often very great ; so much so that the previous ligature of the carotid has been advised and performed. This was done by Lizars in his first case ; and, in spite of this, the hemorrhage was such as to necessitate leaving the operation unfinished. I was present when, in the summer of 1881, Dr. Schuppert, Sr., of New Orleans, operated in the amphitheatre of the Charity Hospital, and the patient died on the operating table, mostly from loss of blood. No previous ligature had been applied. Several cases of secondary hemorrhage are on

record, and so serious as to require the ligation of the carotid, even as late as the nineteenth day; this last case died. There are evidently two classes of these tumors as regards hemorrhage—one that bleeds profusely, and the other less so. The latter are most common; the former are especially the soft tumors, and those which extend beyond the limits of the bone itself. However desirable, it is very difficult to say which will bleed or not, or how far the tumors extend.

