





NLM 00072701 1





Surgical Clinic of the University of Giessen

(Medical Director: Prof. Dr. Fr. BERNHARD)

EXPERIENCES WITH MEDULLARY NAILING
OF FRACTURES

by

Dr. med. K. KATZ
Lecturer of the University

and

Dr. med. J. WEIS.

Translation prepared by:
U.S. Fleet, U. S. Naval Forces, Germany
Technical Section (Medical)



WE

185

K19e

1945

UH

390

FG3737P

Project 2, fol. 10

f. c. 1

TABLE OF CONTENTS

	page
Table of Contents	I
Foreword by Commander Harry J. ALVIS, MC, USN	II
Introduction	2 - 3
Historical Development of Fracture Treatment	3 - 5
Range of Medullary Nailing within Operative Fracture Treatment	5 - 6
Superiority and Risks of Medullary Nailing General Indication	6 - 11
Indication for Marrow Nailing of Closed Fractures	12 - 14
a) Humerus	14 - 17
b) Forearm	17 - 22
c) Femur	22 - 28
d) Leg	28 - 33
Technique of Percutaneous Medullary Nailing of Simple Fractures	33 - 38
a) Humerus	38 - 45
b) Forearm	45 - 48
c) Femur	48 - 54
d) Leg	55 - 64
Some Errors and Risks Connected with Medullary Nailing	64 - 70
Personal Experience with Medullary Nailing of Simple Fractures	71 - 72
Open Medullary Nailing of Primarily Simple Fractures	72 - 81
Indication for Medullary Nailing of Compound Fractures	81 - 99
Medullary Nailing of Gunshot Fractures	99 - 101
Osteotomy and Medullary Nailing of Fractures Healed in an Unfavorable Position	101 - 110
Medullary Nailing of Retarded Fracture Healing and of Pseudarthrosis	111 - 138
Influence of Medullary Nailing upon the Formation of Callus	139 - 143
Reaction of Bone Marrow to Medullary Nailing	143 - 144
Additional Fields of Medullary Nailing	144 - 149
Literature	150 - 151

FOREWORD.

This manuscript, prepared in 1945 just after the close of the war, presents the point of view of the Surgical Clinic of the University of Giessen concerning the use of the medullary nail.

Admittedly their experience was not as extensive as that of other clinics but it was unique in that it included a number of cases originally nailed in a field hospital on the Finnish front by Dr. Kuentscher. The Giessen Clinic at that time was a general surgical clinic and was not predominantly concerned with orthopedic work. This manifests itself in the greater emphasis on basic surgical principles and less on the mechanical aspects of the use of the new medullary nail.

Harry J. Alvis,
Commander, Medical Corps,
U. S. Navy.

INTRODUCTION

When studying the medical journals one sees at a first glance that the treatment of fractures, though an old and widely explored field of surgery, has been subject to continuous change in the years before, during, and after the recent war. On the one hand this may be due to the considerable increase in the rate of accidents before the war in Germany, when the growing use of motor vehicles in wider circles of the population as well as the work on numerous large building projects (Autobahn) was particularly responsible for the increased opportunity to injure bones - quite apart from the war casualties. On the other hand the development of new methods of treatment revived and maintained the interest of the physicians dealing with fracture treatment. The new method of treatment presently in the foreground of discussion is medullary nailing of tube bone fractures according to KUENTSCHER a method which was first published in 1940. The procedure of the "stable osteosynthesis" (KUENTSCHER) is described as follows: At a place distant from the fracture site a small incision is made and a long, strong, and appropriately shaped "nail" is driven into the medullary cavity which forges the fragments so firmly together that, as a rule, the fractured extremity can immediately be moved and after a short time can be used or subjected to weight-bearing without any additional external support. Here several problems, some of them of a theoretical, some of them of a practical and technical nature, resulting from medullary nailing shall be investigated as well as the clinical experience and the results collected with the patients of the Surgical Clinic at Giessen.

So far there are only a few summarizing volumes on medullary nailing. The first book published on the matter was that of HAEBLER (1) which gave a very detailed and gratifyingly outspoken report on a material comprising 250 cases. The author of this book also treated the details of the technique and particularly discussed the problem of nailing gunshot fractures. This study was published during the war and in many a respect bears its stigmata, a fact which frequently may have been embarrassing for its author too. In addition, mention must be made of the 3rd volume of BOEHLER's (2) "Technique of Fracture Treatment in Peace and War" which through the plentiful material (more than 500 cases, of which 236 were observed in the emergency hospital in Vienna under the direction of BOEHLER), through the systematic description, and through the evaluation of the single cases as well as of entire groups of patients treated with the same method is of extraordinary value, as it always makes the personal experience of BOEHLER the center of consideration. As a third study published in form of a monograph the "Technique of Medullary Nailing" by KUENTSCHER and MAATZ (3) must be mentioned which, however, almost exclusively deals with technical problems. References to smaller studies of the Clinic of Kiel and other scientists who have investigated the method will be made in the course of this treatise.

In publishing our material, consisting of 280 cases, we want to point out right in the beginning that not all of these had been treated in the Giessen Clinic in the first

stage of their injury. Some of them were previously treated elsewhere and they were admitted at Giessen for expert examination, and for the continuation of treatment. One or the other reader may believe that the number of cases, particularly of those treated by ourselves is small and it even may be that some who have a greater experience with marrow nailing may deny our competence to judge and evaluate the method on the base of such a small number of patients. We do not share this opinion. The small number is due to the fact that contrary to other surgeons we did not apply the method to every fracture suitable for medullary nailing. On the contrary, right from the beginning - our first medullary nailings were made as early as 1942 - we maintained the contention that only a very critical selection of those fractures for which the application of medullary nailing was permissible could be of value for the method. Nailing constitutes one of the most audacious of surgical enterprises. The superiority of the method was so obvious that it could be applied only with wellfounded judgement, if it was intended to promote its acknowledgement in surgery, rather than its rejection.

So much for the views first held by the Giessen clinic. On the following pages the attentive reader will observe the development of our attitude.

HISTORICAL DEVELOPMENT OF FRACTURE TREATMENT

To understand and to evaluate critically the originality of the method and its difference from the previously usual operative fracture treatment, a short survey on the historical development of the general problems arising within the theory of fractures is necessary. Medullary nailing involves the problem of improving a certain technique and because the method calls attention to the principles of fracture treatment in general, even today one can see that quite a number of new problems have originated from it. These problems not only refer to the method applied for treatment, but also to the biological processes taking place during fracture healing. When treating the fractures of the extremities two exigencies always have to be fulfilled. The restitution of the anatomical structure and the restitution of the function of the injured limb. It is not possible in every case to meet both requirements absolutely. Sometimes in the course of time the demand for overcoming the structural change, sometimes for restitution of function was a matter of preference determining medical action. As always, also in the field of fracture treatment extreme advocates of the one and of the other aim were to be found. Although it almost seems to be a matter of course that the perfect solution is the restoration of the normally built up anatomic structure, which is the principal basis for the unhampered function of the extremities, the damages caused by prolonged immobilization prevail in many cases even with an ideal reduction of a fracture. This experience led to the result that some of the surgeons finally disregarded the correct anatomic reduction of the fragments and exclusively directed their attention to the preser-

vation of the mobility of the joints even accepting a shortening of the long bones almost equal to crippling, if only the function of the extremity was preserved to the greatest extent by early exercises. Such a procedure can be regarded as obsolete in this extreme form. With fractures of the upper extremity and particularly with those of the humerus the renunciation of the perfect reduction of the fragments is justified to a certain degree, as for the hand as well as for the arm grasping and moving are of greater importance than correct axial position and equilateral length of the extremities. For the lower extremity including the foot the restoration of the axis bearing the weight of the body and an equal length of the sound and treated extremity certainly are of a greater significance, as in this case the ability to bear weight and equivalent lengths mean more for standing upright and walking than the full mobility of the joints. It is particularly the occurrence of late impairments of the joints of the lower extremity due to inadequate static stress which must be taken into account. BOEHLER e.g. is of the opinion that a curvation of the femur by more than 5 degrees has a detrimental effect upon the joints and he insists in it being straightened out.

Thus we have outlined the principal problems to be solved by the various methods of fracture treatment and from these exigencies the practical basis of every method of treatment can be deduced. This essentially consists of reduction and retention. The principles of the procedure to be followed for the reduction of dislocated fractures are firmly established for all kinds of fractures with the exception of single modifications and improvements of the reduction technique. Since the introduction of wire extension the decision must be made in every individual case whether a fracture shall immediately be reduced to the best possible position or whether reduction shall be achieved by traction and counter-traction during a prolonged period of time. One may deduce from the development of the reduction technique that efforts have been increasingly directed to applying the reducing force to the bone, as the soft tissues enveloping the bones of the extremities never constitute such an adequate point of application as the fragments themselves. For this reason the development of technique from Schmerz's clamp and Steinmann's nail to the Klapp wire was certainly to be expected. Formerly reduction and retention not only were two completely different procedures but also required different appliances. It was the method of wire extension which united the two stages in one single technical and instrumental procedure, as the wire drilled through the bone not only was employed as a manubrium for the traction to be administered for reduction which, thanks to R. KLAPP as well as KIRSCHNER and their disciples, complied in the most minute technical details with this requirement. In addition, wire extension was capable of effecting retention. In this connection, wire extension takes a special place in fracture treatment. There is no need to discuss in detail the great advantages of the wire extension method.

With medullary nailing in its perfect form reduction and retention are again divided into two separate stages, but in many cases the advantages of the internal immobilization without any immobilization bandage are so predominant that the separation of the treatment into two stages is no longer a method of greater significance.

Since the most early times of scientific fracture surgery one of the best founded rules was the principle that no closed fracture should be changed into an open fracture because of the hazard of infection. It is particularly the debris, consisting of bone splinters, periosteum, escaped bone marrow, crushed musculature, and blood, which constitutes such a favorable culture medium for pus organisms that this rule must be maintained under all conditions. Presently even the reversed rule was valid according to which a compound fracture should be converted into a closed fracture as soon as possible if it is compatible with the general principles of wound treatment. These considerations were the reason why operative reduction was taken up fairly late, only hesitatingly, and at no time without contradiction. Doubtlessly there are situations which do not permit evading operative opening of the fracture site and the adjustment of the bones under direct control of the eye, if - particularly with old fractures - none of the other methods is successful. However, it is particularly the experienced surgeons who constantly raised a warning voice demanding that the indication for operative reduction be confined to the utmost minimum, though it may be ever so tempting to gain really excellent anatomical results in this way. Warnings have also been expressed with regard to the introduction of metallic or other stable foreign bodies aiming to retain the fracture in position, because of the danger of infection and the disturbance of the healing of the fracture. Nevertheless it must be admitted that the fixation of the fragments at the fracture site itself by means of wire, bolts, pins, screws, or plates was only a natural step, if once it had been decided to open the fracture site. Even today this admonition should not be disregarded although some surgeons relying upon modern chemotherapy may be inclined to compromise the principles valid so far.

In this context we should like to call attention to the fact that with the introduction of sulfonamides and particularly of penicillin into fracture surgery ventures may be undertaken which in former times were not considered permissible. Therefore the surgeons are relieved of a great part of their responsibility by these drugs.

RANGE OF MEDULLARY NAILING WITHIN THE OPERATIVE FRACTURE TREATMENT.

So far medullary nailing is the only method which meets satisfactorily the two most essential postulates of fracture treatment; The application of the immobilizing force to the bone under optimal conditions and with a stability of immobilization which cannot be attained by any other procedure. It is a well-known fact that absolute

immobilization is an especially important factor for fracture healing. Secondly, the insertion of the marrow nail can in most cases be effected from a place far distant from the fracture site. Therefore, when nailing a fresh uncomplicated fracture, there is no need to establish a communication between the fracture and the outside, not even for a moment. It is a characteristic feature of the peculiar technic of medullary nailing that it has to be considered among the operative methods of treatment, but that under normal conditions the opening of the fracture and the insertion of foreign bodies in the fracture area can be avoided. This is in contradistinction to other operations made for the reduction or the retention of the fragments. Although in contradiction to KUENTSCHER (4), we believe that medullary nailing should be considered among the methods of operative fracture treatment, not only because a small incision is necessary to insert the nail into the medullary cavity, but also because of the possible summation of a certain number of perilous factors seeming insignificant at first glance. These involve the anesthesia - regional or spinal anesthesia, sometimes narcosis - the position of the patient, and the frequently prolonged duration of the operation. GRIESSMANN and SCHUETTEMEYER (5) stating that "in general the duration of the operation does not exceed 10 or 15 minutes" certainly create a faulty impression for beginners, as very frequently much time is required for the operation including reduction, fluoroscopy, and X-ray pictures. To these hazards must be added the reduction, the hazard of fat embolism, of infection, traumatic shock, and probably still other factors, the combination of which may have the effect that the whole procedure assumes the character of a major surgical intervention.

However, since under normal conditions the opening of the fracture site is avoidable, one is in a position to maintain the basic rule and to avoid converting a closed fracture into an open one. At any rate, marrow nailing is far superior to the heretofore available methods in those cases in which there is an absolute indication for operative reduction. This statement may be made, because medullary nailing permits reducing the risk of operation to a minimum. Exceptions occurring when medullary nailing is applied shall be mentioned below.

SUPERIORITY AND RISKS OF MEDULLARY NAILING GENERAL INDICATION.

The time has come now to outline more sharply the superiority as well as the risks of the medullary nailing of fractures. Numerous publications permit one to survey the experience gained during the early years and to compare it with the results obtained with our patients.

Some general advantages of medullary nailing are beyond contradiction: In most of the cases the patient is spared a long confinement to bed, as after the healing of the incision at the insertion site and with the nail seated firmly, there are no objections to permitting the patient

to get up, and, with fractures of the lower extremity, to subject the broken limb early to weight-bearing. Concurrently local damage of the injured extremity is avoided such as muscular atrophy, decalcification of the bones and above all ankylosis of the joints. As regards reducing confinement to bed for old persons, the medullary nail is comparable to the femur neck nail and it is at least possible to let the patients make extensive exercises in bed if for some other reason getting up cannot be permitted. Every physician knows how dangerous it is to keep older patients immobile in plaster casts, or confined to bed by extension treatment, as it provokes circulatory disorders, pneumonia, and decubital ulcers. One must add to this the immobility caused by the fracture pain even including insufficient respiratory movements. In this connection the excellent success of systematic exercises in bed must be mentioned which were recommended ten years ago chiefly by KIRSCHNER. By the stable osteosynthesis - in every case a really firm seat of the nail is essential - the fracture pains are relieved immediately and continuously and thus the dangers arising from the lack of movement can be prevented. For this reason we also follow the principle to nail immediately every fracture of the femur neck. Hence the majority of the general disadvantages inherent in fracture treatment as practiced so far, can usually be abolished with one stroke by medullary nailing. By no means, however is marrow nailing permissible if shock is present. As the fractured bone is sufficiently stabilized through the internal fixation it is seldom necessary to apply an additional plaster cast or extension bandage except in the case of leg fractures. And even in an unfavorable case one can limit oneself to the application of a plaster cast which exempts the knee joint so that it can be moved at an early date. If one does not want to trust the fixation of the fragments to the nail alone one may employ an additional walking cast. This combined with the nail permits exercises and weight-bearing at an earlier time than would be possible without nailing. In this case the walking cast can be kept smaller than could be risked without the medullary nail. This will be discussed together with the individual forms of fractures. Since the introduction of medullary nailing we are relieved to a great extent of the concern for the mobility of the joints in the proximity of the fracture. Finally attention may be called to the economic factor, as in view of the shorter duration of hospitalization the costs are noticeably reduced for the patients as well as for the insurance company (HAEBLER (6)).

In contrast to the apparent general superiority of the new method, as described above, some direct disadvantages must be mentioned although they are of a more local nature. It was pointed out already that medullary nailing is an operative procedure, whereas the aim should be to exclude operative intervention as much as possible from fracture treatment. In this case it is not so much the operative reduction itself which should be avoided, but rather the hazard of infection connected with it. The zone of debris and the hematoma present at the fracture site represent an excellent medium for pus organisms so that the old principle of avoiding the conversion of a closed fracture into an open one is still valid even in the era of sulfonamide and penicillin treatment. Reference to this fact was made above. Medullary nailing is a

compromise between conservative and operative reduction and KUENTSCHER (7) deduces from this fact that it does not constitute an operative fracture treatment. Even though with the ideal performance of the operation the fracture site is not exposed, the forcible insertion of the nail into the medullary cavity causes a communication between the fracture and the outside which in one or the other case may give access to infection. There is no doubt that the more ardent supporters of medullary nailing are right in stressing the fact that the insertion of the nail at a distant place, which has to be considered as sterile, does not involve the same peril of infection as the exposure of the fracture site itself, provided that the operation is practiced with complete asepsis. This is particularly true if the operation is made at the site of the complicating wound. However, in spite of all precautions the opportunity is created for pathogenic organisms to invade the tissue, a fact which would be completely excluded in the case of entirely conservative methods. Medullary nailing causes a breach in the principle of keeping the fracture closed, even though it is applied at the place where danger is least. For this reason one must take into account that the method involves a certain risk of infection which, however, is not necessarily greater than that of any other aseptic operation. In practice with closed fractures the advantages of marrow nailing predominate so that the decision to apply the method is not difficult as far as the risk of infection is concerned.

According to HAEBLER's calculations the number of infections with the "percutaneous" nailing method amounts to 1.5 % while they amount to 11% if the fracture cleft is exposed. The cases of infection after medullary nailing of closed fractures were exhaustively described by MAATZ and REICH (8) whose unreserved discussion of the failures is of particular value due to the detailed presentation of the case histories. Therefore that study shall be subjected to a closer investigation here. Its authors described 14 cases of traumatic osteomyelitis, some of which they observed themselves while the others were reported to them from neighboring hospitals, and the medical histories of cases of bone infection published earlier by A. W. FISCHER and MAATZ (9) were recorded again. We are of the opinion that for the judgement of the risk of infection due to medullary nailing in its narrower sense only those cases are really suitable for evaluation in which a closed fracture became purulent after medullary nailing. This occurred in three instances. Suppuration of open fractures or after the exposure of the fracture site or after osteotomy cannot unrestrictedly be held against the method of medullary nailing as here infection theoretically could occur without the nailing. A closer study of the case history of these three closed fractures revealed that only in one instance nailing really was the cause of infection, and MAATZ and REICH underlined the fact that with regard to this the case stood alone among the 200 medullary nailings performed by them.

In a 45 year old female patient (case 3) there was a closed oblique fracture of the left tibia which was nailed without any difficulty, the incision site however showed drainage from the very beginning on. When after five weeks the medullary nail was removed, pus was evacu-

ated. The fracture site became purulent after 10 weeks and foot-joint empyema also ensued. At the time of reporting "a pyemic condition was distinctly visible".

Contrary to this single observation of infection of a fracture originating from the site where the nail was inserted, the two other cases of infection were easily explainable. With an 18 year old male patient (case 1) a metastatic suppuration of a closed fracture of the left leg occurred which had originated from the infected right knee-joint and various other hematmata also began to suppurate simultaneously. Amputation of the right thigh had to be performed. The patient died. In the case of a two year old child (case 2) with a closed fracture of the shaft of the femur the fracture site became purulent subsequent to a very difficult nailing procedure after which the nail protruded too far. Infection "apparently occurred via the medullary cavity after the formation of a suppurating fistula at the nail insertion site". The process could be controlled through incision and the final result after 5 months was satisfactory.

These observations show clearly that infection originating from the nail insertion site is one of the most rare incidences occurring in the course of the treatment of closed fractures. If one were to express the observations of MAATZ and REICH in per cent, the figure certainly would remain below the figures for the infection hazard of strictly aseptic operations; this was also stressed by the above mentioned authors.

With a total of 102 medullary nailings of closed fractures we have observed slight infection in three cases, which, however, did not substantially disturb the course of the healing of the fractures. These infections occurred in the humerus and in the leg. In addition we were faced with two cases of osteomyelitis of the nailed tibia. One of these patients died from a knee-joint empyema which gave rise to a suppurative thrombosis of the pelvic veins.

Quite a different cardstick of course must be applied to all complicated fractures. This will be considered in detail below when the indication for the medullary nailing of complicated and compound fractures will be discussed.

In the chapter dealing with the superiority and the risks of medullary nailing in general, the problem of fat embolism must also be considered, which becomes prominent for every surgeon used to anatomic thinking as soon as he commences to study the marrow nailing method. A minor degree of fat embolism is regularly found after every bone injury as was shown by the very thorough investigations of FEHR (10). Of course it is possible that particularly in cases of older individuals whose bone marrow is rich in

fat, fat or fat cells may be pressed into the circulatory system by the pressure of the medullary nail, be it even due only to an over-all rise of the pressure in the marrow cavity. It must be said here that the pressure increase can be largely avoided, if the marrow is given occasion to escape while the nail is driven in. This is easy, as the medullary nail is no solid rod with a circular cross-section, but is shaped like a tube in which the fat or the bone marrow is diverted towards the insertion site. The nail, therefore, does not have a syringe piston effect (KUENTSCHER). The expedient to avoid fat embolism is to withdraw the guide-rod from time to time before continuing to drive the nail further in, if, as in the case of the femur, a guide-rod is employed. The fracture itself also permits the contents of the medullary cavity to escape and thus provides a certain pressure equalization (RAISCH 1943). Moreover, allegedly there also prevails a certain overpressure in the marrow cavity under physiological conditions (LARSEN (11)). On the other hand the fracture site too may be exposed to overpressure caused by a large hematoma and the ruptured veins may give access to fat droplets as far as they are not compressed. Experience shows generally that the hazard of fat embolism is not great and that it even is a particularly rare occurrence in the case of open fractures. MAATZ attempted to clarify conditions by means of animal experiments and with guinea-pigs and dogs he nailed as many as four long bones in the same animal without a fracture being present, so that the fracture cleft could not act as a decompression valve for the overpressure in the medullary cavity. The fat embolism found hereafter was so small that it was practically of no bearing. MAATZ, however, points out that patients who due to their fracture and its sequelae are liable to embolism should preferably be excluded from medullary nailing to avoid any additional fat embolism, as it has the appearance that only the summation of the two factors becomes a real threat. HAEBLER, too, discussed this problem in detail and arrived at the same conclusion as regards practical action. One should not disregard the fact that the fatal hazard of fat embolism exists, though the figures for a fatal outcome due to fat embolism be ever so low, since only through a thorough investigation of the causes will it be possible to meet it effectually. For this reason the case histories published by HAEBLER shall be subjected to a closer scrutiny. They are particularly valuable because of the analysis he made of them. There were 6 deaths among 250 cases of medullary nailing. Two of them died from fat embolism, and a third case was also attributed to fat embolism by HAEBLER in view of its clinical picture, although the pathologist denied fat embolism as the cause of death. Unfortunately no histological examination was made. All these fatal cases were cases of femur fractures. Hence it results that particular care should be applied to the nailing of the femur. FISCHER and MAATZ found one case of death each with medullary nailing of the femur and the leg among 200 marrow nailings made before 1942. One of those deaths occurred after medullary nailing of both legs which was necessitated by fractures caused by a jump from a window. Among our material of more than 200 cases we lost on-

ly one patient through fat embolism subsequent to medullary nailing. This was a 60 year old patient whose general condition was not good and who suffered from bilateral oblique fractures of the femur. Both femora were treated with medullary nailing in one session; this was one of our first cases of medullary nailing. With our present experience one must conclude retrospectively that the fatal embolism could perhaps have been avoided if only one side had been treated first, and the other side at a later date after general recovery had ensued.

Considering the conditions of mechanical pressure one should examine carefully whether it would not be advisable in case of a large fracture hematoma to immobilize the fracture by means of wire extension until the hematoma is partly resorbed and thus the pressure of the hematoma upon the marrow cavity has lessened. Moreover one should consider that with old fractures whose cleft is filled with callus or cicatrized tissue the pressure valve can be restored artificially. In such cases it may perhaps be better to expose the fracture and to nail it after exposure (HAEBLER) in order to avoid fat embolism, a procedure which has to be considered as an exception. This consideration however should not lead to the deduction of a rule. A special decision must be made for every individual case. Data from the anamnesis, the presence of adiposity, the condition of heart and lungs, all must serve as guides in this decision.

The sole example of fat embolism shows that the method of medullary nailing requires a very accurate evaluation in every individual case. But there is no reason to reject the method as a whole because of isolated failures. There is no doubt that the application of medullary nailing is rendered more complicated by such considerations and experiences than it appeared in the beginning, but it is particularly the necessity to weigh the pros and cons in every single case which attracts the attentive surgeon as every fracture requires an individual operation. This is not the chief reason why medullary nailing ranges among the great operations of surgery.

By all these considerations the whole field of indication will be defined separately for every individual case, and our study shall contribute particularly to this end. In view of the relative newness of the method the same considerations make it advisable to restrict the method for the time being to hospitals in which all appliances are available, and which at least, as regards technique, provide security by reliable asepsis and by the smooth applicability of all devices required for careful nailing and for the control of all possible complications. An X-ray apparatus is indispensable, and the best results are certainly obtained if the equipment permits operating with two roentgenoscopes simultaneously, as exact reduction must be accomplished under the fluoroscope in two planes at right angles before the nail is driven in.

INDICATIONS FOR MARROW NAILING OF CLOSED FRACTURES.

The indications for marrow nailing of closed fractures were classified by KUENTSCHER and MAATZ (12). According to their system the fractures of the long bones are classifiable in: fractures "most suitable", "suitable", "still suitable", and "not suitable" for medullary nailing. Regardless of the opinion held about the classification of a complex biologic process it is obvious that in such a practical field as surgery, valuable hints are obtained by systematic classification and that this is the most appropriate method to present the observations and the results. In this way definite rules may be found and possibilities for comparison gained. It is natural, however, that the individual classes of the topic must be considered with the understanding that they refer to the typical form of the various types of fractures of the long bones, that means after the elimination of all complications. As it is not possible, however, to reduce nature to a rigid system it will hardly occur that the fractures admitted for treatment appear in their pure forms. Nevertheless a certain simplification will always be of didactic value and in this case it is left to the surgeon to use the schematic system for weighing the discrepancies and to classify for instance a fracture as "not suitable" which according to the classification schema would be "still suitable", and to exclude it from nailing and vice versa. In this field all of us still have to learn, and for this reason a certain system of consideration can only be of advantage. As yet no surgeon is compelled to nail fractures which he would rather like to treat otherwise according to his ability or audacity, and the non-performance of medullary nailing presently can in no case be interpreted as malpractice. For that reason KUENTSCHER and MAATZ (1945) stressed that every surgeon who wants to become acquainted with the method should have an opportunity "to commence with a very limited range of indication". Experienced surgeons, among whom KUENTSCHER as the inventor of the method and his co-worker MAATZ have to be counted chiefly, may widen the range of indication. KUENTSCHER and MAATZ defined their opinion as follows: "Since its introduction the method has proven valuable to such a high degree that one is right to maintain that every "nailable" fracture should be treated with the medullary nailing method".

When studying in detail the indications for the medullary nailing of the various fracture types we rely upon the assumption that the general directives discussed above will be considered in every individual case. The local indication principally depends on the mechanical conditions. After an examination of the general condition of the patient and of all data recognized as important for the general indication for medullary nailing one will have to deliberate in the case of every closed fracture of the upper and the lower extremity whether or not medullary nailing is feasible and in addition the question must be considered whether the reduction and retention of the fracture will be more successful with or without the medullary nail. This means that the surgeon must be capable of a critical judgement of his personal skill, his experience, and his dexterity, and that he must take counsel with himself whether he will be more successful when treating the fracture with a medullary

nail or without it. Moreover it is necessary to consider after-treatment beforehand, as with an increasing experience with medullary nailing the result will turn out that one tends to use it more and more because it does not lead to muscular dystrophy and ankylosis of the joints. It is particularly under the view point of early exercises that one is entitled to such a procedure also with those fractures whose reduction and retention would have been practicable with other non-operative methods.

As outlined above in cases of closed fractures the indication for medullary nailing is definitely determined by the state of the injured extremity. If there is a very extensive hematoma associated with a considerable swelling of the fractured limb or even dermal vesicles it is better to postpone medullary nailing to a later date when the swelling has subsided, the vesicles have dried, and the skin abrasions are covered with epithelium again, provided that it does not require more time than one can account for with regard to the reduction. In connection with the indication for medullary nailing, skin abrasions on principle involve a hazard of infection which must be considered as just as serious as the soiled wound of a compound fracture. Such a dilatory action and conservative treatment prior to reduction and the application of a plaster cast was usual so far in all similar cases. However, it shall be specifically stated here that for the choice of the time of medullary nailing the deliberations in the case of a compound fracture must be entirely different from those in the case of a simple fracture according to recent experience. This will be given closer consideration below. With a closed fracture early medullary nailing is not the principal thing, and a dilatory treatment for a few days does not mean a waste of most valuable time, but it rather creates more favorable local conditions for medullary nailing. The local indication is largely determined by the proportion between the bone tube and the medullary nail and reversely by the possibility or impossibility to adapt the nail to the bone tube. Here motives originating from the theory of indication intersect purely technical factors so that it is not possible to describe each of the factors separately, since they are linked together. This was felt by all scientists who worked on the medullary nailing method and we regret that sometimes we will be compelled to repeat ourselves here.

The width of the medullary cavity is not equal in all sections of the bone, but usually it is more narrow towards the middle. In consequence the nail to be driven in cannot be thicker than the most narrow part of the bone tube. This constitutes a disadvantage as the difficulty of immobilizing a fracture by means of a medullary nail increases with the distance of the fracture from the most narrow part of the medullary cavity. We shall see later during the discussion of the various types of fractures that this disadvantage can frequently be compensated without causing noteworthy complications by peculiarities of technical proceeding which either refer to the nail insertion site or to the type of nail to be employed.

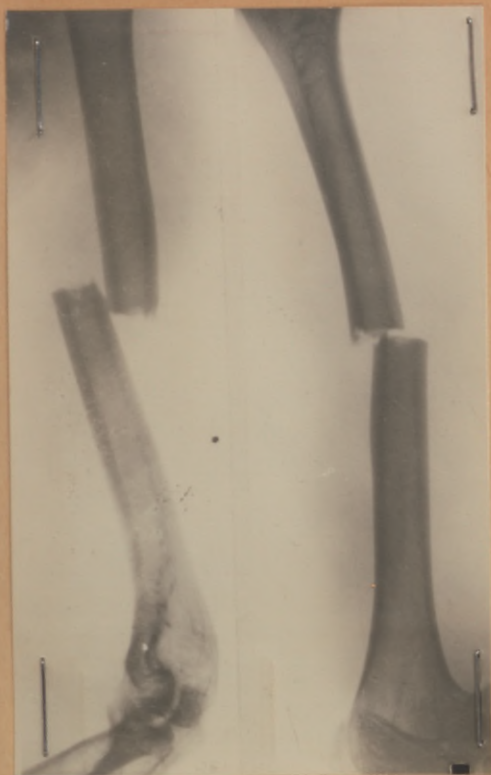Medullary nailing has excellently stood the test with multiple fractures. Here the single fragments can be threaded upon the nail provided they still constitute whole parts of the tube, be they ever so short.

"All fractures involving the joints have to be excluded from medullary nailing as fragments which still are in a fairly favorable position may be driven asunder by the nail, as there is no sufficient hold for the nail, and as the joints are endangered by its intrusion (KUENTSCHER and MAATZ 1945).

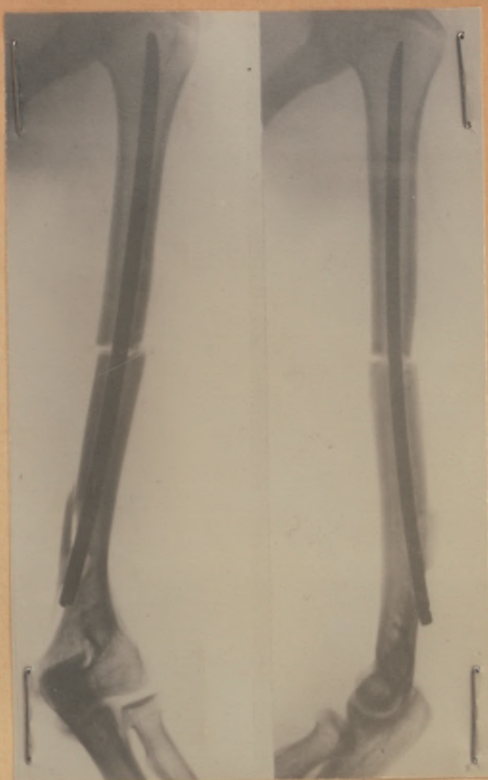a) Humerus.

Among the fractures of the humerus those of the middle of the shaft and the lower third are suited best, as here the cavity of the humerus has its smallest diameter. Amongst these it is the transverse fracture which can best be immobilized by the medullary nail (Illustration 1). The judgement of the situation is somewhat more difficult, if one is faced with fractures located very close to the shoulder or elbow joint, that means particularly in the case of fractures of the collum chirurgicum or with supracondylar humerus fractures. In the final analysis KUENTSCHER and MAATZ consider all humerus fractures as "very suitable" for medullary nailing, but we do not share this opinion entirely. The views of KUENTSCHER and MAATZ are based upon the fact that for nailing humerus fractures one can proceed from the proximal end as well as from the distal end. When the medullary nail is driven in from the proximal end, that means from a spot immediately below the humerus head with the supracondylar fractures close to the elbow joint, the nail at least acts as a bolt and prevents dislocation of the distal fragment even if it does not find a firm hold in the distal fragment because this is too short. If in addition the supracondylar fractures are bedded upon an abduction splint or in a plaster cast, they can be held in an appropriate or fairly appropriate position. This frequently is really difficult without the medullary nail. In this case the plaster cast and the splint need not remain for a longer time than until enough callus had formed to hold the fracture in place. EHRLICH (13) and HAEBLER (14) point to the fact that with the nailed humerus a distension of the fragments may occur due to the weight of the arm alone, that means that the fragments are forced asunder. We also made this observation (Illustration 2). According to the observation of HAEBLER (15) distension of the fragments chiefly occurred with complicated fractures when, due to the impairment of the muscles, muscular traction was reduced. In such cases the danger of pseudarthrosis is imminent. One must anticipate it and make the proximal or distal nailing dependent on whether the nail will find a firm hold in the peripheral fragment. This will not always be the case. Therefore early roentgenoscopy is more important here than in any other case. The best evidence of instability of the fragments is the pain felt when they move. In many cases the pain reveals more than anything else whether or not the fracture is sufficiently immobilized. If there was a distension the fracture must be reduced again by jolting, and this condition must be maintained by the application of a splint or a plaster cast.

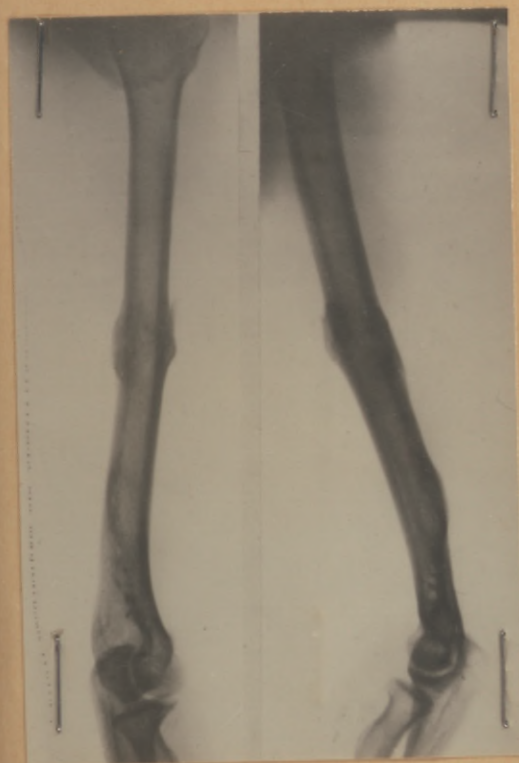BOEHLER prefers to exclude from nailing fractures less than 8 cm distant from the elbow joint, as he does not consider them suitable. We do not believe that every case of fracture of the collum chirurgicum is "very suitable" as the



1 a



1 b



1 c

Illustration 1.

- a) Before treatment
- b) Condition after medullary nailing from the distal end (a small piece of bone was cracked off on the nail insertion site).
Distension of the fragments.
- c) Condition after healing of fracture and removal of medullary nail.



nail to be driven in from the distal end only in rare cases finds such a firm hold in the spongiosa of the humerus head that one could say that it is not preferable to immobilize the collum fracture with conservative methods rather than with the medullary nail. Just because the retention of this type of fracture is usually successful even without medullary nailing we would like to regard medullary nailing as feasible but not as absolutely indicated. As with the fractures of the upper extremity there usually is no general indication for medullary nailing with the purpose of avoiding prolonged confinement to bed, treatment with the medullary nailing method is not necessary in such cases. BOEHLER also holds that the fractures of the collum chirurgicum may be nailed, but this wording reveals that it is not absolutely indicated.

Illustration 2.
Distension of fragments of a humerus fracture.

It is advisable to divide the humerus according to KUENTSCHER and MAATZ into four parts instead of the usual three; division in four parts is apt to prevent misunderstandings. HAEBLER stated that he recently applies medullary nailing from the distal end "only to fractures in the lower third". This opinion is easy to

defend as the nail driven in laterally through the corticalis will find a firm hold with its head there as well as the longer part of the nail in the long tube of the proximal fragment which is the case particularly when the most narrow part of the humerus is located in the proximal fragment and when the nail becomes securely stuck in it. If the distal fragment is very short, that means if the fracture is located in the distal quarter of the bone, the lateral insertion of the nail is difficult unless one comes so close to the elbow-joint that this is imperilled in its turn. Moreover with distal nailing one is bound to proceed very obliquely in a shallow curve through the corticalis to the medullary cavity. This may cause the cracking off of small bone fragments, an occurrence which as a rule does no harm though it is undesirable (Illustration 3). This will happen all the more easily, as when nailing from the distal end one is compelled to insert the nail very close to the fracture site, since there is no alternative if the fracture is located in the distal quarter of the bone. Although no sufficient fixation of these short fragments can be expected from nailing from the proximal end in view of the above mentioned disadvantage we would like to give preference to nailing from the proximal end in such cases, because it permits the retention of these types of fractures so easy to dislocate and because it prevents lateral displacement. When discussing the technique of medullary nailing we once again shall deal with the decision on whether

proximal or distal nailing should be applied. An additional bandage insures fixation.

b) Forearm.

KUENTSCHER and MAATZ are very liberal as regards the width of indication for the medullary nailing of forearm fractures. This is revealed by Illustration 4 taken from the book of these authors. The typical radius fracture of the distal end needs no medullary nailing, as treatment with the conservative method generally employed so far is usually sufficient. If this does not yield a satisfactory result, nailing also cannot improve the condition, since the distal fragment is too short to provide sufficient hold for the nail. Likewise the use of the medullary nail in cases of olecranon fractures has not proven successful as the bone which is spongy there does not hold the nail (KUENTSCHER and MAATZ). Only a few cases of olecranon fracture with a particularly long fragment are suitable for medullary nailing (Illustrations 5 and 6). BOEHLER considers all those forearm fractures as not suitable, "which with their distal end are less than 6 cm away from the joint". KUENTSCHER and MAATZ express it in a somewhat different manner but the result is practically the same when they state that "all those fractures are suitable for medullary nailing" the shorter fragment of which still has a medullary cavity long enough to permit the medullary nail to stick in it. "Very suitable" are the transverse

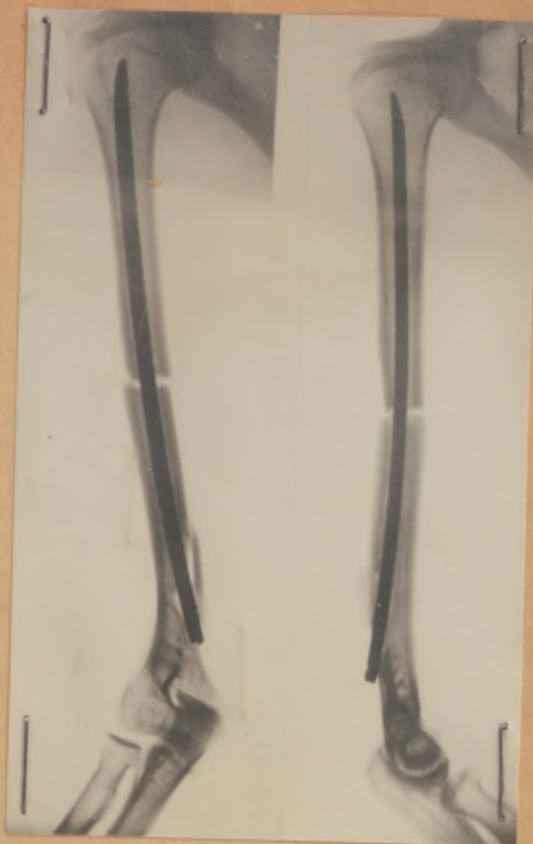

Illustration 3.
Cracking off of wedge-shaped piece of bone during insertion of nail.


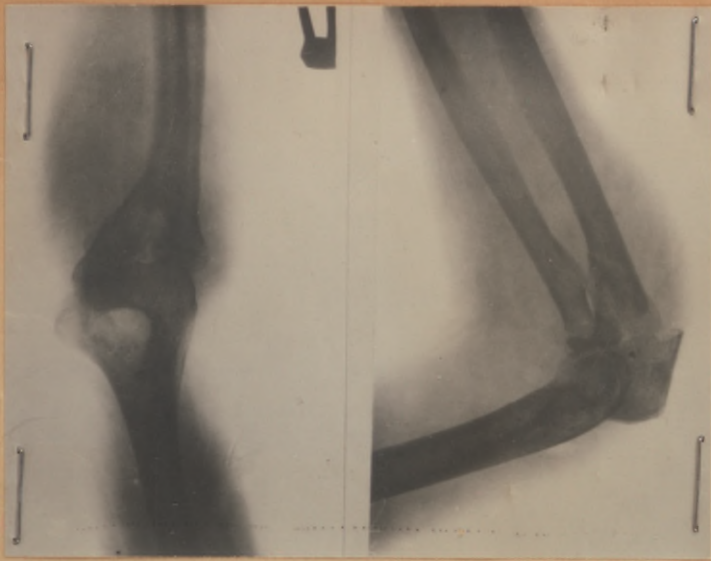
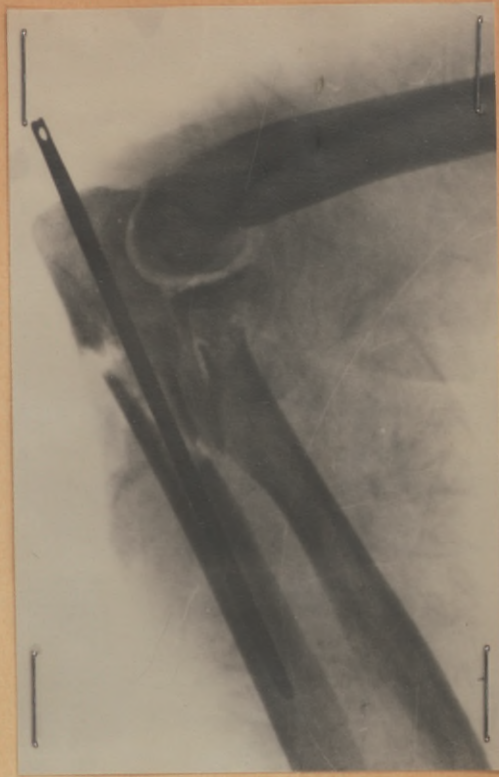


Illustration 4.
Width of indication for forearm (from KUENTSCHER and MAATZ, Technique of Medullary Nailing). All fractures within the shaded areas are suitable for medullary nailing.



5 a



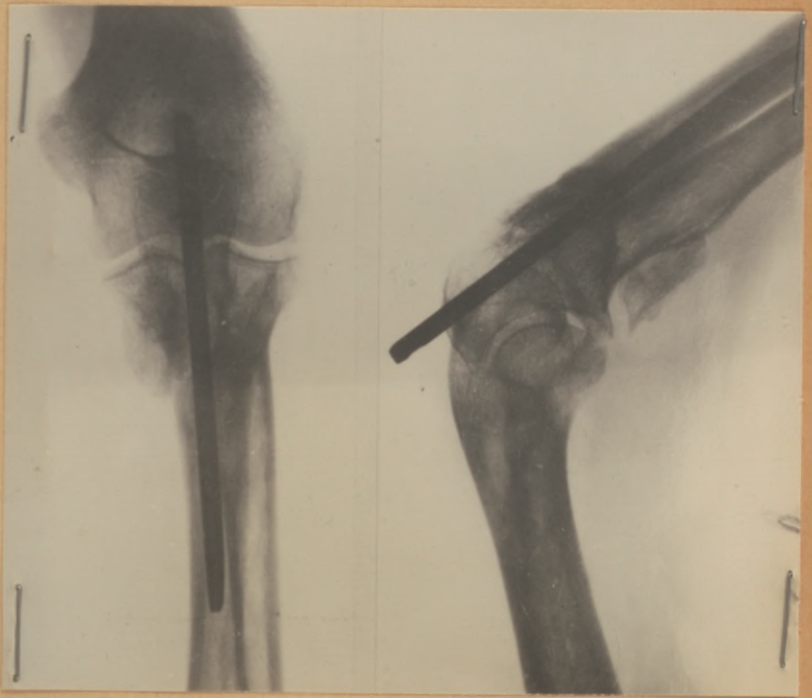
5 b

Illustration 5.

- a) Olecranon fracture and fracture of radius head.
- b) Condition after medullary nailing of olecranon fracture.



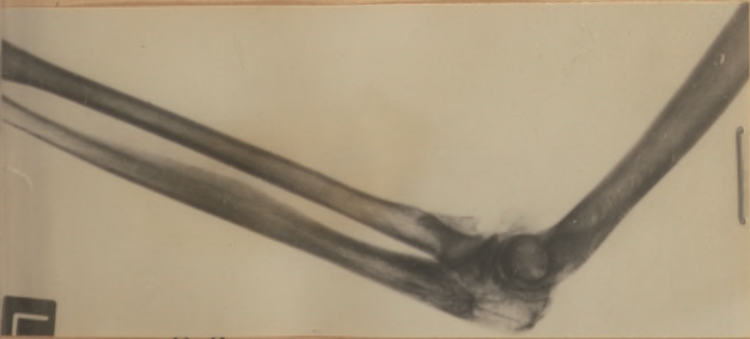6 a



6 b

Illustration 6.

- a) Olecranon fracture
- b) Condition after medullary nailing
- c) Restoration after removal of the nail.



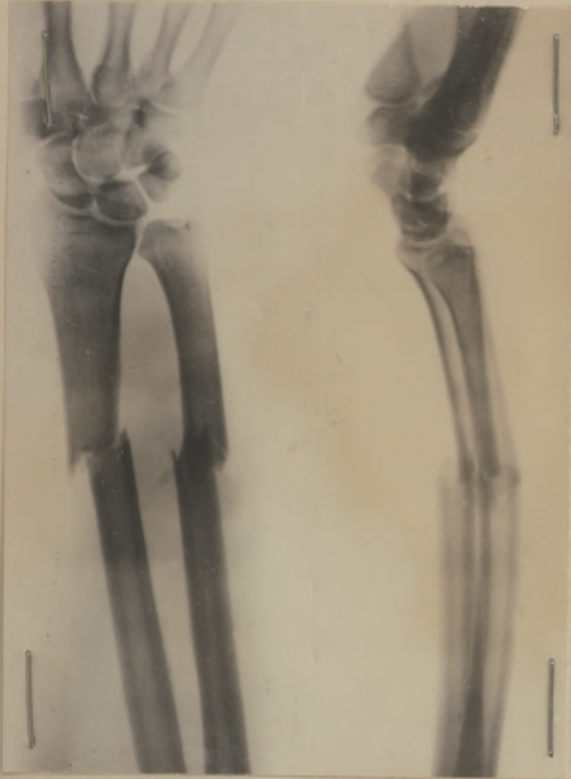6 c

fractures of the forearm which are located in the middle of the shaft of both bones. Moreover we would like to consider treatment with medullary nailing as particularly indicated in the case of oblique fractures of the middle of the shaft of the forearm, as it is a common experience that their reduction is difficult and that it is still more difficult to retain them in a good position by means of a plaster cast. This will then lead most frequently to an operative reduction, that means to the exposure of the fracture and to an operative immobilization of at least one of the fractured bones by means of one of the foreign bodies available for treatment so far. Infection and a delay of callus formation, however, are in the background as dangerous incidents.

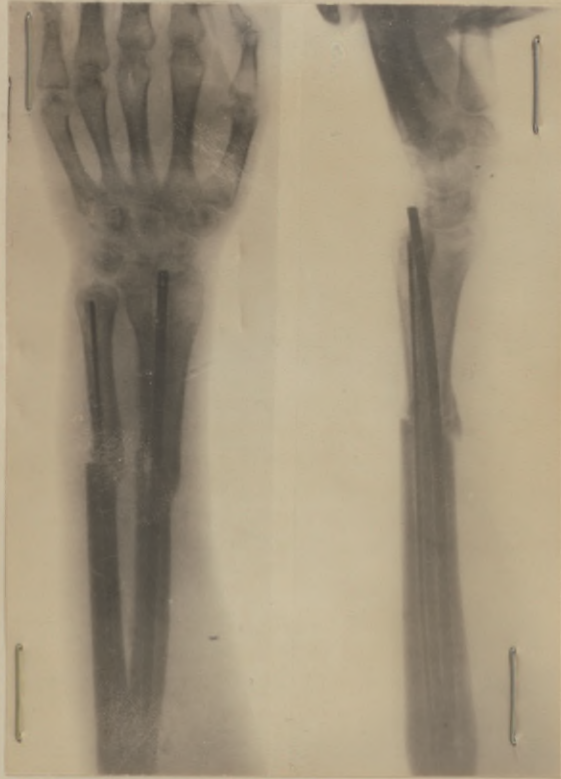No other method but medullary nailing is able to immobilize those fractures without an exposure of the fracture. HAEBLER too considers medullary nailing superior to such methods as e.g. the double-wire plaster cast. Operative reduction is not avoidable in every case; but if one is successful in accomplishing medullary nailing while the fracture remains closed, the hazards are reduced to a minimum. If the nails are firmly seated exercises may be taken up early; in a case published by MAATZ this was feasible after 10 days.

If only one of the bones of the forearm is fractured it should be nailed, if the two bones of the forearm are fractured it is advisable to nail both of them. Forearm fractures do not occur so frequently that every surgeon comes into a position to form his personal opinion about the suitability of the medullary nailing method for their treatment within a short period of time and with many cases. Therefore the literature shall be discussed here more thoroughly. Above all it had to be decided whether in the case of forearm fracture it is sufficient to nail one of the fractured bones and which of the two, radius or ulna should be subjected to medullary nailing in this case. BOEHLER e.g. applied medullary nailing in the case of a greenstick fracture of both forearm bones, first only to the radius and he obtained a satisfactory result of reduction of the ulna too. At first the callus also developed well on both of the bones, as the X-rays (16) show. After 5 weeks, however, the callus of the not-nailed ulna fracture was resorbed, while that of the radius remained excellent as regards shape and extent, and after 13 months there was a complete pseudarthrosis of the ulna while the radius fracture was consolidated by bone. This incident certainly is not the only case of that type and most probably it must be traced back to the fact that in the case of the not-nailed fracture the bone was resorbed within the range of the fracture cleft, as it can be frequently observed on X-ray pictures. The gap formed this way was not filled by callus and the nailing of the adjacent bone prevented the automatic union of the reduced fracture planes. Later on we shall have to deal several times with the problem of distension. With such a condition no stimulus for the formation of callus can be expected from the medullary nailing of the pseudarthrosis bridging-over the gap, as the firmly healed neighboring bone acts as a "distending bone". HAEBLER (17) employed other means, and he nailed the ulna, probably because the performance of medullary nailing with a straight nail from the tip of the olecranon is sim-

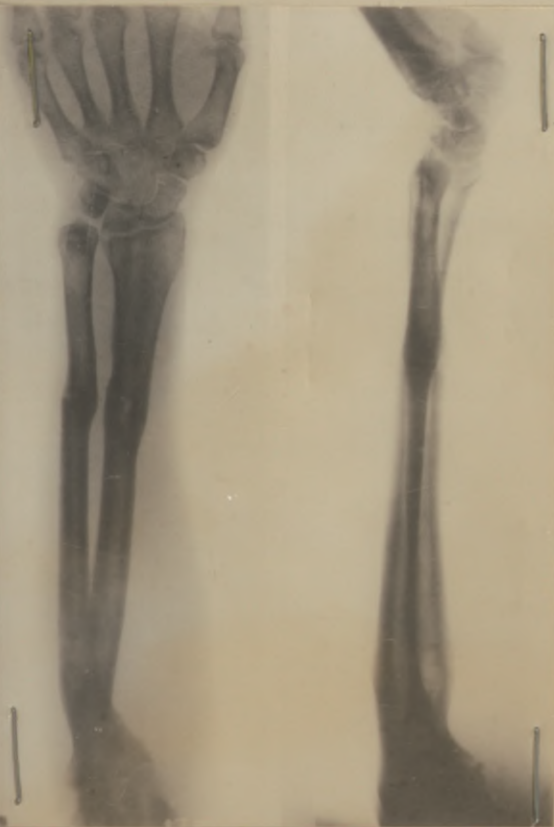ple and easy. His experience, however, brought forth the decision to nail the simultaneous radius fracture as well in spite of its being in a favorable position, because the proper objective of KUENTSCHER's method, the stable osteosynthesis, can only be achieved when both bones of the forearm are nailed. One must aim to attain this final result if one desires to start early exercises. If one were to renounce it and were to content oneself with plaster cast, in most of the cases medullary nailing even of one of the fractured forearm bones would not be necessary. If



7 a



7 b



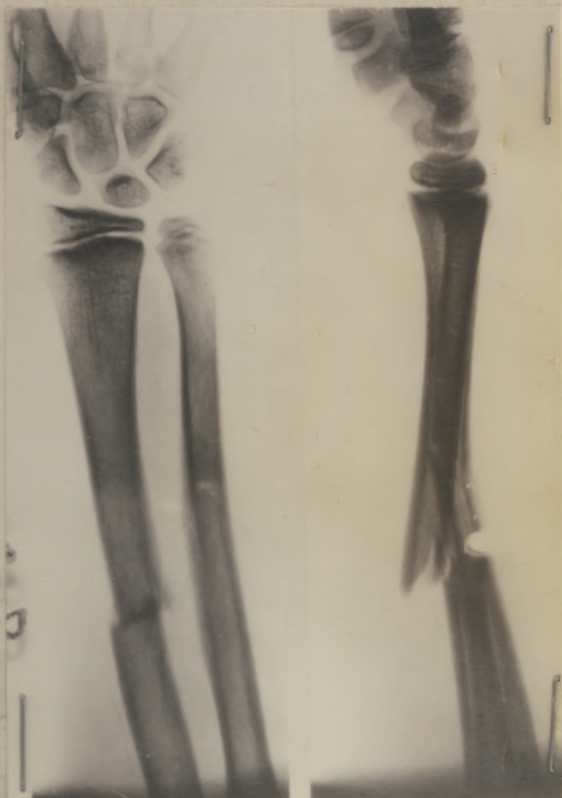7 c

Illustration 7.

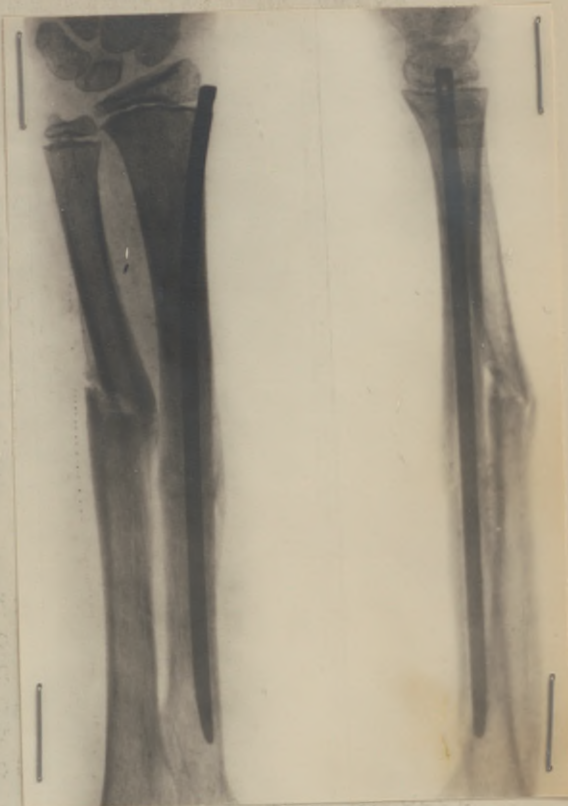- a) Forearm fracture
- b) Medullary nailing of both forearm bones
- c) Condition after healing of fracture and removal of medullary nails.

it is possible, however, to subject both bones to medullary nailing, KUENTSCHER's method in cases of forearm fractures doubtlessly yields better results than the other methods. The Giessen clinic was reluctant at first to apply medullary nailing to both forearm bones (Illustration 7) simultaneously. This is quite natural as formerly conservative fracture treatment was exercised in the clinic, and we shied from the use of met-

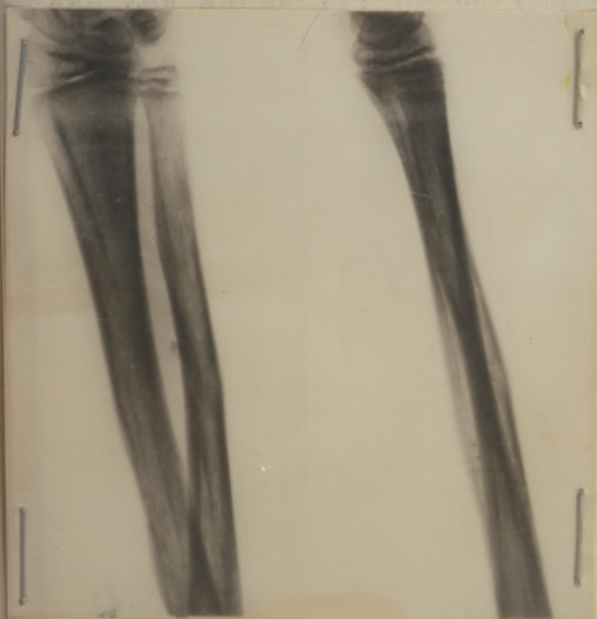allic foreign bodies of such a big size. The tendency to be satisfied in cases of forearm fractures with a purely conservative method is an explanation for why today only few experiences with medullary nailing of closed forearm fractures are available. The majority of cases represents open nailing with slowly healing fractures, with fractures healed in an unsatisfactory position, and with pseudarthroses after forearm fractures. At first we used to nail the radius. Ulnar pseudarthrosis as observed by BOEHLER, did not occur among our cases (Illustration 8), but in view of the small



8 a



8 b



8 c

Illustration 8.

- a) Fracture of the shaft of the forearm.
- b) Condition after nailing of radius
- c) Condition after healing of fracture of both bones and after removal of medullary nail.

number of forearm nailings performed in our clinic, this does not mean anything. For a critical evaluation of the method one failure is more important than many successful treatments, be they ever so satisfactory,

as it reveals the possibility of failures and suggests the measures of prevention. This observation and the opinion also held by HAEBLER that only by medullary nailing of both bones of the forearm a stable osteosynthesis is established induced us later to apply medullary nailing to both forearm bones. We should, however, like to warn not to enforce this goal under all circumstances, if there are technical difficulties or counter-indications of another nature.

c) Femur.

Medullary nailing was first performed on the femur. This is a natural consequence of the fact that the medullary cavity of the femur alone among the marrow cavities of the long bones resembles a straight tube. One can employ an absolutely straight and rigid nail. The insertion site which is located medially to the tip of the trochanter major permits the insertion of the guide-rod and of the nail right in the final direction. For this reason very favorable technical conditions prevail for the performance of the procedure. Nevertheless we must consider carefully what fractures of the femur shall be treated with medullary nailing (18). It is particularly BOEHLER who points out explicitly what hazards of operative fracture treatment too freely employed so far can be avoided by the KUENTSCHER method particularly in the case of the femur. The literature references about incidents including the death of the patient reported by BOEHLER (19) which have occurred in the course of operative fracture treatment involving the exposure of the fracture site are truly frightening. By means of KUENTSCHER's medullary nail, which is inserted far distant from the fracture site, this hazard can be eliminated in the majority of the cases. With the nail firmly seated the opportunity to take full advantage of the method is so great that it is worthwhile in every case to consider whether or not it is permissible to renounce this favorable outlook for treatment. BOEHLER is justified in raising objections against an uncritical operation of the femur fracture when there is only lateral displacement of the fragments the reposition of which according to his experience is not as important as to permit or indicate the exposure of the fracture. Lateral displacements will be easily corrected by medullary nailing as well. If, therefore, with closed femur fractures considered with a view to the site of the fracture, doubts are raised whether or not medullary nailing may be applied, that means if one is convinced that one is able to yield as satisfactory results by conservative treatment as by treatment with medullary nailing, the general indication is decisive. Age, general health, shorter or longer confinement to bed, and all other considerations of this kind will very frequently speak in favor of medullary nailing and with an increasing experience the decision to apply marrow nailing will become increasingly easier, as observed by ourselves and other surgeons.

A matter of greatest import is to accurately follow the rules for the reduction which in any case - here as well as with other bones - must be performed prior to medullary nailing. The marrow nail is no reduction appliance,

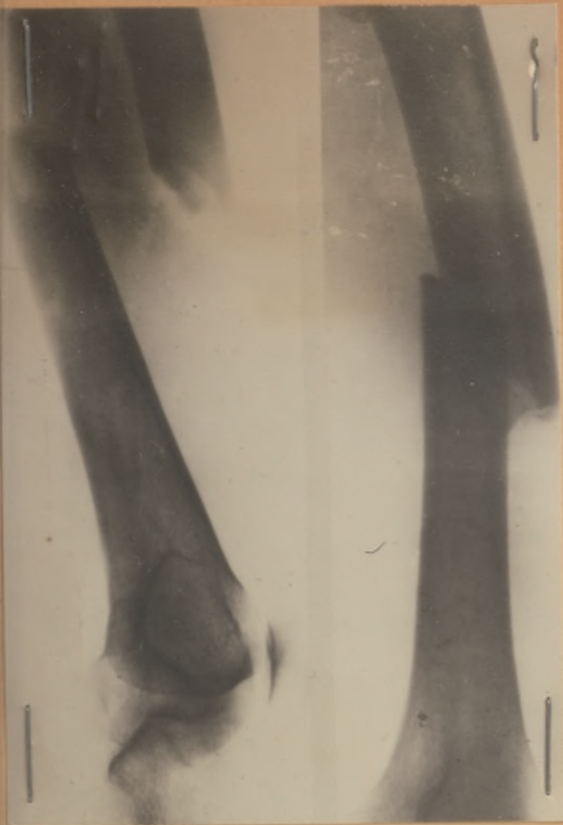but it merely serves for the purpose of retention; it constitutes a splint which is applied inside the bone instead of outside. Reference to this was made above, but it is just with the femur fracture that these elements must be observed with particular care, and it is for this reason that we would like to call attention to them once again when these fractures are discussed.

The technical performance of the medullary nailing of the femur sometimes may be easy and under favorable circumstances may be accomplished within ten minutes. But that should not lead to extend in the case of the femur the indications for the medullary nailing of fractures farther than with other bones, because if difficulties of technique occur it is particularly here that they cause complications involving even danger to life.

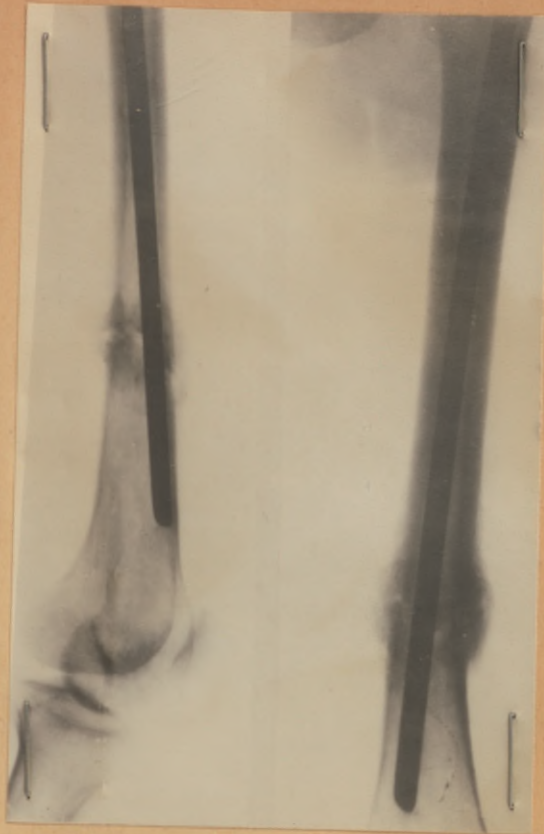The marrow cavity of the femur is larger than any other and in older persons it, therefore, has the greatest fat content, so that here the hazard of fat embolism is greater than with other bones. This finds its expression in the fact that the majority of fat emboli associated with the medullary nailing were observed particularly with the femur. Shock, position of the patient, spinal anesthesia, size of the nail as a foreign body, all these circumstances assume importance with the medullary nailing of the femur fractures which influence much more the whole organism than it is the case with fractures of the smaller bones. Therefore, with the femur fracture caution is advisable in every regard. After critical examination of the failures FISCHER and MAATZ (20) arrived at a similar opinion, and they wrote: "The deaths occurring after medullary nailing of the femur and the leg reveal that this operation which really is not great may be the decisive factor for the fatal result when there are other simultaneous injuries. This does not mean that some of the patients would not have died if marrow nailing was not performed".

HAEBLER goes so far as to contend that medullary nailing of the femur is more difficult than any other type of medullary nailing. This fact, however, is traced back by him to the difficulties of reduction. More recently with increasing experience his opinion might no longer be valid in this pointed manner. The technique of reduction will be discussed in detail below.

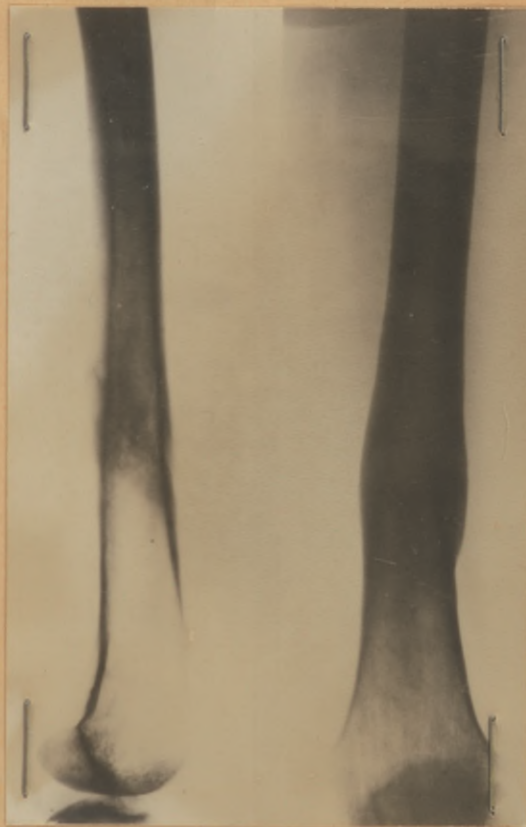The technical difficulties may be set aside to a great extent, nevertheless there remains the question of what is the indication for the medullary nailing of the various types of femur fractures. Particularly suited for medullary nailing are the transverse and the oblique fractures (Illustration 9, 10, 11). According to KUENTSCHER and MAATZ the most suitable range for medullary nailing of the femur shaft fracture is located at least 6 cm below the trochanter major and at least 8 cm above the condyles. Medullary nailing was extraordinarily successful in case of multiple fractures (Illustration 12) the fragments of which can be threaded upon the nail (see also BOEHLER (21) and EHALT (22)). For the treatment of the subtrochanteric fractures a specially shaped nail is required (see Technique). The long spiral fractures are less suitable, as with these the medullary nail frequently does not find sufficient support, and as it is not



9 a



9 b



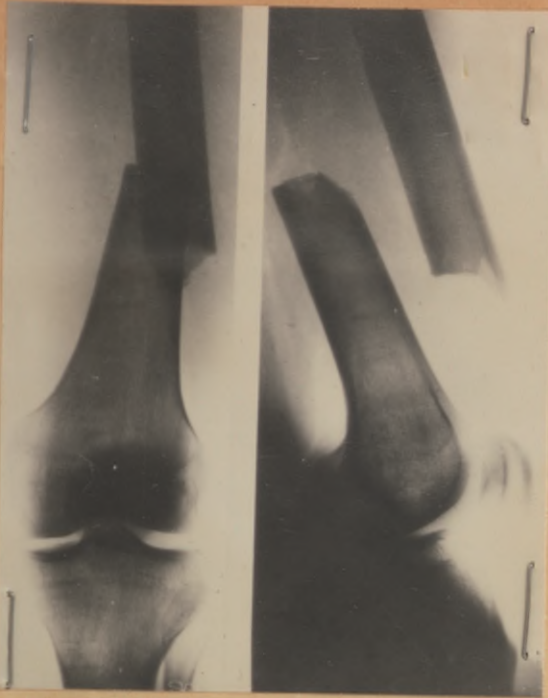9 c

Illustration 9.

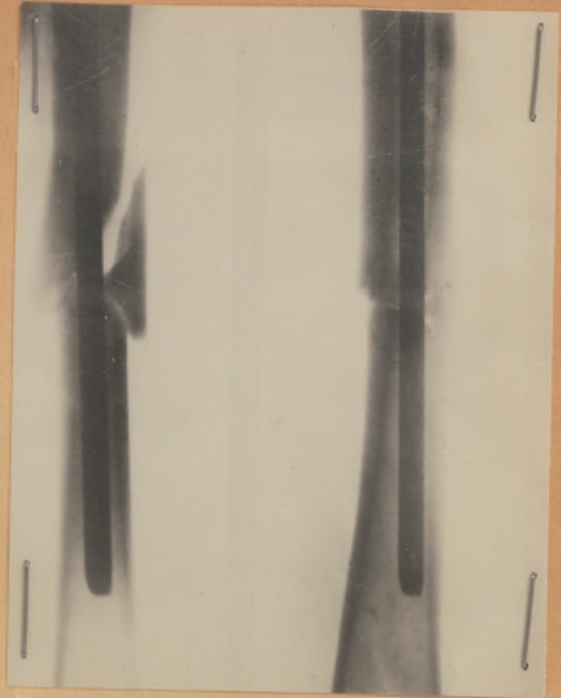- a) Short oblique fracture of femur shaft
- b) Condition after medullary nailing
- c) Condition after healing of fracture and removal of medullary nail.

possible to avoid the danger of rotation. Nevertheless excellent results may be obtained with the spiral fractures (Illustration 13 and 14). As soon as additional supports such as plaster bandages or wire extension are required for the retention of the fracture, the medullary nailing method is deprived of its most essential advantage: immobilization while movement is unimpeded. Here it becomes a doubtful procedure again, as in such cases the question arises whether it is permissible to apply medullary

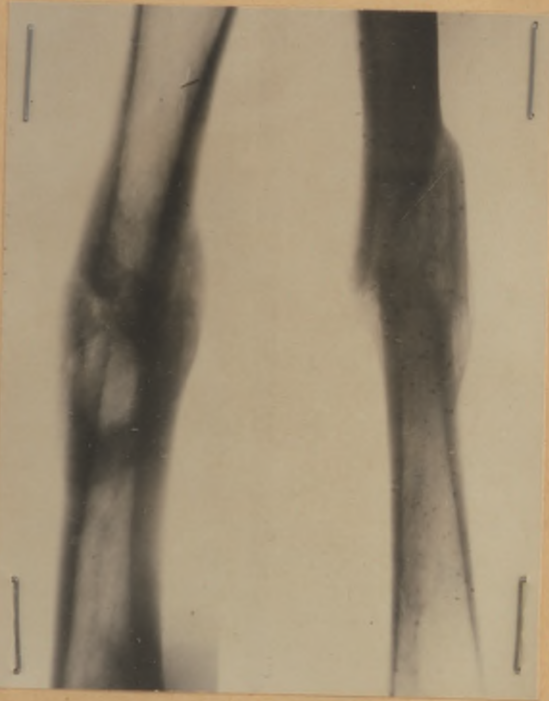nailing if its superiority cannot be fully exhausted, and whether one rather is not obliged to renounce its use and to spare the patient this operation which under favorable



10 a



10 b



10 c

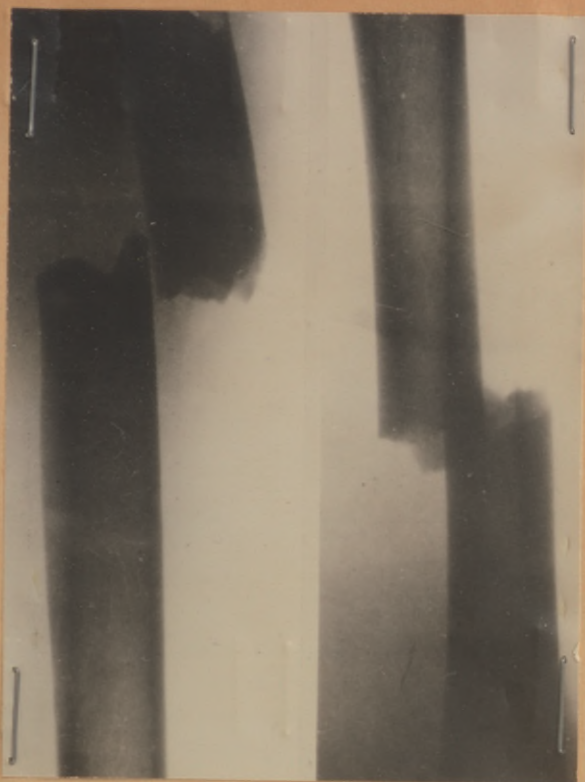Illustration 10.

- a) Short oblique fracture of femur
- b) Condition after medullary nailing.
Cracked off bone piece
- c) Condition after healing of fracture and removal of medullary nail.

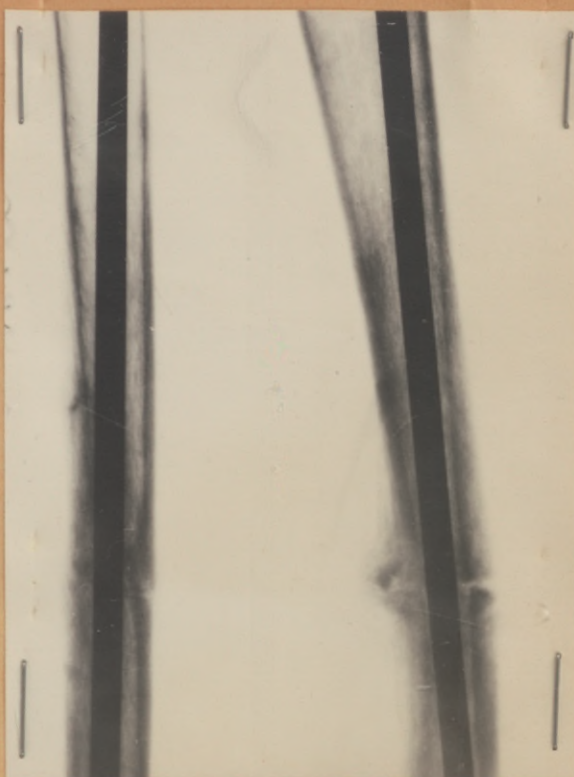
conditions, however, eliminates all disadvantages of the conservative method.

A type of femur fracture whose treatment, as is well known, may cause considerable inconvenience is the supracondylar fracture. With this type of fracture one constant-

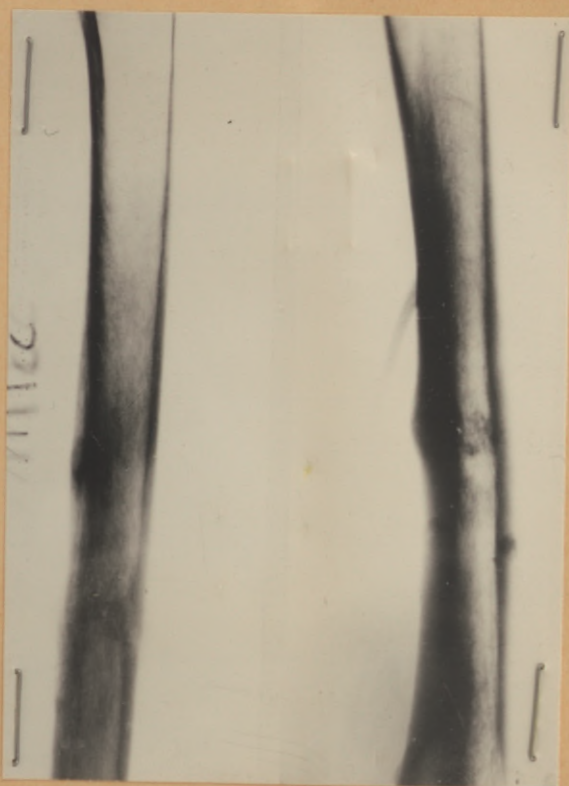
ly has to oppose the tendency of the peripheral fragment to deviate at an angle from the longitudinal axis and it is particularly here that many methods were suggested endeavoring e.g. to accomplish treatment with several wires pierced through the bone. Due to the shortness of the distal fragment with these fractures a satisfactory mechanical fixation of the medullary nail will be possible in very rare cases only. Here the conditions are somewhat similar to those prevailing with the supracondylar fracture of the humerus. But par-



11 a




11 b



11 c

Illustration 11.

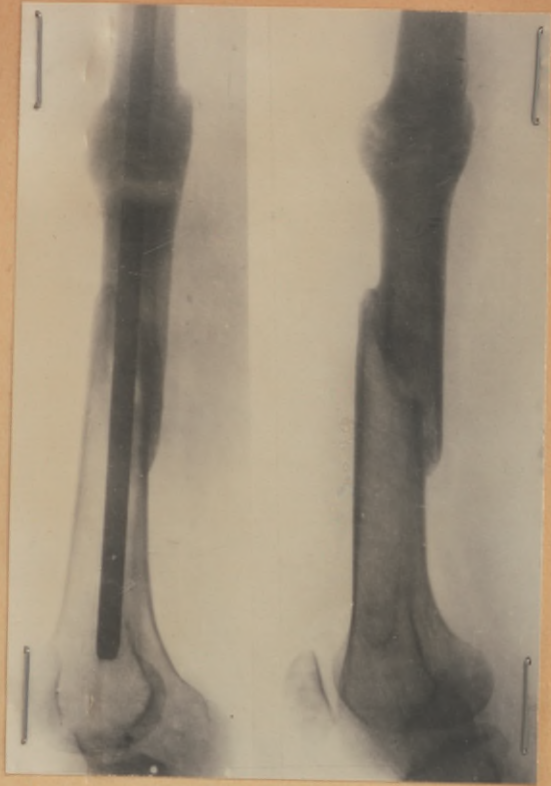- a) Transverse fracture of femur
- b) Condition after medullary nailing
- c) Condition after healing of fracture and removal of medullary nail. Formation of bone resembling exostosis above fracture.



12 a



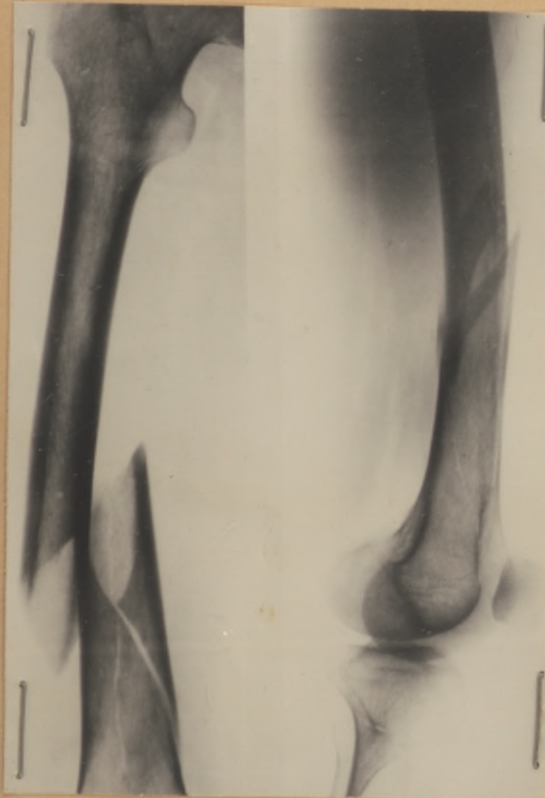12 b



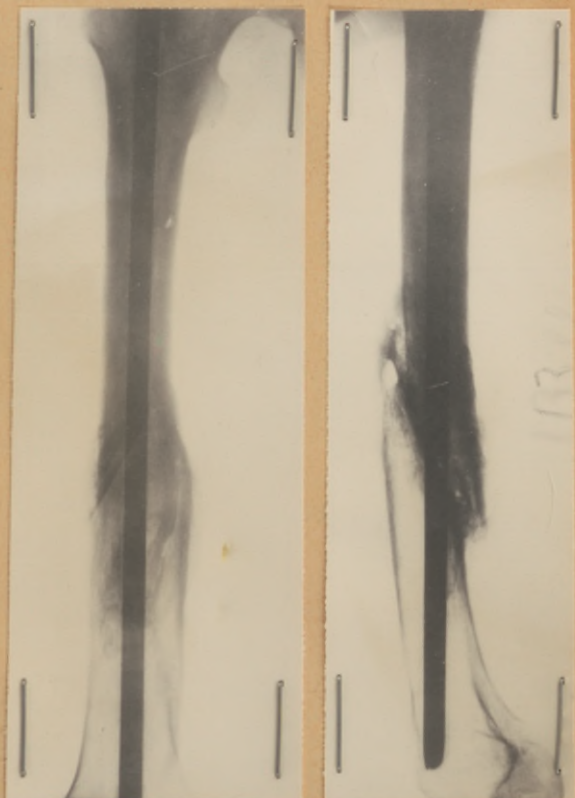
12 c

Illustration 12.

- a) Multiple fracture of femur
- b) Multiple fracture of femur threaded upon medullary nail
- c) Condition after healing of fracture and removal of nail.



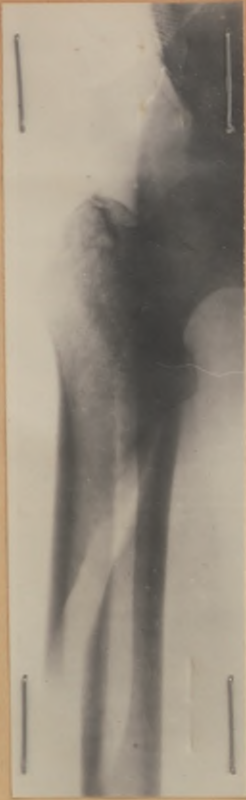13 a



13 b

Illustration 13.

- a) Spiral fracture of femur with fracture line extending to knee-joint (leg of same extremity amputated)
- b) Condition after medullary nailing and progressive state of fracture healing. Five years after medullary nailing the nail is still in place without causing discomfort.



14 a



14 b

Illustration 14.

- a) Long spiral fracture of femur
- b) Condition after medullary nailing and progressive state of fracture healing.

particularly with these fractures medullary nailing is very helpful as it prevents the distal fragment from angulation. There is no other method to effect it with the same security. Here the nail acts as a pin or a bolt. KUENTSCHER and MAATZ therefore consider the supracondylar femur fracture as "very suitable" for medullary nailing. Even though an additional support (plaster bandage extending over the whole extremity) is indispensable (after KUENTSCHER and MAATZ for 4 weeks) the favorable outlook for a satisfactory result and for the possibility of early exercises leads to the decision to perform medullary nailing in the case of this type of fracture too. Extending the width of indication we purposely go beyond HAEBLER's postulate to nail the supracondylar femur fracture only in those cases "in which one does not succeed in retaining the reduction by a plaster bandage or permanent extension".

d) Leg.

The indication for the medullary nailing of the leg fractures to a great extent depends on mechanical factors. One may begin by stating that only the tibia has to be nailed, while medullary nailing of the fibula can always be omitted and no other surgeons practicing medullary nailing perform it. The medullary cavity of the tibia varies in width. As usual the nail fits best in the most narrow

part which is located at the borderline between the middle and lower third. For this reason osteosynthesis is most successful if it is applied to the transverse fractures occurring at this level. EHALT considers medullary nailing the most appropriate treatment of this type of fracture. As the diameter and the shape of the nail must conform with the medullary cavity a really stable osteosynthesis cannot be accomplished with those fractures of the tibia which are located in other parts of this bone. The experience gathered with the so-called spread-nail is not wide enough to permit final opinion on it. KUENTSCHER and MAATZ attempted to give a yardstick for the indication for medullary nailing of the leg. As in many cases their hints are very useful for the decision of whether or not medullary nailing should be performed, they will be given here once more:

"The minimum length of the shorter fragment cannot be given in centimeter values, as the shape of the medullary cavity is in the decisive factor. If there is a great discrepancy between the smallest and largest diameter of the medullary cavity, that means if there is a considerable disproportion between the thickness of the nail and the width of the marrow cavity, the range of the fractures "suitable for medullary nailing" moves towards the middle of the length of the shaft. The borderline begins where the difference between the diameter of the medullary cavity (m) and the diameter of the nail (n) is equal to or greater than the diameter of the bone cylinder (k), so that the fragments no longer are compelled to stand upon each other, but rather that one fragment can topple off the other " (Illustration 15). We shall be faced with this problem once more when we discuss the selection of the nail.

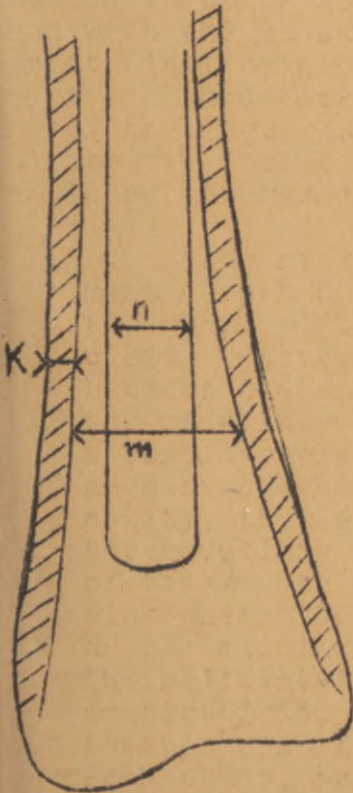


Illustration 15.

For fractures of the leg the proportion of the diameter of the medullary nail (n), the diameter of the medullary cavity at a level with the fracture (m), and the diameter of the bone mantle (k) is decisive. Here the equation is valid: $m - n = \text{or} < k =$ "suitable" according to the shape of the fracture.

$m - n > k$
"not suitable"

(From KUENTSCHER and MAATZ: Technique of Medullary Nailing).

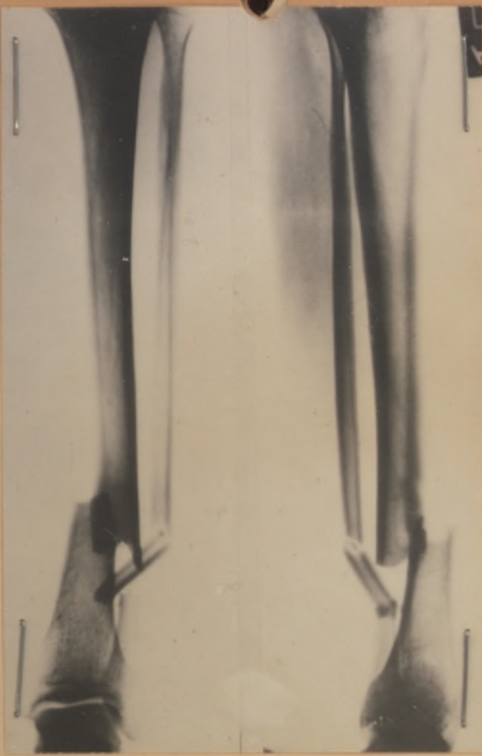After the medullary nailing of leg fractures one frequently is compelled to employ an external support in form of bedding the limb on a splint or in a plaster cast. For this reason the objection is justified that with such a treatment of the fracture the characteristics of medullary nailing, the stable internal immobilization, are not brought to bear and that therefore it is not quite intelligible why medullary nailing should be employed at all, if an additional plaster cast is necessary. This is true to a certain degree and therefore the indication for the nailing in cases of leg fractures must be examined with special care. Experience shows that with some types of fracture medullary nailing doubtlessly is justified, as it yields better results than the conservative methods. Its superiority finds its expression in the excellent retention, the restriction to short plaster bandages not extending over the knee-joint, markedly earlier mobility of joints than with conservative treatment, and an earlier feasibility to subject the fractured bone to weight-bearing. All this reduces the period of confinement to bed and hospitalization considerably (Illustration 16). These are points of view which are of a certain bearing for the decision whether or not medullary nailing should be performed. Even though no stable fixation can be accomplished by the nail it can be of excellent service in many cases by preventing the fragments from dislocation or bending.

The operation as such, frequently is very easy to perform, but here, too, difficulties may arise which rather refer to after-treatment so that the easy technique alone should not be decisive for the indication if other factors speak against medullary nailing. Time and again KUENTSCHER's thesis is quoted that the nailing of the leg "may be considered as one of the easiest operations known". This only refers to the typical cases and KUENTSCHER applied it expressly to these alone, but there are surgeons with a lesser experience and who are all too ready to overlook this restriction in KUENTSCHER's statements. Therefore HAEBLER, too, underlines the difficulties which arise particularly with the medullary nailing of old fractures. In the chapter dealing with the technique of medullary nailing we shall show how to overcome them.

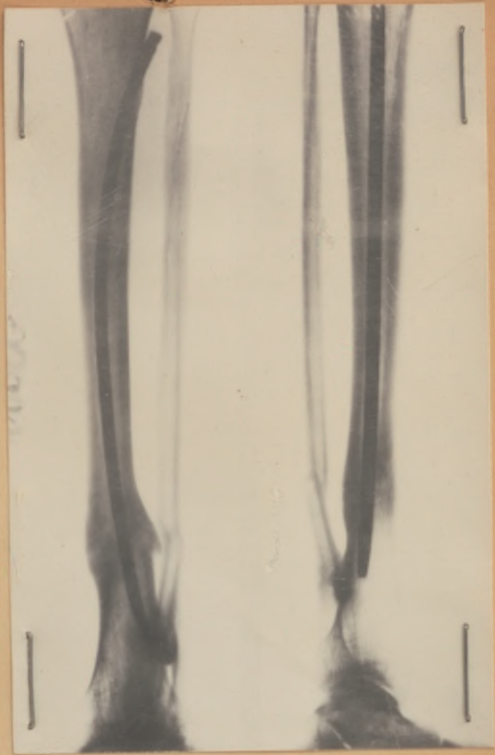
Not suited for medullary nailing are the fractures immediately above the tuberositas tibiae and close to the upper foot joint.

On the whole one may say about the medullary nailing of leg fractures that it is indicated to a lesser degree than that of the other extremities. The reason for this was explained above. In addition one should not expect that other difficulties arising during the treatment of leg fractures are entirely eliminated by medullary nailing. Thus, e.g. there is the problem of the fibula acting as a distending-bone and the delay of the healing of the tibia after medullary nailing which is linked to that. Slowly healing though nailed fractures of the tibia, therefore, should not be considered as a drawback of the method, as the mechanical conditions implied in the presence of two bones or the biological fact of the consolidation of the fibula fracture frequently setting in earlier, cannot be eliminated.

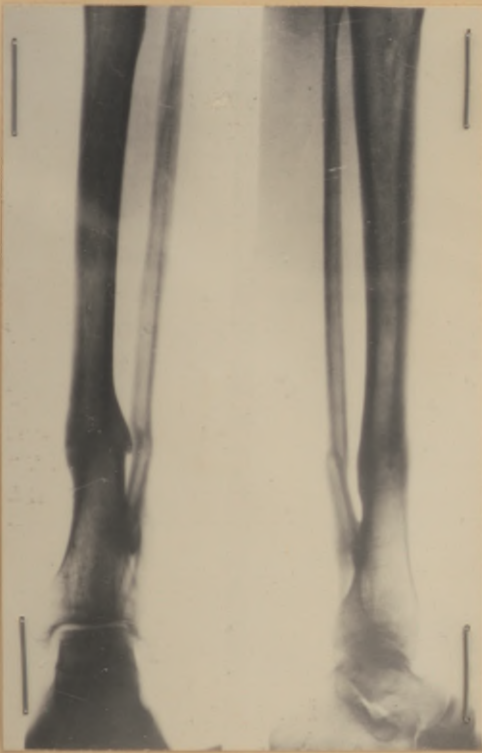As regards the indication for medullary nailing of leg fractures, therefore several clear directives of a general



16 a



16 b



16 c

Illustration 16.

- a) Low transverse fracture of leg
- b) Condition after medullary nailing
- c) Condition after healing of fracture and removal of nail.

and local nature can be established. The general considerations refer to the age of the patient, to the condition of his circulatory system, and to the hazard of fat embolism, for which the period of time elapsed since the injury may play a certain role (obstruction of the pressure valve through a big pressurized fracture hematoma or by formation of callus which has already set in); the local considerations depend on the

type of the fracture, whether simple or compound, or the technical possibilities originating from the mechanical conditions, and on the hazard of infection. As in every difficult operation a certain play must be given to the skill, the experience, and the temperament of the surgeon.

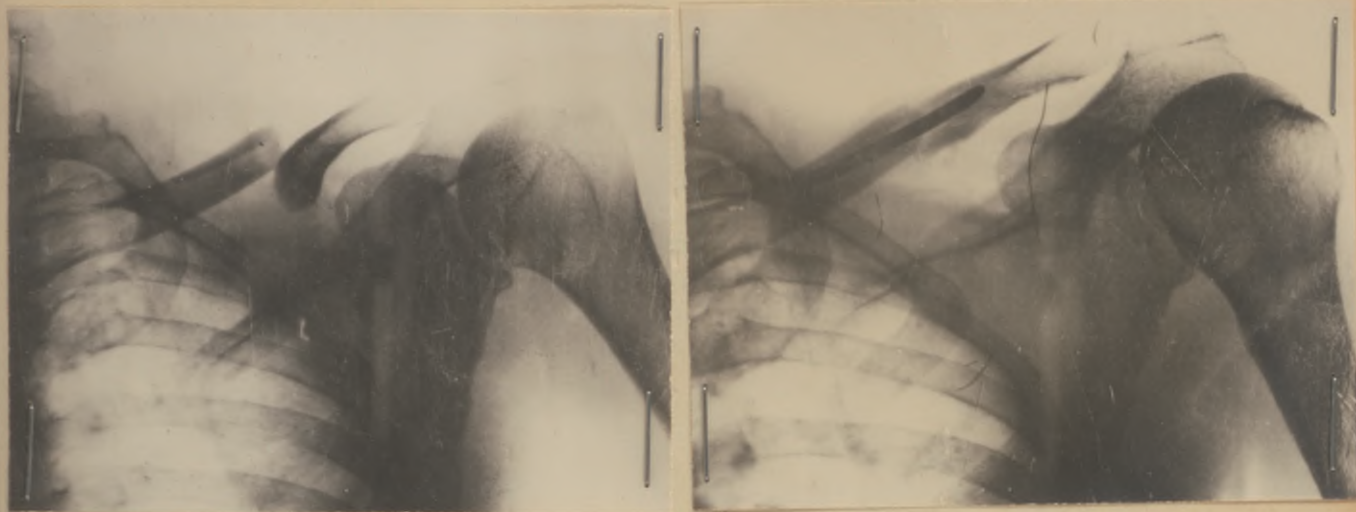
This is a purely individual or psychologic factor and it must seriously be taken into account, because it seems to have a decisive influence upon the views held with regard to medullary nailing. This has been mentioned several times, and any surgeon about to apply medullary nailing should consider this factor as much as any other as decisive for the indication for medullary nailing. With almost all surgeons examining the method the observation may be made that from initial doubt their attitude gradually changes to acceptance and the same happened to us. From now on opinions will differ. There are surgeons who become enthusiastic about medullary nailing and increasingly fond of it. This shows in the choice of the alternative beginning with the question which fracture must be nailed by all means and progressing to the other extreme which fracture cannot be nailed as yet under the present circumstances. The more critical surgeons who are less enthusiastic form an opinion on the positive and the negative side of the problem. This does not mean that they are able to weigh the advantages and disadvantages of the method systematically but rather that their decision is accompanied by never ceasing doubts and the concern about the right means to be applied. It certainly is not incidental that such an experienced emergency surgeon as LORENZ BOEHLER devoted a special chapter to the psychology of the surgeon in the third volume of his book on the technique of fracture treatment which deals exclusively with medullary nailing.

The technique of medullary nailing may be easy and it may be performed quickly and elegantly, but every person with experience knows that incidents may occur which can be controlled or predicted only after long surgical practice. This has nothing to do with surgical dexterity but it may occur in every operation. Just as during an appendectomy one may be faced with unusual situations which cannot be overcome by a less experienced surgeon though thoroughly in command of the typical operation, medullary nailing as belonging to the major operations frequently may be accompanied by difficulties which for their elimination require the skill and a certain undeterminable factor of mastership that can only be acquired by extensive professional experience. Therefore medullary nailing should not be considered as an intervention which is always easy and in no case should it be assigned to an insufficiently trained assistant.

The surgical clinic at Giessen as one of the first to take up medullary nailing was fully aware of its responsibility for the injured and it first began within very confined limits to check and develop the method. Since the experience gained was favorable the clinic was able to widen the indication gradually in the course of the last years. This was done under critical evaluation of every single case and under regular comparison of the current reporting of other surgeons, particularly of the Kiel school which, as the inaugurator of medullary nailing, "naturally was very liberal in the use of the method in order to test it" (FISCHER and MAATZ). In the beginning we therefore subjected only simple fractures to medullary nailing and among these preferably those of the femur, since the superiority of the new method over all others practiced so far was particularly obvious here. The experience permitting the widening of the range of application of medullary nailing and the

particularities with regard to the selection of the case as well as the increasing security and refinement of the technique leading to the same result, are revealed best by the publication of our material and the success and the failures obtained with it.

Medullary nailing of the clavicle is only indicated if there is a considerable dislocation of the fragments and if reduction cannot be accomplished with conservative methods. This is rarely the case. Sometimes, however, the pressure upon the brachial plexus urges operation (Illustration 17).



a

b

Illustration 17.

- a) Fracture of clavícula
- b) Condition after medullary nailing.

Formation of callus sets in.

TECHNIQUE OF PERCUTANEOUS MEDULLARY NAILING OF SIMPLE FRACTURES.

Prior to any discussion of the special problems associated with medullary nailing the technique shall be described as employed in all the cases of the Giessen clinic and as it has developed there in the course of the last years. This will be preceded by an account of all those matters and appliances which are fundamental for every medullary nailing. The finer technical development which has proven necessary or useful for some types of fractures shall be demonstrated when the respective section of the extremities and the treatment of its fractures will be discussed.

Concerning the numerous variations of the technique (armamentarium etc.) special reference is made to the description by KUENTSCHER and MAATZ. We are not so much concerned with an exhausting description of the appliances and instruments and their use, but rather with the demonstration of our personal procedure, and although it is not free from subjective judgement we hope that it will be useful for those surgeons who like ourselves are compelled today to rely on a minimum of technical devices, due to the great difficulties in the procurement of instruments and appliances.

The technique of medullary nailing is still in the stage of development. If we add another technical chapter to the literature on the Kuentscher-nailing despite the fact that there are already several publications by several outstanding orthopedic surgeons, we are guided by two considerations. The emergency of our time has made us particularly conscious of the shortage of technical equipment and the inability to manufacture special devices for this very technical method in Germany. This urges the restriction to a very simple technique in the field of medullary nailing. This may even be considered as an advantage. Thus attention is focussed on the harmony between physiology and technics, biology and mechanics. On the other hand one should not forget that particularly in fracture treatment, where there is a preponderance of the mechanical requirements, a specified technical outfit simplifies the execution of the tasks even for those technically less endowed, improves the results, and thus best serves the patient. Seen from this angle we must regret many a gap in our equipment as being a considerable disadvantage. When describing our experiences and results, however, the description of the methods by which they were obtained is a matter of necessity.

The lack of a practical reduction appliance was always considered a particular handicap. The exact anatomic reduction of the fragments should always precede medullary nailing, because only in this way does the operation remain a relatively minor procedure. One must postulate that such an appliance secures retention of the fragments at least during the insertion of the nail. This postulate is apparently met by the reduction appliance of MAATZ (23)(24). We do not dispose of this "Kiel model" and we had to rely on auxiliary devices. Other reduction appliances have been designed specially for the leg and the humerus by LINSMAYER (25) and by WITTMOSER (26). We always had excellent results with BOEHLER's screw extension apparatus which was of special use for the medullary nailing of the leg fractures. BOEHLER (27) also described special devices.

Another difficulty lies in the manufacture of special types of medullary nails. We, as well as most surgeons, are dependent upon using machined marrow nails available commercially. It is quite obvious that the nail really should be specially shaped according to the bone for which it is intended. The ideal condition would be that for every bone an appropriately fitting nail could be chosen or manufactured. Apart from the fact that today there are no means as yet to transmit the dimensions of the bone onto the medullary nail, as the shape of the foot is transmitted onto the foot support, there are, nevertheless, certain cases in which the special manufacture of the medullary nail determined in its shape by the bone or by the shape of the fracture would be desirable. It would at least be an advantage to dispose of a stock of specially shaped medullary nails in addition to the nail sets presently available. Such nails were recommended by KUENTSCHER and MAATZ for particularly wide medullary cavities. Moreover it is desirable to dispose of nails armed with saw-teeth for the perforation of those sections of the medullary cavity which are obstructed by solid callus. They are required when refractures or fractures with a delayed callus formation are to be nailed.

An indispensable requirement for medullary nailing is an extension table or an operating table with an attachable extension appliance. It is quite out of the question to undertake medullary nailing without extension appliances, and no surgeon should be allowed to attempt such an enterprise relying on his technical skill, and it should be considered as an obvious lack of responsibility if such a thing were to occur. For the medullary nailing of the lower leg something like BOEHLER'S screw extension apparatus also is indispensable. Lacking the special apparatus, extension appliances for all directions must be available for reduction.

A further basic requirement moreover is sufficient assistance. This refers to a lesser extent to the operation itself which with the so-called percutaneous medullary nailing is a minor operation only. Only medullary nailing combined with an exposure of the fracture and operative reduction necessitate the presence of one or two assistant surgeons. This does not go beyond the practice employed in all other operations. When commencing even the seemingly most **simple** medullary nailing operation, one must be prepared in case unforeseeable circumstances suddenly require operative reduction. In this case the operation is considerably more extensive. In cases where unsuccessful efforts force one to extend the operation, the procedure should be concluded as promptly and carefully as possible. Such action should not be handicapped by insufficient assistance. One therefore can only give the urgent advice not to begin by underestimating marrow nailing as an operation and little service is rendered to the patient, to the method, and to the reputation of the responsible surgeon by a failure. This may also be considered as a hint to the fact that no medullary nailing should be undertaken in hospitals with an insufficient number of medical personnel. The special role of the fluoroscopist shall be mentioned below.

One of the most important requirements is a suitable X-ray apparatus. It should be possible to screen the nailed extremity on the operating or extension table as well as to take X-ray pictures of it. It would be most appropriate, of course, to have two X-rays at hand, as fluoroscopy should always be available in two planes and as the readjustment of a single X-ray tube requires some time during which the reduced fracture may be disturbed. Reduction, therefore, is always checked with the fluoroscope; it even would be preferable to accomplish it under fluoroscopic observation, at least as far as the final adjustment is concerned. Then it usually is easy to introduce the medullary nail. The length of the medullary nail may also be determined before the insertion by simply laying it along the injured extremity with simultaneous fluoroscopy. From these conditions the question emerged repeatedly who really is the more important person during medullary nailing, the surgeon operating the fluoroscope or the surgeon driving the nail in, because there is no doubt that the most important part of medullary nailing is reduction for which the screening surgeon is responsible. The maintenance of asepsis seldom permits the operating surgeon to check the result of reduction himself. There is nothing more disastrous during medullary nailing than insufficient asepsis. Though the most important part is assigned to the fluoroscopist, and the operator has to rely

fully on him, we always maintained that the full responsibility for medullary nailing lies on the shoulders of the operating surgeon who accomplishes the operation proper, be it ever so small and easy to perform. Screening is a matter of the assistant. However, one may also proceed otherwise, making it more easy for the operating surgeon to bear the responsibility: he is to reduce the fragments first and immobilize them by an appropriate appliance or by reliable extension appliances, to prevent the fragments from re-dislocation while the nail is introduced. Only after reduction is performed are the hands to be scrubbed and the medullary nail driven in. In this case the screening assistant is charged with the task of checking the fitting of the nail in the medullary cavity, the passing of the fracture site, and of checking the lower limit to which the tip of the nail may or shall be hammered in. Little time is lost when such a procedure is employed, and through the certainty about the position of the fragments as well as the personal knowledge about the conditions prevalent in the fracture obtained during reduction, as well as by the recognition of the tendency of the fragments to dislocate, this loss of time is amply balanced for the operating surgeon. Such observations sometimes exert a considerable influence on the introduction of the nail. Thus, for instance, in some instances successful passing of the fracture site is only possible, when the tip of the nail is pointed downwards or to one side. These are details of technique which may be decisive for the practical performance of the operation.

Medullary nailings should not be performed without a portable roentgenoscope, the so-called cryptoscope (Illustration 18). Roentgenograms are no substitute for the control of the



Illustration 18.

Cryptoscope according to BRAUN. For operation and reduction the surgeon looks through a "noephan" glass (specially smoked glass) without taking off the cryptoscope (after BOEHLER: Technique of Fracture Treatment).

mobile fragments and it may frequently happen that unforeseen difficulties of reduction occur requiring so many roentgenograms in two planes that the whole operation becomes expensive and dangerous to the patient and the staff. When proceeding with the aid of the cryptoscope strict attention has to be paid that neither the roentgenologist nor the entire operating group are exposed to the damaging effect of

the X-rays. The medical personnel should endeavor to protect themselves against the X-rays, the effect of which adds up with frequent medullary nailing. The patient is exposed to the irradiation only for the short period of the surgical part of the intervention. BOEHLER devoted a short but impressive chapter of his book to the problem of protection against irradiation.

There is not much to be said about the basic stock of instruments (Illustration 19). It does not require mentioning that the medullary nails should be available in all usual lengths and diameters.




Illustration 19.
Instruments for medullary nailing.

Experience has shown, however, that some surgeons were so eager to begin with medullary nailing that they commenced it without even having an extraction instrument (28). This, however, is just as important as the nail and hammer, because it is by no means the rule that the first nail will fit correctly with the first insertion. If in such a case one is compelled to extract it again, one will be astonished in the beginning of the great amount of force necessary for this and all other solutions will either not lead to the desired result at all, or only after prolonged attempts. All this can be avoided by using an extraction instrument. We have always obtained very good results with the so-called extraction-hook and the slotted extraction-hammer. We had unsatisfactory results with the construction of a traction pulley, in which a wire threaded through the nailhole was wound up on a windlass and pulled the nail out of the medullary cavity. The wires broke, or the windlass pressed into the bone and caused inconvenience by tissue damage (29). Nevertheless it may occur that no force is able to move the nail forwards or backwards. Then the only means is to saw it off level with the wound. Therefore a metal saw which can be sterilized also belongs to the standard set of instruments. In such cases one must wait until the bone atrophy setting in around the nail in the course of time permits the removal of the remnants of the nail after a few months. The fracture then of course cannot be treated by medullary nailing, and the conservative methods must be used.

After this short discussion regarding the appliances and instruments which are the same in all types of medullary nailing, the special details for each type of fracture will be described. In accordance with the purpose of this treatise we shall confine ourselves to our own method. References concerning discrepancies from the general literature shall be given wherever necessary. We will assume that we have to deal only with simple fractures and for better survey we shall at first describe only that part of the technique which is typical.


a) Humerus.

The technique to be applied on the humerus shall be described in all details with the purpose of outlining our technic as completely as possible, as many particulars can be shown which are repeated with every medullary nailing so that one can refer to them when the remaining extremities are discussed.


For the medullary nailing of humerus fractures we either employed general anaesthesia or plexus anaesthesia. The latter makes the intervention as a whole less trying, but we contend that it is not permissible to insist on the performance of medullary nailing under plexus anaesthesia. When the patients are very anxious or nervous, general anaesthesia is more convenient for the surgeon as well as for the patient. Finally one must consider whether or not reduction can be effected without the complete elimination of the muscular tension. Local anaesthesia was employed in very rare cases only, and even KUENTSCHER and MAATZ have recommended it only with the forearm. BOEHLER shows more liking for local anaesthesia, but for the humerus he prefers conduction anaesthesia, while for the lower extremity he is more fond of spinal anaesthesia. Generally speaking local or conduction anaesthesia offers the advantage of facilitating the bedding of the patient.

A matter of the greatest importance for any kind of reduction is the position (Illustration 20) of the body and of the extremity and three requirements must be fulfilled: One of them is to accomplish the reduction of the fragments as smoothly as possible, another to take care that the nailing procedure can be performed without a second change of the position. The third requirement is that the fluoroscopy which is indispensable for the two above mentioned procedures should not be impeded by the position of the patient. During the medullary nailing of the humerus the patient is to be laid in dorsal recumbent position and the shoulder of the injured side should slightly project over the edge of the operating table. BOEHLER used to put the injured extremity in his screw extension apparatus. The thorax has to be fixed to the operating table with a large unpadded belt which is applied closely below the axilla. The shoulder joint as well as the elbow joint are bent to 90 degrees. Thus it usually is easy to accomplish the reduction of the humerus fractures by extension and counter-extension - if necessary by means of a wire pierced through the proximal end of the ulna. KUENTSCHER and MAATZ recommend traction with a cuff applied to the hand while the arm is extended and abducted by 45 degrees in the

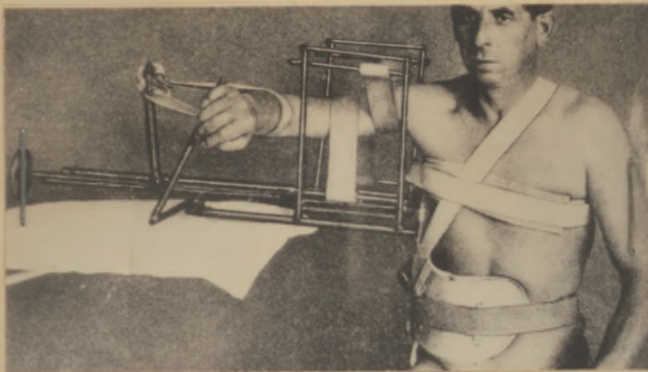
shoulder joint. If there is no extension apparatus care has to be taken that a sufficient number of assistants are present who are strong enough to keep the reduced fracture in the position desired.



a



b



c

Illustration 20.

- a) Position for humerus nailing in the screw extension apparatus after BOEHLER
- b) Position for humerus nailing after LINSMAYER
- c) Position for humerus nailing after WITTMOSER (From BOEHLER, Technique of Fracture Treatment)
- d) Position for humerus nailing after KUENTSCHER and MAATZ (From Technique of Medullary Nailing)



d

The medullary nail has to be selected of appropriate length and diameter. Its length does not depend on the length of the fractured bone, but it rather must be taken into account that the medullary nail will have to extend from the insertion site to the upper or lower portion of the bone; it therefore has always to be shorter than the bone. The length of the medullary nail, however, may also be determined after the area to be operated is draped by placing the nail upon the covering sheet, and then its length can directly be compared by fluoroscopy with the bone. The determination of the correct diameter of the medullary nail causes more difficulties. Its thickness has to depend on the most narrow part of the medullary cavity. Too thin a nail does not provide a stable osteosynthesis. In this case the fragments will be loose and the operation will end as a failure. If the nail is too thick it may not be possible to drive it beyond the most narrow part of the cavity. Still more harm is done by forceful insertion of too thick a nail with the final result that the bone bursts asunder. Although this seems to be a rare occurrence it means a hazard involving an injury which should be avoided by all means. Sometimes smaller parts of the bone are cracked off in the area near the fracture. Even though it does not result in an irreparable damage it means a lack of care chargeable to the operating surgeon. KUENTSCHER and MAATZ recommended a "metal scale" to be laid alongside at a level with the bone before the first roentgenogram of the fracture is taken. If the focal ray is directed through the scale and the center of the bone, an equivalent perspective is obtained upon the X-ray film. Every step of the scale is 2 mm. long. The steps are valid for the longitudinal axis of the extremity and thus it can be avoided that the torsion of the measuring scale acts as a source of errors. Thus the width of the medullary cavity can be read off with the first roentgenogram taken. BOEHLER, as well as ourselves, so far has had no reason to use this auxiliary. With the usual focal distance of 80 cm., which must remain the same for all pictures, 1 mm. must be subtracted from the medullary cavity shown on the roentgenogram of the humerus, because of the enlargement of the proportions caused by the distance of the bone from the film. The lumen of the most narrow part varies between 6 and 9 mm. in adults. It really makes no difference which method is employed, as long as it is always the same. A free estimate of the thickness of the nail is in no case reliable.

With fractures of the humerus the surgeon must decide whether he is to drive the nail in from the proximal or from the distal end. Experience revealed that especially in the case of the humerus a really stable osteosynthesis has not always been obtained. There were axial angulations occurring after nailing or it happened that subsequent to the operation the fracture-cleft was gaping when the arm hung down and when it was not placed in an additional splint. These failures were particularly observed with the fractures of the humerus above the middle and after the insertion of the nail from the distal end. The explanation for these failures is implied in the mechanical condition created by the shape of the medullary tube and its relation to the nail. These relations may be demonstrated by a schematic design in the form of a construction plan (Illustration 21).

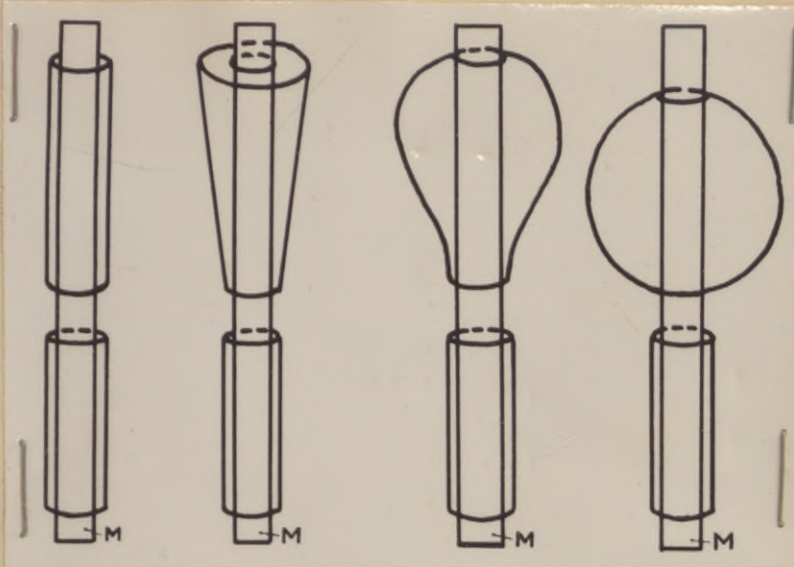


Illustration 21.

Schematic demonstration of the points of attachment of the medullary nail in cases of differing widths of the medullary cavity of both fragments.

The medullary cavities of both fragments form two cylindrical tubes the upper of which, in accordance with the width of the medullary cavity of the humerus, increases towards the proximal end and assumes the form of a hollow cone, of a pear, or in extreme cases of a ball. The internal immobilization within such a system can only then guarantee a sufficient stability if it is applied in every fragment on two different points at varying levels. This accomplishment generally has to be aimed for in every case of medullary nailing, no matter what bone is involved. In cases of fracture in the upper and middle third, except for the subcapital fractures, it is recommendable to perform nailing from the proximal end. Then the medullary nail finds a firm hold in the proximal fragment at the point where it perforates the corticalis, and torsion is prevented, while the lower part of the nail by internal mechanical friction is jammed in the relatively long section of the medullary cavity which at this place is more narrow. If the fracture is located near the borderline of the lower third or still farther below, it is more advisable to insert the nail from the distal end, as in this case the short distal fragment is retained by the nail jammed in its corticalis and as the long friction surface lies in the upper parts. We have pointed out above that for reasons of clarity in the nailing technique KUENTSCHER and MAATZ divide the humerus in quarters. They do this principally with the purpose to discuss their proceeding in the case of a very short proximal or distal fragment. These short first or fourth quarters cannot be fixed with either end of the nail to such an extent that a firm fixation is obtained. We doubt whether medullary nailing from the distal end recommended for the treatment of fracture in the first (proximal) quarter, really offers such a firm hold to the tip of the nail located in the spongiosa

of the upper part of the humerus that an additional support becomes superfluous and immediate exercises can be taken up. We believe that subcapital fractures of the humerus are not suited for medullary nailing. In case of a fracture in the upper quarter, which is located only a little below the typical subcapital fracture, medullary nailing from the proximal end is usually impossible, since it may easily occur that the short fragment splinters when the nail is driven in and since the medullary nail does not obtain the hold desired if this happens. Moreover there is the danger that the fracture hematoma is opened when the incision is made over a fragment which is too short. This has to be avoided by all means as it would be equivalent to the exposure of the fracture site. This is a point which has to be considered in all cases. Medullary nailing from the distal end in these cases can only serve the purpose to prevent the fragments from sliding off and therefore represents only an aid to the retention accomplished by the application of a splint, of a plaster cast, or by extension, but it does not represent the retention appliance proper. The same is valid for the fractures in the lower quarter. There are exceptions from this rule and quite in contrast to the above mentioned considerations they even gave good results. They will be discussed later when the special experiences of our clinic will be recorded. Here we want to describe the typical procedure to be established as a rule. For the decision whether a humerus fracture is to be nailed from the proximal or distal end the approximate rule may be set that the tip of the nail should be located in the shorter fragment if this is very short. Therefore fractures in the upper quarter have to be nailed from the distal end, those in the lower quarter from the proximal end (KUENTSCHER and MAATZ); this shall, however, not be maintained as a schematic dogma, but it only should facilitate the choice of the direction from which the medullary nail is inserted in individual cases.

When the medullary nail is driven in from the proximal end, the insertion site is located closely below the tuberculum majus, that means on the anterior side and slightly lateral when the patient is in the position as outlined above. One must keep to this spot as otherwise one easily penetrates into the subdeltoid sulcus or as it may occur that the nail hits the acromion during abduction. After blunt separation of the deltoid musculature the muscle parts are held apart by hooks. Then one feels one's way with the left index finger to the bone. It is not absolutely necessary to have the bone under direct view. Then the awl is set onto the bone under the direction of the finger and the oblique tract is pierced through the corticalis extending into the medullary cavity. The oblique course of the perforation is most important for the insertion of the nail. We made the experience that there is no need to widen the hole made with the awl with a chisel or a drill, provided the awl is thick enough to pierce a hole large enough for the tip of the medullary nail. The awl may be used simultaneously as a guide rod for the nail and the first hammer-blows may be made with the awl in place. The medullary nail is driven in under an angle as small as practicable, that means as close along the longitudinal axis of the bone as possible, until it can be anticipated that its tip has arrived at the fracture cleft. If the medullary nail meets with resistance beforehand, a fact frequently to be recognized by a change in the note of the hammer-blows, the tip has caught in the

compacta in the opposite wall of the medullary cavity, and it must be withdrawn slightly or driven back, and one should try to diminish the angle still more. This really harmless incident can almost always be avoided if the hole pierced with the awl is bored as obliquely as possible.

As soon as the nail-tip reaches the fracture cleft the assistant in charge of fluoroscopy has to increase his activities and it becomes obvious now that accurate reduction means a great advantage for the performance of medullary nailing. If the fragments are fitted well upon each other, the nail tip slides without any difficulty into the medullary cavity of the distal fragment and then the most problematic moment of the whole procedure is overcome. In the case of a failure, when the nail-tip comes to lie beside the distal bone in the fracture cleft or when it is caught in the corticalis of the distal fragment, an assistant has to correct the reduction according to the directives of the fluoroscopist. If there is a multiple fracture with more than two fragments, medullary nailing, so to speak, aims at threading the fragments upon the medullary nail. With this type of fracture it is due to the mechanical conditions and quite natural that accurate reduction prior to the act of threading the fragments is not always possible, as the traction exerted for reduction usually has no influence upon the middle fragments. In this case the prominent part of the medullary nail after reaching the fracture cleft can be used as a handle to move the fragment above the nail and the operating surgeon accomplishes threading according to the directions of the fluoroscopist. Regular attention should be paid to the X-ray tube working at intervals only so that the patient as well as the operating team are hit by the X-rays as little as possible. This is easy to perform, if the fluoroscopist lights the X-ray tube only when the cryptoscope is adjusted so that no prolonged search for the fracture cleft or the nail tip is required. This shows clearly that the entire operation is composed of seeming trifles the systematic observation of which, however, is indispensable for a smooth and continuous course of the operation.

For the medullary nailing of the humerus, the tibia, and of the forearm bones, double nails are usually employed, that means coupled nails the thinner of which fits exactly into the groove of the thicker nail. One usually begins to nail with the thicker nail and after passing the fracture cleft one drives it in so far that the external part of the nail is about 5 or 6 cm. long. Prior to the insertion of the second nail which principally serves the purpose of stabilizing the hold of the nail with regard to the torsion of the fracture - that means dislocatio ad peripheriam - it is absolutely necessary to ascertain whether or not torsion of the fragments has taken place. In this stage of the operation it can be reduced without any difficulty.

Now the inner nail is driven in further, until it is at a level with the outer nail, and the final insertion of both nails together can now be accomplished. With the medullary nailing of the humerus during this stage the assistant must exert strong counterpressure against the elbow, as the nail should be firmly wedged in the medullary cavity which towards the distal end narrows conically. Therefore it sometimes is appropriate if the interior thinner nail

is longer by 1 cm. than the exterior nail.

The roentgenologist should check the distance of the nail-tip from the elbow-joint, which should be as small as possible. If the length of the nail was estimated correctly, the eye of the nail is visible just above the periosteum at the upper end. When medullary nailing is finished, the fracture is wedged together by strong blows with the thenar of the assistant pressing against the elbow. The skin suture and a dressing finish the operation.

Subsequently roentgenograms are made in two planes at right angles to each other. The films must be large enough to demonstrate the relation of the fragments to each other and the fit of the nail at the fracture site and at the elbow-joint. This is important to avoid overlooking complications, as now the injured limb will be left alone for a long time. Curvation at the fracture site which easily occurs due to the considerable bending tension of the medullary nail, may be straightened over a well padded wooden wedge without any particular inconvenience.

When medullary nailing is effected from the distal end of the humerus, the position in principle is the same as with medullary nailing from the proximal end. The medullary nail is inserted from a site 1 or 2 cm. above the fossa olecrani on the extensor side. It is advisable to select a medullary nail which is as long as possible, so that due to its long friction surface in the spongiosa it finds a firm hold in the medullary cavity widening towards the proximal end. The skin incision should be 3 or 4 cm. long extending along the longitudinal axis; the triceps is bluntly separated. The awl most appropriately is pierced through at a level with the upper angle of the skin incision, because it thus is possible to avoid a further injury of the skin by the pressure and the friction of the penetrating nail which during insertion must be guided at a very small angle to the bone. At this place the bone frequently is so hard that the awl does not perforate it. Then the chisel or the drill-cutter must be used to bore a hole into the corticalis. This hole should be located exactly over the longitudinal axis of the bone, as it may occur otherwise that the medullary cavity is missed. With a very hard bone the hole must be large enough to give access to the nail without its getting jammed. If the drilled hole is very close to the distal end, the nail sometimes meets osseous substance overbridging the medullary cavity in the form of transverse trabeculae. These must also be perforated with the awl so that the prepared drill channel not infrequently has a length of several centimeters. In this case it renders good service for a firm fixation of the medullary nail. As for the rest the insertion of the double nail is accomplished as it was just described for the proximal nailing of the humerus. The first thicker nail sometimes shows the tendency to be driven forward too, as its thinner partner is driven in. This involves the danger of it being driven in too far and entering the shoulder joint with its tip; it may also occur that its distal end disappears in the medullary cavity. This hazard of course is present whenever double nails are employed, no matter what type of fracture is treated. One can avoid this hazard by fixing the nails by means of a single-pronged hook or by a retraction hook. Before the final 4 to 6 cm. is covered, the extension is released so that the fracture can be wedged together. The assistant

surgeon pushes vigorously against the shoulder. Finally the skin is sutured and, if necessary, angulations are straightened out and roentgenograms taken.

Due to the variable diameter of the medullary cavity of the humerus the mechanical conditions for a really stable union of the fragments are not always favorable, and even after a technically faultless performance of medullary nailing under consideration of all mechanical peculiarities small wabbling movements and rotary movements are not infrequently observed. Only with the transverse fractures close to the middle of the shaft may one be fairly sure that no additional external support will be required. In all other cases an abduction cast or bedding on an abduction splint for several weeks is advisable. For such cases which appeared appropriately immobilized and for which as a matter of security an immobilizing bandage seemed to be desirable, a U-shaped plaster splint has proved useful. It should begin in the axilla, embrace the elbow joint bend at right angles and then extend to the shoulder joint at the lateral side. It has to remain in place for 3 or 4 weeks. This plaster splint permits extended movement of the shoulder joint and it does not hamper the use of the hand; together with the nail it is really useful. It is certain that the cleft of the fragments which may occur on the humerus after the operation and which is caused by the weight of the forearm and the lower fragment, is frequently eliminated by such a U-shaped splint. If this complication of after-treatment occurs nevertheless, a circular plaster-cast must be applied.

The responsibility for the dismissal of the patient and for ambulatory treatment can be borne after 10 or 14 days if the healing of the wound takes a normal course, A fluoroscopic control at intervals of 4 weeks will show the progress of the healing of the fracture.

The removal of the nail is only to be undertaken if the bony consolidation of the fracture is completely terminated. There is no reason to insist on an early removal of the nail. With local anesthesia the head of the nail is approached through the old scar and the nail is extracted by means of a single-pronged hook or another extraction instrument.

b) Forearm.

The medullary nails for the ulna and the radius vary with the shape of the two bones. Those destined for the ulna are straight, those destined for the radius are slightly curved, similar to the humerus nails, and sometimes the medullary cavity of the ulna is so confined in space that even the thinnest medullary nails with a V-shaped cross-section have no room in them. In such cases strong Kirschner-wires may be employed for a sufficient interior immobilization. For the determination of the length of the nail, which can be accomplished by directly holding it to the thin coat of soft tissue through which the bone can be felt or seen, attention has to be paid that the nail extends beyond the fracture cleft by at least 4 cm. The longer the medullary nail, the better its hold will be.

For anaesthesia plexus anaesthesia deserves preference, provided that no objective or subjective reasons are opposed to it. The reduction particularly of the transverse fractures of the forearm not infrequently is a very complicated procedure which can be accomplished only with difficulties requiring a considerable amount of time. It is particularly because of the long period of time sometimes to be taken into account for reduction alone and to be added to the time required for the medullary nailing itself that we consider plexus anaesthesia more conservative for the patient than general anaesthesia.

Stress should always be laid upon a correct position of the patient, and the personnel should be trained to regularly place the patient in the same position. Thus, all manipulations are accomplished in a way which can only be achieved by straightforward proceeding and by training. This will save many an inconvenience for the patient and the operating surgeon, and the whole procedure consisting of reduction and medullary nailing will be as sparing as possible. The patient is put upon the operating table in dorsal recumbent position. The humerus is abducted in the shoulder joint by slightly more than 90° . Around the upper arm close above the elbow-joint a padded belt pulls the arm in horizontal direction opposite to the direction of the forearm which is bent to an angle of 80° at the elbow-joint and runs parallel to the longitudinal axis of the body, the hand pointing towards the foot. The actual traction effecting reduction is applied to the hand. It is all the same whether a cotton glove is fixed to the hand with mastix or whether a gauze bandage stuck to it is employed, or whether according to the suggestion of KUENTSCHER and MAATZ a "devil's-grip" extension is applied to every finger and then connected by a cord with a spreading-bow which in its turn is linked to a pulley. We preferred to exert traction by hand, one hand holding the thumb, the other the remaining fingers. KUENTSCHER and MAATZ discovered a very ingenious maneuver by fixing the patient upon the operating table with a counter-traction applied to the foot of the healthy side (Illustration 22).

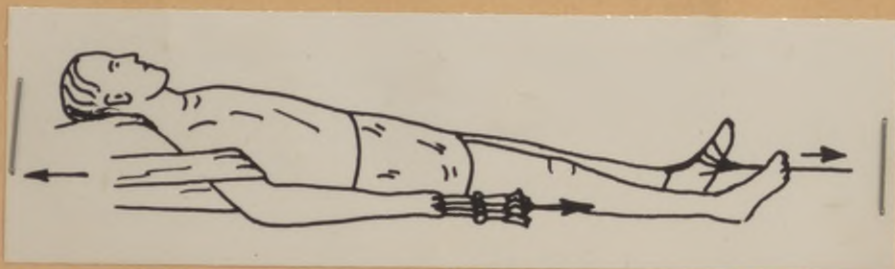


Illustration 22.

Position for forearm nailing.
(From KUENTSCHER and MAATZ:
Technique of Medullary Nail-
ing).

If no such measures are taken it may occur that during the reduction procedure the whole mechanical conditions are altered so that in the case of a failure of the reduction one

is compelled to restore the original position and to repeat the manipulation. We have had no personal experience with special reduction devices. If one relies on the rules given above, reduction as well as medullary nailing usually offer no difficulties.

The medullary nail for the ulna is driven in from the olecranon. A longitudinal incision 1 or 2 cm. in length is made over the tip of the elbow, and access is obtained to the medullary cavity by opening it with the awl on the posterior edge of the olecranon through the insertion site of the triceps tendon. The longitudinal axis of the bone must be observed with utmost accuracy to avoid a faulty direction. It is not absolutely necessary to employ a guide-rod in the shape of a thick Kirschner-wire, but in some cases it facilitates the procedure. When the nail has passed the fracture cleft, the extension is released, and the assistant grasping the wrist presses vigorously against the direction in which the nail is driven in. The nail is hammered in so far that its eye just projects from the bone. If one lets the nail project too far, it exerts pressure upon the thin skin and causes discomfort when the elbow-joint is moved. The skin is sutured and a roentgenogram is taken. Usually there is no need to correct curvatures.

If there is only a fracture of the ulna, no additional immobilizing dressing is required. When employing a Kirschner wire for internal immobilization we attach a padded dorsal splint to the arm reaching from the bases of the metacarpals to the elbow and leave it in place for about 3 weeks.

For medullary nailing of the radius the nail is inserted from the distal end. The position is the same as in medullary nailing of the ulna. During reduction extension by means of an adhesive glove is very useful, particularly if the reduction of the fracture meets with difficulties and if the hands of the assistant surgeon are frequently exposed to X-ray irradiations. BOEHLER employs a strap which encompasses the four fingers at a level with the basal joints. As for the rest, the arm is extended in the screw-extension apparatus which, however, necessitates the availability of the link bearing a ball and socket joint which is to support the hand. HAEBLER recommends a leather bandage which is wound around the hand in such a way "that its edge is at a level with the base of the first metacarpal bone". We believe, that the cotton glove is more convenient, because it does not disturb the ready access to the insertion site.

A small incision is made pointing from the articular edge of the radius to the proximal end, and the bone is exposed between the tendons of the m. extensor pollicis longus and brevis. The drill-hole should be bored about 2 cm. proximally from the articular surface. HAEBLER enters "between the m. extensor carpi radialis and m. extensor pollicis brevis and the long extensor muscles of the fingers", while KUENTSCHER and MAATZ proceed from the processus styloideus radii, and BOEHLER "from the extensor side of the lower end of the radius". After the medullary cavity is sufficiently opened and at an angle which is as small as possible, a slightly bent Kirschner-wire is inserted first. This shows whether the way is free for the medullary nail. The wire must slide easily into the medullary cavity. This guide-wire also facilitates to a certain degree the insertion of the nail, and it serves to prevent the nail-tip from being caught in the opposite corticalis; an incident which occurs readily.

At its head the medullary nail must be bent in accordance with the curvature which it has to pass at the distal end of the radius (Illustration 23). It is easy to bend the medullary nail according to requirements by putting it between the jaws of the extraction hammer and bending it manually. If this is not done, the danger arises that due to its tensed position the medullary nail penetrates through the soft spongiosa towards the wrist-joint. Thus a damage of the wrist-joint and the epiphysis may occur, a hazard which can be avoided if one drives the nail in more from the dorsal than from the lateral aspect. By these means one circumvents the curvature of the path of the nail in the distal end of the radius which is curved strongest at the lateral side.




Illustration 23.

Schematic design of curvature of medullary nail for radius at the distal end of the bone.

The fracture cleft is passed under fluoroscopic control, maximal distraction, and by guiding the nail with its projecting part. After the nail has entered the proximal fragment for about 1 cm., the extension is relaxed, the guide-wire removed if there is one, and the nail driven in completely, while the assistant surgeon presses against the elbow.

In the case of an isolated radius fracture an immobilizing bandage is not absolutely necessary. For an early discharge of the patient for ambulatory treatment the application of an unpadded dorsal plaster splint for 2 or 3 weeks is advisable.

The medullary nail is not removed unless the roentgenogram shows a solid callus which guarantees the bony consolidation of the fracture. This may take a very long time, sometimes even 4 or 6 months. However, it means no really significant delay as the injured patient soon may regain his full capacity to work, even though the nail is in place. Therefore one can take one's time in removing the nail.

c) Femur.

The technique of medullary nailing of the femur includes comprehensive roentgenograms taken beforehand with the intended nailing in mind. Their purpose is to provide a survey of the whole length of the femur. To this end films at least 40 cm. in length are required. Nevertheless they sometimes are not long enough and therefore we adopted the procedure to take pictures in two planes, one of which shows the neck of the femur together with the tip of the trochanter and the fracture site, while the other displays the cleft of the knee-joint and the fracture site.

The approximate length of the medullary nail is to be estimated along the sound leg. The nail should extend from the tip of the trochanter major to the lateral cleft of the knee-joint. If later on it projects from the trochanter by 2 cm. the distal end will be located near the epiphyseal line. A more accurate determination of the length and the diameter of the nail may be achieved by means of the roentgenograms and even during operation by means of the guide-rod. In the case of the femur an accurate determination of the length down to millimeters is not required as some projection of the nail-head is allowable. Only with fractures close to the knee-joint is an exact determination of the length of the medullary nail necessary. It is achieved by measuring the guide-rod inserted into the medullary cavity up to the desirable position of the nail and by calculating the difference between the measured total length of the guide-rod and its projecting part at the trochanter. To this difference the 2 cm. required to make the nail-head project must be added (Illustration 24).

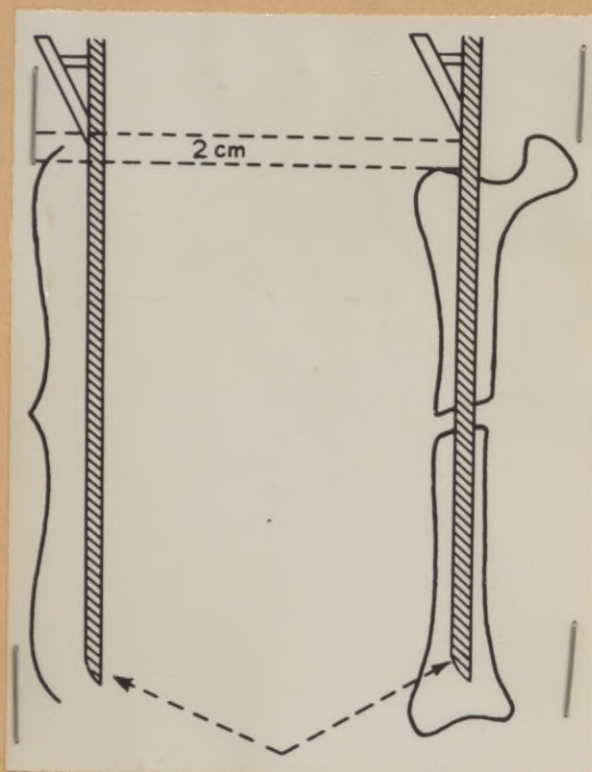


Illustration 24.

Schematic design of how the guide-rod is used for the determination of the nail length in case of femur nailing.

The width of the medullary cavity may be determined on the roentgenograms. Once more I refer to the "scale" employed by KUENTSCHER and MAATZ which was described in the chapter dealing with humerus nailing. In the case of adults the diameter of the most narrow place of the femur, located slightly above the middle of the shaft, varies between 8 and 12 mm. and it even may amount to 16 mm. If as usual in our clinic the roentgenograms are taken at a focal distance of 80 cm., 1 or 2 mm. must be subtracted from the width of the medullary cavity shown in the roentgenogram to obtain the real diameter. The use of too thick a medullary nail may cause unsurmountable difficulties during operation. The

nails of the ordinary set are V-shaped, straight, and have a length of 24 to 44 cm. and a diameter of 9, 10, and 11 mm. Before commencing the operation care should be taken that the guide-rods belonging to the nails are ready for use.

For children the femur nails cannot be used because of their thickness. In such cases one must content oneself with medullary nails destined for the humerus or the leg and straightened as much as possible.

The guide-rod serves to thread the fragments and to guide the medullary nail which during insertion slides along it. In addition it is used to determine the length of the nail, as mentioned above (30).

No medullary nailing of the femur is to be attempted without the extraction instruments ready for use. Here they are more necessary than with any other type of nailing. It may happen that the medullary nail employed is too thick and therefore has to be extracted, and everybody facing this situation for the first time will be amazed at the force required for this purpose. In the case of nailing a fresh fracture KUENTSCHER estimates the force required at about 300 kg.

In all cases of femur nailing in which there is no contra-indication we as well as KUENTSCHER and MAATZ and HAEBLER employ spinal anesthesia with 3 cc. of a 5% novocaine solution. The spinal anesthesia should be placed as low as possible to paralyze as few vaso-regulating segments as possible. In fresh cases BOEHLER prefers local anesthesia, but we believe that sometimes it is not sufficient to cause relaxation of the strong musculature of the femur. Medullary nailing of children, which is used in rare cases only, should be performed under general anesthesia.

Before performing the first medullary nailing of the femur, the position of the patient should be tried with a healthy person. One cannot do without an operating table combined with an extension device. Improvisation is not permissible and there is no need to stress expressly that for medullary nailing adequate apparatus and instruments are as necessary as for any other major operation.

In our clinic the extension table of LEHMANN is employed. KUENTSCHER and MAATZ recommended lateral position upon the sound extremity the hip-joint being moderately bent. BOEHLER, too, operates in lateral position. In the beginning we also adopted this position, but we abstained from it more and more, and now we use the dorsal recumbent position. On LEHMANN's extension table the pelvic support is attached outside the extension bar on the injured side, so that the hip projects over the edge of the table. The whole extension device is abducted by about 45° towards the sound side, and thus the hip-joint of the patient is adducted by the same angle. Lowering the extension bar for the healthy extremity by about 20° causes a slightly oblique position of the pelvis while there is a considerable adduction and a slight flexion of the injured limb in the hip-joint (Illustration 25). This provides an ideal access to the tip of the trochanter, and reduction is much easier than in the lateral position. Only in cases of high femur fractures sometimes lateral position seems to be more adequate. The above described semi-oblique dorsal recumbent position permits exhausting all possibilities offered by the device of varying between adduction, flexion and extension, elevating and lowering, to such

an extent that an axial adjustment of the distal fragment is achieved thereby alone.

The lateral displacement is reduced by lateral traction applied close to the fracture site. It is advisable to mark the fracture site on the skin under X-ray control. There is no doubt that the reduction appliances designed by BOEHLER, WITTMOSER and LINSMAYER, render good services. One of the two, either the extension table, or the reduction apparatus, must be available.

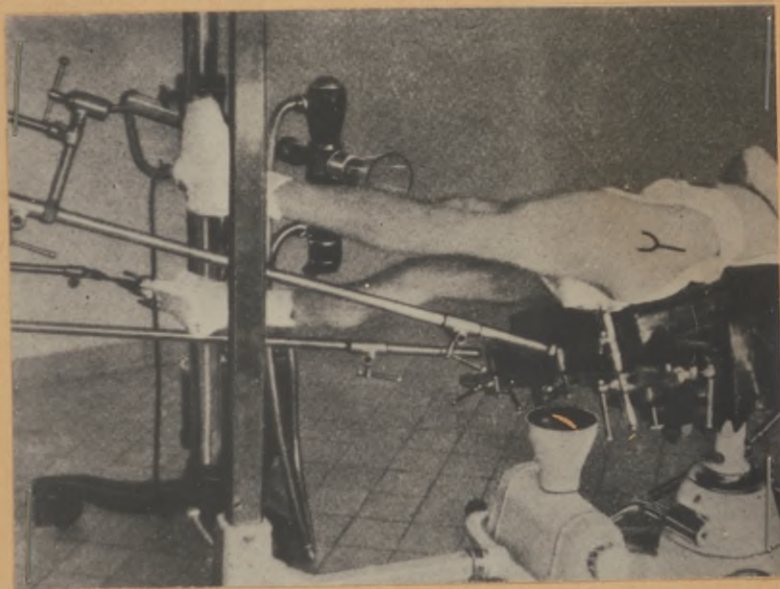
Here too, the operation proper starts after the reduction. The trochanter major is draped with sterile sheets. Most appropriately the thigh is not covered to allow a constant check of



a

the direction of the guide-rod and the medullary nail.

The skin incision is made about the width of two fingers above the palpable trochanter tip, and it is about 4 or 5 cm. in length. The musculature is bluntly separated. Then one penetrates with the index finger to the crest of the trochanter. The guide-rod pierces through the tip of the trochanter at its medial edge and it is pushed cautiously forward along the longitudinal axis of the bone with rotating movements. Thus the medullary cavity is usually found without any difficulty. If the force of the hand is not sufficient to perforate the thin bone, one will succeed by light hammer blows upon the guide-rod as if it were a nail. As soon as the guide-rod has entered the medullary cavity, which is revealed by fatty bone-marrow flowing out, it slides along inside it without greater resistance. Short fluoroscopic flashes check its position and its further progress. Small lateral pal-



b

Illustration 25.

- a) Position for femur nailing
- b) Position for femur nailing
(from HAEBLER: The Stable Osteosynthesis".

lating movements. Thus the medullary cavity is usually found without any difficulty. If the force of the hand is not sufficient to perforate the thin bone, one will succeed by light hammer blows upon the guide-rod as if it were a nail. As soon as the guide-rod has entered the medullary cavity, which is revealed by fatty bone-marrow flowing out, it slides along inside it without greater resistance. Short fluoroscopic flashes check its position and its further progress. Small lateral pal-

pations with the guide-rod during which it touches the hard walls of the medullary cavity facilitate the judgment of its correct position.

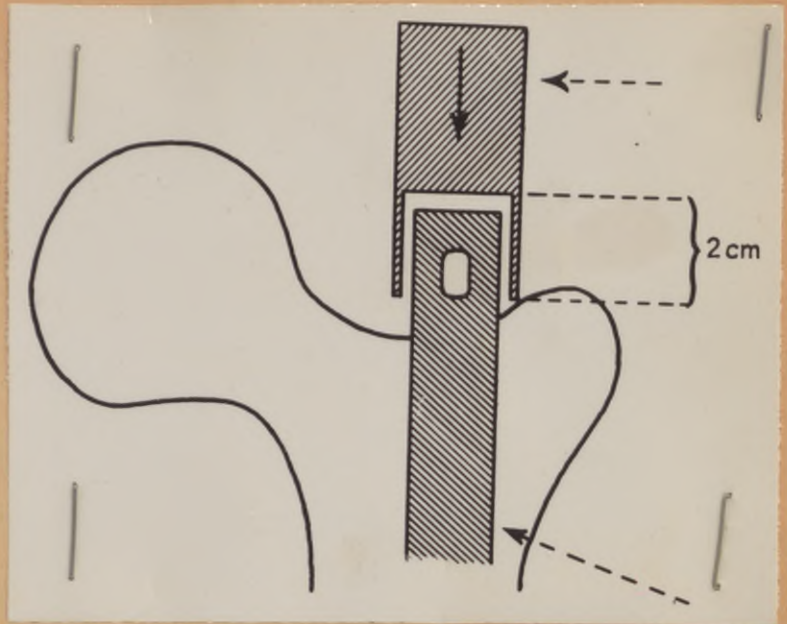
If reduction was successful we attempt to insert the guide-rod immediately into the distal fragment. A rapid passing of this obstacle is decisive for a further smooth progress of the procedure. The guide-rod is pushed forward as far as the nail is to lie in the distal fragment. As mentioned above, this proceeding permits to determine the length of the nail accurately. If, however, one is not successful in passing the fracture cleft with the guide-rod, the nail is immediately guided over the rod and driven in until it arrives at the fracture cleft. This must be accomplished slowly and by short hammer-blows to give the bone marrow an opportunity to escape from the fracture cleft so as to bring into full effect the natural pressure valve formed there and to regulate the pressure equalization in the compressed medullary cavity. Attention was called to this point when the risks of medullary nailing (fat embolism) were discussed. For the same reason if one wants to be very cautious, it is advisable to withdraw the guide-rod at intervals so that the bone marrow may escape through the groove of the nail at the top too, and then to insert the guiderod again. The medullary nail driven up to the fracture cleft in the case of difficulties constitutes a useful handle by which the position of the bone may be adjusted so that in this way the threading of the guide-rod into the distal fragment, as it was repeatedly described above, sometimes is considerably facilitated. Here too, stress must be laid upon the fact that this type of technical procedure does not represent the usual way, but only is one of the alternatives, a trick to be applied for overcoming a difficult situation. It should be made a principle to attempt by all means to progress in the normal way and to accomplish reduction prior to medullary nailing. One should not be confident that the nail or the guide-rod once driven up to the fracture cleft can be moved beyond it by some ingenious method or other.

The further progress of the medullary nailing depends on the directives of the fluoroscopist. If he is not entirely sure whether the guide-rod has entered the medullary cavity of the distal fragment, an incident which may occur and which should not be interpreted as a lack of attentiveness or ability of the assistant, it is preferable to abstain from further attempts and to take roentgenograms in two different planes. When all difficulties are overcome, the nail is driven in further. As soon as the head of the nail approaches the skin incision, the danger arises that the skin or the soft tissue may be hit by the hammer and bruised. At this stage of the operation the use of a hammering-cap (punch) is required which has to be set on the nail head. Such an instrument was manufactured in our workshop from a short piece of a medullary nail which had been cut off at both ends. It offers the advantage that the guide-rod can slide in its groove, thus preventing the cap from slipping off during hammering. In addition at the one end of the hammering-cap a piece 2 cm. long and shaped like a tube was fitted which can be pushed onto the nail head (Illustration 26). This prevents driving the nail in too far, as the cap rests upon the bone, while the nail covered by it projects from the bone by 2 cm. If too thin a nail is used it would otherwise be possible to drive it in too easily and therefore too far. KUENTSCHER and

MAATZ designed two different hammering-caps which are to transmit the blows of the hammer to the principal parts of the medullary nails.

Illustration 26.

Design of the hammering-cap (punch) employed for driving in the femur nail until it projects by 2 cm.



Prior to the last hammer-blows the extension is removed. One of the assistants pushes on the heel or, when the leg is bent, against the knee by strong blows with the flat palm or with the thenar simultaneously with the hammer-blows of the operating surgeon, thus wedging the fracture together. Then the skin incision is sutured and a roentgenogram terminates the operation.

After-treatment: The injured extremity is bedded upon a Braun's splint. The foot is suspended at the forefoot with a loose bandage held in place with mastix and thus outward rotation is prevented. Additional external supports are necessary in spite of the medullary nailing there is the hazard of a certain shifting, bending, or shortening. The shape of the fracture or its position sometimes may require a change of its position over the medullary nail. For this reason the mode of the first after-treatment for the various types of femur fractures must be described separately. Here, due to the weight of the extremity and to the motor force in action, much greater forces take effect upon the fracture and the medullary nail than is the case in the other long bones, so that it needs no explanation that supporting measures are necessary.

Transverse fractures and short oblique fractures of the femur proximal of the middle of the shaft in the range of the most narrow section of the medullary cavity require no additional external support provided they are held together by a nail of sufficient thickness. In such cases the leg is immobilized by means of a Braun's splint until the wound is healed. Subsequently, exercises in bed are taken up and after a few days the leg may be subjected to weight-bearing outside the bed. These ideal cases may commence walking after an average of 2 weeks.

Fractures below the middle of the femur shaft are bedded upon a Braun's splint and an unpadded dorsal plaster splint attached to it, as with these fractures the possibility of bending is greater and as it cannot be prevented by a Braun's splint alone. These patients are not allowed to get up earlier than after 4 weeks.

Transverse fractures and oblique fractures immediately below the trochanter major can be saved from axial angulation and shortening only by an additional extension bandage. There is the danger of the formation of a coxa vara.

The multiple fractures of the femur which are particularly suitable for medullary nailing must be subjected to extension during after-treatment to avoid shortening. Confinement to bed for at least several weeks is necessary.

Spiral fractures in the upper third of the femur with a cracked off wedge cannot be immobilized in a satisfactory position with the medullary nail alone. Even with the most appropriate position and even though the medullary nail is optimal in thickness and length the fragments are telescoped into each other and shortening and axial angulation occur. These fractures have also to be treated with an additional extension bandage. As a rule a weight of 4 or 5 kg. is sufficient, since the medullary nail also provides a certain hold.

Of course the surgeons extensively employing medullary nailing endeavor to adapt themselves to the conditions of the medullary cavity of the various bones and of the various fracture types by an increasing refinement of their instrumental technique and by the special construction of instruments, particularly of the nails, so that stable osteosynthesis can be achieved even in more difficult cases. Only in this way will it be possible to render additional support by plaster or extension bandages superfluous and to bring medullary nailing as a method closer to its ideal. For the subtrochanteric transverse and oblique fractures the Kiel Klinik (31), (32), designed a thick and conically shaped medullary nail which fills the wide upper section of the medullary cavity. Simultaneously a larger support for the nail in the mass of the trochanter is provided so that the hazard of the nail cutting through the spongiosa is considerably lessened.

The supracondylar fractures cannot be retained in a satisfactory position by the medullary nail alone, as it finds no sufficient hold in the spongiosa of the short distal fragment. The fractures with a simultaneous comminution of the condyles are not suitable for medullary nailing. Despite the insufficient retention one must acknowledge that by means of the medullary nail it can be accomplished still better than with other methods, provided one does not expect that the nail insures a really stable fixation. For this reason the nailing of supracondylar femur fractures must regularly be associated with the application of a plaster cast which at least extends to the inguinal region, and even may become necessary to apply a pelvic plaster cast. The plaster cast should be left in place not less than 4 weeks and the patient should be confined to bed for at least 6 to 8 weeks. As regards the position, and above all the mobility of the knee-joint, the success obtained with this procedure is usually better than with a purely conservative treatment, although even nowadays it cannot be avoided with this type of fractures that failures of treatment with medullary nailing occur, which assume the form of axial angulation and secondary damage of the knee-joint.

d) Leg.

Medullary nailing of the leg means medullary nailing of the tibia. There is no need to nail the fibula. Nevertheless it should not be disregarded since it is this neighboring bone that influences fracture healing in many a sense. From the purely technical view medullary nailing of the tibia can be considered as an easy operation. This is actually the case with many tibia fractures, as the thin coat of soft tissue does not bar access to the medullary cavity, and it facilitates reduction by the possibility of grasping the bone. Nevertheless medullary nailing of the tibia offers difficulties which are particularly caused by the varying width of the medullary cavity and its course.

The cross-section of the medullary nails for the tibia is V-shaped too. They must be flexible and their slightly rounded tip has to point upwards. Smoothing the tip is necessary to enable the nail to slide along the wall of the medullary cavity on the opposite side. To compensate the insufficiency of the nail with regard to its stabilizing function which is caused by its flexibility. KUENTSCHER designed the medullary nail for the leg as a double nail. A second nail shaped exactly like the first one and only a bit thinner, fits into the groove of the first nail and stiffens it by lying exactly parallel. Nevertheless the double nail frequently is not sufficient to provide really stable osteosynthesis. This deficiency is particularly noticeable with fractures at the proximal end where the medullary cavity is very wide. There the nail cannot fill the cavity completely. For this reason an external support is required frequently in addition to the nail.

The most narrow part of the medullary cavity is located between the middle and lower thirds. Its diameter varies between 10 and 12 mm, and it becomes larger above and below this place. Hence it is easy to understand that the transverse fractures on the border between the middle and lower thirds are principally suited for medullary nailing. To determine the thickness of the nail it is only required to measure the diameter of the medullary cavity in anterior-posterior direction, as in the lateral direction the nails are bent together by the rigid walls of the bone during introduction. The length of the nail must be determined very accurately as too short a nail is valueless for fixation. If the nail is too long the danger arises that it may cross the lower epiphyseal line and penetrate into the upper foot-joint, an accident, which in view of the danger of infection, must be prevented by all means. The upper end of the nail should not project too far from the bone, as here the skin lies next to the bone providing an easy opportunity for decubital ulcers. It should project just with its eye from the tibia. The length of the tibia nail is measured best after the reduction of the fracture. The length is from the insertion site, which is located beside the tuberositas tibiae, to the distance the nail tip is to have from the joint. The most easy and safe method is to expose the site of insertion by a skin incision during the operation and after reduction and to hold the nail alongside the crest of the tibia under complete asepsis, so as to determine its optimal length by fluoroscopy.

For anesthesia we prefer low spinal anesthesia for elderly patients. It is particularly useful for prolonged surgical interventions such as osteotomy and operation of pseudarthrosis. With younger patients and under ordinary conditions it usually serves the purpose to employ local

anesthesia for the percutaneous nailing of simple fractures. The fracture cleft and the site of insertion are anesthetized and ether or evipan are given in addition during the act of driving in the nail, if necessary.

The position of the patient is here of greater importance for the smooth performance of a medullary nailing than with other bones. For this operation BOEHLER's screw-extension apparatus has proved best. Provided that no operative reduction must be made we exclusively use the screw-extension apparatus for the reduction of the leg fracture (Illustration 27).

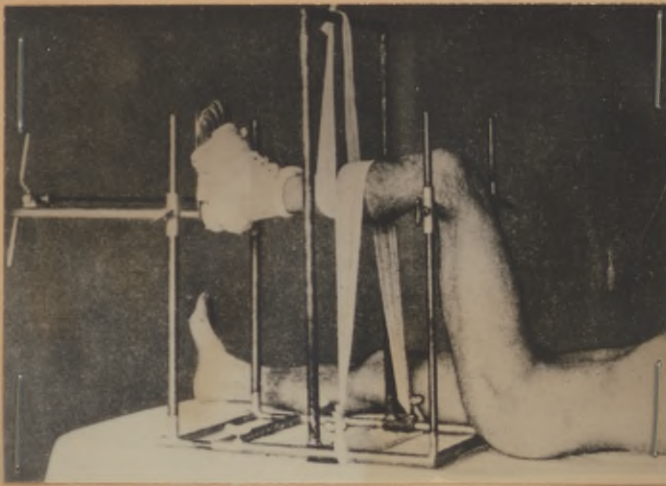


Illustration 27.

Position of the leg in BOEHLER's screw-extension apparatus for reduction and medullary nailing (From BOEHLER: Technique of Fracture Treatment, III, p.246).

With its help reduction is more easy and sparing than with any other apparatus. It is moreover possible to retain the fragments in their reduced position without having to rely upon an assistant. Access is barred neither for the operating surgeon nor for the X-ray apparatus. The application of lateral traction permits the reduction even of the smallest dislocation in an excellent manner. KUENTSCHER and MAATZ completed BOEHLER's apparatus by attaching longitudinal bars serving to bear the lateral traction devices. Of course one can also use the extension contrivance correspondingly (HAEBLER). Here too, medullary nailing should not be started before reduction is completed.

The insertion site is exposed medially from the tuberositas tibiae by a longitudinal incision 4 cm. in length. KUENTSCHER and MAATZ as well as HAEBLER proceed through the tuberositas tibiae itself. The insertion of the nail laterally from the tuberositas and in particular cases even medially showed some advantages which induced us to continue employing it. In case of a later infection it is easier to inspect the situation from here as survey is not impeded by the ligamentum patellae and as it is certain that with the lateral incision there is less danger that the infection ascends to the knee-joint. In addition the drill-hole can be bored in a more oblique direction and this facilitates the introduction of the nail as well as its extraction.

Last and not least the nail finds a firmer hold if, as is the case here, the oblique duct is long. BOEHLER also performs nailing from a point lateral to the tuberositas tibiae. The following account of a most regrettable incident convinced us that it is less dangerous to insert the nail from a place lateral to the tuberositas tibiae than from the center of the tuberositas.

Medical history: 69 year old male patient with a leg fracture at the junction of the middle and lower thirds. The tibia shows a transverse fracture with a 1 cm. long medial wedge. Wire extension through the talus, reduction, plaster cast were applied first. The indication for medullary nailing was suggested by the age of the patient, chronic valvular heart disease combined with an asthmatic condition and a chronic bronchitis, a simultaneous fracture of both malleoli on the same leg as well as by the considerable tendency of the fracture to dislocate. The insertion of the two medullary nails at the tuberositas tibiae 9 days after the accident (10 August 1941) was easy. Then a U-shaped plaster splint was applied and the wound seemed to heal without any disturbance. Four weeks after the operation reddening and swelling of the insertion site was observed which disappeared soon. Five weeks after the operation the patient got up while the plaster splint was still in place. Soon afterwards an ulcer developed medially to the fracture site in an area of old varicose veins (the bacteriological examination showed hemolytic staphylococci) from which a 1 cm. long sequestrum was detached (17 November 1941). Several days later a small abscess had to be opened at the insertion site of the nail. It healed quickly. Eleven weeks after medullary nailing (24 December 1941) the patient was dismissed after an Unna's plaster bandage was applied, while the ability of the patient to walk was satisfactory. Later on the patient was readmitted because of a fistula on the leg which was curretted. On the next day a febrile phlegmon developed at the insertion site of the medullary nail. After a large incision a considerable amount of pus was evacuated. The nail was removed at this time. (3 Feb 1942). An empyema of the knee-joint (the bacteriological examination showed the presence of hemolytic streptococci) and in addition a peri-articular phlegmon developed. Transitory symptoms of ileus set in and in spite of a wide opening of the phlegmon death occurred on 6 March 1942.

For the development of the phlegmon on the knee-joint, be it due to conveyance of the infection from the ulcer above the fracture site or to the outbreak of an inflammation at the insertion site of the nail, medullary nailing must be held responsible. The post-mortem examination revealed the presence of granulation tissue rich in cells and of young connective tissue with a large amount of macrophagi in the med-

ullary cavity of the tibia, on the whole showing the picture of cicatrized tissue and no signs of a medullary phlegmon. In addition a purulent necrotic inflammation of the lower section of the colon was found, which was interpreted as a septic metastasis.

The awl should be bored in at the lower angle of the incision, because during the act of driving it in the nail lies close to the area above the drill-hole, and very obliquely, so that it exerts a strong pressure upon its support. When it is driven in at the center of the wound or at its upper angle, strong pressure is exerted upon the skin, leading to a considerable damage of the tissue. However, if it is driven in from the lower angle of the wound, the area where the strongest pressure is exerted lies within the wound, that means it practically is located upon the bone, and the skin suffers no damage. The awl must perforate the bone at a very small angle to the axis of the medullary cavity. This can always be accomplished by hand without a hammer if rotating movements are made. After the length of the nail was determined as described above, the thicker nail is driven in first and the slightly hooked tip of the nail points upwards. The nail is guided by hand at the smallest possible angle to the bone. As soon as the nail tip comes close to the fracture cleft, the roentgenologist begins action. When arrived at the fracture cleft the nail sometimes has the tendency to protrude from the medullary cavity in a frontal direction. In this case the distal fragment must under X-ray control slightly be pushed towards the extensor side of the leg, so that one might say it captures the nail with its medullary cavity. If the fracture cleft is passed, the medullary nail is driven in so far that it projects with its proximal end by 3 or 4 cm. Then the second thinner nail is inserted below the former. It slides along under it as upon a guide-rail, and it is driven in just as far. Here, attention must be paid that the first nail is not driven forward and it even may become necessary to fix it with a single pronged hook at its eye. As soon as the two nails are at the same level, extension is released. The assistant surgeon pushes against the heel, and the operating surgeon hammers in both nails together to the desired length. If it cannot be avoided that the nails lie upon the skin above the incision pressing upon it, one does well to hold a large gouge between the skin and the nail so that the nail slides as in a groove while the pressure of its edges is caught up by the gouge and distributed over its large smooth area. After the termination of the medullary nailing, the fracture is wedged together by blows of the thenar against the heel. If during this procedure the nails are pushed out slightly, they may be driven in again by means of the hammering-cap. Then the skin is sutured, a dressing applied and a roentgenogram is taken. If the reduced extremity shows curvation, such as recurvation or varus and valgus position of the leg, it may be straightened over a padded wooden block.

In very favorable cases it is sufficient to place the leg upon a Braun's splint, while the foot is immobilized with an adhesive stockinet bandage. Usually an additional circular plaster bandage is required. As always when a fracture is not sufficiently immobilized by medullary nailing alone, a careful after-treatment is a matter of the greatest importance. With the leg too, the superiority of medullary nailing over the purely conservative method is revealed. It includes early exercises, because with the transverse fractures one usually does not need to leave the plaster cast in place for more

than 4 weeks, and after the termination of this period one may apply a walking cast which permits the patient to subject his leg to weight-bearing. This practically means that the period of confinement to bed is much shorter than usual, and it is practically this circumstance which suggests treating such fractures with medullary nailing which, seen from the mechanical point of view, do not seem to be suitable. That means that medullary nailing should preferably be performed in such cases which for reasons of general health require a reduction of the period of confinement to bed. Finally the possibility of an early subjection to weight-bearing also is of advantage as regards the social or economic indication, since it reduces the period of hospitalization.

To accomplish a better immobilization than with the double nail MAATZ (33) designed special nails such as the spread nail and the turn-spread-nail. The spread-nail consists of an ordinary double nail, in the distal end of the outer nail a small inclined plane is fixed. The inner nail encounters it and thus is deviated from the parallel course (Illustration 28) so that the distal end is pressed against the bone wall on the other side. Thus both nails find a firm hold on the wall of the distal portion of the medullary cavity, the one in front, the other at the back. "The turn-

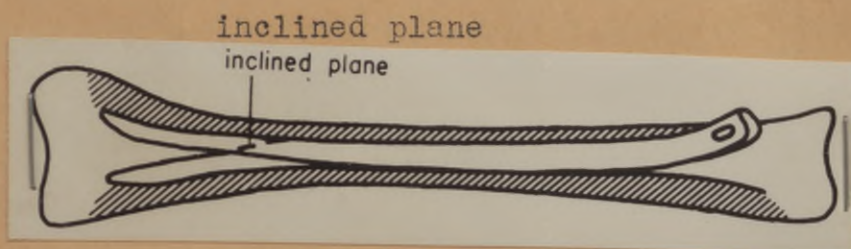


Illustration 28.

Spread-nail for the tibia with an inclined plane (from KUENTSCHER and MAATZ: Technique of Medullary Nailing).

spread-nail also consists of two medullary nails. The outer nail corresponds to a standard nail. The inner nail has a circular cross-section and has an S-shaped longitudinal profile. The lower part of this nail is inserted in such a way that its concave aspect points to the front. Then the nail is turned by 180° by means of a screw-driver set onto it. The completely introduced inner nail is secured by a transverse pin or a wire against further intrusion, and the outer nail is driven in". (KUENTSCHER and MAATZ).

Due to difficulties of industrial production during and after the war it was not possible for a long time to obtain such special nails. We therefore made the attempt to employ the available standard nails in a modified form to obtain a greater security of stabilization. The procedure was as follows: The thicker nail was driven in laterally into the medullary cavity until its tip had safely passed the fracture cleft. For this purpose the insertion hole had to be bored with special obliqueness and depth. During introduction the concave cross-section of the nail should not point in posterior direction as usual, but in medial direction. This is easy to achieve by putting an instrument (forceps or elevator) into the eye of the nail, by means of which rotation in posterior direction is prevented. Before the thinner nail is

in it must be bent appropriately by hand so that the curvation of the lower end of the nail is almost eliminated, the nail assuming a slightly S-shaped profile as a whole. Now, this nail must be driven in in such a way that the two concave sides point against each other and that the second nail slides with its hollow upon the V-shaped arm of the first nail as upon a rail. (Illustration 29). As long as both




Illustration 29.

Schematic design of how to use a double nail for the tibia as a spread nail.

nails project by 3 or 4 cm. over the bone, the tip of the thinner one shows no tendency as yet to deviate from the rail. The desired spread of the nail tips still is paralleled by a certain spread of the upper nail ends. If in the course of further proceeding both nails are hammered in together, the upper ends approach each other, because they are pressed together by the insertion hole. Their tips spread to the same measure. This involves no danger, as the two nails already have passed the fracture site. In this way a firmer fixation and a larger total cross-section of the nails can be obtained by the spreading of the nail tips and thus a better filling of the distal medullary cavity is achieved (Illustration 30). After satisfactory experiments on skeletons the procedure was practiced on patients.

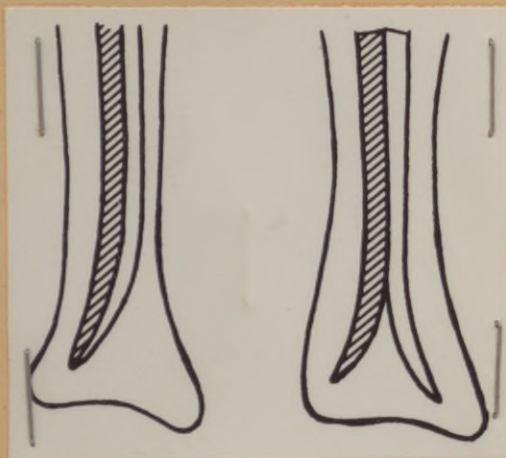
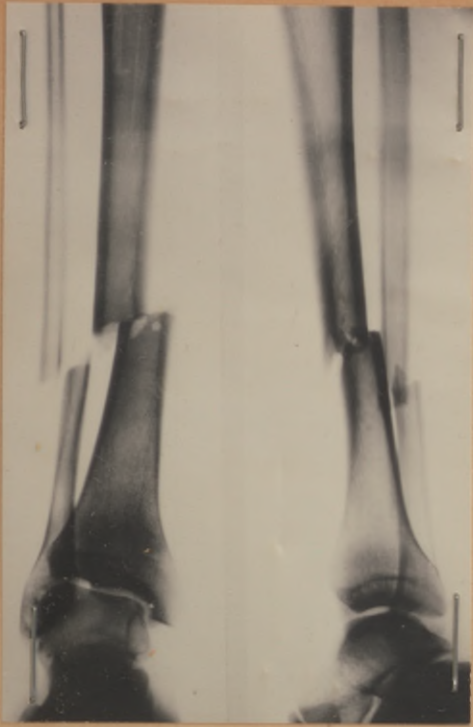
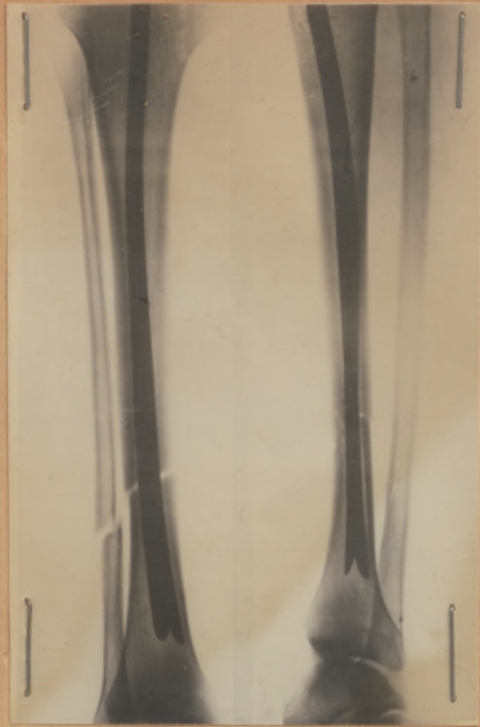Illustration 30.

Modified double nail.
(after WEIS)

Medical history: 18 year old male patient with a transverse fracture in the lower third of the leg (Illustration 31). Medullary nailing was performed with a double nail employed as a spread-nail. A clinically satisfactory stable osteosynthesis was obtained. After 1 week the limb of the patient was subjected to weight-bearing. Dismissal three weeks after medullary nailing. The gait was normal and caused no pain.



a



b



c

Illustration 31.

- a) Transverse fracture of leg
- b) Medullary nailing with modified spread-nail
- c) Weight-bearing one week after medullary nailing.

This method was used in another 4 cases with the same good result. In none of the cases was an additional external immobilization necessary. Nevertheless we would not consider the method as more than an improvised auxiliary procedure. Satisfactory results are to be expected only in particularly suitable cases. The eligibility of a fracture for this method does not only depend on the site of the fracture which has to be at the most narrow part of the medullary cavity of the tibia, but also on its type. Only transverse fractures and short oblique fractures are suitable, as

the surfaces of their fragments fit well upon each other, and as the medullary nail is not expected to prevent lateral sliding off or longitudinal dislocation.

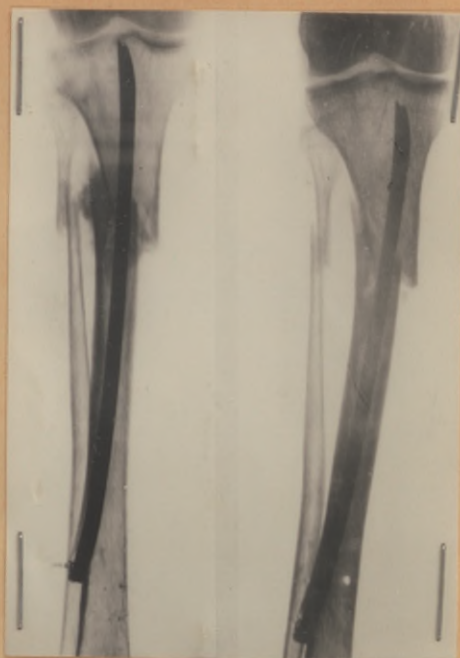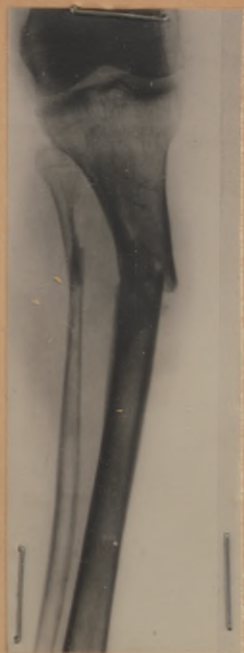In exceptional cases KULNTSCHER and MAATZ performed medullary nailing of the tibia from the medial malleolus, that means in the inverse direction from the distal end towards the proximal end, while the medullary cavity was very narrow (6 mm.) and while there was an oblique fracture located between the middle and lower thirds. In this case the turn-spread-nail would not have been sufficient for immobilization. We, too, performed medullary nailing from the distal end towards the proximal end in one case and the final result was really good. The double nail, however, was not driven in from the medial malleolus, but from a place located in the lower third of the tibia. Thus it was possible to take advantage of the internal friction for a firm hold of the nail along the whole length of the short proximal fragment. Typical medullary nailing from proximal to distal would have encompassed less than one half of the proximal fragment, and as the X-ray pictures revealed later (Illustration 32) it would have had to be considered as not suitable for medullary nailing. We believe however, that this mode of proceeding is beyond the limits of the capacity of the medullary nailing method and that treatment by wire loop (see below) is more conservative if one has decided to rely on operative treatment. A particular disadvantage of proceeding from the distal end is the danger of penetrating into the upper foot-joint.

Only a little experience could be collected with the medullary nailing of the fractures of the clavicle, as it rarely occurs that it must be performed. It does not make any difference whether the nail is driven in medially or laterally (Illustration 17). The width of the medullary cavity is the decisive factor, as it may be so narrow that even the thinnest nails are too thick. In this case they may be replaced by Kirschner wires, but it hardly is possible to achieve a stable osteosynthesis with them. They may provoke an abundant formation of callus (callus luxurians) which involves the danger of compression of the brachial plexus. In such cases a wire loop is preferable, possibly in concurrence with a staplelike freshening of the fragments.

The retraction of the medullary nail is effected not earlier than when the roentgenograms display a completely organized callus and when the fracture cleft has disappeared. It causes no particular technical difficulties. BOEHLER recommends the wire grid of JESCHKE which is laid upon the extremity in the region of the nail head and roentgenographed together with the bone. It sometimes may facilitate the localization of the nail head if the bone has grown over it or if the nail has wandered deeper into the medullary cavity resulting in the disappearance of the nail head into the insertion hole. Usually an incision in the old scar under local anesthesia is sufficient to discover the nail. Due to the atrophy of the bone around the nail formed in the course of time, it usually can be extracted without any special appliance. In some cases the nail head must be exposed by means of hammer and chisel. During the extraction of the nail pain is felt and for this reason we prefer to give a short evipan or ethyl chloride anesthesia. After the removal of the nail the small incision is sutured again.

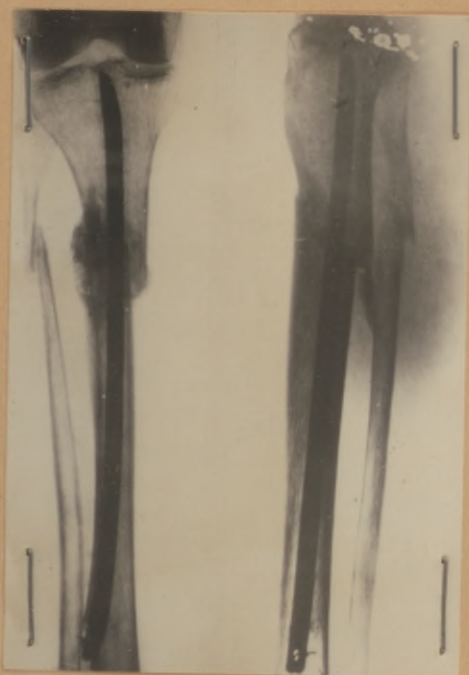When double nails were inserted and if they coincide on the roentgenograms so that they appear as one single nail it

is recommended to take X-ray pictures immediately after the extraction of the nail, as it has happened that the second nail escaped notice and remained in the medullary cavity. This may particularly occur if one is compelled to remove nails which were put in long ago in another hospital and if the patient neither is informed about the details nor in the possession of Elevant medical documents.



a

b



c

Illustration 32

- a) Leg fracture with short proximal fragment.
- b) Medullary nailing from distal with double nail.
- c) Satisfactory adjustment of fracture. Advanced stage of callus formation.

In our hospital an incident occurred during the extraction of a double nail of the tibia which shall be mentioned here. While a rather firmly seated nail was removed the double nail located below it penetrated with its head into the knee-joint (Illustration 33). It was not difficult to remove it through a small incision which, however, opened the knee-joint. No infection set in and

the joint was freely movable afterwards (see also OPITZ (34)).

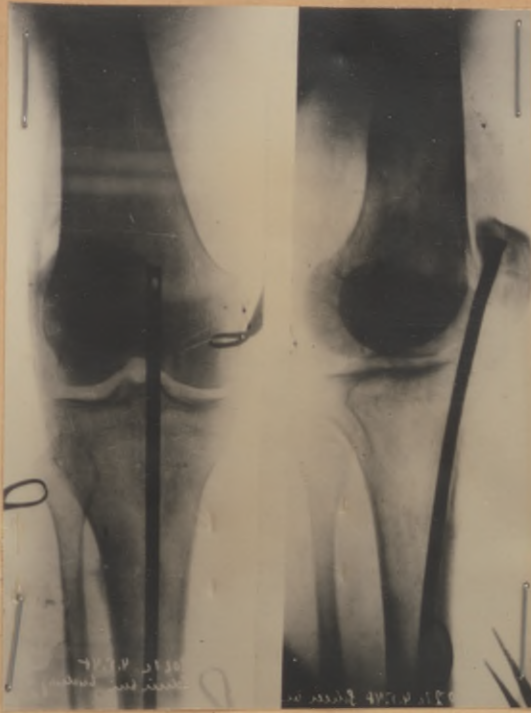

Illustration 33

Double nail penetrating into the knee-joint during extraction.

SOME ERRORS AND RISKS CONNECTED WITH MEDULLARY
NAILING.

Subsequently I want to refer to several complications which usually result from a faulty technical procedure. We shall limit ourselves to personal observations and to the more significant literature references. There are numerous publications about minor incidents (usually published in the Zbl.Chir. or Chir.). One of the most frequent errors is to use too short a medullary nail. Due to the lever effect of the longer part, the shorter end may be subjected to bending and this not only involves the nail alone, but also the whole fracture (Illustration 34). If the nail is strong enough to resist bending in such cases, it may in turn become the cause for the splintering off of bone splinters within the area of the fracture (Illustration 35), so that the nail tip protrudes from the medullary cavity laterally and penetrates into the soft tissue. If too thick a nail is introduced with great force, it may happen that the bone is forced asunder as if a wedge was used (Illustration 10). Such an incident was described by SPRENGEL (35).

Illustration 34

Curvation of a humerus fracture caused by too short a nail.

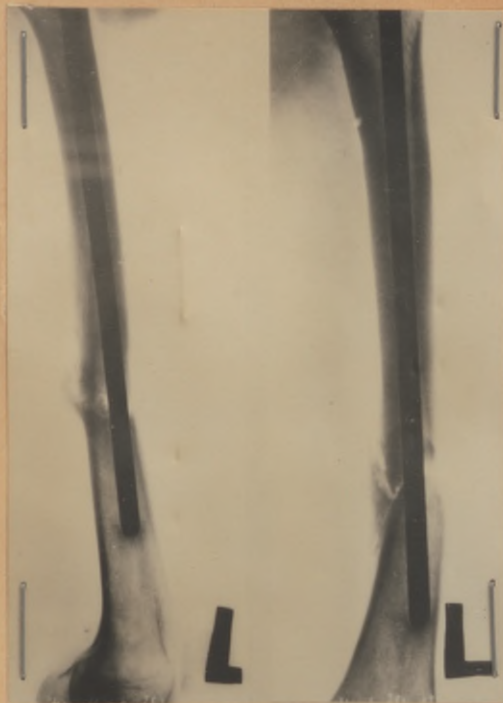

Illustration 35

A large piece of bone is splintered off as a result of too strong expansion while bending, the medullary nail being too short.

Illustration 34

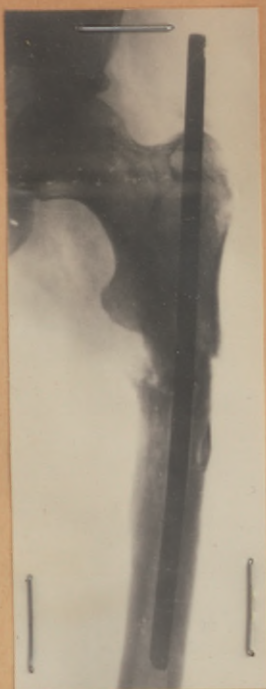Curvation of a humerus fracture caused by too short a nail.

Other complications have their source in the use of too long nails and may be classified under the heading of wandering of medullary nails. We observed them after nailing a spontaneous fracture of the femur, where the nail moved upwards, so that it had to be replaced twelve months after the first nailing (Illustration 36 and 37). If the nail extends to the distal fragment for a short stretch, wabbling movements of the nail tip may occur enhancing loosening and ascending of the nail.

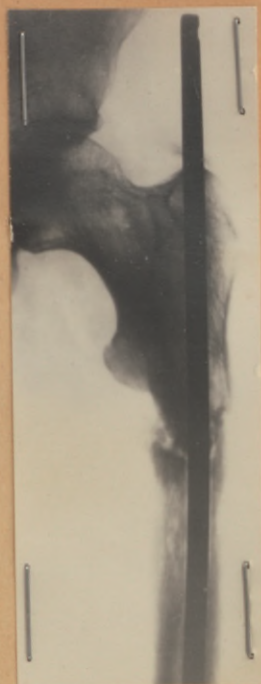In the lower leg there is the danger that very long nails perforate the upper foot-joint (Illustration 38). Apart from the possibility of articular infection an arthritis and deformity of the joint may result. After the medullary nailing of longdrawn oblique or spiral fractures the nail itself may remain immovable. The shortening of the fragments over the medullary nail may be sufficient to force the articular cleft of the foot-joint towards the tip of the nail, even though



a



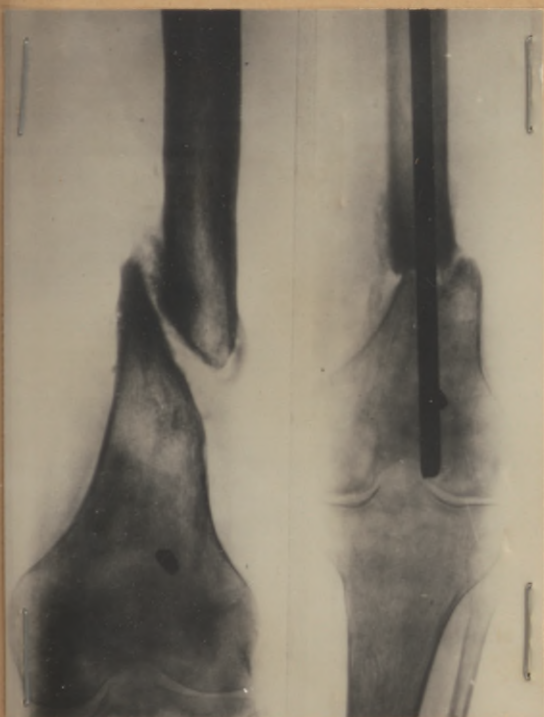b



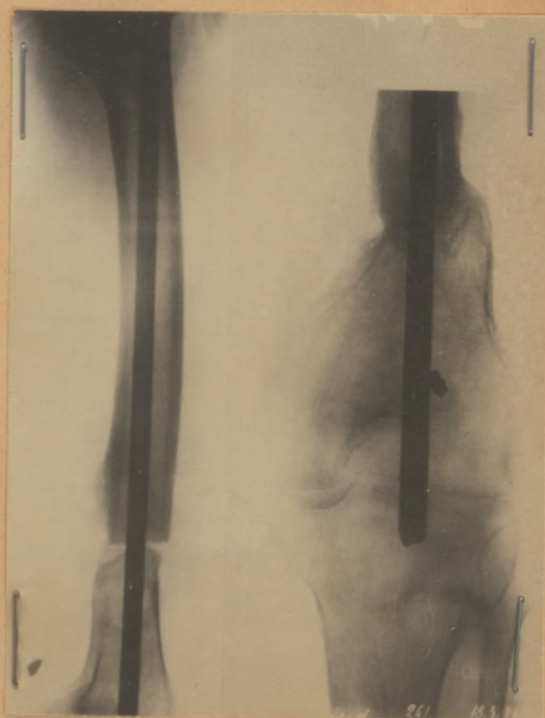c

Illustration 36

Wandering of a femur nail in proximal direction.
Spontaneous fracture with sarcoma (A.E., 29 years old).

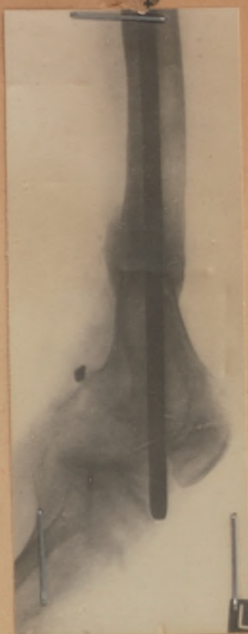


a

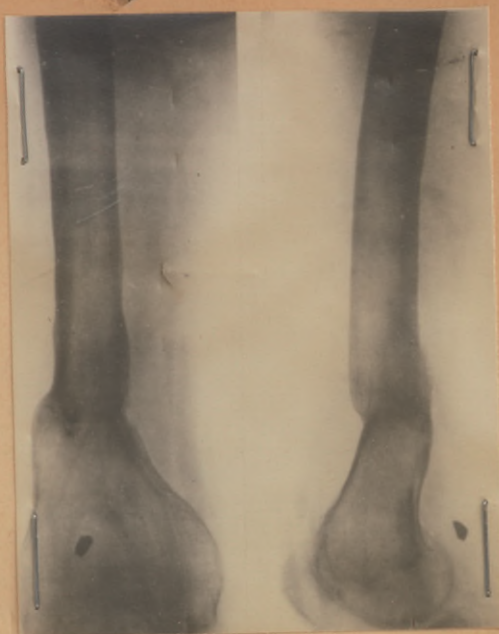

b

(Text see next page)



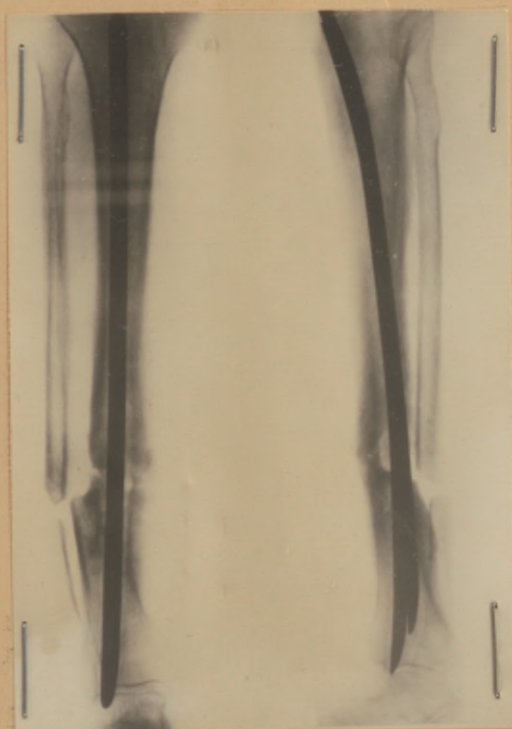c



d

Illustration 37

- a) Pseudarthrosis close to the knee-joint after gunshot fracture of the femur.
- b) Resection of pseudarthrosis and medullary nailing.
- c) Migration of medullary nail into knee-joint.
- d) Pseudarthrosis is healed, medullary nail is removed.



c

d

- a) Pseudoarthrosis close to the ankle-joint after gunshot fracture of the tibia.
- b) Resection of pseudoarthrosis and medullary nailing.
- c) Migration of Illustration 38 into ankle-joint.
- d) Pseudoarthrosis is healed, wandering of nail into the ankle-joint is removed.

it originally had the correct length. Finally it may occur that the tip of the nail perforates the corticalis and penetrates into the soft tissue in consequence of an angulation of the distal fragment (Illustration 39).

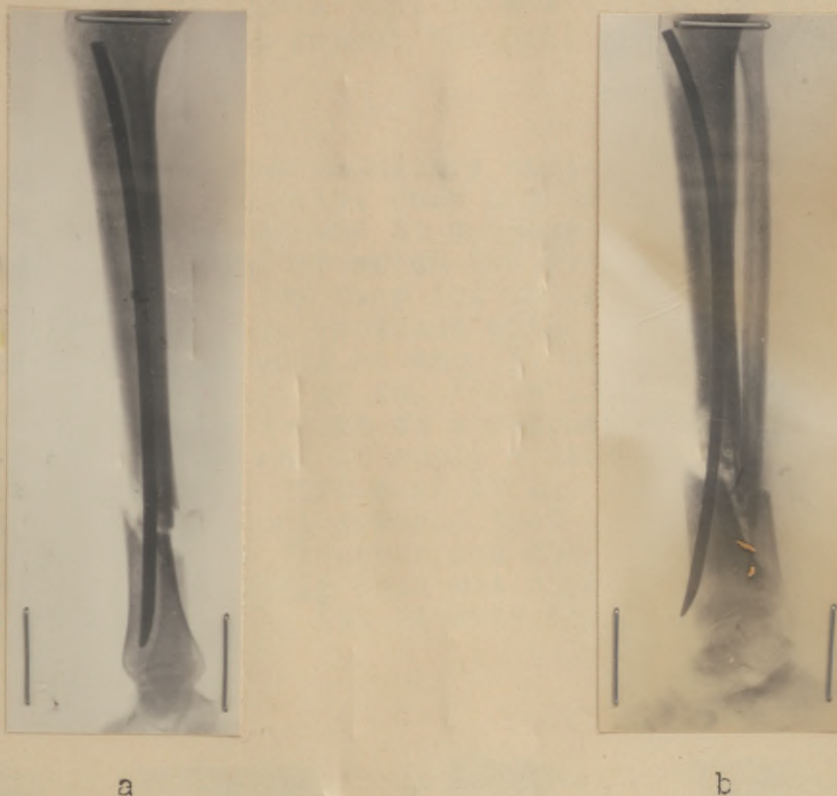

Illustration 39

- a) Medullary nailing of tibia fracture.
- b) Perforation of nail tip through corticalis and penetration into soft tissue.

Further incidents may arise from a disproportion between the guide-rod and the medullary nail. If the guide-rod chosen is too thin, the nail may deviate from it and be hammered through the wall of the bone.

Some of the failures may be traced back to deficiencies of material. SPRENGELL (36) observed a guide-rod breaking off in the medullary cavity of the femur. He hammered the medullary nail in nevertheless and he left the broken tip of the guide-rod in place. This caused no disturbance of fracture healing. The medullary nails themselves may corrode if the metal is defective and if the nail is in place for a longer time (SPRENGELL), and finally the nail may break. These nail fractures may be interpreted as due to a deterioration of the metal, if they are a level with the fracture cleft. An article about these so-called fatigue fractures of the medullary nail was published by STOTZ (37) of the Giessen hospital.

These fractures are most inconvenient as it may be impossible to extract the peripheral remnant of the medullary nail. BOEHLER (38) helped himself by introducing into the peripheral remnant of the nail a guide-rod, the tip of which was smoothed and rounded and bent at an angle of 90° for a length of 4mm. "As soon as fluoroscopy revealed that this nail had surpassed the nail tip, it was turned by 180° so that the angulated piece caught the nail. Thus it could be extracted."

Refractures over the medullary nail while still in place occur not infrequently. They may be due to the fact that the patients are allowed to subject the extremity to weight-bearing at a time at which the fracture is not united as yet by organized callus over its whole extent. Thus, if the patients suffer a new accident which need not be great, the bone is fractured again at the old site. We observed such refractures predominantly at the tibia (Illustration 40 and 41). Usually it is sufficient to straighten the fragments together with the nail and to apply a plaster cast subsequently. Conditions are different if the nail was already removed and a new accident severed that bone. If at this point of time the first fracture was completely consolidated, the new fracture frequently does not appear exactly in the line of the old fracture, but closely above or below it.

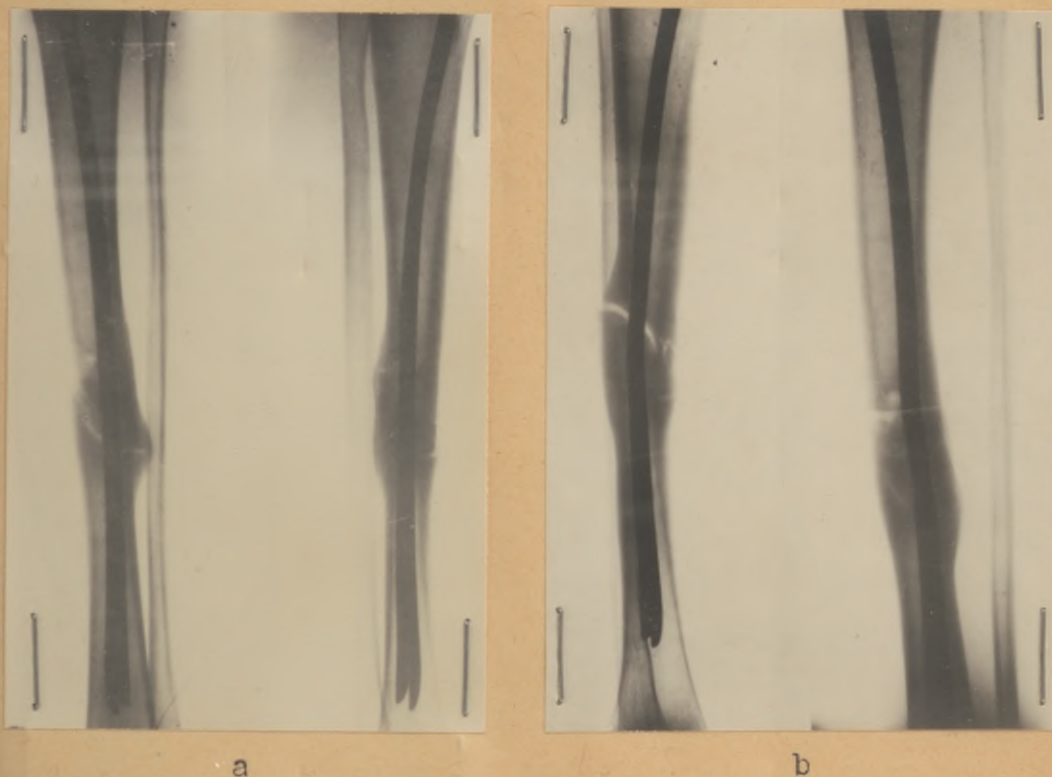
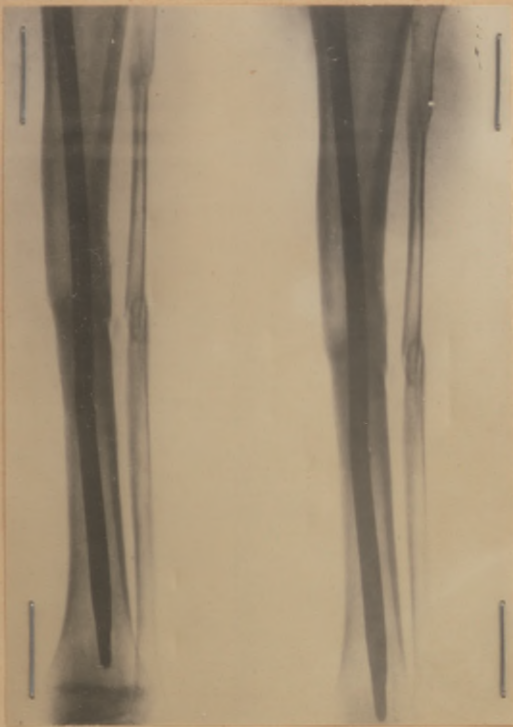

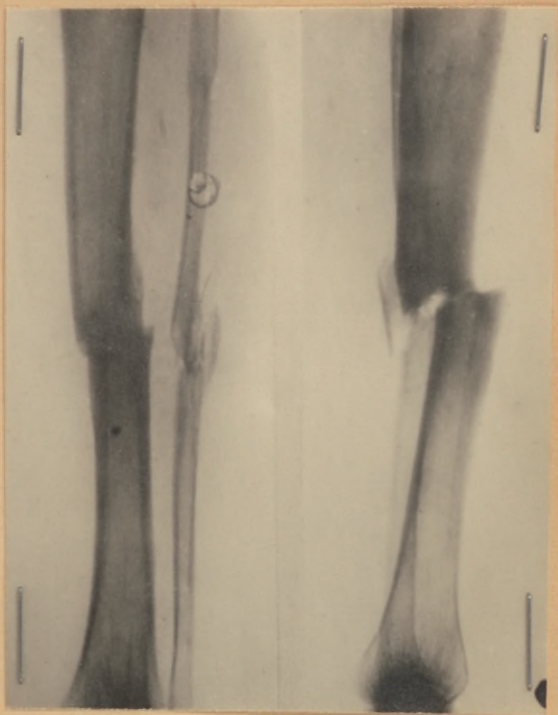Illustration 40
a) Freshly healed tibia fracture.
b) Refracture while double nail is still in place.

This is due to the callus being more resistant than the bone in the immediate vicinity, particularly if it is poor in calcium as a result of

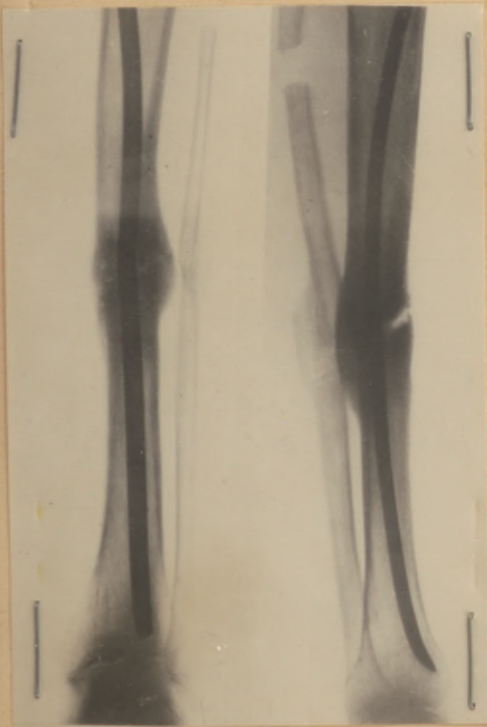previous prolonged treatment. In such cases a new fracture due to a new accident must be assumed in the expert opinion for the insurance company. Treatment may again consist of medullary nailing.



a



b



c

Illustration 41

- a) Healed leg fracture shortly before extraction of medullary nail.
- b) Refracture after extraction of nail.
- c) Medullary nailing of refracture, advanced stage of callus formation.

PERSONAL EXPERIENCE WITH MEDULLARY NAILING

OF SIMPLE FRACTURES.

During the period of time embraced by this report 102 simple fractures were treated with percutaneous medullary nailing at the University of Giessen hospitals. The majority of these fractures were femur fractures (45). Besides, there were 32 leg fractures, 18 humerus, and 7 forearm fractures. Our results are demonstrated in the table (Illustration 42). It reveals that bony healing without any complication was obtained in 82 cases corresponding to 80%. Complications were observed in 18 cases. They usually consisted of a delay of solidification of the fracture (12 cases), while slight infections were observed in 3 cases. Osteomyelitis was observed

Percutaneous Medullary Nailing of Closed Fractures

Bone involved	Number of Cases	No Compli- cations	Complica- tions	Reason for Failure	Number of Complica- tions or Deaths
Humerus	18	13	5	4 delayed healing, 1 slight infection	---
Forearm	7	6	1	1 delayed healing	---
Femur	45	40	5	4 delayed healing, 1 pseudar- throsis	1 death through embolism after doub- le nailing
Leg	32	23	7	3 delayed healing, 2 slight in- fection 2 osteomye- litis	1 death through em- pyema of knee-joint and throm- bosis of pelvic veins
Total:	102	82	18	---	---

Illustration 42

in 2 cases, both of them involving the tibia. Pseudarthrosis of the femur was observed in 1 case in spite of treatment by medullary nailing. Among these 102 closed fractures treated with percutaneous medullary nailing fatal outcome was observed in 2 cases, one of the patients dying from fat embolism after medullary nailing of both legs, the other one dying after the development of a knee-joint empyema originating from the medullary nailing of the tibia and causing a septic thrombosis of the pelvic veins. This latter case induced us to choose a place lateral to the tuberositas tibiae as the insertion site, since the perforation of the ligamentum patellae provokes the danger of infection for the knee-joint. At this time no penicillin was available.

The success obtained with regard to the adjustment of the fracture and above all the excellent mobility of the joints as well as the possibility to dismiss the patients early for ambulatory treatment with the medullary nail in place, determined us to continue with the method under consideration of the indication which was thoroughly discussed above. In the course of the last years we sometimes extended the field of indication, and sometimes reduced it according to the experience made. There is no doubt that the sulfonamides and principally penicillin are drugs which have a decisive influence upon the indication for the medullary nailing even of the compound fractures. This shall be mentioned here beforehand and with all due caution.

OPEN MEDULLARY NAILING OF PRIMARILY SIMPLE FRACTURES.

The preceding chapter outlining the range of medullary nailing within the conservative and operative fracture treatment, its general advantages and disadvantages, and some danger sources of a similar general nature, could treat their subjects with finality, as the principal problems of the method have been settled today to such an extent that vital points of a general nature no longer are a matter of discussion. The treatment of the indication for the medullary nailing of simple fractures could also proceed along similar lines: fundamental rules were established which most likely will not be subject to significant changes in the near future. These chapters were then followed by the description of the technique of the medullary nailing of simple fractures. The discussion of technical modifications as they were necessitated by the medullary nailing of compound fractures or by a simultaneous operative exposure of the fracture site, be it for reasons of reduction, or of osteotomy of old and unsatisfactorily healed fractures, was purposely disregarded. The description of the easiest technique employed in the ideal case of a simple fracture suitable for percutaneous nailing was to give a model of the typical procedure for every bone and its various types of fractures. This is to be considered as the basis of the technique and as an unalterable frame for the following discussion of the other possibilities for the application of the medullary nail. In every case of medullary nailing the operating surgeon must endeavor to adapt the operation to that schedule representing, if one might say so, the ideal technique, or with other words: the technical concept of the method. The topics of the following chapters, however, are still subject to change as the literature shows, and so far it has not yet been possible to establish a strict dogma in all points. We therefore deem it correct if in accordance with the variability of the procedure and of the results a greater space is reserved to the subjective character of the literature references and to our personal observations. We believe that it is only of advantage for the method if the success and the failures observed within our range of observation are put in the foreground, as finally it is only the free communication of all experiences which gives a rounded picture of the width of the field of medullary nailing as well as of the counter-indications.

It sometimes happens that notwithstanding all manipulations and reduction appliances a fracture cannot be reduced satisfactorily. Then, of course, it is not possible to introduce the medullary nail. These are the fractures which before the introduction of the medullary nail method necessitated operative reduction. The question is, whether

such operatively reduced fractures should be nailed or not. By the operative exposure of the fracture site one abandons the most important advantage of medullary nailing, that is a diminished risk of infection and the preservation of the biologic complex which is encompassed by the term "fracture focus". Strictly speaking operative reduction renders medullary nailing senseless. If, however, one is compelled to perform operative reduction, it is essential for the further course of fracture healing to select the correct method of retention. It rarely is possible to unite the fracture planes so securely by simple cogging that there is no hazard of dislocation after the application of a plaster or extension bandage. Therefore, we have to rely upon foreign bodies to retain the fragments in place. We have almost completely abandoned the use of Lane's plate as its application resulted in failures which could have been avoided with other methods. They usually consisted in loosening and bending of the screws, or a matter of greater consequence, in the formation of pseudarthrosis, because the splint apparently acted as a distension mechanism which prevented a close contact of the fracture planes. In the chapter dealing with pseudarthrosis such an example will be given. A wire suture applied through drill-holes in the longitudinal axis of the bone usually contradicts the most primitive laws of mechanics, and it is not able to provide a satisfactory fixation of the two fragments upon each other. One repeatedly however, observes fractures in which a wire loop applied in longitudinal direction attempts to unite the fragments firmly, an enterprise which is successful in very rare cases only and with bones of a small diameter (forearm). When regarding the way a joiner would proceed to fix two laths together, one will appreciate the inadequacy of these wire sutures. We are not quite sure as yet whether or not they exert an inhibiting effect upon the formation of callus as foreign bodies. It is, however, quite possible that this was sometimes the case. In the case of long oblique fractures and of spiral fractures a wire loop around the circumference of the bone (cerclage) is practicable. There is no principal objection against this method and later on we will be able to show that it can be used to advantage. But it is particularly these transverse fractures, eligible for operative reduction which cannot be treated by a wire loop slung around them. In these cases we several times employed medullary nailing for the purpose of retention and it yielded good results.

Regardless of the risk or the inoffensiveness, the positive or the negative value of the introduction of foreign bodies, one should always endeavor to disturb as little as possible the fracture site in which complex biologic processes take place. During discussions of the problem of buried foreign bodies the medullary nail was frequently rejected, because the medullary nail allegedly constitutes the biggest of all buried foreign bodies known so far and because it allegedly disturbs and impairs the progress of fracture healing. This reasoning most certainly is not correct. If foreign bodies disturb fracture healing this effect usually is due to faulty application. The numerous experiences made by the surgeons all over the world with the fastening of bone grafts during the treatment of pseudarthroses speak against damages caused by simple wire loops. VON ERTL(39) certainly goes to far in

generally rejecting the wire suture and the wire loop. An insufficient immobilization resulting in the disturbance of fracture healing, or other mechanical deficiencies such as the distending effect of Lane's plate may be a factor of much greater importance than the fact that the nail is a foreign body. One should not expect one or two wire loops to produce an absolutely stable fixation of a fracture without an additional external support, particularly if, as is the case with the femur, one has to deal with extremities of considerable weight constituting long levers. We believe that these factors frequently are responsible for the technical deficiencies, but that they are not the effect of the foreign bodies alone. As for the medullary nail it must be said that it has no contact with those tissues in which the healing of the fracture takes place, that means with the periosteum and the muscular coat. The medullary nail constitutes no foreign body in the fracture. Its effect upon the bone marrow also cannot be the reason for its rejection as a means for retention after operative reduction, since it became obvious by innumerable percutaneously nailed fractures that this factor plays no essential part. In fact the medullary nail represents the best instrument for the fixation of the transverse fractures after they have been reduced operatively and no better method is available (SCANZONI (40)). Moreover, the operative reduction using the medullary nail is much more conservative than the use of other foreign bodies, as the intervention at the fracture site itself is limited to a minimum, to reduction exclusively, and as no further damage is caused particularly as regards the periosteum. This also eliminates any debate as to whether or not transverse fractures can primarily be treated by a locking bone graft. In addition the medullary nail frequently can be inserted from the fracture site after exposure and this increases the security and the speed of the intervention. Furthermore all the other general advantages of medullary nailing are positive factors, above all the short time of confinement to bed, and the possibility to begin exercises early.

As regards technique the open medullary nailing of the femur offers several peculiarities and therefore it shall be described separately. The fracture is exposed by a longitudinal incision at the lateral aspect of the thigh. The best position of the patient on the operating table is a slightly oblique one. The use of the extension apparatus is only necessary in the case of a considerable longitudinal shortening but it is advisable in any case to apply the extension sleeve to the foot before the operation, as it may become necessary to apply strong traction during the operation. If the obstacle to reduction is eliminated the long guide-rod is introduced from the fracture site into the medullary cavity of the proximal fragment, and it is pushed upwards immediately. At the proximal end of the bone the tip of the guide-rod protruding beside the trochanter major is exposed by the same short cutaneous incision as is practised with the percutaneous medullary nailing. Now, the medullary nail determined as to length and thickness is guided over the rod from above as usual, and

it is hammered in until it appears in the fracture cleft. Subsequently the guide-rod is withdrawn through the lateral incision, it is turned round and inserted from above into the nail which now guides the rod. The guide-rod also appears in the fracture cleft, the fragments are united by single-pronged hooks, and the guide-rod is inserted into the distal medullary cavity. From now on medullary nailing is performed as usual. The wounds are sutured and the extremity is bedded, or a plaster cast is applied if necessary. If it is not possible to unite the fracture planes despite extension, which may occur with old neglected cases, one may be successful if one angulates the fragments to a great extent (There is an instructive illustration of this proceeding on page 13 of the monograph prepared by KUENTSCHER and MAATZ on the Technique of Medullary Nailing). By no means, however, should one extend the femur too abruptly in one session, as there is the danger of a rupture of the intima of the arteria femoralis.

The hazard, of infection is not greater with the medullary nail than ^{with} any other operative reduction. If one has reason to worry about the aseptic performance of the intervention it is recommended to powder the wound with sulfonamide (marfanil-prontalbin) and to give an injection of sulfonamides or penicillin subsequent to the operation. Here, too, the approved principle is valid that an absolute immobilization is the best means to prevent infection. This purpose is served in the first place by medullary nail, but one should not forget that the immobilization of the soft parts is of just as great importance.

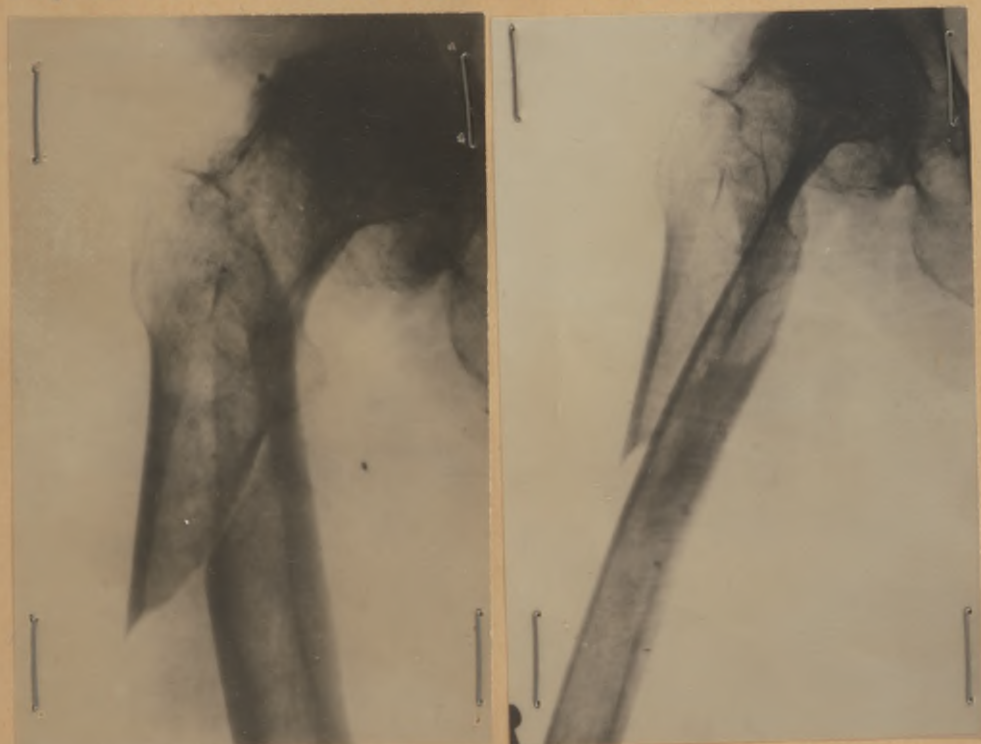
In addition to the fractures which due to difficulties of reduction are reduced operatively, the long oblique and spiral fractures also are eligible for operative treatment, as wireloops put around the fracture planes lying obliquely upon each other offers the safest means for an exact reduction and retention of these special types of fractures. In such cases one, therefore, will frequently decide in favor of a primarily operative treatment involving the exposure of the fracture. In consequence of the opening of the medullary cavity which mainly runs in a longitudinal direction, medullary nailing is not always capable of immobilizing the fracture sufficiently. The fragments may separate as well in a lateral direction so that the medullary nail finds only an insufficient hold in the short parts where the bone is intact and a longitudinal displacement and rotation of the fragments over the inserted nail is to be feared with long oblique fractures and with spiral fractures (dislocatio ad peripheriam).

On the thigh and on the leg DECKER(41) used to expose the fracture and to perform simple looping with catgut or silk threads. He did not employ medullary nailing in such cases for fear of the additional

operative strain for the patient. His concern as regards the immersion of foreign bodies was so great that he applied only one single looping (cerclage) possibly not consisting of wire, and that for elimination of any further disturbance of the condition of the fracture he performed these operations in bed for many years. Additional fixation was accomplished by means of wire extension which remained in place even after the operative fixation, or plaster cast was used for this purpose. Even short oblique fractures which can just be held by the loop, were treated in this way. The result of such a treatment was satisfactory and since 1934 there was no case of infection.

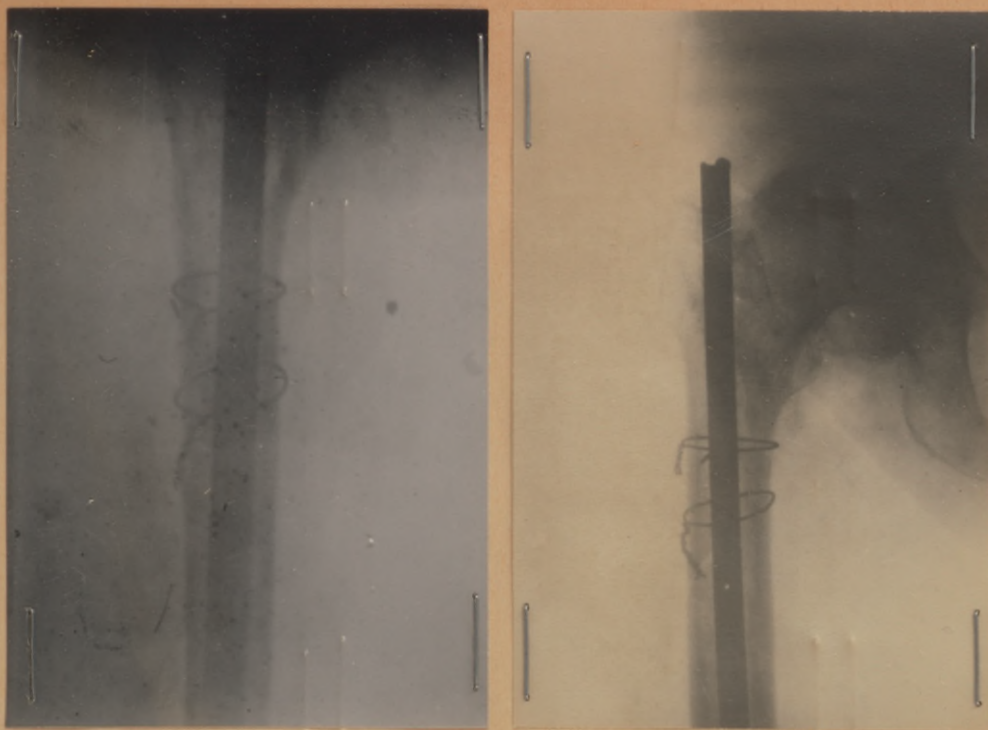For the operable oblique and spiral fractures to be selected in every individual case we chose a compromise by combining the wire loop with medullary nailing. In this case one may restrict oneself to one or two wire loops and thus take care that the fracture is spared, while the remaining part of the fixation is left to the medullary nail. Wire looping, therefore, restores so to speak the continuity of the osseous tube required for medullary nailing, and the conditions are created for the use of the nail with all its well known advantages. A medical history and several illustrations may serve as an example:

Medical history: Lucie H., 67 years old, slipped and fell on an even floor on 10 January 1948. She suffered a long oblique fracture of the right femur shaft; the hip-joint was completely stiffened in consequence of a previous arthrosis deformans. On January 12, 1948, the fracture was reduced operatively, and the fragments were immobilized by wire loops. The medullary nail was inserted at the site of the operation wound (spinal anesthesia). The wound healed without any complications after it was bedded upon a Volkmann's splint. Walking was resumed first on February 4th 1948, and the patient was dismissed for ambulatory treatment on February 28th 1948. The joints were mobile to the same degree as before the accident (Illustration 43).



a

(Text see next page)

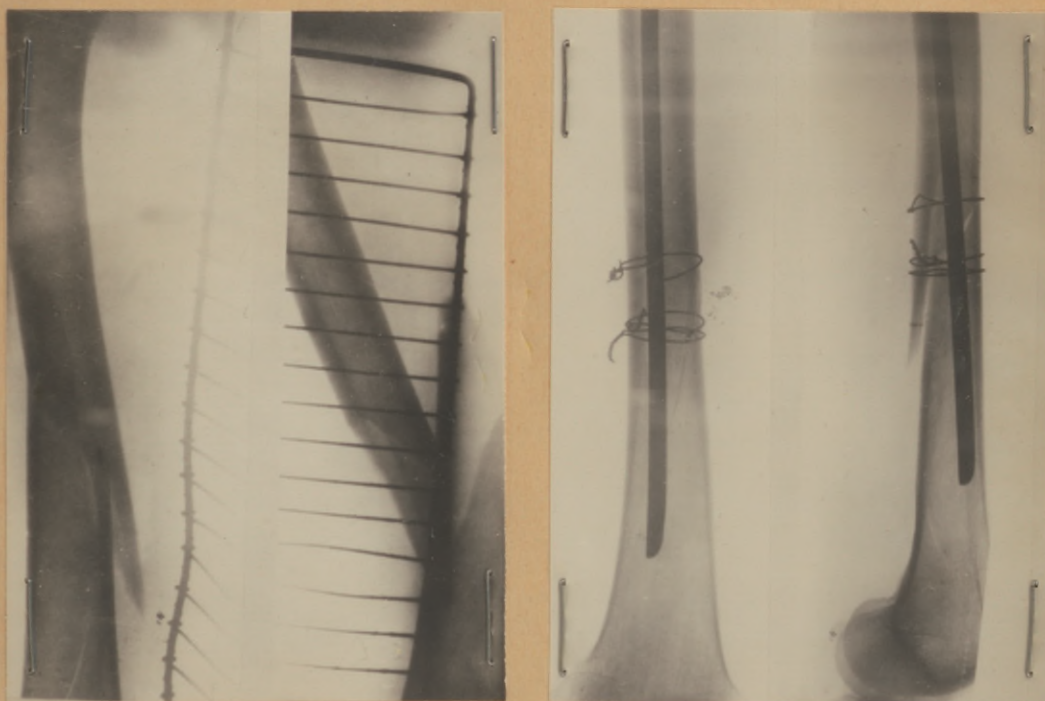


b

Illustration 43

- a) Long oblique fracture of femur.
- b) Condition after wire looping and medullary nailing.

The therapeutic result obtained with another case created in the same way is shown in Illustration 44.



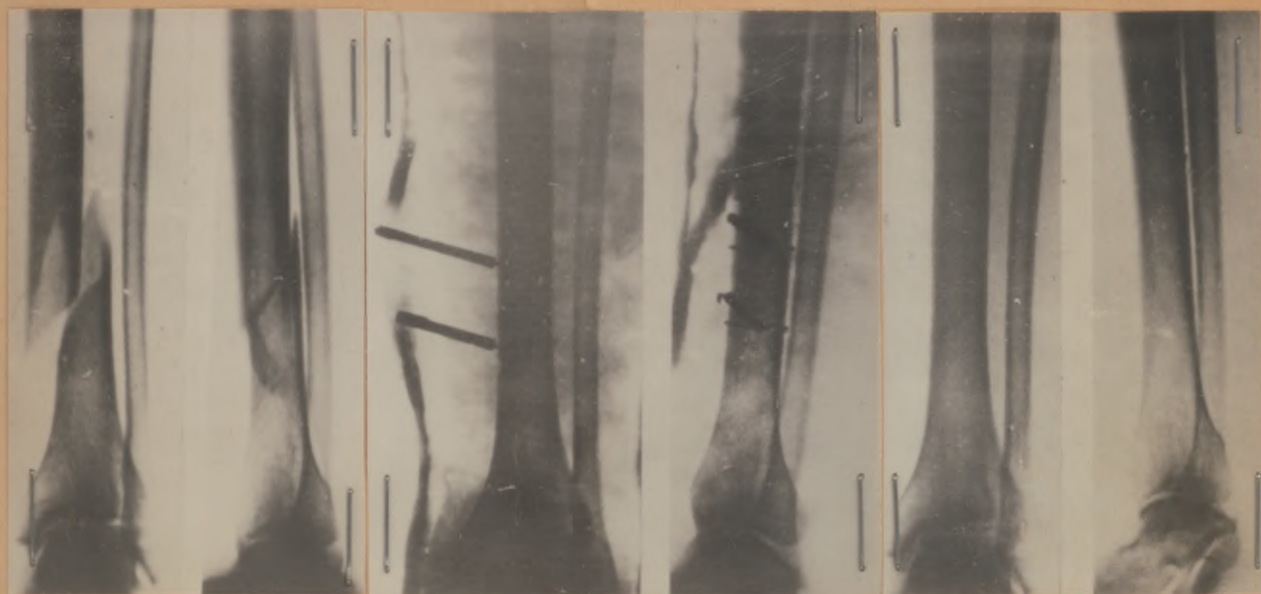a

b

Illustration 44

- a) Spiral fracture of femur.
- b) Condition after wire looping and medullary nailing.

For some of the oblique and spiral fractures of the leg no medullary nailing was required in addition to the wire loop (Illustration 45). In such cases the method suggested by MAGNUS, the so-called MAGNUS-tube has proved useful, so that we shall employ it again in suitable cases. It seems



a

b

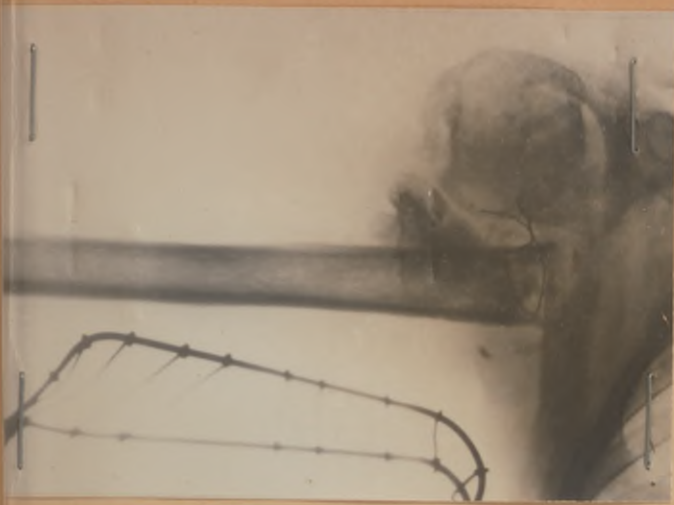c

Illustration 45

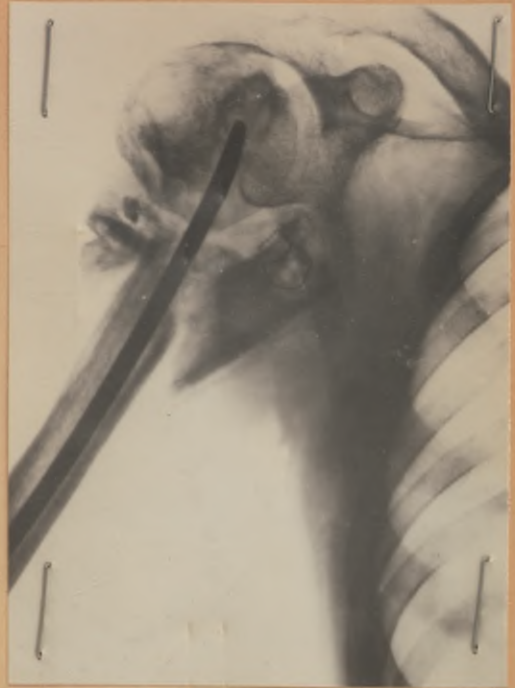- a) Oblique fracture of leg.
- b) Fixation of fracture by wire loops and Magnus-tube.
- c) Condition after healing of fracture and removal of wires.

that the method presently has been forgotten, a fate it really does not deserve. In our cases the fixation of the tibia fragment was so stable that we could abstain from additional medullary nailing. The application of Braun's splint and an early walking cast yielded excellent results even with regard to the mobility of the joints. In these cases medullary nailing would not have offered a note worthy advantage. One always must be aware of the fact that schematized fracture treatment is by no means ideal. The choice of the most adequate method for every individual fracture should be based on the multitude of the available methods and if after the examination of all advantages and disadvantages one is under the impression that less severe interventions lead to better results they must be given priority before medullary nailing.

Although it is a fundamental feature of the medullary nailing method that it renders operative reduction of not primarily complicated fractures superfluous in fresh cases, there are nevertheless older fractures or such fractures which are on the border between fresh and old, which cannot be reduced to a satisfactory position by conservative measures. They are usually fractures which even with the application of the usual types of treatment would have required operative reduction particularly when attempts for conservative treatment had no success. In a certain number of such cases medullary nailing may be a profitable means for retention subsequent to the operative union of the fragments. As an example I would like to mention the case of a subcapital humerus fracture which in another clinic had already been the object of a futile attempt to unite it with wire sutures (Illustration 46).



a



b

Illustration 46

- a) Old subcapital humerus fracture after wire suture performed in another hospital.
- b) Condition after operative reduction and medullary nailing from the distal end.

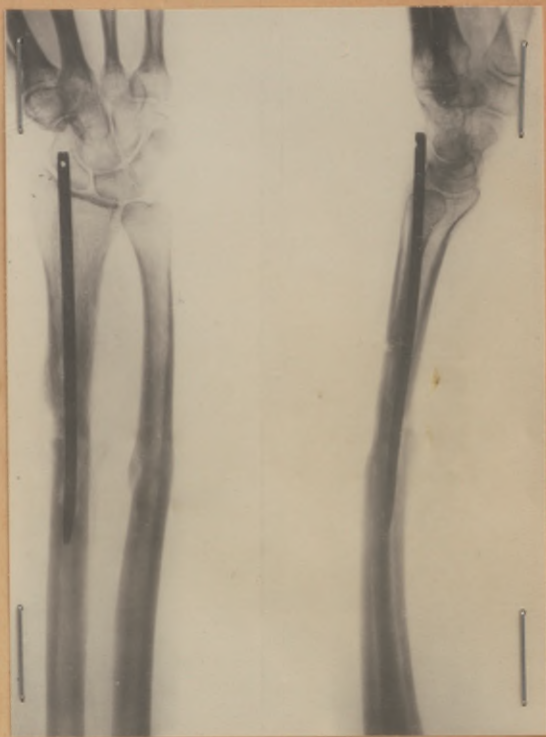In this case reduction was achieved operatively and it was kept stable by the medullary nail. The conditions required that here the nail was hammered in from the humerus shaft towards the proximal end which is not the typical procedure. When discussing the indication for the medullary nailing of the humerus fractures we contended that the subcapital fractures are suited for medullary nailing though not without restriction. We still hold the same opinion and the above mentioned case of medullary nailing used for the treatment of such a fracture is no proof of the contrary. It only shows that in special cases medullary nailing may successfully be used with a subcapital fracture too. One may even contend that any other method would hardly have been able to achieve retention of such a fracture which for mechanical reasons is very difficult to treat so satisfactorily as was feasible with medullary nailing.

The fractures of the forearm shaft range among the types of fractures which also most frequently offer considerable difficulties to reduction. Some of the obstacles observed in these cases may certainly be overcome by medullary nailing if one only is successful in reducing at least one of the two bones and in fixing it with the medullary nail. Here an attempt at medullary nailing is also permissible if reduction prior to medullary nailing was not successful, as sometimes a medullary nail introduced into one of the fragments provides the possibility of controlling the bone in such a way that finally the nail tip stands opposite the medullary cavity of the other fragment, so that the nail can be driven into it. If reduction fails even though such a stratagem was employed, the operative reduction of such fractures is indicated. Here medullary nailing renders the operation very sparing and economic, as in many cases there is no need to

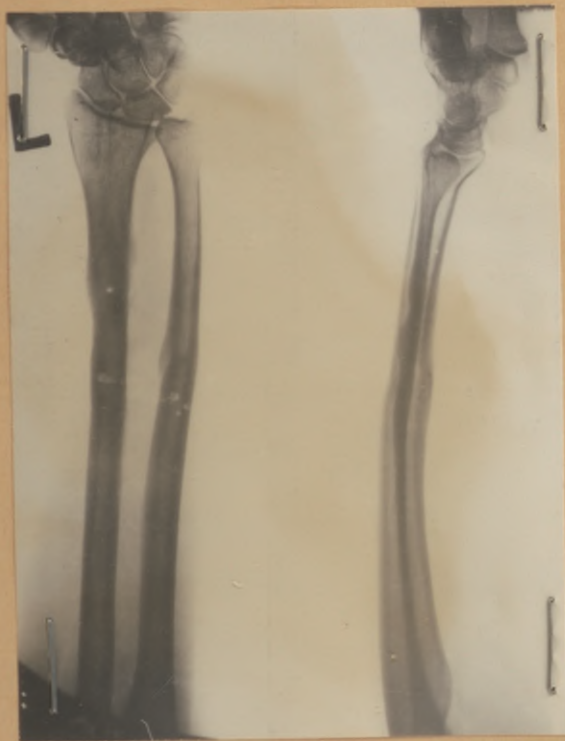nail more than one bone, because the other one assumes a good position automatically after a good anatomic adjustment of its neighbor. Thus, for instance, in the case of a 4 week old forearm shaft fracture only the radius was reduced operatively and nailed with the final result of an ideal adjustment of the ulna the fracture of which was soon consolidated subsequently, while the nailed radius took more time for bony consolidation (Illustration 47).



a



b



c

Illustration 47

- a) Transverse fracture of forearm.
- b) Medullary nailing of radius. Healing has set in on both bones of the forearm.
- c) Healing of fracture and removal of medullary nail.

These few hints may be sufficient to throw a light upon the actually rare necessity of exposing a primarily closed fracture for the purpose of reduction and medullary nailing. Considerably more significance must be attributed to the oper-

ation in the fracture site for the treatment by osteotomy of fractures healed in an inadequate position and also for the elimination of pseudarthroses.

INDICATION FOR MEDULLARY NAILING
OF COMPOUND FRACTURES.

The decision of whether or not in the case of compound fractures medullary nailing has to be considered as indicated is grave, unavoidable, and of fundamental importance.

So far the basic principle to be applied to the treatment of a compound fracture was to convert it first to a closed fracture, and even this was only practicable if the wound had not to be considered as seriously infected. In cases of serious infection or contamination the excision of the wound (FRIEDRICH) is not reliable and open wound-treatment must, therefore, be taken into the bargain. Although medullary nailing does not break with these principles to a large extent, it cannot be denied that it causes a breach in the wall of this thousand-fold approved principle. This was mentioned above, when the range of medullary nailing within the methods applicable for fracture treatment was discussed.

It may be appropriate here to say a few words about the significance of the term "compound fracture". It is necessary to narrow the meaning of this term, that means to outline it more precisely, and one should not count every fracture combined with an additional wound among the compound fractures as is frequently done. Rather, it is absolutely clear that only such fractures can be considered as compound fractures where the fractured bone came into communication with the outer world. In most of the cases this happened in such a way that one of the broken bones pierced the soft tissue from within. It is most important to know this fact, as such a mechanical process is less apt to cause soiling of the wound than a complication of the fracture as the result of direct force acting from without. This is important for the particular reason that in the former case rather than in the latter one may hope to restore aseptic conditions by operative wound treatment, and to nurse the wound after closing it. An additional soiled injury which does not communicate with the fracture cannot be classified as a compound fracture.

The surgical treatment of the complicating as well as of the non-complicating injuries has to follow the lines of general surgery. The investigative work of the generation of surgeons subsequent to FRIEDRICH has developed the eight-hours limit. These principles are also valid for the medullary nailing of compound fractures which will be shown as really possible and the only matter of importance is, whether these principles permit surgical wound treatment with primary suture and a transmutation of the open fracture to a closed one or not. If this is not the case, the compound fracture cannot be treated by medullary nailing. If these approved principles are considered, skill and experience will succeed to keep the breach broken into them as small as possible.

It is of great value that during the first years of medullary nailing a current and unrestricted record was kept about the success and the failures of the method. Thus it was possible to recognize the true amount of the failures and particularly of the infections which sometimes took a fatal

course. The number of failures is by no means so great as to have a negative effect upon the validity of the method. Rather, the analysis of the cases of infection gave sufficient clearness about the range of indication for the medullary nailing even of compound fractures (FISCHER and REICH (42)), EHALT (43).

Nevertheless BOEHLER (44) shows some reluctance against the nailing of fresh open fractures. "The prerequisite for a satisfactory result is a thorough wound excision and a dermal cover free from tension." - "The open medullary nailing of the open leg fractures was a failure, and I therefore forbade it in my sphere of work."

Even though infections of the medullary cavity occur, they usually are easy to control, as the medullary nail itself, so to speak, acts as a drain, and as in addition one must take into account that the fracture is immobilized by the nail to such an extent as might ever be desired. A phlegmon of the whole marrow cavity is an extraordinarily rare occurrence, as revealed by the literature and personal experience. Conditions were considerably improved during recent years by the possibility of administering sulfonamides and above all penicillin to the patients. It was mentioned earlier and we would like to repeat it here that with the help of penicillin one is entitled in many cases to make a primary suture and to perform medullary nailing of complicated fractures. This was not permissible prior to the penicillin era. We even believe that this kind of treatment, if applied in the right manner, no longer constitutes a risk or a heroic attempt, but that our ideas regarding the treatment of infected wounds and complicated fractures may even become subject to fundamental changes. Under the right manner we understand the responsible combination of the operative wound treatment with the immediate administration of penicillin in a sufficient dosage within the eight-hour limit. To the same measure to which the indication for the primary wound suture of infected wounds is extended, the field of application of medullary nailing is enlarged. It therefore is not true that the principles valid so far and outlined above could or should be disregarded, but it is rather this enlargement of the field of indication which evokes and requires the sense of responsibility of the surgeon.

FISCHER and REICH (45) are in favor of the medullary nailing of compound fractures, and they believe that the medullary nail may remain in place in spite of suppuration, as with their cases the process of inflammation was restricted to the fracture site and to the bone marrow, and as no diffuse phlegmon of the bone marrow and no progressive osteomyelitis developed.

EHALT (46) recommends the medullary nailing of open fractures, while FISCHER and MAATZ (47) have abandoned medullary nailing of severe compound fractures. They also underline that compound fractures must be nailed immediately if one wants to avoid the hazard of infection. MAATS and REICH (48) gave detailed records about the course of a bone infection after medullary nailing, and they drew the same conclusions as FISCHER and REICH. However, among their patients there were several cases of serious sepsis which in the final analysis had to be charged to medullary nailing. The thorough description of these cases was very instructive.

In accordance with these directives the Giessen clinic attempted the medullary nailing of compound fractures with great caution. This is also the reason why we do not yet possess so numerous material as to be able to give percentages with regard to success and failure or complications. We must, therefore, restrict ourselves to five medical histories as examples. We believe, however, that the study of this delicate chapter of the Kuentscher Nailing is better made in the form of accurate reports on individual cases, than in the form of greater statistical compilations, which cannot give indication of the difficulties and problems to be overcome with the medullary nailing of compound fractures to an extent as it is possible with the aid of the individual case history. We are not so much concerned with showing a large number of fractures healing smoothly and without complications after being treated with medullary nailing, but rather with stressing what must and what may be done.

As regards the technique of the medullary nailing of compound fractures, the following method proved useful. The position to be selected should be the same as with percutaneous medullary nailing of closed fractures. Then wound excision should be accomplished first, but the wound should not be closed yet. After the excision of the wound the medullary nail is hammered in with a clean set of instruments until it arrives at the fracture site. If one is not immediately successful in passing the fracture site and in introducing the medullary nail into the cavity of the distal fragment, one had better keep the wound gaping open by hooks and the insertion of the nail into the distal medullary cavity is performed under direct vision. One goes through the wound already present, while for the open medullary nailing of primarily closed fractures a particular incision is made to expose the fracture site. When medullary nailing is terminated, the wound is powdered with merfanil-prontalbin sulfonamide powder and sutured.

Medical history: A.W., 27 years old. Comminuted fracture of the right femur due to pistol shot on June 11th, 1947 (Illustration 48). The patient was operated on immediately, the entrance and exit wounds were excised,

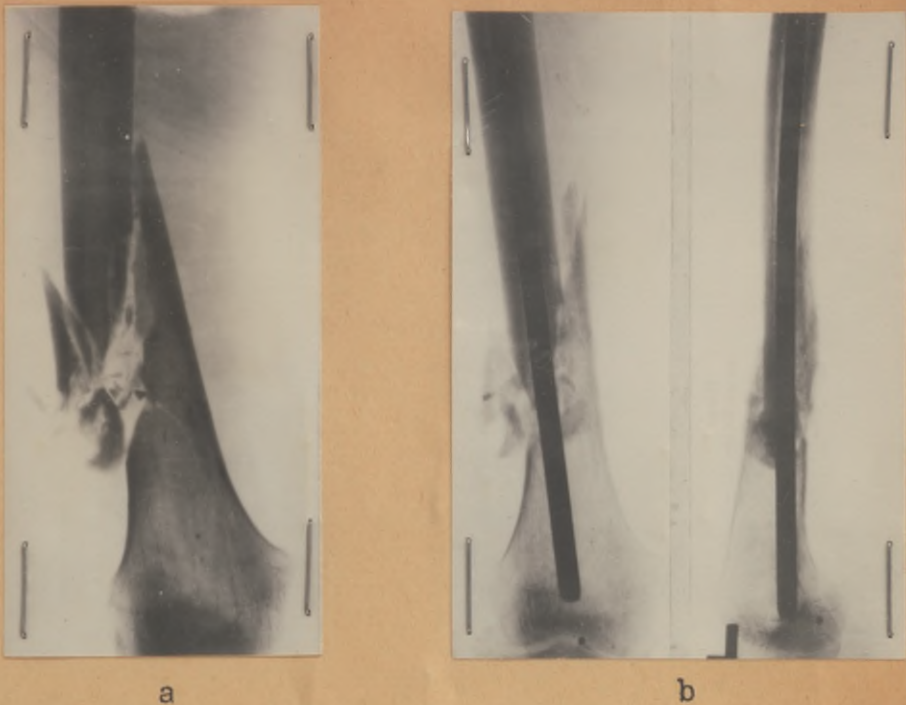


Illustration 48
a) Gunshot fracture of femur.
b) Condition after medullary nailing.

and percutaneous medullary nailing from the trochanter major was performed. The wound was sutured per primam and 1 million units of penicillin were given subsequently by administering 30,000 units every 2 hours. On August 2, 1947, the patient was dismissed. The fracture healed in a satisfactory position without any complication. 4 months after the gunshot fracture, on October 13, 1947, the condition of the fracture was good, as shown in the illustration.

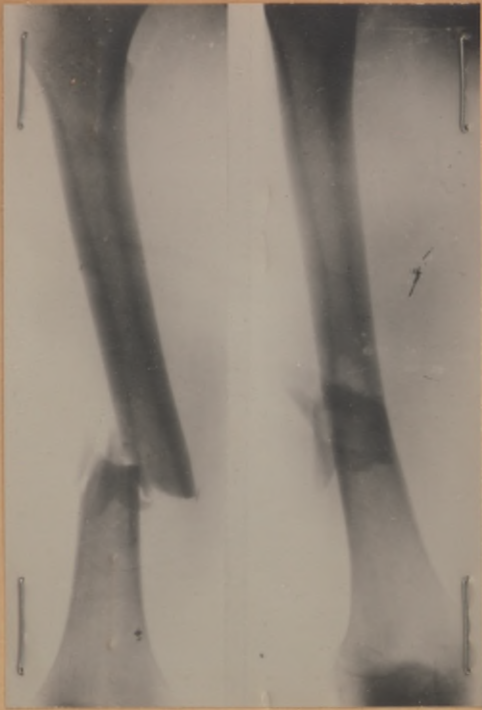This case reveals that even gunshot fractures may be treated with medullary nailing, if excision of the wound and medullary nailing are performed within the eight-hour limit, and if penicillin is available. We shall give a separate record about the gunshot fractures when the compound fractures will be discussed.

Medical history: A.R., 28 years old, was the victim of a traffic accident on November 26, 1945 whereby he suffered a femur fracture on both sides as well as a compound fracture of the right leg. Both femora were treated by percutaneous medullary nailing. The complicating wound on the leg was carefully operated on, and it was sutured under the ample use of marfanil-prontalbin powder, as the eight-hour limit had already been exceeded. The tibia too was treated with medullary nailing. The wounds had healed on December 7, 1945. Later on a slight suppuration was observed on the wound of the leg, although in the beginning there were

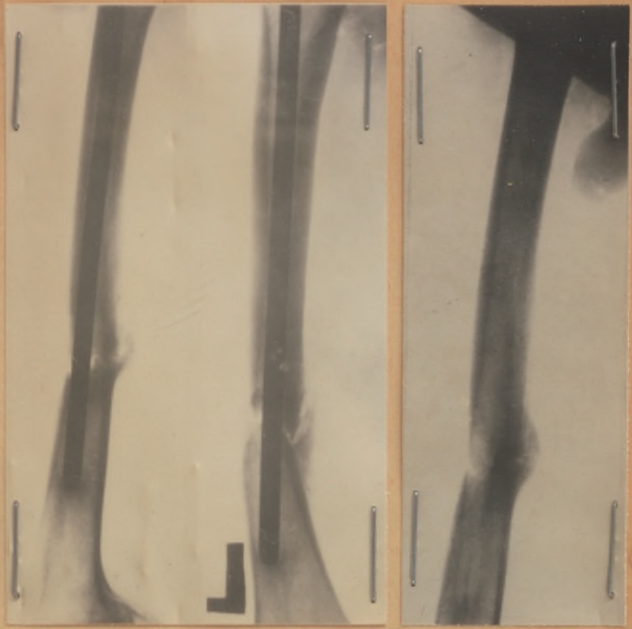
no signs of disturbed healing. Because of the distending effect of the fibula, a fibular resection was made on February 14, 1946. The spot beside the tuberositas tibiae, where the medullary nail was driven in, began to secrete slightly during the month of February 1946. At that time as a precautionary measure (March 9, 1946), the medullary nail was extracted from the tibia, and a circular plaster cast was applied. The suppuration decreased in the course of time. Later on (June 27, 1946) an abscess was formed on the right leg, an incision was made, and two medium-sized bone sequestra were removed. Subsequently suppuration ceased, and the patient was dismissed on October 3, 1946, to ambulatory treatment. During the following period of time several incisions were necessary as circumscribed abscesses had formed several times. The suppuration was always easy to control. The medullary nail of the left femur was removed on January 8, 1947. On January 21, 1947, the patient was readmitted because of a refracture of the left femur. Medullary nailing was performed again and then a satisfactory callus formation set in. The femur was readjusted satisfactorily. The medullary nail of the left femur is still in place, because on the roentgenograms the fracture cleft is still visible in outlines (Illustration 49). The various incidents had the result that the medullary nail in the right femur was not removed either although it would have been practicable according to the condition of that fracture; but there was no need for precipitate action. The joints of the two legs are freely movable in spite of the prolonged treatment with the exception of a slight impediment of the right upper foot-joint.

This case showed that medullary nailing of several simultaneous fractures is quite possible, and here it was the only means to obtain a free mobility of the joints. The transitory secretion of pus did not prevent a satisfactory final result. It is, however, quite possible that the course of healing would have been much more favorable if penicillin had been available.

Medical history: P.H., 15 years old, suffered a compound fracture of the right femur on April 15, 1946, when he was run over by a tractor. Operation was performed immediately. The wound was excised and a medullary nail was introduced from the exposed fracture. Marfanil-prontalbin powder was sprayed over the wound, which was sutured, and only a thin subcutaneous rubber drain tube was laid into the wound. This drain was removed on April 17, 1946. The progress of healing showed no complications, the leg was first subjected to weight-bearing on May 5, 1946, and the patient was dismissed for ambulatory treatment on May 18, 1946 (Illustration 50).

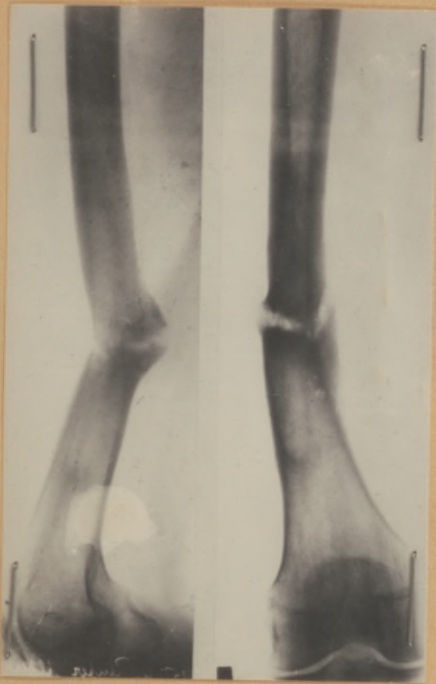

a

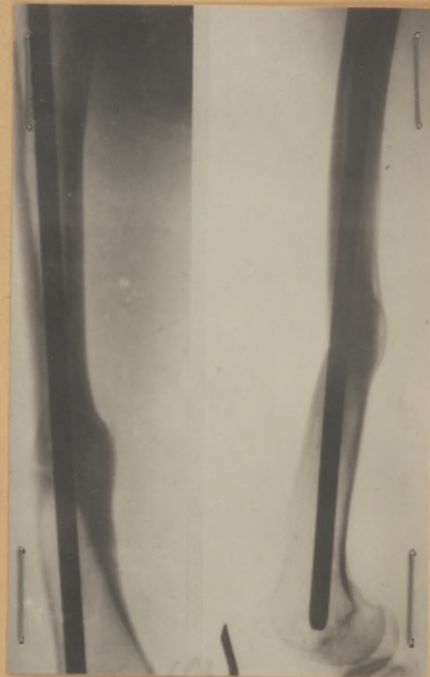

b

c



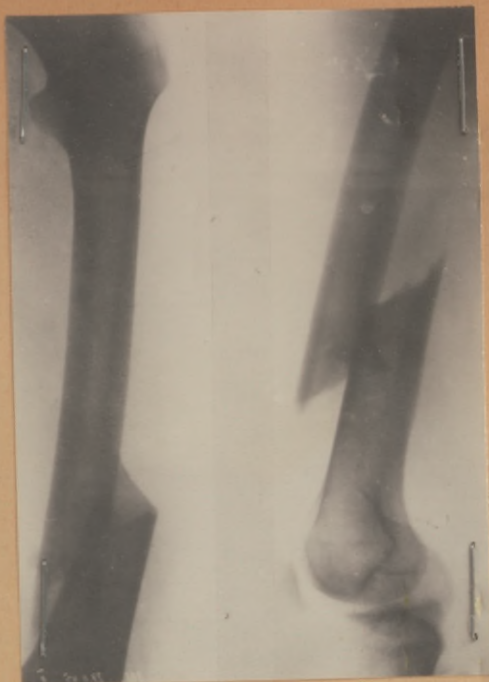d



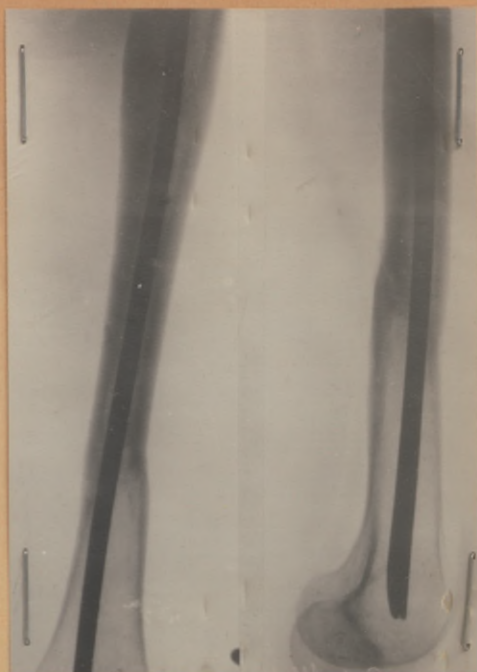
e

Illustration 49

- a) A.R., 28 years old, transverse fracture of left femur (simultaneous fracture of right femur and leg).
- b) Medullary nailing with too short a nail.
- c) Condition after healing of fracture and removal of medullary nail.
- d) Refracture of left femur. This was due to insufficient fixation during treatment, the nail being too short.
- e) Condition after second medullary nailing because of refracture. Good progress of callus formation.



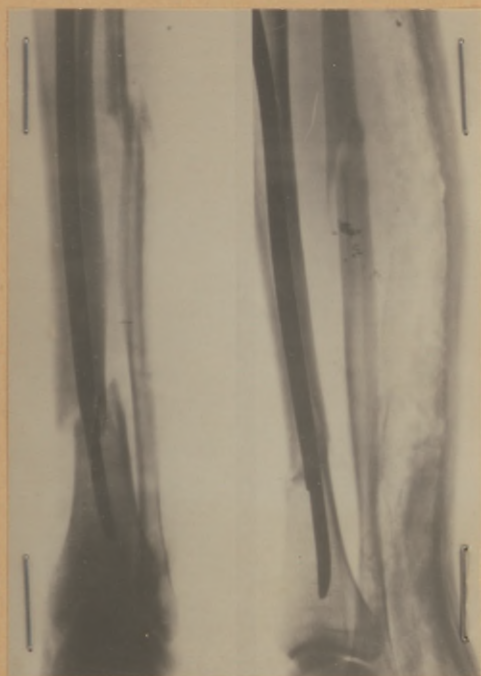f



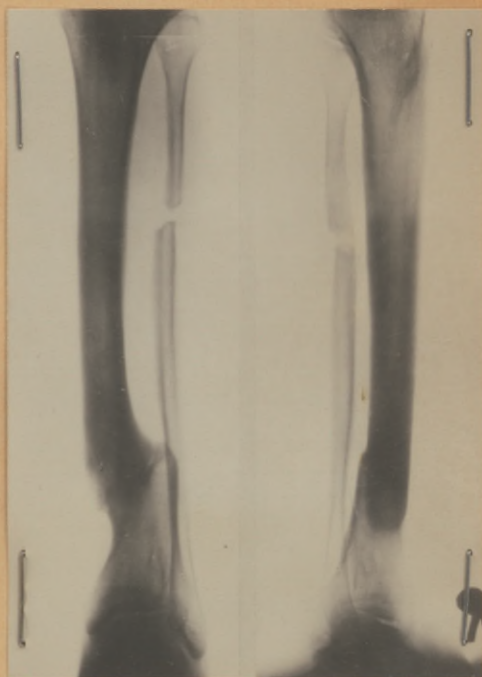g

Illustration 49 (cont'd)

- f) Oblique fracture of right femur (simultaneous fracture of left femur and right leg).
- g) Medullary nailing. Good progress of callus formation.



h



i

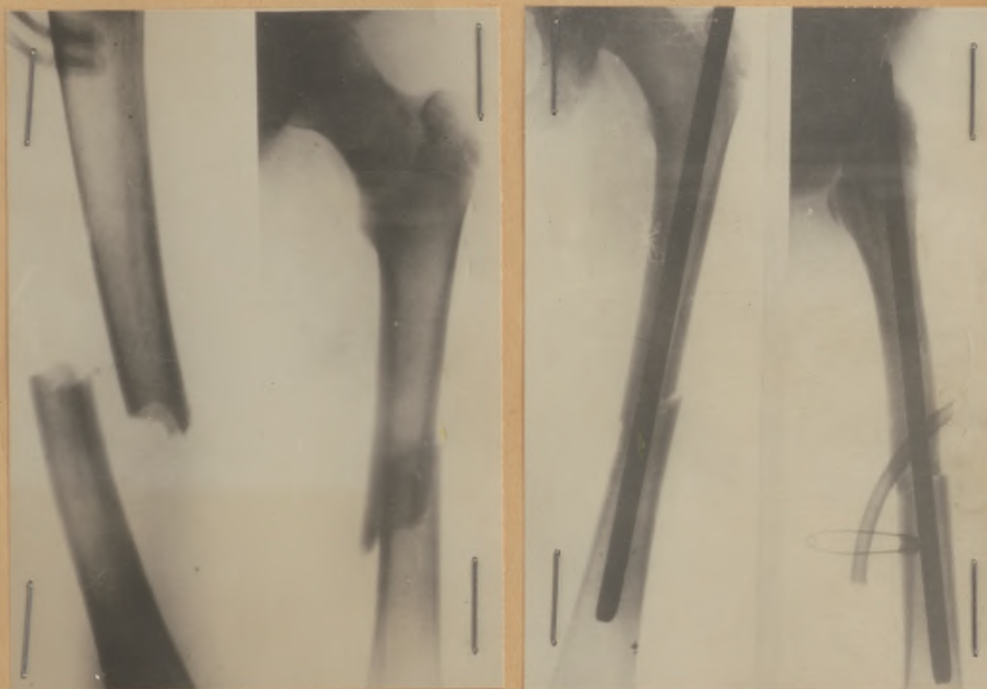
Illustration 49 (cont'd)

- h) A.R., 28 years old, compound fracture, leg treated with a double nail (simultaneous femur fracture on both sides).
- i) Condition after healing of fracture and removal of medullary nails. In the course of treatment resection of tibia was necessary. The tibia fragments were shifted by half the width of the shaft, as the fracture was not very suitable for medullary nailing because the distal fragment was too short.

The latter case shows the course of a femur fracture which was immediately treated in the correct way. Illustration 51 shows the undisturbed healing of another nailed compound fracture of the leg, as well as Illustration 52. Today we would immediately commence with penicillin treatment for security reasons together with simultaneous medullary nailing. But in the case described above this was not necessary. We dispose of a larger number of compound fractures, which had healed without any complications after reduction and medullary nailing within the eight-hour limit.

An early, most preferably prophylactic administration of penicillin is apt to soothe all worrying, which is always in the background when complicated fractures are nailed. Under the protection of penicillin which in this particular case was immediately available, we excised the considerably soiled wound of the complicated leg fracture and we sutured it per primam, while there was a considerable tension. Medullary nailing was accomplished within the eight-hour limit. The undisturbed course of the wound healing per primam and without any rise of temperature is particularly apt to demonstrate the great gain which is represented by this for the time being latest form of fracture treatment. As early as 4 weeks after the injury, the patient could get up with a walking cast and as regards the fracture, this would have been possible earlier, if there had not been a simultaneous cerebral concussion prolonging the period of confinement to bed.

Conditions are somewhat different in the following case which shows that even severe injuries which at an earlier time almost certainly would have necessitated the amputation of the limb can in an excellent way be treated with medullary nailing and penicillin, thus enabling the preservation of the injured extremity.



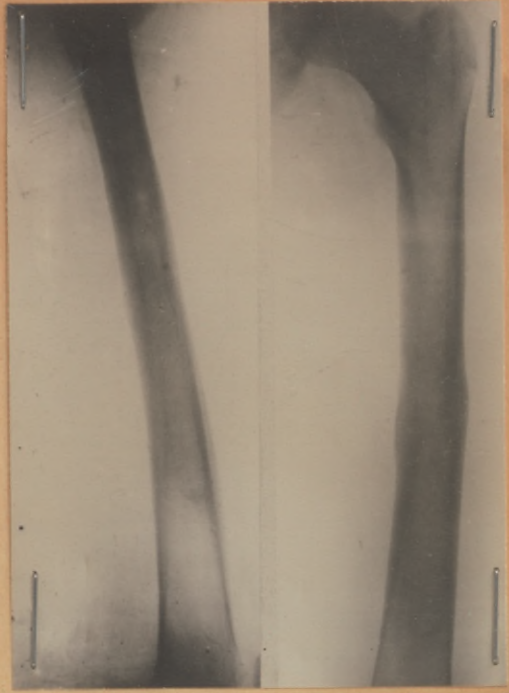a

b

(Text see next page)



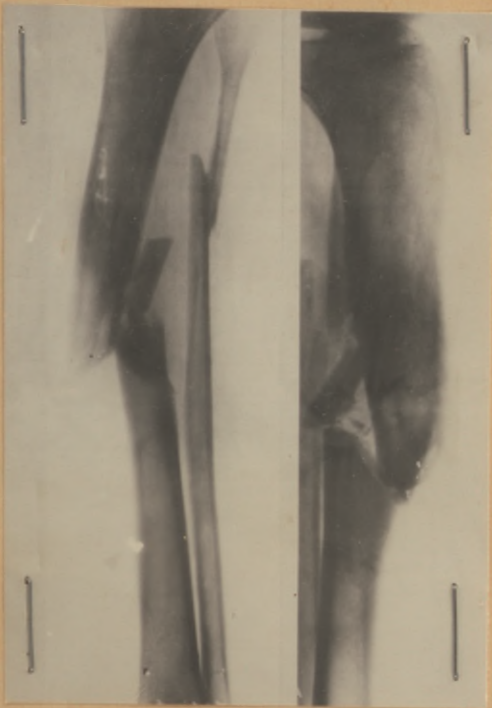
c



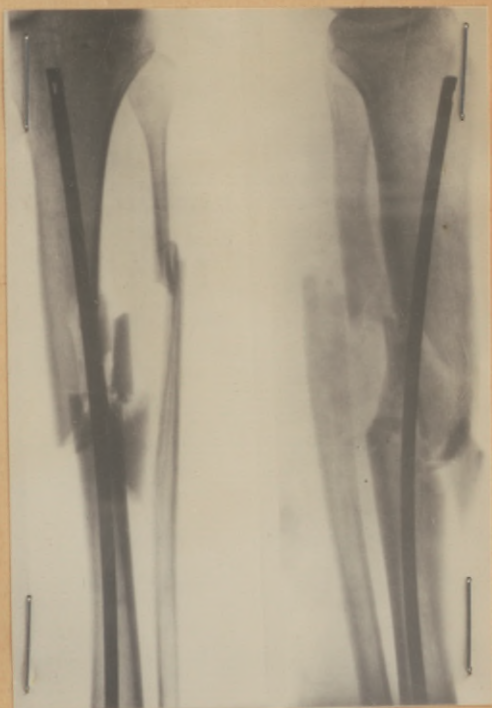d

Illustration 50

- a) Compound fracture of right femur.
- b) Condition after medullary nailing.
- c) Weight-bearing and mobility 2 weeks after medullary nailing.
- d) Condition after fracture healing and removal of medullary nail.

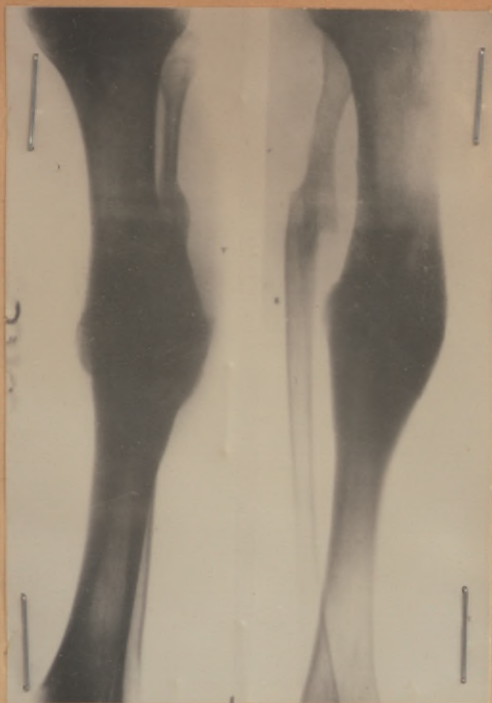

a



b

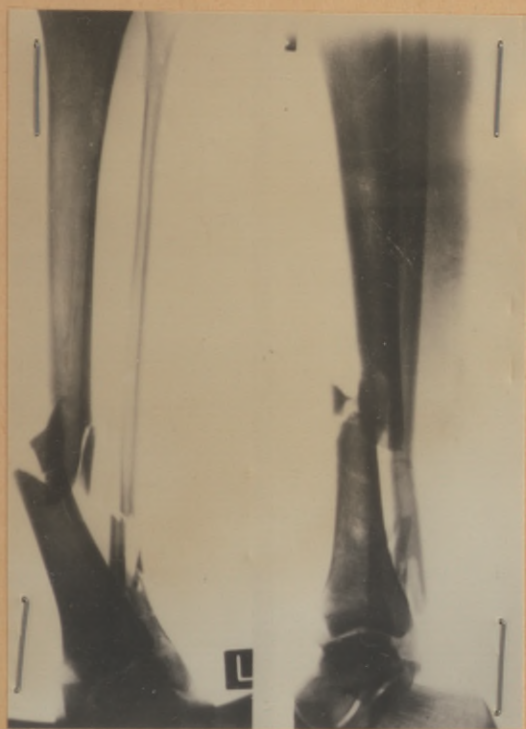(Text see next page)



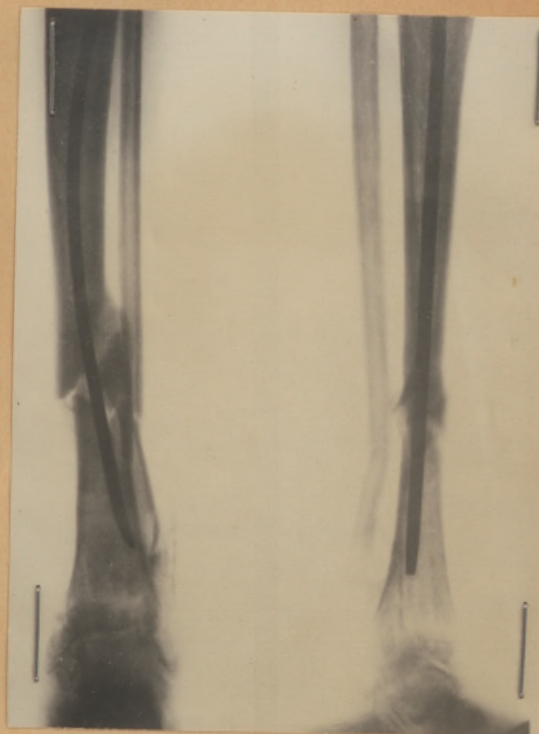c

Illustration 51

- a) Compound leg fracture.
- b) Condition after medullary nailing and primary wound suture.
- c) Healing of fracture. Removal of medullary nail.



a

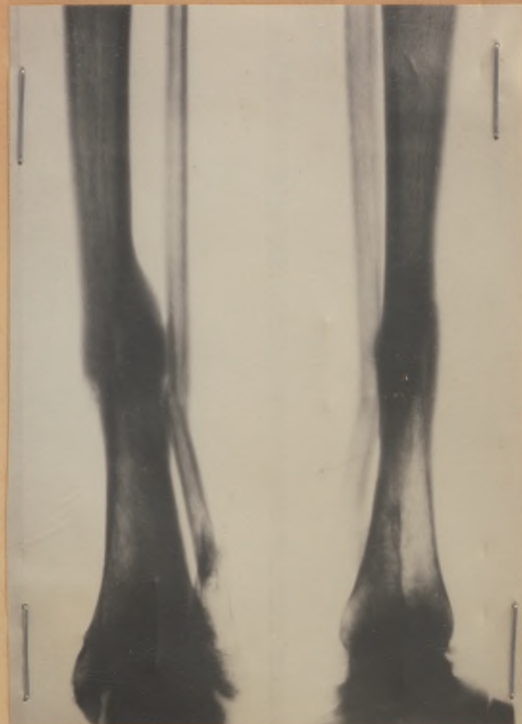

b

Illustration 52

- a) Compound leg fracture and fracture of medial malleolus.
- b) Medullary nailing after healing of complicating wounds, 3 weeks subsequent to injury.

- c) Illustration 52 (cont'd)
Healing of fracture and
removal of medullary nail.

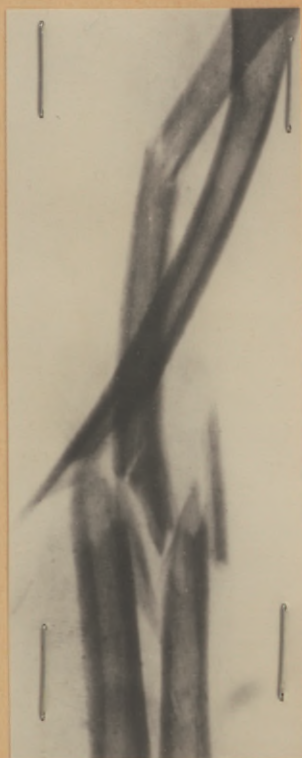
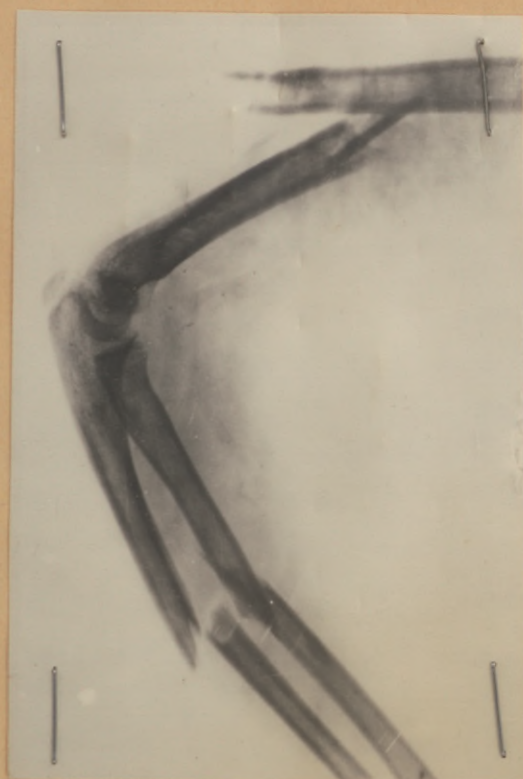
Medical history: P.D., 15 years old, suffered a compound fracture of the left humerus with a large comminuted wound (Illustration 53 a), as well as a compound fracture of the forearm on the same side. The wound was treated operatively and it was sutured per primam after it had been powdered with marfanil-prontalbin powder. The humerus fracture was treated by medullary nailing from the proximal end and due to the small caliber of the medullary cavity, the forearm fracture could be fixed by Kirschner wires only. Subsequently sulfonamides and penicillin were given. The wounds healed per primam. The accident had occurred on March 12, 1947, and the patient could be dismissed on April 3, 1947, for a period of 2 weeks. The further course of healing also was undisturbed as far as the healing of the wound and of the fracture was concerned, apart from an incomplete paresis of the radial nerve and an impairment of the median nerve. The radial nerve was not visible in the large wound caused by the injury. In the course of treatment restoration of the nerve function was slowly established (Illustration 53, b-g). On the humerus, however, no bony solidification occurred, and a pseudarthrosis developed over the medullary nail in place. After one year it was consolidated within 3 weeks as the result of the transplantation of a tibia graft according to PHEMISTER (see chapter dealing with pseudarthrosis).

Another case among the compound fractures treated by us, who came under treatment after the eight-hour limit was exceeded, could not be nailed per primam.



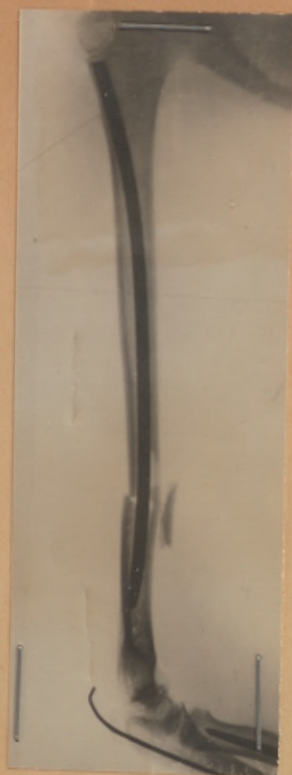a




b

Illustration 53

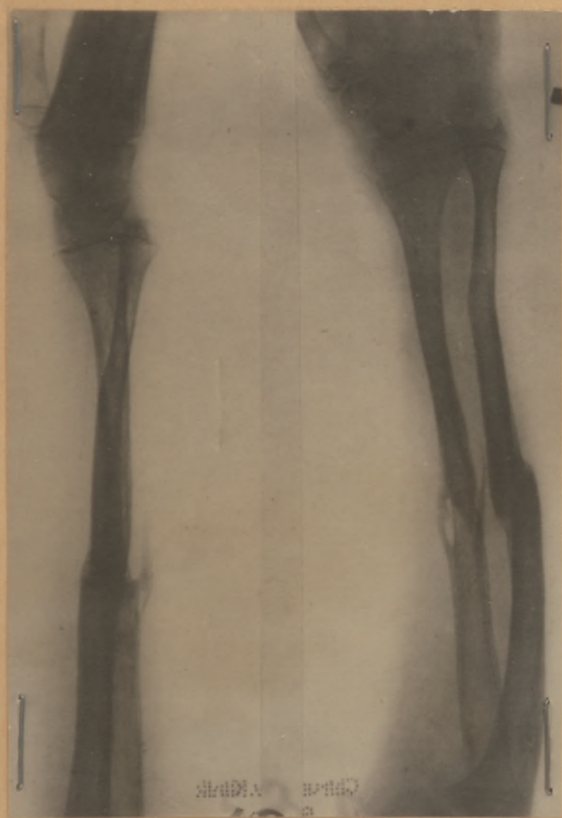- a) P.D., 15 years old, comminated wound and compound fracture of left humerus and forearm.
- b) Compound fracture of left humerus and forearm (March 12, 1947).



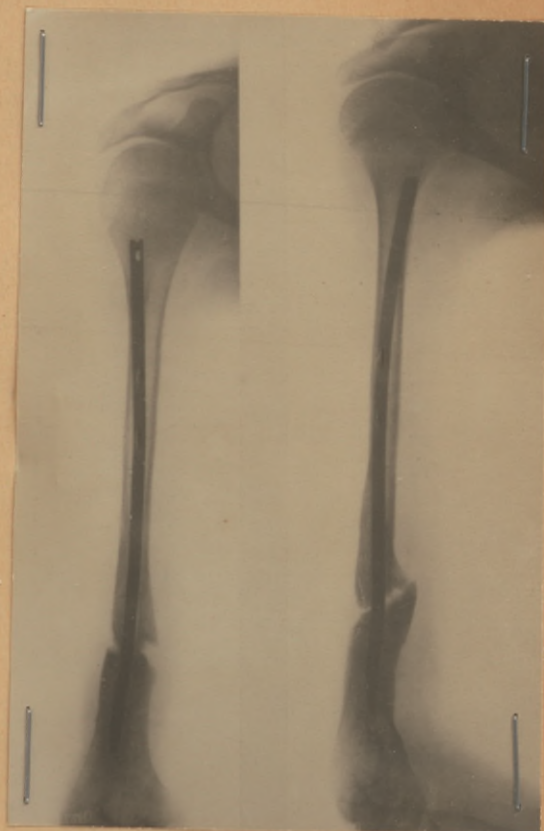c



d



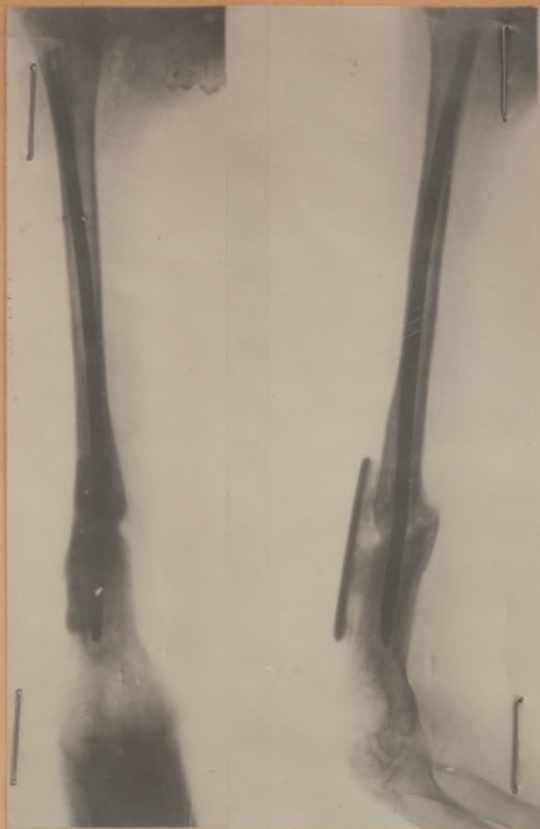e



f

Illustration 50 (continued)

- c) and d) Medullary nailing of humerus from the proximal end, and medullary nailing of both forearms (March 12, 1947)
- e) Condition after healing of forearm fracture and removal of medullary nails (September 17, 1947).
- f) Pseudarthrosis of humerus while medullary nail is in place, probably resulting from distension of fragments (February 11, 1948)



^g
Illustration 53 (cont'd)

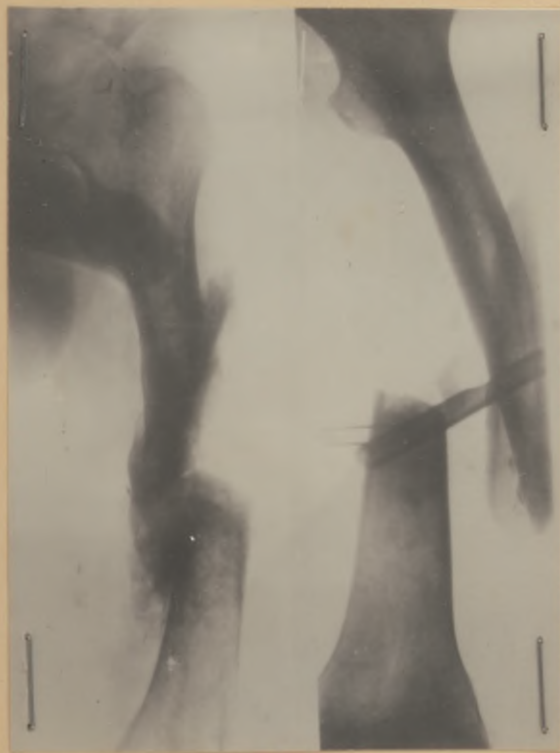- g) Condition 3 weeks after bone graft according to PHEMISTER. Commencement of bony solidification of pseudarthrosis.

Medical history: W.H., 47 years old, was run over by a car on August 29, 1942, and suffered a compound fracture of the left leg. The wound was treated by counter-incision, and a drain was inserted. The fracture was reduced and wire extension was applied through the talus, the extremity being bedded upon a Braun's splint. After the wound had healed, medullary nailing of the tibia was performed on September 22, 1942, that means 3 weeks after the accident. No complication occurred subsequently. The patient rose as early as on October 24, 1942, after a U-shaped plaster cast had been applied. On October 28, 1942, the patient was dismissed for ambulatory treatment. The plaster splint was removed on November 11, 1942, when the fracture was consolidated; medullary nail was extracted on March 6, 1943. The final result was excellent. The patient was incapacitated by about 15 %. The medical case history reveals that the medullary nail remained in place for a long period of time, but unfortunately we are not able to give a satisfactory explanation for that fact. However, we frequently made the observation that the medullary nail caused so little inconvenience to the patients that they themselves put off the removal of the nail, if once the fracture had healed. The case described above shows that capacity to work was regained while the medullary nail was in place, and this was the case on January 20, 1943, that means about 5 months subsequent to the injury. The medullary nail was removed more than 1 year later.

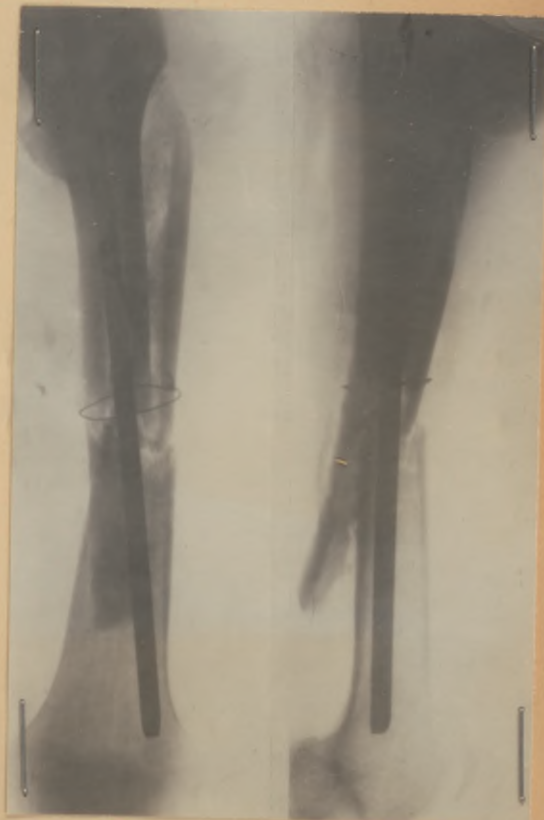This case, therefore, shows that with correct observation of the principles of wound treatment medullary nailing performed even after the complicated wound had healed, may yield an excellent result. In this connection we should like to mention particularly that it is not necessary to let pass such a prolonged interval between the healing of the infected wound and the adjusting operation of the bone, as is required in the case of osteotomy or of the operations of pseudarthroses since with percutaneous medullary nailing the previously infected wound need not be opened. In these cases too, we have a feeling of security through the aid given by the sulfonamides and penicillin.

Medical history: P.K., 31 years old, suffered a motor-cycle accident on March 22, 1945, leading to a compound fracture of the left femur. Medullary nailing was not performed until the day after the injury. A serious osteomyelitis developed which caused the formation of sequestra as well as an extremely dangerous condition of the patient in the course of the sickness. A transitory sepsis developed. There is no need to give all particulars (Illustration 54). Finally we were successful in preserving the leg. The nail was removed on September 8, 1945. Later on there still was a condition of chronic osteomyelitis and sequestra were formed. Today the leg is shortened by 12 cms, the knee-joint is stiffened in extensor position, and the mobility of the hip and of the foot-joint is considerably reduced.

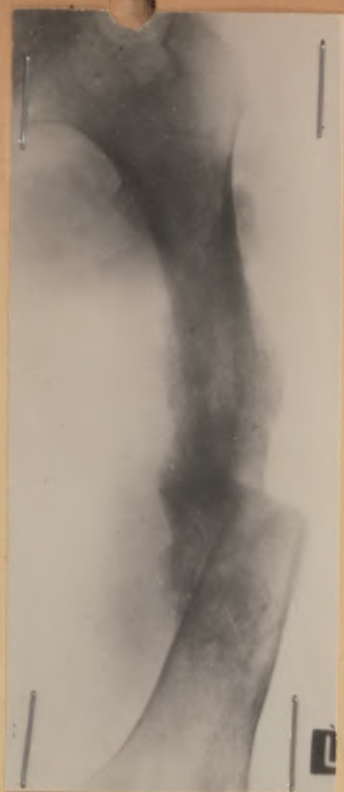This case shows clearly what dangers may occur if one deviates from the safe way of the above described principles performing medullary nailing after the eight-hour limit is over, and before the infected wound is healed.



a



b



c

Illustration 54.

- a) Compound fracture of the femur, treated at first with wire extension. The wound is drained.
- b) Medullary nailing on the next day together with the opening of the fracture and additional wire loops. Primary wound suture.
- c) Condition after fracture healing and removal of medullary nail. Cf. clinical data in the text.

We abstained from describing in detail those cases of medullary nailing of compound fractures in which health was restored without any complications. We just stressed some remarkable case histories which demonstrated the principles to be maintained by all means. No fatal case and no case of amputation occurred during the period on which we gave this report (until the end of 1947).

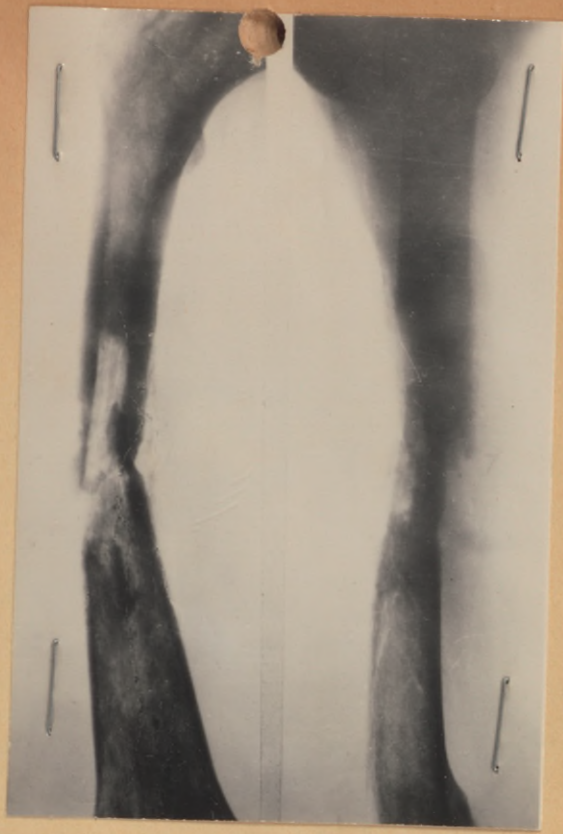After this time, however, there was a fatal case of a leg fracture with additional soiled wounds. By a mistake these wounds were not sufficiently appreciated as a counter-indication, the tibia was nailed without regard to the eight-hour limit, and a severe phlegmon originated from the nail insertion site which resulted in a septic condition and finally in death.

Here, some consideration must be given to the medullary nailing of infected fractures. In the preceding chapters we made clear our fundamental point of view within the frame of general surgical principles, and the majority of the authors also reject medullary nailing in such cases, but it shall not be forgotten, that voices were raised in favor of the medullary nailing of infected purulent fractures (49) (50).

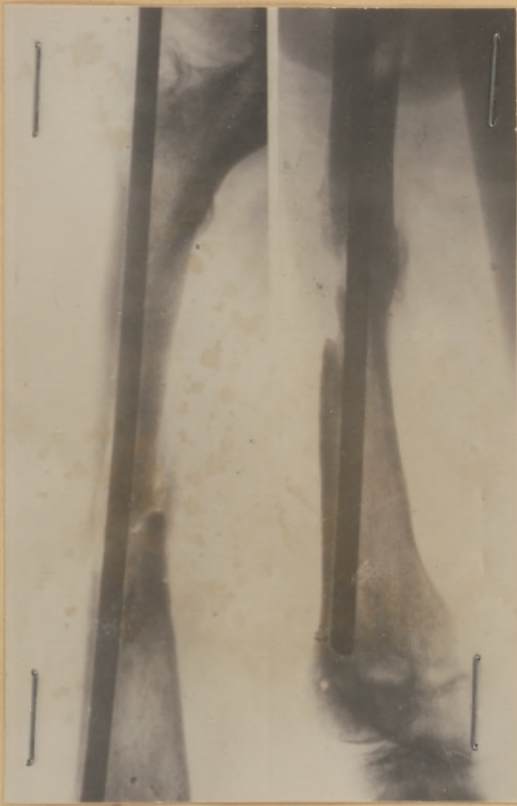As a principal argument for proceeding in such a way the immobilization secured by the medullary nail was mentioned, as it always was recognized as a vital factor for the control of the infection. BOEHLER also had observed such cases taking a favorable course after they had been nailed in another hospital. In the Giessen University hospitals NUSSELT (51) treated a case of infected gunshot fracture of the femur. In the case of this patient "a bone graft was made elsewhere a few weeks after the wound had healed because of a pseudarthrosis after gunshot fracture. This kind of treatment had an unfavorable outlook from the very beginning on. Marked suppuration ensued which was associated with severe septic symptoms, chills, and jaundice. The temperature was very high for



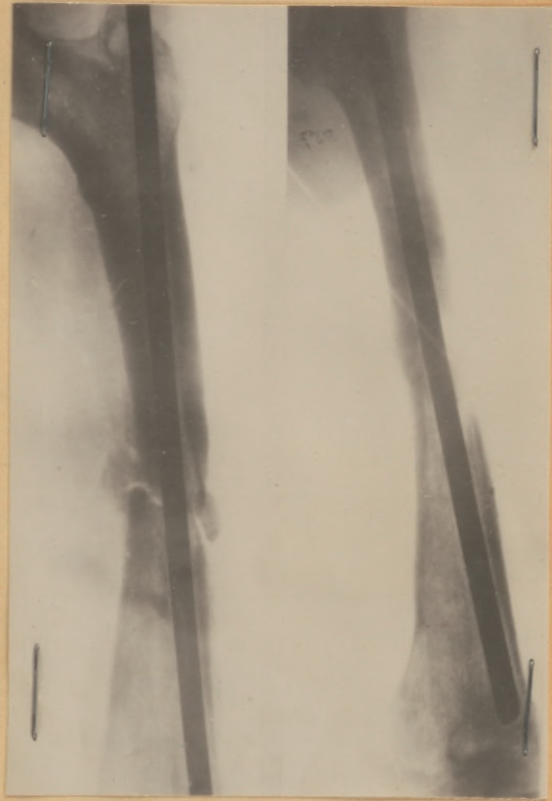a



b



e



d

Illustration 55

- a) Gustav A., 34 Years old, pseudarthrosis after gunshot fracture of femur, 4 weeks after bone-graft. Septic suppuration.
- b) Condition after removal of bone-graft.
- c) Condition 6 weeks after percutaneous medullary nailing.
- d) Commencing growth of bone bridge. Local osteomyelitis.

many weeks, and the patient was admitted to our hospital for amputation. After thorough consideration we decided on medullary nailing in this almost desperate case, as good results were yielded with some similar cases of medullary nailing during the war. Here, too, full success was obtained (Illustration 55). The suppuration ceased fairly rapidly, the wound shows only slight fistular secretion now, and the injured extremity can be used again to a certain extent. It therefore is permissible to assume that in this case the immobilization of the pseudarthrosis by means of the medullary nail played a decisive part in the fight against the infection...."

MEDULLARY NAILING OF GUNSHOT FRACTURES.

As soon as the possibility of treating compound fractures with medullary nailing was recognized - this was the case in the course of the war years 1939 till 1945 simultaneously with the development of the Kuentscher nailing - it was only logical to include the gunshot fractures in the method. There were only a few theoretical objections as one could not expect that any other method for the immobilization of gunshot fracture of the long bones would be more successful than medullary nailing. Moreover, neither extension or plaster bandages nor a combination of both are able to immobilize a gunshot fracture during transportation to the same degree as medullary nailing. The exact and stable fixation of the fragments applied to the bone itself necessarily was as important for the prevention or the control of the infection not only of the bone, but also of the injured soft tissue, because every gunshot fracture had to be considered as contaminated. In addition it is an advantage of the method that the access to the injured extremity was easier when there were neither plaster casts nor extension bandages constituting an obstacle to observation and treatment.

KUENTSCHER (52) himself strongly recommended in 1943 to apply medullary nailing to the gunshot fractures and he gave an account of more than 28 relevant cases showing all the advantages he had expected. There is indeed no fundamental difference between the compound fracture after an accident in peacetime and the gunshot fracture in war. This consideration necessarily must lead to the consequence that the same principles are applied to the medullary nailing of gunshot fractures as they were worked out for the medullary nailing of the compound fractures acquired in peacetime. They principally consist in the strict observation of the eight-hour limit and the control of wound infection by all means or in the correct judgement of the seriousness of the infection and in the exclusion of the fracture from medullary nailing if infection had occurred. This is nothing new, and I repeat it to stress the responsibility involved.

HAEBLER (53), too, assumes a positive attitude with regard to the medullary nailing of gunshot fractures, and he is of the opinion "that it is wrong to warn against marrow nailing of open infected fractures or of gunshot fractures on principle, because it had occurred once upon a time that osteomyelitis ensued upon an open fracture. In such a case osteomyelitis may occur, but then it is due to faulty technique. If a really stable osteosynthesis was performed, no osteomyelitis will be found even with a suppurating fracture."

Contrary to his reserve as to the question of the medullary nailing of fresh open fractures, BOEHLER (54) is in favor of the nailing of gunshot fractures, provided that some conditions of a general and local character are fulfilled on the part of the patient as well as of the surgeon and his armamentarium. As regards the details, information may be obtained from BOEHLER's book. His recommendation of the medullary nailing, however, is limited to the gunshot fracture of the femur. For the remaining long bones BOEHLER does not employ medullary nailing, because these fractures can be treated so well with the older methods that they constitute no urgent indication for medullary nailing, or because sequestra may be formed subsequently as is the case with the lower leg.

The fact that the invention and the development of the method of medullary nailing coincided with the years of World War II constituted an enhancing as well as an inhibiting factor. An enhancing factor, because the method could be administered in the immense field of treatment of gunshot fractures and because in this way an opportunity was created for the method to prove its value to such an extent as would never have been possible in peacetime; an inhibiting factor, because the conditions of war brought it about that the new method was given into the hands of inexperienced surgeons and thus could not yield its optimal effect, and as the varying conditions of war prevented its organic development in logical succession. It, therefore, was certainly an appropriate measure to forbid medullary nailing in hospitals near the frontline. RAISCH (55) warned against medullary nailing in the advanced medical units. The reasons for this warning not only were the danger of infection, but in addition the lack of the minimum technical equipment such as fluroscopy and other things. Moreover, it should not be overlooked that it is of importance that medullary nailing and its after-treatment are carried out by the same surgeon, a postulate which under war conditions is practicable in very rare cases only. No roentgenogram and no report, be it ever so detailed, is able to give the full number of the many significant details and their real character known to the first operating surgeon only, and which as a whole are no details, as they influence the treatment during the first days and weeks subsequent to medullary nailing insensibly, and as they may be decisive for the preservation of the injured limb or even of life. The postulate made above that even today the percutaneous nailing of closed fractures should be limited to those hospitals in which all necessary appliances and instruments are available, not to speak of the training and the ability of the physicians in charge, is particularly valid with regard to compound fractures, and among these to the especially difficult conditions present with gunshot fractures.

The prerequisites permitting the medullary nailing of gunshot fractures were principally complied with in the Navy during the war, and here particularly on the big battleships. On these, the appliances required for operation were on hand, no transportation over large distances was necessary, there were always the same surgeons who could rely on the help of well-trained medical orderlies. Thus a smooth performance of medullary nailing and an adequate after-treatment were guaranteed. (HEIM (56)).

We had no opportunity ourselves to use medullary nailing for the treatment of fresh gunshot fractures during the war. In the chapter dealing with the medullary nailing of compound fractures one will find the medical history of a patient with a comminuted fracture of the femur due to a pistol-shot. This accident happened 1947, and the injury was cured in a very satisfactory manner by wound excision, medullary nailing, and the administration of penicillin. However, in the military hospital attached to our University Hospitals during the war (under the direction of Professor BERNHARD) a certain number of gunshot fractures treated with the medullary nail in hospitals near the frontline were admitted for expert opinion and the course of these cases and the success obtained with them enable us to give our independent opinion.

It is not possible to give an exhaustive description of the problem within this book. That would require a study of its own. Besides one of us has not been in the position to observe such cases nailed in the advanced medical units, and nearly the whole material was lost by the events of war. However, summing up we may draw the conclusion that in a few selected cases medullary nailing is undoubtedly able to yield excellent results with gunshot fractures too, while the majority is not suitable for this kind of treatment. It is the proper selection which in the final analysis determines success. This decision, therefore, can only be placed into the hands of a fully trained surgeon who not only is thoroughly acquainted with the technique of medullary nailing and the whole course of the treatment, but who in addition disposes of a great general surgical experience. If this requirement is not met, there is the danger of great damage being done. It is of particular significance to take into account the zones of comminution by the gunshot injuries of the long bones. According to FRANZ (57) their extent ranges between 8 and 10 cms. with fractures of the humerus caused by a rifleshot, and over 12 to 14 cms with fractures of the femur. With shell splinter injuries and injuries due to explosive bullets the zone of comminution may be even larger. Along the extent of the zone of comminution the bone is destroyed to such a degree that the medullary nail finds no hold and therefore provides no fixation. In all such cases, therefore, a plaster cast or an extension bandage should be applied and it is quite clear that it is not possible to subject such fractures to early weight-bearing, as the fragments would telescope over the medullary nail causing a considerable shortening of the injured extremity.

One of the surgeons of the hospital who was well trained in medullary nailing employed the method for the treatment of a gunshot fracture of the femur, but he did not take into account the effect of the extensive zone of comminution, and as a result the extremity was shortened by 6 cms.

OSTEOTOMY AND MEDULLARY NAILING OF FRACTURES HEALED IN AN UNFAVORABLE POSITION.

During the years subsequent to the war an increased number of fractures healed in an unfavorable position was observed which necessitated osteotomy for correction. This not always was the fault of the previous surgeon in charge of the treatment, but it frequently was the result of the fact that extensive injuries of the soft tissue in the case of war injuries, or severe infections prevented an undisturbed fracture treatment. Not infrequently the unfavorable

position was due to the lack of the required appliances and to similar incidental causes such as prevailed during the last months of the war. With war experience the knowledge of the possibilities for the treatment of such bone fractures was increased, and the introduction of the Kuentscher nailing contributed to a substantial enlargement of the therapeutic methods in this field too. The most varied targets may be set for osteotomy ranging from simple refracturing of fractures consolidated in deformity to extensive reconstructive operations of the long bones deviating from the axis in all directions. Experience has taught that the retention of bones re-aligned by operation is the very field of medullary nailing.

The indication for such a proceeding is given more frequently in the case of the lower extremity than of the arm, as the anatomic accuracy of axial adjustment is more important for the function of the lower limb than of the arm. One must add to this the danger of late joint damages. The weight of the body resting in a faulty axial position very frequently one even may say regularly, causes secondary arthrotic alterations of the hip, knee, and foot joints, so that for this reason alone it is absolutely necessary to correct the axial position of the upper and the lower leg. The osteotomies performed on the arm involved predominantly the fractures of the forearm bones, which due to an unfavorable position cause a restricted mobility and an arthrosis of the wrist joint.

While preparing osteotomy the condition of the soft tissues, particularly of the skin, must be the subject of special attention. Particularly as a sequela of war injuries or as a result of infections and of phlegmons extensive scars are often found within the area of the fracture, as well as defective soft tissue, areas of skin atrophy, cicatrization, and an inadequate vascularization, a condition which, when neglected, endangers the success of any operation of the bone by provoking suppuration or necroses of the external skin cover. This is the reason why no osteotomy should be performed before a sufficient period of time has passed since the end of suppuration or fistulation. It has become fairly common knowledge that a minimum period of six months has to be observed. However, in many cases where no quick action was necessary, and in which one would have risked the loss of the extremity we have waited as long as one year. But even after such a long period it may happen that small abscesses filled with pus are formed in which small foreign bodies, silk threads, bone splinters etc. are found. It, therefore, is absolutely necessary to make a thorough local and general inspection of the patients prior to the operation and to obtain information about the presence of hidden sources of infection by examining the blood sedimentation rate and the leucocyte count. In addition the condition of the soft tissues, particularly of the skin, must be improved prior to osteotomy, and it may even be required to perform an autodermic graft prior to the operation. This means that it is more practical to restore the soft tissue before the bone is built up again.

Medullary nailing doubtlessly is the best method for the fixation of the extremities after osteotomy. Mention was made above of the deficiencies of other stabilizing foreign bodies having a purely mechanic effect. The technique of medullary nailing after osteotomy is easier than that of percutaneous nailing, since the difficulties of reduction are eliminated by the exposure of the bone and by

the realignment under direct vision , and in the majority of cases there is no better way than to introduce the medullary nail from the site of the osteotomy. The technique of femur nailing from the fracture site described above may serve as an example. But even in cases in which the medullary nail is inserted at the typical site, the tip of the nail appearing at the site of the osteotomy can be inserted into the other fragment under direct vision, a procedure that represents a considerable technical facilitation rendering the operation more sparing and rapid.

For osteotomy the patient need not be bedded in the extension appliance. If there is a considerable shortening of the extremity involved it is recommendable to attach a sleeve or a loop to the hand or to the foot prior to the operation. By means of this sleeve vigorous traction can be exerted by hand if during the operation such a necessity should arise. Usually, however, the bone ends involved can be controlled and adjusted by elevators or by singlepronged hooks in the operation wound. In most cases the medullary cavity is obstructed by callus and the best thing to do is to bore a hole in both directions at the site of the osteotomy using the pointed awl prior to the insertion of the nail. If this is not practicable, hammer and chisel or the electric ball drill may be used. The diameter and the length of the nail are determined during the operation in the same way as described before.

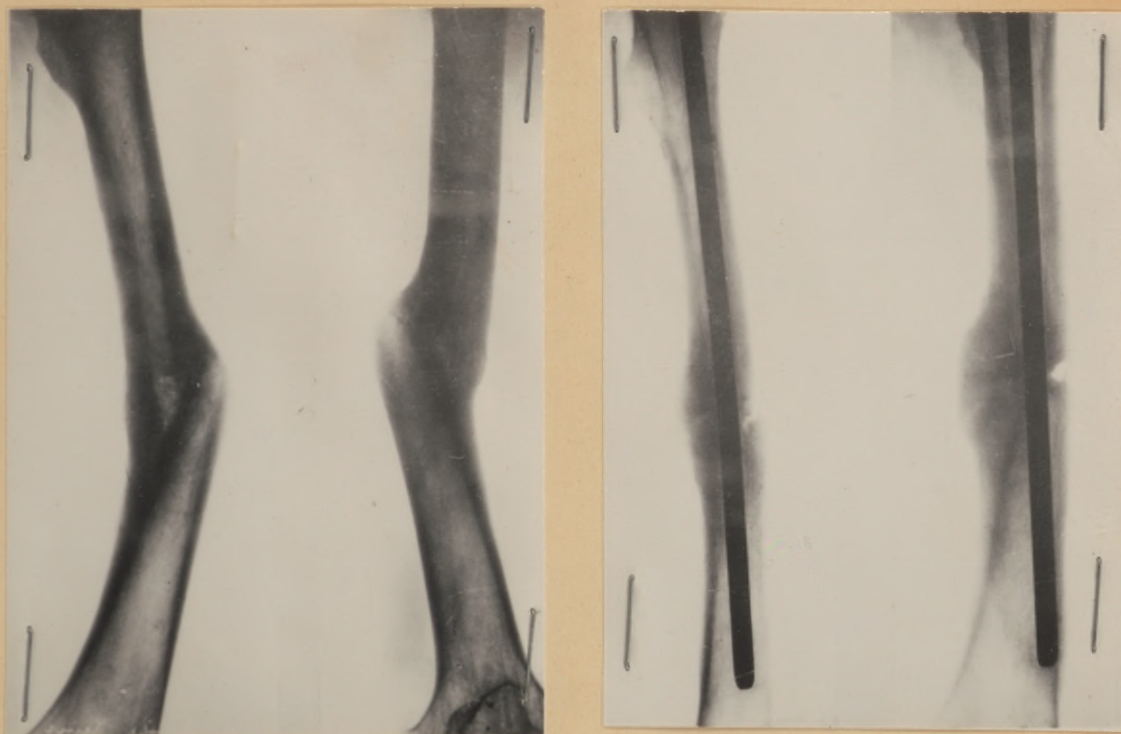
FISCHER and MAATZ (58) in 1942 gave a report about 14 osteotomies on the femur and about 1 on the leg performed because of an unfavorable position of the fracture. All of them took a satisfactory course with one exception requiring amputation because of infection and deficient healing. In 1947 GRIESSMANN and SCHUETTEMAEYER (59) described two other osteotomies one of which, a 63 year old male patient, suffered a post-operative shock and died after femur osteotomy. The other case showed a satisfactory result and the previous shortening amounting to 5.5 cms. could be reduced to 1.5 cms.

In the Giessen University Hospitals 68 osteotomies combined with medullary nailing were performed before the end of 1947. The experience gained thereby encouraged us more and more to employ the medullary nail as a means of retention for fractures realigned by operation. Our results are shown on the following table (Illustration 56). In the majority of cases we had to deal with fractures of the lower extremity healed with deformity. Only several typical examples out of the ample material available shall be discussed here (Illustration 57 to 62).

Treatment by Osteotomy combined with
Medullary Nailing of 68 Fractures
healed in an unfavorable Position.

Bone	Number	Bony Conso- lidation	Complications	
			Osteomyelitis	Pseudarthrosis
Humerus	3	3	1 purulent fis- tula on nail insertion site	-
Forearm	12	12	-	1 osteotomy on ulna and ra- dius, pseudar- throsis on ulna
Femur	43	43	1 severe osteo- myelitis in operation area	2 bony consoli- dation as a result of additional bone graft
Leg	10	10	1 infection of soft tissue on nail insertion site	-
Total	68	68		

Illustration 56

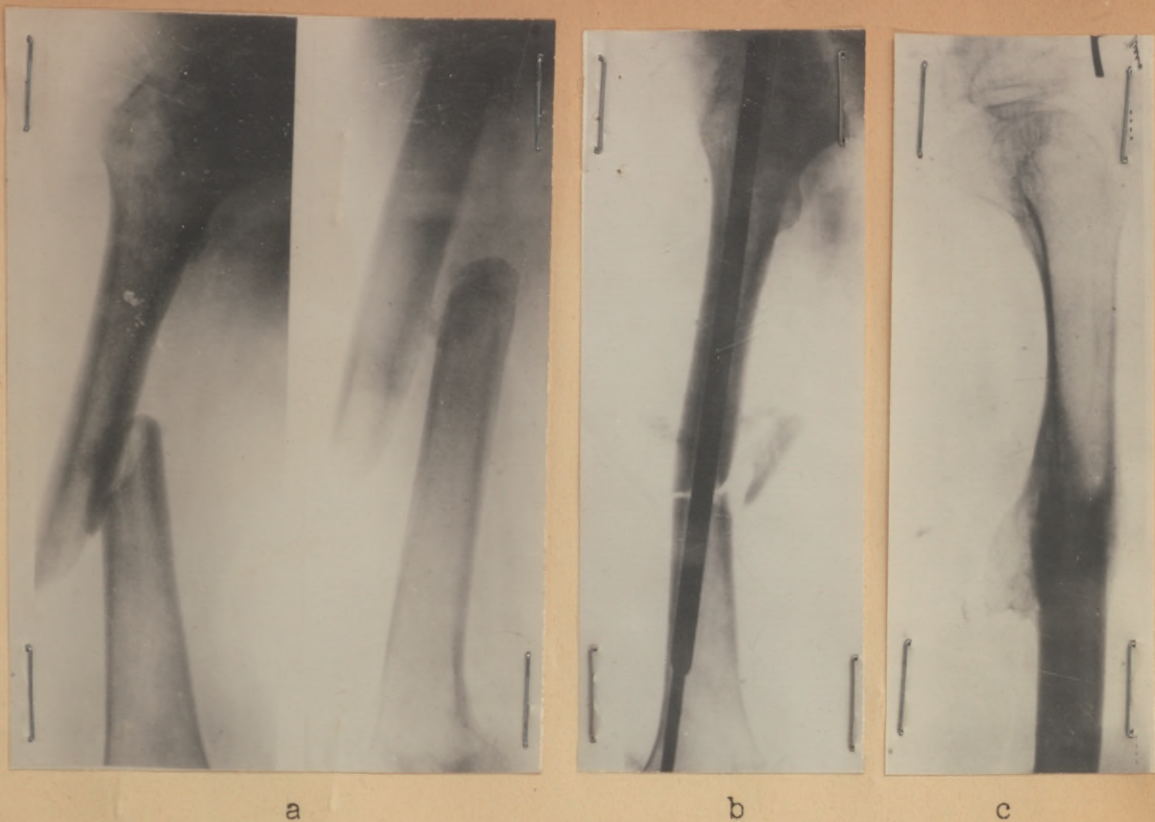


a

b

Illustration 57

- a) Femur fracture healed in an unfavorable position.
- b) Condition after osteotomy, realignment and medullary nailing. Advanced formation of callus.



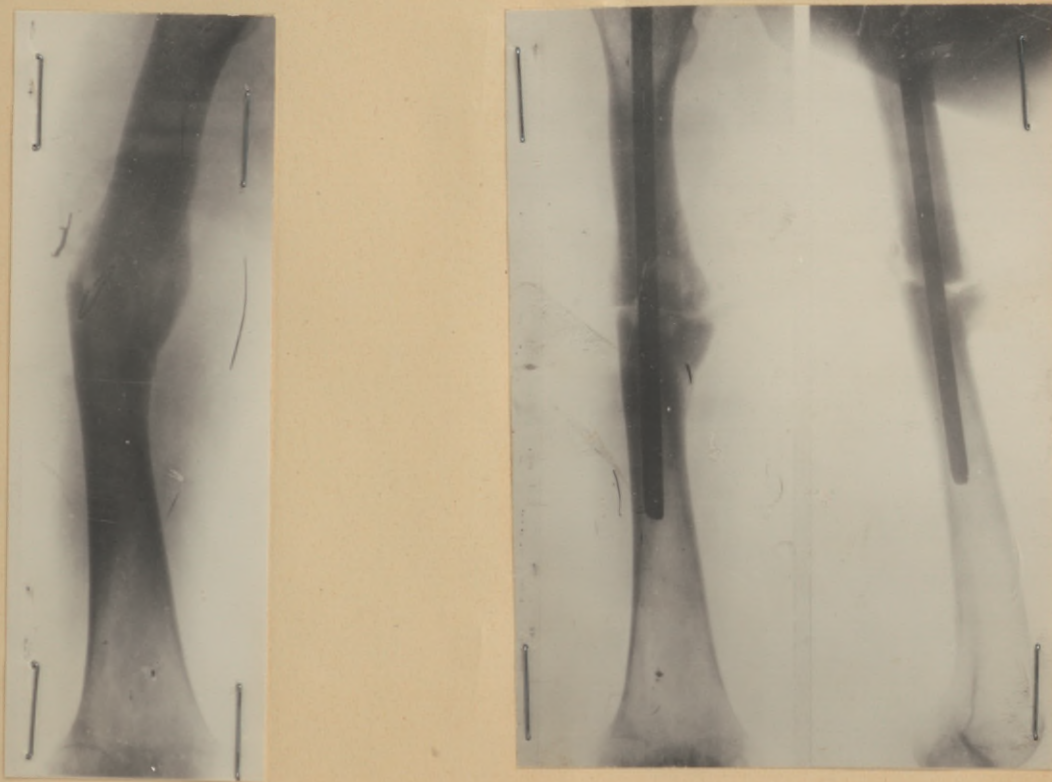
a

b

c

Illustration 58

- a) Femur fracture healed in an unfavorable position.
- b) Condition after osteotomy, realignment and medullary nailing.
- c) Healing of fracture and removal of medullary nail.

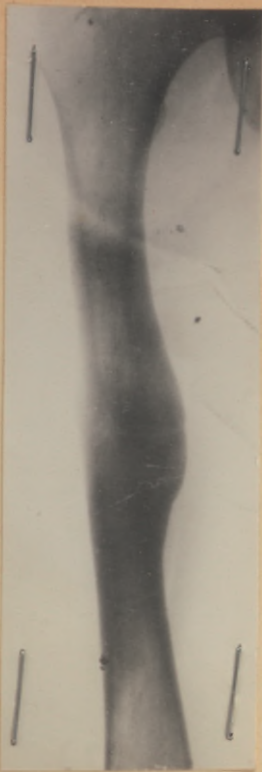

a

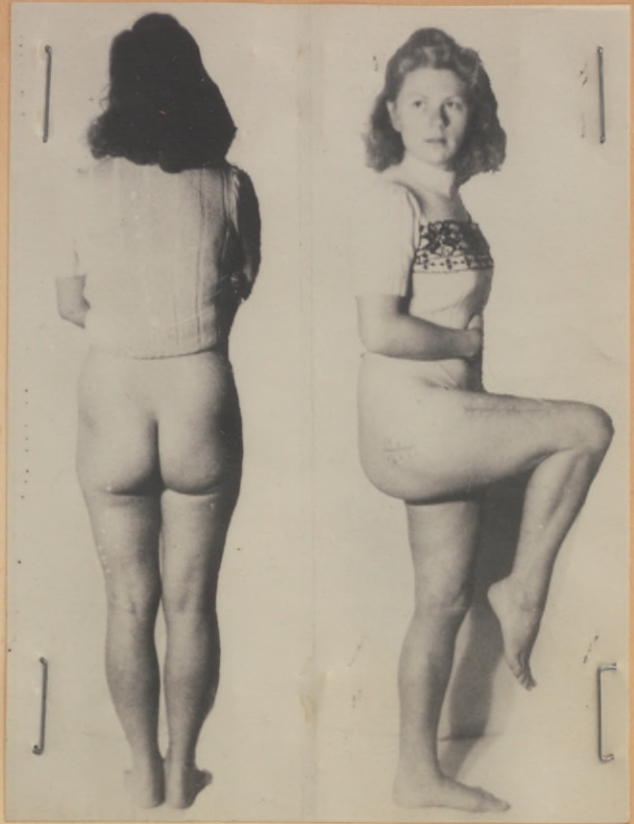
b

Illustration 59

- a) Femur fracture healed in an unfavorable position.
- b) Condition after osteotomy, realignment and medullary nailing.



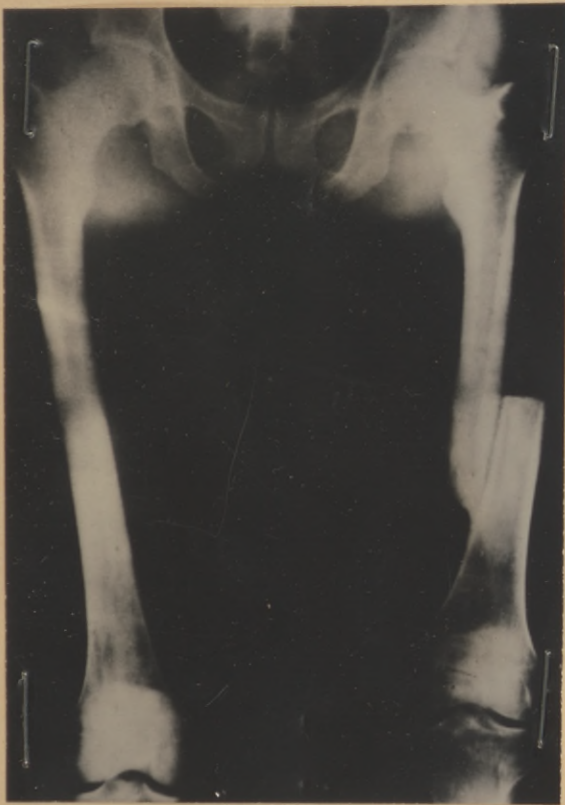c




d

Illustration 59 (cont'd)

- c) Fracture is healed and medullary nail removed.
- d) Patient 6 months after the operation.



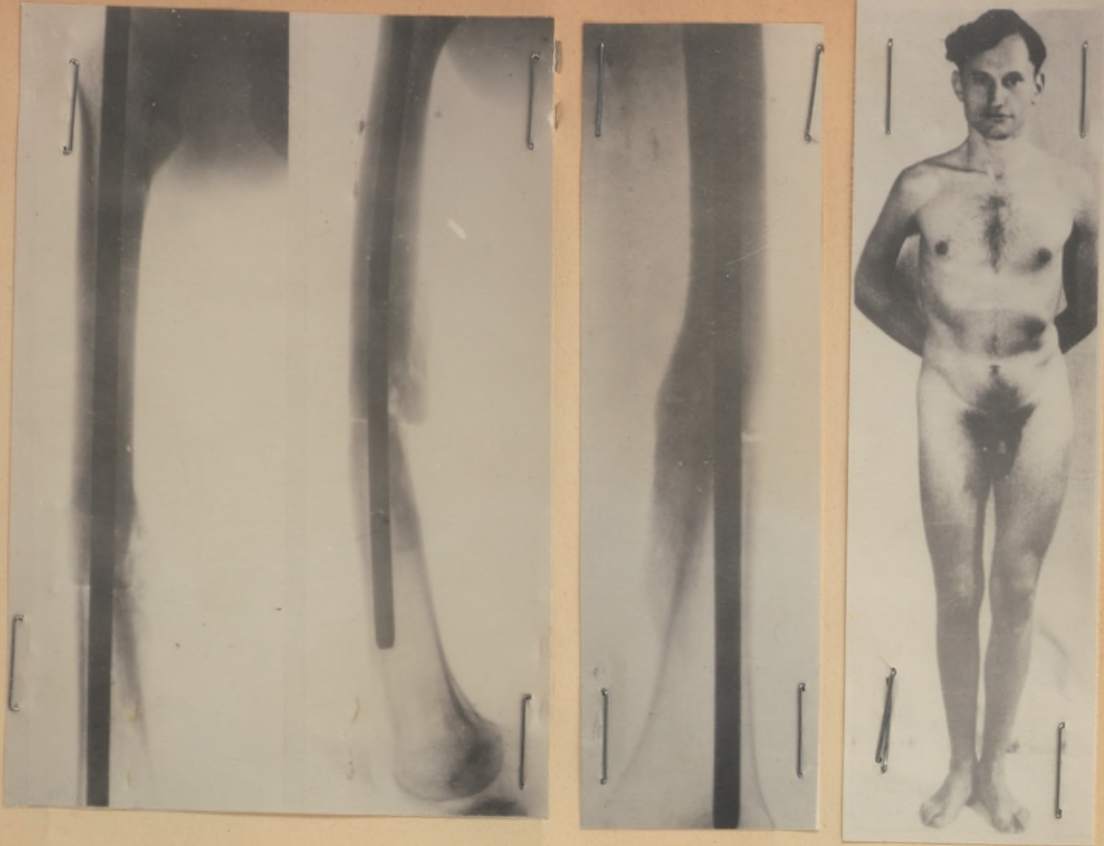a



b

Illustration 60

- a) Femur fracture healed in an unfavorable position and shortened by 5.5 cms.
- b) Patient before the operation.

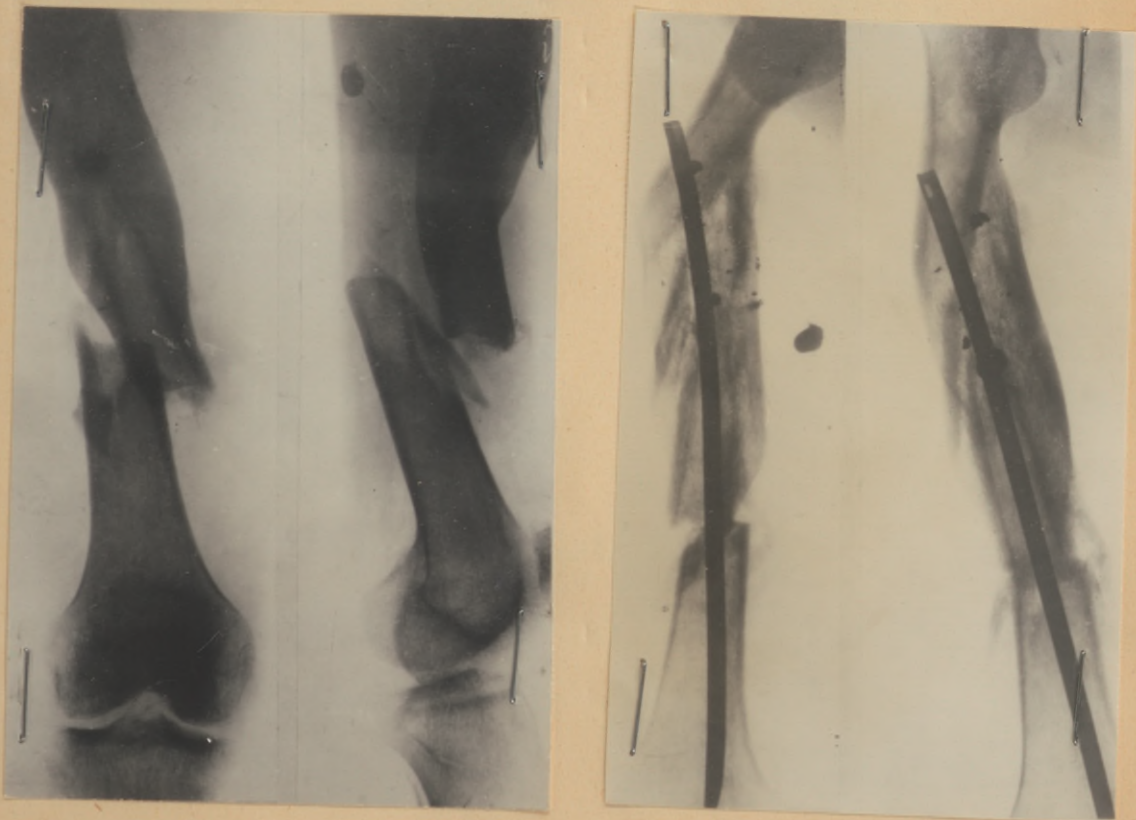


c

d

Illustration 60 (cont'd)

- c) Condition after osteotomy and medullary nailing. Shortening is compensated up to 1 cm.
- d) Advanced formation of callus. Patient 9 months after the operation.



a

b

Illustration 61

- a) Multiple gunshot fracture of femur healed in an unfavorable position.
- b) Condition after osteotomy and medullary nailing.

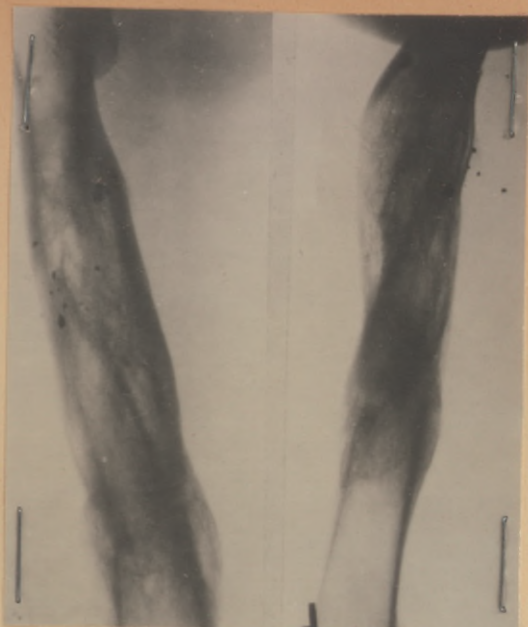
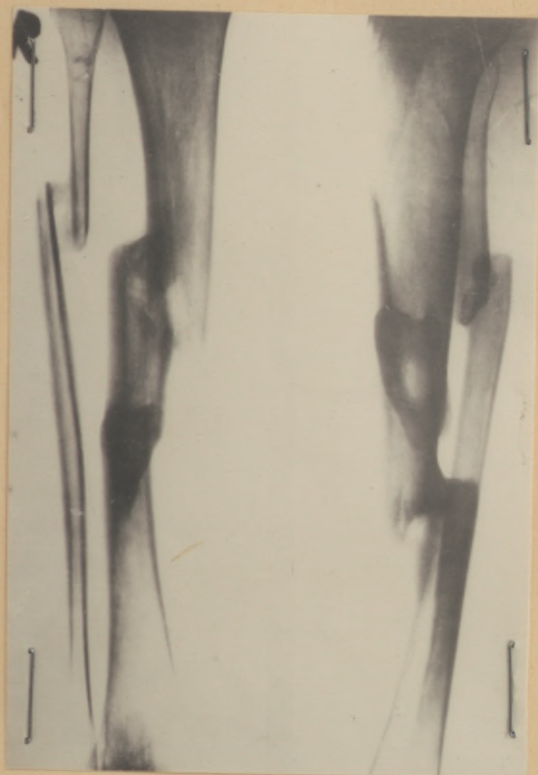
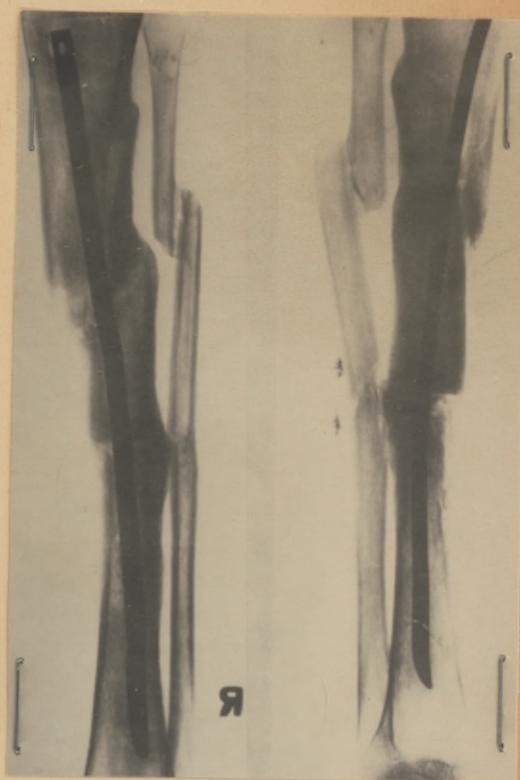Illustration 61(cont'd)
c) Fracture is healed and medullary nail is removed.

c



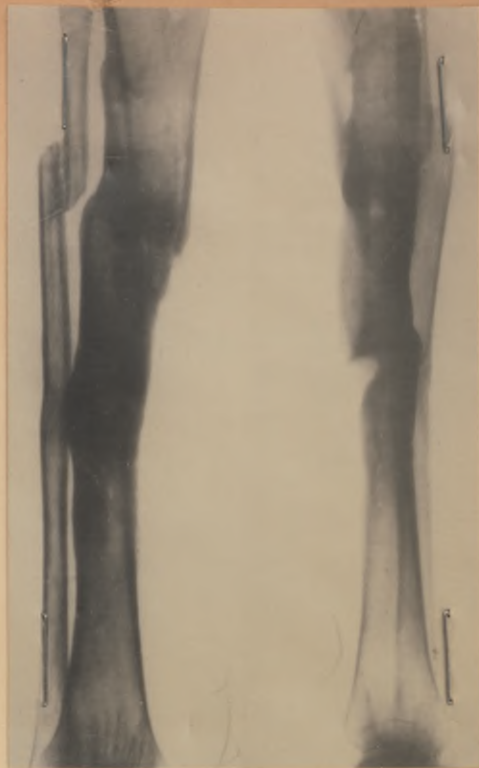a



b

Illustration 62
a) Multiple fracture of leg healed in an unfavorable position.
b) Condition after osteotomy and medullary nailing.

- Illustration 62 (cont'd)
c) Fracture is healed and medullary nail removed.

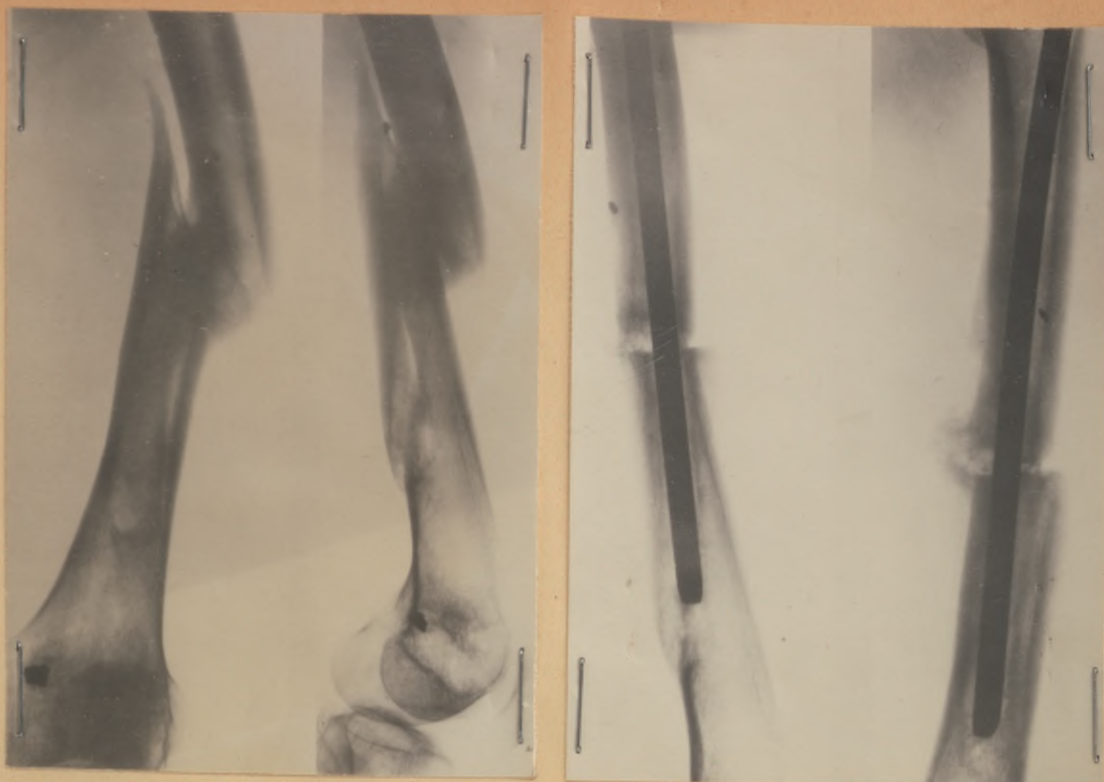


c

Recently one more patient came under treatment here and his case shall be described because of the particular conditions involved.

Medical history: G.R., 37 years old suffered a shell splinter injury and fracture of the left femur and of the right leg in 1944. The condition of the right leg required amputation, while the left femur fracture healed in a considerable varus position so that the patient complained of static discomfort in the knee and foot joints. It therefore was necessary to straighten the left femur by osteotomy. For the operation (Professor BERNHARD) spinal anesthesia was used and the old fracture site was exposed by a longitudinal incision on the lateral aspect of the femur. Above and below the old fracture site the bone was sawed through with a circular saw. The medullary cavity of the distal fragment had to be opened with the awl. The operation was continued in the way described for the nailing of the femur through the wound. The position of the bone was perfect. The wound was sutured after it was powdered with marfanil powder. For the sake of security a femur plaster cast was applied. Subsequently every 3 hours 25,000 units of penicillin, altogether 500,000 units were given. The wound healed per primam. After 6 weeks the leg was carefully subjected to weight-bearing for the first time, and two days later the patient could be dismissed for ambulatory treatment. The knee joint can now be straightened completely and bent by 90°. The result of the position is demonstrated by the illustration (Illustration 63).

This case is particularly impressive as it was a patient with a leg amputation whose other leg was consolidated after femur fracture in such an unfavorable position that in the long run he was not able to subject it to weight-bearing. Especially in this case late damages of the joints had to be expected with absolute certainty, as due to the amputation of the other leg this extremity was exposed to increased stress. The risk of an infection to be taken into account was all the greater, particularly as it represented



a

b

Illustration 63

- a) G.R., 37 years old, Gunshot fracture of left femur healed in an unfavorable position. Right leg amputated.
- b) Condition after osteotomy, readjustment, and medullary nailing. Beginning formation of callus.

an old gunshot fracture. Under this shadow the osteotomy assumed the character of an ultimate and heroic operation which had to be dared because otherwise the patient would have had to walk on crutches all his life. We therefore not only deemed it justified but rather considered it as an absolute necessity to reduce the risk of the operation right from the beginning by the prophylactic administration of penicillin. This case shows most impressively that the success of medullary nailing not only is a matter of technique but also of the consideration given to the particular situation of the patient and to all eventualities of the further course. This was already stressed above and as a matter of fact these are matters known to every surgeon conscious of his responsibility.

Disturbance of fracture healing or of bony consolidation after osteotomy occurred in two cases both of them involving the femur only. Infections subsequent to osteotomy were observed in 3 cases.

MEDULLARY NAILING OF RETARDED FRACTURE
HEALING AND OF PSEUDARTHROSIS.

The elimination of pseudarthroses always played a special part in the field of fracture treatment and this is due to two reasons: Continuous attempts were made to obtain information on the process of fracture healing and on its disturbance through studying the mechanism of the formation of pseudarthroses. The treatment of the pseudarthroses had to aim at giving as physiological an assistance as possible to the natural process of the undisturbed fracture healing. In this context it is intended to refer only to the treatment of the pseudarthroses. Here an exact and sufficiently prolonged immobilization after bone grafting proved to be the most essential factors. Problems are similar in the case of delayed consolidation of fractures whose difference from pseudarthroses is in many cases considered as a gradual variation only. However, we believe that there is a substantial difference between these two forms of failure of bony consolidation in fractures, since in the case of delayed fracture healing mechanical factors may usually be considered as causative, while the development of a pseudarthrosis is due to the faulty progress of a biologic process of development. This differentiation also is of practical significance for the prognosis and the choice of the operation to be performed. The two conditions can be recognized to a lesser degree by the period since the occurrence of the fracture and by means of the clinical examination, than on the basis of roentgenoscopic inspection.

Both of them, delayed fracture consolidation as well as the fully developed pseudarthrosis, require operative treatment. In the case of delayed fracture healing one sometimes succeeds to obtain consolidation with a less strenuous procedure. This consists of drilling according to Beck and a simultaneous resection of bone from the fibula, if there was a distending effect preventing the extensive union of the tibial fracture planes able to bear weight. In all other cases the fracture site must be exposed by operation, the cicatrized tissue removed, the ends of the fragments freshened, and the fully developed pseudarthrosis resected. If necessary, bone grafting should be performed; the bone graft either being taken from another region of the body or formed from the fractured bone itself in the shape of an interlocking plastic.

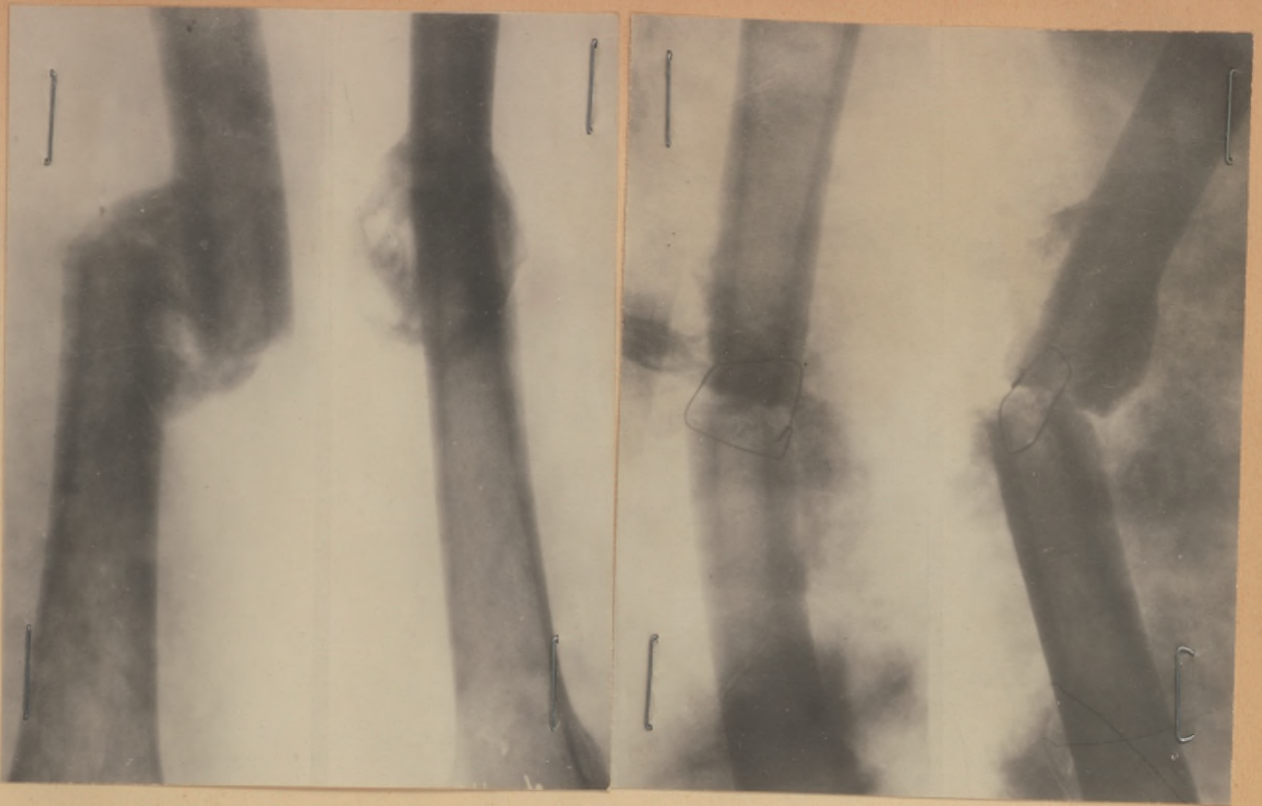
In any case an exact and prolonged immobilization of the fractures treated in this way is one of the most essential requirements for success. This is where medullary nailing comes into its rights. Every experienced surgeon knows, for instance, the difficulties encountered when attempting to immobilize absolutely an operated femur pseudarthrosis by plaster cast and in a favorable position. The weight of the leg, the long levers and the thick masses of soft tissue constitute considerable obstacles. Moreover it is the desire of the surgeons to avoid the introduction of larger foreign bodies into the fracture and its environment particularly during the treatment of a pseudarthrosis and subsequent to bone grafting. ERTL (60) attributes the sole responsibility for the failures occurring sometimes to the wire loops by which the bone grafts are usually fixed. Even though experience revealed that this view certainly is exaggerated, one should take advantage of every opportunity to avoid the use of foreign bodies and to take the biologic conditions into account. This will be discussed later.

"In the case of delayed callus formation medullary nailing constitutes "a causal therapy", as the cause for the slow consolidation of fractures in the majority of cases is of a mechanical nature. The medullary nail eliminates the injurious shearing forces and it promotes the effect of the pressure forces enhancing bony consolidation."
(KUENTSCHER and MAATZ)

The importance of medullary nailing, however, not only is due to the fact that the fixation is established on the bone itself and that it solves the problem of immobilization better than any other method. The relative harmlessness of the medullary nail as a foreign body was discussed earlier. In addition, however, it has shown that in the case of delayed fracture consolidation one not infrequently succeeds in obtaining healing by medullary nailing alone without any other additional operation. This may be achieved by percutaneous medullary nailing as it is applied to the fresh simple fractures. This, however, can only be accomplished when the fracture planes are already in a state of satisfactory adjustment, as the coarse cicatrized tissue between and beside the fracture planes permits closed reduction without operation in very rare cases only. If, however, the fragments are adjusted in a satisfactory position, medullary nailing alone may be sufficient to bring the delayed fracture healing to a close. This, no doubt, means a progress and an amplification of our method, as it not only permits avoiding an operation in the fracture site itself, but also offers a strict immobilization in a perfect position. The latter may be maintained indefinitely. Moreover, there is the advantage that to fractures of the lower extremity walking casts may be applied early and exercises of the joints may be taken up much earlier than with any other method (VOGL (61)).

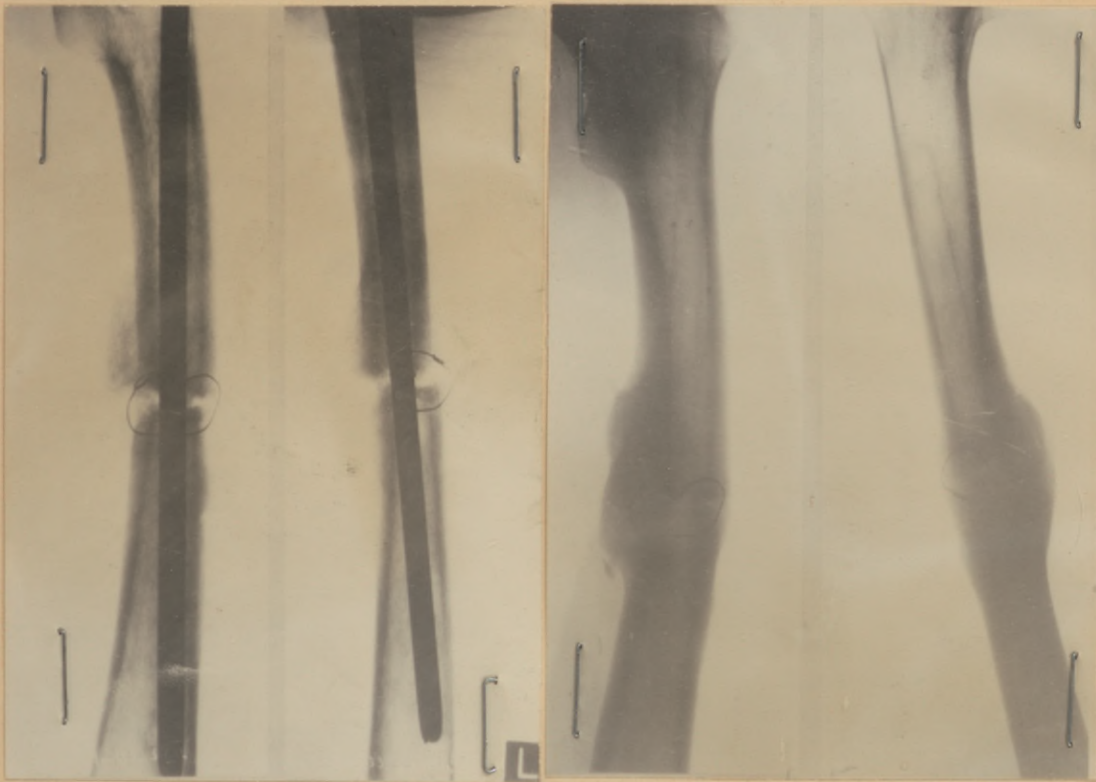
Experience has shown that in suitable cases percutaneous medullary nailing is capable of terminating delayed fracture healing (Illustration 64). The conditions for success are the adjustment of the fragments so that medullary nailing can be achieved without greater manipulations for reduction, moreover a configuration of the fracture planes permitting as broad as possible a contact, and a very narrow fracture cleft, as one cannot expect that thicker masses of callus or cicatrized tissue can be bridged over by medullary nailing alone. On the leg, medullary nailing most suitably should be combined with a resection on the fibula in such cases in which the latter bone acts "as a distension splint" (GULEKE (62)).

If percutaneous medullary nailing is not practicable, which frequently is revealed not earlier than during the operation, and if it is caused by an immobility of the fragments forbidding even small manipulations aiming at reduction, it is preferable to perform operative reduction. On the leg a small incision over the fracture is sufficient in such cases, and through this incision the cicatrized tissue found between the fragments may rapidly be removed without requiring the freshening of the bone ends, as the fracture usually is wedged together by standing upon it. After the removal of the cicatrized tissue we never had difficulties in performing medullary nailing. Our proceeding, which, so to speak, lies between operative reduction of a fresh fracture and osteotomy spares the fracture in a most favorable way. This operation is hardly more strenuous than drilling according to BECK. If in the one or



a

b



c

d

Illustration 64

- a) Femur fracture consolidated in an unfavorable position causing shortening by 5 cms.
- b) Delayed callus formation (pseudarthrosis). Condition 4 months subsequent to osteotomy and wire suture made in another hospital.
- c) Condition after percutaneous medullary nailing without any other additional intervention.
- d) Condition of fracture after healing and removal of medullary nail.

the other case this method yields no results a bone graft may be applied later on to bridge the fracture over, while the medullary nail remains in place as a retention appliance.

The pseudarthroses may be divided into two large groups, the contact pseudarthroses with or without the formation of a typical pseudo-articulation, and the gaping pseudarthroses which can be observed particularly frequently as a consequence of gunshot fractures. Another classification according to the degree of functional disorder was recently suggested by GULEKE (63) who makes a difference between rigid, waddling, and gaping pseudarthroses. These types of pseudarthrosis were discussed in many publications during and after World War I, and they were studied thoroughly so that their causes as well as their treatment is generally clear. Among the leading German surgeons it was particularly GULEKE (64) and LEXER (65) who discussed in several studies the origin, the prophylaxis, and the treatment of the various types of pseudarthroses. Within this study it is not possible to give a detailed description of all problems incurring in this connection. We refer to the monograph prepared by G. BRANDT (66), but it is necessary here to discuss the principal points whose knowledge is required for the practice of medullary nailing.

The following faults made during fracture treatment proved the most essential factors provoking the development of pseudarthrosis: A frequent cause is the insufficient immobilization of the fracture including the precipitate subjection to weight-bearing. In addition, exaggerated and prolonged extension treatment resulting in a distention of the fragments may be responsible for the development of pseudarthroses. In the case of compound fractures, particularly of gunshot fractures, too extensive a removal of splinters should be avoided, as in this way elements required for fracture healing are eliminated. Finally the interposition of soft tissue or foreign bodies (sequestra, drain tubes) and prolonged severe suppuration have to be considered as causative factors. In the case of gaping pseudarthroses the large size of the gap between the fragments prevents bony bridging over. Finally it can be prevented by the distending effect of a neighboring bone (fibula, radius, ulna).

Once pseudarthrosis has developed it can only be consolidated by operation. Recently resection of the pseudarthrosis combined with an extensive freshening of the bone fragments and the transplantation of a bone graft was commonly recognized as the only method. This means that the pseudarthrosis is to be converted again to a fresh fracture, similar to the procedure practised for osteotomy of the fractura male sanata, and the biologic process of fracture healing is adequate by released and supported by the grafted bone. It is easily possible that in many cases there would be no need for a bone graft, and BOEHLER regards it as a "considerable simplification" that the operation of pseudarthrosis is terminated as soon as the fragments are freshened and the medullary nail introduced. Contrary to this we would like to stress that we do not transplant the bone graft to effect a fixation of the fragments, but for the only purpose of stimulating the healing process in a biologic manner, that means to stimulate the formation of callus. This is the characteristic feature of the pseudarthrosis that no callus is formed and that the healing process takes a faulty development towards pseudo-articulation.

After the resection of the pseudarthrosis there is the necessity to provide a secure immobilization of the freshened fragments. As we have seen during the discussion of the osteotomies, this can be achieved best by means of the medullary nail (RAISCH (67)). The medullary nailing therefore serves as a tool for the realization of the stable fixation which is one of the principal postulates of fracture treatment and thus it serves particularly to prevent the

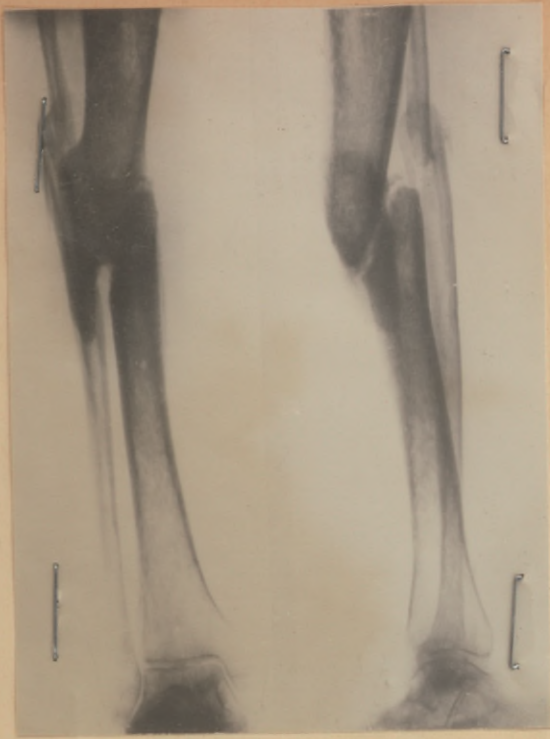formation of pseudarthrosis. Especially in those cases in which a pseudarthrosis had developed previously, one should endeavor all the more to eliminate all factors liable to cause pseudarthrosis once more.

The following case will show that a pseudarthrosis can be cured by resection and medullary nailing alone without the transplantation of a bone graft:

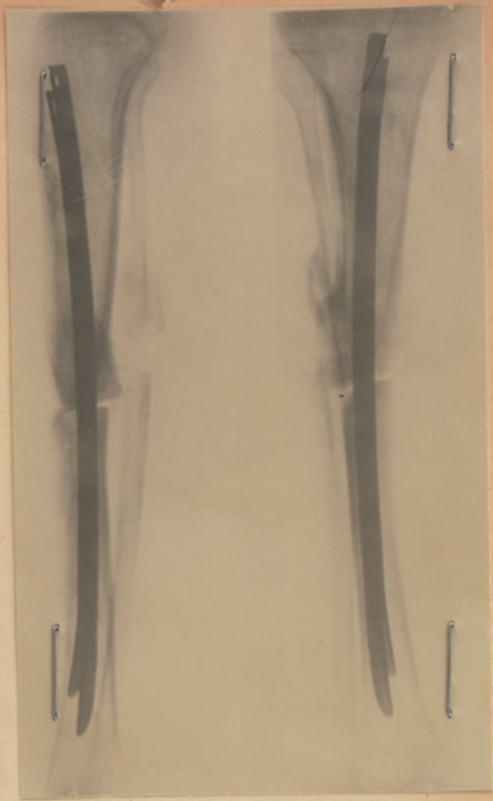
Medical history: W.P., 60 years old male patient, suffered a fracture of the right tibia in May 1945 and was treated in another hospital with Lanes plate. A pseudarthrosis developed. The patient was admitted to the surgical Hospitals of Giessen University on September 19, 1946. The pseudarthrosis was resected and medullary nailing was performed with a double nail. A fibula resection was accomplished on September 23, 1946. Bony consolidation ensued and the medullary nail was removed on October 15, 1947 (Illustration 65). Other such examples are demonstrated in Illustrations 66 to 69.

The question remains to be discussed whether medullary nailing alone is able to achieve the healing of a pseudarthrosis. In theory this is quite imaginable, as the medullary nail pierces the tissue layers lying between the fragments establishing the communication of both parts of the medullary cavity. In the literature one constantly finds the contention that one of the principal requirements for the operation of a pseudarthrosis is to open the medullary cavities. *) This is a question one can answer today by the evaluation of several observations. These leave no doubt that under favorable conditions it is possible to bring about the consolidation of pseudarthroses solely by the introduction of a medullary nail without any additional operation and without an exposure of the pseudarthrosis. GERHARDT (68) was under the impression that the medullary nail stimulated the formation of callus when introduced for the treatment of pseudarthroses.

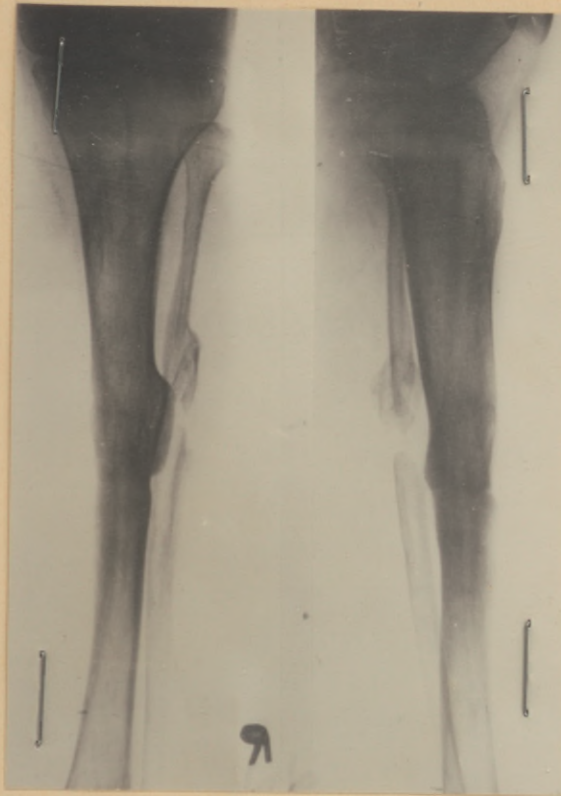*) See for instance BUNDSCHUH during the discussion of the lecture of NUSSELT: Chir. 1947, 429.



a



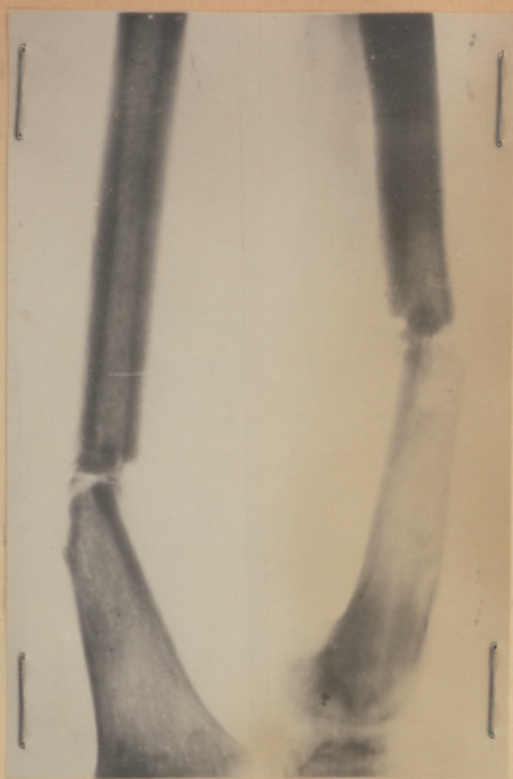b



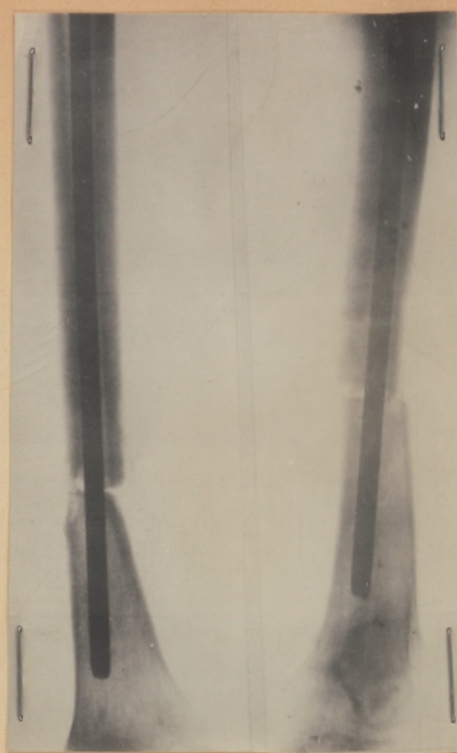
c

Illustration 65

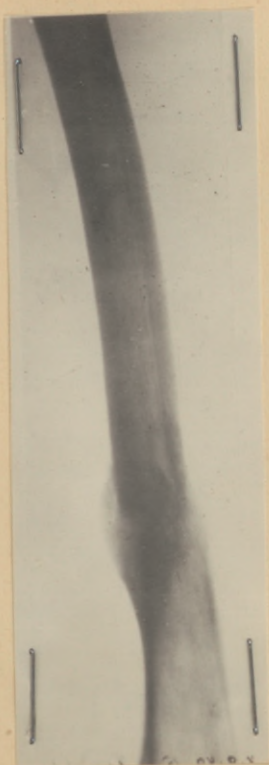- a) W.P., 60 years old. Pseudarthrosis of tibia.
- b) Condition after resection of pseudarthrosis, medullary nailing, and fibular resection.
- c) Pseudarthrosis is healed and medullary nail removed.



a



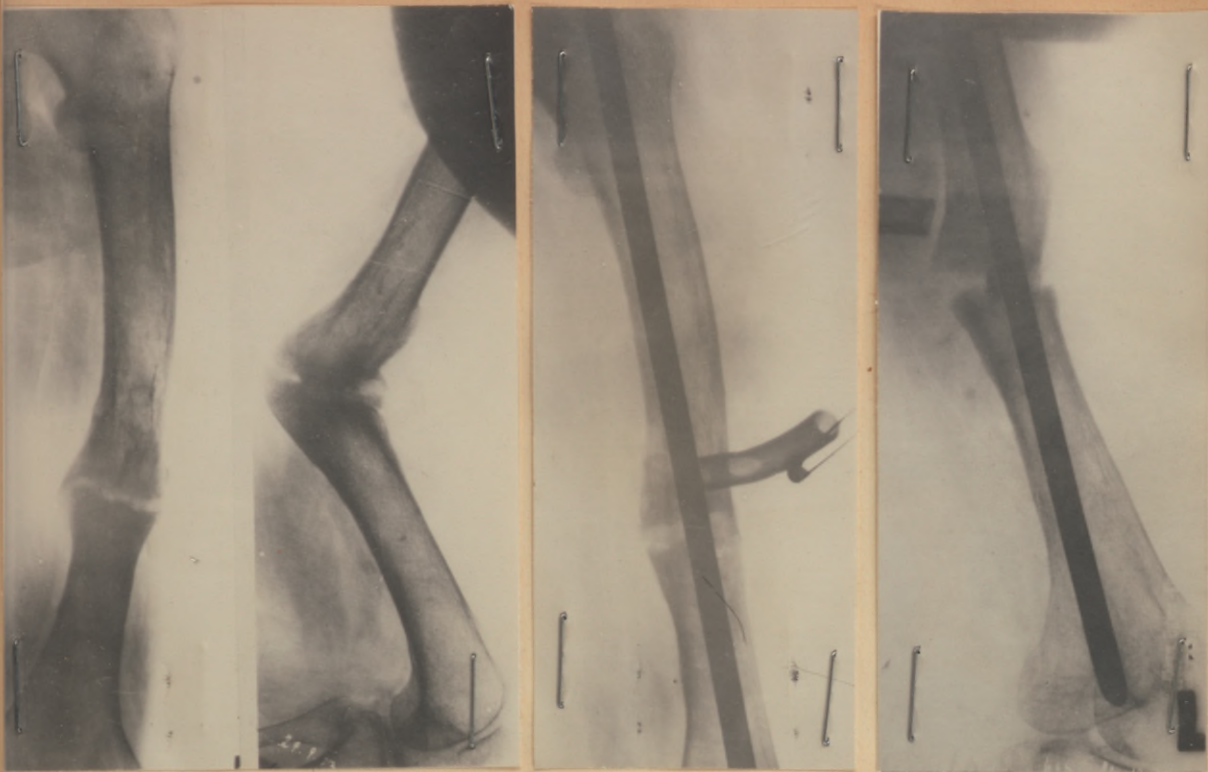
b



c

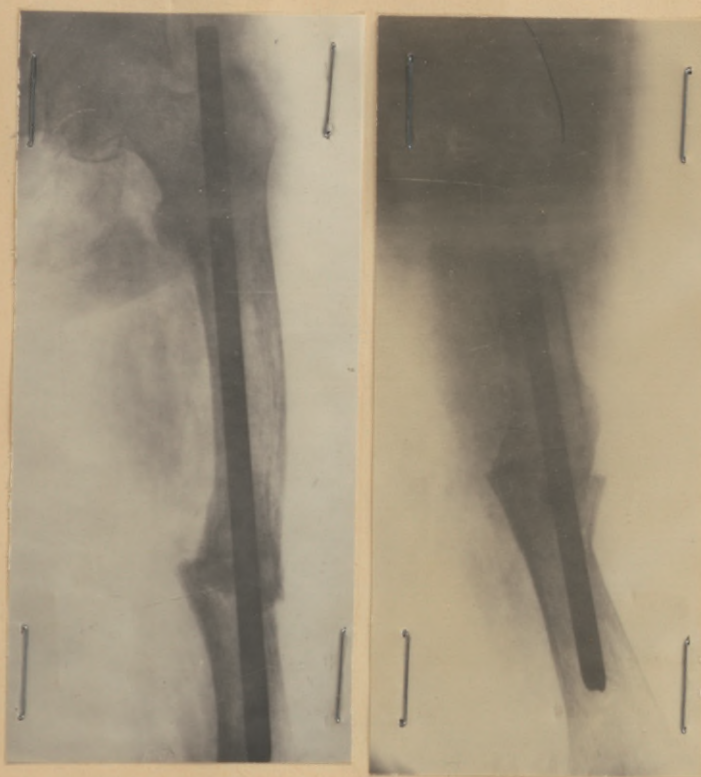Illustration 66

- a) Pseudarthrosis of femur.
- b) Condition after resection of pseudarthrosis and medullary nailing.
- c) Pseudarthrosis is healed and medullary nail removed.



a

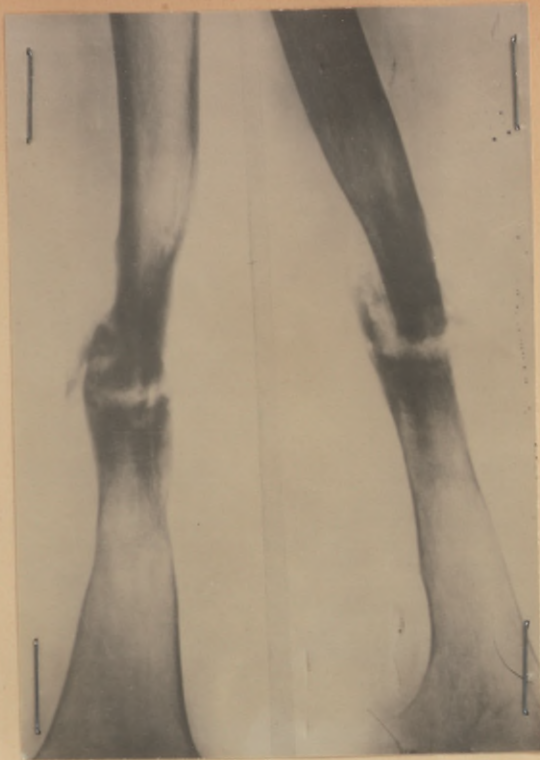b



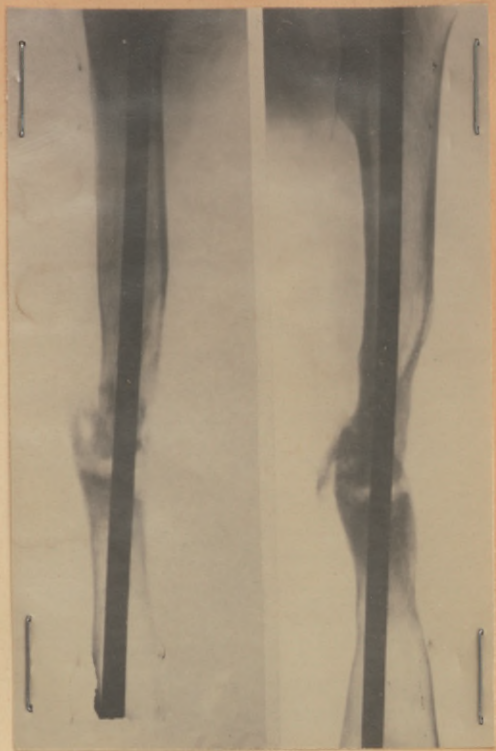c

Illustration 67

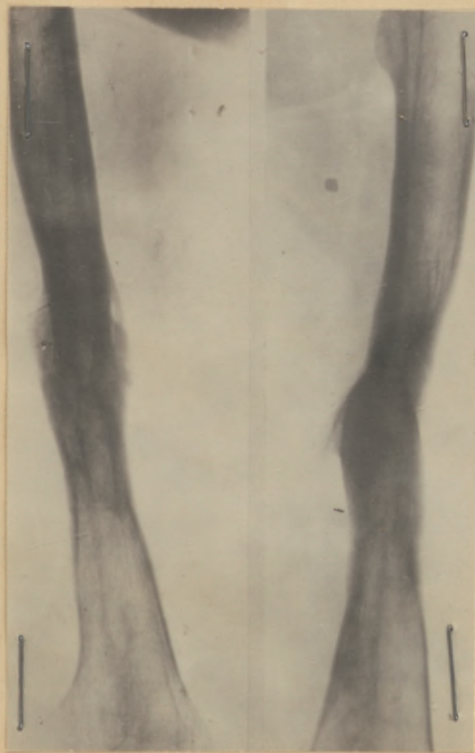- a) Pseudarthrosis of femur.
- b) Resection of pseudarthrosis.
Medullary nailing and drainage
of wound.
- c) Beginning formation of callus.



a



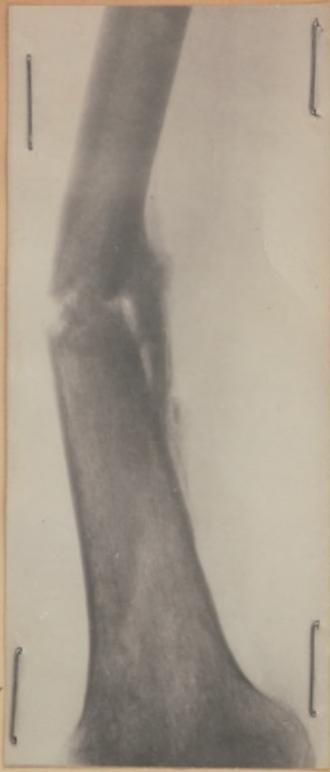b



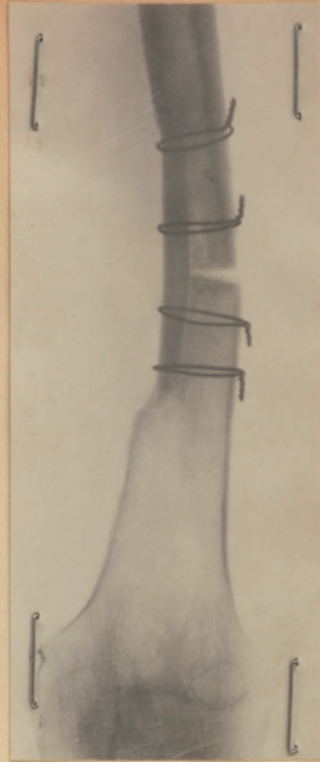
c

Illustration 68

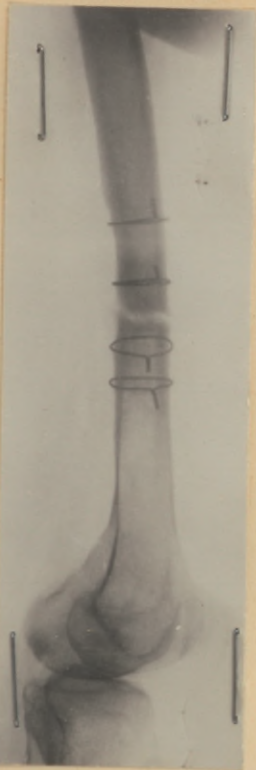- a) Pseudarthrosis of femur after failure of previous bone graft.
- b) Condition after removal of cicatrized tissue from fracture cleft and after medullary nailing.
- c) Pseudarthrosis is healed. The x-ray shows the condition during an examination after three years subsequent to operation.



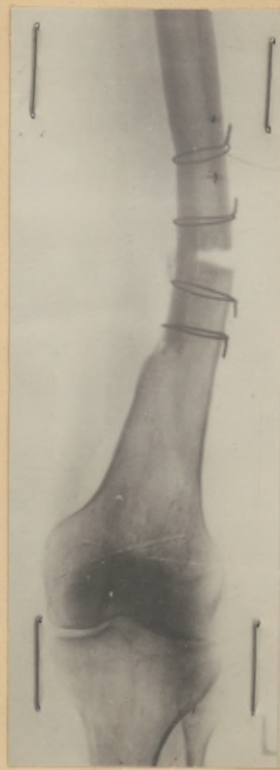a



b



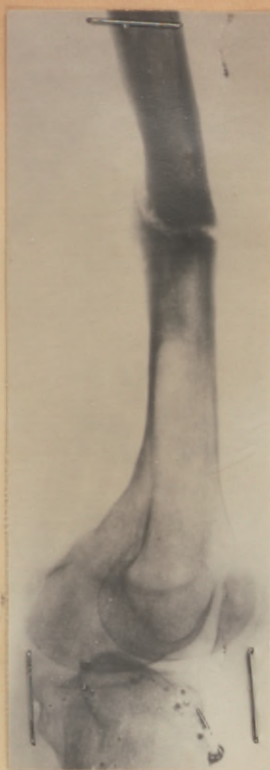c



d

Illustration 69

- a) Pseudarthrosis of left femur. Extension band-
age and plaster cast applied in another hospital.
- b) Condition after bone grafting and the application
of wire loops.
- c) Fracture of bone graft and bending of the fractured
femur.
- d) Bone graft is resorbed and a contact pseudarthrosis
has developed.



e



f

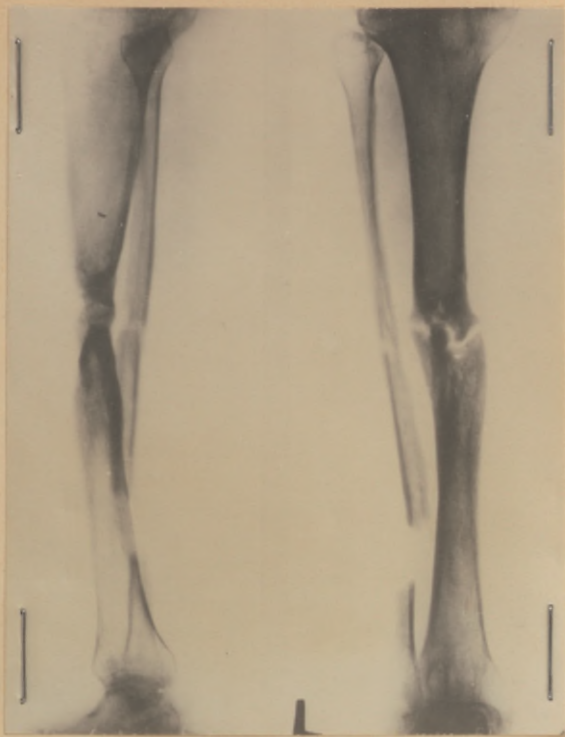

g

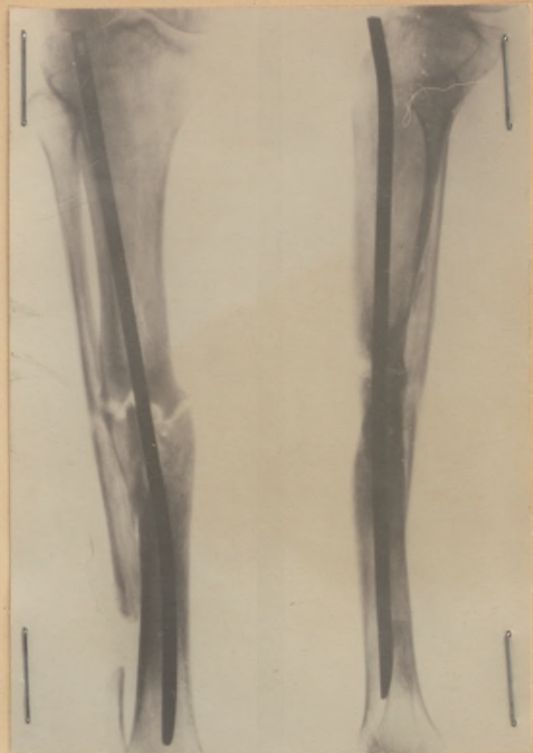Illustration 69 (cont'd)

- e) Condition after resorption of bone graft and removal of wire loops.
- f) Osteotomy and transverse freshening of the pseudarthrosis. Fixation by medullary nail. Beginning of callus formation on the nail tip.
- g) The fracture cleft is bridged over by bone. Increased formation of callus at the nail tip.

The consolidation of pseudarthroses after percutaneous medullary nailing alone is demonstrated here by several roentgenograms (Illustration 70-72).



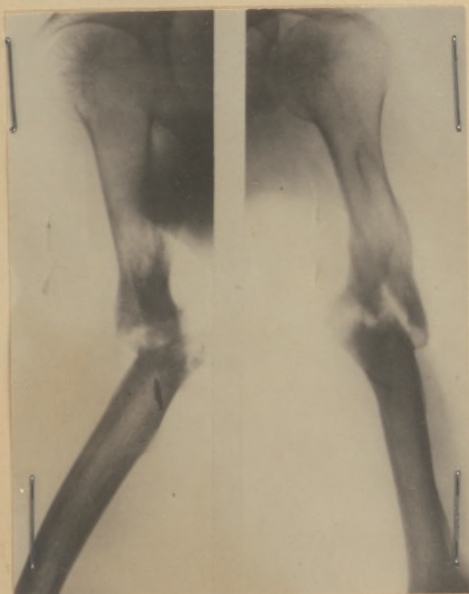a



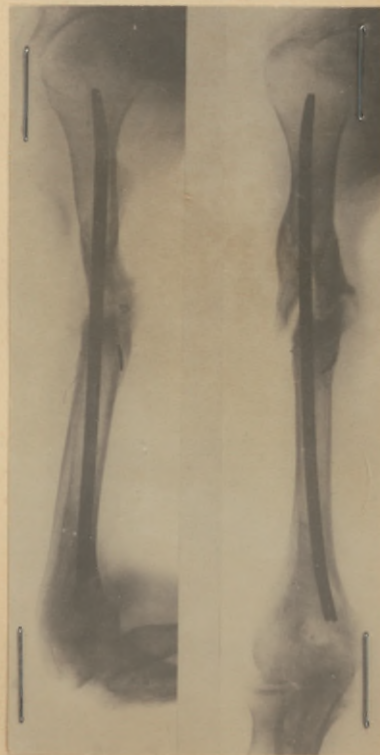b

Illustration 70

- a) Pseudarthrosis of leg which despite fibular resection is not consolidated.
- b) Condition after percutaneous medullary nailing.



a



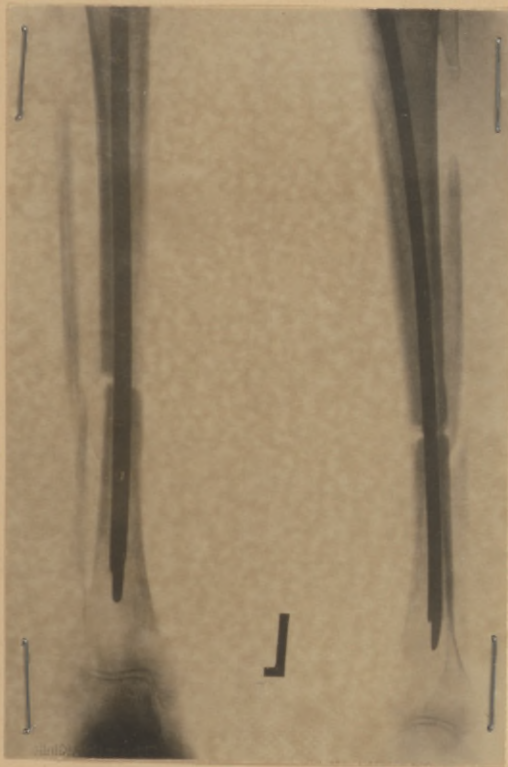
b

Illustration 71

- a) Pseudarthrosis of humerus after gunshot fracture.
- b) Condition after percutaneous medullary nailing. Because of unfavorable conditions relating to the soft tissue no osteotomy was performed.

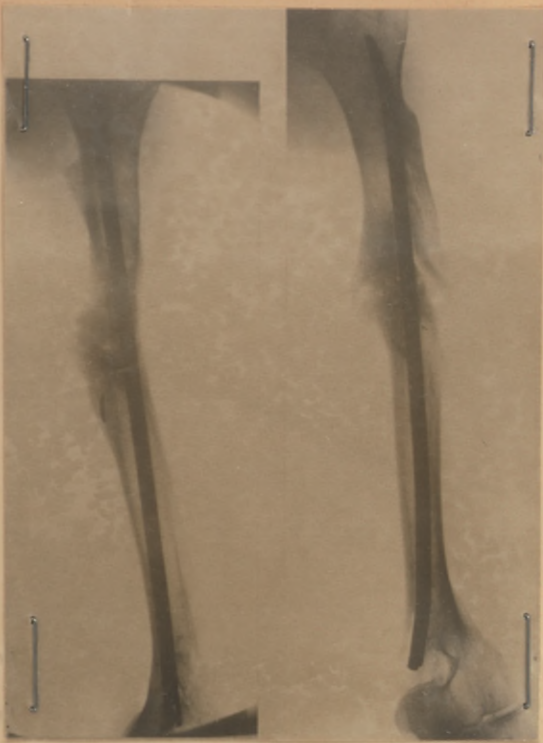
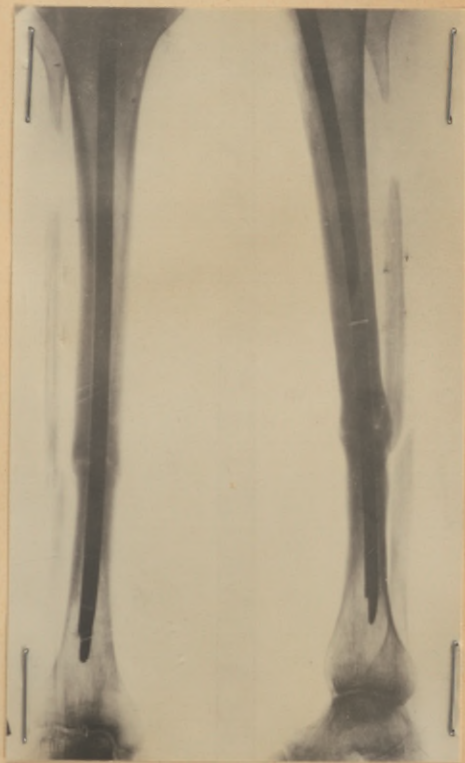
Illustration 71(cont'd)
c) Advanced formation of callus 4 months after percutaneous medullary nailing and without any additional intervention.



a

b

Illustration 72
a) Pseudarthrosis of leg. Condition after percutaneous medullary nailing with double nail. This was preceded by fibular resection as the only measure prior to nailing.
b) Advanced formation of callus.

As to that problem we should like to outline our experience and our points of view as follows: Under special conditions it may be possible to achieve healing of a contact pseudarthrosis by medullary nailing alone. This method however, does not represent the method of choice, but we use it with preference, if the exposure of the pseudarthrosis to an increased degree is linked to the hazard of infection, caused either by foreign bodies still present within the area of the pseudarthrosis or by prolonged suppuration in the case of a compound fracture. This, however, also means that the treatment of pseudarthroses resulting from suppuration may be commenced much earlier than when the pseudarthrosis would have to be exposed. Reference to this fact was previously made by NUSSELT (69). A further indication for percutaneous medullary nailing may be the condition of the soft tissue, particularly of the skin; if the operative elimination of the pseudarthrosis involves the danger of dermal necrosis it is suitable to perform percutaneous medullary nailing as a first attempt. This can not be done unless reduction is practicable without which no percutaneous medullary nailing can be performed. It remains to be stressed that the percutaneous medullary nailing of a pseudarthrosis in any case can be only regarded as an attempt to cure the condition by a measure which is as sparing as possible. If this yields no results medullary nailing constitutes just the first act of planned treatment. In such a case the transplantation of a bone graft follows as the second act which then inflicts considerably lesser damage on the tissue around the pseudarthrosis, because the medullary nail stabilized the bone thus saving the preceding bone grafting. The fixation by the medullary nail has a particularly favorable result when pseudarthroses located close to the joints are operated, as the fragments which frequently are very short give no hold to the bone graft and thus prevent the simultaneous fixation of the bone fragments as a whole. It will then not be necessary in every case to resect the pseudarthrosis according to a scheduled operation. A small freshening is sufficient, no precisely fitting bedding need be prepared for the graft, and the operation really represents not more than the introduction of a bone graft to bridge over the pseudarthrosis and to act as a biologic stimulant of the factors enhancing the formation of callus.

In a study which has appeared recently HELLNER (70) classified the pseudarthroses in genuine or "ordinary", and in gaping pseudarthroses. As its title "Medullary Nailing and Free Bone Graft" indicates and as the text reveals two methods are compared with each other in this study, a proceeding which in our opinion is not permissible. This may also explain why HELLNER had to admit a number of failures among his operations of pseudarthroses, a fact which aroused his pronounced dislike for medullary nailing in connection with the treatment of pseudarthroses. In the first pages of his study HELLNER overlooks the fact that medullary nailing is only a method for retention just as is the plaster cast, while, however, the bone graft is not a method for fixation with homologous material - this is also revealed by the cases reported by HELLNER where extensive use of wire loops is made to fix the bone graft - but a biologic method for stimulating the callus formation. For logic reasons it therefore, is not permissible to compare the results of medullary nailing and of bone grafting with each other. None of those who became familiar with these problems will be surprised that some of HELLNER's pseudarthroses healed with bony consolidation solely after resection

and nailing. *) The failures found, however, were not due to deficient fixation by the medullary nail and by the plaster cast, as HELLNER believed. If it was possible to cure pseudarthroses by bone grafting, then this was not achieved because the short graft effected a really stable fixation of the freshened fragments, but principally because of the biologic stimulation of the callus by the graft, possibly even indirectly by the removal of the bone substance. One really should not believe that a bone graft attached to the bone by means of a few wire loops is better able to achieve immobilization than the long medullary nail driven into the marrow cavity. HELLNER certainly is right in stating that due to atrophy of the bone the medullary nail soon will lose its capacity of providing an absolutely fitting stable fixation. But it is only in very rare cases that we rely exclusively on the fixation provided by the medullary nail alone, since we add a plaster cast after the operation of pseudarthroses as was done by HELLNER too. After bone grafting, the bone and the bone graft suffer an alteration caused by the process of metamorphosis, and thus it happens that an absolutely stable fixation can be guaranteed in no case.**) Therefore the conclusion is justified that with regard to the problem of immobilization the medullary nail and an additional plaster cast are at least equal in value to the combination of bone grafting and plaster cast immobilization the medullary nail and an additional plaster cast are at least equal in value to the combination of bone grafting and plaster cast immobilization, if ever one is ready to accept HELLNER's thesis of the stabilizing rôle of the bone graft which seems to be shared (see above, BOEHLER) by other authors too. We repeat once more that such a comparison provides no basis for discussion.

These considerations were enlarged and essentially supported by the experience of decades collected by PHEMISTER (72) with the method practised by him for the treatment of the pseudarthroses. PHEMISTER employed one or even two bone grafts usually taken from the area adjoining the pseudarthrosis and he attached them alongside the pseudarthrosis without preparing a bedding for the graft. Only bony processi were removed by chiseling, if necessary, to establish as large a contact of the bone graft as possible with the two fragments touched by it. These bone grafts were neither grooved nor bolted, nor were they kept in place by wires or other material. If the shape of the bone graft permitted a more

*) Some of the experiences made in the Giessen University Hospitals the treatment of pseudarthroses by medullary nailing were described by NUSSELT (71).

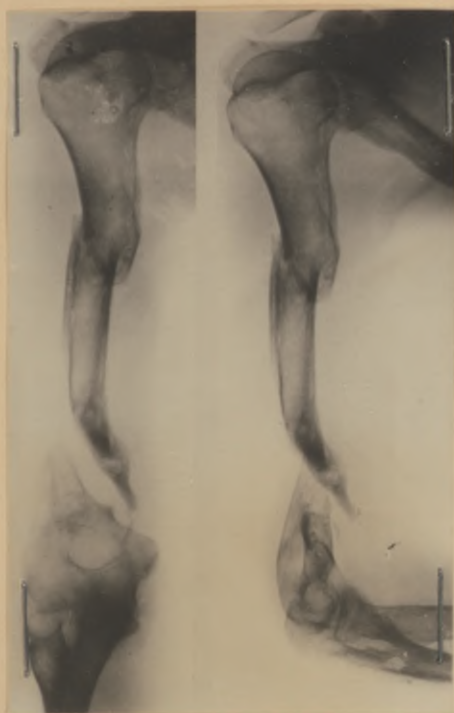***) This was clearly shown by Illustration 8 in HELLNER's study.

adequate attachment to the bone if it was reversed, so that the periosteum pointed inwards, PHEMISTER proceeded in this way. This did not disturb the process of healing *). Only the soft tissue was sutured and a plaster cast was applied. The pseudarthrosis was not resected or freshened and it was left as it was. The pseudarthroses treated in this way resulted in a bony healing, as was shown by PHEMISTER in a great number of roentgenograms. For such a procedure, of course, only those pseudarthroses are suitable the position of which requires no correction. It is interesting to know that PHEMISTER underlined the metaplastic metamorphosis of the cicatrized tissue of the contact pseudarthroses which is converted to bone tissue and here we find the experience pointed out by HELLNER too, that bone may be formed by connective tissue cells. In a case showing vertebral fracture and simultaneous paralysis of the legs demonstrated by PHEMISTER not even a plaster cast was applied as the legs remained immobile due to the paralysis. The successful proceeding of PHEMISTER shows clearly that a bone graft is no retention appliance but a means for the stimulation of the metaplastic osseous metamorphosis of the zone of the pseudarthrosis (see Illustration 53 g). It is possible that PHEMISTER was not conscious of this predominantly biologic role of the bone graft, but his instinct for the healing process of the bone showed him the right way. The immobilization after bone graft certainly is indispensable, but as PHEMISTER's cases show, it may be accomplished by a plaster cast quite as well as by the medullary nail, as we were able to observe. As to its origin the metaplasia pointed out by PHEMISTER is closely related to the crystallization process of HENSCHEN quoted by HELLNER.

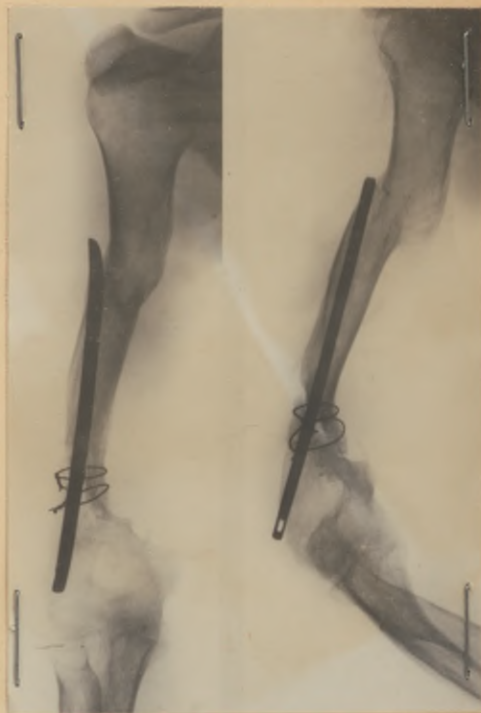It shall be stressed once more that after all one knows today about pseudarthroses and medullary nailing, there can be no doubt that medullary nailing alone is no method for the treatment of pseudarthroses, but only a mechanical auxiliary, which should be used without hesitation with or without a bone graft. One of the great advantages of medullary nailing consists in the fact that it enables us to stop using the wire loops rejected by so many surgeons for the fixation of the bone grafts. Therefore, if the bone graft is fixed by a groove this is not made to forge the fragments together in a joiner's way (HELLNER) but quite on the contrary to prevent the bone graft from shifting without the use of foreign bodies.

*) We do not fully understand why HELLNER subjected the bone grafts in the "aseptic workshop" to such a radical "joiner's fashioning", so that even the periosteum was rasped off with a file which was particularly underlined by HELLNER. Even if one is ready to accept the concept originating from VON ERTL that not the periosteum but its cambium layer sticking to the outermost corticalis accomplishes the regeneration of the bone, it is not necessary to remove the periosteum and to rasp the transplanted bone graft "on all sides".

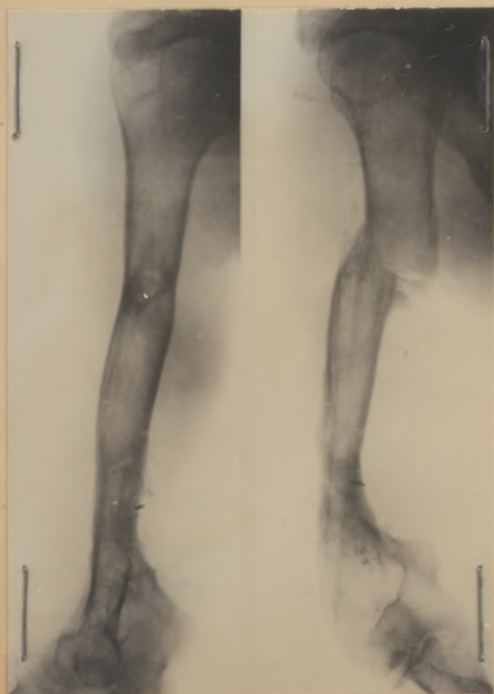The medullary nail gains its greatest importance for the retention of the fragments after the operation of gaping pseudarthroses. Here it is necessary to bridge over the gap by bone grafts and for the purpose of avoiding shortening which would impair particularly the function of the lower extremity, to immobilize the fracture ends at a great distance from each other and in an appropriate axial position. If one does not want to bridge over the gap with a bone graft, but instead wants to introduce small bone pieces or spongiosa particles according to MATTI, no other fixation than that by medullary nailing is suitable (CELLARIUS (73)). ZENKER (74) was several times successful in employing the method of spongiosa transplantation. The stabilization is a task which not always can be accomplished by the bone graft alone (Illustration 73), particularly on the femur, where fractures of the bone graft all too frequently annihilated the favorable original result of the restoring operation. Even the use of two strong bone grafts (BATEMAN (75)) cannot always prevent such an incident. For this technical necessity we dispose of no better auxiliary than the medullary nail, and it may be said that the stabilization of the gaping pseudarthroses similar to that of the osteotomies constitutes the very domain of medullary nailing.



a



b



c

Illustration 73

- a) Gaping pseudarthrosis after multiple gunshot fracture of humerus.
- b) Condition after exposure of pseudarthrosis and fixation of fragments by two wire loops without any bone graft. Medullary nailing from the distal end.
- c) Pseudarthrosis has healed, medullary nail and wires are removed.

The technique of our proceeding was to prepare a bedding for the bone graft in the fragments of the bone by means of the circular saw and a chisel after the resection of the pseudarthrosis. Then the bone graft was taken from the tibia, attention having to be paid to all layers adhering from periosteum to bone marrow. To reduce the number of wire loops required for the fixation of the transplanted bone we beveled the ends of the bedding as well as those of the bone graft in such a way that they could slide in as in a groove. This method was described by BRUN (76) as early as 1917 (Illustration 74). Then usually a wire loop attached to each side is sufficient (Illustration 75), but sometimes we attained our object without any looping at all, provided the bone graft was exactly

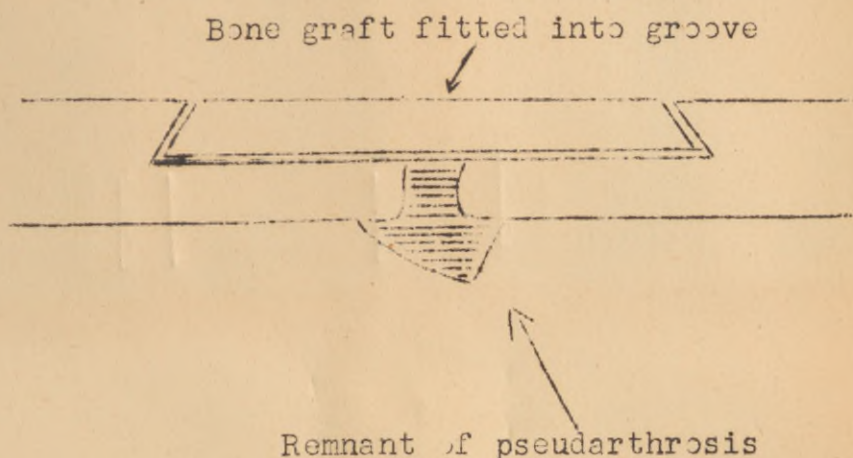
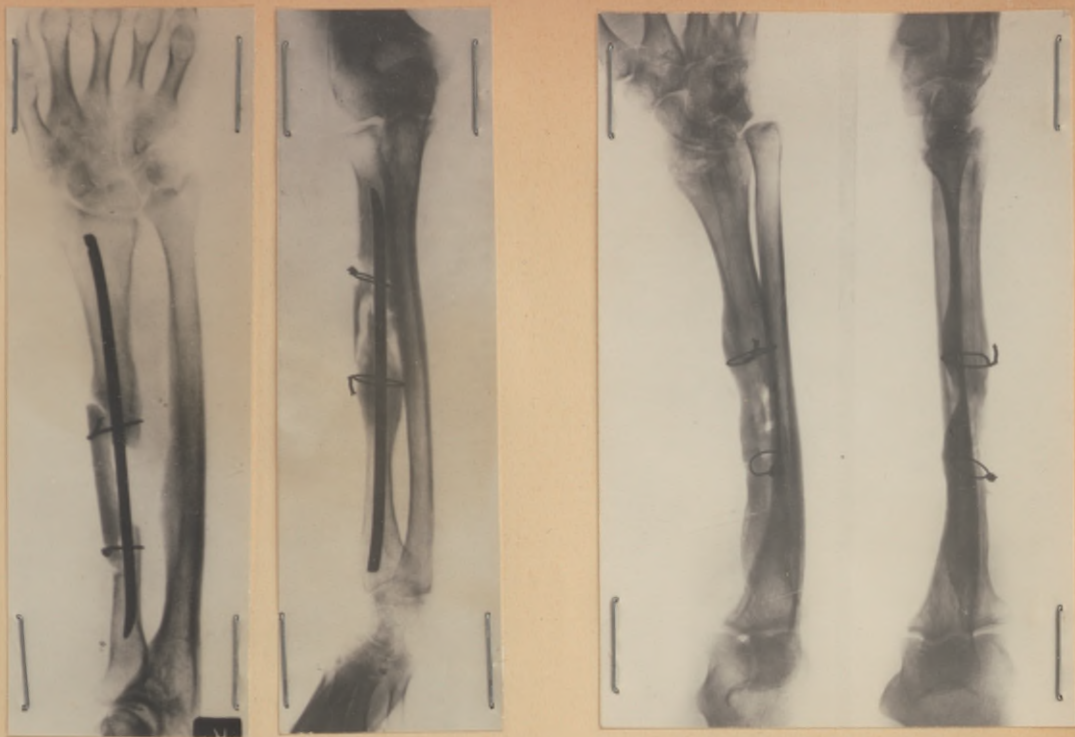


Illustration 74

Schematic design of how a bone graft is fitted into the groove for the purpose of bridging over a pseudarthrosis (after BRUN: Zbl. Chir. 1917, 969).

and firmly fitted into the groove (Illustration 76). This certainly is desirable and it is only feasible with the aid of the medullary nail which insures the fixation of the extremity. Valuable as medullary nailing is for the operation of gaping pseudarthroses it nevertheless must be admitted that in some cases the presence of the medullary nail has a disturbing effect in so far as it takes up part of the space necessary for the bone graft. Unfortunately we made the experience that primarily thick and strong tibia grafts had to be reduced in size considerably if it was intended to insert them in the bedding prepared for the bone graft, as the medullary nail took too much room. It is worth considering whether in such cases it would not have been better to abstain from the preparation of a bedding and to attach the transplantation simply alongside the freshened fragments to avoid reducing its valuable components.



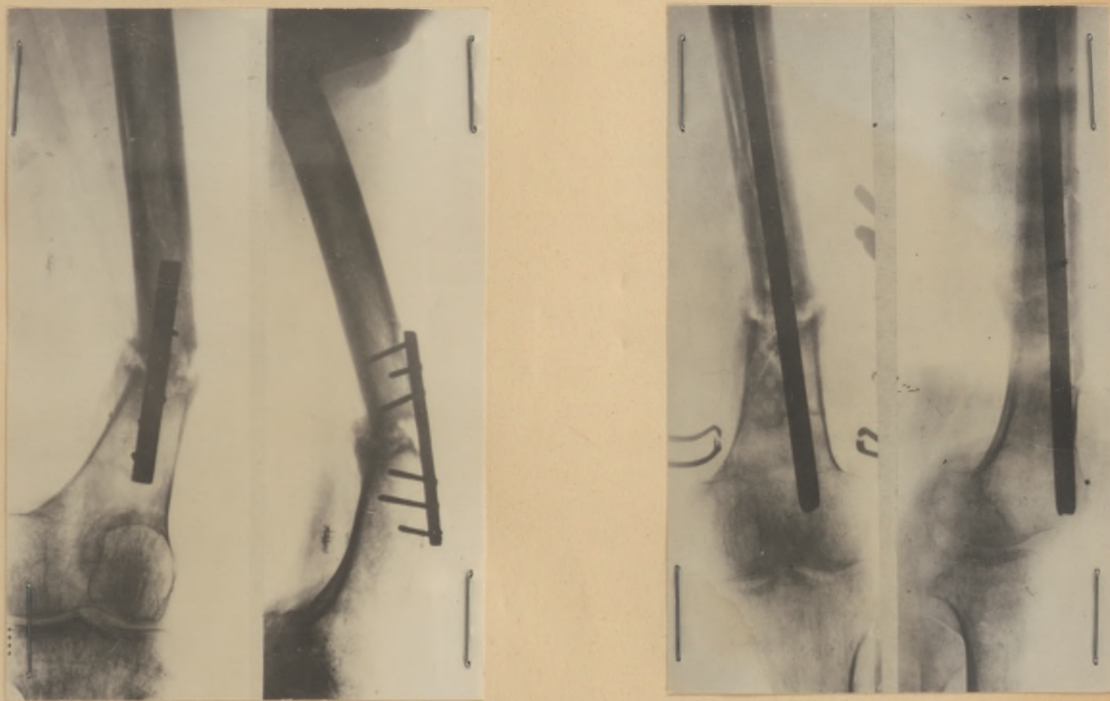
a

b

c

Illustration 75

- a) Gaping pseudarthrosis of radius treated with bone graft and medullary nailing.
- b) Infection within the operation area resulted in a sequestration of the bone graft, part of which is detached.
- c) Favorable final result despite infection. The gaping pseudarthrosis is bridged over by bone. The medullary nail is removed.



a

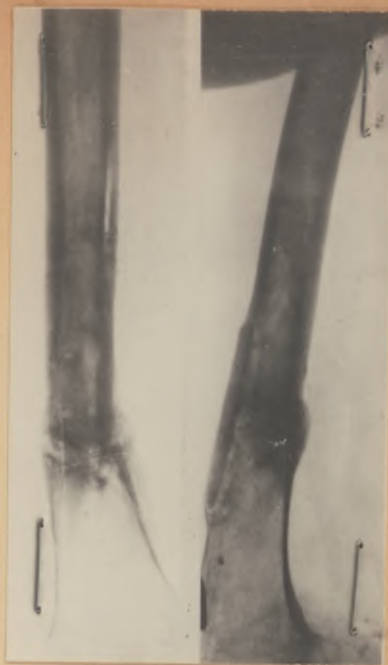b

Illustration 76

- a) Pseudarthrosis of femur caused by distending effect of a Lane's plate attached to the bone in another hospital.
- b) Condition after removal of Lane's plate, reduction, bone grafting, and medullary nailing. On the lateral aspect the grooving of the bone graft without any additional fixation is clearly visible.

Illustration 76 (cont'd)

c) Condition after healing of pseudarthrosis and removal of medullary nail.



c

Recently LEZIUS (77), most likely on the basis of K.H. BAUER's (78) studies recommended a procedure by which the gap on the forearm bones can be bridged over by a bone graft containing a medullary cavity. For this purpose part of a rib or fibula must be used. The stability of the bone is guaranteed by Kirschner wires inserted in the medullary cavities of the fragments and of the transplanted bone. The principle of medullary nailing is therefore maintained. The transplanted bone is threaded upon the wire as in the treatment of compound fractures. Actually, the use of whole bone segments for transplantation is nothing new. GULEKE (79) as early as 1916 pointed to the bolting of bones with parts of the fibula covered with periosteum according to LEXER. Merely the fixation of the transplanted bone segment by foreign bodies inserted into the medullary cavity shows a similarity to the Kuentscher Nailing.

For the treatment of large tibia defects LEZIUS (80) recommended transplanting a circular tibia segment from the healthy leg to the leg with the pseudarthrosis. In the course of this operation the pseudarthrotic tibia must be lengthened by one half of the length of the gap after accurate measuring, while the healthy tibia must be shortened by the same amount. Of course it is necessary to shorten the fibula of the healthy leg to a corresponding extent. Both tibiae are provided with medullary nails so that excellent results with regard to position are yielded. By this procedure, however, the whole individual becomes shorter so that even with a shortening by few centimeters extremely inconvenient disproportions in the length of the extremities are created. Such operations are permissible almost exclusively after gunshot fractures with their large bone gaps, and particularly these injuries are menaced to a high degree by infection. A failure of the tibia graft to heal into the bone caused by suppuration is particularly grave, since then the valuable material was spoiled by the useless shortening of the healthy leg. It is most questionable whether one is allowed to perform such an intervention in view of the possibility of a failure. At any rate those cases which were examined by us in accordance with LEZIUS defied this method of treatment of gaping pseudarthroses. Recently I learned that LEZIUS himself has become decidedly more cautious

recommending his method only for femur fractures. The method is only practicable if the wound is not contaminated and if sufficient penicillin and suprinal are available.

Our proceeding in relation to medullary nailing and bone grafting shall be shown by roentgenograms (Illustration 77 to 80).

The results obtained with medullary nailing of pseudarthroses are given in the table (Illustration 81). Moreover, TUERK (81) compiled a survey on the results of the treatment of 38 pseudarthroses admitted to the Giessen University Hospitals. It reveals that in the case of contact pseudarthroses of the tibia the average amount of time required for full consolidation after resection and medullary nailing with and without bone graft was 8 months. A bony bridging of the pseudarthrosis was to be observed on an average after 4 months. Moreover, it is of interest to observe the difference between the treatment of pseudarthroses in peacetime before and after invention of the nailing method. This is demonstrated by the comparison of the number of days spent in hospital. Before medullary nailing 3,824 days were spent in hospital, in contrast to 1,722 days spent after the introduction of this method of treatment. In 12 cases contained in this survey the reduction of capacity was 0%. Most of those cases which were still measurably restricted in their working capacity after the successful treatment of their pseudarthrosis showed an immobilization of the joints as a reason for their invalidity, but the stiffening had already been present before the pseudarthrosis operation thus constituting an irreparable sequela.

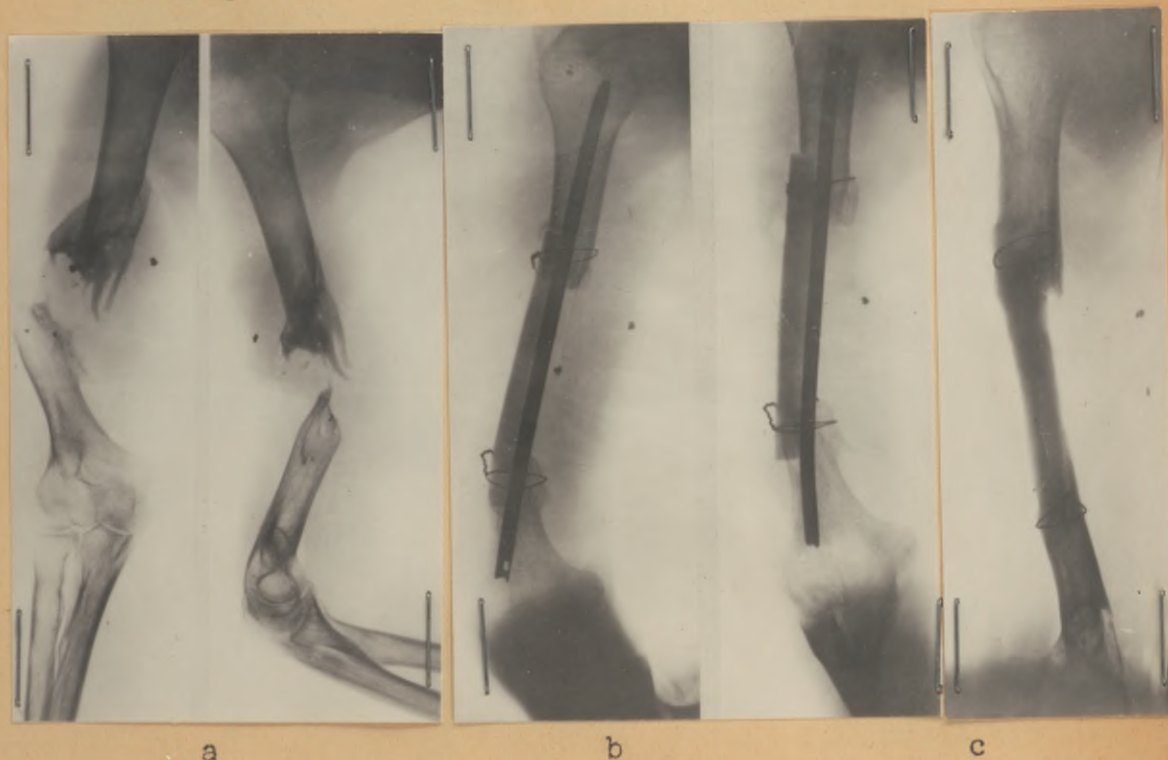
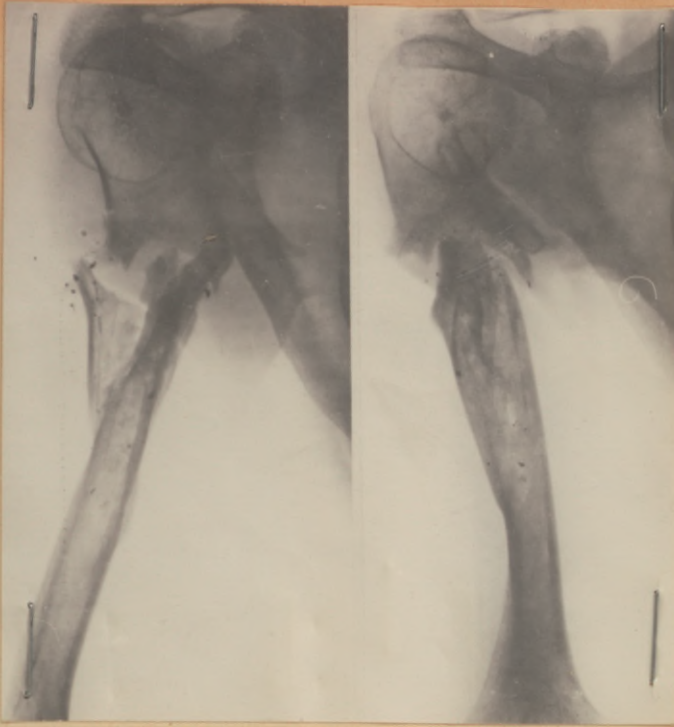
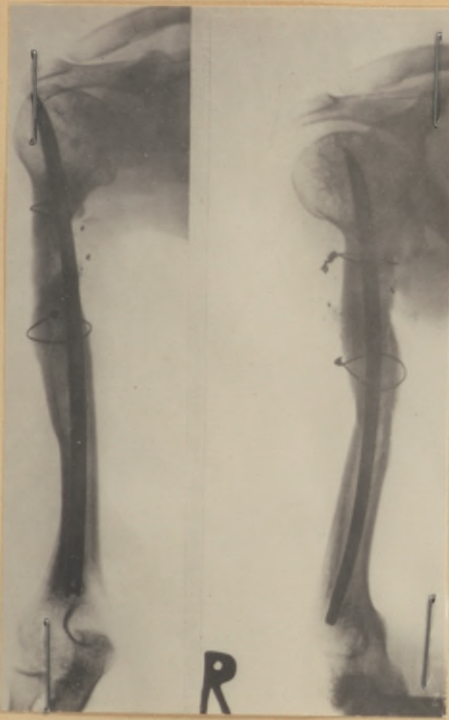

Illustration 77

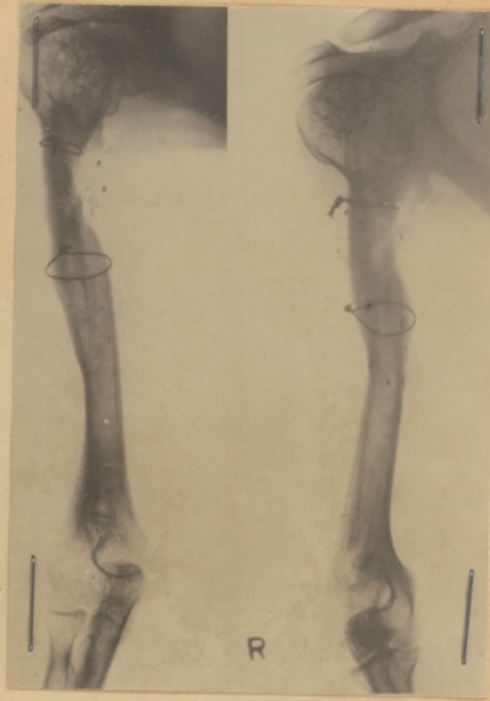- a) Gaping pseudarthrosis after gunshot fracture of humerus.
- b) Resection of pseudarthrosis, bone graft and medullary nailing.
- c) Condition after healing of pseudarthrosis and removal of medullary nail.



a



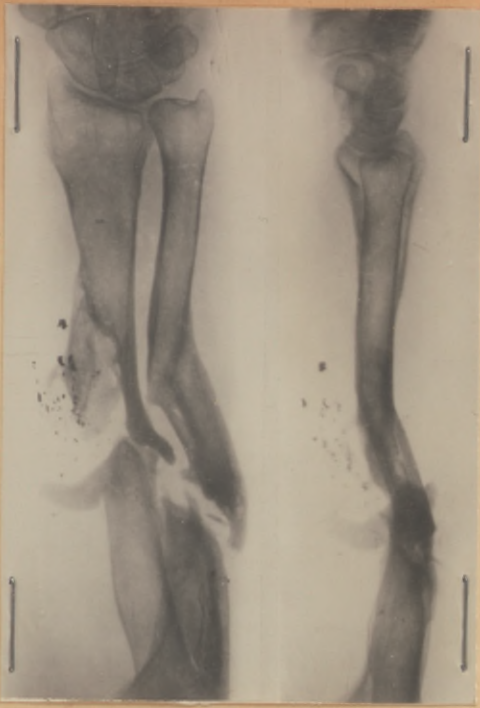b



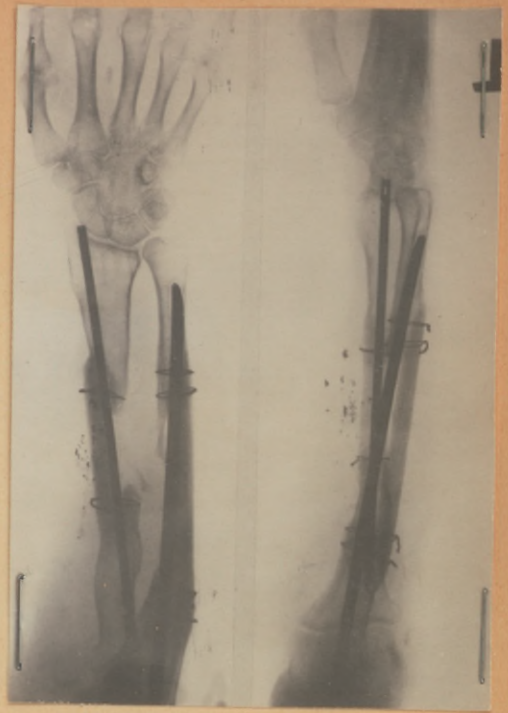c

Illustration 78

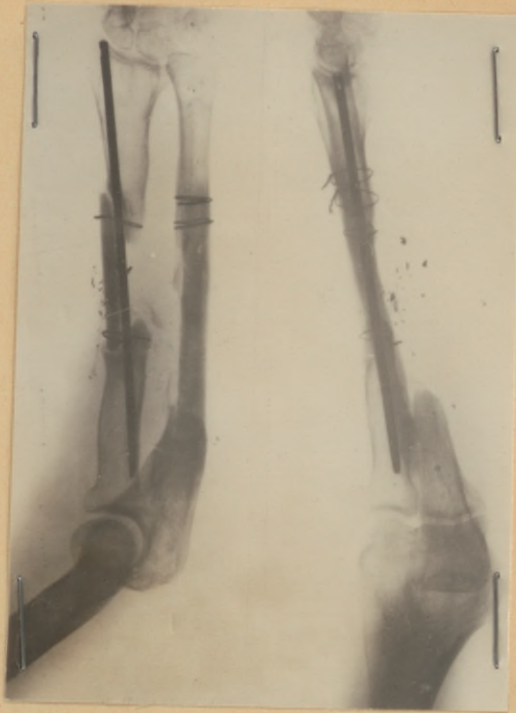- a) Gaping pseudarthrosis of humerus near the shoulder joint.
- b) Condition after resection of pseudarthrosis, bone graft, and medullary nailing from the distal end.
- c) Pseudarthrosis has healed and medullary nail removed.



a



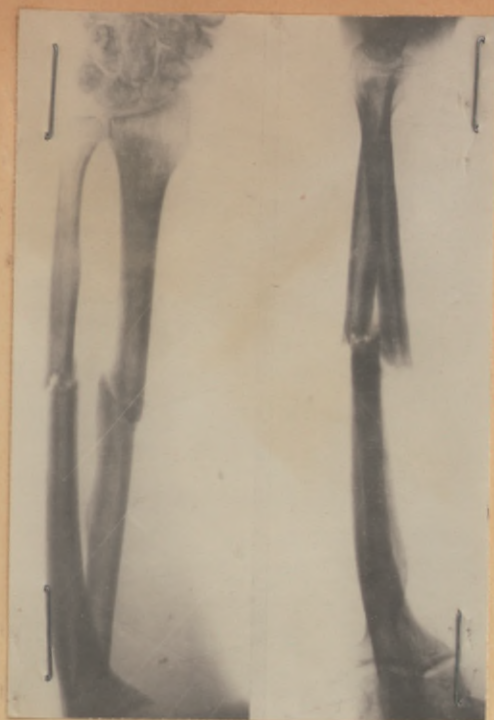b



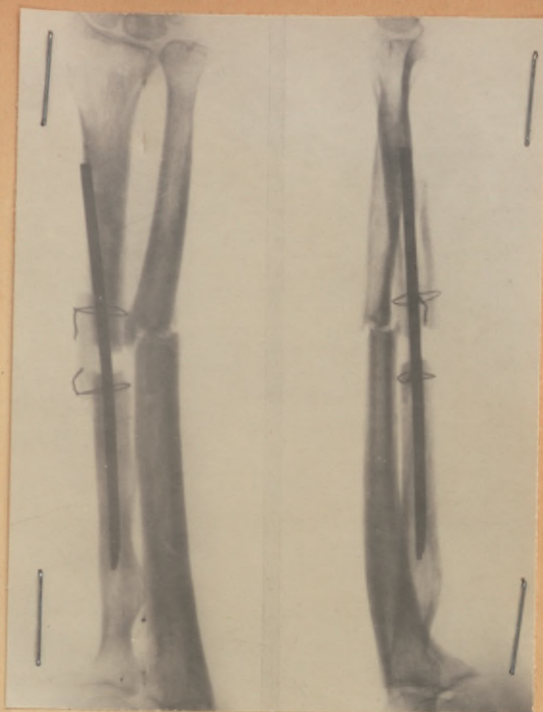
c

Illustration 79

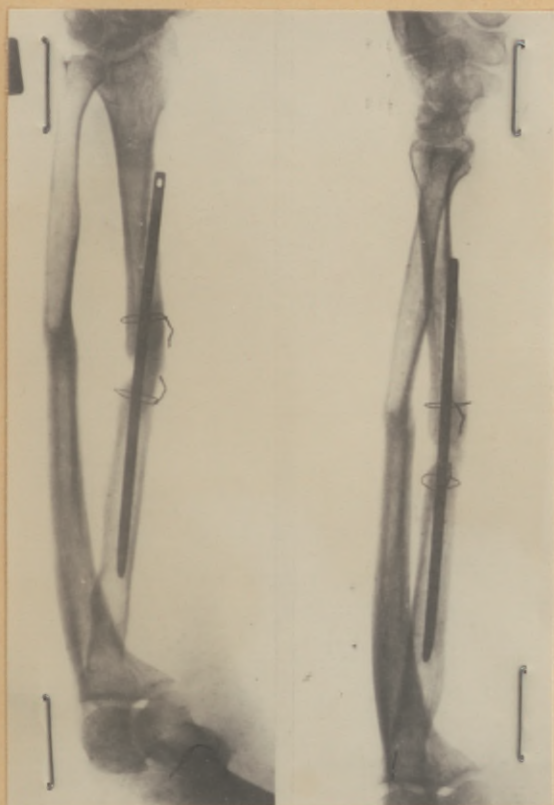- a) Gaping pseudarthrosis after gunshot fracture of left forearm.
- b) Condition after resection of pseudarthrosis, bone graft, and medullary nailing of both forearm bones.
- c) Pseudarthrosis of ulna has healed, medullary nail and upper wires are removed. The medullary nail of the radius is still in place, as the bone graft has not yet healed in definitely.



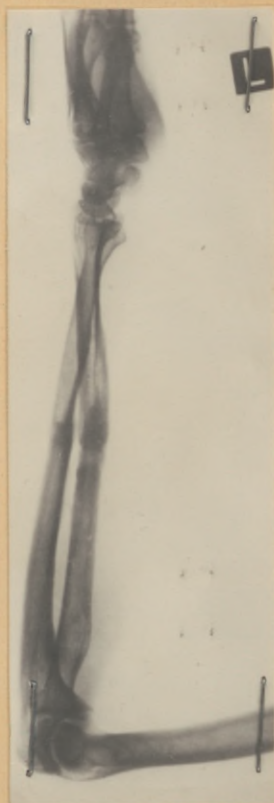a



b



c



d

Illustration 80

- a) Pseudarthrosis of forearm.
- b) Condition after resection of radial pseudarthrosis, bone graft, and medullary nailing of radius alone.
- c) After the radial bone graft has healed in, the pseudarthrosis of the ulna also was consolidated. Stimulation of callus formation by the adjacent bone graft (cf. PHEMISTER)
- d) Condition after removal of wires and of medullary nail, $1\frac{1}{2}$ years after operation.

Results of Treatment of 47 Pseudarthroses with Medullary Nailing.

Bone Involved	Number of cases	Percutaneous nailing	Bony Consolidation	Resection and Medullary Nailing	Bony Consolidation	Resection Bone graft and Medullary Nailing	Bony Consolidation	Complications
Humerus	11	2	2	7	7	2	1	1 Local osteomyelitis, sequestration of bone graft
Forearm	15	-	-	9	9	6	6	5 slight local osteomyelitis, bone graft healed in
Femur	12	2	2	10	10	-	-	-
Tee	9	7	5	1	1	1	-	2 Failures of attempt to perform percutaneous medullary nailing in case of a large defect of the tibia; due to cicatrization no bone graft practicable 1 Local osteomyelitis with sequestration of bone graft
Total:	47	11		27		0		

Illustration 81

The chapter dealing with the treatment of delayed fracture healing and with pseudarthrosis would be incomplete without a closer study of the distending effect which plays an important rôle in the development of both conditions. GULEKE made reference to it as early as 1916. The knowledge of that disturbance due to mechanical conditions has increased during the last years and now it ranges among the recognized factors to be taken into account for every fracture treatment. In the forearm it frequently is the neighboring sound bone which brings about the distending effect and which prevents the consolidation of the fractured bone.

A glance at the normal anatomic conditions shows that the longitudinal dislocation of the forearm bones is prevented by the membrana interossea in a particular manner. This membrana relaxes but with extreme pronation and even then to a very slight degree only. In all other positions however, it has to be considered as so tensed, that, for instance, during a fall upon the forearm or the hand it rather is the bone which breaks than the membrana which ruptures. "The ligaments, therefore, may be considered as practically indestructable (VON LANZ and WACHSMUTH (82)).

On the forearm the danger of a "distending effect" exerted by the sound bone usually arises when the pseudarthrosis of the adjoining bone was resected so extensively that the bridging over of the gap is menaced. In such a case besides the bone graft one disposes of the possibility to shorten the healthy bone correspondingly.

It occurs not infrequently that on the originally sound bone a fracture, in the sense of a fatigue fracture or even pseudarthrosis, develops. Even after bone grafting the distending effect of an adjoining bone must be taken into account. This effect may become manifest by the development of a slowly progressing fracture, in the sense of a fatigue fracture, in the firmly healed in bone graft. Then immediate action must be taken by resecting the adjacent bone or by cutting it through with a chisel in oblique direction (GULEKE (83)) so that its ends may slide past each other. According to our experience it is not sufficient to chisel the tibia in an oblique direction as it frequently happens that the osteotomy of the fibula is consolidated earlier than the tibia fracture, where the process of healing is delayed and it then occurs that the distending effect returns again. For this reason since 1940 we have usually resected (STOTZ (84)) about 3 cm. of the fibula subperiosteally, an operation which constitutes no particular operative strain for the patient as its performance is easy and rapid. For this purpose we employ Sauerbruch's special scissors for the first rib.

Here it shall not be concealed that in the case of some of the fibular resections it was revealed that the fibula although seemingly showing a distending effect on the roentgenogram was not at all consolidated at the site of its fracture, and that it would have given way to the pressure of the body weighing upon the leg. That does not mean that the entire problem of the distending bone was a faulty concept, particularly as also in these cases of previously delayed consolidation of the tibia the fracture was wedged together by walking on it after the resection of the fibula. But it shows how careful one must be in evaluating such things and also in interpreting the X-ray pictures. For these special cases, however, we may imagine that the fibular resection provoked a new biologic stimulation leading to the healing of the fracture, and thus proved a profit for the tibia.

The distending effect of Lane's plate was mentioned above. It usually is caused by the fact that the ends of the fragments atrophy before the formation of callus sets in. This has the result that the fracture cleft is somewhat enlarged and the mechanical immobilization by the plate screwed in prevents the fragments from following the muscle traction or the pressure exerted by weight-bearing and from fitting together in such a way they touch each other (Illustration 82).

KUENTSCHER and MAATZ underlined earlier that under certain conditions the medullary nail may also exert a distending effect which results in a delayed formation of callus or to pseudarthrosis. BOEHLER too made reference to this fact. It even was found with single-boned limb segments (humerus, femur), whenever the medullary nail for some reason had not effected a really stable osteosynthesis. Then the fragments make slight movements and the fracture does not come to a rest. While small defects are bridged over by callus, if the nail is firmly seated, the fracture healing is disturbed when immobilization is insufficient. This disturbance, therefore, cannot be charged to medullary nailing as a method, as it always is due to the non-observation of the establishment of mechanical condition which are indispensable for medullary nailing.

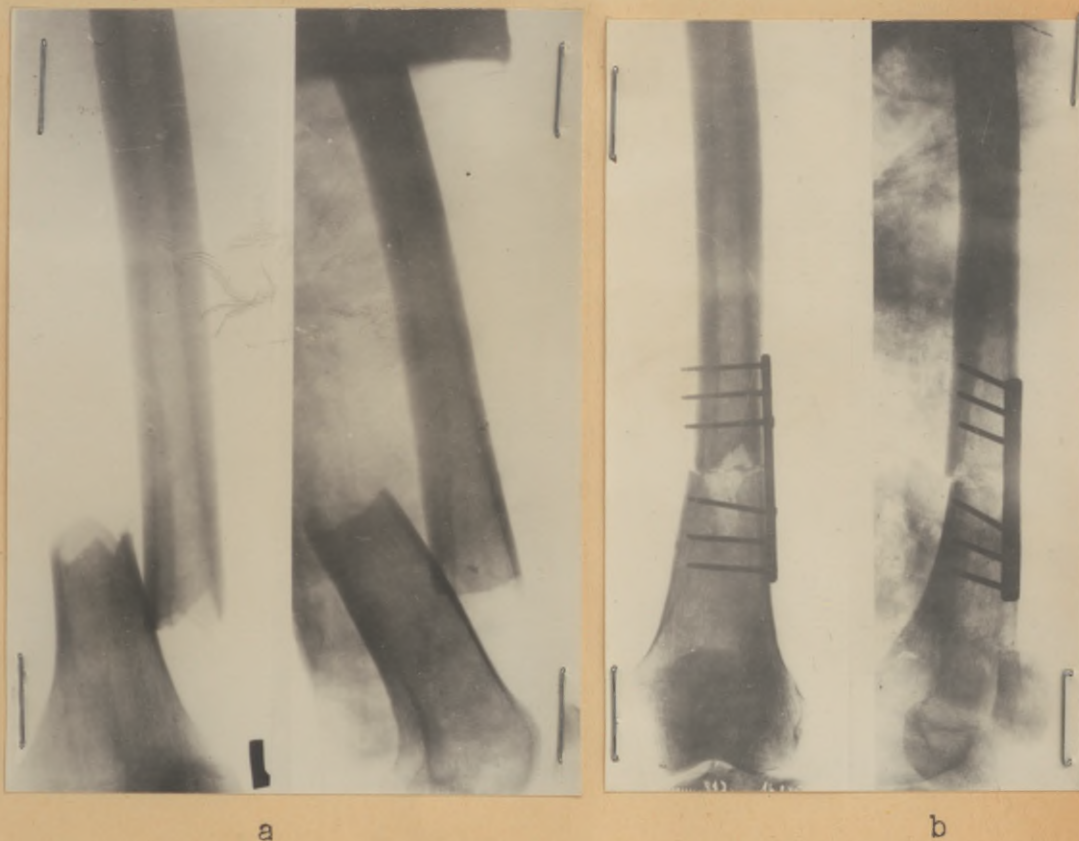
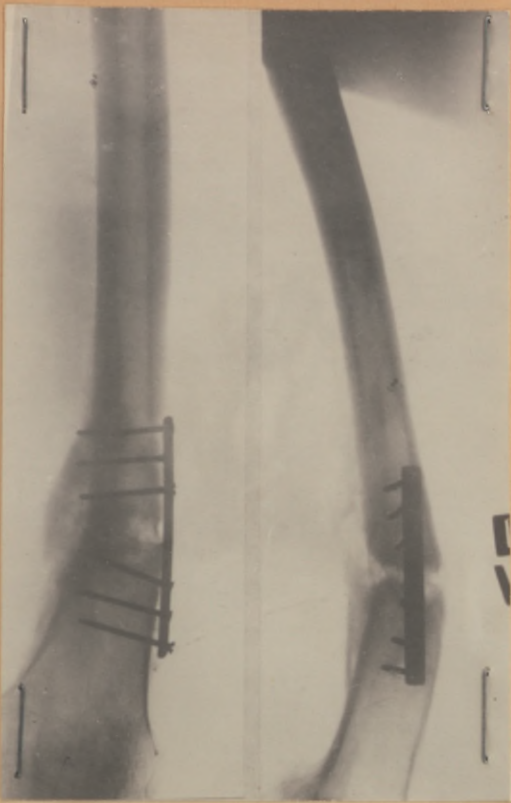
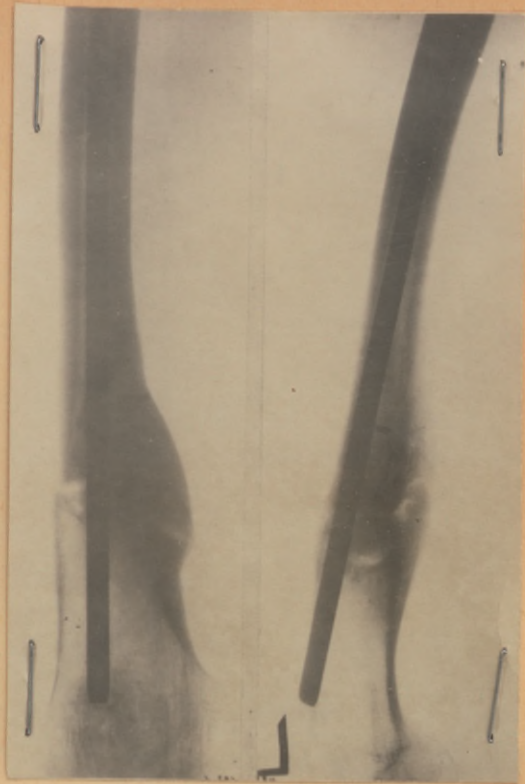

Illustration 82
a) Supracondylar femur fracture.
b) Condition after application of Lane's plate.



c



d

Illustration 82 (cont'd)

- c) Considerable axial bending and insufficient formation of callus, 6 months after application of Lane's plate.
- d) Lane's plate is removed, the position of the fragments reduced, immobilization by medullary nailing. After a period of 1 year the medullary nail has penetrated the compacta with its tip. The satisfactory result of the fracture was not impaired by this incident.

INFLUENCE OF MEDULLARY NAILING UPON THE
FORMATION OF CALLUS.

The formation of callus after fracture may originate from the most varying zones or tissue elements. These are the bone marrow or the endosteum, the bone tissue itself, the periosteum, and finally the soft tissue immediately adjacent to the fracture. Within the limits of this study we are not able to discuss the whole problem of fracture healing, as opinions about the origin of callus still differ widely. There is no doubt that each of the tissue elements mentioned above is capable of forming callus probably with the exception of the bone tissue itself. Most likely all of them contribute to fracture healing. At any rate it is not possible to study the individual effect of the various tissues separately and we should like to assume that in the one case the endosteal, in the other case the periosteal callus predominates constantly or temporarily, or that in single cases the major part of the callus is formed by way of metaplasia of soft tissue parts directly adjoining to the fracture. The extent to which the investigative work in the field of callus formation is still in flow is revealed by the last studies of OBERDALHOF (85). They gave a survey on the whole problem of the physiology of fracture healing. VON ERTL (86) also gave a historical survey of the problem.

OBERDALHOF has introduced a new component into the process of callus formation by attributing to a new osteoplastic factor K the task of forming the new bone from an extracellular osseous base substance. The effect of the K-factor is assumed as being humoral, hormonal, or enzymic, and its essential rôle is to effect the binding of the calcium salts to the mesenchymal basic substance or to the mesenchymal germinative tissue. During this process metaplastic processes in the soft tissues surrounding the fracture and on the cells of newly formed vascular germs allegedly play the principal part. This theory is only mentioned here, because it is the result of the latest studies about the topic of bone regeneration and of fracture healing. We do not agree with OBERDALHOF in all points.

Today the more practical question is acute whether the medullary nail enhances or inhibits callus formation and on which components of this complex the medullary nail exerts its effect.

One may assume, and that has become the general opinion, that as a result of medullary nailing fracture healing progresses more slowly than with the methods of fracture treatment employed so far. In practice this delay is of no particular importance, as the patients regain their capacity to work at an early time, while the nail is still in place. To this one must add the excellent adjustment of the fragments usually effected by the medullary nail, so that the average anatomical results are more satisfactory than those obtained with the conservative method. The satisfactory anatomic adjustment of the fragments has also the result, that the function is better in the long run and the advantages of medullary nailing with regard to the elimination of the stiffening of joints are revealed by the restoration of the capacity of the patient to work at an earlier time than after treatment with the methods employed so far. Therefore, in the course of time those individuals who have to pay for the treatment, such as for instance the professional insurance companies will also arrive at the conviction that a prolonged duration of treatment can be taken into the bargain if there is a favorable outlook as to permanent healing. This refers to the pensions to be paid to the patient later, and in the final analysis more money will

be saved by medullary nailing, even though it requires more time than the conservative treatment.

The problem of callus formation was treated in a number of publications, but no agreement could be reached. KUENTSCHER (87) himself at first established the thesis that the medullary nail intercepts or absorbs all thrusting, shearing, and bending forces noxious for the formation of callus, and that the fracture is subjected to a pure pressure tension which allegedly is the most desirable mechanical and biologic condition for the formation of callus. He also discussed the chemical stimulation of the ossification by the metalions. A phenomenon observed by all surgeons is the sometimes extremely extensive callus formation which frequently assumes the shape of a so-called ball callus (Illustration 83). In the early stages of medullary nailing it was interpreted as due to the outflow of bone marrow at the fracture site subsequent to the introduction of the nail, until BOEHLER (88) was able to give the more satisfactory explanation that here we have to deal with a stimulated callus which always is formed when the fracture is not completely immobilized so that minute waddling movements occurred. These very small movements of the nail are also revealed by the roentgenograms, as in such cases an unmistakable zone of transparency is formed around the nail tip (Illustration 84). Despite this explanation HAEBLER (89) still maintains the thesis of a myelogenic formation of callus. Nobody will ever deny that the bone marrow is capable of forming bone, as on roentgenograms one frequently observes the development of a narrow osseous zone around the medullary nail within the medullary cavity, which even after the removal of the medullary nail is preserved for a longer period and which was designated as the nail groove (Illustration 85). Recently ROTTER (90) studied the histology of the endosteal formation of bone.

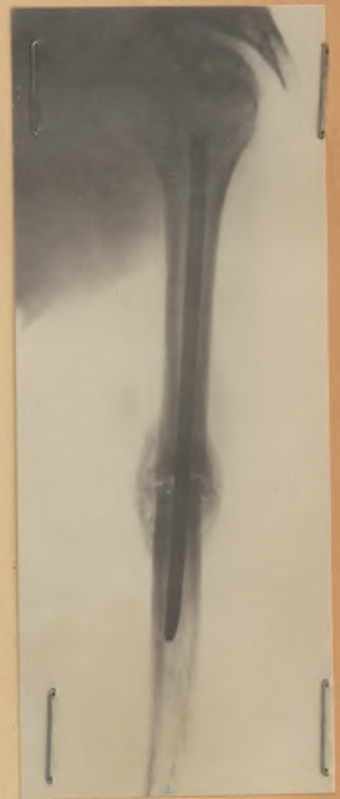

Illustration 83
Ball callus.

A phenomenon frequently to be observed is the so-called callus cap (Illustration 86), which is found around the nail head projecting from the bone. We only observed it on the femur. The thesis of HAEBLER and of other authors according to which the callus cap represents an ossification formed by escaping bone marrow does not seem clearly proven to us, and it certainly is not permissible to make use of the callus cap as an argument for the explanation of the ball callus as a medullary callus. Bone may be formed in absence of bone marrow as one knows from the metaplastic formation of bone in operation scars or on the pulmonary apex or in sclerotic arteries, and it is well known that metaplastic bone marrow is sometimes found on such metaplastic bone trabeculae.

Let us mention briefly the further observation of callus formed by the effect of the medullary nail far from the fracture site. These are cases of periosteal thickening



Illustration 84
Zone of transparency
around the nail tip
as a result of minutious
waddling movements.

above that spot of the corticalis under which the nail tip is located. We are under the impression that this callus zone is formed when the nail tip is about to penetrate through the corticalis, and that it may be considered as a strengthening of the menaced spot accomplished by nature for the preservation of the bone. This phenomenon is usually observed over nails which are too short and the tip of which is not firmly seated in the large medullary cavity or pressed against a circumscribed spot of the osseous wall by an unfavorable lever effect of the fragments (Illustration 87). But it also happens that this periosteal reaction fails to appear and that the tip of the nail penetrates the corticalis (Illustration 82). Attention was called to this fact when the migration of the medullary nail was discussed.

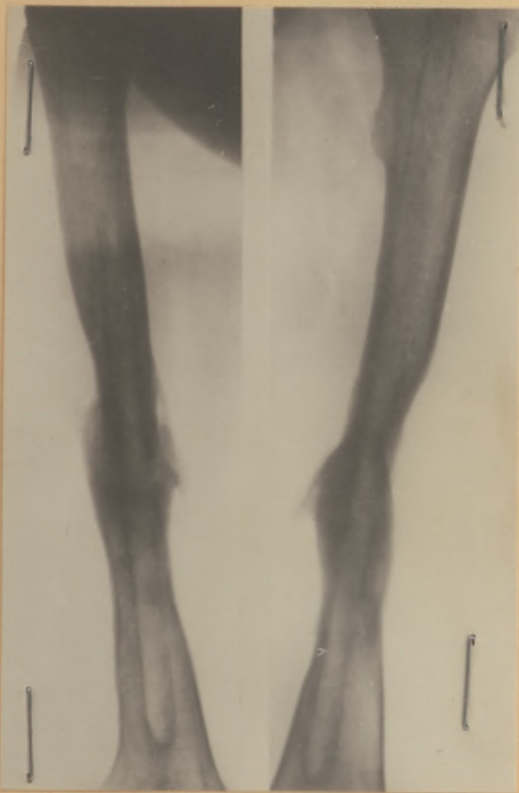

Illustration 85
Endosteal callus adjacent
to the medullary nail, the
so-called nail groove.

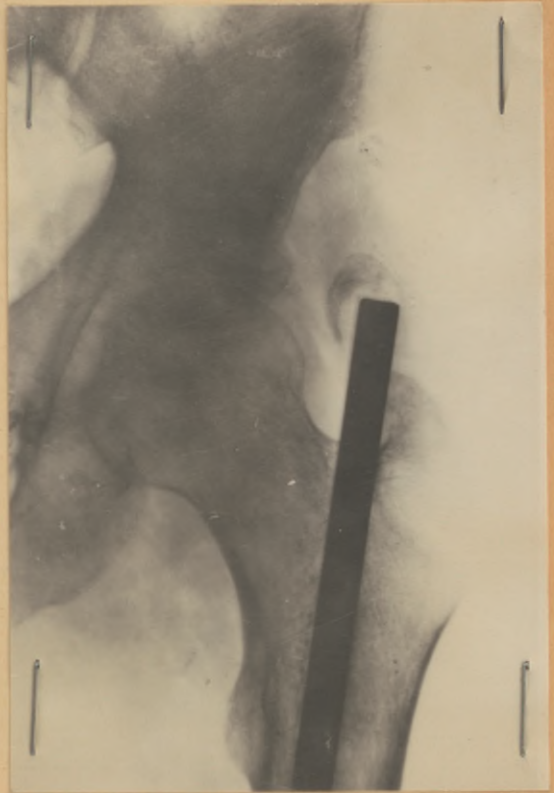
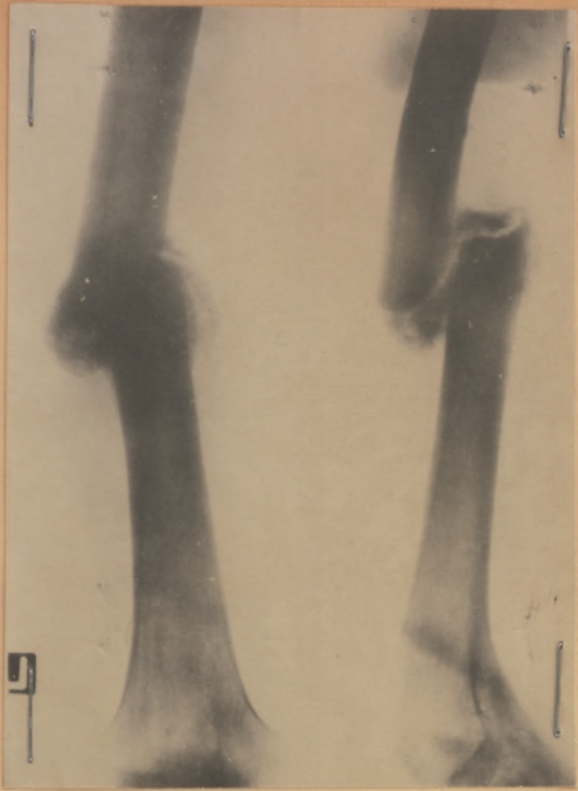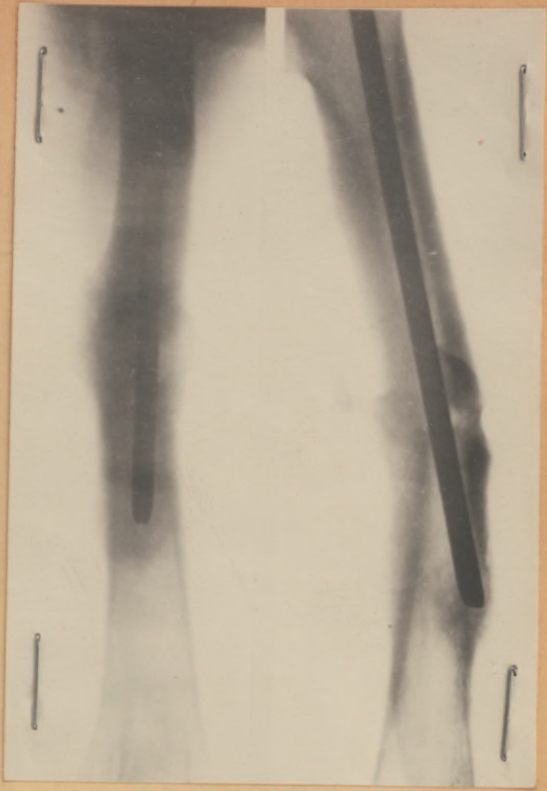


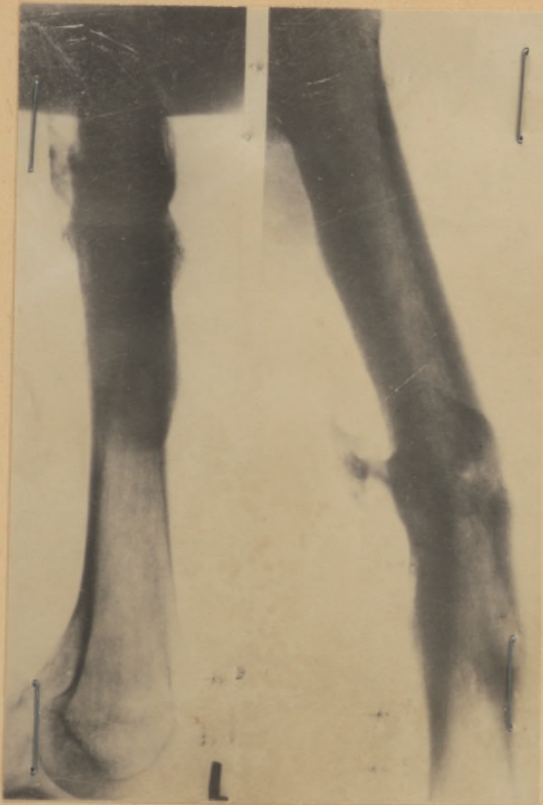Illustration 86
Callus cap.



a



b



c

Illustration 87

- a) Fracture of femur consolidated in an unfavorable position.
- b) Condition after osteotomy, readjustment and medullary nailing. The medullary nail is too short. Note the periosteal formation of bone over the nail tip.
- c) Fracture is healed and medullary nail removed.

KUENTSCHER points out that the influence of the medullary nail upon the bone and upon the bone marrow can by no means be compared with the damages observed after the bolting of shaft fractures by means of ivory bolts and other material, such as for instance bone parts. The bolts fill the medullary cavity, they squach the endosteum, and the growth of vessels from within towards the compacta and towards the callus is suppressed by the presence of these foreign bodies. Due to its V-shape the medullary nail comes into close contact with the bone at three points only, and in its groove the physiological metabolism of the bone marrow can continue. This was also revealed by the animal experiments of KUENTSCHER.

As to the problem of callus formation one may conclude that experience showed neither an enhancing nor a directly inhibiting effect of the medullary nail (SCHNEIDER (91)).

REACTION OF BONE MARROW TO MEDULLARY NAILING.

In addition to the temporary mechanical damage caused by the medullary nail the bone marrow suffers several alterations which have to be discussed here once more, as they are of practical significance. In the summarizing literature they were described by BOEHLER, HAEBLER, KUENTSCHER and MAATZ. The investigations of the marrow itself show results conforming with the alterations observable in the peripheral blood by means of the blood count. In the case of children one regularly finds an eosinophilia (KUENTSCHER (92)) and the same was observed with our juvenile patients. In adults eosinophilia was discussed at first in a single case (RAISCH (93)) and systematic investigations in this direction were accomplished by SLANY (94). The eosinophilia of children and of adults was confirmed by SLANY's studies. In addition he found a considerably increased release of reticulocytes which did not disappear before the removal of the nail. With juvenile persons juvenile leucocytes are released to the blood stream (myelocytes and juvenile-forms). With a good number of patients anemia ensues after medullary nailing which is associated with a drop of the number of erythrocytes and of the hemoglobin values. This phenomenon disappears after the removal of the medullary nail.

No satisfactory explanation was found in literature for the alterations of the blood count. One could, however, imagine that the destruction of the bone marrow in the nailed bone provokes a condition of medullary aplasia. But it is certain that the eosinophilia of the peripheral blood does not originate from this single bone alone or from its bone marrow. Most probably the bone marrow reacts to the mechanical noxa composed of the presence of the foreign body and the effect of the metal as a whole system as it is known from the blood diseases and we should like to interpret its reaction in the form of eosinophilia and a simultaneous reaction of the spleen as a hyperergic reaction.

At any rate the findings in the blood count show that in every case of medullary nailing an accurate and constant check of the blood count must be made. If the above described alterations assume threatening proportions, an incident sometimes occurring with children, the medullary nail must be removed without regard to the fracture which in this case may be immobilized by a plaster cast.

As regards the regeneration of the bone marrow after scraping out in case of pernicious anemia, see the study of WALTERHÖFLER and SCHRAMM (95).

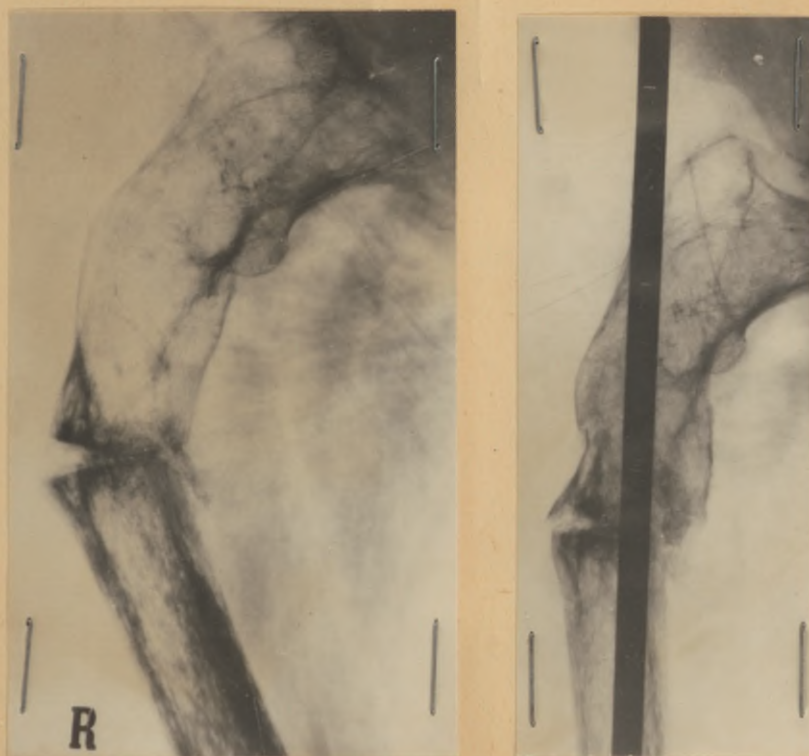
The early resumption of exercises when the bone was immobilized by medullary nailing, its unrestricted vascularization, the short period during which immobilizing bandages must be worn, are factors counteracting bone atrophy, which is well known as resulting from the treatment with plaster casts. We particularly observed no case of an incontestable Sudeck atrophy after an uncomplicated treatment with the medullary nail. Here we agree with FISCHER and MAATZ (96) who stated that "only those patients showed a Sudeck atrophy whose injury was complicated by additional fractures of the same limb, by infection, or by prolonged additional fixation. In no case was it observed after uncomplicated Kuentscher nailing. There were only a few cases in which the roentgenogram showed traces of a slight spotted transparency, but this did not permit the diagnosis of Sudeck atrophy. In no case did medullary nailing cause serious dystrophy or atrophy." HAEBLER (97) showed a picture with "a marked atrophy of the bones of the wrist joint" observed 8 weeks after the medullary nailing of the ulna from the olecranon, while there was a simultaneous fracture of the forearm shaft reduced to a satisfactory position. A plastercast had been applied for 4 weeks. "The very sensitive patient had hardly moved the elbow joint, as she felt the medullary nail below the skin on the elbow.

ADDITIONAL FIELDS OF MEDULLARY NAILING.

In the preceding chapters we showed the overwhelming value of medullary nailing for the treatment of simple fractures and the possibilities of application in the case of compound fractures and finally of gunshot fractures. Another field of medullary nailing are the so-called pathologic fractures, usually spontaneous fractures developing as a result of pathologic processes in the bone. First of all mention must be made of the ostitis fibrosa cystica localisata. This disease is located predominantly in the upper third of the femur, and the diagnosis can frequently be made before a spontaneous fracture occurs, if early discomfort is felt. So far treatment consisted in the opening and scraping out of the honeycombed osseous cysts and of a subsequent immobilization with or without the insertion of bone grafts. The result of treatment is not always satisfactory in the long run, particularly if the cavities become obstructed again and the formation of cysts recurs. If ostitis fibrosa is treated with the medullary nail which may be performed percutaneously, no operative exposure and scraping out is required even if a spontaneous fracture had occurred. The medullary nail itself accomplishes the opening of the cyst thus providing the escape of its content and in addition it prevents the premature obstruction of the cyst so that it can be filled with osseous structure and furthermore it serves the purpose of fixing and securing the bone liable to fracture, or of immobilizing the spontaneous fracture in the same way as with the fracture of traumatic origin. This constitutes a considerable amplification of the treatment of this disease, and simultaneously it simplifies its operation and reduces the period of incapacity of the extremity involved. BOEHLER (98) observed such a case in

which a fracture occurred during the introduction of the medullary nail in the range of the femur cyst. Nevertheless the 32 years old patient could rise after 5 weeks, and after 6 weeks she could be dismissed from hospital. After 2 months the fracture was healed and consolidated and the patient was able to walk without any discomfort all day long. After 8 months the cyst was completely replaced by bone structure and the nail was removed. We treated 2 patients ourselves with medullary nailing, who suffered from spontaneous fractures due to *ostitis fibrosa*.

1. Medical history: 49 years old female patient who in 1926 suffered a fracture of the right femur as a result of *ostitis fibrosa cystica*. At that time a bone splinter was grafted on. 17 years later the patient fell and a fracture developed at the same site. In another hospital the patient was treated for 7 months with plaster and extension bandages, but no healing of the fracture was achieved. When she was admitted to our hospital the hip and the knee joint were almost completely stiffened. Because of the stiffening of the hip joint and to confirm the diagnosis we decided to expose the fracture and to perform retrograde medullary nailing from the site of the fracture. After 10 weeks the patient was able to walk without any aid. Several months later the medullary nail moved upwards (Illustration 88) and it pushed against the pelvic bone so that it had to be hammered in deeper. After $1\frac{1}{2}$ years the medullary nail was removed in another hospital. We were informed by the patient that she was free from discomfort $2\frac{1}{2}$ years after the operation and that she is able to do all work behind the counter of her own shop.



a

b

Illustration 88

- a) Pathologic fracture in the case of *ostitis fibrosa* of femur. Condition after bone graft applied 17 years ago.
- b) Condition after medullary nailing. Nail has moved upwards.

2. Medical history: A 29 year old man was under treatment as long as 4 years because of a tumor of the femur and he was admitted to our clinic with the diagnosis of "pathologic fracture". The disease had set in with a swelling at the lateral aspect of the left thigh and with violent pains confining him to bed. The tumor was irradiated for several months. The symptoms were slightly improved, but finally spontaneous perforation occurred at several spots of the femur and a brownish fluid was evacuated. In another hospital a large tumor was removed. The histological examination yielded no clear results. Tuberculosis could be excluded. It seemed to be very likely that it was a so-called "brown tumor" of a benign character. Almost 2 years later when the patient was able to walk fairly well, he fell in the street and suffered a fracture on a level with the former site of the tumor. In this condition he was admitted to our hospital. In spite of the serous fistular secretion still present we performed percutaneous medullary nailing on a level with the fracture. As early as 4 weeks after this operation the patient could be dismissed. Continuous examinations showed a slowly progressing formation of callus. 2½ years after its introduction the nail was removed. At that time the fracture was entirely consolidated and the ability of the patient to walk was hardly impaired. Later on refracture ensued. The second medullary nailing was made in another hospital. Here a fracture of the femur neck developed simultaneously, most likely as a result of the alteration of the bone structure caused by the pathologic process and the previous irradiation (Illustration 89).

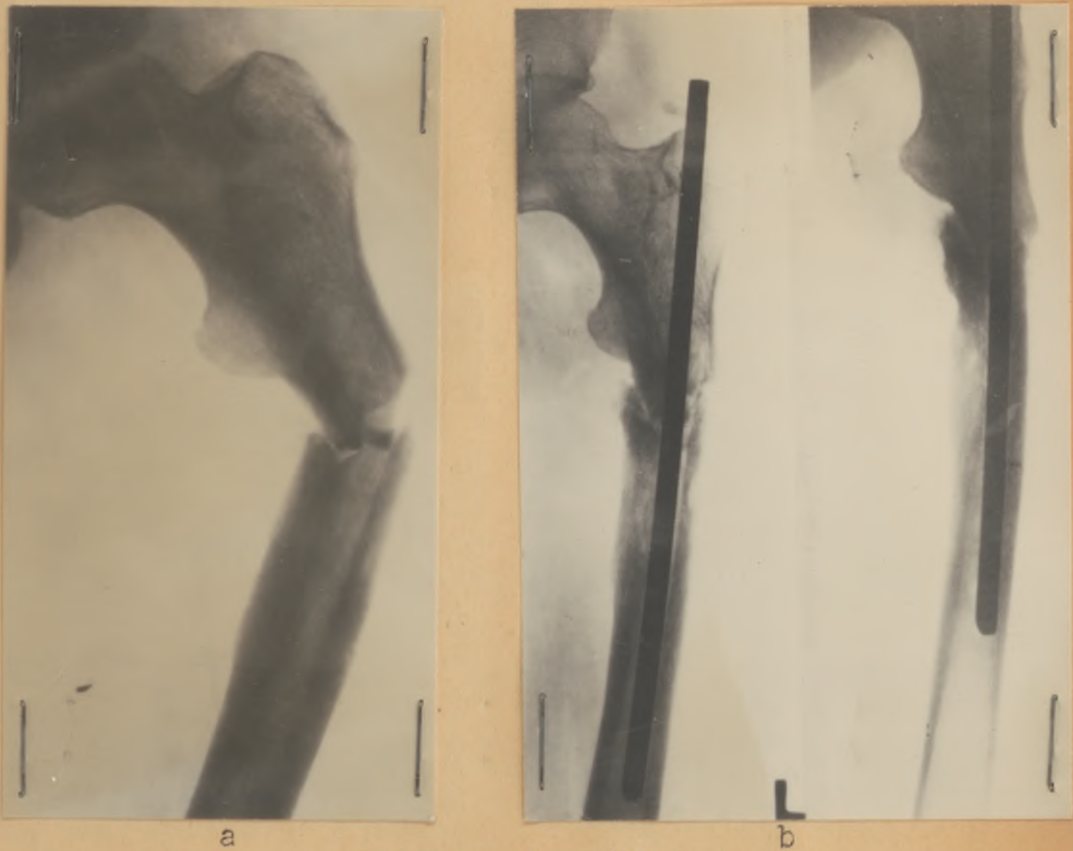
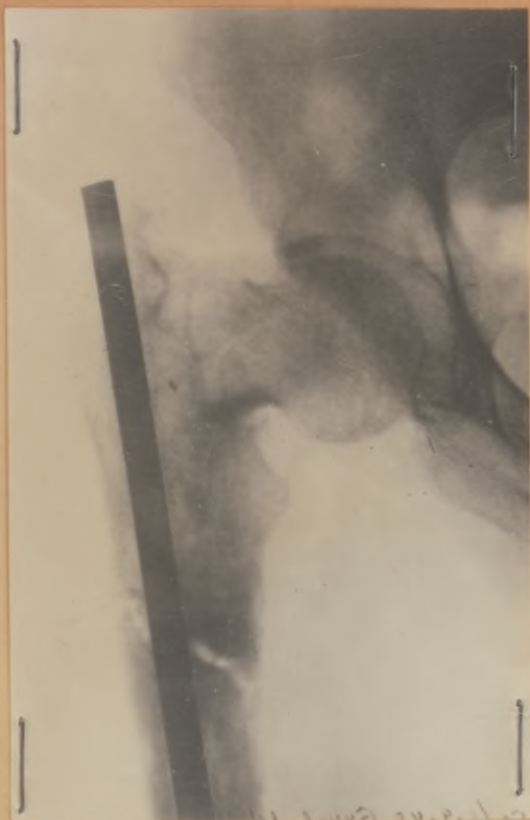
Illustration 89

- a) A.E., 29 years old, pathologic fracture (spontaneous fracture) of femur, most probably due to sarcoma (no definite histologic diagnosis available).
- b) Condition after medullary nailing (medullary nailing was performed under the assumed diagnosis of osteitis fibrosa).



c

Illustration 89 (cont'd)

- c) Condition 4 years after the spontaneous fracture of the femur. Now there is an additional fracture of the neck of the femur which most probably was caused by the second medullary nailing, after the first nail had been removed and a spontaneous refracture of the femur had occurred.

SCHUMANN (99) described the successful medullary nailing of a spiral fracture of the femur in a patient suffering from tabes dorsalis. The injured extremity could be subjected to weight-bearing 37 days after the operation. A firm bony consolidation ensued.

HAASE (100) performed medullary nailing in the case of a spontaneous fracture due to metastasis of a hypernephroma. He was able to make the interesting observation that shortly after medullary nailing the tumor spread in a distal direction, exclusively along the course of the medullary nail. The author explains this process with the spread of Tumor cells with the nail into the depth of the medullary cavity. If this opinion is right one may deduce from it that bacteria may be spread into the medullary cavity in the same way. The hazard of infection was discussed in the chapter dealing with the medullary nailing of compound fractures.

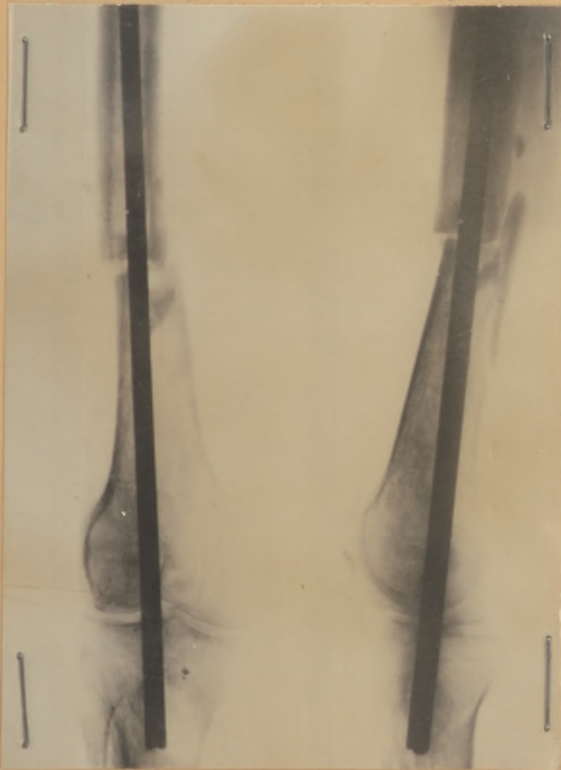From the medullary nailing of fractures caused by malignant tumors one generally cannot expect more than a mechanical stabilization of the fractured bone by means of the internal immobilization. But this is also justified if one bears in mind that it possibly spares the patient a prolonged confinement to bed with all its consequences of mental depression and general physical reduction, and that we are at least able to relieve him of the pains caused by the fracture by immobilizing the fragments. The rare occurrence of such cases is the reason why we dispose only of one relevant observation. It refers to a 16 year old boy who had suffered a spontaneous fracture in the area of a Ewing-sarcoma of the femur (Illustration 90). Even though we were not able to influence the progress of the malignant bone tumor, we nevertheless were successful in enabling the patient by medullary nailing to rise and to walk without discomfort. The subjective complaints and the nursing of the patient could be considerably facilitated by this operation.

Medullary nailing is also of advantage for the adjustment and fixation of the leg after knee-joint resection. In this case it is best to drive in the medullary nail from the middle of the tibia towards the proximal end up into the femur. No damage of the further course of healing due to the spread of pus germs into the medullary cavity was observed by us or by other authors (HONECKER (101)).

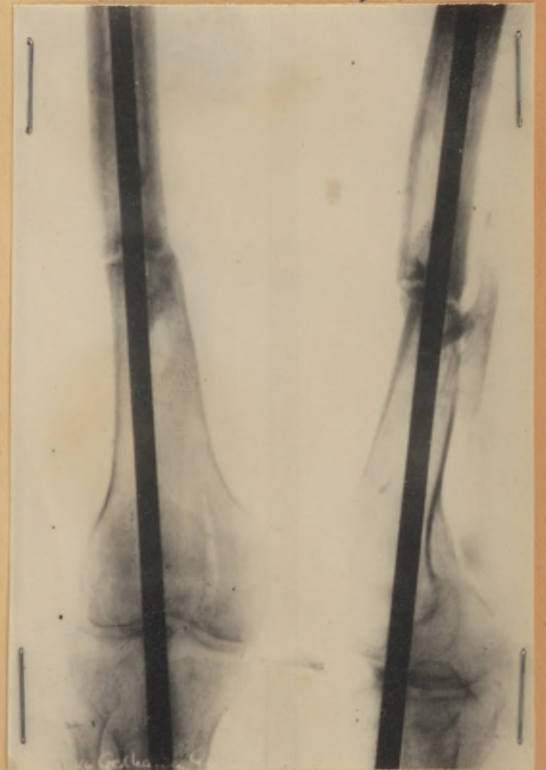

Illustration 90
F.Z., 16 years old, spontaneous fracture of left femur due to Ewing-sarcoma, treated with medullary nail.

This form of medullary nailing also permits the purposeful stiffening of joints destroyed by comminuted fractures whose restoration is beyond expectation. In such cases too the knee-joint is particularly suitable to be stiffened by means of the medullary nail, as the straight axis of the leg permits the use of straight femur nails (Illustration 91).

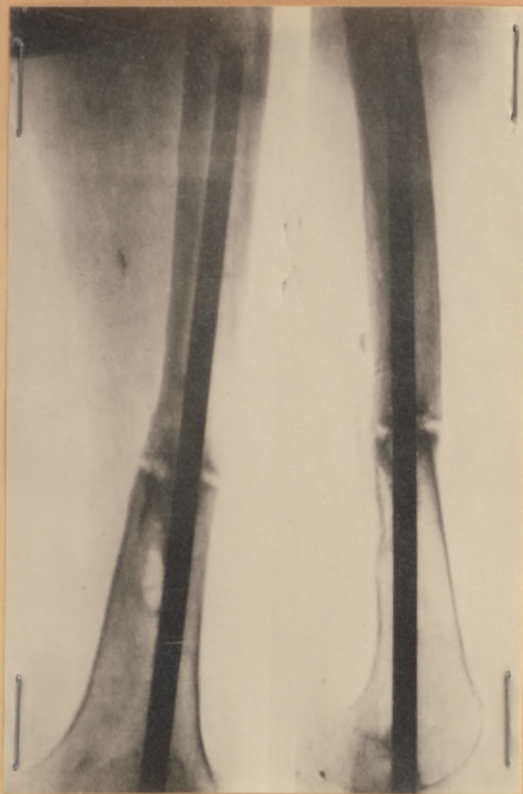


a



b

(Text see next page)



c

Illustration 91


- a) Pseudarthrosis of femur in the case of a stiffened knee-joint. Resection of pseudarthrosis and medullary nailing from the distal end through the stiffened knee-joint in upward direction.
- b) Beginning formation of callus.
- c) Condition 2 years after medullary nailing.


LITERATURE

- 1) HAEBLER, C.: The stable Osteosynthesis etc.,
I.F. Lehmann, Munich and Berlin 1944
- 2) BOEHLER, L.: Technique of Fracture Treatment etc.,
Maudrich, Wien 1944
- 3) KUENTSCHER, G. and MAATZ, R.: Technique of Medullary
Nailing, Thieme, Leipzig 1945
- 4) KUENTSCHER, G.: Zbl. Chir. 1942, 1837
- 5) GRIESSMANN, H. and SCHUETTENMEYER, W.: Chirurg 1947, 316
- 6) HAEBLER, C.: Zbl. Chir. 1943, 374
- 7) KUENTSCHER, G.: Zbl. Chir. 1942, 1837
- 8) MAATZ, R and REICH, H.: Beitr. Klin. Chir. 174, 358 (1943)
- 9) FISCHER, A.W. and MAATZ, R.: Arch.Klin.Chir. 203, 531(1942)
- 10) FEHR, A.: Beitr. Klin.Chir. 174, 25 (1942)
- 11) LARSEN quoted after MAATZ: Zbl. Chir. 1943, 383
- 12) KUENTSCHER, G. and MAATZ, R.: Technique of Medullary Nailing.
- 13) EHRLICH quoted after HAEBLER l.c.
- 14) HAEBLER, C.: The Stable Osteosynthesis etc. p. 153
- 15) HAEBLER, C.: Zbl. Chir. 1943, 734
- 16) BOEHLER, L.: l.c.p. 146-147, III. 391-398
- 17) HAEBLER, C.: l.c.p. 189 and Chir. 1943, 278
- 18) KUENTSCHER, G.: Zbl. Chir. 1940, 1145
- 19) BOEHLER, L.: l.c. vol. 3, p. 21 ss.
- 20) FISCHER, A.W. and MAATZ, R.: Arch.Klin.Chir. 203, 531 (1942)
- 21) BOEHLER, L.: Zbl. Chir. 1942, 1294
- 22) EHALT, W.: Zbl. Chir. 1942, 1296
- 23) KUENTSCHER, G. and MAATZ, R.: l.c.p. 25
- 24) FISCHER, A.W. and MAATZ, R.: Arch.Klin.Chir. 203, 531(1942)
- 25) LINSMAYER, H.: Chirurg 1943, 48
- 26) WITTMOSER, R.: Chirurg 1943, 52
- 27) BOEHLER, L.: Chirurg 1943, 50
- 28) In addition to the Kiel instruments special extraction
instruments have been described by J. PFEIFFER (Zbl. Chir.
1943, 1659) and O.STOEHR (Zbl.Chir.1943, 754)
- 29) Von BRUECKE, H.: Zbl. Chir. 1943, 387
- 30) K.T. HERZOG: Zbl. Chir. 1943, 865 designed a special
U-shaped guide-rod whose exterior arm
currently indicates the position of its
interior arm introduced into the medullary
cavity.
- 31) MAATZ, R.: Zbl. Chir. 1943, 1641
- 32) KUENTSCHER, G. and MAATZ, R.: l.c.
- 33) MAATZ, R.: Zbl. Chir. 1943, 1641
- 34) OPITZ, W.: Chir. 1948, 142
- 35) SPRENGELL, H.: Zbl. Chir. 1942, 271
- 36) SPRENGELL, H.: Zbl. Chir. 1942, 911 and 271
- 37) STOTZ, W.: Zbl. Chir. 1944
- 38) BOEHLER, L.: l.c.p. 106
- 39) Von ERTL, J.: Regeneration and its Use in Surgery,
Johann Ambrosius Barth, Leipzig 1939
- 40) SCANZONI: Zbl. Chir. 1943, 1000
- 41) DECKER, P.: Schweiz.Med.Wschr. 1947, 733
- 42) FISCHER, A.W. and REICH, H.: Zbl. Chir. 1943, 299
- 43) EHALT, W.: Zbl. Chir. 1942, 1849
- 44) BOEHLER, L.: l.c. p. 89
- 45) FISCHER A.W. and REICH, H.: Zbl. Chir. 1943, 299
- 46) EHALT, W.: Zbl. Chir. 1942, 1849
- 47) FISCHER, A.W., and MAATZ, R.: Arch.Klin.Chir. 203, 531(1942)
- 48) MAATZ, R. and REICH, H.: Beitrag Klin. Chir. 174, 358 (1943)
- 49) EHRLICH, W.: Zbl. Chir. 1941, 1378
- 50) HAEBLER, C.: l.c.
- 51) NUSSELT, H.: Chir. 1948 (not published as yet).
- 52) KUENTSCHER, G.: Zbl. Chir. 1943, 1700
- 53) HAEBLER, C.: l.c.p. 6
- 54) BOEHLER, L.: Technique of Fracture Treatment etc.,
p. 197 ss.- Chir. 1943, 8

- 55) RAISCH, O.: Zbl. Chir. 1943, 390
56) HEIM, H.: Chir. 1943, 387
57) FRANZ, C.: Textbook of War Surgery. Springer, Berlin 1936.
58) FISCHER, A.W. and MAATZ, R.: Arch.Klin.Chir. 203, 531(1942)
59) GRIESSMANN and SCHUETTE ~~MEYER~~, W.: Chir. 1947, 316
60) Von ERTL, J.: l.c.
61) VOGL, A.: Zbl. Chir. 1943, 1649
62) GULEKE, N.: Beitr.Klin.Chir. 98, 661 (1916)
63) GULEKE, N.: Chir. 1948, 89
64) GULEKE, N.: Literature see BRANDT, G.: Delayed Healing of Bone Fractures and Formation of Pseudarthroses. Thieme, Leipzig, 1937.
65) LEXER, E.: See BRANDT
66) BRANDT, G.: Delayed Healing of Bone fractures and Formation of Pseudarthroses. Thieme, Leipzig, 1937.
67) RAISCH, O.: Zbl. Chir. 1943, 390
68) GERHARDT, F.: Zbl. Chir. 1942, 1858
69) NUSSELT, H.: Chir. 1947, 429
70) HELLNER, H.: Chir. 1948, 241
71) NUSSELT, H.: Abstract in Chir. 1947, 429
72) PHEMISTER, D.: See p. 126 *)
73) CELLARIUS, Th.: Zbl. Chir. 1943, 745
74) ZENKER, R.: Chir. 1947, 339
75) BATEMAN, J.E.: Am.J. Surg. 1947, 423
76) BRUN, H.: Zbl. Chir. 1917, 969
77) LEZIUS, A.: Chir. 1947, 208
78) BAUER, K.H.: Zbl. Chir. 1943, 254
79) GULEKE, N.: Beitr.klin. Chir. 98, 661 (1916)
80) LEZIUS, A.: Chir. 1947, 162
81) TUERK, W.: Diss. Giessen 1948
82) Von LANZ, TH. and WACHSMUTH, W.: Practise of Anatomy I/3 p. 158, Springer, Berlin 1935.
83) GULEKE, N.: Chir. 1948, 89
84) STOTZ, W.: Zbl. Chir. 1942, 1418
85) OBERDALHOF, H.: Chir. 1946, 123; Arch.klin.Chir. and Dt.Z.Chir. 207 - 260, 109 (1947)-Chir. 1947, 428
86) Von ERTL, J.: l.c.
87) KUENTSCHER, G.: Klin.Wschr. 1940, 6 and 833.- Zbl.Chir. 1941, 857, - Zbl.Chir. 1942, 1837
88) BOEHLER, J.: Zbl. Chir. 1943, 1833
89) HAEBLER, C.: l.c.p. 21
90) ROTTER, W.: Klin.Wschr. 1948, 279
91) SCHNEIDER, E.: Zbl. Chir. 1942, 1854
92) KUENTSCHER, G.: Zbl. Chir. 1942, 1837
93) RAISCH, O.: Zbl. Chir. 1943, 390
94) SLANY: Arch. f. Orthop. und Unfallchir. 1944, 43
95) WALTERHOEFER and SCHRAMM: Arch. Klin.Chir. 119, 766(1922)
See also A.W. FISCHER: Arch.Klin.Chir. 200, 72 (1940)
96) FISCHER, A.W. and MAATZ.: Arch.klin.Chir. 203, 539 (1942)
97) HAEBLER, C.: l.c. p. 190
98) BOEHLER, L.: l.c. p. 238
99) SCHUMANN, G.: Zbl. Chir. 1942, 1861
100) HAASE, W.: Zbl. Chir. 1943, 1266
101) HONECKER, K.: Chir. 1947, 306

101) HONIGER, K.: Beitr. 1925, 300
 100) HASE, W.: Zbl. Anat. 1921, 1266
 99) SCHWAB, C.: Zbl. Anat. 1921, 1267
 98) BOHNER, L.: I. p. 218
 97) KRETSCHER, G.: I. p. 190
 96) FISCHER, A.W. and MATTEI: Arch. Ital. Anat. 1921, 1267 (1922)
 95) WALTER-BONNER and SCHWAB: Arch. Ital. Anat. 1921, 1267 (1922)
 94) STARY: Arch. Ital. Anat. 1921, 1267 (1922)
 93) RABON, O.: Zbl. Anat. 1921, 1267
 92) KRETSCHER, G.: Zbl. Anat. 1921, 1267
 91) SCHWAB, C.: Zbl. Anat. 1921, 1267
 90) BOHNER, W.: Zbl. Anat. 1921, 1267
 89) HENSE, C.: I. p. 21
 88) BOHNER, L.: I. p. 21
 87) KRETSCHER, G.: Zbl. Anat. 1921, 1267
 86) VAN DER WIT, J.: I. p. 21
 85) GARDINHOFF, H.: Zbl. Anat. 1921, 1267
 84) STOLT, W.: Zbl. Anat. 1921, 1267
 83) QUERE, N.: Zbl. Anat. 1921, 1267
 82) VAN KAMP, H. and WACHSUTH, W.: Zbl. Anat. 1921, 1267
 81) TRENK, F.: Zbl. Anat. 1921, 1267
 80) LEBENS, A.: Zbl. Anat. 1921, 1267
 79) BAUER, K.H.: Zbl. Anat. 1921, 1267
 78) LEBENS, A.: Zbl. Anat. 1921, 1267
 77) BROWN, H.: Zbl. Anat. 1921, 1267
 76) BROWN, H.: Zbl. Anat. 1921, 1267
 75) BROWN, H.: Zbl. Anat. 1921, 1267
 74) GILLIES, Th.: Zbl. Anat. 1921, 1267
 73) PHELISSON, H.: Zbl. Anat. 1921, 1267
 72) WESSELT, H.: Zbl. Anat. 1921, 1267
 71) WESSELT, H.: Zbl. Anat. 1921, 1267
 70) WESSELT, H.: Zbl. Anat. 1921, 1267
 69) WESSELT, H.: Zbl. Anat. 1921, 1267
 68) WESSELT, H.: Zbl. Anat. 1921, 1267
 67) WESSELT, H.: Zbl. Anat. 1921, 1267
 66) WESSELT, H.: Zbl. Anat. 1921, 1267
 65) WESSELT, H.: Zbl. Anat. 1921, 1267
 64) WESSELT, H.: Zbl. Anat. 1921, 1267
 63) WESSELT, H.: Zbl. Anat. 1921, 1267
 62) WESSELT, H.: Zbl. Anat. 1921, 1267
 61) WESSELT, H.: Zbl. Anat. 1921, 1267
 60) WESSELT, H.: Zbl. Anat. 1921, 1267
 59) WESSELT, H.: Zbl. Anat. 1921, 1267
 58) WESSELT, H.: Zbl. Anat. 1921, 1267
 57) WESSELT, H.: Zbl. Anat. 1921, 1267
 56) WESSELT, H.: Zbl. Anat. 1921, 1267
 55) WESSELT, H.: Zbl. Anat. 1921, 1267
 54) WESSELT, H.: Zbl. Anat. 1921, 1267
 53) WESSELT, H.: Zbl. Anat. 1921, 1267
 52) WESSELT, H.: Zbl. Anat. 1921, 1267
 51) WESSELT, H.: Zbl. Anat. 1921, 1267
 50) WESSELT, H.: Zbl. Anat. 1921, 1267
 49) WESSELT, H.: Zbl. Anat. 1921, 1267
 48) WESSELT, H.: Zbl. Anat. 1921, 1267
 47) WESSELT, H.: Zbl. Anat. 1921, 1267
 46) WESSELT, H.: Zbl. Anat. 1921, 1267
 45) WESSELT, H.: Zbl. Anat. 1921, 1267
 44) WESSELT, H.: Zbl. Anat. 1921, 1267
 43) WESSELT, H.: Zbl. Anat. 1921, 1267
 42) WESSELT, H.: Zbl. Anat. 1921, 1267
 41) WESSELT, H.: Zbl. Anat. 1921, 1267
 40) WESSELT, H.: Zbl. Anat. 1921, 1267
 39) WESSELT, H.: Zbl. Anat. 1921, 1267
 38) WESSELT, H.: Zbl. Anat. 1921, 1267
 37) WESSELT, H.: Zbl. Anat. 1921, 1267
 36) WESSELT, H.: Zbl. Anat. 1921, 1267
 35) WESSELT, H.: Zbl. Anat. 1921, 1267
 34) WESSELT, H.: Zbl. Anat. 1921, 1267
 33) WESSELT, H.: Zbl. Anat. 1921, 1267
 32) WESSELT, H.: Zbl. Anat. 1921, 1267
 31) WESSELT, H.: Zbl. Anat. 1921, 1267
 30) WESSELT, H.: Zbl. Anat. 1921, 1267
 29) WESSELT, H.: Zbl. Anat. 1921, 1267
 28) WESSELT, H.: Zbl. Anat. 1921, 1267
 27) WESSELT, H.: Zbl. Anat. 1921, 1267
 26) WESSELT, H.: Zbl. Anat. 1921, 1267
 25) WESSELT, H.: Zbl. Anat. 1921, 1267
 24) WESSELT, H.: Zbl. Anat. 1921, 1267
 23) WESSELT, H.: Zbl. Anat. 1921, 1267
 22) WESSELT, H.: Zbl. Anat. 1921, 1267
 21) WESSELT, H.: Zbl. Anat. 1921, 1267
 20) WESSELT, H.: Zbl. Anat. 1921, 1267
 19) WESSELT, H.: Zbl. Anat. 1921, 1267
 18) WESSELT, H.: Zbl. Anat. 1921, 1267
 17) WESSELT, H.: Zbl. Anat. 1921, 1267
 16) WESSELT, H.: Zbl. Anat. 1921, 1267
 15) WESSELT, H.: Zbl. Anat. 1921, 1267
 14) WESSELT, H.: Zbl. Anat. 1921, 1267
 13) WESSELT, H.: Zbl. Anat. 1921, 1267
 12) WESSELT, H.: Zbl. Anat. 1921, 1267
 11) WESSELT, H.: Zbl. Anat. 1921, 1267
 10) WESSELT, H.: Zbl. Anat. 1921, 1267
 9) WESSELT, H.: Zbl. Anat. 1921, 1267
 8) WESSELT, H.: Zbl. Anat. 1921, 1267
 7) WESSELT, H.: Zbl. Anat. 1921, 1267
 6) WESSELT, H.: Zbl. Anat. 1921, 1267
 5) WESSELT, H.: Zbl. Anat. 1921, 1267
 4) WESSELT, H.: Zbl. Anat. 1921, 1267
 3) WESSELT, H.: Zbl. Anat. 1921, 1267
 2) WESSELT, H.: Zbl. Anat. 1921, 1267
 1) WESSELT, H.: Zbl. Anat. 1921, 1267





NATIONAL LIBRARY OF MEDICINE



152

NLM 00072701 1