


Allen (H.)

On a case of human
Congenital malformation



Dr. J. S. Billings
with the author's regards

ON A CASE
OF
HUMAN CONGENITAL MALFORMATION
(**Perobrachia**),
BY HARRISON ALLEN, M.D.,
Prof. of Physiology University of Penn'a.

(*Proceedings American Philosophical Society, Vol. XXI, 1883, p. 413.*)





Dec. 21, 1883.]

413

[Allen.

On a Case of Human Congenital Malformation. By Harrison Allen, M.D.

(Read before the American Philosophical Society, December 21, 1883.)

I desire to place upon record the facts in the case of a man born with rudiments of the superior extremities. Similar cases, it is true, have been recorded, and in a sense, this history lacks the claim of a positive contribution to knowledge. But it is well to record each example of unusual conformation, when novel facts pertaining to the adult state, to habit and to acquired deformity, can be demonstrated.*

The case is one of a group denominated *Perobrachia* and is embraced in the following account :

John E. Casey, aged sixty-four years, one of a family of seven well-formed children of healthy parentage was examined Nov., 1883. The subject was four feet and seven inches in height. In the place of the left superior extremity a small pedunculated lobule one inch in length was suspended from the axilla a short distance behind the group of axillary hairs. This lobule retained a slender rod of bone which could easily be determined, and which doubtless was homologous with the bones of the normal left superior extremity.

The right superior extremity was a small unidigitate member, bent at the middle so as to resemble a letter L and when at rest so disposed to the trunk as to correspond in length to the side of the thorax.

The humerus was apparently dislocated upon the dorsum of the scapula on an outward extension of the glenoid cavity, and the bone was thus held in an exceptional relation to the scapula. The shaft of the humerus was bent at the distal third so as to present a convexity outward and yielded a short distance above the elbow to its lateral side, a small spine which while detected with ease, did not form an elevation of the skin.

The position of the olecranon and that of the elbow-joint could be readily determined. The remaining portion of the extremity represented elements in a single axis excepting at the terminal phalanx. Within this axis the bones of the forearm, of the metacarpus, and the two phalanges of one digit could be identified.

The bones of the left shoulder-girdle were small but complete.

Of the right elements it was found that those of the shoulder-girdle were unusually well developed. Both scapulas were elevated, and the clavicles obliquely placed, the sternal ends determining the lowest, and the eleva-

*A somewhat similar specimen to the one described is reported by Otto (*Monstru. Tab. xvi, figs. 7, 8, p. 138*). The condition was symmetrical, the radius absent, and the single finger was identified as the fifth, since the ulnar nerve passed to it. The subject was an unviable female fetus, of the seventh month. Förster (*Missbildungen*) refers to several cases; references imperfect and not reliable. See also Anger (*Nouveaux Elements de l'Anat. Chirurgicale*, 573, 574).

tion of the scapulas (through the agency of the trapezii, rhomboidei and elevators of the angle of the scapula) the highest levels.

FIG. 1.



FIG. 1—Front view of a case of Perobrachia, showing the rudiment of the left upper extremity, and the undigitable right upper extremity.

FIG. 2.

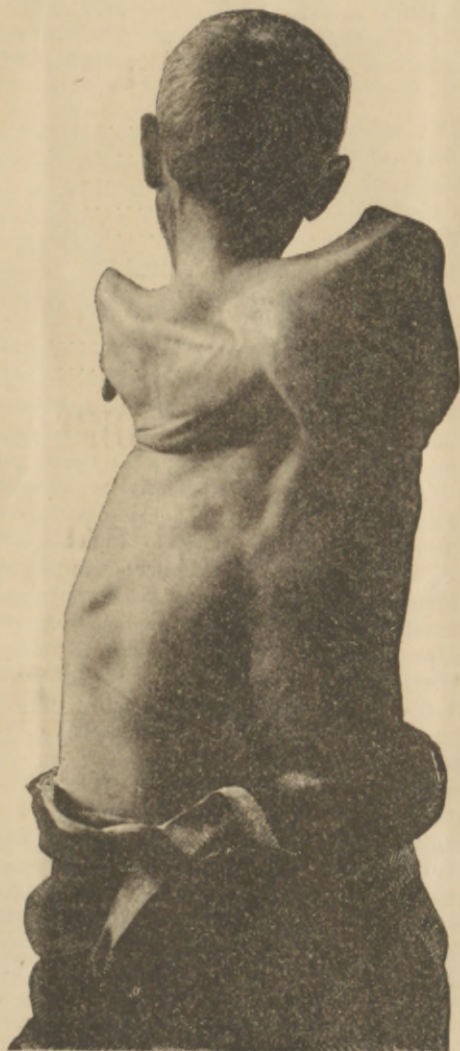


FIG. 2.—Back view of a case of Perobrachia, showing the rudiment of the left upper extremity, the disproportion between the scapulas, the deviation of the vertebral column, and the relaxation of the muscles of the buttock.

The *measurements* were as follows :

Left Side.

The length of the spine of scapula.....	5'' .3'''
Greatest length of scapula.....	5'' .6'''
Distance from angle to tip of acromion.....	6'' .6'''
Length of clavicle.....	3'' .6'''

Right Side.

The length of spine of scapula.....	5'' .6'''
Greatest length of scapula.....	5'' .6'''
Distance from angle to coracoid process.....	6'' .9'''
Length of clavicle.....	6'' .0'''
Length of humerus.....	10'' .0'''
Distance from proximal border of exostosis to the elbow.....	4'' .0'''
Distance from elbow-joint to wrist-joint.....	2'' .0'''
Length of first phalanx.....	1'' .6'''
Length of second phalanx.....	0'' .9'''

The *motions* of the left extremity were confined to upward traction of the scapula as already mentioned, and backward traction of the lobule, the latter apparently through the agency of a pannicular muscular sheet.

The motions of the right extremity embraced the powerful effects of the tractors of the scapula, and the flexors and extensors of the forearm. The shoulder-joint being ankylosed, the extrinsic muscle of the shoulder-girdle, the trapezius, the serratus magnus, the levator anguli scapula, and the serratus magnus, and possibly the sub-clavius, were mainly effective in moving the extremity. The pectoralis major was also powerful. Abduction of the arm (probably rhomboidal) was associated with marked median (*i. e.* vertebral) deviation of the scapula; adduction (pectoral) with equally marked lateral deviation. Abduction was limited, the arm not being carried out from the trunk beyond an angle of 45°. Adduction on the other hand was powerful and complete.

The motion of the elbow permitted all the portion of the limb placed distally to the joint to be moderately extended. At the end of extension the elbow was distinctly angulated. At the end of flexion the forearm and hand are doubled up to the median side of the humerus. The terminal phalanx when the limb was at rest was strongly adducted, and a re-entering angle was formed between the median border of the first and the second phalanx. When the limb was flexed this angle was directed upward and outward; but when the limb was extended it was directed outward. From this circumstance it may be said that the flexion and extension at the elbow-joint was accompanied with sub-rotation.

Together with the primal or congenital defects numerous acquired ones were present. The most conspicuous of these was a lateral deviation of the vertebral column to the right, the result probably, of the unantagonized traction of the muscles of the right side, and in part also to imperfect

ossification in the bones comprising the column. As a result of this deviation the scapula of the left side was displaced and the angle lodged *behind the upper border of the ilium*. It thus appeared to be wedged down in the pelvis. A second acquired defect was found in the muscles of the buttock and the back of the thigh. The gluteus maximus of each side was feeble, and in no position of the body became tense. The entire labor of holding the trunk erect was thrown upon the hamstrings which, particularly the biceps flexor, was on each side of enormous size.

Under the head of *habits*, the result of the defects described, may be included the manner by which the subject could attend to acts of the toilet and to the handling of tools, etc. Like most persons whose arms are either defective or absent, the toes and lips become highly functionalized, and the methods of their use are in this case no different from others recorded. Casey has supported himself, honorably, as a farm laborer and peddler; and has, for a period of years extending beyond the average longevity, preserved good health and character. For many years he was employed as a driver of oxen. The guiding staff was held by the powerful pectoral muscles between the arm and the chest. A nail can be driven with accuracy and force by placing the handle of the heavy hammer between the arm and the chest wall, holding the nail upright between the first and second toe of the left foot, and while standing erect on the foot of the opposite side, he flexes the left leg at the knee. In this position the body is supposed to be standing on the right leg, the left leg flexed and the left foot raised upon a bench or stool. The motion of striking the blow is secured by throwing the trunk suddenly forward from a position of backward traction or extension; the shoulder-muscle being occupied keeping the hammer in position between the arm and the trunk. The act of writing is accomplished by holding the pen between the flexed arm and the side of the head, the lips being used in guiding the pen. Other acts such as dressing, shaving, etc., are possible.

REMARKS.—The modern method of studying congenital defects, as formulated by Meckel and St. Hilaire, father and son, is based upon the assumption that every embryo exhibiting an aberrant disposition of parts is an example of perverted or arrested development. The school of St. Hilaire accepts the conclusions that such perversions and arrests are exhibitions of and reversions to the characteristics of lower animals.*

While these statements cannot be in all respects controverted, an error is prevalent as to the systematic value of aberrant structures. An exam-

* "These (specimens) compose organic entities perfectly characteristic, amenable to law but placed in another kind of regular arrangement. When monsters are thus rigorously determined, I propose to group them after the zoological method and to determine for them genera and species." (Etienne Geoffroy St. Hilaire, *Ann. Sc. Nat.* xiv, 1828, 408.)

"An animal exhibiting anomaly which is essentially the same in structure as a part normally developed in a lower form, may be said to be degraded, and thus to have taken on the characters of creatures lower in the scale than itself." (Isidore Geoffroy St. Hilaire, *Propositions*, etc., 61.)

ple in the form above described, of a solidungulate extremity would suggest to the evolutionist a comparison with the foot of the horse; the single unguis, the nearly straight though multi-articulate axis from the unguis to the elbow, the main lines of motion, are identical in the two instances. But it is equally like the wing of a bird, and an analogy might be instituted with that limb: the extreme degree of flexion possible between the two main segments, the presence of two bones in the forearm, are the same in both. Such a method of comparison is no more conclusive than the likeness of clouds to camels and to whales. We can say with Polonius, such things are very like, and yet be no nearer in the end to a conclusion than in the beginning. The real comparison and only comparison which is profitable to make is with the general history of the superior extremity studied as a distinct subject, no matter what special form of limb may be differentiated in various animals. The presence of the exostosis upon the humerus is in this way comparable to other spinous outgrowths such as are seen in long slender shafts (as in the ribs of fish and of birds), and in many examples of diseased and perverted action in the long bones of man.

While such strictures are applicable to the various regions of the body, they cannot be made to apply to the subdivisions of a given anatomical system. The variations in the muscular system of man, for example, are often precise instances of reversion to the normal arrangement as met with in lower forms. In this way the study of minute variations in the shape of a muscle, or in the distribution of a nerve or a blood vessel, is more valuable for the purpose of the student of evolution than is the investigation of monstrous deformations.

