

Moore (W^o O.)

HEMIANOPSIA OR HEMIANOPIA.

CLINICAL LECTURE DELIVERED AT THE NEW YORK POST-GRADUATE
MEDICAL SCHOOL.

BY WILLIAM OLIVER MOORE, M.D.,

Professor of Diseases of the Eye and Ear, New York Post-Graduate Medical School
and Hospital, etc.

[REPRINTED FROM INTERNATIONAL CLINICS, VOL. III., SECOND SERIES.]

824 - 37966



HEMIANOPSIA OR HEMIANOPIA.

CLINICAL LECTURE DELIVERED AT THE NEW YORK POST-GRADUATE
MEDICAL SCHOOL.

BY WILLIAM OLIVER MOORE, M.D.,

Professor of Diseases of the Eye and Ear, New York Post-Graduate Medical School
and Hospital, etc.

[REPRINTED FROM INTERNATIONAL CLINICS, VOL. III., SECOND SERIES.]



Ophthalmology.

HEMIANOPSIA OR HEMIANOPIA.

CLINICAL LECTURE DELIVERED AT THE NEW YORK POST-GRADUATE MEDICAL SCHOOL.

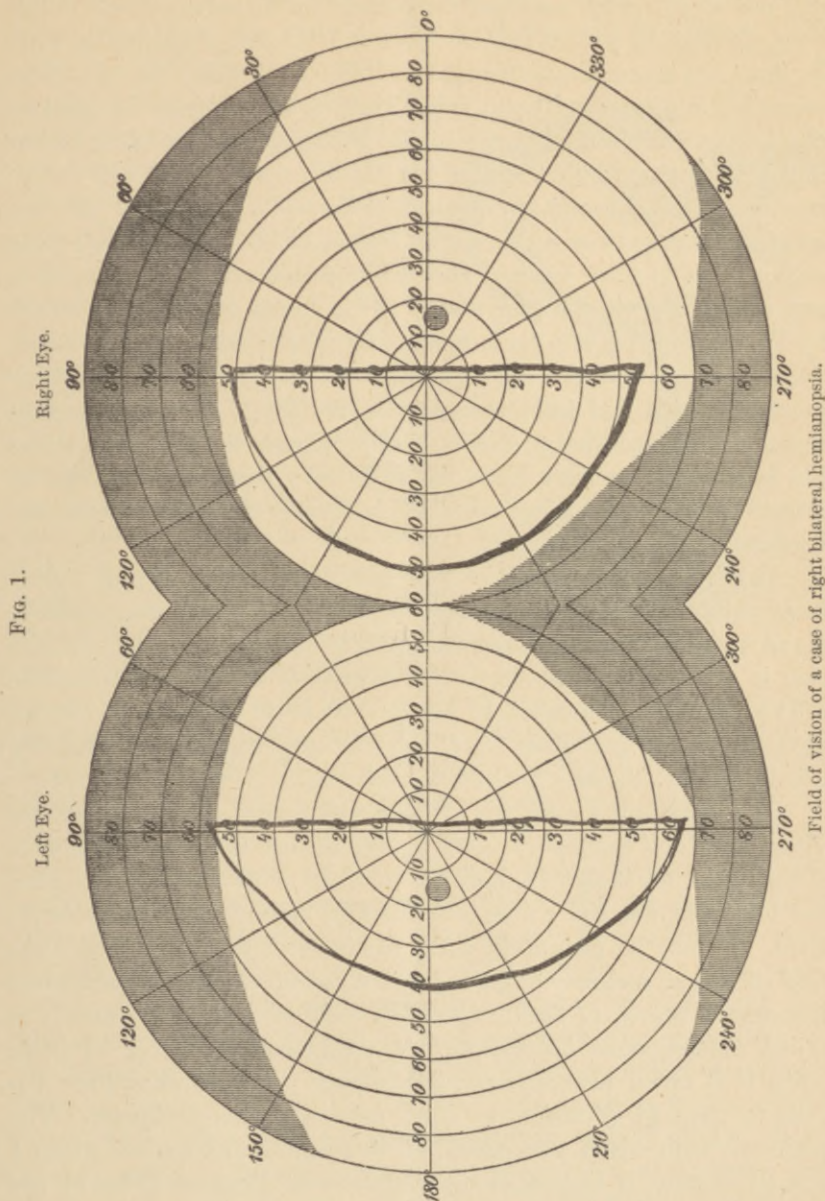
BY WILLIAM OLIVER MOORE, M.D.,

Professor of Diseases of the Eye and Ear, New York Post-Graduate Medical School and Hospital, etc.

GENTLEMEN,—The case before you illustrates one of those peculiar phases of anatomical distribution which is always interesting to the medical man, although not so amenable to treatment as many others. On this account, it is of practical value chiefly as being an aid to the localization of disease of the cerebral centre.

This patient, J. B. W., aged fifty-five years, was sent to me by Dr. Barton, of the Nose and Throat Department, for examination. He was first seen by me on March 3, 1892. On examination, vision is found to be $\frac{1}{20}$ in each eye, and not improved by glasses. He gives us the following history. On the 28th of December, 1891, he noticed a sudden loss of vision in the right eye while in a stooping position, but observed nothing wrong in the left. "The right eye was blind for a few moments," as he expresses it. This occurred during convalescence from *la grippe*. The patient, as you observe, is a man of rather feeble appearance, and looks older than he should at his age. He is unable to do any work, and has not followed his employment for the last three years. The eyes appear to be perfectly normal externally, the pupils respond to light, the cornea is clear, and only negative signs are present. The ophthalmoscope shows nothing, save perhaps a slightly dull and dirty look to the optic nerves, and a possible narrowing of the vessels, although each fundus has the same appearance, so that we have no means of comparison, and therefore the narrowing may be only apparent. The external symptoms and the ophthalmoscopic appearances are therefore negative. By the use of Emerson's perimeter, the visual field is found to be deficient, as you observe from the tests I have just

made in the temporal half of the right eye and the nasal half of the left; in other words, the patient has what is called hemianopsia or



hemianopia. I would have you understand, at this point, that the term hemianopia should be clearly distinguished from hemiopia,—hemiopia


meaning "half-sight." The patient, then, has "right hemianopsia bilateral." The accompanying field, as outlined on the chart which I now show you, gives an exact delineation in the part enclosed in ink lines of what the patient sees, the portion left blank representing what he does not see, or the hemianopsia. (See cut of field, Fig. 1.) The color-field is correct in all particulars; it is rarely affected. The patient also has a tumor in the left side of the abdominal region, which causes him considerable trouble, and he has had occasional attacks of unconsciousness, lasting from a few moments to one and a half hours. He has had these attacks twice a year for some time, or, to be more definite, five such seizures in three years. They are unaccompanied by convulsion, and are simply attacks of syncope. This tumor has been examined by Professor Abbe, who leans to the diagnosis of aneurism of one of the abdominal vessels. My own theory of the case, without wishing to conflict with that just given, is that the tumor in the abdominal cavity is not aneurismal, but is a solid tumor, for the reason that the hemianopsia present leads me to believe that he has a similar growth in the brain, lying upon the left optic tract and causing the hemianopsia.

As regards the treatment of this particular case before you, I shall have nothing to say, except that the cause of his condition must be discovered, and then the treatment belongs to general medicine. The case is of interest to us chiefly on account of its bearing upon the relation of the hemianopsia to the growth or to whatever is causing pressure on the left optic tract. Iodide of potassium is the remedy usually given internally for such a condition.

Hemianopsia is a condition of blindness limited to one-half of the visual field, and hemiopia is used incorrectly as a synonyme, as I have already said, for it signifies *vision* in one-half of the visual field, and as the blindness, not the vision, is the defect, hemianopsia is the correct term. It may be present in either the inner or the outer half of the field of vision, and may affect one or both eyes. If both, it may affect like-named halves of both, as the left half of each eye, when it is called homonymous hemianopia, or unlike-named halves of both, when it is called heteronymous hemianopia. To determine these defects in the field of vision, we have recourse to the perimeter. The perimeter with which you should all be familiar, and the one which I usually employ, is known as the perimeter of Emerson (Fig. 2), one of our colleagues. The instrument consists of a standard, bearing an arc of a circle which can be rotated, and upon which degrees are marked. Two slides are also placed on this arc, and there is a hole in the central

portion of the arc. A chin-rest is also provided. The patient is directed to close one eye, and to fix the other upon the opening in the arc of the circle. The arc is first placed vertically, and great care must be taken that the patient looks steadily upon the point of fixation. The slides are then gradually made to approach the centre, and the point where they are first seen is carefully noted by the observer. These charts accompany the instrument and enable the observer readily to make a correct copy of the field. Having found the vertical visual field, the arc is placed horizontally, and the same process gone through with, and so with any desired meridian. You will notice in this case that the sharply-defined hemianopia in each eye does not make itself evident until the slide is brought to the centre line. I can recommend this perimeter to you for its compactness, durability, and comparative cheapness. Many other perimeters have

FIG. 2.



Perimeter of Emerson.

been made, and are to be found in the offices of distinguished ophthalmologists, usually behind the office sofa, because they are so cumbersome that they have been thrown aside as practically useless. Before the invention of Emerson's perimeter, many made use of a simple blackboard in testing the visual field. The unequal size of the two portions of each visual field is so marked that in homonymous hemianopsia the patient usually ascribes the blindness to the eye having the larger portion of the field absent, and a careful examination is necessary to establish the existence of the bilateral affection.

As the lens in the eye reverses the image of an object seen upon the retina, each half of the visual field corresponds to the opposite half of the retinal expansion. Hemianopsia, therefore, indicates a suspension of function in the half of the retina *opposite* to the defective visual field. Such a functional derangement of half of the retina is made possible by the origin, course, and distribution of the nerve-fibres in the optic nerves (Fig. 3). Going from behind forward, and starting at the left occipital lobe, we find located here the cuneus and subadjacent gyri, constituting the cortical visual zone in man. From here

certain fibres pass forward into the primary optic centres, including the corpora quadrigemina, the corpora genicularum, and the thalamus opticus, and from these latter arise what are known as the right and left optic tracts. They pass forward until they reach what is called the

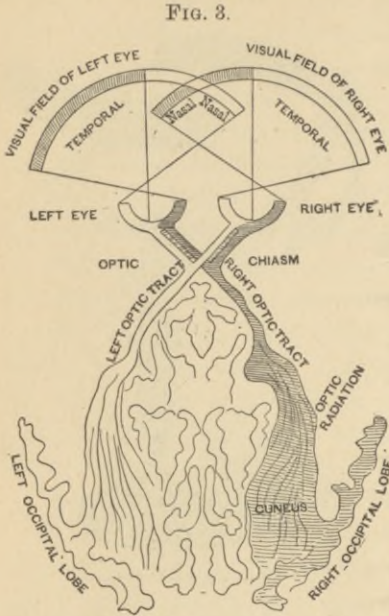


Diagram of the origin, course, and distribution of the nerve-fibres of the optic nerve.

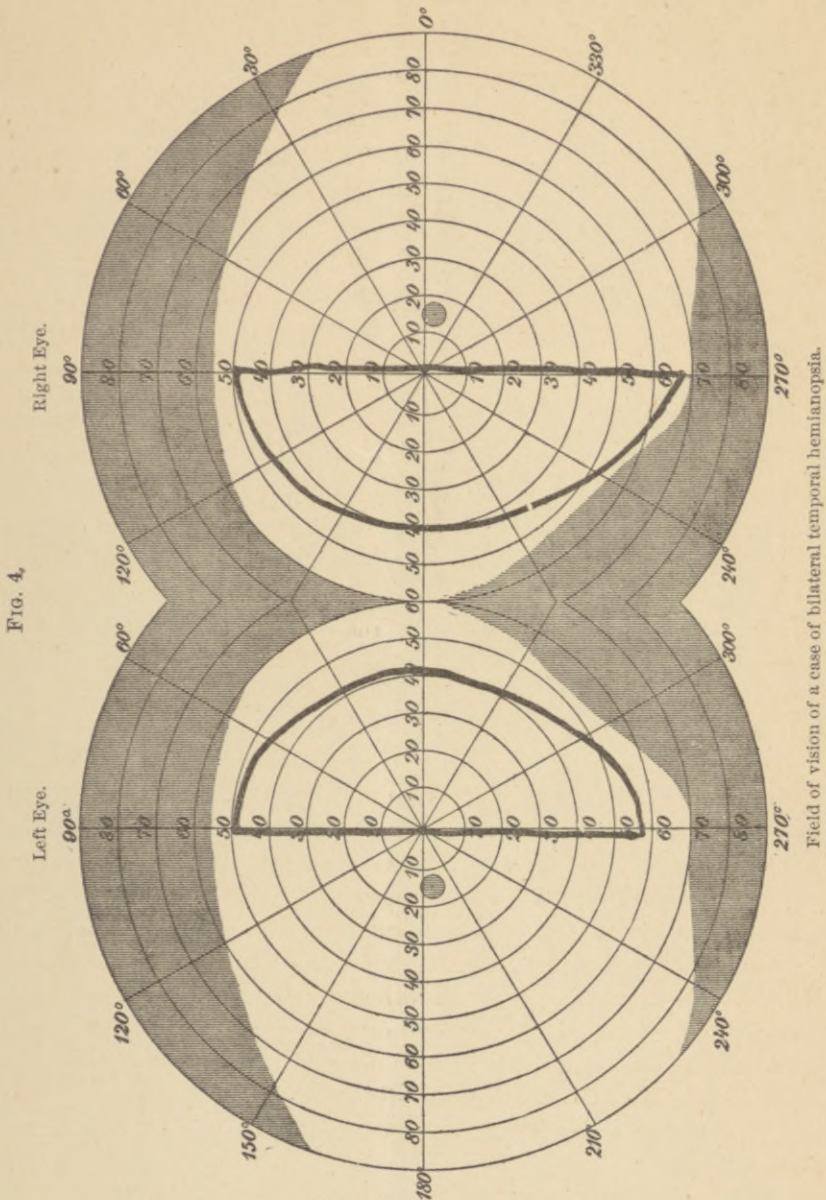
crossing, or commissure, or chiasm, and, in a plain, practical way, we may say that the right optic tract goes to supply the right half of each eye, and the left optic tract goes to supply the left half of each eye. Each optic tract also sends certain fibres of its same side directly to the corresponding halves of its distribution. From this it will be seen that, in the case which we have before us this morning, pressure brought to bear upon the left optic tract would cause a lack of innervation of the left half of each retina, and therefore the condition of the visual field already described, or right hemianopsia.

So we may have monocular hemianopsia or both-sided. A lesion occurring in front of the chiasm or near its anterior border may press so that the nasal half of each retina may be involved in the derangement. This, however, is a more rare form of hemianopsia; but the cut, Fig. 4, illustrates such a case as seen by me on April 7, 1891. This latter is called bilateral temporal hemianopsia. Hemianopsia is a local symptom of brain-disease, which is of value in determining the lesion in connection with the other symptoms. It is not amiss, therefore, gentlemen, to urge the importance of investigating the visual fields in all cases of cerebral disease, especially if the ophthalmoscopic signs are negative. It is also well from time to time, where the field is found to be defective, to make examinations to see whether the fields increase or diminish.

The prognosis is relatively better in nasal and temporal than in homonymous hemianopsia.

The treatment will depend upon the indications furnished by the

general symptoms. Syphilis should be looked for, and, if found, of course treated in the usual way. If pain is present, relief can be



obtained by dry cups, ice-cloths, and the administration of antipyrine in doses of five or ten grains.

