


BRUSH (E.D.N.)

INDEX
MEDICUS.


Sarcoma of the Dura Mater.

REPORT OF A CASE, WITH ILLUSTRATIONS.



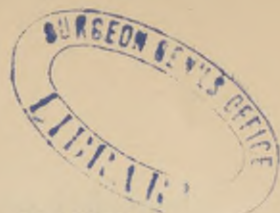
BY EDWARD N. BRUSH, M. D.,

Assistant Physician, New York State Lunatic Asylum.



From the *American Journal of Insanity* for January, 1880.





SARCOMA OF THE DURA MATER.

REPORT OF A CASE, WITH ILLUSTRATIONS.

BY EDWARD N. BRUSH, M. D.,

Assistant Physician, New York State Lunatic Asylum.

The following case is here reported, both on account of its clinical and pathological significance. In March, 1875, I was invited by my friend, Dr. E. C. W. O'Brien, of Buffalo, to see Mr. S——, who had sought advice concerning a tumor situated just anterior to the junction of the saggital and lambdoid sutures. The patient was a gentleman aged fifty-six, of clear, ruddy complexion, large frame and somewhat inclined to obesity. For some years he had been occupied as librarian in a large public library, but had recently assumed charge of some mining interests. The tumor was about the size of a small walnut. It was quite movable under the scalp, and pretty firm pressure and free handling gave rise to no indications of pain or uneasiness. Its growth had been slow and unattended by pain. From these facts, and from the presence of what was apparently a similar growth, though of several years' standing at the outer and upper margin of the left orbit, an ordinary sebaceous tumor of the scalp was diagnosed, and its removal suggested. Not being able at the time to leave his business, the patient preferred to postpone the operation until he could take a short vacation in the summer. I saw nothing more of him until February 13, 1876, when I was requested to assist in the removal of the tumor, which I then found had increased rapidly in size, and was therefore somewhat inconvenient. I was quite surprised on carefully examining the patient, at the size and shape which the

tumor had attained. It measured about four and one-half inches in one diameter, by about six in the other, and projected from the cranium some three inches at the most prominent point. The tumor was covered by the dense, shining scalp; was irregularly nodulated, and but slightly movable. The slight mobility was accounted for by the extreme tension of the scalp. The tumor was not painful on pressure, and the patient allowed pretty free manipulation without complaint; it did not pulsate, was soft and somewhat elastic. Some portions of the exterior were red and vascular, and attracted attention and comment.

After due consideration it was decided to attempt to remove the tumor, and to proceed as far as possible by enucleation, after the first incision. Anæsthesia, with ether, being induced, an incision was made from before backwards, over the most prominent part of the tumor. Attention was at once attracted to the unexpected thickness and great vascularity of the scalp. The tissues through which the knife passed were dense, and the vessels much enlarged. When exposed, the tumor showed what was apparently a containing sac or cyst-wall. I at once passed my finger into the wound, and commenced the process of enucleation. The growth was easily separated from the scalp, but I was surprised on approaching its base to find that my finger did not pass under it and come in contact with the cranium, but seemed to follow out the covering membrane, which apparently spread out in all directions upon the skull, and made it impossible to raise the tumor from its attachments. Thinking that I might possibly have mistaken a layer of fascia for the investing membrane of the tumor, this was ruptured with the nail, and the finger passed immediately down upon the cranium and thence under

the tumor. I at once recognized the fact that the finger had passed into the substance of the growth; that it was not sebaceous, and that beyond the membrane just ruptured, it had no retaining sac. Using the finger as a director the incision was enlarged in order that the tumor might be more easily examined, and the extent of its attachments determined. This done I passed my finger through the opening already made in the apparent covering of the tumor, down to its base. In doing so it came in contact with roughened and denuded bone, and in sweeping the finger under the growth to separate it from the skull I was startled by passing it into an opening in the cranium. A brief examination satisfied all present that the tumor either had its origin from, or passed into the cranial cavity, and it was decided to discontinue the attempt at removal. Before closing the incision, Prof. J. F. Miner was called in consultation. After a careful examination he expressed the opinion that the growth originated within the cranium, that it had eroded its way through the cranial walls, and that its removal was impossible. The incision was loosely drawn together, warm water dressings applied and the patient placed in bed.

On recovering from the ether the patient's mind was clear and active, pulse one hundred, respiration unimpeded, and he complained of but little pain. A portion of the incision healed by first intention, but the extensive separation of the attachments of the tumor, which had been made with the finger, destroyed its vitality, and in a few days, I was able to lift out a large portion of its most prominent part. After the removal of a few remaining shreds by suppurative process, a red protuberant mass, about the size of a walnut, was noticed at the bottom of the cavity; this mass bled easily and pulsated regularly. The pulse

never rose above one hundred and twenty, and frequently was as low as eighty. The discharge from the wound was profuse, and at times quite offensive. No chill or febrile stage was at any time observed. For four weeks the patient remained in this comfortable condition. Motion and sensation were at all times normal, and he continued to direct his business affairs as clearly as ever, and carefully arranged matters in view of his probable death.

On the morning of March 8th, Mr. S. noticed a loss of power and sensation of the right side. This condition gradually increased until it reached almost complete hemiplegia. The eyes were suffused, pupils contracted, face red, pulse rapid and bounding, temperature 103° . He complained of intense headache, was easily disturbed and restless when asleep, but at no time delirious, motion and sensation gradually returned, and on the thirteenth, were nearly normal. The headache was relieved by bromide of potassium, and the temperature controlled by quinia. From the tenth to the time of the death, the catheter had to be resorted to, to evacuate the bladder. On the twentieth, there was nearly complete *left* hemiplegia. At midnight on March 22d, I saw the patient, being hastily summoned in the absence of his attending physician, Dr. O'Brien. He was in a semi-comatose condition, respiration stertorous—twelve per minute; pulse, rapid and feeble. He could only be aroused with considerable effort, but would then make intelligent replies to questions. The coma increased steadily, and terminated in death in the forenoon of the twenty-third.

AUTOPSY.—The tumor projected from the upper back part of the head in the median line. Its base had a diameter of some six inches, and it projected about

three inches above the skull. In its center was a crater-like excavation, two inches in diameter, extending down to bone. Its edges were ragged, red and granulating, the sides grayish and sloughing. The weight of the tumor was estimated at one and one-half pounds. On section the pericranium was found to be elevated by the tumor. The scalp, though thickened, was separable from the morbid growth on all sides. On separating the tumor from the skull, the central portion of its base was found continuous with an inter cranial portion, through an irregular, ragged erosion in the cranial walls, with a diameter of from one and one-half to two inches. The eroding process had affected the border of the perforation for a circle of half to three-quarters of an inch breadth about it. This erosion is shown in Fig. one, representing the outer surface of the calvarium.

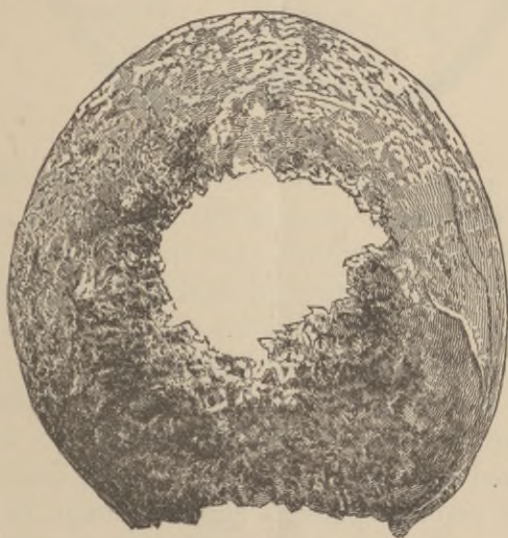

FIG. I.

Other portions of the bone covered by the tumor were more or less roughened. The inner surface of the calvarium showed the channels for meningeal vessels

deeper than common. The margin of the opening was rough and irregular, and its edges bevelled by the eroding process, as shown in Fig. two, showing that the tumor was originally wholly inter-cranial.

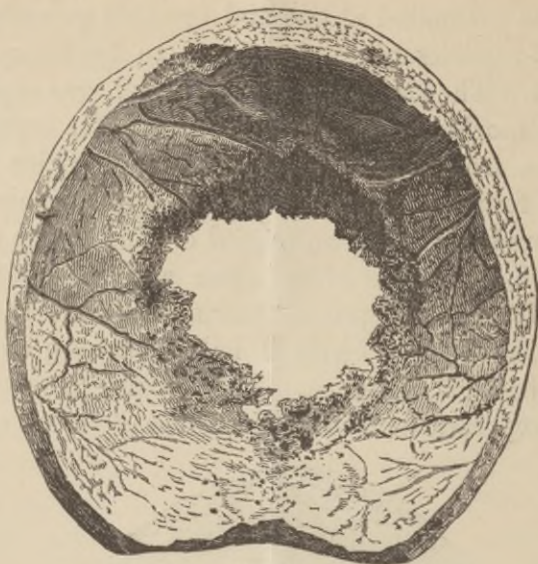

FIG. II.

The dura mater was thickened, non adherent; pia injected. The tumor arose in the falx cerebri, extending between the hemispheres for the depth of an inch and one-half. The portion internal to the skull weighed four ounces. The convolutions on either side of the median line were flattened by pressure, and marked depression was observed in the lobes of either hemisphere where the tumor had lain. They were, however, not involved in the new growth. On incision, an abscess, the size of a pigeon's egg, was found in the left posterior central convolutions. The brain was not subjected to microscopic examination. Sections of the tumor, placed under the microscope, showed it to be round celled sarcoma. The interesting features of this

case are the size and origin of the tumor, and the absence of all brain disturbance, until a short time prior to death, due probably to the early relief of pressure by perforation of the cranial vault. Growths of this character are recorded under various names, as fungus hæmatodes, fungus duræ matris, malignant tumor of the dura mater, etc. Gross mentions two operations for the removal of similar tumors, and Erichsen and Hamilton mention operative procedure as the last resort, advising enlargement of the cranial aperture, and careful dissection of the tumor from the dura mater. It hardly seems to me, that a full knowledge of the parts involved, would justify an attempt to remove a tumor of this character.

THE
AMERICAN JOURNAL OF INSANITY.

THE AMERICAN JOURNAL OF INSANITY is published quarterly, at the State Lunatic Asylum, Utica, N. Y. The first number of each volume is issued in July.

EDITOR,

JOHN P. GRAY, M. D., LL. D., *Medical Superintendent.*

ASSOCIATE EDITORS,

JUDSON B. ANDREWS, M. D.,

EDWARD N. BRUSH, M. D.,

SELWYN A. RUSSELL, M. D.,

} *Assistant Physicians.*

THEODORE DEECKE, *Special Pathologist.*

TERMS OF SUBSCRIPTION,

Five Dollars per Annum, in Advance.

EXCHANGES, BOOKS FOR REVIEW, and BUSINESS COMMUNICATIONS may be sent to the EDITOR, directed as follows: "JOURNAL OF INSANITY, STATE LUNATIC ASYLUM, UTICA, N. Y."

The JOURNAL is now in its thirty-sixth volume. It was established by the late Dr. Brigham, the first Superintendent of the New York State Lunatic Asylum, and after his death edited by Dr. T. Romeyn Beck, author of "Beck's Medical Jurisprudence;" and since 1854, by Dr. John P. Gray, and the Medical Staff of the Asylum. It is the oldest journal devoted especially to Insanity, its Treatment, Jurisprudence, &c., and is particularly valuable to the medical and legal professions, and to all interested in the subject of Insanity and Psychological Science.

