



NATIONAL LIBRARY OF MEDICINE



NLM 00053448 9





50.


THE ESSENTIALS

HISTOLOGY

GENERAL AND SPECIAL

FOR THE USE OF STUDENTS

HISTOLOGY



BY DR. J. H. H. ...
NEW YORK, ...

HISTOLOGY

THE ESSENTIALS
OF
HISTOLOGY,

DESCRIPTIVE AND PRACTICAL.


FOR THE USE OF STUDENTS.

BY

Sharpey-
E. A. SCHÄFER, LL.D., F.R.S.,

JODRELL PROFESSOR OF PHYSIOLOGY IN UNIVERSITY COLLEGE, LONDON;
EDITOR OF THE HISTOLOGICAL PORTION OF QUAIN'S "ANATOMY."

NEW (FIFTH) EDITION, REVISED AND ENLARGED
WITH 392 ILLUSTRATIONS.



LIBRARY
SURGEON GENERAL'S OFFICE

SEP. 12. 1898

163 385

LEA BROTHERS & CO.,
PHILADELPHIA AND NEW YORK.

1898.

Annex

QS

504

S532e

1898

DESCRIPTIVE AND PRACTICAL

FOR THE USE OF STUDENTS

BY

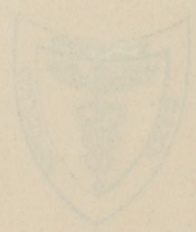E. A. SCHAYER, M.D., M.R.S.

ASSISTANT PROFESSOR OF PHYSIOLOGY IN THE UNIVERSITY OF PENNSYLVANIA

NEW EDITION, REVISED AND ENLARGED

WITH ONE HUNDRED ILLUSTRATIONS

LIBRARY
UNIVERSITY OF PENNSYLVANIA
PHILADELPHIA



LEA BROTHERS & CO.
PHILADELPHIA AND NEW YORK
1898

PREFACE.

THIS Book is written with the object of supplying the student with directions for the microscopical examination of the tissues. At the same time it is intended to serve as an Elementary Text-book of Histology, comprising all the essential facts of the science, but omitting unimportant details, the discussion of which is only calculated to confuse the learner. For a similar reason references to authorities have also generally been omitted. Those illustrations which are taken from other authors are duly acknowledged; the rest have either been drawn expressly for this work, or have been borrowed for it from Quain's *Anatomy* or from the author's *Course of Practical Histology*. To the book last mentioned the student who desires to work independently is referred for details of method which need not be provided for those who are working under the immediate supervision of a teacher.

For conveniently accompanying the work of a class of medical students, the book is divided into forty-six lessons. Each of these may be supposed to occupy from one to three hours, according to the relative extent to which the preparations are made beforehand by the teacher, or during the lesson by the students. A few of

the preparations—*e.g.* some of those of the sense-organs—cannot well be made in a class, but it has been thought advisable not to injure the completeness of the work by omitting mention of them.

Only those methods are recommended upon which experience has proved that full dependence can be placed, but the directions given are for the most part capable of easy verbal modification in accordance with the ideas or experience of different teachers.

CONTENTS.

INTRODUCTORY.

	PAGE
ENUMERATION OF THE TISSUES—GENERAL STRUCTURE OF ANIMAL CELLS,	1

LESSON I.

USE OF THE MICROSCOPE—EXAMINATION OF COMMON OBJECTS,	8
--	---

LESSON II.

STUDY OF THE HUMAN BLOOD-CORPUSCLES,	12
--	----

LESSON III.

ACTION OF REAGENTS UPON THE HUMAN BLOOD-CORPUSCLES,	19
---	----

LESSON IV.

STUDY OF THE BLOOD-CORPUSCLES OF AMPHIBIA,	22
--	----

LESSON V.

THE AMEBOID PHENOMENA OF THE COLOURLESS BLOOD-CORPUSCLES,	24
---	----

LESSON VI.

EPITHELIUM—CELL-DIVISION,	28
-------------------------------------	----

	PAGE
LESSON VII.	
COLUMNAR AND CILIATED EPITHELIUM AND TRANSITIONAL EPITHELIUM,	35
LESSON VIII.	
STUDY OF CILIA IN ACTION,	40
LESSON IX.	
THE CONNECTIVE TISSUES: AREOLAR AND ADIPOSE TISSUE: RETIFORM TISSUE,	43
LESSON X.	
THE CONNECTIVE TISSUES (<i>continued</i>): ELASTIC TISSUE, FIBROUS TISSUE, DEVELOPMENT OF CONNECTIVE TISSUE,	52
LESSON XI.	
THE CONNECTIVE TISSUES (<i>continued</i>): ARTICULAR CARTILAGE, SYNOVIAL MEMBRANES,	58
LESSON XII.	
THE CONNECTIVE TISSUES (<i>continued</i>): COSTAL CARTILAGE, FIBRO-CARTILAGE,	63
LESSON XIII.	
THE CONNECTIVE TISSUES (<i>continued</i>): BONE AND MARROW,	66
LESSON XIV.	
THE CONNECTIVE TISSUES (<i>continued</i>): DEVELOPMENT OF BONE,	74
LESSON XV.	
STRUCTURE OF STRIATED MUSCLE,	82
LESSON XVI.	
STRUCTURE OF STRIATED MUSCLE (<i>continued</i>),	86

LESSON XVII.

	PAGE
CONNECTION OF MUSCLE WITH TENDON—BLOOD-VESSELS OF MUSCLE— CARDIAC MUSCLE—DEVELOPMENT OF MUSCLE—PLAIN MUSCLE, .	90

LESSON XVIII.

STRUCTURE OF NERVE-FIBRES,	96
--------------------------------------	----

LESSONS XIX. AND XX.

STRUCTURE OF GANGLIA—STRUCTURE OF NERVE-CELLS—STRUCTURE OF NEUROGLIA-CELLS — DEVELOPMENT OF NERVE-FIBRES — WALLERIAN DEGENERATION,	103
--	-----

LESSON XXI.

MODES OF TERMINATION OF NERVE-FIBRES,	119
---	-----

LESSON XXII.

STRUCTURE OF THE LARGER BLOOD-VESSELS,	130
--	-----

LESSON XXIII.

SMALLER BLOOD-VESSELS—MICROSCOPIC STUDY OF THE CIRCULATION —DEVELOPMENT OF BLOOD-VESSELS,	137
--	-----

LESSON XXIV.

LYMPHATIC VESSELS, SEROUS MEMBRANES,	142
--	-----

LESSON XXV.

LYMPHATIC GLANDS, TONSIL, THYMUS,	148
---	-----

LESSON XXVI.

THE SKIN,	154
---------------------	-----

LESSON XXVII.

STRUCTURE OF THE HEART,	168
-----------------------------------	-----

LESSON XXVIII.

	PAGE
THE TRACHEA AND LUNGS,	172

LESSON XXIX.

STRUCTURE OF THE TEETH, THE TONGUE, AND MUCOUS MEMBRANE OF THE MOUTH—TASTE-BUDS,	179
---	-----

LESSON XXX.

THE SALIVARY GLANDS: PHARYNX AND OESOPHAGUS,	192
--	-----

LESSON XXXI.

STRUCTURE OF THE STOMACH,	199
-------------------------------------	-----

LESSONS XXXII. AND XXXIII.

STRUCTURE OF SMALL AND LARGE INTESTINE,	207
---	-----

LESSON XXXIV.

STRUCTURE OF THE LIVER AND PANCREAS,	218
--	-----

LESSON XXXV.

STRUCTURE OF THE SPLEEN, SUPRARENAL CAPSULE, AND THYROID BODY,	225
---	-----

LESSON XXXVI.

STRUCTURE OF THE KIDNEY,	232
------------------------------------	-----

LESSON XXXVII.

STRUCTURE OF THE URETER, BLADDER, AND MALE GENERATIVE ORGANS,	240
--	-----

LESSON XXXVIII.

GENERATIVE ORGANS OF THE FEMALE, AND MAMMARY GLANDS,	251
--	-----

CONTENTS.

xi

LESSON XXXIX.

	PAGE
STRUCTURE OF THE SPINAL CORD,	261

LESSON XL.

THE MEDULLA OBLONGATA,	272
----------------------------------	-----

LESSON XLI.

PONS VAROLII AND MESENCEPHALON,	279
---	-----

LESSON XLII.

STRUCTURE OF THE CEREBELLUM AND CEREBRUM,	289
---	-----

LESSONS XLIII. AND XLIV.

STRUCTURE OF THE EYELIDS AND OF THE PARTS OF THE EYEBALL,	306
---	-----

LESSON XLV.

STRUCTURE OF THE OLFACTORY MUCOUS MEMBRANE AND OF THE EXTERNAL AND MIDDLE EAR,	328
---	-----

LESSON XLVI.

STRUCTURE OF THE LABRYNTH,	333
--------------------------------------	-----

APPENDIX.

METHODS,	344
--------------------	-----

INDEX,	356
------------------	-----

THE ESSENTIALS OF HISTOLOGY.

INTRODUCTORY.

ENUMERATION OF THE TISSUES AND THE GENERAL STRUCTURE OF ANIMAL CELLS.

Animal Histology¹ is the science which treats of the minute structure of the tissues and organs of the animal body; it is studied with the aid of the microscope, and is therefore also termed *Microscopical Anatomy*.

Every part or organ of the body, when separated into minute fragments, or when examined in thin slices (sections), is found to consist of certain textures or tissues, which differ in their arrangement in different organs, but each of which exhibits characteristic structural features.

The following is a list of the principal tissues which compose the body:—

1. **Epithelial.**
2. **Connective:** Areolar, Fibrous, Elastic, Adipose, Lymphoid, Cartilage, Bone.
3. **Muscular:** Voluntary, Involuntary or plain, Cardiac.
4. **Nervous.**

Some organs are formed of several of the above tissues, others contain only one or two.

It is convenient to include such fluids as the *blood* and *lymph* amongst the tissues, because they are studied in the same manner and contain cellular elements similar to those met with in some of the other tissues.

The elements which compose the tissues are of the nature either of *fibres* or *cells*. Some tissues are composed almost entirely of fibres with relatively few cells interspersed amongst the fibres; this is the case with most of the connective tissues. Others, such as the epithelial tissues, are composed entirely of cells, whilst nervous and muscular tissues are formed of cells which are partly or wholly extended to form fibres.

Cells.—A *cell* is a minute portion of living substance or *protoplasm*, which is sometimes inclosed by a *cell-membrane* and always contains a vesicle which is known as the *nucleus*.

¹ From *ιστός*, a web or texture.

The **protoplasm** of a cell (fig. 1, *p*) is composed of albuminous substances, and is characterised in typical cells by possessing the property of spontaneous movement. When the cell is uninclosed by a membrane a change in the shape, or even in the position of the cell, may be thereby produced. This is characteristically shown in the movements of the unicellular organism known as the amoeba (fig. 2), and hence the name amoeboid movement, by which it is generally designated. The protoplasm often exhibits a granular appearance. This, under high magnifying powers, is sometimes seen to be due to the fact that it contains a reticulum or spongework,

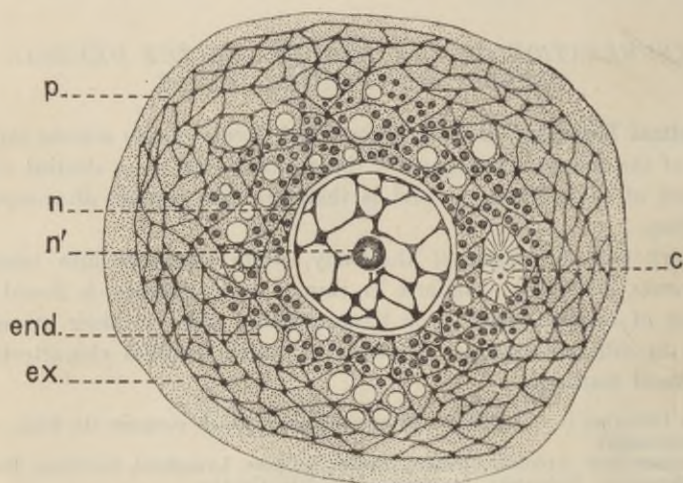


FIG. 1.—DIAGRAM OF A CELL, HIGHLY MAGNIFIED.

p, protoplasm, consisting of hyaloplasm and a network of spongioplasm; *ex.*, exoplasm; *end.*, endoplasm, with distinct granules and vacuoles; *c*, double centrosome; *n*, nucleus; *n'*, nucleolus.

which appears under the microscope in the form of a network (fig. 1), the remainder of the protoplasm being a clear soft substance which occupies the interstices of the reticulum, and may also cover the surface or project beyond the rest of the cell. The granular appearance above mentioned is often caused by the knots in the network appearing when imperfectly observed as separate granules. The material which forms the reticulum is termed *spongioplasm*; the clearer material which occupies its meshes is *hyaloplasm*. The protoplasm of a cell often, if not always, includes actual granules of an albuminous nature; but it is uncertain whether such granules are essential constituents of the protoplasm (as is contended by Altmann) or materials which have been formed by the protoplasm, and which are in a sense

accidental inclusions. It may be convenient to term these albuminous granules collectively *granuloplasm*. That they are of importance appears to be evident from the fact that many of the chemical changes of cells occur in them. Besides the granules above referred to, which may be regarded as actual constituents of the protoplasm, others occur which are not thus to be regarded, such as pigment granules, fat globules, and vacuoles containing watery fluid, with or without glycogen or other substances in solution. Materials which are thus included in the protoplasm of a cell are either stored up for the nutrition of the cell itself, or are

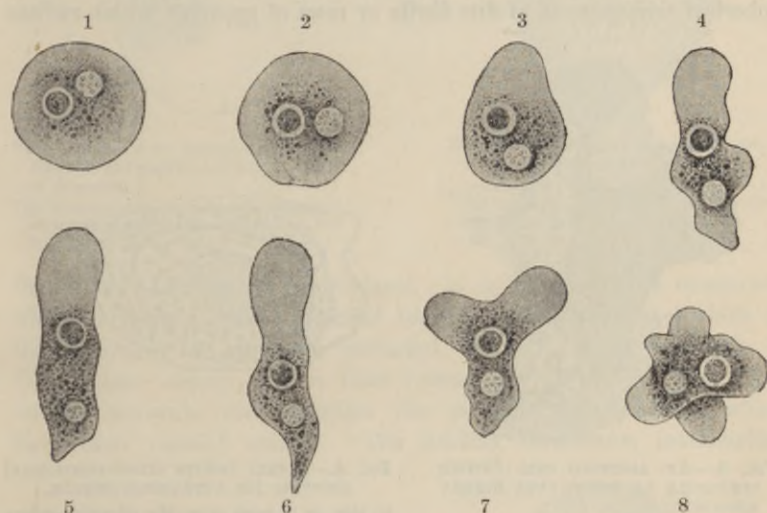


FIG. 2.—SUCCESSIVE CHANGES EXHIBITED BY AN AMOEBÆ. (Verworn.)

converted into substances which are eventually extruded from the cell in order to serve some purpose useful to the whole organism, or to be got rid of from the body. The term *paraplasm* has sometimes been given to any such material within a cell other than the actual protoplasm. Paraplasm is often present in sufficient quantity to reduce the protoplasm to a relatively small amount, the bulk of the cell being occupied by other material, as when starch becomes collected within vegetable cells or fat within the cells of adipose tissue. It is frequently the case that the paraplasmic and granular material is confined mainly to the middle of the cell in the neighbourhood of the nucleus, an external zone of the protoplasm being left clear. The two portions of protoplasm which are thus somewhat imperfectly differentiated off from one another have been termed respectively the *endoplasm* and the *exoplasm* (fig. 1). They are exhibited in

the amoeba (fig. 2), and also in the white blood-corpuscule represented in fig. 3.

In some cells there are fine but distinct striæ or fibrils running in definite directions. These are very commonly met with in fixed cells, such as various kinds of epithelium-cells, nerve-cells, and muscle-cells. But besides this special differentiation, which appears to be related to the special function of the cell, and is not universal, there is another structure in the cell-protoplasm, which is known as the *attraction-particle* or *centrosome* (figs. 1, 4). This is surrounded by a spherical arrangement of fine fibrils or rows of granules, which radiate

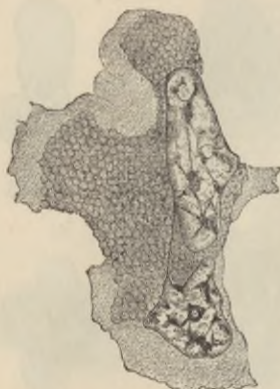

FIG. 3.—AN AMOEBOID CELL (WHITE CORPUSCLE OF NEWT) VERY HIGHLY MAGNIFIED.

Showing a double nucleus with reticulum of chromoplasm, and the protoplasm composed of two portions, a clearer exoplasm, and a granular-looking endoplasm.

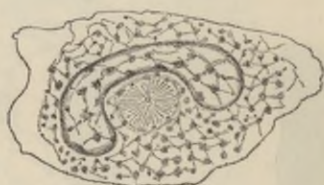

FIG. 4.—A CELL (WHITE BLOOD-CORPUSCLE) SHOWING ITS ATTRACTION-SPHERE.

In this, as in most cases, the attraction-sphere lies near the nucleus.

from a clear area, in the middle of which lies the attraction-particle. The attraction-spheres, with their central particles, were discovered by Ed. v. Beneden in the ovum or egg-cell, and were at first supposed to be peculiar to the ovum, but they have now been recognised (by Flemming and others) in very many cells, both animal and vegetable, and are probably of universal occurrence. They are usually double (fig. 1), the twin spheres being connected by a spindle-shaped system of delicate fibrils (*achromatic spindle*): this duplication invariably precedes the division of a cell into two (fig. 5).

A **cell-membrane** is rarely distinct in animal cells, nor has its chemical nature been sufficiently investigated. It is formed by the external layer of the protoplasm, and is probably of more extensive occurrence than has generally been supposed, although in most cases

it is only represented by the thinnest possible film. The osmotic effect of water upon most animal cells affords a clear indication of the existence of such a limiting film.

The **nucleus** of the cell (fig. 1, *n*) is a minute vesicle, spherical, ovoid, elongated, or irregularly lobulated (see figs. 1, 3, 4, 6) in

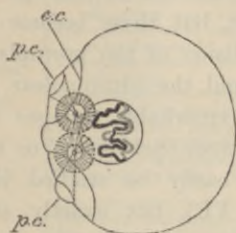


FIG. 5.—OVUM OF ASCARIS, SHOWING DOUBLE ATTRACTION-SPHERE. (Ed. v. Beneden.)

The nucleus with its contorted filament of chromoplasm is represented, but the protoplasm of the cell is not filled in.

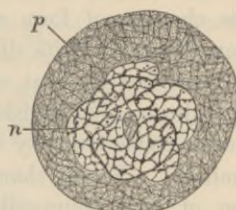


FIG. 6.—CELL FROM BONE-MARROW. (Carnoy.)

p, protoplasm with fine reticulum; *n*, nucleus, long and folded, with intranuclear network.

shape, embedded in the protoplasm. It is bounded by a membrane which incloses a clear substance (*nuclear matrix*), and the whole of this substance is generally pervaded by an irregular network of fibres, some coarser, others finer (*intranuclear network*). This intranuclear network often exhibits one or more enlargements, which have been termed *nucleoli*. The nuclear membrane, intranuclear

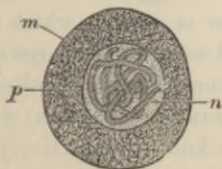


FIG. 7.—GLAND-CELL FROM A LARVA OF NEMOTOCERA. (Carnoy.)

m, cell-membrane; *p*, protoplasm; *n*, nucleus with convoluted filament.

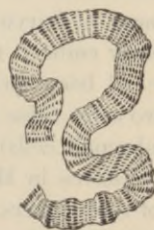

FIG. 8.—PART OF THE NUCLEAR FILAMENT IN FIG. 7 GREATLY MAGNIFIED.

fibres, and nucleoli all stain deeply with hæmatoxylin and with most basic dyes; this property distinguishes them from the nuclear matrix, and they are accordingly spoken of as *chromatic* (composed of *chromoplasm*), the matrix as *achromatic*. Sometimes instead of being united into a network the intranuclear fibres take the form of convoluted filaments, having a skein-like appearance (fig. 7). This is

always the case when a nucleus is about to divide, but it may also occur in the resting condition. These filaments may sometimes be seen with very high magnifying powers to be made up of fine juxtaposed particles arranged either in single or multiple rows, thus imparting a cross-striated appearance to the filament (see figs. 7, 8). The fibres within the nucleus have been observed to undergo spontaneous changes of form and arrangement, but these become much more evident during its division. The division of the protoplasm is always preceded by that of the nucleus, and the intranuclear fibres undergo during its division a series of remarkable changes which are known collectively by the term *karyokinesis* (Schleicher) or *mitosis* (Flemming).¹ These changes may most easily be studied in the division of epithelium-cells (see Lesson VI.), but exactly similar phenomena have been shown to occur in cells belonging to the other tissues.

The **nucleoli** of cells are not all of the same nature. Some are nothing more than accumulations of the material which forms the fibres of the intranuclear network or skein. These are usually irregular in shape, and may be termed *pseudo-nucleoli* to distinguish them from the true nucleolus, which is generally a spherical accumulation of a material differing in its chemical and staining reactions from that of the nuclear network in which it is embedded. The true nucleolus is usually single, but may be double or multiple: it sometimes contains a vacuole-like globule in its interior (fig. 1). It is most characteristic of "resting" cells, being rarely visible after the commencement of karyokinesis.

In the early embryo the whole body is an agglomeration of cells. These have all been formed from the *ovum* or *egg-cell*, which divides first into two cells, these again into two, and so on until a large number of cells (embryonic cells) are produced. Eventually the resultant cells arrange themselves in the form of a membrane (*blastoderm*) which is composed of three layers. These layers are known respectively as the *ectoderm* or *epiblast*, the *mesoderm* or *mesoblast*, and the *entoderm* or *hypoblast*. The ectoderm gives rise to most of the epithelial tissues and to the tissues of the nervous system; the entoderm to the epithelium of the alimentary canal (except the mouth), and the glands in connection with it; and the mesoderm to the connective and muscular tissues.

The tissues are formed either by changes which occur in the inter-cellular substance, or by changes in the cells themselves; frequently by both these processes combined. The cells which are least altered

¹The simple division of a nucleus by a process of fission without karyokinetic changes is termed *amitotic division*: it occurs only in rare instances.

from their embryonic condition are the white corpuscles of the blood, and these may be regarded therefore as typical cells.

The histogenetical relation between the three layers of the blasto-derm and the several tissues and organs of the body is exhibited in the following table:—

Ectoderm or Epiblast.	<ul style="list-style-type: none"> The epithelium of the skin or epidermis, and its appendages, viz., the hairs, nails, sebaceous and sweat glands. The epithelium of the mouth, and of the salivary and other glands which open into the mouth. The enamel of the teeth. The gustatory organs. The epithelium of the nasal passages, and the cavities and glands which open into them. The epithelium covering the front of the eye. The crystalline lens. The retina. The epithelium lining the membranous labyrinth of the ear. The epithelium lining the central canal of the spinal cord, the aqueduct of Sylvius, and the fourth, third, and lateral ventricles of the brain. The tissues of the nervous system. The pituitary body. The pineal gland.
Mesoderm or Mesoblast.	<ul style="list-style-type: none"> The connective tissues. The blood- and lymph-corpuscles. The epithelial lining of the heart, blood-vessels, lymphatics, and serous membranes (endothelium). The epithelium of the uriniferous tubules. The epithelium of the internal generative organs, and the generative products in both sexes. The muscular tissues, voluntary, involuntary, and cardiac. The spleen and other lymphatic and vascular glands.
Entoderm or Hypoblast.	<ul style="list-style-type: none"> The epithelium of the alimentary canal (from the pharynx to the lower end of the rectum) and of all the glands which open into it (including the liver and pancreas). The epithelium of the Eustachian tube and cavity of the tympanum. The epithelium of the larynx, trachea, and bronchi, and of all their ramifications. The epithelium of the pulmonary alveoli. The epithelium of the thyroid body. The concentric corpuscles of the thymus gland. The epithelium of the urinary bladder and ureters.

LESSON I.

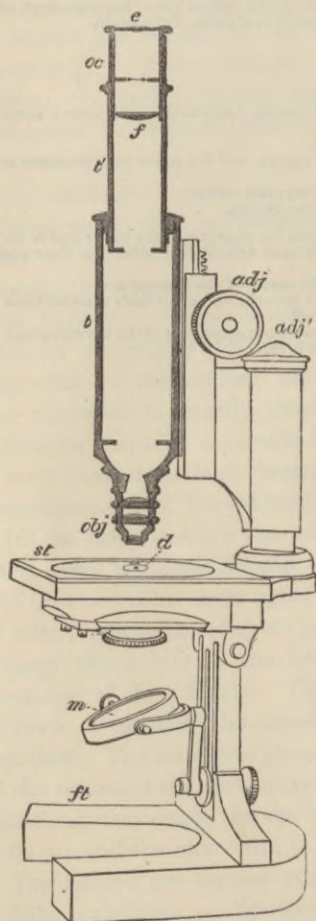
USE OF THE MICROSCOPE. EXAMINATION OF
CERTAIN COMMON OBJECTS.

FIG. 9.—DIAGRAM OF MICROSCOPE.

THE requisites for practical histology are a good compound microscope; slips of glass technically known as 'slides,' upon which the preparations are made; pieces of thin glass used as covers for the preparations; a few simple instruments, such as a razor, a scalpel, scissors, forceps, and needles mounted in wooden handles; and a set of fluid re-agents for mounting and staining microscopic preparations.¹ A sketch-book and pencil are also necessary, and must be constantly employed.

Examine the microscope (fig. 9). It consists of a tube (*t t'*) having two systems of lenses, one at the upper end termed the 'eye-piece' or 'ocular' (*oc*), the other at the lower end, termed the 'objective' (*obj*). There should be at least two objectives—a low power working at about $\frac{1}{2}$ inch from the object, and a high power, having a focal distance of about $\frac{1}{8}$ inch; and it is also useful to have two or more oculars of different power. The focus is obtained by cautiously bringing the tube and lenses down towards the object by the coarse adjustment, which is either a telescopic or a rack-and-pinion movement (*adj*), and focussing exactly by the fine adjustment, which is always a finely cut screw (*adj'*).

The stage (*st*) upon which the preparations are placed for examination, the mirror (*m*) which serves to reflect the light up through the central aperture in the stage and along the tube of the instrument, and the diaphragm (*d*) below the stage which is used to regulate the amount of light thus thrown up, are all parts the employment of which is readily understood. A substage condenser (not shown

¹The directions for making the principal fluids used in histological work will be found in the Appendix.

in the diagram), which serves to concentrate the light thrown up by the mirror to the centre of the object, is valuable when high powers and stained preparations are employed.

The combinations of objectives ($\frac{1}{2}$ inch and $\frac{1}{3}$ inch focal distance) and oculars above referred to will generally give a magnifying power of from 50 to 400 diameters, and this is sufficient for most purposes of histology. But to bring out minute points of detail in the structure of cells and of certain tissues examination with much higher magnifying powers may be necessary. Objectives of high power are usually made as immersion-lenses; i.e. they are constructed to form a proper image of the object when the lowermost lens of the system is immersed in a layer of liquid which lies on the cover-glass of the object and has a refractive index not far removed from that of the glass itself. For this purpose either water or an essential oil (oil of cedar-wood) is used. Many advantages are obtained by the employment of these lenses, especially those for oil-immersion.

The best lenses for histological work are made of the so-called 'apochromatic' glass of Zeiss; specially constructed 'compensating' eye-pieces are used with these.

A scale for measuring objects should be constructed for each microscope. To do this, put a stage-micrometer (which is a glass slide ruled in the centre with lines $\frac{1}{10}$ and $\frac{1}{100}$ millimeter apart) under the microscope in such a manner that the lines run from left to right (the microscope must not be inclined). Focus them exactly. Put a piece of white card on the table at the right of the microscope. Look through the instrument with the left eye, keeping the right eye open. The lines of the micrometer will appear projected upon the paper. Mark their apparent distance with pencil upon the card, and afterwards make a scale of lines in ink, of the same interval apart. A magnified representation is thus obtained of the micrometer scale. Mark upon it the number of the eye-piece and of the objective, and the length of the microscope-tube. This scale-card will serve for the measurement of any object without the further use of the micrometer. To measure an object, place the scale-card upon the table to the right of the microscope and view the object with the left eye, keeping the right eye open. The object appears projected upon the scale, and its size in $\frac{1}{10}$ or $\frac{1}{100}$ of a millimeter can be read off. It is important that the same objective and eye-piece should be employed as were used in making the scale, and that the microscope tube should be of the same length. The lines on English stage-micrometers are often ruled $\frac{1}{100}$ and $\frac{1}{1000}$ inch apart.¹

Before beginning the study of histology the student should endeavour to familiarise himself with the use of the microscope, and at the same time learn to recognise some of the chief objects which are liable to occur accidentally in microscopic specimens. On this account it has been considered desirable to introduce directions for the examination and recognition of starch-granules, moulds and torulae, air-bubbles, linen, cotton, and woollen fibres, and the usual constituents of the dust of a room, into the first practical lesson.

1. Examination of starch-granules. Gently scrape the cut surface of a potato with the point of a knife; shake the starch-granules so obtained into a drop of water upon a clean slide and apply a cover-glass.

With the low power the starch-granules look like dark specks differing considerably in size; under the high power they are clear, flat, ovoid particles (fig. 10, *St*), with a sharp outline when exactly focussed. Notice the change in appearance of the outline as the microscope is focussed up or down. On close examination fine concentric lines are to be seen in the granules arranged

¹For the method of measuring with an ocular micrometer, and for determining the magnifying power of a microscope, the student is referred to the author's *Course of Practical Histology*.

around a minute spot which is generally placed eccentrically near the smaller end of the granule. Sketch two or three starch-granules.

Notice the appearance of air-bubbles in the water. If comparatively large they are clear in the middle, with a broad dark border due to refraction of the light; if small they may look entirely dark.

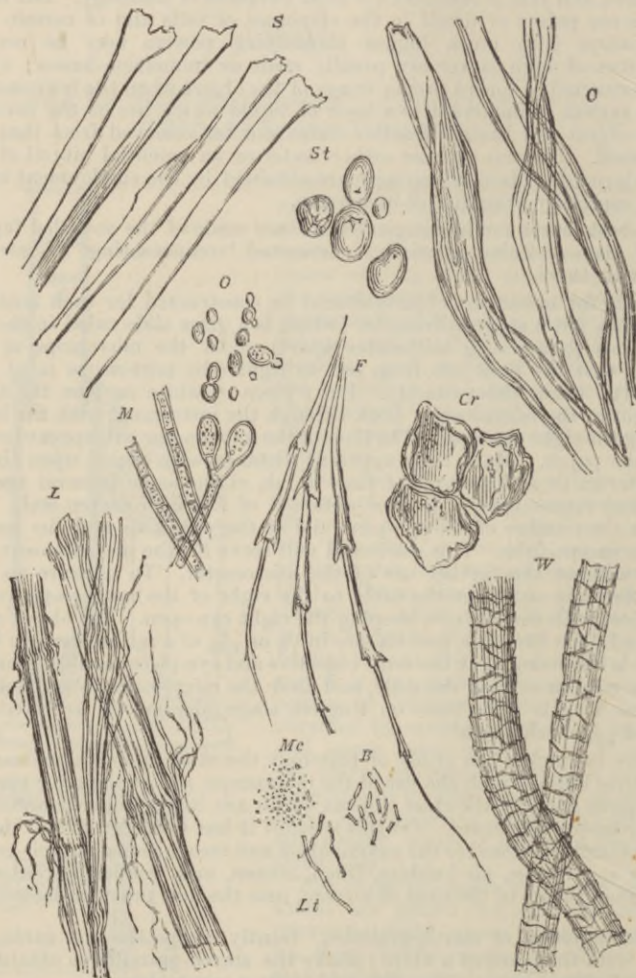


FIG. 10.—ORGANIC MATTERS FREQUENTLY PRESENT IN DUST. (Heitzmann.)

S, fibres of silk; *C*, of cotton; *L*, of linen; *W*, of wool; *F*, feather; *St*, starch-granules; *Cr*, cork; *O*, torulae; *M*, mycelium or threads of mildew; *Mc*, micrococci; *B*, bacteria; *Lt*, leptothrix filaments (500 diameters).

2. Examine some yeast which has been grown in solution of sugar. Observe the yeast-particles or torulae, some of them budding. Each torula contains a clear vacuole, and has a well-defined outline, due to a membrane. Sketch two or three torulae.

3. Examine some mould (*Penicillium* or *Mucor*) in water. Notice the long branching filaments (hyphæ), and also the torula-like particles (spores) from which hyphæ may in some instances be seen sprouting. Sketch part of a hypha.

4. Examine fibres of linen and of cotton in water, using a high power. Compare the well-defined, relatively coarse, striated, and slightly twisted linen, with the longer, thinner, and more twisted cotton-fibres. Sketch one of each kind.

5. Mount two or three hairs from the head in water and look at them, first with the low, then with the high power. Examine also some fibres from any woollen material and compare them with the hairs. They have the same structure, although the wool is finer and is curled; its structure may be partly obscured by the dye. Draw one or two woollen fibres.

6. Examine some dust of the room in water with a high power. In addition to numerous groups of black particles of carbon (soot) there will probably be seen fibres of linen, cotton, or wool, and shed epithelium-cells derived from the epidermis.

LESSON II.

STUDY OF THE HUMAN BLOOD-CORPUSCLES.

1. HAVING cleaned a slide and cover-glass, prick the finger and mount a small drop of blood quickly, so that it has time neither to dry nor to coagulate. Examine it at once with the high power.

Note (a) the coloured corpuscles, mostly in rouleaux and clumps, but some lying apart seen flat or in profile; (b) the colourless corpuscles, easily made out if the cover-glass is touched by a needle, on account of their tendency to stick to the glass, whilst the coloured corpuscles are driven past by the currents set up; (c) in the clear spaces, fibrin-filaments and elementary particles or blood-tablets.

Sketch a roll of coloured corpuscles and one or two colourless corpuscles. Count the number of colourless corpuscles in a field of the microscope.

2. To be made like 1, but the drop of blood is to be mixed upon the slide with an equal amount of normal saline solution,¹ so that the red corpuscles tend to be less massed together, and their peculiar shape is better displayed.

Sketch a red corpuscle seen on the flat and another in profile (or optical section). Also a crenated corpuscle.

Measure ten red corpuscles, and from the results ascertain the average diameter of a corpuscle. Measure also the largest and the smallest you can find.

3. Make a preparation of blood as in § 1 and put it aside to coagulate. After ten minutes remove the cover-glass and run a drop or two of distilled water over the coagulated film. This decolorises the red corpuscles. Replace the water by a moderately dilute solution of Spiller's purple; leave this on the preparation for a few minutes; wash with distilled water: then allow the preparation to dry, and mount the film by putting a drop of xylol balsam upon it and covering with a cover-glass. The purple stains the nuclei of the white corpuscles and also brings the network of fibrin-filaments and the elementary particles clearly into view (fig. 16, A).

4. To fix and stain the coloured corpuscles:—Place upon a slide a drop of 1 p.c. osmic acid mixed with a little aqueous solution of eosin. Prick the finger, and mix the blood directly with the coloured fluid, stirring them together with a needle. Cover the mixture and put aside for an hour, protected from evaporation; then add some glycerine and water. Fix the cover-glass with gold size.

5. To study the granules of the colourless corpuscles and their different reactions to staining reagents, a film of blood is inclosed between two cover-glasses, which are then separated and the film on each quickly dried by being passed through or over a flame. The films are stained by immersing the cover-glasses (1) in a 1 p.c. aqueous solution of eosin, after which they are rinsed with water and are then placed (2) in a 1 p.c. aqueous solution of methylene blue. If the staining solutions are employed warm a few minutes will suffice. The film is nearly decolorised by rinsing with absolute alcohol, and is then placed in xylol and finally mounted in xylol balsam.

¹ Made by dissolving from 6 to 9 grammes of common salt in 1 litre of ordinary water.

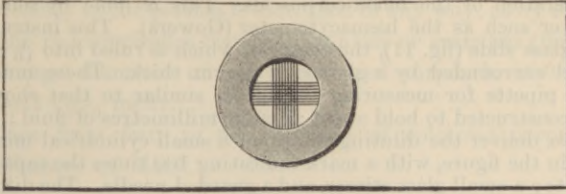


FIG. 11.—HEMACYTOMETER SLIDE, RULED IN SQUARES (OF 0.1 MM.) FOR THE ENUMERATION OF BLOOD-CORPUSCLES.

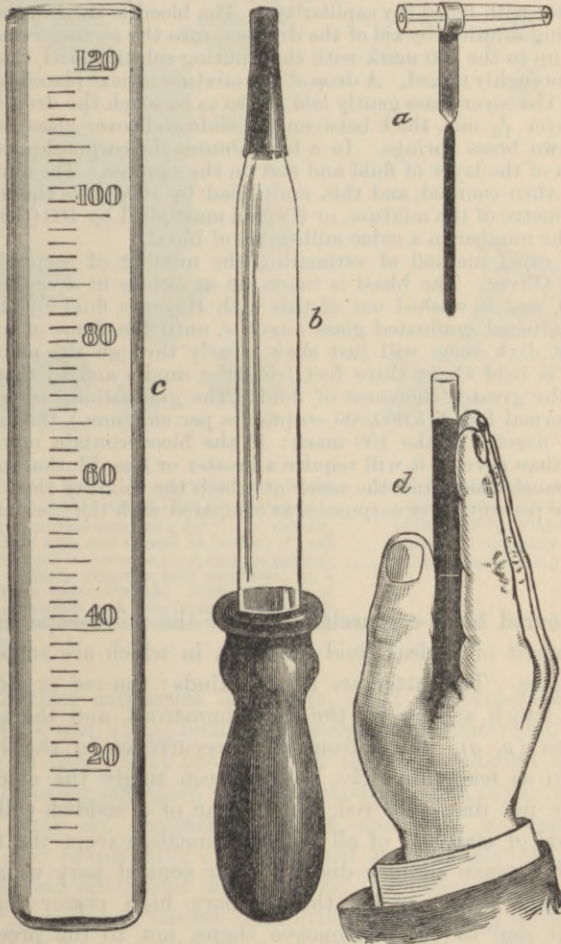


FIG. 12.—OLIVER'S APPARATUS FOR ESTIMATING THE NUMBER OF CORPUSCLES IN BLOOD BY MEANS OF THE OPACITY METHOD.

a, pipette for measuring blood; *b*, dropper for adding mixing solution; *c*, graduated tube; *d*, mode of observing.

6. Enumeration of the blood-corpuscles. This is done by some form of blood-counter such as the hæmacytometer (Gowers). This instrument consists of a glass slide (fig. 11), the centre of which is ruled into $\frac{1}{10}$ millimetre squares and surrounded by a glass ring $\frac{1}{10}$ mm. thick. There must also be provided a pipette for measuring the blood, similar to that shown in fig. 12, *a*, and constructed to hold about 5 cubic millimetres of fluid; a dropper (fig. 12, *b*) to deliver the diluting solution; a small cylindrical mixing glass, not shown in the figure, with a mark indicating 100 times the capacity of the blood pipette; a small glass stirrer, and a guarded needle. The diluting solution is that recommended by Hayem, viz. distilled water 200 cc., sulphate of soda 5 grms., common salt 1 grm., corrosive sublimate, 0.5 grm. A little of this is first put in the mixing vessel, the finger is then pricked, and the pipette filled exactly with blood (by capillarity). The blood is then washed out of it with diluting solution, by aid of the dropper, into the mixing vessel, which is now filled up to the 100 mark with the diluting solution, and the blood and this are thoroughly mixed. A drop of the mixture is next placed in the centre of the cell, the cover-glass gently laid on (so as to touch the drop, which thus forms a layer $\frac{1}{10}$ mm. thick between the slide and cover-glass), and pressed down by two brass springs. In a few minutes the corpuscles have sunk to the bottom of the layer of fluid and rest on the squares. The number in ten squares is then counted, and this, multiplied by 100, gives the number in a cubic millimetre of the mixture, or if again multiplied by 100 (the amount of dilution) the number in a cubic millimetre of blood.

A more rapid method of estimating the number of corpuscles is that devised by Oliver. The blood is taken up as before in a capillary pipette (fig. 12, *a*), and is washed out of this with Hayem's fluid by the dropper, *b*, into a flattened graduated glass mixer, *c*, until the flame of a small wax candle in a dark room will just show clearly through the mixture, when the vessel is held about three feet from the candle and so that the light traverses the greater thickness of fluid. The graduations are so arranged that for normal blood (5,000,000 corpuscles per cub. mm.), the mixture will now stand exactly at the 100 mark: if the blood contain more or fewer corpuscles than normal, it will require a greater or less dilution to attain the requisite translucency, and the mark at which the mixture then stands will indicate the percentage of corpuscles as compared with the normal.

The coloured blood-corpuscles.—Under the microscope the blood is seen to consist of a clear fluid (*plasma*), in which are suspended the *blood-corpuscles*. The latter are of two kinds: the *red* or *coloured* (fig. 13, *r*, *r'*), which are by far the most numerous, and the *white*, *pale*, or *colourless* (*p*, *g*), which from their occurrence in the lymph are also known as *lymph-corpuscles*. When seen singly the coloured corpuscles are not distinctly red, but appear of a reddish-yellow tinge. In the blood of man and of all other mammals, except the Camelidæ, they are biconcave circular disks. Their central part usually has a lightly shaded aspect under the ordinary high power (fig. 14, 1), but this is due to their biconcave shape, not to the presence of a nucleus. They have a strong tendency to become aggregated into rouleaux and clumps when the blood is at rest, but if it is disturbed they readily become separated.

If the density of the plasma is increased in any way, as by evaporation, many of the red corpuscles become shrunken or crenated (fig. 13, *c*).

The average diameter of the human red corpuscle is 0.0075 millimetre (about $\frac{1}{3200}$ inch).¹

There are from four to five millions of coloured corpuscles in a cubic millimetre of blood.

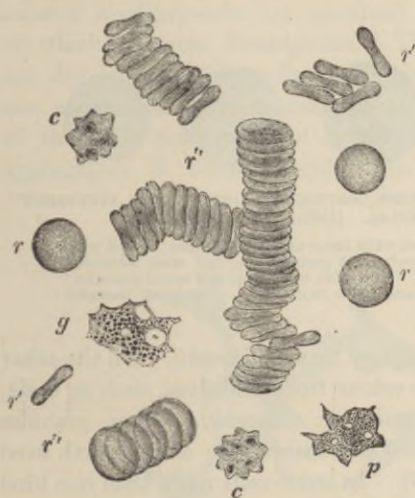


FIG. 13.—HUMAN BLOOD AS SEEN ON THE WARM STAGE. (Magnified about 1200 diameters.)

r, *r*, single red corpuscles seen lying flat; *r''*, *r'''*, red corpuscles on their edge and viewed in profile; *r''*, red corpuscles arranged in rouleaux; *c*, *c*, crenate red corpuscles; *p*, a finely granular pale corpuscle; *g*, a coarsely granular pale corpuscle. Both have two or three distinct vacuoles, and were undergoing changes of shape at the moment of observation; in *g*, a nucleus also is visible.

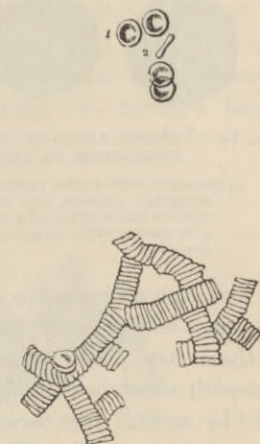

FIG. 14.—HUMAN RED CORPUSCLES LYING SINGLY AND COLLECTED INTO ROLLS. (As seen under an ordinary high power of the microscope.)

The colourless corpuscles of human blood are protoplasmic cells, averaging 0.01 mm. ($\frac{1}{3500}$ inch) in diameter when spheroidal, but they vary much in size. They are far fewer than the coloured corpuscles, usually numbering not more than ten thousand in a cubic millimetre. Moreover, they are specifically lighter, and tend to come to the surface of the preparation. If examined immediately the blood is drawn, they are spheroidal in shape, but they soon become irregular (fig. 13, *p*, *g*), and their outline continually alters, owing to the amoeba-like changes of form to which they are subject. Some of the colourless

¹The following list gives the diameter in parts of a millimetre of the red blood-corpuscles of some of the common domestic animals:—Dog, 0.0073; rabbit, 0.0069; cat, 0.0065; sheep, 0.0050; goat, 0.0041.

corpuscles are very pale and finely granular, others contain coarser and more distinct granules in their protoplasm; others again have a hyaline protoplasm without any apparent granules. In some corpuscles the protoplasm forms only a thin coating to the nucleus (lymphocytes). The corpuscles have usually been classified according to the character and reactions of the majority of their granules (fig. 15). Thus some of the granules are readily stained by basic dyes such as methylene

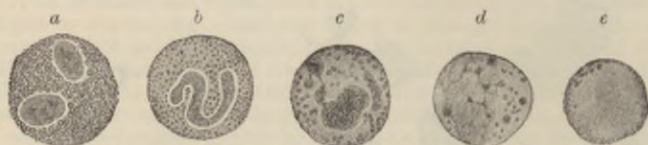


FIG. 15.—VARIOUS KINDS OF COLOURLESS CORPUSCLES, SHOWING THE DIFFERENT CHARACTERS OF THE GRANULES. (Böhm and v. Davidoff.)

- a*, leucocyte with double nucleus, filled with large oxyphil granules; *b*, cell with elongated nucleus, and small neutrophil granules; *c*, cell with lobulated nucleus and amphophil granules; *d*, cell with both large and small granules; *e*, leucocyte with large nucleus and little protoplasm, containing basophil granules.

blue, and such granules are accordingly termed *basophil*. On the other hand, some more readily take up colour from acid dyes, such as eosin, and these have been termed *oxyphil* or *eosinophil*. Other granules (*amphophil*) are stained by both acid and basic dyes; and a fourth kind chiefly by neutral dyes (*neutrophil*). In some cells more than one kind of granule is met with. The protoplasm may also contain clear spaces or vacuoles, and it has a reticular structure. Each pale corpuscle has at least one nucleus, which is difficult to see in a fresh preparation,



FIG. 16.—FIBRIN-FILAMENTS AND BLOOD-TABLETS.

- A*, network of fibrin, shown after washing away the corpuscles from a preparation of blood that has been allowed to clot; many of the filaments radiate from small clumps of blood-tablets. *B* (from Osler), blood-corpuscles and elementary particles or blood-tablets, within a small vein.

but is easily seen after the action of most reagents and after staining. It sometimes appears multiple, but it will usually be found that the apparently separate nuclei are actually joined by threads of nuclear substance (fig. 30, *b*, *c*).

In the clear fluid in which the blood-corpuscles are suspended, a network of fine straight intercrossing filaments (fibrin) soon makes its

appearance (fig. 16, A). There are also to be seen a certain number of minute round colourless discoid particles, either separate or collected into groups or masses, which masses may be of considerable size. These are the *elementary particles* or *blood-tablets*. Their meaning is not known. Fatty particles, derived from the chyle, may also occur in the plasma.

Development of blood-corpuscles.—In the embryo, the first-formed *coloured blood-corpuscles* are amœboid nucleated cells, the protoplasm of which contains hæmoglobin. These embryonic blood-corpuscles are developed within cells of the mesoblast, which are united with one another to form a protoplasmic network (fig. 17). The nuclei of the cells multiply, and around some of them there occurs an aggregation of coloured protoplasm. Finally the network becomes

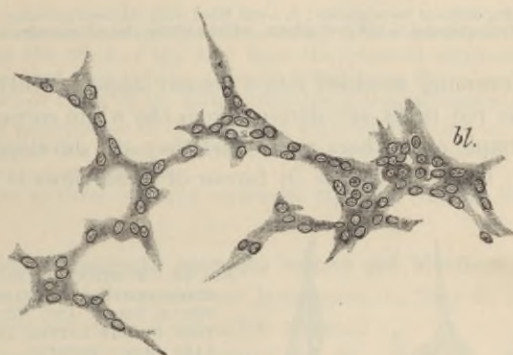


FIG. 17.—DEVELOPMENT OF BLOOD-VESSELS AND BLOOD-CORPUSCLES IN THE VASCULAR AREA OF THE GUINEA-PIG.

bl., blood-corpuscles becoming free in the interior of a nucleated protoplasmic mass.

hollowed out by an accumulation of fluid in the protoplasm, and thus are produced a number of capillary blood-vessels, and the coloured nucleated portions of protoplasm are set free within them as the embryonic blood-corpuscles (fig. 17, *bl.*).

In later embryonic life, nucleated coloured corpuscles disappear from mammalian blood, and are replaced by the usual discoid corpuscles. These are formed within certain cells of the connective tissue, a portion of the substance of the cell becoming coloured by hæmoglobin, and separated into globular particles (fig. 18, *a, b, c*), which are gradually moulded into disk-shaped red corpuscles. In the meantime the cells become hollowed out, and join with similar neighbouring cells to form blood-vessels (fig. 19, *a, b, c*). The process is therefore the same as before, except that the cell-nuclei do not participate in it.

Although no nucleated coloured corpuscles are to be seen in the blood in post-embryonic life, they continue to be found in the marrow of the bones (see Lesson XIII.), and in some animals they have also been found in the spleen. It is thought probable that the red disks may be formed from these by the nucleus disappearing and the coloured

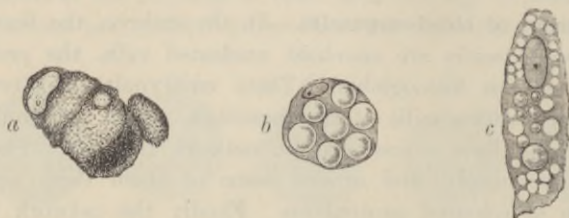


FIG. 18.—BLOOD-CORPUSCLES DEVELOPING WITHIN CONNECTIVE-TISSUE CELLS.

a, a cell containing diffused hæmoglobin; *b*, a cell filled with coloured globules; *c*, a cell containing coloured globules in the protoplasm, within which also are numerous vacuoles.

protoplasm becoming moulded into a discoid shape. Others have supposed that the red disks are derived from the white corpuscles of the blood and lymph, and others again that they are developed from the blood-tablets; but the evidence in favour of these views is insufficient.

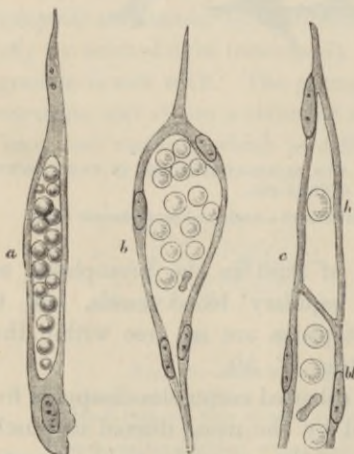


FIG. 19.—FURTHER DEVELOPMENT OF BLOOD-CORPUSCLES IN CONNECTIVE-TISSUE CELLS, AND TRANSFORMATION OF THE LATTER INTO CAPILLARY BLOOD-VESSELS.

a, an elongated cell with a cavity in its protoplasm occupied by fluid and by blood-corpuscles mostly globular; *b*, a hollow cell, the nucleus of which has multiplied. The new nuclei are arranged around the wall of the cavity, the corpuscles in which have now become discoid; *c* shows the mode of union of a 'hematopoietic' cell, which in this instance contains only one corpuscle, with the prolongation (*bc*) of a previously existing vessel. *a*, and *c*, from the new-born rat; *b*, from a fetal sheep.

The *white blood-corpuscles* and *lymph-corpuscles* occur originally as free unaltered embryonic cells, which have found their way into the vessels from the circumjacent mesoblast. Later they become formed in lymphatic glands and other organs composed of lymphoid tissue, and pass from these directly into the lymphatics and so into the blood.

LESSON III.

ACTION OF REAGENTS UPON THE HUMAN BLOOD-CORPUSCLES.

1. MAKE a preparation of blood as in Lesson II. 1, and apply a drop of water, at one edge of the cover-glass. Examine at a place where the two fluids are becoming mixed. Notice particularly the first effect of water upon both red and white corpuscles, as well as the ultimate action.

Sketch both kinds of corpuscles under the action of water.

2. Repeat on another preparation, using very dilute alkali (0.2 per cent. caustic potash in salt solution) instead of water. Notice the complete solution first of the white and then of the coloured corpuscles as the alkali reaches them.

3. Repeat on another preparation, using dilute acetic acid (1 per cent.). Observe that the effect of the acid upon the coloured corpuscles is similar to that of water, but that it has a different action upon the colourless corpuscles. Sketch two or three of the latter after the action is completed.

4. Make a preparation of blood mixed with salt solution as in Lesson II. 2, and investigate the action of tannic acid (1 part tannic acid to 100 of distilled water) in the same way.

Sketch two or three coloured corpuscles after the reaction is complete.

The action of reagents upon the human red blood-corpuscles shows that, although to all appearance homogeneous, they in reality consist of an external envelope of colourless material which forms a thin film inclosing the dissolved colouring matter or *hæmoglobin*. Thus, when water reaches the corpuscle, it passes through the film by osmosis and swells the corpuscle, causing it to become globular; eventually the film is burst through, and the colouring matter escapes into the serum. Salt, on the other hand, by increasing the density of the fluid in which the corpuscles float, causes a diffusion of water out of the corpuscle, and a consequent shrinking and corrugation of the surface, the crenated form (fig. 20, *f*) being thereby produced. The separation of the hæmoglobin from the corpuscle can be effected not only by water (fig. 20, *a-e*), but also by dilute acids, by the action of heat (60° C.), the freezing and thawing of blood, the vapour of chloroform, and the passage of electric shocks through blood. The mixing of blood from one species of animal with the blood or serum of animals of other species also has a similar action,

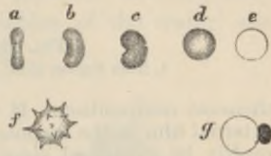


FIG. 20.

a-e, successive effects of water upon a red corpuscle; *f*, effect of solution of salt; *g*, effect of tannic acid.

The separation of the hæmoglobin from the corpuscle can be effected not only by water (fig. 20, *a-e*), but also by dilute acids, by the action of heat (60° C.), the freezing and thawing of blood, the vapour of chloroform, and the passage of electric shocks through blood. The mixing of blood from one species of animal with the blood or serum of animals of other species also has a similar action,

probably owing to differences of density or alkalinity. Tannic acid produces a peculiar effect (fig. 20, *g*); the hæmoglobin is discharged from the corpuscle, but is immediately altered and precipitated, remaining adherent to the envelope in the form of a round or irregular globule of a brownish tinge (hematin?).

Some of these reactions occur by a process of osmosis as in the case of water, but in others a solution of the envelope of the corpuscle is produced by the reagent, and the hæmoglobin is thus allowed to escape. The film or envelope is probably in large measure composed of lecithin and cholesterol (along with a little nucleo-proteid—Halliburton), and these are substances which possess many of the physical properties of fats, although of a different

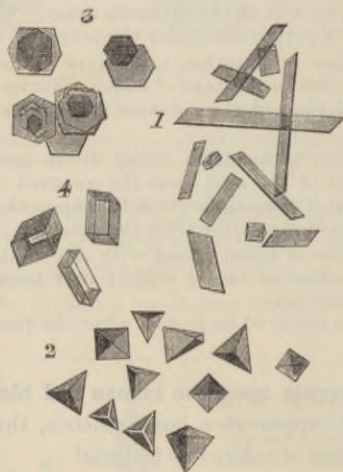


FIG. 21.—BLOOD CRYSTALS, MAGNIFIED.

1, from human blood; 2, from the guinea-pig; 3, squirrel; 4, hamster.

chemical composition. If we assume that such fatty substances form an external film to the corpuscle, the running of the red disks into rouleaux can readily be explained, since it has been shown by Norris that disks of any material, *e.g.* cork, suspended in a fluid, tend in the same way to adhere in rouleaux, provided their surfaces are covered with a layer which is not wetted by the fluid.

The envelope of the red corpuscle is often termed the *stroma*, but this name rests upon an entirely false conception of the structure of the corpuscle, and although of late years almost universally used, it ought to be entirely abandoned. In adopting the name, it was supposed that the corpuscle is formed of a homogeneous porous material (*stroma*—Rollett), in the pores of which the hæmoglobin is contained, but there is no reasonable foundation for this belief, whereas the supposition that there exists a delicate external film or envelope inclosing a coloured fluid is in accordance with all the known facts regarding the action of reagents upon these bodies.

Blood-crystals.—In the blood of some animals (fig. 21), crystals of hæmoglobin readily form after its separation by any of these means from the red corpuscles. These crystals are rhombic prisms in man and most animals, *e.g.* the rat, but tetrahedra in the guinea-pig, (2) and hexagonal plates in the squirrel (3). They are most appropriately studied along

with the chemical properties of blood. The same remark applies to the minute dark-brown rhombic crystals (*hæmin*, fig. 22), which are formed when dried blood from any source whatever is heated with glacial acetic acid, and to the reddish-yellow crystals of *hæmatoidin* (fig. 23), which are found in old blood extravasations.



FIG. 22.—HÆMIN CRYSTALS, MAGNIFIED.
(Preyer.)

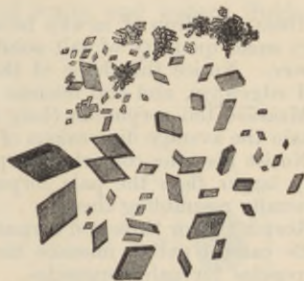


FIG. 23.—HÆMATOIDIN CRYSTALS.
(Frey.)

The structure of the **colourless corpuscles** is also brought out by the action of some of the reagents above noticed. As the water reaches them their amœboid movements cease; they become swollen out into a globular form by imbibition of fluid (fig. 24, 1), and the granules within the protoplasm can be seen to be in active Brownian motion. Their nuclei also become clear and globular, and are more conspicuous than before. With the further action of the water, the corpuscle bursts and the granules are set free.



FIG. 24.

1, first effect of the action of water upon a white blood-corpuscle; 2, 3, white corpuscles treated with dilute acetic acid; *n*, nucleus.

Acids have an entirely different action upon the white corpuscles. Their nuclei become somewhat shrunken and very distinct (fig. 24, 2 and 3), and a granular precipitate is formed in the protoplasm around the nucleus. At the same time, a part of the protoplasm generally swells out so as to form a clear bleb-like expansion (an appearance which also often accompanies the death of the corpuscle from other causes). Dilute caustic alkalies rapidly cause the destruction of the white corpuscles.

LESSON IV.

STUDY OF THE BLOOD-CORPUSCLES OF AMPHIBIA.

1. OBTAIN a drop of newt's blood by cutting the tail, and mix it with a very small quantity of salt solution upon a slide. Examine with the high power. Notice the shape of the coloured corpuscles both when seen flat and edgewise, and the nucleus within each.

Measure ten corpuscles (long and short diameters), and from the results obtain the average dimensions of the newt's blood-corpuscle.

Notice also the colourless corpuscles, smaller than the red, but considerably larger than the pale corpuscles of human blood, although otherwise generally resembling these.

Sketch two or three red corpuscles and as many white.

Be careful not to mistake the rounded liberated nuclei of crushed red corpuscles for pale corpuscles.

Enormous cells and nuclei belonging to the cutaneous glands as well as the granular secretion of those glands may be present in this preparation.

2. Apply a drop of water to the edge of the cover-glass of the same preparation and notice its action upon the corpuscles.

Sketch two or three corpuscles altered by the action of the water.

3. Mount another drop of blood, and apply dilute acetic acid (1 per cent.) instead of water at the edge of the cover-glass. Make sketches showing the effect of the acid upon both red and white corpuscles.

4. Examine the corpuscles of newt's blood which has been allowed to flow into boracic acid solution (2 per cent.). Notice the effect produced upon the coloured corpuscles. Sketch one or two.

5. Mount in glycerine-jelly a drop of frog's blood which has been fixed by Flemming's solution (see Appendix) and stained with picocarmine.

The **coloured blood-corpuscles of amphibia** (fig. 25), as well as of most vertebrates below mammals, are biconvex elliptical disks, considerably larger than the biconcave circular disks of mammals.¹ In addition to the coloured body of the corpuscle, which consists, as in mammals, of hæmoglobin inclosed within an envelope, there is a colourless *nucleus*, also of an elliptical shape, but easily becoming globular, especially if liberated by any means from the corpuscle. The nucleus resembles that of other cells in structure, being bounded

¹The following are the dimensions in parts of a millimetre of the coloured corpuscles of some oviparous vertebrates:—

	Long diameter.	Short diameter.
Pigeon, - - - - -	0·0147	0·0065
Frog, - - - - -	0·0223	0·0157
Newt, - - - - -	0·0293	0·0195
Protelus, - - - - -	0·0580	0·0350
Amphiuma, - - - - -	0·0770	0·0460

by a membrane, and having a network of filaments traversing its interior (fig. 26). It is not very distinct in the unaltered corpuscle, but is brought clearly into view by the action of reagents, especially acetic acid. The action of reagents upon the red corpuscle of amphibia is otherwise similar to that produced upon the mammalian corpuscle, water and acetic acid causing it to swell into a globular form and then to become decolorised; solution of salt causing wrinkling of the envelope, and so on. The first effect of water and watery fluids is

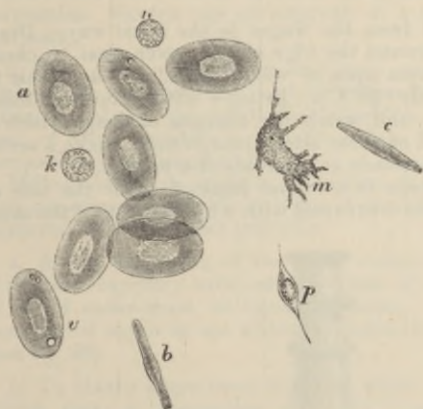


FIG. 25.—FROG'S BLOOD. (Ranvier.)

a, red corpuscle seen on the flat; *v*, vacuoles in a corpuscle; *b*, *c*, red corpuscles in profile; *k*, pale corpuscle at rest; *m*, pale corpuscle exhibiting amoeboid movements; *n*, nucleus which has become set free from a coloured corpuscle; *p*, colourless fusiform corpuscle.

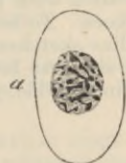


FIG. 26.—COLOURED CORPUSCLE OF SALAMANDER, SHOWING INTRANUCLEAR NETWORK. (Flemming.)

sometimes to drive the hæmoglobin away from the envelope at the points where the water is passing through this membrane: a stellate appearance is thereby often produced. Boracic acid also causes the hæmoglobin to be withdrawn from the envelope; it becomes partially or wholly collected around the nucleus, which may then be extruded from the corpuscle.

The colourless corpuscles (fig. 25, *k*, *m*), although larger, are very similar to those of mammals. Like them, they are either wholly pale and finely granular or inclose a number of very distinct granules of similar nature to those met with in mammals. These corpuscles vary much in size and in the activity of their amoeboid movements: those which have a multilobular nucleus (fig. 30) are usually the most active. Reagents have the same effect upon them as on those of mammals. The presence of glycogen may be demonstrated in them by its reaction with iodine (port-wine colour).

LESSON V.

*THE AMÆBOID PHENOMENA OF THE COLOURLESS
BLOOD-CORPUSCLES.*

1. MAKE a preparation of blood from the finger in the usual way. Draw a brush just moistened with oil around the edge of the cover-glass to check evaporation. Place the preparation upon a 'warm stage,' and heat this to about the temperature of the body (38° C.). Bring a white corpuscle under observation with the high power, and watch the changes of shape which it undergoes. To become convinced of these alterations in form, make a series of outline sketches of the same corpuscle at intervals of a minute.

The simplest form of warm stage is a copper plate of about the size of an ordinary slide, perforated in the centre and with a long tongue of the same



FIG. 27.—SIMPLE WARMING APPARATUS, COMPLETE, SHOWN IN OPERATION.

metal projecting from the middle of one edge (fig. 27). The copper plate rests upon the stage of the microscope with a piece of cloth or other non-conducting material between. The preparation is made upon an ordinary slide or on a large cover-glass, which is placed upon the warm stage and pressed into contact with it by the brass clips. Heat is applied to the copper

tongue by a small spirit-lamp flame, and a greater or less amount is conducted to the warm stage and the superjacent preparation according to the point to which the flame is applied. To ascertain that the right temperature is got and maintained, put two pieces of paraffin, one melting at 35° C. (95° F.) and another at 38° C. (100° F.), on either side of the preparation. The temperature must be such that the first piece is melted and remains so whilst the second remains unmelted.¹

2. Mount a drop of newt's blood diluted with an equal amount of salt solution, and examine it in the same manner upon the copper stage, at first cold, afterwards warm; the temperature must, however, be kept below 30° C. Observe the effect of heat in accelerating the amœboid movements of the pale corpuscles. Sketch one at intervals of a minute (*a*) in the cold, (*b*) whilst warmed.

3. Take some yeast which has been mixed with salt solution, and mix a little of the yeast and salt solution with a fresh drop of newt's blood, slightly oiling the edge of the cover-glass as before. Endeavour to observe the inception of the yeast-torulæ by the white corpuscles. Sketch one or two corpuscles containing torulæ.

Milk-globules or particles of carbon or of vermilion may also be used for this experiment, but the process of inception or "feeding" is most readily observed with the yeast particles.

4. At the beginning of the lesson collect a drop of newt's or frog's blood into a fine capillary tube, seal the ends of the tube, and mount it in a drop of oil of cedar-wood or Canada balsam. Towards the end of the lesson examine it again to see white corpuscles emigrating from the shrunken clot (see fig. 28).

5. To obtain a specimen with the white corpuscles fixed in amœboid condition, make a preparation of newt's blood, mixed with salt solution, and set it aside for ten minutes. By this time the corpuscles will be freely amœboid, and will probably show well-marked pseudopodia. To fix them in this condition let a jet of steam from a flask or kettle play for two or three seconds upon the cover-glass. The heat instantly kills the corpuscles, and they are fixed in the form they presented at the moment the steam was applied. They may now be stained by passing dilute hæmalum under the cover-glass, or by removing the latter and staining with eosin and methylene blue in the manner recommended in Lesson II. § 5. If hæmalum be used, the stain is followed by dilute glycerine, after which the cover may be cemented and the preparation kept.

The amœboid phenomena which are exhibited by the protoplasm of the colourless blood-corpuscles consist, in the first place, of spontaneous changes of form, produced by the throwing out of processes or *pseudopodia* in various directions. When first thrown out the pseudopodia are composed of hyaloplasm alone, and they are probably produced by a flowing of the hyaloplasm out of the meshes of the spongioplasm (see p. 2). If the corpuscle is stimulated, either mechanically, as by tapping the cover-glass, or electrically, the hyaloplasm is withdrawn again into the spongioplasm, and the pseudopodia are thereby retracted, the corpuscle becoming spherical. A change of

¹For exact work, an apparatus somewhat more complex than the above is required. For description of such, see *A Course of Practical Histology*.

form caused by the protrusion of the pseudopodia, may, when active, be followed by changes in place or actual locomotion (migration) of the corpuscle. When a pseudopodium, or the external surface of the corpuscle, comes in contact with any foreign particle, the protoplasm tends to flow round and enwrap the particle, and particles thus incepted may then be conveyed by the corpuscle in its locomotory changes from one place to another. This property appears to play an important part in many physiological and pathological processes.



FIG. 28.—WHITE CORPUSCLES OF FROG'S BLOOD MIGRATING FROM SHRUNKEN CLOT WITHIN A CAPILLARY TUBE. (From Sanderson's Handbook for the Physiological Laboratory.)

It is probable that particles of organic matter which are taken up by the pale corpuscles may undergo some slow process of intracellular digestion within their protoplasm.

The processes of the granular corpuscles are generally quite clear at first, and the granules afterwards flow into them.

The migration of the colourless corpuscles from the blood-vessels into the surrounding tissue, or from a blood-clot into the surrounding serum (fig. 28), is owing to these amoeboid properties.

The conditions which are most favourable to this amoeboid activity

of the white corpuscles are (1) the natural slightly alkaline medium, such as plasma, serum, or lymph, or faintly alkaline normal saline solution. Any increase of density of the medium produces a diminution of amœboid activity, whilst, on the other hand, a slight decrease in its density has the opposite effect; (2) a certain temperature. In

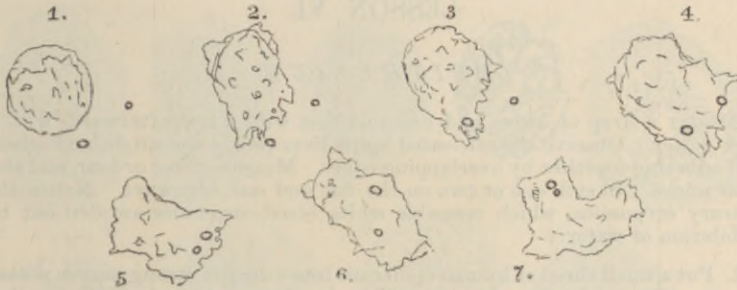


FIG. 29.—CHANGES OF FORM OF A WHITE CORPUSCLE OF NEWT'S BLOOD, SKETCHED AT INTERVALS OF A FEW MINUTES, SHOWING THE INCEPTION OF TWO SMALL GRANULES AND THE CHANGES OF POSITION THESE UNDERWENT WITHIN THE CORPUSCLE.

warm-blooded animals the phenomena cease below about 10° C. When gradually warmed the white corpuscles become more and more active up to a certain point, the maximum being a few degrees above the natural temperature of the blood. Above this point they become

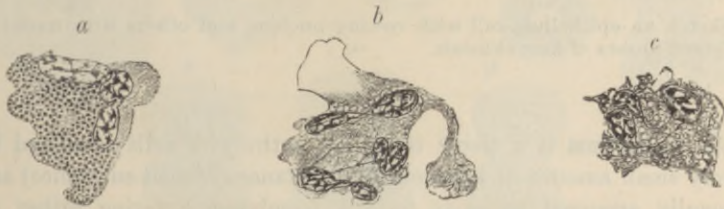

FIG. 30.—THREE AMEBOID WHITE CORPUSCLES OF THE NEWT, KILLED BY INSTANTANEOUS APPLICATION OF STEAM.

a, a coarsely granular cell; *b*, *c*, ordinary finely granular cells. The nuclei appear multiple, but are seen to be connected by fine filaments of chromoplasm traversing the protoplasm.

spheroidal and at a somewhat higher temperature their protoplasm is coagulated and killed. Acids at once kill the corpuscles and stop the movements. Narcotic gases and vapours, such as carbonic acid gas or chloroform vapour, also arrest the movement, but it recommences after a time if their action is discontinued.

LESSON VI.

EPITHELIUM.

1. MOUNT a drop of saliva and examine first with a low, afterwards with a high power. Observe the nucleated epithelium-cells, some single, and others still adhering together by overlapping edges. Measure three or four, and also their nuclei. Sketch one or two on the flat and one edgewise. Notice the salivary corpuscles, which resemble white blood-corpuscles swollen out by imbibition of water.

2. Put a small shred of human epidermis into a drop of strong caustic potash solution (20 p.c.) for five minutes. Then break it up in water with needles, cover and examine. Observe the now isolated swollen cells. Measure some.

3. Study the arrangement of the cells in a section through some stratified epithelium, such as that of the mouth, skin, or cornea.¹ Notice the changes in shape of the cells as they are traced towards the free surface. Measure the thickness of the epithelium. Count the number of layers of cells.

4. Study the minute structure of epithelium-cells and their nuclei, both at rest and dividing, in sections of the skin of the newt's tail or in shreds of peritoneum or epidermis of the salamander-tadpole. The preparation may, for this purpose, be stained either with hæmatoxylin or with some aniline dye such as safranin.²

Sketch an epithelium-cell with resting nucleus, and others with nuclei in different phases of karyokinesis.

An **epithelium** is a tissue composed entirely of cells separated by a very small amount of intercellular substance (cement-substance) and generally arranged so as to form a membrane covering either an external or an internal free surface.

The structure of epithelium-cells, and the changes which they undergo in cell-division, are best seen in the epidermis of the newt or of the salamander-tadpole; in the latter especially, the cells and nuclei are much larger than in mammals.

Structure of the cells.—Each epithelium-cell consists of *protoplasm* containing a *nucleus*. The protoplasm may either look granular, or it may have a reticulated appearance. In some kinds of epithelium it

¹The methods of preparing sections are given in the Appendix.

²A method which serves the purpose of exhibiting the division of nuclei is given in the Appendix.

is striated. The nucleus is a round or oval vesicle lying in the protoplasm. Usually there is only one, but there may be two or more. The cell-substance is often modified in its chemical nature; its external layer may become hardened to form a sort of membrane, or the whole cell may become horny (keratinised); or the cell may develop fibrils

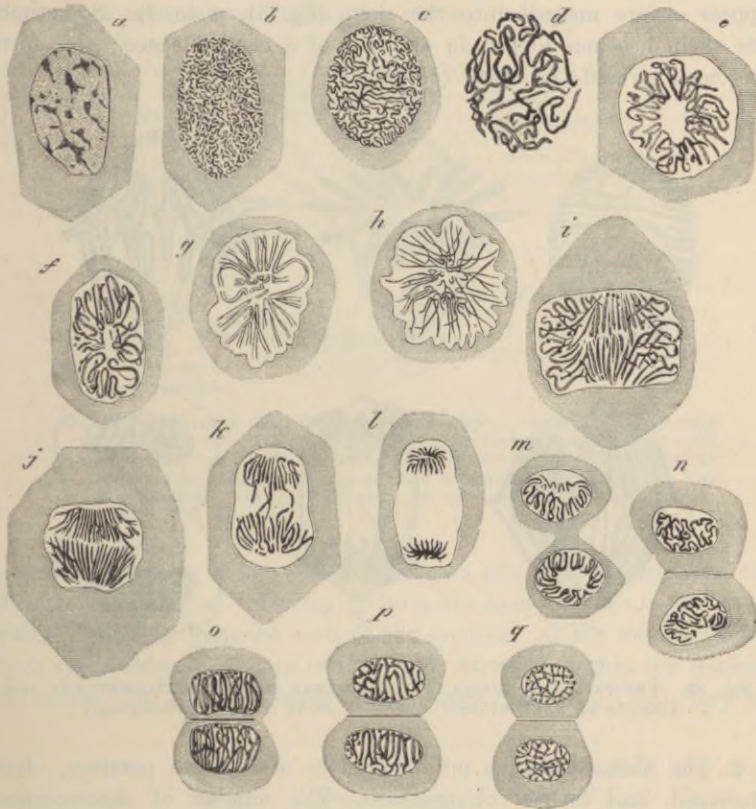


FIG. 31.—EPITHELIUM-CELLS OF SALAMANDER LARVA IN DIFFERENT PHASES OF DIVISION BY KARYOKINESIS. (Flemming.)

within it, and passing from it into adjacent cells, or lastly, there may be a separation of materials within the cell which are ultimately either used by the organism, as in the ordinary secreting glands, or eliminated as waste products as in the kidney.

Division of the cells.—The division of a cell is preceded by the division of its attraction-sphere, and this again appears to determine the division of the nucleus. The latter, in dividing, passes through

a series of remarkable changes (figs. 31, 32), which may thus be briefly summarised:—

1. The network of chromoplasm-filaments of the resting nucleus becomes transformed into a sort of *skein*, formed apparently of one long convoluted filament, but perhaps in reality of a number of filaments (fig. 32, *A*); the nuclear membrane and the nucleoli disappear or are merged into the skein (fig. 31, *a* to *d*). Sometimes the skein becomes looped in and out of a central space; this form has been termed the *rosette* (*e*).

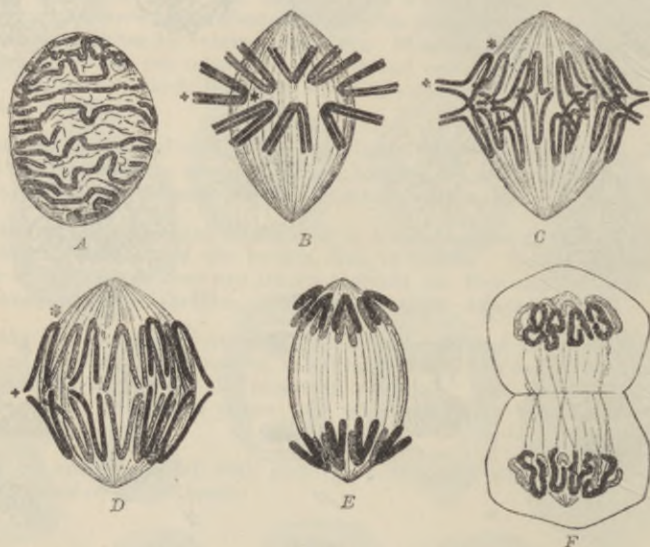


FIG. 32.—THE PRINCIPAL PHASES OF THE NUCLEAR CHROMATIN FILAMENTS IN THE PROCESS OF KARYOKINESIS SHOWN IN MORE DETAIL. (Flemming.)

2. The filament breaks into a number of separate portions, often V-shaped, and termed *chromosomes*. The number of chromosomes varies with the species of animal; in some animals the dividing nuclei may contain at this stage only four chromosomes, in others twenty-four or more. As soon as they become distinct they are usually arranged radially like a star (*astroid*, fig. 31, *f*, *g*; fig. 32, *B*).

3. Each of the chromosomes splits longitudinally into two, so that they are now twice as numerous as before (*stage of cleavage*, fig. 31, *g*, *h*). This longitudinal cleavage may occur at an earlier stage.

4. The fibres separate into two groups, the ends being for a time interlocked (*stage of metakinesis*, fig. 31, *i*, *j*, *k*; fig. 32, *C*, *D*).

5. The two groups pass to the opposite poles of the now elongated

nucleus and form a star-shaped figure at each pole (*dyastroid*, fig. 31, *l*; fig. 32, *E*). Each of the stars represents a daughter-nucleus.

6, 7, 8. Each star of the dyastroid goes through the same changes as the original nucleus, but in the reverse order—viz. a skein, at first more open and rosette-like (fig. 31, *m*; fig. 32, *F*), then a closer skein (fig. 31, *n*), then a network (fig. 31, *o*, *p*, *q*); passing finally into the typical reticular condition of a resting nucleus.

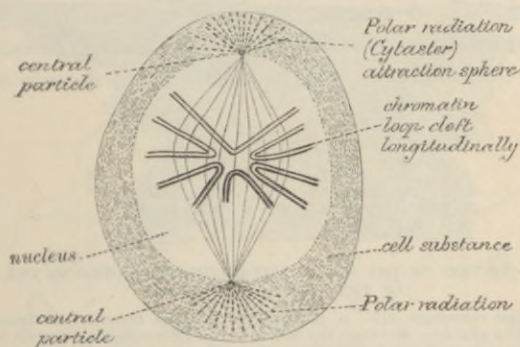


FIG. 33.—A DIVIDING CELL, SHOWING ATTRACTION-PARTICLE AT EITHER POLE OF NUCLEUS FROM WHICH THE GRANULES OF THE PROTOPLASM ARE SEEN RADIATING, AND WITH WHICH ALSO THE SPINDLE-SHAPED SYSTEM OF ACHROMATIC FIBRES TRAVERSING THE NUCLEUS IS CONNECTED. THE CHROMOSOMES, SIX IN NUMBER, ARE ARRANGED ASTRALLY AT THE EQUATOR OF THE SPINDLE. (Rabl.)

The protoplasm of the cell divides soon after the formation of the dyastroid (fig. 31, *m*). During division fine lines are seen in the protoplasm, radiating from the ends of the nucleus. Other lines produced by a spindle-shaped system of *achromatic* fibres lie within the nucleus, diverging from the poles towards the equator (figs. 32, 33, 34); they are

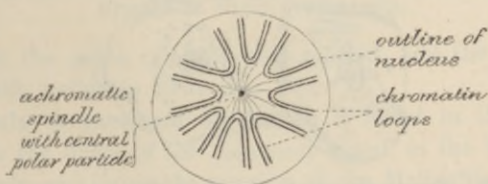

FIG. 34.—A NUCLEUS AT A STAGE SIMILAR TO THAT SHOWN IN THE LAST FIGURE, BUT SEEN FROM ONE OF THE POLES INSTEAD OF IN PROFILE. THE SPINDLE IS REPRESENTED FORESHORTENED. EIGHT CHROMOSOMES ARE REPRESENTED. (Rabl.)

usually less easily seen than the other or *chromatic* fibres, but are not less important, for they are derived from the achromatic spindle of the attraction-spheres, which, as we have seen, always initiate the division

of a cell (fig. 4). Moreover, the achromatic fibres within the nucleus appear to form guides along which the chromosomes or chromoplasmic filaments are conducted towards its poles.

Classification of epithelia.—Epithelia are classified according to the shape and arrangement of the component cells. Thus we speak of *scaly* or *pavement*, *cubical*, *columnar*, *polyhedral*, and *spheroidal* epithelium. All these are *simple* epithelia, with the cells only one layer deep. If

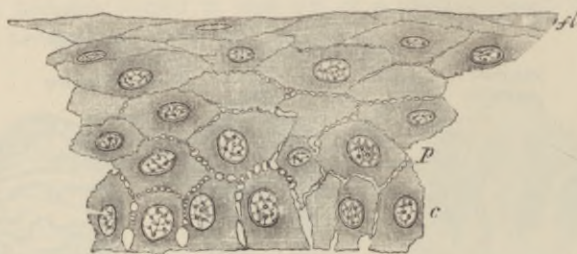

FIG. 35.—SECTION OF THE STRATIFIED EPITHELIUM COVERING THE FRONT OF THE CORNEA OF THE EYE.

c, lowermost columnar cells; *p*, polygonal cells above these; *fl*, flattened cells near the surface. Between the cells are seen intercellular channels bridged over by processes which pass from cell to cell.

forming several superposed layers, the epithelium is said to be *stratified*, and then the shape of the cells differs in the different layers. Where there are only three or four layers in a stratified epithelium, it is termed *transitional*.

Stratified epithelium covers the anterior surface of the cornea, lines the mouth, pharynx (lower part), and gullet, and forms the epidermis which covers the skin. In the female it lines the vagina and the neck of the uterus. The cells nearest the surface are always flattened

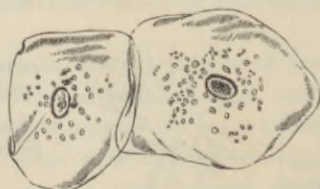

FIG. 36.—EPITHELIUM-SCALES FROM THE INSIDE OF THE MOUTH. (Magnified 260 diameters.)

and scale-like (fig. 35, *fl*; fig. 36), whereas the deeper cells are more rounded or polyhedral, and those of the deepest layer generally somewhat columnar in shape (fig. 35, *c*). Moreover, the deeper cells are soft and protoplasmic, and are separated from one another by a system of intercellular channels, which are bridged across by numerous

fibres passing from cell to cell, these giving the cells, when separated, the appearance of being beset with short spines (*prickle-cells* of Max Schultze).

Some of the deeper cells multiply by division, the nuclei first dividing in the manner already described. The newly formed cells tend as they enlarge to push those external to them nearer to the surface, from which they are eventually thrown off. As they approach the surface they become hard and horny, and in the case of the epidermis lose entirely their cellular appearance, which can, however, be in a measure restored by the action of potash (§ 2). The cast-off superficial cells of the stratified epithelium of the mouth, which are seen in

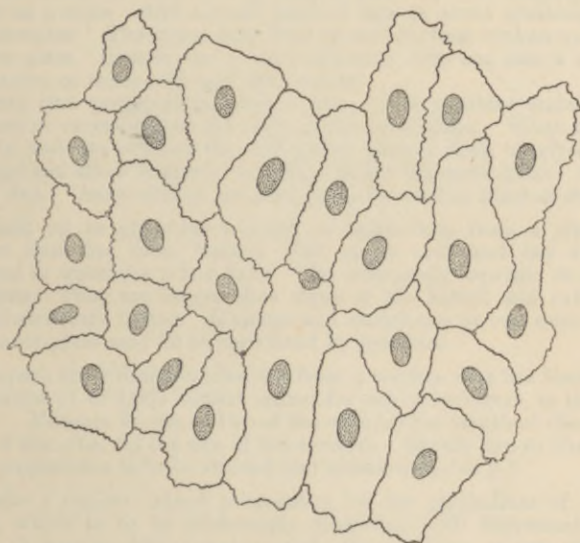


FIG. 37.—PAVEMENT EPITHELIUM OR ENDOTHELIUM OF A SEROUS MEMBRANE.
NITRATE OF SILVER PREPARATION.

abundance in the saliva (§ 1), are less altered, and the remains of a nucleus is still visible in them (fig. 36).

Simple scaly or **pavement epithelium** is found in the saccules of the lungs, in the ducts of the mammary gland, in the kidney (in the tubes of Henle, and lining the capsules of the Malpighian bodies), and also lining the cavities of serous membranes (fig. 37), and the interior of the heart, blood-vessels, and lymphatics. When occurring on internal surfaces, such as those of the serous membranes, blood-vessels, and lymphatics, it is often spoken of as **endothelium**.

Polyhedral or **spheroidal epithelium** is characteristic of many secreting glands, where it is often known from its function as *secreting*

or *glandular* epithelium. **Columnar epithelium** and **ciliated epithelium** are for the most part found covering the inner surface of mucous membranes; which are membranes moistened by *mucus* and lining passages in communication with the exterior, such as the alimentary canal and the respiratory and generative passages.

The detailed study of most of these may be reserved until the organs in which they occur are respectively described, but some will be dealt with in the next lessons.

The *hairs* and *nails* and the *enamel* of the teeth are modified epithelial tissues. They will be found described along with the skin and mouth respectively.

LESSON VII.

COLUMNAR AND CILIATED EPITHELIUM, AND
TRANSITIONAL EPITHELIUM.

1. TAKE a piece of rabbit's intestine which has been one or two days in chromic acid solution (1 part chromic acid to 2,000 normal saline solution). Scrape the inner surface with a scalpel, break up the scrapings in a drop of water on a slide. Add a small piece of hair to avoid crushing, and cover the preparation. The tissue may then be still further broken up by tapping the cover-glass. Sketch one or two columnar cells and also a row of cells. Measure two or three cells and their nuclei.

To keep this preparation, place a drop of very dilute staining solution (hæmalum or carmalum) at one edge of the cover-glass. When the stain has passed in and has stained the cell-nuclei, place a drop of glycerine at the same edge and allow it slowly to diffuse under the cover-glass. Cement this another day. Osmic acid (1 per cent.) may be used in place of stain.

2. Break up in glycerine a shred of epithelium from a piece of frog's intestine that has been treated with osmic acid, and has subsequently macerated in water for a few days. The cells easily separate on tapping the cover-glass. They are larger than those of the rabbit and exhibit certain points of structure better. Measure and sketch one or two cells.

The cover-glass may be at once fixed by gold size.

3. Prepare the ciliated epithelium from a trachea that has been in chromic acid solution (1 to 2,000 normal saline) for one or two days, in the same way as in § 1. Measure in one or two of the cells (*a*) the length of the cells, (*b*) the length of the cilia, (*c*) the size of the nucleus. Sketch two or three cells.

This preparation is to be stained and preserved as in § 1.

4. Make a similar teased preparation of the epithelium of the urinary bladder, which is to be moderately distended with bichromate of potash solution (1 part to 800 of water), and after an hour or two cut open and placed in more of the same solution. Observe the large flat superficial cells, and the pear-shaped cells of the second layer. Measure and sketch one or two of each kind. The cells will vary greatly in appearance according to the amount of distension of the organ.

Stain and preserve as in §§ 1 and 3.

All the above varieties of epithelium will afterwards be studied *in situ* when the organs where they occur come under consideration.

Columnar epithelium.—The cells of a columnar epithelium (fig. 38) are prismatic columns, which are set closely side by side, so that when seen from the surface a mosaic appearance is produced. They often taper somewhat towards their attached end, which is generally truncated, and set upon a basement membrane. Their free surface is covered by a thick striated border (fig. 39, *str*) which may sometimes

become detached in teased preparations. The protoplasm of the cell is highly vacuolated and reticular, and fine longitudinal striæ may be seen in it, which appear continuous with the striæ of the free border. The nucleus (*n*) is oval and reticular. The lateral borders of the cells

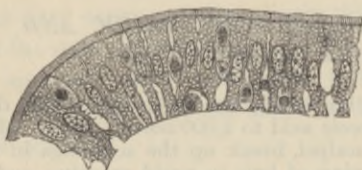

FIG. 38.

FIG. 38.—A ROW OF COLUMNAR CELLS FROM THE INTESTINE OF THE RABBIT. Smaller cells are seen between the epithelium-cells; these are lymph-corpuses.

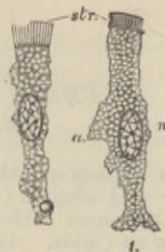

FIG. 39.

FIG. 39.—COLUMNAR EPITHELIUM-CELLS OF THE RABBIT'S INTESTINE.

The cells have been isolated after maceration in very weak chromic acid. The cells are much vacuolated, and one of them has a fat-globule adhering to it near its attached end; the striated border (*str*) is well seen, and the bright disk separating it from the cell-protoplasm; *n*, nucleus with intranuclear network; *a*, a thinned-out wing-like projection of the cell which probably fitted between two adjacent cells.

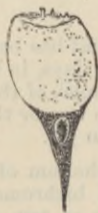

FIG. 40.—GOBLET-CELL FROM THE TRACHEA. (Klein.)

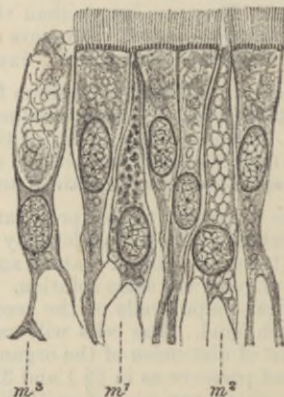

FIG. 41.—CILIATED COLUMNAR EPITHELIUM, FROM THE TRACHEA OF A RABBIT. *m*¹, *m*², *m*³, mucus-secreting cells in various stages of mucigen formation. The preparation was treated with dilute chromic acid in the manner recommended in the instructions for practical work.

are often somewhat irregular or jagged, the result of the presence of amœboid lymph-cells, which are generally found between the columnar cells, at least in the intestine. After a meal containing fat the cells may contain fat globules, which become stained black in the osmic preparation.

Columnar epithelium-cells are found lining the whole of the interior of the stomach and intestines: they are also present in the ducts of most glands, and sometimes also in their secreting tubes and saccules. The epithelium which covers the ovary also has a modified columnar shape, but cells having *all* the structural peculiarities indicated above are found only in the alimentary canal and in its diverticula.

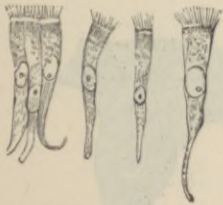

FIG. 42.—COLUMNAR CILIATED EPITHELIUM-CELLS FROM THE LOWER PART OF THE NASAL PASSAGES. EXAMINED FRESH IN SERUM. (Sharpey.)

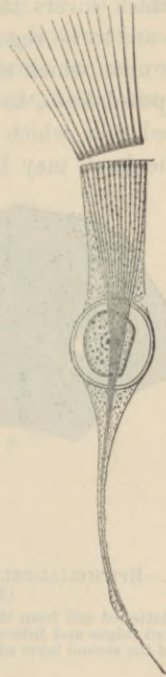

FIG. 43.—CILIATED CELL, FROM THE INTESTINE OF A MOLLUSC. (Engelmann.)

Goblet-cells.—Some columnar cells, and also cells of glandular, ciliated, and transitional epithelia, contain mucigen, which is laid down within the cell in the form of granules (fig. 41, m^1 , m^2) and may greatly distend the part of the cell nearest the free border. When the mucigen is extruded as mucus, this border is thrown off, and the cell takes the form of an open cup or chalice (fig. 40 and fig. 41, m^3).

These *goblet-cells*, or, as they may more appropriately be termed, *mucus-secreting cells*, are probably not mere temporary modifications of the ordinary columnar and ciliated cells amongst which they are found, but permanently differentiated cells, which, after having got rid of

their mucus by extrusion, again form a fresh supply in the same way as before.

Ciliated epithelium.—The cells of a ciliated epithelium are usually columnar in shape (figs. 41, 42), but in place of the striated border of the ordinary columnar cell the free surface is surmounted by a bunch of fine tapering filaments (*vibratile cilia*) which, during life, move spontaneously to and fro, and serve to produce a current in the fluid which covers them.

The *cilia* are to be regarded as prolongations of the cell-protoplasm. The border upon which they are set is bright, and appears formed of little juxtaposed *knobs*, to each of which a cilium is attached. In the large ciliated cells which line the alimentary canal of some molluscs (fig. 43), the knob may be observed to be prolonged into the proto-

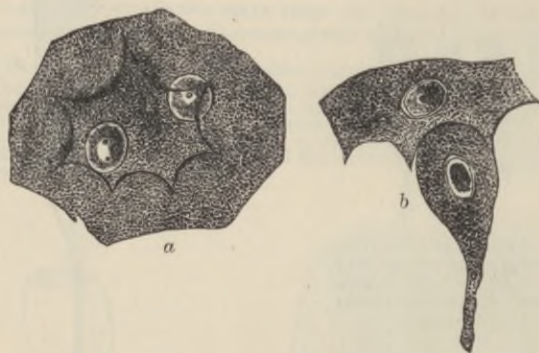


FIG. 44.—EPITHELIAL-CELLS FROM THE BLADDER OF THE RABBIT. (Klein.)
(Magnified 500 diameters.)


a, large flattened cell from the superficial layer, with two nuclei and with strongly marked ridges and intervening depressions on its under surface; *b*, pear-shaped cell of the second layer adapted to a depression on one of the superficial cells.

plasm of the cell as a fine varicose filament, termed the *rootlet* of the cilium. These filaments perhaps represent the longitudinal striæ often seen in the protoplasm of the columnar cell, the bunch of cilia being homologous with the striated border. The protoplasm and nucleus have a similar vacuolated and reticular structure in both kinds of cell.

Ciliated epithelium is found in man throughout the whole extent of the air-passages and their prolongations (but not in the part of the nostrils supplied by the olfactory nerves, nor in the lower part of the pharynx, nor in the terminal bronchioles); in the Fallopian tubes and the greater part of the uterus; in some of the efferent ducts of the testicle (where the cilia are longer than elsewhere in the body); in the ventricles of the brain, and the central canal of the

spinal cord; and, according to some authorities, in the convoluted tubules of the kidney.

Transitional epithelium is a stratified epithelium consisting of only two or three layers of cells. It occurs in the urinary bladder, the ureter, and the pelvis of the kidney. The superficial cells (fig. 44, *a*) are large and flattened; they often have two nuclei. On their under surface they exhibit depressions, into which fit the larger ends of pyriform cells, which form the next layer (fig. 44, *b*). Between the tapered ends of the pyriform cells one or two layers of smaller polyhedral cells are found. The epithelium seems to be renewed by division of these deeper cells, but it is not certain that the superficial cells do not also multiply.



LESSON VIII.

STUDY OF CILIA IN ACTION.

1. MOUNT in sea-water one or two bars of the gill of the marine mussel (fig. 45). Study the action of the large cilia. Now place the preparation upon the copper warm stage (see Lesson V.) and observe the effect of raising the temperature.

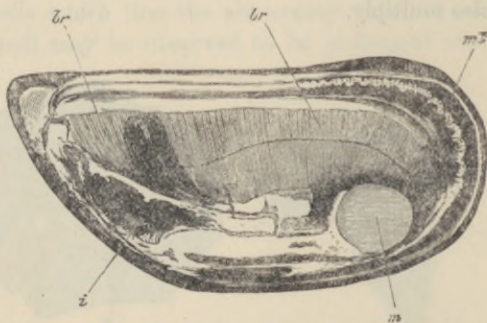


FIG 45.—VALVE OF MUSSEL (*MYTILUS EDULIS*) SHOWING *br, br*, THE EXPANDED GILLS OR BRANCHIÆ, WHICH, OWING TO THE LITTLE BARS OF WHICH THEY ARE COMPOSED, PRESENT A STRIATED ASPECT.

ml, mantle; *m*, cut adductor muscle; *i*, mass of viscera; the dark projection just above is the foot.

Keep this preparation until the end of the lesson, by which time many of the cilia will have become languid. When this is the case pass a drop of dilute potash solution (1 part KHO to 1,000 of sea-water) under the cover-glass and observe the effect.

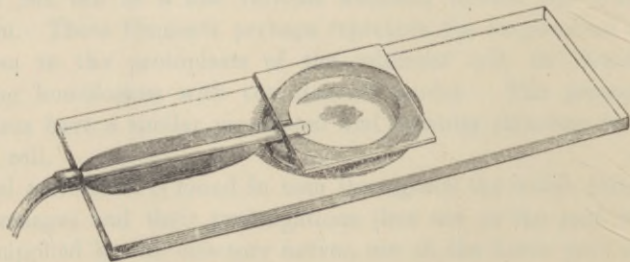


FIG. 46.—MOIST CHAMBER ADAPTED FOR PASSING A GAS OR VAPOUR TO A PREPARATION UNDER THE MICROSCOPE.

2. Cement with sealing-wax a piece of small glass tubing to a slide so that one end of the tube comes nearly to the centre of the slide. To do this

effectually the slide must be heated and some sealing-wax melted on to it and allowed to cool. The glass tube is then made hot and applied to the slide, embedding itself as it does so in the sealing-wax. On this put a ring of putty or modelling wax (half an inch in diameter and rising above the glass tube) so as to include the end of the tube. Make a deep notch in the ring opposite the tube. Place a small drop of water within the ring (fig. 46).

Put a bar from the gill upon a cover-glass in the least possible quantity of sea-water; invert the cover-glass over the putty ring, and press it gently down. The preparation hangs in a *moist chamber* within which it can be studied through the cover-glass, and into which gases or vapours can be passed and their effects observed.

Pass CO_2 through the chamber, and after observing the effect replace it by air (see fig. 47). Repeat with chloroform vapour instead of CO_2 .

The movement of cilia.—When in motion a cilium is bent quickly over in one direction with a lashing whip-like movement, immediately recovering itself. When vigorous the action is so rapid, and the rhythm so frequent (ten or more times in a second), that it is impossible to follow the motion with the eye. All the cilia upon a ciliated surface are not in action at the same instant, but the move-

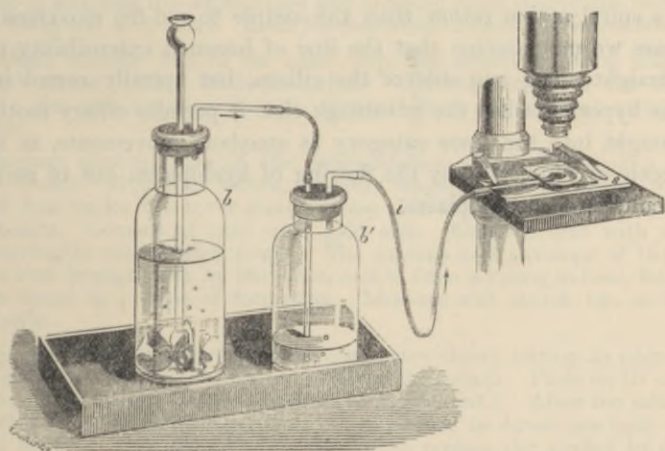


FIG. 47.—METHOD OF SUBJECTING A PREPARATION TO A STREAM OF CARBON-DIOXIDE.

b, bottle containing marble and hydrochloric acid; *b'*, wash-bottle, connected by indiarubber tube, *t*, with the moist chamber, *s*.

ment travels in waves over the surface. If a cell is detached from the general surface, its cilia continue to act for a while, but at once cease if they are detached from the cell.

The rhythm is slowed by cold, quickened by warmth; but heat beyond a certain point kills the cells. The movement will continue for some time in water deprived of oxygen. Both CO_2 gas and

chloroform vapour arrest the action, but it recommences on restoring air. Dilute alkaline solutions quicken the activity of cilia, or may even restore it shortly after it has ceased.

Various attempts have been made to explain the manner in which cilia act, some supposing that one side of each cilium is contractile, others that their movement is a passive one, and that the real movement is at their rootlets in the protoplasm of the cell. The latter supposition is, however, inadequate to explain the very considerable bend which active cilia exhibit; and the former is negatived by the fact that in rigor mortis the cilia are not bent over as they would be by the contraction which always accompanies rigor, but stand up straight. A third hypothesis assumes the cilia to be permanent processes of the cell protoplasm with a delicate limiting membrane, and ascribes the action to differences of pressure within the cilia caused by an alternate flowing and ebbing of hyaloplasm from the body of the cell into them; if we assume that one side of each cilium is less extensible than the other, it must necessarily be bent over by an increase of pressure in the manner usually observed. Some cilia have a spiral action rather than the simple to-and-fro movement; in this case we may assume that the line of lessened extensibility passes not straight along one side of the cilium, but spirally round it.

This hypothesis has the advantage that it permits ciliary motion to be brought into the same category as amœboid movements, in so far that both are explicable by the flowing of hyaloplasm out of and into a reticulum of spongioplasm.

LESSON IX.

THE CONNECTIVE TISSUES.

AREOLAR AND ADIPOSE TISSUE, RETIFORM TISSUE.

1. TAKE a little of the subcutaneous tissue or of the intermuscular connective tissue of a rabbit or guinea-pig and spread it out with needles on a dry slide into a large thin film. Keep the centre moist by occasionally breathing on it, but allow the edges to dry to the slide. Before commencing put a drop of salt solution on a cover-glass, and now invert this over the film. Examine with a high power. Sketch one or two bundles of white fibres and also one or two elastic fibres, distinguishable from the former by their sharp outline, isolated course, and by their branching. Sketch also one or more connective-tissue corpuscles, if any such are visible in the clear interspaces. Look also for migratory cells (lymph-corpuscles). Next carefully remove the cover-glass and replace the salt solution by dilute acetic acid (1 per cent.). Watch its effect in swelling the white fibres and bringing more clearly into view the elastic fibres and corpuscles. Look for constricted bundles of white fibres.

2. Make another film in the same way, but mount in dilute magenta solution¹ mixed with a little hæmalum. The elastic fibres are deeply stained; the cells are also shown. Cement the cover-glass at once with gold size.

3. Prepare another film of the subcutaneous tissue, including a little adipose tissue. Mount, as before, in dilute magenta and hæmalum, with a piece of hair under the cover-glass to keep this from pressing unduly upon the fat-cells. Cement at once with gold size. Examine first with a low and afterwards with a high power. The nucleus and envelope of the fat-cell are well brought out by the stain, and if from a young animal, fat-cells will be found in process of formation. Measure and sketch two or three of the cells.

4. Spread out another large film of connective tissue, letting its edges dry to the slide, but keeping the centre moist by the breath. Place on its centre a large drop of nitrate of silver solution (0.75 per cent.). After ten minutes, wash this away with distilled water, and expose to direct sunlight until stained brown. Then dehydrate with alcohol, replace the alcohol by clove-oil, and this by Canada balsam dissolved in xylol. Cover² and examine. Sketch the outlines of two or three of the cell-spaces.

5. Prepare a section of fresh lymphatic gland by a freezing microtome and immerse it for a few minutes in 0.5 per cent. solution of caustic potash, or in a pancreatic digestive fluid at 38° C. The alkali destroys the cells, and thus allows the network of fibres which compose the retiform tissue to be seen. They are in all respects like the fibrils of areolar tissue. The sections may be coloured with carmalum and mounted in glycerine.

¹See Appendix.

²Preparations which are mounted in Canada balsam solution will soon become fixed by the hardening of the Canada balsam at the edges of the cover-glass. They must on no account be cemented with gold size.

6. A better method of displaying the retiform tissue of a lymphatic gland or any other organ containing much of it is the following (Spalteholz). Place a piece of the organ for twenty-four hours or more in alcohol, then overnight in a 1 per cent. solution of carbonate of soda to which a few drops of glycerine extract of pancreas have been added. Cautiously transfer the semi-digested structure to alcohol again, and leave it for a few hours. Then stain by Heidenhain's process,¹ prepare sections and mount them in Canada balsam. The fibrils of connective and retiform tissue are the only structures which have remained undigested and they are deeply coloured by the hæmatoxylin.

The **connective tissues** include *areolar* tissue, *adipose* tissue, *elastic* tissue, *fibrous* tissue, *retiform* and *lymphoid* tissue, *cartilage* and *bone*. All these tissues agree in certain microscopical and chemical characters. They, for the most part, have a large amount of intercellular substance in which fibres are developed, and these fibres are of two kinds—*white* and *yellow or elastic*. Moreover, there are many points of similarity between the cells which occur in these tissues; they are all developed from the same embryonic formation, and they tend to pass imperceptibly the one into the other. Besides this, the use of these several tissues is everywhere similar; they serve to connect and support the other tissues, performing thus a passive mechanical function. They may therefore be grouped together, although differing considerably in external characters. Of the connective tissues, however, there are three which are so intimately allied as to be naturally considered together, being composed of exactly the same elements, although differing in the relative development of those elements: these are the areolar, elastic, and fibrous tissues. Adipose tissue and retiform tissue may both be looked upon as special modifications of areolar tissue. Areolar tissue being the commonest and, in a sense, the most typical, its structure may be considered first.

Areolar tissue.—The areolar tissue presents to the naked eye an appearance of fine transparent threads and laminae which intercross in every direction with one another, leaving intercommunicating meshes, or areolæ, between them. When examined with the microscope, these threads and fibres are seen to be principally made up of wavy bundles of exquisitely fine transparent fibres (*white fibres*, fig. 48). The bundles run in different directions, and may branch and intercommunicate with one another; but the individual fibres, although they pass from one bundle to another, never branch or join other fibres. The fibres are cemented together into the bundles by a clear substance containing mucin, and the same clear material forms also the basis or *ground-substance* of the tissue, in which the bundles themselves course, and in which also the corpuscles of the tissue lie embedded. This ground-

¹ See Appendix.

substance between the bundles can with difficulty be seen in the fresh tissue on account of its extreme transparency; but it can be brought to view by staining with nitrate of silver, as in § 4. The whole of the tissue is thereby stained of a brown colour, with the exception of the spaces which are occupied by the corpuscles (*cell-spaces*, fig. 49).

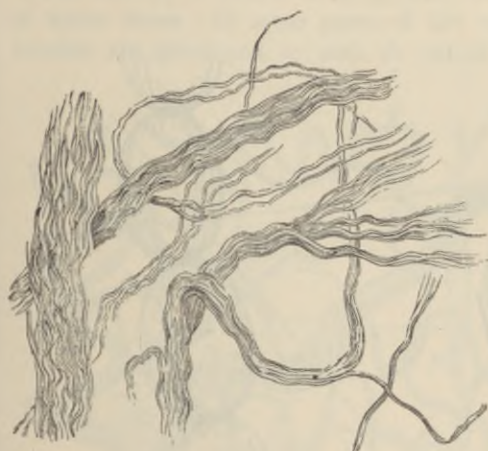


FIG. 48.—BUNDLES OF THE WHITE FIBRES OF AREOLAR TISSUE PARTLY UNRAVELLED. (Sharpey.)



FIG. 49.—GROUND SUBSTANCE OF CONNECTIVE TISSUE STAINED BY SILVER. (The cell-spaces are left white.)

Besides the white fibres of connective tissue here described, fibres of a different kind (fig. 50) may be made out in the preparations; these are the *elastic fibres*. They are especially well seen after treatment with acetic acid, and after staining with magenta, or, in sections, with orcein; but they can be detected also in the fresh preparation. They are characterised by their distinct outline, their straight course, the fact that they never run in bundles, but singly, and that they branch and join neighbouring fibres. If broken by the needles in making the preparation, the elastic recoil causes them to curl up, especially near the broken ends. Besides the microscopical differences, the two kinds of fibres differ also in their chemical characters. Thus the white fibres are dissolved by boiling in water, and yield gelatin, but are not dissolved by tryptic digestion; whereas the substance of which the elastic fibres are composed (*elastin*) resists for a long time the action of boiling water, although it is dissolved by tryptic digestion. Moreover, the white fibres swell and become indistinct under the action of acetic acid; the elastic fibres are unaltered by this reagent.

The bundles of white fibres which have been swollen out by acid sometimes exhibit curious constrictions (fig. 51). These are due either to elastic fibres coiling round the white bundles, or to cell-processes encircling them, or to an investment or sheath which remains unbroken at certain parts, and thus prevents the swelling up of the bundle at these places.

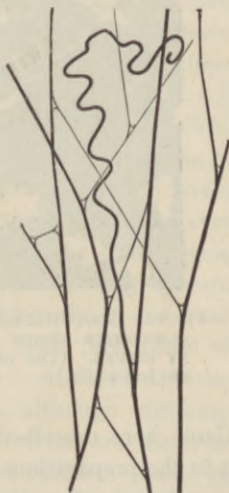


FIG. 50.—ELASTIC FIBRES OF AREOLAR TISSUE. FROM THE SUBCUTANEOUS TISSUE OF THE RABBIT.

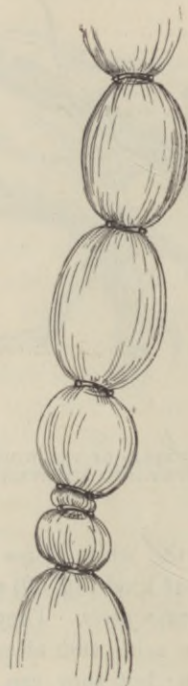

FIG. 51.—A WHITE BUNDLE SWOLLEN BY ACETIC ACID. FROM THE SUBARACHNOID TISSUE AT THE BASE OF THE BRAIN. (From Toldt.)

The cells of areolar tissue.—Several varieties of connective-tissue cells are distinguished, viz.: (1) Flattened *lamellar-cells*, which are often branched (fig. 52, *c*, *c'*) and may be united one to the other by their branches, as in the cornea, or are unbranched and joined edge to edge like the cells of an epithelium; the cell-spaces have in all cases a similar arrangement. (2) *Plasma-cells* of Waldeyer (fig. 52, *p*), which are composed of a soft much-vacuolated protoplasm, rarely flattened, but otherwise varying greatly in shape and size. (3) *Granule-cells* (*g*), usually spheroidal or ovoidal in shape, and formed, like the plasma-cells, of soft

protoplasm, but thickly occupied with albuminous granules, which are deeply stained by eosin and by some other aniline dyes. Migratory lymph-corpuscles may also be seen here and there in the areolar tissues (*wander-cells*). In the middle coat of the eye the connective-tissue cells are filled with granules of pigment (*pigment-cells*).

The cells lie in spaces in the ground-substance between the bundles of white fibres. In some parts of the connective tissue the white bundles are developed to such an extent as to pervade almost the

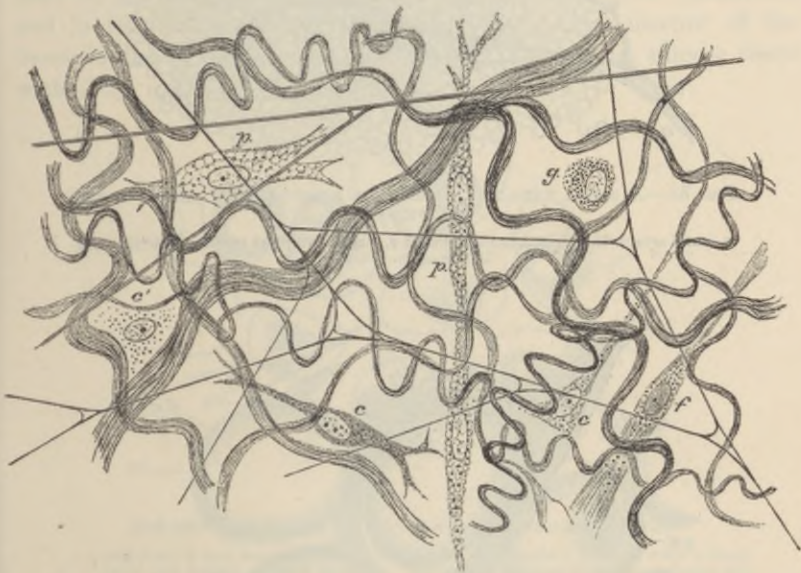


FIG. 52.—SUBCUTANEOUS TISSUE FROM A YOUNG RABBIT, PREPARED AS DIRECTED IN § 1. (Highly magnified.)

The white fibres are in wavy bundles; the elastic fibres form an open network. *p, p*, plasma-cells; *g*, granule-cell; *c, c'*, lamellar-cells; *f*, fibrillated-cell.

whole of the ground-substance, and then the connective-tissue corpuscles become squeezed into the interstices, flattened lamellar expansions of the cells extending between the bundles, as in tendon (see next Lesson).

The cells and cell-spaces of areolar tissue come into intimate relation with the cells lining the lymphatic vessels and small blood-vessels. This connection can best be seen in silvered preparations; it will be again referred to in speaking of the origin of the lymphatics.

Adipose tissue consists of vesicles filled with fat (figs. 53, 54), and collected into lobules, or into tracts which accompany the small blood-vessels. The vesicles are round or oval in shape, except where closely

packed, when they become polyhedral from mutual compression. The fat-drop is contained within a delicate protoplasmic envelope (fig. 54, *m*) which is thickened at one part, and here includes an oval flattened

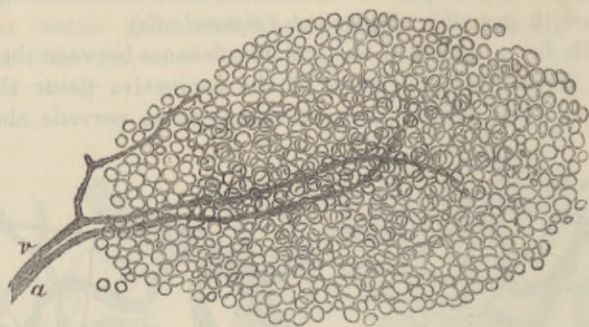


FIG. 53.—A SMALL FAT-LOBULE FROM THE SUBCUTANEOUS TISSUE OF THE GUINEA-PIG.

a, small artery distributed to the lobule; *v*, small vein; the capillaries within the lobule are not visible.

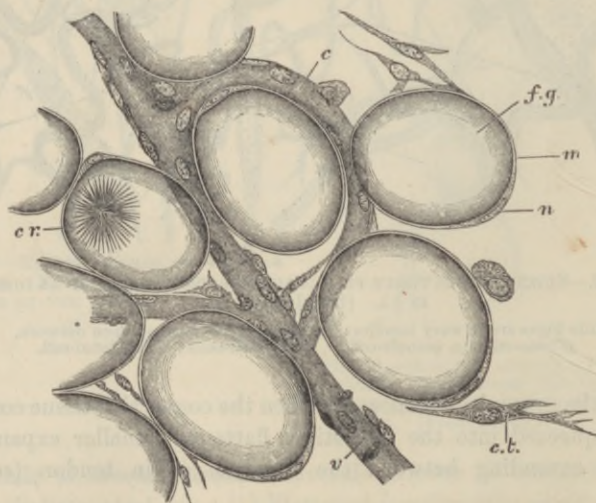


FIG. 54.—A FEW CELLS FROM THE MARGIN OF A FAT-LOBULE.

f.g. fat-globule distending a fat-cell; *n*, nucleus; *m*, membranous envelope of the fat-cell; *c r.* bunch of crystals within a fat-cell; *c*, capillary vessel; *v*, venule; *c.t.* connective-tissue cell; the fibres of the connective-tissue are not represented.

nucleus. The fat is stained of an intense black by osmic acid. The vesicles are supported partly by filaments of areolar tissue, but chiefly by a fine network of capillary blood-vessels.

The fat when first formed is deposited within granular cells of areolar tissue (fig. 55). It appears to be produced by a transformation of albuminous granules into droplets of fat. As these droplets increase in size they run together into a larger drop, which gradually fills the cell more and more, swelling it out so that the cell-protoplasm eventually appears merely as the envelope of the fat-vesicle.

Fat is found most abundantly in subcutaneous areolar tissue, and under the serous membranes; especially in some parts, as at the back of the peritoneum around the kidneys, under the epicardium, and in the mesentery and omentum. The yellow marrow of the bones is also principally composed of fat. There is no adipose tissue within the cavity of the cranium.

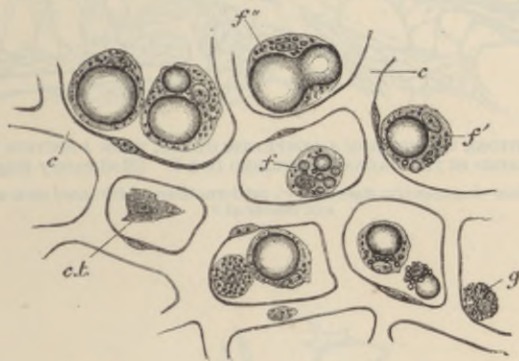

FIG. 55.—DEPOSITION OF FAT IN CONNECTIVE-TISSUE CELLS.

f, a cell with a few isolated fat-droplets in its protoplasm; *f'*, a cell with a single large and several minute drops; *f''*, fusion of two large drops; *g*, granular cell, not yet exhibiting any fat-deposition; *c.t.* flat connective-tissue corpuscle; *c*, *c*, network of capillaries.

Retiform or **reticular tissue** (figs. 56, 57) is a variety of connective tissue in which the intercellular or ground-substance has mostly disappeared or is replaced by fluid. There are very few or no elastic fibres in it, and the white fibres and bundles of fibres form a dense network, the meshes of which vary in size, being very small and close in some parts; more open and like areolar tissue in other parts. In some places where the tissue occurs the fibres are almost everywhere enwrapped by flattened branched connective-tissue cells, and until these are removed it is not easy to see the fibres. Chemical differences have been stated to occur between the fibres of retiform tissue and those of ordinary areolar tissue, but these are doubtful, and it is certain that microscopically the two kinds of fibres are indistinguishable.

Lymphoid or adenoid tissue is retiform tissue in which the meshes of the network are largely occupied by lymph-corpuses. This is by far the most common condition of a retiform tissue, and is met with in the lymphatic glands and allied structures, and also in the tissue of the alimentary mucous membrane, and in some other situations.

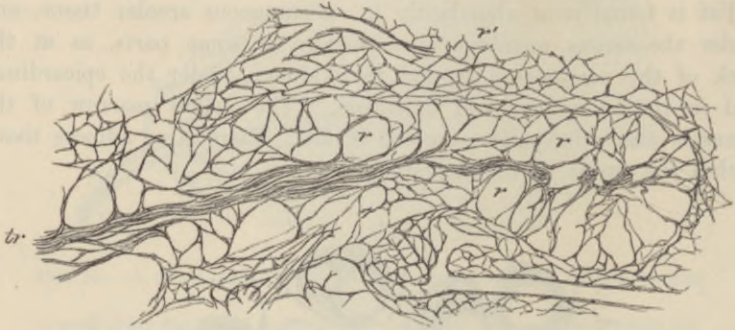


FIG. 56.—RETIFORM TISSUE FROM A LYMPHATIC GLAND, FROM A SECTION WHICH HAS BEEN TREATED IN THE MANNER DESCRIBED IN § 5. (Moderately magnified.)

tr, a trabeculum of connective tissue; *r*, *r'*, retiform tissue, with more open meshes at *r* and denser at *r'*.

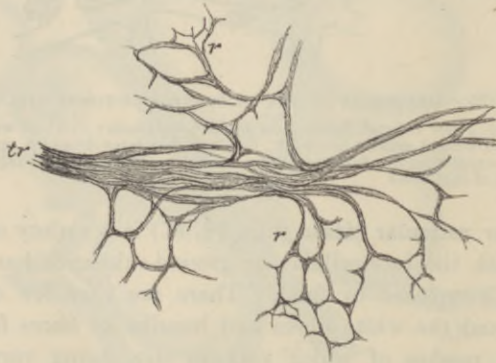


FIG. 57.—PORTION OF THE ABOVE, MORE HIGHLY MAGNIFIED.

Basement-membranes (*membranæ propriae*) are homogeneous-looking membranes, which are found forming the surface-layers of connective-tissue expansions in many parts, especially where there is a covering of epithelium, as on mucous membranes, in secreting glands, and elsewhere. They are generally formed of flattened connective-tissue cells joined together to form a membrane; but in some cases they are

evidently formed not of cells, but of condensed ground-substance, and in others they are of an elastic nature.

Jelly-like connective tissue, although occurring largely in the embryo, is found only in one situation in the adult—viz. forming the vitreous humour of the eye. It seems to be composed mainly of soft ground-substance, with cells scattered here and there through it, and with very few fibres, or none at all. These several varieties of connective tissue will be more fully described in connection with the organs where they occur.

1. Examine a thin transverse section of the vitreous body of a frog (Rana temporaria) which has been preserved in 2 per cent solution of iodine in alcohol. The section is to be stained with iodine and mounted on a slide glass. Note the large well-defined glass concretions (hyaline bodies) and the smaller, more numerous, faintly stained granules on the surface. Note the presence of small, dark, spindle-shaped cells which are distributed throughout the elastic tissue.

2. Examine a thin transverse section of the vitreous body of a frog which has been preserved in 2 per cent solution of iodine in alcohol. The section is to be stained with iodine and mounted on a slide glass. Note the large well-defined glass concretions (hyaline bodies) and the smaller, more numerous, faintly stained granules on the surface. Note the presence of small, dark, spindle-shaped cells which are distributed throughout the elastic tissue.

3. Place off the end of the tail of a dead rabbit (Lepus) and cut the tail into three parts. The longest part is to be stained with iodine and mounted on a slide glass. The middle part is to be stained with iodine and mounted on a slide glass. The shortest part is to be stained with iodine and mounted on a slide glass. Note the presence of small, dark, spindle-shaped cells which are distributed throughout the elastic tissue.

4. Place under two other pieces of tendon and after washing them in distilled water stain them with a stain as before. Then the stain is to be washed off and a drop of water is to be added. Then wash the preparation with distilled water and express the slide to draw out a very few fibres. Note the presence of small, dark, spindle-shaped cells which are distributed throughout the elastic tissue.

LESSON X.

THE CONNECTIVE TISSUES (continued).

ELASTIC TISSUE, FIBROUS TISSUE, DEVELOPMENT OF CONNECTIVE TISSUE.

1. TEASE out as finely as possible a small shred of elastic tissue (ligamentum nuchæ of the ox or ligamenta subflava of man) in glycerine and water, slightly coloured by magenta. Cover and cement the preparation. Note the large well-defined fibres constantly branching and uniting with one another. Look for transverse markings on the fibres. Measure three or four. Sketch a small part of the network. Note the existence of bundles of white fibres amongst the elastic fibres.
2. Examine a thin transverse section of ligamentum nuchæ which has been hardened in 2 per cent. solution of bichromate of potash. The section is to be stained with hæmalum and mounted in Canada balsam by the usual process,¹ or simply in glycerine and water. Observe the grouping of the fibres and their angular shape. Notice also the nuclei of connective-tissue cells amongst the fibres. Sketch one or two groups.
3. Pinch off the end of the tail of a dead mouse or rat, draw out the long silk-like tendons and put them into salt solution. Take two of the longest threads and stretch them along a slide, letting the ends dry firmly to the slide but keeping the middle part moist. Put a piece of hair between them and cover in salt solution. Observe with a high power the fine wavy fibrillation of the tendon. Draw. Now run dilute acetic acid (0.75 per cent.) under the cover-glass, watch the tendons where they are becoming swollen by the acetic acid. Notice the oblong nucleated cells coming into view between the tendon bundles. Sketch three or four cells in a row. Lastly, lift the cover-glass, wash away the acid with distilled water, place a drop of Ehrlich's hæmatoxylin or carmalum solution on the tendons, and leave the preparation until it is deeply stained; then wash away the stain and mount the preparation in faintly acidulated glycerine. Cement the cover-glass with gold size.
4. Take one or two other pieces of tendon, and after washing them in distilled water, stretch them upon a slide as before, fixing the ends by allowing them to dry on to the slide. Put a drop of nitrate of silver solution (0.75 per cent.) on the middle of the tendons, and leave it on for five minutes, keeping the preparation in the dark. Then wash off the silver nitrate with distilled water, and expose the slide to direct sunlight. In a very few minutes the silvered part of the tendons will be brown. As soon as this is the case, dehydrate the tendons with alcohol *in situ* upon the slide, run off the alcohol, and at once put a drop of clove oil on the preparation. In a minute or two the clove-oil can be replaced by xylol balsam and covered.
5. Stain with magenta solution a thin section of a tendon which has been hardened in 70 per cent. alcohol. Mount in dilute glycerine and cement the cover-glass at once. Sketch a portion of the section under a low power.

Elastic tissue is a variety of connective tissue in which the elastic fibres preponderate. It is found most characteristically in the ligamentum nuchæ of quadrupeds and the ligamenta subflava of the vertebræ, but the connective tissue of other parts may also have a considerable development of elastic fibres. It occurs in an almost pure form in the walls of the air-tubes, and uniting the cartilages of the larynx. It also enters largely into the formation of the lungs and of the walls of the blood-vessels, especially the arteries.

In the ligamentum nuchæ the fibres are very large and angular (fig. 58); they often exhibit cross-markings or even transverse clefts.

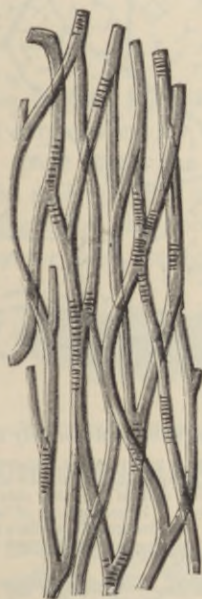

FIG. 58.—ELASTIC FIBRES FROM THE LIGAMENTUM NUCHÆ OF THE OX, SHOWING TRANSVERSE MARKINGS ON THE FIBRES.

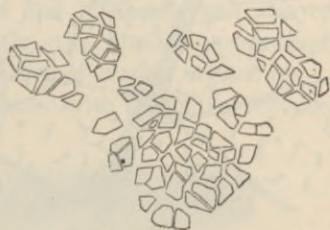


FIG. 59.—CROSS-SECTION OF ELASTIC FIBRES FROM THE LIGAMENTUM NUCHÆ OF THE OX.

When dragged asunder, they break sharply across; they constantly branch and unite, so as to form a close network. In transverse section they are seen to be separated into small groups (fig. 59) by intervening white bundles of connective tissue.

Elastic tissue does not always take the form of fibres, but may occur as membranes (as in the blood-vessels). Sometimes the fibres are very small, but their microscopical and chemical characters are always very well marked (see p. 45).

Fibrous tissue is almost wholly made up of bundles of white fibres running in a determinate direction. These again are collected into

larger bundles, which give the fibrous appearance to the tissue. The bundles are constantly uniting with one another in their course, although their component fibres remain perfectly distinct.

The interspaces between the larger bundles are occupied by areolar tissue (fig. 60) in which the blood-vessels and lymphatics of the fibrous

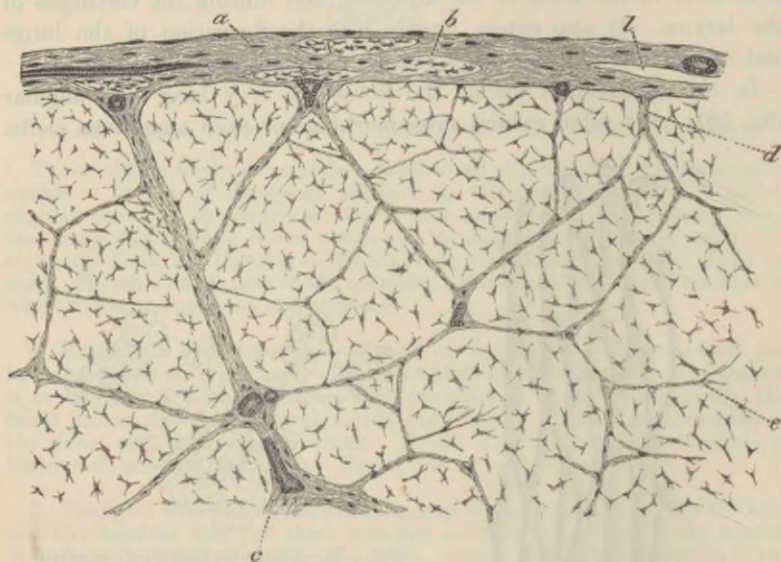


FIG. 60.—PART OF A LARGE TENDON IN TRANSVERSE SECTION. (Moderately magnified.)

a, areolar sheath of the tendon, with the fibres for the most part running transversely; but with two or three longitudinal bundles, *b*; *l*, lymphatic cleft in the sheath; immediately over it a blood-vessel is seen cut across, and on the other side of the figure a small artery is shown cut longitudinally; *c*, large septum of areolar tissue; *d*, smaller septum; *e*, still smaller septum. The irregularly stellate bodies are the tendon-cells in section.

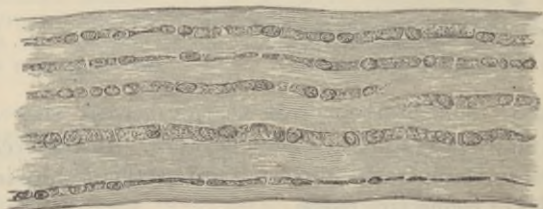

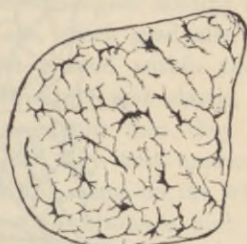
FIG. 61.—TENDON OF MOUSE'S TAIL; SHOWING CHAINS OF CELLS BETWEEN THE TENDON-BUNDLES. (175 diameters.)

tissue are conveyed. The interstices between the smallest bundles are occupied by rows of lamellar connective-tissue corpuscles (*tendon-cells*), which, from being squeezed up between three or more bundles, become flattened out in two or three directions. In transverse section the

cells appear somewhat stellate (figs. 60, 62), but when seen on the flat they appear lamellar (fig. 61), and from this aspect their general shape is square or oblong. They lie, as before said, in rows between the tendon-bundles, and the nuclei of adjacent cells are placed opposite

FIG. 62.—TRANSVERSE SECTION OF TENDON OF MOUSE'S TAIL, STAINED. (175 diameters.)

The flattened processes of the tendon-cells appear in section as lines, frequently coming off at right angles from the body of the cell.



one another in pairs (fig. 63). The cell-spaces correspond in general figure and arrangement to the cells which occupy them (fig. 64).

Fibrous tissue forms the tendons and ligaments, and also certain membranes, such as the dura mater, the fibrous pericardium, the fasciæ of the limbs, the fibrous covering of certain organs, etc. It is found wherever great strength, combined with flexibility, is concerned.



FIG. 63.—EIGHT CELLS FROM THE SAME TENDON AS REPRESENTED IN FIG. 61. (425 diameters.)

The dark lines on the surface of the cells are the optical sections of lamellar extensions directed towards or away from the observer.

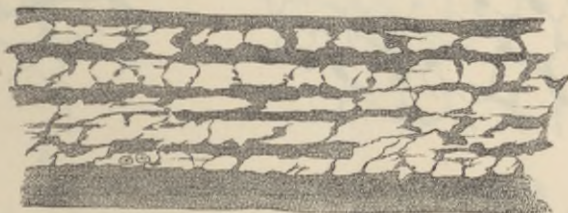


FIG. 64.—CELL-SPACES OF TENDON OF MOUSE'S TAIL, BROUGHT INTO VIEW BY TREATMENT WITH NITRATE OF SILVER. (175 diameters.)

It receives a few blood-vessels, disposed longitudinally for the most part, and contains many lymphatics. Tendons and ligaments also receive nerve-fibres, which, in some cases, end in small localised ramifications like the end-plates of muscle, while others terminate in end-bulbs or in simple Pacinian corpuscles. These will be described along with the modes of ending of nerve-fibres.

Development of connective tissue.—Connective tissue is always developed in the mesoblast or mesoderm of the embryo. In those parts of this layer which are to form connective tissue, the embryonic

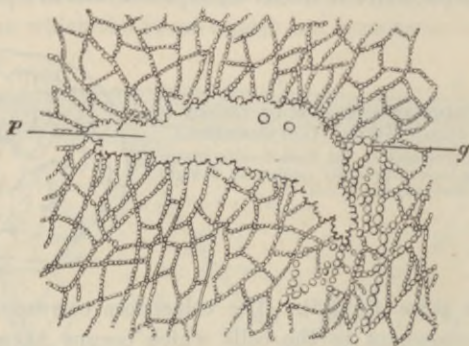


FIG. 65.—DEVELOPMENT OF ELASTIC TISSUE BY DEPOSITION OF FINE GRANULES. (Ranvier.)

g, fibres being formed of rows of 'elastin' granules; *p*, flat plate-like expansion of elastic substance formed by the fusion of 'elastin' granules.

cells become separated from one another by a muco-albuminous semi-fluid intercellular substance (ground-substance), but the cells generally remain connected by their processes. The connective-tissue fibres, both white and elastic, are probably deposited in this ground-substance, the elastic substance in the form of granules (fig. 65, *g*), which

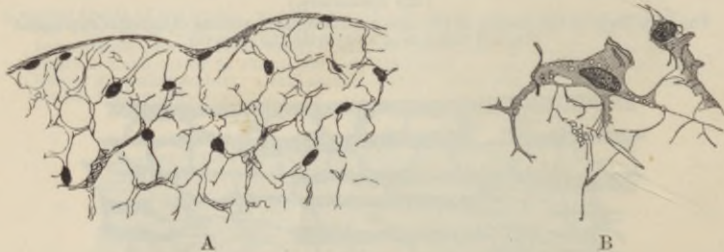

FIG. 66.—SECTION OF JELLY OF WHARTON. (Flemming.)

A, moderately magnified, showing ramified cells intercommunicating by their branches; B, two cells further enlarged, showing wavy fibrils in contact with the cells.

subsequently become connected together into elastic fibres or laminae, as the case may be, the white fibres appearing at first in the form of very fine bundles, which afterwards become gradually larger; so that in fibrous tissue the whole ground-substance is eventually pervaded by them, and the cells of the tissue become squeezed up into the intervals between them. Before any considerable development

of fibres has taken place, the embryonic connective tissue has a jelly-like appearance; in this form it occurs in the umbilical cord, where it is known as the *jelly of Wharton* (fig. 66).

There has been always a considerable difference of opinion as to the origin of the fibres of connective tissue, some histologists holding that they are formed within the protoplasm of cells, which gradually lose their cell-characters as the fibres become developed within them; others taking the view that the fibres, both white and elastic, are extracellular formations. While there is no doubt that they are produced under the influence of the cells, for they first appear in close proximity to those structures (fig. 66, B), it seems on the whole probable that they are deposited in the ground-substance and not actually in the cell-protoplasm, so that they are rather to be looked upon, like the ground-substance itself, as formed by a process of secretion than by one of cell-transformation.

LESSON XI.

THE CONNECTIVE TISSUES (continued).

ARTICULAR CARTILAGE: SYNOVIAL MEMBRANES.

1. CUT two or three very thin tangential slices of the fresh cartilage of a joint, mount them in salt solution or serum, and examine with a high power. Observe carefully the form and grouping of the cells. Look at the thin edge of the section for spaces from which the cells have dropped out. Measure two or three cells and their nuclei, and sketch one or two groups. Now replace the salt solution by water and set the preparation aside for a little while. On again examining it, many of the cartilage-cells will be found to have shrunk away from their containing capsules.

2. Make other sections of the cartilage (1) from near the middle, (2) from near the edge. Place the sections for two or three minutes in acetic acid (1 per cent.), wash them with water, and stain with dilute hæmalum or carmalum solution. When stained mount in dilute glycerine and cement the cover-glass. In (2) look for branched cartilage-cells. Draw one or two.

3. Make vertical sections of articular cartilage from an end of bone which has been decalcified in $\frac{1}{2}$ per cent. chromic acid solution, and mount the sections in glycerine and water, or, after staining, in xylol balsam.¹ Sketch the arrangement of the cells in the different layers.

4. Brush a fresh joint with distilled water; drop 0.75 per cent. nitrate of silver solution over it; after five minutes wash away the nitrate of silver and expose in water to direct sunlight. When browned, place in spirit for half an hour or more, and then with a razor wetted with spirit cut thin sections from the surface and mount in xylol balsam after passing through clove oil. The cells and cell-spaces show white in the brown ground-substance. Draw.

5. To study the structure of the synovial membrane mount other slices from the silvered preparation of the joint (§ 4) just beyond the limits of the articular cartilage, and also look for small fringed projections of the membrane. Snip them off with scissors and mount as before in balsam.

6. The superficial flexor tendons of the foot of the ox or sheep run in grooves formed by the deep flexors, and these grooves are lined, and the tendons which pass through them are covered by vaginal synovial membranes. To show the structure of these treat one of the superficial flexor tendons with silver nitrate in the same way as recommended for the joint, and after hardening in spirit cut sections from the surface and mount them in balsam.

Cartilage or *gristle* is a translucent bluish-white tissue, firm, and at the same time elastic, and for the most part found in connection with bones of the skeleton, most of which are in the embryo at first repre-

¹See Appendix.

sented entirely by cartilage. Two chief varieties of cartilage are distinguished. In the one, which is termed *hyaline*, the matrix or ground-substance is almost clear, and free from obvious fibres; in the other, which is termed *fibro-cartilage*, the matrix is everywhere pervaded by connective-tissue fibres. When these are of the white variety, the tissue is *white fibro-cartilage*; when they are elastic fibres, it is *yellow or elastic fibro-cartilage*.

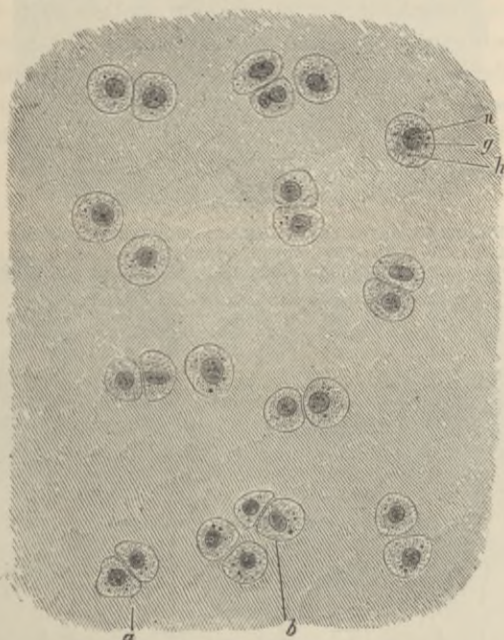


FIG. 67.—ARTICULAR CARTILAGE FROM HEAD OF METATARSAL BONE OF MAN (OSMIC ACID PREPARATION). THE CELL-BODIES ENTIRELY FILL THE SPACES IN THE MATRIX. (340 DIAMETERS.)

a, group of two cells; *b*, group of four cells; *h*, protoplasm of cell, with *g*, fatty granules; *n*, nucleus.

Hyaline cartilage occurs principally in two situations—namely (1) covering the ends of the bones in the joints, where it is known as *articular cartilage*; and (2) forming the rib-cartilages, where it is known as *costal cartilage*. It also forms the cartilages of the nose, of the external auditory meatus (but not the pinna), most of those of the larynx, and the cartilages of the windpipe; in these places it serves to maintain the shape and patency of the orifices and tubes.

Articular cartilage.—The cells of articular cartilage are generally scattered in groups of two or four throughout the matrix (fig. 67). The latter is free from fibres, except at the extreme edge of the

cartilage, where the connective-tissue fibres from the synovial membrane extend into it; and here also the cartilage-cells are often branched, and offer transitions to the branched connective-tissue corpuscles of

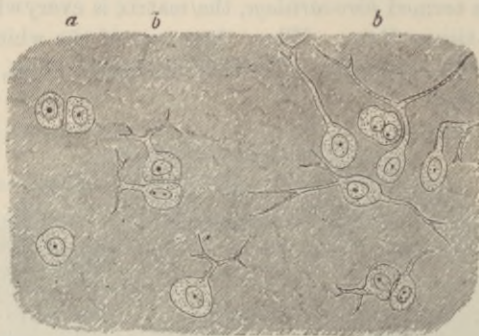


FIG. 68.—BORDER OF ARTICULAR CARTILAGE SHOWING TRANSITION OF CARTILAGE-CELLS INTO CONNECTIVE-TISSUE CORPUSCLES OF SYNOVIAL MEMBRANE. FROM HEAD OF METATARSAL BONE, HUMAN. (About 340 diameters.)

a, ordinary cartilage-cells; *b*, *b*, with branching processes.

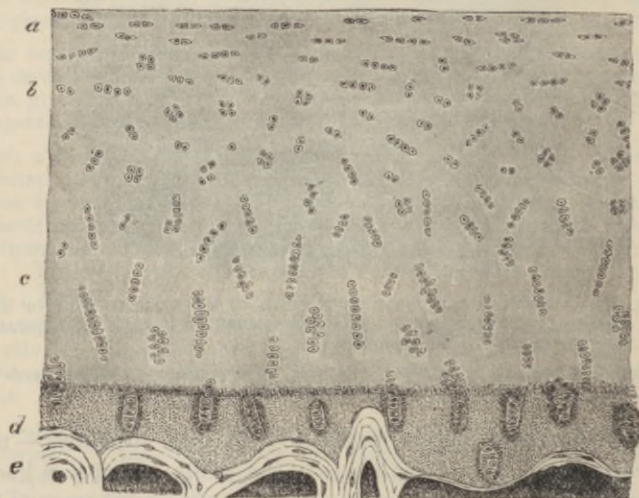


FIG. 69.—VERTICAL SECTION OF ARTICULAR CARTILAGE COVERING THE LOWER END OF THE TIBIA, HUMAN. (Magnified about 30 diameters.)

a, cells and cell-groups flattened conformably with the surface; *b*, cell-groups irregularly arranged; *c*, cell-groups disposed perpendicularly to the surface; *d*, layer of calcified cartilage; *e*, bone.

that membrane (*transitional cartilage*, fig. 68). By long maceration in brine, however, evidence of a fibrous structure may be obtained, even in the matrix of true hyaline cartilage. Some histologists also

describe fine communications in the matrix uniting the cartilage-cells with one another, but these are of doubtful occurrence.

The matrix immediately around the cartilage-cells is often marked off from the rest by a concentric line or lines, this part of the matrix, which is the latest formed, being known as the *capsule* of the cell. The cells are bluntly angular in form, the sides opposite to one another in the groups being generally flattened. The protoplasm is very clear, but it may contain droplets of fat; and with a high power fine interlacing filaments and granules have been observed in it. During life the protoplasm entirely fills the cavity or cell-space which it occupies in the matrix; but after death, and in consequence of the action of water and other agents, it tends to shrink away from the capsule. The nucleus is round, and shows the usual intranuclear network.

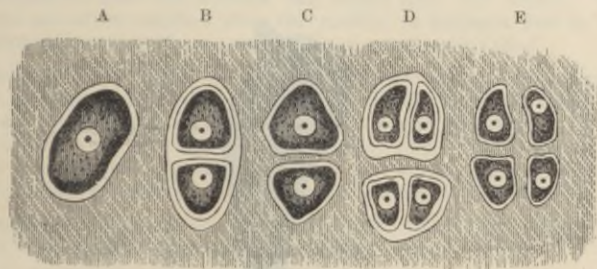


FIG. 70.—PLAN OF THE MULTIPLICATION OF CELLS OF CARTILAGE. (Sharpey.)

A, cell in its capsule; B, divided into two, each with a capsule; C, primary capsule disappeared, secondary capsules coherent with matrix; D, tertiary division; E, secondary capsules disappeared, tertiary coherent with matrix.

In vertical section (fig. 70) the deeper cell-groups (*c*) are seen to be arranged vertically to the surface, the more superficial ones (*a*) parallel to the surface; whilst in an intermediate zone the groups are irregularly disposed (*b*). In the deepest part of the cartilage, next the bone, there is often a deposition of calcareous salts in the matrix (*calcified cartilage, d*).

The disposition of the cells of cartilage in groups of two, four, and so on, is apparently due to the fact that these groups have originated from the division of a single cell first into two, and these again into two, and so on (fig. 70). It would seem that the matrix is formed of successive portions, which are deposited around each cartilage-cell as the so-called 'capsules,' each newly formed portion soon blending in its turn with the previously formed matrix, whilst a new capsule is formed within it. The division of the cartilage-cell, like that of other cells, is accompanied by a process of karyokinesis.

Embryonic cartilage is characterised by the cells being usually more sharply angular and irregular; they are even in some cases markedly branched, like those which occur at the junction of cartilage and synovial membrane in the adult. The cells are also more closely packed, the matrix being in relatively less amount than in later life.

SYNOVIAL MEMBRANES.

The **synovial membranes** are often compared with the serous membranes. They are indeed, like the latter, connective-tissue membranes which bound closed cavities moistened with fluid, but they are not connected with the lymphatic system, nor is the fluid (synovia) which moistens them of the nature of lymph. Moreover, there is either no epithelial lining, or it occurs only in patches, in place of the continuous lining which we find in the serous membranes. Long villus-like

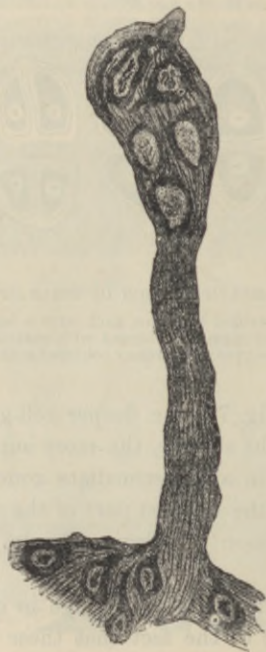

FIG. 71.—VILLUS OF SYNOVIAL MEMBRANE. (Hammar.)

projections occur in many parts; they are often covered by small rounded cells, and probably serve to extend the surface for the secretion of synovia. The blood-vessels of synovial membranes are numerous, and approach close to the inner surface of the membrane. They are well seen in preparations from an injected limb.

LESSON XII.

THE CONNECTIVE TISSUES (continued).

COSTAL CARTILAGE. FIBRO-CARTILAGE.

1. MAKE transverse and tangential sections of a rib-cartilage, which may either be fresh, or may have been preserved in spirit or formol. Stain them with hæmalum or carmalum (if fresh, after treatment with acetic acid as in Lesson XI., § 2), and mount in glycerine. Sketch a part of a transverse section under a low power and a cell-group from one of the tangential sections under a high power. Notice especially the arrangement of the cells, somewhat concentric near the surface but radial near the centre. The costal cartilages are often ossified near the middle in animals, but in man when ossification occurs it is the superficial layer which is invaded.

2. Make sections of the cartilage of the external ear (pinna), either fresh or after hardening in alcohol. Mount in dilute glycerine faintly coloured with magenta, or stain with orcein and mount in balsam. If from the ox, notice the very large reticulating elastic fibres in the matrix. Notice also the isolated granules of elastin, and around the cartilage-cells the area of clear ground-substance. Draw a small portion of the section.

3. Mount a section of the epiglottis in the same way. Notice the closer network of much finer fibres in its cartilage.

4. Cut sections of white fibro-cartilage (intervertebral disk), which has been hardened in saturated solution of picric acid, followed by spirit, or in spirit only. Stain the sections with dilute hæmalum or carmalum. Mount in dilute glycerine. Observe the wavy fibres in the matrix and the cartilage-cells lying in clear areas often concentrically striated. Look for branched cartilage-cells. Sketch three or four cells and the adjoining fibrous matrix.

Costal cartilage.—In the costal cartilages the matrix is not always so clear as in the cartilage of the joints, for it often happens that fibres become developed in it. The cells are generally larger and more angular than those of articular cartilage, and collected into larger groups (fig. 72). Near the circumference, and under the perichondrium or fibrous covering of the cartilage, they are flattened and parallel to the surface, but in the deeper parts they have a more irregular or a radiated arrangement. They frequently contain fat. The cartilages of the larynx and windpipe and of the nose resemble on the whole the costal cartilages, but the study of them may be deferred until the organs where they occur are dealt with.

Elastic or yellow fibro-cartilage occurs in only a few situations. These are, the cartilage of the external ear and that of the Eustachian

tube, and the epiglottis and cartilages of Santorini of the larynx. The matrix is everywhere pervaded with well-defined branching fibres, which unite with one another to form a close network (fig. 73). These fibres resist the action of acetic acid, and are stained deeply by magenta; they are evidently elastic fibres. In the ox they are very large, but smaller in man, especially in the cartilage of the epiglottis (fig. 74). They appear to be developed, as with elastic tissue elsewhere (see p. 56), by the deposition of granules of elastin

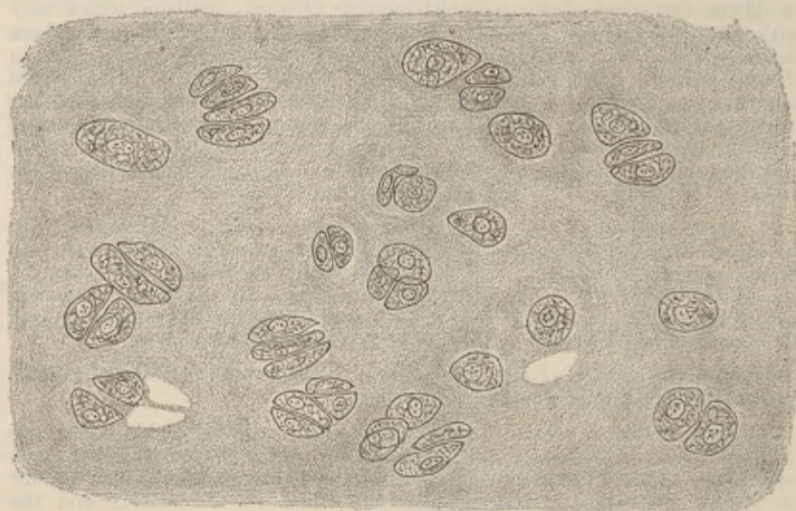


FIG. 72.—SECTION OF RIB-CARTILAGE, SHOWING CELLS AND CELL-GROUPS IN A SOMEWHAT FIBROUS-LOOKING MATRIX.

Two or three empty cell-spaces are seen from which the cells have dropped out in preparing the section.

in the matrix, which at first lie singly, but afterwards become joined to form the fibres.

White fibro-cartilage is found wherever great strength combined with a certain amount of rigidity is required: thus we frequently find fibro-cartilage joining bones together, as in the case of the intervertebral disks and other symphyses. Fibro-cartilage is also often employed to line grooves in which tendons run, and it may be found in the tendons themselves. It is also employed to deepen cup-shaped articular surfaces; and in the case of the interarticular cartilages, such as those of the knee and lower jaw, to allow greater freedom of movement whilst diminishing the liability to dislocation. Under the microscope white fibro-cartilage looks very

like fibrous tissue, but its cells are cartilage-cells, not tendon-cells (fig. 75). They are rounded or bluntly angular and surrounded by a concentrically striated area of clear cartilage-matrix. In some

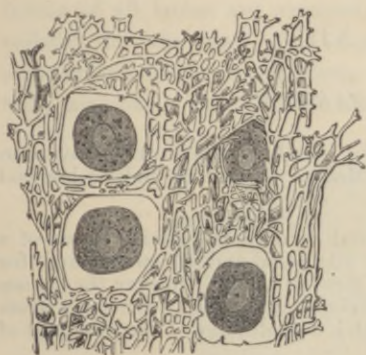


FIG. 73.—SECTION OF THE ELASTIC CARTILAGE OF THE EAR. (Hertwig.) (Highly magnified.)

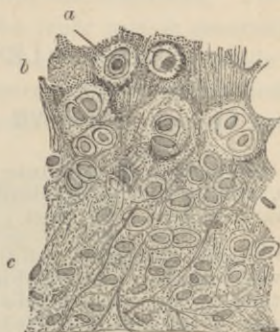

FIG. 74.—SECTION OF PART OF THE CARTILAGE OF THE EPIGLOTTIS. (Kanvier.)

a, cartilage cell in clear area; *b*, granular-looking matrix near the middle of the cartilage, the granular appearance being due partly to the fine reticulum of elastic fibres, partly to the presence of granules of elastic substance in the matrix; *c*, clearer matrix with longer fibres.

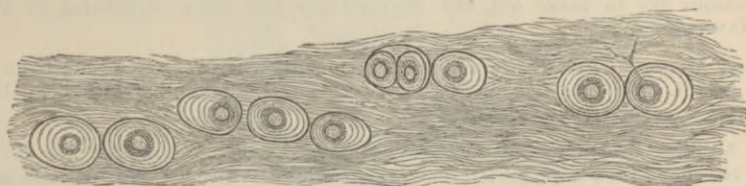


FIG. 75.—WHITE FIBRO-CARTILAGE FROM AN INTERVERTEBRAL DISK, HUMAN. (Highly magnified.)

The concentric lines around the cells indicate the limits of deposit of successive capsules. One of the cells has a forked process which extends beyond the hyaline area surrounding the cell, amongst the fibres of the general matrix.

parts of the intervertebral disk many of the cells are branched, and may be looked upon as transitional forms to connective-tissue corpuscles.

LESSON XIII.

BONE AND MARROW.

1. In thin sections of hard bone made by grinding, observe the Haversian canals, lamellæ, lacunæ, canaliculi, etc. Make a sketch first under a low and afterwards under a high power.

2. With fine forceps strip off a thin shred from the superficial layers of a bone which has been decalcified in dilute nitric acid and afterwards kept for some time in dilute alcohol. Mount the shred in water. Observe the fibrous structure of the lamellæ. Look for perforating fibres or the holes from which they have been dragged out. Sketch a small piece of the thin edge of a lamella.

3. Stain with dilute magenta solution very thin sections of compact bone which has been decalcified in chromic or picric acid, or in phloroglucin and nitric acid, and mount in dilute glycerine, cementing at once. Look for fibres of Sharpey piercing the circumferential lamellæ. The elastic perforating fibres are more darkly stained than the others. Notice the stained nuclei of the bone-corpuscles in the lacunæ. In the thinnest parts of the sections try to make out the blood-vessels and other structures in the Haversian canals.

4. Mount in xylol balsam stained sections of marrow from a long bone of a rabbit. Observe the fat-cells, the reticular tissue supporting them, the proper marrow-cells in this tissue, etc.

5. Tease in salt solution or serum some of the red marrow from the rib of a recently killed animal. Observe and sketch the proper marrow-cells and look for myeloplaxes and nucleated coloured blood-corpuscles. If examined carefully, amœboid movements may be detected in the latter and in the marrow-cells.

6. Make a stained preparation of red marrow by smearing a little upon a cover-glass, allowing it to dry quickly over a flame, and placing it in a 1 per cent. solution of eosin in spirit. After half-an-hour, rinse the cover-glass with clean spirit and place it in 1 per cent. watery solution of methylene-blue for five minutes. Rinse again with spirit until the colour is in great part but not wholly removed, and then with distilled water. Allow to dry and mount with xylol balsam.

Bone is a connective tissue in which the ground-substance is impregnated with salts of lime, chiefly phosphate, these salts constituting about two-thirds of the weight of the bone. When bones are macerated this earthy matter prevents the putrefaction of the animal matter. When bones are calcined they lose one-third of their weight, owing to the destruction of the animal matter; when steeped in acid

the earthy salts are dissolved and only the animal matter is left. This, like areolar and fibrous tissue, is converted into gelatine by boiling.

Bony tissue is either *compact* or *cancellated*. Compact bone is dense, like ivory; cancellated is spongy with obvious interstices. The outer layers of all bones are compact, and the inner part is generally cancellated, but the shaft of a long bone is almost entirely made up of compact substance except along the centre, which is hollow and filled with marrow. The interstices of cancellated bone are also occupied

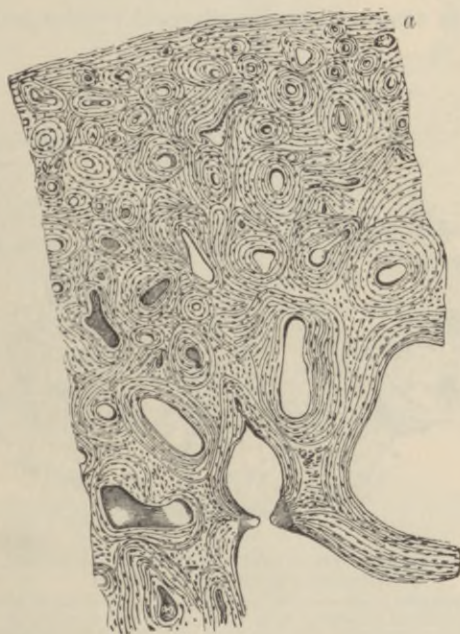

FIG. 76.—TRANSVERSE SECTION OF A BONE (ULNA). (Sharpey.)
(Magnified 20 diameters.)

The openings of the Haversian canals are seen encircled by concentric lamellæ.
Other lamellæ (a) run parallel with the surface.

by marrow. Externally bones are covered except at the joints by a vascular fibrous membrane, the *periosteum*.

True bone is always made up of *lamellæ*, and these again are composed of fine *fibres* lying in a *calcified ground-substance*. Between the lamellæ are branched cells, the *bone-corpuscles*, which lie in cell-spaces or *lacunæ*. The ramified passages which contain the cell-processes are termed *canaliculi*.

In cancellated bone the blood-vessels run in the interstices supported by the marrow. In compact bone they are contained in little canals

—the *Haversian canals*—which everywhere pervade the bone. These canals are about 0.05 mm. ($\frac{1}{2000}$ inch) in diameter, but some are smaller, others larger than this. Their general direction is longitudinal, *i.e.* parallel to the long axis of the bone, but they are constantly united by transversely and obliquely running passages. In a section across the shaft of a long bone they are seen as small rounded or irregular holes (fig. 76). When the section has been made by grinding, the holes get filled up with air and debris, and they then look black by transmitted light, as do also the lacunæ and canaliculi (fig. 77). Most of the lamellæ in compact bone are disposed concentrically around the

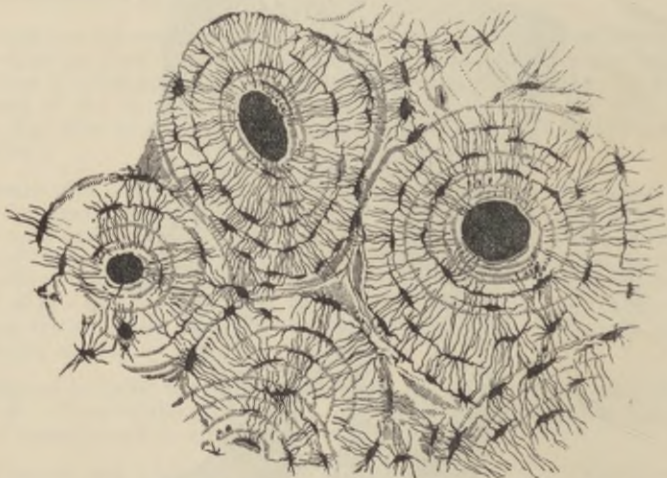


FIG. 77.—TRANSVERSE SECTION OF COMPACT TISSUE (OF HUMERUS). (Sharpey.)
(Magnified about 150 diameters.)

Three of the Haversian canals are seen, with their concentric rings; also the lacunæ, with the canaliculi extending from them across the direction of the lamellæ. The Haversian apertures had become filled with air and debris in grinding down the section, and therefore appear black in the figure, which represents the object as viewed by transmitted light.

Haversian canals; they are known as the Haversian lamellæ, and with the included canal form what is known as a *Haversian system*. The lacunæ of a Haversian system communicate with one another and with the Haversian canal, but not as a rule with the lacunæ of other Haversian systems. The angular interstices between the Haversian systems are generally occupied by bony substance which is fibrous but not lamellar. Besides the lamellæ of the Haversian systems there is a certain thickness of bone at the surface, immediately underneath the periosteum, which is composed of lamellæ arranged parallel with the surface; these are the *circumferential* or *periosteal lamellæ* (fig. 76, a). They are pierced here and there by canals for blood-vessels,

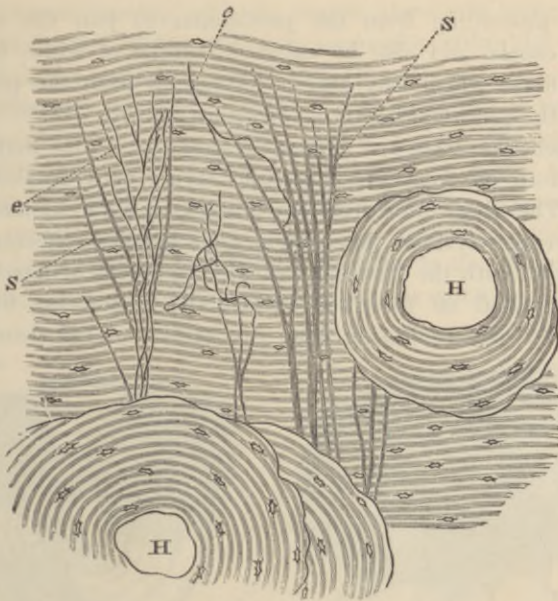


FIG. 78.—TRANSVERSE SECTION OF DECALCIFIED HUMAN TIBIA, FROM NEAR THE SURFACE OF THE SHAFT.

h, h, Haversian canals, with their systems of concentric lamellae; in all the rest of the figure the lamellae are circumferential; s, ordinary perforating fibres of Sharpey; e, e, elastic perforating fibres. Drawn under a power of about 150 diameters.




FIG. 79.—LAMELLE TORN OFF FROM A DECALCIFIED HUMAN PARIETAL BONE AT SOME DEPTH FROM THE SURFACE. (Sharpey.)

a, lamellae, showing decussating fibres; b, b, thicker part, where several lamellae are superposed; c, c, perforating fibres; the fibrils which compose them are not shown in the figure. Apertures through which perforating fibres had passed are seen, especially in the lower part, a, a, of the figure. Magnitude as seen under a power of 200 diameters, but not drawn to scale. (From a sketch by Allen Thomson.)

which are proceeding from the periosteum to join the system of Haversian canals, and also by calcified bundles of white fibres and by elastic fibres which may also be prolonged from the periosteum. These are the *perforating fibres of Sharpey* (fig. 78).

The lamellæ of bone are fibrous in structure. This may be seen in shreds torn off from the superficial layers of a decalcified bone (fig. 79). The fibres often cross one another in adjacent lamellæ, and in the Haversian systems they run in some lamellæ concentrically, in others parallel with the Haversian canal. In shreds of lamellæ which have been peeled off from the surface the perforating fibres may sometimes be seen projecting from the surface of the shred, having

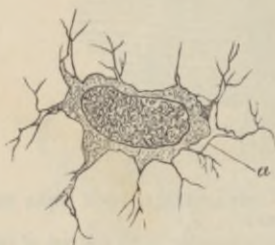


FIG. 80.—A BONE-CELL ISOLATED AND HIGHLY MAGNIFIED. (Joseph.)

a, proper wall of the lacuna (Neumann's layer), where the corpuscle has shrunk away from it.

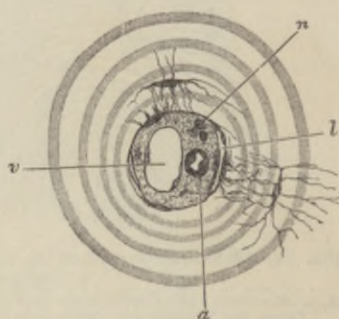


FIG. 81.—SECTION OF A HAVERSIAN CANAL, SHOWING ITS CONTENTS. (Highly magnified.)

a, small arterial capillary vessel; *v*, large venous capillary; *n*, pale nerve-fibres cut across; *l*, cleft-like lymphatic vessel; one of the cells forming its wall communicates by fine branches with the branches of a bone-corpuscle. The substance in which the vessels run is connective tissue with ramified cells; its finely granular appearance is probably due to the cross-section of fibrils. The canal is surrounded by several concentric lamellæ.

been torn out of the deeper lamellæ (fig. 79, *c*, *c*). Where tendons or ligaments are inserted into bone, their bundles of white fibres are prolonged into the bone as perforating fibres.

The lacunæ are occupied by nucleated corpuscles, which send branches along the canaliculi (fig. 80). They have a special lining layer different in chemical composition from the rest of the bone, being much more resistant to the action of strong chemical solvents such as hydrochloric acid (Neumann). The dentinal tubules of the teeth have a similar lining layer.

The Haversian canals contain one or two blood-capillaries and nervous filaments, besides a little connective tissue; and the larger ones may also contain a few marrow-cells. There are also cleft-like

lymphatic spaces running with the vessels, their cells being connected through canaliculi with branches from corpuscles within the neighbouring lacunæ of the osseous substance (fig. 81).

The **periosteum** (which is studied in torn-off shreds, in preparations stained *in situ* with silver nitrate, and in stained sections from an unmacerated bone which has been decalcified in nitric, chromic, or picric acid) is a fibrous membrane composed of two layers, the inner of which contains many elastic fibres. In the outer layer numerous blood-vessels ramify and send from it branches to the Haversian canals of the bone. The periosteum ministers to the nutrition of the bone,

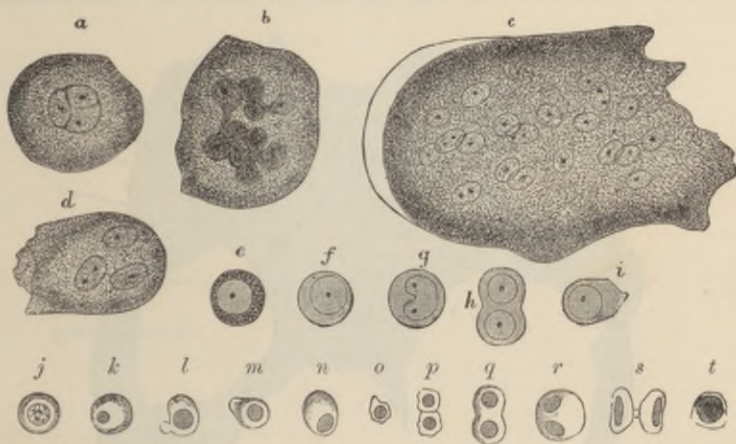

FIG. 82.—CELLS OF THE RED MARROW OF THE GUINEA-PIG. (Highly magnified.)

a, a large cell, the nucleus of which appears to be partly divided into three by constrictions; *b*, a cell, the enlarged nucleus of which shows an appearance of being constricted into a number of smaller nuclei; *c*, a so-called giant-cell or myeloplax with many nuclei; *d*, a smaller myeloplax with three nuclei; *e-i*, proper cells of the marrow; *j-t*, various forms of coloured nucleated cells, some in process of division.

partly on account of the blood-vessels and lymphatics it contains, partly, especially in young animals, on account of the existence between it and the bone of a layer of *osteoblasts* or *bone-forming cells*, a remainder of those which originally produced the bone. It also serves to give attachment to muscular fibres.

The **marrow of bone** is of a yellow colour in the shafts of the long bones of most animals, and is there largely composed of adipose tissue, but in the shafts of the long bones of some animals, and in the cancellated tissue, it is usually red, the colour being partly due to the large amount of blood in its vessels. This red marrow is chiefly composed of round nucleated cells—the *marrow cells* (fig. 82, *e-i*)—which resemble large white blood or lymph-corpuscles, and, like these, are amœboid.

They also exhibit the same kind of differences as to the character of the granules which they contain, some being basophil, others oxyphil, and others amphophil or neutrophil. There are also to be seen mingled with them a number of corpuscles somewhat smaller in size, but nucleated and amoeboid, and of a reddish tint (fig. 82, *j-t*). These cells, which are termed *erythroblasts*, resemble the nucleated coloured blood-corpuscles of the embryo, and they are believed to be cells from which the coloured blood-disks become developed (Neumann). Many of them are in process of division by karyokinesis, and others are seen with the nucleus in a more or less atrophied condition; from which it may be inferred that the transformation

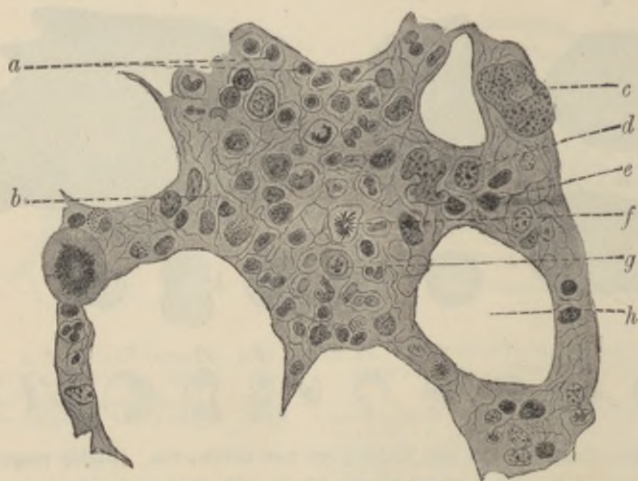


FIG. 83.—SECTION OF RED MARROW. (Böhm and v. Davidoff.)

a, e, erythroblasts; *b*, reticulum; *c*, myeloplaxe; *d, g*, proper marrow cells; *f*, a marrow-cell dividing; *h*, space which was occupied by fat.

into a discoid blood-corpuscle is accompanied by the disappearance of the nucleus (Bizzozero).¹ Lastly, the marrow contains a certain number of very large cells with multiple nuclei, the *myeloplaxes* of Robin (fig. 82, *a, b, c, d*). These are especially numerous wherever bone is becoming absorbed, but are not confined to such situations, being indeed normal constituents of marrow. Sometimes, instead of possessing several nuclei, these cells contain but one large nucleus, which then usually shows an appearance as of budding (*b*). They are also characterised by possessing a number of centrosomes grouped together near the nucleus. Lastly, the existence of cells within the

¹In birds the erythroblasts are confined to the large blood-spaces of the marrow.

marrow containing blood-corpuscles in various stages of transformation into pigment, similar to those which occur in the spleen pulp, has also been affirmed (Osler). The marrow is very vascular, the capillaries and veins being large and thin-walled; indeed, according to some authorities, the walls of the capillaries are imperfect, so that there is an open communication between them and the interstices of the tissue, and in this way it is supposed that the coloured blood-disks, which are believed to be produced from the coloured nucleated cells (erythroblasts) of the marrow, may get into the circulation. There is not, however, an interstitial circulation of blood in the marrow such as is found in the spleen.

LESSON XIV.

DEVELOPMENT OF BONE.

1. MOUNT in xylol balsam a section of a foetal lower jaw which has been stained in bulk and embedded in paraffin.¹ Find the part where the lower jaw-bone is becoming ossified, and carefully study the appearance which it presents. The bone is prolonged in the form of osteogenic fibres which are covered with osteoblasts.

2. Intramembranous ossification may also be studied in the parietal bone of a fetus which has been preserved in Müller's fluid. A piece of the growing edge is scraped or brushed free from its investing membranes, and from most of the cells which cover and conceal it, and is mounted in glycerine with or without previous staining with carmalum.

3. Mount in balsam sections of a foetal limb which has been stained in bulk. The bones will be found in different stages of ossification, those of the digits being least developed. Make sketches illustrating the three chief stages of endochondral ossification. Notice the peculiar terminal ossification of the third phalanx.

4. Make with a sharp scalpel a longitudinal section at the line of ossification in a more advanced bone which has not been decalcified (preservation in Müller's fluid or 5 per cent. formol). Other sections may be carried across a bone near its plane of ossification, and others through an epiphysis. These sections will show the mode of progress of the calcification. The sections can be mounted in glycerine.

True bone is essentially formed in all cases by an ossification of connective tissue. Sometimes the bone is preceded by cartilage, which first becomes calcified, and this is then invaded, and for the most part removed, by an embryonic tissue which re-deposits bony matter in the interior of the cartilage, whilst at the same time layers of bone are being formed outside underneath the periosteum. This is *intracartilaginous* or *endochondral ossification*. Sometimes the bone is not preceded by cartilage, and then the only process which occurs is one corresponding to the subperiosteal ossification of the former variety; the ossification is then known as *intramembranous*.

Ossification of cartilage.—This may be described as occurring in three stages. In the *first stage* the cells in the middle of the cartilage become enlarged and arranged in rows radiating from the centre

¹For the methods of staining, embedding, and mounting, 1 and 3, see Appendix, "Embedding in Paraffin."

(fig. 84), and fine granules of calcareous matter are deposited in the matrix. Simultaneously with this the osteoblasts underneath the periosteum deposit a layer or layers of fibrous lamellæ upon the

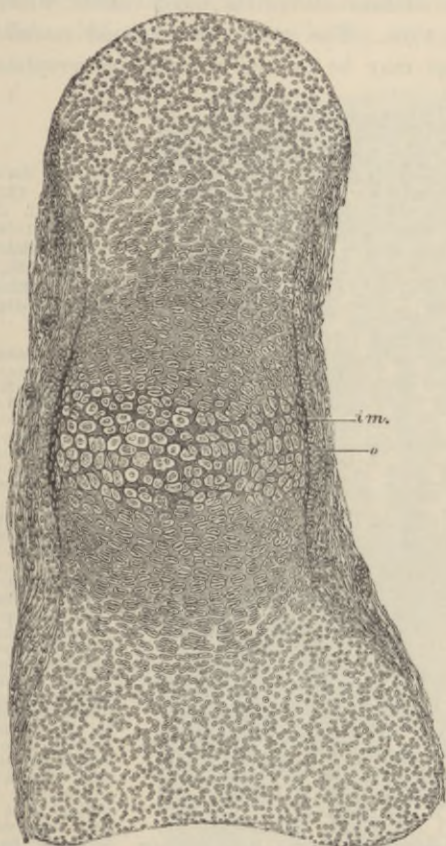


FIG. 84.—SECTION OF PHALANGEAL BONE OF HUMAN FETUS, AT THE TIME OF COMMENCING OSSIFICATION. (From a preparation by F. A. Dixey. The preparation was stained in bulk with magenta. The drawing is made from a photograph.) (Magnified about 75 diameters.)

The cartilage-cells in the centre are enlarged and separated from one another by stained calcified matrix; *im*, layer of bone deposited underneath the periosteum; *o*, layer of osteoblasts by which this layer has been formed. Some of the osteoblasts are already embedded in the new bone as lacunæ. The cartilage-cells are becoming enlarged and flattened and arranged in rows above and below the calcified centre. At the ends of the cartilage the cells are small, and the groups are irregularly arranged; the fibrous periosteum is not sharply marked off from the cartilage.

surface of the cartilage, and these lamellæ also become calcified (fig. 84, *im*). As they are formed, some of the osteoblasts (*o*) are included between them and become bone-corpuscles.

In the *second stage* some of the subperiosteal tissue eats its way

through the newly formed layer of bone and into the centre of the calcified cartilage (fig. 85, *ir*). This is freely absorbed before it (fig. 86), so that large spaces are produced which are filled with osteoblasts and contain numerous blood-vessels which have grown in at the same time. The spaces are termed *medullary spaces*, and this second stage may be termed the *stage of irruption*.

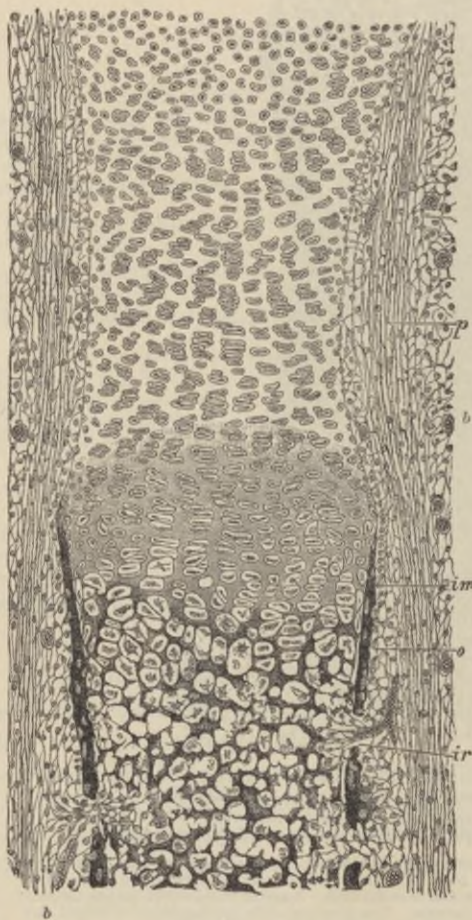


FIG. 85.—SECTION OF PART OF ONE OF THE LIMB-BONES OF A FETAL CAT, AT A MORE ADVANCED STAGE OF OSSIFICATION THAN IS REPRESENTED IN FIG. 84, AND SOMEWHAT MORE HIGHLY MAGNIFIED. (From a drawing by J. Lawrence.)

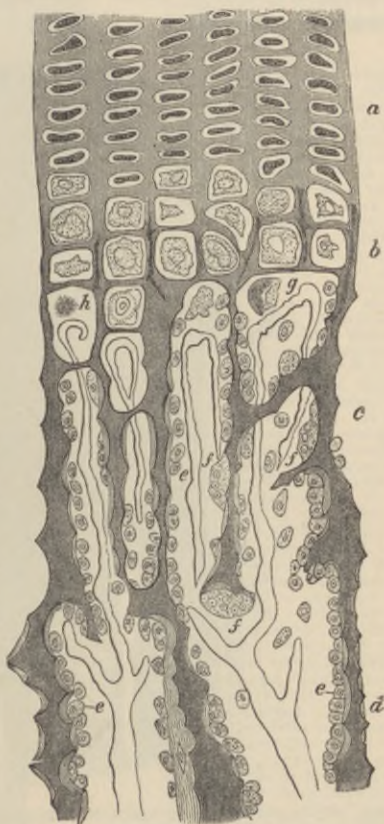The calcification of the cartilage-matrix has advanced from the centre, and is extending between the groups of cartilage-cells, which are arranged in characteristic rows. The subperiosteal bony deposit (*im*) has extended *pari passu* with the calcification of the cartilage-matrix. The cartilage-cells in the calcified part are mostly shrunken and stellate; in some cases they have dropped out of the space. At *ir* and in two other places an irruption of the subperiosteal tissue, composed of ramified cells with osteoblasts and growing blood-vessels, has penetrated the subperiosteal bony crust, and has begun to excavate secondary areolæ or medullary spaces; *p*, fibrous layer of the periosteum; *o*, layer of osteoblasts, some of them are embedded in the osseous layer as bone-corpuscles in lacunæ; *b*, blood-vessels occupied by blood-corpuscles. Beyond the line of ossification the periosteum may be noticed to be distinctly incurved. This incurvation is gradually moved on, the cartilage expanding behind it until the head of the bone is reached, when it forms the periosteal notch or groove represented in fig. 88, p. 79.

In the *third stage* of endochondral ossification there is a gradual advance of the ossification towards the extremities of the cartilage, and at the same time a gradual deposition of fresh bony lamellæ and spicules on the walls of the medullary spaces, and on the surface of the new bone under the periosteum. The advance into the cartilage always takes place by a repetition of the same changes, the cartilage-cells first

enlarging and becoming arranged in rows, the matrix between the rows becoming calcified, and then the calcified cartilage becoming excavated from behind by the osteoblastic tissue so as to form new medullary spaces (fig. 86). The walls of these are at first formed only by remains of the calcified cartilage-matrix (fig. 86, *c*), but they soon

FIG. 86.—PART OF A LONGITUDINAL SECTION OF THE DEVELOPING FEMUR OF THE RABBIT. (Klein.) (Drawn under a magnifying power of 350 diameters.)

a, rows of flattened cartilage-cells;
b, greatly enlarged cartilage-cells close to the advancing bone, the matrix between is partly calcified;
c, *d*, already formed bone, the osseous trabeculae being covered with osteoblasts (*e*), except here and there, where an osteoclast (*f*) is seen, eroding parts of the trabeculae;
g, *h*, cartilage-cells which have become shrunken and irregular in shape. From the middle of the figure downwards the dark trabeculae, which are formed of calcified cartilage-matrix, are becoming covered with secondary osseous substance deposited by the osteoblasts. The vascular loops at the extreme limit of the bone are well shown, as well as the abrupt disappearance of the cartilage-cells.



become thickened by lamellæ of fibrous bone (*b*) which are deposited by the osteoblasts, and between which bone-corpuscles become included, as in the case of the subperiosteal bone. The latter advances *pari passu* with the endochondral calcification, but beyond this the uncalcified cartilage grows both in length and breadth, so that the ossification is always advancing into larger portions of cartilage; hence the endochondral bone as it forms assumes the shape of an hour-glass, the cylindrical shape of the whole bone being maintained by additions of periosteal bone to the outside (see fig. 87). The absorption of the

calcified cartilage-matrix appears to be effected, as is the case with absorption of bony matter wherever it occurs, by large multi-nucleated cells (fig. 86, *f, f*) which are termed *osteoclasts*. They are cells of the same nature as the myeloplaxes of the marrow, and are found on surfaces where absorption of bone is taking place, whereas the osteoblasts are always found covering surfaces where bony deposit is proceeding (fig. 89).

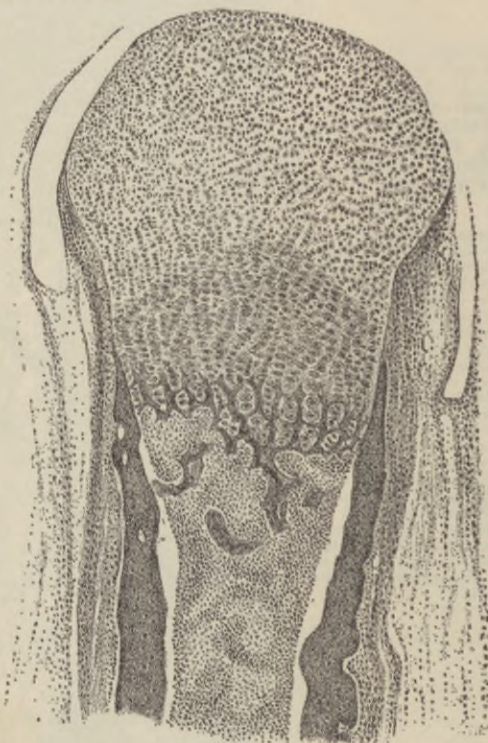


FIG. 87.—LONGITUDINAL SECTION THROUGH PART OF A PHALANX OF A SIX MONTHS' HUMAN EMBRYO. (Kölliker.)

The calcified cartilage is completely absorbed almost to the limit of advancing calcification. The darker substance on either side is periosteal bone. The embryonic marrow has shrunk somewhat away from it.

The bone which is first formed is more reticular and less regularly lamellar than that of the adult, and contains no Haversian systems. The regular lamellæ are not deposited until some little time after birth, and their deposition is generally preceded by a considerable amount of absorption. It is about this time also that the medullary canal of the long bones is formed by the absorption of the bony tissue which originally occupies the centre of the shaft.

After a time the cartilage in one or both ends of the long bones begins to ossify independently, and the *epiphyses* are formed. These

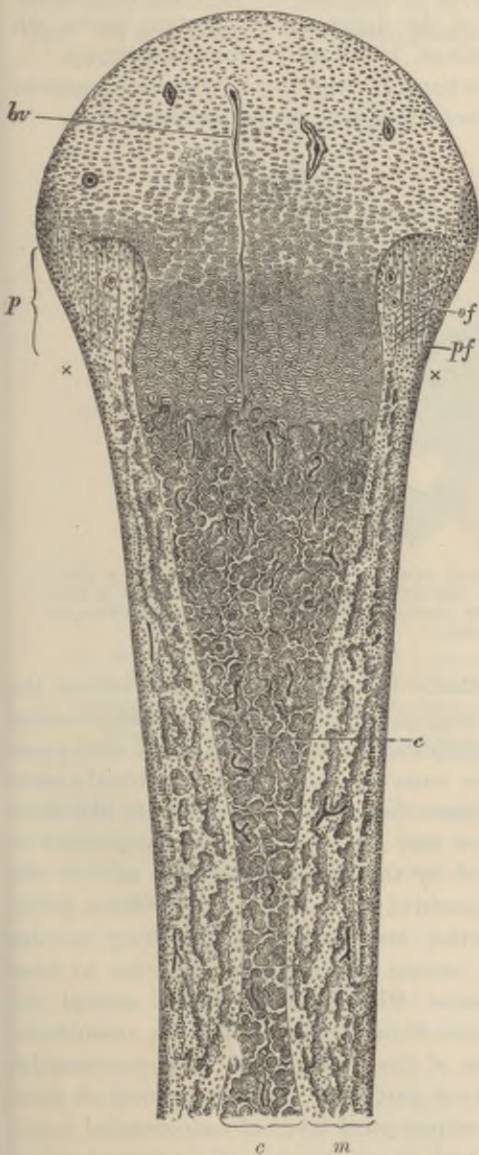


FIG. 88.—LONGITUDINAL SECTION THROUGH THE UPPER HALF OF THE DECALCIFIED HUMERUS OF A FETAL SHEEP, AS SEEN UNDER A MAGNIFYING POWER OF ABOUT 30 DIAMETERS. (From a drawing by J. Lawrence.)

c, the part of the shaft which was primarily ossified in cartilage; what remains of the primary bone is represented dark, enveloped by the clear secondary deposit. The areolae of the bone are occupied by embryonic marrow with osteoblasts, and blood-vessels variously cut, represented as dark lines. One long straight vessel (*bv*) passes in advance of the line of ossification far into the cartilaginous head, most of the others loop round close to the cartilage. At one or two places in the older parts of the bone elongated groups of cartilage-cells (*c*) may still be seen, which have hitherto escaped absorption. *m*, the part of the bone that has been ossified in membrane, that is to say, in the osteoblastic tissue under the periosteum. It is well marked off from the central portion, and is bounded, peripherally, by a jagged edge, the projections of which are indistinctly seen to be prolonged by bunches of osteogenic fibres. A row of osteoblasts covers the superficial layer of the bone. The subperiosteal layer is prolonged above into the thickening (*p*), which encroaches upon the cartilage of the head of the bone, and in which are seen, amongst numerous osteoblasts and a few blood-vessels, the straight longitudinal osteogenic fibres (*of*), and some other fibres (*pf*) crossing them, and perhaps representing fibres of Sharpey. The calcareous salts having been removed by an acid, the granular ossific deposit passing up between the rows of cartilage-cells is not seen in this specimen; it would have extended as far as a line joining the marks *x**x*. Observe the general tendency of the osseous trabeculae and the vascular channels between them to radiate from the original centre of ossification. This is found to prevail more or less in all bones when they are first formed, although the direction of the trabeculae may afterwards become modified in relation with varying physiological conditions, and especially as the result of pressure in different directions.

are not joined to the shaft until the growth of the bone is completed. Growth takes place *in length* by an expansion of the cartilage (*inter-*

mediate cartilage) which intervenes between the shaft and the epiphyses, and by the gradual extension of the ossification into it; *in width* entirely by the deposition of fresh bony layers under the periosteum. In the terminal phalanges of the digits the ossification starts, not from the middle of the cartilage, but from its distal extremity.

For the regeneration of portions of bone which have been removed by disease or operation it is important that the periosteum be left.

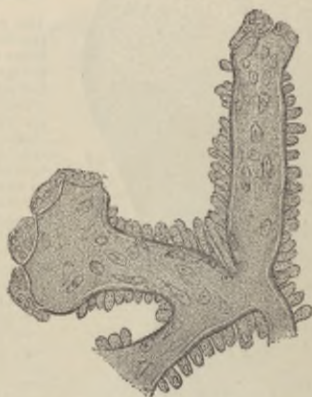


FIG. 89.—BONY TRABECULE FROM THE DEVELOPING LOWER JAW OF A CALF, SHOWING OSTEOCLASTS AT THE EXTREMITIES WHERE ABSORPTION IS PROCEEDING, AND OSTEOBLASTS COVERING THE SIDES WHERE DEPOSITION OF BONE IS GOING ON. (Kölliker.)

Intramembranous ossification.—In this variety of ossification, the bone is not preceded by cartilage at all, and therefore no endochondral bone is formed, but the calcification occurs in a sort of embryonic fibrous tissue which contains numerous osteoblasts and blood-vessels (fig. 90). The fibres of this tissue (osteogenic fibres), which, like those of fibrous tissue, are collected into small bundles, become inclosed in a calcareous matrix, produced by the deposition of lime salts in the ground-substance of the connective tissue; and as the fibres grow, the calcification extends further and further, so that bony spicules are formed, which, as they become thickened, run together to form reticular layers, leaving spaces filled with osteoblasts around the blood-vessels. The osteogenic fibres are covered with osteoblasts, and as the bone forms, some of these become left as bone-corpuscles within lacunæ. Thus in every particular the development of these bones resembles that of the subperiosteal layer of endochondral bone; which is also to be considered as an instance of intramembranous ossification, although taking place on the surface of cartilage. Moreover, it is the same subperiosteal tissue which, in endochondral

ossification, deposits the true or secondary bone upon those parts of the calcified cartilage-matrix which have escaped absorption; and this must also, therefore, be reckoned as developed according to the same type. In fact, even in intracartilaginous ossification, very little of the

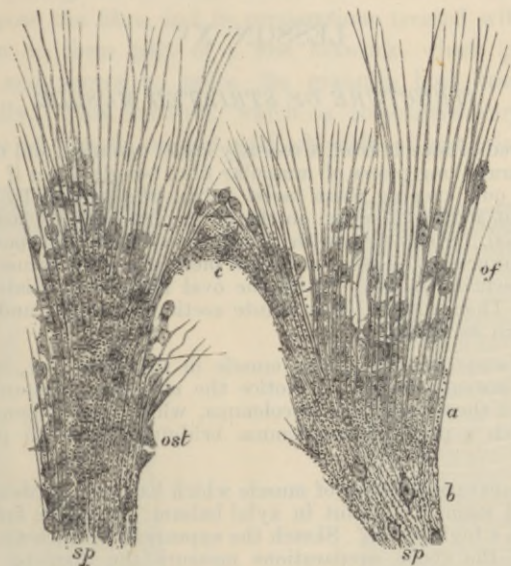


FIG. 90.—PART OF THE GROWING EDGE OF THE DEVELOPING PARIETAL BONE OF A FETAL CAT, $1\frac{1}{2}$ INCH LONG. (From a drawing by Mr. J. Lawrence.)

sp, bony spicules, with some of the osteoblasts embedded in them, producing the lacunæ; *of*, osteogenic fibres prolonging the spicules, with osteoblasts (*ost*) between them and applied to them; *a*, granular calcific deposit occurring in the ground-substance between the fibres; *c*, union of two adjacent spicules.

calcified cartilage-matrix eventually remains; this being almost wholly absorbed and either replaced by true or fibrous bone which has been formed by osteoblasts, or swept away to form the medullary and other cavities.

LESSON XV.

STRUCTURE OF STRIATED MUSCLE.

1. TAKE a shred of muscle from a recently killed mammal, and on a dry slide carefully separate long pieces of muscular fibre (single fibres if possible) and stretch them out, keeping them moist during the process by breathing on the slide. Put a drop of serum on the cover-glass before placing this over the preparation. Study first with a low, then with a high power. Sketch all the appearances to be seen in a small piece of a fibre, focussing carefully the most superficial layers. Notice the oval nuclei immediately under the sarcolemma. Then allow a little dilute acetic acid to run under the cover-glass and watch its effect.

2. Prepare some fibres of frog's muscle in the same way, but mount in salt solution instead of serum. Notice the muscular substance shrinking away here and there from the sarcolemma, which then becomes distinctly visible. Sketch a piece of sarcolemma bridging across an interval thus produced.

3. Study transverse sections of muscle which has been hardened in alcohol or formol and stained. Mount in xylol balsam. Examine first with a low and then with a high power. Sketch the appearances which are seen.

In each of the above preparations measure the diameter of some of the fibres.

4. Place in 1 per cent. osmic acid a small shred of mammalian muscular tissue which has been stretched upon a cork. After 24 hours, when it will be deeply stained, wash it in water and with needles break the fibres up in glycerine as finely as possible. Cover and examine with a high power.

Voluntary muscle is composed of long cylindrical fibres, measuring on an average about $\frac{1}{500}$ inch in diameter (.05 mm.) in mammalian muscles, but having a length of an inch or more. Each fibre has an elastic sheath, the *sarcolemma*, which incloses the contractile substance. The sarcolemma is seldom distinct, unless the contained substance becomes broken (fig. 91).

The contractile substance of the fibre is characterised by the alternate dark and light stripes which run across the length of the fibre; hence the name, *cross-striated* or *striped muscle*. On focussing, it can be seen that the stripes pass through the whole thickness of the fibre; they may therefore be looked upon as representing alternate disks of dark and light substance. If the substance be very carefully focussed, rows of apparent granules are seen lying in or at the boundaries of

the light streaks, and very fine longitudinal lines may, with a good microscope, be detected uniting the apparent granules (fig. 92). These fine lines, with their enlarged extremities the granules, are more conspicuous in the muscles of insects. They indicate the divisions between the longitudinal elements (*muscle-columns, sarcostyles, fibrils*), which compose the fibre, and in preparations treated with dilute acid they appear to form part of a fine network, which pervades that substance, and serves to unite the granules both transversely and longitudinally. This network, which is sometimes very distinct in preparations of muscle treated with chloride of gold, is, however, a

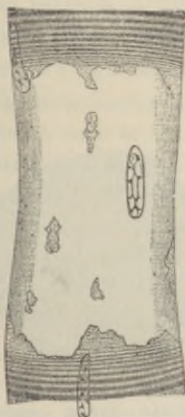


FIG. 91.—SARCOLEMA OF MAMMALIAN MUSCLE HIGHLY MAGNIFIED.

The fibre is represented at a place where the muscular substance has become ruptured and has shrunk away, leaving the sarcolemma (with a nucleus adhering to it) clear. The fibre had been treated with serum acidulated with acetic acid.




FIG. 92.—MUSCULAR FIBRE OF A MAMMAL EXAMINED FRESH IN SERUM, HIGHLY MAGNIFIED, THE SURFACE OF THE FIBRE BEING ACCURATELY FOCUSED.

The nuclei are seen on the flat at the surface of the fibre, and in profile at the edges.

network in appearance only: in reality it is the optical expression of the interstitial substance which lies between the muscle-columns. This substance is termed *sarcoplasm*.

On examining the transverse section of a fibre with a high power, it is seen to be subdivided everywhere into small angular fields, *Cohnheim's areas* (fig. 94). These represent sections of the sarcostyles of which the fibres are composed, and into which they may be split after death, or after being hardened in certain reagents, *e.g.* chromic acid or osmic acid. The interstitial substance or sarcoplasm lies between them and can be made visible by treatment with dilute acid or by staining with chloride of gold (figs. 96, 97).

A fine clear line is sometimes seen running transversely across the fibre in the middle of each dark band. This is termed *Hensen's line*.

If instead of focussing the surface of the fibre it be observed in its depth, an appearance different from that shown in fig. 92 is frequently visible, namely, a fine dotted line (*Dobie's line*), bisecting each clear stripe (fig. 93); this appearance is often considered to represent a membrane (*Krause's membrane*), which subdivides the sarcostyles at regular intervals (see p. 87). But Krause's membrane is rarely, if ever, visible in fresh mammalian muscle, and it is much more



FIG. 93.—PORTION OF A MEDIUM-SIZED HUMAN MUSCULAR FIBRE, SHOWING THE INTERMEDIATE LINE MENTIONED IN THE TEXT. (Sharpey.)

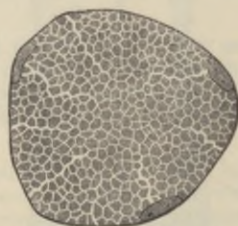


FIG. 94.—SECTION OF A MUSCULAR FIBRE, SHOWING AREAS OF CONHEIM.

Three nuclei are seen lying close to the sarcolemma.

probable that the line in question is an interference line, caused by the light being transmitted between disks of different refrangibility. Haycraft believes that the cross-striation of voluntary muscle is entirely due to refractive effects produced by a varicosity of the component fibrils, basing his view upon the fact that in impressions of the fibres made in soft collodion all the cross-striations which are observed in the fibre itself are reproduced. There can be no doubt that a well marked cross-striated appearance can be produced in homogeneous fibrils by regularly-occurring varicosities, and many of the appearances observed in muscle may, as Haycraft contends, be referred to this cause. But even when a fibre or fibril is stretched so that it exhibits

no varicosities, the cross-striations are still perfectly distinct (fig. 98, B, C, D). Moreover, in view of the entirely different manner in which the substance of the dark and clear stripes behave to many staining reagents, and especially to chloride of gold when applied as directed in Lesson XVI., § 3, the fact being that very definite structural appearances can under these circumstances be made out, the homogeneity of the muscle-fibril cannot be admitted.

Besides the sarcolemma and striated substance, a muscular fibre also exhibits a number of oval nuclei which have the usual structure of cell-nuclei: their chromoplasm often has a spiral arrangement. Sometimes there is a little granular substance (protoplasm) at each pole of the nucleus; each nucleus with the adjacent protoplasm has been spoken of as a *muscle-corpuscle*. In mammalian muscle the nuclei usually lie immediately under the sarcolemma (figs. 91, 92, 94). But some animals, such as the rabbit, have, besides muscles of the ordinary type of structure which in this animal are pale in colour, others of a deep red colour. These *red muscles* were found by Ranvier to exhibit certain differences both in structure and function. One difference of structure is that the nuclei are not confined to the surface, but are scattered throughout the substance of the fibres. Here and there, in all mammals, amongst the ordinary fibres are some in which the nuclei are distributed through the thickness of the fibres; this is the case also in the muscular fibres of the frog. In some muscle-fibres, such as those of the diaphragm, which are in constant activity, the protoplasm of the muscle-corpuscles is often greatly developed.

The transverse section of a muscle shows the fibres to be nearly cylindrical in figure. Between the fibres there is a certain amount of areolar tissue, which serves to support the blood-vessels and also unites the fibres into fasciculi; the fasciculi are again united together by a larger amount of this intramuscular connective tissue (*endomysium*).

LESSON XVI.

STRUCTURE OF STRIATED MUSCLE (continued).

1. Cut off the head of a beetle or other insect (*e.g.* wasp), and bisect the trunk with scissors so as to expose the interior. Notice two kinds of muscular tissue, the one belonging to the legs greyish in colour, the other attached to the wings yellowish. Preparations of both kinds of muscle are to be made in the same way as living mammalian muscle (see previous Lesson), but it is better to mount them either in a drop of white of egg or of the insect's blood. In both preparations the dark-looking air-tubes or tracheæ form prominent objects ramifying amongst the fibres. Observe the structure of the two kinds of muscle so far as it can be made out in the fresh preparation. If the preparation is made quickly, waves of contraction will probably be observed passing along the fibres.

2. Make another preparation, mounting the muscle in vinegar. (Alcohol-hardened muscle may be used for this purpose.) Notice that the muscular substance swells up somewhat and becomes clearer, whilst the sarcoplasm-network of the leg muscles, with its lines and dots, comes more distinctly into view. In a well-teased preparation of alcohol-hardened muscle, the leg-fibres will be frequently found breaking across into disks. Make careful drawings from this preparation.

3. Rollett's method. Place an insect (wasp, small beetle) into 90 per cent. alcohol for from 24 to 48 hours. Then take a small piece of each kind of muscle, and place in strong glycerine for some hours. Transfer to 1 per cent. chloride of gold solution: leave the pieces of muscle in this from 15 to 30 minutes according to their size. From the gold solution they are transferred to formic acid (1 part of the strong acid to 3 of water), and kept in the dark for 24 hours, but they may be kept longer without disadvantage. The muscle is then teased in glycerine. Some of the fibres will be found after this method to have their sarcoplasm darkly stained, and to show, therefore, the appearance of a network both in longitudinal and transverse view: others, on the other hand, have the sarcous elements stained, and the sarcostyles thereby rendered very evident, but the sarcoplasm is unstained. Some fibres may show an intermediate condition.

Ordinary or leg-muscles of insects.—In the muscles of insects the stripes are relatively broad, and their structure can be more readily seen than in mammals. In the living fibres from the muscles which move the legs, the sarcoplasm presents a striking appearance of fine longitudinal lines traversing the muscle, and enlarging within the light stripes into rows of dots (fig. 95). This is still better seen in fibres and portions of fibres which have been treated with dilute acid (fig. 96). In separated disks produced by the breaking across of

muscle-fibres, the surfaces of the disks show a network with polyhedral meshes in some insects (fig. 97, A), one formed of lines radiating from the centre of the fibre in others (fig. 97, B). The nuclei, with some inclosing protoplasm, usually lie in the middle of the fibre.

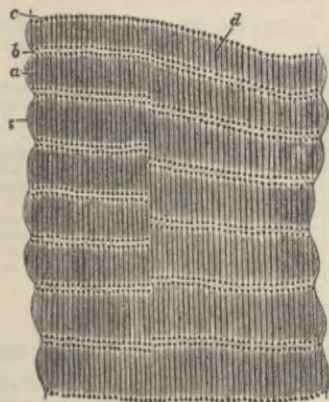


FIG. 95.—LIVING MUSCLE OF WATER-BEETLE (*DYTISCU MARGINALIS*.) (Highly magnified.)

s, sarcolemma; *a*, dim stripe; *b*, bright stripe; *c*, row of dots in bright stripe, which seem to be the enlarged ends of rod-shaped particles, *d*, but are really expansions of the interstitial sarcoplasm.

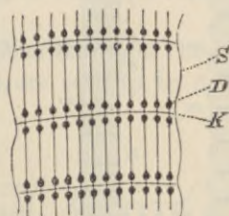


FIG. 96.—PORTION OF LEG-MUSCLE OF INSECT TREATED WITH DILUTE ACID.

S, sarcolemma; *D*, dot-like enlargement of sarcoplasm; *K*, Krause's membrane. The sarcous elements are swollen and dissolved by the acid.

Wing-muscles of insects.—The wing-muscles of insects are easily broken up into sarcostyles (fibrils), which also show alternate dark and light striae.

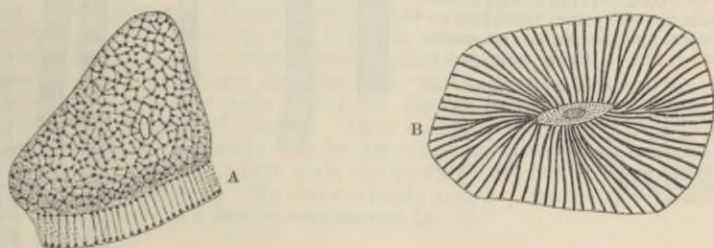


FIG. 97.—TRANSVERSE SECTIONS OF INSECT LEG-MUSCLE, VIEWED IN ISOLATED DISKS, TREATED WITH DILUTE ACID.

A, from a beetle. The disk is viewed partly on the flat, partly in profile; the sarcoplasm appears longitudinally as lines, transversely as a network.

B, from a wasp, showing a radial disposition of the sarcoplasm.

The sarcostyles are subdivided at regular intervals by thin transverse disks (*membranes of Krause*) into successive portions, which may be termed *sarcomeres*. Each sarcomere is occupied by a portion of the dark stria of the whole fibre (*sarcous element*): the sarcous element

is really double, and in the stretched fibre separates into two at the line of Hensen (figs. 98, D; 99, B). At either end of the sarcous element is a clear interval separating it from the membrane of Krause: this clear interval is more evident the more the sarcostyle is extended,

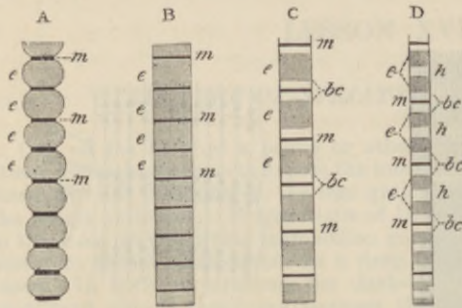


FIG. 98.—FIBRES OF THE WING-MUSCLES OF AN INSECT. (Ranvier.)

The fibres are in different conditions of extension from A least extended, to D most extended. *e, e*, sarcous elements; *m, m*, membranes of Krause; *bc*, clear intervals on either side of Krause's membranes, which in the stretched sarcostyles are occupied by fluid which has passed out from the pores of the sarcous elements; *h*, separation of the sarcous element into two parts, a clear interval being left between them.

but diminishes to complete disappearance in the contracted muscle (figs. 98, 99, A). The cause of this is to be found in the structure of the sarcous element. Each sarcous element is pervaded with longitudinal canals or pores, which are open in the direction of

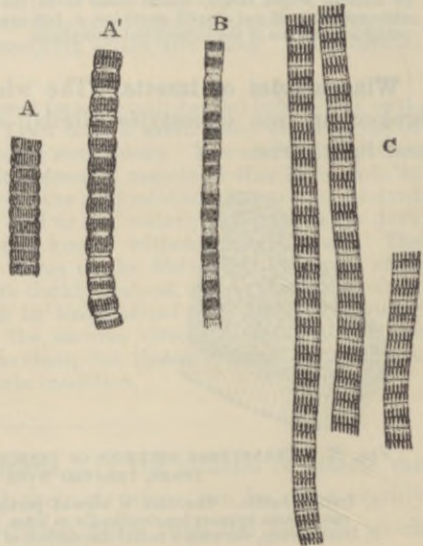


FIG. 99.—SARCOSTYLES OF THE WING-MUSCLES OF A WASP, PREPARED IN THE MANNER DESCRIBED IN LESSON XVI., SEC. 3. (Highly magnified.)

A, A', sarcostyles showing degrees of contraction. B, an extended sarcostyle, with its sarcous elements separated at the line of Hensen. C, three sarcostyles moderately extended. The structure of the sarcous elements is shown in these.

Krause's membranes, but closed at the middle of the sarcous element. In the contracted or retracted muscle, the clear part of the muscle-substance has passed into these pores, and has therefore disappeared from view, but swells up the sarcous element and shortens the sarcomere:

in the extended muscle, on the other hand, the clear part has passed out from the pores of the sarcous element, and now lies between this and the membrane of Krause, the sarcomere being thereby lengthened and narrowed. The sarcous element does not lie free in the middle of the sarcomere, but is attached laterally to a fine inclosing envelope, and at either end to Krause's membrane by very fine lines, which may represent fine septa, running through the clear substance (fig. 101).

When muscle-fibres are examined with polarised light between crossed Nichol's prisms, the sarcous elements are seen to be doubly refracting.

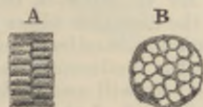

FIG. 100.—ISOLATED SARCOUS ELEMENTS OF A WING-MUSCLE, SHOWING THE TUBULAR OR POROUS STRUCTURE. (Magnified 2300 diameters.)

A, profile view; B, surface view, seen on the flat.

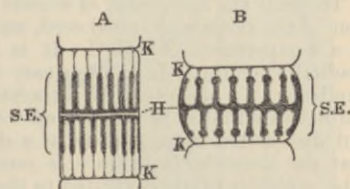


FIG. 101.—DIAGRAM OF A SARCOMERE IN A MODERATELY EXTENDED CONDITION, A, AND IN A CONTRACTED CONDITION, B.

K, K, membranes of Krause; H, line or plane of Hensen; S.E., poriferous sarcous element.

If we compare the structure of the sarcomere with that of the protoplasm of an amoeboid cell we find several points in common. In both there is a framework of labile material (spongioplasm, substance of sarcous element), which tends to stain with hæmatoxylin and similar reagents, and which incloses in its meshes or pores a clear, probably semi-fluid substance (hyaloplasm, clear substance of sarcomere), which remains unstained by these reagents. In both instances also the clear substance or hyaloplasm, when the tissue is subjected to stimulation, passes into the pores of the porous substance or spongioplasm (contraction), whilst in the absence of such stimulation it tends to pass out from the spongioplasm (formation of pseudopodia, extension of muscle). Thus both the movements of cell-protoplasm and those of muscle may be described as being brought about by similar means, although at first sight the structure of muscle is so dissimilar from that of protoplasm. We have already noticed that the movements of cilia are susceptible of a similar explanation (p. 42).

LESSON XVII.

CONNECTION OF MUSCLE WITH TENDON; BLOOD-VESSELS OF MUSCLE; CARDIAC MUSCULAR TISSUE; DEVELOPMENT OF MUSCLE; PLAIN MUSCULAR TISSUE.

1. To study the connection of muscle with tendon, a frog is killed by destruction of the brain and spinal cord, and placed in about a litre of water raised to a temperature of 55° C. It is left in this for 15 minutes, the water gradually cooling. It is then easy to dissociate the muscular fibres in large numbers. To observe their attachment to the tendon-bundles a fine longitudinal shred must be snipped off with scissors at the tendinous attachment, and dissociated upon a slide in a drop of water. It will usually be found that the muscular substance is retracted from the end of the sarcolemma tube, which is firmly cemented to the tendon bundle. The structure may be brought more distinctly into view by adding to the dissociated fibres a drop of a weak solution of iodine in salt solution or in serum (iodised serum).¹ To preserve the specimen, mount it in dilute glycerine coloured by magenta.

2. The blood-vessels of muscle. These are to be studied in longitudinal and transverse sections of injected muscle. It will be noticed that the capillaries are very numerous, and form a network with oblong meshes. In the red muscles of the rabbit, small dilatations are seen on the transverse cords of the network.

3. The muscular tissue of the heart is studied in sections of that organ and also in teased preparations. To prepare the latter, place a small piece of heart-muscle in 30 per cent. alcohol for a few days: stain in picro-carmin solution (see Appendix) for some hours; and tease in dilute glycerine.

4. Tear off a small shred of the muscular coat of a piece of intestine which has been from 24 to 48 hours in $\frac{1}{8}$ per cent. bichromate of potash solution or in 30 per cent. alcohol. Hold the shred with forceps in a drop of water and fray it out with a needle. In this process many cells will be set free and can be seen with a low power. The preparation may then be covered and examined with a high power. Sketch one of the cells. Then allow dilute hæmalum or carmalum solution to pass under the cover-glass and lastly a drop of glycerine. Sketch another cell after staining. Measure two or three cells and their nuclei.

Ending of muscle in tendon.—A small tendon-bundle passes to each muscular fibre and becomes firmly united with the sarcolemma, which extends over the end of the fibre (fig. 102). Besides this immediate attachment, a further connection is established by the

¹This method is the one given by Ranvier (*Traité Technique*, 2me édition, p. 395). The muscle-endings may also sometimes be well seen at the extremities of the tendons, which are removed from the mouse's tail in the manner described in Lesson X.

fact that the areolar tissue between the tendon-bundles is continuous with that which lies between the muscular fibres.

Blood-vessels of muscle.—The capillaries of muscular tissue are very numerous. They run, for the most part, longitudinally, with transverse branches, so as to form long oblong meshes (fig. 103). No blood-vessels ever penetrate the sarcolemma. In the red muscles of the rabbit, the transverse capillaries have small dilatations upon

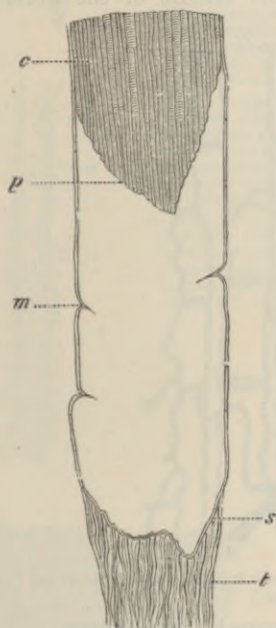


FIG. 102.—TERMINATION OF A MUSCULAR FIBRE IN TENDON. (Ranvier.)

m, sarcolemma; *s*, the same membrane passing over the end of the fibre; *p*, extremity of muscular substance, *c*, retracted from the lower end of the sarcolemma-tube; *t*, tendon-bundle passing to be fixed to the sarcolemma.

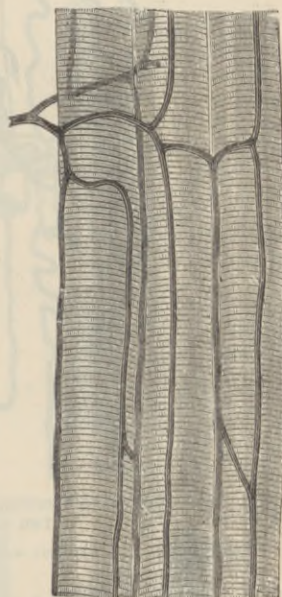


FIG. 103.—CAPILLARY VESSELS OF MUSCLE.

them (fig. 104). Associated with this and other peculiarities of structure (see p. 85), it is found that the red muscles have a much slower rate of contraction and a much longer period of latency than the ordinary muscles.

Lymphatic vessels, although present in the connective-tissue sheath (perimysium) of a muscle, do not penetrate between its component fibres.

The **nerves** of voluntary muscles pierce the sarcolemma and

terminate in a ramified expansion known as an *end-plate* or *end-organ* (see Lesson XX.).

Development.— Voluntary muscular fibres are developed from embryonic cells of the mesoderm, which become elongated, and the nuclei of which become multiplied, so as to produce long multi-nucleated fusiform or cylindrical fibres. These become cross-striated, at first along one side, the change gradually extending around the fibre and also towards the centre; but the middle of the fibre, to

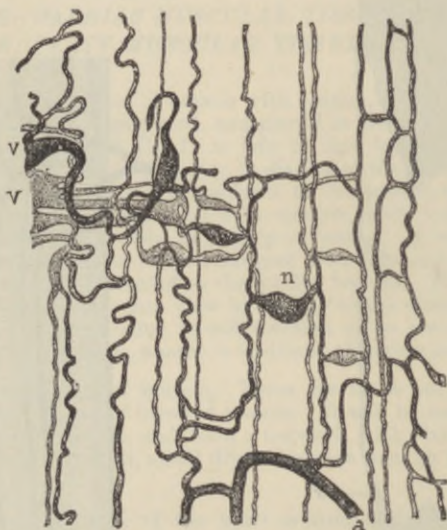


FIG. 104.—VASCULAR NETWORK OF A RED MUSCLE (SEMI-TENDINOSUS) OF THE RABBIT. (Ranvier.)

a, arteriole; *v*, *v*, venules; *n*, dilatation on transverse branch of capillaries.

which the nuclei are at first confined, remains for some time unaltered (fig. 105). Eventually the change in structure extends to this also, and the nuclei pass gradually to occupy their ordinary position under the sarcolemma, which has also become formed.

CARDIAC MUSCLE.

The muscular substance of the heart is composed of transversely striated muscular fibres, which differ from those of voluntary muscle in the following particulars, viz. :—their striations are less distinct; they have no sarcolemma; they branch and unite with neighbouring fibres, and their nuclei lie in the centre of the fibres. Moreover, the fibres are composed of a series of short cylindrical cells (figs. 106, 107) joined together end to end, each corresponding to one of the nuclei.

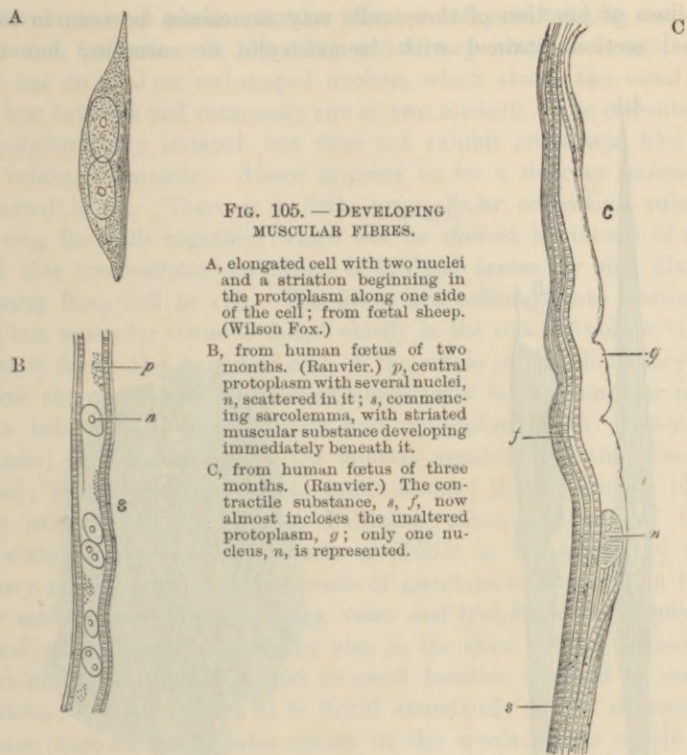


FIG. 105. — DEVELOPING MUSCULAR FIBRES.

A, elongated cell with two nuclei and a striation beginning in the protoplasm along one side of the cell; from foetal sheep. (Wilson Fox.)

B, from human foetus of two months. (Ranvier.) *p*, central protoplasm with several nuclei, *n*, scattered in it; *s*, commencing sarcolemma, with striated muscular substance developing immediately beneath it.

C, from human foetus of three months. (Ranvier.) The contractile substance, *s*, *f*, now almost incloses the unaltered protoplasm, *g*; only one nucleus, *n*, is represented.

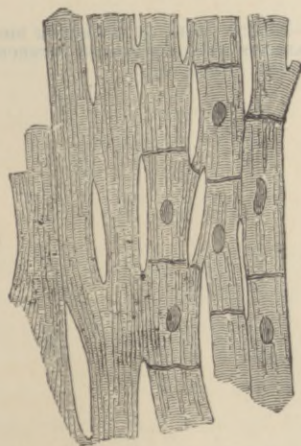


FIG. 106. — MUSCULAR FIBRES FROM THE HEART, MAGNIFIED, SHOWING THEIR CROSS-STRIÆ, DIVISIONS, AND JUNCTIONS. (Schweigger-Seidel.)

The nuclei and cell-junctions are only represented on the right-hand side of the figure

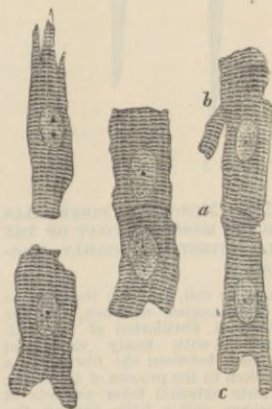

FIG. 107. — SIX MUSCULAR FIBRE-CELLS FROM THE HEART. (Magnified 425 diameters.)

a, line of junction between two cells; *b*, *c*, branching of cells. (From a drawing by J. E. Neale.)

The lines of junction of these cells may sometimes be seen in longitudinal sections stained with hæmatoxylin or carmine; but they

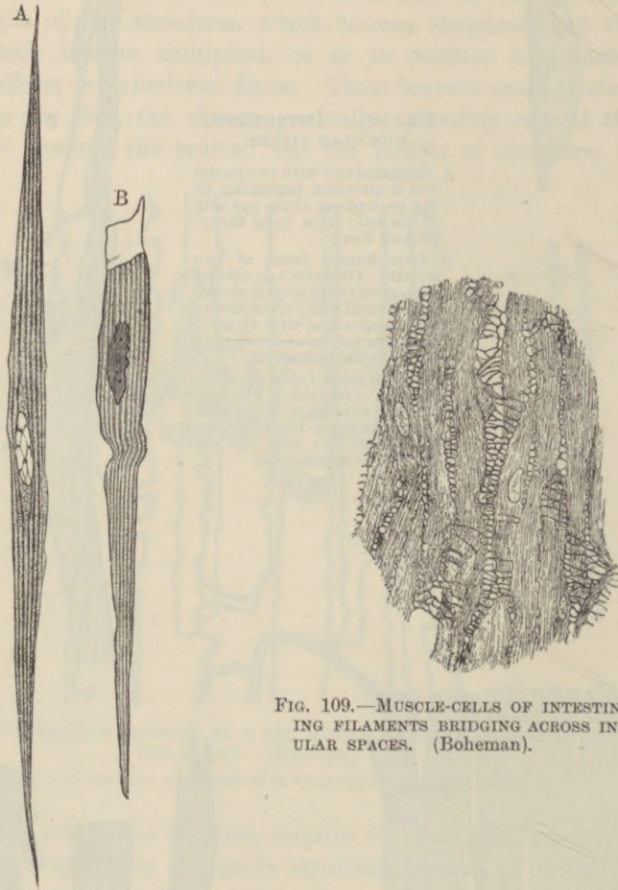


FIG. 108.—MUSCULAR FIBRE-CELLS FROM THE MUSCULAR COAT OF THE SMALL INTESTINE, HIGHLY MAGNIFIED.

A, a complete cell, showing the nucleus with intra-nuclear network, and the longitudinal fibrillation of the cell-substance, with finely vacuolated protoplasm between the fibrils; B, a cell broken in the process of isolation; a delicate external layer projects at the broken end a little beyond the striated substance of the cell.

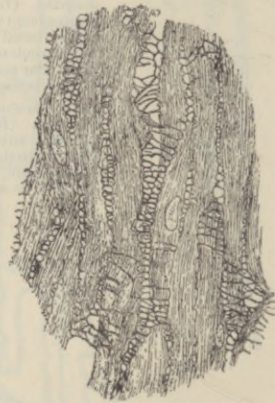

FIG. 109.—MUSCLE-CELLS OF INTESTINE SHOWING FILAMENTS BRIDGING ACROSS INTERCELLULAR SPACES. (Boheman).

come much more distinctly into view in sections of the fresh tissue stained with nitrate of silver.

Involuntary or **plain muscular tissue** is composed of long, somewhat flattened, fusiform cells (fig. 108), which vary much in length. Each cell has an oval or rod-shaped nucleus, which shows the usual intranuclear network and commonly one or two nucleoli. The cell-substance is longitudinally striated, but does not exhibit cross-striæ like those of voluntary muscle. There appears to be a delicate non-striated external layer. There is a little intercellular cementing substance uniting the cells together, which can be stained by nitrate of silver, and this intercellular substance is bridged across by fine filaments passing from cell to cell. The fibres are collected into fasciculi.

Plain muscular tissue is found chiefly in the walls of hollow viscera; thus it forms the muscular coat of the whole of the alimentary canal below the œsophagus, and occurs abundantly in the muscular coat of that tube also, although it is here intermixed with cross-striated muscle; it is found also in the mucous membrane of the alimentary canal; in the trachea and its ramifications; in the urinary bladder and ureters; in the uterus, Fallopian tubes, and ovary; in the prostate, the spleen, and muscle of Müller in the orbit, and in the ciliary muscle and iris. The walls of gland ducts also contain it, and the middle coat of the arteries, veins and lymphatics is largely composed of this tissue. It occurs also in the skin, both in the secreting part of the sweat-glands, and in small bundles attached to the hair-follicles; in the scrotum it is found abundantly in the subcutaneous tissue (dartos), and it also occurs in the areola of the nipple.

LESSON XVIII.

STRUCTURE OF NERVE-FIBRES.

1. TEASE a piece of fresh nerve rapidly in salt solution (or by the method of semidesiccation, afterwards mounting in salt solution), injuring the fibres as little and obtaining them as long and straight as possible. Study the medullated fibres, carefully noticing all the structures that are visible—viz., nodes of Ranvier, nuclei of primitive sheath, double contour of medullary sheath, medullary segments, etc. Measure the diameter of half a dozen fibres. Draw a short length of a fibre very exactly.

2. Prepare a piece of sympathetic nerve in the same way. The nerves passing to the spleen are the best for the study of non-medullated fibres. Measure and sketch as before.

3. Separate (in dilute glycerine) into its fibres a small piece of nerve or nerve-root that has been twenty-four hours in $\frac{1}{2}$ per cent. osmic acid. The nerve should have been moderately stretched on a piece of cork by means of glass pins before being placed in the acid. Keep the fibres as straight as possible and only touch them near their ends with the needles. Sketch two portions of a fibre under a high power, one showing a node of Ranvier and the other a nucleus of the primitive sheath. Look for fibres of Remak. Measure the length of the nerve-segments between the nodes of Ranvier.

4. Mount in xylol balsam sections of a nerve which has been hardened in picric acid. Stain with picro-carmin or hæmatoxylin. The nerve should be straightened out before being placed in the hardening solution. Examine the sections first with a low and afterwards with a high power. Notice the lamellar structure of the perineurium, the varying size of the nerve-fibres, the axis cylinder in the centre of each fibre, etc. Measure the diameter of five or six fibres, and sketch a small portion of one of the sections.

5. Mount in glycerine sections of a splenic nerve (of ox or sheep) which was placed as soon as possible after death in 1 per cent. osmic acid.

Nerve-fibres are of two kinds, *medullated* and *non-medullated*. The cerebro-spinal nerves and the white matter of the nerve-centres are composed of medullated fibres; some of the sympathetic nerves are largely made up of non-medullated fibres.

The **medullated** or **white fibres** are characterised, as their name implies, by the presence of the so-called *medullary sheath* or *white substance*. This is a layer of soft substance, physically of a fatty nature, which encircles the essential part of a nerve-fibre, viz., the *axis-cylinder*. Outside the medullary sheath is a delicate but tough homogeneous membrane, the *primitive sheath* or *nucleated sheath* of

Schwann, but this is not present in all medullated fibres, being absent in those which are within the nerve-centres. The primitive sheath is also known as the *neurolemma*.

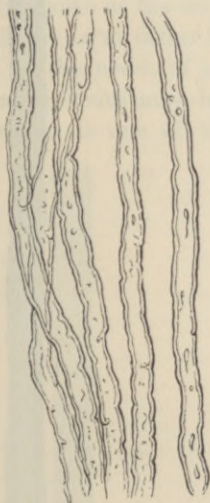

FIG. 110.—WHITE OR MEDULLATED NERVE-FIBRES, SHOWING THE SINUOUS OUTLINE AND DOUBLE CONTOURS. 114

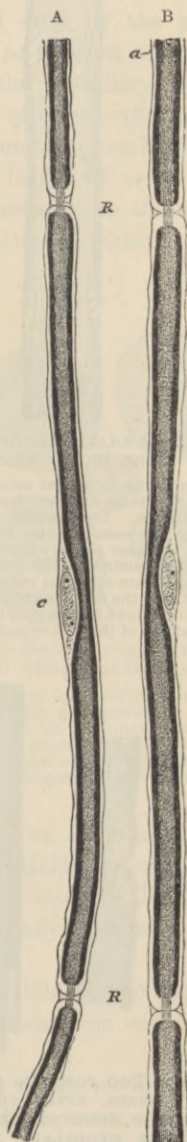


FIG. 111.—PORTIONS OF TWO NERVE-FIBRES STAINED WITH OSMIC ACID (FROM A YOUNG RABBIT). (425 diameters.)

R, R, nodes of Ranvier, with axis-cylinder passing through. *a*, primitive sheath of the nerve; *c*, opposite the middle of the segment, indicates the nucleus and protoplasm lying between the primitive sheath and the medullary sheath. In *A* the nodes are wider, and the intersegmental substance more apparent than in *B*. (Drawn by J. E. Neale.)

The *medullary sheath* is composed of a highly refracting fatty material, which gives a characteristic dark contour and tubular appearance



FIG. 112.—A SMALL PART OF A MEDULLATED FIBRE, HIGHLY MAGNIFIED.

The fibre looks in optical section like a tube—hence the term tubular, formerly applied to these fibres. Two partial breaches of continuity are seen in the medullary sheath, which at these places exhibits a tendency to split into laminae. The primitive sheath is here and there apparent outside the medullary sheath, and the delicate striae which are visible in the middle of the fibre probably indicate the fibrillations of the axis-cylinder.

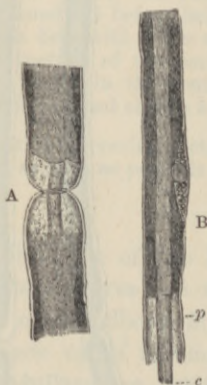


FIG. 114.—TWO PORTIONS OF MEDULLATED NERVE-FIBRES, AFTER TREATMENT WITH OSMIC ACID, SHOWING THE AXIS-CYLINDER AND THE MEDULLARY AND PRIMITIVE SHEATHS. (Key and Retzius.)

A, node of Ranvier. B, middle of an internode with nucleus. *c*, axis-cylinder, projecting; *p*, primitive sheath, within which the medullary sheath, which is stained dark by the osmic acid, is somewhat retracted



FIG. 113.—NERVE-FIBRE STAINED WITH OSMIC ACID. (Key and Retzius.)
K, nucleus; L, node of Ranvier.

to the nerve-fibres (fig. 110). It affords a continuous investment to the axis-cylinder, except that, as was shown by Ranvier, it is interrupted at regular intervals in the peripheral nerve-fibres, the axis-cylinder at these places being encompassed only by the primitive sheath. Hence the primitive sheath appears to produce a constriction in the nerve-fibre, and the interruptions of the medullary sheath are accordingly known as the *constrictions* or *nodes of Ranvier* (fig. 111, R, R; fig. 113, L), the term nodes being applied from the resemblance which they bear to the nodes of a bamboo. The length of nerve between two successive nodes may be termed an internode; in the middle of each internode is one of the nuclei of Schwann's sheath. Besides



FIG. 115.—AXIS-CYLINDER, HIGHLY MAGNIFIED, SHOWING THE FIBRILS COMPOSING IT. (M. Schultze.)

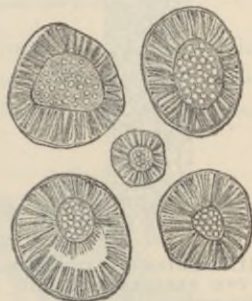


FIG. 116.—SECTION ACROSS FIVE NERVE-FIBRES. (Magnified 1000 diameters.)

The nerve was hardened in picric acid and stained with picro-carmin. The radial striation of the medullary sheath is very apparent. In one fibre the rays are broken by shrinkage of the axis-cylinder. The fibrils of the axis-cylinder appear tubular.

these interruptions the medullary sheath shows a variable number of oblique clefts (figs. 111, 113), which subdivide it into irregular portions, which have been termed *medullary segments*, but there is reason to believe that the clefts are artificially produced. Osmic acid stains the medullary sheath black.

The *axis-cylinder*, which runs along the middle of the nerve-fibre, is a soft transparent thread which is continuous from end to end of the nerve.¹

On account of the peculiar refractive power of the medullary sheath it is difficult to see the axis-cylinder in the fresh nerve except at the nodes, where it may be observed stretching across the interruption in

¹ According to Engelmann the axis-cylinder is probably not structurally continuous across the nodes of Ranvier.

the medullary sheath, and it may also sometimes be seen projecting from a broken end of a nerve-fibre. It is longitudinally striated,

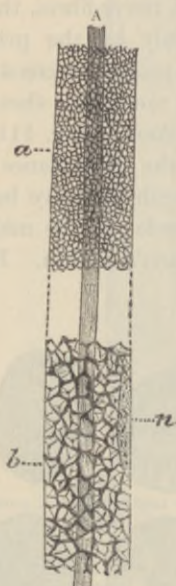


FIG. 117.—RETICULAR APPEARANCES IN THE MEDULLARY SHEATH OF NERVE-FIBRES. (Gedoelst.)

The reticulum is finer at *a*, coarser at *b*; *n*, nucleus of fibre; *A*, axis-cylinder.

being made up of exceedingly fine fibrils (*ultimate fibrils*, fig. 115), which are stained darkly by chloride of gold. Staining with nitrate of silver produces a curious transversely striated appearance in the axis-cylinder, but it is not known if this indicates a pre-existent structure. Kühne has described a special reticular sheath of the axis-cylinder lying within the medullary sheath, and composed of a peculiar chemical substance termed *neurokeratin*. The reticulum is, however, situated within the substance of the medullary sheath (fig. 117), and it is by no means clear that it is not produced by the action of the reagents employed to show it.

Non-medullated fibres.—Intermingled with the medullated fibres there may always, even in the cerebrospinal nerves, be found a certain number of pale fibres devoid of the dark double contour which is characteristic of the presence of a medullary sheath. These are the *grey* or *non-medullated fibres*, also called,

Non-medullated fibres.—Intermingled with the medullated fibres there may always, even in the cerebrospinal nerves, be found a certain number of pale fibres devoid of the dark double contour which is characteristic of the presence of a medullary sheath. These are the *grey* or *non-medullated fibres*, also called,



FIG. 118.—NON-MEDULLATED FIBRE FROM A BRANCH OF THE SYMPATHETIC OF THE RABBIT. (Tuckett.)

after their discoverer, *fibres of Remak* (fig. 118). They frequently branch, which the medullated fibres never do except near their termination, and they are beset with numerous nuclei which perhaps belong to a delicate sheath. The sympathetic nerves are partly made up of fibres of this nature, but, on the other hand, many of the fibres of the sympathetic nerves possess a thin medullary sheath.

Structure of the nerve-trunks.—In their course through the body the nerve-fibres are gathered up into bundles or *funiculi*, and the

funiculi may again be united together to form the nerves which we meet with in dissection. The connective tissue which unites the funiculi and invests the whole nerve, connecting it to neighbouring

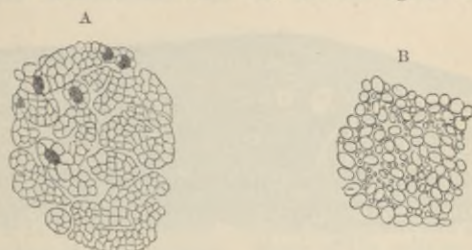

FIG. 119.—SECTIONS ACROSS NON-MEDULLATED FIBRES FROM THE SPLENIC NERVE OF THE OX. (Tuckett.)

A, in an unaltered condition. B, showing post-mortem changes.

parts and conveying to it blood-vessels, lymphatics, and even nerve-fibres destined for its coats, is termed the *epineurium* (fig. 120, *ep*). That which ensheathes the funiculi is known as the *perineurium*

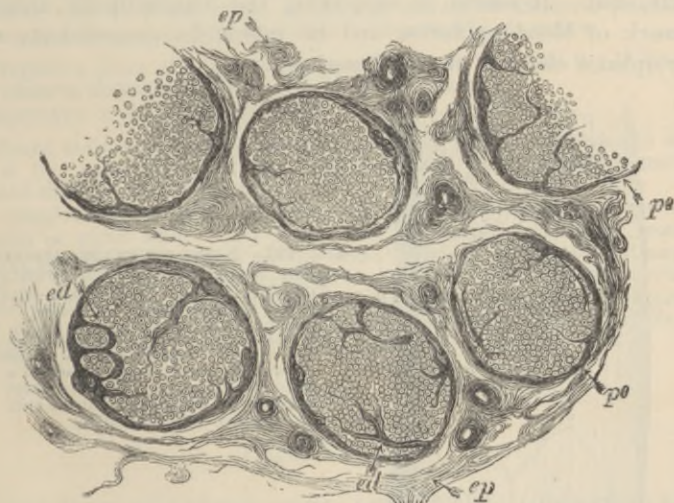

FIG. 120.—SECTION OF A PART OF THE MEDIAN NERVE (HUMAN). (DRAWN AS SEEN UNDER A LOW MAGNIFYING POWER.) (From Landois after Eichhorst.)

ep, epineurium, or general sheath of the nerve, consisting of connective-tissue bundles of variable size separated by cleft-like areolæ, with here and there blood-vessels; *pe*, lamellated connective-tissue sheaths (perineurium) of the funiculi; *ed*, interior of funiculus, showing the cut ends of the medullated nerve-fibres, which are embedded in the connective tissue within the funiculus (endoneurium).

(fig. 120, *pe*). It has a distinctly lamellar structure (fig. 121, *P*), the lamellæ being composed of connective tissue and covered on both surfaces by flattened epithelioid cells (fig. 122). Between the lamellæ

are clefts for the conveyance of lymph to the lymphatics of the epineurium. The delicate connective tissue which lies between the nerve-fibres of the funiculus is the *endoneurium* (fig. 120, *ed* ;

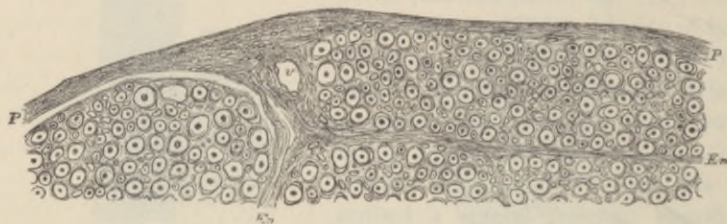

FIG. 121.—PART OF A SECTION OF ONE OF THE FUNICULI OF THE SCIATIC NERVE OF MAN. (Key and Retzius.) (Magnified.)

P, perineurium consisting of a number of closely arranged lamellae; *En*, processes from the perineurium, passing into the interior of the funiculus, and becoming continuous with the endoneurium, or delicate connective tissue between the nerve-fibres. The connective-tissue fibrils of the endoneurium are seen cut across as fine points, often appearing to ensheath the nerve-fibres with a circle of minute dots (fibril-sheath of Key and Retzius). Numerous nuclei of connective-tissue cells are embedded in the endoneurium; *v*, section of a blood-vessel.

fig. 121, *En*). It assists in supporting the longitudinally arranged meshwork of blood-capillaries, and its interstices communicate with the lymphatic clefts of the perineurium.

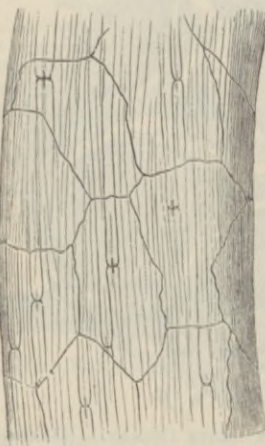

FIG. 122.—NERVE-FUNICULUS STAINED WITH NITRATE OF SILVER SHOWING THE OUTLINES OF EPITHELIOID-CELLS OF THE PERINEURIUM. (Ranvier.)

The dark crosses on the nerve-fibres at the nodes of Ranvier are due to the staining of the axis-cylinder and of a band of intercellular substance which encircles the axis-cylinder at the node (constriction band of Ranvier).

All the branches of a nerve, and even single nerve-fibres which are passing to their distribution, are invested with a prolongation of the perineural sheath, which is then known as the *sheath of Henle*.

The nerve-trunks themselves receive nerve-fibres (*nervi nervorum*) which ramify chiefly in the epineurium and terminate within this in end-bulbs (Horsley).

LESSON XIX.

STRUCTURE OF GANGLIA.

1. PUT a small piece of spinal ganglion into 1 per cent. osmic acid for two or three hours. Place it in water containing a fragment of thymol for two days or more. Tease it in dilute glycerine. Notice the spheroidal ganglion-cells; their large nuclei and distinct nucleoli. Many of the cells may still be seen within their nucleated membranous sheath. Look for cells which still retain the axis-cylinder process and for T-shaped junctions of nerve-fibres with this.

2. Place a spinal ganglion of the rabbit or cat in salt solution containing 1 part in 100 of methylene blue. In an hour's time transfer it to fresh salt solution, and tease a small piece carefully, with the aid of a dissecting microscope in order to isolate some of the cells. The ganglion cells with their processes should appear coloured, and the rest of the tissue nearly colourless. The colour may be fixed by the addition of picrate of ammonia (saturated solution), and the preparation may then be mounted in glycerine.

3. Prepare a piece of sympathetic ganglion as in §§ 1 and 2. If from a rabbit observe that many of the cells are bi-nucleated.

Measure two or three cells in each of the above preparations.

4. Mount stained sections of ganglia in Canada balsam. These will serve to show the arrangement of the cells and fibres in the ganglion and the nucleated sheaths around the nerve-cells.

The ganglia may be fixed and hardened in saturated solution of corrosive sublimate or picric acid. They may either be stained in bulk or sections cut from paraffin and stained on the slide.¹ Or the fresh ganglia may be stained by immersion in 1 per cent. methylene blue in salt solution; rinsed with salt solution; fixed with picrate of ammonia for 15 minutes, then placed for 15 minutes more in Bethe's fixative for methylene blue,¹ and finally hardened in alcohol and prepared for sections in the usual way.

LESSON XX.

NERVE-CELLS OF SPINAL CORD AND BRAIN; DEGENERATION OF NERVE-FIBRES; DEVELOPMENT OF NERVE-CELLS AND FIBRES.

1. TEASE out a portion of the grey matter from a piece of spinal cord that has been a day or two in dilute chromic acid ($\frac{1}{20}$ per cent.), or in 30 per cent. alcohol. Or a little of the grey matter may, after macerating for a day or two in either of the above fluids, be shaken up in a small stoppered bottle, and after standing a little while some of the sediment at the bottom of the bottle may be pipetted off and mounted. Before covering, look for the nerve-

¹ See Appendix.

cells with a low power, and if possible get out one or two clear of the surrounding substance. Mount in water with a thick hair under the cover-glass. Notice the large branching cells, some with a mass of pigment near the nucleus. Observe the fibrillation of the cell-processes. Many axis-cylinders will be seen in this preparation deprived wholly or partially of their medullary sheath, and their fibrillar structure can then also be well seen. Carefully sketch these appearances. To keep this preparation run solution of osmic acid or picro-carmin under the cover-glass, and when the cells are stained allow a drop of glycerine to pass in by diffusion. Or the picro-carmin may be added to the debris in the bottle and the whole left to stain for some hours and then the cells sought out. Similar preparations may be made from the grey matter of the cerebral cortex and cerebellar cortex.

2. Examine the nerve-cells and neuroglia-cells in sections from the spinal cord, cerebrum, and cerebellum of a small animal, *e.g.* young rat or kitten, prepared either by Golgi's or by Ehrlich's method.¹ The sections with Golgi's method must be mounted in thick xylol balsam without a cover-glass, and the balsam dried rapidly on a warm plate.

3. Make teased preparations from a nerve which, some days previously, has been cut nearer the spinal cord. The nerve should have been prepared with osmic acid, as in Lesson XVIII., § 3. Notice the breaking up of the myelin of the medullary sheath, varying in degree according to the length of time the section has been made previously. In preparations from the central cut end of the nerve new fibres may be seen budding from near the extremities of the undegenerated fibres of the stump.

Nerve-cells only occur in the grey matter of the nerve-centres, and in little groups on the course of certain of the peripheral nerves, these groups often causing nodular enlargements of the nerves, which are known as *ganglia*. The most important ganglia are those which are found upon the posterior roots of the spinal nerves, upon the roots of some of the cranial nerves, and upon the trunk and principal branches of the sympathetic nerve. Minute ganglia are also found very numerously in connection with the nerves which are supplied to involuntary muscular tissue, as in the heart, alimentary canal, bladder, uterus, etc.

Nerve-cells vary much in size and shape; many are large, some being amongst the largest cells met with in the body, but others are quite small. The nucleus is generally large, clear, and spherical, with a single large and distinct nucleolus; there may also be a network of chromoplasm, but this is not always to be seen. The protoplasm is fibrillated, the fibrils passing into the processes. It also sometimes contains peculiar angular granules (Nissl's granules) staining darkly with methylene blue (fig. 124). Many nerve-cells have a clump of pigment granules at one side of the nucleus. This is especially marked in certain localities (*locus cœruleus*, *locus niger*).

¹See Appendix.

Every nerve-cell has one or more processes. These processes are of two kinds. The first kind is that known as the *axis-cylinder process* or *nerve-fibre process*, so called (by Deiters) because it becomes

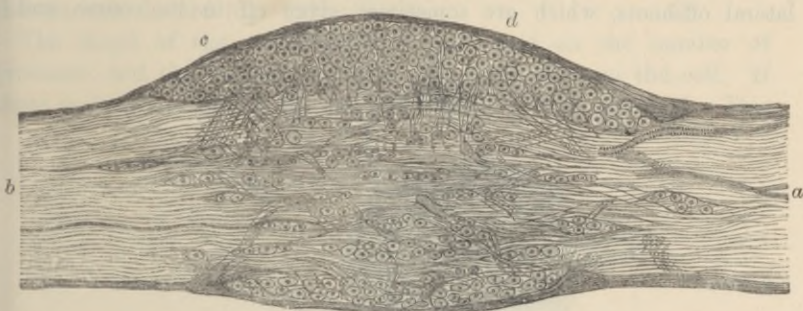

FIG. 123.—LONGITUDINAL SECTION THROUGH THE MIDDLE OF A GANGLION ON THE POSTERIOR ROOT OF ONE OF THE SACRAL NERVES OF THE DOG, AS SEEN UNDER A LOW MAGNIFYING POWER.

a, nerve-root entering the ganglion; *b*, fibres leaving the ganglion to join the mixed spinal nerve; *c*, connective-tissue coat of the ganglion; *d*, principal group of nerve-cells, with fibres passing down from amongst the cells, probably to unite with the longitudinally coursing nerve-fibres by T-shaped junctions.

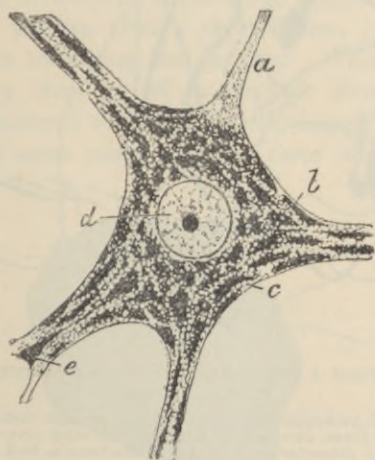


FIG. 124.—BODY OF A NERVE-CELL FROM THE SPINAL CORD, STAINED BY NISSL'S METHOD. (S. Ramon y Cajal.)

a, axis-cylinder process or neuron; *b*, protoplasm of cell, consisting of *c*, vacuolated substance and *e*, angular granules, stained by the methylene blue; *d*, nucleus.

the axis-cylinder of a nerve-fibre, or, in the case of the non-medullated fibres, becomes the nerve-fibre itself. Probably no nerve-cell is without this process. The other kind of process of the nerve-cell is the one which was termed by Deiters the *protoplasmic process*.

It is characterised by the fact that as soon as it leaves the cell it begins to branch dendritically, whereas the axis-cylinder process does not branch until near its termination, with the exception of a few lateral offshoots, which are sometimes given off in its course and

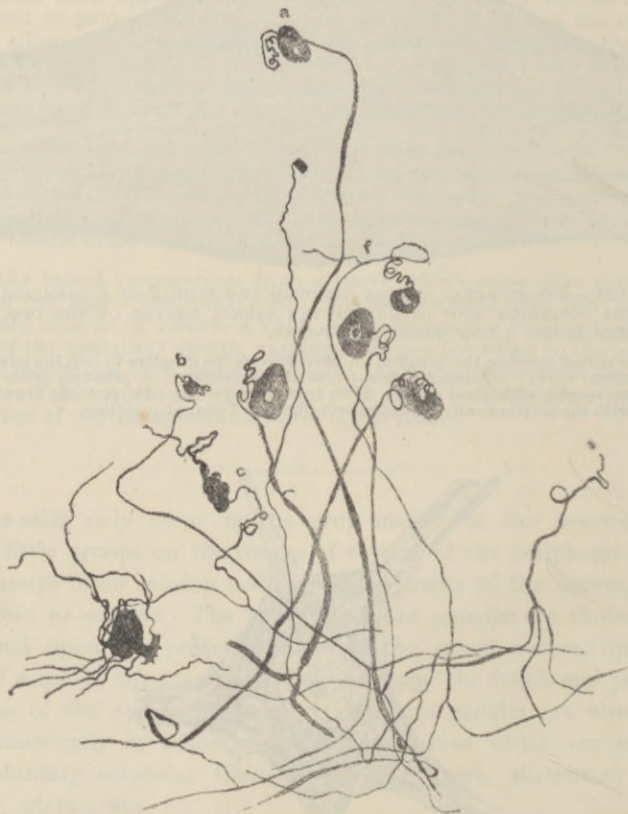

FIG. 125.—CELLS FROM A SPINAL GANGLION SHOWN BY THE METHYLENE-BLUE METHOD. (Dogiel.)

a, ordinary cell with axis-cylinder process dividing at some distance from the cell-body into two fibres, one passing centrally, the other peripherally; *b*, smaller cell of the same character; *c*, *d*, cells with dendrons as well as a neuron. Cells like these are rare in the spinal, but common in the sympathetic ganglia; *e*, cell showing a trifold division of its neuron; *f*, neuron giving off two collaterals before dividing.

which are known as its *collaterals*. The branching processes, which are often many in number, are termed *dendrons*, and the nerve-fibre process, which is usually single, the *neuron*.¹ Dendrons may

¹From *νευρον*, a nerve. Some neurologists use the name neuron to denote the whole nerve-cell. The axis-cylinder process is then termed "neuraxon," or "axon." This terminology is, however, misleading, and ought to be dropped.

be absent; the cell is then said to be adendric. Most nerve-cells have only one neuron (*mononeuric*), but some have two or more (*dineuric*, *trineuric*, etc.). The dendrons contain Nissl's granules, but the neurons do not (fig. 124).

The shape of the cell depends a good deal on the number of processes, and the manner in which they come off from the cell. If there is but one process the cell is generally nearly spherical. This

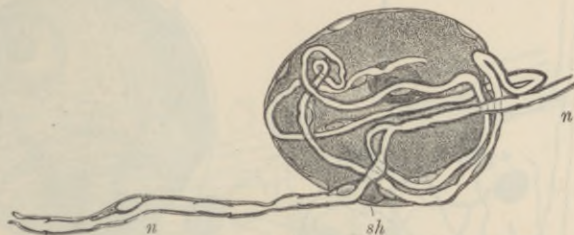


FIG. 126.—CELL FROM A SPINAL GANGLION. (Retzius.)

sh, nucleated sheath of the cell; *n*, *n'*, the nerve-fibre which the single process of the cell, after a number of coils, joins.

is the case with most of the cells of the spinal ganglia (figs. 125, 126); in these the single process, after a short course, joins one of the nerve-fibres which is traversing the ganglion. When there are two main processes, they often go off in opposite directions from the cell, which is thus rendered somewhat spindle-shaped, but occasionally they emerge at the same part. In some cases where there appear



FIG. 127.—PART OF A SPINAL GANGLION-CELL SHOWING ITS FIBRILLATED STRUCTURE. (Dogiel.)

n, neuron or axis-cylinder process.

to be two fibres connected with a cell, one of them is really derived from another nerve-cell elsewhere, and is passing to end in a ramification which envelops the ganglion-cell (fig. 128); it may be coiled spirally around the issuing nerve-process as in fig. 129. When there

are three or more processes, the cell becomes irregularly angular or stellate, as in the motor-cells of the spinal cord (figs. 131, 132).

In the **ganglia** each nerve-cell has a nucleated sheath (fig. 126) which is continuous with the sheath of the nerve-fibre with which the cell is connected. In the spinal ganglia, and in many of the ganglia at the roots of the cranial nerves, the cells have only one

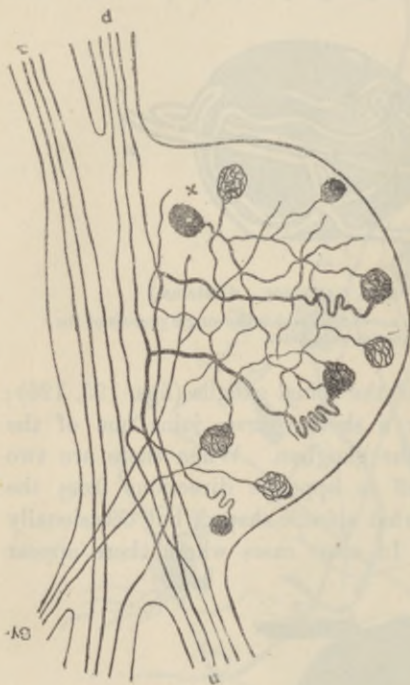


FIG. 128.—DIAGRAM SHOWING SOME OF THE CELLS OF A SPINAL GANGLION AND THEIR CONNECTION WITH NERVE-FIBRES. (Dogiel.)

a, p, anterior and posterior root of spinal nerve; *n,* an issuing nerve bundle; *sy,* fibres from sympathetic; *x,* a cell, the neuron of which ends in ramifications around the cell bodies of the ordinary ganglion-cells.

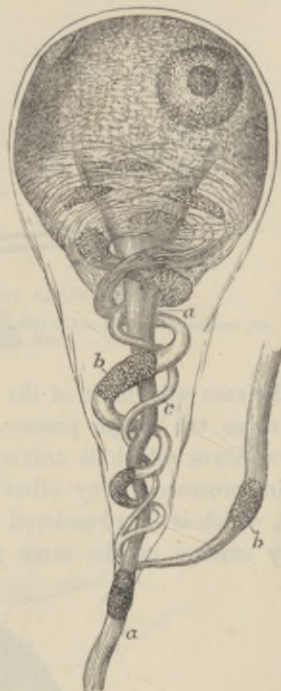


FIG. 129.—SYMPATHETIC GANGLION-CELL OF A FROG, HIGHLY MAGNIFIED. (Beale.)

a, a, straight fibre; *b, b,* coiled fibre, dividing as it passes to the cell.

process, the neuron or axis-cylinder process, which soon acquires a medullary sheath and then passes with a somewhat convoluted course to some little distance from the cell, where, still within the ganglion, it divides into two, one fibre passing to the nerve-centre, and the other towards the periphery. The branching is T-shaped and always occurs at a node of Ranvier (figs. 125, 126). These cells have no dendrons. In the sympathetic ganglia the nerve-cells usually have

several dendrons and one neuron; this passes out from the ganglion as a non-medullated nerve-fibre (fig. 130). The cells are disposed in aggregations of different size, separated by the bundles of nerve-fibres which are traversing the ganglion (fig. 123). The ganglion if large

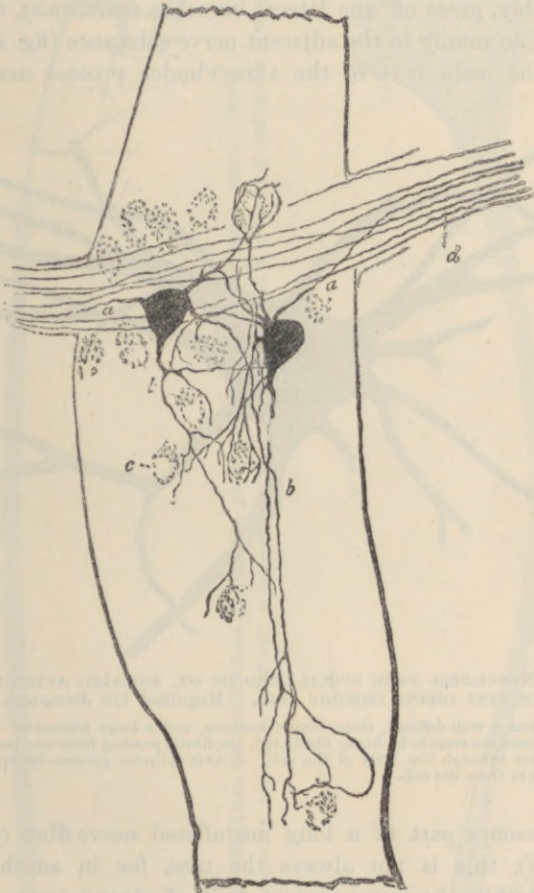


FIG. 130.—SYMPATHETIC GANGLION-CELLS WITHIN A SMALL GANGLION OF THE INTESTINE. (Dogiel.)

a, a, neurons; *b, b*, dendrons ending in terminal arborescences which invest other cells, *c*.

is inclosed by an investing capsule of connective tissue which is continuous with the epineurium and perineurium of the entering and issuing nerve-trunks.

In preparations made by Golgi's chromate of silver method the nerve-cells and their processes are coloured black by a deposit of reduced

silver, so that the processes can be traced for a considerable distance from the body of the cell, in fact in many instances as far as their remotest ramifications (figs. 130, 134, 135). It is found by the employment of this method that the axis-cylinder process is not always an unbranched process, as was formerly supposed, but that it usually, if not invariably, gives off fine lateral branches (*collaterals*), which themselves tend to ramify in the adjacent nerve-substance (fig. 134). And, although the main part of the axis-cylinder process usually passes

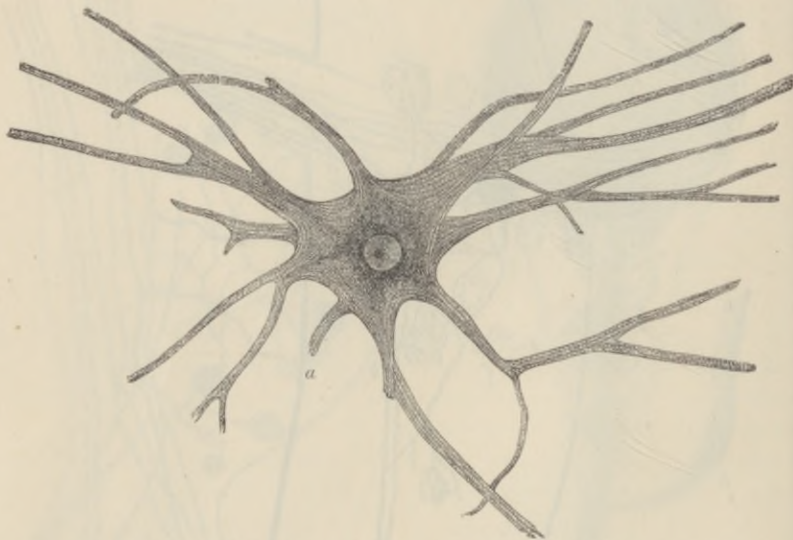

FIG. 131.—NERVE-CELL FROM SPINAL CORD OF OX, ISOLATED AFTER MACERATION IN VERY DILUTE CHROMIC ACID. (Magnified 175 diameters.)

The cell has a well-defined, clear, round nucleus, and a large nucleolus. The cell-processes are seen to be finely fibrillated, the fibrils passing from one process into another through the body of the cell. *a*, axis-cylinder process broken a short distance from the cell.

on and becomes part of a long medullated nerve-fibre (cell of first type, Golgi), this is not always the case, for in another type of nerve-cell within the nerve-centres (cell of second type, Golgi), the axis-cylinder process breaks up, after a short course as a medullated fibre, into a terminal arborescence, which usually envelops other nerve-cells. Moreover, even the long process of type 1 (which becomes the axis-cylinder of a long nerve fibre) ultimately ends in a similar manner, that is to say, in a terminal ramification or arborescence, as will be seen in studying the endings of nerve-fibres, and the structure of the central nervous system.

Each nerve-cell is an anatomically independent element, and the

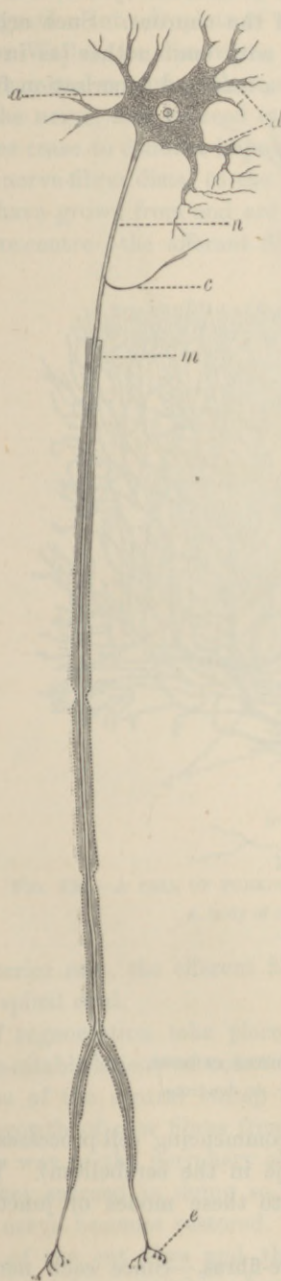


FIG. 132.—DIAGRAM OF MULTIPOLAR NERVE-CELL FROM ANTERIOR HORN OF SPINAL CORD. (Stöhr.)

a, body of cell; *d*, dendrons; *n*, neuron; *c*, collateral; *m*, commencement of medullary sheath; *e*, arborescent ending (on a muscle-fibre).

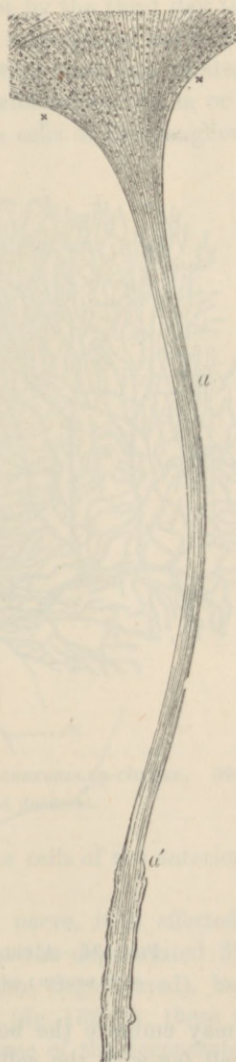

FIG. 133.—AXIS-CYLINDER PROCESS OF A NERVE-CELL FROM THE SPINAL CORD. (M. Schultze.)

$\times \times$, portion of the granular cell-body, out of which the fibrils of the axis-cylinder process, *a*, are seen to emerge. At *a'*, this process acquires a medullary sheath. (Highly magnified.)

connection of one nerve-cell with another is effected by the terminal arborisations either of the dendrons or of the neurons. Such arborisations from different cells may interlace with one another (as in the olfactory glomeruli and in the retina), or a terminal arborisation from

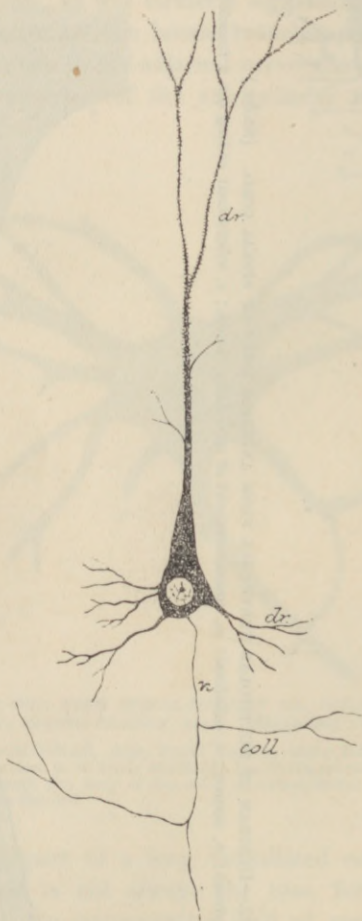


FIG. 134.—A CELL FROM THE CORTEX CEREBRI.
n, its neuron; coll., collaterals; dr, dr, dendrons.

one cell may embrace the body or the commencing cell-processes of another cell (as with the cells of Purkinje in the cerebellum). The term *synapse* (Foster) has been applied to these modes of junction without continuity.

Degeneration and regeneration of nerve-fibres.—Since each nerve-fibre is the process of a nerve-cell, when a nerve is cut, the separated

part dies, and its medullary sheath undergoes a gradual process of disintegration into droplets of myelin, the process being termed from the elder Waller, its discoverer, *Wallerian degeneration* (fig. 136, A to C). In man and mammals these changes begin 24 to 48 hours after section of the nerve, and proceed rapidly, so that by the third day the nerve-fibres cease to conduct impulses. When a peripheral nerve is cut, all the nerve-fibres distal to the point of section must degenerate, because all have grown from and are connected with nerve-cells in or near the nerve-centre—the afferent fibres with the cells of the ganglion on the

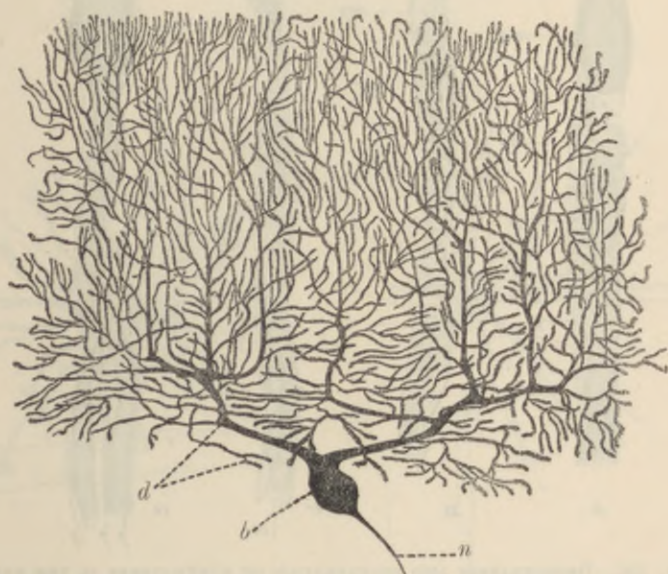


FIG. 135.—A CELL OF PURKINJE FROM THE CEREBELLAR CORTEX. (Stöhr.)

b, body of cell; *n*, neuron; *d*, dendrons.

posterior root, the efferent fibres with the cells of the anterior horn of the spinal cord.

If regeneration take place in the cut nerve, it is effected not by a re-establishment of connection between the degenerated fibres and those of the central stump (which are not degenerated), but by an outgrowth of new fibres from the stump (fig. 136, D); these may find their way to the periphery along the course of the degenerated fibres. If they succeed in doing so, the continuity and conducting power of the nerve becomes restored. If regeneration fail to occur, the central end of the cut fibre and the cell-body from which it takes origin undergo slow atrophic changes resulting from disuse. These are,

however, of a totally different character from those above described. No regeneration of cut nerve-fibres ever occurs in the brain or spinal cord, but the process of degeneration of the fibres which are cut off

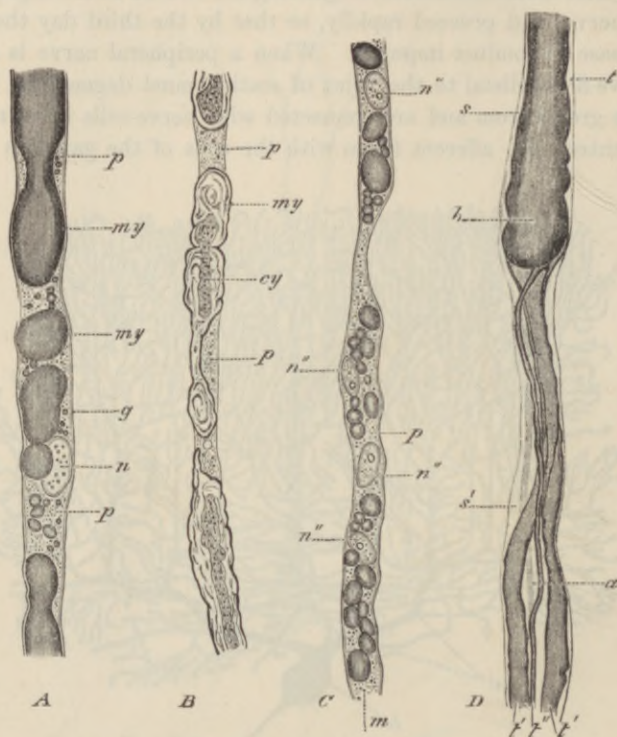


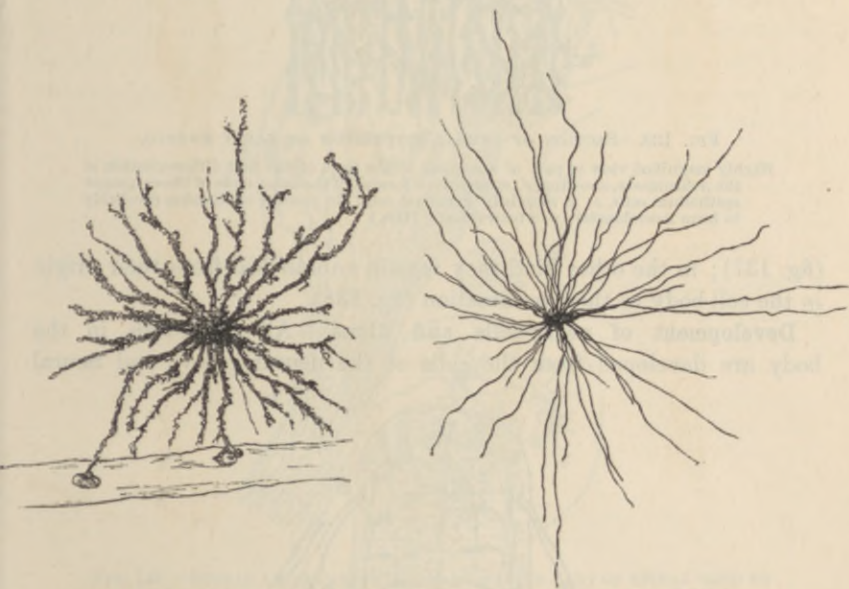
FIG. 136.—DEGENERATION AND REGENERATION OF NERVE-FIBRES IN THE RABBIT. (Ranvier.)

A, part of a nerve-fibre in which degeneration has commenced in consequence of the section, fifty hours previously, of the trunk of the nerve higher up; *my*, medullary sheath becoming broken up into drops of myelin; *p*, granular protoplasmic substance which is replacing the myelin; *n*, nucleus; *g*, neurolemma. *B*, another fibre in which degeneration is proceeding, the nerve having been cut four days previously; *p*, as before; *cy*, axis-cylinder partly broken up, and the pieces inclosed in portions of myelin, *my*. *C*, more advanced stage of degeneration, the medullary sheath having almost disappeared, and being replaced by protoplasm, *p*, in which, besides drops of myelin, *m*, are numerous nuclei, *n''*, which have resulted from the division of the single nucleus of the internode. *D*, commencing regeneration of a nerve-fibre. Several small fibres, *t'*, *t''*, have sprouted from the somewhat bulbous cut end, *t*, of the original fibre; *a*, an axis-cylinder which has not yet acquired its medullary sheath; *s*, *s'*, primitive sheath of the original fibre. *A*, *C*, and *D* are from osmic preparations; *B*, from an alcohol and carmine preparation.

from their cell-bodies takes place in the same manner as at the periphery. Both in the nerve-centres and in the peripheral nerves (if regeneration fail to occur), the place of the degenerated fibres becomes eventually occupied by strands of fine fibres, somewhat

similar to the fibres of cicatricial tissue, and probably allied to connective-tissue fibres. These strands stain more deeply with carmine and remain unstained by osmic acid and by the Weigert-Pal method,¹ thus differing from the surrounding normal nerve-structure.

Neuroglia-cells. In the brain and spinal cord the nerve-cells and nerve-fibres are supported by a peculiar tissue which has been termed the *neuroglia*. It is composed of cells and fibres, the latter being prolonged from the cells. Of the fibres some are radially disposed. These start partly from the fixed ends of the ciliated epithelium cells



FIGS. 137 AND 138.—NEUROGLIA CELLS OF BRAIN SHOWN BY GOLGI'S METHOD.
(Andriezen.)

Fig. 137.—Cell with dendritic processes.

Fig. 138.—Cell with unbranched processes (spider cell).

which line the central canal of the spinal cord and the ventricles of the brain, and pass in a radial direction, slightly diverging as they proceed, and constantly branching, towards the surface of the organ, where they end in slight enlargements attached to the pia mater; others appear to arise from elongated cells of the surface of the nerve-centres. The other fibres of the tissue are prolongations of the cell-processes of the neuroglia- or glia-cells proper (spider-cells). These cells are stellate in shape (figs. 137, 138), and their fine processes pass as neuroglia-fibres between the nerve-cells and nerve-

¹ See Appendix.

fibres, which they aid in supporting. There appear to be two kinds of these neuroglia-cells differing from one another in the behaviour of their processes. In the one kind the processes branch repeatedly

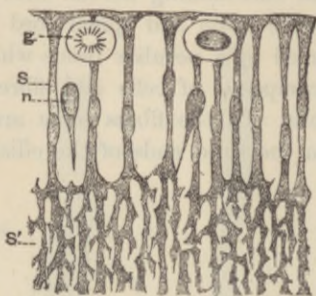


FIG. 139.—SECTION OF NEURAL EPITHELIUM OF EARLY EMBRYO.

Highly magnified view of part of a section, at the time of the first differentiation of the neuroblasts, showing, *s'*, spongework formed of the outer ends of the columnar epithelium cells, *s*; *g*, rounded "germinal cells" in process of division (probably to form neuroblasts); *n*, a neuroblast. (His.)

(fig. 137); in the other kind they remain unbranched from their origin in the cell-body to their termination (fig. 138).

Development of nerve-cells and fibres.—All nerve-cells in the body are developed from the cells of the neural groove and neural

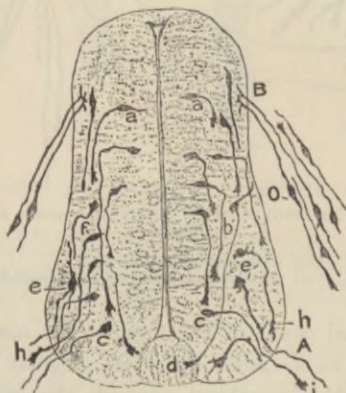


FIG. 140.—SECTION OF SPINAL CORD OF CHICK OF THIRD DAY OF INCUBATION. (S. Ramon y Cajal.)

A, anterior root-fibres formed by outgrowths of neurons of motor neuroblasts, *c, e*;
 B, posterior root-fibres formed by ingrowths of neurons of sensory neuroblasts, *o*, in ganglion rudiment; *a*, early neuroblasts; *b*, neuroblast giving rise to a commissural neuron, *d*; *h, i*, enlarged ends of growing neurons; *e, e*, neuroblasts of which the dendrons are beginning to appear.

crest of the early embryo; the neural groove closing to form the neural canal, the cells of which form the spinal cord and brain, and

the neural crest giving off at intervals sprouts which become the rudiments of the ganglia. The cells which line the neural canal are at first all long columnar cells, but amongst these, and probably produced by a metamorphosis of some of these, rounded cells (*neuroblasts*, fig. 139) make their appearance, and presently from each one a process begins to grow out. This is the axis-cylinder process (*neuron*), and is characterised by its enlarged extremity (fig. 140). As

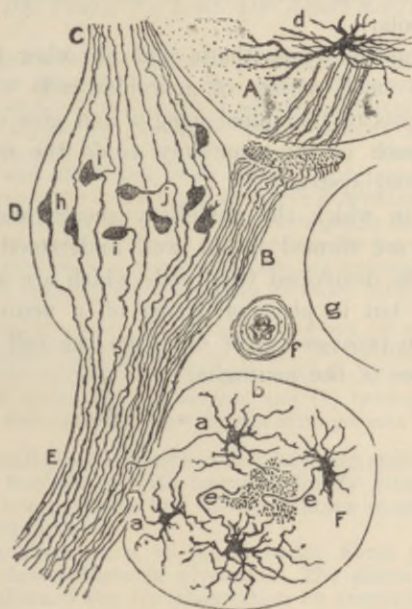


FIG. 141.—SPINAL AND SYMPATHETIC GANGLIA AND PART OF SPINAL CORD OF CHICK OF SEVENTEENTH DAY OF INCUBATION. (S. Ramon y Cajal.)

A, antero-lateral part of spinal cord with *d*, a motor nerve-cell; the fibres of the anterior root are seen emerging and passing to B (the connection is accidentally interrupted in the section); C, posterior root formed of fibres which have grown from the ganglion cells in D, spinal ganglion; E, mixed spinal nerve; F, sympathetic ganglion; *a, a*, neurons of sympathetic cells, passing to join the spinal nerve; *b*, dendrons of these cells; *c*, neurons passing to the sympathetic cord; *a*, cell of spinal ganglion still bipolar; *i, i*, bipolar cells becoming transformed into unipolar; *j*, unipolar cell with T-junction; *f*, section of an artery; *g*, vertebra.

it grows, it may emerge from the antero-lateral region of the canal and become a *motor neuron* or *anterior root-fibre*. The dendrons appear somewhat later than the neuron. The axis-cylinder processes of some of the neuroblasts remain within the nerve-centre, and are developed into association or intracental fibres.

The sprouts from the neural crest contain the neuroblasts from which the posterior root-fibres are developed. Neurons grow out from these neuroblasts in two directions, so that the cells become

bipolar (fig. 140). One set, forming the posterior root-fibres, grow into the postero-lateral portion of the spinal cord and ramify in the developing grey matter; the other set, containing the afferent fibres of the mixed nerves, grow towards the developing anterior roots, and eventually mingle with them to form the mixed nerves. As development proceeds, the bipolar ganglion cells become gradually transformed in most vertebrates, by a shifting of the two neurons, into unipolar cells (fig. 141); but in many fishes the cells remain permanently bipolar.

The ganglia on the sympathetic and on other peripheral nerves are formed from small masses of neuroblast-cells which separate off from the rudiments of the spinal ganglia and give origin to neurons and dendrons much in the same way as do the neuroblasts within the central nervous system.

The manner in which the medullary sheath and neurolemma of the nerve-fibres are formed is not well understood. The neuroglia cells appear to be developed from cells which are at first similar to the neuroblasts, but in place of giving off a neuron and dendrons, a number of fine processes grow out from the cell in all directions, forming the fibres of the neuroglia.

LESSON XXI.

MODES OF TERMINATION OF NERVE-FIBRES.

1. SHELL out a Pacinian corpuscle from a piece of cat's mesentery which has been kept for two or three days in $\frac{1}{10}$ per cent. chromic acid or 30 per cent. alcohol, and clear it as much as possible of adhering fat, but be careful not to prick or otherwise injure the corpuscle itself. Mount in water with a thick hair to prevent crushing with the cover-glass. Sketch the corpuscle under a low power, and afterwards draw under a high power the part of the core where the nerve enters and the part where it terminates. Notice the fibrous structure of the lamellar tunics of the corpuscle and the oval nuclei belonging to flattened epithelioid cells which cover the tunics. The distinct lines which when seen in the fresh corpuscle are generally taken for the tunics, are really the optical sections of these flattened cells.

2. Mount in dilute glycerine one or more sections of a rabbit's cornea which has been stained with chloride of gold. Notice the arrangement in plexuses of the darkly-stained nerve-fibres and fibrils, (1) in the connective-tissue substance, (2) under the epithelium, and (3) between the epithelial cells. Make one or two sketches showing the arrangement of the fibrils.

3. Spread out a small piece of muscle which has been stained with chloride of gold by Löwit's method, or with hæmatoxylin by Sihler's method, and examine it with a low power to find the nerve-fibres crossing the muscular fibres and distributed to them.

Try and separate those parts of the muscular fibres to which nerves appear to go, and mount them in glycerine. The pieces of muscle may advantageously be thinned out for observation by pressure upon the cover-glass. Search thoroughly for the close terminal ramifications (end-plates) of the axis-cylinders immediately within the sarcolemma.

It is rather difficult to dissociate the fibres, and much patience is sometimes required in searching for the nerve-terminations, but when they are found the trouble is amply repaid.¹

Modes of ending of sensory nerve-fibres.—Nerve-fibres which are distributed to sensory parts end either in *special organs* or in *free terminal ramifications*. Within the special organs the ending is also usually ramified. There are three chief kinds of special organs, termed respectively *Pacinian corpuscles*, *tactile corpuscles*, and *end-bulbs*. In the *tactile corpuscles* and *end-bulbs* the connective-tissue sheath of a medullated fibre expands to form a solid bulbous enlargement, which is cylindrical or spheroidal in the end-bulbs and ellipsoidal in the

¹ For methods of staining nerve-terminations see Appendix.

tactile corpuscles. In both kinds of end-organ there is a capsule of connective tissue within which is generally a sort of core containing

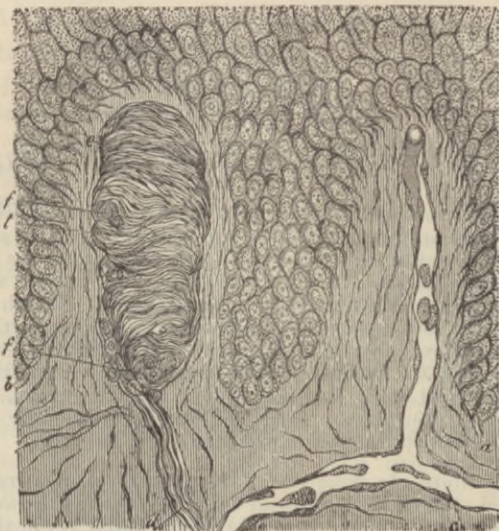


FIG. 142.—SECTION OF SKIN SHOWING TWO PAPILLE AND DEEPER LAYERS OF EPIDERMIS. (Biesiadecki.)

a, vascular papilla with capillary loop passing from subjacent vessel, *c*; *b*, nerve-papilla with tactile corpuscle, *t*. The latter exhibits transverse fibrous markings; *d*, nerve passing up to it; *f, f*, sections of spirally winding nerve-fibres.

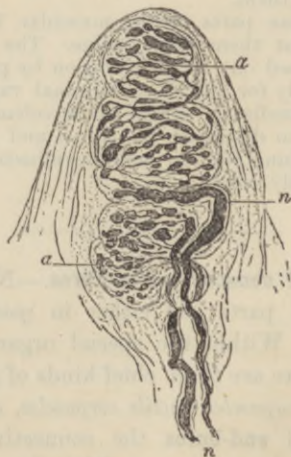


FIG. 143.—TACTILE CORPUSCLE WITHIN A PAPILLA OF THE SKIN OF THE HAND, STAINED WITH CHLORIDE OF GOLD. (Ranvier.)

n, two nerve-fibres passing to the corpuscle; *a, a*, varicose ramifications of the axis-cylinders within the corpuscle.

numerous nucleated cells. As the nerve-fibre enters the corpuscle (which in the tactile corpuscle only happens when it has reached the

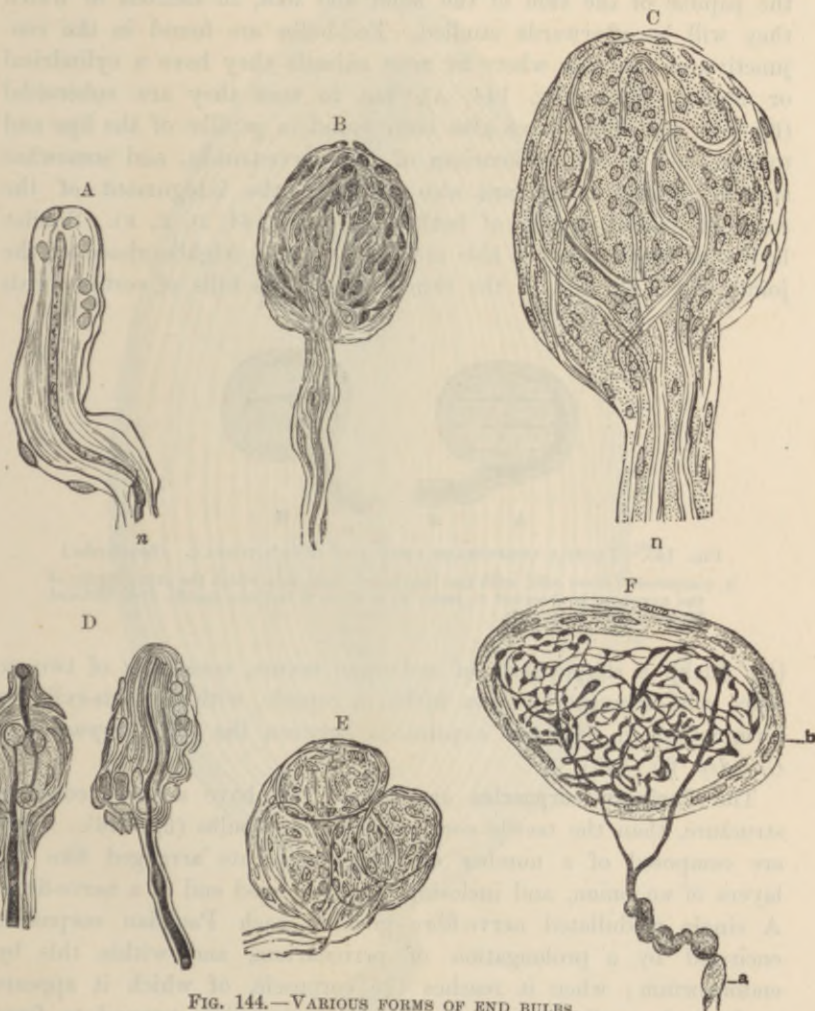


FIG. 144.—VARIOUS FORMS OF END BULBS.

- A, Cylindrical end-bulb from the conjunctiva of the calf. (Merkel.)
- B, End-bulb from the human conjunctiva treated with acetic acid and osmic acid. $\frac{200}{200}$. (W. Krause.)
- C, Articular corpuscle, human. $\frac{200}{200}$. (W. Krause.)
- D, Simple tactile end-organs from the clitoris of the rabbit. (Izquierdo.)
- E, Compound end-bulb from the clitoris. Human. (W. Krause.)
- F, End-bulb from the glans penis showing ending of axis-cylinder. Methylene-blue preparation. (Dogiel.) a, medullated nerve-fibre; b, sheath of end-bulb.

distal part of the corpuscle, after having wound spirally once or twice round it) it loses its sheaths and is prolonged as an axis-cylinder only,

which terminates after either a straight or a convoluted course within the organ (see figs. 142 to 144). Tactile corpuscles occur in some of the papillæ of the skin of the hand and foot, in sections of which they will be afterwards studied. End-bulbs are found in the conjunctiva of the eye, where in most animals they have a cylindrical or oblong shape (fig. 144, A), but in man they are spheroidal (fig. 144, B). They have also been found in papillæ of the lips and tongue, and in the epineurium of the nerve-trunks, and somewhat similar sensory end-organs also occur in the integument of the external genital organs of both sexes (fig. 144, D, E, F). Similar bodies of larger size are also met with in the neighbourhood of the joints (fig. 144, c). In the skin covering the bills of certain birds

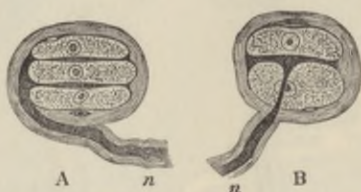


FIG. 145.—TACTILE CORPUSCLES FROM THE DUCK'S TONGUE. (Izquierdo.)

A, composed of three cells, with two interposed disks, into which the axis-cylinder of the nerve, *n*, is observed to pass; in B there is but one tactile disk inclosed between two tactile cells.

(*e.g.* duck), a simple form of end-organ occurs, consisting of two or more cells arranged in rows within a capsule, with the axis-cylinder terminating in flattened expansions between the cells (*corpuscles of Grandry*, fig. 145).

The **Pacinian corpuscles** are larger, and have a more complex structure, than the tactile corpuscles and end-bulbs (fig. 146). They are composed of a number of concentric coats arranged like the layers of an onion, and inclosing the prolonged end of a nerve-fibre. A single medullated nerve-fibre goes to each Pacinian corpuscle, encircled by a prolongation of perineurium, and within this by endoneurium; when it reaches the corpuscle, of which it appears to form the stalk, the lamellæ of the perineurium expand to form some of the tunics of the corpuscle. The nerve passes on, piercing the other tunics, and still provided with medullary sheath, and surrounded by endoneurium, to reach the central part of the corpuscle. Here the endoneurium is prolonged to form a sort of core of cylindrical shape, along the middle of which the nerve-fibre, now deprived of its medullary and primitive sheaths, passes in a straight course as a simple axis-cylinder (figs. 146, *n'*; 147, *c.f*) to terminate

at the farther end of the core, either in an arborisation or in a bulbous enlargement.

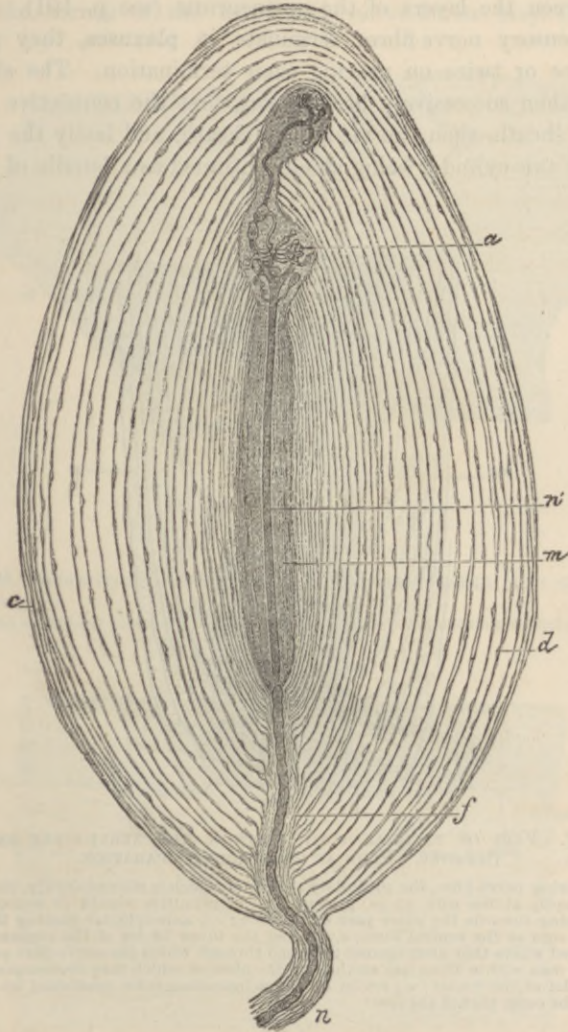


FIG. 146.—MAGNIFIED VIEW OF A PACINIAN BODY FROM THE CAT'S MESENTERY. (Ranvier.)

n, stalk of corpuscle with nerve-fibre, inclosed in sheath of Henle, passing to the corpuscle; *n'*, its continuation through the core, *m*, as axis-cylinder only; *a*, its terminal arborisation; *c*, *d*, sections of epithelioid cells of tunics, often mistaken for the tunics themselves; *f*, channel through the tunics which expands into the core of the corpuscle.

The tunics of the corpuscle are composed of connective tissue, the fibres of which for the most part run circularly. They are covered

on both surfaces with a layer of flattened epithelioid cells, and here and there cleft-like lymph-spaces can be seen between them like those between the layers of the perineurium (see p. 101).

When sensory nerve-fibres terminate in **plexuses**, they generally branch once or twice on nearing their termination. The sheaths of the fibres then successively become lost, first the connective tissue or perineural sheath, then the medullary sheath, and lastly the primitive sheath, the axis-cylinder being alone continued as a bundle of primitive

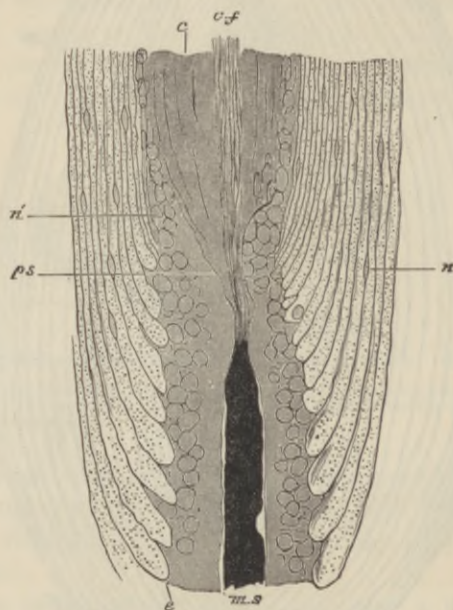


FIG. 147.—PART OF PACINIAN BODY, SHOWING THE NERVE-FIBRE ENTERING THE CORE. FROM AN OSMIC ACID PREPARATION.

ms, entering nerve-fibre, the medullary sheath of which is stained darkly, and ends abruptly at the core; *c*; *ps*, prolongation of primitive sheath or neurolemma passing towards the outer part of the core; *c,f*, axis-cylinder passing through the core as the central fibre; *e*, some of the inner tunics of the corpuscle, enlarged where they abut against the canal through which the nerve-fibre passes—the dots within them are sections of the fibres of which they are composed; *n*, nuclei of the tunics; *n'*, nuclei of the endoneurium-cells, continued by others in the outer part of the core.

fibrils (fig. 148, *n*). This branches and with the ramifications of the axis-cylinders of neighbouring nerve-fibres forms a primary plexus. From the primary plexus smaller branches (*a*) come off, and these from a secondary plexus (*e*) nearer the surface, generally immediately under the epithelium if the ending is in a membrane covered by that tissue. Finally, from the secondary plexus nerve-fibrils proceed and form a terminal ramification amongst the epithelium cells (fig.

149, *p*), the actual ending being generally in free varicose fibrils (*b*). Such a mode of ending in terminal plexuses is most characteristically seen in the cornea of the eye. The nerve-fibrils may be brought

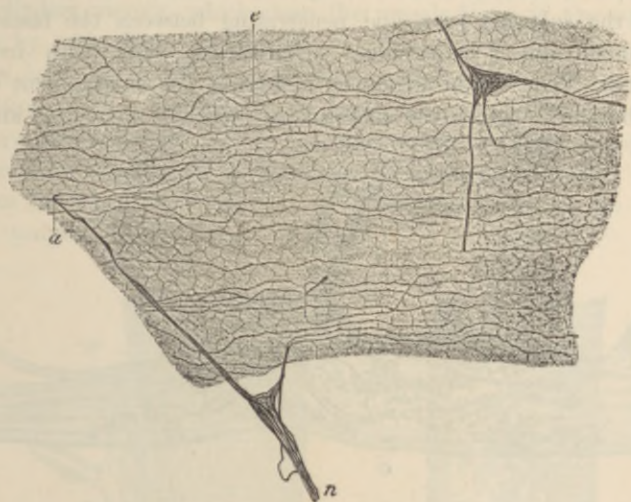


FIG. 148.—SUBEPITHELIAL PLEXUS OF THE CORNEA TREATED WITH CHLORIDE OF GOLD. (Ranvier.)

n, branch of primary plexus; *a*, small branch passing to join the subepithelial plexus, *c*.

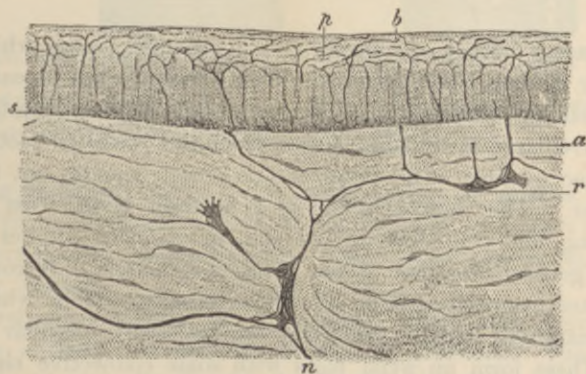


FIG. 149.—VERTICAL SECTION OF CORNEA STAINED WITH CHLORIDE OF GOLD. (Ranvier.)

n, *r*, primary plexus in connective tissue of cornea; *a*, branch passing to subepithelial plexus, *s*; *p*, intra-epithelial plexus; *b*, terminations of fibrils.

distinctly into view by staining with chloride of gold, and then the fibrillar structure of the ramifications of the axis-cylinders also becomes very apparent.

Nerve-endings in tendons.—A special modification of the terminal plexus is met with in many of the tendons, near the points of attachment of the muscular fibres. The tendon-bundles are somewhat enlarged, and the nerve-fibres—one, two, or even more in number—pass to the enlarged part, and penetrating between the fasciculi of the tendon end in a terminal arborisation, beset with irregular varicosities. The whole structure, including the enlargement of the tendon-bundle in which the arborisation occurs, is known as an *organ of Golgi* (fig. 150).

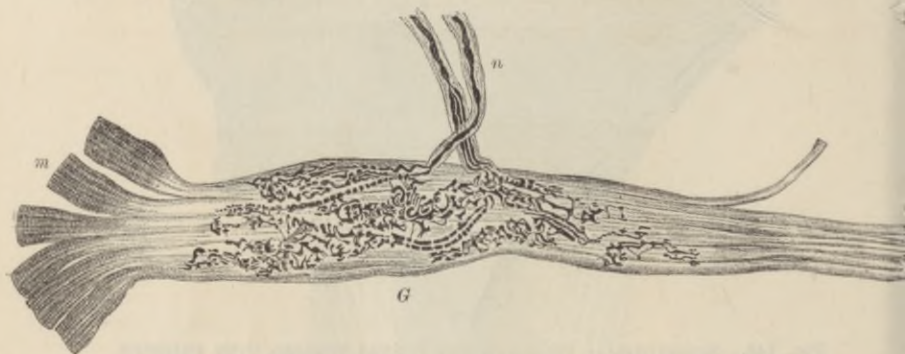


FIG. 150.—ORGAN OF GOLGI FROM THE HUMAN TENDO ACHILLIS. CHLORIDE OF GOLD PREPARATION. (Ciaccio.)

m, muscular fibres; *t*, tendon-bundles; *G*, Golgi's organ; *n*, two nerve-fibres passing to it.

The **sensory nerves of muscles** end in peculiar organs which were termed by Kühne *muscle-spindles*. Their structure has recently been investigated by Sherrington, who has shown beyond question that they receive large medullated nerves from the posterior root-ganglia, about three or four such fibres entering each spindle not far from its equator. The muscle-spindle is a fusiform body, from 0.75 to 4 mm. long, and from 0.08 to 0.2 mm. in diameter; it lies parallel with the general direction of the fibres of a muscle. It consists of a lamellated connective-tissue sheath externally, within which is a bundle (intrafusal bundle) of from two to twelve peculiar muscle-fibres. These form an axial mass with some connective tissue and the nerve-fibres; between this axial bundle and the sheath is a lymphatic periaxial space, bridged across by filaments of connective tissue. The intrafusal muscle-fibres are somewhat like embryonic fibres in appearance, being smaller than the other fibres of the muscle and having a relatively large number of nuclei with surrounding protoplasm as in the red variety of muscle. At the proximal end of the spindle they are usually only two or three in number, but they become

cleft as they pass through it; at the distal end they usually terminate in tendon-bundles. The nerve-fibres which pass to the spindle are of large size; they divide after reaching the intrafusal bundle, but retain their medullary sheath for a time, although eventually terminating as axis-cylinders merely, which clasp the muscle-fibres in the equatorial region by wide flattened expansions. No motor nerve-fibres appear to pass into the spindles, nor do their muscle-fibres undergo atrophy on section of the muscular nerve, as is the case eventually with the ordinary muscle-fibres. It is not uncommon to find two or three spindles close together or even inclosed in a common sheath. Muscle-spindles have not been found in the eye-muscles, nor in the muscles of the tongue.

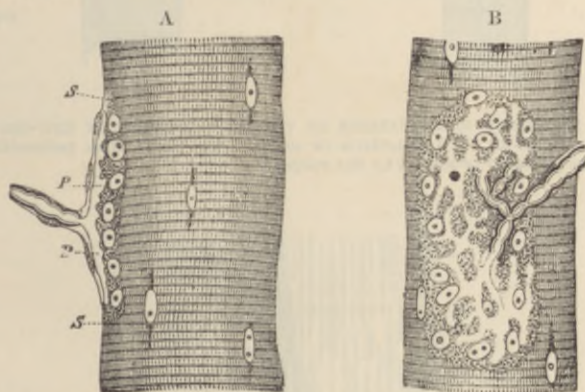


FIG. 151.—NERVE-ENDING IN MUSCULAR FIBRE OF A LIZARD (*Lacerta viridis*). (Kühne.)

A, end-plate seen edgeways; B, from the surface; *s, s*, sarcolemma; *p, p*, expansion of axis-cylinder. In B the expansion of the axis-cylinder appears as a clear network branching from the divisions of the medullated fibres.

Ending of motor nerves.—The motor nerves to muscles terminate in plexiform ramifications, which in striated (voluntary) muscles are collected into special organs termed *motor end-organs*, or, less correctly, *end-plates*.

In **involuntary muscle**, the nerve-fibres, which near their termination are entirely non-medullated, end in plexuses. The primary plexuses are generally furnished with ganglion-cells in abundance. From these other nerve-fibres pass which form secondary plexuses and terminal ramifications amongst the contractile fibre-cells. The gangliated plexuses will be more fully studied in connection with the intestine.

In **voluntary muscle**, the nerves, which are always medullated, terminate in special motor end-organs. A medullated fibre will branch

two or three times before ending, and then each branch passes straight to a muscular fibre. Having reached this, the neurolemma of the



FIG. 152.—TERMINAL RAMIFICATIONS OF THE AXIS-CYLINDER IN END-ORGANS OF MUSCLE, STAINED WITH CHLORIDE OF GOLD. (Ranvier.) The varicosities here seen are probably produced by the reagent.

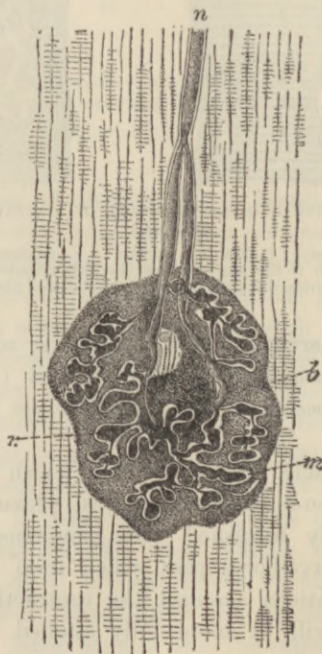


FIG. 153.—MOTOR END-ORGAN OF A LIZARD, GOLD PREPARATION. (Kühne.)

n, nerve-fibre dividing as it approaches the end-organ; *r*, ramification of axis-cylinder upon, *b*, granular bed or sole of the end-organ; *m*, clear substance surrounding the ramifications of the axis-cylinder.

nerve-fibre is continued into the sarcolemma of the muscle, the medullary sheath stops short, and the axis-cylinder ends in a close terminal ramification with varicosities upon its branches (figs. 151, 152). This ramification is embedded in a layer of granular nucleated protoplasm. In some cases the ramification is restricted to a small portion of the muscular fibre, and forms with the granular bed a slight prominence (*eminence of Doyère*). This is the case in insects and mammals. In the lizard the ramification is rather more extended than in mammals, whilst in the frog it is spread over a considerable length of the fibre. In mammals there appears to be only one end-plate to each fibre, while in reptiles there may be several. The end-plate is covered, externally to the sarcolemma, by an expansion of the sheath of Henle of the nerve-fibre.

LESSON XXII.

STRUCTURE OF THE LARGER BLOOD-VESSELS.

1. SECTIONS of a medium-sized peripheral artery and vein, *e.g.* popliteal or radial. In this preparation the limits of the vascular coats can be well seen and also the differences which they present in the arteries and veins respectively. The sections may be stained with hæmalum and mounted in xylol balsam.

2. Mount in xylol balsam a thin slice cut from the inner surface of an artery which, after having been cut open longitudinally and washed with distilled water, has been rinsed with nitrate of silver solution and exposed to the light in spirit. This preparation will show the outlines of the epithelium cells which line the vessel.

3. A piece of an artery which has been macerated for some days in 30 per cent. alcohol is to be teased so as to isolate some of the muscular cells of the middle coat and portions of the elastic layers (networks and fenestrated membranes) of the inner and middle coats. The tissue may be stained cautiously with diluted hæmalum, and glycerine afterwards added. The muscular cells are recognisable by their irregular outline and long rod-shaped nuclei. Sketch one or two and also a piece of fenestrated membrane. The fenestrated membrane is best obtained from one of the arteries of the base of the brain.

4. Transverse sections of aorta and carotid. Notice the differences in structure between these and the section of the smaller artery.

5. Transverse section of vena cava inferior. Notice the comparatively thin layer of circular muscle, and outside this the thick layer of longitudinal muscular bundles.

Make sketches from 1, 4, and 5 under a low power, from 2 and 3 under a high power.

An **artery** is usually described as being composed of three coats, an *inner* or elastic, a *middle* or muscular, and an *external* or areolar (fig. 154, *b, c, d*). It would, however, be more correct to describe the wall of an artery as being composed of muscular and elastic tissue lined internally by a pavement epithelium (endothelium) and strengthened externally by a layer of connective tissue. For the present, however, we may adhere to the generally received mode of description.

The *inner coat* (*tunica intima*) is composed of two principal layers. The inner one is a thin layer of *pavement epithelium*, the cells of which are somewhat elongated in the direction of the axis of the vessel (fig. 155), and form a smooth lining to the tube. After death they

become easily detached. Next to this comes an elastic layer in the form either of *elastic networks* (fig. 157) or of a *fenestrated membrane* (fig. 156). In some arteries there is a layer of fine connective tissue intervening between the epithelium and the fenestrated membrane (*subepithelial layer*).

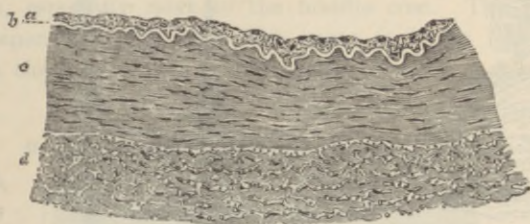


FIG. 154.—TRANSVERSE SECTION OF PART OF THE WALL OF THE POSTERIOR TIBIAL ARTERY. (75 diameters.)

a, epithelial and subepithelial layers of inner coat; *b*, elastic layer (fenestrated membrane) of inner coat, appearing as a bright line in section; *c*, muscular layer (middle coat); *d*, outer coat, consisting of connective-tissue bundles. In the interstices of the bundles are some connective-tissue nuclei, and, especially near the muscular coat, a number of elastic fibres cut across.

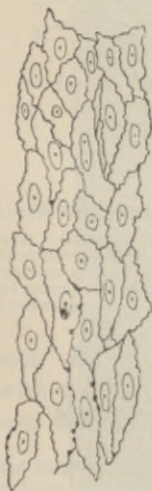

FIG. 155.—EPITHELIAL LAYER LINING THE POSTERIOR TIBIAL ARTERY. (250 diameters.)

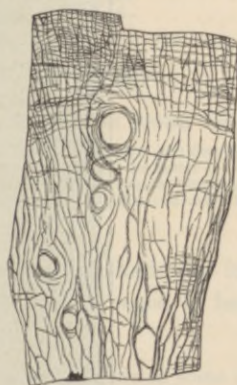

FIG. 156.—PORTION OF FENESTRATED MEMBRANE OF HENLE FROM AN ARTERY. (Toldt.)

The *middle coat* (*tunica media*) consists mainly of circularly disposed plain muscular fibres, but it is also pervaded in most arteries by a network of elastic fibres which are connected with the fenestrated membrane of the inner coat and are sometimes almost as much

developed as the muscular tissue itself. This is especially the case with the larger arteries, such as the carotid and its immediate

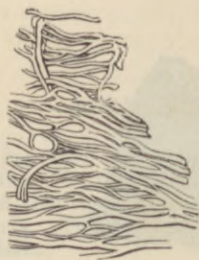

FIG. 157.—ELASTIC NETWORK OF ARTERY. (Toldt.)

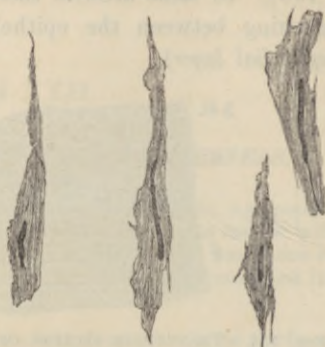

FIG. 158.—MUSCULAR FIBRE-CELLS FROM SUPERIOR THYROID ARTERY. (340 diameters.)

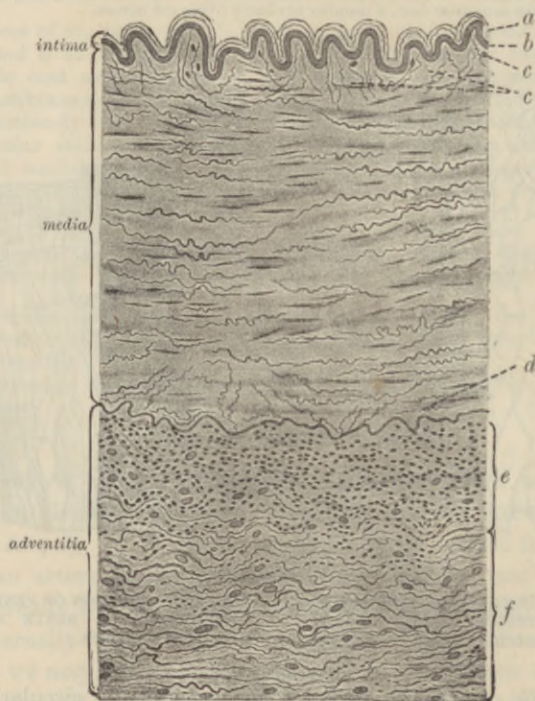


FIG. 159.—SECTION OF A MEDIUM-SIZED ARTERY. (Grünstein.)

a, epithelium and subepithelial layer of inner coat; *b*, its elastic layer; *c*, *c*, *d*, innermost and outermost layers of middle coat, with elastic fibres passing obliquely to join the elastic layers which bound that coat; *e*, innermost part of outer coat or adventitia, showing many elastic fibres cut across; *f*, outer part of adventitia.

branches, but in the smaller arteries of the limbs the middle coat is almost purely composed of muscular tissue. The muscular fibres are comparatively short, with long rod-shaped nuclei, and are often irregular in shape (as in fig. 158).

The *outer coat* is formed of connective tissue with a good many elastic fibres, especially next to the middle coat. The strength of an artery depends largely upon this coat; it is far less easily cut or torn than the other coats, and it serves to resist undue expansion

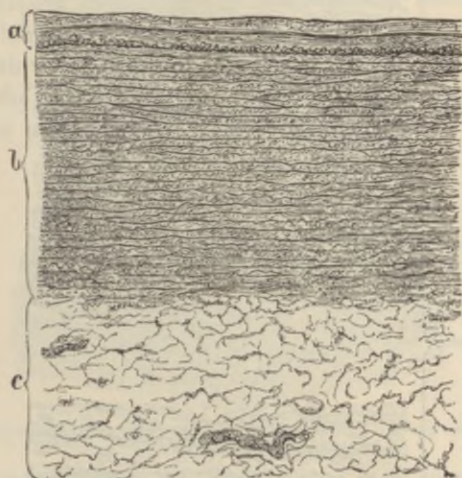


FIG. 160.—SECTION OF THORACIC AORTA AS SEEN UNDER A LOW POWER. (Toldt.)

a, the inner coat consisting of three layers, viz.: 1. Epithelium seen as a fine line. 2. Subepithelial layer. 3. Elastic layers. In the outer part of the inner coat, at its junction with the middle, a layer of longitudinal muscular fibres is represented as cut across. *b*, middle coat with its elastic membranes; *c*, outer coat with two vasa vasorum.

of the vessel. Its outer limit is not sharply marked, for it tends to blend with the surrounding connective tissue (hence it has been termed *tunica adventitia*).

Variations in structure.—The *aorta* (figs. 160, 161) differs in some respects in structure from an ordinary artery. Its inner coat contains a considerable thickness of subepithelial connective tissue, but the elastic layers of this coat are chiefly composed of fine fibres, and are not especially marked off from those of the middle coat, so that the inner and middle coats appear almost blended with one another. On the other hand, there is a very great development of elastic tissue in the middle coat, forming membranous layers which alternate with layers of the muscular tissue. A good deal of connective tissue also takes part in the formation of the middle coat, so that the coat is unusually strong. The inner and middle coats constitute almost the entire thickness of the wall, the outer coat being relatively thin.

The other variations which occur in the arterial system chiefly have reference to the development and arrangement of the muscular tissue. Thus in

many of the larger arteries there are longitudinal muscular fibres at the inner boundary of the middle coat, and in some arteries amongst the circular

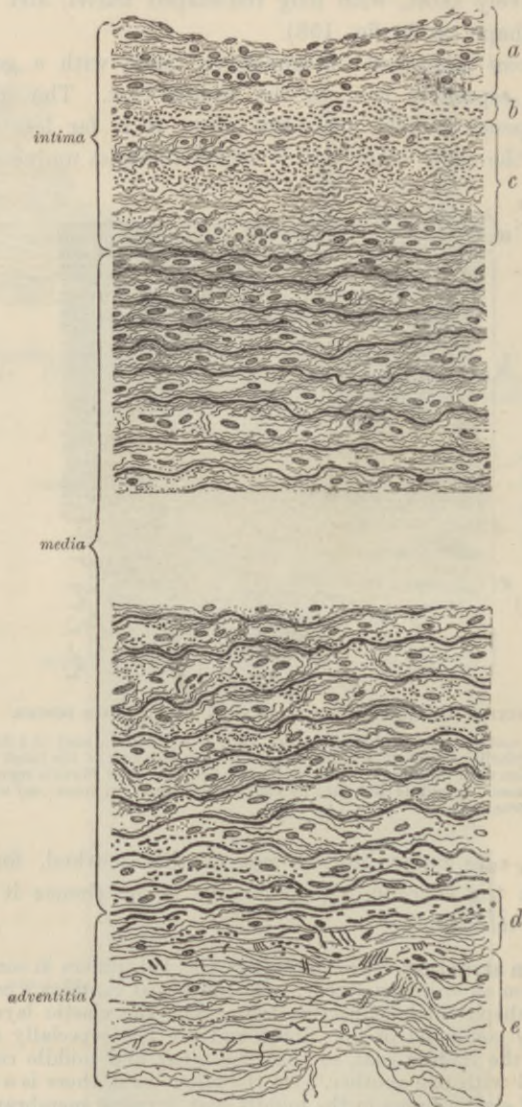


FIG. 16L.—SECTION OF AORTA MORE MAGNIFIED. (Grünstein.)

a, epithelial and subepithelial layers of inner coat; *b*, *c*, outer layers of inner coat containing many fine elastic fibres; *d*, *e*, parts of outer coat.

fibres of the middle coat. This is the case in the aorta. In some parts of the umbilical arteries there is a complete layer of longitudinal fibres internal

to the circular fibres and another external to them, whilst the amount of elastic tissue is very small. Longitudinal fibres are also present in some other arteries (iliac, superior mesenteric, splenic, renal, etc.), external to the circular fibres, and therefore in the outer coat of the artery.

The **veins** (fig. 162) on the whole resemble the arteries in structure, but they present certain differences. In the *internal coat* the same layers may be present, but the elastic tissue is less developed and seldom takes the form of a complete membrane. The epithelium-cells are less elongated than those of the arteries. The *middle coat* (*c*) contains less elastic tissue and also less muscular tissue, being partly occupied by bundles of white connective-tissue fibres. These are continuous with those of the external coat, which is relatively better developed in the veins than in the arteries, so that, although thinner, their walls are often stronger.

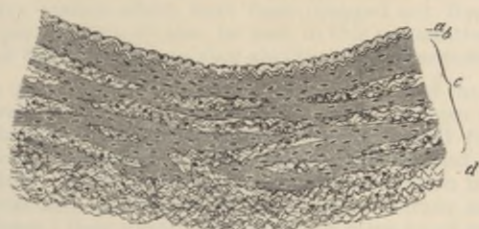


FIG. 162.—TRANSVERSE SECTION OF PART OF THE WALL OF ONE OF THE POSTERIOR TIBIAL VEINS (MAN).

a, epithelial and subepithelial layers of inner coat; *b*, elastic layers of inner coat; *c*, middle coat consisting of irregular layers of muscular tissue, alternating with connective tissue, and passing somewhat gradually into the outer connective tissue and elastic coat, *d*.

Many of the veins are provided with *valves*, which are semilunar folds of the internal coat strengthened by a little fibrous tissue: a few muscular fibres may be found in the valve near its attachment. The layer of the inner coat is rather thicker and the epithelium-cells are more elongated on the side which is subject to friction from the current of blood than on that which is turned towards the wall of the vessel.

The larger arteries and veins possess blood-vessels (*vasa vasorum*) and lymphatics, both of which ramify chiefly in the external coat. Nerves are distributed to the muscular tissue of the middle coat, after forming a plexus in the outer coat.

Variations in different veins.—The veins vary in structure more than do the arteries. In many veins longitudinal muscular fibres are found in the inner part of the middle coat, as in the iliac, femoral, umbilical; in others they occur external to the circularly disposed fibres, and are described as

belonging to the outer coat. This is the case in the inferior vena cava, and also in the hepatic veins and in the portal vein and its tributaries. In the superior vena cava and in the upper part of the inferior vena cava the circular fibres of the middle coat are almost entirely absent. The veins of the following parts have no muscular tissue, viz. pia mater, brain and spinal cord, retina, bones, and the venous sinuses of the dura mater and placenta.

It is only the larger veins, and especially those of the limbs, that possess valves. They are wanting in most of the veins of the viscera (although occurring abundantly in some of the tributaries of the portal vein), in those within the cranium and vertebral canal, in the veins of the bones, and in the umbilical vein.

contains the elastic tissue and also has muscular tissue partly composed of bundles of which the middle coat is relatively better continuous with those of the arterial coat, which is relatively thinner, developed in the same plane as the arteries so that although thinner, their walls are often stronger.




FIG. 122. A transverse section of a vein showing the internal structure of the vessel wall and the lumen. The drawing is very light and difficult to discern against the page background.

Many of the veins are provided with valves, which are situated in the middle coat, and are attached to the inner coat by their fibrous tissue. A few muscular fibres may be found in the veins near its attachment. The layer of the inner coat is thicker than that of the middle coat, and is more elastic than the middle coat, which is subject to friction from the current of blood, and is thus turned towards the wall of the vessel.

The larger arteries and veins possess fibrous tissue (see artery) and lymphatic vessels which rarely differ in the external coat. Nerves are distributed to the muscular tissue of the middle coat, after forming a plexus in the outer coat.

Variations in different veins.—The veins vary in structure more than in arteries. In many veins the middle coat is absent, and the inner coat is the only one present. In some veins the middle coat is present, but the circular fibres are absent. In some veins the middle coat is present, but the circular fibres are absent. In some veins the middle coat is present, but the circular fibres are absent. In some veins the middle coat is present, but the circular fibres are absent.

LESSON XXIII.

SMALLER BLOOD-VESSELS. MICROSCOPIC STUDY OF THE CIRCULATION; DEVELOPMENT OF BLOOD-VESSELS.

1. TAKE a piece of pia mater which has been stained with hæmatoxylin, and separate from it some of the small blood-vessels of which it is chiefly composed. Mount the shreds in dilute glycerine, or after dehydrating with alcohol and passing through clove oil they can be mounted in xylol balsam. The structure of the small arteries can be studied in this preparation, the nuclei of the epithelium and of the muscular coat being brought distinctly into view by the stain. The veins of the pia mater possess no muscular tissue. Capillary vessels which have been dragged out from the brain in removing the pia mater may also be seen in this preparation. Sketch two small arteries of different sizes, giving also their measurements.

2. Mount in xylol balsam a piece of the omentum of the rabbit, stained with silver nitrate. The membrane should be stretched over a cork or a ring of glass or vulcanite, rinsed with distilled water, treated for five minutes with 0.75 per cent. nitrate of silver solution, again washed and exposed to sunlight in spirit. When stained brown, the preparation is removed from the light. Pieces may now be cut off from the membrane and mounted, as directed, in balsam; they should include one or more blood-vessels.

This preparation is intended to show the epithelium of the smaller blood-vessels and accompanying lymphatics, and also the epithelium of the serous membrane. Sketch a small piece showing the epithelium of the vessels.

3. Kill a frog by destroying the brain and study the circulation of the blood in the mesentery. It can also be studied in the web of the frog's foot, and in the tongue of the frog or toad, or in the tail of the tadpole or of any small fish. But for observing the phenomena attending commencing inflammation and the emigration of leucocytes from the vessels, the mesentery is the most convenient object. The frog can be immobilised with water in which chloroform has been shaken up: a lateral incision is made in the abdominal wall, a loop of intestine drawn out, and laid over a ring of cork which is fixed to a glass plate and covered with a thin piece of glass. The membrane must be kept wet with salt solution.¹

The coats of the **small arteries and veins** are much simpler in structure than those of the larger vessels, but they contain at first all the same elements. Thus there is a lining epithelium (endothelium) and an elastic layer forming an *inner coat*, a *middle coat* of circularly disposed plain muscular tissue, and a thin *outer coat*. The same differences also are found between the arteries and veins, the walls of the veins being thinner and containing far less muscular tissue

¹ For details of the methods of studying the circulation, see *A Course of Practical Histology*.

(fig. 163), and the lining epithelium-cells, much elongated in both vessels, are far longer and narrower in the small arteries than in the corresponding veins (fig. 164).

In the smallest vessels it will be found that the elastic layer has disappeared in the veins, and the muscular tissue is considerably reduced in thickness in both kinds of vessels. Indeed, it is soon represented by but a single layer of contractile cells, and even these no longer form a complete layer. By this time also, the outer coat and the elastic layer of the inner coat have entirely disappeared both from arteries and veins. The vessels are reduced, therefore,

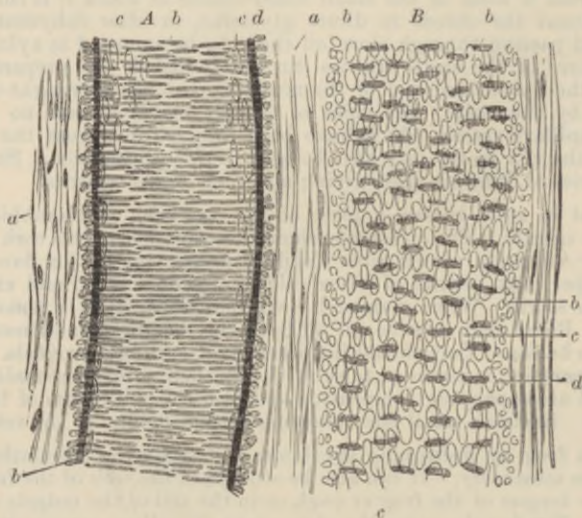


FIG. 163.—SMALL ARTERY, *A*, WITH CORRESPONDING VEIN, *B*, TREATED WITH ACETIC ACID. (Kölliker.) (Magnified 350 diameters.)

a, external coat with elongated nuclei; *b*, nuclei of the transverse muscular tissue of the middle coat (when seen endwise, as at the sides of the vessel, their outline is circular); *c*, nuclei of the epithelium-cells; *d*, elastic layers of the inner coat.

to the condition of a tube formed of pavement-epithelium cells, with a partial covering of circularly disposed muscular cells.

Even in the smallest vessels, which are not capillaries, the differences between arteries and veins are still manifested. These differences may be enumerated as follows:—The veins are larger than the corresponding arteries; they branch at less acute angles; their muscular cells are fewer, and their epithelium-cells less elongated; the elastic layer of the inner coat is always less marked, and sooner disappears as the vessels become smaller.

Capillary vessels.—When traced to their smallest branches, the arteries and veins eventually are seen to be continued into a network

of the smallest blood-vessels or capillaries. The walls of these are composed only of flattened epithelium-cells (fig. 165) continuous with those that line the arteries and veins; these cells can be exhibited by staining a tissue with nitrate of silver. The capillaries vary

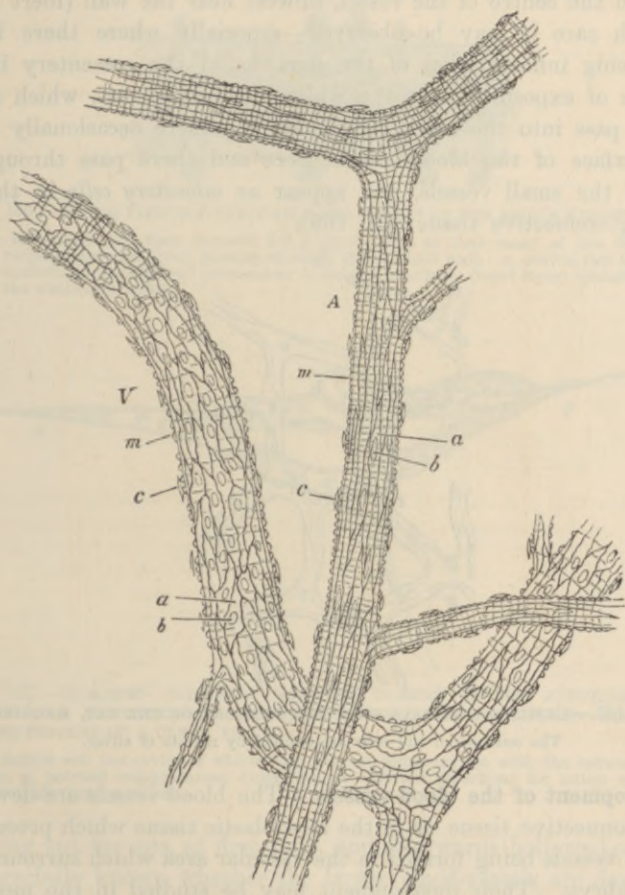


FIG. 164.—A SMALL ARTERY, *A*, AND VEIN, *V*, FROM THE SUBCUTANEOUS CONNECTIVE TISSUE OF THE RAT, TREATED WITH NITRATE OF SILVER. (175 diameters.)

a, a, epithelial cells with *b, b* their nuclei; *m, m*, transverse markings due to staining of substance between the muscular fibre-cells; *c, c*, nuclei of connective-tissue corpuscles attached to exterior of vessel.

somewhat in size and in the closeness of their meshes; their arrangement in different parts, which is mainly determined by the disposition of the tissue-elements, may best be studied in injected preparations, and will be described when the structure of the several organs is considered.

In the transparent parts of animals, the blood may be seen flowing through the capillary network from the arteries into the veins. The current is very rapid in the small arteries, somewhat less so in the veins, and comparatively slow in the capillaries. The current is fastest in the centre of the vessel, slowest near the wall (inert layer), and with care it may be observed—especially where there is any commencing inflammation of the part, as in the mesentery in consequence of exposure—that the white blood-corpuscles, which always tend to pass into the inert layer, and to adhere occasionally to the inner surface of the blood-vessels, here and there pass through the coats of the small vessels, and appear as *migratory cells* in the surrounding connective tissue (fig. 166).

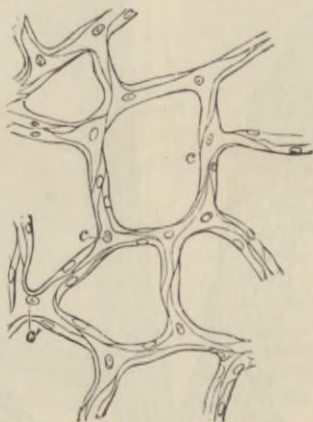


FIG. 165.—CAPILLARY VESSELS FROM THE BLADDER OF THE CAT, MAGNIFIED.
The outlines of the cells are stained by nitrate of silver.

Development of the blood-vessels.—The blood-vessels are developed in the connective tissue or in the mesoblastic tissue which precedes it, the first vessels being formed in the vascular area which surrounds the early embryo. Their development may be studied in the mesoblast of the chick, in the omentum of the new-born rabbit, or in the serous membranes and subcutaneous connective tissue of foetal animals. They are developed from cells (vaso-formative cells or angioblasts) which become hollowed out by an accumulation of fluid in their protoplasm (Klein), and in the case of developing blood-vessels coloured blood-corpuscles may also be formed within these cells (see Development of Blood-corpuscles, Lesson II.). The cells branch and unite with one another to form a network, and their cavities extend into the branches. In the meantime their nuclei multiply and become

distributed along the branches, cell-areas being subsequently marked out around them. In this way intercommunicating vessels—capillaries containing blood—are produced (fig. 167). These presently become connected with previously formed vessels, which extend themselves

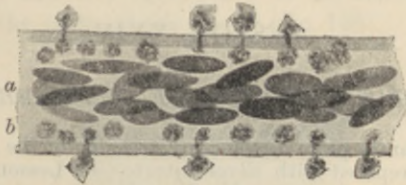


FIG. 166.—BLOOD FLOWING THROUGH A SMALL VEIN OF THE FROG'S MESENTERY.

The mesentery had been exposed for a short time, so that many of the white corpuscles are observed passing through the vascular wall. *a*, central fast layer containing the coloured corpuscles; *b*, outer slower layer (inert layer) containing the white corpuscles.

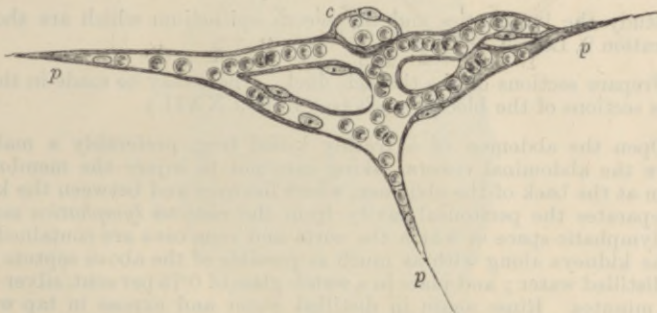


FIG. 167.—ISOLATED CAPILLARY NETWORK FORMED BY THE JUNCTION OF SEVERAL HOLLOWED-OUT CELLS, AND CONTAINING COLOURED BLOOD-CORPUSCLES IN A CLEAR FLUID.

c, a hollow cell the cavity of which does not yet communicate with the network; *p*, *p*, pointed cell-processes, extending in different directions for union with neighbouring capillaries.

by sending out sprouts, at first solid, and afterwards hollowed-out. It is not precisely known whether the larger blood-vessels are developed at first as capillaries, the muscular and other tissues being subsequently added, or whether they are formed as clefts in the mesoblastic tissue, which become bounded by flattened cells.

LESSON XXIV.

LYMPHATIC VESSELS; SEROUS MEMBRANES.

1. MOUNT in balsam a piece of the central tendon of the rabbit's diaphragm which has been prepared with silver nitrate (see Lesson XXIII., § 2), the pleural surface having been first brushed to remove the superficial epithelium so as to enable the nitrate of silver more readily to penetrate to the network of underlying lymphatic vessels. Observe the lymphatic plexus under a low power; sketch a portion of the network. If the peritoneal surface is focussed, the epithelium which covers that surface will be seen, and opposite the clefts between the radially disposed tendon-bundles stomata may be looked for in this epithelium.

2. Study the lymphatics and the serous epithelium which are shown in preparation 2, Lesson XXIII.

3. Prepare sections of the thoracic duct. These may be made in the same way as sections of the blood-vessels (see Lesson XXII.).

4. Open the abdomen of a freshly killed frog, preferably a male, and remove the abdominal viscera, taking care not to injure the membrane or septum at the back of the abdomen, which lies over and between the kidneys and separates the peritoneal cavity from the *cisterna lymphatica magna*, a large lymphatic space in which the aorta and vena cava are contained. Cut out the kidneys along with as much as possible of the above septum; rinse with distilled water; and place in a watch-glass of 0.75 per cent. silver nitrate for 5 minutes. Rinse again in distilled water and expose in tap water to the light. When slightly browned snip off a portion of the membranous septum, float it flat on a slide, drain off the superfluous water and allow it to dry; then add a drop of xylol balsam and cover the preparation.

To the lymphatic system belong not only the *lymphatic vessels* and *lymphatic glands*, but also the *cavities of the serous membranes*, which are moistened with lymph and are in open communication with lymphatic vessels which run in their parietes.

The larger **lymphatic vessels** somewhat resemble the veins in structure, except that their coats are much thinner and their valves much more numerous. In lymphatics of somewhat smaller size, the wall of the vessel is formed, first, by a lining of pavement-epithelium cells (lymphatic endothelium), which are elongated in the direction of the axis of the vessel; and, secondly, by a layer of circularly and obliquely disposed muscular fibres. In the smallest vessels (so-called *lymphatic capillaries*, which, however, are generally considerably larger than the

blood-capillaries), there is nothing but the epithelium remaining, and the cells of this are frequently not more elongated in one direction than in another, but have a characteristic wavy outline (fig. 170).

The lymphatics receive numerous nerve-fibres, which are non-medullated, and end in a ramification of the finest fibrils, which are distributed to the coats of the vessel (fig. 168).

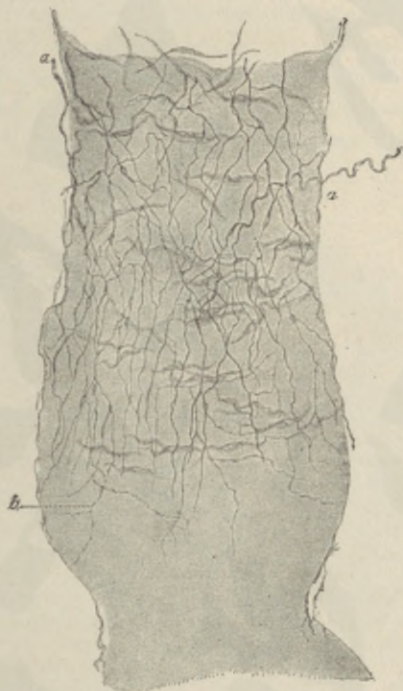

FIG. 168.—NERVES OF A LYMPHATIC VESSEL, SHOWN BY METHYLENE BLUE.
(Dogiel.)

a, a, non-medullated fibres passing to the vessel; *b*, part of their terminal ramification.

Lymphatics begin in two ways—either in the form of *plexuses*, as in membranes (fig. 169), or as *lacunar interstices*, as is the case in some of the viscera.

In order to show the lymphatic vessels, it is generally necessary to stain a tissue with nitrate of silver; but they may easily be injected by sticking the nozzle of an injecting canula into any tissue which contains them, and forcing coloured fluid under gentle pressure into the interstices of the tissue.¹

¹ For details of procedure in injecting blood-vessels and lymphatics the student is referred to the *Course of Practical Histology*.

In silver preparations it may be observed that the lymphatics always appear in the form of clear channels in the stained ground-



FIG. 169.—LYMPHATIC PLEXUS OF CENTRAL TENDON OF DIAPHRAGM OF RABBIT, PLEURAL SIDE. (Klein.)

a, larger vessels with lanceolate cells and numerous valves; *b*, *c*, lymphatic capillaries with wavy-bordered cells.

substance of the connective tissue, and that their walls are in close connection with the cells and cell-spaces of that tissue. But, except in the case of the serous membranes, there is no open communication

between the lymphatic vessels and the interstices of the connective tissue. The lymphatic vessels are developed from hollowed-out cells in the same manner as the blood-vessels (Klein).

SEROUS MEMBRANES.

The **serous membranes**, which may be conveniently studied in connection with the lymphatic system, are delicate membranes of connective tissue which surround and line the internal cavities of the body, and are reflected over many of the thoracic and abdominal viscera; in passing to which they form folds, within which blood-vessels, lymphatics, and nerves pass to the viscera.

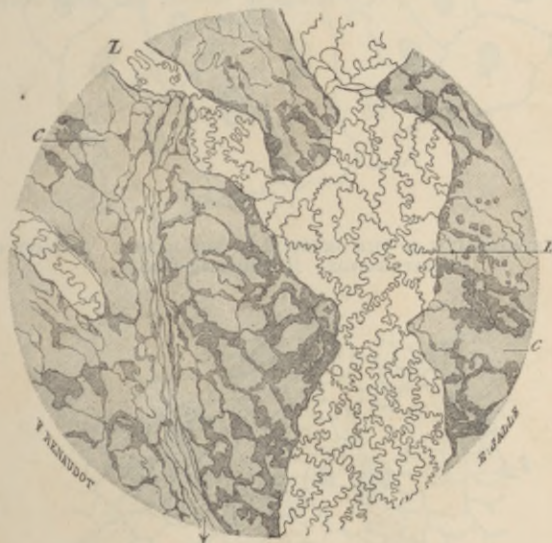

FIG. 170.—A SMALL PART OF THE LYMPHATIC PLEXUS OF THE PLEURAL LAYER OF THE DIAPHRAGM. (Magnified 110 diameters.) (Ranvier.)

L, lymphatic vessel with characteristic epithelium; c, cell-spaces of the connective tissue here and there abutting against the lymphatic.

The inner surface is lined by a continuous layer of *pavement-epithelium* (*endothelium*) (fig. 171), which is very distinct in nitrate of silver preparations. In some places there are apertures in the epithelium which lead directly into subjacent lymphatic vessels. These apertures are called *stomata*, and are surrounded by small protoplasmic cells (fig. 172, s, s). They are most numerous upon the peritoneal surface of the diaphragm, but are present in most serous membranes. They are nowhere better studied or more easily seen

than in the peritoneal membrane at the back of the abdominal cavity in the frog. This membrane lies between and at the sides of the

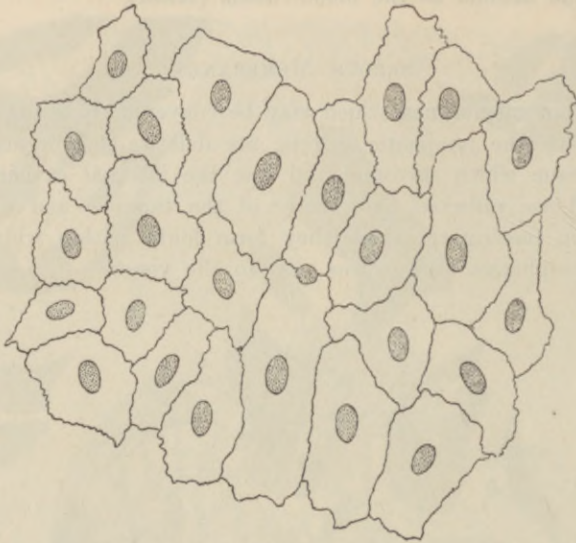


FIG. 171.—ENDOTHELIUM OF THE OMENTUM OF THE RABBIT. NITRATE OF SILVER PREPARATION. (Highly magnified.)

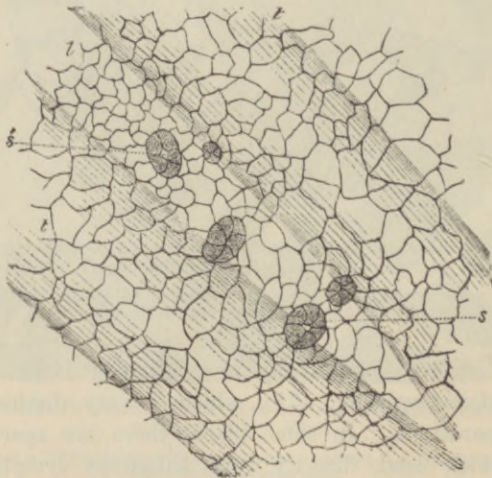

FIG. 172.—SMALL PORTION OF PERITONEAL SURFACE OF DIAPHRAGM OF RABBIT, STAINED WITH NITRATE OF SILVER TO SHOW THE SEROUS EPITHELIUM. (Klein.)

t, t, lymph-channel below the surface, lying between tendon bundles, *t, t*, and over which the surface-cells are seen to be relatively smaller, and to exhibit five stomata, *s, s*, leading into the lymphatic. The epithelium of the lymphatic channel is not represented.

kidneys, and serves to separate the peritoneal cavity from the large lymphatic space just behind it. If the membrane is prepared by the nitrate of silver method the stomata and the cells which surround them on either side of the membrane are well shown.

The pavement-epithelium of the serous membrane rests upon a homogeneous basement-membrane, which is especially well marked in the serous membranes of man. The rest of the thickness of the membrane is composed of connective tissue, with a network of fine elastic fibres near the inner surface.

The cavities of the serous membranes are originally formed in the embryo as a cleft in the mesoderm (pleuro-peritoneal split, coelom) which becomes lined with epithelium, and its wall eventually becomes differentiated into the serous membrane.

LESSON XXV.

LYMPHATIC GLANDS, TONSIL, THYMUS.

1. SECTIONS of a lymphatic gland which has been hardened either in formol followed by alcohol, or in chromic or picric acid followed by alcohol, stained in bulk with magenta, carmalum or picrocarmine, and embedded in paraffin.¹ Notice (1) the fibrous and muscular capsule, with trabeculae extending inwards from it through the cortex and anastomosing with one another in the medulla, (2) the dense lymphoid tissue (adenoid tissue of some authors) forming large masses in the cortex (cortical nodules) and rounded cords in the medulla (medullary cords). Notice also the clearer channel or lymph-sinus which everywhere intervenes between the fibrous tissue and the lymphoid tissue. Observe the fine fibres and branched cells which bridge across this channel.

Make a general sketch under a low power of a portion of the cortex together with the adjoining part of the medulla, and under a high power drawings of small portions of cortex and medulla.

The retiform tissue of the lymphatic glands has already been studied (Lesson IX.).

2. In sections of tonsil prepared similarly to those of the lymphatic gland, notice the large amount of lymphoid tissue only imperfectly collected into nodules. Observe also that the stratified epithelium, which covers the mucous membrane here as elsewhere in the mouth, is infiltrated with lymph-corpuscles. Here and there pit-like recesses may be met with, with mucus-secreting glands opening into the pits.

3. A similar preparation of the thymus gland of an infant or young animal. Notice that the masses of lymphoid tissue which form the lobules of the gland are separated by septa of connective tissue, and that they show a distinction into two parts, cortical and medullary. Observe the differences of structure of these two parts, and especially notice the concentric corpuscles in the medullary part.

Make a sketch of one of the lobules under a low power and of a small part of the medulla under a high power, including one or two concentric corpuscles. Measure the latter.

Structure of a lymphatic gland.—A lymphatic gland is composed of a *fibrous and muscular framework*, which incloses and supports the proper glandular substance, but is everywhere separated from it by a narrow channel, bridged across by cells and fibres, which is known as the *lymph-channel*. The *framework* consists of an envelope or *capsule* (fig. 173, *c*), and of *trabeculae* (*tr*), which pass at intervals inwards from the capsule, and after traversing the cortex of the gland, divide and reunite with one another so as to form a network

¹ See Appendix.

of fibrous bands. At one part of the gland there is usually a depression (*hilum*), and at the bottom of this the medulla comes to the surface and its fibrous bands are directly continuous with the capsule.

The proper *glandular substance* (*l.h*) is composed of lymphoid tissue, *i.e.* a fine reticulum with the meshes thickly occupied by lymph-corpuscles. It occupies all the interstices of the gland, form-

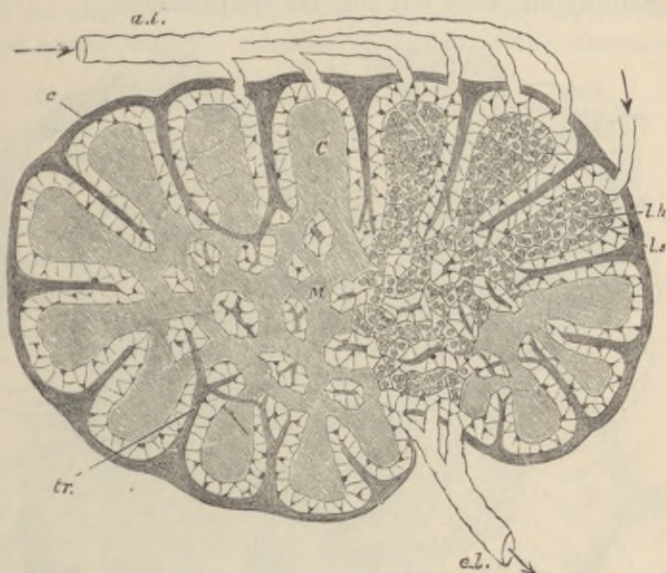


FIG. 173.—DIAGRAMMATIC SECTION OF LYMPHATIC GLAND. (Sharpey.)

a.l. afferent, *e.l.* efferent lymphatics; *C*, cortical substance; *M*, reticulating cords of medullary substance; *l.h.*, lymphoid tissue; *l.s.*, lymph-sinus; *c*, fibrous coat sending trabeculae, *tr.*, into the substance of the gland.

ing comparatively large rounded masses in the cortex (lymphoid nodules, *C*) between the trabeculae, and smaller reticulating cord-like masses (lymphoid cords, *M*) in the medulla.

The cells which bridge across the lymph-channel in the medulla (fig. 174, *c*) are branching nucleated cells which often contain pigment, so that this part of the gland has a dark colour. The lymph-channel is bridged across not only by these, but also by fibres derived from the capsule and trabeculae, which pass to the lymphoid tissue and become lost in its reticulum. But these fibres are often covered and concealed by the branched cells.

Lymphatic vessels (fig. 173, *a.l.*) enter the lymph-channels after ramifying in the capsule, and the lymph is conveyed slowly along the channels of the cortical and medullary part towards the hilum,

taking up many lymph-corpuscles in its passage. At the hilum it is gathered up by an efferent vessel or vessels (*e.l.*) which take origin in the lymph-sinuses of the medulla.

The efferent lymphatics always contain many more lymph-corpuscles than those which enter the gland, for lymph-corpuscles are constantly being formed by indirect division of the pre-existing cells in the glandular substance, and especially in the cortical nodules (Flemming), and gradually find their way into the lymph-channel.

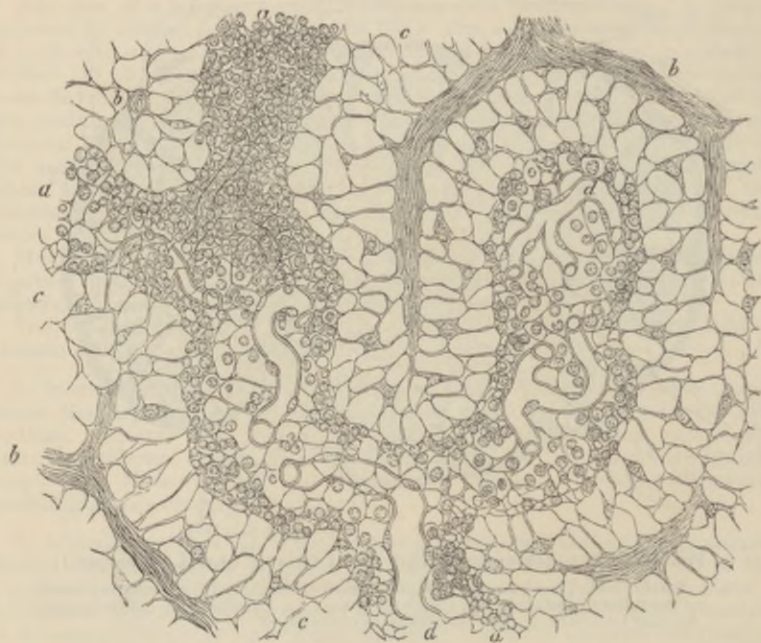

FIG. 174.—SECTION OF THE MEDULLARY SUBSTANCE OF A LYMPHATIC GLAND. (300 diameters.) (Recklinghausen.)

a, a, a, lymphoid cords; *c*, lymph-sinus; *b, b*, trabeculae; *d, d*, capillary blood-vessels.

An artery passes into each gland at the hilum; its branches are conveyed at first along the fibrous cords, but soon pass into the lymphoid tissue, where they break up into capillaries (fig. 174, *d*). The blood is returned by small veins, which are conducted along the fibrous trabeculae to the hilum again.

In some lymphatic glands the fibrous trabeculae are very slightly developed.

Hæmal lymphatic glands.—In many animals a certain number of lymphatic glands are observable which have a red colour. Some of these on section show that what corresponds to the lymph-channel in ordinary

lymphatic glands is in them occupied by blood. Others have the greater part of the interior occupied by large sinuses filled with blood; in addition to which there are a number of cords of lymphoid tissue.¹ The name *hæmal glands* has been given to these peculiar lymphatic glands, and it has been conjectured that they are connected with the production of blood-corpuscles, but we possess as yet no information as to the manner in which the blood passes into the sinuses, nor what relation the lymphatic vessels bear to them.

The **tonsils** are two masses of lymphoid tissue placed one on each side of the pharynx, into which they project. They are covered on the free surface with the stratified epithelium of the mucous mem-

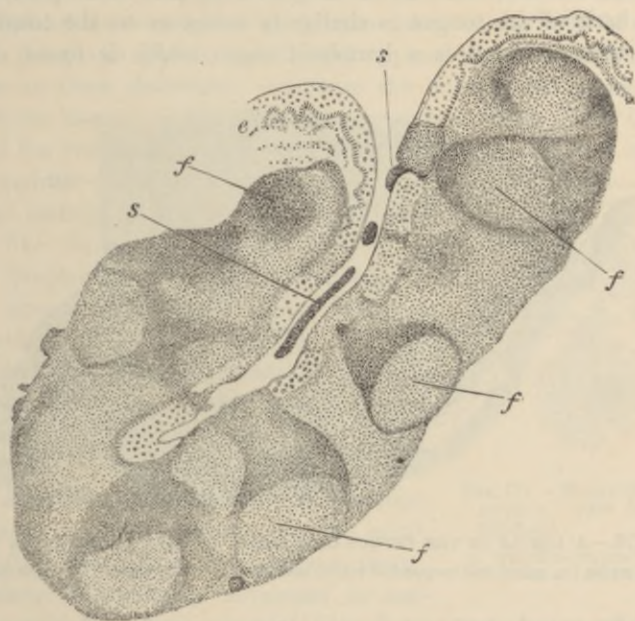


FIG. 175.—SECTION THROUGH ONE OF THE CRYPTS OF THE TONSIL. (Stöhr.)

e, e, stratified epithelium of surface of mucous membrane, continued into crypt; *f, f*, follicles or nodules of the lymphoid tissue, which is elsewhere diffuse; opposite each nodule numbers of lymph-cells are passing through the epithelium; *s, s*, masses of cells which have thus escaped from the organs to mix with the saliva as salivary corpuscles.

brane, and this surface is pitted with apertures which lead into recesses or crypts in the substance of the organ (fig. 175). These recesses are all lined by a prolongation of the stratified epithelium, and into them the ducts of numerous small mucous glands open. The tonsils are composed almost entirely of lymphoid tissue, which, besides being diffused over the whole organ, is at intervals aggregated

¹ See Vincent and Harrison, *Journ. Anat. and Physiol.* xxxi. p. 176, and Clarkson, *A Text-Book of Histology*, Plate xxxvi.

into small nodules, in which the lymph-cells are more closely arranged than elsewhere. In these nodules active multiplication of the lymph-cells by karyokinesis is constantly proceeding. This is, in fact, the cause of the formation of nodules in the tissue, as in most other organs in which lymphoid tissue occurs. On this account the nodules are sometimes termed *germ-centres*. Even the epithelium which covers the tonsils is infiltrated with lymph-corpuscles (Stöhr), and they may also wander out on to the free surface, and become mingled with the saliva as salivary corpuscles (see Lesson VI., § 1).

The mucous membrane of the neighbouring part of the pharynx and of the back of the tongue is similar in structure to the tonsils.

The **thymus gland** is a lymphoid organ which is found only in

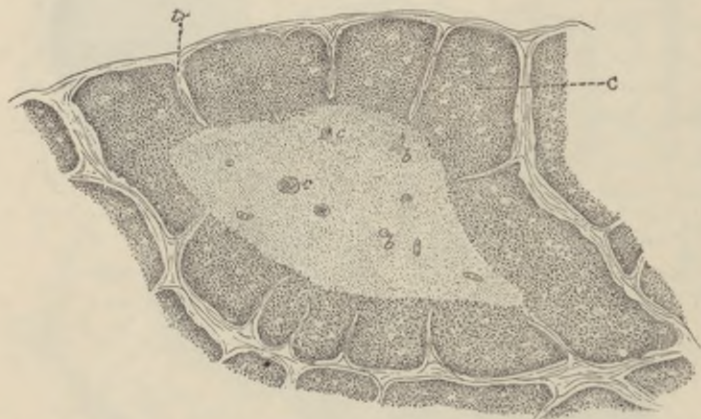


FIG. 176.—A LOBULE OF THE THYMUS OF A CHILD, AS SEEN UNDER A LOW POWER.
c, cortex; c, concentric corpuscles within medulla; b, blood-vessels; tr, trabeculae.

the embryo and during infancy. It is composed of a number of lobules (fig. 176) varying in size, which are separated from one another by septa of connective tissue, along which the blood-vessels and lymphatics pass to and from the lobules. Each lobule shows plainly, when examined with a low power, a distinction into an outer cortical and an inner medullary portion. The cortical part of the lobule is imperfectly divided into nodules by trabeculae of connective tissue, and is very similar in structure to the lymphoid tissue of the lymphatic glands and tonsils, with which it also agrees in exhibiting numerous indications of indirect cell-division; but the medulla is more open in its texture, and the reticulum is composed of larger, more transparent, flattened cells, and contains fewer lymph-corpuscles. Moreover, there are found in the medulla peculiar con-

centrically striated bodies (the *concentric corpuscles*, figs. 176, 177), which are "nests" of flattened epithelial cells arranged concentrically around one or more central cells. Sometimes these corpuscles are compound, two or three being grouped together and similarly inclosed by flattened cells. They appear to represent the remains of an epithelial tube which, in an early embryonic condition, occurs in the organ.

The lymphoid tissue is abundantly supplied with capillary blood-vessels, and large lymphatic vessels issue from the thymus, but in what way the latter are connected with the lobules has not been ascertained.

Lymphoid tissue occurs in many other parts of the body in addition to the lymphatic glands, tonsils, and thymus gland, although it may not, as in these structures, constitute the bulk of the organ. Thus it is found in many mucous membranes, such as those of the intestine and of the respiratory tract, both in a diffuse form and also collected into nodular masses which are like the cortical nodules of a lymphatic gland, and may, like those, be partially surrounded by a lymph-sinus. In the spleen also a large amount of lymphoid tissue is found ensheathing the smaller arteries, and also expanded into nodular masses (*Malpighian corpuscles of the spleen*). In these organs it will be studied subsequently.

Lymphoid tissue also occurs in considerable amount in the serous membranes, especially in young animals; in the adult it is often transformed into adipose tissue. The tissue is generally developed in connection with lymphatic vessels (Klein), an accumulation of retiform tissue and lymph-cells taking place either external to and around the lymphatic (*perilymphatic nodule*); or the lymphatic is dilated into a sinus and the formation of lymphoid tissue occurs within it (*endolymphatic nodule*).

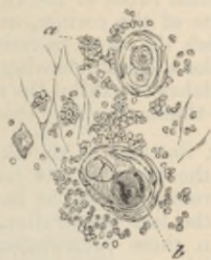

FIG. 177.—ELEMENTS OF THE THYMUS. (300 diameters.) (Cadiat.)

a, lymph-corpuscles; b, concentric corpuscle.

LESSON XXVI.

THE SKIN.

1. SECTIONS of skin from the palmar surface of the fingers. The skin is best hardened in picric acid or formol, followed by alcohol. The sections are to be made vertical to the surface, and should extend down as far as the subcutaneous tissue. They may be stained with carmalum or hæmalum, followed by picric alcohol, and mounted in xylol balsam. In these sections notice the layers of the epidermis and their different behaviour to the staining fluids. Notice also the papillæ projecting from the corium into the epidermis and look for tactile corpuscles within them. In very thin parts of the sections the fine intercellular channels in the deeper parts of the epithelium (see Lesson VI.) may be seen with a high power. The convoluted tubes of the sweat-glands will be seen here and there in the deeper parts of the corium, and in thick sections the corkscrew-like channels by which the sweat is conducted through the epidermis may also be observed. Make a sketch showing the general structure under a low power, and other sketches to exhibit the most important details under a high power. Measure the thickness of the epidermis and the length of the papillæ.

2. Sections of the skin of the scalp, vertical to the surface and parallel to the slope of the hair-follicles, and others parallel to the surface, and therefore across the hair-follicles. Stain and mount in the same way as in the last preparation. Examine also the structure of the hairs.

In these preparations the details of structure of the hairs and hair-follicles, together with the sebaceous glands and the little muscles of the hair-follicles, are to be made out.

3. Vertical sections across the nail and nail-bed, cut with a plane iron. To cut such hard structures as the nail it is best to soak the tissue in strong gum arabic for a few days, then place it in an appropriate position upon a cork or on the object-carrier of a microtome, and plunge the whole into 70 per cent. alcohol. This renders the gum hard, and enables sections to be cut of sufficient fineness. To remove the gum the sections are placed in water for a few hours; they may then be stained with hæmalum or carmalum and mounted in the usual manner in xylol balsam. Notice the ridges (not papillæ) of the corium projecting into the epidermis. Observe also the distinction of the epidermis into Malpighian layer and nail proper.

4. Mount in xylol balsam a section from a portion of skin of which the blood-vessels have been injected, and notice the distribution of the capillaries to the sweat-glands, to the hair-follicles, and to the papillary surface of the corium.

The **skin** is composed of two parts, *epidermis* and *cutis vera*.

The **epidermis**, or scarf skin, is a stratified epithelium (fig. 178). It is composed of a number of layers of cells, the deeper of which are soft and protoplasmic, and form the *rete mucosum* of Malpighi, whilst the

superficial layers are hard and horny, this horny portion sometimes constituting the greater part of the thickness of the epidermis. The deepest cells of the *rete mucosum*, which are set on the surface of the cutis vera, are columnar (fig. 178, *c*) in shape. In the coloured races of mankind these cells contain pigment-granules. In the layers immediately above them the cells are polyhedral (fig. 178, *p*). Between all these cells of the *rete mucosum* there are fine intercellular clefts

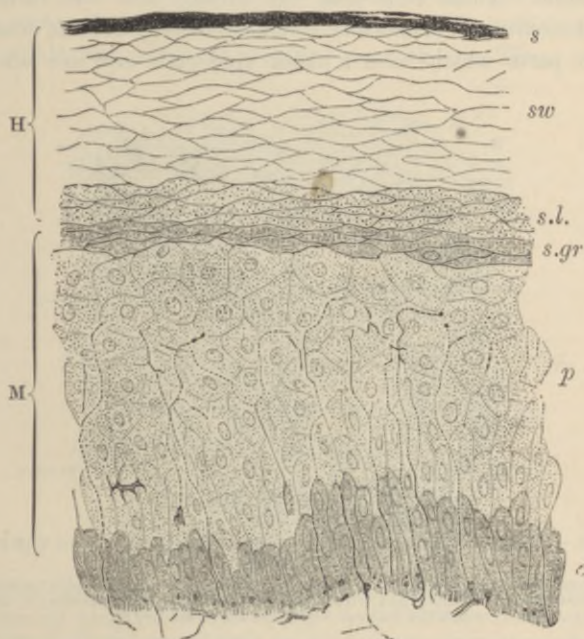


FIG. 178.—SECTION OF EPIDERMIS. (Ranvier.)

H, horny layer, consisting of *s*, superficial horny scales; *sw*, swollen-out horny cells; *s.l.* stratum lucidum; M, rete mucosum or Malpighian layer, consisting of *p*, prickle-cells, several rows deep; *c*, elongated cells forming a single stratum near the corium; and *s.gr*, stratum granulosum of Langerhans, just below the stratum lucidum; *n*, part of a plexus of nerve-fibres in the superficial layer of the cutis vera. From this plexus fine varicose nerve-fibrils may be traced passing up between the epithelium-cells of the Malpighian layer.

which separate the cells from one another, but are bridged across by fine fibres, which pass from cell to cell, and also through the substance of the cells (Ranvier, Delépine). The intercellular channels serve for the passage of lymph, and within them occasionally lymph-corpuscles may be found, often having a stellate figure from compression.

The most superficial layer of the rete mucosum is formed of somewhat flattened cells filled with granules or droplets of a material which stains deeply with carmine and hæmatoxylin (*stratum granulosum*,

fig. 178, *s.gr*; fig. 179, *c*). Superficial to the stratum granulosum is a layer in which the cells are indistinct and some of which contain flakes or larger droplets of a material which is chemically similar to the granules in the last layer. This layer has a clear appearance in section, and is known as the *stratum lucidum*. Immediately superficial to this layer is the *horny part* of the epidermis. It is composed of a number of strata of distinct cells, the nuclei of which are no longer visible. These cells near the surface take the form of thin horny scales (*stratum squamosum*), which eventually become detached (*s*). In certain parts which have a thick epidermis and are not covered

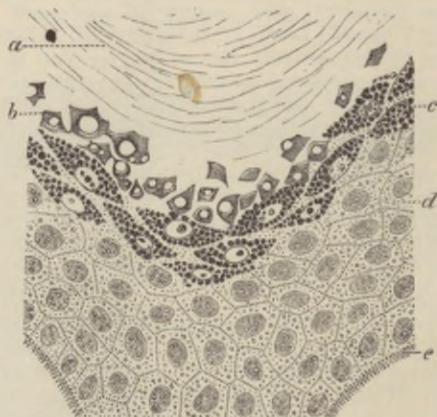


FIG. 179.—PORTION OF EPIDERMIS FROM A SECTION OF THE SKIN OF THE FINGER, COLOURED WITH PICROCARMINE. (Ranvier.)

a, stratum corneum; *b*, stratum lucidum with diffused flakes of eleidin; *c*, stratum granulosum, the cells filled with drops of eleidin; *d*, prickle-cells; *e*, dentate projections by which the deepest cells of the epidermis are fixed to the cutis vera.

with hair (*e.g.* the palms and soles), the superficial part of the epidermis is a layer mainly formed by a number of greatly swollen cells, forming collectively what has been termed the *epitrichial layer*. In the embryo it covers the whole body, but is thrown off when the hairs are developed.

The growth of the epidermis takes place by a multiplication of the cells of the deeper layers. The newly formed cells, as they grow, push towards the surface those which were previously formed, and in their progress the latter undergo a chemical transformation, which converts their protoplasm into horny material: this change seems to occur just at and above the stratum granulosum (see fig. 179). The granules which occupy the cells of the last-mentioned layer are composed of a substance termed *eleidin*, which according to Ranvier is transformed into keratin.

No blood-vessels pass into the epidermis, but it receives nerves which ramify between the cells of the rete mucosum in the form of fine varicose fibrils (fig. 178).

The *cutis vera* or corium is composed of dense connective tissue, which becomes more open and reticular in its texture in its deeper part, where it merges into the subcutaneous tissue. It is thickest over the posterior aspect of the trunk, whereas the epidermis is thickest on the palms of the hands and soles of the feet. The superficial or vascular layer of the corium bears minute *papillæ*, which project up into the epidermis, which is moulded over them. These papillæ for

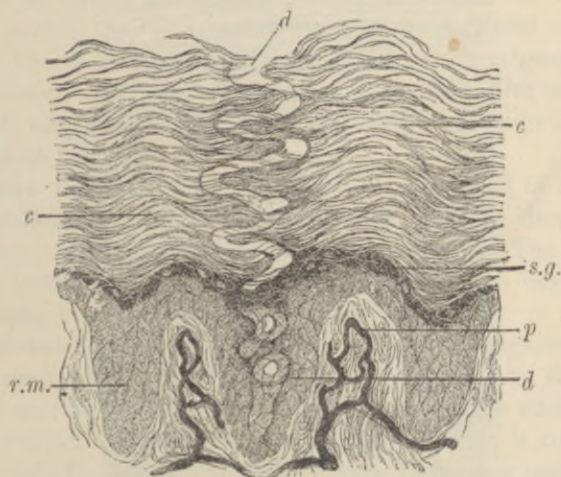


FIG. 180.—DUCT OF A SWEAT-GLAND PASSING THROUGH THE EPIDERMIS.
(Magnified 200 diameters.) (Heitzmann.)

p, papillæ with blood-vessels injected; *r.m.* rete mucosum between the papillæ; *c*, *c*, stratum corneum; *s.g.* stratum granulosum; *d*, *d*, sweat-duct passing through epidermis.

the most part contain looped capillary vessels (fig. 180), but some, especially those of the palmar surface of the hand and fingers, and the corresponding part of the foot, contain tactile corpuscles, to which medullated nerve-fibres pass (fig. 142, *b*, p. 120).

In some parts of the body (scrotum, penis, nipple, and its areola), involuntary muscular tissue occurs in the deeper portions of the *cutis vera*, and in addition, wherever hairs occur, small bundles of this tissue are attached to the hair-follicles.

The blood-vessels of the skin are distributed almost entirely to the surface, where they form a close capillary network, sending up loops into the papillæ (fig. 180). Special branches are also distributed to the various appendages of the skin, viz. the sweat-glands and

hair-follicles, with their sebaceous glands and little muscles, as well as to the little masses of adipose tissue which may be found in the deeper parts of the cutis.

The lymphatics originate near the surface in a network of vessels, which is placed a little deeper than the blood-capillary network. They receive branches from the papillæ, and pass into larger vessels, which are valved, and which run in the deeper or reticular part of the corium. From these the lymph is carried away by still larger vessels, which course in the subcutaneous tissue.

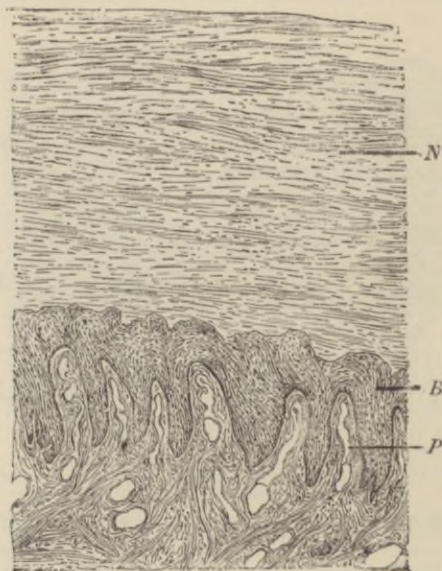


FIG. 181.—SECTION ACROSS THE NAIL AND NAIL-BED. (100 diameters.) (Heitzmann.)

P, ridges with blood-vessels; *B*, rete mucosum; *N*, nail.

The **appendages of the skin** are the *nails*, the *hairs*, with their *sebaceous glands* and the *sweat-glands*. They are all developed as thickenings and downgrowths of the Malpighian layer of the epidermis.

The **nails** are thickenings of the stratum lucidum of the epidermis, which are developed over a specially modified portion of the corium, which is known as the *bed* or *matrix of the nail*, the depression at the posterior part of the nail-bed from which the root of the nail grows being known as the *nail-groove*. The distal part of the nail forms the *free border*, and is the thickest part of the body of the nail. The substance of the nail (fig. 181, *N*) is composed of clear horny cells,

each containing the remains of a nucleus; it rests immediately upon a Malpighian layer (*B*) similar to that which is found in the epidermis generally. The corium of the nail-bed is beset with longitudinal ridges instead of the papillæ which are present over the rest of the skin; these, like the rest of the superficial part of the corium, are extremely vascular. The nails are developed in the fœtus at about the third month, the groove being formed at this time in the corium, and the nail-rudiment appearing in it as a thickening of the stratum lucidum, which lies over the bed. It becomes free in the sixth month, its free end being at first thin, but as it grows forward over the bed it appears to receive additions on its under surface—at least in the posterior part of the bed—so that after a time the distal end becomes thicker. The epitrichial layer of the cuticle which originally covered the developing nail becomes detached about the fifth month, and, after birth, only remains as the narrow border of cuticle which overlies the *lunula* at the root.

The **hairs** are growths of the epidermis, developed in little pits—the *hair-follicles*—which extend downwards into the deeper part of the corium, or even into the subcutaneous tissue. The hair grows from the bottom of the follicle, the part which thus lies within the follicle being known as the *root* (fig. 183).

The substance of a hair is mainly composed of a pigmented, horny, *fibrous material* (fig. 182, *f*), which can be separated by the action of sulphuric acid into long tapering fibrillated cells, the nuclei of which are still visible. The fibrous substance of the hair is covered by a layer of delicate imbricated scales, termed the *hair-cuticle* (*c*). In many hairs, but not in all, the centre is occupied by a dark-looking axial substance (*medulla*, *m*), formed of angular cells which contain granules of eleidin, and frequently have a dark appearance from the presence of minute air-bubbles. The latter may also occur in interstices in the fibrous substance. When they are present, the hair looks white by reflected light. The *root* has the same structure as the body of the hair, except at its extremity, which is enlarged into a *knob* (fig. 183); this is composed mainly of soft, growing cells, and fits over a vascular *papilla* (*p*), which projects up into the bottom of the follicle. The follicle, like the skin itself, of which it is a recess, is composed of two parts: one epithelial, and the other connective tissue. The epithelial or epidermic part of the follicle closely invests the hair-root, and is often in great part dragged out with it; hence it is known as the *root-sheath*. It consists of an outer layer of soft columnar and polyhedral cells, like the Malpighian layer of the epidermis—the *outer root-sheath* (figs. 183, *f*; 184, *e*;

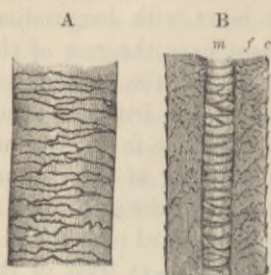


FIG. 182.—PIECE OF HUMAN HAIR. (Magnified.)

A, seen from the surface; B, in optical section. *c*, cuticle; *f*, fibrous substance; *m*, medulla, the air having been expelled by Canada balsam.

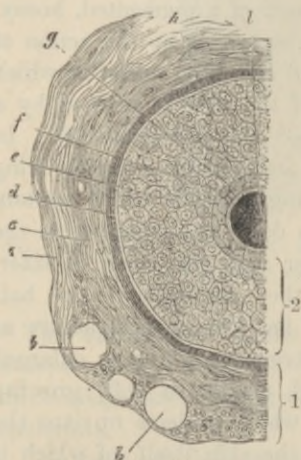


FIG. 184.—SECTION OF HAIR-FOLLICLE. (Biesiadecki.)

1, dermic coat of follicle; 2, epidermic coat or root-sheath. *a*, outer layer of dermic coat, with blood-vessels, *b*, *b*, cut across; *c*, middle layer; *d*, inner or hyaline layer; *e*, outer root-sheath; *f*, *g*, inner root-sheath; *h*, cuticle of root-sheath; *l*, hair.

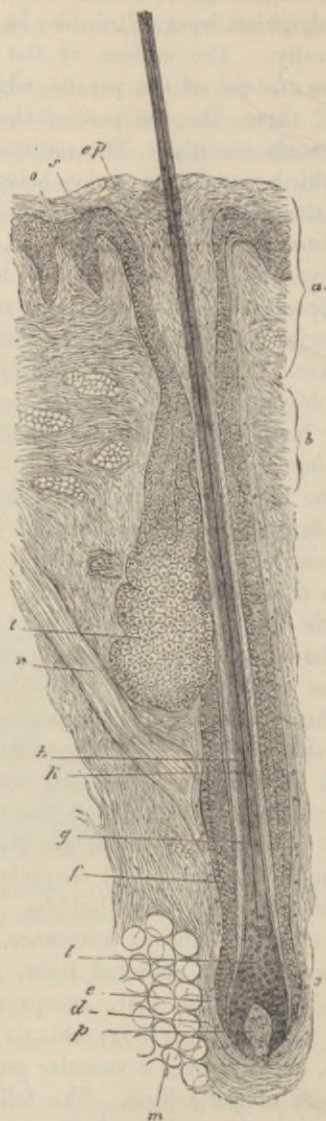


FIG. 183.—HAIR-FOLLICLE IN LONGITUDINAL SECTION. (Biesiadecki.)

a, mouth of follicle; *b*, neck; *c*, bulb; *d*, *e*, dermic coat; *f*, outer root-sheath; *g*, inner root-sheath; *h*, hair; *k*, its medulla; *l*, hair-knob; *m*, adipose tissue; *n*, hair-muscle; *o*, papilla of skin; *p*, papilla of hair; *s*, rete mucosum, continuous with outer root-sheath; *ep*, horny layer; *t*, sebaceous gland.

185, *e*, *e'*, *e''*); and of an inner, thinner, horny stratum next to the hair—the *inner root-sheath* (figs. 183, *g*; 184, *f*; 185, *f*, *g*). The inner

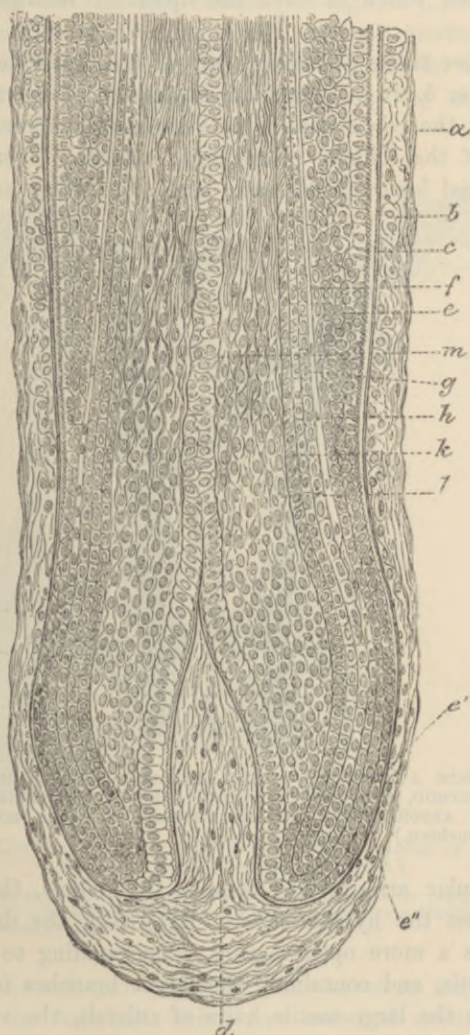


FIG 185.—LONGITUDINAL SECTION THROUGH THE BOTTOM OF A HAIR-FOLLICLE.
(Mertsching.)

a, outer; *b*, inner, and *c*, hyaline layers of the dermic coat of the follicle; *d*, papilla; *e*, *e'*, *e''*, outer root-sheath; *f*, Henle's layer of inner root-sheath; *g*, Huxley's layer; *h*, cuticle of root-sheath; *k*, hair-cuticle; *l*, fibrous layer of hair becoming formed; *m*, medulla of hair.

root-sheath itself consists of three layers, the outermost being composed of oblong cells without nuclei (*Henle's layer*), the next of

flattened polyhedral nucleated cells (*Huxley's layer*), and the third—the *cuticle of the root-sheath*—being a thin layer of downwardly imbricated scales, which fit over the upwardly imbricated scales of the hair itself.

The connective tissue or dermic part of the hair-follicle (figs. 184, *a, c, d*; 185, *a, b, c*) is composed internally of a vascular layer, separated from the root-sheath by a basement-membrane termed the *hyaline layer* of the follicle. This inner vascular layer corresponds to the superficial layer of the cutis vera. Its fibres and cells have



FIG. 186.—FROM A SECTION OF SKIN PREPARED BY THE CHROMATE OF SILVER METHOD, SHOWING THE UPPER PART OF TWO HAIRS AND THE TERMINAL ARBORISATIONS OF NERVE-FIBRES IN THEIR ROOT-SHEATHS. (Van Gehuchten.)

a regular circular arrangement around the follicle, the cells being flattened against the hyaline layer. Externally the dermic coat of the follicle has a more open texture, corresponding to the reticular part of the cutis, and containing the larger branches of the arteries and veins. In the large tactile hairs of animals, the veins near the bottom of the follicle are dilated into sinuses, so as to produce a kind of erectile structure.

A hair receives nerve-fibres which pass into the papilla, and others which enter the root-sheath. These last descend from the superficial nerves of the corium and form ring-like arborisations in the upper part of the hair-follicle (fig. 186).

The hair grows from the bottom of the follicle by multiplication

of the soft cells which cover the papilla, these cells becoming elongated to form the fibres of the fibrous substance, and otherwise modified to produce the medulla and cuticle (see fig. 185).

When a hair is eradicated, a new hair is produced from these cells. It is not uncommon to find hair-follicles in which the whole of the lower part has degenerated in such a way that the vascular

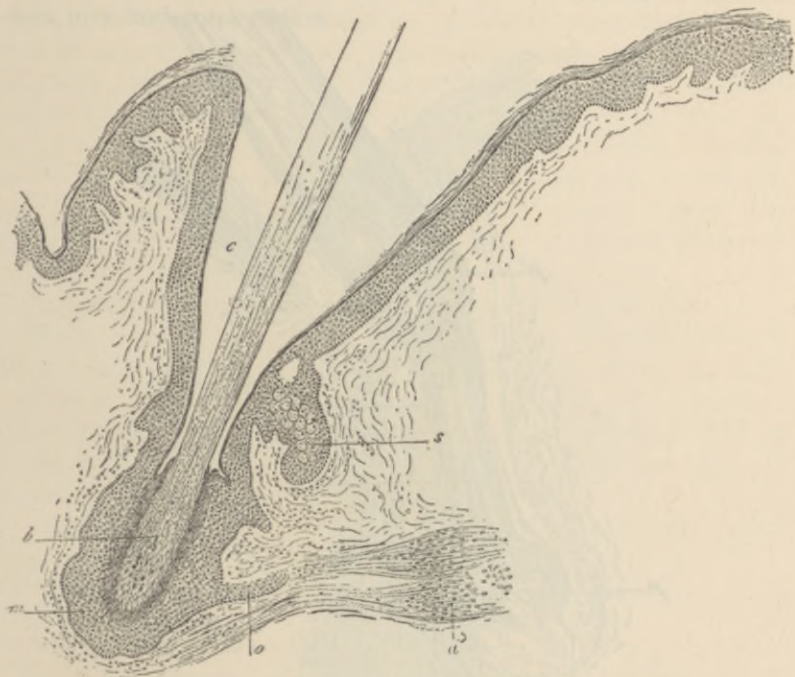


FIG. 187.—LONGITUDINAL SECTION THROUGH THE FOLLICLE OF A HAIR WHICH HAS CEASED TO GROW. (Ranvier.)

m, epithelium at the bottom of the follicle (which contains no papilla); *b*, modified hair-bulb; *c*, neck of the follicle; *s*, sebaceous gland; *o*, epithelial projection at the insertion of the arrector pili, *a*.

papilla, and the soft growing cells which cover it, may have entirely disappeared, the hair-bulb being now attached at its sides as well as below to the epithelium of the follicle (fig. 187). The hair then ceases to grow, and eventually becomes lost, but its place may be again supplied by a new hair, which becomes formed in a down-growth from either the bottom or the side of the hair-follicle, a new papilla first becoming formed at the extremity of the down-growth (fig. 188). If not previously detached, the old hair may be pushed out from the follicle by the one which replaces it.

The hairs are originally developed in the embryo in the form of small solid downgrowths from the Malpighian layer of the epidermis. The hair-rudiment, as it is called, is at first composed entirely of soft growing cells; but presently those in the centre become differentiated, so as to produce a minute hair invested by inner root-sheath, and its base resting upon a papilla which has

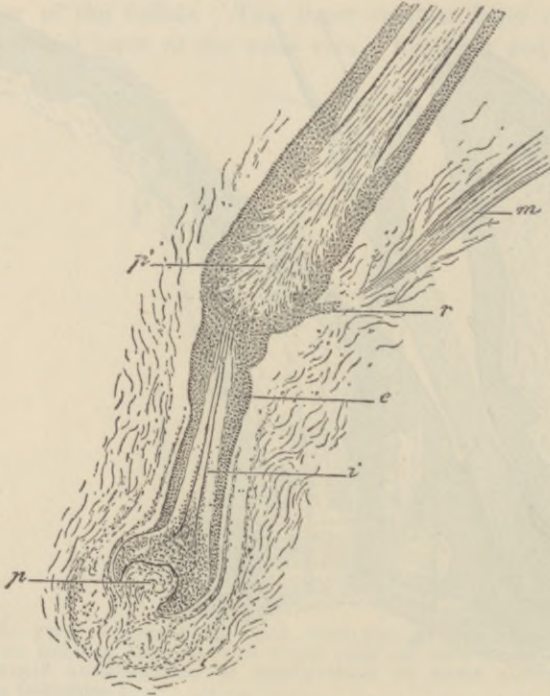


FIG. 188.—REPLACEMENT OF OLD HAIR BY A NEWLY-DEVELOPING ONE IN THE HUMAN SCALP. (Ranvier.)

p, papilla of the new hair; *i*, its inner root-sheath; *e*, its outer root-sheath; *p'*, attached lower extremity of the old hair; *r*, epithelial projection at insertion of arrector pili, *m*.

become formed at the extremity of the hair-rudiment and is continuous with the connective tissue of the corium (fig. 189, *p*). As the minute hair grows, it pushes its way through the layers of the epidermis, which it finally perforates, the epitrichial layer being thrown off (p. 156). The hair-rudiments appear at the third or fourth month of foetal life; their growth is completed about the fifth or sixth month, and the fine hairs which they form constitute a complete hairy covering termed the *lanugo*. This is entirely shed within a few months of birth, the new hairs being formed in

down-growths from the old hair-follicles in the manner already mentioned.

Hairs grow at the rate of half an inch per month. They are found all over the body except on the palms of the hands and the soles of the feet, and on the distal phalanges of the fingers and toes. They usually slant, and in the negro the hair-follicles are even considerably curved. On the scalp they are set in groups, as is well seen in a horizontal section.

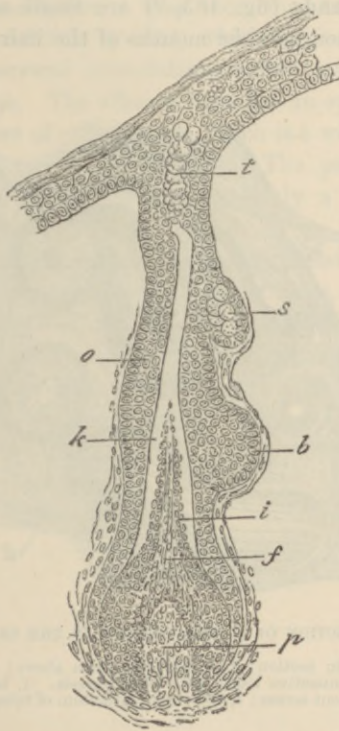


FIG. 189.—DEVELOPING HAIR FROM HUMAN EMBRYO OF $4\frac{1}{2}$ MONTHS. (Ranvier.)

p, papilla; *j*, hair-rudiment; *i*, cells forming inner root-sheath; *k*, keratinised part of inner root-sheath, uncoloured by carmine; *o*, outer root-sheath; *b*, epithelial projection for insertion of arrector pili; *s*, sebaceous gland; *t*, sebaceous matter forming independently in the part which will become the neck of the follicle.

The hairs of animals are often curiously marked by the arrangement of their medulla, the markings being characteristic of particular species.

Muscles of the hairs.—A small muscle composed of bundles of plain muscular tissue is attached to each hair-follicle (*arrector pili*, fig. 183, *n*; 187 *a*); it passes from the superficial part of the corium, on the side

to which the hair slopes, obliquely downwards, to be attached near the bottom of the follicle to a projection formed by a localised hypertrophy of the outer root-sheath. When the muscle contracts, the hair becomes more erect, and the follicle is dragged upwards so as to cause a prominence on the general surface of the skin, whilst the part of the corium from which the little muscle arises is correspondingly depressed; the roughened condition known as 'goose skin' being in this way produced.

The **sebaceous glands** (fig. 183, *t*) are small saccular glands, the ducts from which open into the mouths of the hair-follicles. Both the

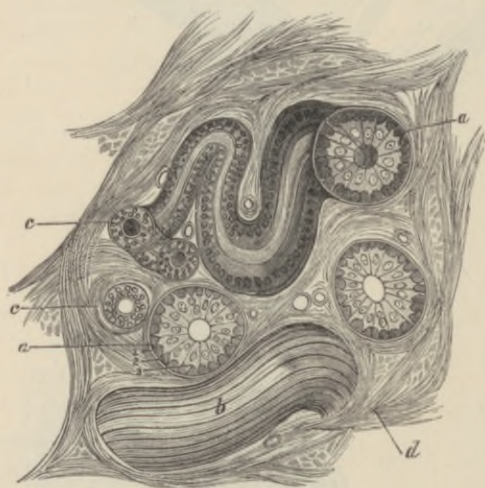


FIG. 190.—SECTION OF A SWEAT-GLAND IN THE SKIN OF MAN.

a, a, secreting tube in section; *b*, a coil seen from above; *c, c*, efferent tube; *d*, intertubular connective tissue with blood-vessels. 1, basement-membrane; 2, muscular fibres cut across; 3, secreting epithelium of tubule.

duct and the saccules are lined by epithelium, which becomes charged with fatty matter. This sebaceous matter is discharged into the cavity of the saccule, probably owing to the disintegration of the cells within which it is formed. There may be two or more sebaceous glands attached to each follicle.

The sebaceous glands are developed as outgrowths from the outer root-sheath (fig. 189, *s*).

The **sweat-glands** are abundant over the whole skin, but they are most numerous on the palm of the hand and on the sole of the foot. They are composed of coiled tubes, which lie in the deeper part of the

integument and send their ducts up through the cutis to open on the surface by corkscrew-like channels which pierce the epidermis (fig. 180, p. 157).

The *glandular* or *secreting tube* is a convoluted tube composed of a basement-membrane lined by a single layer of cubical or columnar epithelium-cells, and with a layer of longitudinally or obliquely disposed fibres between the epithelium and basement-membrane. These fibres are usually regarded as muscular, but the evidence on this point is not conclusive. The secreting tube is considerably larger than the *effluent tube* or *duct*, which begins within the gland and usually makes several convolutions before leaving the gland to traverse the cutis vera. The effluent tube has an epithelium consisting of two or three layers of cells, within which is a well-marked cuticular lining, but there is no muscular layer. The passage through the epidermis has no proper wall, but is merely a channel excavated between the epithelium-cells.

The **ceruminous glands of the ear** are modified sweat-glands.

The sweat-glands are developed, like the hairs, from downgrowths of the Malpighian layer of the epidermis into the corium, the rudiments which are thus formed becoming eventually coiled up at their extremities and converted into hollow tubes. The muscular (?) fibres of the tubes as well as the secreting epithelium-cells are thus epiblastic structures.

The sweat-glands receive nerve-fibres, and each gland has a special cluster of capillary blood-vessels.

LESSON XXVII.

STRUCTURE OF THE HEART.

1. In sections through the wall of the auricle notice the relative thickness of the epicardium, myocardium, and endocardium. Observe the blood-vessels and nerve-fibres under the epicardium, often embedded in fat; here and there a ganglion may be seen under this membrane. Notice also the elastic networks under both the pericardium and endocardium. Make a general sketch from this section.

2. In sections through the wall of the ventricle the same points are to be noticed. The muscular fibres are variously cut. In those cut longitudinally, the branching of the fibres and their union into a network may be seen. Notice also that although the fibres are cross-striated this is less distinct than in voluntary muscle, and the nuclei lie in the centre of each fibre. Transverse markings may also be seen passing across the fibres between the nuclei and indicating a division into cells. The endocardium is very thin, especially over the columnæ carneæ.

3. If a portion of endocardium of the sheep's heart is spread out on a slide and examined in salt solution, a network of large beaded fibres may be seen with a low power or even with a lens. These are the *fibres of Purkinje*, and they will be seen to be formed of large, square-looking cells, usually containing two nuclei, and having striated muscular substance at their periphery.

4. The lymphatics of the heart are easily injected with Berlin blue by sticking the nozzle of the injecting syringe into the muscular substance, in the interstices of which the lymphatics arise. These commencing lymphatics lead to efferent vessels which pass under the epicardium towards the base of the heart.

5. Section through one of the valves of the heart.¹

6. The epithelium which covers the epicardium, and that which lines the endocardium, may be studied in preparations of the fresh organ which have been well washed with distilled water; then treated with nitrate of silver, again washed, and subsequently exposed to the light and hardened in alcohol. Surface sections are to be made and mounted in xylol balsam.

The muscular tissue of the heart (*myocardium*) forms the main thickness of the ventricles and also of parts of the auricles. It is composed of a network of fibres which are formed of uninucleated transversely striated cells, the structure of which has already been studied (Lesson XVII., p. 92).

¹The appearances which are to be studied in sections 1, 2, and 5 can all be obtained in one preparation, viz. a vertical section including a portion of auricle and ventricle and a flap of the intervening auriculo-ventricular valve.

In the interstices of the muscular tissue there is a little areolar tissue in which run the very numerous blood-capillaries and the lacunar lymphatics.

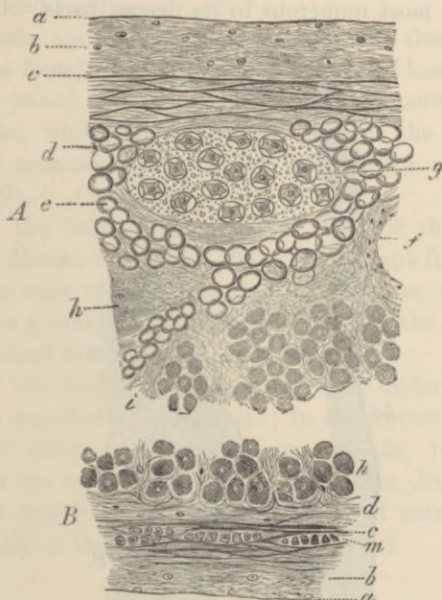


FIG. 191.—SECTION OF THE RIGHT AURICLE.

- A*, Epicardium and adjacent part of the myocardium. *a*, serous epithelium in section; *b*, connective-tissue layer; *c*, elastic network; *d*, subserous areolar tissue; *e*, fat; *f*, section of a blood-vessel; *g*, a small ganglion; *h*, muscular fibres of the myocardium; *i*, intermuscular areolar tissue.
- B*, Endocardium and adjacent layer of the myocardium. *a*, lining epithelium; *b*, connective tissue with fine elastic fibres; *c*, layer with coarser elastic fibres; *d*, sub-endocardial connective tissue continuous with the intermuscular tissue of the myocardium; *h*, muscular fibres of the myocardium; *m*, plain muscular tissue in the endocardium.

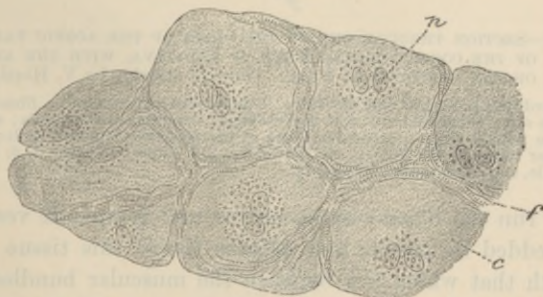


FIG. 192.—FRAGMENT OF THE NETWORK OF PURKINJE FROM THE VENTRICULAR ENDOCARDIUM OF THE SHEEP. (Ranvier.) $\frac{300}{\mu}$.

c, cell; *n*, nuclei; *f*, striated substance in the periphery of the cells.

The myocardium is covered externally by a layer of serous membrane—the *epicardium* (cardiac pericardium, fig. 191, *A*)—composed, like other serous membranes, of connective tissue and elastic fibres, the latter being most numerous in its deeper parts. Underneath the

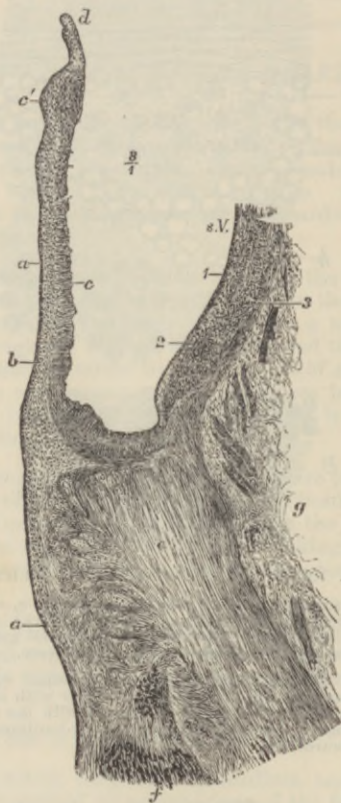


FIG. 193.—SECTION THROUGH ONE OF THE FLAPS OF THE AORTIC VALVE, AND PART OF THE CORRESPONDING SINUS OF VALSALVA, WITH THE ADJOINING PART OF THE VENTRICULAR WALL. (From a drawing by V. Horsley.)

a, endocardium, prolonged over the valve; *b*, sub-endocardial tissue; *c*, fibrous tissue of the valve, thickened at *c'* near the free edge; *d*, section of the lunula; *e*, section of the fibrous ring; *f*, muscular fibres of the ventricle attached to it; *g*, loose areolar tissue at the base of the ventricle; *s.V.* sinus Valsalvæ; *1*, *2*, *3*, inner, middle, and outer coats of the aorta.

epicardium run the blood-vessels, nerves, and lymphatic vessels of the heart, embedded in areolar and adipose tissue, this tissue being continuous with that which lies between the muscular bundles; and the free surface of the membrane is covered by serous epithelium.

The *endocardium* (fig. 191, *B*) has a structure not very unlike the pericardium. It is lined by a pavement-epithelium (or endothelium),

like that of a serous membrane, and consists of connective tissue with elastic fibres in its deeper part, between which there may, in some parts, be found a few plain muscular fibres. Fat is sometimes met with under the endocardium.

In some animals, *e.g.* the sheep, and sometimes also in man, large beaded fibres are found under the endocardium. These are formed of large clear cells joined end to end, and generally containing in their centre two nuclei, whilst the peripheral part of the cell is formed of cross-striated muscular tissue; they are known as the *fibres of Purkinje* (fig. 192).

The *valves* of the heart are formed of folds of the endocardium strengthened by fibrous tissue (fig. 193). This tissue forms a thickening near the free edge of the valve (*c'*). At the base of the auriculo-ventricular valves a little of the muscular tissue of the auricle may be found passing a short distance into the valve.

The *nerves* of the heart are seen in sections underneath the epicardium of both auricles and ventricles; in the former situation they are connected at intervals with small ganglia (fig. 191, *g*). Their branches pass to the muscular substance, and after dividing into fine fibrils, these are described as ending in enlarged extremities, which are applied directly to the muscular fibres (Ranvier).

LESSON XXVIII.

THE TRACHEA AND LUNGS.

1. In sections of the trachea and larynx, notice the epithelium, the basement-membrane (of some thickness in the human trachea), the lymphoid tissue of the mucous membrane, the elastic tissue external to this, and, lastly, the fibrous membrane containing the cartilages. In the mucous membrane and submucous areolar tissue look for sections of mucous glands, ducts of which may be seen opening on the surface. At the back of the trachea notice the plain muscular fibres transversely arranged; there may be larger mucous glands external to these.

2. In sections of lung similarly prepared notice the sections of the alveoli collected into groups (infundibula). Find sections of bronchial tubes, some cut longitudinally and passing at their extremities into the infundibula, others cut across; the latter show the structure of the tubes best. In each tube notice the ciliated epithelium internally. Next to this the mucous membrane containing numerous elastic fibres and often thrown into folds; then the layer of circular muscular fibres, and, outside this, loose fibrous tissue in which in larger bronchial tubes the pieces of cartilage may be seen embedded. Small mucous glands may also be observed in the fibrous tissue sending their ducts through the other layers to open on the inner surface. Notice that the section of a branch of the pulmonary artery always accompanies a section of a bronchial tube.

In the sections of the alveoli observe the capillary vessels passing from one side to the other of the intervening septa; and in places where the thin wall of an alveolus is to be seen in the section, try and make out the network of blood-capillaries upon it. Notice within the alveoli nucleated corpuscles which very frequently contain dark particles in their protoplasm. They are amoeboid cells which have migrated from the blood-vessels and lymphatics, and have taken in inhaled particles of carbon. They seem to pass back into the lung tissue, for similar cells may be seen in this. Make a sketch of part of the wall of a bronchial tube and of one or two of the alveoli.

3. In sections of lung the air-cells of which have been filled with a mixture of gelatine and nitrate of silver solution, the epithelium of the alveoli may be studied. The sections can be made with the freezing microtome, and mounted in glycerine, which should be warmed after the cover-glass is applied in order to melt the gelatine.

4. Mount in xylol balsam a section of lung in which the pulmonary vessels have been injected. Study the general arrangement of the vessels with a low power, and the network of capillaries of the alveoli with a high power. Observe that the veins run apart from the arteries. Sketch the capillary network of one or two adjoining alveoli.

The **trachea** or windpipe is a fibrous and muscular tube, the wall of which is rendered somewhat rigid by C-shaped hoops of cartilage which are embedded in the fibrous tissue. The muscular tissue, which

is of the plain variety, forms a flat band, the fibres of which run transversely at the back of the tube. The trachea is lined by a *mucous membrane* (fig. 194, *a-d*), which has a ciliated epithelium upon its inner surface. The epithelium-cells have been already described (Lesson VII.); they rest upon a thick basement-membrane. The mucous membrane proper consists of areolar and lymphoid tissue, and contains numerous blood-vessels and lymphatics. In its deepest part

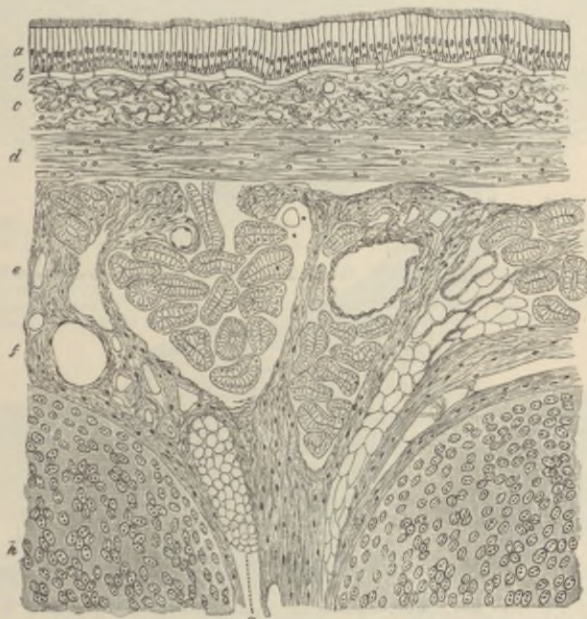


FIG. 194.—LONGITUDINAL SECTION OF THE HUMAN TRACHEA, INCLUDING PORTIONS OF TWO CARTILAGINOUS RINGS. (Klein.) (Moderately magnified.)

a, ciliated epithelium; *b*, basement-membrane; *c*, superficial part of the mucous membrane, containing the sections of numerous capillary blood-vessels and much lymphoid tissue; *d*, deeper part of the mucous membrane, consisting mainly of elastic fibres; *e*, submucous areolar tissue, containing the larger blood-vessels, small mucous glands (their ducts and alveoli are seen in section), fat, etc.; *f*, fibrous tissue investing and uniting the cartilages; *g*, a small mass of adipose tissue in the fibrous layer; *h*, cartilage.

is a well-marked layer of longitudinal elastic fibres (*d*). Many small glands for the secretion of mucus are found in the wall of the trachea. They may lie either within the mucous membrane or in the submucous areolar tissue (*e*) or, lastly, at the back of the trachea, outside the transverse muscular fibres.

The two divisions of the trachea, the *bronchi*, are precisely similar in structure to the main tube.

The **larynx** is also very like the trachea so far as the structure of

the mucous membrane is concerned, but over the true vocal cords and upon the epiglottis, as well as here and there in the part above the glottis, stratified epithelium is found; and taste-buds (see next Lesson) may occur in this epithelium, except over the vocal cords.

The lymphoid tissue is especially abundant in the mucous membrane of the ventricle of Morgagni, and a large number of mucous glands open into this cavity and into that of the sacculus.

The true vocal cords are composed of fine elastic fibres.

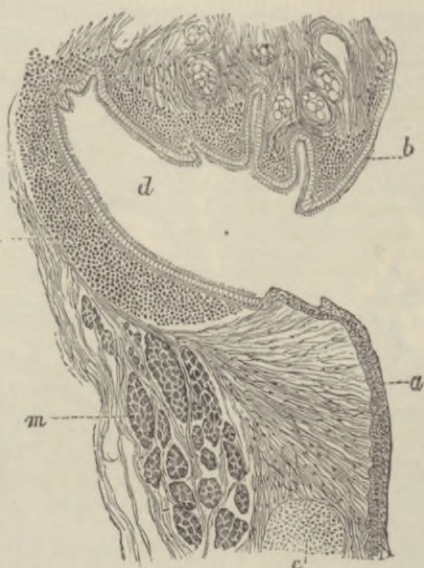


FIG. 195.—LONGITUDINAL SECTION THROUGH THE VENTRICLE OF THE LARYNX OF A CHILD. (Klein.)

a, true vocal cord; *b*, false vocal cord; *c*, nodule of cartilage; *d*, ventricle of Morgagni; *l*, lymphoid tissue; *m*, thyro-arytenoid muscle.

The cartilages of the trachea and larynx are hyaline, except the epiglottis and the cartilages of Santorini and of Wrisberg, which are composed of elastic fibro-cartilage.

The **lungs** are formed by the ramifications of the *bronchial tubes* and their terminal expansions, which form groups of sacculated dilatations (*infundibula*), beset everywhere with small hemispherical bulgings, known as the *air-cells* or *pulmonary alveoli*.

The **bronchial tubes** (figs. 196, 197) are lined in their whole extent by ciliated epithelium which rests on a basement-membrane. External to this is the corium of the mucous membrane, containing a large number of longitudinal elastic fibres and some lymphoid tissue.

Outside this again is a complete layer of plain muscular fibres encircling the tube. Next comes a loose fibrous layer in which,

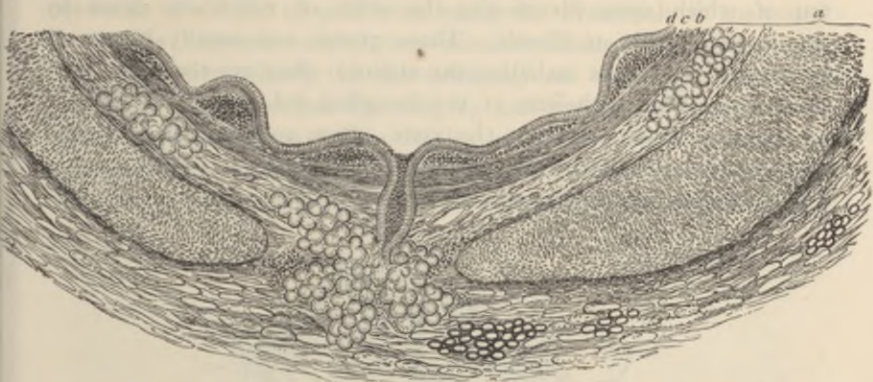


FIG. 196.—PORTION OF A TRANSVERSE SECTION OF A BRONCHIAL TUBE, HUMAN, 6 MM. IN DIAMETER. (F. E. Schultze.) (Magnified 30 diameters.)

a, cartilage and fibrous layer with mucous glands, and, in the outer part, a little fat; in the middle, the duct of a gland opens on the inner surface of the tube; *b*, annular layer of involuntary muscular fibres; *c*, elastic layer, the elastic fibres in bundles which are seen cut across; *d*, columnar ciliated epithelium.

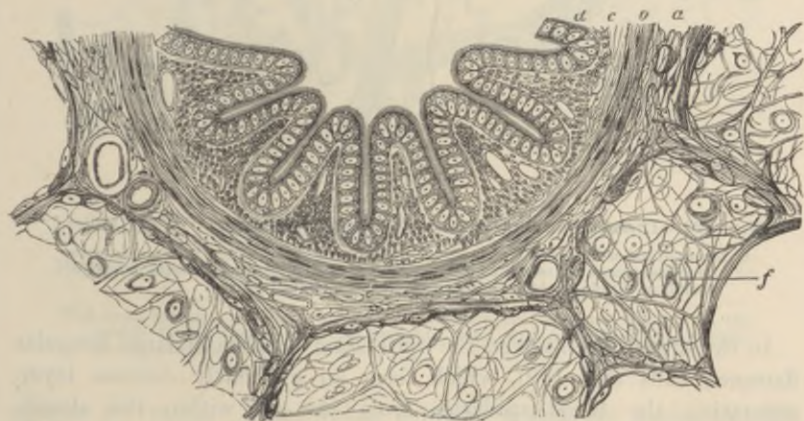

FIG. 197.—SECTION OF A SMALL BRONCHIAL TUBE FROM THE PIG'S LUNG. (F. E. Schultze.) (This section is much more magnified than that represented in the previous figure.)

a, fibrous layer; *b*, muscular layer; *c*, mucous membrane in longitudinal folds, with numerous longitudinally running elastic fibres cut across; *d*, ciliated epithelium; *f*, adjacent alveoli.

in the larger tubes (fig. 196), small plates of cartilage are embedded. Mucous glands are also present in this tissue.

The smallest bronchial tubes, which are about to expand into the infundibula, gradually lose the distinctiveness of the several layers,

their wall at the same time being thinned out. These smallest bronchial tubes open into dilatations (termed *atria* by Miller, fig. 198, A), out of which open diverticula, the sides of which are beset by groups of air-cells or alveoli. These groups are usually known as *infundibula* (this term including the atrium); they are termed air-sacs by Miller. The epithelium of the bronchial tubes becomes changed as they are traced towards the atria; from columnar and ciliated it becomes cubical and non-ciliated. Some air-cells open directly into the terminal bronchi and atria.

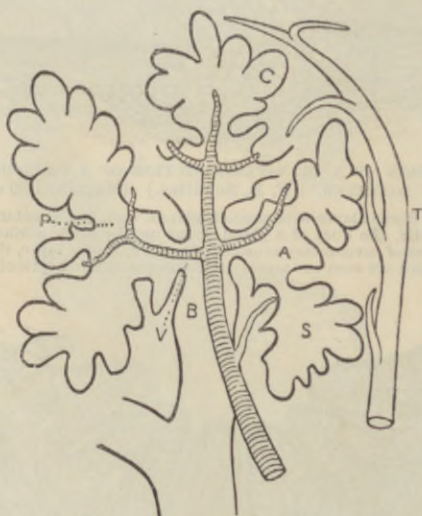


FIG. 198.—DIAGRAM OF THE ENDING OF A BRONCHIAL TUBE. (W. S. Miller.)

B, termination of bronchial tube; v, vestibule by means of which it communicates with the atria, A; s, cavity communicating with atrium and beset with alveoli, c; p, ending of pulmonary arteriole; t, commencement of vein.

In the **alveoli** themselves, the epithelium consists of large irregular flattened cells (fig. 199), which form an extremely delicate layer, separating the blood-capillaries from the air within the alveoli. Amongst the flattened cells are here and there groups of smaller and thicker (cubical) epithelium-cells. The capillary network of the alveoli is very close (fig. 200), and the capillary vessels of adjoining alveoli are in complete continuity, the vessels passing first to one side and then to the other of the septa which separate the adjacent alveoli.

Blood-vessels.—Branches of the pulmonary artery accompany the bronchial tubes to be distributed to the capillary networks upon the alveoli, from which the blood is returned by the pulmonary veins.

An arteriole runs with each lobular bronchiole, and, dividing into as many branches as there are atria, is distributed to the capillary networks of all the air-cells with which the bronchiole is connected. From this network one or two venules collect the blood, usually coursing (independently of the arteriole) on the outer border of the group of air-sacs (see fig. 198, T), and unite with other venules to form efferent veins. The venules of the superficial lobules are connected with a vascular network at the surface of the lung underneath the pleura: this network is also connected with the bronchial

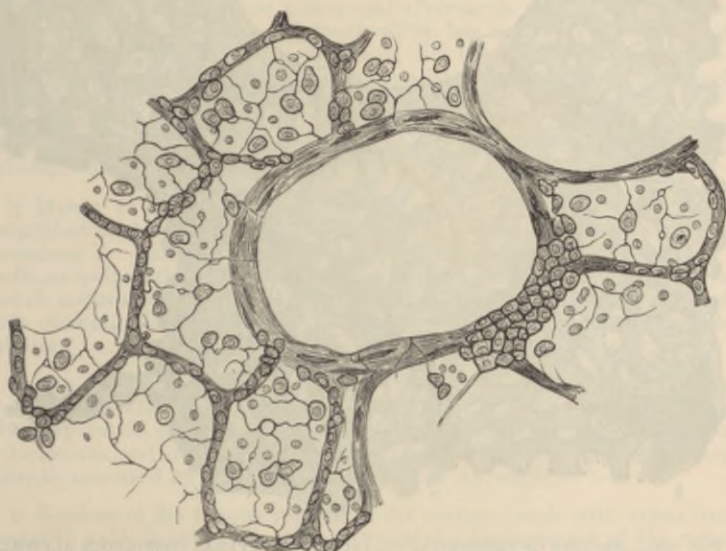


FIG. 199.—SECTION OF PART OF CAT'S LUNG, STAINED WITH NITRATE OF SILVER. (Klein.) (Highly magnified.)

The small granular and the large flattened cells of the alveoli are shown. In the middle is a section of a lobular bronchial tube, with a patch of the granular pavement-epithelium cells on one side.

system of vessels. These veins, pursuing a separate course through the tissue of the lung, join in their course with others to form larger vessels which pass to the root of the lung. Branches from the bronchial arteries are distributed to the walls of the bronchial tubes, and to the connective tissue of the lung. The bronchial veins at first accompany the bronchial arteries, but most of the blood brought to the lungs by the bronchial arteries is returned by the pulmonary veins. Connective tissue intervenes everywhere in small quantity between the infundibula (interstitial tissue), and forms a distinct layer, containing much elastic tissue, covering the surface of

the lung underneath the serous membrane (subserous tissue). In some animals (*e.g.* guinea-pig) the subserous layer contains plain muscular tissue, which is especially developed near the lung-apex; it has not been detected in man.

The **lymphatics** of the lung accompany the bronchial tubes, the branches of the pulmonary artery, and the branches of the pulmonary vein; and they also form a network in the subserous tissue. All

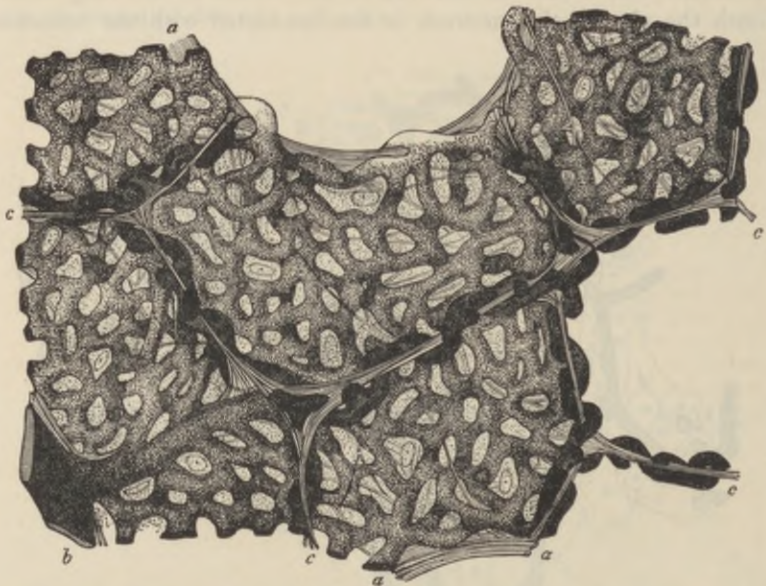


FIG. 200.—SECTION OF INJECTED LUNG, INCLUDING SEVERAL CONTIGUOUS ALVEOLI. (F. E. Schultze.) (Highly magnified.)

a, a, free edges of alveoli; *c, c*, partitions between neighbouring alveoli, seen in section; *b*, small arterial branch giving off capillaries to the alveoli. The looping of the vessels to either side of the partitions is well exhibited. Between the capillaries is seen the homogeneous alveolar wall with nuclei of connective-tissue corpuscles and elastic fibres.

the lymphatics tend towards the hilum, and enter lymphatic glands at the root of the lung. Those in the subserous tissue have been said to communicate, by means of stomata between the epithelial cells of the serous membrane, with the cavity of the pleura, but this connection is denied by Miller.

The **pleura**, which covers the surface of the lung, has the usual structure of a serous membrane. It is provided with a special network of blood-vessels, which is supplied from the pulmonary veins of the superficial lobules, and is also connected, as already noticed, with the bronchial system of vessels.

LESSON XXIX.

STRUCTURE OF THE TEETH, THE TONGUE, AND MUCOUS MEMBRANE OF THE MOUTH.

1. STUDY first with the low power and afterwards with the high power a longitudinal section of a human tooth which has been prepared by grinding. It is better to purchase this specimen, for the process of preparation is difficult and tedious without the aid of special apparatus. Examine carefully the enamel, the dentine, and the cement. The dark appearance of the dentinal tubules is due to their containing air in the dried specimen. Measure the diameter of the enamel prisms and of some of the dentinal tubules. Make sketches from each of the tissues.

2. Mount in xylol balsam a section of a tooth, *in situ*, which has been decalcified in chromic acid or phloroglucin and nitric acid,¹ and stained with hæmalum or carmalum. In this section the mode of implantation of a tooth, as well as the structure of the pulp, can be made out. Make a general sketch under a low power, and under a high power draw a small piece of the pulp showing the processes of the odontoblasts extending into the dentinal tubules.

3. The development of the teeth and the formation of their tissues are studied in sections made across the snout and lower jaw of fœtal animals. The preparation should be stained in bulk with alcoholic magenta, carmalum or hæmalum, and embedded in paraffin or celloidin; if the former, the sections must be mounted by an adhesive process (see Appendix).

4. Sections of the tongue vertical to the surface; stain with carmalum and mount in xylol balsam. In these sections the arrangement of the muscular fibres and the structure of the papillæ of the mucous membrane may be studied; and if the organ have been previously injected, the arrangement of the blood-vessels in the muscular tissue and in the mucous membrane will also be well seen.

THE TEETH.

A **tooth** consists in man of three calcified tissues: the *enamel*, which is of epithelial origin, the *dentine*, and the *cement*, or *crusta petrosa*. The dentine forms the main substance of a tooth, the enamel covers the crown, and the cement is a layer of bone which invests the root (fig. 201).

The **enamel** is formed of elongated hexagonal *prisms* (fig. 202), which are set vertically, or with a slight curvature, upon the surface of the dentine. They are marked at tolerably regular intervals with

¹See *Course of Practical Histology*.

slight transverse shadings producing an indistinct cross-striated appearance. Sometimes coloured lines run through the enamel across the direction of its prisms. The enamel prisms have when first laid down

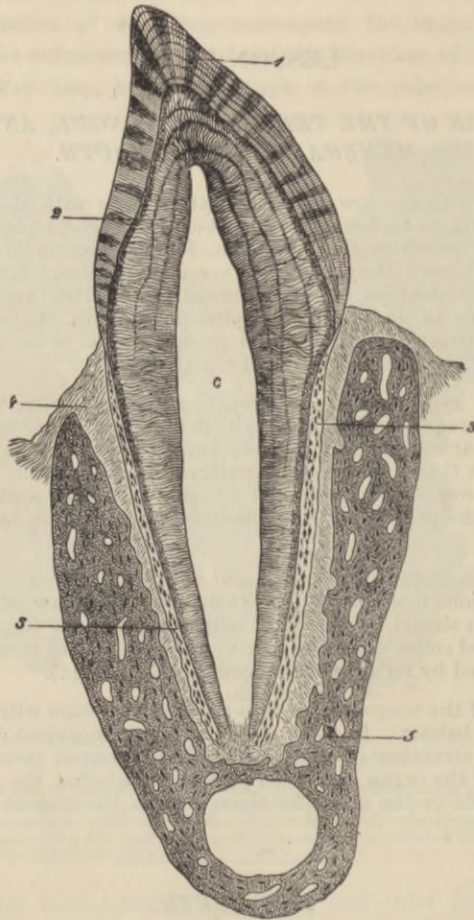


FIG. 201.—VERTICAL SECTION OF A TOOTH IN SITU. (15 diameters.) (Waldeyer.)

c, is placed in the pulp-cavity, opposite the cervix or neck of the tooth; the part above is the crown, that below is the root (fang). *1*, enamel with radial and concentric markings; *2*, dentine with tubules and incremental lines; *3*, cement or crusta petrosa, with bone-corpuscles; *4*, dental periosteum; *5*, bone of lower jaw.

a fibrous structure (fig. 209), but this becomes almost entirely obscured after their calcification is complete. C. Tomes has shown that the enamel of the fully-formed tooth contains only an extremely minute proportion of animal matter: practically it is wholly composed of earthy matter (lime salts).

The **dentine** is composed of a hard dense substance like bone, but containing no Haversian canals or lacunæ. It is pierced everywhere, however, by fine canaliculi (*dentinal tubules*, figs. 203, 204), radiating outwards from a central cavity which, during life, contains the pulp. The tubules branch at acute angles as they pass outwards; their branches become gradually finer towards the periphery of the dentine.

The tubules have a proper wall of their own, which can be isolated by steeping a section of tooth in strong hydrochloric acid. In the living tooth they are occupied by protoplasmic fibres, which are prolonged from the superficial cells of the pulp.

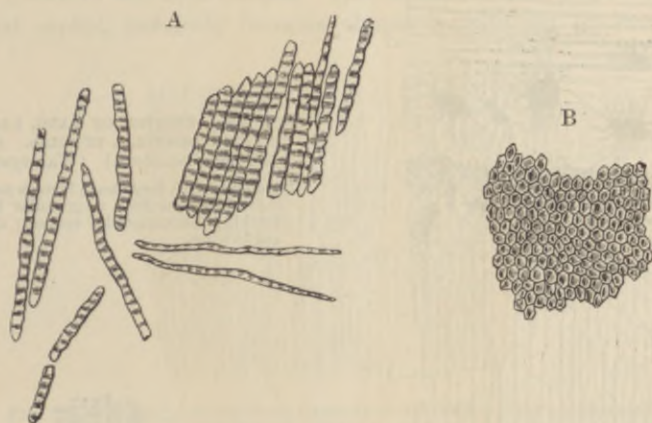


FIG. 202.—ENAMEL PRISMS. (350 diameters.) (Kölliker.)

A, Fragments and single fibres of the enamel, isolated by the action of hydrochloric acid.
B, Surface of a small fragment of enamel, showing the hexagonal ends of the fibres.

The intertubular substance appears for the most part homogeneous, but here and there indications can be seen in it of a globular formation. This is especially the case near the surface of the dentine, where the globular deposit and the interglobular spaces may produce a granular appearance (*granular layer*, fig. 203, 2), and also in the course of certain lines or clefts which are seen traversing the dentine across the direction of the tubules (*incremental lines*, fig. 201, shown magnified in fig. 205). The dentine can be separated into lamellæ along these incremental lines.

The animal matter of dentine resembles bone and the connective tissues generally in having its ground-substance pervaded by fibres which yield gelatine on boiling. These fibres, which have been especially investigated by v. Ebner and by Mummery, are difficult of demonstration in the fully calcified dentine; but in developing

dentine and in dentine which is attacked by caries they are more easily shown.

The **pulp** (fig. 206, *p*) consists of a soft, somewhat jelly-like, connective tissue, containing many branched cells, a network of blood-vessels, and some nerve-fibres which pass into the pulp-cavity along with the blood-vessels by a minute canal at the apex of the fang. The superficial cells of the pulp form an almost continuous layer, like an epithelium. They are known as *odontoblasts*, from having been concerned in the formation of the dentine.

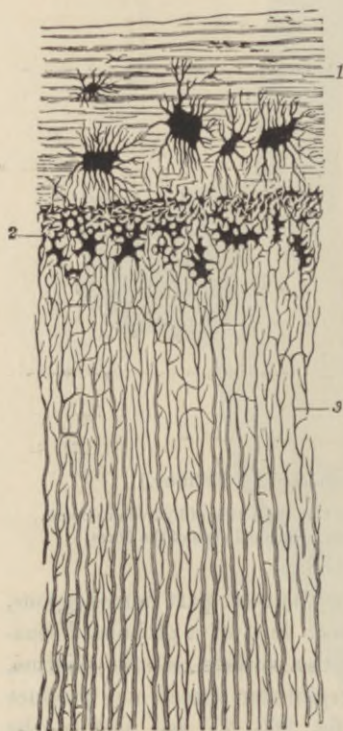


FIG. 203.—SECTION OF FANG, PARALLEL TO THE DENTINAL TUBULES. (Magnified 300 diameters.) (Waldeyer.)

1, cement, with large bone lacunæ and indications of lamellæ; 2, granular layer of Purkinje (interglobular spaces); 3, dentinal tubules.

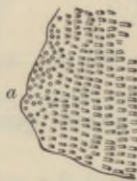

FIG. 204.—SECTIONS OF DENTINAL TUBULES. (Fraenckel.)

a, cut across; *b*, cut obliquely. (About 300 diameters.)

The **crusta petrosa** (fig. 203, 1) is a layer of lamellated bone including lacunæ and canaliculi, but without Haversian canals, at least normally in the human teeth. It is covered with periosteum (*dental periosteum*), which also lines the socket, and serves to fix the tooth securely.

Formation of the teeth.—The teeth are developed in the same manner as the hairs. A continuous thickening of the epithelium occurs along the line of the gums, and grows into the corium of the

mucous membrane (*common dental germ*, or, *dental lamina*, fig. 207, A). At regular intervals there is yet a further thickening and growth from the common germ into the tissue of the mucous membrane, each of these special rudiments, which are ten in number, swelling out below into a flask-shaped mass of cells, the *special dental germ* (fig. 207, B) of a milk tooth. The intermediate parts of the dental lamina long remain, forming a common epithelial strand uniting the several special dental germs to one another and to the epithelium covering the gum (fig. 207, F). A vascular *papilla* is continued from the corium into the bottom of each special germ (fig. 207, C, D); this papilla has the shape of the crown of the future tooth. Each special dental germ, with its included papilla, presently becomes almost entirely cut off from the

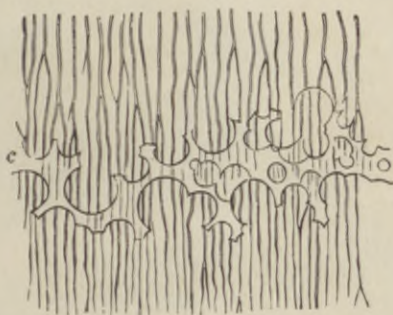


FIG. 205.—A SMALL PORTION OF DENTINE WITH INTERGLOBULAR SPACES.
(Kölliker.) (350 diameters.)

c, portion of incremental line formed by the interglobular spaces, which are here filled up by a transparent material.

epithelium of the mouth, and surrounded by a vascular membrane—the *dental sac*. The papilla becomes transformed into the dentine and pulp of the future tooth, and the enamel is deposited upon its surface by the epithelial cells of the dental germ. The root of the tooth, with its covering of cement, is formed at a later period, when the tooth is beginning to grow up through the gum by a gradual elongation of the base of the papilla. The shaping of this into the form of the root is determined by a growth of the epithelium of the dental germ, which extends in the form of a fold (the *epithelial sheath* of v. Brunn) towards the future apex of each fang.

Previously to the deposition of the enamel, the dental germ undergoes a peculiar transformation of its previously polyhedral epithelium-cells into three layers of modified cells. One of these is a layer of columnar cells (*adamantoblasts*, or *ameloblasts*, fig. 208, d), immediately covering the surface of the dentine. These columnar cells form the

enamel-prisms by a fibrous formation (fig. 209), followed by a deposition of calcareous salts external to the cells (or, as some hold, by a direct calcification of their protoplasm). The cells next to the dental sac form a single layer of cubical epithelium (fig. 208, *e*), and nearly all the other cells of the dental germ become transformed into branching corpuscles (*c*) communicating by their processes, and thus forming a continuous network. This part of the dental germ, after it is thus modified, is known as the *enamel organ*.

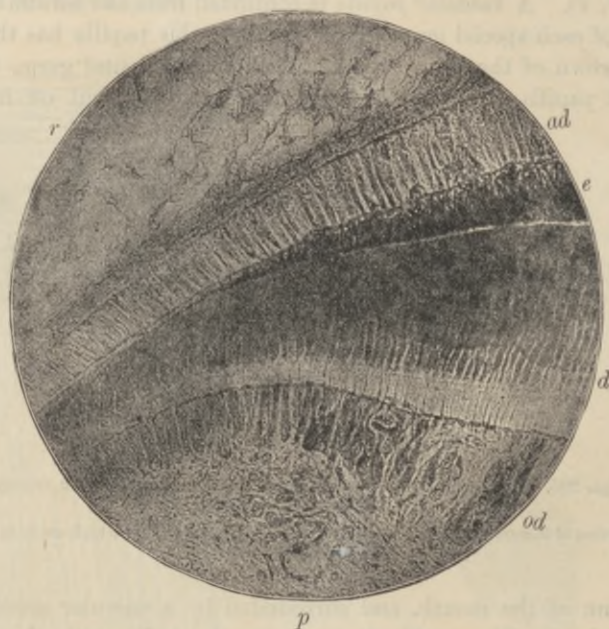

FIG. 206.—SECTION OF PART OF A DEVELOPING TOOTH. (From a photograph by Leon Williams.)

d, dentine; *od*, odontoblasts sending their processes into the dentine tubules; *p*, branched cells of the pulp; *e*, developing enamel; *ad*, adamantoblasts; *r*, reticulum or spongework of the enamel organ.

The *dentine* of the tooth is formed by calcification of the surface of the papilla. At this surface there is a well-marked layer of odontoblasts (fig. 210, *c*), and these produce a layer of dentinal matrix which forms a sort of cap to the papilla, and which soon becomes calcified by the deposition of globules of calcareous matter. Processes of the odontoblasts remain in the dentine as it is forming, and thus the dentinal tubules are produced. Subsequently other layers of dentine are formed within the first by a repetition of the same process, and in this way the papilla gradually becomes calcified. A part, however,

remains unaltered in the centre of the tooth, and with its covering of odontoblasts forms the pulp.

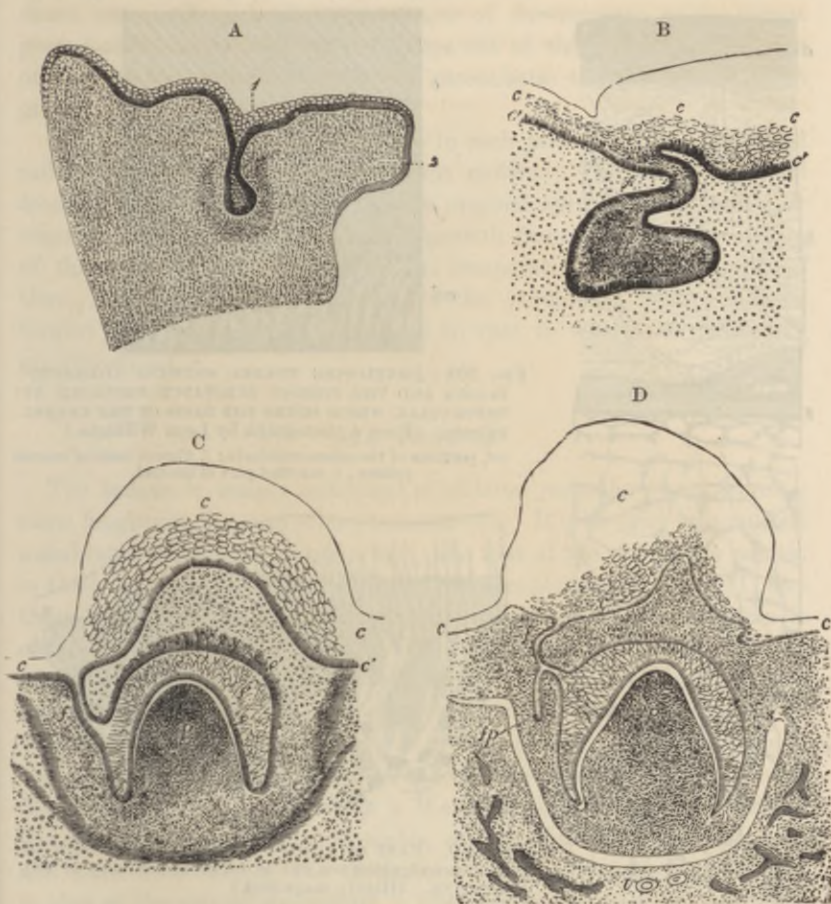


FIG. 207.

A. SECTION ACROSS THE UPPER JAW OF A FETAL SHEEP, 3 CENTIMETRES LONG.
(Waldeyer.)

1, common dental lamina dipping down into the mucous membrane where it is half surrounded by a horseshoe-shaped more dense-looking tissue, the germ of the dentine and dental sac; 2, palatine process of the maxilla.

B. SECTION SIMILAR TO THAT SHOWN IN THE PREVIOUS FIGURE, BUT PASSING THROUGH ONE OF THE SPECIAL DENTAL GERMS HERE BECOMING FLASK-SHAPED. (Kölliker.)

e, e', epithelium of mouth; *f*, neck; *f'*, body of special dental germ.

C AND D. SECTIONS AT LATER STAGES THAN A AND B, THE PAPILLA HAVING BECOME FORMED AND HAVING INDENTED THE DENTAL GERM, WHICH HAS AT THE SAME TIME GROWN PARTLY ROUND IT. (Kölliker.)

e, epithelium of gum, sketched in outline; *f*, neck of dental germ; *f'*, enamel-organ; *e*, its deeper columnar cells; *e'*, projections into the corium; *p*, papilla; *s*, dental sac forming. In D, the dental germ (*f**p*) of the corresponding permanent tooth is seen.

The ten milk-teeth are formed in each jaw in this manner. These, however, become lost within a few years after birth, and are replaced



FIG. 208.—A SECTION THROUGH THE ENAMEL ORGAN AND DENTAL SAC FROM THE TOOTH OF A CHILD AT BIRTH. (250 diameters.) (Kölliker.)

a, outer dense layer of the dental sac; *b*, inner looser texture of the same with capillary blood-vessels and a somewhat denser layer towards the enamel organ; *c*, spongy substance; *d*, inner cells (adamantoblasts); and *e*, outer cellular layer of the enamel organ.



FIG. 209.—DEVELOPING ENAMEL SHOWING ADAMANTOBLASTS AND THE FIBROUS SUBSTANCE PRODUCED BY THESE CELLS, WHICH FORMS THE BASIS OF THE ENAMEL PRISMS. (From a photograph by Leon Williams.)

ad, portions of the adamantoblasts; *f*, fibrous basis of enamel prisms; *e*, calcified part of enamel.

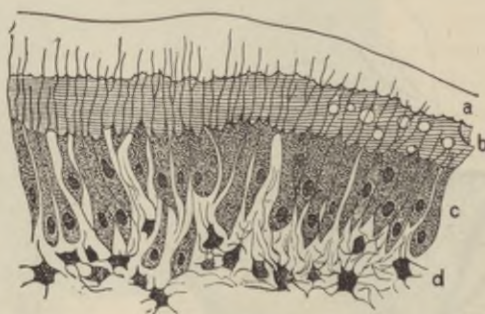


FIG. 210.—PART OF SECTION OF DEVELOPING TOOTH OF YOUNG RAT, SHOWING THE MODE OF DEPOSITION OF THE DENTINE. (Highly magnified.)

a, outer layer of fully calcified dentine; *b*, uncalcified matrix, with a few nodules of calcareous matter; *c*, odontoblasts with processes extending into the dentine; *d*, pulp. The section is stained with carmine, which colours the uncalcified matrix, but not the calcified part.

by permanent teeth in much the same way that a new succession of hairs occurs. A small outgrowth takes place at an early period from the dental germ of each of the milk-teeth (fig. 207, D, *fp*), and this

eventually becomes the germ of the corresponding permanent tooth. It gradually enlarges, acquires a papilla, forms an enamel organ: in short, passes through the same phases of development as its parent germ; and when the milk-tooth drops out of the jaw in consequence of the absorption of its roots (by osteoclasts) the permanent tooth grows up into its place.

But there are six permanent teeth in each jaw which do not succeed milk-teeth; these are the permanent molars. They are developed from an extension backwards of the original epithelial thickening or common dental germ and the downgrowth from this into the corium of three successive special germs at comparatively long intervals of time. Within these the tissues of the permanent molars become formed in a manner exactly similar to that in which the milk-teeth are developed.

THE TONGUE.

The **tongue** is mainly composed of striated muscular fibres, running some longitudinally, and others transversely. It is covered by a mucous membrane, the epithelium of which, like that of the rest of the mouth, is thick and stratified, and conceals microscopic papillæ (fig. 211) like those of the skin. Besides these, the upper surface of the organ is covered with larger papillæ, which give it a rough appearance. These, which are termed the *lingual papillæ*, are of three kinds: (1) About twelve or thirteen comparatively large circular projections, each of which is surrounded by a narrow groove (fossa), external to which the mucous membrane is raised above the general level (vallum) (fig. 212). These papillæ form a V-shaped line towards the back of the tongue; they receive filaments of the glosso-pharyngeal nerve, and have taste-buds in the epithelium which covers their sides, and in that of the side of the vallum. They are known as the *circumvallate papillæ*. (2) All the rest of the papillary surface of the tongue is covered by *conical papillæ*, so named from the conical pointed cap of epithelium which is borne by each; sometimes this cap is fringed with fine epithelial filaments, when they are termed *filiform* (fig. 213). (3) Scattered here and there amongst the conical papillæ are other larger papillæ, the *fungiform* (fig. 214). These are very vascular, and lie partly embedded in little depressions of the mucous membrane.

Small tubular glands may be seen between the superficial muscular fibres sending their ducts to the surface. Most of them secrete mucus, but those which open into the trenches of the circumvallate papillæ, and a few others elsewhere, yield a serous secretion (*glands of Ebner*).



FIG. 211.—SECTION OF MUCOUS MEMBRANE OF MOUTH, SHOWING THREE MICROSCOPIC PAPILLÆ AND STRATIFIED EPITHELIUM. THE BLOOD-VESSELS HAVE BEEN INJECTED. (Toldt.)

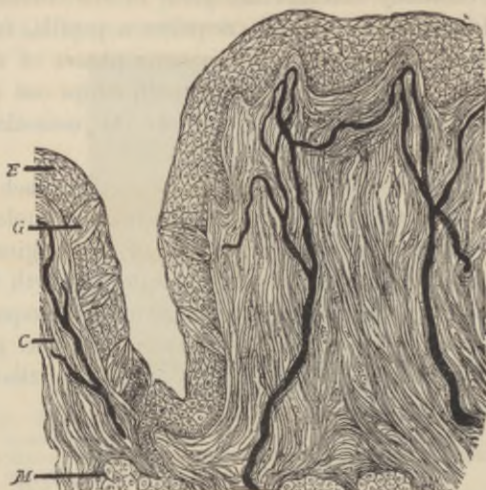


FIG. 212.—SECTION OF CIRCUMVALLATE PAPILLA, HUMAN. THE FIGURE INCLUDES ONE SIDE OF THE PAPILLA AND THE ADJOINING PART OF THE VALLUM. (Magnified 150 diameters.) (Heitzmann.)

E, epithelium; *G*, taste-bud; *C*, corium with injected blood-vessels; *M*, gland with duct.

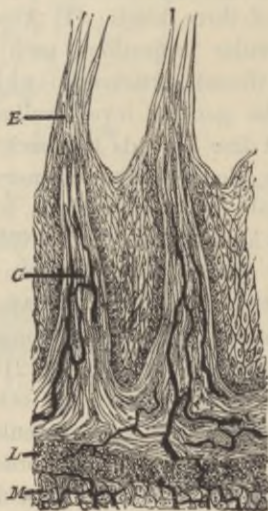

FIG. 213.—SECTION OF TWO FILIFORM PAPILLÆ, HUMAN. (Heitzmann.)

E, epithelium; *C*, corium; *L*, lymphoid tissue; *M*, muscular fibres of tongue.

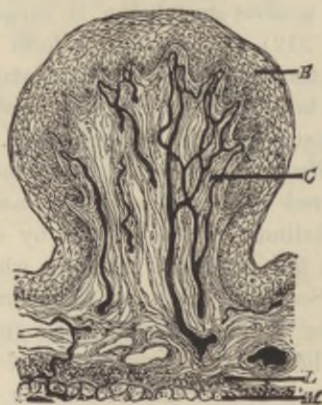

FIG. 214.—SECTION OF FUNGIFORM PAPILLA, HUMAN. (Heitzmann.) (Letters as in previous figure.)

The mucous membrane at the back of the tongue contains a large amount of lymphoid tissue.

The **taste-buds**.—The minute gustatory organs which are known as *taste-buds* may be seen in sections which pass through the papillæ

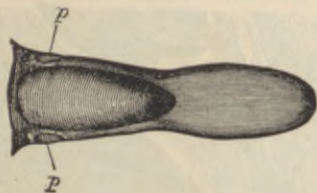


FIG. 215.—TONGUE OF RABBIT, SHOWING THE SITUATION OF THE PAPILLÆ FOLIATÆ, *p*.

vallatæ or the papillæ fungiformes; they are also present here and there in the epithelium of the general mucous membrane of the tongue, especially at the back and sides, and occur also upon the under surface of the soft palate, and on the epiglottis. But they are most easily studied in the papillæ foliatæ of the rabbit, two small oval areas

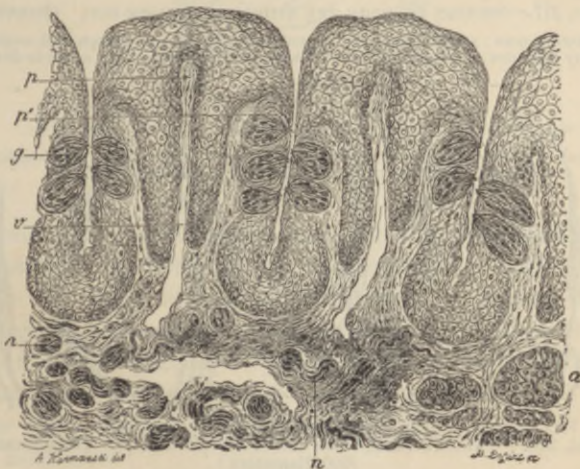


FIG. 216.—VERTICAL SECTION OF PAPILLA FOLIATA OF THE RABBIT, PASSING ACROSS THE FOLLE. (Ranvier.)

p, central lamina of the corium; *v*, section across a vein, which traverses the whole length of the folia; *p'*, lateral lamina in which the nerve-fibres run; *g*, taste-bud; *n*, sections of nerve-bundles; *a*, serous gland.

lying on either side of the back of the tongue and marked transversely with a number of small ridges or laminae with intervening furrows (see figs. 215 and 216). Sections across the ridges show

numerous taste-buds embedded in the thick epithelium which clothes their sides.

The taste-buds are ovoid clusters of epithelium-cells which lie in cavities in the stratified epithelium (fig. 217). The base of the

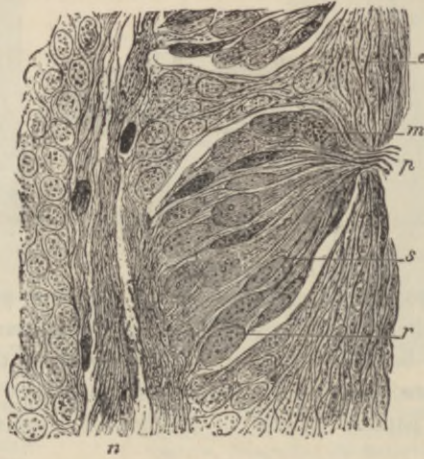

FIG. 217.—SECTION THROUGH THE MIDDLE OF A TASTE-BUD. (Ranvier.)

p, gustatory pore; *s*, gustatory cell; *r*, sustentacular cell; *m*, lymph cell, containing fatty granules; *e*, superficial cells of the stratified epithelium; *n*, nerve-fibres.

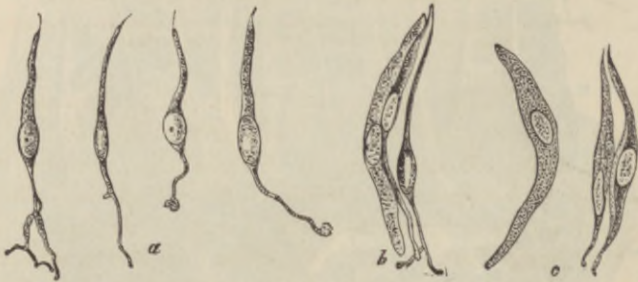

FIG. 218.—VARIOUS CELLS FROM TASTE-BUD OF RABBIT. (Engelmann. (600 diameters.)

a, four gustatory cells from central part; *b*, two sustentacular cells, and one gustatory cell, in connection; *c*, three sustentacular cells.

taste-bud rests upon the corium of the mucous membrane, and receives a branch of the glosso-pharyngeal nerve; the apex is narrow and communicates with the cavity of the mouth by a small pore in the superficial epithelium (*gustatory pore*, fig. 217, *p*).

The cells which compose the taste-buds are of two kinds, viz.:

1. The *gustatory cells* (fig. 218, *a*), which are delicate fusiform or bipolar cells composed of the cell-body or nucleated enlargement, and of two processes, one distal, the other proximal. The distal process is nearly straight, and passes towards the apex of the taste-bud, where it terminates in a small, highly refracting cilium-like appendage, which projects into the bottom of the pore above mentioned. The proximal process is more delicate than the other, and is often branched

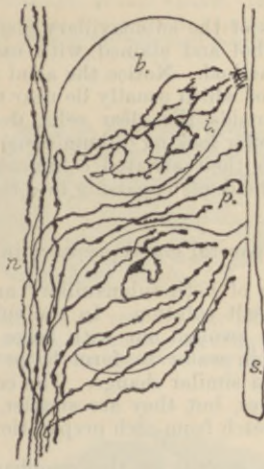


FIG. 219.—NERVE-ENDINGS IN TASTE-BUDS. (G. Retzius.)

n, nerve-fibres of taste-buds; *b*; *i*, ending of fibrils within taste-bud; *p*, ending in epithelium between taste-buds; *s*, surface epithelium.

and varicose. The nerve-fibres take origin in ramifications amongst the gustatory cells (Retzius). 2. The *sustentacular cells* (fig. 218, *c*). These are elongated cells, mostly flattened, and pointed at their ends; they lie between the gustatory cells, which they thus appear to support, and in addition they form a sort of envelope or covering to the taste-bud. Between the cells of the taste-bud lymph-corpuscles are often seen, having probably wandered hither from the subjacent mucous membrane.

LESSON XXX.

THE SALIVARY GLANDS.

1. STUDY carefully sections of the submaxillary gland of a dog. The gland may be hardened in alcohol and stained with carmalum or with hæmatoxylin by Heidenhain's method. Notice the acini filled with clear (mucus-secreting) cells, the nuclei of which usually lie near the basement-membrane. Notice here and there, outside the clear cells, demilunes or crescents of small darkly stained granular-looking (albuminous) cells. Observe also the sections of the ducts with their striated columnar epithelium. Try and find a place where one of the ducts is passing into the alveoli. Sketch under a high power.

2. Study sections of the parotid gland prepared in a similar way.

3. Examine small pieces of both submaxillary and parotid gland of the dog fresh in 2 per cent. salt solution. In the submaxillary gland notice that the alveolar cells are swollen out with large granules or droplets of mucigen, which swell up in water to form large clear vacuoles. Dilute acids and alkalis produce a similar change. The cells of the parotid gland are also filled with granules, but they are smaller, and simply dissolve in watery fluids.¹ Make a sketch from each preparation under a high power.

4. Prepare a transverse section of the œsophagus. Notice the thick muscular coat partly containing cross-striated fibres and the mucous membrane with its papillæ and stratified epithelium. Look for mucous glands in the submucosa. Sketch under a low power.

The **salivary glands** may be looked upon as typical of secreting glands in general. They are composed of a number of *lobules* bound together loosely by connective tissue. Each small lobule is formed of a group of saccular or somewhat tubular *alveoli* or *acini* (fig. 220) from which a duct passes, and this, after uniting with other ducts to form larger and larger tubes, eventually leaves the gland to open upon the surface of the mucous membrane of the mouth.

The alveoli are inclosed by a basement-membrane, which is reticular (fig. 221). This basement-membrane is continued along the ducts. Within it is the epithelium, which in the alveoli is composed of polyhedral cells (fig. 222, *a*), but in the ducts is regularly columnar, except

¹ To study the changes which the alveolar cells undergo during secretion, pilocarpine is injected subcutaneously into an animal in sufficient amount to produce copious salivation; after half an hour the animal is killed and its salivary glands are examined as in preparation 3. The granules are not seen in preparations that have been in alcohol, but osmic acid preserves them moderately well; they are best seen in the fresh tissue.




FIG. 220.—DIAGRAM OF THE CONSTRUCTION OF A LOBULE OF A TUBULO-RACEMOSE (ACINO-TUBULAR) MUCOUS GLAND. (Kölliker.)

a, duct; *b*, a branch of the duct; *c*, alveoli as they lie together in the gland; *d*, the same separated, showing their connection as an irregular tube.

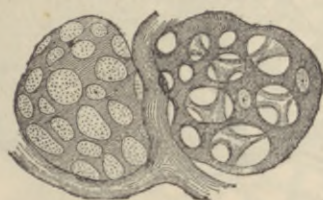

FIG. 221.—MEMBRANA PROPRIA OF TWO ALVEOLI ISOLATED. (R. Heidenhain.)

The preparation is taken from the orbital gland of the dog, which is similar in structure to a mucous salivary gland.

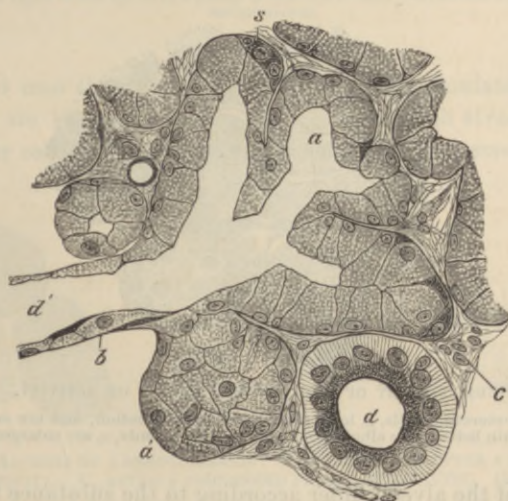


FIG. 222.—SECTION OF THE SUBMAXILLARY GLAND OF THE DOG, SHOWING THE COMMENCEMENT OF A DUCT IN THE ALVEOLI. (Magnified 425 diameters.)

a, one of the alveoli, several of which are in the section shown grouped around the commencement of the duct *d'*; *a'*, an alveolus, not opened by the section; *b*, basement-membrane in section; *c*, interstitial connective tissue of the gland; *d*, section of a duct which has passed away from the alveoli, and is now lined with characteristically striated columnar cells; *s*, semilunar group of darkly stained cells at the periphery of an alveolus.

in that part of the duct which immediately opens into the alveoli (*junctional part*); in this it is flattened (*d'*). The columnar epithelium of the ducts is peculiar, in that the cells show a distinction into two unequal zones, an outer, larger, striated zone, and an inner, smaller, granular one (fig. 222, *d*).

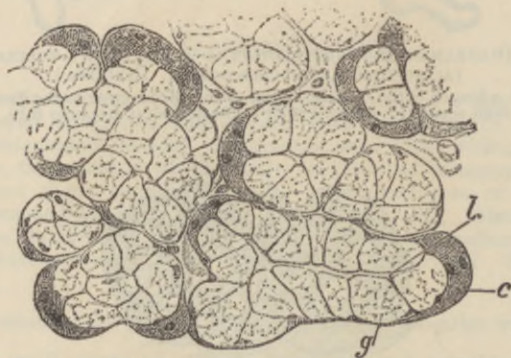


FIG. 223.—SECTION OF A DOG'S SUBMAXILLARY, AFTER A PROLONGED PERIOD OF REST. (Ranvier.)

l, lumen of alveolus; *g*, mucus-secreting cells; *c*, crescent, formed of albuminous cells.

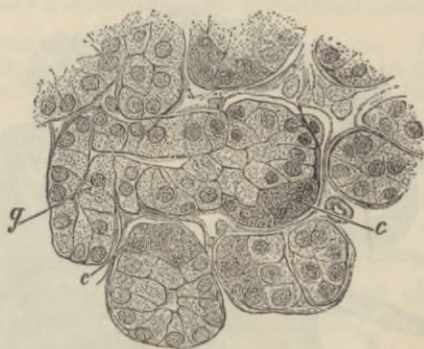

FIG. 224.—SUBMAXILLARY OF DOG, AFTER A PERIOD OF ACTIVITY. (Ranvier.)

The mucus-secreting cells, *g*, have discharged their secretion, and are smaller and stain better; the albuminous cells of the crescents, *c*, are enlarged.

The cells of the alveoli differ according to the substance they secrete. In alveoli which secrete mucus, such as all the alveoli of the dog's submaxillary (fig. 223), and some of the alveoli of the same gland in man (fig. 225), the cells, if examined in normal saline solution or after hardening with alcohol, are clear and swollen. But if examined rapidly in serum, or in solutions of salt of from 2 to 5 per cent.,

they are seen to be occupied by large and distinct granules, formed of a substance which is known as *mucigen* (fig. 227, a). The mucigen is dissolved out of the cell and discharged as *mucus* into the lumen of the

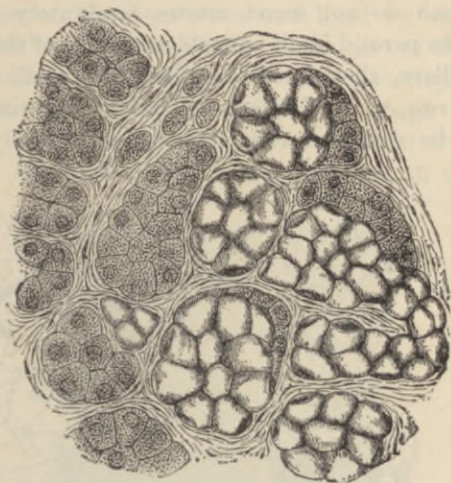


FIG. 225.—SECTION OF PART OF THE HUMAN SUBMAXILLARY GLAND. (Heidenhain.)

To the right of the figure is a group of mucous alveoli; to the left a group of serous alveoli.

alveolus and into the ducts, when the gland is stimulated to activity. These cells are known as *mucous cells*. But in each alveolus there are some smaller cells which do not contain mucigen, but small albuminous

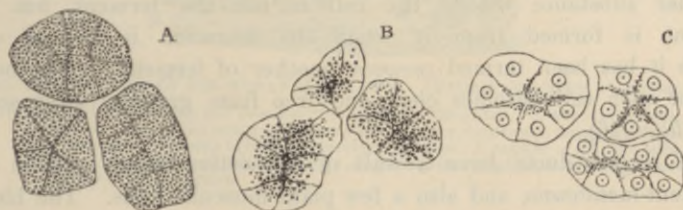


FIG. 226.—ALVEOLI OF A SEROUS GLAND. A, AT REST. B, AFTER A SHORT PERIOD OF ACTIVITY. C, AFTER A PROLONGED PERIOD OF ACTIVITY. (Langley.)

In A and B the nuclei are obscured by the granules of zymogen.

granules, and these generally form crescentic groups which lie next to the basement-membrane (figs. 222, 223). These are the so-called *crescents* of Gianuzzi; their constituent cells are known also as *marginal*

or *albuminous cells*. Special diverticula pass from the lumen of the alveoli between the mucous cells to penetrate to the crescents and to branch amongst their constituent cells; these diverticula are best shown by the Golgi method of staining¹ (fig. 228). In alveoli, on the other hand, which do not secrete mucus, but watery or albuminous saliva, such as the parotid in all animals, and some of the alveoli of the human submaxillary, all the cells are filled with small granules when the gland is at rest, which do not swell with water nor form mucin; they appear to be albuminous in nature, and probably yield to the

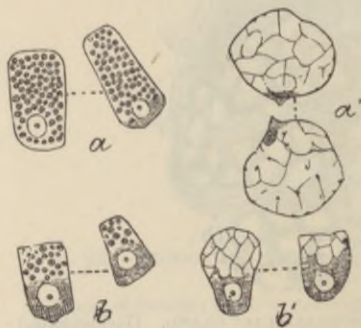


FIG. 227.—MUCOUS CELLS FROM FRESH SUBMAXILLARY GLANDS OF THE DOG. (Langley.)

a, from a resting or loaded gland; *b*, from a gland which has been secreting for some time; *a'*, *b'*, similar cells which have been treated with dilute acid.

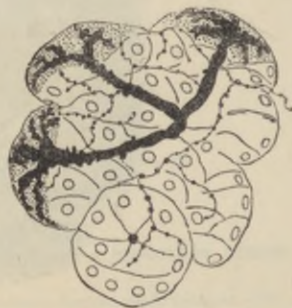

FIG. 228.—ALVEOLI OF THE SUBMAXILLARY GLAND OF THE DOG. (G. Retzius.) Chromate of silver method.

The extensions of the lumen into the crescents of Gianuzzi are shown, and also the endings of the nerve-fibrils.

secretion of the gland its ferment (ptyalin) and its albumin. The granular substance within the cell is not the ferment, but the ferment is formed from it when the secretion is poured out. Hence it has been termed *zymogen* (mother of ferment). The outer part of each cell becomes clear and free from granules after secretion (fig. 226).

The largest ducts have a wall of connective tissue outside the basement-membrane, and also a few plain muscular cells. The blood-vessels of the salivary gland form a capillary network around each alveolus. The lymphatics commence in the form of lacunar vessels encircling the alveoli. The nerve-fibres, which are derived both from the cerebro-spinal nerves and from the sympathetic, have only recently been satisfactorily traced to their termination; they ramify as fine varicose fibrils amongst the alveolar cells (fig. 228).

¹ See Appendix.

THE PHARYNX AND ŒSOPHAGUS.

The **pharynx** is composed of a *fibrous membrane*, which is encircled by striated muscles, the *constrictors*, and lined by *mucous membrane*. The mucous membrane is lined in the upper part of the pharynx and on the upper surface of the soft palate with ciliated epithelium, which is continuous with that of the nostrils, and through the Eustachian tube with that of the tympanum. Below the level of the soft palate the epithelium is stratified like that of the mouth and gullet, into

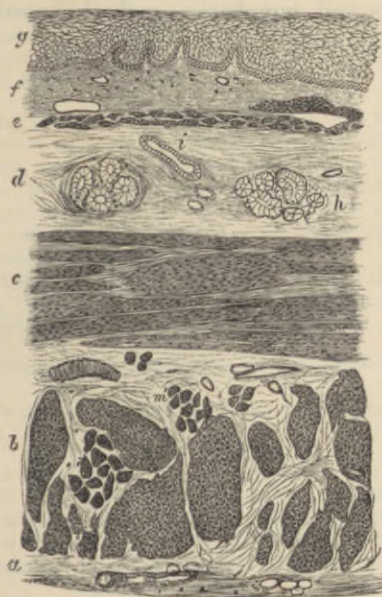


FIG. 229.—SECTION OF THE HUMAN ŒSOPHAGUS. (From a sketch by V. Horsley.)

The section is transverse, and from near the middle of the gullet. *a*, fibrous covering; *b*, divided fibres of the longitudinal muscular coat; *c*, transverse muscular fibres; *d*, submucous or areolar layer; *e*, muscularis mucosæ; *f*, papillæ of mucous membrane; *g*, laminated epithelial lining; *h*, mucous gland; *i*, gland duct; *m*, striated muscular fibres in section.

which it passes. In certain parts the mucous membrane contains a large amount of lymphoid tissue (especially at the back, where it forms a projection which is sometimes termed the pharyngeal tonsil), and there are numerous mucous glands opening on its surface.

The **œsophagus** or gullet, which passes from the pharynx to the stomach, consists, like the pharynx, of a *fibrous covering*, a *muscular coat*, a lining *mucous membrane*, and intervening connective tissue (*submucosa* or *areolar coat*) (fig. 229). The muscular coat is much more

regularly arranged than that of the pharynx, and is composed of striated muscle in about its upper third only, the rest being of the plain variety. There are two layers of the muscular coat—an outer layer, in which the fibres run longitudinally, and an inner, in which they course circularly. The mucous membrane is lined by a stratified epithelium, into which microscopic papillæ from the corium project. The corium is formed of areolar tissue, and its limits are marked externally by a narrow layer of longitudinally disposed plain muscular fibres, the *muscularis mucosæ*. This is separated from the proper muscular coat by the areolar coat, which contains the larger branches of the blood-vessels and lymphatics, and also most of the mucous glands of the membrane.

LESSON XXXI.

THE STRUCTURE OF THE STOMACH.

1. VERTICAL longitudinal sections through the cardia, including the lower end of the œsophagus and the adjacent cardiac portion of the stomach. These are intended to show the abrupt transition of the stratified epithelium of the œsophagus into the columnar epithelium of the stomach, and also the character of the gastric glands in the immediate neighbourhood of the cardia. The tissue may be stained in bulk with carmalum, and the sections passed through picric acid dissolved in alcohol.

2. Sections of the fundus of the dog's stomach, cut perpendicularly to the surface of the mucous membrane. The tissue is stained with hæmalum or carmalum, and eosin, and the sections are mounted in Canada balsam.

In these sections the general arrangement of the coats of the stomach is to be studied, and sketches are to be made under a low power illustrating this arrangement, and others under a high power showing the structure of the glands of the mucous membrane.

Measure the whole thickness of the mucous membrane, the thickness of the muscular coat, the size of the columnar epithelium-cells of the surface, and that of the cells in the deeper parts of the glands.

3. Sections of the mucous membrane of the fundus, cut parallel to the surface.

These sections will show better than the others the arrangement of the cells in the glands.

4. Vertical sections of the mucous membrane from the pyloric region of the dog's stomach. If the section is taken longitudinally through the pylorus, the transition of the gastric glands into the glands of Brunner of the duodenum will be made manifest. Make a sketch under a low power of one of the glands in its whole length, filling up some of the details with the high power.

5. Study the arrangement of the blood-vessels of the stomach in vertical sections of the wall of an organ the vessels of which have been injected.

The wall of the **stomach** consists of four coats, which, enumerated from without in, are as follows, viz.: *serous, muscular, areolar, or sub-mucous, and mucous membrane.*

The *serous coat* is a layer which is derived from the peritoneum. It is deficient only along the lines of the lesser and greater curvatures.

The *muscular coat* consists of three layers of plain muscular fibres. Of these the bundles of the outer layer run longitudinally, those of the middle layer circularly, and those of the inner layer obliquely. The longitudinal and circular bundles become thicker and stronger

towards the pylorus, at which they pass into the corresponding layers of the small intestine; at the pylorus itself the circular layer is greatly thickened to form the *sphincter muscle*. The oblique fibres are only present in the left or cardiac part of the stomach.

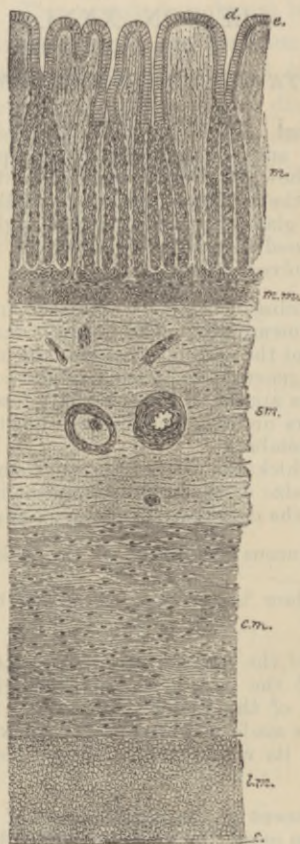

FIG. 230.—DIAGRAM OF SECTION THROUGH THE COATS OF THE STOMACH. (Mall.)

m., mucous membrane; *e.*, epithelium; *d.*, orifice of gland-duct; *m.m.*, muscularis mucosae; *sm.*, submucosa; *c.m.*, circular muscular layer; *l.m.*, longitudinal muscular layer; *s.*, serous coat.

The *areolar* or *submucous coat* is a layer of areolar tissue, which serves to unite the mucous membrane loosely to the muscular coat; in it ramify the larger branches of the blood-vessels and lymphatics.

The *mucous membrane* is a soft thick layer, generally somewhat corrugated in the empty condition of the organ. Its thickness is mainly due to the fact that it is largely made up of long tubular glands, which open upon the inner surface. Between the glands

the mucous membrane is formed of areolar with much lymphoid tissue. Externally it is bounded by the *muscularis mucosæ*, which consists of an external longitudinal and an inner circular layer of plain muscular fibres. The *glands* are formed of a basement-membrane lined with epithelium. Each gland consists of *secreting tubules* from

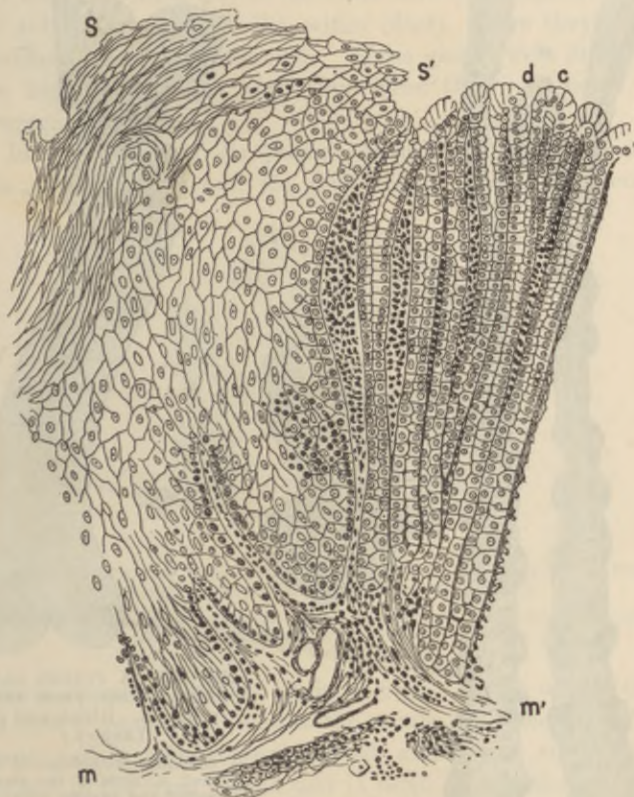

FIG. 231.—SECTION OF THE JUNCTION OF THE OESOPHAGEAL AND GASTRIC MUCOUS MEMBRANE OF THE KANGAROO. (135 diameters.)

S, stratified epithelium continuous with that of oesophagus abruptly discontinued at *s''*; c, columnar epithelium of gastric mucous membrane, continuous with lowermost columnar cells of Malpighian layer of oesophageal epithelium; d, orifices or ducts of cardiac glands; m, corium of oesophageal mucous membrane sending papillæ into the epithelium; *m'*, corium of gastric mucous membrane.

one to four in number, opening at the surface into a larger tube, the *duct* of the gland. The duct is in all cases lined by columnar epithelium of the same character as that which covers the inner surface of the mucous membrane, but the epithelium of the secreting tubules is different from this, and also differs somewhat in the glands

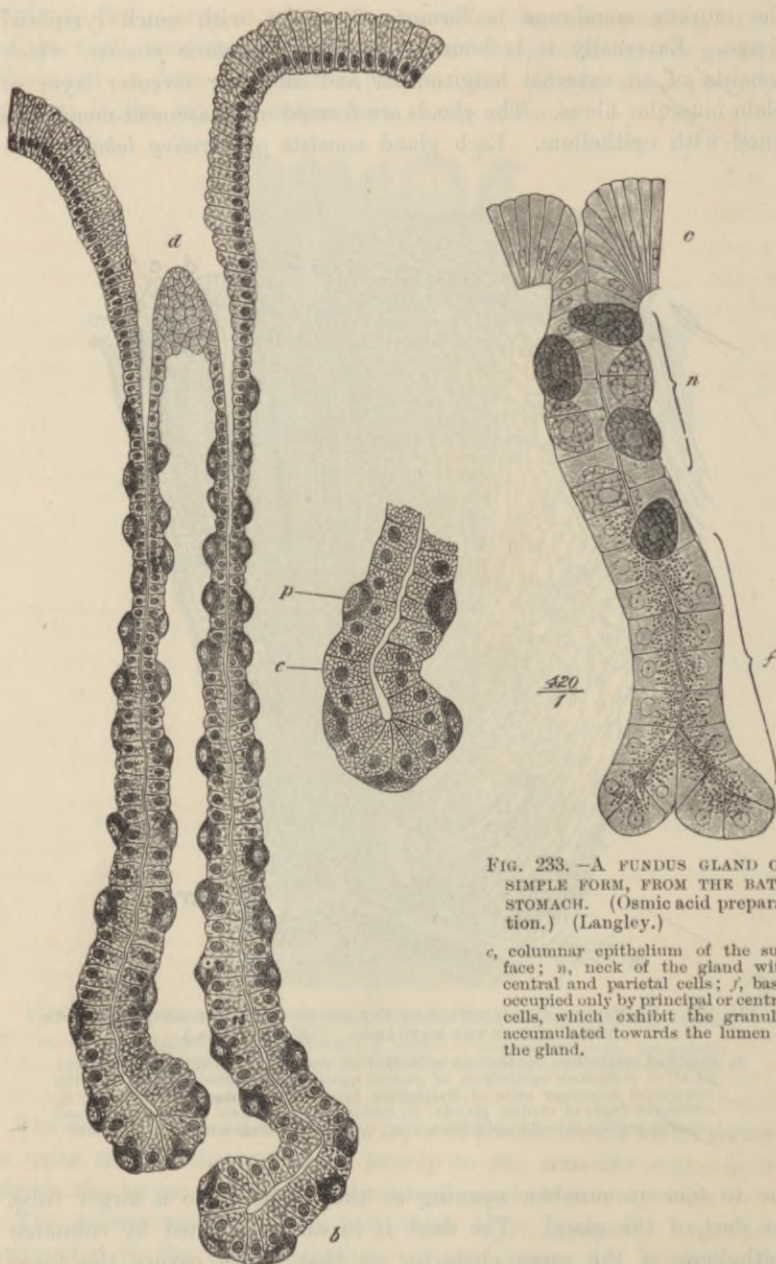


FIG. 232.—A FUNDUS GLAND FROM THE DOG'S STOMACH. (Highly magnified.) (Klein.)

d, duct or mouth of the gland; *b*, base of one of its tubules. On the right the base of a tubule more highly magnified; *c*, central cell; *p*, parietal cell.

FIG. 233.—A FUNDUS GLAND OF SIMPLE FORM, FROM THE BAT'S STOMACH. (Osmic acid preparation.) (Langley.)

c, columnar epithelium of the surface; *n*, neck of the gland with central and parietal cells; *f*, base, occupied only by principal or central cells, which exhibit the granules accumulated towards the lumen of the gland.

of different regions of the organ. The following varieties are met with:—

(1) Close to the œsophageal opening or cardia the glands (glands of the cardia, fig. 231) are long and usually simple. Their secreting tubules are lined by cells which are granular in appearance and of a short columnar form, and of the same nature throughout the length of the tubule, except near the orifice (duct), where they give place to columnar mucus-secreting cells. These glands were first described in the kangaroo.¹ They have since been shown to be of general occurrence.

(2) In the *glands of the fundus* or *oxyntic glands* (fig. 232) the tubules are also long, and the duct short. The epithelium of the

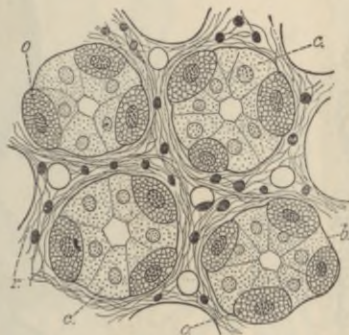

FIG. 234.—SECTION OF THE MUCOUS MEMBRANE OF THE FUNDUS OF THE STOMACH TAKEN ACROSS THE DIRECTION OF THE GLANDS.

b, basement-membrane; *c*, central cells; *o*, parietal cells; *r*, retiform tissue (with sections of blood-capillaries) between the glands.

tubules is composed of two kinds of cells. Those of the one kind, which form a continuous lining to the tubule, are somewhat polyhedral in shape, and in stained sections look clearer and smaller than the others, but in the fresh glands, and in osmic preparations, they appear filled with granules (fig. 233).² These cells are believed to form pepsin, and are termed the *chief cells* of the cardiac glands, or from their relative position in the tubule immediately surrounding the lumen, the *central cells*. Scattered along the tubule, and lying between the chief cells and the basement-membrane, are a number of other spheroidal or ovoidal cells, which become stained by many reagents more darkly than the central cells. These are the *superadded* or

¹ Schäfer and Williams, *Proc. Zool. Soc.* 1876.

² The granules are most numerous at the inner part of the cell, a small outer zone being left clear. After prolonged activity this outer zone increases in size while the granules diminish in number as in the analogous cases of the pancreas and parotid glands (Langley).

parietal cells (*oxyntic cells*¹ of Langley). Each parietal cell is surrounded by a network of fine passages, communicating with the lumen of the gland by a fine canal, which passes between the central cells (fig. 235).

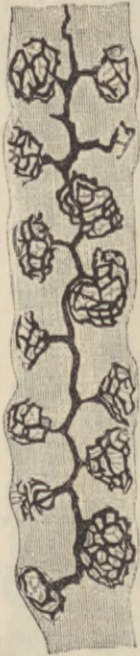


FIG. 235.—A FUNDUS GLAND PREPARED BY GOLGI'S METHOD, SHOWING THE MODE OF COMMUNICATION OF THE PARIETAL CELLS WITH THE GLAND-LUMEN. (E. Müller.)

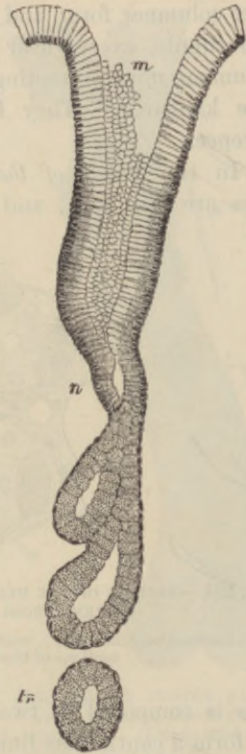

FIG. 236.—A PYLORIC GLAND, FROM A SECTION OF THE DOG'S STOMACH. (Ebstein.)

m, mouth; n, neck; tr, a deep portion of a tubule cut transversely.

(3) In the *pyloric glands* (fig. 236) the *ducts* are much longer than in the fundus glands, and the secreting tubules possess cells of only one kind.² These correspond to the chief cells of the fundus glands. They are of a columnar or cubical shape, and in the fresh condition of a granular appearance, and quite unlike the columnar epithelium-

¹ So called because they are believed to produce the acid of the gastric secretion.

² In man it is only quite near the pylorus that the parietal cells are altogether absent.

cells of the surface, which are long tapering cells, the outer part of which is filled with mucigen.

At the pylorus itself these glands become considerably lengthened and enlarged, and are continued into the submucous tissue, the muscularis mucosæ being here absent; they thus present transitions to the glands of Brunner, which lie in the submucous tissue of the duodenum (fig. 237).

The *blood-vessels* of the stomach are very numerous, and pass to the organ along its curvatures. The arteries pass through the muscular

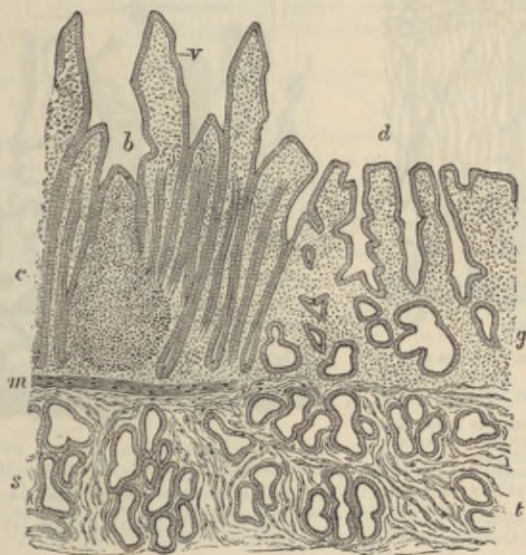


FIG. 237.—SECTION THROUGH THE PYLORUS, INCLUDING THE COMMENCEMENT OF THE DUODENUM. (Klein.)

v, villi of duodenum; b, apex of a lymphoid nodule; c, crypts of Lieberkühn; s, secreting tubules of Brunner's glands; d, ducts of pyloric glands of stomach; g, tubes of these glands in mucous membrane; t, deeper lying tubes in submucosa, corresponding to secreting tubules of Brunner's glands of duodenum; m, muscularis mucosæ.

coat, giving off branches to the capillary network of the muscular tissue, and ramify in the areolar coat. From this, small arteries pierce the muscularis mucosæ, and break up into capillaries near the bases of the glands (fig. 238). The capillary network extends between the glands to the surface, close to which it terminates in a plexus of relatively large venous capillaries which encircle the mouths of the glands. From this plexus straight venous radicles pass through the mucous membrane, pierce the muscularis mucosæ, and join a plexus of veins in the submucous tissue. From these veins blood is carried.

away from the stomach by efferent veins, which accompany the entering arteries.

The *lymphatics* (fig. 239) arise in the mucous membrane by a plexus of large vessels dilated at intervals, and looking in sections like clefts in the interglandular tissue. From this plexus the lymph is carried into large valved vessels in the submucous coat, and from these,

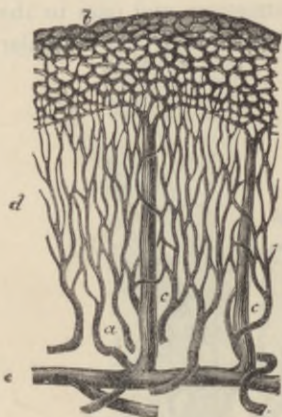


FIG. 238.—PLAN OF THE BLOOD-VESSELS OF THE STOMACH. (Modified from Brinton.)

a, small arteries passing to break up into the fine capillary network, *d*, between the glands; *b*, coarser capillary network around the mouths of the glands; *c*, *c*, veins passing vertically downwards from the superficial network; *e*, larger vessels in the submucosa.



FIG. 239.—LYMPHATICS OF THE HUMAN GASTRIC MUCOUS MEMBRANE, INJECTED. (C. Lovén.)

The tubules are only faintly indicated; *a*, muscularis mucosæ; *b*, plexus of fine vessels at base of glands; *c*, plexus of larger valved lymphatics in submucosa.

efferent vessels pass through the muscular coat to reach the serous membrane, underneath which they pass away from the organ. The muscular coat has its own network of lymphatic vessels. These lie between the two principal layers, and their lymph is poured into the efferent lymphatics of the organ.

The nerves have the same arrangement and mode of distribution as those of the small intestine (see next Lesson).

LESSONS XXXII. AND XXXIII.

STRUCTURE OF THE INTESTINE.

LESSON XXXII.

1. SECTIONS of the duodenum and jejunum vertical to the surface. The general arrangement and structure of the intestinal wall is to be studied in these sections.

Make a general sketch under the low power and carefully sketch part of a villus under the high power.

2. Sections parallel to the surface of the intestine, and therefore across the long axis of the villi and glands of the mucous membrane. In order to keep the sections of the villi together so that they are not lost in the mounting, it is necessary either to embed in celloidin or, if paraffin be used, to employ an adhesive method of mounting (see Appendix).

In this preparation, sketch the transverse section of a villus and of some of the crypts of Lieberkühn.

3. Transverse vertical sections of the ileum passing through a Peyer's patch. Observe the nodules of lymphoid tissue which constitute the patch and which extend into the submucous tissue. Observe the lymphoid cells in the superjacent columnar epithelium. Notice also the sinus-like lymphatic or lacteal vessel which encircles the base of each nodule. Make a general sketch under a low power.

4. To study the process of fat-absorption, kill a rat three or four hours after feeding it with a little fat, or a frog two or three days after feeding with lard. Put a very small shred of the mucous membrane of the intestine into osmic acid (0.5 per cent.) and another piece into a mixture of 2 parts Müller's fluid and 1 part osmic acid solution (1 per cent.). After forty-eight hours teased preparations may be made from the osmic acid preparation, in the same manner as directed in Lesson VII., § 2; the rest may be then placed in 70 per cent. alcohol. The piece in Müller and osmic acid may be left for ten days or more in the fluid. When hardened, the pieces of tissue are soaked in gum, and sections made with a freezing microtome and mounted in glycerine. The sections should not be passed through any fluid which dissolves fat.

LESSON XXXIII.

1. SECTIONS of small intestine the blood-vessels of which have been injected. Notice the arrangement of the vessels in the several layers. Sketch carefully the vascular network of a villus.

2 From a piece of intestine which has been stained with chloride of gold¹ tear off broad strips of the longitudinal muscular coat, and mount them in glycerine. It will generally be found that portions of the nervous plexus of

¹ See Appendix.

Auerbach remain adherent to the strips, and the plexus can in this way easily be studied.

From the remainder of the piece of intestine tear off with forceps the fibres of the circular muscular layer on the one side, and the mucous membrane on the other side, so as to leave only the submucous tissue and the muscularis mucosæ. This tissue is also to be mounted flat in glycerine: it contains the plexus of Meissner.

Sketch a small portion of each plexus under a high power.

3. Sections of the large intestine, perpendicular to the surface. These will show the general structure and arrangement of the coats. Sketch under a low power.

4. Sections of the mucous membrane of the large intestine parallel to the surface, and therefore across the glands. Sketch some of the glands and the interglandular tissue under a high power.

5. The arrangement of the blood-vessels of the large intestine may be studied in sections of the injected organ.

THE SMALL INTESTINE.

The wall of the **small intestine** consists, like the stomach, of four coats.

The *serous coat* is complete except over part of the duodenum.

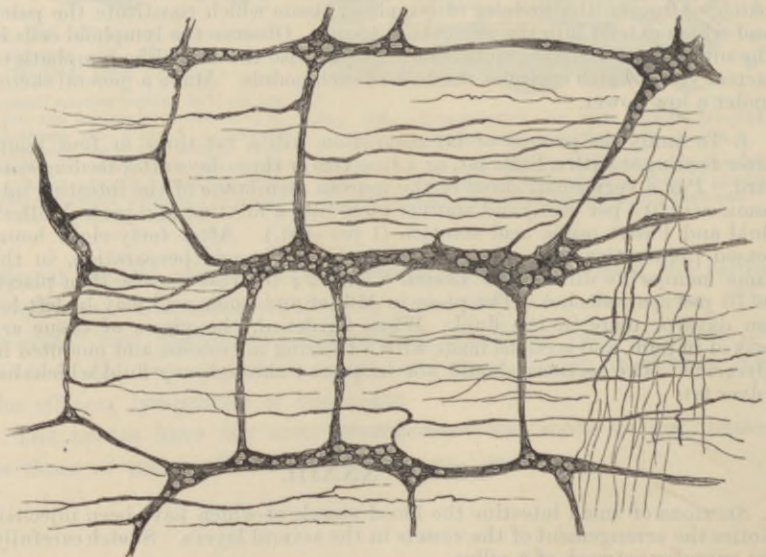


FIG. 240.—PLEXUS OF AUERBACH, BETWEEN THE TWO LAYERS OF THE MUSCULAR COAT OF THE INTESTINE. (Cadiat.)

The *muscular coat* is composed of two layers of muscular tissue, an outer longitudinal and an inner circular. Between them lies a

network of lymphatic vessels and also the close gangliated plexus of non-medullated nerve-fibres known as the *plexus myentericus* of Auerbach. The ganglia of this plexus may usually be seen in vertical sections of the intestinal wall, but the plexus, like the one in the submucous coat immediately to be described, can only be properly displayed in preparations made with chloride of gold (fig. 240) or methylene-blue or by Golgi's method.

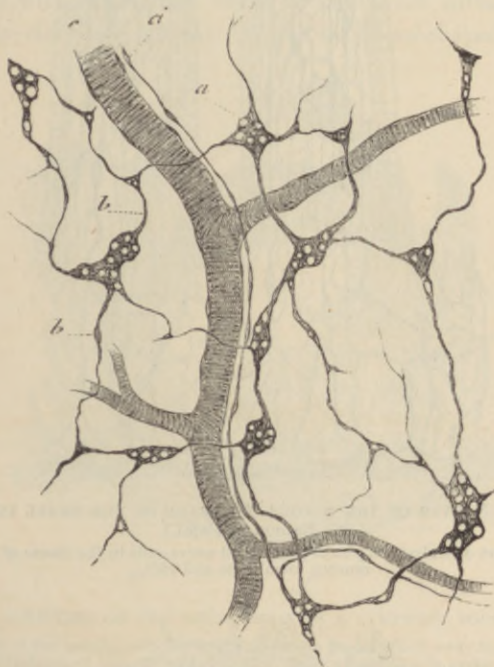


FIG. 241.—PLEXUS OF MEISSNER FROM THE SUBMUCOUS COAT OF THE INTESTINE.
(Cadiat.)

The *submucous coat* is like that of the stomach; in it the blood-vessels and lymphatics ramify before entering or after leaving the mucous membrane, and it contains a gangliated plexus of nerve-fibres—the *plexus of Meissner*—which is finer than that of Auerbach and has fewer ganglion-cells (fig. 241). Its branches are chiefly supplied to the muscular fibres of the mucous membrane, but also to the glands and villi (fig. 242).

The *mucous membrane* is bounded next to the submucous coat by a double layer of plain muscular fibres (*muscularis mucosæ*). Bundles from this pass inwards through the membrane towards the inner

surface and penetrate also into the villi. The mucous membrane proper is pervaded with simple tubular glands—the *crypts of Lieberkühn*—which are lined throughout by a columnar epithelium like that which covers the surface and the villi. The mucous membrane between these glands is mainly composed of lymphoid tissue, which

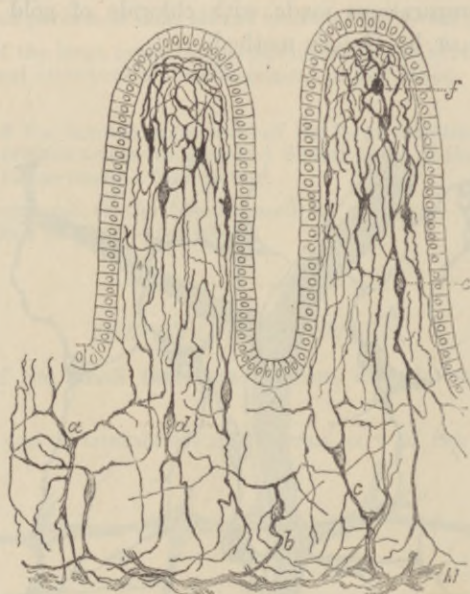


FIG. 242.—NERVES OF THE MUCOUS MEMBRANE OF THE SMALL INTESTINE.
(S. Ramon y Cajal.)

M, part of Meissner's plexus; *a-f*, small nerve-cells in the tissue of the mucous membrane and villi.

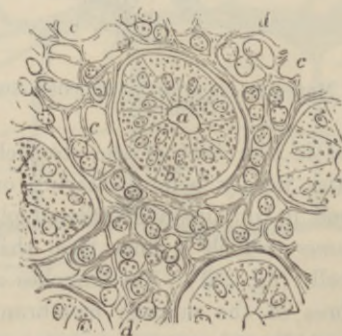

FIG. 243.—CROSS-SECTION OF A SMALL FRAGMENT OF THE MUCOUS MEMBRANE OF THE INTESTINE, INCLUDING ONE ENTIRE CRYPT OF LIEBERKÜHN AND PARTS OF THREE OTHERS. (Magnified 400 diameters.) (Frey.)

a, cavity of the tubular glands or crypts; *b*, one of the lining epithelium-cells; *c*, the interglandular retiform tissue; *d*, lymph-cells.

is aggregated at intervals into more solid nodules (fig. 244), constituting when they occur singly the so-called *solitary glands* of the intestine, and when aggregated together form the *agminated glands* or *patches of Peyer*. The latter occur chiefly in the ileum.

The *glands of Brunner*, which have been already noticed (p. 205), occur in the duodenum. They are small tubulo-racemose glands in the submucosa; they send their ducts to the inner surface of the mucous membrane between the crypts of Lieberkühn.

The *villi* with which the whole of the inner surface of the small intestine is closely beset are clavate or finger-shaped projections of

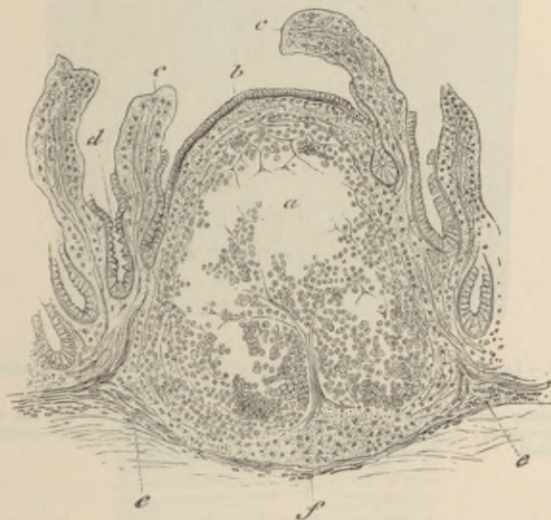

FIG. 244.—SECTION OF THE ILEUM THROUGH A LYMPHOID NODULE. (Cadiat.)

a, middle of the nodule with the lymphoid tissue partly fallen away from the section;
 b, epithelium of the intestine; c, villi: their epithelium is partly broken away;
 d, crypts of Lieberkühn.

the mucous membrane, and are composed, like that, of retiform tissue covered with columnar epithelium (figs. 245, 246). The characters of this have been already described (Lesson VII.). Between and at the base of the epithelium-cells many lymph-corpuscles occur, as well as in the meshes of the retiform tissue. The epithelium rests upon a basement-membrane formed of flattened cells. In the middle of the villus is a lacteal vessel which is somewhat enlarged near its commencement (fig. 245, *l*). It is replaced in some animals by a network of lymphatics. Surrounding this vessel are small bundles of plain muscular tissue prolonged from the muscularis mucosæ. The network of blood-capillaries (figs. 245, 246, 247) lies for the most



FIG. 245.—LONGITUDINAL SECTION OF A VILLUS FROM A RAT, KILLED THREE HOURS AFTER FEEDING WITH BREAD AND WATER.

ep, columnar epithelium, with numerous lymph-corpuses between the cells; *bl*, blood-vessels; *l*, lacteal, containing lymph-corpuses, *c*, some partly disintegrated.

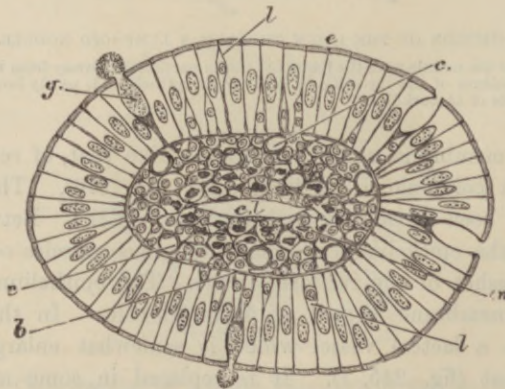


FIG. 246.—CROSS-SECTION OF AN INTESTINAL VILLUS.

c, columnar epithelium; *g*, goblet-cell, its mucus is seen partly extruded; *l*, lymph-corpuses between the epithelium-cells; *b*, basement-membrane; *c*, blood-capillaries; *m*, section of plain muscular fibres; *c.l.*, central lacteal.

part near the surface within the basement-membrane; it is supplied with blood by a small artery which joins the capillary network at the base of the villus; the corresponding vein generally rises near the extremity.

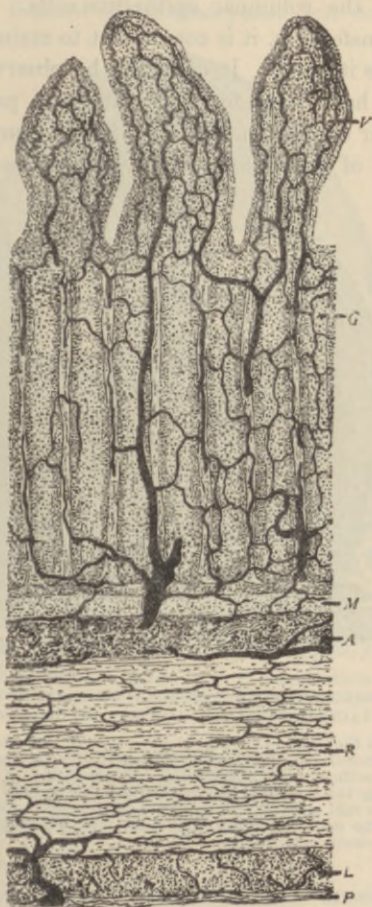


FIG. 247.—SMALL INTESTINE (VERTICAL TRANSVERSE SECTION), WITH THE BLOOD-VESSELS INJECTED. (Heitzmann.)

V, a villus; *G*, glands of Lieberkühn; *M*, muscularis mucosae; *A*, areolar coat; *R*, circular muscular coat; *L*, longitudinal muscular coat; *P*, peritoneal coat.

The *lymphatics* (lacteals) of the mucous membrane (fig. 248), after receiving the central lacteals of the villi, pour their contents into a plexus of large valved lymphatics which lie in the submucous tissue and form sinuses around the bases of the lymphoid nodules. From the submucous tissue efferent vessels pass through the muscular coat,

receiving the lymph from an intramuscular plexus of lymphatics, and are conveyed away between the layers of the mesentery.

Absorption of fat.—The lymph-corpuscles of the villi are believed to be important agents in effecting the passage of fat particles into the lacteals from the columnar epithelium-cells. In order to study the process of transference, it is convenient to stain the fat with osmic acid, which colours it black. It can then be observed that in animals (rat, frog) which have been fed with fat these particles are present (1) in the columnar epithelium-cells; (2) in the lymph-cells; and (3) in the central lacteal of the villus. The lymph-cells are present not only

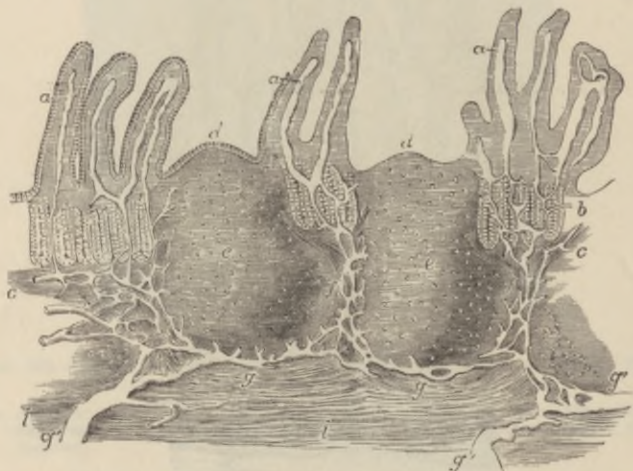


FIG. 248.—VERTICAL SECTION OF A PORTION OF A PATCH OF PEYER'S GLANDS WITH THE LACTEAL VESSELS INJECTED. (32 diameters.) (Frey.)

The specimen is from the lower part of the ileum: *a*, villi, with their lacteals left white; *b*, some of the tubular glands; *c*, the muscular layer of the mucous membrane; *d*, cupola or projecting part of the nodule; *e*, central part; *f*, the reticulated lacteal vessels occupying the lymphoid tissue between the nodules, joined above by the lacteals from the villi and mucous surface, and passing below into *g*, the sinus-like lacteals under the nodules, which again pass into the large efferent lacteals, *g'*; *i*, part of the muscular coat.

in the reticular tissue of the villus, but also in considerable number between the epithelium-cells; and they can also be seen in thin sections from osmic preparations within the commencing lacteal; in the last situation they are undergoing disintegration.

Since the lymph-cells are amœboid, it is probable from these facts that the mechanism of fat-absorption consists of the following processes—viz. (1) absorption of fat into the columnar epithelium-cells of the surface; (2) inception of fat by lymph-corpuscles in the epithelium, these taking it up after it has passed out of the epithelium-cells; (3) migration of lymph-corpuscles carrying fat particles through the

tissue of the villus and into the central lacteal; (4) disintegration and solution of the immigrated lymph-corpuses, and setting free their contents.

This migration of the lymph-corpuses into the lacteals of the villi is not a special feature of fat-absorption, but occurs even when

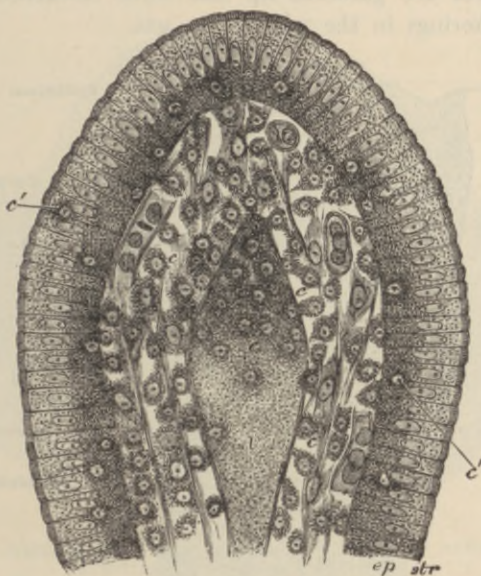


FIG. 249.—SECTION OF THE VILLUS OF A RAT KILLED DURING FAT-ABSORPTION.

ep, epithelium; *str*, striated border; *c*, lymph-cells; *c'*, lymph-cells in the epithelium; *l*, central lacteal containing chyle and disintegrating lymph-corpuses.

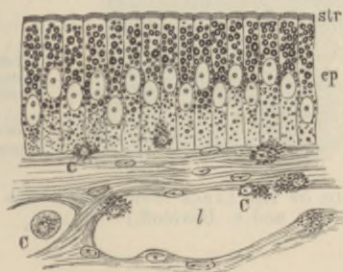

FIG. 250.—MUCOUS MEMBRANE OF FROG'S INTESTINE DURING FAT-ABSORPTION.

ep, epithelium; *str*, striated border; *c*, lymph-corpuses; *l*, lacteal.

absorption of other matters is proceeding (fig. 245); so that the transference of fat-particles is merely a part of a more general phenomenon accompanying absorption.

THE LARGE INTESTINE.

The large intestine has the usual four coats, except near its termination, where the serous coat is absent. The muscular coat is peculiar in the fact that along the cæcum and colon the longitudinal muscular fibres are gathered up into three thickened bands which produce puckerings in the wall of the gut.

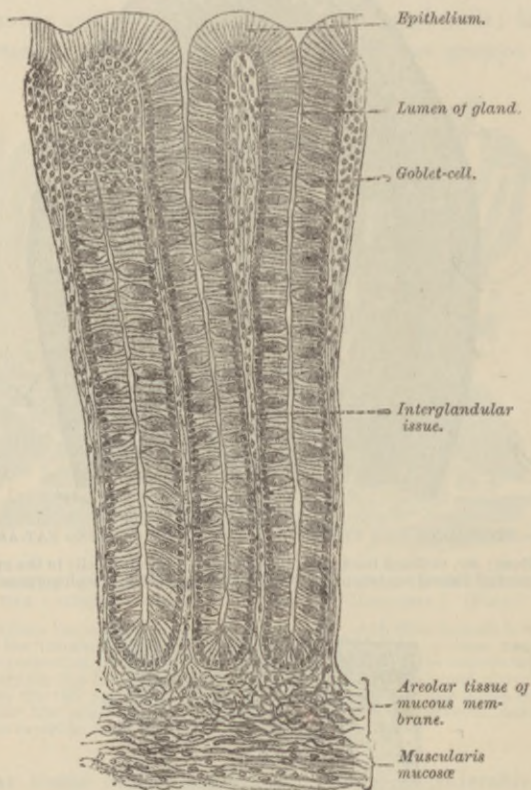


FIG. 251.—GLANDS OF THE LARGE INTESTINE OF MAN. (From Böhm and v. Davidoff.) $\frac{200}{1}$.

The *mucous membrane* of the large intestine is beset with simple tubular glands somewhat resembling the crypts of Lieberkühn of the small intestine, and lined by columnar epithelium similar to that of the inner surface of the gut, but containing many more mucus-secreting or goblet-cells (fig. 251). The extremity of each gland is usually slightly dilated. The interglandular tissue is like that of

the stomach, and is beset here and there with solitary (lymphoid) glands (fig. 252). The arrangement of the blood-vessels and lymphatics in the large intestine resembles that in the stomach. The nerves of the large intestine also resemble those of the stomach and small intestine in their arrangement.

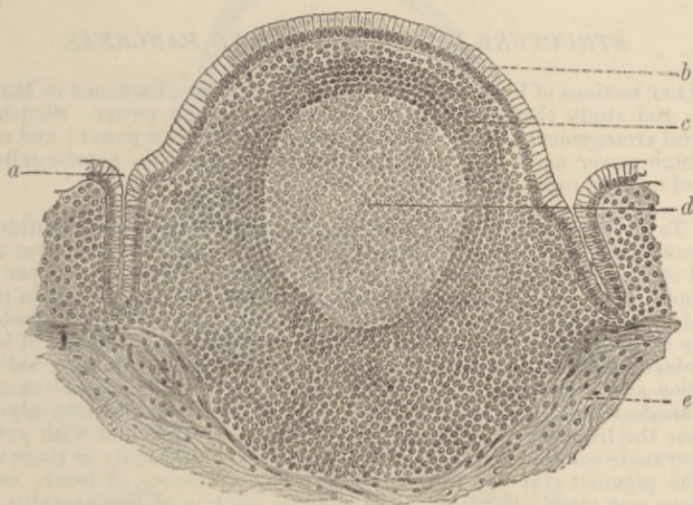


FIG. 252.—SECTION THROUGH A SOLITARY GLAND IN THE HUMAN LARGE INTESTINE. (Böhm and v. Davidoff.)

a, crypt of Lieberkühn; *b*, epithelium of surface; *c*, lymphoid cells more closely packed; *d*, central part of lymphoid nodule (area of multiplication of cells); *e*, submucosa.

At the lower end of the rectum the circular muscular fibres of the gut become thickened a little above the anus to form the *internal sphincter* muscle. In the anal region also there are a number of compound racemose mucous glands opening on the surface of the mucous membrane (*anal glands*). The anus has a lining of stratified epithelium continuous with that of the skin.

LESSON XXXIV.

STRUCTURE OF THE LIVER AND PANCREAS.

1. MAKE sections of liver, pig's and human, from pieces hardened in Müller's fluid, and study them carefully with a low and high power. Sketch the general arrangement of the cells in a lobule under the low power; and under the high power make very careful drawings of some of the hepatic cells and also of a portal canal.

2. To observe the glycogen and the iron-containing pigment within the liver-cells, kill a rabbit (for glycogen preferably about six hours after a full meal of carrots), and at once throw a thin piece of the liver into 96 per cent. alcohol. When well hardened the piece may be embedded in paraffin in the usual way, or sections may be cut with the free hand without embedding. Some of the sections so obtained are to be treated with a solution of iodine in potassic iodide: then rapidly dehydrated by alcohol containing iodine in solution and passed into clove-oil (not xylol). They may now be mounted in Canada balsam (not xylol balsam). These are to exhibit the glycogen within the liver cells. Other sections are to be treated first with potassic ferrocyanide solution and then with dilute hydrochloric acid: in these many of the pigment granules will be stained blue (presence of iron); or the sections may simply be placed in an aqueous solution of hæmatoxylin (1 to 300), with and without previous treatment with alcohol containing 10 parts per cent. hydrochloric acid, after which they may be mounted in the ordinary way (Macallum's method).

3. Study, first with the low power and afterwards with a high power, a section of the liver in which both the blood-vessels and the bile-ducts have been injected.¹ Make a general sketch of a lobule under the low power and draw a small part of the network of bile-canaliculi under the high power.

4. Tease a piece of fresh liver in serum or salt solution for the study of the appearance of the hepatic cells in the recent or living condition.

5. Stained sections of pancreas from a gland which has been hardened in alcohol, or in formol followed by alcohol. Small pieces of the gland are stained in bulk and the sections mounted in the usual way in Canada balsam.

Make a sketch under the low power.

6. Tease a small piece of fresh pancreas in serum or salt solution. Notice the granules in the alveolar cells, chiefly accumulated in the half of the cell which is nearest the lumen of the alveolus, leaving the outer zone of the cell clear.

Sketch a small portion of an alveolus under a high power.

¹ For the method of injecting these, see *Course of Practical Histology*. They can also be demonstrated in sections of liver which have been prepared by Golgi's method (see Appendix).

THE LIVER.

The liver is a solid glandular mass, made up of the *hepatic lobules*. These are polyhedral masses about 1 mm. ($\frac{1}{25}$ inch) in diameter,

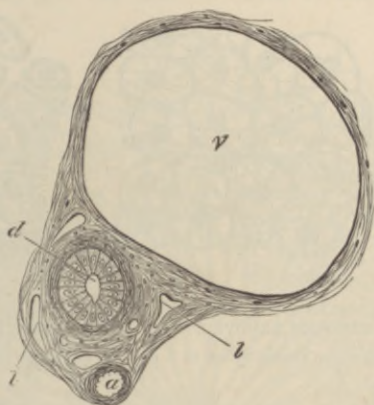


FIG. 253.—SECTION OF A PORTAL CANAL.

a, branch of hepatic artery; *v*, branch of portal vein; *d*, bile-duct; *l, l*, lymphatics in the areolar tissue of Glisson's capsule which incloses the vessels.

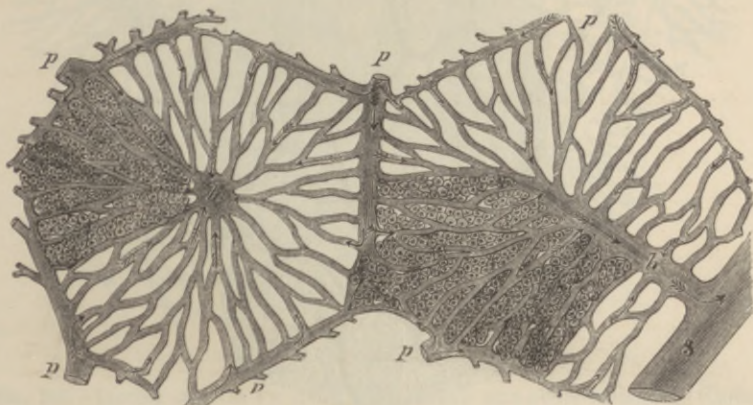


FIG. 254.—DIAGRAMMATIC REPRESENTATION OF TWO HEPATIC LOBULES.

The left-hand lobule is represented with the intralobular vein cut across; in the right-hand one the section takes the course of the intralobular vein. *p*, intralobular branches of the portal vein; *h*, intralobular branches of the hepatic veins; *s*, sublobular vein; *c*, capillaries of the lobules. The arrows indicate the direction of the course of the blood. The liver-cells are only represented in one part of each lobule.

composed of cells, and separated from one another by connective tissue. In some animals, as in the pig, this separation is complete, and each lobule is isolated, but in man it is incomplete. There is

also a layer of connective tissue underneath the serous covering of the liver, forming the so-called *capsule* of the organ.

The *blood-vessels of the liver* (portal vein and hepatic artery) enter it on its under surface, where also the bile-duct passes away from

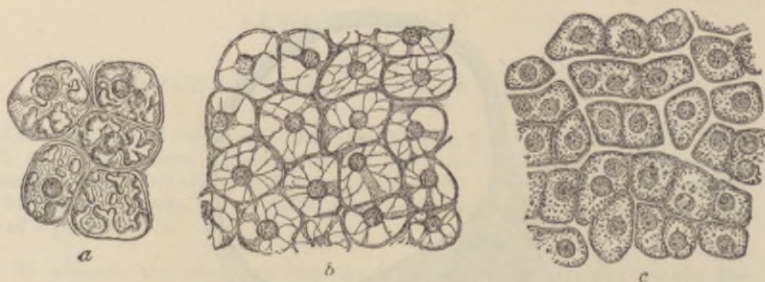


FIG. 255.—HEPATIC-CELLS STILL CONTAINING GLYCOGEN, *a*, AND WITH THEIR GLYCOGEN REMOVED, *b*, *c*. (Heidenhain.)

In *c* there was less glycogen present than in *b*, and the section is differently prepared.

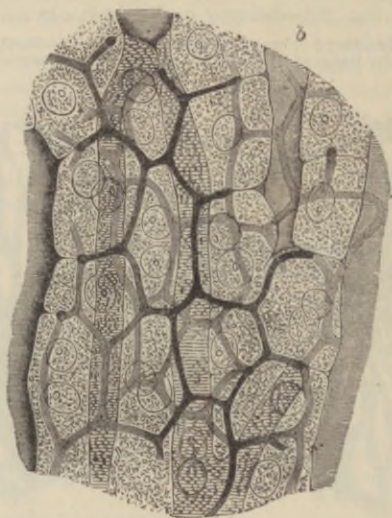


FIG. 256.—SECTION OF RABBIT'S LIVER WITH THE INTERCELLULAR NETWORK OF BILE-CANALICULI INJECTED. (Highly magnified.) (Hering.)

Two or three layers of cells are represented; *b*, blood-capillaries.

the gland. The branches of these three vessels accompany one another in their course through the organ, and are inclosed by loose connective tissue (capsule of Glisson, in which are lymphatic vessels, the whole being termed a *portal canal* (fig. 253). The smallest branches

of the vessels penetrate to the intervals between the hepatic lobules, and are known as the interlobular branches. The blood leaves the liver at the back of the organ by the hepatic veins; the branches of these run through the gland unaccompanied by other vessels (except lymphatics) and can also be traced to the lobules, from each

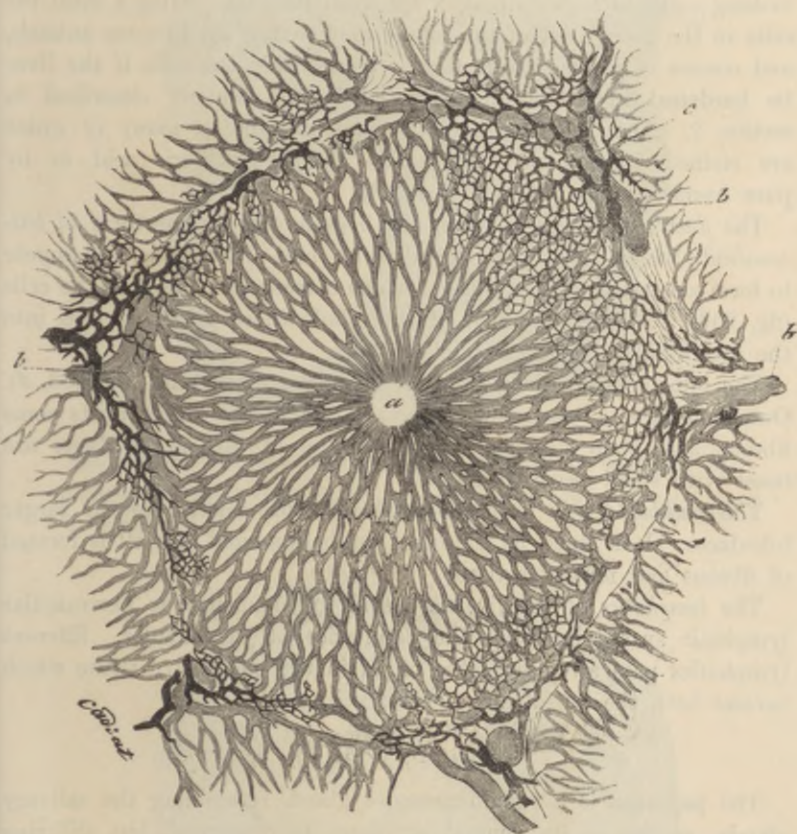


FIG. 257.—LOBULE OF RABBIT'S LIVER, VESSELS AND BILE-DUCTS INJECTED. (Cadiat.)
 a, central vein; b, b, peripheral or interlobular veins; c, interlobular bile-duct.

of which they receive a minute branch (intralobular vein) which passes from the centre of the lobule, and opens directly into the (sublobular) branch of the hepatic vein.

Each lobule is a mass of hepatic cells pierced everywhere with a network of blood-capillaries (fig. 254), which arise at the periphery of the lobule, there receiving blood from the interlobular branches

of the portal vein (*p*), and converge to the centre of the lobule, where they unite to form the intralobular branch of the hepatic vein. The interlobular branches of the hepatic arteries join this capillary network a short distance from the periphery of the lobule.

The *hepatic cells* (figs. 254, 256), which everywhere lie between and surround the capillaries, are polyhedral, somewhat granular-looking cells, each containing a spherical nucleus. After a meal the cells in the outer part of the lobule may contain fat in some animals, and masses of glycogen can also be seen within the cells if the liver be hardened in alcohol and treated in the manner described in section 2. The cells also contain pigment-granules, many of which are stained by potassic ferrocyanide and hydrochloric acid, or by pure hæmatoxylin (presence of iron¹).

The *ducts* commence between the hepatic cells in the form of *bile-canaliculi*, which lie between the adjacent sides of two cells, and appear to form a network, the meshes of which correspond in size to the cells (fig. 256). At the periphery of the lobule these canaliculi pass into the interlobular bile-ducts (fig. 257).

The bile-ducts are lined by clear columnar epithelium (fig. 253, *d*). Outside this is a basement-membrane, and in the larger ducts some fibrous and plain muscular tissue. Many of the larger ducts are beset with small cæcal diverticula.

The *gall-bladder* is in its general structure similar to the larger bile-ducts. It is lined by columnar epithelium, and its wall is formed of fibrous and muscular tissue.

The *lymphatics* of the liver are said to commence as perivascular lymphatic spaces inclosing the capillaries of the lobules. Efferent lymphatics pass away from the organ in the connective tissue which invests both the portal and hepatic veins.

THE PANCREAS.

The **pancreas** is a tubulo-racemose gland, resembling the salivary glands, so far as its general structure is concerned, but differing from them in the fact that the alveoli, in place of being saccular, are longer and more tubular in character. Moreover, the connective tissue of the gland is somewhat looser, and there occur in it at intervals small groups of epithelium-like cells (fig. 258, *a*; fig. 259), which are supplied with a close network of convoluted capillary vessels; their function is unknown, but their presence is very characteristic of the pancreas.

¹ Any iron which is in organic combination in the tissue must first be set free by treatment with 10 p.c. hydrochloric acid.

The cells which line the alveoli are columnar or polyhedral in shape. When examined in the fresh condition, or in osmic preparations, their protoplasm is filled in the inner two-thirds with small

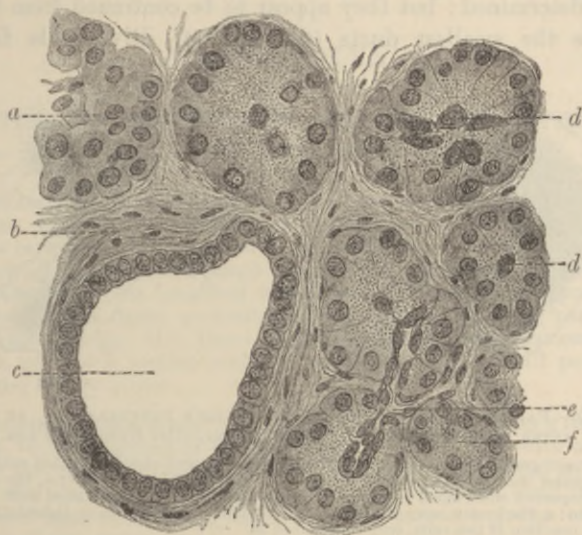


FIG. 258.—SECTION OF HUMAN PANCREAS. (Böhm and v. Davidoff.) $\frac{1}{2}$ in.

a, group of cells in interstitial tissue; *b*, connective tissue; *c*, larger duct; *d*, *d*, alveoli with centro-acinar cells; *e*, duct passing into alveoli; *f*, inner granular zone of alveolus.

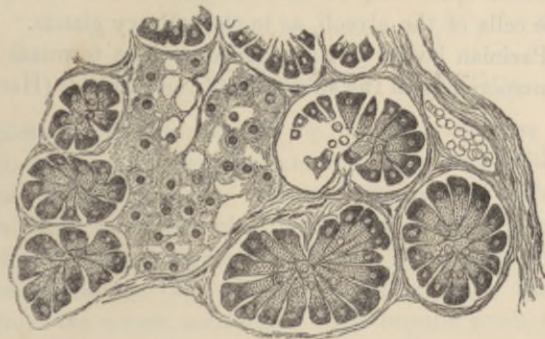


FIG. 259.—SECTION OF PANCREAS OF ARMADILLO SHOWING SEVERAL ALVEOLI AND A LARGE INTERALVEOLAR CELL-ISLET. (V. D. Harris.)

granules, but the outer third is left clear (fig. 260, *A*). After a period of activity the clear part of the cell becomes larger, and the granular part smaller (*B*). In stained sections the outer part is coloured more deeply than the inner (figs. 258, 259).

In the centre of each acinus there may generally be seen some spindle-shaped cells (*centro-acinar cells* of Langerhans—fig. 258, *d*), the nature of which (whether epithelial or connective tissue) has not been definitely determined; but they appear to be continued from the cells which line the smallest ducts (fig. 258, *e*). Diverticula from the

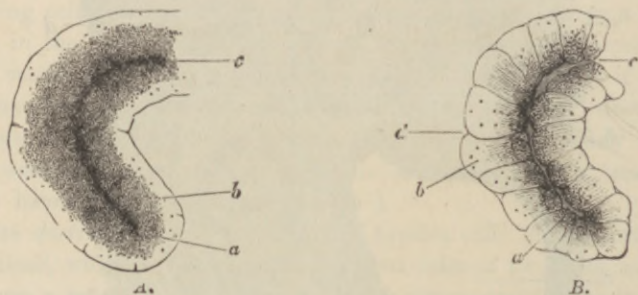


FIG. 260.—PART OF AN ALVEOLUS OF THE RABBIT'S PANCREAS. *A*, AT REST; *B*, AFTER ACTIVE SECRETION. (From Foster, after Kühne and Lea.)

a, the inner granular zone, which in *A* is larger and more closely studded with fine granules than in *B*, in which the granules are fewer and coarser; *b*, the outer transparent zone, small in *A*, larger in *B*, and in the latter marked with faint striae; *c*, the lumen, very obvious in *B*, but indistinct in *A*; *d*, an indentation at the junction of two cells, only constant in *B*.

lumen penetrate between the alveolar cells, as in the salivary glands (p. 196). The pancreas has many nerves, with numerous small nerve-cells distributed upon their course; the nerve-fibrils end by ramifying amongst the cells of the alveoli, as in the salivary glands. In the cat, which has Pacinian bodies in its mesentery, these terminal organs are also found numerous in the substance of the pancreas (Harris).

LESSON XXXV.

STRUCTURE OF THE SPLEEN, SUPRARENAL CAPSULE, AND THYROID BODY.

1. SECTIONS of the spleen stained with hæmatoxylin or with methyl-blue and eosin. Notice the trabeculæ extending into the substance of the organ from the capsule. Notice also that the glandular substance is of two kinds, (1) lymphoid tissue accumulated around the small arteries and here and there massed to form *lymphoid nodules*—the Malpighian corpuscles of the spleen—and (2) a tissue consisting of a reticulum of fibrils, partly covered with branched cells: this tissue contains blood in its interstices.

Sketch part of a section under a low power and a small portion of the pulp under a high power.

2. Sections across a suprarenal capsule hardened in Müller's fluid. Notice the deep brown staining of the medulla. Examine first with a low power, noticing the general arrangement and extent of the cortical and medullary parts of the organ, and making a general sketch which shall include both. Afterwards sketch carefully under the high power a group of cells from each part of the organ.

3. Sections of the thyroid body stained with hæmatoxylin. Notice the vesicles lined with cubical epithelium and filled with a "colloid" substance which becomes stained with hæmatoxylin. Sketch one or two vesicles. Measure several vesicles.

 THE SPLEEN.

The **spleen** is the largest of the so-called ductless glands. It appears to be functionally connected in some way with the blood, white blood-corpuscles being certainly formed and coloured blood-corpuscles being probably submitted to destruction within it.

Like the lymphatic glands, the spleen is invested with a fibrous and muscular *capsule* (fig. 261, A), and this again has a covering derived from the serous membrane. The capsule sends fibrous bands or trabeculæ (*b*) into the organ, and these join with a network of similar trabeculæ which pass into the gland at the hilum along with the blood-vessels. In the interstices of the fibrous framework thus constituted lies a soft pulpy substance containing a large amount of blood, and therefore of a deep red colour, dotted within which are here and there to be seen small whitish specks, the *Malpighian corpuscles of the spleen* (*c, c*). These are composed of lymphoid tissue

which is gathered up into masses which envelop the smaller arteries, whilst the red pulp which everywhere surrounds them and which forms the bulk of the organ is composed of a close network of retiform tissue fibrils, covered by flattened and branched cells like connective-tissue corpuscles. Coursing through the pulp and communicating with its interstices are capillary blood-vessels which are connected with the terminations of the arteries; whilst in other parts venous channels arise from the pulp, and bring the blood which has passed into its interstices from the arterial capillaries towards the larger

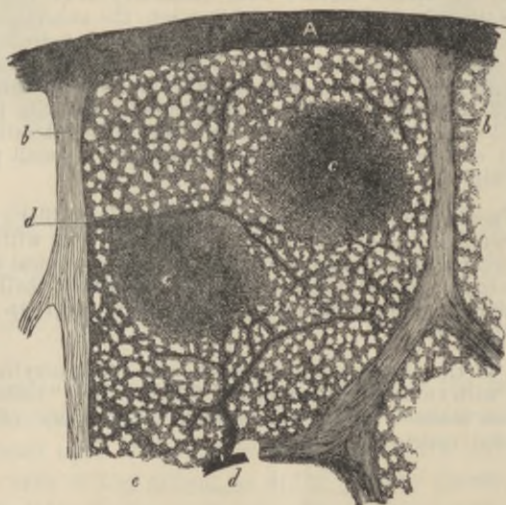


FIG. 261.—VERTICAL SECTION OF A SMALL SUPERFICIAL PORTION OF THE HUMAN SPLEEN, AS SEEN WITH A LOW POWER. (Kölliker.)

A, peritoneal and fibrous covering; *b*, trabeculae; *c*, *c*, Malpighian corpuscles, in one of which an artery is seen cut transversely, in the other longitudinally; *d*, injected arterial twigs; *e*, spleen-pulp.

veins of the organ, which run in the trabeculae, and are by them conducted to the hilum. The arteries, which are also at first conducted from the hilum along the trabeculae into the interior of the organ, presently leave the trabeculae, and their external coat becomes converted into a thick sheath of lymphoid tissue which invests them in the remainder of their course, and in places becomes swollen into the Malpighian corpuscles already mentioned. These small arteries distribute a few capillaries to the Malpighian corpuscles, and then break up into pencils of small vessels which open into the pulp in the manner before described.

The cellular elements of the spleen-pulp are of three kinds, viz.

peculiar, large, amœboid cells, called splenic cells, lymph-corpuses, and the branched, flattened cells which form the spongework. The

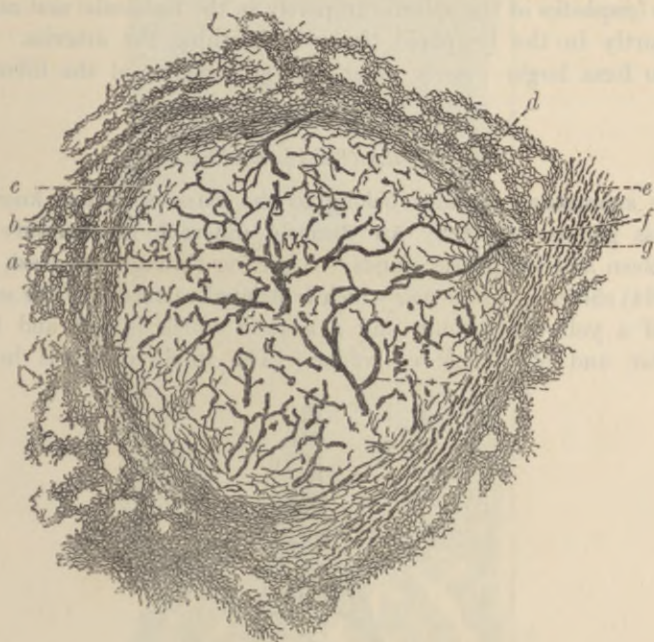


FIG. 262.—RETICULUM OF SPLEEN, GOLGI METHOD. (Oppel.)

a, Malpighian corpuscle; *b*, part of its reticulum; *c*, condensed reticulum at its margin; *d*, more open tissue next to this; *e*, wall of arteriole; *f*, capillaries of Malpighian corpuscle; *g*, reticulum of arteriole expanding into that of the Malpighian corpuscle.

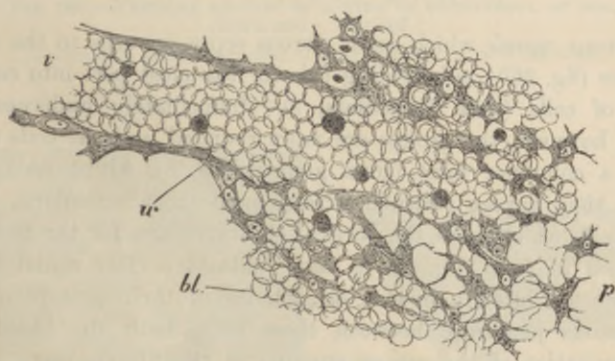


FIG. 263.—THIN SECTION OF SPLEEN-PULP, HIGHLY MAGNIFIED, SHOWING THE MODE OF ORIGIN OF A SMALL VEIN IN THE INTERSTICES OF THE PULP.

v, the vein, filled with blood-corpuses, which are in continuity with others, *bl*, filling up the interstices of the retiform tissue of the pulp; *u*, wall of the vein. The shaded bodies amongst the red blood-corpuses are pale corpuses.

first-named are frequently found to contain coloured blood-corpuscles in their interior in various stages of transformation into pigment.

The *lymphatics* of the spleen run partly in the trabeculæ and capsule, and partly in the lymphoid tissue ensheathing the arteries. They join to form larger vessels which emerge together at the hilum.

THE SUPRARENAL CAPSULES.

The **suprarenal capsules** belong to the class of bodies known as ductless glands, but they are entirely different in structure from the spleen and lymphatic glands. A section through the fresh organ (fig. 264) shows a *cortical zone* which is striated vertically to the surface, and of a yellowish colour, and a *medulla* which is soft and highly vascular, and of a dark-red colour. The whole organ is invested

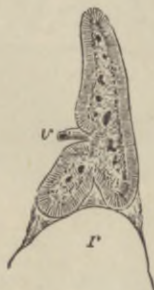

FIG. 264.—A VERTICAL SECTION OF THE SUPRARENAL BODY OF A FETUS, TWICE THE NATURAL SIZE, SHOWING THE DISTINCTION BETWEEN THE MEDULLARY AND CORTICAL SUBSTANCE. (A. Thomson.)

v, issuing vein; r, summit of kidney.

by a fibrous *capsule* which sends fibrous septa inwards to the cortical substance (fig. 265), subdividing this for the most part into columnar groups of cells (*zona fasciculata*, *c*). Immediately underneath the capsule, however, the groups are more rounded, and the cells tend to assume a columnar form (*zona glomerulosa*, *b*), whilst next to the medulla they have a reticular arrangement (*zona reticularis*, *d*).

The cells which form the cortical substance are, for the most part, polyhedral in form (fig. 266); each contains a clear round nucleus, and there are often yellowish oil-globules in their protoplasm. No blood-vessels penetrate between these cells, both the blood-vessels and lymphatics of the cortex running in the fibrous septa between the columns; the lymphatics are said to communicate with fine spaces which run between the cells of the columns.

The cells of the medulla (fig. 267) are more irregular in shape,

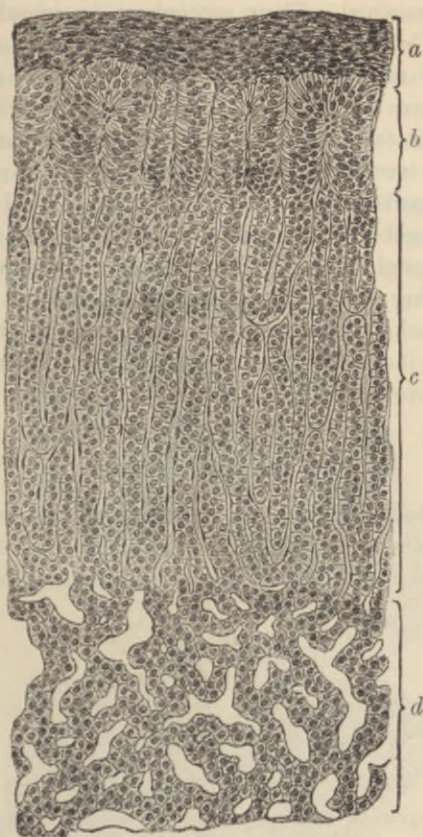


FIG. 265.—VERTICAL SECTION OF CORTEX OF SUPRARENAL OF DOG.
(Böhm and v. Davidoff.)

a, capsule; b, zona glomerulosa; c, zona fasciculata; d, zona reticularis.

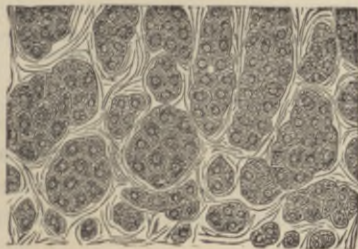


FIG. 266.—CELLS AND CELL-GROUPS FROM THE CORTICAL SUBSTANCE OF THE SUPRARENAL BODY. (Eberth.)

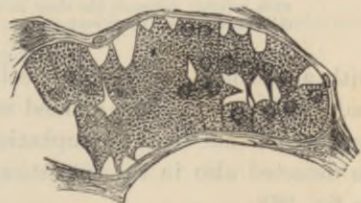

FIG. 267.—CELLS FROM THE MEDULLARY PART OF THE SUPRARENAL CAPSULE OF THE OX. (Eberth.)

and are often branched. Their protoplasm is granular, and it may in some animals contain a brownish pigment, but in man the dark red colour of the medulla is largely due to the blood contained in the large venous spaces by which it is pervaded, and which receive the blood after it has traversed the capillaries of the cortex. Investing the larger veins are longitudinal bundles of plain muscular fibres; and numerous nerves, after traversing the cortical substance, are distributed throughout the medulla, where they form a close plexus provided with ganglion-cells. The cells of the medulla are characterised by staining brown by chromic acid and its salts, provided the organ is fresh. The medulla appears to produce a chemical substance which increases the tonicity of the muscular system, both voluntary and involuntary.

THE THYROID BODY.

The **thyroid body** consists of a framework of connective tissue inclosing numerous spherical or oval vesicles (fig. 268) which are lined with cubical epithelium. The cavities of the vesicles are filled

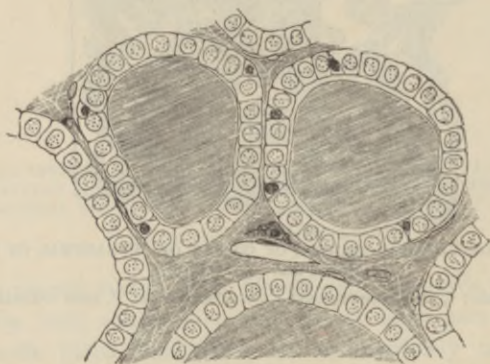


FIG. 268.—SECTION OF THE THYROID GLAND OF A CHILD.

Two vesicles are represented and portions of three others. The vesicles are filled with colloid; between the clear cubical epithelium-cells, smaller, darkly-stained cells are here and there seen.

with a peculiar viscid liquid (colloid) which is coagulated by alcohol and which then becomes stained with hæmatoxylin. A similar material has been found in the lymphatics of the gland, and may sometimes be detected also in the interstices of the connective tissue, as shown in fig. 268.

The blood-vessels of the thyroid are exceedingly numerous, and the capillaries form close plexuses round the vesicles.

Disease of the thyroid or its extirpation is accompanied by remarkable changes in the chemical composition of the blood and many of the tissues, a condition of myxœdema, and eventually of cretinism, being produced.

Parathyroids.—In close proximity to the thyroid are always to be found four small glandular organs of different structure from the thyroid proper, although somewhat resembling its embryonic condition. These bodies, one of which usually lies on the lateral and one on the mesial surface of each lateral lobe, are formed of columns of granular epithelium-cells, with a very vascular connective

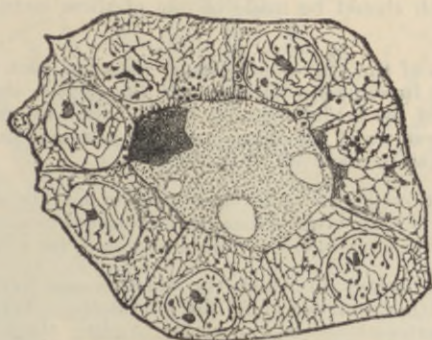

FIG. 269.—SECTION OF A VESICLE OF A DOG'S THYROID, HIGHLY MAGNIFIED.
(Andersson.)

tissue between the columns. If left after removal of the thyroid, they are stated to undergo hypertrophy and to supply its function. Besides these bodies, there is also frequently to be found in connection with the thyroid a small mass of lymphoid tissue which resembles the thymus tissue in structure and, like it, contains concentric corpuscles.

Carotid and coccygeal glands—These are minute glandular organs without ducts, lying respectively at the bifurcation of the carotid artery and in front of the apex of the coccyx. They are composed of columns of polyhedral cells, with numerous blood-capillaries between the columns. Their function is unknown.

LESSON XXXVI.

STRUCTURE OF THE KIDNEY.

1. SECTIONS passing through the whole kidney of a small mammal, such as a mouse or rat. These sections will show the general arrangement of the organ and the disposition of the tubules and of the Malpighian corpuscles.

A general sketch should be made of one of these sections under a low power.

2. Thin sections of the kidney of a larger mammal, such as the dog, may next be studied. In some the direction of the section should be parallel with the tubules of the medulla, and in others across the direction of those tubules. The characters of the epithelium of the several parts of the uriniferous tubules are to be made out in these sections.

3. Separate portions of the uriniferous tubules may be studied in teased preparations from a kidney which has been subjected to some process which renders it possible to unravel the uriniferous tubules for a certain distance.¹

4. Sections of a kidney in which the blood-vessels have been injected. Examine these with a low power of the microscope. Try and follow the course of the arteries—those to the cortex sending their branches to the glomeruli, those to the medulla rapidly dividing into pencils of fine vessels which run between the straight uriniferous tubules of the boundary zone. Notice also the efferent vessels from the glomeruli breaking up into the capillaries which are distributed to the tubules of the cortical substance.

Make sketches showing these points.

The **kidney** is a compound tubular gland. To the naked eye it appears formed of two portions—a *cortical* and a *medullary*. The latter is subdivided into a number of pyramidal portions (*pyramids of Malpighi*), the base (boundary zone) of each being surrounded by cortical substance, while the apex projects in the form of a *papilla* into the dilated commencement of the ureter (*pelvis of the kidney*).² Both cortex and medulla are composed entirely of tubules—the *uriniferous tubules*—which have a straight direction in the medulla and a contorted arrangement in the cortex; but groups of straight tubules also pass from the medulla through the thickness of the cortex (*medullary rays*, see fig. 270).

The **uriniferous tubules** begin in the cortical part of the organ in

¹ For a method which may be employed for this purpose, see *Course of Practical Histology*.

² In many animals the whole kidney is formed of only a single pyramid, but in man there are about twelve.

dilatations, each inclosing a tuft or glomerulus of convoluted capillary blood-vessels (*corpuscles of Malpighi*), the dilated commencement of the tubule being known as the *capsule* (fig. 271, 1). The tubule leaves the capsule by a *neck* (2), which is rarely narrower than the rest of the tubule in mammals, but in some animals (*e.g.* frog) is long, and has ciliated epithelium; the tubule is at first convoluted (*first convoluted tubule*, 3), but soon becomes nearly straight or slightly spiral only (*spiral tubule*, 4), and then, rapidly narrowing, passes down into the medulla towards the dilated commencement of the ureter

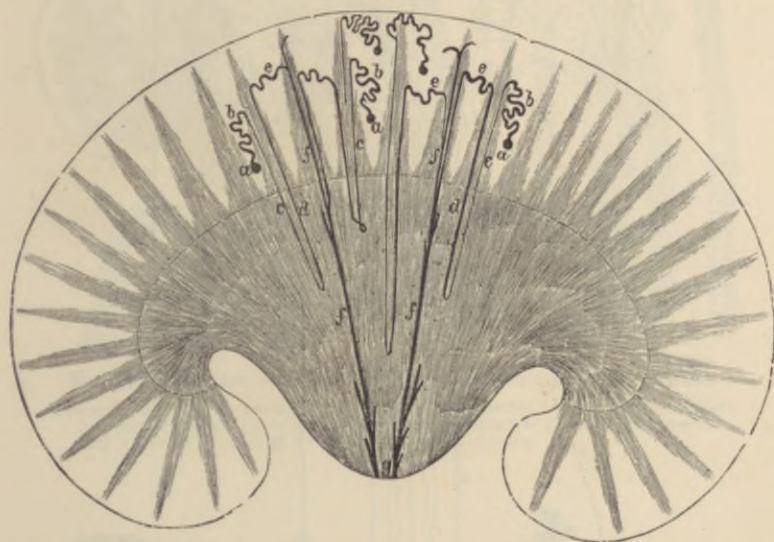


FIG. 270.—DIAGRAM OF THE CURVE OF THE TUBULES IN A UNIPYRAMIDAL KIDNEY, SUCH AS THAT OF THE RABBIT. (Toldt.)

a, Malpighian bodies; b, first convoluted tubule; c, d, looped tube of Henle; e, second convoluted; f, collecting tube; g, ducts of Bellini.

as the *descending tubule of Henle* (5). It does not at once, however, open into the pelvis of the kidney, but before reaching the end of the papilla it turns round in the form of a loop (*loop of Henle*, 6) and passes upwards again towards the cortex, parallel to its former course, and at first somewhat larger than before, but afterwards diminishing in size (*ascending tubule of Henle*, 7, 8, 9). Arrived at the cortex, it approaches close to the capsule from which the tubule took origin, but at a point opposite to the origin, viz. near the afferent and efferent vessels of the glomerulus (Golgi). It then becomes larger and irregularly zigzag (*zigzag or irregular tubule*, 10), and may again be somewhat convoluted (*second convoluted tubule*, 11),

eventually, however, narrowing into a vessel (*junctional tubule*, 12), which joins a straight or *collecting tubule* (13). This now passes through the medullary substance of the kidney (14) to open at the apex of the papilla as one of the *ducts of Bellini* (15).

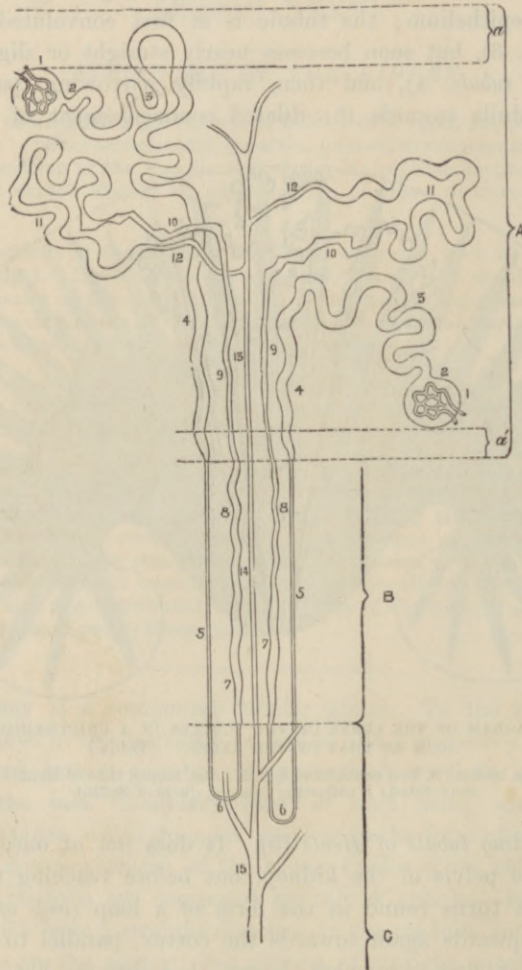


FIG. 271.—DIAGRAM OF THE COURSE OF TWO URINIFEROUS TUBULES. (Klein.)

A, cortex; B, boundary zone; C, papillary zone of the medulla; *a*, *a'*, superficial and deep layers of cortex, free from glomeruli. For the explanation of the numerals, see the text.

The tubules are throughout bounded by a basement-membrane, which is lined by epithelium, but the characters of the epithelium-cells vary in the different parts of a tubule. In the *capsule* the

epithelium is flattened and is reflected over the glomerulus (fig. 272, *a*). In some animals (*e.g.* mouse) the fibrillated epithelium of the con-

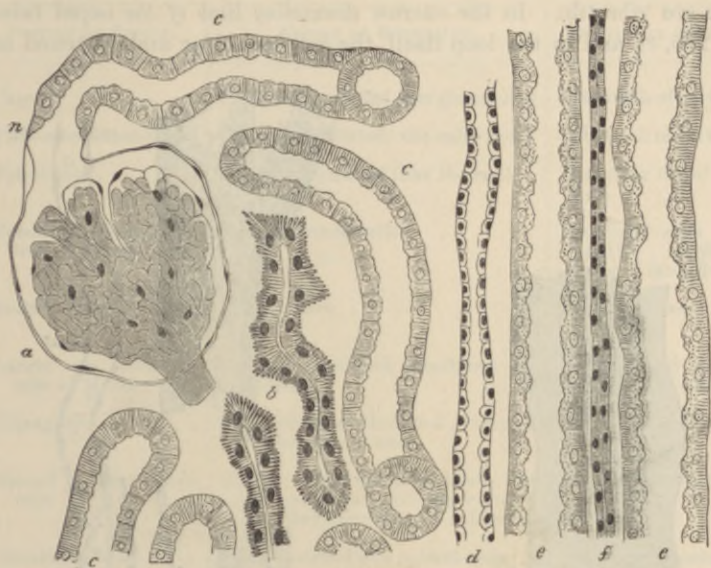


FIG. 272.—TUBULES FROM A SECTION OF THE DOG'S KIDNEY. (Klein.)

a, capsule, inclosing the glomerulus; *n*, neck of the capsule; *c, c*, convoluted tubules; *b, b*, irregular tubules; *d*, collecting tube; *e, e*, spiral tubes; *f*, part of the ascending limb of Henle's loop, here (in the medullary ray) narrow.

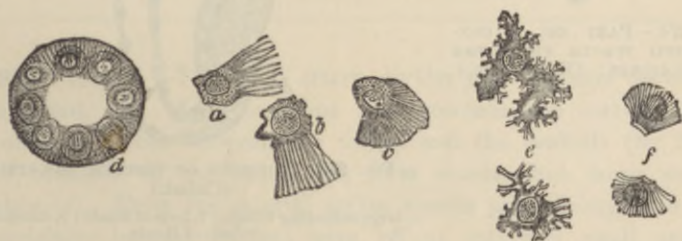

FIG. 273.—STRUCTURE OF THE EPITHELIUM OF THE CONVOLUTED TUBULES. (R. Heidenhain.)

d, section of a convoluted tubule from the rat, showing the unaltered protoplasm occupying a circular area around the nucleus of each cell; *a, b, c*, isolated cells from the convoluted tubules of the rat; *e*, isolated cells from the dog's kidney, viewed from the inner surface, and showing the irregular contour of the protoplasm; *f*, isolated cells from the newt, showing the rods and a homogeneous cuticular layer.

voluted tube is prolonged a little way into the capsule. In the first convoluted and spiral tubules the epithelium is thick, and the cells show a marked fibrillar structure (figs. 272, 273). Moreover, they interlock

laterally and are difficult of isolation; in some animals they have been described as being ciliated. They certainly often exhibit a brush of cilium-like processes projecting into the lumen, but it is doubtful if these are vibratile. In the narrow *descending limb of the looped tubules* (fig. 275, *c*), and in the loop itself, the cells are clear and flattened and

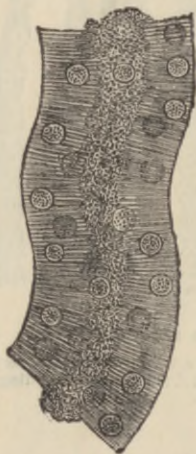


FIG. 274.—PART OF A CONVOLUTED TUBULE FROM THE DOG'S KIDNEY. (Heidenhain.)

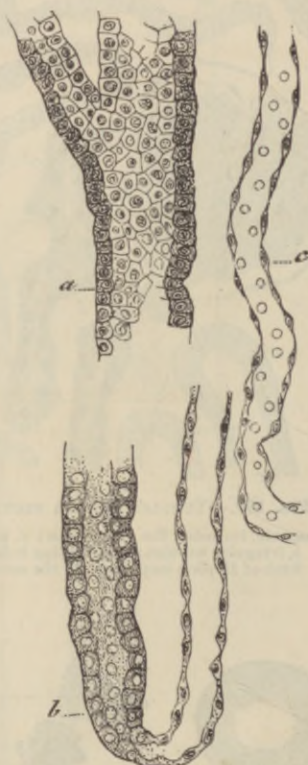


FIG. 275.—PORTIONS OF TUBULES, ISOLATED. (Cadiat.)

a, large collecting tubule; *b*, loop of Henle; *c*, descending tubule of Henle.

leave a considerable lumen; in the *ascending limb* they again acquire the striated structure and nearly fill the lumen. The fibrillations of the cells are still more marked in the *zigzag tubules* (fig. 272, *b*), and a similar structure is present also in the *second convoluted tubules*, into which these pass. On the other hand, the *junctional tubule* has a large lumen and is lined by clear flattened cells, and the *collecting tubes* have also a very distinct lumen and are lined by a clear cubical or columnar epithelium (figs. 272, *d*; 275, *a*; 276, *a*).

The following gives a tabular view of the parts which compose a uriniferous tubule, and the nature of the epithelium in each part:—

PORTION OF TUBULE.	NATURE OF EPITHELIUM.	POSITION OF TUBULE.
Capsule	Flattened, reflected over glomerulus	Labyrinth of cortex. ¹
First convoluted tube.	Cubical, fibrillated, the cells interlocking	Labyrinth of cortex.
Spiral tube	Cubical, fibrillated (like the last)	Medullary ray of cortex.
Small or descending tube of Henle	Clear flattened cells	Boundary zone and partly papillary zone of medulla.
Loop of Henle	Like the last	Papillary zone of medulla.
Larger or ascending tube of Henle	Cubical, fibrillated, sometimes imbricated	Medulla, and medullary ray of cortex.
Zigzag tube	Cells strongly fibrillated; varying height; lumen small	Labyrinth of cortex.
Second convoluted tube	Similar to first convoluted tube, but cells are longer, with larger nuclei, and they have a more refractive aspect	Labyrinth of cortex.
Junctional tube	Clear flattened and cubical cells	Labyrinth passing to medullary ray.
Straight or collecting tube	Clear cubical and columnar cells	Medullary ray and medulla.
Duct of Bellini	Clear columnar cells	Opens at apex of papilla.

Blood-vessels.—The renal artery divides into branches on entering the organ, and these branches pass towards the cortex, forming incomplete arches between the cortex and the medulla (fig. 277, *a*). The branches of the renal vein form similar but more complete arches (*g*). From the arterial arches vessels pass through the cortex (*interlobular arteries, b*), and give off at intervals small arterioles (*efferent vessels of the glomeruli*), each of which enters the dilated commencement of a uriniferous tubule, within which it forms a glomerulus. From the glomerulus a somewhat smaller *efferent vessel* passes out, and this at once again breaks up into capillaries, which are distributed amongst the tubules of the cortex (*e*); their blood is collected by veins which accompany the arteries and join the venous arches between the cortex and the medulla, receiving in their course

¹The part of the cortex between and surrounding the medullary rays is so named.

certain other veins which arise by radicles having a somewhat stellate arrangement near the capsule (*venæ stellulae*, *j*).

The medulla derives its blood-supply from special offsets of the arterial arches, which almost immediately break up into pencils of fine straight arterioles running in groups between the straight tubules of the medulla. These arterioles gradually break up into a capillary network with elongated meshes which pervades the medulla (fig. 277, *f*), and which terminates in a plexus of somewhat larger venous capillaries in the papillæ. From these and from the other capillaries the veins collect the blood, and pass, accompanying the straight arterioles, into

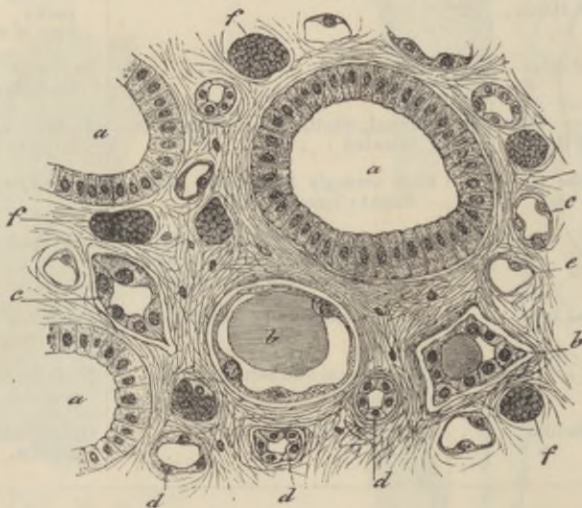


FIG. 276.—SECTION ACROSS A PAPILLA OF THE KIDNEY. (Cadiat.)

a, large collecting tubes (ducts of Bellini); *b*, *c*, *d*, tubules of Henle; *e*, *f*, blood-capillaries.

the venous arches between the cortex and medulla. The groups of small arteries and veins (*vasa recta*) in the part of the medulla nearest to the cortex alternate with groups of the uriniferous tubules, and this arrangement confers a striated aspect upon this portion of the medulla (*boundary zone*, fig. 278, *g*).

The efferent vessels of those glomeruli which are situated nearest to the medulla may also break up into pencils of fine vessels (*false arteriæ rectæ*) and join the capillary network of the medulla (fig. 277, *d*).

Between the uriniferous tubules, and supporting the blood-vessels, is a certain amount of connective tissue (fig. 276), within which are cleft-like spaces from which the lymphatics of the organ originate.

Nerve-fibrils have been described as ramifying amongst the epi-

thelium-cells of the tubules, but it is probable that most of the nerves of the kidneys are distributed to the arterioles.

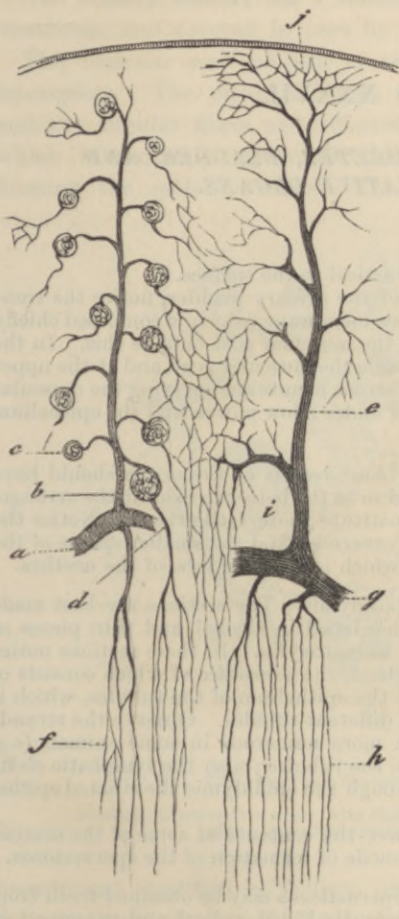


FIG. 277.—VASCULAR SUPPLY OF KIDNEY.
(Cadiat.) Diagrammatic.

a, part of arterial arch; *b*, interlobular artery; *c*, glomerulus; *d*, efferent vessel passing to medulla as false arteria recta; *e*, capillaries of cortex; *f*, capillaries of medulla; *g*, venous arch; *h*, straight veins of medulla; *j*, vena stellata; *i*, interlobular vein.

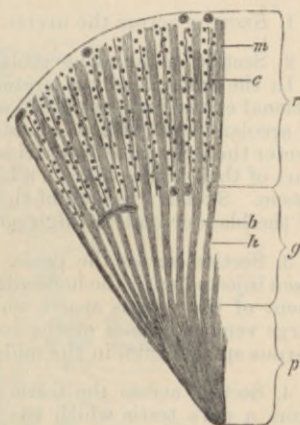


FIG. 278.—SECTION THROUGH PART OF THE DOG'S KIDNEY. (Ludwig.)

p, papillary, and *g*, boundary zones of the medulla; *r*, cortical layer; *h*, bundles of tubules in the boundary layer, separated by spaces, *b*, containing bunches of vessels (not here represented), and prolonged into the cortex as the medullary rays, *m*; *c*, intervals of cortex, composed chiefly of convoluted tubules, with irregular rows of glomeruli, between the medullary rays.

LESSON XXXVII.

*STRUCTURE OF THE URETER, BLADDER, AND
MALE GENERATIVE ORGANS.*

1. SECTION across the ureter.

2. Section of the urinary bladder vertical to the surface.

In the sections of the ureter and of the urinary bladder, notice the transitional epithelium resting on a mucous membrane, which is composed chiefly of areolar tissue without glands, and the muscular coat outside this. In the ureter there is some fibrous tissue outside the muscular coat, and at the upper part of the bladder there is a layer of serous membrane covering the muscular tissue. Sketch a section of the ureter under a low power, and the epithelium of the bladder under a high power.

3. Section across the penis. The blood-vessels of the organ should have been injected with the hardening fluid so as the better to exhibit the arrangement of the venous spaces which constitute the erectile tissue. Notice the large venous sinuses of the corpora cavernosa and the smaller spaces of the corpus spongiosum, in the middle of which is seen the tube of the urethra.

4. Section across the testis and epididymis. The sections are best made from a rat's testis which has been hardened in alcohol, and thin pieces of which have been stained in bulk in hæmatoxylin. In these sections notice the strong capsule surrounding the gland, the substance of which consists of tubules which are variously cut, and the epithelium of the tubules, which is in different phases of development in different tubules. Observe the strands of polyhedral interstitial cells much more numerous in some animals (*e.g.* cat), lying in the loose tissue between the tubules; also the lymphatic clefts in that tissue. Notice in sections through the epididymis the ciliated epithelium of that tube.

Sketch carefully under a high power the contents of some of the seminiferous tubules so as to illustrate the mode of formation of the spermatozoa.

5. Examination of spermatozoa. Spermatozoa may be obtained fresh from the testis or seminal vesicles of a recently killed animal and examined in saline solution. Their movements may be studied on the warm stage; to display their structure a very high power of the microscope is necessary. Measure and sketch three or four spermatozoa.

The **ureter** is a muscular tube lined by mucous membrane. The *muscular coat* consists of two layers of plain muscular tissue, an outer circular, and an inner longitudinal. In the lower part there are some longitudinal bundles external to the circular. Outside the muscular coat is a *layer of fibrous tissue* in which the blood-vessels and nerves ramify before entering the muscular layer.

The *mucous membrane* is composed of areolar tissue and is lined by transitional epithelium.

The **urinary bladder** has a muscular wall lined by a strong mucous membrane and covered in part by a serous coat.

The *muscular coat* consists of three layers, but the innermost is incomplete. The principal fibres run longitudinally and circularly, and the circular fibres are collected into a layer of some thickness which immediately surrounds the commencement of the urethra, forming the *sphincter vesicæ*. The *mucous membrane* is lined by a

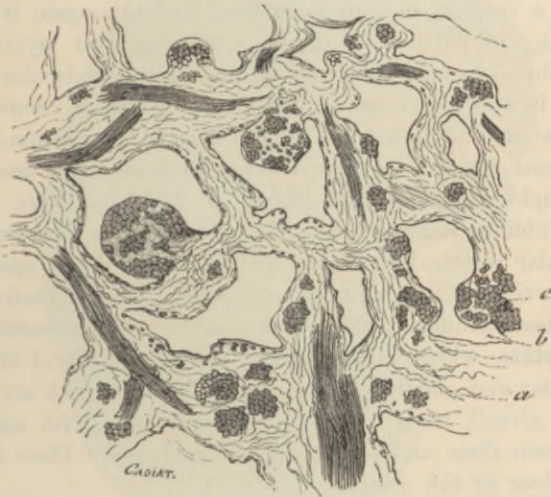

FIG. 279.—SECTION OF ERECTILE TISSUE. (Cadiat.)

a, trabeculae of connective tissue, with elastic fibres, and bundles of plain muscular tissue, some cut across (*c*); *b*, venous spaces.

transitional stratified epithelium like that of the ureter. The shape and structure of the cells have already been studied (Lesson VII.).

The *nerves* to the bladder form gangliated plexuses, and are distributed mainly to the muscular tissue and blood-vessels, but some are said to enter the epithelium.

The **penis** is mainly composed of cavernous tissue which is collected into two principal tracts—the *corpora cavernosa*, one on each side, and the *corpus spongiosum* in the middle line inferiorly. All these are bounded by a strong capsule of fibrous and plain muscular tissue, containing also many elastic fibres and sending in strong septa or trabeculae of the same tissues, which form the boundaries of the cavernous spaces of the erectile tissue (fig. 279). The arteries of

the tissue run in these trabeculæ, and their capillaries open into the cavernous spaces. On the other hand, the spaces are connected with efferent veins. The arteries of the cavernous tissue may sometimes in injected specimens be observed to form looped or twisted projections into the cavernous spaces (*helicine arteries of Müller*).

Urethra.—The cross-section of the urethra appears in the middle of the corpus spongiosum in the form of a transverse slit. It is lined in the prostatic part by transitional, but elsewhere by columnar epithelium, except near its orifice, where the epithelium is stratified. In the female urethra it is stratified throughout. The epithelium rests upon a vascular mucous membrane, and this again is supported by a coating of submucous tissue, containing two layers of plain muscular fibre—an inner longitudinal and an outer circular. Outside this again is a close plexus of small veins which is connected with, and may be said to form part of, the corpus spongiosum.

The *mucous membrane* of the urethra is beset with small mucous glands, simple and compound (*glands of Littré*). There are also a number of oblique recesses termed *lacunæ*. Besides these small glands and glandular recesses, two compound racemose glands open into the bulbous portion of the urethra (*Cowper's glands*). Their acini are lined by clear columnar cells which yield a mucous secretion.

The **prostate**, which surrounds the commencement of the urethra, is a muscular and glandular mass, the glands of which are composed of tubular alveoli, lined by columnar epithelium, with smaller cells lying between them and the basement-membrane. Their ducts open upon the floor of the urethra.

The integument of the penis contains numerous special nerve end-organs of the nature of end-bulbs, and Pacinian bodies are also found upon the nerves. Lymphatic vessels are numerous in the integument of the organ and also in the submucous tissue of the urethra.

The **testicle** is inclosed by a strong fibrous capsule, the *tunica albuginea* (fig. 280, *b*). This is covered externally with a layer of serous epithelium reflected from the *tunica vaginalis*. From its inner surface there proceed fibrous processes or *trabeculæ*, which imperfectly subdivide the organ into lobules, and posteriorly the capsule is prolonged into the interior of the gland in the form of a mass of fibrous tissue, which is known as the *mediastinum* (fig. 280, *f*). Attached to the posterior margin of the body of the gland is a mass (*epididymis*) which when investigated is found to consist of a single convoluted tube, receiving at its upper end the *efferent ducts* of the testis and prolonged at its lower end into a thick-walled

muscular tube, the *vas deferens*, which conducts the secretion to the urethra.

The glandular substance of the testicle is wholly made up of *convoluted tubules*, which when unravelled are of very considerable length. Each commences near the tunica albuginea, and after many windings terminates, usually after joining one or two others, in a *straight tubule*, which passes into the mediastinum, and there forms

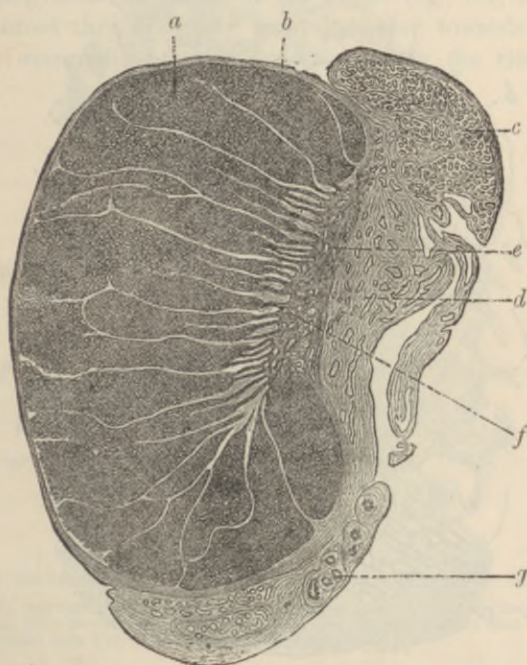


FIG. 280.—SECTION OF HUMAN TESTIS AND EPIDIDYMIS, SOMEWHAT MAGNIFIED.
(Böhm and v. Davidoff.)

a, glandular substance divided into lobules by septa, *f*, of connective tissue; *b*, tunica albuginea; *c*, head of epididymis; *d*, middle part or body of epididymis; *f*, mediastinum giving origin to the septa; *g*, sections of the commencing vas deferens.

by uniting with the other straight tubules, a network of intercommunicating vessels, which is known as the *rete testis*. From the rete a certain number of efferent tubules arise, and after a few convolutions pass into the tube of the epididymis.

Structure of the tubules.—The *seminiferous tubules* are formed of a thick basement-membrane, and contain several layers of epithelium-cells. Of these layers, the one next to the basement-membrane is a stratum of clear cubical cells (*lining epithelium-cells, spermatogonia*,

fig. 286, *a*), the nuclei of which, for the most part, exhibit the irregular network which is characteristic of the resting condition, but in certain tubules they show indications of division. Here and there these epithelium-cells appear enlarged, and project between the more internal layers, being connected with groups of developing

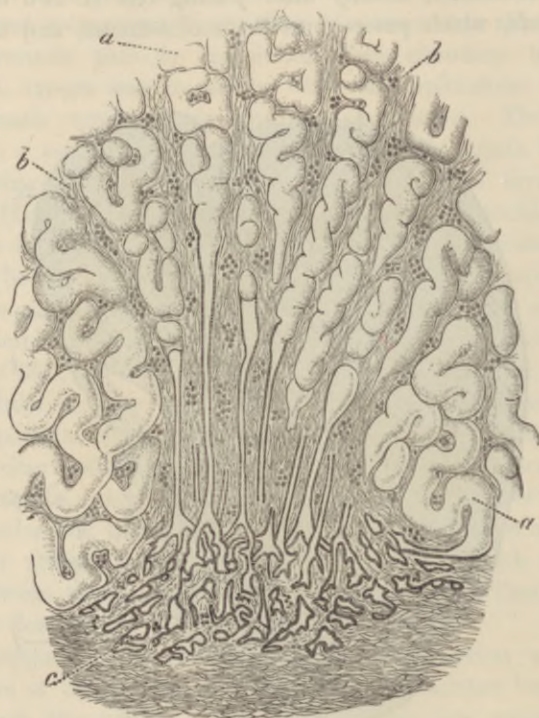


FIG. 281.—PASSAGE OF CONVOLUTED SEMINIFEROUS TUBULES INTO STRAIGHT TUBULES AND OF THESE INTO THE RETE TESTIS. (Mihalkowicz.)

a, seminiferous tubules; *b*, fibrous stroma continued from the mediastinum testis; *c*, rete testis.

spermatozoa. These enlarged cells may be termed *sustentacular cells* (fig. 286, *a'*).¹

Next to this epithelium is seen a zone of larger cells (*spermatogenic cells*, *spermatocysts*, fig. 286, *b*), the nuclei of which are usually in some stage of karyokinetic division; these cells may be two, three, or more deep (as in *a*, fig. 282). Next to them, and most internal,

¹These are the 'spermatoblasts' of some authors—a name given to them on the erroneous supposition that they directly produce the spermatozoa. The term 'spermatoblast' is more applicable to the small cells (spermatids) of the third layer or zone.

are to be seen in some tubules (fig. 282, *b* and *c*) a large number of small protoplasmic cells with simple spherical nuclei (*spermatoblasts*, or *spermatids*, fig. 286, *c*). In other tubules these cells are elongated, and the nucleus is at one end, and in others again these elongated cells are converted into evident spermatozoa, which lie in groups with their heads projecting between the deeper cells and connected with one of the enlarged cells of the lining epithelium, and their tails emerging into the lumen of the tubule (fig. 282, *b*). As they become matured they gradually pass altogether towards the lumen, where they eventually become free (*c*). During the time that this

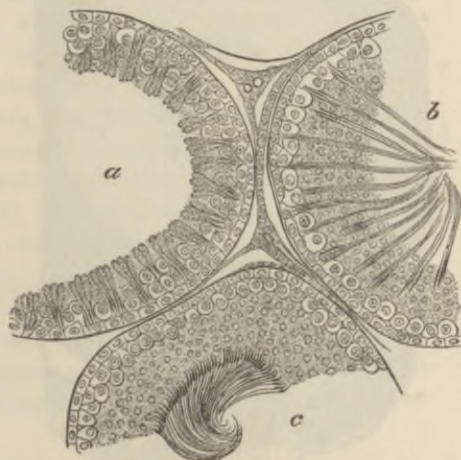


FIG. 282.—SECTION OF PARTS OF THREE SEMINIFEROUS TUBULES OF THE RAT.

a, with the spermatozoa least advanced in development; *b*, more advanced; *c*, containing fully developed spermatozoa. Between the tubules are seen strands of interstitial cells with blood-vessels and lymph-spaces.

crop of spermatozoa has been forming, another set of spermatoblasts has been produced by the division of the spermatogenic cells, and on the discharge of the spermatozoa the process is repeated as before.

The *straight tubules* which lead from the convoluted seminiferous tubes into the rete testis (fig. 281) are lined only by a single layer of clear flattened or cubical epithelium. The tubules of the rete also have a simple epithelial lining, but the basement-membrane is here absent, the epithelium being supported directly by the connective tissue of the mediastinum.

The *efferent tubules* which pass from the rete to the epididymis, and the *tube of the epididymis* itself, are lined by columnar ciliated epithelium, the cilia being very long; these tubes have a considerable amount of plain muscular tissue in their wall.

The *vas deferens* (fig. 283) is a thick tube, the wall of which is formed of an outer thick layer of longitudinal bundles of plain muscular tissue; within this an equally thick layer of circular bundles of the same tissue, and within this again a layer of longitudinal muscle. The tube is lined by a mucous membrane, the inner surface of which is covered by columnar non-ciliated epithelium.

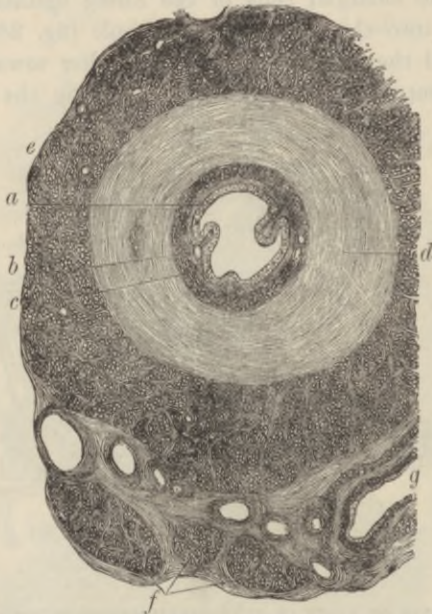

FIG. 283.—SECTION ACROSS THE COMMENCEMENT OF THE VAS DEFERENS.
(Klein.)

c, epithelium; *b*, mucous membrane; *c*, *d*, *e*, inner, middle, and outer layers of the muscular coat; *f*, bundles of the internal cremaster muscle; *g*, section of a blood-vessel.

The *ampullæ* of the vas deferentia, and the *vesiculæ seminales*, are in structure similar to the vas deferens, but their corrugated walls are much thinner and less muscular.

The connective tissue between the tubules of the testis is of very loose texture, and contains numerous lymphatic clefts, which form an intercommunicating system of commencing lymphatic vessels. Lying in this intertubular tissue are strands of polyhedral epithelium-like cells (*interstitial cells*, see fig. 282) of a yellowish colour; they are much more abundant in some species of animals (cat, boar) than in others. They accompany the blood-vessels before these break up to form the capillary networks which cover the walls of the seminiferous tubules.

The **spermatozoa**.—Each spermatozoon consists of three parts, a *head*, a *middle part* or *body*, and a long tapering and vibratile *tail*. In man (fig. 284) the head is of a flattened oval shape, somewhat more flattened and pointed anteriorly; a small barb-like projection has been described at its extremity (Dowdeswell). The *middle-piece* is short and cylindrical, and appears to have a spiral fibre passing round it. The tail is the longest part of the spermatozoon, and when examined with the microscope in the fresh condition is seen to be in continual vibratile motion, the action resembling that of the cilia of a ciliated epithelium-cell. The extremity of the tail (*end-piece*) forms a distinct part of the spermatozoon, and in some animals may become split up into two or three fibrils; these can also sometimes be traced along the whole length of the tail. Human spermatozoa are about 0.06 mm. ($\frac{1}{4000}$ inch) long. In different animals the shape of the head and the extent of middle-piece and tail vary greatly (fig. 285). In the rat (fig. 287, 7) the head is long, and is recurved anteriorly; it is set obliquely on the middle-piece, which is also of considerable extent, and has a closely wound spiral filament encircling it (H. H. Brown). In the newt

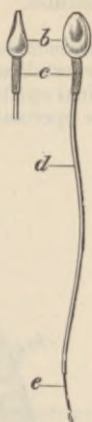

FIG. 284.—HUMAN SPERMATOOZA. 10,000. (Retzius.)

1, in profile; 2, viewed on the flat; b, head; c, middle piece; d, tail; e, end-piece of the tail, which is described as a distinct part by Retzius.

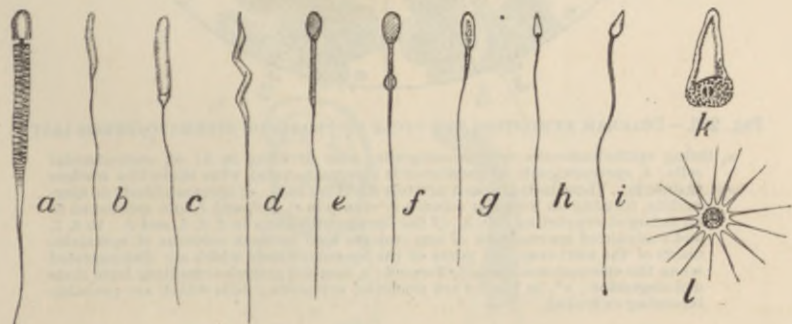


FIG. 285.—DIFFERENT FORMS OF SPERMATOOZA. (From Verworn.)

a, of bat; b, c, of frog; d, of finch; e, of ram; f, g, of boar; h, of a jelly-fish; i, of a monkey; l, of crab; k, of round-worm.

the head is long and tapering, and the tail appears to have a membranous expansion, attached in a spiral manner along its whole length. This has also been described in the human

spermatozoon, but its existence here is doubtful. In arthropods which possess no cilia, the spermatozoa have no vibratile tail. Sometimes two distinct kinds of spermatozoa are met with in the same species of animal.

Spermatogenesis.—The spermatozoa are developed from the small cells (spermatoblasts, spermatids) which form the innermost stratum of the seminal epithelium, and these are themselves produced by the division of the large spermatogenic or mother-cells (spermatocysts) of the second layer. It

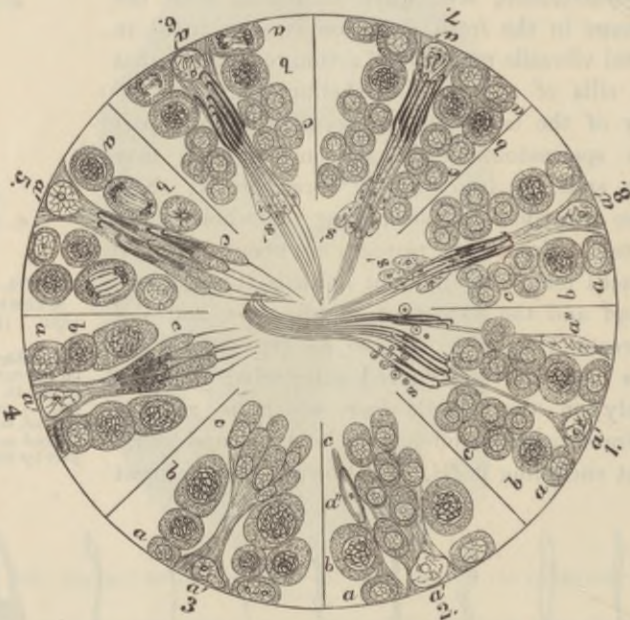

FIG. 286.—DIAGRAM EXHIBITING THE CYCLE OF PHASES OF SPERMATOGENESIS (RAT).

a, lining epithelium-cells or spermatogonia, seen dividing in 6; *a'*, sustentacular cells; *b*, spermatogenic or mother-cells (spermatocysts), with skin-like nuclear filaments. These cells are seen actively dividing in 5. *c*, spermatoblasts or spermatids, forming an irregular column or clump in 6, 7, 8, and 1, and connected to an enlarged supporting cell, *a'*, of the lining epithelium in 2, 3, 4, and 5. In 6, 7, and 8 advanced spermatozoa of one crop are seen between columns of spermatoblasts of the next crop. *s'*, parts of the spermatoblasts which are disintegrated when the spermatozoa are fully formed; *s*, seminal granules resulting from their disintegration; *a''*, in 1 and 2 are nuclei of supporting cells which are probably becoming extruded.

is probable that these mother-cells again are formed by division of some of the lining epithelium-cells or spermatogonia. The cycle of changes therefore which appears to take place is as follows:—1. Division of a lining epithelium-cell into two, one of which becomes a spermatocyst, and passes into the second layer, while the other remains in the first layer, undergoes enlargement, and becomes a sustentacular cell. 2. Division of the spermatocyst. 3. Further division and multiplication of the spermatocysts and the conversion of the resulting daughter-cells into a group of spermatoblasts (spermatids).

4. Elongation of the spermatoblasts and their gradual conversion into mature spermatozoa. As they undergo this conversion their grouping becomes more evident, and each group is found to be connected with a sustentacular cell,

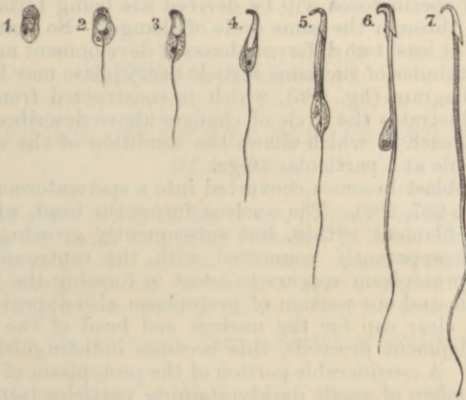


FIG. 287.—SPERMATOBLASTS FROM THE RAT IN DIFFERENT STAGES OF DEVELOPMENT. (H. H. Brown.)

1-6, developing spermatozoa from the testicle; 7, a mature spermatozoon from the vas deferens. The remains of the protoplasm of the cell, which is seen in 6 still adhering to the middle piece of the spermatozoon and containing a number of dark granules, is thrown off as the spermatozoon matures.

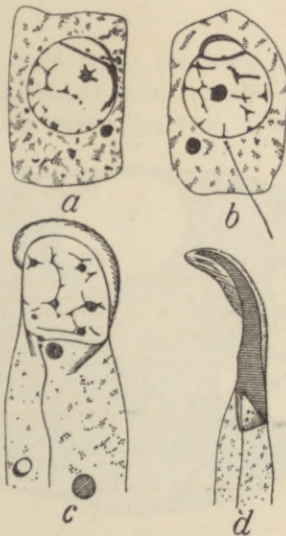


FIG. 288.—CHANGES IN THE SPERMATIDS IN THE COURSE OF FORMATION OF THE SPERMATOZOEA. (Lenhossék.)

a, b, c, d, four stages of transformation; from the rat. The tail filament is seen to extend from the centrosome, which lies close to the nucleus. The head-cap is seen in *c, d*.

which probably ministers to their nutrition. This cell undergoes a gradual process of elongation so that the spermatozoa by the time they are fully developed are brought to the lumen of the tube, in which they then become free. In the meantime other alternate groups of daughter-cells from which the next crop of spermatozoa will be derived are being formed in the same manner, passing through the same cycle of changes. So that in a section of the same tubule, at least two different phases of development may be observed, and in different tubules of the same testicle every phase may be traced. The accompanying diagram (fig. 286), which is constructed from drawings by H. H. Brown, illustrates the cycle of changes above described: it is divided into eight parts, each of which shows the condition of the epithelium of a seminiferous tubule at a particular stage.

Each spermatoblast becomes converted into a spermatozoon in the following manner (figs. 287, 288). The nucleus forms the head, while the tail develops as a fine filament within, but subsequently growing out from, the protoplasm, and apparently connected with the centrosome of the cell (fig. 288). The protoplasm appears to assist in forming the middle piece of the spermatozoon, and one portion of protoplasm also appears from an early stage to form a clear cap for the nucleus and head of the spermatozoon; but as the development proceeds, this becomes indistinguishable from the rest of the head. A considerable portion of the protoplasm of each spermatid containing a number of small darkly staining particles (seminal granules) always becomes detached and disintegrated before the spermatozoon is fully mature (fig. 286, *s, s*).

LESSON XXXVIII.

GENERATIVE ORGANS OF THE FEMALE AND MAMMARY GLANDS.

1. SECTIONS of the ovary of the rabbit or cat. Study the sections with a low power, observing the small and large Graafian follicles, each inclosing an ovum, scattered through the stroma. Measure some Graafian follicles of different sizes; make a general sketch of a section under the low power. Then sketch carefully two or more of the follicles with their contents.

2. Sections across the Fallopian tube. Sketch a section under the low power.

3. Section across the body of the uterus. Observe with the naked eye the thickness of the muscular and mucous coats respectively. Notice the ciliated columnar epithelium lining the organ and extending into the glands of the mucous membrane. Draw a part of the section under the low power.

4. Sections of the mammary gland from an animal killed during lactation. Notice the fat-globules in the alveoli and also in the alveolar cells. Draw an alveolus under the high power.

The **ovary** is a small solid organ, composed of a *stroma* of fibrous tissue, with many spindle-shaped cells, and also containing, especially near its attachment to the broad ligament, a large number of plain

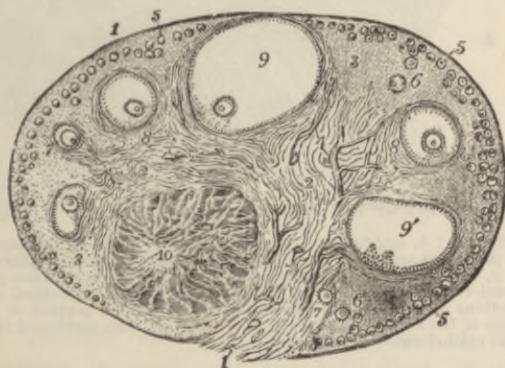


FIG. 289.—SECTION OF THE OVARY OF THE CAT. ♀. (Schron.)

- 1, outer covering and free border of the ovary; 1', attached border; 2, the central ovarian stroma, showing a fibrous and vascular structure; 3, peripheral stroma; 4, blood-vessels; 5, Graafian follicles in their earliest stages lying near the surface; 6, 7, 8, more advanced follicles which are embedded more deeply in the stroma; 9, an almost mature follicle containing the ovum in its deepest part; 9', a follicle from which the ovum has fallen out in preparing the section; 10, corpus luteum.

muscular fibres. It is covered by a layer of small columnar epithelium-cells (*germinal epithelium*, fig. 290, *a*), between which may here and there be seen a few larger spheroidal cells, with large round nuclei.

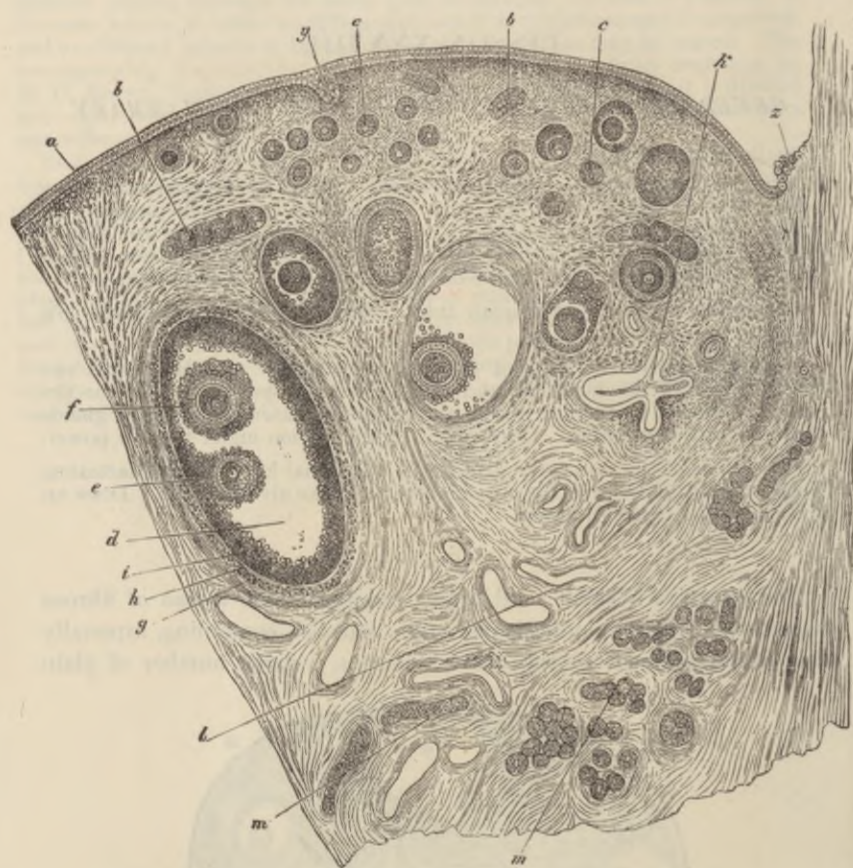


FIG. 290.—SECTION OF THE OVARY OF AN ADULT BITCH. (Waldeyer.)

a, germ-epithelium; *b*, egg-tubes; *c, c*, small follicles; *d*, more advanced follicle; *e*, discus proligerus and ovum; *f*, second ovum in the same follicle (this occurs but rarely); *g*, outer tunic of the follicle; *h*, inner tube; *i*, membrana granulosa; *k*, collapsed retrograded follicle; *l*, blood-vessels; *m, m*, longitudinal and transverse sections of tubes of the parovarium; *y*, involuted portion of the germ-epithelium of the surface; *z*, place of the transition from peritoneal to germinal or ovarian epithelium.

In the young subject the epithelium may occasionally dip down into the subjacent stroma.

The stroma is beset with vesicles of different sizes, the smallest being near the surface of the organ, the larger ones placed more

deeply in the stroma, although, as they increase in size, they may extend towards the surface.

These vesicles are the *Graafian follicles*. Each Graafian follicle has a proper wall (*theca folliculi*) formed of a layer derived from the

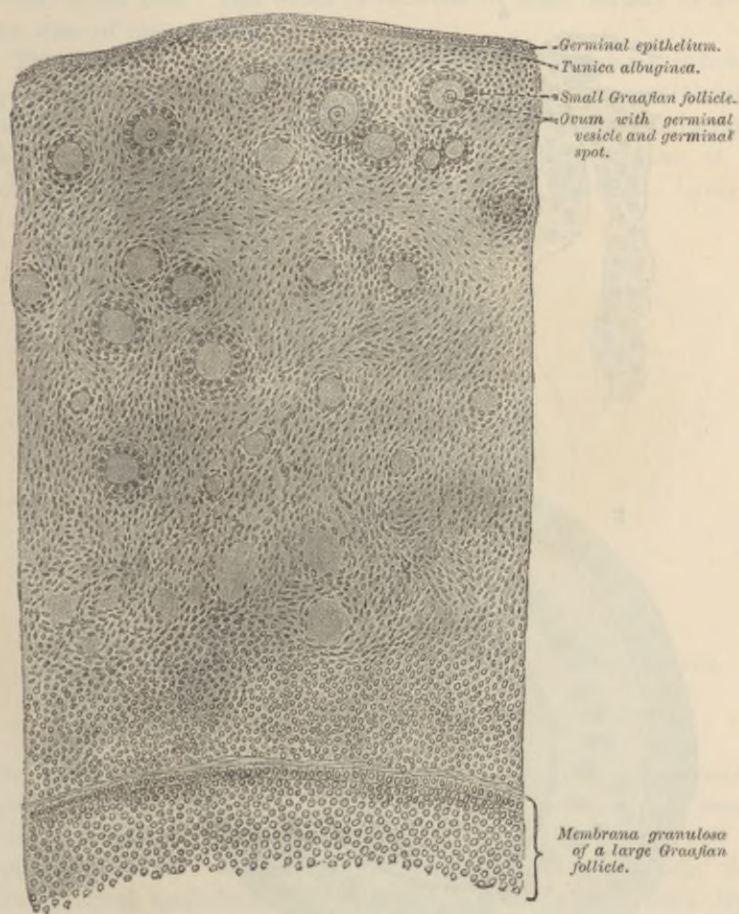


FIG. 291.—SECTION OF PART OF OVARY OF A YOUNG GIRL. $1\frac{1}{2}^{\circ}$.
(Böhm and v. Davidoff.)

stroma, and contains an *ovum* and *epithelium*. In the smallest follicles the ovum is small, and the epithelium of the follicle is formed of a single layer of cells, which may be flattened against the ovum. In somewhat larger follicles the epithelium-cells are in two layers, and these are columnar in shape (fig. 292). In still larger ones, each of these two layers is formed of several strata of cells,

and fluid has begun to collect between the layers at one part. Of the two layers, the one which lines the cavity of the follicle is termed the *membrana granulosa*, while the mass of cells which more immediately surrounds the ovum is known as the *discus proligerus*.

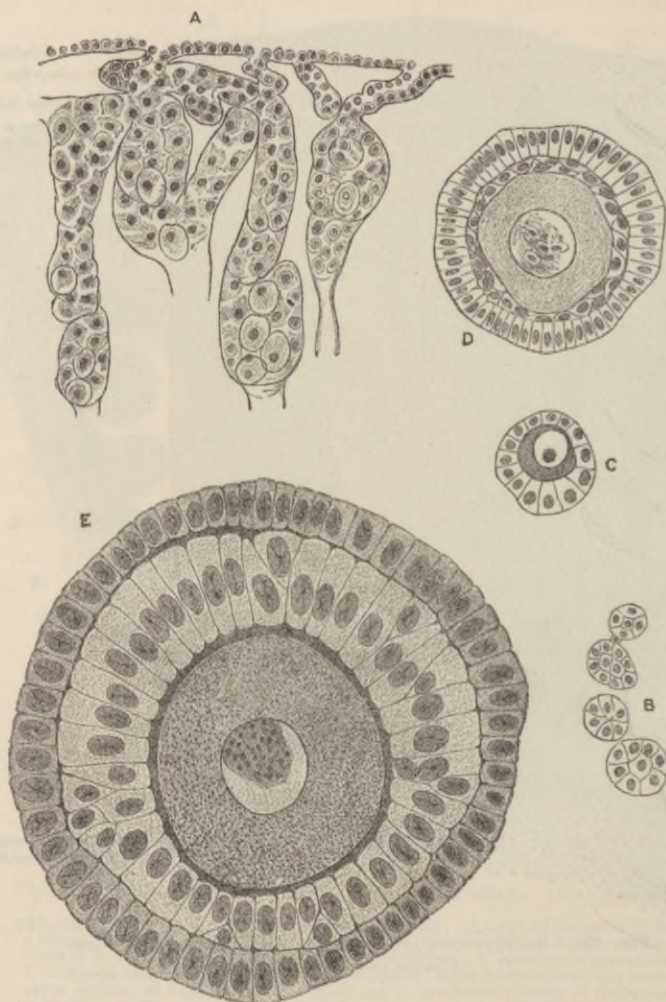


FIG. 292.—FIGURES SHOWING VARIOUS STAGES IN THE DEVELOPMENT OF THE GRAAFIAN FOLLICLES.

- A, from ovary of young rabbit, showing "egg-tubes" of Pitger growing in from germinal epithellum; some of the tubes contain primitive ova; B, primitive Graafian follicles formed from the breaking up of an egg-tube; C, a young Graafian follicle, with a single layer of follicle-epithelium; D, a somewhat older follicle, with the second layer forming within the first; E, a more advanced follicle, showing two complete layers of columnar epithelium surrounding the ovum within the follicle.

In the largest follicles the fluid has much increased in amount, so that the follicle has become gradually larger and more tense. Finally it reaches the surface of the ovary, and projects from that surface, where it eventually bursts, and the liquor folliculi, with its contained ovum, is set free. This event is believed to occur usually at about the time of menstruation.¹

The ova are large spheroidal cells (fig. 293), about 0.2 mm. ($\frac{1}{125}$ inch) in diameter. When mature, as in the largest Graafian follicles, each ovum is surrounded by a thick transparent striated membrane (*zona pellucida*). Within this is the protoplasm of the cell (*vitellus*), filled with fatty and albuminous granules. Lying in

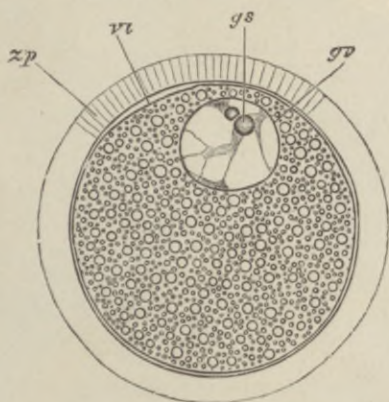


FIG. 293.—SEMI-DIAGRAMMATIC REPRESENTATION OF A MAMMALIAN OVUM.
(Highly magnified.)

zp, zona pellucida; vi, vitellus; gv, germinal vesicle; gs, germinal spot.

the vitellus, generally eccentrically, is the large clear round nucleus (*germinal vesicle*), which contains an intranuclear network, and usually one well-marked nucleolus (*germinal spot*). Both the ova and the epithelium of the Graafian follicles are developed originally from the germinal epithelium. In the embryo, this forms a thick layer, covering the fibrous and vascular stroma. After a time solid cords of epithelium-cells, which in some animals are partly tubular (*egg-tubes* of Pflüger), grow down into the stroma, whilst this at the same time grows into the epithelium. The cords presently become broken up by the ingrowths of stroma into small isolated nests of epithelium-cells, each of which may represent a Graafian follicle. To form the

¹ Some of the Graafian follicles do not burst, but, after attaining a certain stage of maturity, undergo a process of retrograde metamorphosis and eventually disappear.

ova, some of the germinal epithelium-cells become enlarged, and usually there is one such enlarged cell in each of the isolated nests. The remaining cells form the epithelium of the follicle (see fig. 292).

The stroma of the ovary contains, besides the spindle-shaped connective-tissue cells and plain muscular fibres already mentioned, a number of epithelium-like *interstitial cells*, like those found in the intertubular tissue of the testis. They are most abundant near the hilum. *Corpora lutea* may also be seen in the stroma. These are

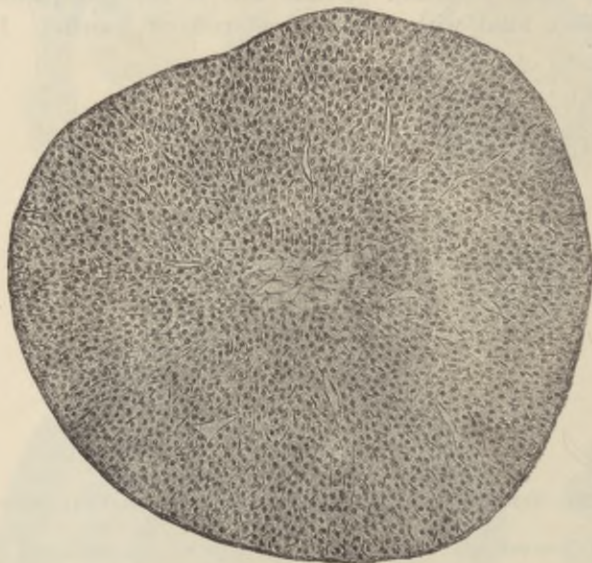


FIG. 294.—CORPUS LUTEUM OF MOUSE. (Sobotta.)

large yellow nodules, which are developed out of the Graafian follicles after the ovum has been extruded. They consist of columns of large yellowish cells, with intervening vascular fibrous tissue, which converge to a central strand of connective tissue occupying the axis of the nodule (fig. 294). The columns of cells are not unlike those of the cortex of the suprarenal capsule. The corpus luteum is derived from the wall (? epithelium) of the follicle, which becomes thickened and folded by multiplication and hypertrophy of its cells; between the folds connective tissue and blood-vessels grow in towards the centre, and in this way the columnar arrangement above mentioned is produced. After persisting for a time the corpus luteum gradually disappears, its tissue becoming merged in the surrounding stroma.

Corpora lutea grow much larger and remain much longer persistent in the event of pregnancy supervening.

The **Fallopian tubes** are lined by a very vascular mucous membrane which is covered with ciliated epithelium, and has numerous longitudinal folds (fig. 295). Externally they are covered by a serous coat, within which is a thin longitudinal layer of plain muscular fibres overlying circular fibres of the same tissue.

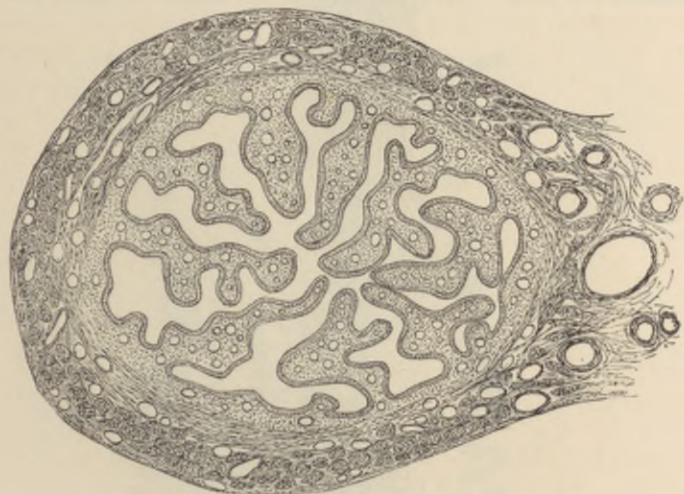


FIG. 295.—SECTION ACROSS THE FALLOPIAN TUBE.

The **uterus** is usually described as composed of two parts, the body and cervix. The wall of the uterus is formed of the following layers:

1. A *serous layer*, derived from the peritoneum, which covers the greater part of the fundus.

2. A *muscular layer*, which is of considerable thickness and is formed of plain muscular fibres disposed in two strata. Of these the outer has its fibres arranged partly longitudinally, partly circularly. The inner muscular layer, on the other hand, is thick; its fibres run in different directions, but chiefly circularly, and it is prolonged internally into the deeper part of the mucous membrane, the extremities of the uterine glands extending between and amongst its fibres. It is imperfectly separated from the thinner external layer by the ramifications of the larger blood-vessels, and, according to some authorities, represents a much-hypertrophied muscularis mucosæ.

3. A *mucous membrane*, which is very thick and is composed of soft

connective tissue containing a large number of spindle-shaped cells. It contains long, simple, tubular glands, which take a curved or convoluted course in passing through the membrane (fig. 296). They are lined by ciliated epithelium continuous with that which covers

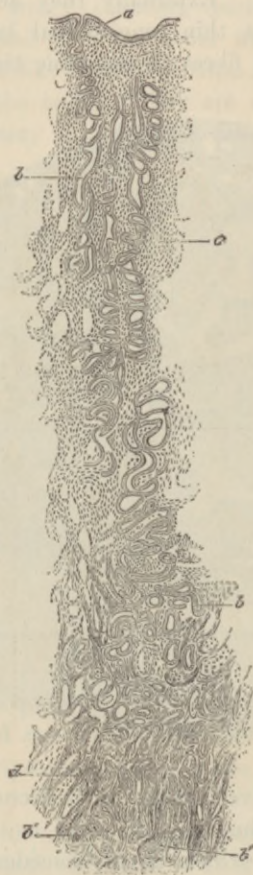

FIG. 296.—SECTION OF THE MUCOUS MEMBRANE OF THE HUMAN UTERUS.
(J. Williams.)

a, epithelium of surface; *b*, *b*, glands; *b'*, their ends amongst the muscular fibres, *d*, in the deeper part of the mucous membrane; *c*, interglandular tissue.

the inner surface of the mucous membrane. In the cervix the mucous membrane is marked by longitudinal and oblique ridges, and the glands are shorter than those of the body of the uterus. Near the os uteri the epithelium becomes stratified and overlies vascular papillæ of the corium. The mucous membrane is exceedingly vascular, and it also contains a large number of lymphatic vessels.

In many animals the uterus is composed of two long tubes (cornua uteri), and the arrangement of the muscular tissue in these is simpler than in the human uterus, which has been formed by the fusion of two such tubes. Fig. 297 exhibits the structure of a cornu of the uterus of a rabbit.

At each menstrual period the mucous membrane of the uterus undergoes a partial process of disintegration accompanied by an escape of blood from the capillaries of the membrane. This is succeeded by

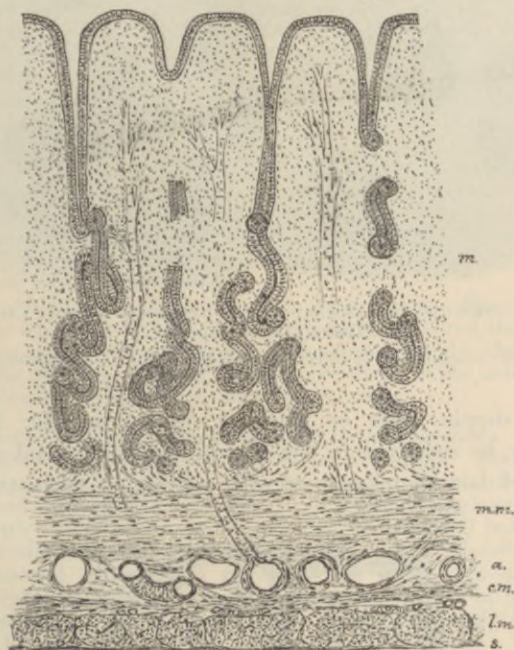


FIG. 297.—SECTION OF THE MUCOUS MEMBRANE OF THE RABBIT'S UTERUS.

s, serous layer; *l.m.*, longitudinal muscular fibres; *c.m.*, circular muscular fibres of the muscular coat; *a*, areolar tissue, with large blood-vessels; *m.m.*, muscularis mucosae; *m*, mucous membrane.

a rapid renewal of the disintegrated part. Should gestation supervene, the process of renewal results in the formation of a greatly thickened mucous membrane, with long convoluted glands, which is then known as the decidua.

The **mammary glands** are compound racemose glands which open by numerous ducts upon the apex of the nipple. The ducts are dilated into small reservoirs just before reaching the nipple. If traced backwards, they are found as in other compound racemose

glands to commence in groups of saccular alveoli (fig. 298). The walls of the ducts and alveoli are formed of a basement-membrane.

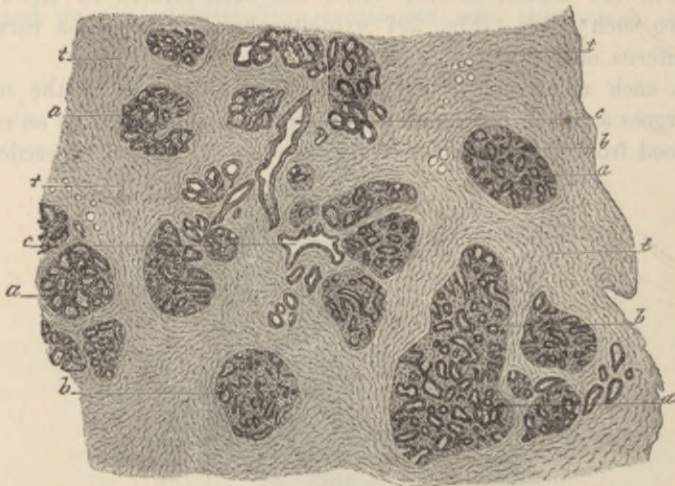

FIG. 298.—SECTION OF MAMMARY GLAND OF WOMAN DURING LACTATION. (Testut after de Sinéty.)

a, lobule of gland; *b*, acini lined by cubical epithelium; *c*, duct; *t*, connective-tissue stroma.

lined by a simple layer of flattened epithelium (fig. 299). Milk globules may be seen within the alveoli and ducts, and at the commencement of lactation amœboid cells containing fat-particles appear

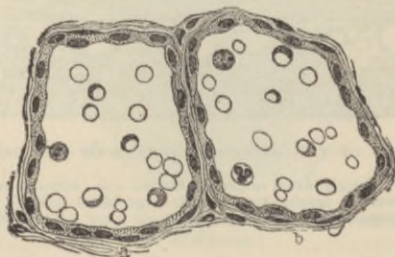


FIG. 299.—ALVEOLI OF THE MAMMARY GLAND OF THE BITCH. (Heidenhain.)

in the secretion (*colostrum corpuscles*). These are probably emigrated lymph-corpuscles similar to the salivary corpuscles of saliva, but they are believed by some authorities to be detached epithelium-cells.

LESSON XXXIX.

STRUCTURE OF THE SPINAL CORD.

1. SECTIONS of the spinal cord from the cervical, dorsal, and lumbar regions. As it is difficult to obtain the human spinal cord sufficiently fresh, that of a dog, cat, or monkey may be used. It is to be hardened by suspending it immediately after removal from the body in a tall jar of Müller's fluid (see Appendix). After a few hours the fluid is changed, and the cord is then left for about a month, when it will be ready for sections. These are to be made either with the freezing microtome or by the celloidin method. They may be stained by the modified Weigert-Pal method given in the Appendix, or by aniline blue-black. The latter stains the nerve-cells and axis-cylinders, the former the medullary sheath of the nerve-fibres. Carminate of ammonia may also be employed to stain the nerve-cells and axis-cylinders.

Notice the relative extent of the grey as compared with the white matter in the different regions of the cord.

Sketch a section from each region under a low power. Sketch also a small portion of the white substance, two or three nerve-cells, and the central canal with its lining epithelium and surrounding neuroglia under the high power.

Measure the diameter of some of the nerve-fibres in the anterior columns, in the lateral columns, and in the posterior columns.

2. Structure of the nerve-cells in the cord (Nissl's method). Place a small piece of spinal cord in 90 per cent. alcohol for a few days. Stain the sections in a 1 per cent. solution of eosin or erythrosin for 20 minutes; then rinse with water and transfer to a 1 per cent. solution of methylene-blue in water shaken up with aniline oil, the solution being heated until bubbles begin to form. Rinse the sections with absolute alcohol until almost all the blue colour is removed, after which they may be passed through xylol and mounted in xylol balsam. The angular granules (p. 104) in the protoplasm of the cell-bodies and in the dendrons are made manifest by the blue: the eosin stains the remainder of the protoplasm.

3. Tracts in the spinal cord. The conducting tracts of the spinal cord may be studied in two ways, viz.: (1) by preparing sections of embryonic cords (from the 5th to the 9th month), the sections being stained by the modified Weigert-Pal process; (2) by preparing sections from the cord of an animal in which either a complete section or a hemi-section has been performed about ten days before the animal is killed, and staining small pieces of the cord from below and from above the section by placing them in a solution consisting of two parts of Müller's fluid and one part of 1 per cent. osmic acid (Marchi's method). The cord must first be partly hardened by placing it for a few days in Müller's fluid.

The spinal cord is composed of grey matter in the centre and of white matter externally. It is closely invested by a layer of connective-tissue containing numerous blood-vessels (*pia mater*), and less closely

by two other membranes (fig. 300). One of these is an areolar membrane, resembling a serous membrane in general structure, but non-vascular and more delicate in texture (*arachnoid*). The other, which lines the vertebral canal, is a strong fibrous membrane known as the *dura mater*. At the middle of the anterior and posterior (ventral and dorsal) surfaces the pia mater dips into the substance of the cord in the *anterior* and *posterior median fissures*, so as to divide it almost completely into two lateral halves. These are, however, united by an isthmus or bridge, which is composed anteriorly of transversely crossing white fibres (*white commissure*), posteriorly of grey matter (*grey commissure*),

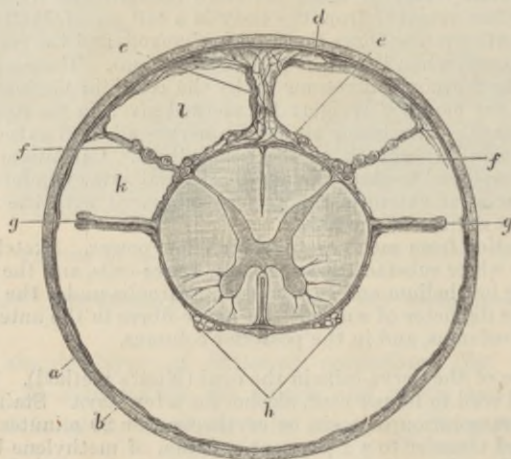


FIG. 300.—SECTION OF THE SPINAL CORD WITHIN ITS MEMBRANES.
(Key and Retzius.)

a, dura mater; *b*, arachnoid; *c*, septum of arachnoid; *d, e*, trabeculae of arachnoid; *g*, ligamentum denticulatum; *f*, bundles of posterior root; *h*, bundles of anterior root; *k, l*, subarachnoid space.

in the middle of which is a minute canal lined by ciliated epithelium (*central canal*).

Each lateral half of the spinal cord contains a crescent of grey matter, which is joined to the corresponding crescent of the opposite side by the grey commissure. Of the two cornua of the crescent the posterior or dorsal is the narrower and comes near the surface of the cord; opposite to it the bundles of the posterior nerve-roots enter the cord. The bundles of the anterior nerve-roots enter the anterior cornu.

The *white matter* of each half of the cord is subdivided by the passage of the nerve-roots into the cornua into three principal columns—*anterior, lateral, and posterior*. In the upper part of the cord the posterior column is subdivided by a septum of connective tissue into

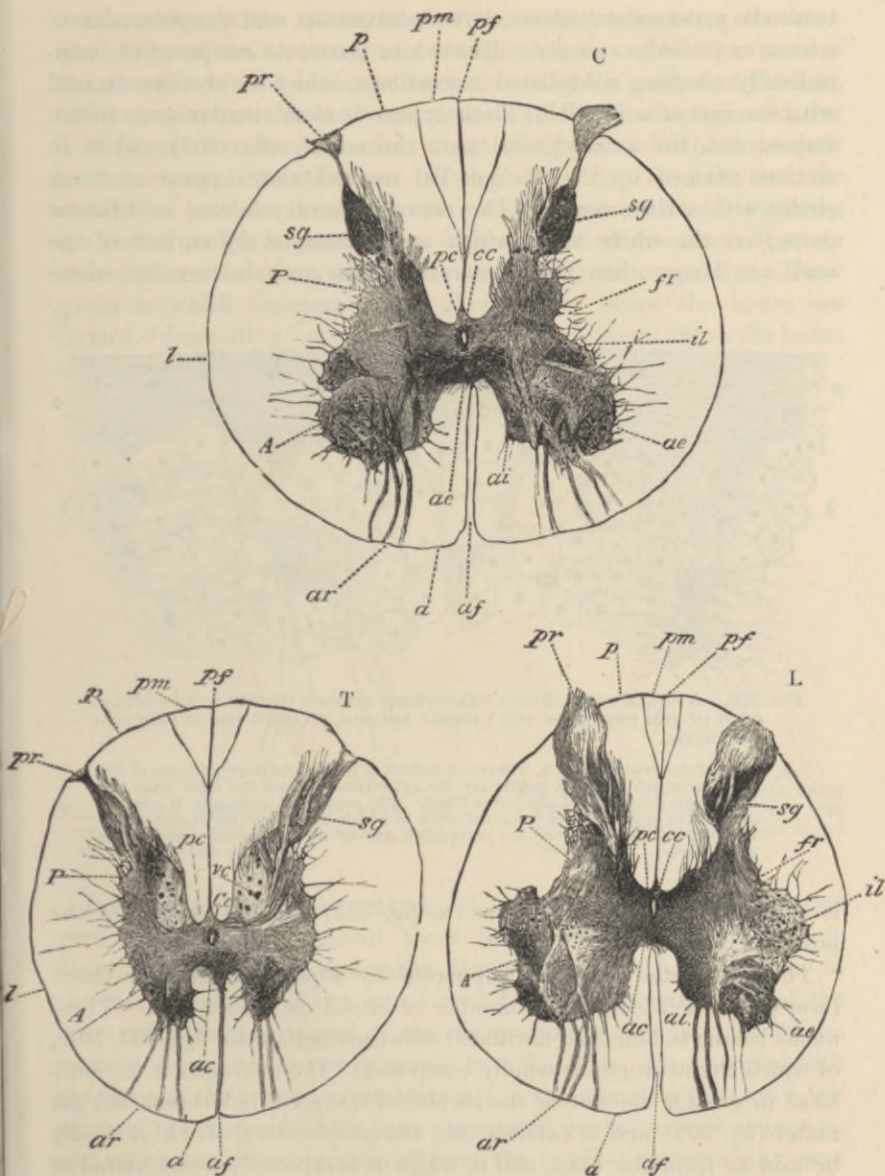


FIG. 301.—TRANSVERSE SECTIONS OF MONKEY'S SPINAL CORD. (Bevan Lewis.)¹

C, from the cervical region; T, from the thoracic region; L, from the lumbar region.

A, anterior cornu; P, posterior cornu; a, anterior column; l, lateral column; p, posterior column; ac, anterior commissure; ae, ai, external and internal cell-groups of anterior cornu; af, anterior median fissure; ar, anterior roots; cc, central canal; fr, formatio reticularis; il, lateral group of cells; vc, vesicular column of Clarke; pc, posterior commissure; pf, posterior median fissure; pm, postero-mesial column; pr, posterior roots; sg, substantia gelatinosa.

¹ Taken by permission of the author from Ferrier's *Functions of the Brain*.

two—the *postero-mesial column* or *funiculus gracilis*, and the *postero-lateral column* or *funiculus cuneatus*. The white matter is composed of longitudinally coursing medullated nerve-fibres, which in sections stained with carmine or aniline blue-black appear as clear circular areas with a stained dot, the axis-cylinder, near the middle (fig. 302); while in sections stained by the Weigert-Pal method they appear as black circles with a clear centre. The nerve-fibres vary in size in different parts; on the whole those which are nearest to the surface of the cord are larger than those nearest to the grey matter, but there

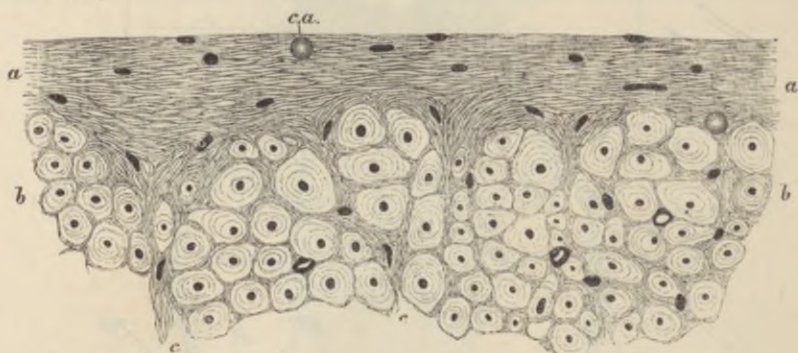


FIG. 302.—A SMALL PORTION OF A TRANSVERSE SECTION OF THE HUMAN SPINAL CORD IN THE REGION OF THE LATERAL COLUMN, TO SHOW THE SUPERFICIAL NEUROGLIA.

a, a, superficial neuroglia; *b, b*, transverse section of part of the lateral column of the cord, in which the dark points are the axis-cylinders, and the clear areas the medullary substance of the nerve-fibres. The superficial neuroglia is seen to exhibit the appearance of a fine feltwork in which numerous nuclei and one or two *corpora amylacea*, *c.a.*, are embedded, and to extend inwards among the nerve-fibres.

is a bundle of very small fibres (*M*, fig. 305) opposite the tip of the posterior horn.

The medullated fibres are supported by a peculiar reticular tissue (*neuroglia*) which contains a number of nuclei embedded in it. These nuclei belong to branched fibrillated cells (*neuroglia-cells*, figs. 303, 304), of which the neuroglia is wholly composed. The neuroglia is accumulated in greater amount at the surface of the cord underneath the pia mater (fig. 302), and it extends into the grey matter, of which it may be said to form the basis, and in which it is especially accumulated at the apex (*caput*) of the posterior horn (where it forms the *substantia gelatinosa* of Rolando) and around the central canal.

The *grey matter*, besides neuroglia, consists of an interlacement of nerve-fibres and of the branching processes of the nerve-cells which are embedded in it.

Disposition of the nerve-fibres of the white columns in tracts.—The course of the nerve-tracts in the spinal cord, and in other parts of the central nervous system, can be made out by the method of Flechsig, which consists in the study of sections of the developing cord, for it is found that the formation of medullary substance occurs sooner in some tracts than in others, so that it is easy to make out the distinction between them. Another method consists in investigating the course which is pursued by degenerations of the nerve-fibres in consequence of lesions produced accidentally or purposely. Those tracts in which degeneration of fibres occurs below the lesion are termed "descending" tracts; those in which it occurs above the lesion are termed "ascending."

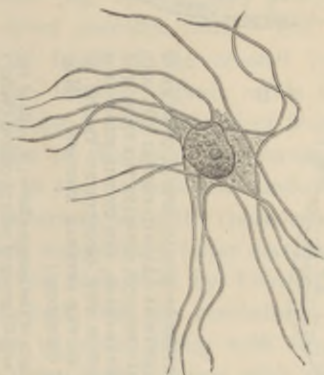


FIG. 303.—A NEUROGLIA CELL FROM THE SPINAL CORD, ISOLATED IN 33 PER CENT. ALCOHOL. (Ranvier.)

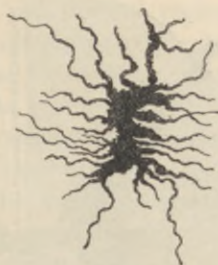

FIG. 304.—A NEUROGLIA CELL FROM THE WHITE SUBSTANCE OF THE SPINAL CORD SHOWN BY THE GOLGI METHOD.

Investigated by these methods, it is found that at the posterior part of the lateral column there is a tract of moderately large fibres, intermingled with smaller fibres, which are found to run in the lateral column of the spinal cord from the opposite side of the brain, after having crossed at the decussation of the pyramids of the medulla oblongata (*crossed pyramidal tract*, fig. 305). Intermingled with the fibres of the crossed pyramidal tract in the lateral column are a few fibres of the pyramid which have not crossed in the medulla oblongata, and which are therefore derived from the cerebral cortex of the same side. The large fibres which lie in the anterior columns next to the anterior median fissure, in the upper part of the human cord, also belong to a portion of the same tract which has not undergone decussation (*direct pyramidal tract*).¹ The relatively small fibres of the postero-

¹This is not found in the lower animals.

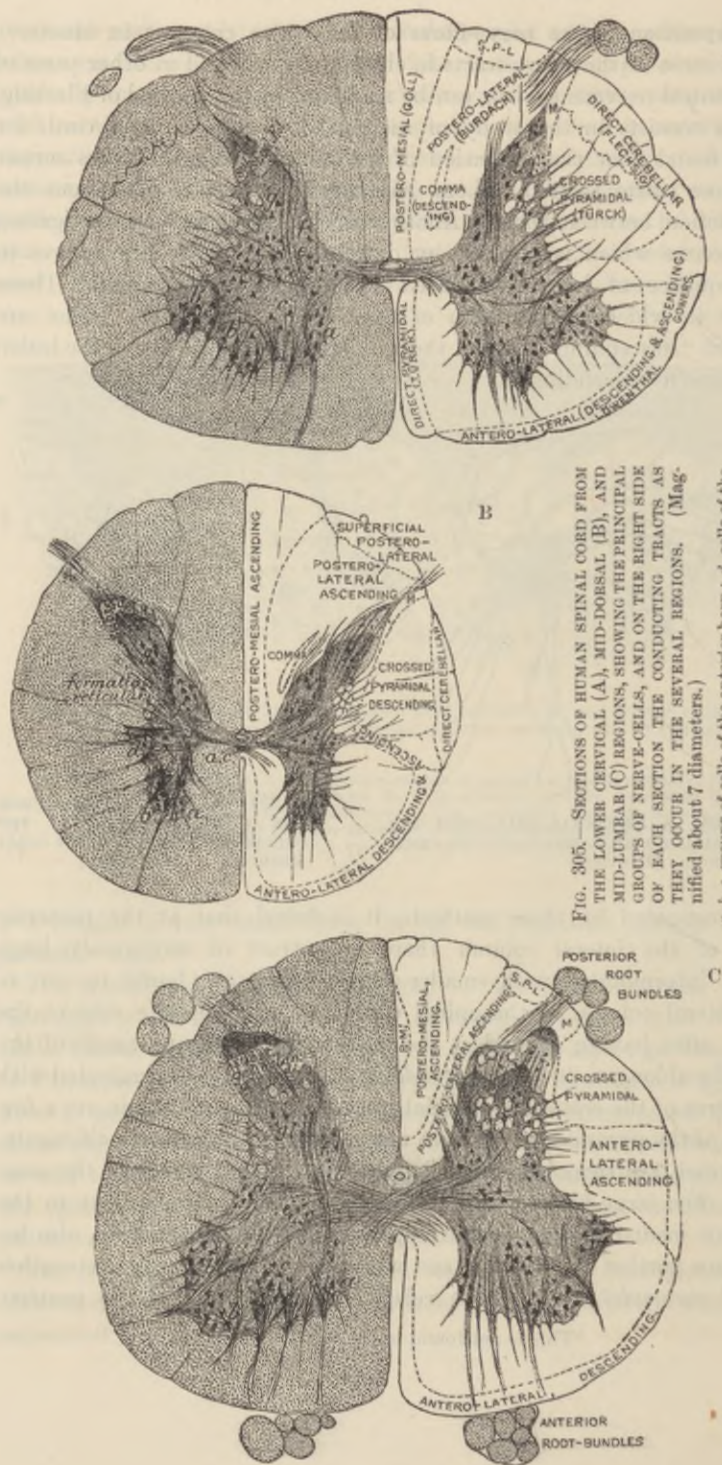


FIG. 305.—SECTIONS OF HUMAN SPINAL CORD FROM THE LOWER CERVICAL (A), MID-DOESAL (B), AND MID-LUMBAR (C) REGIONS, SHOWING THE PRINCIPAL GROUPS OF NERVE-CELLS, AND ON THE RIGHT SIDE THEY OCCUR IN THE SEVERAL REGIONS. (Magnified about 7 diameters.)

a, b, c, groups of cells of the anterior horn; *d*, cells of the lateral horn; *e*, middle group of cells; *f, g*, cells of Clarke's column; *g*, cells of posterior horn; *e, e*, central canal; *a, c*, anterior commissure.

mesial column belong to a tract, known as the *tract of Goll* (fig. 305), which consists of fibres derived below from the posterior nerve-roots and postero-lateral column, and ending above in the grey matter of the funiculus gracilis of the medulla oblongata. The postero-lateral column itself (*tract of Burdach*) is composed of the fibres of the posterior nerve-roots, which run for a short distance in it before entering the postero-mesial column or the grey matter of the cord. The fibres of this tract in the cervical region end in the grey matter of the funiculus cuneatus of the medulla oblongata. In the lateral column there are two other ascending tracts. One of these is only distinct in the cervical and dorsal regions. Here it lies external to the crossed pyramidal tract, and consists of large fibres which are derived from the cells of Clarke's column (fig. 305, *f*) and pass up into the cerebellum (*dorso-lateral* or *direct cerebellar tract*). The other one, situated more anteriorly, lies in front of the crossed pyramidal and direct cerebellar tracts in the lumbar region; while in the dorsal and cervical regions it forms also a narrow band of fibres curving round close to the external surface of the cord, and extending even into the anterior column. This is the *antero-lateral cerebellar tract* or *tract of Gowers*. Its fibres are intermingled with those of another tract (*antero-lateral descending*), which degenerates (after section of the tract) below the section, and was first described by Loewenthal. Both the ascending tracts are connected with the cerebellum, the tract of Gowers passing to that organ over and along with the superior cerebellar peduncle, whilst the dorso-lateral enters with the inferior peduncle. It is uncertain whether the antero-lateral descending tract is connected with the cerebellum, as stated by Marchi, or with cells in the medulla oblongata (Deiters' nucleus), but the latter is more probable. Lastly, there are two or three other small tracts of fibres, some of which degenerate above a section of the cord, others below. One of these, an ascending tract (*i.e.* undergoing degeneration above the point of section), is marked *M* in the figures. This is the *marginal bundle* of Lissauer, and is formed by fine fibres from the posterior roots. Another, placed in the postero-lateral column, is the so-called *comma tract*, degenerating for a few centimetres below the point of section. Other small portions of the posterior columns which are marked in the figure (fig. 305, *P.M.*' and *S.P.-L.*) are differentiated by the method of Flechsig, but their function is not known. They are probably short tracts uniting adjacent portions of the grey matter of the cord.

Disposition of the nerve-cells in the grey matter.—The nerve-cells which are scattered through the grey matter are in part disposed in definite groups. Thus there are two or three groups of

large multipolar nerve-cells in the anterior cornu; their axis-cylinder processes mostly pass out into the anterior nerve-roots (*cells of the anterior horn*, fig. 305, *a, b, c*). A well-marked group of large rounded nerve-cells, best marked in the thoracic region, lies at the base of the posterior horn (*Clarke's column*, fig. 305, *f*). The cells of Clarke's column send their axis-cylinder processes into the direct cerebellar tract (Mott). Another group is seen on the outer side of the grey matter lying in a projection which is sometimes known as the lateral

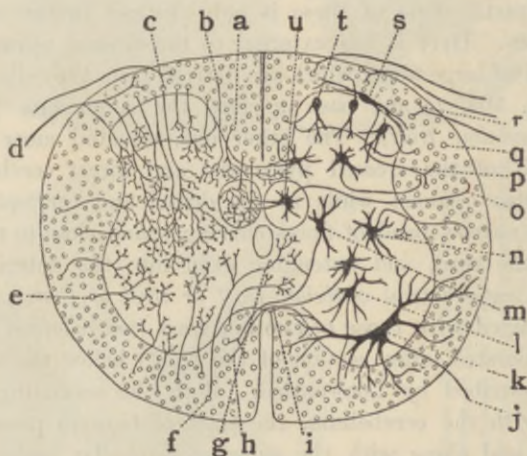


FIG. 306.—DIAGRAM SHOWING THE PROBABLE RELATIONS OF SOME OF THE PRINCIPAL CELLS OF THE CEREBRO-SPINAL SYSTEM TO ONE ANOTHER. (S. Ramón y Cajal.)

a, b, fibres of posterior column sending collaterals into the grey matter; *c, d*, fibres of posterior root entering posterior column; *e, f*, collaterals passing from lateral and anterior columns into grey matter; *g, h, i*, fibres of white commissure; *j*, anterior root-fibre springing from *k*, cell of anterior horn; *l, m, n*, other cells of grey crescent sending their neurons into the white matter; *o*, neuron of cell of Clarke's column passing into the dorsal cerebellar tract; *p*, neuron of cell of substantia gelatinosa; *q*, fibre of dorsal cerebellar tract; *r*, fibre of posterior root passing to tract of Lissauer; *s, t*, cells of substantia gelatinosa; *u*, cell of Clarke's column.

horn (*intermedio-lateral tract*, fig. 305, *d*). This is most distinct in the upper dorsal and lower cervical regions. Another group (*middle cell-group*) lies in the middle of the crescent (fig. 305, *e*). The cells of the posterior horn (*g*) are not collected into a special group.

Course of the nerve-roots in the spinal cord.—The *anterior roots* leave the anterior horn in a number of bundles (fig. 301, *ar*). Most of their fibres are directly continued from the nerve-cells there. On the other hand, these cells are surrounded by an interlacement of ramified nerve-endings, which are derived from various sources,

especially from the collaterals of the posterior root-fibres (see below), and from those of the fibres of the white columns.

The fibres of the *posterior roots* originate in the cells of the posterior root ganglia and pass into the postero-lateral column (see diagram, fig. 306), but the smallest fibres enter the marginal bundle of Lissauer,

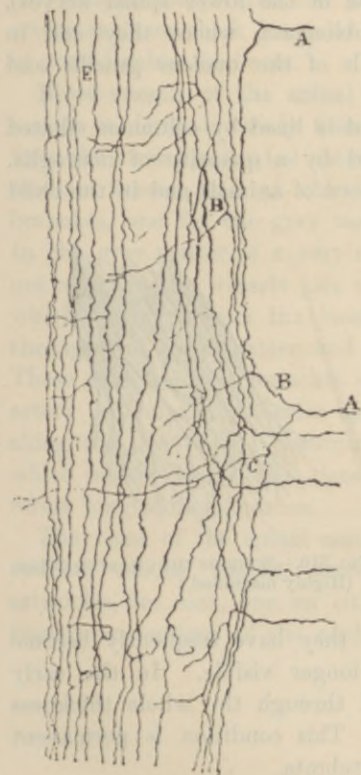


FIG. 307.—FROM A LONGITUDINAL SECTION OF SPINAL CORD, SHOWING THE ENTRANCE OF POSTERIOR ROOT-FIBRES. (S. Ramón y Cajal.)

A, A, fibres entering the postero-lateral column, and bifurcating into an ascending and descending division; B, C, collaterals passing from them into the grey matter; E, other fibres of the posterior white columns also giving off collaterals.

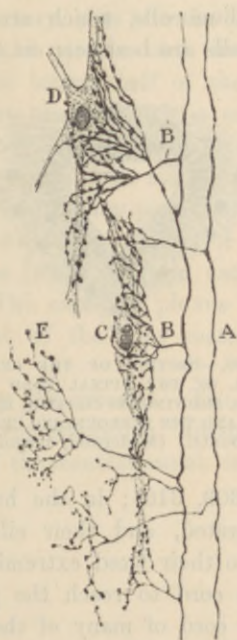

FIG. 308.—ARBORISATION OF COLLATERALS FROM THE POSTERIOR ROOT-FIBRES AROUND CELLS IN THE POSTERIOR HORN OF GREY MATTER. (S. Ramón y Cajal.)

A, fibres of posterior column derived from posterior root; B, collaterals; C, D, nerve-cells in grey matter surrounded by the arborisations of the collaterals; E, an arborisation shown separately.

and some pass into the posterior horn of grey matter. On entering the spinal cord the fibres bifurcate (fig. 307), one branch passing upward, the other downwards. Both from the main fibre and from its branches collateral fibres pass at frequent intervals into the grey matter, and end in arborisations of fibrils which envelop

the nerve-cells both of the posterior and of the anterior horn (fig. 308). The main fibres also for the most part ultimately end in a similar manner in the grey matter, some after a short course only, but others after a longer course. A certain number of the last named fibres pass upwards in the postero-lateral and postero-mesial columns (in the latter especially those of the lower spinal nerves), until they arrive at the medulla oblongata, where they end in terminal arborisations around the cells of the nucleus gracilis and nucleus cuneatus.

The **central canal** of the spinal cord is lined by columnar ciliated epithelium-cells, which are surrounded by a quantity of neuroglia. The cells are best seen in the spinal cord of animals and in the child

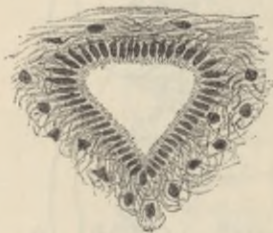

FIG. 309.—SECTION OF THE CENTRAL CANAL OF THE SPINAL CORD OF A CHILD, SHOWING ITS CILIATED EPITHELIUM AND THE SURROUNDING CENTRAL NEUROGLIA. (Moderately magnified.)

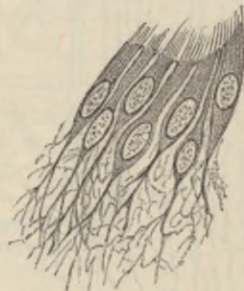

FIG. 310.—SOME OF THE CILIATED CELLS. (Highly magnified.)

(figs. 309, 310); in the human adult they have frequently become proliferated, and their cilia are no longer visible. In the early embryo their fixed extremities extend through the whole thickness of the cord to reach the pia mater. This condition is permanent in the cord of many of the lower vertebrata.

Characters of the spinal cord in the several regions (figs. 301, 305).—In the *cervical region* the white matter, especially that of the lateral columns, occurs in largest proportion. The grey matter, especially in the cervical enlargement, is in considerable amount, and it encroaches in the form of a network upon the adjacent part of the lateral white column. The anterior cornua are thick and the posterior slender. The postero-mesial column is distinctly marked off.

In the *dorsal region* the grey matter is small in amount, and both cornua are slender. The whole cord is smaller in diameter than either in the cervical or lumbar region. The column of nerve-cells known as Clarke's column, and the intermedio-lateral tract, are well marked.

In the *lumbar region* the crescents of grey matter are very thick, and the white substance, especially the lateral columns, relatively small in amount. The isthmus lies nearly in the centre of the cord, whereas in the cervical and dorsal regions it is nearer the anterior surface.

In the part of the spinal cord from which the *sacral* and *coccygeal* nerve-roots take origin the grey matter largely preponderates, the crescents form thick irregular masses, and the grey isthmus is also of considerable thickness.

Blood-vessels of the spinal cord.—The blood-supply of the grey matter is derived mainly from a series of arterioles, which come off from the mesially-situated anterior spinal artery, pass into the anterior median fissure, and at the bottom of this divide each into two branches, one for the grey matter of each lateral half of the cord. In the grey matter is a very close capillary plexus which is supplied not alone by the vessels just mentioned, but also by small arterioles, which converge from the small arteries of the pia mater, passing through the white matter, and supplying this as they pass through it. These arterioles are branches of the above-mentioned anterior spinal artery and of the posterior spinal arteries (which run on each side along the line of the posterior roots). The capillary plexus of the white matter is far less dense than that of the grey matter. It forms longitudinal meshes.

The veins of the spinal cord accompany the arteries. Two longitudinal venous vessels, accompanying corresponding anastomotic arterioles, are seen, one on either side of the central canal, in most transverse sections of the cord.

LESSON XL.

THE MEDULLA OBLONGATA.

SECTIONS of the medulla oblongata (made in the same way as with the spinal cord): (*a*) at the level of the decussation of the pyramids, (*b*) just above the decussation, (*c*) opposite the middle of the olivary body, and (*d*) either through the uppermost part of the olivary body, or just above it.

The structure of the **medulla oblongata** or **spinal bulb** can best be made out by the study of a series of sections taken from below upwards, and by tracing in these the changes which occur in the constituent parts of the spinal cord, taking note at the same time of any parts which may be superadded.

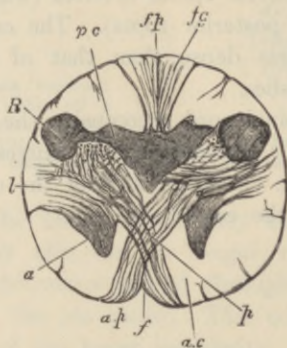


FIG. 311.—SECTION OF THE MEDULLA OBLONGATA AT THE MIDDLE OF THE DECUSSATION OF THE PYRAMIDS. $\frac{3}{4}$. (Lockhart-Clarke.)

f., anterior; *f.p.*, posterior fissure; *a.p.*, pyramid; *a.*, remains of part of anterior cornu, separated by the crossing bundles from the rest of the grey matter; *l.*, continuation of lateral column of cord; *R.*, continuation of substantia gelatinosa of Rolando; *p.c.*, continuation of posterior cornu of grey matter; *f.g.*, funiculus gracilis.

A section through the *region of the decussation of the pyramids* (fig. 311) has much the same form as a section through the upper part of the spinal cord, and most of the structures of the cord can be easily recognised. A considerable alteration of the grey matter is, however, produced by the passage of the large bundles of the crossed pyramidal tract (*p*) from the lateral column of the spinal cord on each side through the root of the anterior horn and across

the anterior median fissure to the opposite anterior column of the medulla oblongata, where, together with the fibres of the direct pyramidal tract, they constitute the prominent mass of white fibres which is seen on the front of the bulb, on each side of the middle line, and which is known as the *pyramid*. By this passage of fibres through the grey matter the tip of the anterior horn (*a*) is cut off from the rest and becomes pushed as it were to the side; in

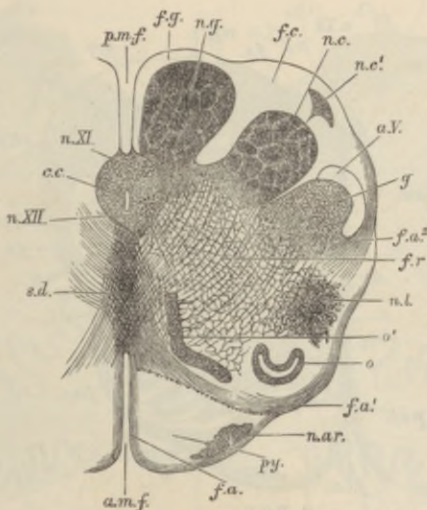


FIG. 312.—SECTION OF THE MEDULLA OBLONGATA IN THE REGION OF THE SUPERIOR PYRAMIDAL DECUSSATION. †. (Schwalbe.)

a.m.f., anterior median fissure; *f.a.*, superficial arciform fibres emerging from the fissure; *py.*, pyramid; *n.a.r.*, nucleus of the arciform fibres; *f.a'*, deep arciform fibres becoming superficial; *o.*, lower end of olivary nucleus; *o'*, accessory olivary nucleus; *n.l.*, nucleus lateralis; *f.r.*, formatio reticularis; *f.a.²*, arciform fibres proceeding from formatio reticularis; *g.*, substantia gelatinosa of Rolando; *a.V.*, ascending root of fifth nerve; *n.c.*, nucleus cuneatus; *n.c'*, external cuneate nucleus; *f.c.*, funiculus cuneatus; *n.g.*, nucleus gracilis; *f.g.*, funiculus gracilis; *p.m.f.*, posterior median fissure; *c.c.*, central canal surrounded by grey matter, in which are, *n.XI.*, nucleus of the spinal accessory; and *n.XII.*, nucleus of the hypoglossal; *s.d.*, superior pyramidal decussation (decussation of fillet).

sections a little higher up it appears as an isolated mass of grey matter which is known as the lateral nucleus (fig. 312, *n.l.*).

A change also occurs in the posterior horn in consequence of the increased development of the posterior column of white matter. This causes the posterior horns (fig. 311, *p c*) to be pushed towards the side, the V which they form with one another being thus opened out; at the same time the tip of the horn swells out and causes a prominence upon the surface of the medulla, which is known as the tubercle of Rolando (*R*). Grey matter also soon becomes formed within the upward prolongations of the gracile funiculus (postero-

mesial column) and of the cuneate funiculus (postero-lateral column, fig. 312, *n.g.*, *n.c.*). But most of the grey matter of the crescent becomes broken up, by the passage of bundles of nerve-fibres through it, into a reticular formation (*f.r.*) the production of which is already foreshadowed in the upper part of the spinal cord. The central canal of the spinal cord is still seen in the lower part of the medulla oblongata (*c.c.*), but it comes nearer to the posterior surface. The

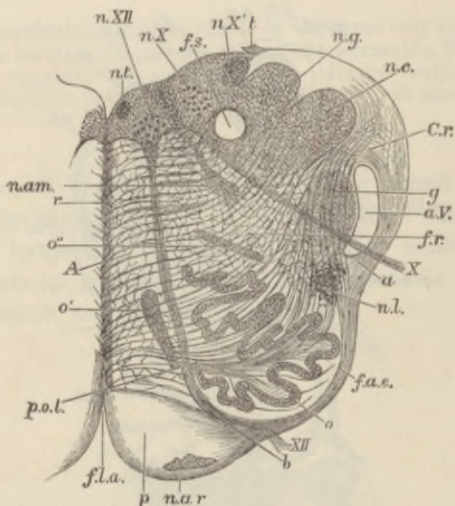


FIG. 313.—SECTION OF THE MEDULLA OBLONGATA AT ABOUT THE MIDDLE OF THE OLIVARY BODY. †. (Schwalbe.)

f.l.a., anterior median fissure; *n.a.r.*, nucleus arciformis; *p.*, pyramid; *XII.*, bundle of hypoglossal nerve emerging from the surface; at *b* it is seen coursing between the pyramid and the olivary nucleus, *o*; *f.a.e.*, external arciform fibres; *n.l.*, nucleus lateralis; *a.*, arciform fibres passing towards restiform body partly through the substantia gelatinosa, *g.*, partly superficial to the ascending root of the fifth nerve, *a.V.*; *X.*, bundle of vagus root, emerging; *f.r.*, formatio reticularis; *c.r.*, corpus restiforme, beginning to be formed, chiefly by arciform fibres, superficial and deep; *n.c.*, nucleus cuneatus; *n.g.*, nucleus gracilis; *t.*, attachment of the tenia; *f.s.*, funiculus solitarius; *n.X.*, *n.X't.*, two parts of the vagus nucleus; *n.XII.*, hypoglossal nucleus; *n.t.*, nucleus of the funiculus teres; *n.am.*, nucleus ambiguus; *r.*, raphe; *A.*, formatio reticularis alba; *o'*, *o''*, accessory olivary nuclei; *o.*, olivary nucleus; *p.o.l.*, pedunculus olivæ.

grey matter which surrounds it contains two well-marked groups of nerve-cells; the anterior (ventral) of these is the lower part of the nucleus of the hypoglossal or twelfth nerve (*n. XII.*), the posterior (dorsal) that of the spinal accessory or eleventh (*n. XI.*). Instead of the comparatively narrow isthmus which joins the two halves of the spinal cord, a broad raphe now makes its appearance; this is formed of obliquely and antero-posteriorly coursing fibres, together with some grey matter containing nerve-cells.

In the section at about the middle of the olive (figs. 313, 314), it

will be seen that a marked change has been produced in the form of the medulla oblongata and the arrangement of its grey matter, by the opening out of the central canal into the fourth ventricle. This causes the grey matter which lower down surrounded the central canal to be now spread out at the floor of that ventricle, and the collections of nerve-cells from which the hypoglossal and

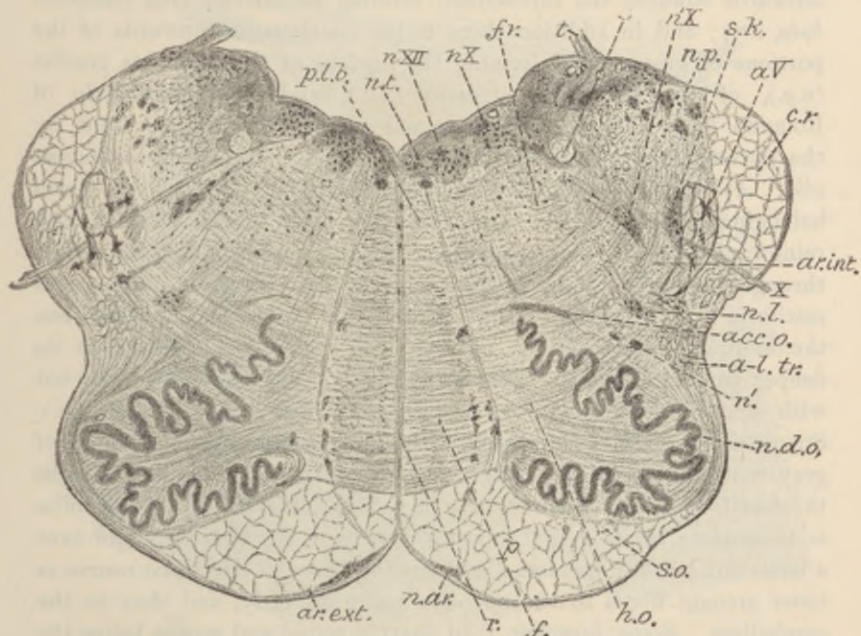


FIG. 314.—SECTION ACROSS THE MEDULLA OBLONGATA AT ABOUT THE MIDDLE OF THE OLIVARY BODY. (Magnified 5 diameters.)

r, raphe; f, fillet; ar.ext., fibræ arcuatæ externæ; n.ar., nucleus arcuatus; py, pyramid; n.d.o., nucleus dentatus olivæ; h.o., hilum olivæ; s.o., siliqua olivæ; acc.o., oliva accessoria; n.l., nucleus lateralis; n., portions of grey matter containing large cells, perhaps detached from the nucleus lateralis; a-l.tr., antero-lateral ascending tract; X, tenth nerve issuing from side of bulb; ar.int., fibræ arcuatæ internæ; a.V., ascending root of fifth nerve; s.k., substantia gelatinosa Rolandi; c.r., corpus restiforme; n.X., ventral nucleus of tenth nerve (nucleus ambiguus); n.p., nucleus posterior; s, fasciculus solitarius (ascending root of X. and IX. nerves); t, tenia (attachment of ependymal root of fourth ventricle); f.r., formatio reticularis; n.X., dorsal nucleus of tenth nerve; n.XII., upper part of nucleus of twelfth nerve; n.t., nucleus of funiculus teres; p.l.b., posterior or dorsal longitudinal bundle.

spinal accessory nerves respectively arise now, therefore, lie in a corresponding situation. At this level, however, the outer group which corresponds with the nucleus of the spinal accessory in the lower part of the bulb has become the *nucleus of the vagus* or tenth nerve (*n.X.*). The nerve-bundles of the roots of these nerves can be seen in the sections coursing through the thickness of the bulb and emerging, those of the hypoglossal (*XII.*) just outside the

pyramids, those of the spinal accessory and vagus (*X.*) at the side of the medulla oblongata. The two sets of emerging fibres thus appear to subdivide each lateral half of the bulb into three areas—a posterior, a middle, and an anterior. Of these the posterior is chiefly occupied by the grey matter of the floor of the fourth ventricle, and, with fibres which are passing obliquely upwards and outwards towards the cerebellum, forming its inferior crus (*restiform body, c.r.*); and in addition there is the continuation upwards of the portions of grey matter forming the nucleus of the funiculus gracilis (*n.g.*), of the funiculus cuneatus (*n.c.*), and of the tubercle of Rolando (*g.*). The anterior or mesial area is occupied in front by the pyramid (*p.*), and behind this by a reticular formation (*reticularis alba, A*) composed of longitudinally coursing bundles of fibres belonging mainly to the tract of the *fillet*, interlaced with and reinforced by fibres that are passing obliquely from the opposite side, through the raphe, towards the nuclei of the posterior columns and restiform body (figs. 314, 315). The middle area, which lies between the issuing bundles of the two sets of nerve-roots, consists in its deeper part of a similar reticular formation (figs. 313, 314, *f.r.*), but with more grey matter and nerve-cells (*reticularis grisea, fig. 315, r.g.*). Superficially there is developed within it a peculiar wavy lamina of grey matter containing a large number of small nerve-cells; this is the *dentate nucleus of the olivary body* (figs. 313, *o*, 314, *n.d.o.*). The lamina is incomplete at its mesial aspect (*hilum olive, fig. 314, h.o.*), and here a large number of fibres issue, and passing through the raphe course as inner arcuate fibres to the opposite restiform body, and thus to the cerebellum. Some, however, turn sharply round and course below the dentate nucleus, forming an investment and capsule to it (*siliqua olive, fig. 314, s.o.*), and passing towards the restiform body of the same side. Just dorsal, or dorso-lateral to the olive is the continuation upwards of the antero-lateral cerebellar tract of the spinal cord; the continuation of the dorsal cerebellar tract is now passing into the restiform body.

The *floor of the fourth ventricle* is covered by a layer of ciliated epithelium-cells, continuous below with those lining the central canal, and above, through the Sylvian aqueduct, with the epithelium of the third and lateral ventricles. The epithelium rests upon a layer of neuroglia known as the *ependyma* of the ventricle. The fourth ventricle is roofed over by a thin layer of pia mater, with projecting choroid plexuses, the under surface of which is covered by a thin epithelial layer continuous at the side with the ciliated epithelium of the floor. The roof becomes somewhat thickened as it is continued into the ependymal layer of the floor of the ventricle; this thickened part

(*tænia* or *ligula*, figs. 313, 314, *t*) is often left attached when the thin epithelial roof is removed along with the pia mater which covers it.

A section taken through the uppermost part of the olivary prominence will still show very much the same form and structural arrangements as that just described. The nucleus of the hypoglossal (fig. 316, *n.XII.*)

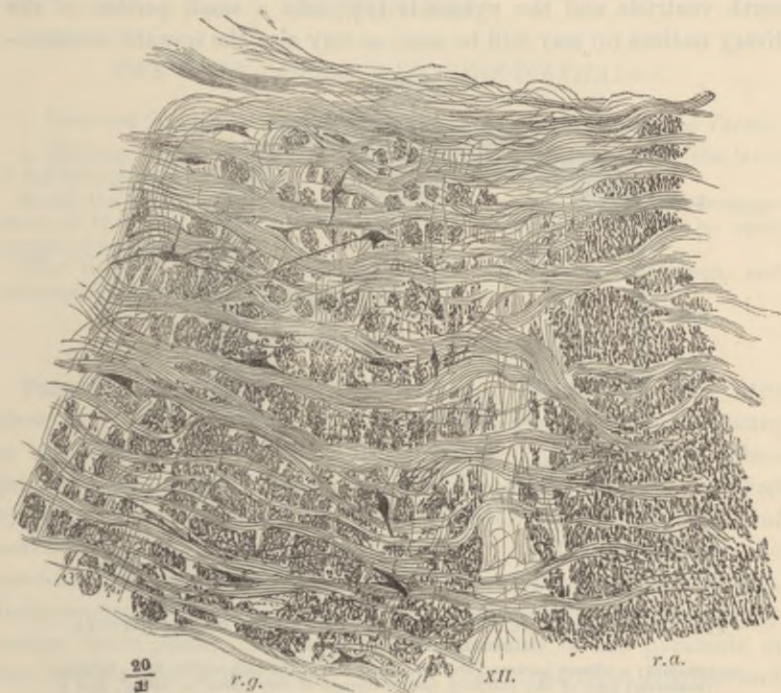


FIG. 315.—PART OF THE RETICULAR FORMATION OF THE MEDULLA OBLONGATA. (Henle.)

r.a., reticularis alba, without nerve-cells; *r.g.*, reticularis grisea, with large nerve-cells; between them a root-bundle of the hypoglossus (*XII.*). The longitudinal fibres of the reticular formation are cut across; the transversely coursing fibres are internal arcuate fibres, passing on the right of the figure towards the raphe.

is still visible in the grey matter of the floor of the ventricle, but the nerve which is now seen arising from the outer part of that grey matter is the eighth or *auditory* (*VIII.*), the bundles of which, as they leave the bulb, embrace the inferior crus of the cerebellum (*corpus restiforme, c.r.*), which is now passing into that organ. The origin of the eighth nerve is thus subdivided into two principal parts, known respectively as the dorsal or lateral and the ventral or mesial roots. The fibres of the dorsal root inclose amongst them numerous ganglion cells; this root becomes the cochlear or true auditory division of the eighth nerve. The ventral root, which becomes the vestibular division

of the eighth nerve, is connected with a mass of grey matter mesial to the restiform body (*n.VIIIp.*), and also with a nucleus (*n.VIIIac.*) lying ventral to the restiform body, and known as the accessory nucleus. The reticular formation (*f.r.*) still occupies the greater part of each lateral half of the bulb between the grey matter at the floor of the fourth ventricle and the pyramids (*py*), and a small portion of the olivary nucleus (*o*) may still be seen, as may also the upward continua-

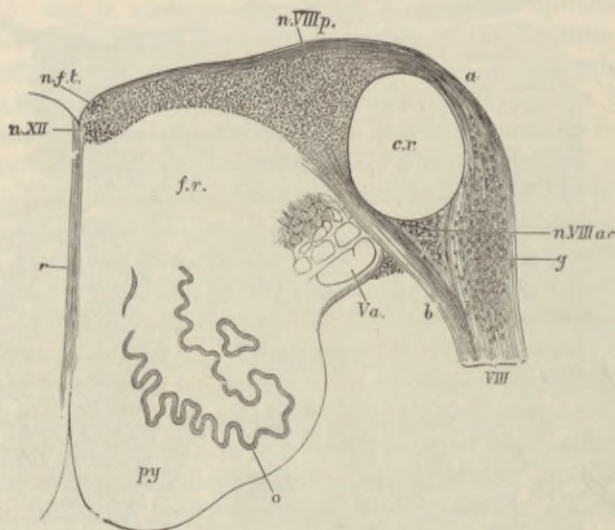


FIG. 316.—TRANSVERSE SECTION OF THE UPPER PART OF THE MEDULLA OBLONGATA. $\frac{1}{2}$. (Schwalbe.)

py, pyramid; *o*, olivary nucleus; *Va.*, ascending root of the fifth nerve; *VIII.*, inferior (posterior) root of the auditory nerve, formed of two parts, *a*, dorsal, and *b*, ventral, which inclose the restiform body, *c.r.*; *n.VIIIp.*, the (so-called) posterior nucleus of the eighth nerve; *n.VIIIac.*, accessory nucleus; *g*, ganglion-cells in the dorsal root; *n.f.t.*, nucleus of the funiculus teres; *n.XII.*, nucleus of the hypoglossal; *r*, raphe; *f.r.*, reticular formation.

tion of the grey matter of the tubercle of Rolando; this is intimately connected with some well-marked bundles of nerve-fibres, which are passing up to the pons to join eventually the root of the fifth nerve (*Va.*). The restiform body (*c.r.*) is formed partly of the fibres of the direct cerebellar tract of Flechsig of the same side, which are derived below from the cells of Clarke's column, and pass above into the middle lobe of the cerebellum, partly of fibres from the opposite olivary nucleus, and partly of fibres from the olivary nucleus of the same side. Those pass to the cerebellar hemisphere mainly. It also receives some fibres from a nucleus which lies just outside the grey matter of the funiculus cuneatus, and is known as the outer cuneate nucleus (fig. 312, *n.c.*).

LESSON XLI.

THE PONS VAROLII AND MESENCEPHALON.

1. SECTIONS through the lower, middle, and upper parts of the pons Varolii.

2. Sections across the region of the corpora quadrigemina, one at the level of the inferior, the other at the level of the superior, pair.

In all the above sections sketch under a low power the general arrangement of the grey and white matter, inserting the positions of the chief groups of nerve-cells.

[The tissue is hardened and the sections are prepared, stained, and mounted in the same way as the spinal cord.]

Pons Varolii.—Sections through the *pons Varolii* (figs. 317, 318) show very much the same arrangement of grey and white matter as that which is met with at the upper part of the medulla oblongata, but the general appearance of the sections is much modified by the presence of a large number of transversely coursing bundles of nerve-fibres, most of which are passing from the hemispheres of the cerebellum to the raphe (fibres of middle peduncle of cerebellum). Intermingled with these bundles is a considerable amount of grey matter (*nuclei pontis*). The continuation upwards of the pyramids of the medulla (*py*) is embedded between these transverse bundles and separated by them from the reticular formation. The deeper transverse fibres, those which are nearest to the reticular formation, belong to a different system from those of the middle peduncle. They form what is known as the *trapezium* (figs. 317, *tr.*; 318, *t.*); a collection of fibres which perhaps connects the superior olivary nucleus (see below) of one side with the accessory auditory nucleus (fig. 316, *n.VIIIac.*) of the other side. The olivary nucleus is no longer seen, but there are one or two small collections of grey matter much more conspicuous in some animals than in man, which lie in the ventral part of the reticular formation, and are known as the *superior olivary nucleus* (*o.s.*). Another important collection of large nerve-cells which is found in the upper part of the medulla oblongata, and extends into the pons Varolii, lies near the floor of the fourth ventricle, a little mesial to the restiform body: this is known as the *nucleus of Deiters* (*D*, fig. 317). The nerve-fibres connected with its cells are stated to be continued downwards

into the antero-lateral column of the spinal cord. The nerves which take origin from the grey matter of this region are part of the eighth, the seventh, the sixth, and somewhat higher up the fifth cranial nerves (see figs. 317 to 319). Of these the eighth and fifth are connected with groups of nerve-cells which occupy the grey matter opposite the ex-

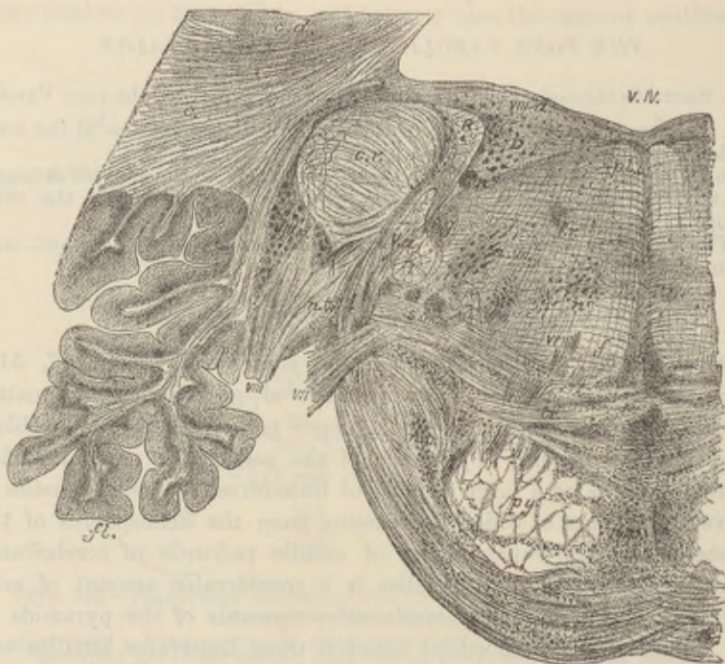


FIG. 317.—TRANSVERSE SECTION THROUGH THE LOWERMOST PART OF THE PONS VAROLII. †.

v.IV., fourth ventricle; c, white matter of cerebellar hemisphere; c.d., corpus dentatum; fl., flocculus; c.r., corpus restiforme; R, ascending auditory bundle of Roller; D, nucleus of Deiters; VIII., issuing root of auditory nerve; VIII.d., its dorsal nucleus; VIII.v., its ventral or accessory nucleus; tr., trapezium; a.tr., its nucleus; f, fillet; p.l.b., posterior longitudinal bundle; f.r., formatio reticularis; n, n', n'', various nuclei within it; V.a., ascending root of fifth nerve; s.g., substantia gelatinosa; s.o., superior olive; VII., issuing root of facial nerve; n.VII., its nucleus; VI., root-bundles of sixth nerve; py, pyramid bundles; n.p., nucleus of pons.

ternal border of the floor of the ventricle; the sixth with a group which is placed also in the grey matter of the floor of the ventricle but nearer the middle line, and the seventh partly with a special nucleus which lies in the formatio reticularis, and partly with the nucleus of the sixth. The fibres of the seventh nerve first pass backwards to the floor of the ventricle, then longitudinally upwards for a short distance, and finally bend forwards and downwards to emerge between the transverse fibres

at the side of the pons. In the reticular formation, two tracts of fibres are now very distinct. One of these lies just ventral to the grey matter of the floor of the fourth ventricle, near the middle line; this is the *dorsal or posterior longitudinal bundle*; it appears to afford connection between the oculo-motor nucleus and the nucleus of the sixth. The other is in the ventral part of the reticular formation, and is somewhat

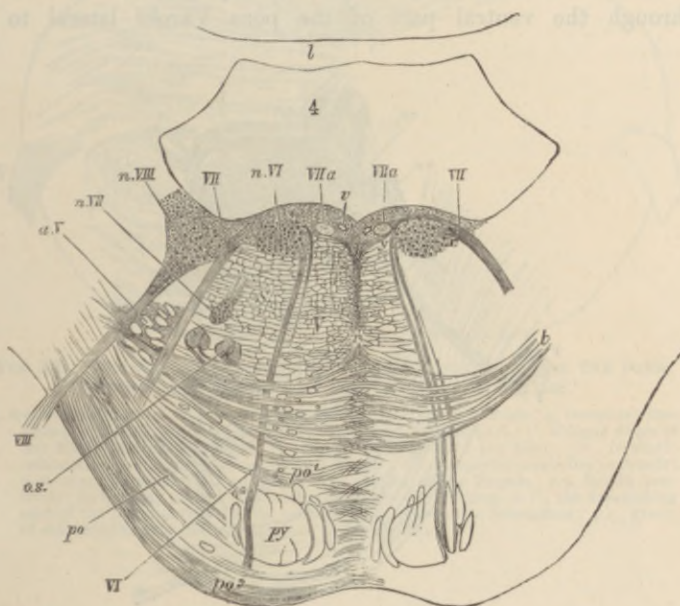


FIG. 318.—SECTION ACROSS THE PONS AT ABOUT THE MIDDLE OF THE FOURTH VENTRICLE. $\frac{1}{2}$. (Schwalbe.)

py, pyramid bundles continued up from the medulla; *po*, transverse fibres of the pons passing from the middle crus of the cerebellum, before (*po¹*) and behind (*po²*) the chief pyramid bundles; *t*, deeper fibres of the same set, constituting the trapezium; the grey matter between the transverse fibres is not represented either in this or the two following figures; *r*, raphe; *a.s.*, superior olivary nucleus; *a.V.*, bundles of the ascending root of the fifth nerve, inclosed by a prolongation of the grey substance of Rolando; *VI.*, root-bundle of the sixth nerve; *n.VI.*, its nucleus; *VII.*, root-bundle of the facial nerve; *VII.a.*, longitudinal portion of the same; *n.VII.*, its nucleus; *VIII.*, (superior) root of the auditory nerve; *n.VIII.*, its nucleus; *v*, section of a vein.

flattened (narrow in section) from above down; this is the *tract of the fillet*. Its fibres appear to be mainly derived from cells in the nuclei of the opposite fasciculus gracilis and fasciculus cuneatus of the medulla oblongata.

At the *upper part of the pons* (fig. 320) the fourth ventricle narrows considerably towards the Sylvian aqueduct, and behind and on either side of it two considerable masses of longitudinal white fibres make

their appearance. These are the *superior peduncles of the cerebellum* (*s.c.p.*), and they tend as they pass upwards gradually to approach the middle line (fig. 321, A), across which in the region of the posterior pair of the corpora quadrigemina they pass, decussating with one another, to the *formatio reticularis* of the opposite side (figs. 322, 323).

The *antero-lateral ascending tract* of the spinal cord is continued up through the ventral part of the pons Varolii lateral to the

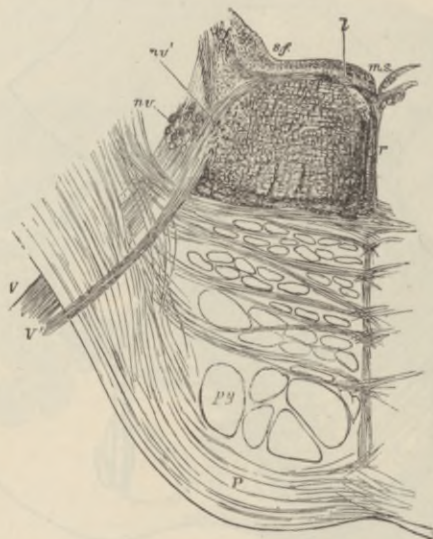


FIG. 319.—OBLIQUE SECTION OF THE PONS ALONG THE LINE OF EXIT TRAVERSED BY THE FIFTH NERVE. $\frac{2}{1}$.

The section passes through the lower part of the motor nucleus (*nv*) from which a bundle of fibres of the motor root is seen passing, *V*; a part of the upper sensory nucleus (*nv'*) is also shown in the section in the form of a number of small isolated portions of grey matter. Amongst these are a few bundles of the ascending root cut across, but most of these have already become diverted outwards to join and assist in forming the issuing part of the main or sensory root, *V*; *l*, small longitudinal bundle of fibres near the median sulcus (*m.s.*), passing outwards to join the root of the fifth nerve; *f.r.*, *formatio reticularis*; *r*, *raphe*; *s.f.*, *substantia ferruginea*.

pyramid bundles, but at about the level of the exit of the fifth nerve its fibres begin to pass obliquely towards the dorso-lateral part of the pons, where the superior cerebellar peduncle is emerging from the cerebellar hemisphere. The tract in question now curves over the lateral aspect of this peduncle, and then takes a sharp backward turn, passing over its dorsal aspect to enter the middle lobe of the cerebellum in the superior medullary velum.

Mid-brain or Mesencephalon.—In sections across the mesencephalon

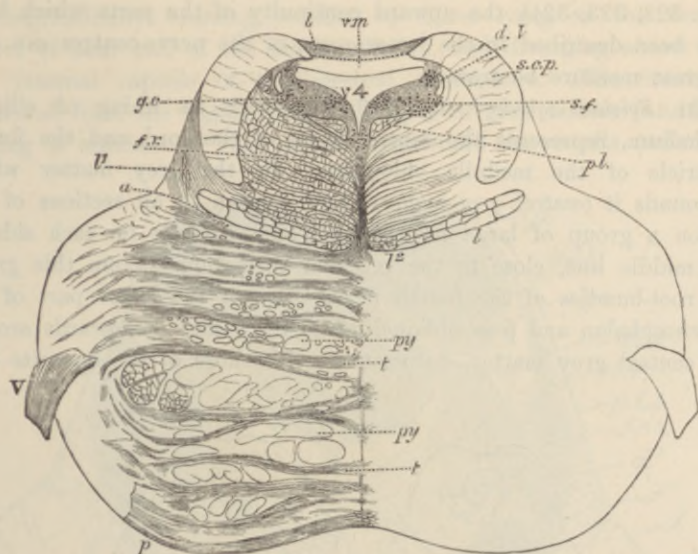


FIG. 320.—TRANSVERSE SECTION THROUGH THE UPPER PART OF THE PONS. (Schwalbe.) Rather more than twice the natural size.¹

p, transverse fibres of the pons; *py, py*, bundles of the pyramids; *a*, boundary line between the tegmental part of the pons and its ventral part; *l'*, oblique fibres of the fillet, passing towards *l''*, longitudinal fibres of the fillet; *f.r.*, formatio reticularis; *p.l.*, posterior longitudinal bundle; *s.c.p.*, superior cerebellar peduncle; *v.4*, superior medullary velum; *b*, grey matter of the lingula; *v.4*, fourth ventricle; in the grey matter which bounds it laterally are seen, *d.V.*, the descending root of the fifth nerve, with its nucleus; *s.f.*, substantia ferruginea; *g.c.*, group of cells continuous with the nucleus of the aqueduct.

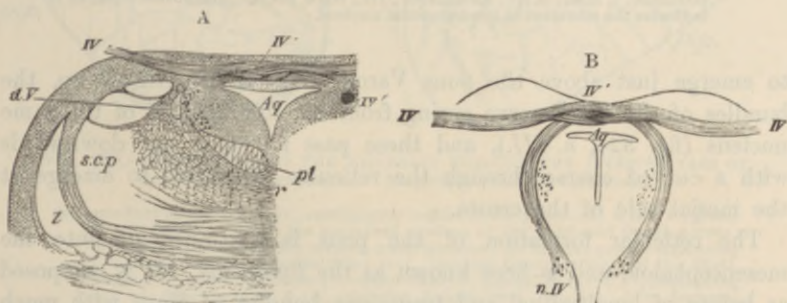


FIG. 321.—SECTIONS THROUGH THE ORIGIN OF THE FOURTH NERVE. $\frac{3}{4}$. (Schwalbe.)

A, transverse section at the place of emergence of the nerve-fibres. *B*, oblique section carried along the course of the bundles from the nucleus of origin to the place of emergence. *Aq.*, Sylvian aqueduct, with its surrounding grey matter; *IV'*, the nerve-bundles emerging; *IV''*, decussation of the nerves of the two sides; *IV'''*, a round bundle passing downwards by the side of the aqueduct to emerge a little lower down; *n.IV'*, nucleus of the fourth nerve; *f.*, fillet; *s.c.p.*, superior cerebellar peduncle; *d.V.*, descending root of the fifth nerve; *p.l.*, posterior longitudinal bundle; *r*, raphe.

¹ The details of this and of several of the preceding figures are filled in under a somewhat higher magnifying power than that used for tracing the outlines.

(figs. 322, 323, 324), the upward continuity of the parts which have thus been described in the lower parts of the nerve-centres can still in great measure be traced.

The *Sylvian aqueduct* (fig. 323, *Sy*), with its lining of ciliated epithelium, represents the central canal of the cord and the fourth ventricle of the medulla oblongata. In the grey matter which surrounds it (*central grey matter*) there is seen in all sections of the region a group of large nerve-cells lying ventrally on each side of the middle line, close to the reticular formation. From this group the root-bundles of the fourth nerve arise at the lower part of the mesencephalon and pass obliquely backwards and downwards around the central grey matter, decussating with those of the opposite side

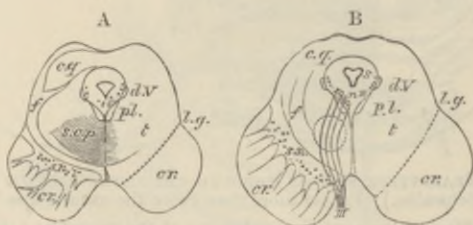


FIG. 322.—OUTLINE OF TWO SECTIONS ACROSS THE MESENCEPHALON.
Natural size.

A, through the middle of the inferior corpora quadrigemina. B, through the middle of the superior corpora quadrigemina. *cr.*, crista; *s.n.*, substantia nigra; *t.*, tegmentum; *s.*, Sylvian aqueduct, with its surrounding grey matter; *c.g.*, grey matter of the corpora quadrigemina; *l.g.*, lateral groove; *p.l.*, posterior longitudinal bundle; *d.v.*, descending root of the fifth nerve; *s.c.p.*, superior cerebellar peduncle; *f.*, fillet; *n.III.*, its nucleus; *III.*, third nerve. The dotted circle in B indicates the situation of the tegmental nucleus.

to emerge just above the pons Varolii (fig. 321). Higher up, the bundles of the third nerve spring from the continuation of the same nucleus (fig. 324, *n. III.*), and these pass forwards and downwards with a curved course through the reticular formation, to emerge at the mesial side of the crista.

The reticular formation of the pons is continued up into the mesencephalon, and is here known as the *tegmentum*. It is composed as before of longitudinal and transverse bundles of fibres with much grey matter intermingled. The transverse fibres include the decussating fibres of the *superior peduncles of the cerebellum* (*s.c.p.*), and the fibres of the *fillet* (*f.*), which are passing in an oblique manner from the raphe to the side of the mesencephalon, to reach eventually the grey matter of the prominences of the corpora quadrigemina. The pyramid bundles of the pons are continued upwards on each side into the *crusta* (figs. 322, *cr.*, 323, 324, *p.p.*) This forms a mass

of longitudinally coursing bundles of fibres lying on the ventral aspect of each half of the mesencephalon, and diverging above into the internal capsule of the cerebral hemisphere. The crusta is separated from the tegmentum by a layer of grey matter (*s.n.*) containing a number of very deeply pigmented nerve-cells (*substantia*

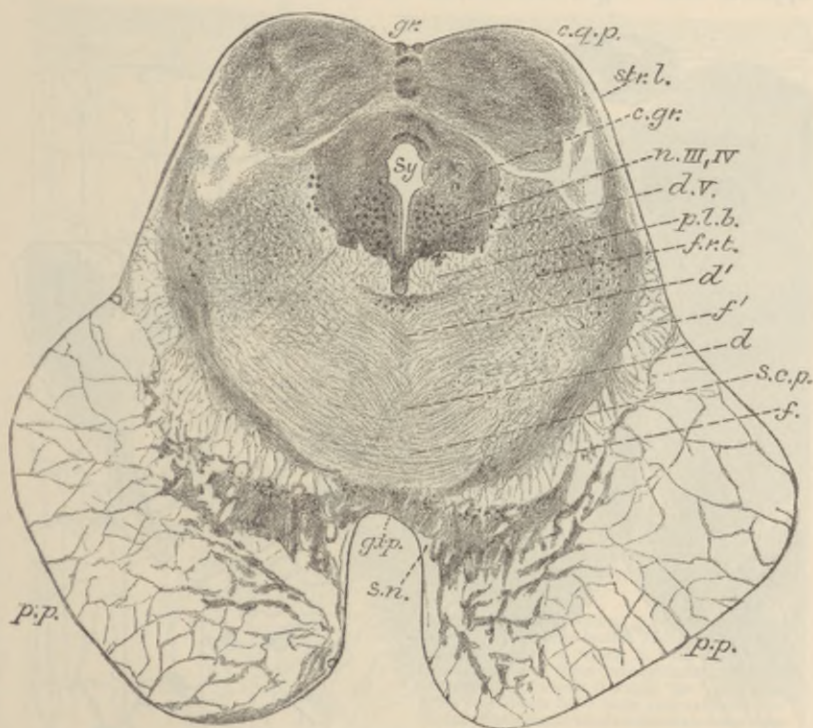


FIG. 323.—SECTION ACROSS THE MID-BRAIN THROUGH THE INFERIOR PAIR OF CORPORA QUADRIGEMINA. Magnified about $3\frac{1}{2}$ diameters.

Sy., aqueduct of Sylvius; *c.gr.*, central grey matter of the aqueduct; *n.III.IV.*, group of cells forming part of the conjoined nucleus of the third and fourth nerves; *c.q.p.*, one of the posterior corpora quadrigemina; *gr.*, median groove separating it from that of the opposite side; *str.l.*, stratum lemnisci (layer of the fillet), forming its superficial layer; *f.*, upper fillet; *f'*, lateral fillet; *d.V.*, descending root of fifth nerve; *p.l.b.*, posterior longitudinal bundle; *f.r.t.*, formatio reticularis tegmenti; *d, d'*, decussating fibres of tegmentum; *s.c.p.*, superior cerebellar peduncle; *p.p.*, pes pedunculi (crusta); *s.n.*, substantia nigra; *g.i.p.*, interpeduncular grey matter.

nigra). The crusta and tegmentum, together with the intervening substantia nigra, constitute the *crus cerebri*.

The prominences of the **corpora quadrigemina** are formed mainly of grey matter containing numerous nerve-cells. From each a bundle of white fibres (*brachium*) passes upwards and forwards towards the

geniculate bodies, eventually joining the optic tract of the same side. On the other hand, each of the prominences receives from below fibres of the *fillet*, which are traceable below into the ventral part of the anterior area of the medulla oblongata, and then through the raphe to the nuclei of the gracile and cuneate funiculi of the opposite side. Since these nuclei contain the terminal arborisations

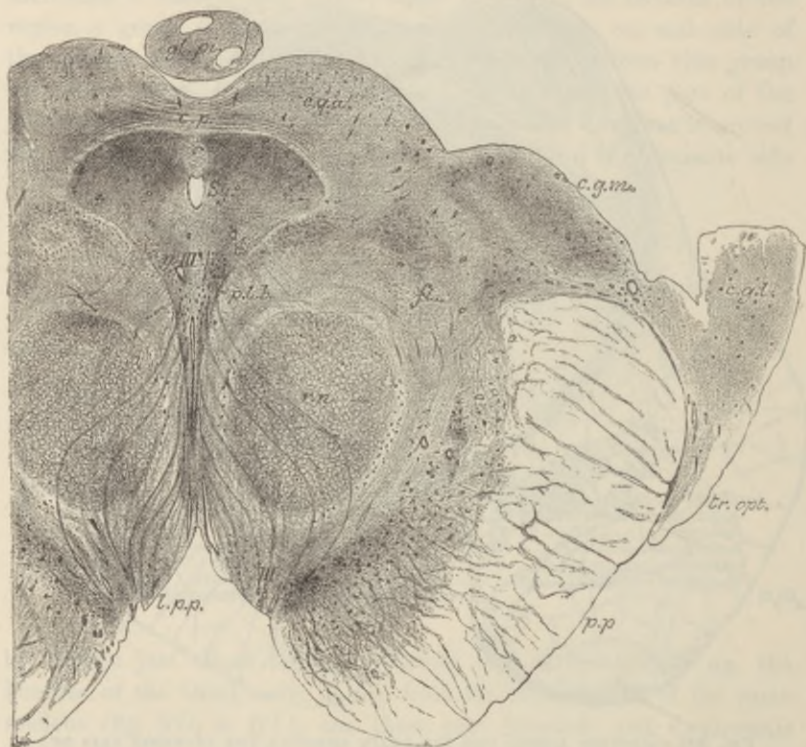


FIG. 324.—SECTION ACROSS THE MID-BRAIN THROUGH THE SUPERIOR CORPORA QUADRIGEMINA. Magnified about $3\frac{1}{2}$ diameters.

c.p., posterior commissure of brain; *gl. pl.*, pineal gland; *c.g.a.*, grey matter of one of superior corpora quadrigemina; *c.g.m.*, mesial geniculate body; *c.g.l.*, lateral geniculate body; *tr. opt.*, optic tract; *p.p.*, crusta or pes pedunculi; *p.l.b.*, posterior longitudinal bundles; *fl.*, upper fillet; *r.n.*, red nucleus; *III.*, issuing fibres of third nerve; *n.III.*, its nucleus; *l.p.p.*, locus perforatus posticus; *Sy.*, Sylvian aqueduct.

of many of the ascending fibres of the posterior spinal roots and the fibres of the fillet emanate from cells in the nuclei, the fillet forms a second link in the chain of afferent fibres leading towards the brain. Other fibres of the fillet are continued up beyond the mid-brain into the subthalamic region of the cerebrum. The superior corpora quadrigemina receive many of the fibres of the optic

tract, which form a superficial white stratum covering the grey matter. These fibres are derived from nerve-cells in the retina, and having arrived at the superior quadrigeminal body and formed the stratum in question, they turn into the grey matter and end in arborisations.

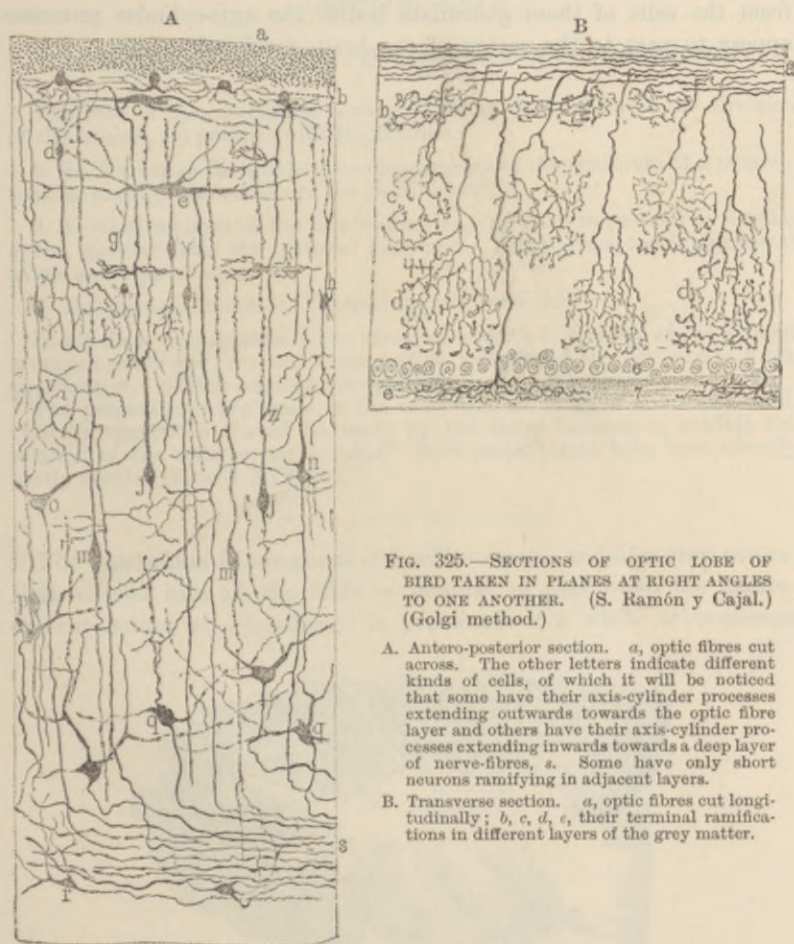


FIG. 325.—SECTIONS OF OPTIC LOBE OF BIRD TAKEN IN PLANES AT RIGHT ANGLES TO ONE ANOTHER. (S. Ramón y Cajal.) (Golgi method.)

- A. Antero-posterior section. *a*, optic fibres cut across. The other letters indicate different kinds of cells, of which it will be noticed that some have their axis-cylinder processes extending outwards towards the optic fibre layer and others have their axis-cylinder processes extending inwards towards a deep layer of nerve-fibres, *s*. Some have only short neurons ramifying in adjacent layers.
- B. Transverse section. *a*, optic fibres cut longitudinally; *b*, *c*, *d*, *e*, their terminal ramifications in different layers of the grey matter.

The cells of the grey matter are very various in form and size, and are disposed in several layers, which are better seen in the optic lobe of the bird than in mammals. Most of their axis-cylinder processes pass ventralwards. Their destination is not certainly known, but some appear to pass downwards with the fillet, others probably turn upwards and run in the tegmentum towards the higher parts

of the brain; whilst others, perhaps most, probably form terminal arborisations around the motor cells of the oculo-motor and other motor nuclei. All the nerve-fibres of the optic nerve and optic tract do not enter the corpora quadrigemina. Some pass into the lateral geniculate bodies and form arborisations there. On the other hand, from the cells of these geniculate bodies the axis-cylinder processes appear to pass to the cortex of the brain (occipital region).

LESSON XLII.

STRUCTURE OF THE CEREBELLUM AND CEREBRUM.

1. SECTIONS of the cerebellum vertical to the surface, (a) across the direction of the laminae, (b) parallel with the laminae.
2. Section across the whole of one hemisphere of the cerebrum of a monkey passing through the middle of the third ventricle.
3. Vertical sections of the cerebral cortex, one from the ascending frontal gyrus, another from the occipital lobe, and a third across the hippocampal gyrus and hippocampus.
4. Transverse sections of the olfactory tract and bulb.

In all these preparations make sketches under a low power of the general arrangement of the grey and white matter, and also of the nerve-cells in the grey matter. Sketch some of the details under a high power.

The preparations are made in the same way as those of the spinal cord. Other preparations should be made by the Golgi method to exhibit the relation of the cells to one another. Such preparations have been already partly studied (Lesson XIX.).

The **cerebellum** is composed of a white centre, and of a grey cortex. Both extend into all the folds or laminae, so that when the laminae are cut across, an appearance is presented of a white arborescence

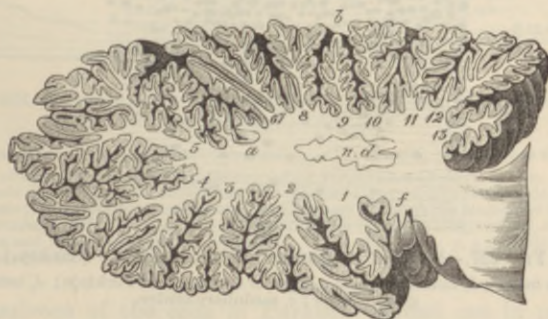

FIG. 326.—SECTION THROUGH ONE OF THE HEMISPHERES OF THE CEREBELLUM ACROSS THE LAMELLE, TO SHOW THE MEDULLARY CENTRE AND ITS PROLONGATIONS INTO THE LAMELLE. (Schwalbe.)

covered superficially by grey matter. The white matter is in largest amount in the middle of each cerebellar hemisphere (fig. 326). There is here present a peculiar wavy lamina of grey matter, similar to that

in the olivary body, and known as the *nucleus dentatus* (*n.d.*). Other isolated grey nuclei lie in the white matter of the middle lobe.

The grey matter of the cerebellum consists of two layers (fig. 327). The *inner* one (that next to the white centre) is composed of a large

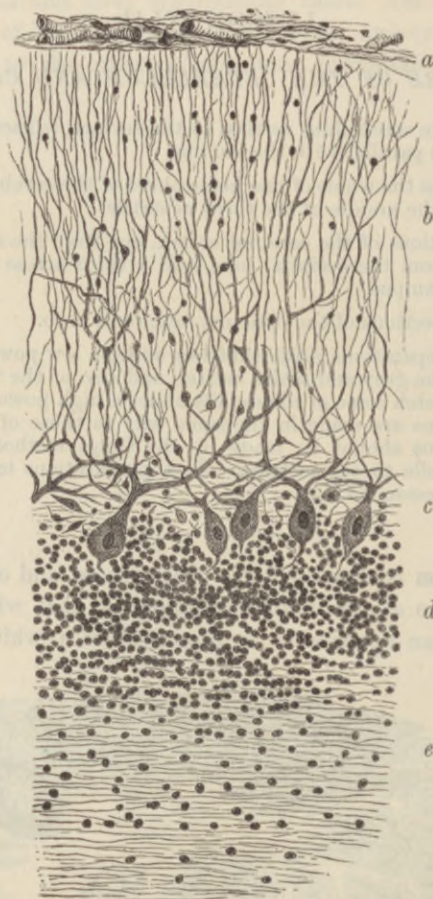


FIG. 327.—SECTION OF CORTEX OF CEREBELLUM. (Sankey.)

a, pia mater; *b*, external layer; *c*, layer of corpuscles of Purkinje; *d*, inner or granule layer; *e*, medullary centre.

number of very small nerve-cells intermingled with a few larger ones and some neuroglia-cells (*granule layer, d*). The *outer one* is thicker, and is formed chiefly of fine nerve-fibres (fig. 328, A) with small nerve-cells scattered through it (*molecular layer, b*). Into its outer part processes of the pia mater conveying blood-vessels pass vertically, and there are also in this part a number of long tapering neuroglia-cells,

somewhat like the Müllerian fibres of the retina. Lying between the two layers of the grey matter is an incomplete stratum of large flask-shaped cells (*cells of Purkinje, c*). Each of these gives off from its base a fine process (neuron), which becomes the axis-cylinder of one of the medullated fibres of the white centre, while from the opposite pole of the cell large ramified processes (dendrons) spread out into the superficial layer of the grey matter.

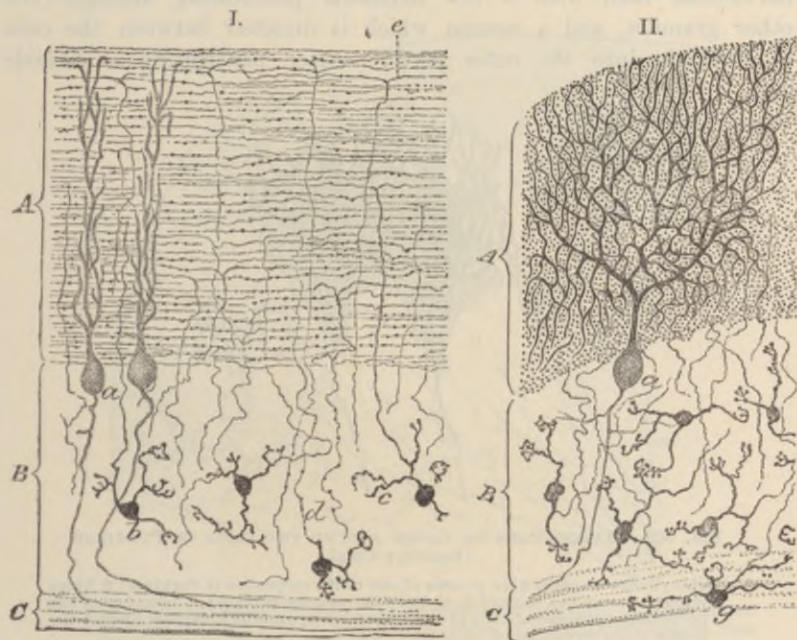


FIG. 328.—SECTIONS OF CORTEX CEREBELLI STAINED BY GOLGI'S METHOD.
(Ramón y Cajal.)

I.—Section made in the direction of the lamina. II.—Section taken across the lamina.

A, outer or molecular layer; B, inner or granule layer; C, medullary centre.

a, corpuscle of Purkinje; b, small granules of inner layer; c, a protoplasmic process of a granule; d, nerve-fibre process of a granule passing into the molecular layer, where it bifurcates and becomes a longitudinal fibre (in II. these longitudinal fibres are cut across and appear as dots); e, bifurcation of another fibre; g, a granule lying in the white centre.

The dendrons of the cells of Purkinje spread out in planes transverse to the direction of the lamellæ of the organ, so that they present a different appearance according to whether the section is taken across the lamellæ or along them (compare fig. 328, I. and II.). These dendrons are invested at their attachment to the cell, and for some extent along their branchings, by basket-works formed by the terminal arborisations of certain fibres of the medullary centre

(fig. 330). The body of the cell of Purkinje is further invested by a felt-work of fibrils formed by the arborisation of axis-cylinder processes of the small nerve-cells in the outer layer of the grey matter (fig. 329). Each cell has therefore a double investment of this nature, one covering the dendrons, the other the body of the cell.

The granules of the inner layer of grey matter are mostly small nerve-cells, each with a few dendrons penetrating amongst the other granules, and a neuron which is directed between the cells of Purkinje into the outer layer. After penetrating a variable



FIG. 329.—BASKET-WORK OF FIBRES AROUND TWO CELLS OF PURKINJE.
(Ramón y Cajal.)

a, axis-cylinder or nerve-fibre process of one of the corpuscles of Purkinje; *b*, fibres prolonged over the beginning of the axis-cylinder process; *c*, branches of the nerve-fibre processes of cells of the molecular layer, felted together around the bodies of the corpuscles of Purkinje.

distance into this layer it bifurcates, and its two branches pass in opposite directions at right angles to the main stem, and parallel to the direction of the lamella (fig. 328, I.). What ultimately becomes of them is not known. In sections cut across the lamellæ the cut ends of these fibres give a finely punctated appearance to the outer layer (fig. 328, II.).

Ramifying amongst the cells of the granule-layer are peculiar fibres derived from the white centre, and characterised by having pencils of fine short branches at intervals like tufts of moss (fig. 330, *m*). These are termed by Cajal the *moss-fibres*; they end partly in the granule layer, partly in the molecular layer.

Structure of the cerebrum.—The grey matter of the cerebral cortex is described as being composed of a number of layers, but

they are not sharply marked off from one another, and they vary in relative development in different regions of the cortex. The cells are for the most part of a pyramidal shape. The following layers are usually distinguished.

1. A thin peripheral stratum (*molecular layer*) containing a few scattered nerve-cells and neuroglia-cells. In the most superficial part of this layer, immediately under the pia mater, is a thin stratum

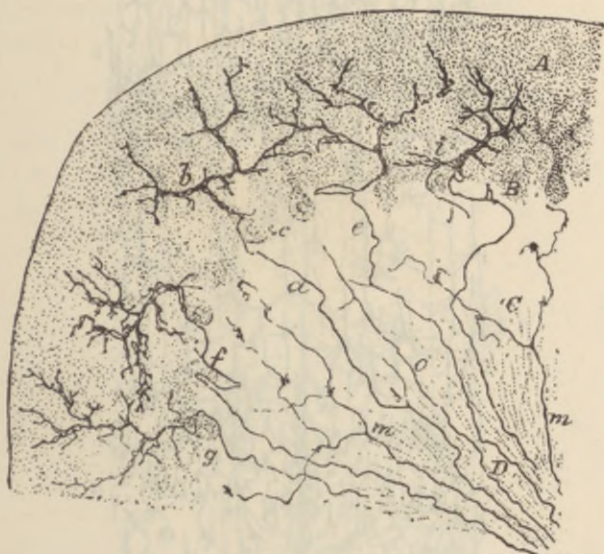


FIG. 330.—TRANSVERSE SECTION OF A CEREBELLAR LAMELLA OF THE ADULT RAT SHOWING THE FIBRES WHICH PASS FROM THE WHITE CENTRE TO THE GREY MATTER. (Ramón y Cajal.)

A, molecular layer; B, level of cells of Purkinje; C, granule layer; D, white substance. *a, c, f, g*, fibres which end in basket-work arborisations, *b*, enveloping the dendrons of Purkinje's cells; *e*, body of cell of Purkinje; *o*, probably an axis-cylinder process from one of the cells of Purkinje; *m*, "moss" fibres ramifying in the granule layer.

of medullated nerve-fibres, and besides these the layer contains a large number of non-medullated fibres, many of which are ramified. They are largely derived from the processes of the deeper nerve-cells of the cortex. Intermingled with these fibres are a certain number of ramified nerve-cells, most of which have two (sometimes three) horizontally disposed axis-cylinder processes, all of which terminate by arborisation within the superficial layer (fig. 331, *a*).

2. A layer of closely set small pyramidal nerve-cells, several deep (*layer of small pyramids, b*).

3. A layer of medium-sized pyramidal cells less closely set, with

small granule-like cells amongst them (*layer of larger pyramids, c*). The pyramidal cells are larger in the deeper parts of the layer.

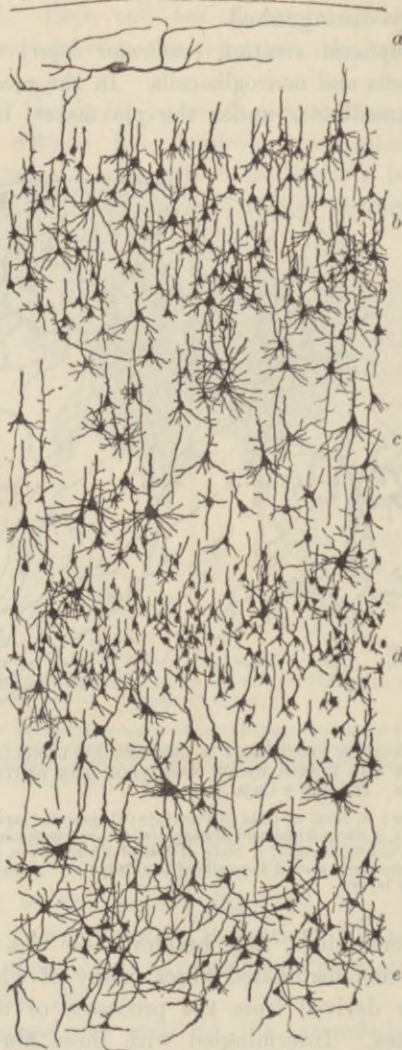

FIG. 331.—SECTION OF CEREBRAL CORTEX PREPARED BY THE GOLGI METHOD.
(Modified from Kölliker.)

a, molecular layer showing one of the polynuclear nerve-cells; *b*, layer of small pyramids; *c*, layer of larger pyramids; *d*, layer of polymorphous cells; *e*, claustral layer.

4. A layer of small irregular *polymorphous cells, d*. In the motor region of the cortex (portions of the frontal and parietal lobes)

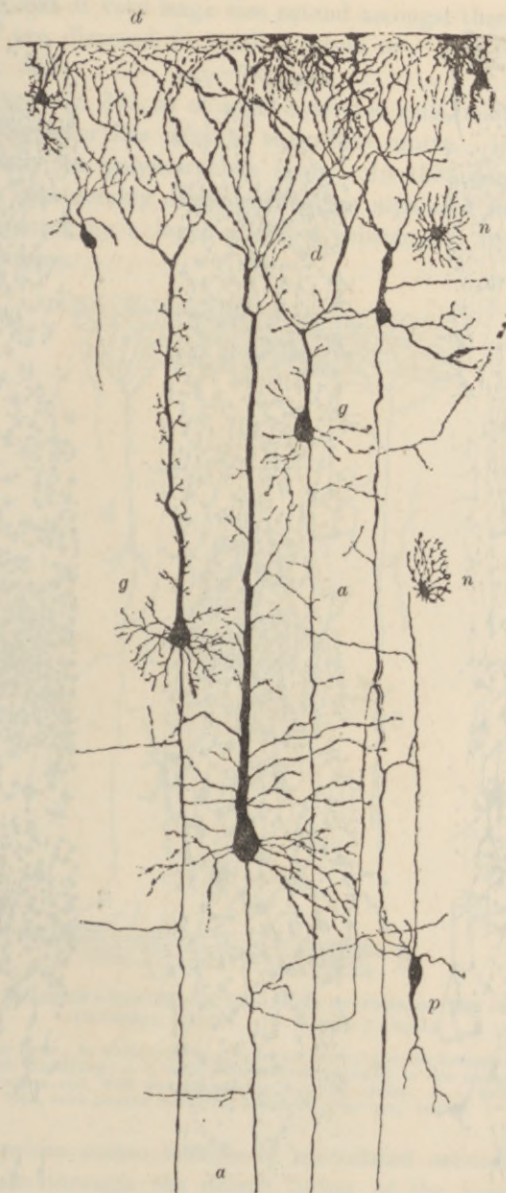


FIG. 332.—SECTION OF CEREBRAL CORTEX OF YOUNG RABBIT, PREPARED BY GOLGI'S METHOD. (G. Retzius.)

g, pyramidal cells of second and third layer sending their axis-cylinder processes, *a*, *a*, towards the white centre; *d*, *d*, dendrons of pyramids; *p*, polymorphous cell of fourth layer, with its axis-cylinder extending towards the surface, *n*, *n*, neuroglia-cells.

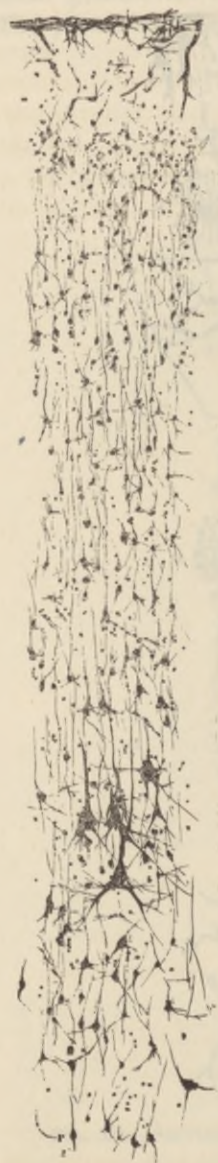

FIG. 333.—SECTION OF CORTEX OF MOTOR AREA.
(Bevan Lewis.)



FIG. 334.—SECTION OF CORTEX OF TEMPORAL LOBE.



FIG. 335.—SECTION OF CORTEX OF OCCIPITAL LOBE.

From Ferrier's *Functions of the Brain*, 2nd edition. They are from preparations and drawings (from the monkey's brain) made by Mr. Bevan Lewis, and are magnified about 145 diameters.

pyramidal cells of very large size extend amongst these polymorphous cells, and are disposed in small clusters or "nests" (Bevan Lewis, Betz) (fig. 333).

5. A layer (fig. 331, *e*) of small scattered cells, many of a fusiform shape. This layer lies next to the white centre. It is not always distinct from the polymorphous layer. In the island of Reil this stratum is considerably developed, and is separated from the rest of the grey matter by a layer of white substance. It is here known as the *claustrum*.

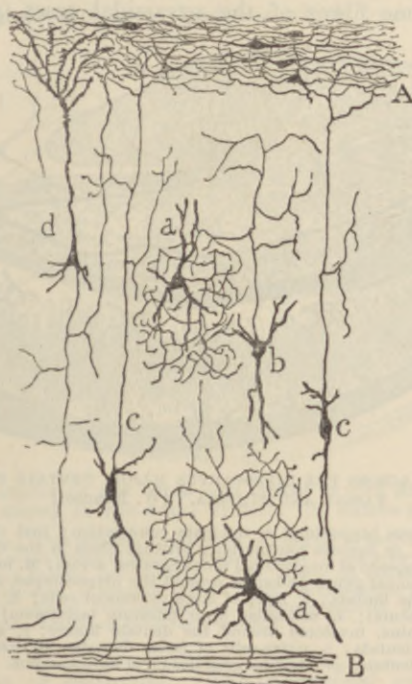


FIG. 336.—DIAGRAM SHOWING THE RELATIONS OF SOME OF THE CELLS IN THE CEREBRAL CORTEX. (S. Ramón y Cajal.)

A, molecular layer; B, white centre; *b*, cell with neuron passing towards the surface, but soon ramifying; *c*, *c*, cells with neurons passing to the molecular layer; *d*, projection cell, with neuron passing to white centre; *a*, *a*, cells of Golgi's second type, with neuron ramifying in the adjacent grey matter.

From the white centre bundles of medullated nerve-fibres pass in vertical streaks through the deeper layers of the grey matter, to lose themselves amongst the pyramidal cells of the more superficial layers. Some of these fibres are continuous with the axis cylinder processes of the pyramidal and polymorphous cells, and therefore take origin in the cortex; others are passing into the cortex to end

amongst the cells of the several layers in free arborisations. The axis-cylinder processes of the pyramidal cells pass into the white centre. Here some of them are continued either directly or by collaterals into the corpus callosum, and go through this to the cortex of the opposite hemisphere (*commissural fibres*); others join *association fibres* which run longitudinally or transversely, eventually to pass again into the grey matter of other parts of the same hemisphere; whilst others again, especially those of the largest pyramidal cells, extend downwards through the corona radiata and internal capsule, and become fibres of the pyramidal tract (*projection fibres*).

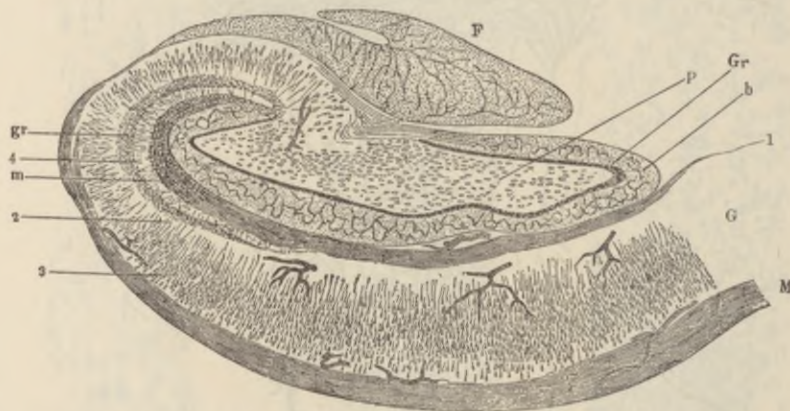

FIG. 337.—SECTION ACROSS THE HIPPOCAMPUS MAJOR, DENTATE FISSURE, DENTATE FASCIA AND FIMBRIA. (W. Krause.)

G, part of the gyrus hippocampi or uncinatè convolution; just above it is the fascia dentata, or dentate convolution; between them is the dentate fissure; F, fimbria, composed of longitudinal fibres here cut across; M, medullary centre of the hippocampal gyrus prolonged around the hippocampus, as the so-called alveus, into the fimbria; 3, layer of large pyramidal cells; 2, their processes (stratum radiatum); 4, molecular layer (stratum lacinosum); 1, superficial medullary lamina, involuted around the dentate fissure; b, molecular layer of the fascia dentata; p, nerve-cells of fascia dentata; Gr, stratum granulosum of fascia dentata; gr, stratum granulosum of hippocampus.

As they pass down through the grey and white matter of the hemisphere they give off collateral fibres to the adjacent grey matter, to the corpus callosum, and to the corpus striatum and optic thalamus.

There is, as already stated, a great amount of variation met with in the relative extent of development of the above layers. Some of these variations are exemplified in the accompanying drawings of preparations from the monkey's cerebral cortex by Bevan Lewis (figs. 333 to 335). From these it will be seen that smaller-sized cells prevail in the sensory regions of the cortex (occipital, temporal); larger and fewer cells occur in the motor parts. The structure

of the hippocampal region presents so many peculiarities as to necessitate a special description.

In the **hippocampus major** and **hippocampal gyrus** (fig. 337) the molecular layer and the white stratum, which overlies it as a thin band in other parts of the cortex, are both very strongly marked, the molecular layer having a very distinctly reticular aspect; internal to it is a layer of closely-packed small cells (*stratum granulosum*). All the rest of the thickness of the grey matter appears mainly to contain long pyramidal cells (fig. 337, 3; fig. 338, *h*), the distal processes or apices of which are prolonged into dendrons which lose themselves in the

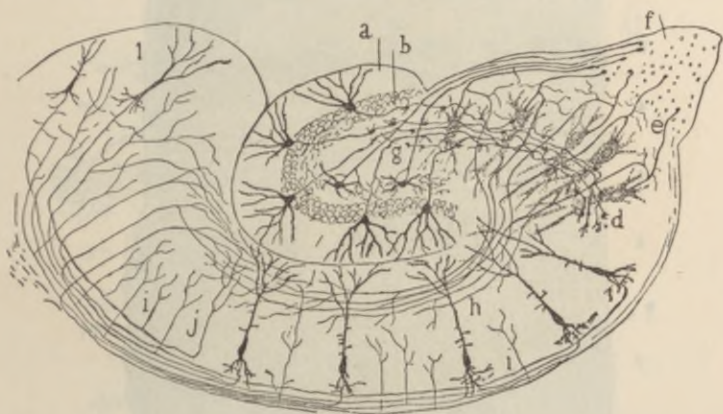


FIG. 338.—RELATIONS OF THE CELLS AND FIBRES OF THE HIPPOCAMPAL REGION, AS SHOWN BY THE GOLGI METHOD. (S. Ramón y Cajal.)

a, fascia dentata; *b*, its stratum granulosum; *d*, ending of neurons of cells of fascia dentata amongst pyramidal cells of hippocampus; *e*, neurons of pyramidal cells of hippocampus passing into fimbria, *f*, and giving off collaterals to superficial medullary lamina; *g*, pyramidal cells of fascia dentata giving neurons to fimbria; *h*, pyramidal cells of hippocampus; *i*, pyramidal cells of hippocampal gyrus; *j*, collaterals coming off from their neurons.

superficial layer of neuroglia. The pyramidal cells rest upon the white layer known as the *alveus*, which is the part of the hippocampus seen within the ventricle, and which is prolonged externally into the fimbria, where its fibres become longitudinal in direction.

In the **dentate gyrus** (*fascia dentata*, figs. 337, 338) the pyramidal cells are arranged in an irregularly radiating manner, occupying the centre of the convolution, and surrounded by a ring of closely packed small cells. External to these is a thick layer of superficial neuroglia.

The **olfactory tract** is an outgrowth of the brain which was originally hollow, and remains so in many animals; but in man the cavity has become obliterated, and the centre is occupied by neuro-

glia, containing no nerve-cells. Outside the central neuroglia lies the white or medullary substance, consisting of bundles of longitudinal white fibres. Most externally is a thin superficial layer of neuroglia.

The **olfactory bulb** (fig. 339) has a more complicated structure. Dorsally there is a flattened ring of longitudinal white bundles in-

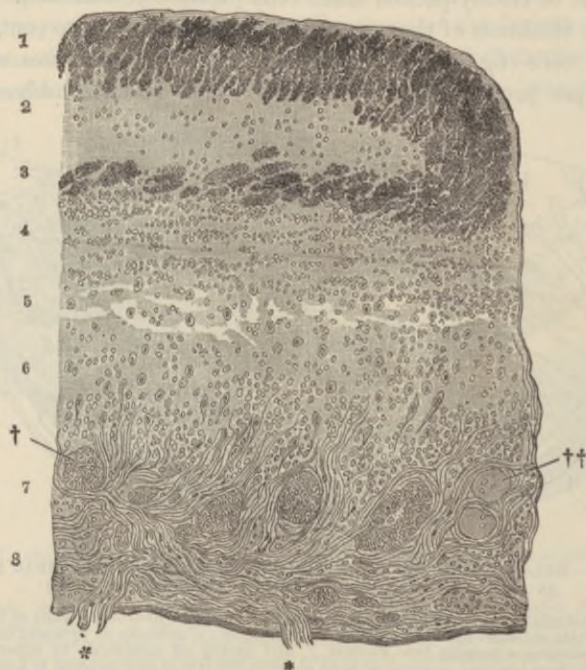


FIG. 339.—SECTION ACROSS A PART OF THE OLFACTORY BULB. (Henle.)

1, 3, bundles of very fine transversely cut nerve-fibres, forming the flattened medullary ring, inclosing the central neuroglia, 2: this is the anterior continuation of the olfactory tract; 5, white layer with numerous small cells (granules); 6, mitral layer; 7, layer of olfactory glomeruli, †, ††; 8, layer of olfactory nerve-fibres, bundles of which are seen at * passing through the cribriform plate of the ethmoid bone.

closing neuroglia (1, 2, 3), as in the olfactory tract, but below this ring several layers are recognised as follows:—

1. A *white or medullary layer* (fig. 339, 4, 5), characterised by the presence of a large number of small cells ("granules") with reticulating bundles of medullated nerve-fibres running longitudinally between them.

2. A *layer of large nerve-cells* (6), with smaller ones intermingled, the whole embedded in an interlacement of fibrils which are mostly derived from the cell-dendrons. From the shape of most of the

large cells of this layer (fig. 340; *m.c.*) it has been termed the "mitral" layer. These cells send their neurons upwards into the next layer, and they eventually become fibres of the olfactory tract and pass along this to the base of the brain, giving off numerous collaterals into the bulb as they pass backwards.

3. The layer of olfactory glomeruli (fig. 339, 7; fig. 340, *gl.*) consists of rounded nest-like interlacements of fibrils which are derived

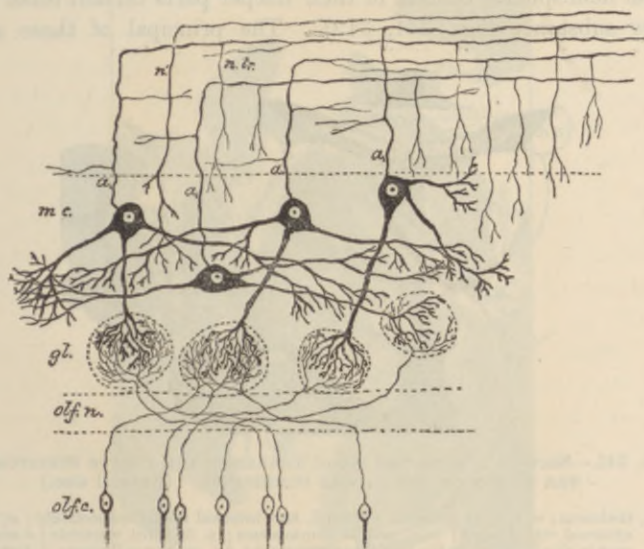


FIG. 340.—DIAGRAM TO SHOW THE RELATIONS OF CELLS AND FIBRES IN THE OLFACTORY BULB.

olf.c., olfactory cells of M. Schultze in the olfactory mucous membrane, sending their basal processes as non-medullated nerve-fibres into the deepest layer of the olfactory bulb (*olf.n.*); *gl.*, olfactory glomeruli containing the terminal arborisations of the olfactory fibres and of processes from the mitral cells; *m.c.*, mitral cells, sending processes down to the olfactory glomeruli, others laterally to end in free ramifications in the nerve-cell layer, and their axis-cylinder processes, *a*, *a'*, upwards, to turn sharply backwards and become fibres of the olfactory tract (*n.t.*). Numerous collaterals are seen coming off from these fibres; *n'*, a nerve-fibre of the olfactory tract apparently ending in a free ramification in the olfactory bulb.

on the one hand from the terminal arborisations of the non-medullated fibres which form the subjacent layer, and on the other hand from arborisations of descending processes of the large "mitral" cells of the layer above.

4. The layer of olfactory nerve-fibres (fig. 339, 8). These are all non-medullated, and are continued from the olfactory fibres of the Schneiderian or olfactory mucous membrane of the nasal fossæ. In this mucous membrane they take origin from the bipolar olfactory cells which are characteristic of the membrane (see Lesson XLV.,

fig. 369), and they end in arborisations within the olfactory glomeruli, where they come in contact with the arborisations of the mitral cells. The relations of the olfactory cells and fibres to the mitral cells, and the continuation of the axis-cylinders of the latter upwards and backwards to join the optic tract, are shown in the accompanying diagram (fig. 340).

Basal ganglia.—Besides the grey matter of the cerebral cortex the cerebral hemispheres conceal in their deeper parts certain other masses of grey substance (figs. 341, 342). The principal of these are the

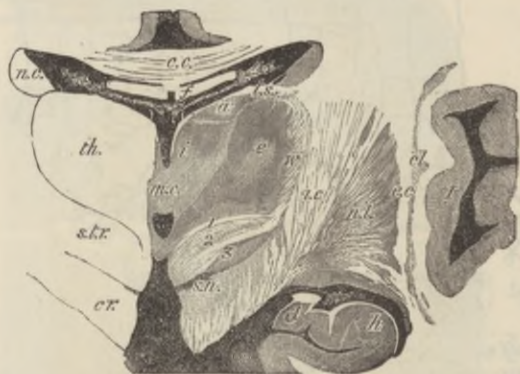

FIG. 341.—SECTION ACROSS THE OPTIC THALAMUS AND CORPUS STRIATUM IN THE REGION OF THE MIDDLE COMMISSURE. (Natural size.)

th., thalamus; *a, e, i*, its anterior, external, and internal nuclei respectively; *v.*, its external white layer; *m.c.*, middle commissure; *v. 3*, third ventricle; a small part is also seen below the middle commissure; *c.c.*, corpus callosum; *f.*, fornix, separated from the third ventricle and thalamus by the velum interpositum. In the middle of this are seen the two veins of Galen and the choroid plexuses of the lateral ventricles. *v.l.*; *t.s.*, stria pinealis; *cr.*, forward prolongation of the crura passing laterally into the internal capsule, *i.c.*; *s.t.r.*, subthalamic prolongation of the tegmentum, consisting of (1) the dorsal layer, (2) the zona incerta, and (3) the corpus subthalamicum; *s.n.*, substantia nigra; *n.c.*, nucleus caudatus of the corpus striatum; *n.l.*, nucleus lenticularis; *e.c.*, external capsule; *cl.*, claustrum; *I*, island of Reil; *h.*, hippocampus; *d.*, fascia dentata.

corpus striatum (*nucleus caudatus*, *n.c.*, and *nucleus lenticularis*, *n.l.*) and *optic thalamus* (*th.*). Between them run the bundles of white fibres which are passing upwards from the crus cerebri, forming a white lamina termed the *internal capsule*. Above the level of these nuclei the internal capsule expands into the medullary centre of the hemisphere.

The **nucleus caudatus** of the corpus striatum is composed of a reddish-grey neuroglia containing both moderately large and small multipolar nerve-cells. It receives fibres from the part of the internal capsule which separates it from the nucleus lenticularis, and next to the lateral ventricle it is covered by a thin layer of neuroglia (ependyma), and over this by the epithelium of the cavity.

The **nucleus lenticularis**, which corresponds in position internally with the island of Reil externally, is divided by two white laminae into three zones. It is separated from the nucleus caudatus and optic thalamus by the *internal capsule* (figs. 341, 342, *i.c.*), which consists of the bundles of medullary fibres which are passing between the white centre of the hemisphere and the crus cerebri; it receives

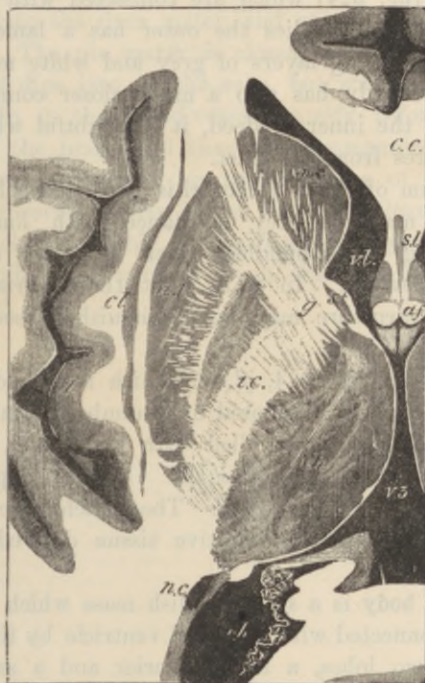

FIG. 342.—HORIZONTAL SECTION THROUGH THE OPTIC THALAMUS AND CORPUS STRIATUM. (Natural size.)

s.l., lateral ventricle, anterior cornu; *c.c.*, corpus callosum; *s.l.*, septum lucidum; *a.f.*, anterior pillars of the fornix; *v3*, third ventricle; *th.*, thalamus opticus; *s.t.*, stria pinealis; *n.c.*, nucleus caudatus, and *n.l.*, nucleus lenticularis of the corpus striatum; *i.c.*, internal capsule; *g.*, its angle or genu; *n.c.*, tail of the nucleus caudatus appearing in the descending cornu of the lateral ventricle; *cl.*, claustrum; *I.*, island of Reil.

on its inner side many white fibres from the capsule, and these impart to it a radially striated aspect. Many of the nerve-cells of the nucleus lenticularis contain yellow pigment.

The **optic thalamus**, which lies at the side of the third ventricle and forms part of the floor of the lateral ventricle, is covered externally by a layer of white fibres, most marked next to the internal capsule, fibres from which pass into the thalamus and serve to connect it with the hemisphere.

The grey matter of the thalamus (fig. 341) is partially subdivided by an oblique white lamina into a smaller, inner (*i*), and a larger outer, nucleus (*e*); these contain a number of small scattered nerve-cells. Anteriorly another portion of grey matter (*a*) is divided off in a similar way; this contains comparatively large nerve-cells.

Attached to the optic thalamus below and externally are the two *geniculate bodies* (fig. 324) which are connected with the optic tract. Of the two geniculate bodies the outer has a lamellated structure consisting of alternating layers of grey and white matter. This external geniculate body has also a much closer connection with the optic tract than the inner; indeed, it is doubtful whether the latter receives any fibres from the tract.

The tegmentum of the crus cerebri is prolonged below the thalamus opticus into a mass of grey substance, with longitudinally and obliquely crossing white bundles, which is known under the name of *subthalamie substance*. In it at least three parts differing from one another in structure may be distinguished (see description of fig. 341).

The **pineal gland** (fig. 324, *gl. pi.*), which is developed in the roof of the third ventricle, is composed of a number of tubes and saccules lined and sometimes almost filled with epithelium, and containing deposits of earthy salts (*brain-sand*). Similar deposits may also occur in other parts of the brain. The follicles are separated from one another by vascular connective tissue derived from the pia mater.¹

The **pituitary body** is a small reddish mass which lies in the sella turcica, and is connected with the third ventricle by the infundibulum. It consists of two lobes, a large anterior and a smaller posterior. The *anterior lobe* is originally developed as a hollow protrusion of the buccal epithelium. It consists of a number of tubules, which are lined by epithelium and united by connective tissue. In some of the tubes the epithelium is ciliated, and sometimes a colloid substance like that occurring in the vesicles of the thyroid has been found in them.

The *posterior lobe* of the pituitary body, although developed from the floor of the third ventricle, contains scarcely any perceptible nervous elements in the adult. It consists chiefly of vascular connective tissue.

The **membranes of the brain** are similar in general structure to

¹ In the chameleon and some other reptiles, the pineal is better developed, and is connected by nerve-fibres with a rudimentary median eye of invertebrate type, placed upon the upper surface of the head.

those of the spinal cord. The dura mater is, however, more closely adherent to the under surface of the bony cavity than is the case in the vertebral canal. The arachnoid is in many places close to the dura mater, and separated by a wide subarachnoid space (which is bridged across by finely reticulating bands of areolar tissue) from the pia mater. In the vicinity of the longitudinal sinus, small rounded elevations (arachnoidal villi, Pacchionian glands) project into the dura mater, and even become embedded in the skull itself. The pia mater is closely adherent to the surface of the brain, and dips into all the sulci, but without forming actual folds (Tuke). In it the blood-vessels ramify before passing into the substance of the brain, and they are accompanied, as they thus enter the cerebral substance, by prolongations of the pia mater, which do not, however, closely invest them, but leave a clear space around each vessel, presumably for the passage of lymph (perivascular space). The capillary network is much closer in the grey than in the white matter.

LESSONS XLIII. AND XLIV.

*STRUCTURE OF THE EYELIDS AND OF THE PARTS OF
THE EYEBALL.*

LESSON XLIII.

1. SECTIONS of the eyelid vertical to its surfaces and transverse to its long axis.

Notice the long sacculated Meibomian glands lying in dense connective tissue close to the conjunctival surface, their ducts opening at the margin of the lid. External to these the small fibres of the orbicularis palpebrarum cut across; a few of the fibres of the muscle lie on the conjunctival side of the duct. A short distance from the Meibomian gland may be observed a tolerably large sebaceous gland; outside this again are the eyelashes. In the skin covering the outer surface of the eyelid a few small hairs may be seen. At the attached part of the eyelid are some bundles of involuntary muscular fibres cut longitudinally in the section, and in the upper eyelid the fibrous attachment of the elevator muscle may be observed attached to the dense connective tissue.

Make a general sketch under a low power.

2. Sections through the posterior part of an eyeball. These sections will show the relative thickness of the several coats and the layers of which each coat is formed. Sections which pass through the point of entrance of the optic nerve will also exhibit the manner in which the nerve-fibres pierce the several coats to reach the inner surface of the retina. The modifications which are found in the neighbourhood of the yellow spot may also be made out if the sections have been taken from the human eye.

3. Sections of the anterior half of an eyeball. These sections should pass through the middle of the cornea. The lens may be left *in situ*, but this renders the preparation of the sections and the mounting of them difficult on account of the extreme hardness which is imparted to the lens-tissue by alcohol.¹

In these sections make a general sketch under a low power, showing the relations of the several parts one with another; and study carefully, and sketch in detail, the layers of the cornea, the place of junction of the cornea and sclerotic, the ciliary muscle, the muscular tissue of the iris, the mode of suspension of the lens, and the pars ciliaris retinae.

4. Mount in glycerine thin tangential sections of a cornea stained with chloride of gold by Cohnheim's method. Sketch three or four of the connective-tissue cells (corneal corpuscles). The arrangement and distribution of the nerve-fibres and their termination amongst the epithelium-cells as shown in chloride of gold preparations have been already studied (Lesson XXI.).

¹The celloidin method of embedding is well adapted for preparations of this kind (see Appendix).

5. Mount in xylol balsam sections of a cornea which has been stained with nitrate of silver. Notice the branched cell-spaces corresponding with the connective-tissue cells of the last preparation.

[This preparation is best made by rubbing the surface of the cornea with lunar caustic after scraping off the epithelium. After ten minutes (by which time the nitrate of silver will have penetrated the thickness of the cornea) the eye is washed with distilled water, and exposed to the light. When brown, tangential sections may be made, for which purpose the cornea may be hardened in spirit.]

LESSON XLIV.

1. REMOVE the sclerotic from the anterior part of an eye which has been preserved in Müller's fluid, and tear off thin shreds from the surface of the choroid, including amongst them portions of the ciliary muscle. Stain the shreds with hæmatoxylin and mount them in glycerine. Sketch the branched pigment-cells, the elastic network, the mode of attachment of the fibres of the ciliary muscle, etc.

2. Injected preparation of choroid and iris. Mount in xylol balsam portions of the choroid coat and iris from an eye, the blood-vessels of which have been filled with coloured injection. Make sketches showing the arrangement of the capillaries and veins.

3. Teased preparation of retina. Break up with needles in a drop of glycerine a minute fragment of retina which has been placed in 1 per cent. osmic acid solution for a few hours, and has subsequently been kept in dilute glycerine. Complete the separation of the retinal elements by tapping the cover-glass. Draw carefully under a high power some of the isolated elements—*e.g.* the rods and cones with their attached fibres and nuclei, the inner granules, the ganglion-cells, the fibres of Müller, hexagonal pigment-cells, etc. In some of the fragments the arrangement of the elements in the retinal layers may be made out even better than in actual sections.¹

Measure the length and diameter of some of the cones, the length of the cone-fibres, and the diameter of some of the outer and inner nuclei.

4. Sections of retina of ox or dog, which has been prepared by Golgi's method. A curled-up piece of fresh retina is placed for from four to five days in osmium-bichromate mixture and is subsequently treated with nitrate of silver solution.²

5. Teased preparation of lens. Separate in water the fibres of a crystalline lens which has been macerated for some days in bichromate of potash or dilute formol solution. Sketch some of the fibres, together and separate.

The eyelids (fig. 343) are covered externally by the skin, and internally or posteriorly by a mucous membrane, the *conjunctiva*, which is reflected from over the globe of the eye. They are composed in the main of connective tissue, which is dense and fibrous under the conjunctiva, where it forms what is known as the *tarsus*.

Embedded in the tarsus is a row of long sebaceous glands (the

¹The distribution of the nerve-fibres and cell-processes within the retina can only be made out satisfactorily by the employment of Golgi's method (see below).

²See Appendix.

Meibomian glands, f), the ducts of which open at the edge of the eyelid. The rest of the thickness of the eyelid is composed of a somewhat loose connective tissue, and contains the bundles of the *orbicularis* muscle (*b*). In the upper eyelid the *levator palpebræ* is

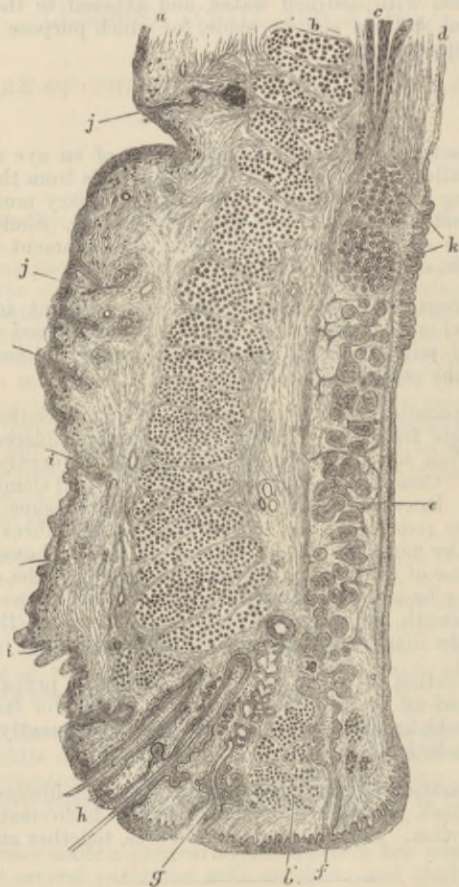


FIG. 343.—VERTICAL SECTION THROUGH THE UPPER EYELID. (Waldeyer.)
(Magnified.)

a, skin; *b*, orbicularis; *b'*, ciliary bundle; *c*, involuntary muscle of eyelid; *d*, conjunctiva; *e*, tarsus with Meibomian gland; *f*, duct of the gland; *g*, sebaceous gland near eyelashes; *h*, eyelashes; *i*, small hairs in outer skin; *j*, sweat-glands; *k*, posterior tarsal glands.

inserted into the tarsus by a fibrous expansion, and some bundles of involuntary muscle are also present near the attachment of the eyelid. The skin has the usual structure; it contains small sweat-glands, and the follicles of small hairs, and, in addition, at the edge

of the eyelid, the large hair-follicles from which the eyelashes grow. The epithelium of the conjunctiva palpebræ is columnar, passing at the edge of the lid into the stratified epithelium of the skin; it also becomes stratified in the part which is reflected over the globe of the eye. The nerves of the conjunctiva terminate for the most part in end-bulbs, which in man are spheroidal, and formed chiefly of a small mass of polyhedral cells; but in the calf and most animals they are elliptical, and consist of a core and lamellated sheath (see Lesson XXI.).

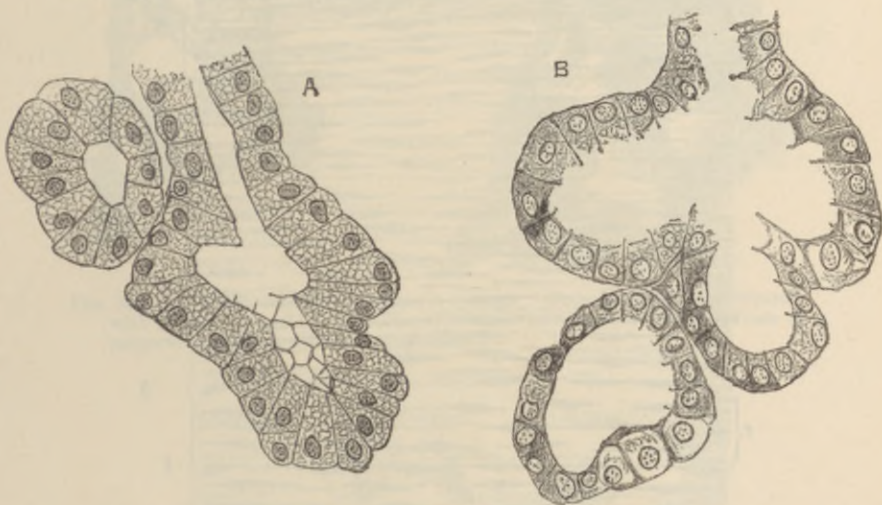


FIG. 344.—SECTIONS OF LACHRYMAL GLAND OF DOG, SHOWING PARTS OF TWO OR THREE ALVEOLI.

A, resting; B, after copious secretion.

The **lachrymal gland** may be briefly mentioned in connection with the eyelid. It is a compound racemose gland, yielding a watery secretion. Its alveoli are lined by columnar cells. Its ducts, of which there are several, open at the upper fold of the conjunctiva, near its outer extremity.

The **sclerotic coat** is composed of dense fibrous tissue, the bundles of which are intimately interlaced. It is thickest at the back of the eyeball. It is covered externally with a lymphatic epithelium, while internally it is lined by a layer of connective tissue containing pigment-cells, which give it a brown appearance (*lamina fusca*). At the entrance of the optic nerve the sclerotic is prolonged into the sheath of that nerve, the bundles of which, piercing the coat, give a sieve-like aspect to the part (*lamina cribrosa*, fig. 354, L.).

The cornea (fig. 345) consists of the following layers (enumerated from before back):—

1. A *stratified epithelium* continuous with the epithelium of the conjunctiva (1).




FIG. 345.—VERTICAL SECTION OF HUMAN CORNEA FROM NEAR THE MARGIN.
(Waldeyer.) (Magnified.)

1, epithelium; 2, anterior homogeneous lamina; 3, substantia propria corneae; 4, posterior homogeneous (elastic) lamina; 5, epithelium of the anterior chamber; a, oblique fibres in the anterior layer of the substantia propria; b, lamellae, the fibres of which are cut across, producing a dotted appearance; c, corneal corpuscles appearing fusiform in section; d, lamellae with the fibres cut longitudinally; e, transition to the sclerotic, with more distinct fibrillation, and surmounted by a thicker epithelium; f, small blood-vessels cut across near the margin of the cornea.

2. A thin lamina of homogeneous connective tissue (*membrane of Bowman*), upon which the deepest cells of the epithelium rest (2).

3. A thick layer of fibrous connective tissue which forms the *proper substance* of the cornea (3). This is continuous laterally with

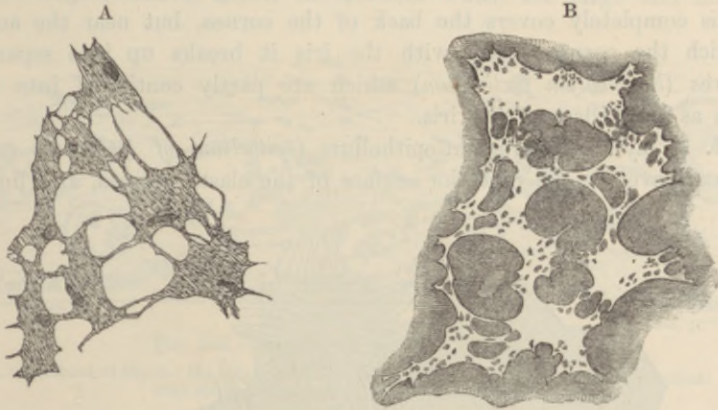


FIG. 346.—A, CORPUSCLES OF THE RAT'S CORNEA. (From a preparation treated with chloride of gold.) B, CELL-SPACES OF THE RAT'S CORNEA. (From a preparation stained with nitrate of silver.)

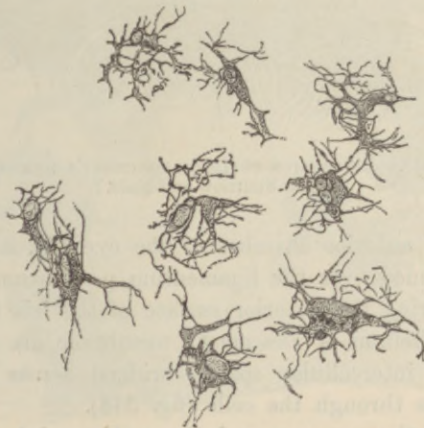


FIG. 347.—CORPUSCLES OF THE CORNEA, ISOLATED. (Waldeyer.)

the tissue of the sclerotic. It is composed of bundles of white fibres arranged in regular laminae, the direction of the fibres crossing one another at right angles in the alternate laminae. Between the laminae lie flattened connective-tissue corpuscles, which are branched and united by their processes into a continuous network; there is

of course a corresponding network of cell-spaces (fig. 346, A, B). In vertical sections the cells appear narrow and spindle-shaped (fig. 345, c). In the superficial laminae there are a few bundles of fibres which run obliquely towards the surface (a).

4. A homogeneous elastic layer (*membrane of Descemet*, fig. 345, 4). This completely covers the back of the cornea, but near the angle which the cornea forms with the iris it breaks up into separate fibres (*ligamentum pectinatum*) which are partly continued into the iris as the pillars of the iris.

5. A layer of pavement-epithelium (*epithelium of Descemet's membrane*) covering the posterior surface of the elastic lamina, and lining

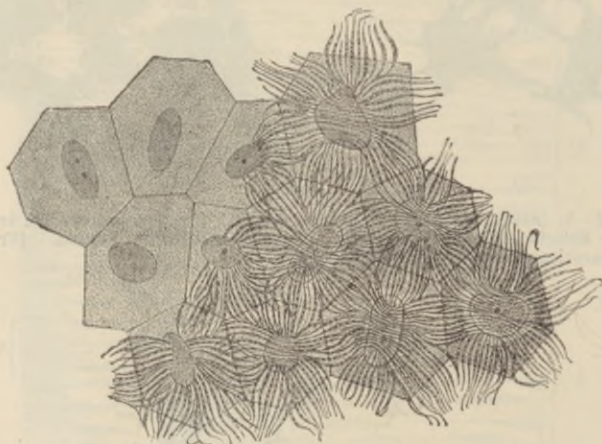

FIG. 348.—EPITHELIUM-CELLS OF DESCEMET'S MEMBRANE.
(After Smirnow and Nuël.)

the front of the anterior chamber of the eye (fig. 345, 5). At the sides it is continued over the *ligamentum pectinatum* into a similar epithelium, covering the anterior surface of the iris (fig. 352). The cells of the epithelium of Descemet's membrane are separated from one another by intercellular spaces, bridged across by bundles of fibrils which pass through the cells (fig. 348).

The nerves of the cornea pass in from the periphery, losing their medullary sheath as they enter the corneal substance. They form a primary plexus in the *substantia propria*, a secondary or sub-epithelial plexus immediately under the epithelium which covers the anterior surface, and a terminal plexus of fine fibrils which pass from the sub-epithelial plexus in pencil-like tufts and become lost between the epithelium-cells (see figs. 148, 149, Lesson XXI.). There

are no blood-vessels or lymphatics in the cornea, although they come close up to its margin.

The **choroid** or **vascular coat** of the eye is of a black colour in many animals, but in the human eye it is dark brown. It is composed of connective tissue, the cells of which are large and filled



FIG. 349.—SECTION OF CHOROID. (Cadiat.)

a, membrane of Bruch: the chorio-capillaris is just above it; *b*, vascular layer; *c*, vessels with blood-corpuscles; *d*, lamina suprachoroidea.

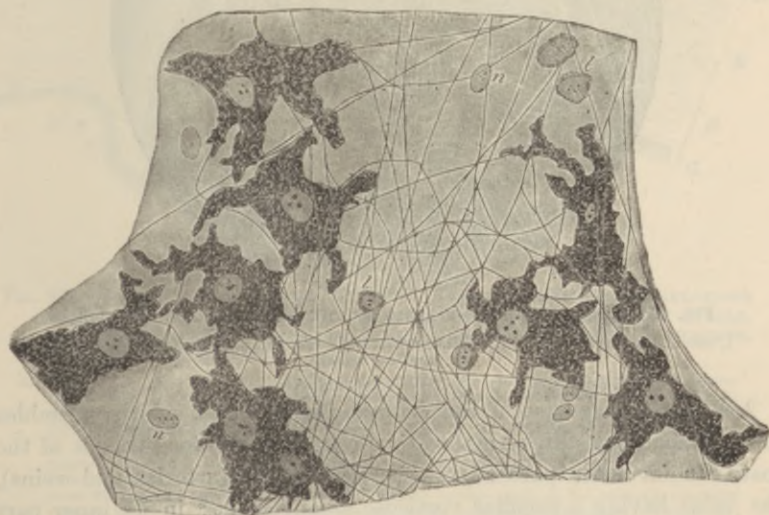

FIG. 350.—A SMALL PORTION OF THE LAMINA SUPRACHOROIDEA. (Highly magnified.)

p, pigment-cells; *f*, elastic fibres; *n*, nuclei of endothelial cells (the outlines of the cells are not indicated); *l*, lymph-cells.

with pigment (figs. 349, 350), and it contains in its inner part a close network of blood-vessels, and in its anterior part the involuntary muscular fibres of the ciliary muscle, which pass backwards from their origin at the junction of the cornea and sclerotic, to be

inserted into the choroid. The choroid is separable into the following layers (enumerated from without in):—

1. The *lamina suprachoroidea* (fig. 349, *d*). This is a loose membrane composed of delicate connective tissue pervaded by a network of fine elastic fibres, and containing many large branched pigment-cells and lymph-corpuscles (fig. 350). It is covered superficially by a lymphatic endothelium, and is separated from the lamina fusca of the sclerotic by a cleft-like lymphatic space which is bridged across here and there by the passage of vessels and nerves, and by bands of connective tissue.

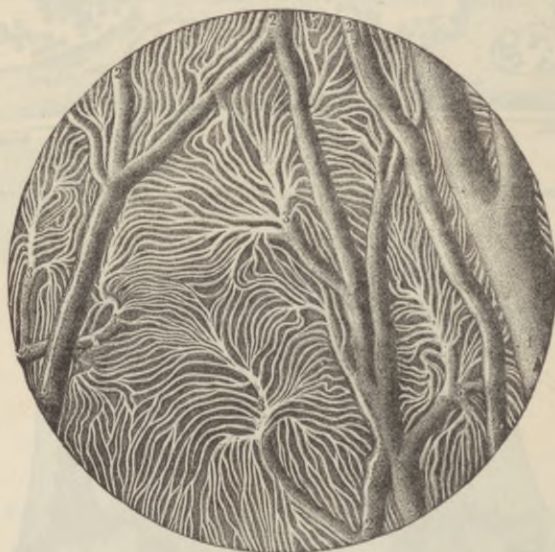

FIG. 351.—INJECTED BLOOD-VESSELS OF THE CHOROID COAT. (Sappey.)

1, one of the larger veins; 2, small anastomosing vessels; 3, branches dividing into the smallest vessels.

2. The *vascular layer* of the choroid (fig. 349, *b*), which resembles the suprachoroidea in structure, but contains the blood-vessels of the coat. In its outer part are the larger vessels (arteries and veins), the veins having a peculiar vorticose arrangement; in its inner part (chorio-capillaris) are the capillaries, which form an extremely close network with elongated meshes, the capillaries radiating from the extremities of the small arteries and veins in a highly characteristic manner (fig. 351). In the ciliary processes the vessels have for the most part a longitudinal direction, but there are numerous convoluted transversely disposed capillaries uniting the longitudinal vessels (fig. 354, *d*).

3. Lining the inner surface of the choroid is a very thin transparent membrane known as the *membrane of Bruch* (fig. 349, a).

The *ciliary muscle* consists of involuntary muscular bundles which

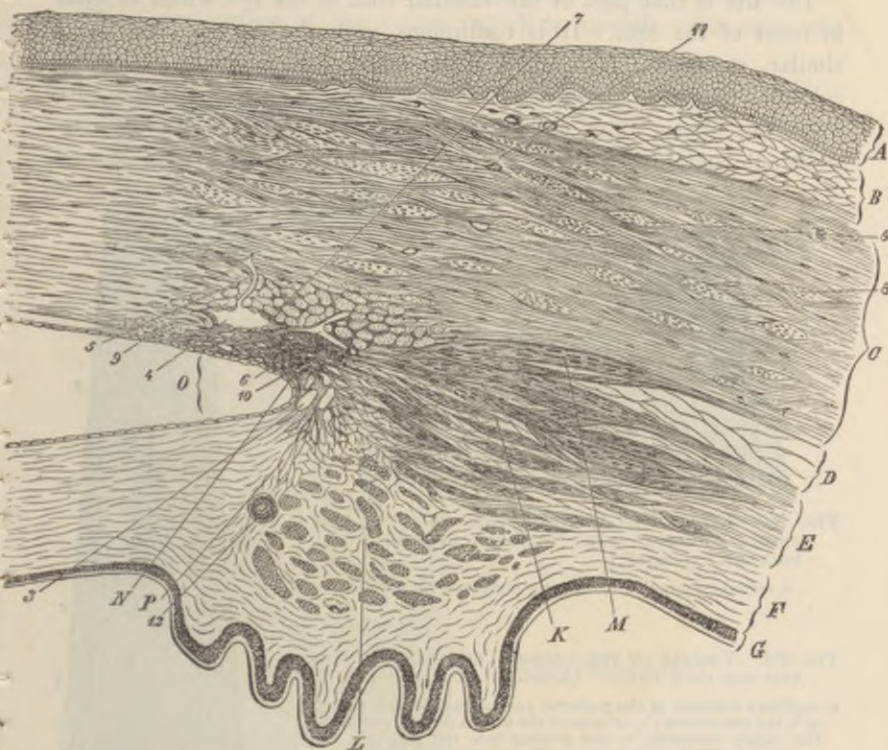


FIG. 352.—SECTION (FROM THE EYE OF A MAN, AGED 30), SHOWING THE RELATIONS OF THE CORNEA, SCLEROTIC, AND IRIS, TOGETHER WITH THE CILIARY MUSCLE, AND THE CAVERNOUS SPACES NEAR THE ANGLE OF THE ANTERIOR CHAMBER. (Waldeyer.) (Magnified.)

A, epithelium; B, conjunctival mucous membrane; C, sclerotic; D, membrana supra-choroidea; E, opposite the ciliary muscle; F, choroid, with ciliary processes; G, tapetum nigrum and pars ciliaris retinae; K, radiating and meridional, and L, circular or annular bundles of the ciliary muscle; M, bundles passing to the sclerotic; N, ligamentum pectinatum iridis at the angle, O, of the anterior chamber; P, fibres passing from it to the iris. 1, anterior homogeneous lamina of the cornea; 2, posterior homogeneous lamina, covered with endothelial cells which are continued over the front of the iris; 3, cavernous spaces at the angle of the anterior chamber (spaces of Fontana); 4, canal of Schlemm, with endothelial lining, and with a vessel, 5, leading from it; 6, other vessels; 7, bundles of fibres of the sclerotic having a circular direction, cut across; 8, larger ones in the substance of the sclerotic; 9, fine bundles cut across, at limit of cornea; 10, point of origin of meridional bundles of ciliary muscle; 11, blood-vessels in sclerotic and conjunctiva, cut across; 12, section of one of the ciliary arteries.

arise at the corneo-sclerotic junction, and pass meridionally backwards to be inserted into the choroid (fig. 352, K). Many of the deeper-seated bundles take an oblique direction, and these pass gradually into others which run circularly around the circumference

of the iris, and on a level with the ciliary processes. This set of circularly arranged bundles constitutes the *circular ciliary muscle* of H. Müller (*L*); it is most marked in hypermetropic eyes.

The *iris* is that part of the vascular coat of the eye which extends in front of the lens. It is continuous with the choroid and has a similar structure, but its pigment-cells often contain variously coloured pigment. Besides the homogeneous connective tissue with numerous elastic fibres and blood-vessels of which it is chiefly composed, it contains two sets of plain muscular fibres. The one set

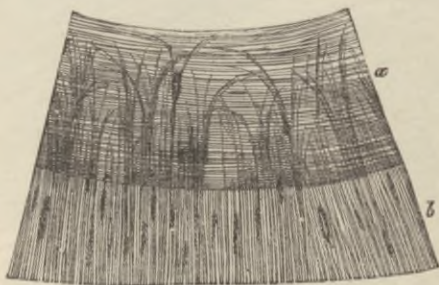
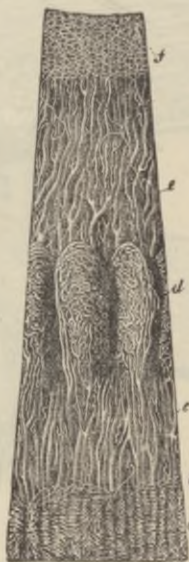
FIG. 353.—SEGMENT OF THE IRIS, SEEN FROM THE POSTERIOR SURFACE AFTER REMOVAL OF THE UVEAL PIGMENT. (Iwanoff.)

a, sphincter muscle; *b*, dilator muscle of the pupil.

FIG. 354.—VESSELS OF THE CHOROID, CILIARY PROCESSES AND IRIS OF A CHILD. (Arnold.) (10 diameters.)

a, capillary network of the posterior part of the choroid, ending at *b*, the ora serrata; *c*, arteries of the corona ciliaris, supplying the ciliary processes, *d*, and passing into the iris, *e*; *f*, the capillary network close to the pupillary margin of the iris.



forms the *sphincter* muscle (fig. 353, *a*), which encircles the pupil, the other set consists of a flattened layer of radiating fibres which extend from the attachment of the iris nearly to the pupil, lying close to the posterior surface and constituting the *dilator* muscle (*b*).¹

The back of the iris is covered by a thick layer of pigmented epithelium (uvea) continuous with the epithelium of the pars ciliaris retinae.

The blood-vessels of the iris converge towards the pupil (fig. 354, *e*). Near the pupil the small arteries form a small anastomotic circle, from which capillaries arise and pass still nearer the pupil, around which they form a close capillary network.

A large number of nerve-fibres are distributed to the choroid and

¹ The existence of a dilator in man is denied by some histologists.

iris, probably going chiefly to the muscular tissue (ciliary muscle and sphincter and dilatator iridis).

The retina consists of the eight layers shown in the accompanying figure (fig. 353), numbered as they occur from within out.

The inner surface of the retina, which is smooth, rests upon the

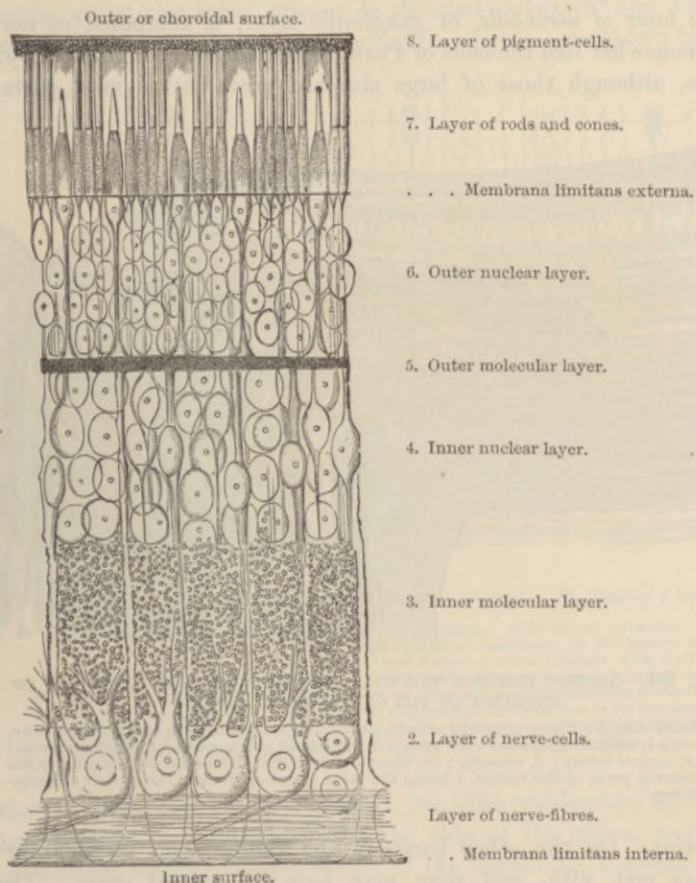


FIG. 355.—DIAGRAMMATIC SECTION OF THE HUMAN RETINA. (M. Schultze.)

hyaloid membrane of the vitreous humour. It is formed of the united bases of the fibres of Müller, which will be afterwards described.

The *layer of nerve-fibres* is formed by the expansion of the optic nerve after it has passed through the coats of the eye (fig. 356). At its entrance it forms a slight eminence (*colliculus nervi optici*).

The nerve-fibres lose their medullary sheath on reaching the retina. Most are connected with (derived from) the cells of the ganglionic layer (fig. 357), but some pass through the ganglionic and molecular layers to form a terminal arborisation in the inner nuclear layer (fig. 358). The layer of nerve-fibres becomes gradually thinner in the anterior part of the retina.

The *layer of nerve-cells*, or ganglionic layer, is composed of nerve-cells somewhat like the cells of Purkinje of the cerebellum but varying in size, although those of large size are prevalent in most parts of

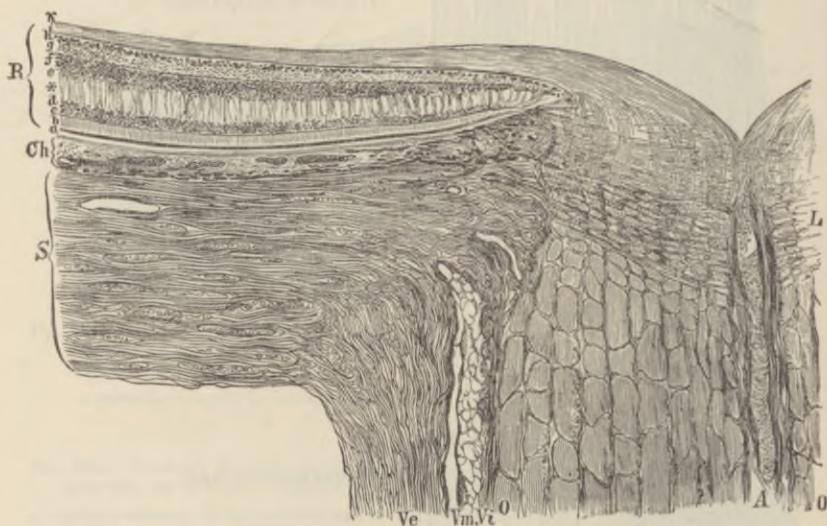


FIG. 356.—SECTION THROUGH THE COATS OF THE EYEBALL AT THE POINT OF ENTRANCE OF THE OPTIC NERVE. (Toldt.)

Ve, dural sheath; *Vm*, arachnoid sheath, and *Vi*, pia-matral sheath of the optic nerve, with lymphatic spaces between them; *O, O*, funiculi of the nerve; *L*, lamina cribrosa; *A*, central artery; *S*, sclerotic; *Ch*, choroid; *R*, retina. The small letters refer to the various parts of the retina, *b* being the layer of rods and cones, and *i* that of nerve-fibres.

the retina. On the other hand, in the yellow spot, smaller nerve-cells are met with, and they may here lie several deep. These nerve-cells have on the one side a fine axis-cylinder process prolonged into a fibre of the layer just noticed, and on the other a thick branching process, the ramifications of which terminate in the next layer in flattened arborisations at different levels (fig. 359, A, B, C).

The *inner molecular layer* is comparatively thick, and has an appearance very like the grey matter of the nerve-centres. A few nuclei are scattered through it, and it is traversed by the processes of the

nerve-cells and of the inner granules, and by fibres from the optic nerve layer, as well as by the fibres of Müller.

The *inner nuclear layer* is mainly composed of bipolar nerve-cells containing large nuclei (*inner granules*). The processes of these cells (fig. 357) extend on the one hand inwards into the inner molecular layer where they spread out into terminal arborisations at different levels, whilst the other process is directed outwards, and forms an arborisation in the outer molecular layer. It has been shown by Cajal

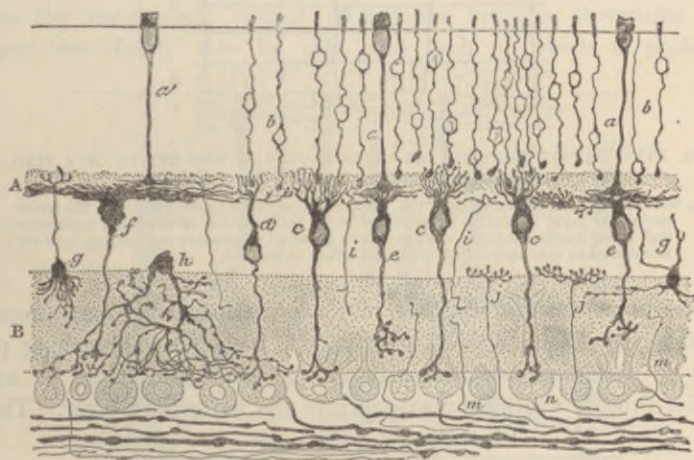


FIG. 357.—SECTION OF DOG'S RETINA, GOLGI METHOD. (S. Ramón y Cajal.)

a cone-fibre; *b*, rod-fibre and nucleus; *c*, *d*, bipolar cells (inner granules) with vertical ramification of their outer processes or dendrons: in the centre of the ramification lie the enlarged ends of rod-fibres; *e*, other bipolars with flattened ramifications abutting against ramified ends of cone-fibres; *f*, large bipolar with flattened ramification; *g*, inner granule-cell sending a neuron towards the rod- and cone-fibres; *h*, amacrine cell with diffuse arborisation of its processes in inner molecular layer; *i*, *j*, *m*, nerve-fibrils passing respectively to outer molecular, inner nuclear, and inner molecular layers; *n*, ganglionic cells.

that there are two kinds of bipolars, one kind (*rod-bipolars*, fig. 357, *c*, *d*) being connected externally with the rods of the retina, and passing inwards to ramify over the bodies of the nerve-cells, whereas those of the other kind (*cone-bipolars*, *e*) are connected with the cone-fibres, and ramify in the middle of the inner molecular layer. The outwardly directed processes of these cone-bipolars are, in some animals, but not in mammals, continued on as far as the external limiting membrane, where each ends in a free extremity (fibre of Landolt, fig. 360, E). Besides these bipolar nerve-cells, there are other inner granules (spongioblasts of inner molecular layer) which are different in character, having ramified processes which extend into the

inner molecular layer (figs. 357, *h*; 360, A, B, C), in which the bodies of these cells are often partly embedded. The cells in question have been regarded as of the nature of neuroglia-cells, but according to Cajal they are probably all nerve-cells. He has termed them

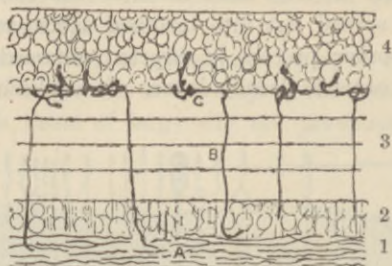


FIG. 358.—SECTION THROUGH THE INNER LAYERS OF THE RETINA OF A BIRD, PREPARED BY GOLGI'S METHOD. (R. y Cajal.)

A, nerve-fibres of optic nerve layer; B, some of these fibres passing through the inner molecular layer to end in an arborisation at the junction of the inner molecular and inner nuclear layers. The layers in this and in the two succeeding cuts are numbered in correspondence with the layers in fig. 355.

amacrine-cells, from the fact that they are destitute of a long process; but some have been noticed to give off, besides the branching processes or dendrons, which ramify in the molecular layer, an axis-cylinder process which may extend into the nerve-fibre layer. There

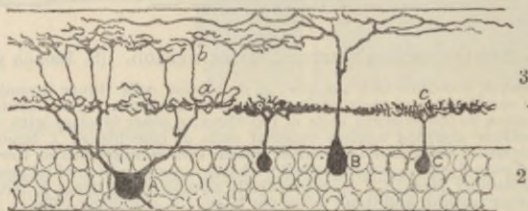


FIG. 359.—SECTION ACROSS THE MOLECULAR AND GANGLIONIC LAYERS OF BIRD'S RETINA, PREPARED BY GOLGI'S METHOD. (R. y Cajal.)

Three or four ganglionic cells, A, B, C, and the terminal arborisations of their dendrons, *a*, *b*, *c*, in the molecular layer, are shown.

are also some cells in the outer part of the granule layer which send their processes into the outer molecular layer. These are the *horizontal-cells* of Cajal (also termed spongioblasts of outer molecular layer). The fibres of Müller have nucleated enlargements (fig. 360, *J*) in the inner nuclear layer.

The *outer molecular layer* is thin, and is composed mainly of the arborisations of the inner granules, of the rod- and cone-fibres, and of the horizontal cells (figs. 357, 360).

As far as the outer molecular layer the retina may be said to consist of nervous elements, but beyond this layer it is formed of modified epithelium-cells.

The *outer nuclear layer* and the *layer of rods and cones* are composed of elements which are continuous through the two layers, and they should properly, therefore, be described as one. It may be termed the *sensory or nerve-epithelium of the retina* (fig. 361, 6 and 7). The elements of which this nerve-epithelium consists are elongated, nucleated cells of two kinds. The most numerous, which we may term the *rod-elements*, consist of peculiar rod-like structures (*rods proper*) set closely side by side, and each of which is prolonged

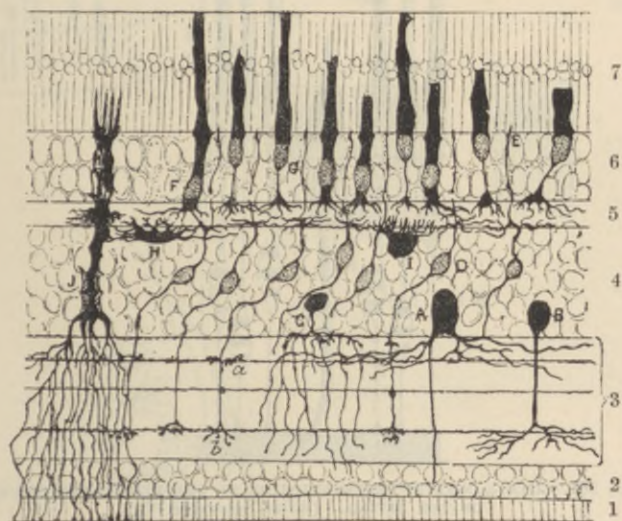


FIG. 360.—SECTION OF BIRD'S RETINA, PREPARED BY GOLGI'S METHOD. (R. y Cajal.)

A, large nerve cell of inner nuclear layer; B, C, amacrine cells; D, small bipolar nerve-cells with one process, ramifying in the inner molecular layer and the other one ramifying in the outer molecular layer, and extending (E) as far as the rods and cones as a fibre of Landolt; F, G, rod- and cone-nuclei respectively; H, I, cells with dendrons ramifying in outer molecular layer; J, fibre of Müller.

internally into a fine varicose fibre (*rod-fibre*) which swells out at one part of its course into a nucleated enlargement, and ultimately ends (in mammals) in a minute knob within the outer molecular layer, where it is embedded in the ramifications of the dendrons of the rod-bipolars. The rod proper consists of two segments, an outer cylindrical and transversely striated segment, which during life has a purplish-red colour, and an inner slightly bulged segment which in part of its length is longitudinally striated. The nucleus of the rod-element often has, in the fresh condition, a trans-

versely shaded aspect (fig. 361). The *cone-elements* are formed of a conical tapering external part, the *cone proper*, which is directly prolonged into a nucleated enlargement, from the farther side of which the *cone-fibre*, considerably thicker than the rod-fibres, passes inwards, to terminate by an expanded arborisation in the outer molecular layer; here it comes into relation with a similar arborisation of dendrons of a cone-bipolar. The cone proper, like the rod, is formed of two segments, the outer of which, much the smaller, is transversely striated, the inner, bulged segment being longi-

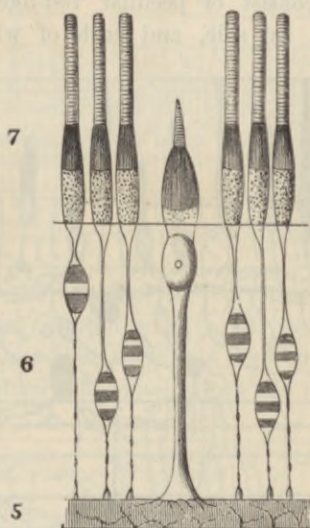


FIG. 361.—DIAGRAMMATIC REPRESENTATION OF THE NERVE-EPITHELIUM OF THE RETINA. (After Schwalbe.)

The designation of the numbers is the same as in fig. 353.

tudinally striated. The inner ends of the rod- and cone-fibres come, as already stated, in contact with the peripheral arborisations of the inner granules, and through these elements and their arborisations in the inner molecular layer a connection is brought about with the ganglionic cells and nerve-fibres of the innermost layers. There appears, however, to be no anatomical continuity between the several elements, but merely an interlacement of ramified fibrils (figs. 357, 360). The connection of the retinal elements with one another and through the optic fibres with the central nervous system (superior corpora quadrigemina and external geniculate bodies) is shown diagrammatically in fig. 362.

In birds, reptiles, and amphibia, a small oil-globule, often brightly

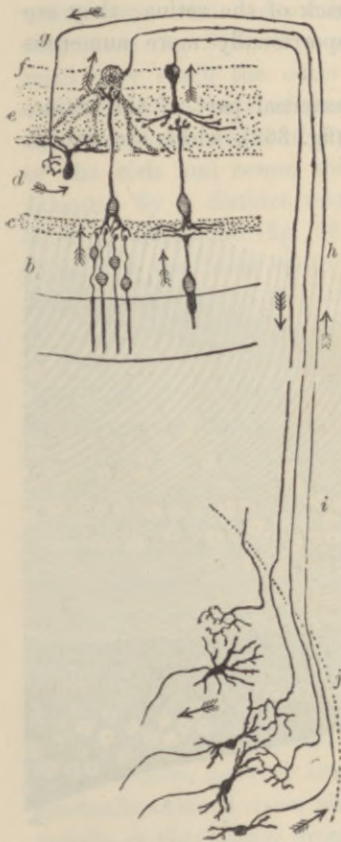


FIG. 362.

FIG. 362.—DIAGRAM OF THE CONNECTIONS OF THE RETINAL ELEMENTS WITH ONE ANOTHER AND WITH THE CENTRAL NERVOUS SYSTEM. (S. Ramón y Cajal.)

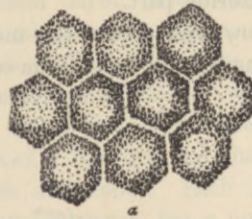
a to *g*, layers of retina; *a*, rods and cones; *b*, outer nuclear layer; *c*, outer molecular layer; *d*, inner nuclear layer; *e*, inner molecular layer; *f*, nerve-cells giving origin to fibres of optic nerve; *g*, *h*, *i*, a centrifugally conducting fibre, with a terminal arborescence in the retina; *j*, grey matter of corpus quadrigeminum.

FIG. 363.—PIGMENTED EPITHELIUM OF THE HUMAN RETINA. (M. Schultze.) (Highly magnified.)


a, cells seen from the outer surface with clear lines of intercellular substance between; *b*, two cells seen in profile with fine offsets extending inwards; *c*, a cell still in connection with the outer ends of the rods.

FIG. 364.—A FIBRE OF MÜLLER FROM THE HUMAN RETINA. ISOLATED. (Henle.) $\frac{1000}{1}$.

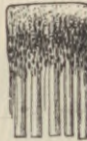b, base of the fibre; *n*, its nucleus; *m.e.l.*, membrana limitans externa; *e.m.l.*, external molecular layer.



a



b



c

FIG. 363.

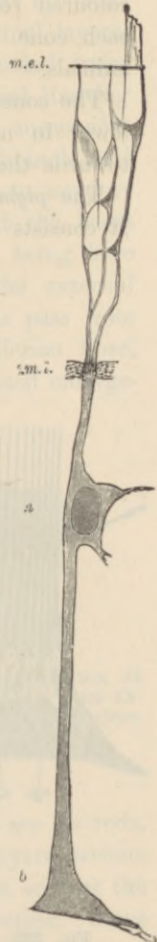

FIG. 364.

coloured red, yellow, or green, is found in the inner segment of each cone. Other variations of structure are met with in different animals.

The cones are most numerous at the back of the retina; they are fewer in number, and the rods are proportionally more numerous towards the anterior part.

The *pigmentary layer* forms the most external part of the retina. It consists of hexagonal epithelium-cells (fig. 363), which are smooth

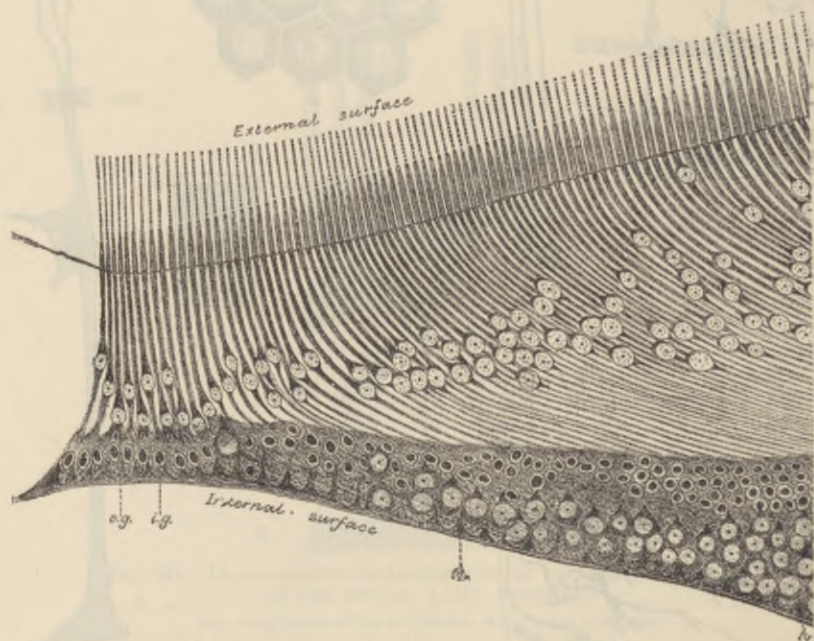


FIG. 365.—SECTION THROUGH THE CENTRAL PART OF THE FOVEA CENTRALIS.
C.H.G. (From a preparation by C. H. Golding-Bird.)

M, bases of Müllerian fibres; *i.g.*, nuclei of inner granules (bipolars); *o.g.*, cone-fibre nuclei.

externally where they rest against the choroid, but are prolonged internally into fine filaments which extend between the rods. The pigment-granules, many of which are in the form of minute crystals, lie in the inner part of the cell, and after prolonged exposure to the light they are found extending along the cell-processes between the rods (Kühne), their function being probably connected with the restoration of the purple colouring matter which has been bleached by the light. This extension of the pigment is accompanied by a shortening of the cones (Engelmann).

Fibres of Müller.—The fibres of Müller (fig. 360, *J*, and fig. 364) are long stiff cells which pass through several of the retinal layers. Commencing at the inner surface of the retina by expanded bases which unite with one another to form the so-called internal limiting membrane (fig. 355), they pass through all the layers in succession, until they reach the outer nuclear layer. Here they branch and expand into a sort of honeycomb tissue which serves to support the fibres and nuclei of the rod- and cone-elements. At the bases of the rods and cones, this sustentacular tissue ceases, being here bounded by a distinct margin which has been called the external limiting membrane (fig. 364, *m.e.l.*), but delicate sheaths pass from it around the bases of the rods and cones. Each Müllerian fibre, as it passes through the inner nuclear layer, has a nucleated enlargement (*n*), indicating the cell-nature of the fibre.

There are two parts of the retina which call for special description.

The *macula lutea* (yellow spot), with its *central fovea* (fig. 365), is the part of the retina which is most immediately concerned in direct vision. It is characterised firstly by its greater thickness (except at the middle of the fovea), secondly by the large number of its ganglion-cells, which are rounded or conical, and thirdly by the large number of cones it contains as compared with the rods. In the central fovea itself there are no rods, and the cones are very long and slender; all the other layers become gradually thinned down almost to complete disappearance, so that the middle of the central fovea is the thinnest part of the retina. Since there are few rods, the nuclear layer loses in great measure its appearance of being composed of closely packed nuclei, and the cone-fibres are very distinct. The direction of these fibres is very oblique in this part of the retina.

The *pars ciliaris retinae*, which commences at the *ora serrata*, where the retina proper abruptly ends, is composed of two epithelial layers (fig. 366), and has no nervous structures. Of the two layers, the external is a thick stratum of pigmented epithelium formed of rounded cells and continuous with the pigmentary layer of the retina on the one hand, and with the uvea of the iris on the other; the inner is a layer of columnar cells, each containing an oval nucleus.

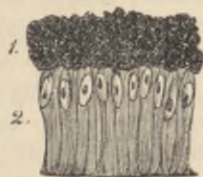


FIG. 366.—A SMALL PORTION OF THE CILIARY PART OF THE RETINA. (Kölliker.) 350 diameters.

1, pigment-cells; 2, columnar-cells.

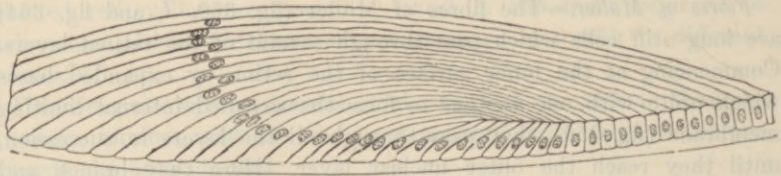


FIG. 367.—SECTION THROUGH THE MARGIN OF THE RABBIT'S LENS, SHOWING THE TRANSITION OF THE EPITHELIUM INTO THE LENS-FIBRES. (Babuchin.)

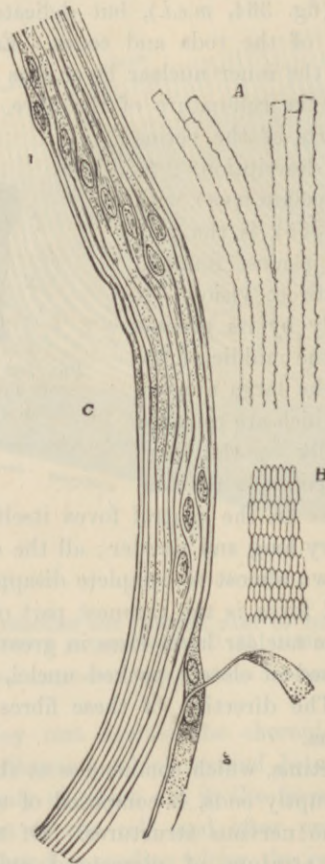


FIG. 368.—FIBRES OF THE CRYSTALLINE LENS. (350 diameters.)

A, longitudinal view of the fibres of the lens from the ox, showing the serrated edges. B, transverse section of the fibres of the lens from the human eye. C, longitudinal view of a few of the fibres from the equatorial region of the human lens. Most of the fibres in C are seen edgewise, and, towards 1, present the swellings and nuclei of the 'nuclear zone'; at 2, the flattened sides of two fibres are seen. (A and B from Kölliker; C from Henle.)

The retina contains but few blood-vessels. The central artery enters and the vein leaves it in the middle of the optic nerve. The larger vessels ramify in the nerve-fibre layer, and there are capillary networks in this layer and in the inner nuclear layer. There are perivascular lymphatic spaces around the veins and capillaries. The sensory epithelium receives no blood-vessels, but is nourished from the vessels of the choroid.

Structure of the lens.—The lens is a laminated fibrous body inclosed by a transparent elastic capsule to which, around the circumference, the fibres of the suspensory ligament are attached. Immediately within the capsule, in front and at the sides, there is a layer of cubical epithelium termed the epithelium of the capsule, but at the margin of the lens the cells become longer and pass by a gradual transition into the lens-fibres (fig. 367). The *fibres* which compose the lens are long and riband-shaped, with finely serrated edges (fig. 368, A); in transverse section they appear prismatic (B). Many of the superficial fibres are nucleated (C), the lens-fibres having originally been developed by the elongation of epithelium-cells.

The **vitreous humour** is composed of soft gelatinous tissue, apparently structureless when examined in the fresh condition, but containing fibres and a few scattered cells, the processes of which are often long and varicose, and the cell-bodies distended by large vacuoles. The *hyaloid membrane*, which invests the vitreous humour, is homogeneous and structureless except in the region of the ciliary processes, where it is fibrous in structure, forming the zonule of Zinn and spreading out into the suspensory ligament of the lens. This part of the hyaloid membrane is connected with a circular fibrous portion of the vitreous humour which serves to give additional firmness to the attachment of the fibres of the suspensory ligament of the lens (Anderson Stuart).

LESSON XLV.

*STRUCTURE OF THE OLFACTORY MUCOUS MEMBRANE
AND OF THE EXTERNAL AND MIDDLE EAR.*

1. VERTICAL sections of the olfactory mucous membrane. The sections may be carried either across the upper turbinate bone, after decalcification in 0·2 per cent. chromic acid, or across the upper part of the nasal septum. Make a sketch under the low power. Notice the difference in the character of the epithelium in the olfactory and respiratory parts of the membrane.

2. Teased preparation of the epithelium of the olfactory mucous membrane. A piece of the membrane is placed quite fresh in osmic acid (1 per cent.) for a few hours, and is then macerated for two days or more in water. The epithelium is broken up in dilute glycerine; the cells easily separate from one another on tapping the cover-glass. Notice the two kinds of cells. Sketch some of the cells under a high power.¹

3. Sections of the external ear (these have been already studied for the cartilage, Lesson XII.).

4. Sections across the cartilaginous part of the Eustachian tube. Sketch under the low power.

5. Preparation of the membrana tympani. A piece of the membrane, stained, is mounted flat in Canada balsam.

Determine the composition of the membrane—*i.e.* the several layers composing it—by focussing carefully with the high power.

STRUCTURE OF THE OLFACTORY MUCOUS MEMBRANE.

The **olfactory region** of the nasal fossæ includes the upper and middle turbinate processes and the upper third of the septum. It is covered by a soft vascular mucous membrane of a yellow colour in man.

The *epithelium* of the olfactory mucous membrane (figs. 369, 370) is very thick and is composed of long tapering cells, set closely side by side and bounded superficially by a cuticular lamina, through which the free ends of the cells project. The cells are of two kinds: 1. Long narrow spindle-shaped or bipolar cells consisting of a larger part or body (*b*), containing the nucleus, and of two processes or poles, one (*c*) straight and cylindrical and extending to the free surface, the other (*d*) very delicate and varicose, looking not unlike

¹The connection of the olfactory cells with the olfactory nerve-fibres is best displayed in embryos, the method of Golgi being employed.

a nerve-fibril and extending down towards the corium. The position of the nuclear enlargement varies, and with it the relative length of the two processes. The distal or free process terminates in a small clear projection, which passes beyond the cuticular membrane; in amphibia, reptiles, and birds, and perhaps also in mammals, it bears fine stiff hairlike filaments. The proximal or varicose process becomes lost amongst the plexus of olfactory nerve-fibrils at the base

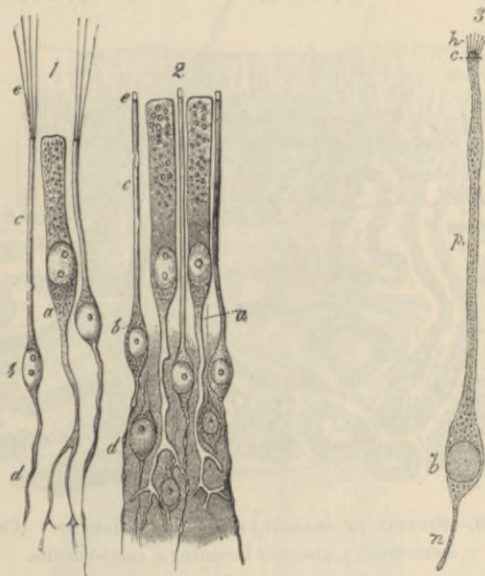


FIG. 369.—CELLS AND TERMINAL NERVE-FIBRES OF THE OLFACTORY REGION.
(Highly magnified.)

1, from the frog; 2 and 3, from man. In 1 and 2, *a*, epithelial cell, extending deeply into a ramified process; *b*, olfactory cells; *c*, their peripheral rods; *e*, the extremities of these, seen in 1 to be prolonged into fine hairs; *d*, their central filaments. In 3, *h*, hairlets; *c*, free border of cell; *p*, peripheral process; *b*, body of cell; *n*, nerve-fibre. 1 and 2 from M. Schultze; 3 from v. Brunn.

of the epithelium; it is connected with one of the fibrils, and ultimately passes through the cribriform plate of the ethmoid to end in an arborisation within one of the olfactory glomeruli (see diagram, fig. 340, p. 301). These cells have been termed *olfactory cells*. 2. Long columnar epithelium-cells (*a*), with comparatively broad cylindrical nucleated cell-bodies placed next to the free surface, and long, forked, and branching tail-like processes extending down to the corium. These are usually regarded not as sensory epithelium-cells, but merely as serving to support the proper olfactory cells. They are the *columnar* or *sustentacular cells*. 3. Tapering cells are

present, at least in some animals, in the deeper part of the epithelium. They rest by their bases upon the corium, and project between the other cells, which they assist to support.

The *corium* of the olfactory mucous membrane is also very thick (fig. 370). It contains numerous blood-vessels, bundles of the olfactory nerve-fibres (which are non-medullated), and a large number of serous glands known as *Bowman's glands* (*b*), which open upon the surface by fine ducts passing between the epithelium cells.

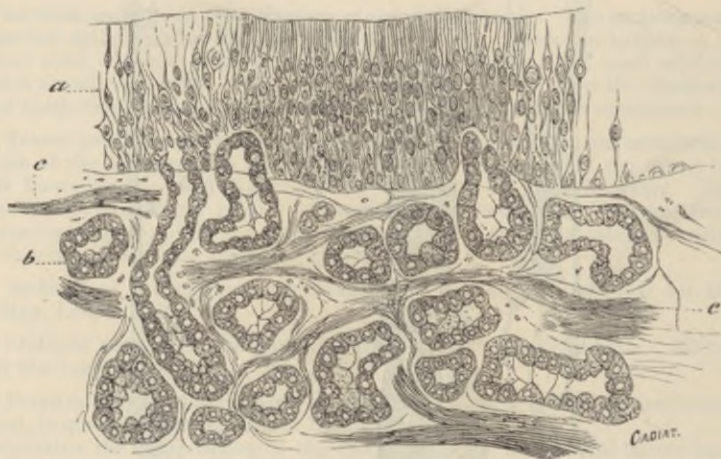

FIG. 370.—SECTION OF OLFACTORY MUCOUS MEMBRANE. (Cadiat.)

a, epithelium; *b*, glands of Bowman; *c*, nerve-bundles.

STRUCTURE OF THE AUDITORY ORGAN.

The **external ear** proper (*pinna*) is composed of elastic fibro-cartilage, invested by a thin closely adherent skin. The skin is covered by small hairs, and connected with these are the usual sebaceous follicles. In some parts—*e.g.* the lobule—there is a considerable amount of adipose tissue; and voluntary muscular fibres are in places attached to the cartilage, and may therefore be seen in sections of the ear.

The **external auditory meatus** is a canal formed partly of cartilage continuous with that of the pinna, partly of bone. It is lined by a prolongation of the skin and is closed by the *membrana tympani*, over which the skin is prolonged as a very thin layer. Near the orifice the skin has hairs and sebaceous glands, and the meatus is also provided throughout the cartilaginous part with small convoluted

tubular glands of a brownish-yellow colour, which yield a waxy secretion (*ceruminous glands*). They appear to represent modified sweat-glands (fig. 371).

The **tympanum** is lined by a mucous membrane which is continuous through the Eustachian tube with the mucous membrane of the pharynx; it is also prolonged into the mastoid cells. The epithelium

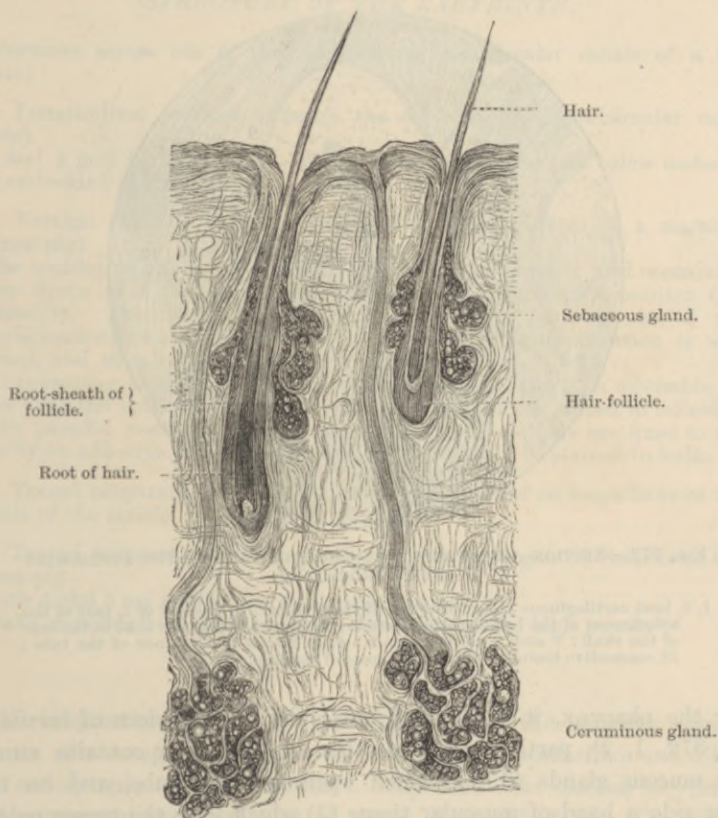


FIG. 371.—CERUMINOUS GLANDS AND HAIRS OF THE EXTERNAL EAR.

is columnar and ciliated in some parts, but in others—*e.g.* roof, promontory, ossicles, and *membrana tympani*—it is a pavement-epithelium.

The **membrana tympani** is a thin membrane formed of fibrous bundles which radiate from the umbo. Within the radial fibres are a few annular bundles. Covering the fibrous membrane externally is a thin layer continuous with the skin of the meatus;

covering it internally is another thin layer, derived from the mucous membrane of the tympanic cavity. Blood-vessels and lymphatics are distributed to the membrane chiefly in the cutaneous and mucous layers.

The **Eustachian tube** is the canal leading from the tympanum to the pharynx. It is formed of bone near the tympanum, but below,

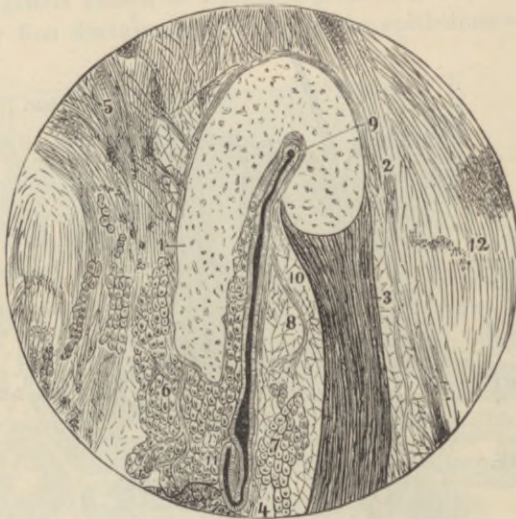


FIG. 372.—SECTION ACROSS THE CARTILAGINOUS PART OF THE EUSTACHIAN TUBE. (Rüdinger.)

1, 2, bent cartilaginous plate; 5, musc. dilatator tube; to the left of 4, part of the attachment of the levator palati muscle; 5, tissue uniting the tube to the base of the skull; 6 and 7, mucous glands; 8, 10, fat; 9 to 11, lumen of the tube; 12, connective tissue on the lateral aspect of the tube.

near the pharynx, it is bounded partly by a bent piece of cartilage (fig. 372, 1, 2), partly by fibrous tissue. The latter contains numerous mucous glands (6, 7), which open into the tube, and on the outer side a band of muscular tissue (3) which joins the tensor palati. The epithelium is ciliated.

LESSON XLVI.

STRUCTURE OF THE LABYRINTH.

1. SECTIONS across one of the membranous semicircular canals of a fish (skate).

2. Longitudinal sections through the ampulla of a semicircular canal (skate).

1 and 2 may be hardened in chromic and osmic acid (see below under 3) and embedded in celloidin.

3. Vertical sections through the middle of the cochlea of a mammal (guinea-pig).

The cochlea is put quite fresh into 0·2 per cent. chromic acid containing a few drops of 1 per cent. osmic acid, or into Flemming's solution (see Appendix). The decalcification can be hastened by the use of the phloroglucin-nitric-acid fluid.¹ When decalcified, the preparation is well washed, and then placed in spirit.

In preparing sections of the above three preparations it is advisable, in order that the epithelium should be kept in position, to embed in celloidin. If the paraffin method of embedding be used, the sections are fixed to the slide by an adhesive process. They should preferably be stained in bulk.

4. Teased preparations of the auditory epithelium of an ampulla or of the macula of the utricle, from the fish.

5. Teased preparations of the epithelium of the organ of Corti from the guinea-pig.

Both 4 and 5 are made from osmic preparations.

Make sketches from all these preparations under the high power.²

The **labyrinth**, which is the essential part of the auditory organ, consists of a complex membranous tube lined by epithelium and filled with endolymph, contained within a bony tube—the osseous labyrinth—of corresponding complexity of shape (figs. 373, 374). The membranous labyrinth does not wholly fill the bony cavity; the rest of the space is occupied by perilymph. The membranous labyrinth (fig. 373) is composed of the *utricle* (*u*), and the three *semicircular canals*, each with an enlargement or ampulla which opens into it, the *sacculæ* (*s*), and the *canal of the cochlea* (*c.c.*).

The branches of the auditory nerve pass to certain parts only of

¹ See Appendix.

² For the methods of obtaining the various parts of the labyrinth for microscopical examination, the reader is referred to the author's *Course of Practical Histology*.

the membranous labyrinth, viz. the maculæ of the utricle and saccule, the cristæ of the ampullæ, and along the whole length of the canal of the cochlea (the shaded parts in fig. 373).

At these places the lining epithelium is specially modified to form a sensory or nerve-epithelium; elsewhere it is a simple pavement-epithelium.

The membranous semicircular canals and the utricle and saccule are composed of fibrous tissue, which is adherent along one side to the endosteum of the bony canal; from the opposite side bands of fibrous tissue pass across the perilymph. Within the fibrous mem-

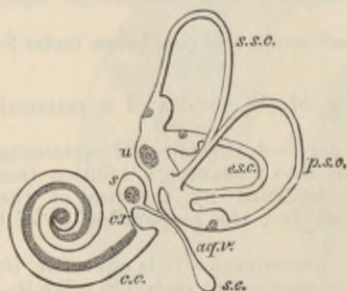


FIG. 373.—PLAN OF THE RIGHT MEMBRANOUS LABYRINTH VIEWED FROM THE MESIAL ASPECT. $\frac{2\frac{1}{2}}{1}$

u, utricle, with its macula and the three semicircular canals with their ampullæ; *s*, saccule; *aq.v.*, aqueductus vestibuli; *s.s.c.*, saccus endolymphaticus; *c.v.*, canalis reuniens; *c.c.*, canal of the cochlea.

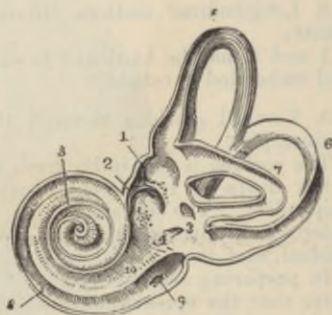

FIG. 374.—VIEW OF THE INTERIOR OF THE LEFT OSSEOUS LABYRINTH.

The bony wall of the labyrinth is removed superiorly and externally. 1, fovea hemieliptica; 2, fovea hemispherica; 3, common opening of the superior and posterior semicircular canals; 4, opening of the aqueduct of the vestibuli; 5, the superior, 6, the posterior, and, 7, the external semicircular canals; 8, spiral tube of the cochlea; 9, scala tympani; 10, scala vestibuli.

brane is a thick clear tunica propria, which, in the semicircular canals, forms papilliform elevations in the interior of the tube (figs. 375, 376).

The places of entrance of the nerve-fibres into the ampullæ are marked by a transverse, inwardly projecting ridge (*crista*), in the saccule and utricle by a thickening of the tunica propria (*macula*). The epithelium at these places is formed of columnar cells (fig. 377), which are surmounted by long, stiff, tapering hairs (*auditory hairs*, fig. 377, *h*), and around these *hair-cells* the axis-cylinders of the nerve-fibres ramify (fig. 379); they are therefore—like the rod- and cone-elements of the retina, the bipolar cells of the olfactory membrane, and the gustatory cells of the taste-buds—sensory or nerve-epithelium cells. Between them are a number of thin and somewhat rigid nucleated cells (*fibre-cells* of Retzius), which rest upon the basement-

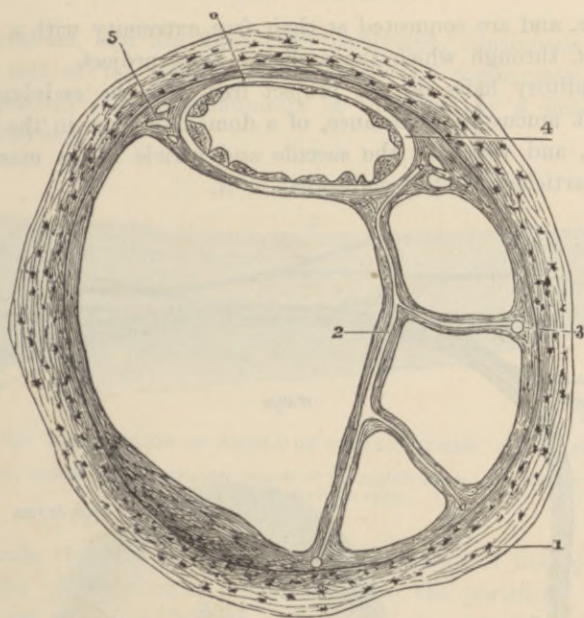


FIG. 375.—SECTION OF ONE OF THE HUMAN SEMICIRCULAR CANALS. (Rüdinger.)
(Magnified.)

- 1, osseous wall; 2, fibrous bands with included blood-vessels, united at 3 with the periosteum; 4, membranous canal with its three layers; 5, short fibrous bands (with intervening spaces) uniting the membranous canal firmly to the periosteum; 6, union of its outermost layer with the periosteum.

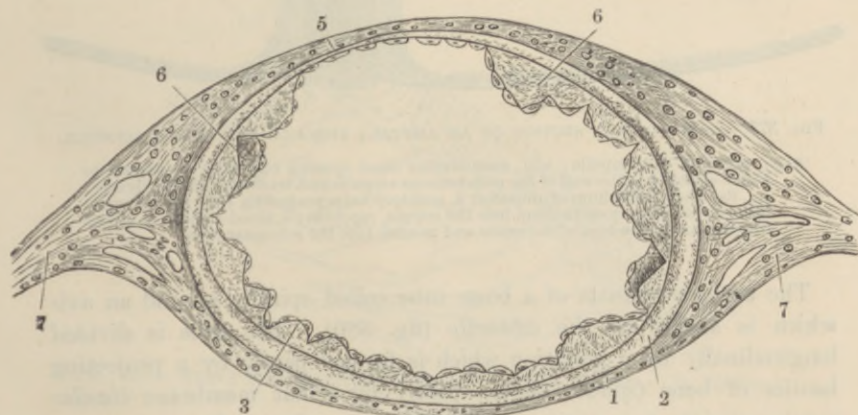


FIG. 376.—SECTION OF MEMBRANOUS SEMICIRCULAR CANAL. (Rüdinger.)
(Much magnified.)

- 1, outer fibrous layer; 2, tunica propria; 3, 6, papilliform projections with epithelial covering; 5, fixed side of the canal, with very thin tunica propria without papillae; 7, fibrous bands passing to periosteum.

membrane, and are connected at their free extremity with a cuticular membrane, through which the auditory hairs project.

The auditory hairs do not project free into the endolymph, but into a soft mucus-like substance, of a dome-like form in the ampullæ (fig. 377), and which in the saccule and utricle has a mass of calcareous particles (*otoliths*) embedded in it.

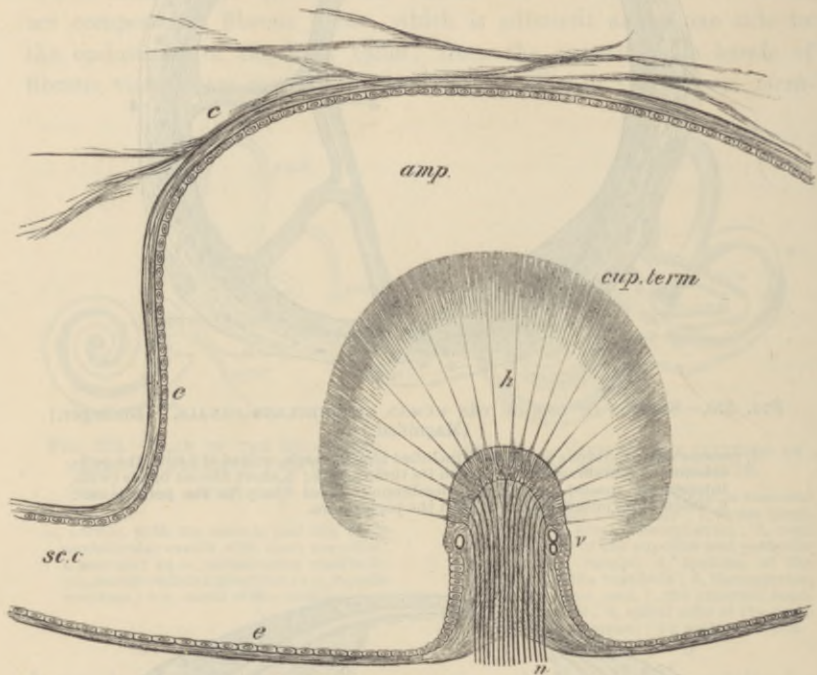


FIG. 377.—LONGITUDINAL SECTION OF AN AMPULLA THROUGH THE CRISTA ACUSTICA.

amp., cavity of the ampulla; *sc.c.*, semicircular canal opening out of it; *c*, connective tissue attached to the wall of the membranous ampulla and traversing the perilymph; *e, e*, flattened epithelium of ampulla; *h*, auditory hairs projecting from the columnar cells of the auditory epithelium into the cupula, *cup.term*; *v*, blood-vessels; *n*, nerve-fibres entering the base of the crista and passing into the columnar cells.

The **cochlea** consists of a bony tube coiled spirally around an axis which is known as the *columella* (fig. 380). The tube is divided longitudinally by a partition which is formed partly by a projecting lamina of bone (*spiral lamina*), partly by a flat membrane (*basilar membrane*), into two parts or *scalæ*; the upper (supposing the cochlea resting base downwards) being termed the *scala vestibuli* (fig. 381, *s.v.*), the lower the *scala tympani* (*s.t.*); the latter is closed at its larger end by the membrane of the fenestra rotunda. The *scalæ* are lined

by endosteum, and are filled with perilymph, continuous with that of the rest of the osseous labyrinth at the commencement of the scala vestibuli; they communicate at the apex by a small opening, the *helicotrema*.

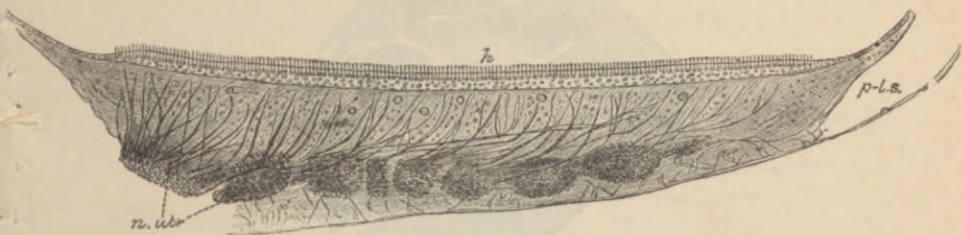


FIG. 378.—SECTION OF MACULA OF UTRICLE, HUMAN. (G. Retzius.)

n. utr., bundles of the utricular branch of the eighth nerve; *h*, auditory hairs;
p.l.s., perilymphatic space.

The scala vestibuli does not occupy the whole of that part of the bony tube of the cochlea which is above the partition. Its outer third is cut off by a delicate connective-tissue membrane (*membrane of Reissner*, fig. 381, *R*), which springs from near the end of the

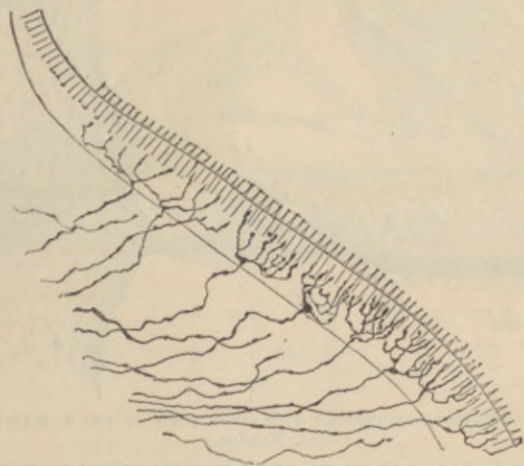


FIG. 379.—NERVE TERMINATIONS IN MACULA. GOLGI METHOD. (G. Retzius.)

spiral lamina, and passes upwards and outwards to the outer wall, thus separating a canal (*D.C*) triangular in section, which is lined by epithelium, and represents the membranous labyrinth of the cochlea (*canal of the cochlea*).

Canal of the cochlea.—The floor of the canal of the cochlea is formed (1) of the extremity of the spiral lamina, which is thickened

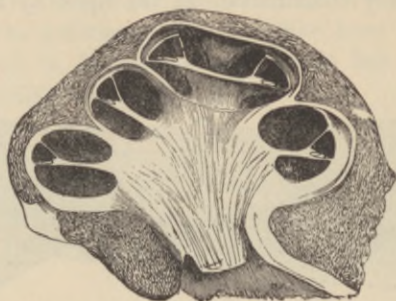

FIG. 380.—VERTICAL SECTION OF THE COCHLEA OF A CALF. (Kölliker.)

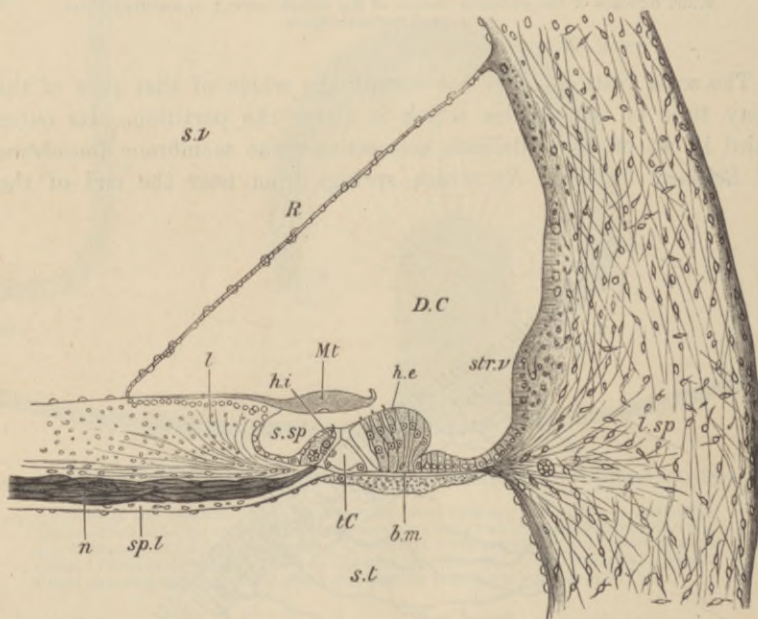


FIG. 381.—VERTICAL SECTION OF THE FIRST TURN OF THE HUMAN COCHLEA. (G. Retzius.)

s.v., scala vestibuli; *s.t.*, scala tympani; *D.C.*, canal of the cochlea; *sp.l.*, spiral lamina; *n.*, nerve-fibres; *l.sp.*, spiral ligament; *str.v.*, stria vascularis; *s.sp.*, spiral groove; *R.*, section of Reissner's membrane; *l.*, limbus laminae spiralis; *Mt.*, membrana tectoria; *t.c.*, tunnel of Corti; *b.m.*, basilar membrane; *h.i.*, *h.e.*, internal and external hair-cells.

above by a peculiar kind of connective tissue, forming an overhanging projection known as the *limbus* (fig. 381, *l*); (2) of the basilar membrane (*b.m.*), which stretches across from the end of the bony

lamina to the outer wall, and is attached to this by a projection of reticular connective tissue termed the *spiral ligament* (*l.sp.*).

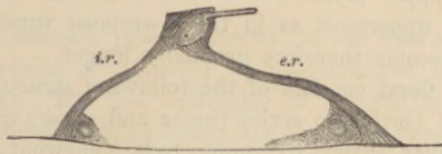


FIG. 382.—A PAIR OF RODS OF CORTI, FROM THE RABBIT'S COCHLEA, IN SIDE VIEW. (Highly magnified.)

b, *b*, basilar membrane; *i.r.*, inner rod; *e.r.*, outer rod. The nucleated protoplasmic masses at the feet are also shown.

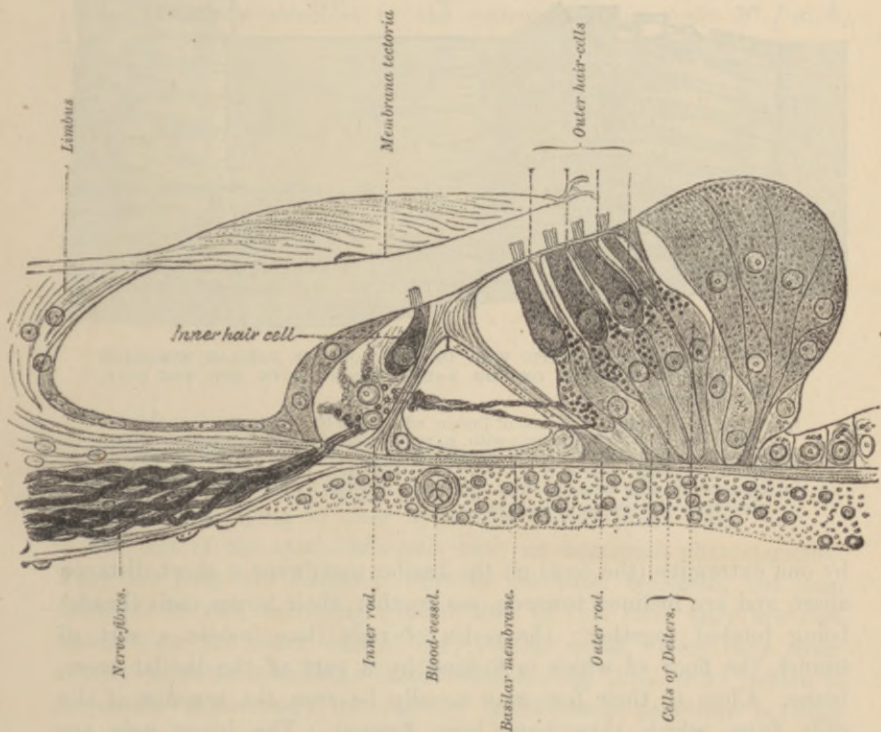


FIG. 383.—SECTION THROUGH THE ORGAN OF CORTI OF THE HUMAN COCHLEA. (G. Retzius.) (Highly magnified.)

The *basilar membrane* is composed of stiff straight fibres, which extend from within out, and are embedded in a homogeneous stratum. It is covered below by a layer of connective tissue continuous with

the endosteum of the scala tympani; above, the modified epithelium, which forms the *organ of Corti*, rests upon it. It becomes gradually broader in the upper turns of the cochlea (rather more than twice as broad in the uppermost as in the lowermost turn), and its constituent fibres become therefore gradually longer.

The **organ of Corti** consists of the following structures:

1. The *rods of Corti*, two series (inner and outer) of stiff, striated fibres of a peculiar shape, the inner rods somewhat like a human ulna, the outer like a swan's head and neck (fig. 382). They rest

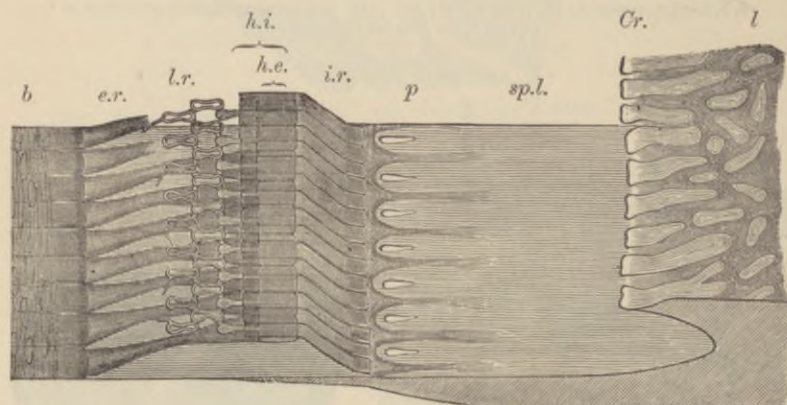


FIG. 384.—SEMI-DIAGRAMMATIC VIEW OF PART OF THE BASILAR MEMBRANE AND TUNNEL OF CORTI OF THE RABBIT, FROM ABOVE AND THE SIDE. (Much magnified.)

l, limbus; *Cr*, extremity or crest of limbus with tooth-like projections; *b*, basilar membrane; *sp.l.*, spiral lamina with *p*, perforations for transmission of nerve-fibres; *i.r.*, fifteen of the inner rods of Corti; *h.i.*, their flattened heads seen from above; *e.r.*, nine outer rods of Corti; *h.e.*, their heads, with the phalangeal processes extending outward from them and forming, with the two rows of phalanges, the lamina reticularis, *l.r.*

by one extremity (the foot) on the basilar membrane a short distance apart, and are inclined towards one another, their larger ends (heads) being jointed together; the series of rods thus inclose a sort of tunnel, the floor of which is formed by a part of the basilar membrane. Close to their feet may usually be seen the remains of the cells from which they have been formed. The inner rods are narrower and rather more numerous than the outer. Each outer rod has a process which extends outwards and is known as the phalangeal process. This forms part of—

2. A *reticular lamina* (fig. 384, *l.r.*), which is a cuticular structure extending like a wire-net over the outer epithelium-cells of the organ of Corti, and is composed of two or three series of stiff fiddle-shaped

rings (phalanges) cemented together in such a manner as to leave square or oblong apertures through which the hair-cells (see below) project.

3. The *outer hair-cells* placed external to the rods of Corti. These are epithelium-cells of columnar shape, arranged in three or four series (fig. 383). The free extremity of the cell is surmounted by a bundle of short *auditory hairs*, and projects through one of the apertures in the reticular lamina; the fixed extremity is prolonged into a stiff cuticular process (fig. 385, *p*), which is attached to the basilar membrane. Between them are other supporting cells which are tapered in the same manner, but rest by their larger end upon the basilar membrane, and are prolonged above into a cuticular process which is attached to the reticular lamina (*cells of Deiters*, figs. 383, 386).

FIG. 385.—AN OUTER HAIR-CELL IN CONNECTION WITH ITS BASILAR PROCESS. From the guinea-pig. (Highly magnified.)

Two auditory hairs have remained attached to the cell; *b*, bulged lower end of cell; *p*, basilar process, protoplasmic above, but becoming cuticular below, and slightly expanded at the extremity, *f*, which is broken away from the basilar membrane.



4. The *inner hair-cells* (fig. 383), placed internal to the rods of Corti. They form a single series of columnar cells surmounted by auditory hairs, lying in close apposition to the inner rods.

The rest of the epithelium-cells have no important characteristics. They are long and columnar next to the outer hair-cells, but soon diminish in size, becoming cubical, and in this form they are continued over the outer wall of the cochlear canal. Here they cover a very vascular membrane (*stria vascularis*, fig. 381, *str.v.*), which is frequently pigmented; its capillary blood-vessels penetrate between the epithelium-cells. Internal to the inner hair-cells the epithelium also soon becomes cubical; it is prolonged in this form over the limbus of the spiral lamina. The epithelium of Reissner's membrane is of the pavement variety.

The *membrana tectoria* (figs. 381, 383) is a soft, fibrillated structure, which is attached along the upper surface of the limbus, and lies like a pad over the organ of Corti. It thins out towards the distal

margin, here becoming somewhat reticular, and, according to Retzius, it is attached to the lamina reticularis. In sections it usually appears raised a short distance above the auditory hairs, but it is probable that it always rests upon them during life.

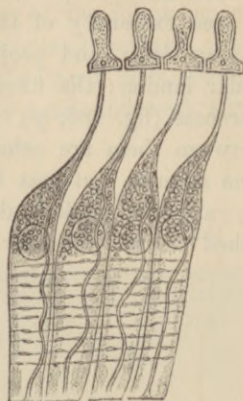


FIG. 386.—FOUR CELLS OF DEITERS FROM THE RABBIT. (After G. Retzius.)
(Highly magnified.)

The varicose lines are spirally-running nerve-fibrils. The phalangeal processes are attached above to a portion of the lamina reticularis.

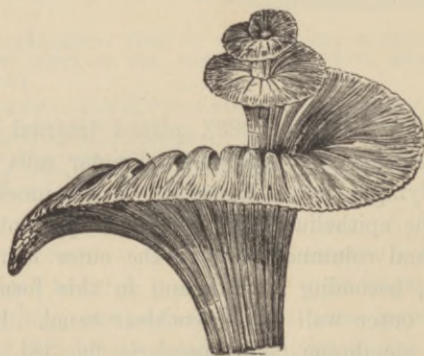

FIG. 387.—GENERAL VIEW OF THE MODE OF DISTRIBUTION OF THE COCHLEAR NERVE, ALL THE OTHER PARTS HAVING BEEN REMOVED.

The fibres of the cochlear branch of the auditory nerve enter the base of the columella, and run in canals through its substance, being gradually deflected outwards as they pass upwards into the spiral lamina, at the base of which they swell out into a ganglionic cord (spiral ganglion). Many, if not all the fibres, are connected with the cells of this ganglion.

After traversing the spiral lamina they emerge in bundles, and the fibres then, having lost their medullary sheath, pass into the epithelium of the inner hair-cell region. Here some of them course at right angles and are directly applied to the inner hair-cells,

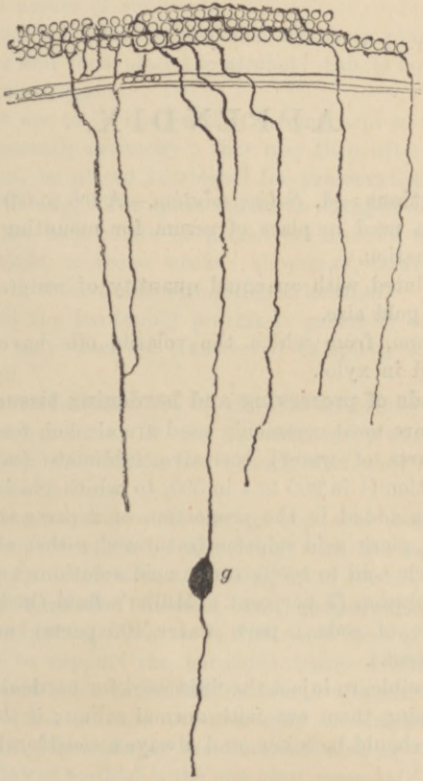


FIG. 388.—ENDING OF SOME OF THE FIBRES OF THE COCHLEAR NERVE AMONGST THE HAIR-CELLS. (G. Retzius.)

This preparation is made by Golgi's method, and is viewed from above. *g*, a cell belonging to the spiral ganglion.

whilst others cross the tunnel of Corti, to become applied in like manner to the outer hair-cells and the cells of Deiters; but there does not appear any direct continuity between the nerve-fibrils and the cell-substance.

APPENDIX.

Mounting solutions :—1. *Saline solution*.—A 0·6 to 0·9 per cent. solution of common salt is used in place of serum for mounting fresh tissues for immediate examination.

2. *Glycerine*, diluted with an equal quantity of water. The cover-glass may be fixed by gold size.

3. *Canada balsam*, from which the volatile oils have been driven off by heat, dissolved in xylol.

General methods of preserving and hardening tissues and organs.—The fluids which are most commonly used are alcohol, formol (diluted with from 9 to 99 parts of water), corrosive sublimate (saturated solution), chromic acid solution (1 in 200 to 1 in 500, to which glacial acetic acid may advantageously be added in the proportion of 2 parts acetic acid to 1000 chromic solution), picric acid solution (saturated, either alone or containing 2 parts of sulphuric acid to 1000), osmic acid solution (1 per cent.), bichromate of potash solution (3 per cent.), Müller's fluid (bichromate of potash $2\frac{1}{2}$ parts, sulphate of soda 1 part, water 100 parts), and bichromate of ammonia (3 per cent.).

It is best, if possible, to inject the fluid used for hardening into the blood-vessels after washing them out with normal saline; if this is not possible, very small pieces should be taken, and always a considerable amount of the hardening fluid.

The fluid of most universal application is formol. This is a 40 per cent. solution of formaldehyde. It hardens tissues quickly and penetrates readily.

For preserving the structure of cells and nuclei, one of the best fixing fluids is that recommended by Flemming. This consists of 15 vols. of 1 per cent. chromic acid, 4 vols. of 2 per cent. osmic acid, and 1 vol. glacial acetic acid. It may be diluted with from two to five times its bulk of water before use. The tissue should be washed for several hours in tap-water after hardening, and then placed in alcohol.

Tissues to be hardened in alcohol should usually be placed at once in strong methylated spirit, or, better, in absolute alcohol. They are ready for cutting as soon as they are dehydrated; as a rule they may be left indefinitely in alcohol without deterioration. Organs which contain much fibrous tissue, such as the skin and tendons, should not go into stronger alcohol than about 80 or 90 per cent.; otherwise they become too hard

to cut. Alcohol is generally used after the other fixing reagents, partly to complete the hardening, partly on account of its dehydrating property, since previous to embedding in paraffin all trace of water must be eliminated from the tissue. If corrosive sublimate be used for hardening, tincture of iodine must be freely added to the alcohol subsequently used, to get rid of the excess of sublimate.

Many tissues can be instantly hardened by being plunged for a minute into boiling water and then placed in alcohol: this is not, however, a good method for glandular organs.

For tissues that are to be hardened in chromic acid an immersion of from 7 to 14 days is generally necessary; they may then, after washing for some hours in tap-water, be placed in alcohol for preservation and to complete the process of hardening. The spirit should be changed once or twice.

Organs placed in bichromate of potash or Müller's fluid are ready for section in a fortnight or three weeks; they may, however, be left for a much longer time in those fluids without deterioration.

With picric acid the hardening process is generally complete in 2 or 3 days; the organs may then be transferred to spirit, which ought to be frequently changed.

The hardening of the brain and spinal cord in Müller's fluid takes from 3 weeks to as many months. It can be hastened by warmth or by placing small pieces in Marchi's solution (see below), after they have been a week or 10 days in Müller's fluid.

Tissues containing calcareous matter, *e.g.* bone and tooth, may be rapidly decalcified in a solution made by dissolving, with the aid of heat, 1 grm. phloroglucin in 10 c.c. nitric acid, and filling up to 100 c.c. with water.

Embedding of hardened tissues, and preparation of sections.—Sections are most advantageously made with some form of microtome. It is generally needful to support the hardened tissue whilst it is being cut, and with this object it is embedded in some substance which is applied to it in the fluid condition and becomes solid on standing. The embedding substance can either simply inclose the tissue, or the tissue may be soaked in it: the latter method is the one most commonly employed.

The embedding substance chiefly used is paraffin of 50° C. melting point.

Embedding in paraffin.—Before being soaked in melted paraffin, the piece of tissue may be stained; it is then dehydrated by absolute alcohol, and soaked in cedar-wood oil, xylol, or chloroform. It is now transferred to molten paraffin, which should not be too hot, and is soaked in this for one or several hours, according to thickness. It is then placed in a mould or in a watch-glass which has been smeared with glycerine, and is covered with molten paraffin which is allowed to cool quickly. A square block of the paraffin containing the tissue is then fixed in the desired position on the microtome, thin sections are cut, the paraffin dissolved out by turpentine or xylol, and the sections mounted.

If it be desired to cut a riband of successive sections, a paraffin of lower melting point is smeared over the opposite sides of the block; the sections then adhere together as they are cut.

Preparation of frozen sections.—The bichromate solutions and formol are the best fluids to use for preserving tissues which are to be frozen in place of being embedded. The tissue requires to be soaked in gum-water before being placed upon the freezing microtome.

Embedding in celloidin.—The piece to be embedded is dehydrated by alcohol, and is then placed in a solution of celloidin in alcohol and ether or in collodion of double strength. After 24 hours or more it is removed from the celloidin (collodion) and placed upon a metal holder (which can be fixed in the microtome when the celloidin has been hardened). When the celloidin is set, the holder is plunged in alcohol (85 per cent.), and after a few hours, sections may be cut with a knife wetted with spirit of the same strength. The sections are placed in 96 per cent. alcohol; and passed

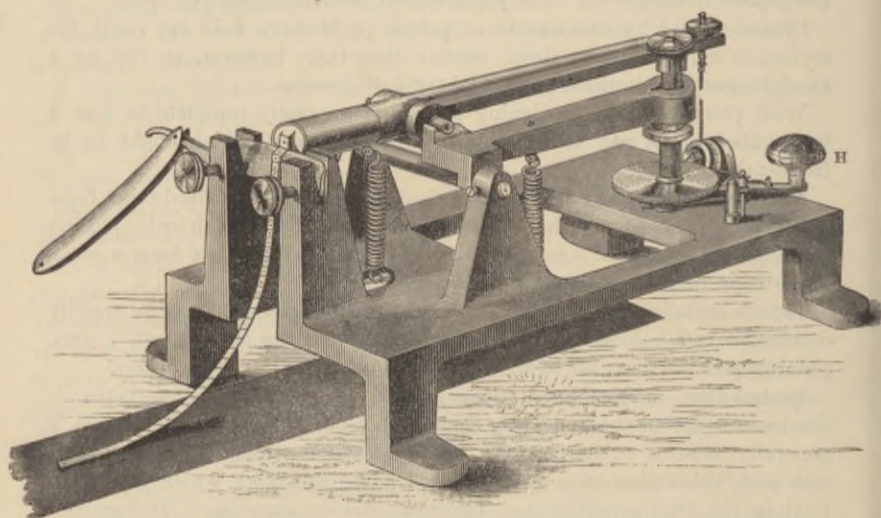


FIG. 389.—ROCKING MICROTOME.

through cedar-wood oil, bergamot oil, or xylol into xylol balsam. They must not go into clove-oil, nor into absolute alcohol. The advantage of the method is that the celloidin, which is quite transparent, need not be got rid of in mounting the sections, and serves to keep the parts of a section together: it is thus very useful for friable tissues or for large sections. The tissue may either be stained in bulk before embedding, or the sections may be stained. The method is especially valuable for the central nervous system.

Microtomes.—A section-cutting apparatus or microtome is essential for histological work. Several kinds are made, but those which are most generally useful are the Cathcart microtome for freezing; the rocking microtome of the Cambridge Scientific Instrument Company, and the tripod microtome for objects which have been embedded in paraffin; and the sliding microtome for celloidin-embedded tissues. The action of the rocker is auto-

matic; that is to say, every to-and-fro movement of the handle, H, not only cuts a section of the tissue of definite thickness, but also moves the paraffin block forwards in readiness for the next section. And by employing a rectangular block of paraffin of the proper consistency, a long series of sections of the same object, of equal thickness, can be obtained and made to adhere together in a riband (as shown in fig. 389). The sections can be kept in series by the employment of some adhesive method of mounting the riband.

The tripod microtome is a simple and efficient little instrument, and has the advantage of being very cheap. It consists of a metal frame (fig. 390) in which the razor is fixed, provided with a micrometer screw by which the height of the razor-edge is adjusted. The paraffin block




FIG. 390.—TRIPOD MICROTOME. (Birch's pattern.)

containing the tissue is fixed by the aid of heat on a flat piece of glass over which the tripod slides. The razor-edge is lowered after each successive section.

In the Cathcart freezing microtome (fig. 391) the tissue, after being soaked in gum-water, is placed on a metal plate and frozen by playing an ether-spray on the under surface of the plate. The plate is moved upwards by a finely cut screw, and the knife or plane used to cut the sections is guided over the plate by passing over glass slips. In using the freezing microtome, especially for the nervous system, it is important not to freeze the tissue too hard, or the section will roll up like an ice-wafer.

For celloidin-embedded preparations it is necessary to cut the sections with a knife kept wetted with spirit. For this purpose a sliding microtome, in which the knife or razor is moved horizontally over the tissue,

with the edge obliquely inclined to the direction of movement, is most useful. That designed by Thoma, and made by Jung of Heidelberg (fig. 392), is admirably constructed, and works with great accuracy. In all cases it is most important that the knife should be in perfect order.

Adhesive methods of mounting.—Friable sections, such as sections of small embryos, and ribands of sections such as are cut with many microtomes, may be mounted in the following way:—A slide or cover-glass is smeared very thinly with a mixture of equal parts of glycerine and white of egg (containing 1 per cent. salicylate of soda); a little water is poured over, and the riband of sections is placed on the water, which is then warmed on a hot




FIG. 391.—CATHCART FREEZING MICROTOME.

plate or over a small flame until the paraffin becomes flattened out, without actually melting. The water is then drained off, the slide put in a warm place for the remainder of the water to evaporate, and then heated sufficiently to melt the paraffin. It is next immersed for an hour in a mixture of equal parts of alcohol and ether to coagulate the albumen (this can be omitted), then in xylol to remove the paraffin, after which the sections may, if already stained, be mounted at once in xylol balsam; if not stained, treat first with alcohol, then water, and then stain, and finally pass through water, alcohol, and xylol, into xylol balsam.

A simpler method, but one which, in most cases, answers the purpose very well, is to place the riband or the individual sections cut from paraffin on the surface of tap-water on a slide, warm just sufficiently to

flatten out the paraffin but not to melt it, then drain off the water, and put the slide and sections aside for one or more hours until all the water has evaporated. The sections are found to have adhered firmly to the slide (they may, if desired, be yet more firmly fixed by drawing a brush moistened with solution of celloidin in oil of cloves over them). The paraffin can now be removed by washing the slide with xylol or immersing it in xylol. If not previously stained they can then be passed through alcohol and stained and mounted as just described.

The following table shows the methods which may be adopted for the treatment of paraffin-cut sections or ribands of sections :

	1. Place on a slide or cover-glass in a drop of tap-water : the glass may previously have been smeared with glycerine and egg-white : warm gently.
	2. Drain off water and allow to dry <i>completely</i> .
	3. Warm until paraffin is just melted.
	4. Dissolve paraffin away with xylol.
If tissue is already stained in bulk.	If tissue is not already stained.
Mount in xylol balsam.	5. Absolute alcohol.
	6. 50 per cent. alcohol.
	7. Stain (<i>e.g.</i> hæmalum or carmalum).
	8. Water.
	9. 50 per cent. alcohol.
For sections cut by the <i>freezing</i> or <i>celloidin methods</i> , if the tissue has already been stained in bulk, the sections need only be put through alcohol and xylol or bergamot oil, and then mounted in xylol balsam. If it has not already been stained, begin at No. 6.	10. Alcohol or methylated spirit (the alcohol may contain either eosin or picric acid, if a double staining is desired).
	11. Xylol or bergamot oil or clove-oil.
	Mount in xylol balsam.

Staining of sections.—The fluids most commonly employed for the staining of sections are:—1. Solutions of hæmatoxylin and alum; 2. Solutions of carmine with or without alum; 3. Certain aniline dyes. The time of immersion in the staining fluid varies according to the strength of the fluid and the mode by which the tissue has been hardened. The necessity of staining sections may be avoided if the tissue is stained in bulk before embedding. For this purpose a piece of tissue is left to stain for 24 hours or more. The excess of stain is removed from the sections (after they have been cleared of paraffin by immersion in xylol) by treating them with alcohol containing 1 to 10 parts per 1000 of hydrochloric acid, and the sections are thus rendered very clear and

distinct in all their details. The sections are then thoroughly washed with tap-water, dehydrated by alcohol, and passed through clove-oil or xylol into xylol balsam. For some purposes an alcoholic solution of magenta is useful for staining in bulk; from this the tissue goes into a small quantity of oil of cloves, and after being soaked with this it is passed through xylol into molten paraffin.

The following are some of the principal staining solutions and methods of staining for special purposes:—

1. *Delafield's hæmatoxylin*.—To 150 cubic centimetres of a saturated solution of alum in water add 4 cubic centimetres of a saturated solution of hæmatoxylin in alcohol. Let the mixture stand 8 days, then decant, and add 25 cubic centimetres of glycerine, and 25 cubic centimetres of methylic alcohol.




FIG. 392.—INCLINED PLANE MICROTOME.

To stain sections add a few drops of this solution to a watch-glassful of *distilled* water. If overstained the excess of colour can be removed by alcohol containing 1 per cent. nitric or hydrochloric acid. With long keeping this solution becomes red instead of blue; a trace of ammonia will restore the blue colour.

2. *Ehrlich's hæmatoxylin*.—Dissolve 2 grammes hæmatoxylin in 100 cubic centimetres alcohol; add 100 cubic centimetres water, 100 cubic centimetres glycerine, and 10 cubic centimetres glacial acetic acid. This solution will keep almost indefinitely: it is valuable for staining in bulk, as it does not overstain tissues. For staining sections it is best to dilute the solution either with distilled water or with 30 per cent. alcohol. After the sections have been stained they must be thoroughly washed with tap-water. This develops the blue colour of the hæmatoxylin.

3. *Kultschitzky's hæmatoxylin*.—Dissolve 1 gramme hæmatoxylin in a little alcohol, and add to it 100 cubic centimetres of a 2 per cent. solution of acetic acid. This solution is valuable for staining sections of the nervous system (see Weigert-Pal process).

4. *Hæmalum*.—Hæmatoxylin-alum solutions acquire their colouring properties only as the hæmatoxylin on keeping becomes converted into hæmatein. The latter substance may, therefore, as recommended by

Mayer, be used advantageously in place of hæmatoxylin. The following mode of preparing the solution may be adopted:—Dissolve 50 grammes of ammonia alum in 1 litre of water, and 1 gramme of hæmatein in 100 c.c. of rectified spirit. Add the hæmatein solution gradually to the alum. The mixture is ready for staining at once, either as it is or diluted with distilled water. A small piece of thymol or a little carbolic acid should be added to prevent the growth of moulds.

5. *R. Heidenhain's method.*—After hardening in alcohol, or in saturated solution of picric acid and then in alcohol, place the tissue for 12 to 24 hours in a $\frac{1}{2}$ per cent. watery solution of hæmatoxylin, and then from 12 to 24 hours more in a $\frac{1}{2}$ per cent. solution of yellow chromate of potash. Now, place in alcohol, pass through xylol, and embed in paraffin.

6. *M. Heidenhain's method.*—Harden in sublimate, followed by alcohol; fix sections to slide by water method; treat with iodised alcohol; transfer to 1.5 per cent. solution of sulphate of iron and ammonia; rinse with distilled water; place in 0.5 per cent. pure hæmatoxylin in water for 12 to 18 hours; differentiate in the sulphate of iron and ammonia solution until nearly decolorised; wash for 15 minutes in tap-water; dehydrate and mount in the usual way. This method is especially adapted for exhibiting the centrosomes of cells.

7. *Carmalum (Mayer).*—One of the best stains either for sections or bulk-staining. If the sections are subsequently passed through alcohol containing picric acid in solution a valuable double stain is produced.

Carminic acid,	-	-	-	-	-	-	-	1 gramme.
Ammonia alum,	-	-	-	-	-	-	-	10 grammes.
Distilled water,	-	-	-	-	-	-	-	200 c.c.

Boil together, allow to cool and filter. Add thymol or a little carbolic acid to prevent the growth of moulds.

8. *Carminate of ammonia.*—Prepared by dissolving carmine in ammonia and allowing the excess of ammonia to escape by slow evaporation. The salt should be allowed to dry and be dissolved in water as required.

9. *Picro-carminate of ammonia (picro-carmine, Ranvier).*—To a saturated solution of picric acid add a strong solution of carmine in ammonia, until a precipitate begins to form. Evaporate on the water bath (or, better, allow it to evaporate spontaneously) to one half its bulk; add a little carbolic acid to prevent the growth of moulds; filter from the sediment.

10. *Borax-carmine.*—Dissolve 4 grammes borax and 3 grammes carmine in 100 cubic centimetres of warm water. Add 100 cubic centimetres of 70 per cent. alcohol, filter and let stand. This solution improves on keeping. It is useful for staining in bulk.

After staining with borax-carmine, the tissue should be placed in 70 per cent. alcohol containing 5 drops of hydrochloric acid to 100 cubic centimetres.

11. *Aniline dyes.*—These are used either in aqueous solution (which may contain 0.01 per cent. of caustic potash) or in water shaken up with aniline oil, and it is usual to overstain a tissue with them, and subsequently to

decolorise with alcohol or with acid-alcohol (1 to 10 per 1000 hydrochloric acid). Those most employed are the "basic" dyes—methyl-blue, methylene-blue, gentian-violet, toluidin-blue, saffranin and vesuvin; and the "acid" dyes—eosin or erythrosin and orange G. Double stains are obtained by combining eosin with methyl-blue or toluidin-blue (Mann), the sections being first stained for 10 minutes in 1 per cent. aqueous eosin and then, after rinsing with water, for 20 minutes in 1 per cent. of the blue solution, after which they are decolorised by absolute alcohol. The decolorisation is arrested by xylol. A double stain is also obtained by combining eosin with hæmalum. A triple stain may be got, as suggested by Ehrlich, by mixing together aqueous solution of orange G., acid-fuchsin, and methyl-green in certain proportions.¹

12. *Magenta-hæmalum*.—Take 5 cubic centimetres of a 1 per cent. alcoholic solution of magenta, and to it add 20 cubic centimetres glycerine. Dilute with distilled water to 100 cubic centimetres. Just previous to use, add one part hæmalum to two parts of the magenta solution. This solution serves for fresh tissues.

13. *Flemming's method for karyokinetic nuclei*.—This is especially valuable for staining cell-nuclei in karyokinesis. The tissue elements having been fixed by sublimate, by dilute chromic and acetic acid, or by Flemming's solution, small shreds or thin sections are placed for 2 days in saturated alcoholic solution of saffranin, mixed with an equal amount of aniline-water. They are then washed with distilled water and decolorised in absolute alcohol (which may contain 1 per 1000 hydrochloric acid) until the colour is washed out from everything except the nuclei. They are then again rinsed in water and placed in saturated aqueous solution of gentian violet for 2 hours, washed again in distilled water, decolorised with alcohol until only the nuclei are left stained, then at once transferred to bergamot oil, and from this are mounted in xylol balsam. Gentian violet and several other aniline colours may be employed in place of saffranin from the first.

14. *Aniline blue-black*.—Dissolve 1 gramme of aniline blue-black in a mixture of 30 parts of water with 20 of alcohol. This is sometimes used for staining sections of the central nervous system.

15. *Marchi's solution*.—This is a mixture of Müller's fluid (2 parts) with 1 per cent. osmic acid (1 part). It is of great value for staining nerve-fibres in the earlier stages of degeneration, before sclerosis sets in (especially a few days after the establishment of a lesion). All the degenerated medullated fibres are stained black, whilst the rest of the section remains almost unstained. It is best to put thin pieces of the brain or cord to be investigated singly into a large quantity of the solution (after previously hardening for 10 days in Müller's fluid), and to leave them in it for a week or more; but if necessary sections can be stained; in this case the process is more complicated.² In either case they are mounted by the usual process in xylol balsam.

¹ For details of these and other staining methods, the student is referred to the author's *Course of Practical Histology*, or to A. E. Lee's *Microtommists' Vade Mecum*.

² See Hamilton, *Brain*, 1897, p. 180.

16. *Weigert-Pal method.*—This method is of great value for the central nervous system. By it all medullated nerve-fibres are stained dark, while the grey matter and any sclerosed tracts of white matter are left uncoloured. The following modification of the original method can be recommended:—Pieces which have been hardened in Müller's fluid and afterwards kept a short time in alcohol (without washing in water) are embedded in celloidin, and sections are cut as thin as possible. Or sections may be made by the freezing method direct from Müller's fluid, if the tissue is first soaked in gum-water for a few hours. In either case they are placed in water, and from this are transferred to Marchi's fluid (see above, § 15), in which they are left for a few hours. They are then again washed in water and transferred to Kulschitzky's hæmatoxylin (see above, § 3). In this they are left overnight, by which time they will be completely black. After again washing in water they are ready to be bleached. This is accomplished by Pal's method as follows:—Place the overstained sections, first in $\frac{1}{4}$ per cent. solution of potassic permanganate for five minutes; rinse with water and transfer to Pal's solution (sulphite of soda 1 gramme, oxalic acid 1 gramme, distilled water 200 cubic centimetres), in which the actual bleaching takes place. They are usually sufficiently differentiated in a few minutes: if not, they can be left longer in the solution without detriment. If after half an hour they are not differentiated enough, they must be put again (after washing) into the permanganate for some minutes, and then again into Pal's solution. After differentiation they are passed through water, alcohol (with or without eosin), and oil of bergamot (or xylol), to be mounted in Canada balsam. The advantages which this modification has over the original methods are (1) the very finest medullated fibres are brought to view with great surety; (2) the staining of the fibres is jet black, and offers a strong contrast to the colourless grey matter; (3) the sections are easily seen and lifted out of the acid hæmatoxylin, which has very little colour; (4) it is difficult to overbleach the sections; (5) the stain is remarkably permanent.

As a modification of the above, Bolton recommends to harden with formol, place the sections for a few minutes in 1 per cent. osmic acid, stain for 2 hours in acid logwood at 40° C., and then proceed with the bleaching process.

17. *Staining with chloride of gold.*—*a. Cohnheim's method.*—Place the fresh tissue for from 30 to 60 minutes in a $\frac{1}{2}$ per cent. solution of chloride of gold; then wash and transfer to a large quantity of water just acidulated with acetic acid. Keep for 2 or 3 days in the light in a warm place. This answers very well for the cornea. If it be principally desired to stain the nerve-fibrils within the epithelium, the cornea may be transferred after 24 hours (after the outlines of the larger nerves are just apparent to the naked eye) to a mixture of glycerine (1 part) and water (2 parts), and left in this for 24 hours more (Klein.)

β. Löwit's method.—Place small pieces of the fresh tissue in a mixture of 1 part of formic acid to 2 to 4 parts of water for $\frac{1}{2}$ to 1 minute; then in 1 per cent. chloride of gold solution for 10 to 15 minutes; then back again into

the formic acid mixture for 24 hours, and into pure formic acid for 24 hours more. After removal from the gold, and whilst in the acid, the tissue must be kept in the dark.

γ. Ranvier's method.—Immerse in lemon-juice for 5 to 10 minutes, then wash with water and place in 1 per cent. gold chloride solution for 20 minutes. Then treat either as in Cohnheim's or as in Löwit's method.

18. *Staining with nitrate of silver.*—Wash the fresh tissue with distilled water; immerse in $\frac{1}{2}$ to 1 per cent. nitrate of silver solution for from 1 to 5 minutes; rinse with distilled water and expose to bright sunlight either in water, alcohol, or glycerine. The tissue, which is generally a thin membrane, may either be mounted in glycerine, or it may be spread out flat in water on a slide, the water drained off, the tissue allowed to dry completely, and then xylol balsam added. This method is used to exhibit endothelium, and generally to stain intercellular substance.

19. *Golgi's chromate of silver methods.*—These are chiefly employed for investigating the relations of cells and fibres in the central nervous system. Two methods are mostly used, as follows:—

a. Very small pieces of the tissue which has been hardened for some weeks in bichromate solution or Müller's fluid are placed for half an hour in the dark in 0.75 per cent. nitrate of silver solution, and are then transferred for 24 hours or more to a fresh quantity of the same solution (to which a drop or two of formic acid may be added). They may then be hardened with 96 per cent. alcohol (half an hour), and sections, which need not be thin, are cut either from celloidin with a microtome or with the free hand. The sections are mounted in xylol balsam, which is allowed to dry on the slide: they must not be covered with a cover-glass, but the balsam must remain exposed to the air.

β. Instead of being slowly hardened in bichromate, the tissue is placed at once in very small pieces in a mixture of bichromate and osmic (3 parts of Müller's fluid to 1 of osmic acid). In this it remains from 1 to 8 days,¹ after which the pieces are treated with silver nitrate, as in the other case. This method is not only more rapid than the other, but is more sure in its results.

20. *Ehrlich's methylene-blue method.*—This method is one of great value for exhibiting nerve-terminations, and in some cases the relations of nerve-cells and fibres in the central nervous system. For its application the tissue must be living: it is therefore best applied by injecting a solution of methylene-blue (1 part to 100 of saline solution) into the blood-vascular or into the lymphatic system, but good results can also be obtained by immersing small pieces of freshly-excised living tissue in a less concentrated solution (0.2 per cent.), or, in the case of the central nervous system, by dusting the methylene-blue powder over a freshly-cut surface, allowing

¹For the central nervous system the shorter times are preferable; for peripheral nerve-endings, the longer times.

some time for it to penetrate, and then treating it with picrate of ammonia and Bethe's solution (see below). In either case the tissue should be freely exposed to air; the blue colour then appears in the nerve-cells and axis-cylinders, even to their finest ramifications. To fix the stain the tissue is treated for some hours with saturated solution of picrate of ammonia, after which the preparation can be mounted in glycerine; but to allow of sections being made from it for mounting in balsam, it must, subsequently to the action of the picrate of ammonia, be treated with Bethe's fluid, viz. :—

Molybdate of ammonia,	- - - - -	25 grains.
Chromic or osmic acid,	- - - - -	1 grain.
Distilled water,	- - - - -	1000 c.c.
Hydrochloric acid,	- - - - -	25 drops.

This renders the colour insoluble in alcohol.

21. *Sihler's method of staining nerve-endings in muscle and blood-vessels.*—Macerate the tissue for 18 hours in the following solution :

Ordinary acetic acid,	- - - - -	1 part.
Glycerine,	- - - - -	1 part.
1 per cent. chloral hydrate solution,	- - - - -	6 parts.

From this transfer to glycerine for from 1 to 2 hours; then unravel somewhat with needles and place for from 3 to 10 days in the following :

Ehrlich's hæmatoxylin,	- - - - -	1 part.
Glycerine,	- - - - -	1 part.
1 per cent. chloral hydrate solution,	- - - - -	6 parts.

It may then be kept for any desired time in glycerine, which should be changed several times.

Preparations are made by careful dissociation with needles. If overstained they may be differentiated by acetic acid until the dark blue colour is changed to violet.

22. *Nissl's method of staining the chromatic granules in nerve-cells.*—This method is given on p. 261. Nissl recommended 90 per cent. alcohol as the hardening agent, but both formol and corrosive sublimate are better. Toluidin-blue (Mann) may be used with advantage in place of methylene-blue, and the sections may first be stained with 1 per cent. aqueous solution of eosin with the aid of heat, and then, after rinsing in water, with hot toluidin-blue solution: they are differentiated in acid alcohol. The effect of heating the solutions is to accelerate and accentuate the staining. The whole process takes only a few minutes.

INDEX.

ACH

- ACHROMATIC spindle, 4, 31.
 Adenoid tissue, 50.
 Adipose tissue, 47.
 Air-bubbles, 10.
 Amœba, 2.
 Angioblasts, 140.
 Aorta, structure of, 133.
 Appendix, 344.
 Areolar tissue, 44.
 Arrector pili, 165.
 Arteries, nerves of, 135.
 — variation in structure of, 133.
 — and veins, smaller, structure of, 137.
 Artery, structure of, 130.
 Attraction particle, 4.
 Auerbach, plexus of, 209.

 BASEMENT membranes, 50.
 Bile-ducts, 222.
 Bladder, 241.
 Blastoderm, 6.
 Blood-corpuscles, action of reagents upon, 19.
 — coloured, 12.
 — colourless, 12, 15.
 — — amoeboid phenomena of, 24.
 — — granules of, 15.
 — — migration from blood-vessels, 140.
 — development of, 17.
 — enumeration of, 13, 14.
 — of amphibia, 22.
 Blood-crystals, 20.
 Blood-tablets, 16.
 Blood-vessels, development of, 140.
 — structure of, 130.
 Bone, 66.
 — development of, 74.
 — lacunæ and canaliculi of, 70.
 — lamellæ of, 67.
 — marrow of, 71.
 Bowman, glands of, 330.
 — membrane of, 311.
 Bronchi, 173.
 Bronchial tubes, 174.
 Brain. *See* Cerebrum, Cerebellum, Medulla oblongata, Mesencephalon, Pons Varolii.
 — membranes of, 304.

DEN

- CAPILLARIES, 138.
 — circulation in, 137, 140.
 Carotid gland, 231.
 Cartilage, articular, 59.
 — costal, 63.
 — embryonic, 62.
 — hyaline, 59.
 — transitional, 60.
 — varieties of, 59.
 Cartilage-cells, 61.
 — capsules of, 61.
 Celloidin for embedding, 346.
 Cells, division of, 6, 29.
 — embryonic, 6.
 — structure of, 1.
 Central tendon of diaphragm, 142.
 Centrosome, 4.
 Cerebellum, 289.
 Cerebrum, 292.
 — basal ganglia of, 302.
 Choroid coat of eye, 313.
 Chromic acid, 344.
 Chromoplasm, 5.
 Chromosomes, 30.
 Ciliary movement, 40.
 — muscle, 315.
 Clarke, column of, 268.
 Coccygeal gland, 231.
 Cochlea, 336.
 Cohnheim, areas of, 83.
 Collaterals, 106.
 Colostrum-corpuscles, 260.
 Conjunctiva, 307.
 Connective-tissue, cells of, 46.
 — — development of, 56.
 — — jelly-like, 51.
 — tissues, 43.
 Cornea, 345.
 Corpora quadrigemina, 285.
 Corpus luteum, 256.
 — striatum, 292.
 Corti, organ of, 340.
 Cotton fibres, 11.
 Crusta petrosa, 182.
 Cutis vera, 157.

 DEITERS, cells of, 341.
 — process of, 105.
 Dendrons, 106, 112.
 Dentine, 181.

DEN

- Dentine, formation of, 184.
 Descemet, membrane of, 312.
 Dobie, line of, 84.
 Doyère, eminence of, 129.
 Dust, 11.
- EAR, 330.
- Ebner, glands of, 187.
 Ehrlich's methylene-blue method, 354.
 Elastic tissue, 53.
 Eleidin, 156.
 Embedding, methods of, 345.
 Enamel, 179.
 — formation of, 183.
 End-bulbs, 119.
 Endocardium, 170.
 Endomysium, 85.
 Endoneurium, 101.
 Endoplasm, 3.
 Endothelium, 33.
 End-plates, 127.
 Epicardium, 170.
 Epidermis, 154.
 Epididymis, 245.
 Epineurium, 101.
 Epithelium, 28.
 — ciliated, 38.
 — classification of, 32.
 — columnar, 35.
 — pavement, 33.
 — stratified, 32.
 — structure and division of cells, 28, 29.
 — transitional, 39.
 Erectile tissue, 241.
 Eustachian tube, 332.
 Exoplasm, 3.
 Eye, 306.
 Eyelids, 307.
 Eye-piece, 8.
- FALLOPIAN tubes, 257.
 Fat, absorption of, 214.
 Fat-cells, 47.
 Fenestrated membrane, 131.
 Fibres, elastic, 45.
 — white, of connective-tissue, 44.
 Fibrin, 12, 16.
 Fibro-cartilage, elastic, 63.
 — white, 64.
 Fibrous tissue, 53.
 Fillet, 276, 281, 284, 286.
 Flemming's solution, 344.
 Formol, 344.
 Freezing method for preparation of sections, 346.
- GALL-BLADDER, 222.
 Ganglia, 103, 108.
 — development of, 118.
 Ganglion-cells, 108.

HYA

- Gas-chamber, 40.
 Gland, thymus, 152.
 — pineal, 304.
 Glands, agminated, 211.
 — anal, 217.
 — carotid, 231.
 — ceruminous, 167, 278.
 — coccygeal, 231.
 — gastric, 203.
 — lachrymal, 309.
 — lymphatic, 148.
 — mammary, 259.
 — Meibomian, 308.
 — of Bowman, 330.
 — of Brunner, 205, 211.
 — of Cowper, 242.
 — of Ebner, 187.
 — of Lieberkühn, 210.
 — of Littre, 242.
 — salivary, 192.
 — sebaceous, 166.
 — solitary, 211, 217.
 — sudoriparous, 166.
 — thymus, 152.
 Glomeruli of kidney, 233.
 Glycogen in colourless blood-corpuscles, 23.
 — in liver cells, 218, 222.
 Goblet-cells, 37.
 Gold-methods, 353.
 Golgi, organ of, 126.
 — method of preparing the nervous system, 354.
 — types of nerve-cells, 110.
 Graafian follicles, 253.
 Grandry, corpuscles of, 122.
 Granuloplasm, 3.
 Ground-substance of connective tissue, 44.
 Gullet. *See* Oesophagus.
- HÆMAL glands, 150.
 Hæmatoidin, 21.
 Hæmin, 21.
 Hæmoglobin, 19.
 Hair-cells of auditory organ, 334, 341.
 Hair-follicle, structure of, 159.
 Hairs, 11, 159.
 — development of, 164.
 — muscles of, 165.
 Haversian canals, 68.
 — systems, 68.
 Heart, 168.
 Henle, fenestrated membrane of, 131.
 — looped tubules of, 233.
 — sheath of, 101.
 Hensen, line of, 84.
 Hepatic lobules, 219.
 Hippocampus, 299.
 Histology, meaning of term, 1.
 Hyaloplasm, 2.

INT

- INTESTINE, large, 216.
 — small, 208.
 Iris, 316.
 Iron in liver cells, 218, 222.
 JELLY of Wharton, 57.
 KARYOKINESIS, 6, 30.
 Kidney, 232.
 — blood-vessels of, 237.
 Krause, membrane of, 84, 87.
 LABYRINTH of ear, 333.
 Lacteals, 213.
 Lanugo, 164.
 Larynx, 173.
 Lens, 327.
 Lieberkühn, crypts of, 210.
 Linen fibres, 11.
 Liver, 219.
 Lung, 174.
 — alveoli of, 176.
 — blood-vessels of, 176.
 Lymphatic glands, 148.
 Lymphatics, 142.
 — connection with cells of connective tissue, 47, 144.
 — development of, 145.
 — nerves of, 143.
 Lymph-corpuses, 14.
 Lymphoid tissue, 50, 149.
 MACULA lutea of retina, 325.
 Malpighian corpuscles of kidney, 233.
 — — of spleen, 225.
 Mammary glands, 259.
 Marchi's fluid, 352.
 Marrow, 71.
 Measuring objects, 9.
 Medulla oblongata, 272.
 Meissner, plexus of, 209.
 Mesencephalon, 282.
 Methods of embedding, 345.
 — of mounting sections, 348.
 — of preparing sections, 345.
 — of preserving and hardening, 344.
 — of staining, 348.
 Micrometer, 9.
 Microscope, choice of, 8.
 — structure of, 8.
 Microscopic work, requisites for, 8.
 Microtomes, 346.
 Migration of colourless blood-corpuses, 26, 140, 215.
 Mitosis, 6.
 Moist chamber, 46.
 Mould, 11.
 Mounting solutions, 344.
 Müller, fibres of, 325.
 Müller's fluid, 344.
 Muscle, blood-vessels of, 91.

PAR

- Muscle, development of, 92.
 — ending of, in tendon, 90.
 — involuntary or plain, 95.
 — nerves of, 126, 127.
 — of heart, 92.
 — of insects, 86, 87.
 — spindles, 126.
 — structure of, compared with protoplasm, 89.
 — voluntary, 82.
 Muscle-corpuses, 85.
 Myeloplaxes, 62.
 Myocardium, 168.
 NAILS, 158.
 Nerve-cells, 103, 104.
 — — development of, 116.
 Nerve-fibres, axis-cylinder of, 96, 99.
 — — degeneration of, 113.
 — — demyelinated, 96.
 — — medullary segments of, 99.
 — — motor, terminations of, 127.
 — — non-medullated, 100.
 — — sensory, modes of termination of, 119, 124.
 — — sheaths of, 96, 97.
 — — trunk, structure of, 100.
 Nervi nervorum, 101.
 Neuroblasts, 117.
 Neuroglia, 115.
 Neurokeratin, 100.
 Neurolemma, 97.
 Neuron, 106, 112.
 Nissl, granules of, in nerve-cells, 104, 261, 355.
 Nucleolus, 6.
 Nucleus, 5.
 OBJECTIVE, 8.
 Ocular, 8.
 Œsophagus, 197.
 Olfactory bulb, 300.
 — cells, 329.
 — mucous membrane, 328.
 — tract, 299.
 Omentum, 137.
 Optic thalamus, 303.
 Ossification in cartilage, 74.
 — in membrane, 80.
 Osteoblasts, 71, 75, 80.
 Osteoclasts, 78.
 Osteogenic fibres, 80.
 Ovary, 251.
 Ovum, 6, 255.
 PACINIAN corpuscles, 122, 224.
 Pancreas, 222.
 Papillæ of tongue, 187.
 — of skin, 157.
 Paraplast, 3.
 Parathyroids, 231.

PEN

- Penis, 241.
 Pericardium, 170.
 Perineurium, 101.
 Periosteum, 71.
 Peyer, patches of, 211.
 Pharynx, 197.
 Pituitary body, 304.
 Pleura, 178.
 Pons Varolii, 279.
 Portal canal, 220.
 Posterior longitudinal bundle, 281.
 Prickle-cells, 33.
 Prostate, 242.
 Protoplasm, 2.
 Purkinje, cells of, 291.
 — fibres of, 171.
- RANVIER, nodes of, 99.
 Remak, fibres of, 100.
 Retiform tissue, 49.
 Retina, 317.
 — macula lutea of, 325.
 — pars ciliaris of, 325.
- SACCULE, 334.
 Saline solution, 344.
 Salivary glands, 192.
 — corpuscles, 28, 152.
 Sarcolemma, 82.
 Sarcomeres, 87.
 Sarcoplasm, 83.
 Sarcostyles, 83.
 Sarcous elements, 87.
 Schwann, sheath of, 96.
 Sclerotic coat of eye, 309.
 Sebaceous glands, 166.
 Sections, preparation of, 345.
 Semicircular canals, 334.
 Seminiferous tubules, 243.
 Serous membranes, 145.
 Sharpey, fibres of, 70.
 Sihler's method of staining nerve-endings, 355.
 Silver-methods, 353.
 Skin, 154.
 Spermatogenesis, 248.
 Spermatozoa, 247.
 Spinal bulb. *See* Medulla oblongata.
 Spinal cord, 261.
 — — blood-vessels of, 271.
 — — central canal of, 262, 270.
 — — characters in different parts, 270.
 — — membranes of, 261.
 — — nerve-cells of, 267.
 — — tracts in, 265.

YEA

- Spleen, 225.
 Spongioplasm, 2.
 Staining of sections, 348.
 Starch granules, 9.
 Stomach, 199.
 — glands of, 203.
 — blood-vessels of, 205.
 — lymphatics of, 206.
 Stomata, 145.
 Suprarenal capsule, 228.
 Sweat-glands, 166.
 Synapse, 112.
 Synovial membrane, 62.
- TACTILE corpuscles, 119.
 Taste-buds, 189.
 Tendon, 55.
 — nerve-endings in, 126.
 Tendon-cells, 54.
 Testicle, 242.
 Thymus gland, 152.
 Thyroid body, 230.
 Tissues, enumeration of, 1.
 — formation from blastodermic layers, 6.
 Tongue, 187.
 Tonsils, 151.
 Tooth, 179.
 — formation of, 182.
 — pulp of, 182.
 Trachea, 172.
 Tympanum, 331.
- URETER, 240.
 Urethra, 242.
 Urinary bladder, 241.
 Uriniferous tubules, course of, 232.
 Uterus, 257.
 Utricle, 334.
- VAS deferens, 246.
 Vasa vasorum, 135.
 Vaso-formative cells, 140.
 Veins, structure of, 135.
 — variations in, 135.
 Vesiculæ seminales, 246.
 Villi, 211.
 Vitreous humour, 327.
- WALLERIAN degeneration, 113.
 Warming apparatus, 24.
 Weigert-Pal method for staining sections of the nervous system, 352.
 Woollen fibres, 11.
- YEAST, 10.

NATIONAL LIBRARY OF MEDICINE



NLM 04580473 2