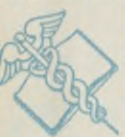

NATIONAL LIBRARY OF MEDICINE



NLM 00104884 1

NATIONAL LIBRARY OF MEDICINE



and Welfare, Public



Health, Education,

NATIONAL LIBRARY OF MEDICINE



Health, Education,

NATIONAL LIBRARY OF MEDICINE



Health, Education,

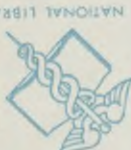NATIONAL LIBRARY OF MEDICINE



Health, Education,



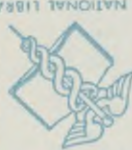Health Service



Health, Education,



Health Service



Health, Education,



Health Service



Bethesda, Md.



U.S. Department of



Bethesda, Md.



U.S. Department of



Bethesda, Md.



U.S. Department of



Bethesda, Md.



U.S. Department of



Bethesda, Md.



U.S. Department of



Health, Education,



Health Service



Health, Education,



Health Service



Health, Education,



and Welfare, Public



and Welfare, Public



and Welfare, Public



and Welfare, Public



and Welfare, Public



Health Service



Health, Education,



Health Service



Health, Education,



Health Service



Bethesda, Md.



U.S. Department of



Bethesda, Md.




U.S. Department of



Bethesda, Md.





SAUNDERS' SERIES OF MANUALS
FOR
STUDENTS & PRACTITIONERS.
WITH COLORED PLATES.

The great popularity shown by the large and increasing sale of the Question-Compendes, together with a demand from Students and others for somewhat larger reference works, has induced the publisher to issue the present series of manuals.

Anatomy and Practical Dissector.

BY

CHAS. B. NANCREDE, A. M., M. D.

Professor of Surgery and Clinical Surgery in the University of Michigan, Ann Arbor; Corresponding Member of the Royal Academy of Medicine, Rome, Italy; Late Surgeon Jefferson Medical College, etc.

Thirty fine Lithographic plates in colors and 175 Wood cuts in the text. Post 8vo, over four hundred pages, cloth or oilcloth for the dissecting-room, \$2.00. Medical sheep, \$2.50.

IN PREPARATION.

DISEASES OF WOMEN,

BY

HENRY J. GARRIGUES., A.M., M.D.

Professor of Obstetrics in the New York Post-Graduate Medical School and Hospital; Gynæcologist to St. Mark's Hospital in New York City; Gynæcologist to the German Dispensary in the City of New York; Consulting Obstetrician to the New York Infant Asylum; Obstetric Surgeon to the New York Maternity Hospital; Fellow of the American Gynæcological Society; Fellow of the New York Academy of Medicine; President of the German Medical Society of the City of New York, etc., etc.

READY SHORTLY.

DISEASES OF THE EYE.

BY

GEO. E. De SCHWEINITZ, M. D.

Ophthalmic Surgeon to Children's Hospital and to the Philadelphia Hospital; Ophthalmologist to the Orthopædic Hospital and Infirmary for Nervous Diseases, etc.

OTHERS PREPARING.

IN PREPARATION.

A NEW
UNABRIDGED DICTIONARY OF
MEDICINE
AND ACCESSORY SCIENCE,

—BY—

JOHN M. KEATING, M. D., (Univ. of Pa.),

FELLOW COLLEGE OF PHYSICIANS OF PHILADELPHIA; VISITING OBSTETRICIAN TO THE PHILADELPHIA HOSPITAL, AND LECTURER ON DISEASES OF WOMEN AND CHILDREN; GYNÆCOLOGIST TO ST. JOSEPH'S HOSPITAL; SURGEON TO THE MATERNITY HOSPITAL, ETC.; EDITOR "CYCLOPÆDIA OF DISEASES OF CHILDREN"; AUTHOR OF "MATERNITY—INFANCY — CHILDHOOD," ETC.

AND

HENRY HAMILTON,

AUTHOR OF "A NEW TRANSLATION OF VIRGIL'S ÆNEID INTO ENGLISH RHYME"; CO-AUTHOR OF "SAUNDERS' MEDICAL LEXICON," ETC.

A voluminous and exhaustive hand-book of Medical, Surgical and Scientific Terminology, containing concise explanations of the various terms used in medicine and the allied sciences, with Accentuation, Etymology, etc. The work, when completed, will form a handsome Royal 8vo. volume of some 1000 pages, beautifully printed from new type on paper especially manufactured for this purpose; it will contain the most recent additions to scientific nomenclature, important tables, etc., under the most convenient system of arrangement—the whole forming the most complete, reliable and valuable dictionary in the market. Indispensable alike to the Student and Practitioner, not only for occasional reference, but for daily use.


EIGHTH THOUSAND.

ESSENTIALS OF ANATOMY
AND
MANUAL OF PRACTICAL DISSECTION,
TOGETHER WITH THE
ANATOMY OF THE VISCERA.
PREPARED ESPECIALLY FOR
STUDENTS OF MEDICINE.

BY

CHARLES B. NANCREDE, M.D.,

PROFESSOR OF SURGERY AND OF CLINICAL SURGERY IN THE UNIVERSITY OF MICHIGAN, ANN ARBOR; CORRESPONDING MEMBER OF THE ROYAL ACADEMY OF MEDICINE, ROME, ITALY; LATE SENIOR SURGEON TO EPISCOPAL HOSPITAL; LATE SURGEON TO JEFFERSON MEDICAL COLLEGE HOSPITAL; FORMERLY LECTURER ON OSTEOLOGY, ETC., IN MEDICAL DEPARTMENT, UNIVERSITY OF PENNSYLVANIA; LATE PROFESSOR OF GENERAL AND ORTHOPÆDIC SURGERY IN PHILADELPHIA POLYCLINIC, ETC.



*THIRD EDITION, REVISED AND ENLARGED.
BASED UPON THE LAST EDITION OF GRAY'S ANATOMY.*

30 HANDSOME FULL-PAGE LITHOGRAPHIC PLATES, IN COLORS,
AND **180** FINE WOODCUTS.

PHILADELPHIA:
W. B. SAUNDERS,
913 WALNUT STREET.

LONDON: HENRY RENSHAW. MELBOURNE: GEORGE ROBERTSON & Co.
1890.

Annet
QS
N176
1890
film no. 10994
item 3

Entered according to Act of Congress in the year 1888, by
W. B. SAUNDERS,
In the Office of the Librarian of Congress, at Washington.

COPYRIGHTED, 1889, 1890.

PREFACE.

THE author has endeavored in this little book to embody only those facts which have appeared to him to be really the "essentials of anatomy;" not that he considers it likely that the student will master every minute detail therein contained, but he believes that the knowledge gained by a study of this work will enable the future practitioner, during the remainder of his professional life, to recall such general impressions as will render intelligible current medical literature, or even the more elaborate monographs, and will at once suggest *where* to consult his anatomical text-books for such terms or facts as may have become indistinct through lapse of time.

While this book cannot replace the larger anatomical works, sufficient descriptive matter has been introduced to enable the student to refresh his memory of the more numerous facts learnt in the lecture and dissecting room, or from his "Gray" or other text-book, differing in this respect from most of the works of its class, which are little more than a list of names, without any distinctive facts connected with them to aid the student in the difficult task of acquiring a knowledge of a branch of medical study almost solely dependent upon the unassisted powers of the memory.

Conciseness, rather than elegance of diction, has been the aim, so that all words such as the articles "a," "an," "the," have been omitted, except where absolutely necessary.

Recognizing that a work of this kind should, as far as possible, conform to that text-book most commonly used, the last

edition of Gray's *Anatomy* has been chosen as the chief authority, although free use has been made of the works of Quain, Leidy, Bock, Allen, Morris *On the Joints*, Starr *On Diseases of Children* (dentition), Tomes *Dental Anatomy*, Potter, Frey, Holden, Politzer, H. Thompson, Astley Cooper *On the Breast*, and original work of one of the author's former students.

The author would here acknowledge his obligations and return his thanks to Prof. Joseph Leidy, of the University of Pennsylvania, for the kind permission to reproduce numerous cuts from the first edition of his *Anatomy*, and to Dr. F. M. Varrell for much valuable assistance in the correction of proof.

CHARLES B. NANCREDE.

PHILADELPHIA, September, 1888.

CONTENTS.

	PAGE
Introduction	17
Bones of the head	23
The frontal bone	23
Parietal bones	25
Occipital bone	27
The sphenoid	30
The temporal bones	34
Ethmoid bone	38
Nasal bones	40
The superior maxillary bones	40
Lachrymal bones	44
Malar bones	44
The palate bones	45
The inferior turbinated bones	47
Vomer	48
The inferior maxillary bone	49
The sutures and fontanelles	51
The cerebral fossæ	53
The orbital cavities	55
The nasal fossæ	58
Bones of the trunk	61
The vertebral column	61
The thorax	64
Hyoid bone	65
The sternum	65
Ribs	66
The pelvic bones	68
The pelvis	73
Bones of the upper extremity	74

	PAGE
The arm	78
The forearm	80
The hand	82
Lower extremity	85
The thigh	85
The patella	87
The leg	88
The foot	90
The articulations	92
Muscles and fasciæ	114
Muscles of the head	116
Muscles of the neck	120
Palatal region	122
Vertebral region	122
Muscles of the back	123
Muscles of the abdomen	129
Muscles of thorax	132
Muscles of the forearm	136
Fasciæ of the hand	139
Muscles of the hand	140
Muscles of lower extremity	141
Muscles of the leg	147
Fasciæ of foot	149
Muscles of the foot	150
Vascular system	152
The arteries	157
The veins	177
The lymphatics	184
Nervous system	185
The spinal cord	198
The cranial nerves	200
The spinal nerves	205
Dorsal nerves	208
The sympathetic nerve	211
Visceral anatomy	216
The digestive organs	216
The teeth	217

CONTENTS.

ix

	PAGE
The mouth	220
The pharynx	224
The œsophagus	226
The stomach	227
The small intestine	229
The large intestine	231
The liver	233
The pancreas	238
The ductless glands	239
The spleen	239
The thyroid gland	241
The thymus gland	242
The suprarenal capsules	242
The abdominal cavity	243
The peritoneum	246
Organs of voice and respiration	249
The larynx	249
The trachea and bronchi	254
The lungs	256
The pleuræ	259
The urinary organs	260
The ureters	265
The bladder	266
The male urethra	269
Female urethra	271
The male generative organs	271
The penis	272
The testes and their coverings	274
Female organs of generation	279
The vagina	281
The uterus and its appendages	281
The mammary glands	286
The organs of sense	287
The skin and its appendages	287
Organs of taste	289
Organs of smell	290
The eye	292

	PAGE
Sclerotic and cornea	293
The humors	300
Appendages of eye	306
Tutamina oculi	306
The ear	309
The external ear	310
The middle ear or tympanum	311
The tympanum	313
The internal ear or labyrinth	318
Anatomy of inguinal hernia	325
Femoral hernia	328
Perineum and ischio-rectal regions	330
Introduction to osteological plates	336
Series of osteological plates from Gray's Anatomy	337

INTRODUCTION

TO

PLATES OF THE VASCULAR SYSTEM.

The great popularity of Dr. Nancrede's "Essentials of Anatomy," suggested to the publisher the desirability of still further extending its usefulness by the addition of a series of plates which might make it of as material service in the dissecting room as are larger and much more elaborate works. With this end in view, much care was bestowed upon the selection of illustrations, and we believe that those presented in the following pages are unrivalled in excellence, except in the large, cumbersome and expensive charts, which are not adapted to the student's purposes.

The study of anatomy must be grounded upon dissection. What the eye sees in a moment, is more indelibly impressed upon the brain, than the most minute and accurate description. Hence, after dissection or the examination of preparations would come trustworthy illustrations. By a study of these the student remembers not words but facts. When it becomes necessary for him to recall the relations of important blood-vessels or nerves, he should not stumble over what Gray says or Leidy taught, but there should flash into his memory, without effort, what he has seen and what he knows. This is said with no thought of deying the value of text. Careful description should go hand-in-hand with illustrations, but should distinctly supplement the latter, since words in themselves, or even the ideas they convey, are far more difficult to remember than ocular impressions.

In the following plates* the topographical features of each region are so beautifully illustrated, that the student can confirm his dissection at a glance, and can as quickly review his knowledge in preparing for examination. Dr. Nancrede being out of the city, with his consent, and at the request of the publisher, the selection and editing of the plates was supervised by

EDWARD MARTIN.

415 S. Fifteenth St., Philadelphia.

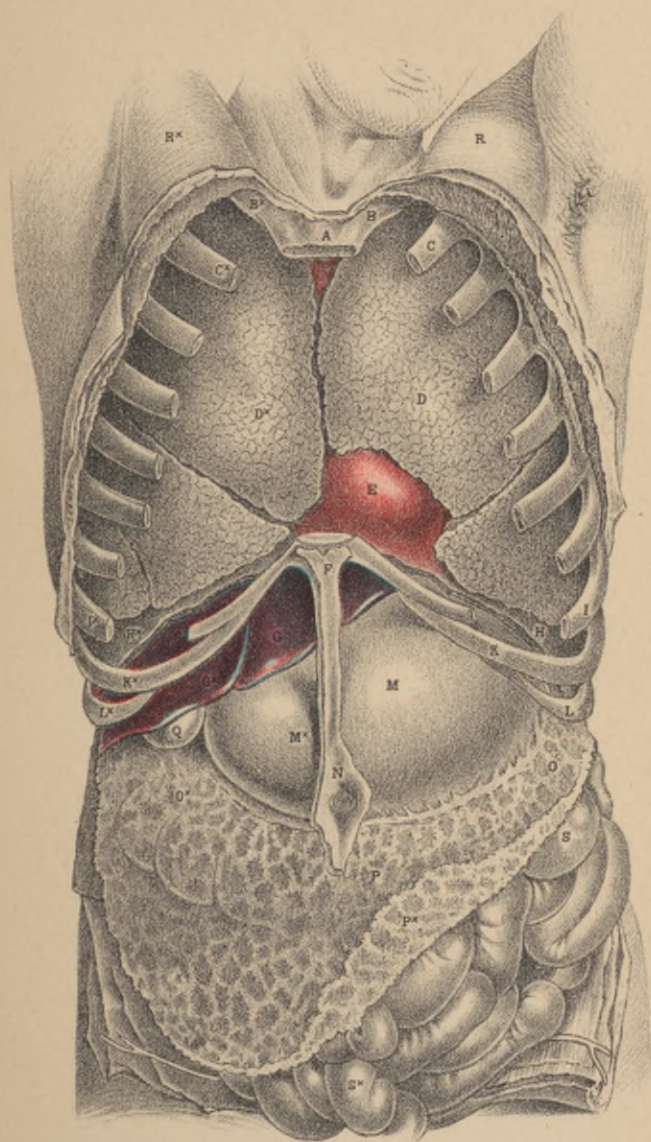
June, 1890.

*Taken from the works of MacLise, Savage, Nuhn and Hirschfeld.

PLATE 1.

SUPERFICIAL DISSECTION OF THE THORAX AND ABDOMEN.

- A.**—Upper bone of the sternum.
- B.B.***—Two first ribs.
- C.C.***—Second pair of ribs.
- D.D.***—Right and left lungs.
- E.**—Pericardium, enveloping the heart—the right ventricle.
- F.**—Lower end of sternum.
- G.G.***—Lobes of the liver.
- H.H.***—Right and left halves of the diaphragm, in section; the right half separating the right lung from the liver, the left half separating the left lung from the broad cardiac end of the stomach.
- I.I.***—Eighth pair of ribs.
- K.K.***—Ninth pair of ribs.
- L.L.***—Tenth pair of ribs.
- M.M.***—The stomach; *m*, its cardiac bulge; *m*,* its pyloric extremity.
- N.**—The umbilicus.
- O.O.***—The transverse colon.
- P.P.***—The omentum, covering the transverse colon and small intestines.
- Q.**—The gall bladder.
- R.R.***—The right and left pectoral prominences.
- S.S.***—The small intestines.



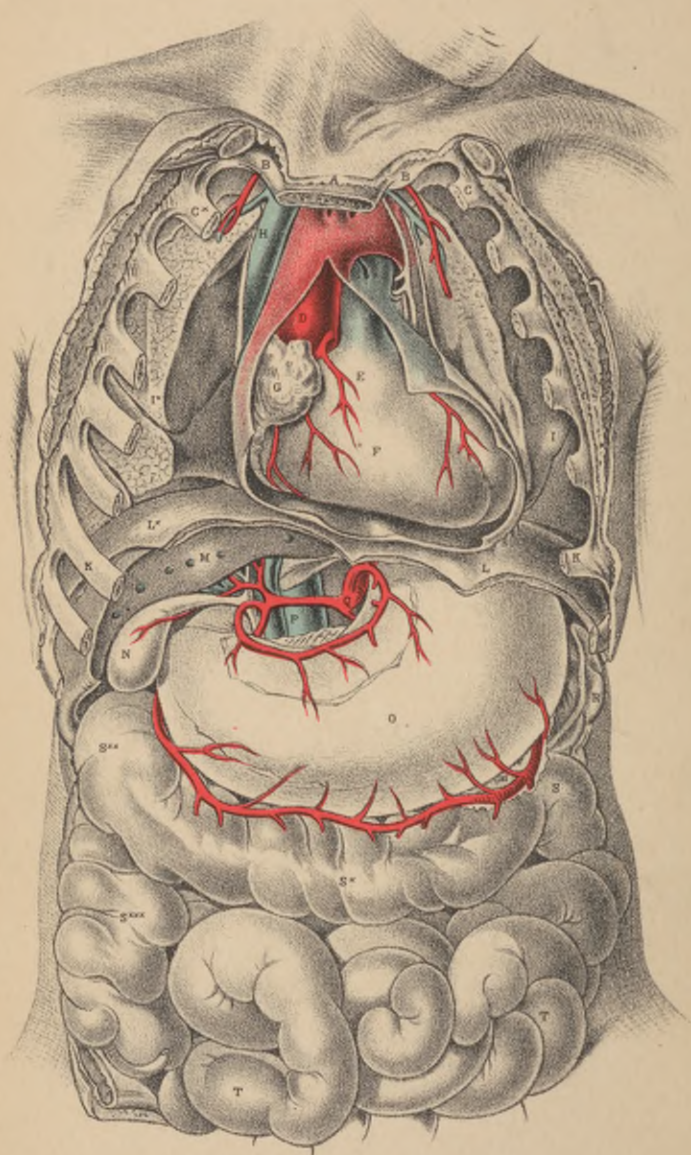


PLATE 2.

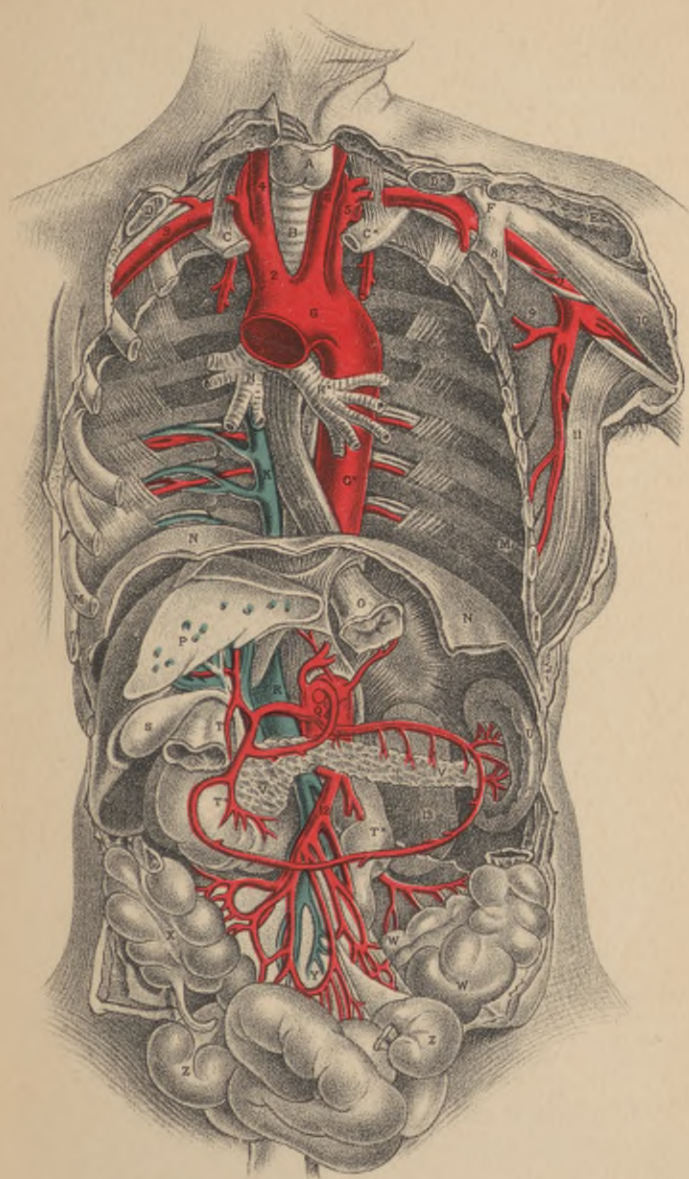
RELATIVE POSITION OF THE DEEPER ORGANS OF THORAX AND THOSE OF THE ABDOMEN.

- A.**—Upper end of the sternum.
- B.B.***—First pair of ribs.
- C.C.***—Second pair of ribs.
- D.**—Aorta, with left vagus and phrenic nerves crossing its transverse arch.
- E.**—Root of pulmonary artery.
- F.**—Right ventricle.
- G.**—Right auricle.
- H.**—Vena cava superior, with right phrenic nerve on its outer border.
- I.I.***—Right and left lungs collapsed, and turned outward to show the heart's outline.
- K.K.***—Seventh pair of ribs.
- L.L.***—The diaphragm, in section.
- N.**—The gall bladder, with its duct to form the common bile duct. The hepatic artery is seen superficial to the common duct; the vena portæ is seen beneath it. The patent orifices of the hepatic veins are seen on the cut surface of the liver.
- O.**—The stomach.
- P.**—Inferior vena cava.
- Q.**—The cœliac axis, dividing into the gastric, splenic and hepatic arteries.
- R.**—The spleen.
- S.S.*S.****—The transverse colon, between which and the lower border of the stomach is seen the gastro-epiploic artery, formed by the splenic and hepatic arteries.
- S.*****—Ascending colon, in the right iliac region.
- T.**—Convulsions of the small intestines, distended with air.

PLATE 3.

DEEP DISSECTION OF THROAT AND ABDOMEN.

- A.**—The thyroid body.
B.—The trachea.
C.C.*—The first ribs.
D.D.*—The clavicles, cut at middle.
E.—Humeral part of great pectoral muscle, cut.
F.—Coracoid process of the scapula.
G.—Arch of the aorta; **G,*** descending aorta in throat.
H.—Right bronchus; **H,*** left bronchus.
I.—Esophagus.
K.—Vena azygos, receiving the intercostal veins.
L.—Thoracic duct.
M.M.*—Seventh ribs.
N.N.—Diaphragm in section.
O.—Cardiac orifice of stomach.
P.—Liver in section, showing patent orifices of hepatic veins.
Q.—Cœliac axis, sending off branches to liver, stomach and spleen. The stomach has been removed to show the looping anastomosis of these vessels around the superior and inferior borders of the stomach.
R.—Inferior vena cava, about to enter its notch in the posterior thick part of the liver, to receive the hepatic veins.
S.—Gall-bladder, communicating by its duct with the hepatic duct, which is lying upon the vena portæ, and by the side of the hepatic artery.
T.—The pyloric end of stomach, joining **T,*** duodenum.
U.—The spleen.
V.V.—The pancreas.
W.—The sigmoid flexure of colon.
X.—The caput coli.
Y.—The mesentery, supporting the numerous looping branches of the superior mesenteric artery.
Z.—Some coils of the small intestine.
2.—Innominate artery.
3.—Right subclavian artery.
4.—Right common carotid artery.
5.—Left subclavian artery.
6.—Left common carotid artery.
7.—Left axillary artery.
8.—Coracoid attachment of the smaller pectoral muscle.
9.—Subscapular muscle.
10.—Coracoid head of the biceps muscle.
11.—Tendon of the latissimus dorsi muscle.
12.—Superior mesenteric artery, with its accompanying vein.
13.—Left kidney.



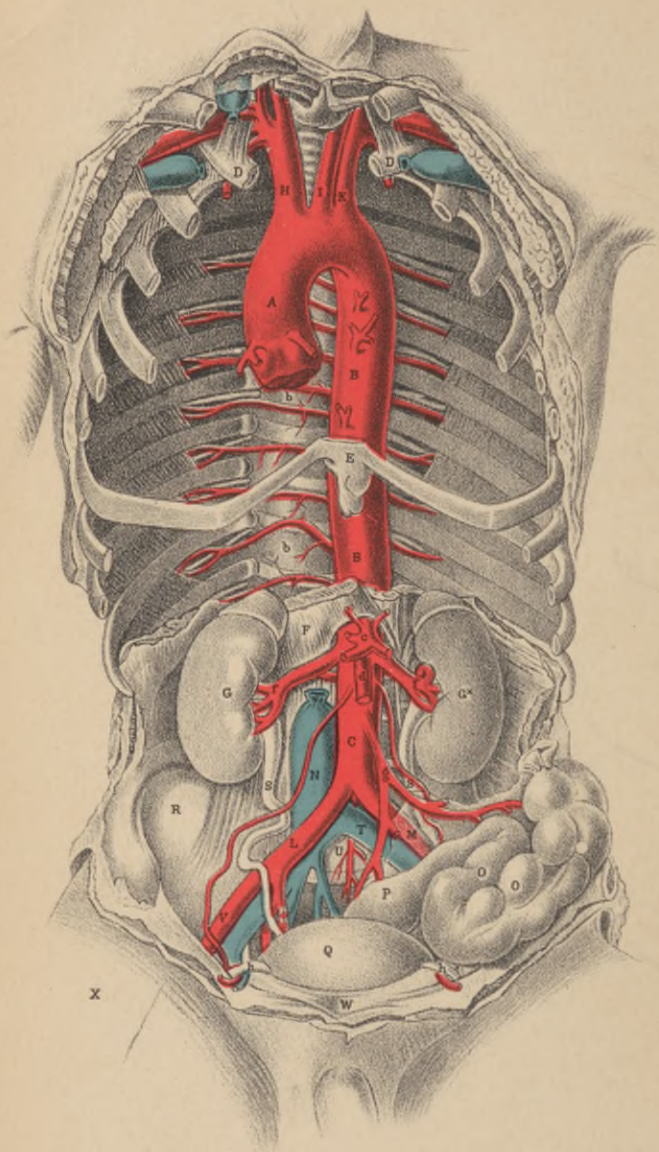


PLATE 4.

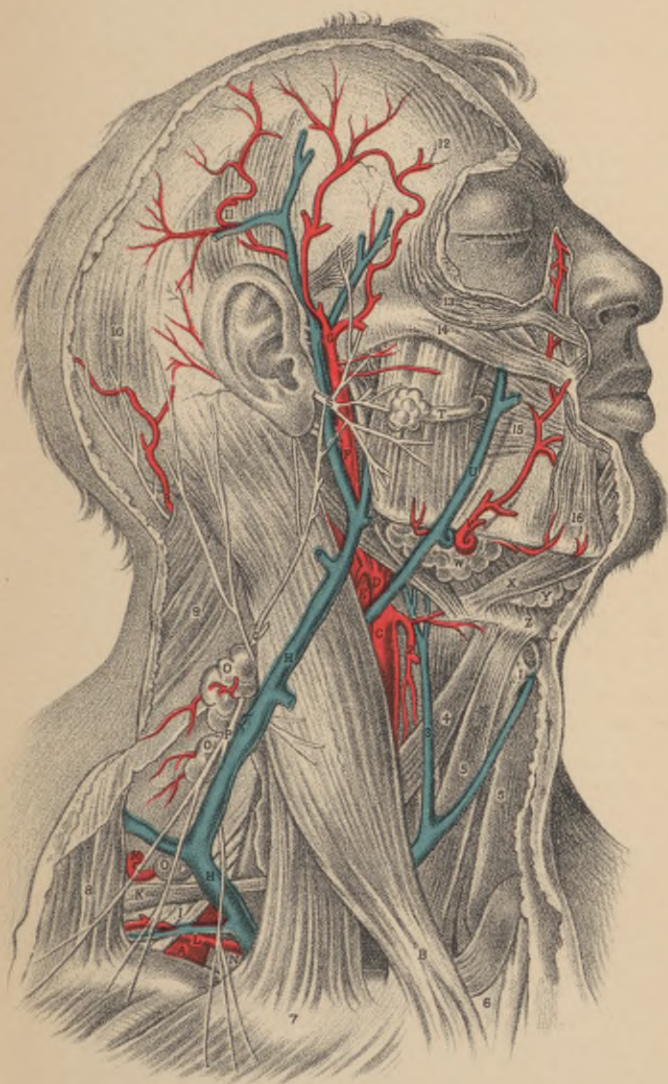
RELATION OF THE PRINCIPAL BLOOD-VESSELS OF THE THORAX AND ABDOMEN TO THE OSSEOUS SKELETON, ETC.

- A.**—Arch of the aorta.
- B.B.**—Descending thoracic, part of the aorta giving off *b, b*, the intercostal arteries.
- C.**—Abdominal part of aorta.
- D.D.**—First pair of ribs.
- E.**—The xyphoid cartilage.
- F.**—Right crus of diaphragm.
- G.G.***—Right and left kidneys.
- H.**—Brachio-cephalic artery.
- I.**—Left common carotid artery.
- K.**—Left subclavian artery.
- L.**—Right common iliac artery at its place of division.
- M.**—Left common iliac artery, seen through the meso-rectum.
- N.**—Inferior vena cava.
- O.O.**—Sigmoid flexure of the colon.
- P.**—The rectum.
- Q.**—Urinary bladder.
- R.**—Right iliac fossa.
- S.S.**—Right and left ureters.
- T.**—Left common iliac vein, joining the right under the right common iliac artery to form the inferior vena cava.
- U.**—Fifth lumbar vertebra.
- V.**—External iliac artery of right side.
- W.**—The symphysis pubis.
- X.**—An incision made over the locality of the femoral artery.
- b.b.**—The dorsal intercostal arteries.
- c.**—The cœliac axis.
- d.**—Superior mesenteric artery.
- f.f.**—Renal arteries.
- g.**—Inferior mesenteric artery.
- h.**—The vas deferens, bending over the epigastric artery and the os pubis, after having passed through the internal abdominal ring.

PLATE 5.

SUPERFICIAL DISSECTION OF THE HEAD AND NECK.

- A.**—Third portion of the subclavian artery.
 - B.**—Sterno-mastoid muscle.
 - C.**—Common carotid artery.
 - D.**—External “ “
 - E.**—Internal “ “
 - F.**—Continuation of the external carotid, through the parotid gland.
 - G.**—Temporal artery.
 - H.**—External jugular vein.
 - I.**—Brachial plexus.
 - K.**—Posterior belly of omo-hyoid.
 - L.**—Suprascapular artery.
 - M.**—Transverse cervical artery.
 - N.**—Scaenus anticus.
 - O.**—Glandulæ concatenatæ.
 - P.**—Superficial descending cervical nerves
 - Q.**—Great auricular nerve.
 - R.**—Occipital artery and nerve.
 - S.**—Facial nerve.
 - T.**—Duct of Stenson.
 - U.**—Facial vein.
 - V.**—Facial artery.
 - W.**—Submaxillary gland.
 - X.**—Digastric muscle.
 - Y.**—Lymphatic gland.
 - Z.**—Hyoid bone.
- 1.—Thyroid cartilage.
 - 2.—Superior thyroid artery.
 - 3.—Anterior jugular vein.
 - 4.—Anterior belly of omo-hyoid.
 - 5.—Sterno-hyoid (right).
 - 6.—Inter-clavicular notch.
 - 7.—Clavicle.
 - 8.—Trapezius muscle.
 - 9.—Splenius capitis.
 - 10.—Posterior belly of occipito-frontalis.
 - 11.—Attollens aurem.
 - 12.—Anterior belly of occipito-frontalis.
 - 13.—Orbicularis palpebrarum.
 - 14.—Zygomaticus major.
 - 15.—Buccinator.
 - 16.—Depressor anguli oris.



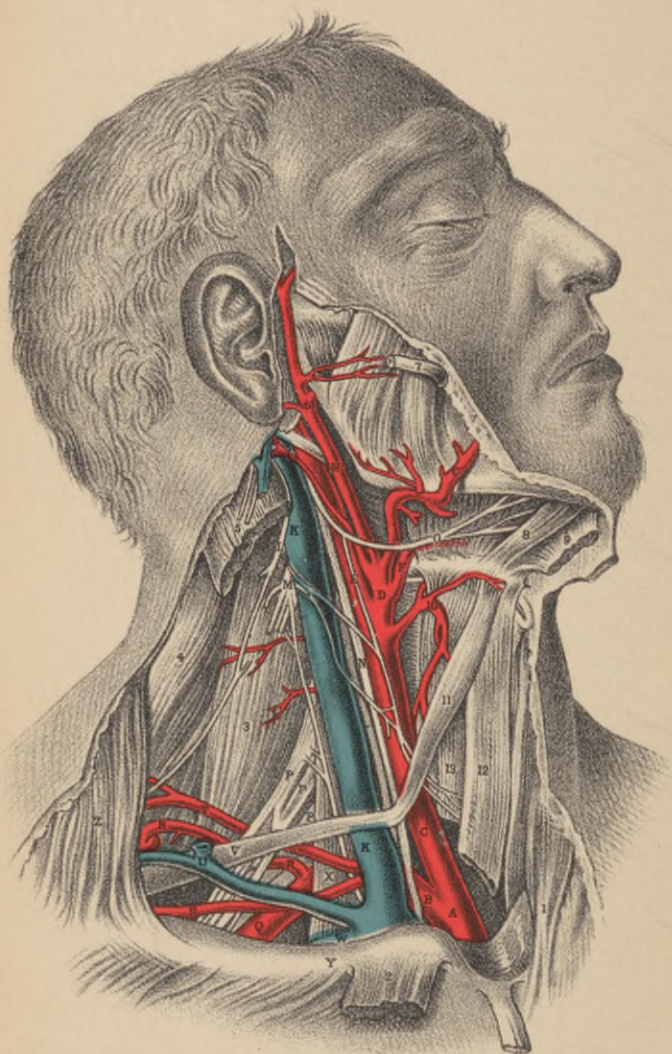


PLATE 6.

DISSECTION OF THE DEEP CERVICAL AND FACIAL REGIONS.

- A.**—Innominate artery, at its point of bifurcation.
 - B.**—Subclavian artery, crossed by the vagus nerve.
 - C.**—Common carotid artery, with the vagus nerve at its outer side, and the descendens noni nerve lying on it.
 - D.**—External carotid artery.
 - E.**—Internal carotid artery, with the descendens noni nerve lying on it.
 - F.**—Lingual artery passing under the fibres of the hyoglossus muscle.
 - G.**—Tortuous facial artery.
 - H.**—Temporo-maxillary artery.
 - I.**—Occipital artery, crossing the internal carotid artery and jugular vein.
 - K.**—Internal jugular vein, crossed by some branches of the cervical plexus, which join the descendens noni nerve.
 - L.**—Spinal accessory nerve, which pierces the sterno-mastoid muscle, to be distributed to it and the trapezius.
 - M.**—Cervical plexus of nerves giving off the phrenic nerve to descend the neck on the outer side of the internal jugular vein, and over the scalenus muscle.
 - N.**—Vagus nerve, between the carotid artery and internal jugular vein.
 - O.**—Ninth, or hypoglossal nerve, distributed to the muscles of the tongue.
 - P. P.**—Branches of the brachial plexus of nerves.
 - Q.**—Subclavian artery in connection with the brachial plexus of nerves.
 - R. R.**—Post-scapular artery passing through the brachial plexus.
 - S.**—Transversalis humeri artery.
 - T.**—Transversalis colli artery.
 - U.**—Union of the post-scapular and external jugular veins, which enter the subclavian vein by a common trunk.
 - V.**—Posterior half of the omo-hyoid muscle.
 - W.**—Part of the subclavian vein, seen above the clavicle.
 - X.**—Scalenus muscle, separating the subclavian artery from vein.
 - Y.**—Clavicle.
 - Z.**—Trapezius muscle.
- 1.—Sternal origin of sterno-mastoid muscle of left side.
 - 2.—Clavicular origin of sterno-mastoid muscle of right side, turned down.
 - 3.—Scalenus posticus muscle.
 - 4.—Splenius muscle.
 - 5.—Mastoid insertion of sterno-mastoid muscle.
 - 6.—Internal maxillary artery, passing behind the neck of lower jaw-bone.
 - 7.—Parotid duct.
 - 8.—Genio-hyoid muscle.
 - 9.—Mylo-hyoid muscle, cut and turned aside.
 - 10.—Superior thyroid artery.
 - 11.—Anterior half of omo-hyoid muscle.
 - 12.—Sterno-hyoid muscle, cut.
 - 13.—Sterno-thyroid muscle, cut.

PLATE 7.

DEEP DISSECTION OF THE HEAD AND NECK.

- A.**—Root of common carotid artery.
 - B.**—Subclavian artery at its origin.
 - C.**—Trachea.
 - D.**—Thyroid axis of subclavian artery.
 - E.**—Vagus nerve, crossing the origin of subclavian artery.
 - F.**—Subclavian artery at third division of its arch.
 - G.**—Post-scapular branch of subclavian artery.
 - H.**—Transversalis humeri branch of subclavian artery.
 - I.**—Transversalis colli branch of subclavian artery.
 - K.**—Posterior belly of omo-hyoid muscle, cut.
 - L.**—Median nerve branch of brachial plexus.
 - M.**—Musculo-spiral branch of same plexus.
 - N.**—Anterior scalenus muscle.
 - O.**—Cervical plexus giving off the phrenic nerve, which takes tributary branches from brachial plexus of nerves.
 - P.**—Upper part of internal jugular vein.
 - Q.**—Upper part of internal carotid artery.
 - R.**—Superior cervical ganglion of sympathetic nerve.
 - S.**—Vagus nerve lying external to sympathetic nerve, and giving off *t*, its laryngeal branch.
 - T.**—Superior thyroid artery.
 - U.**—Lingual artery, separated by hyoglossus muscle from
 - V.**—Hypoglossal or ninth cerebral nerve.
 - W.**—Sublingual salivary gland.
 - X.**—Genio-hyoid muscle.
 - Y.**—Mylo-hyoid muscle, cut and turned aside.
 - Z.**—Thyroid cartilage.
- 1.—Upper part of sterno-hyoid muscle.
 - 2.—Upper part of omo-hyoid muscle.
 - 3.—Inferior constrictor of pharynx.
 - 4.—Cricoid cartilage.
 - 5.—Crico-thyroid muscle.
 - 6.—Thyroid body.
 - 7.—Inferior thyroid artery of thyroid axis.
 - 8.—Sternal tendon of sterno-mastoid muscle, turned down.
 - 9.—Clavicular portion of sterno-mastoid muscle, turned down.
 - 10.—Clavicle.
 - 11.—Trapezius muscle.
 - 12.—Scalenus posticus muscle.
 - 13.—Rectus capitis anticus major muscle.
 - 14.—Stylo-hyoid muscle, turned aside.
 - 15.—Temporal artery.

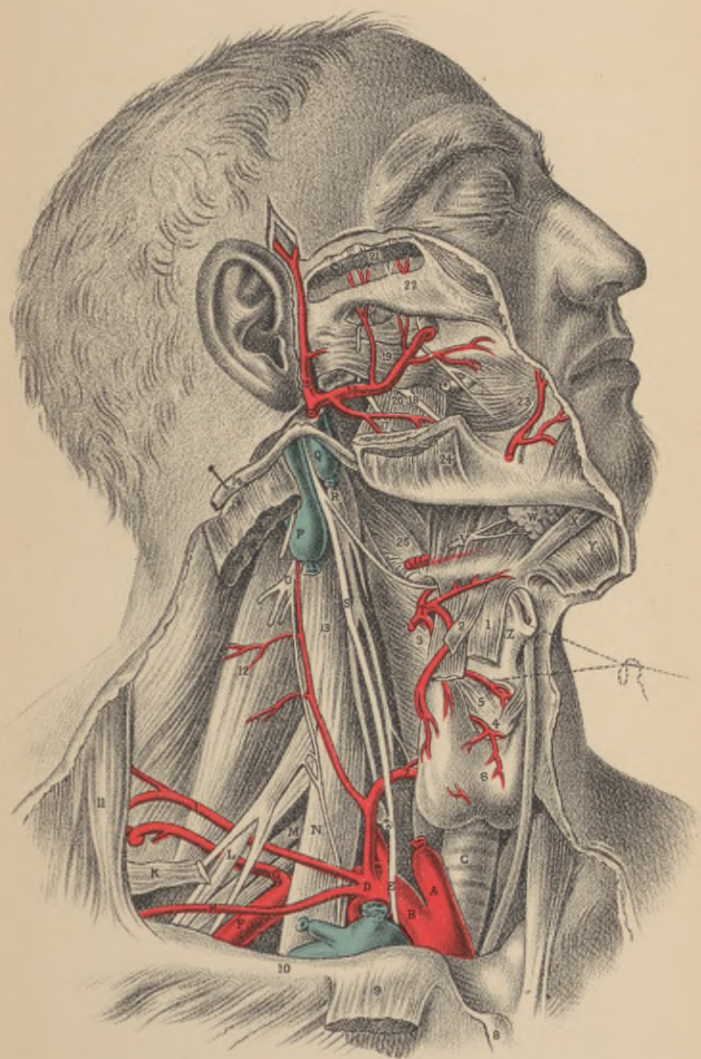


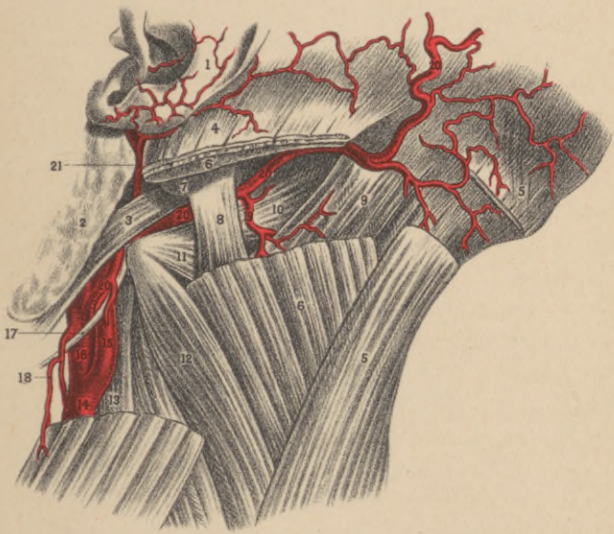
PLATE 7.—CONTINUED.

- 16.—Internal maxillary artery.
- 17.—Inferior dental branch of fifth pair of cerebral nerves.
- 18.—Gustatory branch of fifth pair of nerves.
- 19.—External pterygoid muscle.
- 20.—Internal pterygoid muscle.
- 21.—Temporal muscle, cut to show the deep temporal branches of fifth pair of nerves.
- 22.—Zygomatic arch.
- 23.—Buccinator muscle, with buccal nerve and parotid duct.
- 24.—Masseter muscle, cut on the lower maxilla.
- 25.—Middle constrictor of pharynx.

PLATE 8.

DEEP DISSECTION OF THE LATERAL REGION OF THE NECK.

- 1.—Auricular cartilage.
- 2.—Parotid gland.
- 3.—Digastric.
- 4.—Sterno-cleido mastoid.
- 5.—Trapezius.
- 6.—Splenius capitis.
- 7.—Mastoid process.
- 8.—Trachelo-mastoid muscle.
- 9.—Complexus.
- 10.—Obliquus capitis superior.
- 11.— “ “ inferior.
- 12.—Splenius colli.
- 13.—Scalenus medius.
- 14.—Common carotid artery.
- 15.—Internal carotid artery.
- 16.—External carotid artery.
- 17.—Hypoglossal nerve.
- 18.—Middle sterno-mastoid artery.
- 19.—Princeps cervicis artery.
- 20.—Occipital artery.
- 21.—Posterior auricular artery.



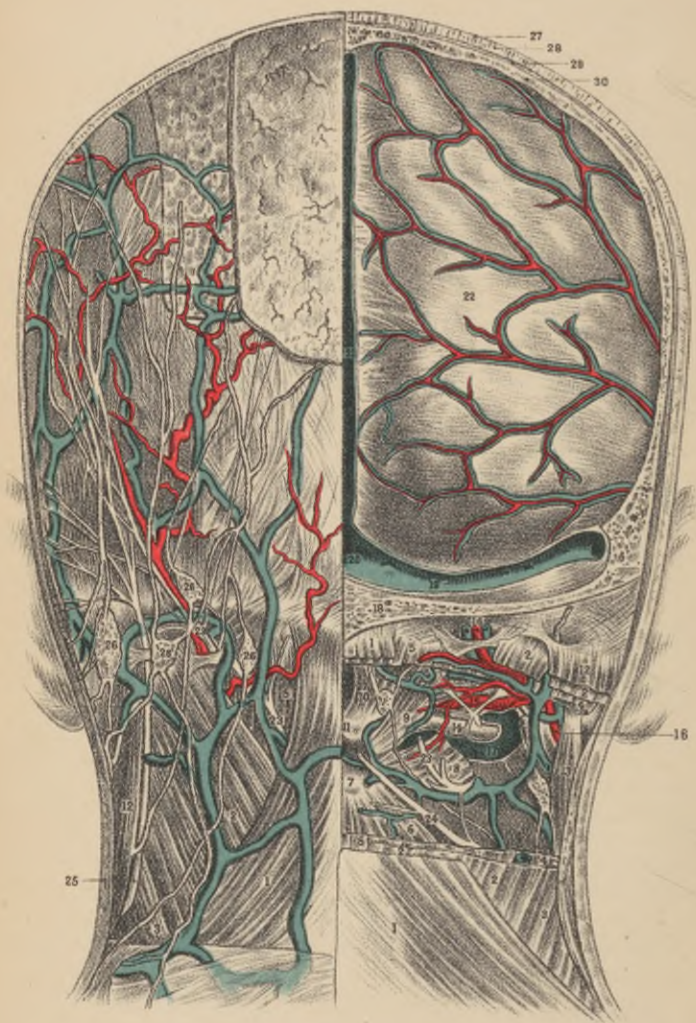


PLATE 9.

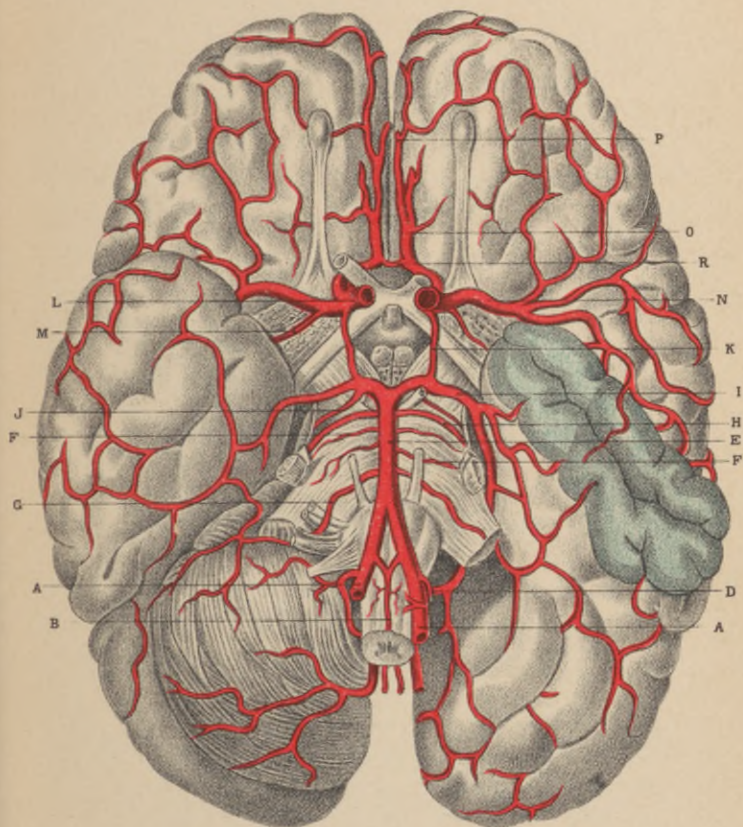
DISSECTION OF THE POSTERIOR ASPECT OF THE NECK AND HEAD.

- 1.—Trapezius.
2. } Splenius capitis et colli.
3. }
- 4.—Trachelo-mastoid.
- 5.—Biventer cervicis and complexus.
- 6.—Semispinalis colli.
- 7.—Spinous process of axis.
- 8.—Obliquus capitis inferior.
- 9.—Rectus capitis posticus major.
- 10.— “ “ “ minor.
- 11.—Spinous process of atlas (first).
- 12.—Sterno-cleido-mastoid.
- 13.—Digastric.
- 14.—Posterior arch of atlas.
- 15.—Vertebral artery.
- 16.—Occipital artery.
- 17.—Sigmoid vein (split), passing between the arches of the first and second vertebra.
It has many connections with the veins both without and within the spinal canal.
- 18.—Section of occipital bone.
- 19.—Right transverse sinus.
- 20.—Torcular Herophili.
- 21.—Longitudinal sinus.
- 22.—Dura mater.
- 23.—Occipitalis major.
- 24.—Posterior branch of the third cervical nerve.
- 25.—Occipitalis minor.
- 26.—Superficial occipital and mastoid glands.
- 27.—Section of the skin.
- 28.—Subcutaneous fat, including the large blood-vessels in its deepest layer.
- 29.—Section of the aponeurosis occipito-frontalis.
- 30.—Section of the parietal bone, showing diploe, inner and outer tables.

PLATE 10.

ARTERIAL SUPPLY TO THE BASE OF THE BRAIN.

- A.A.**—Vertebral arteries.
- B.**—Anterior spinal branches, forming median anterior trunk.
- D.**—Posterior inferior cerebellar artery.
- E.**—Basilar trunk, from convergence of two vertebrals.
- F.F.**—Transverse arteries.
- G.**—Anterior inferior cerebellar artery.
- H.**—Superior cerebellar artery.
- I.**—Posterior cerebral artery, terminal branching of basilar.
- J.**—Choroidean artery, posterior.
- K.**—Posterior communicating artery.
- L.**—Carotid artery, internal.
- M.**—Anterior choroidean artery.
- N.**—Middle cerebral artery.
- O.**—Anterior cerebral artery.
- P.**—Point of reflection of anterior cerebral over the corpus callosum.
- R.**—Anterior communicating artery.



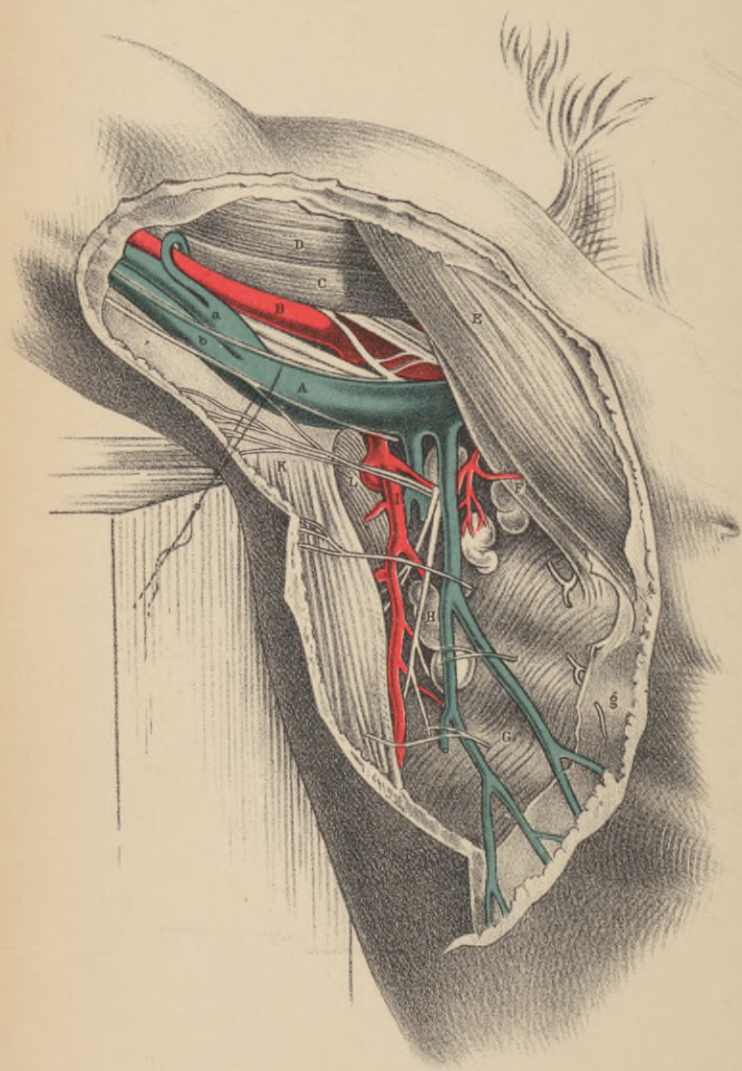


PLATE 11.

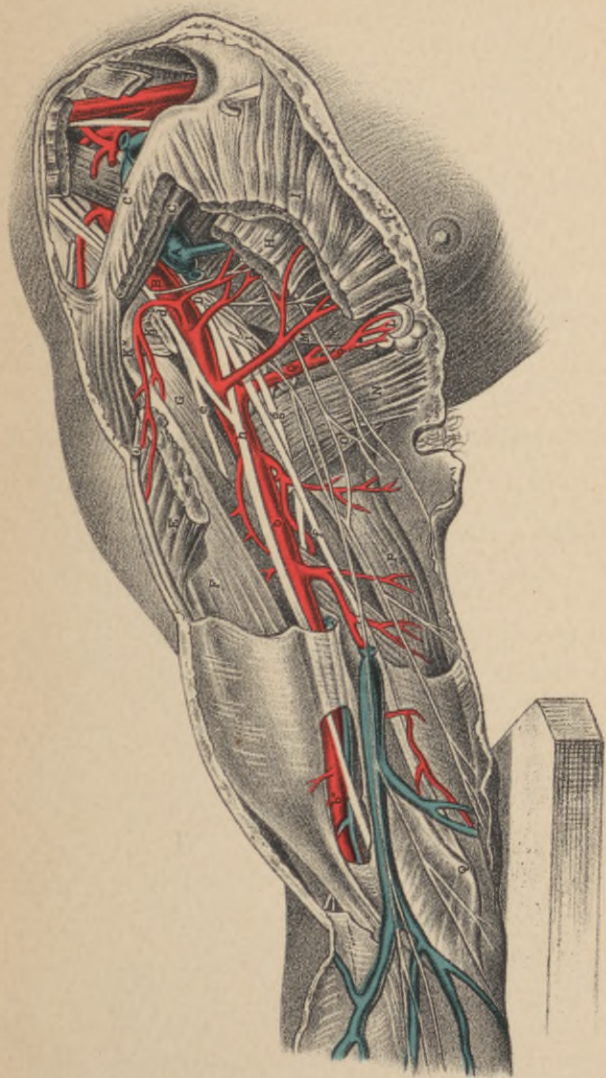
DISSECTION OF THE AXILLA.


- A.**—Axillary vein, drawn apart from the artery to show the nerves lying between both vessels. On the bicipital border of the vein is seen the internal cutaneous nerve; on the tricipital border is the nerve of Wrisberg, communicating with some of the intercosto-humeral nerves; *a*, the common trunk of the venæ comites, entering the axillary vein.
- B.**—Axillary artery crossed by one root of the median nerve; *b*, basilic vein forming with *a*, the axillary vein, **A**.
- C.**—Coraco-brachialis muscle.
- D.**—Coracoid head of biceps muscle.
- E.**—Pectoralis major muscle.
- F.**—Pectoralis minor muscle.
- G.**—Serratus magnus muscle, covered by *g*, the axillary fascia, and perforated at regular intervals by nervous branches called intercosto-humeral.
- H.**—Conglobate gland, crossed by nerve called "external respiratory" of Bell, distributed to the serratus magnus muscle. This nerve descends from the cervical plexus.
- I.**—Subscapular artery.
- K.**—Tendon of latissimus dorsi muscle.
- L.**—Teres major muscle.

PLATE 12.

DISSECTION OF THE AXILLARY AND BRACHIAL REGIONS.

- A.**—Axillary vein cut and tied; *a*, the basilic vein cut.
- B.**—Axillary artery; *b*, brachial artery, in the upper part of its course, having *h*, the median nerve, lying rather to its outer side; *b** the artery on the lower part of its course, with the median nerve to its inner side.
- C.**—Subclavius muscle.
- C.***—Clavicle.
- D.**—Axillary plexus of nerves, of which *d* is a branch on the coracoid border of the axillary artery; *e*, the musculo-cutaneous nerve, piercing the coraco-brachialis muscle; *f*, the ulnar nerve; *g*, musculo-spiral nerve; *h*, the median nerve; *i*, the circumflex nerve.
- E.**—Humeral part of the great pectoral muscle.
- F.**—Biceps muscle.
- G.**—Coraco-brachialis muscle.
- H.**—Thoracic half of the lesser pectoral muscle.
- I.**—Thoracic half of the greater pectoral muscle.
- K.**—Coracoid attachment of the lesser pectoral muscle.
- K.***—Coracoid process of the scapula.
- L.**—Lymphatic glands.
- M.**—Serratus magnus muscle.
- N.**—Latissimus dorsi muscle.
- O.**—Teres major muscle.
- P.**—Long head of triceps muscle.
- Q.**—Inner condyle of humerus.





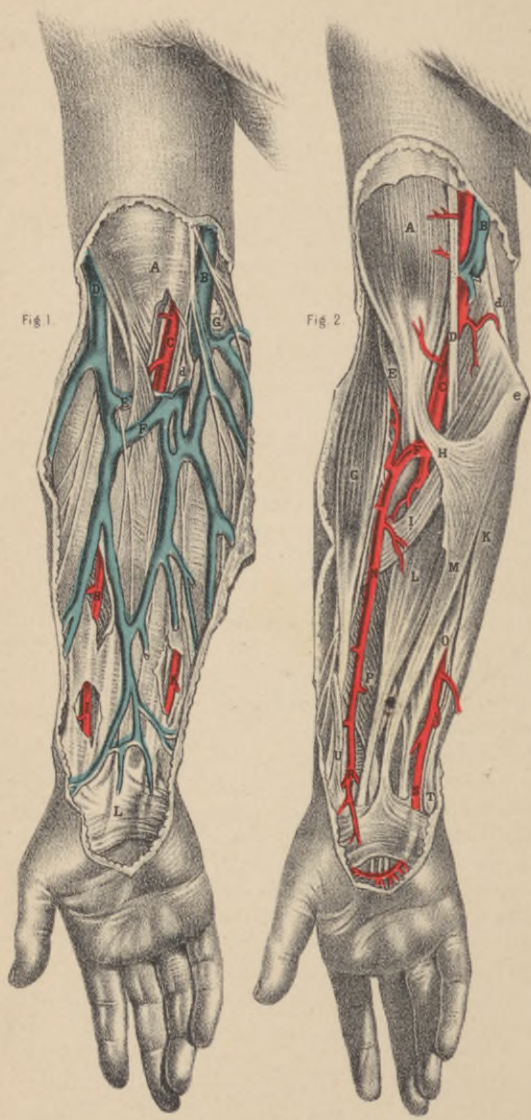


PLATE 13.

SUPERFICIAL AND DEEP DISSECTION OF THE BEND OF THE ELBOW AND FOREARM.

FIG. 1.

- A.**—Fascia, covering the biceps muscle.
- B.**—Basilic vein, with internal cutaneous nerve.
- C.**—Brachial artery, with the venæ comites.
- D.**—Cephalic vein, with the external cutaneous nerve; *d*, the median nerve.
- E.**—A communicating vein, joining the venæ comites.
- F.**—Median basilic vein.
- G.**—Lymphatic gland.
- H.**—Radial artery at its middle.
- I.**—Radial artery of the pulse.
- K.**—Ulnar artery, with ulnar nerve.
- L.**—Palmaris brevis muscle.

FIG. 2.

- A.**—Biceps muscle.
- B.**—Basilic vein, cut.
- C.**—Brachial artery.
- D.**—Median nerve; *d*, ulnar nerve.
- E.**—Brachialis anticus muscle; *e*, the internal condyle.
- F.**—Origin of radial artery.
- G.**—Supinator radii longus muscle.
- H.**—Aponeurosis of the tendon of the biceps muscle.
- I.**—Pronator radii teres muscle.
- K.**—Flexor carpi ulnaris muscle.
- L.**—Flexor carpi radialis muscle.
- M.**—Palmaris longus muscle.
- N.**—Radial artery at middle, with radial nerve on outer side.
- O.**—Flexor digitorum sublimis.
- P.**—Flexor pollicis longus.
- Q.**—Median nerve.
- R.**—Lower end of radial artery.
- S.**—Lower end of ulnar artery, in company with ulnar nerve.
- T.**—Pisiform bone.
- U.**—Extensor metacarpi pollicis.

PLATE 14.

DISSECTION OF THE WRIST AND HAND.

FIG. 1.

- A.**—Radial artery.
- B.**—Median nerve; *b,b,b*, its branches.
- C.**—Ulnar artery, forming **F**, the superficial palmar arch.
- D.**—Ulnar nerve; **E,e,e**, its continuation, branching to the little and ring fingers etc.
- G.**—Pisiform bone.
- H.**—Abductor muscle of the little finger.
- I.**—Tendon of flexor carpi radialis muscle.
- K.**—Opponens pollicis muscle.
- L.**—Flexor brevis muscle of the little finger.
- M.**—Flexor brevis pollicis muscle.
- N.**—Abductor pollicis muscle.
- O.O.O.O.**—Lumbricales muscles.
- P.P.P.P.**—Tendons of the flexor digitorum sublimis muscle.
- Q.**—Tendon of the flexor longus pollicis muscle.
- R.**—Tendon of extensor metacarpi pollicis.
- S.**—Tendons of extensor digitorum sublimis; **P,P,P**, their digital prolongations.
- T.**—Tendon of flexor carpi ulnaris.
- U.**—Union of the digital arteries at the tip of the fingers.

FIG. 2.

- A.**—Radial artery.
- B.**—Tendons of the extensors of the thumb.
- C.**—Tendon of extensor carpi radialis.
- D.**—Annular ligament.
- E.**—Deep palmar arch, formed by radial artery giving off *e*, the artery of the thumb.
- F.**—Pisiform bone.
- G.**—Ulnar artery, giving off the branch **I**, to join the deep palmar arch **E**, of the radial artery.
- H.**—Ulnar nerve; *h*, superficial branches given to the fingers. Its deep palmar branch is seen lying on the interosseous muscles, **M,M**.
- K.**—Abductor minimi digiti.
- L.**—Flexor brevis minimi digiti.
- M.**—Palmar interossei muscles.
- N.**—Tendon of flexor digitorum sublimis and profundus, and the lumbricales muscles, cut and turned down.
- O.**—Tendon of flexor pollicis longus.
- P.**—Carpal end of the metacarpal bone of the thumb.

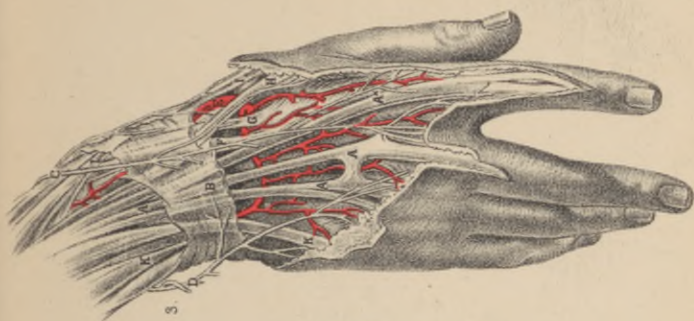


FIG. 3.

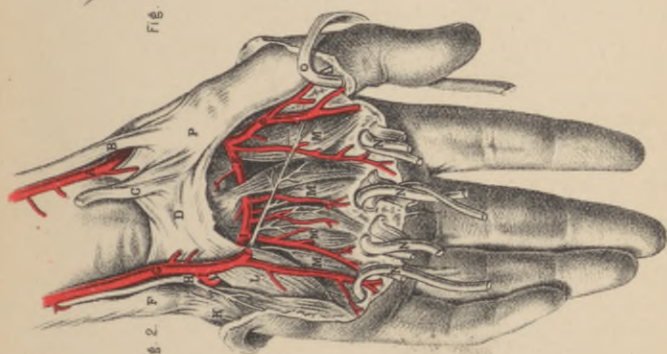


FIG. 2.

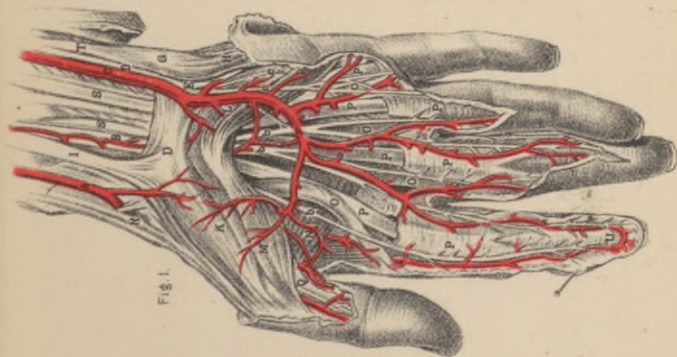


FIG. 1.

PLATE 14.—CONTINUED.

FIG. 3.

- A.A.A.**—Tendons of extensor digitorum communis; **A***, tendon overlaying that of indicator muscle.
- B.**—Dorsal part of the annular ligament
- C.**—End of the radial nerve, distributed over the back of the hand, to two of the fingers and the thumb.
- D.**—Dorsal branch of the ulnar nerve, supplying the back of the hand and the three outer fingers.
- E.**—Radial artery, turning round the carpal end of the metacarpal bone of the thumb.
- F.**—Tendon of extensor carpi radialis brevis.
- G.**—Tendon of extensor carpi radialis longior.
- H.**—Tendon of third extensor of the thumb.
- I.**—Tendon of second extensor of the thumb.
- K.**—Tendon of extensor minimi digiti, joining a tendon of extensor communis.

PLATE 15.

SUPERFICIAL DISSECTION OF THE BACK.

- 1.—Acromion.
- 2.—Trapezius.
- 3.—Latissimus dorsi.
- 4.—Rhomboides major.
- 5.—Infraspinatus.
- 6.—Teres minor.
- 7.—Teres major.
- 8.—Deltoid.
- 9.—Triceps—long head.
10. { Dorsalis scapulæ artery.
11. { “ “ “
- 12.—Intercostal nerves.
- 13.—Rhomboides minor.
- 14.— “ major.
- 15.—Dorsal fascia.
- 16.—Splenius capitis.
- 17.—Intercostal arteries.
- 18.—Transverse scapular artery.
- 19.—Dorsal nerves.
- 20.—Fifth to ninth ribs.
- 21.—Inferior angle of scapula.
- 22.—Spine of scapula.
- 23.—Acromion.
- 24.—Clavicle.
- 25.—Transverse ligament.
- 26.—Capsular ligament.
- 27.—Insertion of rhomboides major.
- 28.— “ “ minor.
- 29.—Levator anguli scapulæ.
- 30.—Clavicular insertion of trapezius.
- 31.—Supraspinatus.
- 32.—Infraspinatus.
- 33.—Deltoid (cut across).
- 34.—Teres minor.
- 35.—Serratus magnus.
- 36.—External intercostals.
- 37.—Dorsalis scapulæ artery, nerve and vein.
- 38.—Transverse scapular artery.
- 39.— “ “ vein and nerve.
- 40.—Supra-scapular artery, nerve and vein.
- 41.—Recurrent or circumflex, scapular artery and vein.
- 42.—External oblique.
- 43.—Intercostal nerves.
- 44.—Serratus posticus inferior.
- 45.—Three lower ribs.

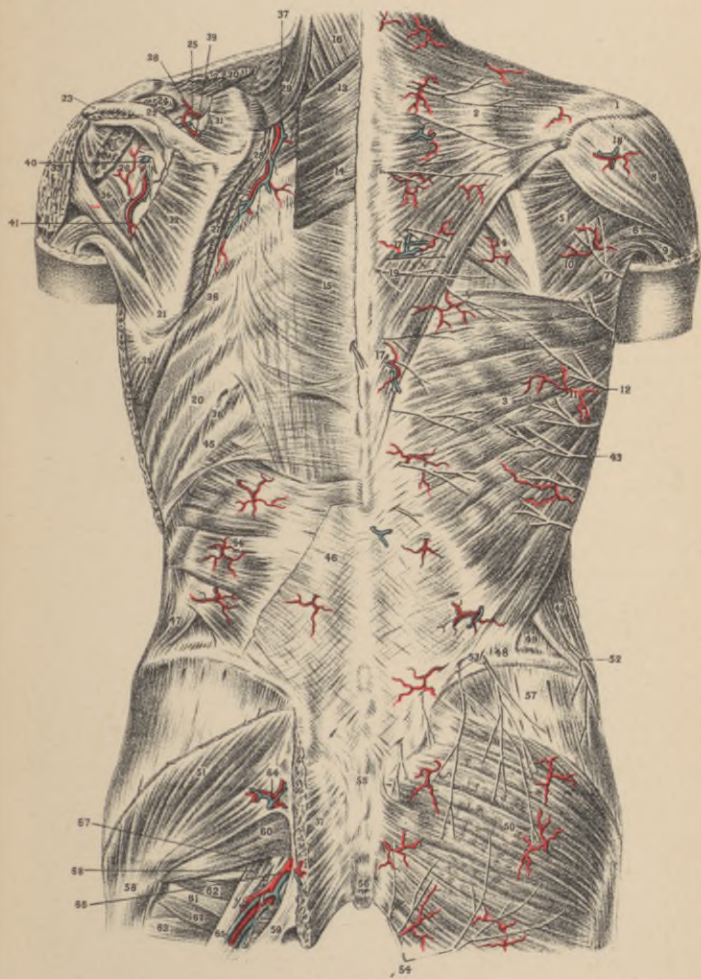


PLATE 15.—CONTINUED.

- 46.—Tendinous origin of latissimus dorsi.
- 47.—External oblique, back part.
- 48.—Crest of ileum.
- 49.—Internal oblique.
- 50.—Gluteus maximus.
- 51.— “ medius.
- 52.—Lowest intercostal nerve.
- 53.—Superior cutaneous nerves.
- 54.—Inferior “ “
- 55.—Sacrum.
- 56.—Coccyx.
- 57.—Origin of gluteus maximus.
- 58.—Greater trochanter.
- 59.—Great sacro-sciatic ligament.
- 60.—Pyriformis.
- 61.—Obturator internus.
- 62.—Gemelli muscles.
- 63.—Quadratus femoris.
- 64.—Superior gluteal artery and nerve.
- 55.—Great sciatic nerve.
- 66.—Sciatic artery and vein.
- 67.—Cutaneous nerve to posterior femoral region.
- 68.—Inferior gluteal nerve.

PLATE 16.

DEEP DISSECTION OF THE BACK.

- 1.—Subscapular muscle, cross section.
- 2.—Serratus magnus “ “
- 3.—Teres major.
- 4.—Triceps, long head.
- 5.—Teres minor, origin.
- 6.—Acromion.
- 7.—Humerus, anatomical neck.
- 8.—Splenius capitis.
- 9.—Splenius colli.
- 10.—Transversalis colli muscle.
- 11.—Cervicalis ascendens muscle.
- 12.—Trachelo-mastoid.
- 13.—Complexus.
- 14.—Semi-spinalis dorsi.
- 15.—Spinalis dorsi.
- 16.—Longissimus dorsi.
- 17.—Sacro-lumbalis; tendinous extension inserted into the nine upper ribs.
- 18.—Cervicalis ascendens, costal origin from the six upper ribs.
- 19.—Intercostal muscle (external).
- 20.—Intercostal artery and vein (passing between the inner and outer layer of the internal intercostal muscle).
- 21.—Supra-spinatus.
- 22.—Capsule of shoulder joint.
- 23.—Deltoid.
- 24.—Triceps muscle, external head.
- 25.—Triceps “ long head.
- 26.—Teres minor.
- 27.—Teres major.
- 28.—Latissimus dorsi.
- 29.—Sacro-lumbalis.
- 30.—Venous plexus of the spinal canal.
- 31.—Lumbar aponeurosis (fascia).
- 32.—Union of the leaflets of the lumbar fascia.
- 33.—Levatores costarum breviores.
- 34.— “ “ longiores.
- 35.—Roots of the lumbar and sacral nerves.
- 36.—Internal oblique muscle.
- 37.—Transversalis “
- 38.—Intercostal artery, vein and nerve (twelfth).
- 39.—Ileo-hypogastric nerve.
- 40.—Great sacro-sciatic foramen.
- 41.—Neck of femur.
- 42.—Trochanter major.
- 43.—Trochanter minor.

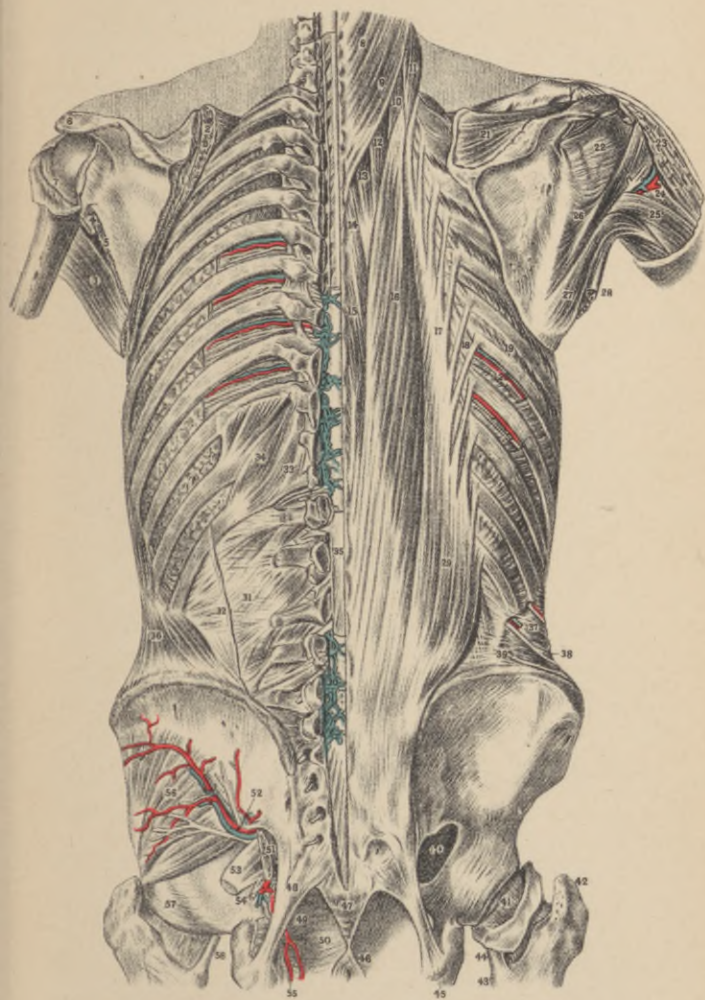


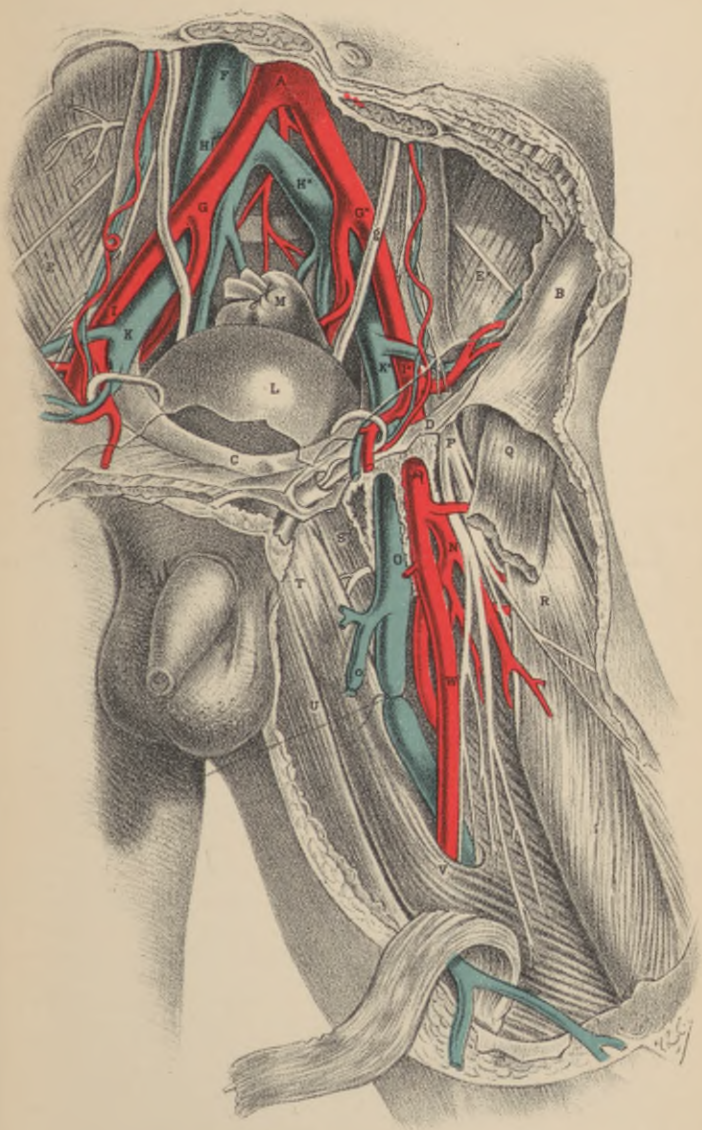
PLATE 16.—CONTINUED.

- 44.—Insertion of psoas and iliacus into trochanter minor.
- 45.—Tuberosity of the ischium.
- 46.—External sphincter ani.
- 47.—Coccyx.
- 48.—Great sacro-sciatic ligament.
- 49.—Obturator internus, cut across immediately after passing under great sacro-sciatic ligament.
- 50.—Levator ani.
- 51.—Pyriformis, cross section immediately after its exit from the foramen magnum.
- 52.—Gluteal artery, veins and nerve.
- 53.—Sciatic nerve.
- 54.—Ischiatic artery.
- 55.—Internal pudic artery.
- 56.—Gluteus medius muscle.
- 57.—Capsule of hip joint.
- 58.—Tendinous insertion of iliacus and psoas.

PLATE 17.

DISSECTION OF PRINCIPAL BLOOD-VESSELS AND NERVES OF THE ILIAC AND FEMORAL REGIONS.

- A.**—The aorta at its point of bifurcation.
- B.**—Anterior superior iliac spine.
- C.**—The symphysis pubis.
- D.**—Poupart's ligament, immediately above which are seen the circumflex iliac and epigastric arteries, with the vas deferens and spermatic vessels.
- E.E.***—Right and left iliac muscles, covered by the peritonæum; the external cutaneous nerve is seen through the membrane.
- F.**—The vena cava.
- G.G.***—The common iliac arteries giving off the internal iliac branches on the sacro-iliac symphyses; *g, g*, the right and left ureters.
- H.H.***—Right and left common iliac veins.
- I.I.**—Right and left external iliac arteries; each is crossed by the circumflex iliac vein.
- K.K.**—Right and left external iliac veins.
- L.**—Urinary bladder, covered by peritonæum.
- M.**—The rectum intestinum.
- N.**—The profundus branch of femoral artery.
- O.**—Femoral vein; *o*, saphena vein.
- P.**—Anterior crural nerve.
- Q.**—Sartorius muscle, cut.
- S.**—Pectinæus muscle.
- T.**—Adductor longus muscle.
- U.**—The gracilis muscle.
- V.**—The tendinous sheath given off from the long adductor muscle, crossing the vessels, and becoming adherent to the vastus internus muscle (forming Hunter's Canal).
- W.**—Femoral artery. The letter is on the part where the vessel becomes first covered by the sartorius muscle.



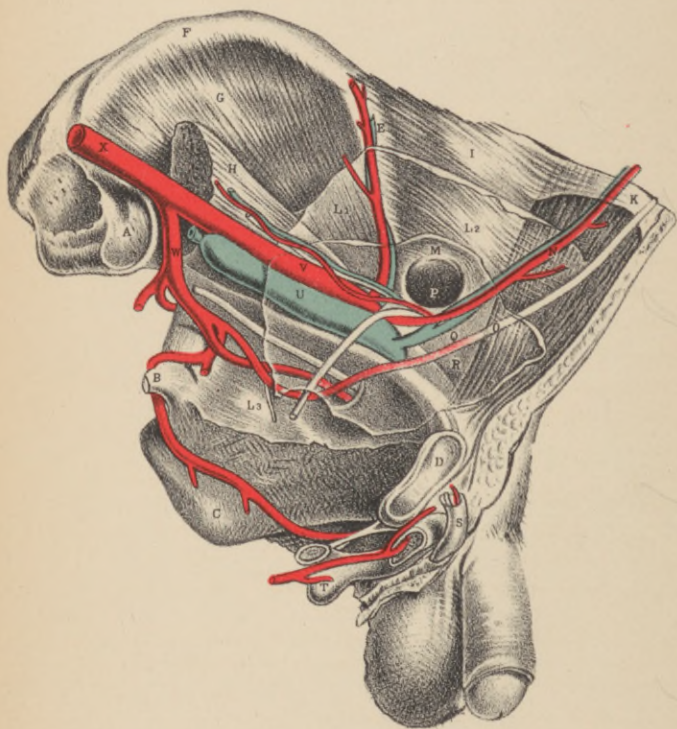


PLATE 18.

DISSECTION SHOWING THE SURGICAL RELATIONS OF THE EXTERNAL ILIAC ARTERY AND THE INTERNAL ABDOMINAL RING.

- A.**—That part of the ilium which abuts against the sacrum.
- B.**—The spine of the ischium.
- C.**—The tuberosity of the ischium.
- D.**—The symphysis pubis.
- E.**—Situation of the anterior superior iliac spine.
- F.**—Crest of the ilium.
- G.**—Iliacus muscle.
- H.**—Psoas magnus muscle, supporting the spermatic vessels.
- I.**—Transversalis muscle.
- K.**—Termination of the sheath of the rectus muscle.
- L¹. L². L³.**—The iliac, transverse and pelvic portions of the transversalis fascia.
- M.**—The peritoneum lining groin.
- N.**—The epigastric vessels lying between the peritoneum, **M**, and the transversalis fascia, **L²**.
- O.**—The umbilical ligament.
- P.**—The neck of the sac of an internal inguinal hernia, formed before the spermatic vessels.
- Q.**—An interval which occasionally occurs between the umbilical ligament and the epigastric artery.
- R. and Q.**—Situations where the direct inguinal hernia occurs when, as in this case, the umbilical ligament crosses the space named the internal fossa—the triangle of Hesselbach.
- S.**—Lower part of the spermatic cord.
- T.**—The bulb of the urethra.
- U.**—External iliac vein, covered by the peritoneum.
- V.**—External iliac artery, covered by the peritoneum.
- W.**—Internal iliac artery.
- X.**—Common iliac artery.

PLATE 19.

DISSECTION OF THE MALE PELVIC ORGANS.

- A.**—The part of the sacrum which joins the ilium.
- B.**—The external iliac artery, cut across.
- C.**—The upper part of the rectum.
- D.**—The ascending pubic ramus.
- E.**—The spine of the ischium, cut.
- F.**—The horizontal pubic ramus, cut.
- G.**—Summit of the bladder, covered by the peritoneum; **G***, its side not covered by the peritoneal membrane.
- H. H.**—Recto-vesical peritoneal pouch.
- I.**—The vas deferens.
- K.**—The ureter.
- L.**—Vesicula seminalis.
- M.**—The spermatic cord.
- N.**—Corpus cavernosum penis; *n*, its artery.
- O.**—Urethra; *o*, the bulbous urethra.
- P.**—Sphincter ani muscle.
- Q.**—The coccyx.
- R.**—The sacro-sciatic ligament.
- S.**—Pudic artery and nerve.
- T.**—The sacral nerves.
- U.**—Pyriformis muscle, cut.
- V.**—The prostate.
- W.**—Lower part of the rectum.
- X.**—Deep perineal fascia.

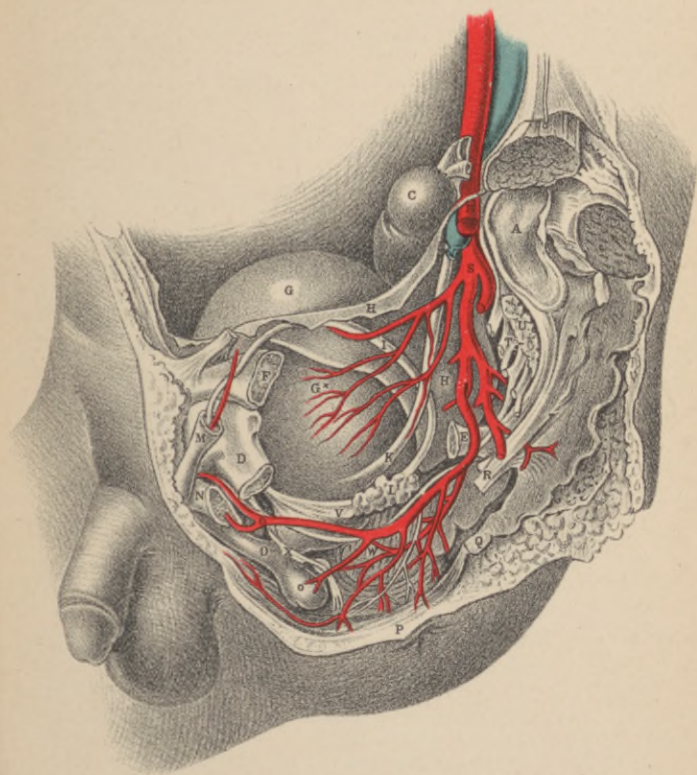


PLATE 20.

SIDE VIEW OF THE FEMALE PELVIS.

- B.**—Bladder (turned down).
R.—Rectum.
L.—Round ligament.
U.—Uterus.
O.—Ovary.
V.—Vagina.
S.—Sacro-iliac synchondrosis.
K.—Kidney.
T.—Fallopian tube.
P.—Pubic symphysis.
a.—Pyriformis muscle (cut).
b.—Gluteal muscles.
c.—Coccygeus muscle.
d.—Obturator internus.
e.—Psoas magnus.
f.—Linea alba.
g.g.—Ureters.
h.—Obturator nerve.
i.—Internal abdominal ring.
k.—Great sacro-sciatic ligament.
1.—Abdominal aorta.
2.—Inferior mesenteric artery.
3, 3.—Common iliac arteries.
4.—Left external iliac artery.
5.—Vena cava inferior.
6, 6.—Renal veins.
7, 7.—Common iliac veins.
8.—External iliac vein.
9.—Internal iliac artery (cut).
10.—Gluteal vein.
11.—Ilio-lumbar vein.
12.—Lateral sacral vein.
13.—Sciatic vein.
14.—Pudic vein.
15.—Obturator vein.
16.—Epigastric vein.
17.—Uterine veins.
18.—Vesico-vaginal veins.
19.—Ovarian veins.
20.—Bulb of the ovary.
21.—Vein to round ligament.
22.—Fallopian veins.

PLATE 21.

SHOWING THE RELATIONS OF THE INTERNAL ILIAC ARTERY AND THE POSITION OF AN ISCHIATIC HERNIA.

- 1.—Cross section of two last lumbar vertebræ.
- 2.— “ “ “ sacrum.
- 3.— “ “ “ coccyx.
- 4.—Vertebral canal.
- 5.—Cross section of the pubic bone.
- 6.—Right pubic arch.
- 7.—Tuberosity of the ischium.
- 8.—Horizontal ramus of the pubis.
- 9.—Anterior superior spinous process of ilium.
- 10.—Crest of the ilium.
- 11.—Gluteus maximus.
- 12.—Greater sacro-sciatic ligament.
- 13.—Lesser sacro-sciatic ligament (covered by coccygeus muscle).
- 14.—Pyriformis muscle.
- 15.—Obturator internus.
- 16.—Obturator canal.
- 17.—Iliacus internus.
- 18.—Psoas major.
- 19.—Rectus femoris.
- 20.—Sartorius.
- 21.—Adductor longus.
- 22.—Gracilis.
- 23.—Adductor magnus.
- 24.—Iliac artery.
- 25.—External iliac artery.
- 26.—Deep epigastric artery.
- 27.—Circumflex iliac artery.
- 28.—Femoral artery.
- 29.—External iliac vein.
- 30.—Superior obturator vein.
- 31.—Internal iliac artery.
- 32.—Ileo-lumbar artery.
- 33.—Superior gluteal artery.
- 34.—Lateral sacral artery.
- 35.—Vesical artery.
- 36.—Anterior branch of internal iliac artery.
- 37.—Obturator artery.
- 38.—Middle hemorrhoidal artery.
- 39.—Internal pudic artery.
- 40.—Inferior gluteal or ischiatic artery.
- 41.—Internal pudic vein.

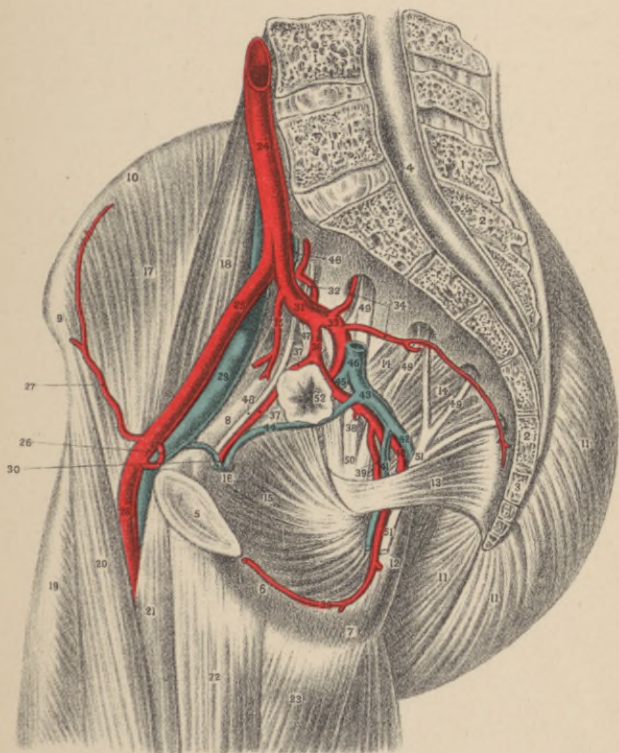


PLATE 21.—CONTINUED.

- 42.—Ischiatic vein.
- 43.—Union of two last mentioned veins into one vessel.
- 44.—Inferior obturator vein.
- 45.—Superior gluteal vein.
- 46.—Internal iliac vein.
- 47.—Fifth and portion of fourth lumbar nerves, forming with the sacral nerves the sacral plexus.
- 48.—Obturator nerve.
- 49.—Anterior branches of the sacral nerves.
- 50.—Sciatic nerve (ischiatric), formed of two lower lumbar and two upper sacral nerves.
- 51.—Pudic nerve.
- 52.—Mouth of the sack of an ischiatic hernia, above the pyriformis and anterior to the superior gluteal artery, with the obturator artery above and the inferior obturator vein below.

PLATE 22.

SUPERFICIAL DISSECTION OF THE INGUINO-FEMORAL REGION.

- A.**—The umbilicus.
- B.**—The upper margin of the pubic symphysis.
- C.**—The anterior superior spine of the left iliac bone.
- D.**—Position of internal abdominal ring.
- E.**—The saphenous opening in the fascia lata, receiving *e*, the saphenous vein.
- F.**—The lax and pendulous cord, overlying upper part of saphenous opening.
- G.**—Lymphatic glands, lying on fascia lata, in the neighborhood of the saphenous opening.
- H.**—The fleshy part of the external oblique muscle.
 - a.*—Superficial fascia of the abdomen.
 - b.*—Same fascia, forming an envelope for the spermatic cord and scrotum.
 - c.*—Inguinal glands, lying near Poupart's ligament.
 - d.*—A common venous trunk, formed by branches from thigh and abdomen, and joining—
 - e.e.*—The saphenous vein.
 - f.*—The middle cutaneous nerve, derived from the anterior crural nerve.
 - g.*—Femoral lymphatic glands.
 - h.*—Superficial external iliac vein.
 - i.*—Superficial epigastric vein.
 - k.*—External cutaneous branches of nerves from the lumbar plexus.

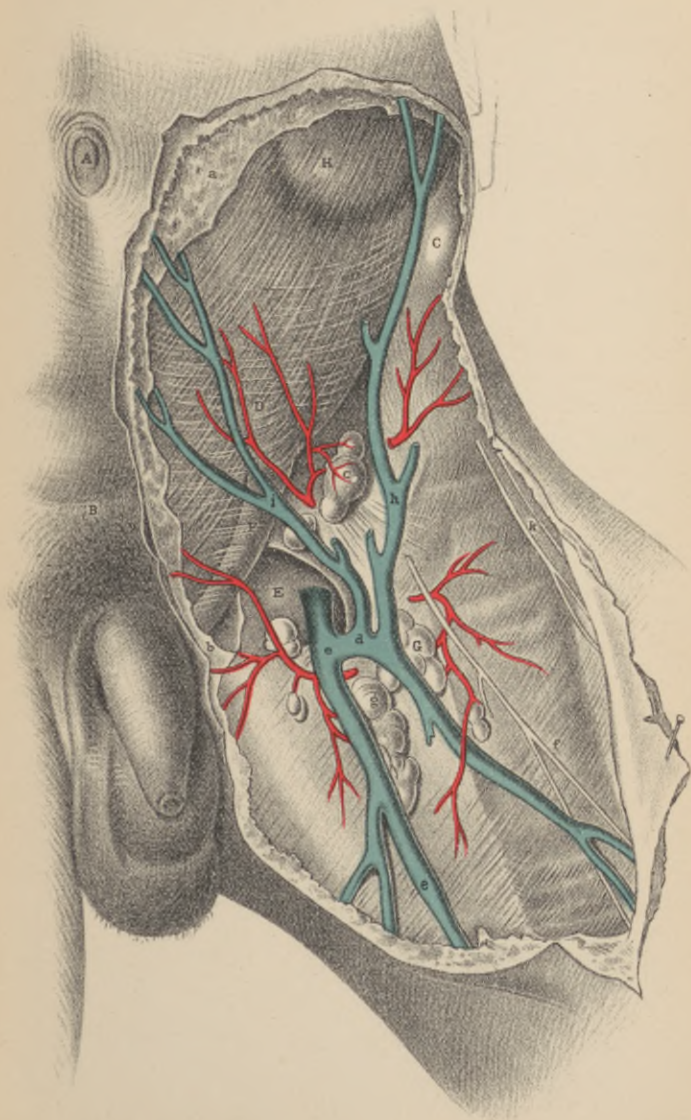


FIG. 2.

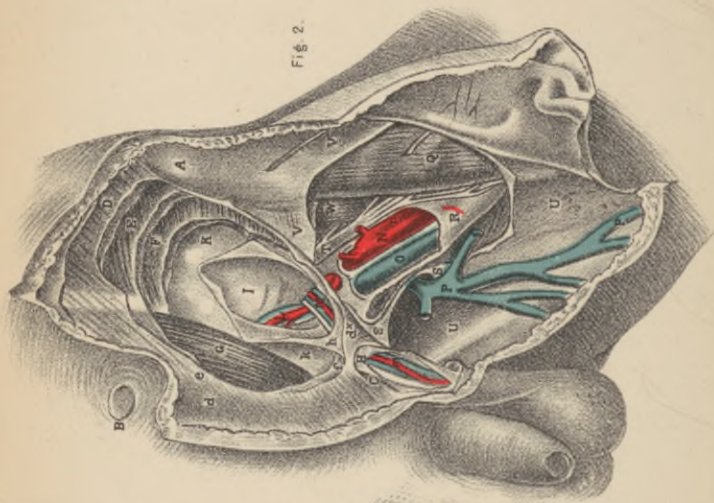


FIG. 1.

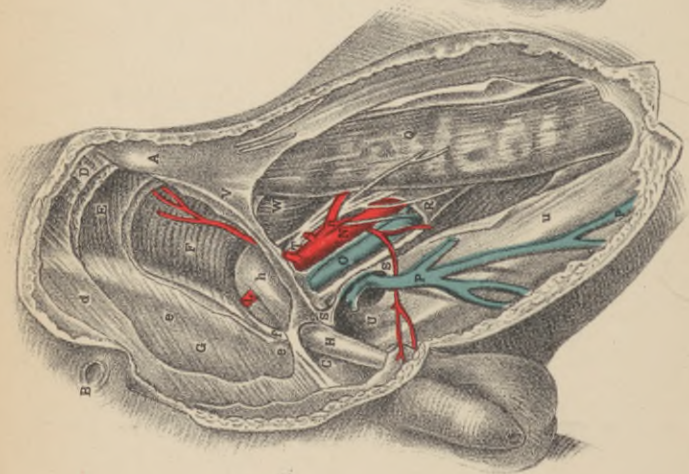


PLATE 23.

DISSECTION OF THE FIFTH, SIXTH, SEVENTH AND EIGHTH LAYERS OF THE INGUINAL REGION, AND THEIR CONNECTION WITH THOSE OF THE THIGH.

FIG. 1.

- A.—Anterior superior iliac spine.
- B.—The umbilicus.
- C.—Spine of the pubis.
- D.—External oblique muscle; *d*, its tendon.
- E.—Internal oblique muscle; *e*, its tendon.
- F.—Transverse muscle; *f*, its tendon, forming, with *e*, the conjoined tendon.
- G.—The rectus muscle enclosed in its sheath.
- H.—The fascia spermatica interna, covering the cord; *h*, its funnel-shaped extremity.
- I.—Epigastric artery.
- N.—Femoral artery; *n*, its profunda branch.
- O.—Femoral vein.
- P.—Saphena vein.
- Q.—Sartorius muscle.
- R.—Sheath of the femoral vessels.
- S.—The falciform margin of the saphenous opening.
- T.—Anterior crural nerve.
- U.—Pubic portion of the fascia lata.
- V.—Iliac portion attached to Poupart's ligament.
- W.—Lower part of the iliacus muscle.

FIG. 2.

- A. B. C. refer to same parts as in Fig. 1.
- D.—External oblique muscle; *d*, its tendon; *d**, the external ring.
- E.—Internal oblique muscle.
- F. N. O. P. Q. R. S. T. U. and W, refer to same parts as in Fig. 1.
- G.—Rectus muscle laid bare.
- H. h.—Fascia spermatica interna laid open, above and below *d**, the external ring.
- I.—The peritonæum, closing the internal ring.
- K.—Fascia transversalis; *k*, its pubic part.
- L.—Epigastric artery and veins.
- M.—Spermatic artery, veins and vas deferens, bending round the epigastric artery at the internal ring; *m*, the same vessels below the external ring.
- V.—Iliac part of the fascia lata.

PLATE 24.

DISSECTION OF THE ANTERIOR CRURAL REGION, THE ANKLE AND THE FOOT.

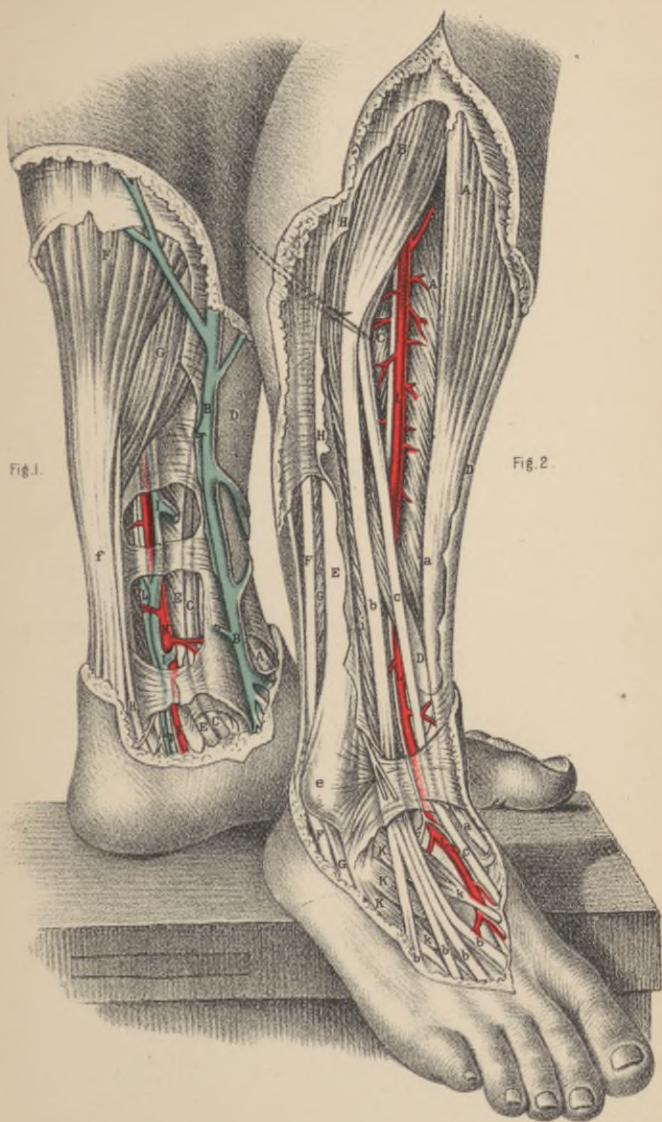
FIG. 1.

- A.**—Tendon of the tibialis anticus muscle.
- B.**—Long saphena vein.
- C.C.**—Tendon of the tibialis posticus muscle.
- D.**—The tibia; *d*, the inner malleolus.
- E.E.**—Tendon of the flexor longus digitorum muscle.
- F.**—Gastrocnemius muscle; *b*, tendo-Achillis.
- G.**—Soleus muscle.
- H.**—Tendon of the plantaris muscle.
- I.I.**—The venæ comites.
- K.K.**—Posterior tibial artery.
- L.L.**—Posterior tibial nerve.

DISSECTION OF INNER AND POSTERIOR ASPECT OF ANKLE AND LOWER THIRD OF LEG.

FIG. 2.

- A.**—Tibialis anticus muscle; *a*, its tendon.
- B.**—Extensor longus digitorum muscle; *b, b, b, b*, its four tendons.
- C.**—Extensor longus pollicis muscle.
- D.D.**—The tibia.
- E.**—The fibula; *e*, the outer malleolus.
- F.F.**—Tendon of the peronæus longus muscle.
- G.G.**—Peronæus brevis muscle; *i*, the peronæus tertius.
- H.H.**—The fascia.
- K.**—Extensor brevis digitorum muscle; *k, k*, its tendons.
- L.L.**—Anterior tibial artery, and nerve descending to the dorsum of the foot.



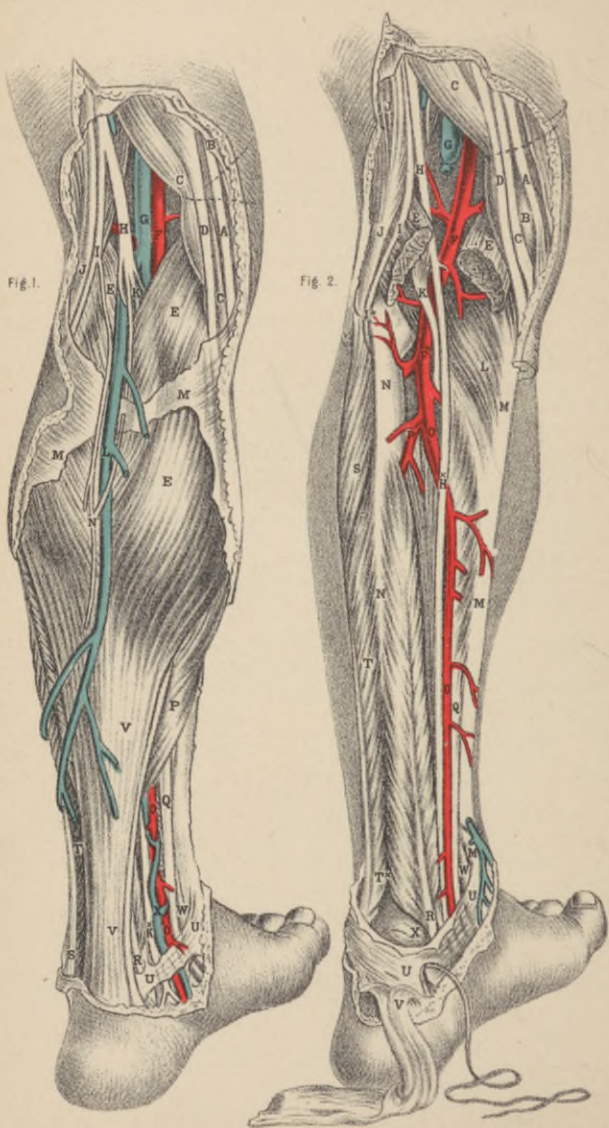


PLATE 25.

DISSECTION OF THE POPLITEAL SPACE AND THE POSTERIOR CRURAL REGION.

FIG. 1.

- A.**—Tendon of the gracilis muscle.
- B.B.**—The fascia lata.
- C.C.**—Tendon of the semimembranosus.
- D.**—Tendon of the semitendinosus muscle.
- E.E.**—The two heads of the gastrocnemius muscle.
- F.**—Popliteal artery.
- G.**—Popliteal vein, joined by the short saphena vein.
- H.**—Middle branch of the sciatic nerve.
- K.**—Posterior tibial nerve, continued from the middle branch of the sciatic, and extending to **K**^{*}, behind the inner ankle.
- L.**—Posterior (short) saphena vein.
- M.M.**—The fascia, covering the gastrocnemius muscle.
- N.**—Short (posterior) saphena nerve, formed by the union of branches from peroneal and posterior tibial nerves.
- O.**—Posterior tibial artery, appearing from beneath the soleus muscle in lower part of the leg.
- P.**—Soleus muscle, joining the tendo-achillis.
- Q.**—Tendon of the flexor communis digitorum muscle.
- R.**—Tendon of flexor longus pollicis muscle.
- S.**—Tendon of the peronæus longus muscle.
- T.**—Peronæus brevis muscle.
- U.U.**—Internal annular ligament, binding down the vessels, nerves and tendons in the hollow, behind the inner ankle.
- V.V.**—Tendo-achillis.
- W.**—Tendon of the tibialis posticus muscle.
- X.**—The venæ comites of the posterior tibial artery.

FIG. 2.

- A.C.D.E.F.G.H.I.** refer to same parts as in Fig. 1.
- B.**—Inner condyle of the femur.
- K.**—The plantaris muscle, lying upon the popliteal artery.
- L.**—Popliteus muscle.
- M.M.M.**—The tibia.
- N.N.**—The fibula.
- O.O.**—Posterior tibial artery.
- P.**—Peroneal artery.
- Q.R.S.T.U.V.W.** refer to same parts as in Fig. 1.
- X.**—The astragalus.

PLATE 26.

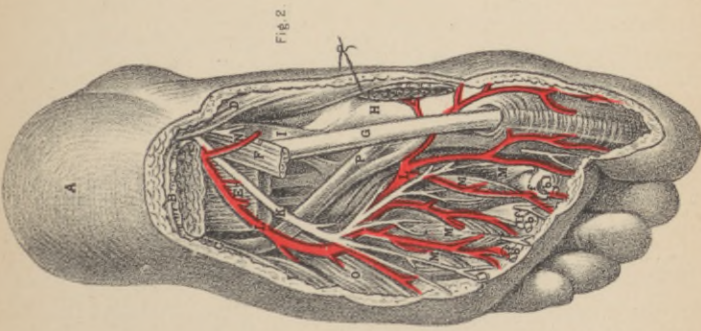
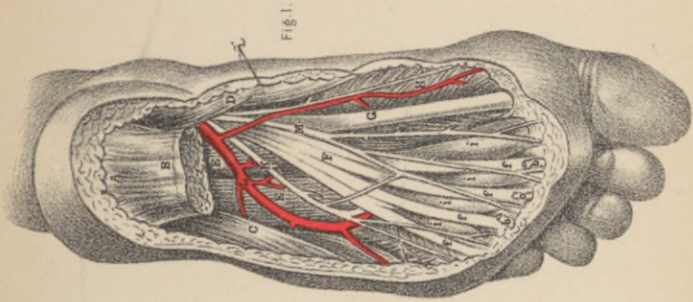
DISSECTION OF SOLE OF FOOT.

FIG. 1.

- A.—The calcaneum.
- B.—Plantar fascia, and flexor brevis digitorum muscle, cut; *b, b, b*, its tendons.
- C.—Abductor minimi digiti muscle.
- D.—Abductor pollicis muscle.
- E.—Flexor accessorius muscle.
- F.—Tendon of the flexor longus digitorum muscle, subdividing into *f, f, f, f*, tendons for the four outer toes.
- G.—Tendon of flexor pollicis longus muscle.
- H.—Flexor pollicis brevis muscle; *i, i, i, i*, the four lumbricales muscles.
- K.—External plantar nerve.
- L.—External plantar artery.
- M.—Internal plantar nerve and artery.

FIG. 2.

- A.—The heel covered by the integument.
- B.—Plantar fascia and flexor brevis digitorum muscle, cut; *b, b, b*, the tendons of the muscles.
- C.—Abductor minimi digiti.
- D.—Abductor pollicis.
- E.—Flexor accessorius, cut.
- F.—Tendon of the flexor digitorum longus, cut; *b, b, b*, its digital ends.
- G.—Tendon of the flexor pollicis.
- H.—Head of the first metatarsal bone.
- I.—Tendon of the tibialis posticus.
- K.—External plantar nerve.
- L.L.—The arch of the external plantar artery.
- M.M.M.M.—The four interosseous muscles.
- N.—External plantar nerve and artery, cut.



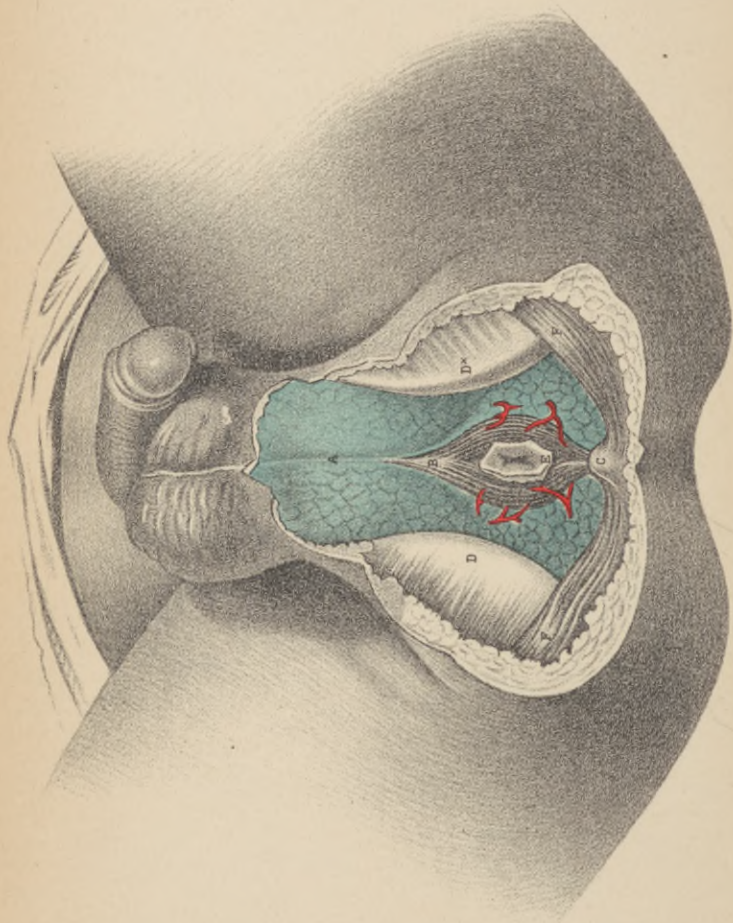


PLATE 27.

DISSECTION OF THE SUPERFICIAL STRUCTURES
OF THE MALE PERINÆUM.

- A.**—Superficial fascia, covering the urethral space
- B.**—The sphincter ani.
- C.**—The coccyx.
- D.D.***—The right and left ischiatic tuberosities.
- E.**—The anus.
- F.F.**—The glutei muscles.

PLATE 28.

DISSECTION OF THE DEEP STRUCTURES OF THE MALE PERINÆUM.

FIG. 1.

- A.**—The urethra.
- B.**—Accelerator urinæ muscle.
- C.**—Central perinæal tendon.
- D. D.**—Right and left erector penis muscle.
- E. E.**—The transverse muscles.
- F.**—The anus.
- G. G.**—The ischiatic tuberosities.
- H.**—The coccyx.
- I. I.**—The glutei muscles.
- K. K.**—Levator ani muscle.
- L.**—Left artery of the bulb.

FIG. 2.

- A. D. F. G. H. I. K. L.**, refer to same parts as in Fig. 1.
- B.**—The urethra.
- C.**—Cowper's glands, between the two layers of—
- E. E.**—The deep perinæal fascia.
- M.**—The bulb of the urethra.

Fig. 2.

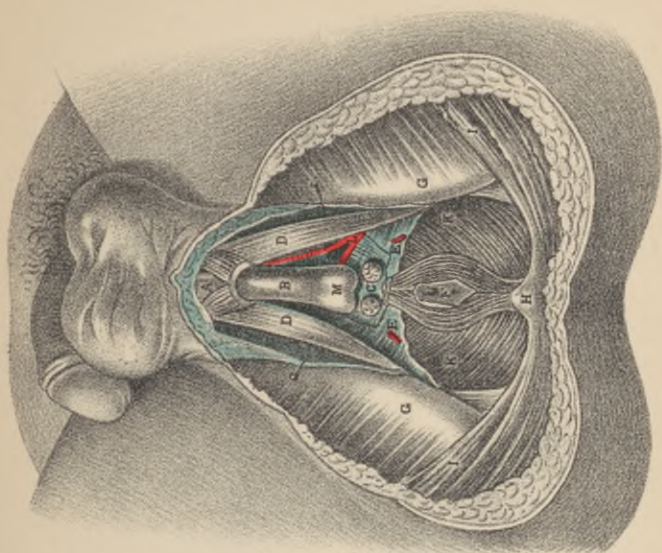
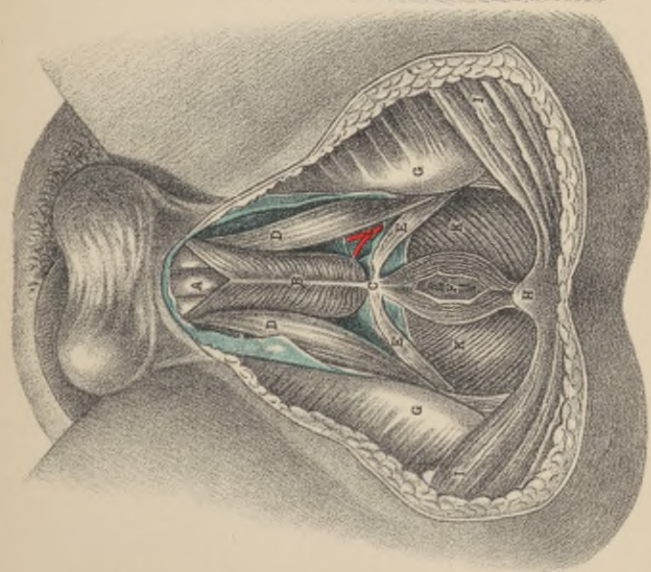



Fig. 1.





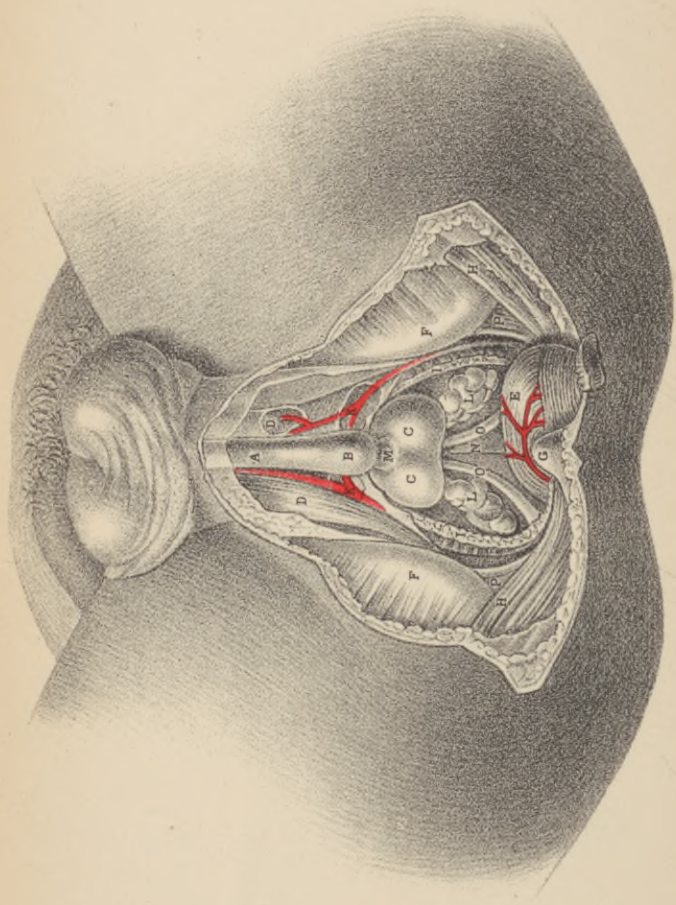


PLATE 29.

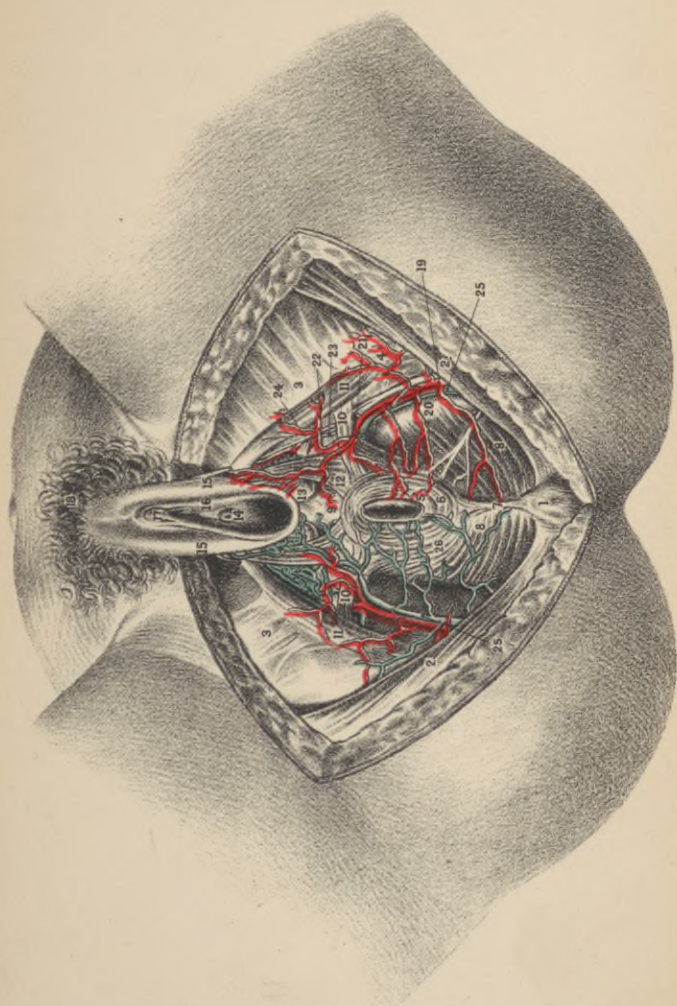
DISSECTION OF THE DEEP STRUCTURES OF THE
MALE PERINÆUM.

- A.B.**—The urethra.
C.C.—The two lobes of the prostate.
D.D.—The two crura penis.
E.—The rectum turned down.
F.—The ischiatic tuberosities.
G.—The coccyx.
H.H.—The glutei muscles.
I.I.—The levator ani muscle.
K.—The left artery of the bulb.
L.—The vesiculæ seminales.
M.—The membranous part of the urethra.
N.—The base of the bladder.
O.—The two vasa deferentia.
P.—The sacro-sciatic ligament.

PLATE 30.

FEMALE PERINEUM AND ISCHIO-RECTAL REGION.

- 1.—Coccyx.
- 2.—Gluteus maximus.
- 3.—Fascia lata, inserted into pubic arch.
- 4.—Tuberosity of ischium.
- 5.—Internal sphincter ani.
- 6.—External “ “
- 7.—Attachment of sphincter ani to coccyx.
- 8.—Levator ani, forming floor of ischio-rectal fossa.
- 9.—Perineum.
- 10.—Transversus peronei muscle.
- 11.—Erector clitoridis.
- 12.—Constrictor vaginae.
- 13.—Glands of Bartholini.
- 14.—Urethral opening.
- 15.—Labia majora.
- 16.— “ minora.
- 17.—Clitoris.
- 18.—Mons veneris.
- 19.—Internal pudic artery.
- 20.—External hemorrhoidal artery. (The three arteries of this name are shown, the middle one only being marked.)
- 21.—Superficial perineal artery. (Supplying anus, perineum, vaginal lips and erector clitoridis.)
- 22.—Transversus peronei artery.
- 23.—Deep branch of internal pudic artery.
- 24.—Artery of the bulb (arteria bulbosa).
- 25.—Internal pudic vein (common).
- 26.—External hemorrhoidal vein. (Other branches of the same vessel not marked).



ESSENTIALS OF HUMAN ANATOMY.

Give the derivation and meaning of the term anatomy.

From two Greek words, literally meaning dissection, but it is used to indicate the study of the physical structure of organized bodies.

How is human anatomy divided ?

Into two great divisions, viz.: 1. General or descriptive anatomy, which deals with the separate parts of the human body; and 2. Surgical or regional anatomy, which describes the relations individual parts, such as muscles, nerves, arteries, etc., bear to each other, in order to enable the surgeon to find or avoid important structures when operating.

What is osteology ?

A subdivision of general anatomy describing the number, form, structure, and uses of the bones.

What is the chemical composition of osseous tissue (bone)?

About one-third (33.30) is organic or animal matter, resolvable into gelatine after prolonged boiling, with traces of chondrigen (the proximate principle of cartilage), and two-thirds inorganic, or mineral, consisting of calcium phosphate (tribasic) 51.04, calcium carbonate 11.30, calcium fluoride 2, magnesium phosphate 1.16, and sodium chloride with traces of sodium dioxide 1.20. Either the organic or inorganic matter may be removed without affecting the form of the bone; the former by exposure to heat with free access of air, after which slight force will reduce the bone to powder; the latter by steeping in dilute hydrochloric acid, which will render a long bone as pliable as a strip of rubber.

Does an increase of the mineral constituents take place in old age; rendering the bones more brittle than in youth?

No; although this is the common statement in text-books, for while equal *bulks* of young and old bones do show marked differences in the proportion of earthy and animal constituents, equal *weights* do not, so that the elasticity in youth and the brittleness in age depend upon the greater sponginess of texture in young bones.

Is bone a homogeneous substance?

No; for while the exterior is composed of a *compact* (hard, ivory) layer, the inner portions are formed of *spongy* or *cancellous* tissue; while the interior of long bones is hollow, forming the medullary (marrow) canal. The compact tissue is used upon the exterior or in the shaft of long bones where "cross-strain" is greatest, whereas cancellous tissue enables the articular end of the bones to be large, for security, yet light, this tissue being capable of bearing enormous pressure without yielding, but incapable of bearing much "cross-strain."

Describe the microscopic structure of bone.

In transverse section, with a low power, a number of holes will be observed, averaging $\frac{1}{800}$ th inch in diameter, surrounded with a series of tolerably concentric circles, consisting of an interrupted series of dark spots. With high powers, the holes, called *Haversian canals* for the passage of vessels, are seen to be surrounded by a series of concentric lines, termed lamellæ, while the dark spots reveal themselves as cavities in the bone, called *lacunæ*, intercommunicating with each other and the central Haversian canal, by means of delicate radiating hollow tubes, called *canaliculi*: this aggregation of structures is called an *Haversian system*. The lacunæ contain bone corpuscles, processes of which extend into the *canaliculi*. As each Haversian system communicates by its canaliculi with those of its neighbor, the exterior of the bone, all portions of its most compact tissue and the medullary canal freely intercommunicate and receive nutrient material. As these systems are circular they would leave interspaces where not in contact;

but these gaps are filled up by layers of bone with *lamellæ* and *canaliculi*, these portions being called *interstitial lamellæ*. In addition to the *concentric lamellæ* around the Haversian canals, an examination of a cross-section of a bone long exposed to atmospheric influences will show that it is composed of a series of circumferential *fundamental lamellæ* running around the whole circumference of the bone.

What is the periosteum?

It is a fibrous membrane serving as a scaffolding to enable the bloodvessels to reach all portions of the exterior of the bone except its articular ends and the points of attachment of strong tendons, the layer in contact with the bone containing many *osteoblasts* or bone-forming cells upon which the growth in thickness of the bone depends.

What is the endosteum?

This term is applied to the delicate connective tissue lining of the medullary and cancellous tissues which contains numerous bone-forming cells (*osteoblasts*).

Describe the medulla or marrow.

There are two varieties. In adult bones—except the cancellous tissue of their articular extremities, that of the vertebral bodies, the sternum, ribs, and cranial bones—the marrow is *yellow*, consisting almost solely of fat (adipose) tissue (ninety-six per cent.). In the other situations just mentioned the marrow is *red* (fœtal), contains not more than one per cent. of fat, and numerous oval, many-nucleated cells (*myeloplaxes*). This kind of marrow is that found in the fœtus and infants.

Do bones receive blood only from vessels in the periosteum?

No, for the medullary tissue of all long bones receives a good-sized artery (the nutrient artery), which obliquely penetrates the compact tissue, after which it divides into two main branches, one ascending the other descending in the medullary canal; the veins chiefly emerge through numerous openings near the articular ends of the bones.

Describe the process of ossification.

There are two methods, viz., the *membranous* and the *cartilaginous*. In the former, at the centre of ossification of a parietal bone for instance, the bone-forming cells (*osteoblasts*) arrange themselves—about the second month of intrauterine life—along the thick bundles of fibrous tissue which radiate from the centre of the future bone; by the deposition of lime-salts in these osteoblasts, the deposit of bone shoots out in needle-like rays toward the circumference. Ossification by cartilage is essentially similar; for *protection of vital centres*, as at the base of the skull, or to maintain *rigidity of parts and proper tension of muscles*, as in the extremities, certain bones are laid down in cartilage. Just before ossification commences the cartilage cells multiply, arrange themselves in columns—especially at the epiphyseal ends—and the intercellular material becomes infiltrated with lime-salts. Now ossification proper commences by the ingrowth from the periosteum of buds of young connective tissue covered with bone-forming cells, which, after causing absorption of the cartilage, become converted into bone. The first bones to ossify are 1, the clavicle; 2, the inferior maxilla (fifth to seventh foetal week).

Of how many bones is the adult human skeleton composed?

Two hundred, including the os hyoides, but excluding the teeth, Wormian bones, all sesamoid bones, except the patellæ, and the ossicles of the middle ear.

Into what classes are bones divided, and give a few instances of each?

Long bones, as femur, tibia; *flat*, as those of the vault of the skull, scapula; *irregular*, as the vertebræ; and *short*, such as the carpal or tarsal bones.

What are Wormian bones?

Irregular fragments, developed from supplementary centres, situated at the junction of two or more cranial sutures, where, during infancy, a membranous interval existed, viz., a *fontanelle*. From their triangular form they are often called *ossa triquetra*.

What are sesamoid bones ?

Those developed in the substance of tendons, whereby the muscles obtain additional *leverage*—*i. e.*, *power*; the patellæ are, by some, classed with these bones.

Of what parts do long bones consist, and what are their uses ?

Of a shaft (body, diaphysis), two articular extremities, and various processes; they are developed in cartilage, from one principal, and one or more additional (epiphyseal) centres of ossification; they serve as supports and levers for power and progression.

Where are short bones employed, and why ?

In the carpus and tarsus, where strength with limited motion is required. They ossify in cartilage.

Describe the structure and uses of flat bones.

They consist of two layers of compact tissue with interposed cancellous tissue, called *diploë*; they serve to protect important viscera, as brain, etc., and afford extended surfaces for origin of muscles; for the most part, they ossify in membrane.

How are bony prominences named ?

Processes, and are described as *articular* and *non-articular*.

Give the names and characteristics of the chief articular processes.

Head, a convex smooth projection, with a constriction or neck beneath; found in freely moving joints.

Condyles, double projecting processes, may have a constriction or neck—*i. e.*, neck of condyle of jaw.

Trochanters, short projecting levers near articulations to facilitate rotation of the bone on its long axis.

Tuberosties, roughened, broad prominences.

Tubercles, similar to the above, but small with reference to the size of the bone.

Spines and spinous processes, more or less pointed projections.

Apophysis, strictly speaking, any bony process which develops from the primary centre of ossification, commonly used, however,

for any process, even if an epiphysis, *after* it has coössified with the mass of the bone.

What is a diaphysis ?

The main portion of a bone (shaft in a long bone, body in an irregular one) between the *epiphyses*.

What is an epiphysis ?

A supplementary centre, usually to provide for growth in *length*, developed in cartilage, which remains separated by a layer of *epiphyseal cartilage* until the growth of the bone is completed, when it coössifies with the *diaphysis*, and all further growth ceases. Epiphyseal centres appear after birth: they coössify in the inverse order of their appearance, except that of the lower end of the fibula. This process of coössification commences about puberty, and the last to unite are those of the upper end of the tibia and the vertebral bodies—as late as twenty-five years.

Mention some of the non-articular processes, with their meaning.

Azygos, without a fellow; *coronoid*, or *coracoid*, like a crow's beak; *mastoid*, like a nipple; *rostrum*, a beak; *styloid*, pen-like; *squamous*, scaly; *vaginal*, ensheathing.

Name some of the articular cavities of bone.

Cotyloid, when they resemble a deep cup; *glenoid*, when they have a shallow-cup form; *trochlear*, pulley-like; *facet*, when smooth, like one of the surfaces of a cut gem; *sigmoid*, when curved in two opposite directions.

What are the principal non-articular cavities called ?

Fossæ, shallow depressions; *sinuses*, deep cavities, communicating with the exterior by small openings; *grooves*, long narrow depressions; *fissures*, cracks; *notches*, deficiencies of edges of bones; *foramina*, holes through bones for transmission of nerves, etc.

BONES OF THE HEAD.

Name the bones composing the head.

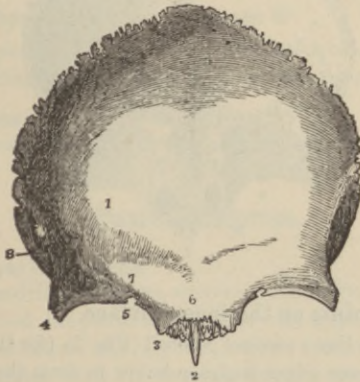
They are twenty-two in number: eight of which (*cranial*) compose the brain-case, viz., one frontal, two parietal, two temporal, one sphenoid, one occipital, and one ethmoid; fourteen are *facial*: two superior maxillary, two malar, two nasal, two lachrymal, two palate, two inferior turbinated, one vomer, and one inferior maxillary; the *ethmoid* also enters largely into the formation of the nasal cavities.

The Frontal Bone.

Of what parts does this bone consist?

Of a vertical and horizontal portion.

FIG. 1.

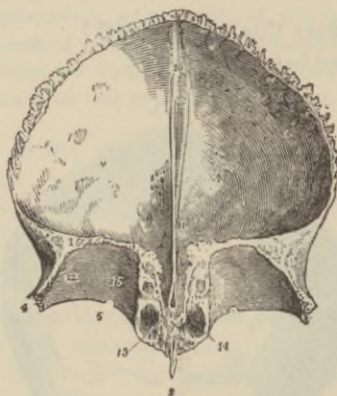


Describe the points on the outer surface of the vertical portion.

On each side of the median line are two *frontal eminences*¹, between which are the remains of, or the completely obliterated, *inter-frontal suture*, leaving a slight linear *depression*, which, above the root of

the nose, terminates in a rounded, projecting *nasal eminence*⁶. Extending outward from this on each side are two curved, rounded *superciliary ridges*⁷, situated beneath which, between the two tables of the skull, lie the *frontal sinuses*¹⁴ (Fig. 2). The junction of the vertical and horizontal portions forms on each side a curved margin, the *supra orbital arch*³⁻⁴, notched or perforated toward its inner part by the *supra-orbital notch*⁵, or *foramen*, transmitting the artery, vein, and nerve of the same name. Each orbital margin terminates by two stout processes, called *internal angular*³ and *external angular*⁴ processes. Between the inner projects the *nasal spine*², in the rough, uneven space, called the *nasal notch*; the margin of the external angular process extends upward as a *temporal ridge*⁸ (Fig. 1).

FIG. 2.



Describe the points on the inner surface.

In the median line a *vertical groove*¹⁰ (Fig. 2) (for the longitudinal sinus) exists, whose edges coalesce below to form the *frontal crest*¹¹, which terminates as a notch, or perhaps complete *foramen cæcum*¹³, which when pervious transmits a small vein.

Describe the horizontal portion.

This consists of two *orbital plates*¹² of a triangular outline, separated by a quadrilateral *ethmoidal notch* (for articulation with

that bone). A shallow *lachrymal*¹² depression (for gland) exists at the outer part of the orbit, also a smaller one or sometimes a small *tubercle*¹⁵ at the anterior inner part for the pulley of the superior oblique muscle. Several half cells are seen along the margins of the ethmoidal notch, which complete the ethmoidal cells when the ethmoid is in position, as well as two *grooves*, which are likewise converted into the *anterior* and *posterior ethmoidal canals*, the former for the nasal nerve and anterior ethmoidal vessels, the latter for the posterior ethmoidal vessels. On each side of the nasal spine open the *frontal sinuses*¹⁴ (absent in children), a part of the nasal cavities, into which they open by the *infundibulum*. The inner surfaces of both vertical and horizontal portions present numerous depressions for the convolutions of the brain, and branching grooves for the anterior meningeal artery.

What centres of ossification has this bone ?

Two, near the orbital arches, in membrane, seventh or eighth fetal week.

With what bones does it articulate ?

With two parietal, the sphenoid, the ethmoid, two nasal, two superior maxillary, two lachrymal, and two malar—twelve in all.

What muscles arise from it ?

The corrugator supercillii, orbicularis palpebrarum, and temporal, on each side.

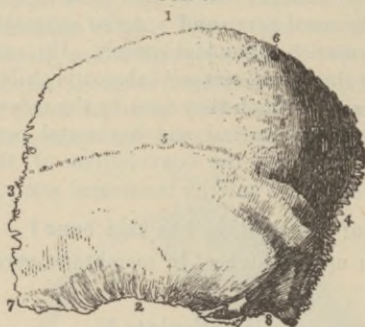
Parietal Bones.

Describe a parietal bone.

It is of a quadrilateral form, convex externally, the most prominent point called the *parietal eminence*. Its upper serrated border forms with its fellow the *sagittal suture*¹; the anterior serrated margin articulates with the frontal, forming part of the *coronal suture*²; its anterior inferior angle⁷, more prolonged than the others, articulates inferiorly with the sphenoid (*spheno-parietal suture*); the remainder of the inferior border², bevel-edged, is overlapped by the squamous plate of the temporal (*squamo-parietal suture*); the posterior serrated border⁴ articulates with the occipital (*occipito-parietal part of lambdoid suture*); while the posterior

inferior angle⁸ joins the mastoid process of the temporal (*masto-parietal suture*). Crossing the middle of the bone, from before backward, is a curved line, the *temporal ridge*⁵, and near the posterior superior angle is often a *parietal foramen*⁶ transmitting a small vein to the superior longitudinal sinus (sometimes a small branch of the occipital artery).

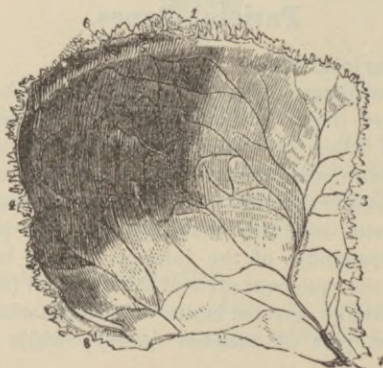FIG. 3.



Describe the internal surface.

This is concave, marked with numerous smooth *digital depressions* for the brain convolutions, with a shallow *half groove*⁵ (Fig. 4) along the superior border for the superior longitudinal sinus, and

FIG. 4.



several *Pacchionian depressions*. At the anterior inferior angle a deep *groove*, branching in various directions, sometimes converted into a foramen, is found⁷, for the middle meningeal artery, and at the posterior inferior angle a broad well-marked *groove*⁸ for part of the lateral sinus.

How is it developed?

In membrane, from one centre at the eminence appearing at the fifth to sixth foetal week.

Give muscular attachments, and articulations.

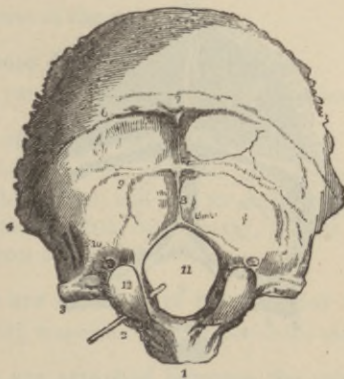
Temporal muscle: articulates with five bones, parietal, occipital, temporal, frontal, and sphenoid.

Occipital Bone.

Of what parts does this bone consist?

Of a curved plate of trapezoidal form, whose anterior blunted angle forms the *basilar process*¹ (Fig. 5), and two lateral *jugular pro-*

FIG. 5.



*cesses*³, arising opposite the two *articular processes* called *condyles*¹², which lie on either side of a large opening, the *foramen magnum*¹¹; the long axes of the *condyles*¹² converge toward each other from behind forward and inward.

What points should be noted on the external convex surface?

Midway between the summit and margin of the foramen magnum the prominent *external occipital protuberance*⁷ for attachment of the ligamentum nuchæ; a median *crest*⁸ extending from this to the margin of the foramen magnum; a pair of *superior curved lines*⁶ extending from the protuberance toward the lateral angles of the bone; a second pair of parallel *inferior curved lines*⁹, starting about midway along the crest.

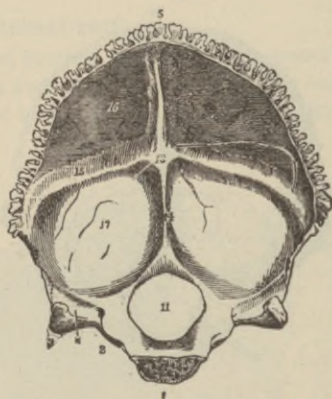
Describe the condyles.

They are two kidney-shaped convex articular surfaces on each side of the foramen magnum, having on their inner sides a rough *tubercle* for the check ligaments.

What foramina are situated near them?

The *anterior condyloid*² (constant) for the hypoglossal nerves, and *posterior condyloid foramina*¹⁰ (inconstant) for a small vein.

FIG. 6.



Describe the basilar process.

A strong quadrilateral plate in front of the foramen magnum with a median tubercular ridge-like *pharyngeal spine*. Its cerebral

surface is smoothly *grooved* longitudinally for the medulla oblongata. At its junction with the jugular processes are the deep jugular *notches* forming part of each *jugular foramen* (foramen lacerum posterius).

Describe the cerebral surface of the bone.

It is deeply concave, divided into *four fossæ*^{16,17} by a *crucial grooved ridge*^{13,14,15}, crossing at a prominent *internal occipital protuberance*¹³; the two lateral and superior grooves lodge, respectively, between the layers of the tentorium cerebelli and the falx cerebri, the lateral, and part of the superior longitudinal sinuses; the inferior groove, or *internal occipital crest*¹⁴, has attached the *falx cerebelli*, and lodges in two grooves, the *occipital sinuses*. The upper surfaces of the jugular processes are deeply *grooved** for the lateral sinuses.

What do the upper two fossæ lodge?

The posterior lobes of the cerebrum.

What do the lower fossæ accommodate?

The hemispheres of the cerebellum.

With what bones does it articulate?

Two parietal, two temporal, sphenoid, and atlas; six in all.

What centres of ossification has it?

One in membrane, at the occipital protuberance (eighth foetal week), one for the basilar, and one for each condyloid portion in cartilage (seventh or eighth foetal week): in four pieces at birth; in sixth year forms one bone.

What muscles are attached to the superior curved line?

Occipito-frontal, trapezius, and sterno-cleido-mastoid.

What muscles are attached between the curved lines?

Complexus and splenius capitis.

What muscles are attached below the inferior curved line?

Rectus capitis posticus major and minor, obliquus superior.

What muscles are attached to the basilar process ?

The superior constrictor of the pharynx, the rectus capitis anticus major and minor.

What muscle is attached to the jugular process ?

The rectus capitis lateralis.

The Sphenoid Bone.**What are its divisions and where is it situated ?**

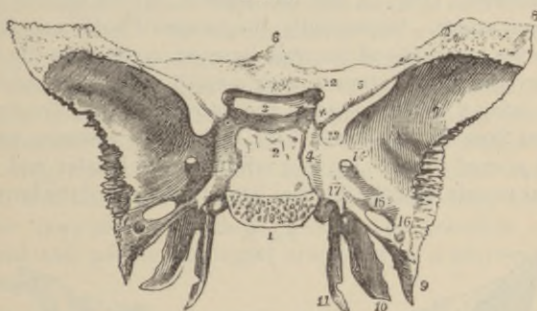
A *body*², two *lesser wings*⁷, two *greater wings*, two *pterygoid plates*, two *spinous processes*¹⁰⁻¹¹, six *clinoid processes*, and three *minor prominences*; it is situated at the base of the cranium articulating with all the cranial bones, and many of the face. Named from a Greek word meaning *wedge*, in the process of development this is its function, serving to enlarge the cranial, nasal, orbital, and oral cavities at puberty.

Describe the body of the sphenoid.

It is large, cuboidal, hollowed out (in adult) into the *sphenoidal sinuses*²⁰ (Fig. 8). Superiorly, in front, is a sharp projecting *ethmoidal spine*⁶ for the ethmoid; behind this, a smooth surface with a longitudinal eminence producing two shallow *olfactory grooves* on either side, bounding which behind is a transverse *optic groove*³ (Fig. 7), lodging the commissure of the optic nerves, terminating in two *optic foramina*¹² (Fig. 7) for the optic nerves and ophthalmic arteries. Behind the groove is the projecting *olivary process*³ (Fig. 7) forming the anterior boundary of a marked depression, the *sella turcica*³ (Fig. 7), lodging the pituitary gland and circular sinus. On each side, in front, are two small projecting *middle clinoid processes*, while behind is a square-shaped projecting plate terminating at either angle by the tubercular *posterior clinoid processes*, and to them are attached portions of the tentorium cerebelli. The sides of this bony plate are *notched* for the sixth pair of nerves, and the superior surface, or *dorsum*² (Fig. 7), with a broad shallow depression, slopes obliquely downward and backward, becoming continuous with the basilar portion of the occipital bone; it supports the pons Varolii. A broad *cavernous groove*⁴ (Fig. 7) for the carotid artery and cavern-

ous sinus exists on either side of the body. The *posterior*¹ (Fig. 7) rough quadrilateral surface articulates with the basilar portion of the occipital bone, coëssifying from the eighteenth to twenty-fifth year.

FIG. 7.



A vertical plate, the *rostrum*^{21,22} (Fig. 8), projects from the *inferior surface* of the body forming part of the nasal septum, having the irregular openings of the *sphenoidal sinuses*²⁰ on either side (absent in child), which open either into the posterior ethmoidal cells or directly into the nasal cavities. Two thin-curved *sphenoidal turbinated*²⁰ bones narrow these orifices to a round opening at their upper part; these plates articulate with the palate and ethmoid bones.

The *inferior surface* presents a continuation of the *rostrum* for the vomer, having on either side a thin plate, the *vaginal process*²², under which slips the alæ of the vomer, and the *pterygo-palatine grooves*, which by articulation with the sphenoidal processes of the palate bones are converted into the *pterygo-palatine canals* for the arteries and nerves of the same name.

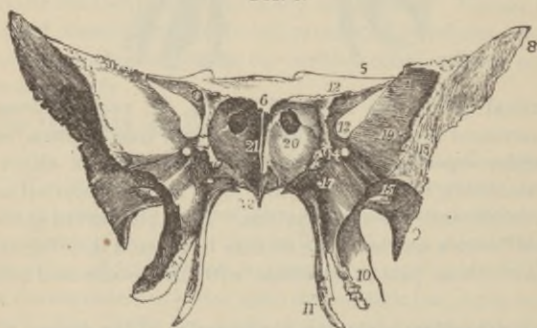Describe the greater wings.

Two strong processes arising from the sides of the body, curving upward, outward, and backward. The concave *cerebral surface*¹⁴ of each wing forms part of the middle fossæ of the skull, presenting a circular opening at its antero-internal part, the *foramen rotundum*¹⁴ for the second branch (sup. maxillary) of the fifth pair of nerves; a second larger ovoidal foramen, the *foramen ovale*¹⁵ (Figs. 7 and 8),

transmitting the third (inf. maxillary) division of the same nerve (sometimes the small petrosal nerve and small meningeal artery), while piercing the sharp, pointed, posterior extremity of the wing, or *spinous process*, is seen a short canal (sometimes double), the *foramen spinosum*¹⁶ (Fig. 7), for the passage of the middle (great) meningeal artery. Occasionally, the *foramen Vesalii*, a small aperture to the inner side of the oval foramen, opposite to the root of the pterygoid process, transmitting a small vein, is detectable.

The *external surface* presents the *pterygoid ridge* dividing the temporal from the zygomatic fossa, and at its posterior part the *spinous process*⁹ (Fig. 8), giving origin to the laxator and tensor tympani muscle, and the internal lateral ligament of the lower jaw.

FIG. 8.



The *anterior* or *orbital surface*, smooth, quadrilateral, forming part of the outer orbital wall, bounded above by a serrated edge for articulation with the frontal, below by a rounded border which enters into the formation of the *spheno-maxillary fissure*, internally aiding in the formation of the *sphenoidal fissure*¹³, presents a serrated articular margin for the malar bone, and has a *notch* at the upper part of the inner border for a branch of the ophthalmic artery, a small *spine* at its lower part, for part of the origin of the external rectus muscle, and (at times) one or more *external orbital foramina*. The *circumference* has been described above.

Describe the lesser wings.

These⁵ (processes of Ingrassias) two thin, triangular processes each arise from the upper and lateral parts of the body, project

transversely outward, to terminate internally in the *anterior clinoid process*^x (Fig. 7), externally in a sharp point. By their anterior borders they articulate with the orbital plates of the frontal bone, while by their posterior free margin they divide the anterior from the middle cerebral fossæ. Between their roots on each side is the *optic foramen*¹² (Fig. 7) for the optic nerve and ophthalmic artery. Their inferior surface forms on either side the back part of the orbital roof, and the upper boundary of the *sphenoidal fissure*¹³ (Fig. 7), or foramen lacerum anterius, which is bounded internally by the sphenoid body, and inferiorly by the orbital margin of the greater wing, transmitting the third, fourth, ophthalmic branch of the fifth and sixth nerves, with the ophthalmic vein, filaments from the cavernous sympathetic plexus, also branches of the lachrymal and middle meningeal arteries, with a process of the dura mater.

Describe the pterygoid processes.

These, consisting of an *internal*¹¹ and *external*¹⁰ plate separated behind by a notch—the *pterygoid fossa*—descend on each side perpendicularly from the junction of the greater wing with the body. At the base of the internal plate is the *scaphoid fossa*, giving origin to the tensor palati muscle, above which is the orifice of the *Vidian canal*¹⁷; this plate terminates by a curved *hamular process*¹¹, around which plays the tendon of the tensor palati muscle. The external pterygoid plate, forming part of the inner wall of the zygomatic fossa, has arising from its inner surface the internal pterygoid, and from its outer the external pterygoid muscle. The *triangular notch* below has fitting into it the tuberosity of the palate bone.

Name the bones with which the sphenoid articulates.

The other seven cranial bones and five facial, viz., the two palate, two malar, and vomer.

By how many centres of ossification is this bone developed?

By fourteen centres: two for the internal pterygoid plates in *membrane*, two for the greater wings and external pterygoid plates, two for the lesser wings, two for the anterior part of the body, two for the sphenoidal turbinated bones, two for the posterior part of the body, two for the *lingula*, i. e., posterior part of the outer

margin of the cavernous groove, appearing from the second foetal month to the third year in *cartilage*. From the tenth to the twelfth year the parts are all ossified, except a portion of the sphenoidal turbinates, which completely unite by the twentieth year.

What muscles have their origin from the sphenoid bone ?

The temporal, external and internal pterygoids, superior pharyngeal constrictor, tensor palati, laxator tympani, levator palpebræ, obliquus superior, superior, internal, external, and inferior recti.

The Temporal Bones.

Where are they situated ?

At the sides and base of the skull.

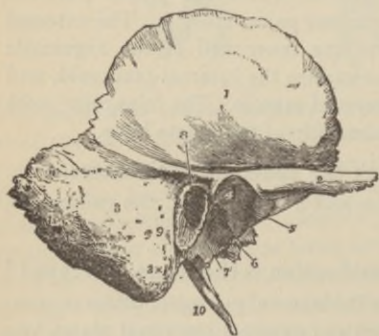What parts does each bone present for examination ?

A *squamous* (scale-like), a *mastoid* (nipple-like), and a *petrous* (stony hard) portion.

Describe the squamous portion.

The main portion is an irregularly semi-circular, smooth plate,¹ grooved posteriorly for the deep temporal arteries, convex externally,

FIG. 9.



and here grooved for the middle meningeal artery, with *digital depressions* for the cerebral convolutions. Posteriorly, a curved ridge (part of temporal) is seen. Springing from its lower part is the long, twisted, arched *zygomatic process*², arising by three roots, viz., a posterior, forming part of the temporal ridge, one running directly inward in front of the glenoid

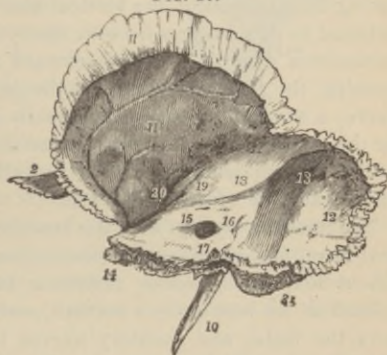fossa, convex, covered with cartilage, forming the *eminentia articularis*⁵, and a middle, the outer margin of the *glenoid fossa*⁴, the

obliquely transverse, ovoidal socket for the condyle of the lower jaw, divided into two parts by the *Glaserian fissure*⁶ (Fig. 11), which transmits the laxator tympani muscle, the tympanic artery, and lodges the processus gracilis of the malleus: part of the parotid gland occupies that portion posterior to the fissure. Parallel to this fissure, in the retiring angle between the squamous and petrous portions, is the opening of the *canal of Huguier* for the chorda tympani nerve. At the junction of the articular eminence with the zygomatic process is the *zygomatic tubercle* for the external lateral ligament of the lower jaw.

Describe the mastoid portion.

This projects³, rough, and perforated by numerous foramina (one large—the *mastoid foramen*⁹—transmits a vein to the lateral sinus, and a small artery), from the postero-inferior portion of the bone. The interior portion of the bone contains the *mastoid cells*, lined with mucous membrane continuous with that of the tympanum. The conical tip is termed the *mastoid process*^{3x}, upon whose inner side a deep grooved *digastric fossa*²⁶

FIG. 10.



(Fig. 11) exists for the digastric muscle, while parallel, but more internal, lies the *occipital groove*²⁷ (Fig. 11), lodging the artery of the same name. A deep, curved *groove*¹³ (Fig. 10) exists on the inner surface of the mastoid portion for part of the lateral sinus, in which can be seen the inner orifice of the mastoid foramen.

Describe the petrous portion.

This is a dense, pyramidal mass, wedged in between the sphenoid and occipital bones, containing the organs of hearing. Its long axis is directed from without inward, forward, and a little down-

ward. Its apex, three surfaces, and three borders must be studied. The *apex*¹⁴ (Fig. 10) lies in the angle formed by the posterior border of the greater sphenoidal wing and the basilar process of the occipital, forms the posterior and external boundary of the foramen lacerum medium, and presents the internal orifice of the carotid canal.

The *base*, its upper half covered by the squamous and mastoid portions, presents the oval, expanded orifice of the *meatus auditorius externus*⁸, its upper margin smooth, but surrounded for the greater part of its circumference by the rough-edged (for the cartilage of the external ear), curved plate of bone called the *auditory process*⁸.

The *anterior surface* forming the posterior part of the middle cerebral fossa, presents an *eminence*¹⁹ (Fig. 10) near the centre indicating the situation of the vertical semi-circular canal of the ear; external to this a *depression* over the tympanum; a shallow groove (sometimes double) leading backward and outward to an oblique opening, the *hiatus Fallopii*²⁰, for the petrosal branch of the Vidian nerve; a smaller opening (occasionally seen external to the latter) for the smaller petrosal nerve; the termination of the *carotid canal*¹⁴ near the apex; above this canal a shallow *depression* for the Gasserian ganglion of the fifth nerve.

The *posterior surface* forms the anterior part of the posterior cerebral fossa, presents about its centre the large orifice of the short (about four lines) *meatus auditorius internus*¹⁵ directed outward (closed at its bottom by a vertical perforated plate), which transmits the facial and auditory nerves (seventh and eighth pairs cranial), the auditory artery, and is lined by the dura mater; behind the meatus is a small slit leading to the *aquæductus vestibuli*¹⁶, transmitting a small artery and vein, and lodging a process of the dura mater.

The *inferior* (basilar) *surface*, from apex to base, presents a rough quadrilateral surface for the origin of the tensor tympani and levator palati muscles; the circular orifice of the *carotid canal*²² (Fig. 11) ascending vertically, then abruptly passing horizontally forward and inward for the passage of the internal carotid artery with its sympathetic nerve plexus; to the inner side of this—a small, triangular opening, the *aquæductus cochleæ*¹⁷, transmit-

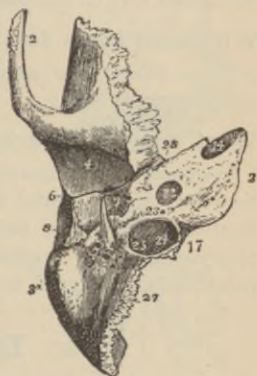
ting a vein from the cochlea to the internal jugular; behind these openings a deep depression, the *jugular fossa*²⁴ (Fig. 11), which lodges the lateral sinus, and, with the jugular notch of the occipital bone, forms the *foramen lacerum posterius*, transmitting the jugular vein and eighth pair of cranial nerves; a small *foramen for Jacobson's nerve*²³ in front of the bony ridge separating the carotid canal from the jugular fossa; on the outer wall of the jugular fossa a small *foramen for Arnold's nerve*²⁵; posterior to the jugular fossa, a square-shaped, smooth facet (covered in the fresh state with cartilage), for articulation with the jugular process of the occipital; a broad, sheath-like, bony plate extending from the carotid canal to the mastoid process, the *vaginal process*⁷, which splitting into two laminae, encloses the base of a long, sharp spine, the *styloid process*¹⁰ (Figs. 10 and 11), from which arise the stylo-pharyngeus, stylo-glossus, and stylo-hyoideus muscles, and the stylo-hyoid and stylo-maxillary ligaments; between this process and the mastoid, a large orifice, the *stylo-mastoid*²⁶ foramen, for the exit of the facial nerve, and the entrance of the stylo-mastoid artery; and, finally, between the vaginal and mastoid processes, the *auricular fissure* for the exit of Arnold's nerve.

At the angle formed by the junction of the petrous and squamous portions, two *canals*²⁸ exist, separated by a thin, bony septum, the *processus cochleariformis*, the upper lodging the tensor tympani muscle, the lower being the bony *Eustachian tube*²⁸.

What additional points of interest do the borders present?

The *superior* is *grooved* for the superior petrosal sinus, and has attached to it the tentorium cerebelli; the *posterior* has a *half-groove* which, with another on the occipital, accommodates the inferior petrosal sinus.

FIG. 11.



From how many centres is this bone developed ?

From ten: one for the squamous and zygoma (in membrane), four for the petrous, two for the mastoid, two for the styloid, and one for the auditory process (all latter in cartilage), from eighth fetal week to sixth fetal month—bone coössifies during first year, except the styloid process.

With what bones does each temporal articulate ?

The occipital, one parietal, sphenoid, one malar, and the inferior maxillary.

What muscular attachments has it ?

Squamous, the temporal; *zygoma*, the masseter; the *mastoid portion*, the occipito-frontal, sterno-mastoid, splenius capitis, trachelo-mastoid, digastricus, and retrahens aurem. *Styloid*, the stylo-pharyngeus, stylo-hyoideus, stylo-glossus. *Petrous*, the levator palati, tensor tympani, tensor palati, and stapedius.

Ethmoid Bone.**Of what parts does this bone consist ?**

Of a *horizontal cribriform plate*³ (sieve-like, whence name), of two *lateral masses*¹⁰ of cells depending from this on either side, between which lies the *perpendicular plate*² forming part of the septum of the nose; the whole bone is of a cuboidal form.

Describe the cribriform plate.

Springing from the upper surface is the *crusta galli*¹ (cock's-comb), a vertical plate running from before backward, whose anterior border is notched to complete the foramen cæcum of the frontal bone. Two deep, longitudinal *olfactory grooves*, for the olfactory bulbs, lie on either side, their bottoms perforated by three rows of small foramina for filaments of the olfactory nerves, and on each side in front is a small slit for the nasal branch of the ophthalmic nerve; the crest gives attachment to the falx cerebri.

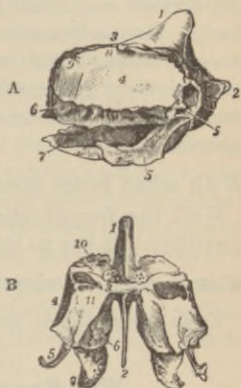
Describe the perpendicular plate.

It is thin, usually deflected to one or other side, forms part of the nasal septum, and has upon each side numerous grooves and canals to accommodate the olfactory nerve filaments.

Of what are the lateral masses formed?

Of thin-walled cavities, the *ethmoidal cells*, whose outer limits are the vertical *orbital*⁴ plates, while their inner walls form part of the nasal fossæ; above they are *grooved* to form with grooves on the frontal the two ethmoidal foramina. The upper outer margins of each mass present a number of half-cells completely closed in when articulated with the ethmoid notch of the frontal bone; posteriorly are also half-cells completed by the sphenoidal turbinated and palate bones; again, in front and below, the cells are completed by the lachrymal and superior maxillary bones; inferiorly an irregular hook-like plate projects, the *unciform process*⁵, which closes in the upper part of the orifice of the antrum. A narrow oblique fissure, the *superior nasal meatus*, subdivides the inner surface, bounded above by the thin-curved *superior turbinated bone*⁶, below by the convex scroll-like *middle turbinated bone*⁷; the *posterior cells* open into the upper part of this fissure, the *anterior* into the frontal sinus above, and below by the flexuous *infundibulum* they communicate with the *middle nasal meatus*, which is bounded above by the middle turbinated bone.

FIG. 12.



How many centres of ossification has this bone?

Three; one for each lateral mass (fourth to fifth foetal month), one for the perpendicular and cribriform plates in *cartilage* during the first year; the ethmoidal cells, completing the bone, form about the fourth or fifth year.

With how many bones does it articulate?

Fifteen: the sphenoid, two sphenoidal turbinated, frontal, two nasal, two superior maxillary, two lachrymal, two palate, two inferior turbinated, and the vomer.

Nasal Bones.

Describe them.

They are of oblong form, their *outer* surfaces concave from above downward, convex from side to side, marked by many small arterial furrows and usually presenting at their centres a single or double venous foramen. Their *inner* surfaces are convex from above downward and concave from side to side, traversed longitudinally by a *groove*, sometimes a *canal*, for a branch of the nasal nerve which escapes by a notch about the middle of the lower thin margin.

With what bones does each nasal articulate ?

With the frontal, ethmoid, its fellow nasal, and the superior maxillary. It has no muscular attachments.

How is each developed ?

From one centre in membrane (eighth foetal week).

The Superior Maxillary Bones.

Describe them.

They each consist of a hollow body and four processes ; together they form the whole upper jaw.

Describe the body.

It is cuboidal in form and hollowed out into a pyramidal cavity, the *antrum of Highmore*¹¹ (Fig. 14). Of its four *surfaces*, the *external* (facial), directed forward and outward, presents, just above the incisor teeth, the *incisive* (myrtiform) *fossa*⁷ (Fig. 13), more externally the larger *canine fossa*⁸ (Fig. 13), separated from the former by the *canine eminence* formed by the socket of the canine tooth ; above this the *infra-orbital foramen*⁹ (Fig. 13) giving egress to the infra-orbital artery and nerve, and, above all, the *margin of the orbit*.

The *posterior surface* is convex, forms part of the zygomatic fossa, has about its centre several apertures of the *posterior dental canals* for the dental vessels and nerves ; at its lower part (especially after the wisdom tooth is formed) is a rounded eminence, the *maxillary*

*tuberosity*² (Fig. 13), which articulates by its rough inner surface with the tuberosity of the palate bone; and just above the rough surface is an oblique *groove* running down on the inner side, which by the apposition of the palate bone forms the *posterior palatine canal*¹⁵ (Fig. 14).

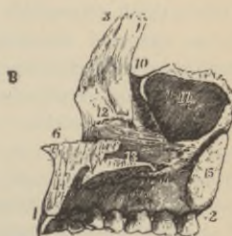
The *superior* (orbital plate) *surface*⁵, thin, smooth, and triangular, forms part of the floor of the orbit, articulates internally by an irregular margin (from behind forward) with the palate bone, os planum of the ethmoid and lachrymal; externally, by its smooth, rounded edge, it helps to form the sphenomaxillary fissure (sometimes articulating in front with the orbital plate of the sphenoid), and in front, part of the orbital margin. Commencing at the middle of the outer border of this surface is the deep *infra-orbital groove*⁵ (Fig. 13), which in front becomes a *canal* of the same name, opening by the infra-orbital foramen; a small canal branching from this passes into the substance of the anterior wall of the antrum—the *anterior dental canal*; at the inner forepart of this orbital surface is a minute *depression* for the origin of the inferior oblique muscle of the eye.

The *internal surface*, unequally divided horizontally into two parts by the *palate process*¹² (Fig. 14), forms above this, part of the outer wall of the nasal fossæ; below, a portion of the cavity of the mouth. The nasal surface presents a large irregular opening into the antrum, above which are irregular cellular cavities closed in, when

FIG. 13.

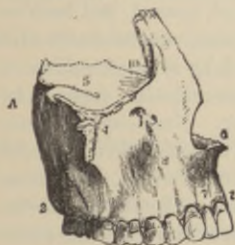

FIG. 14.



articulated, by the ethmoid and lachrymal bones. Below the opening is the smooth surface forming part of the inferior meatus

of the nose; behind a *rough surface*¹⁵ (Fig. 14) for the palate bone with a groove passing from above downward and forward, the *posterior palatine*¹⁵ (Fig. 14), which, closed in by the palate bone, forms the posterior palatine canal; in front, a deeper vertical *groove*¹⁰, which by the apposition of the lachrymal and inferior turbinated bones forms the *lachrymo-nasal duct*; and still more anteriorly the well-marked horizontal, rough-ridged *inferior turbinated crest*, for the inferior turbinated bone.

Describe the antrum of Highmore (maxillary sinus).

It is triangular, with apex outward formed by the malar process, its base the outer nasal wall, and opens, in the fresh state, by a small orifice of the size of a probe point into the middle nasal meatus. In the non articulated bone there is a large, irregular opening, which is narrowed when articulated by portions of the palate, ethmoid, and inferior turbinated bones. On its posterior walls are the *posterior dental canals*, while its floor presents several conical *prominences*, produced by the fangs of the first and second molar teeth; sometimes the floor is actually perforated. The walls are very thin.

Describe the malar process.

It is a rough, triangular eminence⁴, concave on its facial and zygomatic surfaces, and roughly serrated above for the malar bone.

Describe the nasal process.

This is thick, triangular³, rising upward, inward, and backward, with an external concave smooth surface, an internal surface articulating with the frontal above, and by a *rough surface* with the ethmoid, below this is the transverse ridge-like *superior turbinated crest* for the middle turbinated bone. Next comes a smooth, concave surface, part of the middle nasal meatus; then the inferior turbinated crest (see *ante*), and, most inferior of all, the concavity forming part of the inferior nasal meatus. The *anterior border* is thin, serrated for articulation with the nasal bone, and the *posterior border* thick, and grooved for the lachrymal duct, which is directed *backward and a little outward*; where the outer margin of the groove joins the orbital surface, is the *lachrymal tubercle*.

Describe the alveolar process.

This is thick, spongy, with eight cavities of varying depth, that for the canine tooth being deepest, those for the molars widest and subdivided.

Describe the palatine process.

It is a horizontal plate¹³ (Fig. 14), thickest in front, forms most of the roof of the mouth and floor of the nostril; has an upper and lower concave surface. In front, upon the upper surface, is the upper orifice of the *anterior palatine canal*, which conducts to a fossa formed between the two bones, transmitting the anterior palatine vessels through the *foramina of Stenson*, the naso-palatine nerves passing through the intermaxillary suture by the *foramina of Scarpa*; upon the under surface is a longitudinal *groove* (sometimes a canal), leading from the posterior palatine canal, for the posterior palatine vessels and nerve, while in front is seen the lower orifice of the *anterior palatine fossa* (foramen) presenting four openings; the inner border is thickened into a ridge on the upper surface forming the *nasal crest*, between which and its fellow fits the vomer, and which in front forms the *anterior nasal spine*.

How is this bone developed?

Probably by four centres; one for nasal and facial, one for orbital and malar, one for palatal in *membrane*, and one for incisive portion in *cartilage* at sixth to seventh foetal week. Antrum commences at the fourth fetal month.

With what bones does it articulate?

Frontal, ethmoid, nasal, malar, lachrymal, inferior turbinated, palate, vomer, and the other superior maxillary.

Give the muscular attachments.

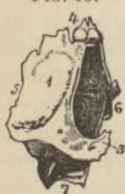Orbicularis palpebrarum, obliquus inferior of eye, levator labii superioris alæque nasi, levator labii superioris, levator anguli oris, compressor nasi, depressor alæ nasi, dilator naris posterior, masseter, buccinator, internal pterygoid, and orbicularis oris.

Lachrymal Bones.

What is their shape and where are they situated ?

They are two small bones situated at the front part of the inner wall of the orbit, resembling in form, thinness, and size a finger-nail, hence called *os unguis*. The external *orbital*¹ surface presents a vertical *ridge* giving origin to the tensor tarsi muscle, in front of which is a concave longitudinal *groove*² forming part of the *lachrymal duct* below, lodging the lachrymal sac above. Below is a hook-like process⁷ articulating with the inferior turbinated bone, assisting to form the lachrymal canal. A depressed furrow is seen on the nasal surface corresponding to the ridge externally; the surface in front forming part of the middle nasal meatus, the posterior closing in the anterior ethmoidal cells.

FIG. 15.



With what bones does it articulate ?

With the frontal⁴, ethmoid⁵, superior maxillary⁶, and inferior turbinated.

How is it developed ?

From one centre in membrane, at the eighth foetal week.

What muscles arise from it ?

The tensor tarsi of Horner.

Malar Bones.

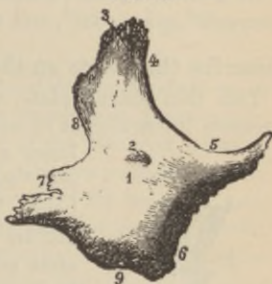
Describe them.

Two small quadrangular bones placed at the upper outer part of face, forming the prominence of the cheek, parts of the orbit, temporal, and zygomatic fossæ. The *external surface*¹ is convex, smooth, perforated by one or more *malar foramina*², for the passage of nerves and vessels; it gives origin to the two zygomatic muscles. The *internal*⁶ concave surface has a rough triangular surface for the superior maxillary bone. It has superiorly a thick serrated-edged *frontal process*³ articulating with the external angular process of the frontal bone; a thick, strong plate-like *orbital*

process, projecting backward, smooth and concave above, forming part of the floor and outer wall of the orbit, convex below, forming part of the temporal fossa, and bounding the spheno-maxillary fissure in front by its free margin, having upon its upper surface the orifices of one or more *temporo-malar canals* for filaments of the orbital branch of the superior maxillary nerve. Externally, projecting backward is the *zygomatic process*⁷ articulating with the zygomatic process of the temporal bone by a serrated margin.

The *upper border*^{4,5}, smooth and arched, forms the outer and inferior margin of the orbit; the *lower border*⁹, thick and rough, gives origin to the masseter muscle; the *anterior border*⁶, roughly bevelled, articulates with the superior maxillary; while the *posterior border*⁸, like an italic *f*, is continuous above with the temporal ridge, below with the upper border of the zygoma.

FIG. 16.



How is it developed ?

From one centre (some say two), at the eighth foetal week *in membrane*.

With what bones does it articulate ?

With the frontal, sphenoid, temporal, and superior maxillary.

What muscles arise from it ?

The levator labii superioris, zygomaticus major and minor, masseter, and temporal.

The Palate Bones.

Describe them.

These two bones, situated at the back part of the nasal fossæ, assist in the formation of the floor and outer wall of the nose, the roof of the mouth, the floor of the orbit, the inner wall of the

antrum, and aid in forming the sphenomaxillary and pterygoid fossæ.

Of what parts does each bone consist?

Of a *vertical plate*², a *horizontal plate*¹, and three processes, the *pterygoid*³, *sphenoidal*⁹, and *orbital*⁸.

Describe the points on the vertical plate.

This thin oblong plate, directed upward and a little inward, presents internally, at its upper part, the *superior turbinated crest*²,

FIG. 17.



lower a second ridge, the *inferior turbinated crest*⁶ for the middle and inferior turbinated bones, between which lies the *groove* for the middle nasal meatus, and below the inferior crest another *groove* for the inferior meatus.

The *posterior border* articulates with the pterygoid process of the sphenoid; on its external surface is a deep *groove* forming the posterior palatine canal by articulation with the superior maxilla, transmitting the vessels and nerve of the same name, while the upper and back *smooth surface* helps to form the inner wall

of the sphenomaxillary fossa, the *anterior smooth* small lamina springing from the anterior border of the bone opposite the inferior turbinated crest—the *maxillary process*—narrows the orifice of the antrum, between which is the rough *maxillary surface*. The posterior surface at the lower portion is pyramidal, forming the *pterygoid process*³, is deeply *grooved*¹⁰, forming part of the pterygoid fossa, with a V-shaped, rough margin for articulation with the pterygoid plates.

The *superior border*, deeply notched by the *spheno-palatine foramen*⁷ (or notch), forms the triangular hollow *orbital process*⁸, in front, articulating *anteriorly* with the maxilla, *posteriorly* with the sphenoid (its cells here usually opening into the sphenoidal sinus), *internally*, with the ethmoid, and has a free *orbital* and *zygomatic* surface, the latter opening into the zygomatic fossa, with a *rounded border* forming part of the sphenomaxillary fissure; behind, projecting upward and inward is the *sphenoidal process*⁹, *grooved* on its

upper surface by a *pterygo-palatine groove* to help to form the same-named canal; articulating here with the sphenoid bone, externally and posteriorly with the pterygoid process, and having an internal concave surface forming part of the outer wall of the nasal fossa.

Describe the horizontal plate.

This, completing the nasal floor and hard palate, presents on its inferior surface a transverse *ridge* for the tensor palati aponeurosis; a deep *groove* assisting in the formation of the posterior palatine canal¹¹; near this the orifices of several *accessory posterior palatine canals*; an *anterior border*, serrated and bevelled for the palate process of the superior maxillary; a smooth concave *posterior border*, for the attachment of the soft palate, terminating in the median line by a projection, which, with its fellow on the other bone, forms the *posterior nasal spine*⁵, for the azygos uvulæ muscle; and an internal thickest border, whose upper edge is raised to form, with its fellow, a *crest*⁴ articulating with the vomer.

How is this bone developed?

By one centre *in membræ* at the angle of junction of the two plates (seventh to eighth fœtal week).

With what bones does it articulate?

The sphenoid, ethmoid, superior maxillary, inferior turbinated, vomer, and opposite palate.

Give the muscular attachments.

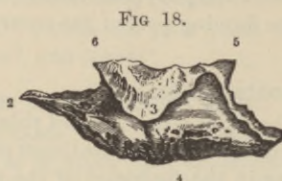
Tensor palati, azygos uvulæ, internal and external pterygoids, and superior constrictor of the pharynx.

The Inferior Turbinated Bones.

Describe them.

They are two thin, scroll-shaped bones, extended horizontally along the outer walls of the nasal fossæ, just below the orifice of the antrum, and are attached to the inferior turbinated crests of the superior maxillary¹ and palate² bones, and present three pro-

cesses for study, a *lachrymal*⁵, in front of the upper border, forming part of the nasal duct by its junction with the lachrymal and



superior maxillary bones; further back, the *ethmoidal process*⁶, joining the unciform process of the ethmoid; and from the lower border of this process the *maxillary process*³ projects, curving downward, and hooking over and narrowing the orifice of the antrum. The outer surface (from the median plane of the head) is concave; its inner convex, roughened, and grooved for arteries and veins.

Name the bones with which it articulates, and its method of development.

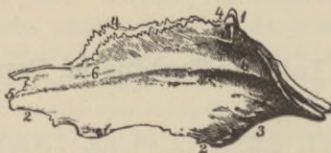It *articulates* with the ethmoid, lachrymal, palate, and superior maxillary bones; it is developed by one centre *in cartilage* (fifth foetal month).

Vomer.

Describe it.

It is single, plowshare-shaped, vertically placed posteriorly in the nasal fossæ (usually deviated to one side), and forms part of

FIG. 19.



the nasal septum. Its *superior border*¹ is deeply *grooved* for the rostrum of the sphenoid, with lateral *wings* (alæ), which slip under

the vaginal processes of the same bone. The *anterior border*⁴ is grooved for the vertical plate of the ethmoid and the nasal septal cartilage. The *inferior border*² is received in the groove formed by the nasal crest of the superior maxillary and palate bones. The *posterior border*³ is free, concave, thick above and thin below, and separates the nasal fossæ behind. On each lateral surface is the *naso-palatine groove*⁵ (sometimes a canal) for the nerve of the same name, and also small *furrows* for the lodgement of bloodvessels.

Name the bones with which it articulates, and its centres of ossification.

The sphenoid, ethmoid, both superior maxillary, and both palate bones. It has but one centre (eighth fœtal week *in membrane*), which includes between its two layers the septal cartilage; ossification is not completed until after puberty.

The Inferior Maxillary Bone.

Enumerate its general characteristics.

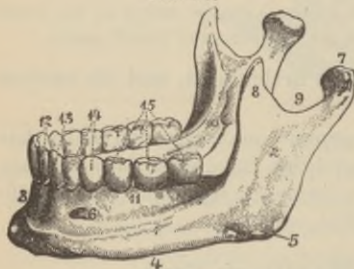
It consists of a *body*¹, with two *rami*², which are surmounted on either side by a curved beak-like *coronoid process*⁸ in front, and an articular *condyloid process*⁷ posteriorly, the constricted portion beneath which is termed the *neck* of the condyle; the depression separating these two processes is called the *sigmoid notch*⁹, crossed by the masseteric vessels and nerve.

Describe the body of the bone.

It is horseshoe shaped, and presents the following points for examination: the prominent triangular eminence in front, the *mental process*³, extending upward from which is a median vertical ridge the *symphysis*³, marking the junction of the two halves of the bone; on either side, just below the roots of the incisor teeth, is the *incisive fossæ*, giving origin to the levator menti; and more externally, below the root of the second bicuspid tooth, the *mental foramen*⁶, for the exit of the mental artery and nerve. Extending outward from the base of the mental process is a distinct *ridge*¹, the *external oblique line*, continuous posteriorly with the anterior border of the ramus; to it are attached anteriorly the depressor labii inferioris and depressor anguli oris. The lower border⁴, just in front

of the attachment of the masseter, is *grooved* for the facial artery. The internal surface presents an indistinct *linear depression*, indicating the point of junction of the two halves of the bone, on either side of the centre of which are four prominent *genial tubercles*, disposed in pairs, sometimes blended into two, or even one irregular

FIG. 20.



mass, the upper giving origin to the genio-hyo-glossus, the lower pair to the genio-hyoid muscles. Upon each side of these tubercles is the oval *sublingual fossa* for the glands similarly named, and beneath each a rough *depression* for the origin of the digastric muscle. Extending obliquely upward and backward from the sublingual fossa is the *internal*

oblique line (mylo-hyoid ridge) for the same named muscle; beneath its edge is the oblong *submaxillary fossa*, for the submaxillary gland; above it the alveolar portion pitted with alveoli (sockets) for sixteen teeth in adult, ten in child.

Describe the rami.

These ascending, flattened, quadrilateral plates present in front the curved *coronoid process*⁸, giving attachment to the temporal muscle; the deep *sigmoid notch*⁹, forming whose posterior boundary is the *condyloid process*⁷ surmounting its narrow *neck*, in front of which is a depression for the tendon of the external pterygoid muscle, and externally a small *tubercle* for the external lateral ligament. The articular surface is oblong, with its long axis transversely oblique from behind forward and outward, and is convex from behind forward, and from side to side. Upon the inner surface of the coronoid process commences a longitudinal *ridge*, with a *groove*, for the temporal above, the buccinator muscle below. The outer surface of the ramus has various *ridges* for the attachment of the masseter muscles; its inner surface presents a central oblique aperture, that of the *inferior dental canal* (communicating with each alveolus and terminating at the mental foramen) for the vessels

and nerve; in front of this opening a prominent *ridge*, terminating behind in a sharp *spine* for the long internal lateral ligament; below the spine the *myo-hyloid groove* for the same named vessels and nerves, and behind the groove a *rough surface*, for the internal pterygoid muscle.

At the junction of the posterior and inferior margins of the ramus is the *angle*⁵ marked with rough oblique ridges externally for the masseter, internally for the internal pterygoid muscle.

With what bones does the inferior maxillary articulate?

With the two temporals.

What ossific centres has it?

It is the second bone of the skeleton to ossify (clavicle first), and is probably developed by only two centres, chiefly in *membrane*, partly in *cartilage*, one for each lateral half, which coössify about the first year.

Compare the forms of the old and adult jaw.

In old age the alveolar portion being absorbed, the angle formed by the ramus with the body is very obtuse, and the dental canal is near the upper surface (important surgically in operating for neuralgia); in adult age the ramus is almost vertical, and the dental canal lies about the middle of the bone.

Give the muscular attachments.

Fifteen pairs; to the *ramus* the masseters, temporals, internal and external pterygoids; to the *inner surface* of the *body*, the genio-hyoglossus, genio-hyoid, mylo-hyoid, digastric, superior pharyngeal constrictor; to the *outer surface* of the *body* the depressor labii inferioris, depressor anguli oris, levator menti, orbicularis oris, platysma myoides, and buccinator.

The Sutures and Fontanelles.

What is a suture?

Rows of interlocking, tooth-like processes, projecting from the *external* table of either bone (the inner tables are merely apposed).

How many sutures are there?

Eighteen.

Name those at the vertex.

The interparietal (sagittal), the fronto-parietal (coronal), and the occipito-parietal (lambdoid).

Name those at the sides.

Spheno-parietal, squamo-parietal, and masto-parietal.

Name those at the base.

One baso-sphenoidal, two petro-occipital, two masto-occipital, two petro-sphenoidal, and two squamo-sphenoidal. The points of junction of the sphenoid with the frontal and ethmoid, and the frontal with the ethmoid, are not usually described as sutures.

Which only of the facial sutures has received a name ?

The *transverse*, that extending from one external angular process of the frontal to the other, joining that bone with the malar, sphenoid, ethmoid, lachrymal, superior maxillary, and nasal bones.

Why does the skull consist of so many pieces ?

To admit of continuous growth of the bones at their edges, *pari passu* with the growth of the brain, hence premature coössification of all the sutures results in *idiocy*. Obliteration of the sutures occurs at variable periods after maturity.

What are the fontanelles ?

They are membranous intervals in the infant's skull, corresponding to the junction of the four angles of the parietal with the contiguous bones. They number six, viz., the *anterior*, of lozenge-shape, at the junction of the sagittal and coronal sutures, usually closed not later than the second year; the *posterior*, triangular, at the junction of the sagittal and lambdoid sutures, closed a few months after birth; and the *lateral*, one at the antero-inferior angle, another at the postero-inferior angle of each parietal bone, which are closed soon after birth.

How are these spaces closed ?

By a gradual extension of the ossifying process, or by the development of additional centres, forming so-called *Wormian bones*.

The Cerebral Fossæ.

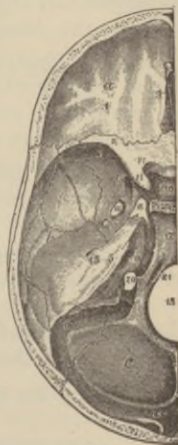Describe the general characteristics of the anterior fossæ with their foramina *a.*

Formed by the orbital plates of the frontal¹, the cribriform plate of the ethmoid with its spine⁹, and the lesser wings² of the sphenoid, they are convex on either side and concave in the median line. The foramina are one median, the *foramen cæcum*, which, if pervious, transmits a vein from the nose to the superior longitudinal sinus; two *slits*⁹ on each side of the crista galli for the nasal nerves; three rows of olfactory foramina on each side for the olfactory filaments; on the outer side of each olfactory groove, the *anterior and posterior ethmoidal foramina*, the former transmitting the anterior ethmoidal artery and the nasal nerve, the latter, the posterior ethmoidal artery and vein.

Give the boundaries and the foramina of the middle fossæ *b.*

In front, they are bounded by the posterior margin of the lesser wings of the sphenoid², the anterior clinoid processes¹¹, and anterior margin of the optic groove; behind, by the upper borders of the petrous portion⁵ of the temporal bones and basilar suture; externally by the squamous plates of the temporal⁴ and anterior inferior angles of the parietals⁷. The *foramina* are on each side, the *optic*¹⁴ for the optic nerve and ophthalmic artery. The *sphenoidal fissure* (foramen lacerum anterius), transmitting the third, fourth, ophthalmic branch of the fifth and the sixth cranial nerves, and filaments of the sympathetic, the ophthalmic vein, branches of the lachrymal and middle meningeal arteries with a process of the dura mater; immediately behind this, the *foramen rotundum*¹⁵, for the superior maxillary division of the fifth cranial nerve; more posteriorly, the *foramen ovale*¹⁶, for the inferior maxillary division of the fifth nerve, the

FIG. 21.



small meningeal artery and the small petrosal nerve; between the two, internally, the *foramen vesalii* (often absent), for a small vein; piercing the posterior inferior angle of the greater sphenoidal wing, the *foramen spinosum*¹⁷, for the middle meningeal artery, meningeal veins, and sympathetic nerve branches from the cavernous plexus; on the inner side of the oval foramen the *foramen lacerum medium*¹⁸ (filled in below by a plate of cartilage in the fresh state), for the internal carotid artery, carotid sympathetic plexus, large petrosal nerve (Vidian), and a small meningeal branch from the ascending pharyngeal artery; on the anterior surface of the petrous portion of the temporal, the *hiatus Fallopii*²³, and beneath it, a small *foramen* for the small petrosal nerve.

What are the posterior fossæ °?

They are deeply concave, and each is formed by the occipital⁸, petrous⁵ and mastoid⁶ portions of the temporal, and the posterior inferior angle of the parietal⁷.

What foramina and other openings does each present?

The *meatus auditorius internus*¹⁹ for the facial and auditory nerves, and the auditory artery; the *aquæductus vestibuli* for a small artery and vein; the *foramen lacerum posterius*²⁰ transmitting the glosso-pharyngeal, pneumogastric, and spinal accessory nerves, the internal jugular vein, and meningeal branches of the ascending pharyngeal and occipital arteries; the *mastoid foramen* (often absent) for a vein; the *posterior condyloid foramen* (often absent) for a vein of the same name; the *anterior condyloid foramen*²¹ for the hypoglossal nerve, and a meningeal branch from the ascending pharyngeal artery: and separating the two fossæ in the median line, the *foramen magnum*¹³, accommodating the medulla oblongata and membranes, the spinal accessory nerves and vertebral arteries.

What additional foramina or openings are found at either side of the base?

*The orifice of the Eustachian tube*³³ admitting air to the middle ear.

*The canal for the tensor tympani muscle*³³ above the former.

The posterior orifice of the Vidian canal for Vidian nerve and vessels.

Glaserian fissure¹⁵ for processus gracilis of the malleus, the laxator tympani muscle, the tympanic artery; and close by

The orifice of the canal of Huguier, transmitting the chorda tympani nerve.

The canal for Jacobson's nerve, the tympanic branch of the glosso-pharyngeal.

The aquæductus cochleæ, for a small artery and vein running to the cochlea.

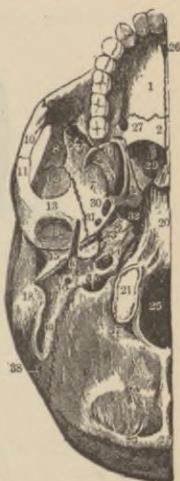The canal for Arnold's nerve, the auricular branch of the pneumogastric.

The auricular fissure, for the exit of Arnold's nerve.

The stylo-mastoid foramen³⁶, for the exit of the facial nerve, and the entrance of the stylo-mastoid artery.

The anterior²⁶ and posterior²⁷ foramina of the palatal region have already been sufficiently described, and this region does not properly belong to the base of the skull, while those opening externally at the base and upon the face have been described sufficiently under the temporal bone, and the superior and inferior maxillary bones.

FIG. 22.



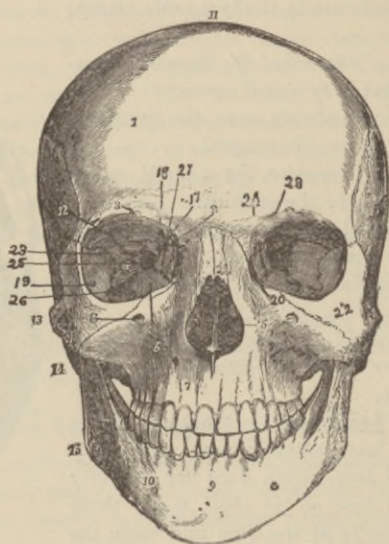
The Orbital Cavities.

Describe them.

They are two quadrilateral pyramidal cavities, with bases outward, their long axes directed from in front inward and backward, in such directions that if prolonged they would meet about the sella turcica of the sphenoid. Seven bones contribute to the formation of each, viz., the frontal¹², ethmoid²⁷, sphenoid²³, lachrymal²⁴, superior maxillary⁶, palate²⁵, and malar²²; they communicate with the cranial cavity, behind, by the optic foramina¹⁸ and sphenoidal fissures²³, with the nasal fossæ through the lachrymo-

nasal duct, and below, externally, by the spheno-maxillary fissure²⁶ with the *temporal*, *zygomatic*, and *spheno-maxillary fossæ*.

FIG. 23.



What bones compose the roof, and what is its form?

The orbital plate of the frontal, anteriorly, the lesser sphenoidal wing behind; it is concave, and directed downward and forward, presenting internally a *depression*²⁸ for the fibro-cartilaginous pulley of the superior oblique muscle of the eye, externally the *lachrymal fossa*¹² for the gland.

Describe the floor, and of what bones formed.

Nearly flat, formed chiefly by the orbital plate of the superior maxillary⁶, and, to a less extent, by the orbital processes of the malar¹⁹ and palate bones; it presents, just external to the lachrymal canal, a *depression* for the inferior ocular oblique muscle; externally, the *malo-maxillary suture*; near the middle the *infra-orbital groove*; and posteriorly, the *palato maxillary suture*.

Give the bones forming, and the points of interest upon the inner wall.

It is flattened, formed by the nasal process of the superior maxillary, the lachrymal²⁴, os planum of the ethmoid²⁷ and sphenoidal body. It presents in front the *lachrymal groove*²⁰, bounded behind by the *lachrymal crest*; further back, respectively, the *lachrymo-ethmoidal* and *ethmo-sphenoidal sutures*.

What forms the outer wall?

The orbital plate of the malar and the greater wing of the sphenoid, and on it are seen the openings of one or two *malar canals*¹⁹ and the *spheno-malar suture*.

Describe the chief points connected with the superior external angle of the orbit.

Posteriorly, the *sphenoidal fissure* (foramen lacerum anterius)²³ for the *entrance* of the third, fourth, ophthalmic branch of the fifth and sixth nerves, and branches of the lachrymal and middle meningeal arteries, a process of the dura mater, sympathetic nerve filaments, and the *exit* of the ophthalmic vein; also the *fronto-malar* and *fronto-sphenoidal sutures*.

What points does the superior internal angle present?

The suture between the lachrymal, ethmoid, and frontal bones; between the junction of the two latter bones, the *anterior ethmoidal foramen*² for the anterior ethmoidal artery and nasal nerve, and the *posterior ethmoidal foramen*¹⁷ for the posterior ethmoidal artery and vein.

What points does the inferior external angle present?

The *spheno-maxillary fissure*²⁶ transmitting the infra-orbital vessels and superior maxillary nerve, the ascending branches from the spheno-palatine ganglion, and the orbital branch of the superior maxillary nerve.

How is the inferior internal angle formed?

By a *suture*, the union of the lachrymal and os planum of the ethmoid with the superior maxillary and palate bones.

What foramen does the orbital margin present?

The *supra-orbital*³ at the junction of the inner and middle thirds, transmitting the supra-orbital artery, veins, and nerve.

What foramen opens at the apex of the orbit ?

The *optic*¹⁸, between the two roots of the lesser wing of the sphenoid, transmitting the optic nerve and the ophthalmic artery.

Recapitulate the openings communicating with the orbit.

The *optic*¹⁸, sphenoidal fissure²³ (foramen lacerum anterius), sphenomaxillary fissure²⁶, infra-orbital canal⁴, anterior² and posterior¹⁷ ethmoidal foramina, malar foramina¹⁹, supraorbital foramen, and lachrymal canal²⁰ (occasionally, in addition, one or more external orbital foramina).

The Nasal Fossæ.**Describe them.**

They are two irregular cavities, extending from the base of the cranium above to the roof of the mouth below¹⁷, separated in the median line by a thin osteo-cartilaginous septum, opening upon their facial aspect by two large apertures, the *anterior nares*^{4 10}, and into the pharynx by the *posterior nares*¹⁵. Each fossa communicates with four sinuses and four cavities.

Of what parts is the nasal septum composed ?

In front, the crest of the nasal bones, and the frontal nasal spine; its middle portion, the vertical plate of the ethmoid; behind, the rostrum of the sphenoid and the vomer; below, the crests of the superior maxillary and palate bones.

What points does the roof of each fossa present ?

In front, the *slit* for the nasal nerve; numerous *foramina* for the olfactory filaments; most posteriorly the opening of the sphenoidal sinus²⁴.

The floor ?

In front, the *anterior nasal spine*¹⁰; behind this the upper opening of the *anterior palatine canal*¹⁴; internally the *nasal crest*¹²⁻¹⁷ of the superior maxillary and palate bones.

Describe the chief points of interest in the outer wall of each fossa.

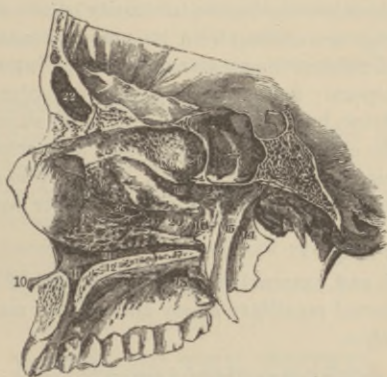This presents three irregular longitudinal passages, formed by

three projecting bony plates, called the *superior*¹⁹, *middle*²⁰, and *inferior meatuses*²¹.

Describe each meatus.

The *superior*¹⁹ occupies the posterior third of the wall, lies between the superior⁶ and middle⁷ turbinated bones (processes of the ethmoid), and has opening into it two *foramina*, the *spheno-palatine*²⁵ posteriorly, the *posterior ethmoidal cells* in front part of the upper wall.

FIG. 24.



The *middle*²⁰ occupies the posterior two-thirds of this wall, lies between the middle and inferior turbinated bones, and has opening into it, in front, the *infundibulum*; in its centre, the *antrum*²⁶.

The *inferior*²¹ lies between the inferior turbinated bone and the nasal floor, extends along the whole length of the outer wall, and has opening into it, in front, the lower orifice of the lachrymo-nasal duct (and the anterior palatine canal in the macerated bone, *not* in the natural state).

Describe the position and boundaries of the temporal fossa.

Situated at the lateral region of the skull, each fossa is marked out upon the skull-cap by the *temporal ridge*, which extends in a curved line first upward and backward from the external angular process of the frontal bone, then downward behind to form the

posterior root of the zygomatic process. Its anterior boundaries are the frontal, malar, and greater wing of the sphenoid, above and behind the temporal ridge, below the pterygoid ridge on the greater wing of the sphenoid, externally the zygomatic arch; it opens below into the zygomatic fossa, and is filled by the temporal muscle, and is traversed by grooves, for branches of the deep temporal artery.

Describe the zygomatic fossa, its boundaries, and communicating fissures.

It is bounded, *anteriorly*, by the tuberosity of the superior maxilla, and the ridge descending from its malar process; *superiorly*, by the pterygoid ridge of the greater sphenoidal wing and squamous plate of the temporal; *behind*, by the posterior border of the pterygoid process; *below*, by the alveolar border of the superior maxilla; *internally*, by the external pterygoid plate; and *externally*, by the ramus of the lower jaw and the zygoma. The *spheno-maxillary* and *pterygo-maxillary fissures* open into its inner upper part.

What does it lodge?

The internal and external pterygoid and part of the temporal muscle, the internal maxillary artery and inferior maxillary nerve and their branches.

Describe the spheno-maxillary fissure.

It runs horizontally, opens into the outer back part of the orbit, lying between the lower orbital border of the greater wing of the sphenoid and the outer border of the orbital plate of the superior maxillary and a small part of the palate bone; externally is a small part of the malar, while, *internally*, it joins the pterygo-maxillary fissure at a right angle; it transmits the infra-orbital artery, the superior maxillary nerve, with its orbital branch, ascending branches from Meckel's ganglion, and serves to connect the orbit with the spheno-maxillary, temporal, and zygomatic fossæ.

What are the boundaries of the pterygo-maxillary fissure, and what passes through it?

It is bounded, in front, by the maxillary tuberosity; behind, by the pterygoid plate of the sphenoid; descends at right angles from

the inner extremity of the spheno-maxillary fissure, transmits branches of the internal maxillary artery, and connects the zygomatic and spheno-maxillary fossæ.

Describe the spheno-maxillary fossa.

Situated at the junction of the spheno-maxillary and pterygo-maxillary fissures, it is bounded, *above*, by the under surface of the body of the sphenoid, and by the orbital process of the palate; in *front*, by the superior maxillary bone; *behind*, by the pterygoid process of the sphenoid; *internally*, by the vertical plate of the palate. In this fossa terminate the sphenoidal, spheno-maxillary, and pterygo-maxillary fissures. The *orbital*, *nasal*, and *zygomatic fossæ* communicate with it, and also the *cranial cavity*.

How many foramina open into it?

Five (sometimes seven or eight); three in the back wall, viz., above, the *foramen rotundum*; more internal and inferior, the *Vidian*; and lowest and most internal, the *pterygo-palatine*; on the inner wall is seen the *spheno-palatine foramen*; below, the upper orifice of the *posterior palatine canal*, and sometimes two or three *accessory posterior palatine canals*.

BONES OF THE TRUNK.

The Vertebral Column.

How are the vertebræ divided?

By regions, viz., into cervical (7); dorsal (12); lumbar (5); sacral (5); and coccygeal (4); 33 in all.

What are the sacral and coccygeal vertebræ called to distinguish them from the remaining bones?

False, the others being called true (false described with pelvic bones).

What parts are common to all vertebræ?

A *body*¹; posteriorly on each side a *pedicle*², supporting two *laminæ*³, which, joining behind enclose the *spinal foramen*⁴; from

the junction projects a *spinous process*⁵: from other parts six additional *processes* arise, viz., two *transverse*⁶, and four *articular*^{7,7'}.

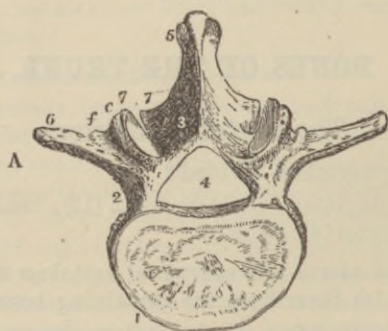
Describe a vertebral body.

Composed of cancellous bone, with a thin, compact layer externally, its sides are concave from above downward, while its *upper surface* is, in the *cervical* region, concave laterally, forming a lip at either side, while the *lower surface* is convex from side to side, and concave from before backward, forming an anterior lip; in the *dorsal* region it is flat above and below; and in the *lumbar region*, flattened, or slightly concave above and below. Articular facets and demi-facets for the heads of the ribs, mark the *dorsal* bodies, neither the lumbar nor the cervical bodies having these.

Describe the pedicles.

They project backward in all but the cervical vertebræ, where they are directed obliquely outward. They present *intervertebral notches* above and below (deepest *above* in the cervical vertebræ; *below* in the dorsal and lumbar spine), forming, when articulated, *intervertebral foramina* for the exit of the spinal nerves, and the entrance of vessels.

FIG. 25.



What are the laminae?

Two broad plates closing in the spinal foramen, roughened at their upper margins and their inferior internal surfaces for the ligamenta subflava.

Describe the transverse processes.

They are bifid in the cervical and perforated by the vertebral foramen for the vertebral vessels; thick, strong, and long, with anterior articular facets, in the dorsal; long and slender in the lumbar: they spring from the junction of the pedicle and lamina, and also from the side of the body in the *cervical* region.

Describe the articular processes.

Two are superior and two inferior, projecting from the junction of the laminae and pedicles. The upper pair look upward and backward in the cervical region; backward and outward in the dorsal, inward and slightly backward in the lumbar; the lower pair are exactly the reverse of the upper in each region.

Describe the spinous processes.

Bifid, short, and horizontal in the cervical; long, triangular, directed obliquely downward in the dorsal; and thick, broad, quadrilateral in the lumbar.

Describe the spinal foramen.

It is largest and triangular in the cervical, smallest and round in the dorsal, medium and triangular in the lumbar.

Name the peculiar vertebræ of each region, and describe them.

The first cervical, or atlas; the second cervical, or axis; the seventh cervical, or vertebra prominens; the first, ninth, tenth, eleventh, and twelfth dorsal, and the fifth lumbar.

The atlas supports the head, and is formed of two *lateral masses* joined by an *anterior* and *posterior arch*; the former presents a *facet* posteriorly for the odontoid process. Upon the upper surface of each lateral mass is an *articular facet*, looking upward, inward, and backward for the occipital condyles, while the *inferior facet* looks downward and directly inward; a small tubercle represents the spinous process. *Development* is by one centre for anterior arch (first year); one for each lateral mass (sixth foetal week).

The axis has surmounting the body the *odontoid process*, with a *facet* in front for articulation with atlas, another behind for the transverse ligament, with a *roughened apex*, to which are attached

the check ligaments; on each side of the odontoid, facing upward and outward, are the superior articulating processes. *Development* is like other vertebræ, except three additional centres for odontoid, two appearing at the sixth foetal month.

The vertebra prominens is so called because of its long, spinous process, to which is attached the ligamentum nuchæ. *Development*, like other vertebræ, except one additional centre for anterior part of transverse process.

The dorsal vertebræ.

The first has an *entire facet* and a *demi-facet* on body; the ninth has a *demi-facet* on body above, and a *facet* on the transverse process; the tenth has *one facet* on the body and *one* on the transverse process; the eleventh and twelfth, *one facet* on the body, none on the transverse processes, the latter also closely resembling those of a lumbar vertebra.

The fifth lumbar has a markedly wedge-shaped body, with the base forward.

How are the ordinary vertebræ developed ?

By one centre for the body, one for each lamina (sixth to eighth foetal week); at sixteen years, one centre for the tip of each transverse, and two for the spinous process; and at twenty-one years, a plate upon the upper and lower surface of the body; the lumbar vertebræ have two additional centres tipping the superior articular processes; coössification at thirty years.

The Thorax.

Give its structure, form, and boundaries.

It is conical in form, and its osseo-cartilaginous framework is formed by the dorsal vertebral bodies behind, the ribs laterally, and the costal cartilages and sternum in front; its base is formed by the diaphragm. Through its apex, the great cervical vessels, the pneumogastric, phrenic, and sympathetic nerves, the trachea, œsophagus, and thoracic duct pass (it is also said, the apices of the lungs during inspiration).

What are the most important structures this cavity contains?

The trachea, primitive bronchi and lungs, the heart, aorta and its primary branches, the internal mammary arteries, the venæ cavæ, bronchial and azygos veins, the pneumogastric, phrenic, and splanchnic nerves, the œsophagus, thoracic duct, lymphatic vessels and glands.

Hyoid Bone.

Describe this bone and its development.

It consists of a body and two *greater* and two *lesser cornua*; the *greater cornua* project backward from the lateral surfaces of the body, and have attached to their tubercular ends the thyro-hyoid ligaments; the *lesser cornua*, attached to the junction between the body and greater cornua, give attachment, by their apices, to the stylo-hyoid ligaments; it is *developed* by five centres: one for body, and one for each greater horn toward the end of foetal life; one for each lesser horn some months after birth.

Give the muscular attachments.

The sterno-hyoid, thyro-hyoid, omo-hyoid, digastric, stylo-hyoid, mylo-hyoid, genio-hyoid, genio-hyo-glossus, hyo-glossus, middle pharyngeal constrictor, and sometimes the lingualis.

The Sternum.

Describe it.

The breast-bone consists of three segments, viz., the manubrium (handle), the gladiolus (sword), and the ensiform (xiphoid) cartilage. Upon the upper border of the *manubrium*⁸ is the *inter-clavicular notch*¹¹; upon either side of which is the *facet*¹² for the clavicle; lower, another for the first rib; below, a *demi-facet*² for the second rib.

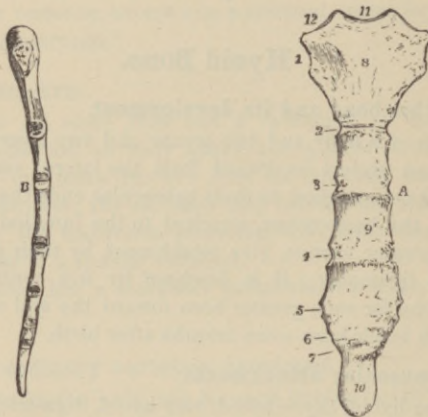
The *gladiolus*⁹ has a *demi-facet*⁷ above for the second rib, another below for the seventh⁷, and, between, *facets*^{3, 4, 5, 6}, for the third, fourth, fifth, and sixth ribs.

The *ensiform cartilage*¹⁰ has a *demi-facet*⁷ above for the cartilage of the seventh rib.

How is this bone developed?

By six centres; one for manubrium, four for gladiolus, one for ensiform cartilage (fifth foetal month to eighteen years); the three pieces rarely coëssify.

FIG. 26.

**What muscles are attached to this bone?**

Above, the sterno-cleido-mastoid, the sterno-hyoid, and sterno-thyroid; below, the rectus abdominis, external and internal oblique, transversalis, and diaphragm; in front, the pectoralis major; behind, the triangularis sterni.

Ribs.**What is their number, and how are they divided?**

Twelve on each side, seven of which are *true*, or those articulating with the sternum by a separate cartilage; five *false*, three of which indirectly articulate through the medium of the seventh cartilage; while the two lowest, having their anterior extremities free, are called *floating ribs*.

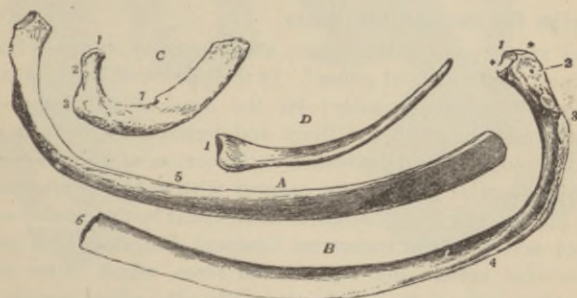Of what parts does a rib consist?

A head, neck, shaft, angle, and tuberosity, except the eleventh and twelfth ribs.

Describe these parts.

The *head*¹ (except first, tenth, eleventh, and twelfth ribs having only one facet) is divided into two facets by a ridge for the inter-articular ligament. The *neck*² is flattened, *roughened* upon its upper border for the anterior, and upon its posterior surface for middle costo-transverse ligaments; in front it is smooth. The *tuberosity*³ (absent in eleventh and twelfth), placed at the base of the neck, presents a facet for the transverse process of the next lower vertebra, and a *rough surface* for the posterior costo-transverse ligament. The *shaft*⁵ is twisted on its long axis (except first and second), externally convex, its upper border rounded, its lower *grooved*⁴ for the intercostal vessels and nerve, and presents at its anterior extremity an *oval depression*⁶ for the costal cartilage. The *angle*⁴, at a variable distance in front of the tuberosity, is indicated by a *rough line*.

FIG. 27.



How are the ribs developed?

By three centres (except eleventh and twelfth, two centres), one each for head, shaft, and tuberosity (for shaft sixth foetal week); for head and tuberosity (sixteen to twenty years); coössifies at twenty-fifth year.

Describe the peculiar ribs.

They are the first, second, tenth, eleventh, and twelfth ribs.

First rib ^c, broad, short, flat, one facet on head, angle absent; on upper surface two parallel grooves, the anterior for the subclavian vein, the posterior for the artery, and between them a *tubercle*⁷ for the anterior scalene muscle a *sure guide to the subclavian artery*.

Second rib, also flattened, the tuberosity and angle nearly coincide, and presents near its middle a *rough eminence*, for the attachment of part of the first, and all of the second digitation of the serratus magnus.

Tenth rib ^d, one facet on head.

Eleventh rib, one facet on head, no tuberosity, no neck, slight angle.

Twelfth rib, one facet on head, neither neck, angle, nor tuberosity.

The Pelvic Bones.**What are they?**

The ossa innominata, the sacrum, and the coccyx.

Describe the innominate bones.

They are formed by the union, about puberty, of three bones, the ilium¹, ischium², and pubes.³ At their point of junction is the *acetabulum*¹⁹ (cotyloid cavity) for the head of the femur—the pubes forming one-fifth, the ilium and ischium each about two-fifths. A rough central depression at the bottom of the acetabulum lodges a vascular mass of fat covered with synovial membrane, while the anterior lower margin is interrupted by the *cotyloid notch*, bridged across by the transverse ligament, beneath which passes the nutrient vessels and ligamentum teres, which latter arises from either side of the notch externally; the whole margin has attached to it the cotyloid ligament. Between the pubes and ischium, on the anterior surface, is the *obturator foramen*²⁰ (thyroid), closed by the membrane of the same name, except above externally where the obturator vessels and nerve escape; the foramen is a large ovoidal opening in the male, a smaller and triangular one in the female.

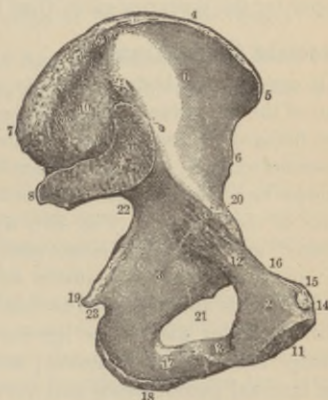
Describe the ilium.

This is the upper expanded portion of the bone, presenting along its upper border the *crest*⁴ with its outer and inner lips, terminating in front by the *anterior superior spinous process*⁸, giving origin to Poupart's ligament, the sartorius and tensor vaginae femoris muscles, and behind by the *posterior superior spinous process*¹⁰, to which are attached part of the erector spinæ muscle and the oblique band of the sacro-iliac ligament. Below both the anterior⁸ and posterior spines¹⁰ is a process called, respectively, the *anterior*⁹ (for straight tendon of the rectus femoris muscle) and *posterior inferior spinous*¹¹ (for great sacro-sciatic ligament); by these projections a *notch* is formed in front and behind, the former giving partial origin to the sartorius muscle and transmitting the

FIG. 28.

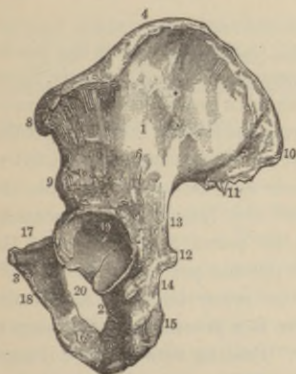

FIG. 29.



external cutaneous nerve. Between the posterior inferior spine and the spinous process of the ischium is situated the *greater sacro-sciatic notch*¹³, giving egress to the pyriformis muscle, the greater and lesser sciatic, superior gluteal and pudic nerves, also one to the obturator externus muscle, and the sciatic, gluteal and pudic vessels. About two inches from the posterior superior

spine, passing downward and outward from the crest, is the *superior curved line*⁷, from the surface back of which arise the gluteus maximus muscles and a few fibres of the pyriformis; about an inch behind the anterior superior spine, passing from the crest downward and backward to the upper part of the great sacro-sciatic notch, is the *middle curved line*⁵, the gluteus medius arising from the space between these two lines; passing downward and backward, from the upper part of the anterior inferior spine to the front of the sacro-sciatic notch, is the *inferior curved line*⁶, between which and the middle arises the gluteus minimus. Above the acetabulum is a *groove* for the reflected tendon of the rectus femoris muscle. The inner surface presents the large, smooth concave *Venter* (internal iliac fossa)¹ (Fig. 29), limited below by the prominent *ilio-pectineal line*, and behind the iliac fossa is the rough *auricular surface*⁹, the lower part for articulation with the sacrum, the upper for the posterior sacro-iliac ligaments.

Describe the ischium.

It consists of a body, tuberosity, and ramus, and forms the lowest part of the innominate bone. The external surface of the *body*² forms two-fifths of the acetabulum; below this is a *groove* for the obturator externus tendon; its inner surface forms the lateral boundary of the true pelvis; from the posterior border, below the centre, projects the *spine of the ischium*¹⁹ (Fig. 29), above and below which are the *greater*²² and *lesser sacro-sciatic notches*²³, the latter giving egress to the obturator externus muscle and its nerve, and ingress to the pudic vessels and nerve. The lowest portion presents a *tuberosity*¹⁸, with an outer and inner lip—to the latter being attached the greater sacro-sciatic ligament; above is a *groove* for lodgement of the internal pudic vessels and nerve. Passing upward and inward from the tuberosity to join the ramus of the pubes, and bounding the obturator foramen in front, is the thin, flattened *ascending ramus*¹⁷.

Describe the pubes.

This bone (also called pectineal) consists of a *body*² or *horizontal*¹² and a *descending* (perpendicular) *ramus*¹³. The outer end forms one-fifth of the acetabulum; above, a rough *ilio-pectineal*

*eminence*²⁰ indicates the point of junction with the ilium; the inner end is the oval *symphysis*¹¹ with eight or nine *ridges* for attachment of the fibro-cartilage; the upper triangular surface presents posteriorly the pectineal portion of the *ilio-pectineal line*¹⁶; the anterior surface presents the *crest*¹⁴, ending externally in the *pubic spine*¹⁵ giving attachment to Poupart's ligament, internally in the *angle*; below is a *groove* for the obturator vessels and nerve; the *descending ramus*¹³, thin and flat, joins that of the ischium, completing the anterior boundary of the obturator foramen.

How are these bones developed ?

By three primary centres, one for each bone (from the eighth foetal week to fifth foetal month); and one for the crest, one for the tuberosity, one for the anterior inferior spine, one for symphysis, and one Y-shaped, joining the three pieces forming the acetabulum, appearing about puberty; bone coössiifies completely about twenty-fifth year. (For order of junction, see Gray.)

What muscular attachments has the innominate bone ?

Those of the abdomen, some of the thigh, those of the perineum, pelvic floor and rotators of the thigh.

Describe the sacrum.

It is composed of five consolidated vertebræ, is of triangular form with broad base and blunted apex and lateral expanded masses or *alæ*; its anterior surface is concave, its posterior convex, and with the coccyx it forms the posterior wall of the true pelvis. Its anterior surface is marked by four transverse *ridges*¹, indicating the lines of junction of the segments; eight *anterior sacral foramina*² with broad shallow *grooves* for the anterior sacral nerves open on this surface; the point of junction with the last lumbar vertebra forms the *promontory* (sacro-vertebral angle); and upon each side are the *alæ*⁷—the expanded portions of the bone. Posteriorly are three or four median tubercles (rudimentary spinous processes); externally are the laminae, those of the fifth and sometimes the fourth being deficient; outside these is a row of rudimentary articular processes. On each side of the spine is a broad *sacral groove*, lodging the origin of the erector spinæ muscle; externally are the four *posterior sacral foramina* on each

side; at the posterior inferior portion of the bone are the two *cornua*—articulating surfaces for the coccyx; each lateral surface

FIG. 30.

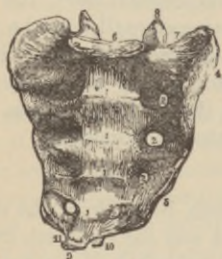
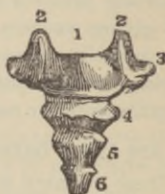
FIG. 31.



has on its anterior upper part an *auricular surface*⁴ for articulation with the ilium; on each side of the apex below is a deep *notch*,^{10 11} for the fifth sacral nerve; the *base*⁶ resembles the upper surface of a lumbar vertebra, with the last of which it articulates; the *apex*⁹, directed downward and forward, has an oval concave articular surface for the coccyx; the *sacral canal* runs the whole length of the bone, triangular above, small and flattened below and deficient in its posterior wall at the lower part; it lodges the sacral nerves, and into it open the anterior and posterior sacral foramina.

What centres of ossification has the sacrum?

Thirty-five, appearing from the eighth foetal week to the twentieth year, coössification being complete from the twenty-fifth to thirtieth year. The bodies have each three centres; each lamina one centre; the lateral masses three centres each; the lateral surfaces two each.

Give the muscular attachments.

The pyriformis, coccygeus and iliacus in front, the gluteus maximus, latissimus dorsi, multifidus spinæ, erector spinæ, and sometimes the extensor coccygis behind.

Describe the coccyx.

Usually composed of four rudimentary vertebræ, more or less coössified, it forms a triangular bone whose *base*¹ articulates with

the sacral apex. The first piece presents two *cornua*², projecting upward from either side of the base for articulation with the sacral cornua, their junction completing the fifth sacral foramina for the posterior branches of the fifth nerves. The *apex*⁶ is rounded and occasionally bifid or turned to one side; two rudimentary *transverse processes*³ are seen on the first piece.

Describe its development.

From four centres: one for each segment, the first piece commencing at birth; second, five to ten years; third, ten to fifteen years; fourth, fifteen to twenty years; coössification varies as to time and manner.

Give the muscular attachments.

Laterally the coccygei; behind the gluteus maximus and extensor coccygeus (when present); apex, sphincter ani; in front levator ani.

The Pelvis.

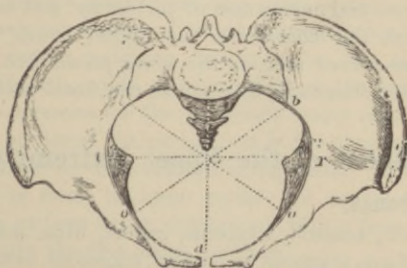
Describe the pelvis.

Formed by the two innominate bones, the sacrum and the coccyx, all above the ilio-pectineal line is called the *false pelvis*, consisting of the two *iliac fossæ*; all below, the *true pelvis*.

Describe the true pelvis.

Its *brim*, or inlet, somewhat heart-shaped, is formed by the linea ilio-pectinea at the sides, completed in front by the spine and

FIG. 32.



crest of the pubes, behind by the anterior margin of the base of the sacrum and promontory of the sacrum. Its average diameters in the female are, antero-posterior^d, four and one-half inches; transverse^{tr}, five and a quarter inches; the oblique^{ob}, five inches; its long axis, if extended, would pass from the middle of the coccyx to the umbilicus; in the male these measurements are diminished by at least one-half inch.

Describe the cavity.

This is bounded in front by the symphysis pubis, behind by the concavity of the sacrum and coccyx, on either side by the broad, smooth, quadrangular inner surface of the body of the ischium, forming a curved canal wider in the middle than at its outlets, measuring in depth at the symphysis one and one-half inches, three and one-half inches in the middle axial line, and four and one-half inches posteriorly, perhaps as much as five and one-half inches in males.

Describe the lower circumference of the pelvis.

This is called the *outlet*, is bounded on each side by the tuberosities of the ischium, the pubic arch in front and tip of the coccyx behind. Its diameters are four and one-quarter to four and three-quarters inches transverse, antero-posterior and oblique four and one-half increased to five by pressure on the coccyx; in the male, the diameters average three and one-half inches.

What are the chief differences between the male and female pelves?

The strength of the bones, distinctness of the muscular impressions, the depth and narrowness of the cavity, and large obturator foramina mark the *male pelvis*: the lighter bones, broader iliac fossæ, the less-curved sacrum, the wider pubic arch, and the universally greater diameters, distinguish the *female pelvis*.

Bones of the Upper Extremity.

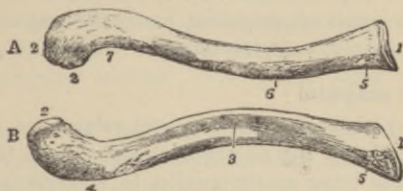
Name the bones.

The clavicle, scapula, humerus, radius, ulna, scaphoid, semi-lunar, cuneiform, pisiform, trapezium, trapezoid, os magnum, unci-form, five metacarpal, and fourteen phalangeal bones.

Describe the clavicle.

It is a long bone, curved like the italic letter *f*, its outer third flattened from above downward, and concave anteriorly; the inner two-thirds are cylindrical and convex anteriorly, and it extends

FIG. 33.



almost horizontally between the sternum and scapula, the two extremities being respectively termed the *sternal*¹ and *acromial*².

Describe the chief points presented by the clavicle, commencing at the outer extremity.

The upper surface has *impressions*, that in front for the deltoid,⁷ that behind for the trapezius; at the outer end is a *facet*² articulating with the acromium process of the scapula; at the posterior border, beneath, is the *conoid tubercle*,⁴ just above the coracoid process of scapula, for the conoid ligament; extending from the tubercle, forward and outward, nearly to the outer end of the anterior border is the *oblique line* for the trapezoid ligament; occasionally at the centre of the anterior border of the outer third is the *deltoid tubercle*. The under surface of the middle portion presents the *subclavian groove*³ for the same named muscle—here appears the *nutrient foramen* directed outward; the inner third of the superior border bears an *impression* for the sterno-mastoid muscle⁵ (A, Fig. 33), while the inner half of the anterior margin has another *impression* for the pectoralis major muscle. Beneath the posterior border of the sternal end is the *rhomboid impression*,⁵ for the rhomboid or costo-clavicular ligament. The *sternal end*¹ is triangular in form, its inner surface for articulation with the sternum, this surface being continuous with a facet beneath, for articulation with the first costal cartilage.

Give its development.

By two centres; one for the shaft earliest in the body (thirtieth day); one for sternal end (eighteenth to twentieth year); uniting about the twenty-fifth year.

Give the muscular attachments.

Sterno-cleido-mastoid, trapezius, pectoralis major, deltoid, subclavius, sterno-hyoid, and platysma.

Describe the scapula.

The shoulder-blade, a large, flat, triangular bone, extends from the first to the eighth ribs on the back and side of the thorax, its posterior margin lying nearly parallel to, and one inch from the spinous processes of the vertebræ.

The *venter* (anterior surface) or *subscapular fossa*¹ is concave, presents some transversely oblique ridges^{1,1,1}, for the tendinous intersections of the subscapular muscle, and a *marginal surface*¹⁵

FIG. 34.

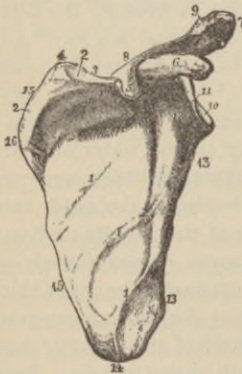
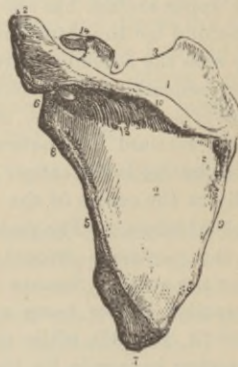


FIG. 35.



along the inner border—triangular above and below, linear between—for the serratus magnus muscle. The *angle* is the transverse depression at its upper part where the fossa is deepest.

The *dorsum*² (posterior surface) (Fig. 35) is divided by a prominent bony ridge, the *spine*¹⁰, affording attachment to the deltoid

and trapezius muscles and ending in the *acromion process*¹², into the *supra*-¹ and *infra-spinatus*² fossa, for the origin of similarly named muscles; in the latter is the *nutrient foramen*¹³. The external border presents a *marginal surface*⁵, divided by the *oblique line* at the junction of the lower and middle thirds, into two surfaces, the lower for the teres major, the upper for the teres minor muscle; about the junction of the middle and upper thirds of this border is a *groove* for the dorsalis scapulæ vessels. The spine posteriorly presents a *triangular surface*¹¹, over which plays the trapezius muscle.

The *acromion process*¹² (summit of the shoulder) is a triangular flattened process, curving outward, forward, and upward, to overhang the glenoid fossa; giving attachment along its outer margin to the deltoid; its inner margin, the trapezius; by its *apex* to the coraco-acromial ligament; and having on its inner margin, behind the apex, an articular *facet*⁹ (Fig. 34) for the clavicle.

Describe the coracoid process of the scapula.

The *coracoid process*⁶ (Fig. 34)¹⁴; (Fig. 35) (like a crow's beak) rises by a broad base from the upper part of the neck of the scapula, curving over the inner upper part of the glenoid cavity. To the anterior margin, near the tip, is attached the pectoralis minor muscle, and from its apex arise the short head of the biceps and the coraco-brachial muscle. To the inner side of the root is a rough *impression* for the conoid ligament, whence runs obliquely forward and outward on its upper surface a *ridge* for the trapezoid ligament.

Describe the scapular borders.

The superior border³—the shortest—presents, at the base of the coracoid, the *suprascapular notch*⁴ (Fig. 35), becoming a foramen when the transverse ligament is in situ, *through* which passes the suprascapular nerve, *above* which passes the suprascapular artery; from the border, just internal to the notch, arises the omo-hyoid muscle. The axillary border⁵—the thickest—presents just below the glenoid fossa a *rough surface*⁸ for the long head of the triceps muscle, succeeding which is a longitudinal *groove* for part of the subscapular muscle. The vertebral border⁹—the longest—presents

an *anterior lip* for the serratus magnus muscle, a *posterior lip* for the supra- and infra-spinatus muscles, and an *intermediate space* for the levator anguli scapulæ above, for the rhomboideus minor from the edge of the triangular base of the spine, and for the fibrous arch of the rhomboideus major muscles below.

Give the points of interest connected with the angles.

The *superior angle*⁴ (Fig. 34) affords partial attachment to the serratus magnus, to the levator anguli scapulæ, and supra-spinatus muscles. The *inferior angle*⁷ (Fig. 35) affords attachment to the teres major muscle, part of the serratus magnus, and (at times) a few fibres of the latissimus dorsi. The external angle or head⁶ presents a shallow pyriform glenoid *fossa*¹⁰ (Fig. 34) for the head of the humerus, deepened, in the fresh state, by the glenoid ligament attached around its circumference, from the upper part of which the long head of the biceps flexor cubiti arises. The *neck*⁸ (Fig. 35) is the slightly depressed surface surrounding the head; the *surgical neck* is well posterior to the head, passing through the suprascapular notch⁴⁻⁸ (Fig. 35).

How is this bone developed?

By seven centres; one for body (second foetal month); two for coracoid (one at first year, one at fifteenth to seventeenth year); two for acromion; one for vertebral border; one for inferior angle (all these last, fifteen to seventeen years); coössification (twenty-two to twenty-five years).

Give the muscular attachments.

Subscapular, supra- and infra-spinatus, deltoid, trapezius, omohyoid, serratus magnus, levator anguli scapulæ, rhomboideus minor and major, triceps, teres minor and major, biceps, coraco-brachial, pectoralis minor, platysma, occasionally latissimus dorsi.

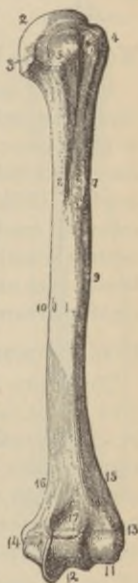
The Arm.

Describe the chief processes and the general characteristics of the humerus.

This, the only *arm* bone, articulates above with the scapula,

below with the ulna and radius. The upper extremity, the *head*², nearly hemispherical, facing upward, inward, and slightly backward, forms, with the glenoid fossa of the scapula, the shoulder or scapulo-humeral joint. Best marked superiorly is the constriction called the *anatomical neck*³, indicating the capsular attachment *above*; external to the head is the *greater tuberosity*⁴ with three facets for the supra- and infra-spinatus and teres minor muscles; in front, directed inward and forward, is the *lesser tuberosity*⁵ for the subscapular muscle; commencing between these two projections, and extending for the upper third of the bone, is the *bicipital groove*, passing obliquely downward and inward, lodging the long head of the biceps muscle; into the *anterior lip*⁷ of this groove is inserted the pectoralis major muscle, into the *posterior lip*⁸ the latissimus dorsi and teres major; while about the centre of the inner border of the bone is a *rough impression* for the coraco-brachial muscle, just below which is the *nutrient canal*¹⁰, directed downward. The constriction beneath the tuberosities is called the *surgical neck*. The *shaft*, cylindrical above, prismatic and flattened below, presents upon the middle of its outer surface a *roughness*⁹ for the deltoid muscle, and below it, winding from behind forward and downward, on the back of the bone, is the *musculo-spiral groove*, for the musculo-spiral nerve and superior profunda artery, internal and external to which arise the inner and outer heads of the triceps muscle. The lower extremity presents an *inner*¹⁴ (very prominent) and an *outer condyle*¹³, extending from each of which, upward on the shaft, are the *internal*¹⁶ and *external condyloid ridges*¹⁵; from the external ridge arise the external lateral ligament and *extensor* and *supinator* muscles; from the inner condyle and ridge arise the internal lateral ligament and the *flexor* and *round pronator* muscles. Projecting from the lower front portion of the outer condyle is the *radial head*¹¹ (capitellum), for the head of the radius; while internal to this, extending from the anterior to the posterior surface of the bone, is the pulley-like *trochlear surface*¹²

FIG. 36.



for the greater sigmoid cavity of the ulna. The *coronoid fossa*¹⁷ in front of the trochlea receives the coronoid process of the ulna during flexion of the forearm, while the *olecranon fossa*, similarly placed behind, accommodates the tip of the olecranon during extension.

How is the humerus developed?

By seven centres: one for shaft (fifth foetal week); one for head (first to second year); one (sometimes two) for tuberosities (second to third year; by fifth year the centres for head and tuberosities have coössified); one for radial head (second year); one for internal condyle (fifth year); one for trochlea (twelfth year); one for external condyle (thirteenth to fourteenth year). The lower centres are all coössified with the shaft by the sixteenth or seventeenth year except that for the internal condyle, which unites at eighteen years, while the head unites at the twentieth year.

Give the muscular attachments.

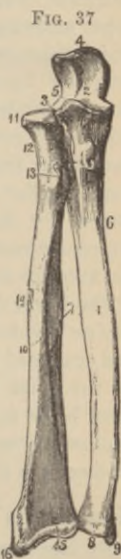
The supra- and infra-spinatus, teres minor, subscapular, pectoralis major, latissimus dorsi, teres major, deltoid, coraco-brachial, brachialis anticus, triceps, subanconeus, pronator radii teres, flexor carpi ulnaris, palmaris longus, flexor digitorum sublimis, flexor carpi radialis, supinator longus, extensor carpi radialis longior and brevior, extensor communis digitorum, extensor minimi digiti, extensor carpi ulnaris, anconeus, and supinator brevis.

The Forearm.

Describe the ulna.

This, the inner forearm bone¹, longer than the radius, forms the greater part of the articulation with the humerus, while it is excluded from the wrist-joint by the interarticular fibro-cartilage. Its upper extremity forms the point of the elbow. The *olecranon process*⁴ presents upon its anterior part a saddle-shaped articular surface which, with its continuation on the coronoid process, is the *greater sigmoid cavity*² for the trochlea of the humerus; continuous with this upon the outer side is the *lesser sigmoid cavity*³ for the head of the radius; to the posterior surface is attached the triceps

tendon, and the *apex* is accommodated by the olecranon fossa of the humerus during extension. Projecting forward below the olecranon is the *coronoid process*⁵, fitting into the same named fossa of the humerus during flexion, its upper surface forming part of the greater sigmoid cavity; it presents, where it joins the shaft, a tubercle for the oblique ligament, and a *rough impression* for the brachialis anticus muscle above and internally. At the front is a small *eminence* for the flexor sublimis digitorum, whence descends a *ridge* for the pronator radii teres. The *shaft*¹, large and prismatic above, smaller and rounded below, has on its anterior surface the *nutrient foramen*, directed upward, and by its *external sharp border*⁷ affords attachment to the interosseus ligament. The lower carpal extremity, or *head*⁸, articulating, by its outer surface, with the sigmoid cavity of the radius, and, by its lower, with the triangular fibro-cartilage, has projecting internally and behind, the *styloid process*⁹, to whose apex is attached the internal lateral ligament, to a depression at its base the fibro-cartilage; upon the posterior surface is a *groove* for the tendon of the ulno-carpal extensor.



How is this bone developed?

By three centres; one for shaft (eighth foetal week); one for head (fourth year); one for olecranon (tenth year, joining shaft at sixteenth year); head coëssified with shaft by twentieth year.

Give the muscular attachments.

Triceps, anconeus, flexor carpi ulnaris, brachialis anticus, pronator radii teres, flexor sublimis and profundus digitorum, flexor longus pollicis (occasionally), pronator quadratus, flexor and extensor carpi ulnaris, anconeus, supinator brevis, extensor ossis metacarpi and secundi internodii pollicis, and extensor indicis.

Describe the radius.

Shorter than the ulna, situated upon the outer side of the forearm, with a small upper extremity, forming only a small part of

the elbow-joint, its lower end is large, forming the chief part of the wrist-joint. It is slightly curved, and of a prismatic form. The *head*¹¹ (upper extremity) is cylindrical, with slightly cupped upper surface, articulating with the radial head of the humerus, by its sides, with the lesser sigmoid cavity of the ulna and the orbicular ligament by which it is embraced; the constriction beneath the head is the *neck*¹²; below, and to the inner side, is the *tuberosity*¹³, rough toward its posterior margin for the biceps tendon, smooth in front for a bursa; the *shaft*¹⁰ is prismoid, curved outward, smaller above than below, having a sharp internal *interosseous border*⁷ for the interosseous ligament, with the *nutrient foramen* directed upward at the junction of the middle and upper thirds of the anterior surface.

The lower *carpal extremity*¹⁵ has on its lower face an *articular surface* divided by a slight ridge into two facets for the *semilunar* and *scaphoid* bones; upon its inner side the shallow *sigmoid cavity* for the ulnar head; externally the *styloid process*¹⁶ giving attachment by its apex to the external lateral ligament, by its base to the supinator longus muscle; and on its posterior and external convex surfaces are five *grooves* for the extensor tendons.

How is this bone developed ?

By three centres; one for shaft (eighth fetal week); one for carpal extremity (second year); and one for head (fifth year, joins shaft at puberty); bone coössified by about twentieth year.

Give the muscular attachments.

The biceps, the supinator brevis, flexor digitorum sublimus and longus pollicis, pronator quadratus, the extensor ossis metacarpi and primi internodii pollicis, pronator radii teres, and supinator longus.

The Hand.

Into what segments is the hand divided ?

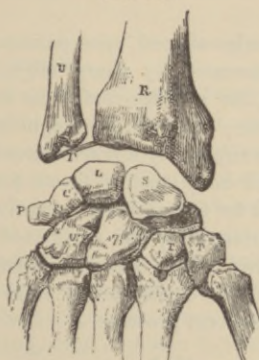Into the carpus (eight bones); metacarpus (five bones); and phalanges (fourteen bones); total, twenty-seven bones.

Describe the arrangement of the carpal bones.

They are placed in two rows of four each; thus, enumerating from the radial to the ulnar side, with palm upward; First, or *proximal row*: scaphoid^s, semilunar^l, cuneiform^c, pisiform^p.

Second, or *distal row*: trapezium^t, trapezoid^{1,t}, os magnum⁷, unciform^u.

FIG. 38.



With how many bones does each articulate?

Scaphoid, five; semilunar, five; cuneiform, three; pisiform, one; trapezium, four; trapezoid, four; os magnum, seven; unciform, five; total, thirty-four.

Describe the chief peculiarities of each bone.

The *scaphoid*^s (boat-shaped) has on the thumb side a tuberosity, a transverse groove on the dorsum parallel to the convex articular surface for radius; facets for os magnum and semilunar bones on its inner lower face; on its lower for the trapezium and trapezoid.

The *semilunar*^l (half-moon) presents a convex facet above for radius; on its outer face a semilunar facet for scaphoid; on its lower, a concave one for os magnum; a quadrilateral one on the inner face for cuneiform.

The *cuneiform*^c (wedge-shaped) has an oval facet in front for pisiform; one external for semilunar; an inferior concave facet for

unciform; a superior convex facet for interarticular fibro-cartilage.

The *pisiform*^v is rounded, with one ovoidal facet for cuneiform.

The *trapezium*^t is obliquely grooved on its palmar surface for the tendon of the flexor carpi radialis; superiorly is a concave facet for scaphoid; below, a saddle-shaped one for thumb-metacarpal; internally, one large concave facet for trapezoid, and a smaller for second metacarpal.

The *trapezoid*^{lt} is wedge-shaped, apex palmar, has four articular surfaces touching, separated by sharp edges, the external for trapezium; inferior (like a ridge-roof), for second metacarpal; internal, for os magnum; superior, for scaphoid.

The *os magnum*⁷ has superiorly a convex head for scaphoid and semilunar, a neck and body; below, facets for three metacarpal bones; externally, one for trapezoid; internally, one for unciform.

The *unciform*^u is triangular, has a sigmoid internal articular facet for cuneiform; two facets below for fourth and fifth metacarpals; one, external, for os magnum; from the palmar surface projects the curved unciform process.

When do these bones ossify?

Os magnum and unciform, during first year; cuneiform, third year; trapezium and semilunar, fifth year; scaphoid, sixth year; trapezoid, during eighth year; pisiform, about twelfth year.

(The muscular attachments to the carpal and tarsal bones will be given under the Muscular System.)

Describe the metacarpal bones.

They are five long bones, with shaft, head, and base. The *first metacarpal* (sometimes considered a phalanx) is shorter, has only one facet on base, and has one ossific centre for shaft (eighth foetal week), and one for *base* (third year). The *second metacarpal* has four facets on base for trapezium, trapezoid, os magnum, and third metacarpal; it, in common with the rest, has one ossific centre for shaft (eighth foetal week), and one for *head* (third year; they coössify by twentieth year). The *third metacarpal* articulates only with the os magnum, on the ulnar side has two small facets for fourth metacarpal, a single facet on the radial side for second

metacarpal, and the outer angle of its base is much prolonged. The *fourth metacarpal* has two facets for unciform and os magnum, a single facet on ulnar side for fifth metacarpal, and two small ones on radial side for third metacarpal. The *fifth metacarpal* articulates with unciform by a concavo-convex facet, has only a lateral facet on the radial side for fourth metacarpal, and on the ulnar side a prominent tubercle for the extensor carpi ulnaris tendon.

Describe the phalanges.

Fourteen in number—three for each finger, two for thumb—they are long bones, having a shaft, base, and condyles, except those of the distal row. The bases of first row, cup-shaped, articulate with heads of the metacarpals; those of second and third have a double concavity, separated by a median ridge, and articulate with the condyles of the row above; the distal extremities of the ungual phalanges have rough, horse-shoe shaped tubercles on their palmar surfaces for attachment of the pulp of the finger; they ossify by one centre for the shaft (eighth foetal week), and one for base (third to fifth year); uniting, from eighteen to twenty years.

LOWER EXTREMITY.

The Thigh.

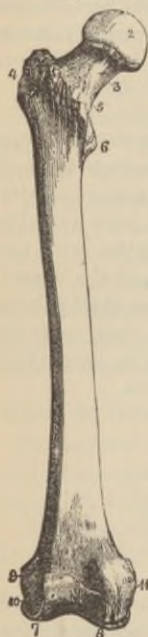
Describe the femur.

It is the longest bone of the skeleton, and inclines toward its fellow to bring the knee-joint near the centre of gravity during walking, this obliquity being greater in the female, from the breadth of the pelvis, and in a short than a tall person of either sex.

The *head*², forming rather more than a hemisphere, directed upward, inward, and forward, has behind and below its centre an ovoid *depression* for the ligamentum teres. The *neck*³, joining the head with the shaft, is flattened and pyramidal; in the adult male it forms an obtuse angle with the shaft; in the female it approaches a right angle; in very old and debilitated subjects its direction becomes horizontal. The *great trochanter*⁴ is a large, irregular,

quadrilateral eminence, directed upward, outward, and backward, marked on its external surface by a *diagonal line* for the gluteus medius; below and behind this is a smooth surface for a bursa beneath the gluteus maximus; in front, from above downward, are

FIG. 39.



inserted the internal obturator and gemelli muscles, the piriformis, and the gluteus minimus; upon its inner surface is the *digital fossa* for the tendon of the obturator internus muscle.

The *lesser trochanter*², small and conical, projects from the lower back part of the base of the neck, receiving the insertion of the psoas muscle above, and the iliacus below.

The *anterior*⁵ and *posterior intertrochanteric lines* connect these processes, the latter being the more prominent, while to the former is attached the anterior portion of the capsular ligament. Extending from the middle of the posterior intertrochanteric line, for about two inches down the shaft, is the *linea quadrati* for the quadratus femoris muscle.

The *shaft*¹, broad and cylindroid at either extremity, narrow and triangular in the centre, slightly curved forward, has its *nutrient foramen* at the junction of the middle and lower thirds of its posterior surface, directed upward; and from its anterior surface arise the crureus and subcrureus muscles.

The *linea aspera*, a prominent longitudinal ridge occupying the middle third of the posterior surface, has an external and an internal lip, and an intermediate space; above, it divides into three lines, one directed upward to base of greater, one to base of lesser trochanter, a third, the most internal continuous with the anterior *intertrochanteric line*, forming, with it, the *spiral line*⁵, while below the *linea aspera* bifurcates to inclose the smooth *popliteal space*, the inner division *grooved* for the femoral vessels. In general terms, this line and its subdivisions have attached the following muscles: the vastus internus and externus, the pectineus, the three adductors, the biceps and gluteus maximus.

Of the two *condyles*, the *internal*⁸ is the longer by about half an

inch, to bring both condyles on the same horizontal plane in the normally oblique position of the femur; above each condyle, behind, is a *depression* for the gastrocnemius (above the *external* the plantar muscle also originates); separating them is the *intercondyloid notch*, to whose sides are attached the crucial ligaments; in front, the condyles form a continuous cartilaginous-covered articular surface; the outer, as well as the inner condyle, presents a *tuberosity*⁹⁻¹¹ upon its free surface for the lateral ligaments, beneath which, on the outer condyle, is a *groove*¹⁰ for the tendon of origin of the popliteus muscle; above the *internal tuberosity*¹¹ is a small *tubercle* for the tendon of the adductor magnus.

Give the development of the femur.

By five centres; one for shaft (fifth foetal week); one for condyles (ninth foetal month); one for head (end of first year); one for greater trochanter (fourth year); one for lesser trochanter (thirteenth to fourteenth year); all coössified by twentieth year in the *reverse order of their appearance*.

Give the muscular attachments.

The three glutei, pyriformis, two obturators, gemelli, quadratus, psoas, iliacus, two vasti, biceps, pectineus, three adductors, crureus, subcrureus, gastrocnemius, plantaris, and popliteus.

The Patella.

Describe the patella.

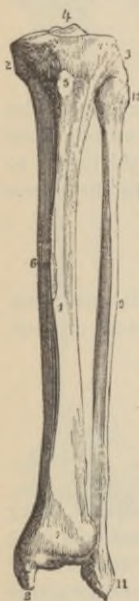
It is flat, triangular, placed at front of the knee-joint, and, being developed in the quadriceps tendon, is considered a sesamoid bone by some; the convex *anterior surface* is roughened; the *posterior surface* is divided by a vertical *ridge* into two smooth *facets* for either femoral condyle, the outer being the broader and deeper; the apex gives attachment to the ligamentum patella; and the superior and lateral borders to the rectus femoris, crureus, and vasti muscles. It is developed by one centre (about three years); the muscular attachments have been already given.

The Leg.

Describe the tibia.

The shin-bone, situated at the inner front part of the leg, is only second in length to the femur; the *head*²⁻³, or upper extremity, is large and expanded on each side into two lateral *tuberosities*²⁻³, bearing upon their upper surfaces smooth concave *ovoidal facets* for

FIG 40.



the femoral condyles, between which is the vertical, bifid *spine*⁴ for the extremities of the semilunar fibro-cartilages, the depressions in front and behind its base giving origin to the crucial ligaments. Below, medianally, in front of the head, is the *tubercle*⁵ for the ligamentum patellæ; separating the tuberosities behind is the *popliteal notch*, giving attachment to the posterior crucial ligament; on the posterior surface of the inner tuberosity is a transverse *groove* for the insertion of the semi-membranosus tendon; upon the back of the outer tuberosity, facing downward, is a *facet* for the head of the fibula; running obliquely from this facet, downward and inward, on the posterior surface, is the *oblique line* for the popliteal fascia, parts of the soleus, flexor longus digitorum, and tibialis posticus muscles; just below the line, directed downward, is the *nutrient canal*, the largest in the skeleton.

The prismoid shaft¹ has three borders, of which the anterior, called *crest* or *shin*⁶, and the external or *interosseous ridge*, for the interosseous membrane, only are of importance. The *lower extremity*⁷, smaller than the upper, has an inferior concave surface for the astragalus, an external rough triangular surface for articulation with the fibula; it is grooved posteriorly for the flexor longus pollicis tendon; has projecting downward, internally, the *internal malleolus*⁸, which articulates by its outer surface with the side of the astragalus, is grooved behind for the tibialis posticus and flexor longus digitorum tendons, and has attached to its tip the internal lateral ligament.

How is this bone developed ?

By three centres: One for shaft (seventh foetal week); one for head (at birth); one for lower end (second year); bone coössi-fied by twentieth year (some authors say twenty-fifth year).

Give the muscular attachments.

Semimembranosus, tibialis anticus and posticus, biceps, extensor and flexor longus digitorum, sartorius, gracilis, semitendinosus, popliteus, soleus, and quadriceps femoris.

Describe the fibula (peroneal bone).

It is long, slender, and is placed externally nearly parallel to the tibia.

The head¹⁰ or upper end articulates by a flattened facet with the external tibial tuberosity³, and is prolonged upward behind into the *styloid process* for the biceps tendon and the external lateral ligament; below and behind is attached the long external lateral ligament.

The *shaft*⁹, triangular and twisted, has three ridges, the internal or *interosseous ridge* being for same-named ligament; about the middle of the anterior internal surface is the *nutrient foramen* directed downward. The *external malleolus*¹¹ forming the lower extremity, longer than the internal, articulates by its inner surface with the outer side of the astragalus; is grooved behind for the peroneus longus and brevis tendons; to its summit is attached the middle, and to rough *depressions* in front and behind the anterior and posterior fasciculi of the external lateral ankle-ligament.

Describe its development.

By three centres: One for shaft (eighth foetal week); one for malleolus (second year); one for head (fourth year); bone coössi-fied by twenty-fifth year, but, *contrary to rule*, the lower epiphysis unites *first*.

Give the muscular attachments.

Biceps, soleus, three peroneals, the extensor and flexor of the great toe, and extensor longus digitorum, and tibialis posticus.

The Foot.

Into what segments are the bones of the foot divided ?

Into the *tarsus* (7); *metatarsus* (5); and *phalanges* (14); total, 26 bones.

Name the tarsal bones.

Calcaneum³ (os calcis), astragalus¹, cuboid⁸, scaphoid⁴, internal⁵, middle⁶, and external⁷ cuneiform.

Give the chief peculiarities of each tarsal bone.

The *astragalus*¹ has a large rounded *head*², a *neck*, a *body*¹, superiorly a *trochlear surface* broader in front than behind, for the tibia, and continuous with it on either side *facets* for the internal and external malleolus; the under surface presents two articular *facets*—that behind for the calcis, that in front partly for calcis but chiefly for the calcaneo-scaphoid ligament—separated by a groove for the calcaneo-astragaloid ligament, running obliquely forward and outward; it articulates with the tibia, fibula, os calcis, and scaphoid, and is *developed* by one centre (seventh foetal month).

The *os calcis*³, the largest tarsal bone, forms by its *tuberosity*³ behind the heel, has a *groove* on its upper surface to correspond to that of the astragalus; behind and in front of which are two articular *facets* for the same bone: on the inner side projects the *susten-taculum tali* supporting the internal articulating surface; beneath this process the inner surface of the bone is deeply concave for the flexor tendons, plantar vessels, and nerves; its anterior concavo-convex surface articulates with the cuboid; on the under surface are an *inner* and *outer tuberosity*; it articulates with the astragalus and cuboid, and is *developed* from two centres, one for main mass (sixth foetal month); one for tuberosity (tenth year); union after puberty.

The *cuboid* has one articular surface each for os calcis, external cuneiform, the fourth and fifth metatarsals, and sometimes the scaphoid; upon the under surface is a deep *groove* for the peroneus longus tendon, and behind this a *ridge* terminating externally in a *tuberosity*; it is *developed* from one centre (ninth foetal month).

The *scaphoid*, situated internally, is concave behind for the head of the astragalus; is convex in front with three *facets* for the three cuneiform bones; externally is a *facet* for the cuboid; and internally, below, is the *tuberosity* for part of the posterior tibial tendon; it is *developed* from one centre (fourth year).

The *internal cuneiform*, the largest, is placed at the inner side of the foot, has its base downward, upon which is the *tuberosity* for part of the tendon of the posterior tibial muscle; in front is a kidney-shaped *facet* for first metatarsal; externally are two *facets* for the second metatarsal in front, the middle cuneiform behind; posteriorly a *facet* for the scaphoid; it is *developed* by one centre (third year).

The *middle cuneiform*, the smallest, has its base upward, a triangular *facet* in front for second metatarsal, another behind for the scaphoid; along the posterior and superior borders of the inner face a *facet* for the internal cuneiform; and externally a smooth *facet* for the external cuneiform; it is *developed* by one centre (fourth year).

The *external cuneiform* is intermediate in size with base upward, has an anterior triangular *facet* for third metatarsal; another posterior for the scaphoid; two upon internal surface for second metatarsal and middle cuneiform; and two upon outer surface for fourth metatarsal and for cuboid: it is *developed* by one centre (first year).

Describe the metatarsal bones.

These five long bones have prismoid shafts⁹, anteriorly a *head* for articulation with the phalanges, posteriorly a *base* articulating with the tarsus and one another.

The *first metatarsal* is shorter, much stouter, and articulates only with the internal cuneiform: *developed* by one centre for *shaft* (seventh foetal week); one for *base* (fifth year), united by the twentieth year.

FIG. 41.



The *second metatarsal*, the longest, articulates posteriorly with the middle cuneiform, and laterally with the other cuneiforms, presenting, therefore, three *facets* on base; *developed* by one centre (seventh foetal week) for *shaft*, one for *head* (third year), united at twenty years.

The *third metatarsal* has a *facet* on base for external cuneiform, two on its inner side and one on its outer for the contiguous metatarsal; *developed* like second.

The *fourth metatarsal* articulates behind with cuboid, has a *facet* on inner side divided into anterior portion for third metatarsal, a posterior for external cuneiform, and externally one *facet* for fifth metatarsal: *developed* like second.

The *fifth metatarsal* has a triangular oblique surface for the cuboid, continuous internally with one for fourth metatarsal; externally a tubercular *eminence*; *developed* like second.

Describe the phalanges.

They resemble closely those of the hand, except that they are strongly compressed from side to side, instead of from before backward: ossification also, similar but later. Thus, the shaft centres appear from two to four months, except distal at seventh foetal week.

THE ARTICULATIONS.

How are the articulations classed ?

In three divisions; 1. *Synarthroses*, immovable, as most of cranial articulations; 2. *Amphiarthroses*, including *synchondroses*, or *symphyses*, yielding (limited motion), as those between the vertebral bodies, the pubic and sacro-iliac symphyses; 3. *Diarthroses*, freely movable.

Into what classes are the synarthroses divided ?

1. *Sutura vera*, consisting of interlocking serrations, including three sub-classes of *S. dentata*, when the bony projections are tooth-like, as the inter-parietal suture; *S. serrata*, when like a fine saw, as the inter-frontal; *S. limbosa*, when the edges are bevelled in addition to dentation, as the fronto-parietal. The *Sutura notha* (false

sutures) include *S. squamosa*, formed by two overlapping bevelled edges, as the squamo-parietal suture; and the *S. harmonia*, mere apposition of roughened surfaces, as the two superior maxillary bones.

2. *Schindelysis*, where a thin edge is received into a cleft or fissure, as the vomer between the superior maxillary bones.

3. *Gomphosis*, the insertion of a conical process into a socket, as teeth in their alveoli (not really a bony articulation, as teeth are *not* bones).

How are diarthroses classed?

As *arthrodia*, gliding joints—the articular processes of the vertebrae; *enarthroses*, ball-and-socket joint—hip- or shoulder-joints: *ginglymus*, hinge-joint—elbow-joint; *diarthrosis rotatoria*, or *lateral ginglymus*, a pivot turning within a ring, or a ring on a pivot, as the superior radio-ulnar and atlo-odontoid.

What varieties of motion do joints enjoy?

Flexion, extension, adduction, abduction, circumduction (a combination *in succession* of the four preceding), rotation, and gliding.

What structures are essential to the formation of each of the three classes of articulations?

For synarthroses, two or more bones, an interposed layer of fibrous tissue (sutural ligament) or, perhaps, cartilage (base of the skull); *symphyses*, an interposed bond of fibro-cartilage, with strong bands of white fibrous tissue, *i. e.*, *ligaments* (ligaments are sometimes composed of yellow elastic tissue, as the ligamenta subflava or ligamentum nuchæ); *diarthroses*, two or more cartilaginous-coated surfaces (reducing friction), sometimes inter-articular fibro-cartilages to deepen joint surfaces, as those of the knee- and temporo-maxillary joints, a complete fibrous capsule, and often additional ligamentous bands, some inter-articular, *i. e.*, within the joint cavity, and a synovial (serous) membrane lining the interior of the capsule, but not extending upon the cartilages; a similar membrane also forms sacs (*bursæ*) outside the joints, with which they often communicate, serving to reduce friction of the tendons, ligaments, etc.; the layer of bone beneath the articular

cartilage is denser, contains neither Haversian canals nor canaliculi, and has larger lacunæ.

What is the rule as regards the nerve supply of joints?

The interior of the joint, the muscles moving it, and the skin over their insertions, are supplied by the same trunk or trunks of nerves (this explains the reflex contractions of diseased joints).

Describe the vertebral articulations.

Formed by the contiguous surfaces of the vertebral bodies and articular processes, their ligaments are as follows:

An *intervertebral connecting fibro-cartilage*, between the bodies of all true vertebræ, except the atlas and axis.

An *anterior common ligament*³ passing medianally over the fronts of the vertebral bodies, most firmly attached to their margins.

A *posterior common ligament*, similarly disposed behind.

Short intervertebral ligaments, fibres running at most over three vertebræ, firmly uniting the bodies where the anterior and posterior common ligaments are deficient.

Ligamenta subflava, of yellow elastic tissue, connecting the laminae.

Supra- and inter-spinous, the former connecting the tips, the latter the remainder of the spinous processes.

*Capsular*⁶, enclosing the articular processes, and lined with synovial membrane.

Inter-transverse, connecting transverse processes; *nerves*, spinal in each region; *arteries*, vertebral and ascending cervical arteries in neck, intercostals in dorsal region, lumbar in loin.

Describe the occipito-atloid articulation.

It is a ginglymo arthrodial joint formed by the condyles of the occipital bone and the superior articulating processes of the atlas. Its ligaments are,

An *anterior occipito atlantal*² (Fig. 42), extending from the anterior margin of the foramen magnum to the anterior arch of the atlas, about one inch broad, blending on either side with the capsular ligaments.

A *posterior occipito-atlantal*, much broader, from the posterior margin of the foramen magnum between the condyles, to the pos-

tero-superior border of the posterior arch of the atlas, and is incomplete on each side for the ingress of the vertebral artery, and egress of the suboccipital nerve.

Two *capsular ligaments*⁷, lined with synovial membrane, surrounding the articular surfaces.

Two *lateral* (or *anterior oblique*), passing upward and inward from the transverse process beyond the vertebral foramen to the inner edge of the jugular foramen; *nerve*, suboccipital; *arteries*, from vertebral.

Describe the atlo-axoidean points.

The lateral joints are arthrodia, that between the atlas and odontoid process a double diarthrosis rotatoria. The ligaments of the lateral joints and arches are,

The *anterior atlanto-axoidean*⁴, membranous, passing between lower front border of atlas to front of the axis.

The *posterior atlanto-axoidean*, stretching between the postero-inferior edge of the ring of the atlas to the superior edge of the arch of the axis behind; it is pierced on each side by the second spinal nerve.

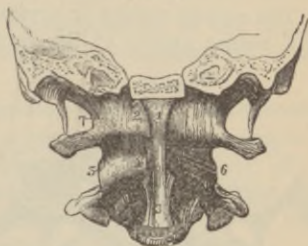
The *anterior*¹⁻³ and *posterior common* ligaments are continued over the median portions of the above to the occiput.

Two *capsulars*^{5,6}, synovial-lined, surrounding the articulating processes.

The ligaments of the central atlanto-axoidean joints are:

The *transverse*² (Fig. 43), extending between the tubercles on the inner surface of each lateral mass of the atlas; it holds the odontoid process in place, and between the two is a synovial membrane surrounded by a *capsule*, the *odonto-transverse joint*; between the odontoid process and the posterior surface of the anterior arch of the atlas, is the atlo-odontoid articulation, surrounded by a *capsule* lined with synovial membrane; passing upward and downward, are two strong vertical bands, attached above to the cranial surface

FIG. 42.



of the basilar margin of the foramen magnum, below, to the upper half of the body of the axis, forming the *occipito-axioidan ligament*³⁻⁴, or vertical portion of the *crucial ligament*; *nerves*, all these joints are supplied by the second cervical or loop between it and the suboccipital; *arteries*, are branches of vertebral.

What other ligaments connect the axis and occiput ?

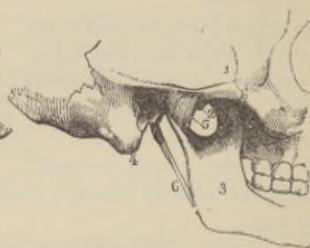
The *posterior common ligament*¹ extends upward, to be attached far up the basilar process; beneath this is,

The *occipito-cervical* or *cervico-basilar ligament*, attached above to the basilar groove of the occiput, below, to the third cervical

FIG. 43.

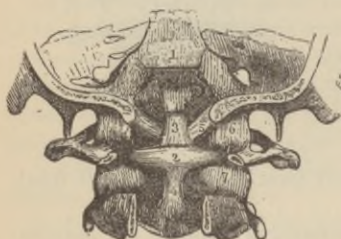

FIG. 44.



body and that of the axis; (next comes the vertical part of the crucial already described); deepest of all are the,

Occipito-odontoid, or *check*⁵, extending from the sides of the apex of the odontoid to inner edge of the anterior portion of the occipital condyles, while stretching between the odontoid tip and the under surface of the basilar process close to the foramen magnum, is the

Central occipito-odontoid, or *ligamentum suspensorium*.

Describe the temporo-maxillary articulation.

The upper compartment is arthrodial, formed by the glenoid fossa and eminentia articularis of the temporal bone and the upper surface of the fibro-cartilage; the lower is ginglymoid, between the under surface of the fibro-cartilage and the condyle of the lower jaw. The ligaments are *capsular*, passing between maxillary and temporal bones near their margins, consisting of ligamentous fibres, which are thicker at certain parts, and are described as

The *external lateral ligament*⁵, attached above to nearly the whole length of the lower edge of the zygoma and its tubercle, below to the outer side of the neck of the condyle of the jaw.

The *short internal lateral ligament*, extending between the spine of the sphenoid and inner edge of the glenoid fossa, and a ridge on the inner side of the neck of the condyle.

The *long internal lateral ligament*, stretching between the spine of the sphenoid and the forepart of the tip of the inferior dental foramen.

The *inter-articular fibro-cartilage*, concavo-convex on the upper surface, concave obliquely transversely below, dividing the joint into two separate synovial cavities.

The *stylo-maxillary ligament*⁶, extending from the styloid process to the angle of the jaw, is really a process of the deep fascia; *nerves*, the masseteric and auriculo-temporal branches of the inferior maxillary nerve; *arteries*, temporal, middle meningeal, ascending pharyngeal, posterior auricular, tympanic branch of the internal maxillary and ascending palatine.

Describe the costo-vertebral articulations.

These are each formed (1) between the head of a rib and the bodies of two adjoining vertebræ (except first, tenth, eleventh, and twelfth, which articulate with but one vertebra each), being *ginglymoid*; and (2) between the tubercle of each rib (except eleventh and twelfth) and the transverse process of a vertebra, and is arthroïdial.

Describe the costo-central articulations.

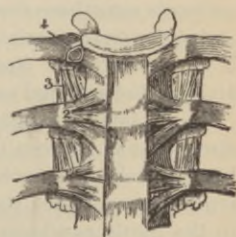
Ginglymoid, the ligaments are (1):

A *capsular ligament*⁴, attached all around each articular surface, the synovial lining being subdivided into two cavities by the

*Inter-articular, or costo-vertebral ligament*⁴, passing between the ridge on the head of the rib to the intervertebral fibro-cartilage.

The *stellate ligament*², arising from the

FIG. 45.



anterior surface of the neck of the rib, whence the fibres radiate to the vertebra next above and below to the one the rib belongs to, and to the intervertebral disk; *nerves*, anterior branches of spinal nerves; *arteries*, the intercostals.

Describe the costo-transverse articulations.

Arthrodial, ten in number, their ligaments are:

Capsular, attached beyond the margins of the articular facets.

*Superior costo-transverse*³ (except first rib), passing between upper border of neck of rib to lower margin of transverse process of the vertebra above.

Middle costo-transverse, connecting the back of neck of rib with the contiguous portion of transverse process of vertebra to which rib belongs.

Posterior costo-transverse, stretching from the tip of transverse process to rough projection beyond facet on the tubercle of rib; *nerves*, posterior branches of dorsal nerves; *arteries*, intercostals and posterior spinal.

Describe the (1) costo-sternal articulations, (2) the connection between the ribs and costal cartilages, and (3) the interchondral joints.

(1) The first is *synarthrodial*, the other six joints are *ginglymoid*.

The *costal* (2) *cartilages* are firmly attached to the cup-like depression at the end of each rib, and by the periosteum continued over to form the perichondrium; in like manner, the cartilage of the first rib unites with the sternum. The cartilages of the remaining six ribs are bound to the sternum by a,

Complete capsular ligament, the anterior and posterior thicker segments sometimes described as,

Anterior and posterior costo sternal ligaments. Occasionally there is an *interarticular ligament*, notably in the second costal joint, dividing the synovial cavity into two.

The (3) interchondral articulations, *arthrodial*, are usually, but not always, found between the edges of the fifth to tenth ribs, inclusive, having each an *interchondral ligament* and a *capsular*, lined with synovial membrane; they are commonly found only from the sixth to the ninth cartilages; in addition, the *costo-xiphoid ligament*

binds the xiphoid cartilage and sixth and seventh cartilages together; *nerves*, intercostals; *arteries*, internal mammary or its branches.

Describe the ligaments of the sternum.

All three segments are bound together by the so-called, *Anterior and posterior ligaments*, with a layer of cartilage between the manubrium and gladiolus (an amphiarthrodial joint, that between ensiform cartilage and gladiolus being synarthrodial).

Describe the sacro-vertebral articulation.

Similar to other vertebral articulations, but has, in addition, The *sacro-lumbar ligament*, extending from the transverse processes, pedicles, and body of the fifth lumbar vertebra to the non-articular portions of the base of the sacrum and periosteum of the contiguous portions of ilium.

The *ilio-lumbar ligament*¹ (Fig. 46), extending from the front surface and back of the tip of the transverse processes of the fifth, and lower edge and front surface, the transverse processes and pedicles of the fourth lumbar vertebra, to the back part of the iliac crest; *nerves*, fourth and fifth lumbar, sympathetic; *arteries*, ilio-lumbar, last lumbar, lateral sacral.

Describe the sacro-iliac articulations.

They are *amphiarthrodial*, formed between the auricular surfaces of the ilium and sacrum, and have the following ligaments upon each side, in addition to the symphyseal cartilage:

The *anterior sacro-iliac*³ (Fig. 47), from the first three pieces of the sacrum to the ilium above the great sacro-iliac foramen.

The *posterior sacro-iliac*² (Fig. 46), very strong, extending between back of the sacrum and posterior two inches of the iliac crest, including the posterior superior spine.

The *oblique*, stretching between the third transverse tubercle of the sacrum to the posterior superior iliac spine.

Superior and inferior, bands of fibrous tissue closing in the joint above and below.

The *interarticular* (interosseous), strongest of all, consists of numerous ligamentous bands passing between the contiguous

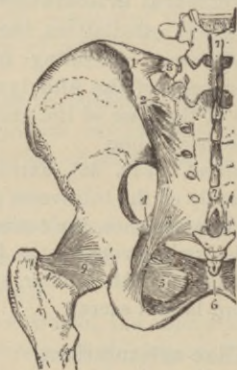
rough surfaces of the sacrum and ilium; *nerves*, from posterior sacral and lumbo-sacral cords; *arteries*, gluteal, ilio-lumbar, and sacral spinal.

Describe the ligaments connecting the sacrum and ischiatic bones on each side.

They are the,

*Greater sacro-sciatic*³, thin, triangular, passing from posterior inferior iliac spine, fourth and fifth transverse sacral tubercles and

FIG. 46.



lower lateral margins of sacrum and coccyx, to the inner margin of the ischiatic tuberosity.

The *lesser sacro-sciatic*⁴, posterior to former, of same shape, stretching between lateral margins of sacrum and coccyx, and the spine of the ischium.

These ligaments convert the two sacro-sciatic notches into the *greater* (by lesser ligament) and *lesser* (by greater ligament) sacro-sciatic foramina, described under iliac and ischiatic bones.

Describe the sacro-coccygeal articulation.

Amphiarthrodial, its ligaments are,

An *interarticular fibro-cartilage*, like that of a vertebra.

An *anterior sacro-coccygeal*, a continuation of the anterior common vertebral.

A *posterior sacro-coccygeal*, a continuation of the posterior common vertebral.

Inter-cornual and *inter-transverse* bands, connecting parts of same name; *nerves*, anterior and posterior branches of the fifth sacral and coccygeal, posterior division of fourth, and probably second and third sacral; *arteries*, lateral and median sacral.

Describe the pubic articulation.

Amphiarthrodial, between the two pubic bones; its ligaments are
An *interosseus fibro-cartilage*.

A *supra-pubic*, extending along crest of pubes on each side, blending with fibro-cartilage.

A *posterior*, little more than periosteum.

An *anterior*, thick, strong, decussating, attached to contiguous portions of body and rami.

An *inferior*, or *sub-pubic*, arched, filling up angle between pubic rami; *nerves* and *arteries* of no special moment.

The *obturator ligament*⁵ is a fibrous membrane filling the same named foramen, except at upper outer part.

Describe the sterno-clavicular articulation.

An *arthrodial* joint formed between the sternal end of the clavicle, and the sternum and cartilage of the first rib, having an inter-articular fibro-cartilage usually dividing the joint into two distinct synovial sacs; its ligaments are,

A *capsular* (usually described as anterior, posterior, etc.) passing between the articular margins, and firmly connected with the fibro-cartilage.

The *inter-clavicular*, passing from the posterior superior angle of the inner extremity of each clavicle, and attached to the sternum between.

The *rhomboid*, or *costo-clavicular*, stretching from the upper border of the first costal cartilage to the rhomboid impression of the clavicle; *nerves*, from descendens noni; *arteries*, contiguous muscular branches.

Describe the acromio-clavicular articulation.

An *arthrodial* joint formed by the outer extremity of the clavicle and the acromion process of the scapula; it frequently has an inter-

articular fibro-cartilage and two synovial sacs, otherwise there is only one sac; its ligaments are,

The *capsular*¹, attached to anterior and posterior borders¹, upper and lower surfaces of the acromion and clavicle.

The *coraco-clavicular*², composed of the *conoid*², conical, attached by apex to base of coracoid process, by base to conoid tubercle of clavicle and a line internal to it.

*Trapezoid*², broad and thin, quadrilateral, stretching between ridge on upper surface of coracoid to oblique line on under surface of clavicle; *nerves*, supra-scapular, anterior circumflex *arteries*, supra-scapular, anterior circumflex, acromial thoracic.

What ligaments bind together the scapular processes?

The *coraco-acromial*³, a triangular flat band, attached by apex to summit of acromion, by base all along outer border of coracoid process.

What other ligament of the scapula has not yet been described?

The *transverse*⁴, bridging across the supra-scapular notch.

Describe the shoulder-joint.

An enarthrodial joint formed by head of the humerus and glenoid fossa of the scapula. Its synovial membrane is reflected upon the tendons of the biceps, subscapular, and infra-spinatus muscles, and the joint has numerous bursæ in its vicinity, with some of which it communicates, notably the subacromial and subscapular; the ligaments are,

*Capsular*⁵, from the margin of the glenoid fossa above, below, and behind, in front extending up on the venter half an inch or more, to be attached by its upper half to the anatomical neck of the humerus, its lower some distance from the articular margin.

*Coraco-humeral*⁶, a superadded band stretching from coracoid process of scapula to greater humeral tuberosity.

The *glenoid*, a dense fibro-cartilage, triangular in cross-section, attached to circumference of fossa, deepening the socket, and continuous above with the long head of biceps muscle⁷, which really serves as one of the *chief ligaments*; *nerves*, supra-scapular, cir-

cumflex, subscapulars; *arteries*, supra-scapular, subscapular, dorsalis scapulae, anterior and posterior circumflex.

Describe the elbow-joint.

Ginglymoid, formed by lower end of the humerus, greater sigmoid cavity of ulna and head of radius, its ligaments are,

FIG. 47.

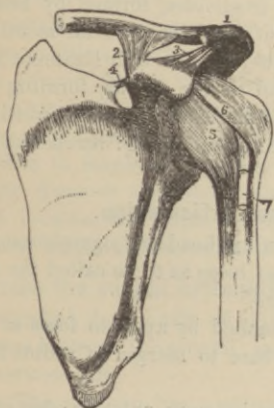
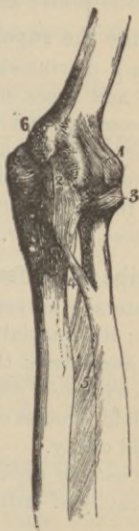

FIG. 48.



A *capsule*¹, large, capacious, and usually described as *anterior*, *posterior*, *internal*, and *external ligaments*.

The *anterior segment*¹ extends from humerus, above articular surface and coronoid fossa, to front of coronoid process of ulna and neck of radius.

The *posterior segment* extends from the back of the humerus, from condyle to condyle, and above the olecranon fossa, to be attached all around the olecranon process, close to its articular margin, and to back of neck of the radius and coronary ligament of the same.

The *external lateral* radiates from lower part of condyle to outer side of neck of radius and coronary ligament.

The *internal lateral*², triangular, rises from antero-inferior aspect of inner condyle, and is attached to inner side of shaft of ulna and olecranon process; *nerves*, musculo-cutaneous, ulnar, median, musculo-spiral; *arteries*, the two profunda arteries, anastomotica magna, anterior and posterior ulnar recurrents, posterior interosseous recurrent, and radial recurrent.

Describe the superior radio-ulnar articulation.

It is a diarthrosis rotatoria, or trochoides, formed by head of radius and lesser sigmoid cavity of ulna, its synovial membrane being continuous with that of elbow-joint; its only ligament is the

*Orbicular*³, surrounding the head of the radius, forming only three-fourths of a circle by most of its fibres, but some, continued below the sigmoid cavity, form a complete circle: *nerves* and *arteries*, those of elbow.

Describe the inferior radio-ulnar articulation.

A lateral ginglymus, formed by ulnar head and sigmoid cavity of radius; its synovial membrane is so loose as to be called the *membrana sacciformis*; the ligaments are,

The *triangular fibro-cartilage*, attached by apex to fossa at base of styloid process of ulna, by its base to margin of radius below sigmoid cavity.

The *anterior radio-ulnar* stretches between anterior edge of sigmoid cavity of radius to rough surface above articular surface of ulna.

The *posterior radio-ulnar* is similarly attached behind; *nerves*, median and posterior interosseous; *arteries*, anterior and posterior interosseous and carpal arch.

What other ligaments bind the radius and ulna together?

The *interosseous membrane*⁵, passing obliquely downward from the interosseous ridge of the ulna to that of the radius.

The *oblique*⁴, attached to the tubercle at base of coronoid process of ulna above, and below to the lower posterior edge of the tubercle of radius; *nerves* and *arteries* are from anterior interosseous nerve and artery.

Describe the wrist-joint.

Is ginglymoid, with a hinge-movement, not only of flexion and extension, but adduction and abduction, a combination of these producing circumduction, thus providing a joint with nearly every movement of a ball-and-socket joint, without its insecurity. It is formed between the radius and triangular fibro-cartilage above, and the first row of carpal bones below; its ligaments are,

An *anterior radio-carpal*, passing between the radius above the articular face and the fibro-cartilage, and the first and second rows of carpal bones.

A *posterior radio-carpal*, similarly disposed, except that, above, it is in addition attached to styloid process of ulna.

An *internal lateral*, fan-shaped, passing from styloid process of ulna to pisiform, and side and back of cuneiform bones.

An *external lateral*, radiating from tip and front of styloid process of radius to scaphoid, os magnum, and trapezium; the *posterior annular ligament* also assists the wrist ligaments proper; *nerves*, ulnar, median, and posterior interosseous; *arteries*, anterior and posterior carpal arches, radial and ulnar.

Describe the carpal articulations.

Arthrodial, they consist of (1) the joints between the first row; (2) those between the second; and (3) those between the two rows, the *medio-carpal*.

(1) The *pisiform* has a separate capsular ligament, with two bands connecting it with the unciform and base of fifth metacarpal, and a separate synovial membrane; the other three bones of this row are connected by two

Interosseous ligaments, between scaphoid and lunar, and lunar and cuneiform; and

Two dorsal and two palmar ligaments, binding together the same bones.

(2) The bones (4) of second row have

Three interosseous ligaments, connecting the os magnum with the trapezoid externally, the unciform internally; a third between the trapezium and trapezoid; and

Three dorsal and three palmar ligaments, passing between the contiguous bony surfaces.

(3) The two rows are united by

A *dorsal and palmar ligament* and *two laterals*, continuous with those of the wrist-joint; the *anterior annular ligament*, passing from the hook of the unciform and from pisiform to the trapezium and scaphoid bones, is an important carpal ligament. The synovial membrane is common to all the carpal joints, except *pisiform*; *nerves*, posterior interosseous, median and ulnar; *arteries*, anterior and posterior carpal of radial and ulnar, carpal of anterior interosseous, interosseous recurrent, carpal of deep palmar arch, and terminal twigs of anterior and posterior interosseous.

Describe the carpo-metacarpal articulations.

That of thumb is *arthrodial*, and enjoys all movements but rotation of the metacarpal on its own axis; it possesses a distinct synovial sac, and its only ligament is the

Capsule attached around the articular surfaces of trapezium and first metacarpal.

The other four metacarpals form *arthrodial* joints with the adjacent carpal bones, with three *dorsal ligaments*, passing from trapezium, trapezoid, and os magnum to second bone; *two ligaments* from os magnum to third; *two ligaments*—one from magnum, the other from cuneiform—to fourth; *one ligament* connecting the fifth metacarpal and unciform.

One palmar ligament passes from trapezium to second metacarpal; *one ligament* each from trapezium, magnum, and unciform to third; *one ligament* connects unciform and fourth bone; *one ligament* passes from unciform to fifth metacarpal.

An *interosseous ligament* connects the contiguous inferior angles of os magnum and unciform with adjacent surfaces of third and fourth metacarpal bones; the *synovial* membrane is that common to intercarpal joints, sometimes the joint formed between fourth and fifth metacarpals and unciform forms a separate synovial sac; *nerves* and *arteries* are same as medio-carpal joint.

Describe the union of the metacarpal bones with one another.

That of the thumb is isolated; the bases of the others are in contact, forming *arthrodial* joints, lined by prolongations of syno-

vial sac of carpus, and are bound together by *palmar, dorsal, and interosseous ligaments*; a *transverse ligament* binds together their heads.

Describe the metacarpo-phalangeal and interphalangeal articulations.

Ginglymoid, they are connected by *two lateral ligaments*, and an *anterior fibro cartilage, or glenoid ligament*, except for thumb, where this is replaced by two *sesamoid bones*, while behind an expansion of the extensor tendon and some loose areolar tissue completes each little synovial lined capsule; *nerves and arteries* from digitals; the *inter-phalangeal* joints resemble the metacarpo-phalangeal in every respect.

Describe the hip-joint.

An *enarthrodial*, but not so freely moving joint as that of the shoulder, it is formed by the head of the femur and the acetabulum on the os innominatum; the ligaments are

The *capsular*⁹, arising near to acetabular margin, and from outer surface of the transverse ligament, it is attached at the femur, in front to the trochanter major, the spiral line (chiefly formed by anterior intertrochanteric line), and behind, to the neck from one-half to two-thirds of an inch from the posterior intertrochanteric line; the capsule has a thicker anterior segment, or superadded band, called

The *ilio-femoral*⁸, or *Y-ligament*, arising from the anterior inferior iliac spine to be attached to the anterior intertrochanteric line, the outer and inner margins so well marked as to seem like distinct ligamentous bands.

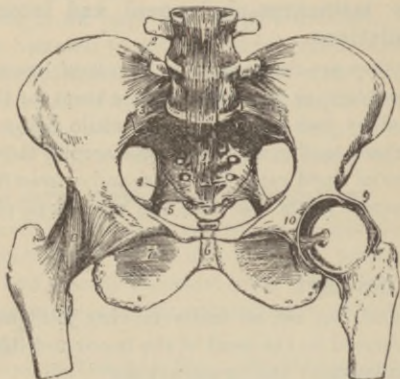
The *ligamentum teres*¹⁰, arising by separate heads from each side of the cotyloid notch externally, passes beneath the transverse ligament covered by the synovial membrane to be attached to a depression on the head of the femur.

Cotyloid, a marginal fibro-cartilage attached all around the acetabular margin and upper surface of the transverse ligament, deepening the socket.

Transverse, a band of unyielding ligamentous fibres bridging the cotyloid notch, converting it into a foramen; *nerves*, from anterior

crural, obturator, accessory obturator, nerve to quadratus femoris muscle, great sciatic or lower part of sacral plexus; *arteries*, inter-

FIG. 49.



nal and external circumflex, obturator, gluteal, and sciatic. The *synovial membrane* commonly communicates with the bursa beneath the ilio-psoas muscle.

Describe the knee-joint.

Ginglymoid, formed by condyles of femur, upper surface of tibial head, and patella, it has the largest *synovial sac* of any joint, sending a prolongation beneath the popliteus muscle and either another two or three inches up the front of the femur, or communicating with a bursa there placed beneath the quadriceps tendon; the bursa between the semi-membranosus and internal head of gastrocnemius, and inner condyle, usually communicates with the joint, and often one or more of the remaining bursæ near the articulation; its ligaments consist of,

An *anterior* or *ligamentum patella*^s (Fig. 51), a continuation of the quadriceps tendon attached to the tubercle of the tibia below, which, with the fibrous hood formed by the two vasti tendons attached to the patellar margins and the oblique lines on the head

of tibia extending upward from the tubercle, cover in the joint in front blending with the lateral ligaments.

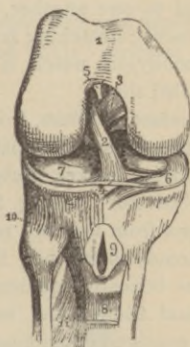
The *posterior* or *ligamentum Winslowii*⁸ (Fig. 50), formed of dense, interlacing fibres, having incorporated with it part of the semi-membranosus tendon⁷ (Fig. 50), arises close above the femoral condyles and intercondyloid notch from one lateral ligament to the other, and is fixed to the border of the outer tibial tuberosity, the bone below the popliteal notch and the shaft below the inner tuberosity.

The *internal lateral*⁶, a strong flat band passing from the depression on inner femoral condyle to the inner border and surface of

FIG. 50.

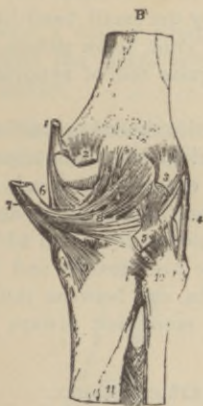

FIG. 51.



shaft of tibia for an inch and a half below the head: it is attached to the internal semilunar fibro-cartilage.

The *external laterals*, two in number:

The *long*⁴, a rounded cord attached above to external tuberosity of femur, below to outer part of head of fibula embraced by tendon of biceps;

The *short*, behind and parallel to above, attached above to lower part of outer femoral tuberosity, below to summit of styloid process of fibula; it is intimately connected with capsule; all the preceding ligaments together form a complete

Capsular ligament, within which are,

The internal ligaments;

*The anterior crucial*², from inner side of depression in front of spine of tibia to inner back part of outer condyle of femur;

*The posterior crucial*³, from back part of depression behind tibial spine and popliteal notch to outer fore part of inner condyle—both crucial ligaments are attached to respective extremities of external semilunar fibro-cartilage.

*Two semilunar fibro-cartilages*⁶⁻⁷ (Fig. 51), attached by extremities to the depressions in front and behind the spine of tibia; they serve to deepen the sockets for femoral condyles, and are attached to head of tibia by the *coronary ligaments*, short bands passing between their outer margins and the tibial head, they are also connected to one another, in front, by the small band-like *transverse ligament*⁴; stretching from front of joint, below patella, to front of intercondyloid notch, is the triangular fold of synovial membrane called the

Ligamentum mucosum, from whose sides extend upward and outward to the sides of the patella, the fringe-like folds termed *ligamenta alaria*; *nerves*, internal and external popliteal, anterior crural, obturator; *arteries*, five articular from popliteal, anastomotic magna from femoral, recurrent anterior tibial; in addition to bursa, already mentioned there is one over patella and its ligament, one beneath ligamentum patellæ, one between inner hamstrings and tibial head, and one or more, not always present, beneath contiguous tendons.

Describe the inferior tibio-fibular articulation.

Arthrodial, formed between facets on fibular head and outer tuberosity of tibia, its ligaments are really a *capsule*, described as,

*Anterior superior tibio-fibular*¹⁰ (Fig. 51), directed obliquely upward and inward from fibula to tibia,

*Posterior superior tibio-fibular*¹⁰ (Fig. 50), similarly disposed behind; the synovial membrane communicates with that of knee in twenty-five per cent. of specimens; *nerves*, from external popliteal; *arteries*, some of those of knee.

Describe the so-called middle tibio-fibular articulation.

The contiguous borders of the bones are connected by the *inter-*

*osseous membrane*¹¹ (Fig. 51), deficient above for passage of anterior tibial artery, below it is perforated by anterior peroneal vessels; its fibres pass from fibula upward to tibia.

Describe the inferior tibio-fibular joint.

Arthrodial, formed superiorly by the rough surfaces of the contiguous bones, below by small cartilage-coated surfaces; its synovial membrane is part of that of the ankle.

The ligaments are:

Inferior interosseous, really thicker part of interosseous membrane passing between the rough surfaces of the two bones.

Anterior and *posterior inferior tibio fibular*, oblique fibrous bands binding together the contiguous bony surfaces in front and behind.

Transverse, a narrow band passing from external malleolus to tibia behind the joint; *nerves*, those of ankle; *arteries*, some of those of ankle.

Describe the ankle-joint.

Ginglymoid, formed by lower end of tibia with its malleolus and the external malleolus, and the upper surface and sides of the astragalus; its ligaments are the,

FIG. 52.

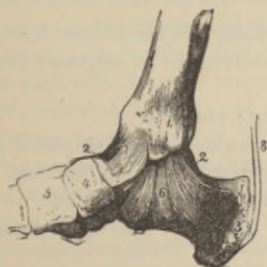
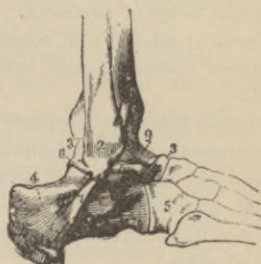


FIG. 53.



*Anterior*⁹ (Fig. 53), connecting the articular margins of the tibia and fibula with the rough upper surface of the astragalus.

*Posterior*² (Fig. 52), thin and imperfect, extends between the external malleolus, back of lower end of tibia and posterior tibio-

fibular ligament above, and the posterior surface of astragalus from one lateral ligament to the other below.

*Internal lateral*⁶ (Fig. 52), (deltoid) radiates from lower border of inner malleolus to astragalus behind and below, in front to scaphoid, and passes almost perpendicularly to the os calcis.

External lateral^{6, 7, 8} (Fig. 53), composed of three fasciculi from anterior margin, apex, and back of external malleolus, it is attached to the astragalus and os calcis: *nerves*, internal saphenous and anterior tibial; *arteries*, anterior and posterior tibials, anterior and posterior peroneals.

Describe the tarsal joints.

Those of the first row are arthrodial: the astragalus and calcis have three ligaments;

External calcaneo-astragaloid, from outer surface of astragalus to same of calcis;

The posterior calcaneo-astragaloid connects the posterior end of astragalus with upper surface of calcis;

The interosseous, the chief bond, filling up the grooves on the under surface of astragalus and upper of os calcis; there are two synovial sacs, one posterior, the other anterior continued between astragalus and scaphoid: *nerves*, posterior tibial or plantar; *arteries*, posterior tibial, tarsal, external malleolar (from ant. tibial), and terminal twigs of peroneal.

Those of second row, scaphoid, cuboid, and cuneiforms have,

Dorsal ligaments, small bands connecting the contiguous bones, and,

Plantar ligaments, similarly disposed; also four

Interosseous ligaments, connecting the sides of the scaphoid and cuboid, the internal and middle cuneiforms, the middle and external cuneiforms, the external cuneiform and cuboid; *nerves*, anterior tibial, internal and external plantars; *arteries*, metatarsal and plantars.

Those between the two rows, or medio-tarsal. (1) The *calcaneo-scaphoid*, arthrodial, has

The *superior calcaneo-cuboid ligament*, connecting the dorsal surfaces of calcis and cuboid.

The *internal (interosseous) calcaneo-cuboid*, connecting inner

under part of front of calcis with inner postero-inferior angle and contiguous part of cuboid.

The *long calcaneo-cuboid* (*plantar*) arises from under surface of calcis between posterior tubercles and anterior tubercle, to be attached to oblique ridge of cuboid and bases of second, third, fourth, and fifth metatarsal bones, completing canal for the long peroneal tendon.

The *short plantar* arises from the anterior calcaneal tubercle and the bone in front, to be attached to the under surface of cuboid behind the ridge, except the outer angle; the synovial sac is distinct from that of other tarsal joints.

The (2) astragalo-scaphoid articulation is the only enarthrodial (ball-and-socket) joint of tarsus, and communicates with the anterior calcaneo-astragaloid; its ligaments are,

The *superior calcaneo-scaphoid*, dense and thick, extending from anterior internal extremity of calcis to under surface of scaphoid.

The *inferior calcaneo-scaphoid*, passing obliquely forward from neck of astragalus to upper surface of scaphoid; *nerves* of medio-tarsal joint are, external branch of anterior tibial, sometimes musculo-cutaneous or external plantar; *arteries*, anterior tibial, tarsal, metatarsal, or external plantar.

Describe the tarso-metatarsal articulations.

Arthro-dial, between the three cuneiforms and the cuboid, and the bases of the five metatarsals; their ligaments are,

Dorsal, one for first metatarsal and internal cuneiform; one from each cuneiform to second; one from external cuneiform to third; one each from cuboid to fourth and fifth metatarsals.

Plantar, more irregularly disposed ligamentous fibres.

Interosseous, one connecting outer extremity of inner cuneiform to adjacent angle of second metatarsal; one between outer cuneiform and angle of second metatarsal; one connecting outer angle of external cuneiform with side of third metatarsal; *nerves*, anterior tibial and plantars; *arteries*, from dorsalis pedis, metatarsal, and deep plantar arch.

Describe the articulations of the metatarsal bones with one another.

Except the first, their bases are bound together by *dorsal, plantar,*

and *interosseous* ligaments; the distal extremities are united by the *transverse metatarsal ligament*.

Describe the metatarso-phalangeal and inter-phalangeal articulations.

They resemble in all respects those of hand, which see.

How many distinct synovial sacs have the tarsus and metatarsus?

Six, viz.: (1) Between calcis and astragalus, posterior to interosseus ligament; (2) in front of same ligament, between calcis and astragalus, also between astragalus and scaphoid; (3) between calcis and scaphoid; (4) between scaphoid, cuboid, and cuneiforms, communicating between the middle and external cuneiforms with the joints formed between those bones and the bases of the second and third metatarsals; (5) between the sides and bases of the fourth and fifth metatarsals and the cuboid; (6) between the base of first metatarsal and internal cuneiform.

Muscles and Fasciæ.

Describe a muscle.

It is a structure connected with bones, cartilages, ligaments, or skin, directly or through the medium of a tendon or aponeurosis, whose structure is capable of shortening when irritated mechanically or by nerve stimulus, this property being called *muscular contractility* or *irritability*.

How are muscles divided?

According to their form into narrow, broad, penniform (when their fibres converge like the plumes of a pen to *one* side of the tendon); *bipenniform* when so arranged on both sides of a tendon, radiated, etc.

Is there only one variety of muscular tissue?

No, there are *two*, one variety consisting of prismatic fasciculi about $\frac{1}{400}$ th of an inch in diameter, marked by transverse striæ, each bundle surrounded by a sheath or *perimysium*; each fasciculus is formed of a number of *fibrillæ*, $\frac{1}{800}$ th of an inch in diameter,

surrounded by a tubular, transparent elastic membranous *sarcolemma*; every fibril is striated, and consists of a row of minute particles, Bowman's "*sarcous elements*;" this variety of tissue forms the *voluntary, striped muscles*, or those of *animal life*, being under the control of the will; the *involuntary, unstriped*, or the muscles of *organic life*, are not under the control of the will, and consist of elongated, spindle shaped, flattened, nucleated cells, $\frac{1}{300}$ th to $\frac{1}{200}$ th of an inch long, $\frac{1}{4500}$ th to $\frac{1}{3500}$ th broad, and are held together in bundles by a cement substance containing a few connective-tissue corpuscles, the bundles being further collected into larger fasciculi, or flattened bands, bound together by ordinary areolar tissue; this kind of muscle is that found forming the contractile coats of the stomach, intestines, bladder, arteries, veins, lymphatics, ureters, urethra, iris, ciliary body, etc.; when irritated a part contracts, slowly relaxes, while another contiguous portion is contracting, which action being continued produces the *vermicular* (worm-like), peristaltic movements of the intestines. The spontaneously coagulable albuminous substance composing muscle is called *myosin*; so-called *syntonin* is a modification produced by chemical agents.

What are tendons and aponeuroses ?

Tendons are glistening white cords or bands, of white inelastic fibrous tissue, almost without blood- or nerve-supply, and connect the muscular tissue with the part to be moved; *aponeuroses* are membranous expansions of the same tissue serving similar purposes.

What are the fasciæ ?

They are laminæ of fibrous or fibro-areolar tissue investing the soft tissues; the superficial fasciæ are usually fibro-areolar, lie beneath the skin, and are loaded with fat; the deep fasciæ resemble aponeuroses, are dense and inelastic, ensheathing muscles, or serving for their attachment, and tend to preserve the form of the part, since partitions descend between various muscles to become attached to the periosteum of the osseous framework.

To what are the tendons attached ?

To the periosteum and perichondrium with which they become blended, to the subcutaneous tissue, and to ligaments.

What is meant by the origin and insertion of a muscle?

The *origin* is the most fixed and central point from which the muscle acts; the *insertion* the movable point to which the muscular force is directed; but, in many muscular acts the part usually described as the *insertion* becomes the fixed point and the *origin*, the movable one.

Do not some muscles have double origins, although single insertions?

Yes; as the occipito-frontal, digastric, and omo-hyoid.

Muscles of the Head.**Describe the origin, insertion, action, and nerve supply of the following muscles.**

*Occipito-frontalis*¹: *origin*, occipital portion, outer two-thirds of superior curved line of the occipital bone and mastoid process of the temporal; frontal portion, from pyramidalis nasi, corrugator supercilii, and orbicularis palpebrarum; *insertion*, into an aponeurosis covering the vertex of the skull; *action*, raises eyebrows and transversely wrinkles forehead; *nerves*, facial, posterior auricular branch of same, sometimes the small occipital.

*Attolens aurem*⁴: *origin*, occipito-frontalis aponeurosis; *insertion*, superior portion of pinna of ear; *action*, raises pinna; *nerve*, occipitalis minor.

Atrahens aurem: *origin*, lateral margin of occipito-frontalis tendon; *insertion*, a projection on front of helix; *action*, draws the pinna forward and upward; *nerve*, facial.

*Retrahens aurem*⁵: *origin*, mastoid portion of temporal; *insertion*, lower part of concha; *action*, draws ear back; *nerve*, posterior auricular branch of facial.

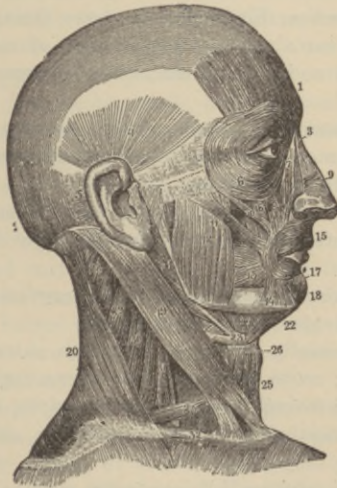
*Orbicularis palpebrarum*⁶: *origin*, internal angular process of the frontal, nasal process of superior maxillary bone, and the anterior surface and margins of the tendo oculi; *insertion*, skin of eyelids and contiguous portions of forehead, temple, and cheek, blending with the occipito-frontal and corrugator supercilii muscles; *action*, closes eyelids; *nerve*, facial.

Corrugator supercilii: *origin*, inner end of superciliary ridge; *insertion*, under surface of orbicularis palpebrarum; *action*, draws eyebrow downward and inward; *nerve*, facial.

Tensor tarsi (Horner's muscle): *origin*, crest of lachrymal bone; *insertion*, by two slips into tarsal cartilages near puncta; *action*, compresses lachrymal sac, and keeps puncta in contact with globe; *nerve*, facial.

*Levator palpebræ superioris*⁸: *origin*, lesser wing of sphenoid; *insertion*, upper border of superior tarsal cartilage; *action*, elevates upper lid; *nerve*, third cranial (motor oculi).

FIG. 54.



*Pyramidalis nasi*³: *origin*, occipito-frontalis; *insertion*, into compressor naris; *action*, depresses inner angle of the eyebrow; *nerve*, facial.

*Levator labii superioris alæque nasi*⁷: *origin*, upper part of nasal process of superior maxillary bone; *insertion*, the cartilage of ala

of nose, and into upper lip blending with orbicularis and levator labii; *action*, draws upward the upper lip, and dilates nostril; *nerve*, facial.

Dilator naris anterior: *origin*, cartilage of ala; *insertion*, integument near its margin; *action*, dilates nostril; *nerve*, facial.

Dilator naris posterior: *origin*, margin of nasal notch of superior maxilla and the sesamoid cartilages; *insertion*, skin near margin of nostril; *action*, dilates nostril; *nerve*, facial.

*Compressor nasi*⁹: *origin*, above and external to incisive fossa of superior maxilla; *insertion*, fibro-cartilage of nose, and is continuous with its fellow and the aponeurosis of pyramidalis nasi; *action*, dilates nostril, by increasing breadth of nose; *nerve*, facial.

Compressor narium minor: *origin*, alar cartilage; *insertion*, skin of tip of nose; *action*, dilates nostril; *nerve*, facial.

Depressor alæ nasi: *origin*, incisive fossa of superior maxilla; *insertion*, septum and back of ala; *action*, narrows nostril; *nerve*, facial.

*Levator labii superioris*⁸: *origin*, lower margin of orbit above infra-orbital foramen; *insertion*, muscular substance of upper lip; *action*, elevates lip; *nerve* facial.

*Levator anguli oris*¹⁶: *origin*, canine fossa of superior maxilla; *insertion*, angle of mouth; *action*, elevates angle of mouth; *nerve*, facial.

*Zygomaticus major*¹¹: *origin*, malar bone; *insertion*, angle of mouth; *action*, elevates angle of lip; *nerve*, facial.

*Zygomaticus minor*¹⁰: *origin*, malar bone anteriorly; *insertion*, angle of mouth; *action*, same as zygomaticus major; *nerve*, facial.

Levator labii inferioris (levator menti): *origin*, incisive fossa of lower jaw; *insertion*, skin of lower lip; *action*, elevates lower lip; *nerve*, facial.

Depressor labii inferioris^{17, 18} (*quadratus menti*): *origin*, external oblique line of lower jaw; *insertion*, skin of lower lip; *action*, depresses lower lip; *nerve*, facial.

*Depressor anguli oris*¹⁴: *origin*, external oblique line of lower jaw; *insertion*, angle of mouth; *action*, depresses angle of mouth; *nerve*, facial.

*Orbicularis oris*¹⁵: *origin*, nasal septum and superior and inferior

maxillary borders by accessory fibres called *accessorii orbicularis superioris* and *inferioris*, and *naso-labialis*; *insertion*, the buccinator, and other muscles converging to the mouth; *action*, closes mouth; *nerve*, facial.

*Buccinator*¹³: *origin*, behind, from the pterygo-maxillary ligament, above and below, the external surfaces of alveolar processes of the three molar teeth; *insertion*, orbicularis oris; *action*, compresses cheek; *nerve*, facial and buccal branch of inferior maxillary.

Risorius (*Santorini*): *origin*, fascia over masseter muscle; *insertion*, angle of mouth; *action*, laughing muscle; *nerve*, facial.

*Masseter*¹²: *origin*, the superficial portion, from the malar process of the superior maxilla and the anterior two-thirds of the lower border of the zygomatic arch, the deep portion, from the posterior third of the lower border and the inner surface of the zygomatic arch; *insertion*, upper half of ramus and outer surface of coronoid process of lower jaw; *action*, raises, protracts, and retracts lower jaw, a masticatory muscle; *nerve*, inferior maxillary.

Temporal: *origin*, temporal fossa and fascia; *insertion*, coronoid process of lower jaw; *action*, raises and retracts lower jaw, a muscle of mastication; *nerve*, inferior maxillary.

Internal pterygoid: *origin*, inner surface of external pterygoid plate and grooved surface of palate bone, the tuberosity of the palate and superior maxillary bones; *insertion*, lower back part of inner side of ramus as high as dental foramen, and angle of jaw; *action*, draws lower jaw forward, a muscle of mastication; *nerve*, inferior maxillary.

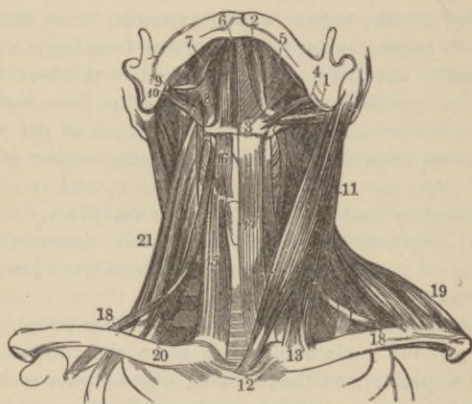
External pterygoid: *origin*, pterygoid ridge on greater wing of sphenoid, the bone included between it and base of pterygoid process, the outer surface of external pterygoid plate; *insertion*, depression in front of neck of condyle of lower jaw and inter-articular fibro-cartilage; *action*, draws jaw forward, a triturating masticatory muscle; *nerve*, inferior maxillary. Sometimes the internal maxillary artery passes between the two heads of this muscle; sometimes pierces it; often lies below it.

Muscles of the Neck.

Platysma myoides: *origin*, clavicle, acromion, and fascia of pectoral, deltoid, and trapezius muscles; *insertion*, lower jaw beneath oblique line, angle of mouth, cellular tissue of face; *action*, wrinkles skin of neck, depresses jaw and angle of lip; *nerves*, facial, superficial branches cervical plexus.

*Sterno-cleido-mastoid*¹¹ (Fig. 55): *origin*, upper front part of ster-

FIG. 55.



num, inner third upper border of clavicle; *insertion*, mastoid process of temporal and outer two-thirds superior curved line of occipital bone; *action*, acting *singly*, flexes head sideways, and rotates chin to opposite side, *both* acting flex head on neck, and then on chest; *nerves*, spinal accessory, deep branches of cervical plexus.

*Sterno-hyoid*¹⁴: *origin*, riband like, from posterior surface of sternum and inner end of clavicle; *insertion*, body of hyoid bone; *action*, depresses hyoid bone; *nerve*, filaments from loop between descendens and communicans noni.

*Sterno-thyroid*¹⁵: *origin*, posterior surface of sternum and cartilage of first rib; *insertion*, oblique line on ala of thyroid cartilage; *action*, depresses larynx; *nerve* same as sterno-hyoid.

*Thyro-hyoid*¹⁶: *origin*, oblique line of thyroid cartilage; *insertion*, lower border of body and greater cornu of hyoid bone; *action*, may elevate larynx when hyoid is fixed; *nerve*, hypoglossal.

*Omo-hyoid*¹⁸: *origin*, from upper border of scapula near suprascapular notch, perhaps, also, from transverse ligament; *insertion*, body of hyoid bone, its *central tendinous portion* being held down by a process of deep cervical fascia prolonged down to be attached to cartilage of first rib; *action*, depresses hyoid bone, larynx, and draws them backward to one or other side; *nerve*, from loop between descendens and communicans rami.

*Digastric*¹²: *origin*, has two fleshy bellies with an intermediate rounded tendon, the posterior¹ is attached to digastric groove of mastoid process of temporal, the anterior² to depression on inner side of lower border of jaw near symphysis; *insertion*, tendon perforates stylo-hyoid, and is held to side of body of hyoid bone by aponeurotic loop lined with synovial membrane; *action*, raises the hyoid bone; if this be fixed by its muscles, depresses lower jaw; *nerves*, posterior belly by facial, anterior by mylo-hyoid branch of inferior dental.

*Stylo-hyoid*⁴: *origin*, middle of outer surface of styloid process of temporal; *insertion*, body of hyoid at junction with greater cornu, it is perforated by digastric tendon; *action*, same as digastric; *nerve*, facial.

*Mylo-hyoid*⁵: *origin*, mylo-hyoid ridge of lower jaw; *insertion*, body of hyoid bone and median raphé; *action*, same as digastric and stylo-hyoid; *nerve*, mylo-hyoid branch of inferior dental; it forms the muscular floor of the mouth.

*Genio-hyoid*⁶: *origin*, inferior genial tubercle of lower jaw; *insertion*, body of hyoid bone; *action*, same as mylo-hyoid; *nerve*, hypoglossal.

*Genio-hyo-glossus*⁷: *origin*, superior genial tubercle of lower jaw; *insertion*, body of hyoid bone, side of pharynx and tongue from base to apex; *action*, protrudes tongue by posterior and inferior fibres, retracts it by anterior fibres, both muscles acting render tongue concave from side to side, as in sucking; *nerve*, hypoglossal.

*Hyo-glossus*⁸: *origin*, body, lesser, and whole length of greater cornu of hyoid bone; *insertion*, side of tongue; *action*, draws down sides of tongue, making it convex; *nerve*, hypoglossal.

*Stylo-glossus*⁹: *origin*, near centre of antero-external surface of styloid process and stylo-maxillary ligament; *insertion*, side of tongue and hyo-glossus muscle; *action*, draws tongue upward and backward; *nerve*, hypoglossal.

Lingualis: *origin*, forms bulk of tongue lying between hyo-glossus and genio-hyo-glossus on each side, running from base to apex, some fibres being attached to hyoid bone; *action*, renders tongue convex from before backward; *nerve*, chorda tympani.

Palatal Region.

Levator palati: *origin*, under surface of apex of petrous portion of temporal bone and contiguous portion of cartilaginous Eustachian tube; *insertion*, into posterior surface of soft palate; *action*, elevates soft palate; *nerve* facial through petrosal nerve of Vidian.

Tensor palati: *origin*, scaphoid fossa, outer side of Eustachian tube, spine of sphenoid, edge of tympanic plate; *insertion*, after reflection around hamular process, into forepart of aponeurosis of soft palate and under surface of palate bone; *action*, renders soft palate tense; *nerve*, branch from otic ganglion.

Azygos uvulæ: *origin*, posterior nasal spine and palatal aponeurosis; *insertion*, uvula; *action*, raises uvula; *nerve*, facial through petrosal of Vidian; it is not a *single* muscle as the name implies.

Palato-glossus (anterior pillar of fauces): *origin*, anterior surface of palate external to uvula; *insertion*, side and dorsum of tongue; *action*, as one of its names implies, constrictor isthmii faucium; *nerve*, palatine branches Meckel's ganglion.

Palato-pharyngeus (posterior pillar of fauces): *origin*, soft palate; *insertion*, posterior border of thyroid cartilage and side of pharynx; *action*, closes posterior fauces; *nerve*, same as for palato-glossus.

Vertebral Region.

Rectus capitis anticus major: *origin*, by four tendinous slips from anterior tubercles of transverse processes of third, fourth, fifth, and sixth cervical vertebræ; *insertion*, basilar process of occipital bone; *action*, flexes head; *nerves*, suboccipital, deep branches of cervical plexus.

Rectus capitis anticus minor: *origin*, front of lateral mass of atlas and root of its transverse process; *insertion*, basilar process of occipital bone behind preceding muscle; *action*, flexes head; *nerves*, suboccipital, deep branches of cervical plexus.

Rectus lateralis: *origin*, upper surface transverse process of atlas; *insertion*, jugular process of occipital bone; *action*, draws head laterally when one acts, flexes when both act; *nerves*, suboccipital, deep branches of cervical plexus.

Longus colli: *origin*, *superior oblique portion* from anterior transverse tubercles of third, fourth, and fifth cervical vertebræ; *insertion*, tubercle on anterior arch of atlas; the *inferior oblique portion* arises from bodies of first two or three dorsal vertebræ; *insertion*, transverse processes of fifth and sixth cervical vertebræ; *vertical portion* extends between bodies of upper three dorsal and lower three cervical, and those of second, third, and fourth cervical vertebræ; *action*, flexes and slightly rotates cervical spine; *nerves*, anterior branches from lower cervical nerves.

*Scalenus anticus*²⁰ (Fig. 55): *origin*, tubercle on upper surface of first rib; *insertion*, anterior tubercles of transverse processes of third, fourth, fifth, and sixth cervical vertebræ; *action*, lateral flexion of cervical spine or elevation of ribs; *nerves*, anterior branches lower cervical nerves.

*Scalenus medius*²¹: *origin*, upper surface of first rib behind subclavian groove; *insertion*, posterior tubercles of transverse processes of lower six cervical vertebræ; *action*, similar to preceding; *nerves*, anterior branches from lower cervical.

Scalenus posticus: *origin*, outer surface of second rib; *insertion*, posterior tubercles of lower two or three cervical vertebræ; *action*, flexes neck laterally, or elevates second rib; *nerves*, anterior branches from lower cervical.

Muscles of the Back

First layer:

*Trapezius*¹: *origin*, inner third of superior curved line of occipital bone, ligamentum nuchæ, spinous processes of seventh cervical and all dorsal vertebræ, and corresponding portion of supra-spinous ligament; *insertion*, outer third posterior border of clavicle, inner

margin of acromion process, the superior lip of crest of spine of scapula, and tubercle at its inner extremity; *action*, one acting draws head to its own side, both acting, draw head backward, and with head fixed, elevate point of shoulder; middle and lower fibres partially rotate scapula on chest; *nerves*, spinal accessory, deep branches of cervical plexus.

Ligamentum nuchæ (a thin band of condensed cellulo-fibrous membrane): *origin*, external occipital protuberance; *insertion*, spinous processes of all cervical vertebræ except atlas; a rudiment of strong elastic ligament sustaining head in herbivora, etc.

*Latissimus dorsi*⁴: *origin*, by an aponeurosis from spinous processes of lower six dorsal vertebræ, those of lumbar and sacral vertebræ and supra-spinous ligament, also external lip of iliac crest behind external oblique, and from three or four lower ribs; *insertion*, inner lip and bottom of bicipital groove of humerus; *action*, acting on humerus, draws it downward and backward while rotating it inward, with fixed arms, raises lower ribs in forcible inspiration, assists greater pectorals and abdominal muscles in drawing trunk forward as when climbing, using crutches, etc.; *nerve*, long subscapular nerve.

Second layer :

*Levator anguli scapulæ*¹⁰: *origin*, by three or four tendinous slips from posterior tubercles of transverse processes of three or four upper cervical vertebræ; *insertion*, posterior border of scapula between superior angle and triangular surface at root of spine; *action*, raises scapular angle; *nerves*, filaments from fifth cervical and from deep branches cervical plexus.

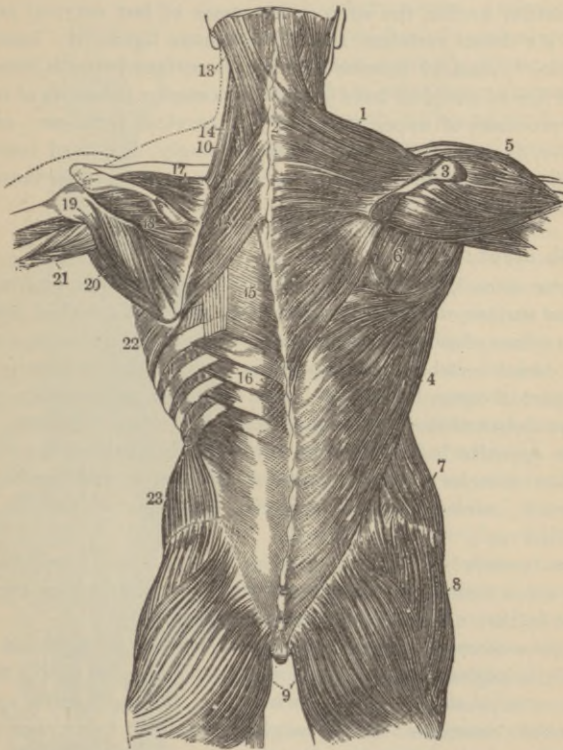
*Rhomboideus minor*¹¹: *origin*, ligamentum nuchæ, and spinous processes of seventh cervical and first dorsal vertebræ; *insertion*, margin of triangular surface at root of spine of scapula; *action*, draws inferior angle backward and upward; *nerve*, fifth cervical.

*Rhomboideus major*¹²: *origin*, spinous processes of upper four or five dorsal vertebræ and supra-spinous ligament; *insertion*, tendinous arch stretched from triangular surface at root of spine of scapula to inferior angle, the arch being connected with scapular border by thin membrane; *action*, draws inferior angle upward and backward; *nerve*, fifth cervical.

Third layer :

Serratus posticus superior: *origin*, by thin aponeurosis from ligamentum nuchæ and spinous processes of seventh cervical and

FIG. 56.



two or three upper dorsal vertebræ; *insertion*, by fleshy digitations into upper borders of second, third, fourth, and fifth ribs a little beyond their angles; *action*, elevates ribs during inspiration; *nerves*, external posterior branches of cervical nerves.

*Serratus posticus inferior*¹⁶: *origin*, by thin aponeurosis from spinous processes of last two dorsal and upper two or three lumbar

vertebræ and interspinous ligaments; *insertion*, by four digitations into lower borders of four lower ribs, beyond their angles; *action*, depresses ribs in expiration; *nerves*, external branches of dorsal nerves.

Splenius capitis et colli^{13 14}: *origin*, tendinous from lower half of ligamentum nuchæ, the spinous processes of last cervical and of upper six dorsal vertebræ, and supraspinous ligament; *insertion*, (*S. capitis*¹³) mastoid process and rough surface beneath superior curved line of occipital bone (*S. colli*¹⁴), posterior tubercles of transverse processes of upper three or four cervical vertebræ; *action*, together, draw head directly backward, singly, flex head laterally and slightly rotate to same side; *nerves*, external posterior branches of cervical nerves.

Fourth layer :

Erector spinæ^{1, 2, 3, 4, 5, 6} (Fig. 57): *origin*, sacro-iliac groove, the anterior surface of lumbo-sacral tendon, which is attached internally to spines of sacrum, the spinous processes of lumbar and three lower dorsal vertebræ and supraspinous ligament externally, the back part of inner lip of iliac crest, with the rudimentary transverse processes of the sacrum and great sacro-sciatic ligament; this muscle opposite last rib divides into sacro-lumbalis and longissimus dorsi muscles; *action*, maintains spine erect and bends body backward; *nerves*, external posterior branches of lumbar and dorsal nerves.

Sacro-lumbalis^{1, 2}: *origin*, is part of erector spinæ; *insertion*, by six or seven tendons into angles of six lower ribs; *action*, same as erector spinæ; *nerves*, same as erector spinæ.

Musculus accessorius ad sacro-lumbalem: *origin*, by flattened tendons from angles of six lower ribs; *insertion*, angles of six upper ribs; *action*, same as erector spinæ; *nerves*, those of erector spinæ.

Cervicalis ascendens: *origin*, angles of four or five upper ribs; *insertion*, posterior tubercles of transverse processes of fourth, fifth, and sixth cervical vertebræ; *action*, keeps neck erect; *nerves*, external posterior branches of cervical nerves.

*Longissimus dorsi*³: *origin*, is part of erector spinæ; *insertion*, posterior surface of lumbar transverse processes, tubercles at back of articular processes, tips of transverse processes of all the dorsal

vertebræ, and from six to eleven ribs between their tubercles and angles; *action* and *nerves* same as erector spinæ.

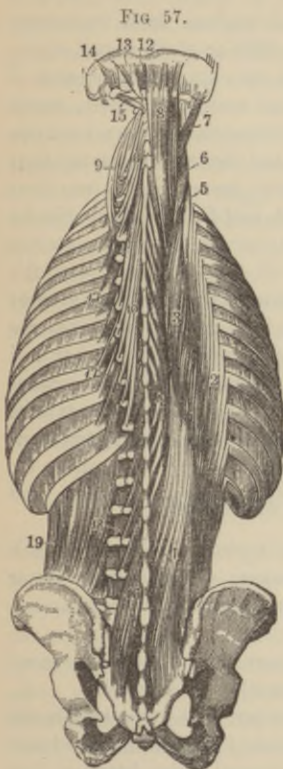Transversalis colli^{6,9}: *origin*, tendinous from summits of six upper dorsal transverse processes; *insertion*, posterior tubercles of transverse processes from second to sixth cervical vertebræ; *action*, keeps neck erect; *nerves*, external posterior branches of cervical nerves.

*Trachelo-mastoid*⁷: *origin*, by tendons from transverse processes of third, fourth, fifth, and sixth dorsal vertebræ and articular processes of the three or four lower cervical; *insertion*, posterior margin of mastoid process; *action*, flexes head laterally; *nerves*, external posterior branches of cervical nerves.

Spinalis dorsi: *origin*, by tendons from spinous processes of last two dorsal and first two lumbar vertebræ; *insertion*, by separate tendons into spinous processes of from four to eight dorsal vertebræ; *action*, erects spine; *nerves*, external posterior branches of dorsal nerves.

Spinalis colli: *origin*, fifth and sixth cervical spinous processes, also sometimes those of first and second dorsal (this muscle is sometimes absent); *insertion*, spinous process of axis, occasionally those of the two vertebræ below; *action*, extends cervical spine; *nerves*, external posterior branches of cervical nerves.

*Complexus*⁸: *origin*, by seven tendons from tips of transverse processes of upper three dorsal and seventh cervical vertebræ, and articular processes of the three cervical vertebræ above this; *insertion*, internally between curved lines of occipital bone; *action*, both draw head backward, singly,



lateral flexion with rotation turning face to opposite side; *nerves*, internal posterior branches of cervicals, sub-occipital and great occipital: (the biventer cervicis being usually blended with this muscle will receive no separate description).

Fifth layer :

*Semispinalis dorsi*¹⁰: *origin*, by small tendons from transverse processes of from tenth or eleventh to fifth or sixth dorsal vertebræ; *insertion*, by five or six tendons, into spinous processes of upper four dorsal and lower two cervical vertebræ; *action*, erects spinal column; *nerves*, internal posterior branches of dorsal nerves.

*Semispinalis colli*¹¹: *origin*, tendinous and fleshy from upper four dorsal transverse processes and articular processes of lower four cervicals; *insertion*, second, third, fourth, and fifth cervical spinous processes; *action*, erects cervical spine; *nerves*, internal posterior branches of cervical nerves.

*Multifidus spinæ*¹⁶: *origin*, back of sacrum, aponeurosis of erector spinæ (sacral region); posterior superior iliac spine, posterior sacroiliac ligaments (iliac regions); articulating processes (lumbar and cervical regions); transverse processes (dorsal region); *insertion*, lamina and spinous process of third or fourth vertebra above (most superficial), second or third above (middle layer); two contiguous vertebræ (deepest layer); keeps spine erect and rotates it; *nerves*, internal posterior branches of cervical, dorsal, lumbar, and sacral nerves.

Rotatores spinæ (eleven pairs in dorsal region only): *origin*, each from upper back part of transverse process; *insertion*, lower outer part of lamina of vertebra above; *action*, as name implies; *nerves*, internal posterior dorsal branches.

Supra-spinales: *origin* and *insertion*, cervical spinous processes; *action*, extend cervical spine; *nerves*, branches of cervical.

Inter-spinales: *origin*, variable in number, there are usually six cervical pairs commencing between apices of second and third vertebral spines; two, occasionally three dorsal pairs, between first and second, eleventh and twelfth, sometimes second and third vertebræ; four lumbar pairs; sometimes a pair between last dorsal and first lumbar, and fifth lumbar and sacrum; *action*, extend spine; *nerves*, internal posterior nerves of regions.

Extensor coccygis: *origin*, last bone of sacrum, or first of coccyx; *insertion*, lower part of coccyx, behind; *action*, as named; *nerve*, posterior sacral.

*Intertransversales*¹⁸: *origin* and *insertion*, between anterior and posterior tubercles of transverse processes in cervical⁷, occupy intertransverse spaces in other regions (twelve dorsal and four lumbar); *action*, lateral flexion, singly, steady spine when both sides act; *nerves*, posterior spinal branches of each region.

*Rectus capitis posticus major*¹³: *origin*, spinous process of axis; *insertion*, inferior curved line of occipital bone and surface below; rotates head; *nerves*, suboccipital and great occipital.

*Rectus capitis posticus minor*¹²: *origin*, tubercle on posterior arch of atlas; *insertion*, rough surface beneath inferior curved line, nearly as far as foramen magnum; *action*, extends head; *nerves*, suboccipital and great occipital.

*Obliquus capitis inferior*¹⁵: *origin*, apex of spinous process of axis; *insertion*, apex of transverse process of atlas; *action*, rotates atlas and head; *nerves*, suboccipital and great occipital.

*Obliquus capitis superior*¹⁴: *origin*, tendinous from upper part of transverse process of atlas; *insertion*, between curved lines of occipital bone external to complexus; *action*, extends head; *nerves*, suboccipital and great occipital.

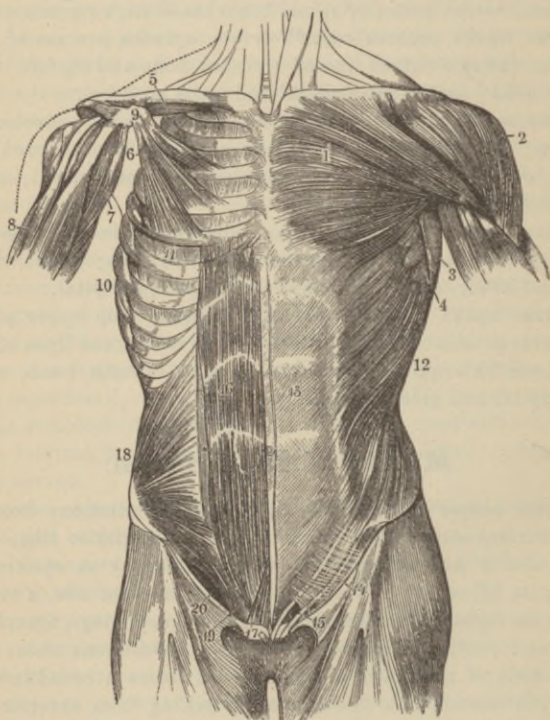
Muscles of the Abdomen.

*External oblique*¹²: *origin*, by eight fleshy digitations from external surface and lower borders of the eight inferior ribs; *insertion*, anterior half of outer lip of iliac crest, by an aponeurosis joining its fellow of opposite side it forms the *linea alba*, a median tendinosis raphé, is connected with ensiform cartilage, symphysis, spine, and pectineal line of pubes; it is continuous above with aponeurosis of pectoralis major, below it forms a broad infolded band, continuous with fascia lata, stretching from anterior iliac spine to pubic spine, *i. e.*, *Poupart's ligament*, reflected from which into the pectineal line, is a portion called *Gimbernat's ligament*; just above crest of pubis is the triangular external abdominal ring, its external border being Poupart's ligament, its inner, aponeurotic fibres, both called *pillars of the ring*; *action*, compresses viscera,

flexes thorax on pelvis, or flexes pelvis on thorax, according to which is the fixed point, also assists expiration; *nerves*, lower intercostal, ilio-hypogastric, ilio-inguinal.

*Internal oblique*¹⁸: *origin*, fleshy from outer half of Poupart's ligament, anterior two-thirds of middle lip of iliac crest, and pos-

FIG. 58.



terior lamella of lumbar fascia; *insertion*, crest and pectineal line of pubis with transversalis muscle—forming *conjoined tendon* part of inner boundary of internal abdominal ring—cartilages of lower four ribs, and by an aponeurosis, which splits for its upper

three-fourths to enclose the rectus muscle, into linea alba, the anterior layer blending with aponeurosis of external oblique, the posterior with that of transversalis muscle, the undivided lower fourth passing in front of rectus; *action* and *nerves*, same as external oblique.

Transversalis: *origin*, fleshy from outer third of Poupart's ligament, anterior three-fourths of inner lip of iliac crest, inner surface of six lower costal cartilages, and by a broad aponeurosis from lumbar spinous and transverse processes; *insertion*, with internal oblique as the *conjoined tendon* into pubic crest and pectineal line, by its aponeurosis into linea alba, the upper three-fourths passing *behind* rectus abdominis, the remainder *in front* of that muscle; *action* and *nerves* similar to external oblique.

Lumbar fascia: the vertebral aponeurosis of the transversalis divides into an anterior thin layer attached to front of lumbar transverse processes and to lower margin of last rib, thus forming the *ligamentum arcuatum externum*; a middle, stronger layer, attached to apices of transverse processes; and a posterior layer attached to apices of spinous processes; the quadratus lumborum lies between anterior and middle layers, the erector spinæ between the middle and posterior; the last receives the attachment of the internal oblique, and blended with the aponeuroses of the serratus posticus inferior and latissimus dorsi, forms the lumbar fascia.

*Rectus abdominis*¹⁶: *origin*, by two tendons from pubic crest and ligaments over symphysis pubis; *insertion*, cartilages of fifth, sixth, and seventh ribs; this muscle is enclosed in a sheath, the upper three-fourths in front formed by the aponeurosis of the external oblique and half of that of the internal oblique, behind for the same extent of the transversalis aponeurosis with the posterior division of that of the internal oblique; at the lower fourth the aponeuroses of all these muscles pass *in front* of the rectus; from two to five tendinous intersections traverse the muscle called *lineæ transversæ*, while the *lineæ semilunares*, two curved tendinous lines corresponding to the outer border of the recti muscles, extend on either side from the eighth costal cartilage to the pubes; *action*, flexes thorax on pelvis, and *vice versa*, also compresses abdominal viscera; *nerves*, same as external oblique.

Pyramidalis: *origin*, tendinous from pubic bone and anterior

pubic ligament, lying in front of, but in same sheath with rectus; *insertion*, linea alba midway between pubes and umbilicus; *action*, a tensor of linea alba; *nerves*, same as those of external oblique.

*Quadratus lumborum*¹⁹ (Fig. 57): *origin*, ilio-lumbar ligament, adjacent two inches of iliac crest, and upper borders of transverse processes of third, fourth, and fifth lumbar vertebræ; *insertion*, one-half of lower border of last rib, apices of transverse processes of upper four lumbar vertebræ; *action*, flexes trunk—both acting; flexes laterally—one acting; depresses ribs with fixed pelvis and is then an expiratory muscle; *nerves*, anterior branches of lumbar nerves.

Muscles of Thorax.

*External intercostals*¹¹ (Fig. 58) (eleven pairs): *origin*, each from outer lip of groove on lower border of each rib from tubercle to costal cartilage; *insertion*, pass obliquely downward and forward to upper border of rib below for same distance; *action*, raise and evert ribs in inspiration; *nerves*, intercostals.

Internal intercostals (eleven pairs): *origin*, each from inner lip of groove on lower border of rib reaching from angle to sternum; *insertion*, passing downward and backward to upper border of rib below; *action*, depress and invert the ribs in expiration; *nerves*, intercostals.

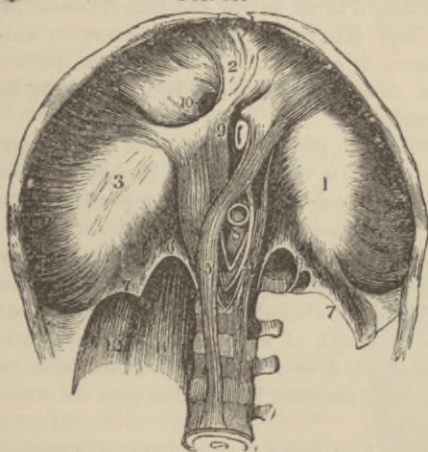
Infracostales: vary in number, most common between lower ribs; *origin*, from inner surface of one rib; *insertion*, inner surface of first, second, or third rib below, passing obliquely downward and backward; *action*, inspiratory muscles; *nerves*, intercostals.

Triangularis sterni: *origin*, lower part of side of sternum, inner surface of ensiform cartilage, and sternal ends of costal cartilages of three or four lower true ribs; *insertion*, by fleshy digitations into lower border and inner surfaces of costal cartilages of second, third, fourth, and fifth ribs; *action*, draws down costal cartilages in expiration; *nerves*, intercostals.

Latores costarum: *origin* (twelve pairs), extremities of dorsal transverse processes; *insertion*, rough surface between tubercle and angle of rib below; *action*, assist external intercostals in raising ribs; *nerves*, intercostals.

Diaphragm: origin, arched and convex toward chest, from ensiform cartilage in front, on either side, inner surfaces of cartilages and bony portions of lower six or seven ribs, behind, from the ligamentum arcuatum externum⁷ and internum⁶, and by its crura^{4,5}, the left from bodies of second and third, the right, from those of second, third, and fourth lumbar vertebræ; *insertion*, into central cordiform tendon^{1,2,3}; *action*, chief respiratory muscle, increasing capacity of chest by becoming flattened when contracted; also aids all efforts of expulsion as of feces, etc.; *nerves*, phrenic and phrenic plexus of sympathetic.

FIG. 59.



Openings of the Diaphragm: the aortic⁸, median, in front of vertebral bodies—really behind diaphragm—for aorta, vena azygos major, thoracic duct, sometimes left sympathetic nerve; the *esophageal*⁹, elliptical, muscular, formed by crura, for œsophagus and pneumogastric nerves; the *opening for vena cava*¹⁰, highest, quadrilateral bounded by four tendinous bundles meeting at right angles; the right *crus*⁴, transmits the sympathetic, greater and lesser splanchnic nerves; the *left crus*⁵, the left greater and lesser splanchnic nerves, and vena azygos minor.

Muscles of shoulder and arm.

*Pectoralis major*¹ (Fig. 58): *origin*, anterior surface inner half of clavicle, half the breadth of anterior surface of sternum as low as sixth or seventh rib, cartilages of all true ribs except first or seventh, or both, and from aponeurosis of external oblique; *insertion*, fibres converge and overlap, the lower being folded back upon themselves, to be attached by a flat tendon to anterior lip of bicipital ridge of humerus; *action*, draws arm forward and inward; with fixed arm, an accessory muscle of forced inspiration; *nerve*, anterior thoracic.

*Pectoralis minor*⁶ (Fig. 58): *origin*, tendinous from upper margin and outer surface of third, fourth, and fifth ribs near cartilages, and aponeurosis over intercostal muscles; *insertion*, anterior border coracoid process of scapula; *action*, depresses point of shoulder, elevates ribs during inspiration when scapula is fixed; *nerves*, anterior thoracic.

*Subclavius*⁵: *origin*, tendinous from first costal cartilage; *insertion*, groove on middle third of under surface of clavicle; *action*, draws clavicle downward and inward toward the thorax; *nerve*, branch from cord formed by fifth and sixth cervical.

*Serratus magnus*⁴ (Fig. 58): *origin*, by nine fleshy digitations from outer surface and upper border of upper eight ribs (second rib has two) and aponeurosis covering upper intercostal spaces; *insertion*, whole length of anterior aspect of posterior border of scapula; *action*, elevates ribs in inspiration with fixed scapula, also raises point of shoulder by rotating bone on chest wall; *nerve*, posterior thoracic.

*Deltoid*² (Fig. 58): *origin*, outer third of anterior border and upper surface of clavicle, outer margin and upper surface of acromion process, and the whole length of lower border of spine of scapula; *insertion*, tendinous into rough prominence on middle of outer side of shaft of humerus; *action*, raises arm to right angle, also draws it forward by anterior fibres, or slightly backward by posterior portion; *nerve*, circumflex.

*Subscapularis*⁴ (Fig. 60): *origin*, inner two-thirds of subscapular fossa; *insertion*, lesser tuberosity of humerus; *action*, rotates head of humerus inward; *nerve*, subscapular.

*Supraspinatus*¹⁷ (Fig. 56): *origin*, internal two-thirds of same-

named fossa and the fascia covering it; *insertion*, highest facet of greater tuberosity of humerus; *action*, assists deltoid, fixes head of humerus in socket; *nerve*, suprascapular.

*Infraspinatus*¹⁸ (Fig. 56): *origin*, internal two-thirds of infraspinous fossa; *insertion*, tendinous, middle facet of greater tuberosity of humerus; *action*, rotates head of humerus outward; *nerve*, suprascapular.

*Teres minor*¹⁹ (Fig. 56): *origin*, upper two-thirds of dorsal surface of axillary border of scapula and intermuscular septa; *insertion*, lowest facet on greater tuberosity of humerus; *action*, rotates head of humerus outward; *nerve*, circumflex.

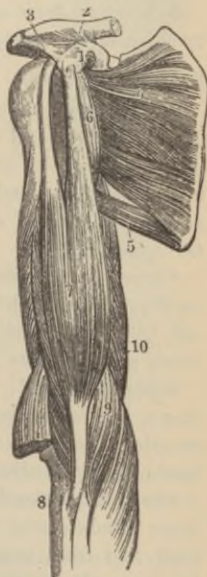*Teres major*²⁰ (Fig. 56): *origin*, dorsal aspect of inferior angle of scapula and intermuscular septum separating from teres minor and infraspinatus; *insertion*, internal lip of bicipital groove; *action*, draws humerus downward and backward when raised, also rotates it inward; *nerve*, lower subscapular.

*Coraco-brachialis*⁶ (Fig. 60): *origin*, fleshy from apex of coracoid process of scapula; *insertion*, tendinous, into rough ridge at middle of inner side of shaft of humerus; *action*, draws humerus forward and inward, also elevates it; *nerve*, musculo-cutaneous, which perforates the muscle.

*Biceps flexor cubiti*⁷ (Fig. 60): *origin*, *short head*, tendinous, in common with coraco-brachialis from tip of coracoid process of scapula, *long head*, upper margin of glenoid cavity by rounded tendon continuous with glenoid ligament; *insertion*, tendinous into back part of tuberosity of radius (a bursa is interposed in front), and by a broad aponeurosis opposite elbow, into fascia of forearm; *action*, flexes and supinates forearm, renders forearm fascia tense; *nerve*, musculo-cutaneous.

*Brachialis anticus*⁹: *origin*, lower half of outer and inner surfaces of shaft of humerus, embracing insertion of deltoid; *insertion*, ten-

FIG. 60.



dinous into anterior surface of coronoid process of ulna; *action*, flexes forearm; *nerves*, musculo-cutaneous and musculo-spiral.

*Triceps extensor cubiti*¹⁰: *origin*, scapular or long head, from rough triangular depression below glenoid fossa, the *external head* from posterior surface of shaft between upper part of musculo-spiral groove and insertion of teres major, the *internal head* from posterior surface below musculo-spiral groove; *insertion*, tendinous, back, upper surface of olecranon process of ulna; *action*, extends forearm and arm; *nerve*, musculo-spiral.

Subanconeus: *origin*, humerus above olecranon fossa; *insertion*, posterior ligament of elbow; *action*, prevents loose capsule from being pinched during extension; *nerve*, musculo-spiral.

Muscles of the Forearm.

Anterior, or flexor and pronator group: All take origin from internal condyle, except pronator quadratus.

Superficial layer.

*Pronator radii teres*⁴ (Fig. 61): *origin*, double, above, from internal condyle and common tendon, fascia of forearm and intermuscular septum, below, from inner side of coronoid process of ulna; *insertion*, tendinous, into rough ridge on middle of outer surface of shaft of radius; *action*, pronates forearm, aids flexion; *nerve*, median.

*Flexor carpii radialis*⁵: *origin*, internal condyle by common tendon, forearm fascia, and intermuscular septa; *insertion*, tendinous, into base of index metacarpal; *action*, flexes wrist, then forearm; *nerve*, median.

*Palmaris longus*⁶: *origin*, inner condyle by common tendon, fascia, and intermuscular septa; *insertion*, tendinous, into anterior annular ligament and palmar fascia; *action*, tightens palmar fascia; *nerve*, median.

*Flexor carpi ulnaris*⁸: *origin*, double, by common tendon from inner condyle and from inner margin of olecranon by aponeurosis, and from upper two-thirds of posterior border of ulna and intermuscular septum; *insertion*, tendinous, into pisiform bone, annular ligament and base of little finger metacarpal; *action*, flexes hand on forearm; then forearm on arm; *nerve*, ulnar.

*Flexor sublimis digitorum*⁷ (*perforatus*): *origin*, by three heads, one from internal condyle by common tendon and from internal lateral ligament and intermuscular septa, a second from inner side of the coronoid process of ulna, the third from oblique line of radius; *insertion*, by four tendons, each of which splits for the passage of the deep flexor tendons, each half becoming attached to middle of lateral margins of second phalanges; *action*, flexes fingers, then hand on forearm, then forearm on arm; *nerve*, median.

Deep layer.

Flexor profundus digitorum (*perforans*): *origin*, upper two-thirds of antero-internal surface of shaft of ulna, inner side of coronoid process, by an aponeurosis from upper two-thirds of posterior border of ulna and ulnar half of interosseous membrane; *insertion*, into bases of last phalanges by four tendons, which pass between the two slips of flexor sublimis tendons; *action*, flexes fingers, then wrist on forearm; *nerves*, ulnar and anterior interosseous.

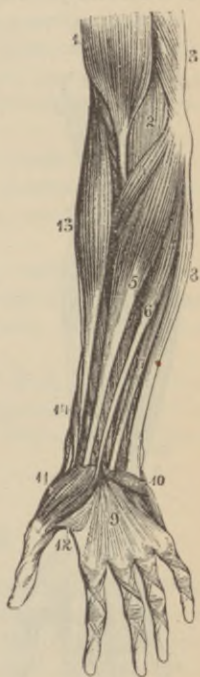Flexor longus pollicis: *origin*, upper two-thirds of front of shaft of radius, adjacent interosseous membrane, sometimes from base of coronoid process; *insertion*, base of last phalanx of thumb; *action*, flexes last thumb phalanx; *nerve*, anterior interosseous.

Pronator quadratus: *origin*, oblique line on lower fourth of anterior surface of ulna, the bone below, the anterior border of ulna and aponeurosis over muscles; *insertion*, lower fourth of anterior surface and external border of radius; *action*, pronates hand; *nerve*, anterior interosseous.

Radial Region: all the extensors and supinators arise, at least partially, from the external condyle and ridge of the humerus.

*Supinator longus*¹³: *origin*, upper two-thirds of external condyloid

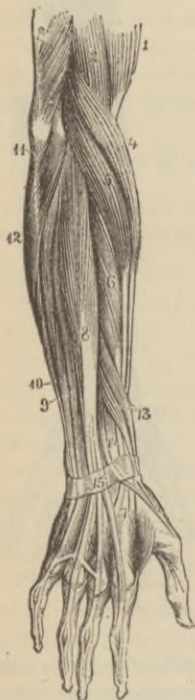FIG 61.



ridge and external intermuscular septum; *insertion*, base of styloid process of radius; *action*, supinates forearm after it has been pronated, flexes forearm on arm, second in power only to biceps; *nerve*, musculo-spiral.

*Extensor carpi radialis longior*⁵ (Fig. 62): *origin*, lower third of external condyloid ridge and external intermuscular septum; *insertion*, radial side of base of metacarpal bone of index finger; *action*, extends wrist; *nerve*, musculo-spiral.

FIG. 62.



*Extensor carpi radialis brevior*⁶: *origin*, external condyle by common tendon, external lateral ligament, the covering aponeurosis and the intermuscular septa; *insertion*, radial side of base of metacarpal of middle finger; *action*, extends wrist; *nerve*, posterior interosseous.

*Extensor communis digitorum*⁸: *origin*, external condyle by common tendon, deep fascia and intermuscular septa; *insertion*, second and third phalanges of each finger by three main tendons, one of which subdivides into two; *action*, extends fingers, then hand, finally forearm on arm; *nerve*, posterior interosseous.

*Extensor minimi digiti*⁹: *origin*, common tendon and intermuscular septa; *insertion*, with tendon of common extensor into second and third phalanges of little finger; *action*, extends little finger; *nerve*, posterior interosseous.

*Extensor carpi ulnaris*¹⁰: *origin*, by common tendon from external condyle, middle third of posterior border of ulna below anconeus and forearm fascia; *insertion*, ulnar side of base of fifth metacarpal; *action*, extends

wrist; *nerve*, posterior interosseous.

Anconeus: *origin*, back of outer condyle of humerus; *insertion*, side of olecranon and upper fourth of posterior surface of shaft of ulna; *action*, extends forearm; *nerve*, musculo-spiral.

*Supinator brevis*¹¹: *origin*, external condyle of humerus, external lateral ligament and orbicular ligament of radius, oblique line of ulna, triangular depression in front of it and aponeurosis covering muscle; *insertion*, back inner part of neck of radius, bicipital tuberosity, and oblique line; *action*, supinates forearm; *nerve*, posterior interosseous which pierces it.

*Extensor ossis metacarpi pollicis*¹³: *origin*, posterior surface of shaft of ulna below anconeus, interosseous ligament, and middle third of posterior surface of shaft of radius; *insertion*, base of thumb-metacarpal; *action*, extends thumb-metacarpal; *nerve*, posterior interosseous.

*Extensor primi internodii pollicis*¹³: *origin*, posterior surface of shaft of radius and interosseous membrane; *insertion*, base of first thumb-phalanx; *action*, extends phalanx on metacarpal; *nerve*, posterior interosseous.

*Extensor secundi internodii pollicis*¹⁴: *origin*, posterior surface of shaft of ulna and interosseous membrane below extensor ossis metacarpi; *insertion*, last phalanx of thumb; *action*, extends thumb; *nerve*, posterior interosseous.

Extensor indicis: *origin*, posterior surface of shaft of ulna below extensor secundi; *insertion*, with tendon of common extensor into second and third phalanges of index finger; *action*, extends index finger; *nerve*, posterior interosseous.

Fasciæ of the Hand.

The *anterior annular ligament* is stretched between pisiform bone and unciform process of unciform bone on one side, and the tuberosity of scaphoid and ridge of trapezium on the other; it is continuous with forearm and palmar fascia, and receives the insertion of the palmaris longus muscle and partially that of flexor carpi radialis, which pierces it; beneath it pass the median nerve and, in one synovial sheath, the tendons of the flexor sublimis and profundus digitorum and the flexor longus pollicis.

The *posterior annular ligament*, continuous with forearm fascia, is attached on dorsum internally to ulna, cuneiform, and pisiform bones and palmar fascia, externally to ridges on back of and margin of radius. Six separate synovial compartments exist for the ex-

tensor tendons; from without inward, they are: (1) outer side of styloid process, for extensor ossis metacarpi and extensor primi internodii pollicis; (2) behind same process, for extensor carpi radialis longior and brevior; (3) next for extensor secundi internodii pollicis; (4) more internally still, for extensor communis digitorum and extensor indicis; (5) opposite interval between radius and ulna, for extensor minimi digiti; and (6) back of ulna, for extensor carpi ulnaris.

The *palmar fascia*⁹ (Fig. 61), consisting of a central and two lateral portions, invests muscles of hand forming their common sheath; the central segment is triangular, attached to anterior annular ligament above, below dividing into four slips opposite metacarpal heads, each slip dividing again to enclose flexor tendons and be inserted on sides of first phalanges; strong transverse fibres connect the separate processes, and vertical septa, continuous on each side with interosseous aponeurosis, separate the middle from lateral palmar groups of muscles; beneath is the superficial palmar arch, median and ulnar nerves; the lateral portions of this fascia thinly invest the muscles of the thenar and hypothenar eminences.

Muscles of the Hand.

*Abductor pollicis*¹¹ (Fig. 61): *origin*, ridge of trapezium and annular ligament; *insertion*, tendinous into radial side of base of first thumb-phalanx; *action*, draws thumb from median line—*i. e.*, abducts it; *nerve*, median.

Opponens pollicis: *origin*, palmar surface of trapezium and annular ligament; *insertion*, whole length of radial side of thumb-metacarpal; *action*, flexes metacarpal; *nerve*, median.

*Flexor brevis pollicis*¹² (Fig. 61): *origin*, by two heads between which lies flexor longus pollicis tendon, the external from trapezium and outer two-thirds of annular ligament, the internal from trapezoid, os magnum, base of third metacarpal, and sheath of tendon of flexor carpi radialis; *insertion*, sides of base of first thumb-phalanx by two tendons each containing a sesamoid bone; *action*, as name implies; *nerves*, median and ulnar.

Adductor pollicis: *origin*, whole palmar length of metacarpal of middle finger; *insertion*, ulnar side of base of first thumb-phalanx

and internal sesamoid bone; *action*, draws thumb toward median line; *nerve*, ulnar.

The preceding muscles form the *thenar eminence*.

*Palmaris brevis*¹⁰: *origin*, tendinous from annular ligament and palmar fascia; *insertion*, skin on inner border of palm; *action*, wrinkles skin on inner palmar side; *nerve*, ulnar.

Abductor minimi digiti: *origin*, pisiform bone and expansion of tendon of flexor carpi ulnaris; *insertion*, ulnar side of base of first little finger phalanx; *action*, draws little finger from median line; *nerve*, ulnar.

Flexor brevis minimi digiti: *origin*, tip of unciform process and annular ligament; *insertion*, base of first little finger phalanx with the abductor; *action*, flexes little finger; *nerve*, ulnar.

Opponens minimi digiti: *origin*, beneath preceding, from unciform process and annular ligament; *insertion*, whole length of little finger metacarpal; *action*, flexes fifth metacarpal; *nerve*, ulnar.

The four preceding muscles form the *hypothenar eminence*.

Lumbricales: *origin*, tendons of deep flexor; *insertion*, tendinous expansion of extensor communis tendon over dorsum of each finger; they are four in number; *action*, aid in extending second and third phalanges (Duchenne, Hutchinson); *nerves*, two outer by median, two inner by ulnar.

Dorsal interossei (four in number): *origin*, by two heads from adjacent sides of the metacarpal bones; *insertion*, into bases of first phalanges and aponeurosis of common extensor; *action*, extend second and third phalanges, abduct fingers from middle line passing through centre of middle finger; *nerve*, ulnar.

Palmar interossei (three in number): *origin*, from entire length of palmar surfaces of second, fourth, and fifth metacarpal bones; *insertion*, into bases of first phalanges of same fingers; *action*, adduct (draw) fingers toward middle finger; *nerve*, ulnar.

Muscles of Lower Extremity.

*Psoas magnus*¹¹ (Fig. 63): *origin*, sides of bodies, intervertebral substances and bases of transverse processes of last dorsal and all the lumbar vertebræ; *insertion*, tendinous, with iliacus, into lesser

trochanter; *action*, flexes thigh on pelvis, or *vice versâ*, also rotates femur outward; *nerves*, anterior branches of lumbar nerves.

Psoas parvus (often absent): *origin*, sides of bodies and intervertebral substance between last dorsal and first lumbar vertebræ; *insertion*, tendinous into ilio-pectineal eminence and iliac fascia; *action*, tensor of iliac fascia; *nerves*, anterior branches of lumbar nerves.

*Iliacus*¹⁰: *origin*, iliac fossa and inner margin of iliac crest, ilio-lumbar ligament and base of sacrum, anterior superior and inferior iliac spines, the notch between them, and capsule of hip-joint; *insertion*, with tendon of psoas magnus into lesser trochanter; *action*, same as psoas magnus; *nerve*, anterior crural.

The *fascia lata*, or *deep fascia*, is attached above to Poupart's ligament and iliac crest, behind to margins of sacrum and coccyx, internally to pubic arch and linea ilio-pectinea, and below to condyles of femur, tuberosities of tibia, and head of fibula; two strong intermuscular septa pass from the inner surface to whole length of linea aspera; numerous smaller septa provide separate sheaths for each muscle; just below Poupart's ligament, at the upper inner aspect of thigh, is the large oval *saphenous opening*, formed by the margins of the pubic and iliac portions of the fascia lata; *Poupart's ligament* is an artificial production, being in reality the thickened lower portion of the external oblique aponeurosis where the fascia lata becomes continuous with it.

*Tensor vaginæ femoris*⁴: *origin*, anterior part of outer lip of iliac crest and anterior superior iliac spine; *insertion*, fascia lata one-fourth down thigh, whence fascia is continued down to tibial head as the *ilio-tibial band*; *action*, tensor of fascia lata; *nerve*, superior gluteal.

*Sartorius*⁵: *origin*, anterior superior iliac spine and upper half of notch below it; *insertion*, aponeurotic, into upper inner surface of shaft of tibia; *action*, flexes leg upon thigh, thigh upon pelvis, at same time drawing limb inward, thus crossing one leg over the other; *nerve*, anterior crural.

*Rectus femoris*⁶: *origin*, by two tendons, the *straight* from anterior inferior iliac spine, the *reflected* from groove above acetabulum; *insertion*, patella in common with three next muscles; *action*, extends leg; *nerve*, anterior crural.

*Vastus externus*⁷: *origin*, tubercle of femur, great trochanter, rough line leading thence to linea aspera and whole outer lip of linea aspera; *insertion*, aponeurotic into outer border of patella; *action*, extends leg; *nerve*, anterior crural.

Vastus internus and *crureus*⁸: *origin*, line leading from inner side of neck of femur to linea aspera and its whole inner lip, internal intermuscular septum, internal, anterior, and external surfaces of

FIG. 63.

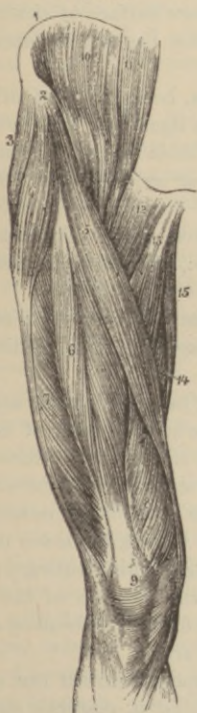
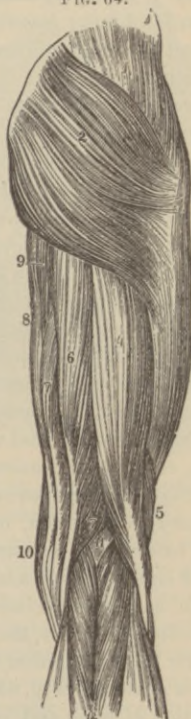
FIG. 64.



the shaft of femur between the anterior intertrochanteric line and the lower fourth of the bone; *insertion*, aponeurotic, into inner side

of patella, blending with other portions of quadriceps tendon; *action*, extends leg; *nerve*, anterior crural. The preceding four muscles are called the quadriceps extensor^{6,7,8}, whose tendon contains the patella⁹, and which is *inserted* into tubercle of tibia by ligamentum patellæ.

Subcrureus: *origin*, by two heads from lower part of shaft of femur; *insertion*, upper part of synovial pouch of knee; *action*, draws up synovial sac; *nerve*, anterior crural. *

*Gracilis*¹⁵: *origin*, aponeurotic from inner margin of ramus of pubes and ischium; *insertion*, upper inner surface of shaft of tibia above and behind sartorius; *action*, flexes leg and adducts thigh; *nerve*, obturator.

*Pectineus*¹²: *origin*, linea ilio-pectinea, bone in front of it, and tendinous prolongation of Gimbernat's ligament; *insertion*, rough line passing from lesser trochanter to linea aspera; *action*, flexes, adducts, and rotates thigh outward; *nerves*, obturator, accessory obturator, anterior crural.

*Adductor longus*¹³: *origin*, tendinous from angle of pubes; *insertion*, middle third of linea aspera; *action*, adducts and flexes thigh; *nerve*, obturator.

Adductor brevis: *origin*, outer surface of descending ramus of pubes; *insertion*, upper part of linea aspera; *action*, adducts and flexes thigh; *nerve*, obturator.

*Adductor magnus*¹⁴: *origin*, descending ramus of pubes, ascending ramus, outer margin, and under surface of tuberosity of ischium; *insertion*, rough line running from great trochanter to linea aspera, whole length of linea aspera, and by a tendon into tubercle above inner condyle of femur, between these portions of muscle is an angular interval for passage of femoral vessels, the lower orifice of Hunter's canal; *action*, adducts and rotates thigh outward; *nerves*, obturator and great sciatic; the external portion of the muscle presents four apertures, the three upper for the perforating arteries, the lowest for termination of profunda artery.

*Gluteus maximus*² (Fig. 64): *origin*, superior curved line of ilium and portion of bone and crest just behind it, posterior surface of last piece of sacrum, side of coccyx, aponeurosis over multifidus spinæ muscle and the great sacro-sciatic ligament; *insertion*, fascia lata and rough line running from great trochanter to linea aspera

between vastus externus and adductor magnus; *action*, maintains trunk erect upon thigh, extends, abducts, and rotates thigh outward; *nerves*, small sciatic, and branch from sacral plexus.

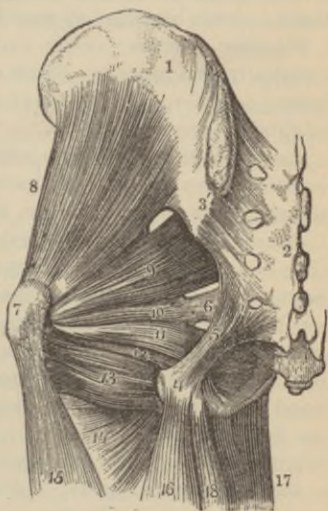*Gluteus medius*¹ (Fig. 64): *origin*, outer surface of ilium between superior and middle curved lines, outer lip of crest between, and gluteal aponeurosis; *insertion*, tendinous into oblique line on great trochanter; *action*, supports trunk, the posterior fibres rotate thigh outward, the anterior fibres rotate thigh inward, it also abducts and draws thigh forward; *nerve*, superior gluteal.

*Gluteus minimus*² (Fig. 65): *origin*, outer surface of ilium between middle and inferior curved lines and margin of sciatic notch; *insertion*, anterior border of great trochanter; *action*, draws forward, abducts and rotates thigh inward, aids in maintaining trunk erect; *nerve*, superior gluteal.

*Piriformis*³: *origin*, by three fleshy digitations from bone between first, second, third, and fourth anterior sacral foramina, likewise grooves leading from them, from margin of great sacro-sciatic foramen, and great sacro-sciatic ligament; *insertion*, passing out of pelvis by great sacro-sciatic foramen is attached to upper border of great trochanter; *action*, an external rotator of thigh, which, when flexed, is abducted by this muscle, also draws pelvis forward with fixed femur; *nerves*, branches of sacral plexus.

*Obturator internus*¹¹: *origin* internal surface of obturator membrane and tendinous arch for passage of vessels, and inner side of obturator foramen; *insertion*, upper border of great trochanter after leaving pelvis by lesser sacro-sciatic foramen; four or five tendinous bands pass in the substance of the muscle (Bigelow)

FIG. 65.



from origin to insertion; *action*, similar to pyriformis; *nerves*, branches of sacral plexus.

*Gemellus superior*¹⁰: *origin*, spine of ischium; *insertion*, with tendon of obturator internus into upper border of great trochanter; *action*, rotates thigh outward; *nerves*, branches of sacral plexus.

*Gemellus inferior*¹²: *origin*, tuberosity of ischium; *insertion*, great trochanter with obturator internus; *action*, an external rotator of thigh; *nerves*, branches of sacral plexus.

Obturator externus: *origin*, inner margin of obturator foramen externally, and inner two thirds of outer surface of obturator membrane; *insertion*, digital fossa of femur; *action*, an external rotator of thigh; *nerve*, obturator.

*Quadratus femoris*¹³: *origin*, outer border of tuberosity of ischium; *insertion*, linea quadrati on back of trochanter major; *action*, external rotator of thigh; *nerves*, branches of sacral plexus.

*Biceps*¹⁶ (Fig. 65); ^{4, 5} (Fig. 64): *origin*, by two heads, the *long*¹⁶ (Fig. 65) from lower inner facet on tuberosity of ischium by tendon common to semitendinosus, the *short head*⁵ (Fig. 64), from linea aspera between adductor magnus and vastus externus, and from intermuscular septum; *insertion*, outer side of head of fibula, the tendon splitting to embrace external lateral ligament of knee, one band extending down as far as outer tuberosity of tibia; this muscle forms the *outer hamstring*; *action*, flexes leg, after which it slightly rotates it outward; *nerve*, great sciatic.

*Semitendinosus*⁶ (Fig. 64), ¹⁸ (Fig. 65): *origin*, by common tendon with preceding muscle from tuberosity of ischium and adjacent aponeurosis; *insertion*, upper inner surface of shaft of tibia, behind sartorius and below gracilis; *action*, flexes leg on thigh; *nerve*, great sciatic.

*Semimembranosus*⁷ (Fig. 64): *origin*, tendinous from upper outer facet on tuberosity of ischium; *insertion*, groove on inner tuberosity of tibia; *action*, flexes leg on thigh, after which it assists popliteus in rotating leg inward; *nerve*, great sciatic; the tendons of sartorius¹⁰ (Fig. 64), gracilis⁸ (Fig. 64), semimembranosus⁷ (Fig. 64), and semitendinosus⁶ (Fig. 66) (enumerated from before backward), form the *inner hamstring*.

Muscles of the Leg.

*Tibialis anticus*³ (Fig. 66): *origin*, outer tuberosity and upper two-thirds of external surface of shaft of tibia, adjacent interosseous membrane, deep surface of fascia, and intermuscular septum; *insertion*, inner under surface of internal cuneiform bone, base of first metatarsal; *action*, flexes and adducts tarsus; *nerve*, anterior tibial.

*Extensor proprius pollicis*⁵: *origin*, middle two-fourths of anterior surface of fibula, and to same extent from interosseous membrane; *insertion*, base of last phalanx of great toe; *action*, extends great toe and, continuing action, flexes tarsus on leg; *nerve*, anterior tibial.

*Extensor longus digitorum*⁴: *origin*, outer tuberosity of tibia, upper three-fourths of anterior surface of fibula, interosseous membrane, deep surface of fascia, and intermuscular septa; *insertion*, divides into three tendons, and one subdivides making four tendons, which are attached to second and third phalanges of four lesser toes; *action*, extends toes, then flexes tarsus on leg; *nerve*, anterior tibial.

*Peroneus tertius*⁶ (part of preceding muscle): *origin*, lower fourth of anterior surface of fibula, interosseous membrane, and intermuscular septum; *insertion*, upper inner part of base of little toe metatarsal; *action*, same as long extensor; *nerve*, anterior tibial.

*Gastrocnemius*¹⁰: *origin*, by two heads from upper back part of condyles of femur and supra-condyloid ridges; *insertion*, with tendons of soleus and plantaris longus forms tendo-Achillis, which is inserted into posterior tuberosity of os calcis; *action*, extends foot; *nerve*, internal popliteal.

*Soleus*⁹: *origin*, tendinous, from back of head of fibula and upper third of postero-internal surface of shaft, from oblique line of tibia and from middle third of its inner border; *insertion*, tuberosity of os calcis by tendo-Achillis; *action*, extends foot; *nerve*, external popliteal.

Plantaris: *origin*, lower part of outer bifurcation of linea aspera and posterior ligament of knee-joint; *insertion*, posterior surface of os calcis with tendo-Achillis; *action*, extends foot; *nerve*, internal popliteal.

*Popliteus*⁶ (Fig. 67): *origin*, depression on outer side of external condyle of femur and posterior ligament of knee-joint; *insertion*, inner two-thirds of triangular surface above oblique line of tibia posteriorly, and tendinous expansion covering muscle; *action*, flexes leg upon thigh, then rotates tibia inward; *nerve*, internal popliteal.

FIG. 66.

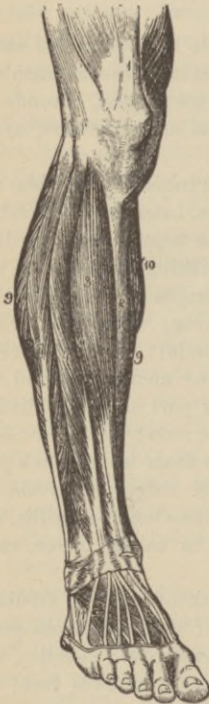
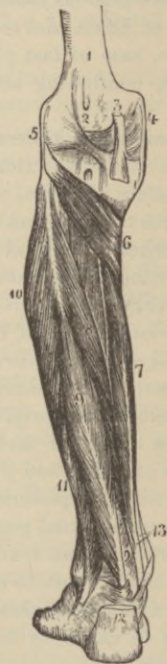
FIG. 67.



*Flexor longus pollicis*⁹ (Fig. 67): *origin*, lower two-thirds of postero-internal surface of shaft of fibula, except its lowest inch, lower part of interosseous membrane, intermuscular septum, and fascia covering tibialis posticus; *insertion*, base of last phalanx of great

toe; *action*, flexes great toe, then extends foot; *nerve*, posterior tibial.

*Flexor longus digitorum*⁷ (Fig. 67) (*perforans*): *origin*, posterior surface of tibia below oblique line internal to tibialis posticus, except lower three inches, also intermuscular septum, tendon passes behind malleolus in groove with tibialis posticus, but in separate synovial sheath; *insertion*, bases of phalanges of lesser toes by four tendons, each passing through a fissure in the tendon of the flexor brevis; *action*, flexes phalanges, then extends foot; *nerve*, posterior tibial.

*Tibialis posticus*⁸ (Fig. 67): *origin*, by two pointed processes, between which pass the anterior tibial vessels, from whole of posterior surface of interosseus membrane except lowest part, posterior surface of tibia, external to flexor longus, between oblique line above and middle of external border below, and from upper two-thirds of internal surface of fibula; *insertion*, tuberosity of scaphoid and internal cuneiform bones; *action*, extends tarsus on leg, adducts foot; *nerve*, posterior tibial.

*Peroneus longus*⁷ (Fig. 66): *origin*, head and upper two-thirds of outer surface of shaft of fibula, deep surface of fascia, and intermuscular septa, passes behind outer malleolus in groove with peroneus brevis⁸ (Fig. 64), then traverses groove of cuboid; *insertion*, outer side of base of great toe metatarsal and internal cuneiform; *action*, extends foot, then everts it; *nerve*, musculo-cutaneous.

*Peroneus brevis*⁸ (Fig. 66): *origin*, lower two-thirds of outer surface of shaft of fibula, intermuscular septa; *insertion*, passes with preceding muscle behind external malleolus in a groove lined with a synovial sheath common to both tendons, to be attached to dorsum of base of fifth metatarsal; *action*, same as peroneus longus; *nerves*, musculo-cutaneous.

Fasciæ of Foot.

The *anterior annular ligament* consists of (1) an upper vertical portion binding down the extensor tendons, attached to lower ends of tibia and fibula, continuous above with leg fascia, and containing only one synovial sheath situated internally for tendon of anterior tibial, the extensor longus digitorum, peroneus tertius, and ex-

tensor proprius pollicis tendons, and anterior tibial vessels and nerve passing beneath it without a distinct sheath; and (2) a horizontal portion attached externally to upper surface of os calcis, and internally to inner malleolus and plantar fascia, containing three sheaths, that internal for anterior tibial tendon, the next for extensor proprius pollicis tendon, and that most external for extensor longus digitorum and peroneus tertius.

The *internal annular ligament* is a strong band extending from inner malleolus to inner margin of calcis, converting the bony grooves on its surface into canals for the flexor tendons and plantar vessels; it is continuous with deep fascia of leg, plantar fascia, and origin of abductor pollicis muscle. Its three fibro-osseous canals transmit, enumerated from within outward, the tendons of posterior tibial, flexor longus digitorum, posterior tibial vessels and nerve—through broad space beneath ligament—and tendon of flexor longus pollicis.

The *external annular ligament* stretches between the extremity of the outer malleolus to outer surface of calcis, forming a common sheath for peroneal tendons.

The *plantar fascia*, the densest of all fibrous membranes, consists of a central and lateral portions; the former, thick and narrow behind, arising from inner tubercle of os calcis, divides into a process for every toe, each again splitting opposite metatarso-phalangeal joints into two slips—between which pass the flexor tendons—to be attached to sides of metatarsal bones and transverse metatarsal ligament; two chief and several subordinate intermuscular septa are given off, separating the muscular layers; the outer and inner segments are thin, and of no special interest.

Muscles of the Foot.

Dorsal region.

Extensor brevis digitorum: *origin*, outer surface of os calcis, external calcaneo-astragaloid ligament, and annular ligament; *insertion*, by four tendons, the first into first phalanx of great toe, the other three into outer sides of long extensor tendons of second, third, and fourth toes; *action*, accessory to long flexor on four inner toes; *nerve*, anterior tibial.

Plantar region. First layer.

*Abductor pollicis*³ (Fig. 68): *origin*, inner plantar tubercle of os calcis, internal annular ligament, plantar fascia, and intermuscular septum; *insertion*, with innermost tendon of flexor brevis pollicis into inner side of base of first great toe phalanx; *action*, abducts great toe; *nerve*, internal plantar.

*Flexor brevis digitorum*⁵: *origin*, tendinous from inner plantar tubercle of calcis, central part of plantar fascia and intermuscular septa; *insertion*, by four tendons for four lesser toes, perforated opposite middle of first phalanges by tendon of long flexor, beyond the perforation the tendon splitting to be inserted into sides of second phalanges; *action*, flexes lesser toes; *nerve*, internal plantar.

*Abductor minimi digiti*⁴: *origin*, outer plantar tubercle of os calcis, bone in front of both tubercles, plantar fascia, and intermuscular septum; *insertion*, with short flexor of little toe into outer side of base of first little toe phalanx; *action*, abducts little toe; *nerve*, external plantar.

Second layer.

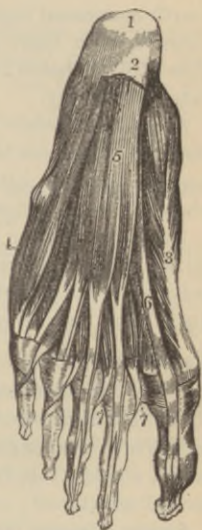Flexor accessorius: *origin*, by two heads, from concave surface of calcis and calcaneo-scapoid ligament and os calcis in front of outer tubercle, and from plantar ligament; *insertion*, outer margin and upper and under surfaces of tendon of long flexor of toes; *action*, aids long flexor; *nerve*, external plantar.

*Lumbricales*⁷: *origin*, tendons of long flexor; *insertion*, expansion of long extensor and bases of first phalanges; *action*, accessory to flexors; *nerves*, the two inner lumbricales by internal, the two outer by external plantar nerve.

Third layer.

Flexor brevis pollicis: *origin*, inner border of cuboid and contiguous portion of external cuneiform, and prolongation of posterior

FIG. 68.



tibial tendon; *insertion*, inner and outer side of base of first great toe phalanx by two tendons, each containing a sesamoid bone, the inner tendon blending with that of the abductor pollicis, the outer with that of adductor pollicis; *action*, flexes great toe; *nerves*, internal plantar, sometimes external plantar.

Adductor pollicis: *origin*, tarsal extremities of second, third, and fourth metatarsal bones and sheath of tendon of peroneus longus; *insertion*, with outer portion of the short flexor into outer side of base of first phalanx of great toe; *action*, adducts great toe; *nerve*, external plantar.

Flexor brevis minimi digiti: *origin*, base of little toe metatarsal and sheath of peroneus longus tendon; *insertion*, outer side of base of first phalanx of little toe; *action*, flexes first, extends second phalanx; *nerve*, external plantar.

Transversus pedis: *origin*, under surface of head of fifth metatarsal bone and transverse metatarsal ligament; *insertion*, with adductor pollicis into outer side of first phalanges of great toe; *action*, adducts great toe; *nerve*, external plantar.

Fourth layer.

Dorsal interossei (four): *origin*, each by two heads from adjacent sides metatarsal bones; *insertion*, tendinous into bases of first phalanges of corresponding toes and aponeurosis of common extensor; *action*, abducts toes from imaginary line passing through centre of second metatarsal; *nerve*, external plantar.

Plantar interossei (three): *origin*, base and inner sides of shaft of third, fourth, and fifth metatarsal bones; *insertion*, inner sides of bases of phalanges of same toes; *action*, adduct toes toward a line passing through middle of second toe; *nerve*, external plantar.

Vascular System.

What is the pericardium?

A closed fibro-serous sac of conical form, its apex surrounding the great vessels for about two inches above their origin, its base downward, attached to the central tendon of diaphragm. The outer fibrous coat is continued as tubular prolongations, lost upon the external coats of the roots of all the great vessels except the inferior vena cava, and is finally traceable as continuous with the

deep layer of the cervical fascia; the serous coat lines the sac, forming a *parietal layer*, is reflected over the heart and great vessels, forming a *visceral layer*; its function is the secretion of a thin fluid in sufficient amount to moisten the surfaces, thus lessening friction during the heart's movements.

Describe the heart.

It is a hollow, conical muscle, with four distinct cavities, situated obliquely between the lungs, the base upward, backward, and to the right, the apex¹¹ (Fig. 69) downward, forward, and to the left, corresponding to fifth intercostal space, one and a half inches below and three-fourths of an inch to the right of the left nipple.

Give the points upon the exterior of the thorax corresponding to space occupied by the heart.

The upper border corresponds to a line drawn across the sternum on a level with the lower borders of the second costal cartilages; its lower border to a line crossing gladiolus from right side of costoxiphoid joint to apex point above described; the right border extending from median line of sternum three inches, its left, one and one-half inches; as the lungs partially cover the heart in front, the "area of heart's dulness" can be roughly indicated, according to Holden, by "a circle one inch in radius, the centre of which is midway between the left nipple and the end of the sternum."

Give the size and weight of the heart.

In adults it measures five inches long, three and one-half broad, and two and one-half thick; weighs in male ten to twelve ounces, in proportion to body 1 to 169; in females, eight to ten ounces, 1 to 149.

What are the four cavities of the heart called?

The right auricle³ and right ventricle⁴, the left auricle and left ventricle, separated by a longitudinal septum—indicated externally in front and behind by the *interventricular grooves*—dividing the heart into lateral halves, the right, or venous heart, the left, or arterial heart; a transverse *auriculo-ventricular groove* on the exterior corresponds to the division between auricles and ventricles.

Describe the right auricle and the chief points requiring study.

Larger than the left auricle, with a capacity of about two fluid ounces, its walls are about one line thick; the venous blood is poured in by the superior¹ and inferior venæ cavæ² and the coronary sinus; note the following points:

The *sinus*, the large quadrangular cavity between the two venæ cavæ; the *appendix auriculæ*, a conical pouch with dentated edge, projecting forward to the left over the root of the aorta³; the *openings* of the two venæ cavæ, also that of the coronary sinus^{3'}, its orifice guarded by a semicircular fold of the auricular lining called the *coronary valve*—sometimes at its junction with the great coronary vein a valve with two unequal segments is found; the *tubercle of Lower*³, a small projection on the right wall directing blood from the superior cava toward auriculo-ventricular opening; the *foramina Thebesii*, the mouth of numerous minute veins returning blood from the heart muscle; the semilunar *Eustachian valve*^{3'} between the anterior margin of the inferior vena cava and auriculo-ventricular opening—it is larger in the fœtus, serving to direct the blood of the inferior cava through the foramen ovale; the *fossa ovalis*^{3'}, an oval depression at the lower part of the septum auricularum, the site of the oval foramen in the fœtus; the *annulus ovalis*, the prominent margin of fossa ovalis; the *musculi pectinati*, small prominent muscular columns, running across the inner surface of the appendix and adjoining wall of the sinus; the oval *auriculo-ventricular orifice*, about one inch in diameter, communicating with the right ventricle, its margins formed by a fibrous ring covered by the lining membrane, and guarded by the tricuspid valve.

Describe the right ventricle.

It is triangular, with apex downward, not quite reaching that of the heart, forming with the right auricle the anterior, rather than the right side of the heart; its capacity has been variously estimated at from two to six fluid ounces; it presents the following points for examination:

Above is the conical prolongation called the *conus arteriosus*, from which opens the orifice of the *pulmonary artery* placed to the left of the auriculo-ventricular orifice anteriorly, corresponding to

junction of third left costal cartilage with sternum, and is surrounded by a fibrous ring; the pulmonary *semilunar valves* guard this orifice; the *tricuspid valve*^{5, 5', 5''} formed of three triangular segments—the largest on the left side—by a reduplication of the lining membrane with interposed fibrous tissue, which are prevented from being forced into the auricle by the,

Chordæ tendineæ^{5''}, fine tendinous cords stretching from (1) the columnæ carneæ to the attached margin, (2) to the centres of the leaflets, and (3) to their free margins.

The *columnæ carneæ*^{4'}, three varieties of muscular columns, (1) simple ridges, (2) bands attached by both extremities, and (3) three or four *musculi papillares*, muscular eminences from which arise the *chordæ tendineæ*.

The three *pulmonary semilunar valves*⁴, two anterior and one posterior, formed by a reduplication of the lining membrane with interposed fibrous tissue, with their free margins strengthened by a bundle of fibrous tissue, whose fibres radiate from a fibro-cartilaginous nodule—the *corpus Arantii*—to all parts, except to two narrow lunated portions on either side of the nodule, which are forced in contact when the valves are closed; above and behind each valve is a dilatation, the *sinus of Valsalva*.

Describe the left auricle.

Resembles the right in having a principal cavity or sinus and an appendix, but its walls are thicker, measuring about one and one-half lines. The following points should be studied:

The *openings of the pulmonary veins*, usually four in number, two emptying into the right and two into the left side; frequently the latter terminate by a common opening.

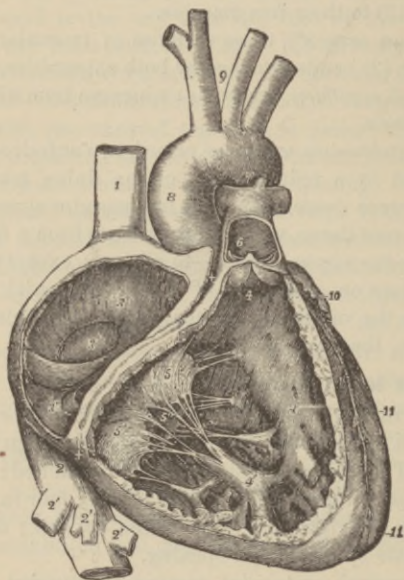
The *oval auriculo-ventricular opening*, surrounded by a fibrous ring, smaller than the right; the *musculi pectinati* fewer and smaller than on the right side; a *depression* over site of the fossa ovalis of the right auricle.

Describe the left ventricle.

Larger and more conical than the right it forms but little of the left side, most of the posterior surface and all the apex¹¹ of the heart, its walls being three times as thick as those of the right ventricle; its inner surface presents for examination,

The *circular aortic opening*, with the usual fibrous ring, in front and to the right of the auriculo-ventricular opening, between them intervenes one of the segments of the mitral valve; the aortic orifice is opposite the left half of the sternum, on a line with the lower border of the third costal cartilage, its mouth being guarded by three semilunar valves; the *mitral valve*, composed of two

FIG. 69.



irregular segments—the larger in front—similar to those of the tricuspid valve, but larger and thicker, the leaflets being provided with chordæ tendinæ, whose mode of attachment is identical with those of the right side. The *semilunar aortic valves* resemble those of the pulmonary artery, but are larger and stronger; *sinuses*, like the sinuses of Valsalva of the pulmonary artery, are found behind the aortic valves.

The *columnæ carneæ* are more numerous, but smaller than on the right side, while there are only two *musculi papillares*.

What is the endocardium?

The delicate lining membrane of the heart continuous with the intima of the great vessels, by its reduplications forming the various valves.

Describe the heart structure.

It consists of *striated anastomosing* muscular fibres taking origin from the fibrous rings surrounding the aortic, pulmonary, and auriculo-ventricular openings, disposed in the *auricles* in a *deep layer* composed of looped and annular fibres, and a *superficial transverse layer*; in the *ventricles* numerous layers have been described, the deepest of which run circularly, the more superficial spirally, curving round the apex to form the *whorl* or *vortex*, those fibres from in front curving around to enter posteriorly, and *vice versa*; the most superficial fibres, especially those behind, pass across the septum from one ventricle to the other.

The Arteries.

What are the arteries?

Cylindrical tubular vessels conveying blood *from* both ventricles to all parts of the body; the blood they carry is called *arterial*; the pulmonary artery arising from the right ventricle conveying blood to the lungs, and the four pulmonary veins returning it to the left auricle, constitute the *lesser or pulmonic circulation*, while the aorta arising from the left ventricle carrying blood to the body generally, and the veins returning it, finally emptying by the two-cavæ into the right auricle, form the *greater or systemic circulation*. In their distribution the arteries freely communicate with one another, the large branches as well as the small forming what are called *anastomoses* or *inosculations*, permitting the establishment of the collateral circulation after obliteration of a main artery.

Describe the structure of the arteries.

They possess three coats, an (1) *internal* (serous) or *intima*; (2)

a *middle (media)*, composed in small vessels almost purely of circular muscular fibres, in the larger chiefly of yellow elastic tissue; this prevents the arteries from collapsing when cut across; (3) an *external (adventitia)* composed of connective tissue. Every vessel, except the intracranial vessels, is included with its vein or veins in a fibro-areolar *sheath*.

FIG. 70.



How are the arteries nourished and their calibre regulated?

The larger vessels are supplied by minute *vasa vasorum*, bloodvessels distributed in a fine network to their external and middle coats; while intricate nerve networks (plexuses), chiefly derived from the sympathetic with branches of the spinal system, supply the same coats of the large vessels—the smaller are usually supplied only with single filaments.

What are capillaries?

The intermediate vessels between the arteries and veins, disposed in the form of a network, of an average diameter of one-three-thousandths of an inch, formed of a fine transparent layer of endothelial cells united by a cement substance.

Describe the aorta^{1, 2, 3}, (Fig. 70).

This, the main trunk of the systemic arteries, arises from the upper part of the left ventricle, ascends and then arches backward to the left over the root of the left lung to descend within the thorax on the left side of the vertebral column, entering the abdominal cavity by the aortic opening^a through the diaphragm, where it terminates opposite the fourth lumbar vertebræ in the

two common iliac arteries²³; the aorta is divided for convenience of study into the arch¹, thoracic², and abdominal aorta³, while the arch is described as consisting of an *ascending*, *transverse*, and *descending portion*. The branches of each subdivision are,

<i>From the arch</i>	{ Two coronary,	Left common carotid ⁷ ,
	{ Innominate ⁴ ,	Left subclavian ⁸ .
<i>From the thoracic aorta</i>	{ Pericardiac,	Posterior mediastinal,
	{ Bronchial ⁹ ,	Intercostals ^{11, 12} ,
	{ Esophageal ¹⁰ .	
<i>From the abdominal aorta,</i>	Two phrenic ¹³ ,	Two spermatic ^{x20} .
	{ Gastric ¹⁵ ,	Inferior mesenteric ²¹ ,
Cœliac axis ¹⁴	{ Hepatic ¹⁷ ,	
	{ Splenic ¹⁶ ,	Eight lumbar ²² .
	Superior mesenteric ¹⁸ ,	
	Two supra renal ¹⁹ ,	Sacra media ²⁴ ,
	Two renal ²⁰ .	

Describe the coronary arteries.

The right arises from the aorta above the free margin of the right semilunar valve, passes in groove between right auricle and ventricle to posterior interventricular groove, where, dividing into two branches, one continues onward anastomosing with the left coronary, the other descends along the interventricular groove to apex of heart anastomosing with descending branch of left coronary; the left coronary, the smaller, arises above the free edge of left semilunar valve, passes forward between pulmonary artery and left appendix, thence obliquely to anterior interventricular groove, where it divides, one branch passing around to join the right vessel, the other descending in the groove to anastomose at apex with descending branch of right vessel.

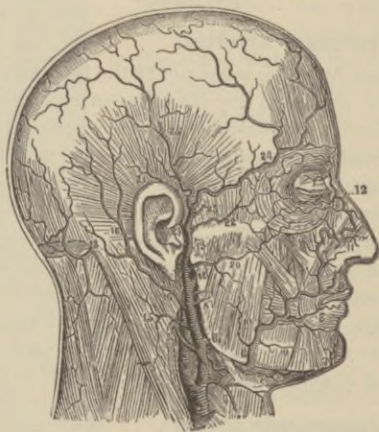
Describe the innominate artery⁴.

Arising from the commencement of transverse portion of arch, it is from one and a half to two inches long and bifurcates at upper border of right sterno-clavicular articulation into right common carotid⁵ and subclavian⁶, sometimes it sends off a *middle thyroid* branch—occasionally no innominate exists, the right carotid and subclavian springing directly from the aorta.

Describe the common carotid^{5, 7}.

The right arises opposite right sterno-clavicular joint from innominate, the left from summit of aortic arch. In the neck their course corresponds to a line passing from the sterno-clavicular joint to a point midway between the mastoid process and angle of lower jaw; below, the trachea only separates them, above there is a wide interval; a common sheath of deep fascia encloses the internal jugular vein, the pneumogastric nerve (posterior to both), and artery, enumerated from *without inward*, while upon the sheath lies the descending branch of the ninth cranial nerve (*descendens noni*); the vessel is overlapped for most of its course by the anterior margin of the sterno-cleido-mastoid muscle, while about its middle it is crossed by the omo-hyoid muscle, the anterior jugular, and middle thyroid veins, while above the omo-hyoid

FIG. 71.



muscle, the sterno-mastoid artery, and the superior thyroid vein cross it; at the lower part of the neck the right internal jugular vein diverges from the artery, but the left often crosses the lower part of corresponding artery; opposite the upper border of the thyroid cartilage, each vessel divides into the internal and external carotid.

Name the branches of the external carotid artery with their subdivisions.

*Superior thyroid*⁴, arising below greater cornu of hyoid bone; its branches are

Muscular,	Hyoid,	Superior laryngeal,
Superficial descending (sterno-mastoid),		Crico-thyroid.

Lingual arises between thyroid and facial running beneath hyoglossus muscle to under surface of tongue; its branches are

Hyoid, Dorsalis Linguae, Sublingual, Ranine.

*Facial*⁶ arises just above lingual to cross lower jaw just anterior to masseter muscle; its branches are

Inferior or ascending palatine,	Muscular ¹⁰ ,	Lateralis nasi ¹¹ ,
Tonsillar,	Inferior labial ⁸ ,	Angular ¹² ,
Submaxillary,	Inferior coronary ⁸ ,	
Submental ⁷ ,	Superior coronary ⁹ .	

*Occipital*¹³ arises posteriorly opposite facial, lies in occipital groove of temporal bone; its branches are

Muscular,	Meningeal,	Cranial	} (distributed over occiput).
Auricular,	Arteria princeps		
Sterno-mastoid.	cervicis.		

*Posterior auricular*¹⁶ arises opposite styloid process, ascends beneath parotid gland to groove between cartilage of ear and mastoid process; its branches are

Stylo-mastoid, Auricular, Muscular, Parotid.

Ascending pharyngeal, running between carotid and side of pharynx; its branches being

External	} (muscular and nervous),	Pharyngeal,	Meningeal.

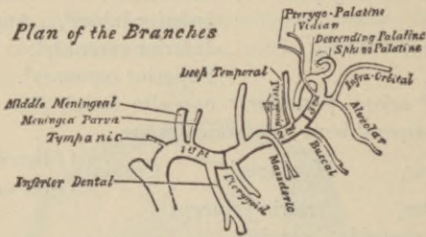
Temporal, the smaller terminal branch, commences in substance of parotid gland, crosses root of zygoma, two inches above which it divides into anterior²⁴ and posterior²⁵ temporal; its branches are

Transverse facial²⁰ (Fig. 71), Middle temporal²³ (Fig. 71),
Anterior auricular.

*Internal maxillary*¹, the larger terminal branch passes inward at right angles to the vessel at the inner side of neck of condyle of the lower jaw; it is divided into three portions, (1) maxillary, (2) pterygoid, and (3) spheno-maxillary.

- | | | |
|---|--|-------------------------|
| (1) Anterior tympanic,
Middle meningeal, | Small meningeal,
Inferior dental | } Incisor,
} Mental. |
| (2) Deep temporal
anterior and posterior,
Pterygoid, | Masseteric,
Buccal. | |
| (3) Alveolar,
Infra-orbital,
Posterior or descending
palatine. | Vidian,
Pterygo-palatine,
Nasal or speno-palatine. | |

FIG. 72.



Describe the internal carotid artery.

It runs in front of the transverse processes of the three upper cervical vertebræ in contact with the pharynx and tonsil to the carotid canal of temporal bone, enters the skull, passes through the cavernous sinus and pierces the dura mater near the anterior clinoid processes when it divides into its terminal branches.

Give its branches.

Tympanic (deep), from artery in carotid canal, anastomosing with tympanic branch of internal maxillary, stylo-mastoid, and Vidian arteries.

Arteriæ receptaculi, small vessels supplying cavernous and inferior petrosal sinuses, pituitary body, Gasserian ganglion; one to the dura mater anastomosing with the middle meningeal is called the *anterior meningeal*,

Ophthalmic, from cavernous portion, enters orbit by optic fora-

men, dividing at the inner angle of the eye into two terminal divisions, the *frontal* and *nasal*; its branches are

Lachrymal,	Nasal,
Supraorbital,	Muscular,
Posterior ethmoidal,	Anterior ciliary,
Anterior ethmoidal,	Short ciliary,
Palpebral,	Long ciliary,
Frontal,	Arteria centralis retinae.

Anterior cerebral passes forward in the great longitudinal cerebral fissure, and communicates with its fellow by the anterior communicating artery, a vessel about two lines long.

Middle cerebral, the largest branch is lodged in the Sylvian fissure and divides into an anterior branch to pia mater; a middle branch to small lobe at outer extremity of fissure; and a posterior branch, supplying middle cerebral lobe.

Anterior choroid, to hippocampus major, corpus fimbriatum, velum interpositum, and choroid plexus.

Posterior communicating runs back to anastomose with posterior cerebral, a branch of basilar artery.

Describe the circle of Willis.

It consists of a vascular anastomosis at the base of the brain, between the branches of the carotids and basilar artery, whereby pressure on, or blocking of any two of the main trunks, will not prevent both sides of the brain from receiving a supply of blood. Its formation is as follows: The two vertebrals by their junction form the *basilar*, which divides into two *posterior cerebral*, these latter being connected with the back part of the internal carotids on each side by a *posterior communicating*, while the anterior terminals of the carotid, viz., the *anterior cerebral* on each side, is connected in front with its fellow by the short *anterior communicating artery* before mentioned.

Describe the subclavian.

On the right side it springs from the innominate, on the left directly from the aortic arch. It is divided into three portions, viz., that internal to the anterior scalene muscle, that behind the muscle, and that external to the scalene, this muscle intervening between the artery and subclavian vein; it ceases to be called sub-

clavian at the lower border of the first rib, being termed axillary. All the branches arise from the first portion, except the superior intercostal on the right side, which comes from the second portion; its branches are,

The *vertebral*, which passes through the foramina in cervical transverse processes except that of seventh, enters skull through foramen magnum, joining its fellow at the lower border of the pons Varolii to form the *basilar artery*; its branches are,

Lateral spinal,	Anterior spinal,
Muscular,	Posterior spinal,
Posterior meningeal,	Posterior inferior cerebellar.

The *basilar*, formed by the *vertebrals*, gives off the following branches :

Transverse, Anterior inferior cerebellar, Superior cerebellar, Posterior cerebral.

Thyroid axis divides almost at once into

Inferior thyroid, to same named gland, giving off		
Laryngeal,	Muscular,	Œsophageal,
Tracheal,		Ascending cervical.

Suprascapular, chiefly to shoulder-joint and supra-spinous fossa; it anastomoses with acromial thoracic, posterior circumflex, the posterior and subscapular arteries.

Transversalis colli, larger than preceding, passes transversely outward to trapezius, beneath which it divides into the

Superficial cervical,	Posterior scapular.
-----------------------	---------------------

Internal mammary arises from under surface of first portion, opposite thyroid axis, descends upon costal cartilages a short distance from the sternum to the sixth interspace, where it divides into *musculo-phrenic* and *superior epigastric*, the latter anastomosing with the deep epigastric of external iliac; the branches are,

Superior phrenic (comes	Anterior intercostal,
nervi phrenici),	Perforating,
Mediastinal,	Musculo-phrenic,
Pericardiac,	Superior epigastric.
Sternal.	

Superior intercostal, its branches are,

Intercostals,	Posterior muscular,	Spinal,
---------------	---------------------	---------

Profunda cervicis, supplying posterior cervical muscles and anastomosing with arteria princeps cervicis from occipital.

Describe the axillary.

It extends from lower border of first rib to lower border of tendons of latissimus dorsi and teres major muscles, when it takes the name of brachial; its branches are,

Superior thoracic, supplying pectoral muscles and thoracic wall.

Acromial thoracic, supplying the deltoid by acromial branches, the serratus magnus, and pectorals by thoracic and descending branches.

Long thoracic, to chest muscles and mammary gland.

Alar thoracic, supplies axillary glands.

Subscapular, anastomosing with supra- and posterior scapular arteries, and giving off the dorsalis scapulæ.

Posterior circumflex, to deltoid muscle and shoulder-joint; it anastomoses with the anterior circumflex, supra-scapular, acromial thoracic, and superior profunda arteries.

Anterior circumflex, to joint and deltoid; it anastomoses with posterior circumflex and acromial thoracic arteries.

Describe the brachial.

A continuation of axillary, extending from lower border of teres major and latissimus dorsi tendons to its bifurcation into radial and ulnar, usually just below bend of elbow; the median nerve crosses it from without inward about midway in its course; its branches enumerated from above downward are,

Superior profunda, descending arm in musculo-spiral groove, giving off posterior articular artery, which anastomoses with the interosseous recurrent, posterior ulnar recurrent, and anastomotica magna, or inferior profunda, while the terminal twigs of the main trunk inosculate with the recurrent radial.

Nutrient artery, to humerus.

Inferior profunda, anastomosing with anterior and posterior ulnar recurrents and anastomotica magna.

Anastomotica magna, anastomosing with posterior articular, inferior profunda, anterior and posterior ulnar recurrents.

Muscular, to arm muscles.

Describe the radial artery.

It appears to be a continuation of brachial, but much smaller, extending from bifurcation at elbow along radial side of forearm to wrist, where, winding beneath the thumb, it passes between the two heads of the first dorsal interosseous muscle to palm, there inosculating with the deep or communicating branch of the ulnar to form

The *deep palmar arch*, having as branches three to four palmar interossei; sometimes described as also giving off the radialis indicis, perforating, and recurrent branches, here credited to main vessel.

The branches of radial are,

Forearm,
Radial recurrent,
Muscular,
Superficialis volæ,
Anterior carpal.

Wrist,
Posterior carpal,
Metacarpal,
Dorsalis pollicis,
Dorsalis indicis.

Hand,
Princeps pollicis,
Radialis indicis,
Perforating,
Interosseous.

Describe the ulnar.

Larger than the preceding, it passes from bifurcation obliquely inward to middle of forearm, thence runs along its ulnar border, across annular ligament to radial side of pisiform bone, curving across palm where, either with or without anastomosing with the superficialis volæ of the radial, it forms the

Superficial palmar arch, whose branches are the four digitals.

The branches of the ulnar are, in the

Forearm,
Anterior ulnar recurrent,
Posterior ulnar recurrent,
Interosseous { *Anterior interosseous,*
 { *Posterior interosseous,*
Muscular.

Wrist,
Anterior carpal,
Posterior carpal.

Hand,
Deep, or communicating branch,
Digitals.

Describe the thoracic aorta² (Fig. 73).

Commencing at left side of lower border of fifth dorsal vertebra, it terminates at the aortic opening^a, in diaphragm in front of body of last dorsal vertebra; its branches are,

Pericardiac, variable in number and origin, for pericardium.

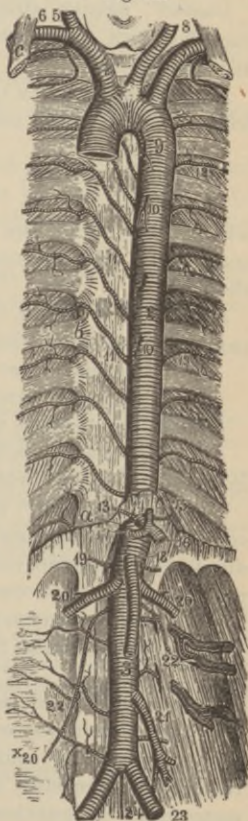
*Bronchial*⁹, irregular in number and origin, usually one right and two left, for lung-tissue proper.

*Esophageal*¹⁰, commonly numbering four to five, anastomosing around the gullet with branches of inferior thyroid, phrenic, and gastric arteries.

Posterior mediastinal, numerous and small to glands and areolar tissue.

Intercostals^{11, 12}, usually ten on either side, each dividing into an anterior and posterior branch, the former subdividing into two at the angle of the ribs, one branch running in groove at lower border of rib above, the other running along the upper border of the rib below, in front both anastomosing with anterior intercostal branches of the internal mammary, with thoracic branches of axillary, with epigastric, phrenic, and lumbar arteries; the posterior division supplies the vertebræ, spinal cord, dorsal muscles, and skin.

Fig. 73.



Describe the abdominal aorta³.

It commences at the aortic opening^a, of the diaphragm in front of body of last dorsal vertebræ, whence descending a little to left of vertebral column it terminates on the body of the fourth lumbar vertebra by dividing into the common iliacs²³; its branches are,

*Cœliac axis*¹⁴, arises opposite margin of diaphragm, passes for half an inch forward to divide into the

*Gastric*¹⁵, passing along greater curvature of stomach, anastomosing with aortic œsophageal, and branches of splenic and hepatic arteries.

*Hepatic*¹⁷, dividing in transverse hepatic fissure into right and left branches for same lobes of liver; its branches are,

Pyloric,	}	Gastro-epiploica dextra,
Gastro-duodenalis,		
Cystic,		

whereby it supplies the parts indicated by names of vessels, and anastomoses with splenic, gastric, and superior mesenteric arteries.

*Splenic*¹⁶, the largest branch, passes behind upper border of pancreas to spleen, giving off the

Pancreaticæ parvæ,	Gastric (vasa brevis),
Pancreatica magna,	Gastro-epiploica sinistra.

(One of the phrenics may arise from the cœliac axis.)

*Phrenic*¹³, one on each side (sometimes one from cœliac axis instead of aorta) to under surface of diaphragm.

*Superior mesenteric*¹⁸ comes off about one-quarter inch below cœliac axis, arching forward and downward to the left, supplying all of small intestine, except first part of duodenum, also cœcum, ascending, and transverse colon, giving off,

Inferior pancreatico-duodenal,	Ileo-colic,
Vasa intestini tenuis,	Colica-dextra,
Colica media.	

*Inferior mesenteric*²¹, arising from left side of aorta two inches above bifurcation, passes down into left iliac fossa and pelvis, supplying descending colon, sigmoid flexure, and greater part of rectum, anastomosing above with the middle colic of superior mesenteric; its branches are,

Colica sinistra, Sigmoid, Superior hemorrhoidal.

Suprarenal, each arises opposite superior mesenteric to supply suprarenal bodies.

*Renal*²⁰, spring nearly at right angles from sides of aorta below superior mesenteric, the right longer than left; each divides into four or five branches before entering hilum of kidney, intervening between the renal vein in *front*, and the ureter *behind*.

*Spermaticæ*²⁰ (ovarian in female), spring from front of aorta on each side, a little below renals, run behind peritoneum to pass in *male* through abdominal ring to testes, in *female* between the laminae of the broad ligaments to the ovaries, Fallopian tubes, uterus, and integument of labium and groin.

*Lumbar*²², commonly four on each side corresponding to intercostals, and like them dividing into

Dorsal branches to vertebræ, spinal cord and back muscles, and abdominal branches, passing forward to anastomose with twigs from epigastric, internal mammary, intercostals, ilio-lumbar, and circumflex iliac.

*Middle sacral*²⁴, springs from bifurcation, descends along middle of sacrum and coccyx, sending branches to rectum, lateral sacral arteries, etc.

Describe the common iliac arteries.

They extend from the aortic bifurcation to left of umbilicus—corresponding to a line touching the highest point of iliac crests—to divide opposite the intervertebral disk between the last lumbar vertebræ and the sacrum, into the *internal* and *external iliac*; the right vessel is somewhat the longer, both being about two inches long, and each at its bifurcation is crossed by the ureter.

Describe the internal iliac.

It measures about one and a half inches, arising at point of bifurcation of common iliac, to divide at upper margin of great sacrosiatic foramen into the *anterior* and *posterior trunk*; its branches are

Anterior division.

Superior vesical, part of foetal hypogastric artery; it supplies vas deferens and ureter, as well as bladder.

Middle vesical, usually branch of former to bladder and vesiculæ seminales.

Inferior vesical (vaginal in female), arising in common with middle hemorrhoidal, and is distributed to base of bladder, prostate gland, and seminal vesicles.

Middle hemorrhoidal, supplies rectum.

Uterine (in female), anastomosing with ovarian.

Obturator, passes through obturator canal to thigh, there dividing into an internal and external branch, anastomosing with twigs of internal circumflex; inside the pelvis its branches are

Iliac, to same named bone and muscle anastomosing with ilio-lumbar; a *vesical*, to bladder; and a *pubic*, inosculating back of pubes with epigastric; in two out of every three cases the obturator springs from internal iliac, in one case in three and a half from epigastric.

Internal pudic, the smaller terminal of anterior division, is distributed to the external organs of generation; giving off the following branches

Inferior hemorrhoidal,	Artery of the bulb,
Superficial perineal,	Artery of the corpus cavernosum,
Transverse perineal.	Dorsal artery of the penis.

Sciatic, the larger terminal, supplies muscles on back of pelvis; its branches are,

Muscular (internal),	Coccygeal,	Muscular (external),
Hemorrhoidal,	Inferior gluteal,	Articular (hip),
Vesical,	Comes nervi ischiadici.	

Posterior division.

Ilio-lumbar, dividing into an iliac and lumbar branch supplying muscular, spinal, and bone branches, anastomosing with gluteal, circumflex iliac, external circumflex, and epigastric arteries, etc.

Lateral sacral, superior and inferior on each side anastomosing with gluteal.

Gluteal, the termination of posterior division, divides into a superficial and deep branch, giving off

Muscular, cutaneous, nutrient (to ilium), and *articular branches*, anastomosing with circumflex iliac and external circumflex arteries.

Describe the external iliac.

Passes along inner border of psoas muscle from bifurcation of common iliac to Poupart's ligament; a line drawn from left side of umbilicus to the midpoint between symphysis pubis and anterior superior iliac spine (in females a little nearer the former), indicates its course; its branches are

Muscular, *Lymphatic* (to glands).

Deep epigastric, usually coming off just above Poupart's ligament, passing between peritoneum and transversalis fascia to pierce the lower third of sheath of the rectus abdominis muscle, continuing back of which it anastomoses with internal mammary and inferior intercostal arteries; its branches are

Cremasteric, *Pubic,* *Muscular.*

Deep circumflex iliac, arises externally nearly opposite epigastric, running along inner side of iliac crest to its middle, there to pierce the transversalis muscle; it anastomoses with ilio-lumbar, gluteal, lumbar, and epigastric arteries.

Describe the femoral artery.

Extending from Poupart's ligament, where the letters N. A. V. indicate its relation with the anterior crural nerve and femoral vein—it terminates at the opening in the adductor magnus (commencement of Hunter's canal); the upper two-thirds of a line drawn from the midpoint between the anterior superior iliac spine and symphysis pubis to inner side of internal condyle of the femur indicates its course. The artery and vein are enclosed in a strong fibrous sheath, but separated by a partition from each other, and lie very superficially above, in "Scarpa's triangle," bisecting it.

What is Scarpa's triangle?

It is a space bounded above by Poupart's ligament, internally by the adductor longus, and externally by the sartorius, the floor being formed chiefly by the iliac, psoas, pectineus, and long adductor muscles, the inner margin of the latter intervening between the artery and capsule of the hip-joint.

The femoral gives off the

Superficial epigastric^A, to inguinal glands, fascia, and skin, anastomosing with deep epigastric and internal mammary.

Superficial circumflex iliac^s, to skin of groin, glands, etc., anastomosing with deep circumflex iliac, gluteal, and external circumflex.

FIG. 74.

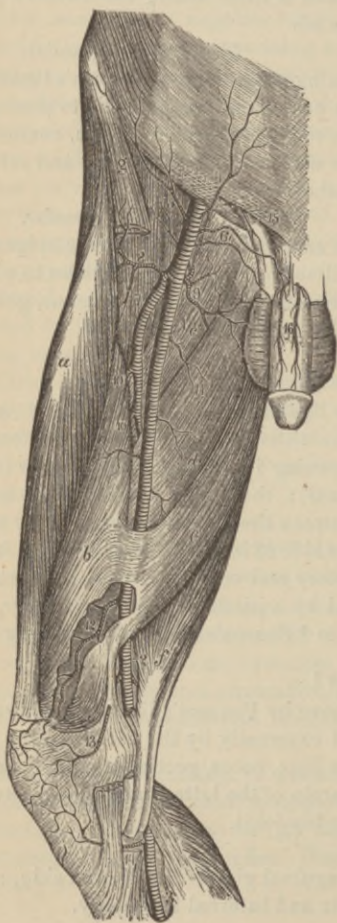
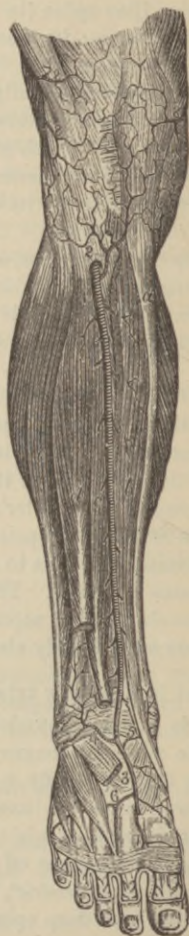

FIG. 75.



*Superficial external pudic*⁶, to skin of genitals, anastomosing with internal pudic.

*Deep external pudic*⁶, to skin of genitals and perineum, anastomosing with superficial perineal.

*Profunda femoris*⁷, springing from outer back part of femoral from one to two inches below Poupart's ligament, terminating at lower third of thigh by the small fourth perforating artery; it gives off

*External*⁸ and *Internal circumflex*⁹. *Three perforating*¹⁰.

*Muscular*¹¹, chiefly to sartorius and vastus internus.

*Anastomotica magna*¹², arises just above Hunter's canal, and divides into a superficial (cutaneous), and a deep branch; anastomosing with the superior¹³ internal and external articular, and recurrent tibial.¹⁴

Describe the popliteal artery.

It commences at the opening in the adductor magnus, and passing obliquely downward and outward behind the knee-joint, divides opposite the lower border of the popliteus muscle into the *anterior* and *posterior tibial arteries*. Its branches are

<i>Superior muscular,</i>	<i>Azygos articular,</i>
<i>Cutaneus,</i>	<i>Inferior internal articular,</i>
<i>Superior external articular,</i>	<i>Inferior external articular,</i>
<i>Superior internal articular,</i>	<i>Inferior muscular or sural.</i>

These anastomose with the inferior perforating terminal branches of profunda, comes nervi ischiadici, anastomotica magna, recurrent tibial and with each other, except the muscular; the azygos articular enters back of joint to supply the synovial membrane and intra-articular ligaments.

Describe the anterior tibial artery.

Commencing at lower border of popliteus muscle, passing between the two heads of the posterior tibial muscle by the defect at the upper part of the interosseous membrane, lying upon its anterior surface and that of the lower third of the tibia, it terminates at the front of bend of the ankle in the *dorsalis pedis artery*; the anterior tibial nerve lies in close contact externally; it gives off the

*Recurrent tibial*², *Muscular*, *Internal*⁵ and *External*⁴ malleolar.

Describe the dorsalis pedis artery³.

It extends from front of bend of ankle to back part of first interosseous space, where it divides into the

*Dorsalis hallucis*⁷, supplying the great toe and adjoining side of second toe, and the

*Communicating*⁷, dipping down between heads of first dorsal interosseous muscle to reach the sole of foot, and form with external plantar the plantar arch; the other branches are the

Tarsal, arching outward across tarsus.

*Metatarsal*⁶, runs anterior to preceding over bases of metacarpal bones, giving off

Three interossei, from which arise *seven digitals*.

Describe the posterior tibial artery.

It extends as a large vessel obliquely downward from lower border of popliteus muscle along tibial side of leg to the midpoint of the depression between the inner ankle and heel, where, beneath the adductor pollicis muscle it divides into the internal and external plantar; the posterior tibial nerve lies first to its inner side, but soon crosses it, to remain close to the outer side; it gives off the

Peroneal, along back of fibular side of leg, giving off

Anterior peroneal, piercing interosseous ligament two inches above outer malleolus, anastomosing with external malleolar and tarsal arteries; it also gives muscular branches and nutrient artery to fibula: the *posterior tibial* also gives off the

Nutrient (of tibia), largest to any bone.

Muscular, to posterior leg muscles.

Communicating, to peroneal, passing transversely across back of tibia about two inches above ankle.

Internal calcanean, several large branches to inner muscles of sole, fat and skin of heel, anastomosing with peroneal and internal malleolar.

Describe the internal plantar.

The smaller terminal of posterior tibial, it runs along inner side of foot and great toe.

Describe the external plantar artery.

It passes obliquely outward and forward to base of fifth meta-

tarsal, whence it curves inward to interval between bases of first and second metatarsal bones, there anastomosing with the communicating branch of the dorsalis pedis, completing the *plantar arch*, whose branches, in addition to numerous *muscular* ones, are,

Posterior perforating, passing up the three outer interosseous spaces to anastomose with the interossei from the metatarsal.

Four digitals, by division supplying both sides of the three outer toes, and the outer side of the second—both sides of the great and inner side of the second toe being supplied by the communicating branch of dorsalis pedis.

Describe the pulmonary artery.

It is a wide vessel conveying venous blood from the right ventricle to the lungs, about two inches long, and springs, in front of the aorta, from left side of the base of the right ventricle, lying for most of its course within the pericardium, passing obliquely to the left, upward and backward, dividing at the under surface of the aortic arch into a *right* and *left pulmonary artery*, the former the longer; each vessel passes horizontally outward to its respective lung, where it divides into two main branches, one of those of the right subdividing to supply the third lobe; these vessels subdivide to terminate in the pulmonary capillaries.

Describe the collateral circulation after ligature of the common carotid.

The chief communications are between superior and inferior thyroids, the profunda cervicis and princeps cervicis of the occipital, the vertebral taking the place of the internal carotid within the cranium. (The student must remember that while all the anastomosing vessels coming off above and below the site of ligature enlarge, and should, therefore, be carefully impressed upon the mind where enumerated in the preceding pages, yet the blood, by dissection, has been found to pass chiefly by the vessels mentioned under each caption.)

After ligature of the subclavian.

Between the supra-scapular and posterior scapular with sub-scapular, the internal mammary and the long and short thoracic and subscapular.

After ligature of axillary.

If below acromial thoracic, chiefly between the subscapular and other scapular arteries of subclavian, and long thoracic, through intercostals with internal mammary; if below subscapular, the posterior circumflex anastomosing with supra-scapular and acromial thoracic, and inosculation between the subscapular and superior profunda.

After ligature of brachial.

(1) Upper third, by anastomoses between circumflex and subscapular and superior profunda; (2) below the profunda arteries, by branches of the profundæ anastomosing with recurrent ulnar, radial, and interosseous.

When thoracic aorta is obliterated.

The internal mammary anastomosing with intercostals; phrenic, by musculo-phrenic and comes nervi phrenici and deep epigastric, superior intercostal and first aortic intercostal; inferior thyroid with first aortic intercostal; transversalis colli with posterior branches of intercostals; axillary and subclavian branches to side of chest with lateral branches of intercostals.

When abdominal aorta is tied.

The deep epigastric communicating with the internal mammary, the intercommunications of superior and inferior mesenteric, or the latter with the internal pudic, and the anastomoses of the lumbar with branches of internal iliac.

After common iliac is tied.

The anastomosis of hemorrhoidal branches of internal iliac with superior hemorrhoidal from inferior mesenteric, the inosculation of the uterine and ovarian, and of vesicals of opposite sides, that of lateral sacral with sacra media, of epigastric with internal mammary, intercostal and lumbar, of ilio-lumbar with last lumbar, of obturators with one another and deep epigastric, of gluteal with posterior sacral branches.

After internal iliac is tied.

Same as above, except obturator also communicates with internal

circumflex, the circumflex and perforating branches of femoral with sciatic, and the circumflex iliac with ilio-lumbar and gluteal.

After external iliac is tied.

The anastomoses between the ilio-lumbar and circumflex iliac; the gluteal and external circumflex; the obturator and internal circumflex; the sciatic with superior perforating and circumflexes; the internal pudic with external pudic and internal circumflex.

After common femoral is tied.

Anastomoses of gluteal and circumflex iliac with external circumflex; obturator and sciatic with internal circumflex; ilio-lumbar with external circumflex; comes nervi ischiadici with surals.

After superficial femoral is tied.

Branches from profunda anastomosing with superior and inferior articulares of knee, anastomotica magna, surals, and origins of anterior and posterior tibial.

(The popliteal is never tied except for wound, when the articular arteries, anastomotica magna, recurrent tibial, perforating branches, and surals would convey the blood.)

The Veins.

Describe the veins.

They are vessels returning venous blood—*i. e.*, blood surcharged with carbonic acid, to the heart, and have the same coats as arteries, but not so thick, especially the middle, in consequence collapsing when divided. One set of veins only carries other than venous blood, *viz.*, the pulmonary, conveying arterial blood from the lungs to the left auricle. Certain of the veins, usually the superficial, have their lining membrane forming semilunar reduplications or valves, arranged in pairs opposite one another, which prevent any reflux of blood. The large arteries are accompanied by deep veins of the same name, generally included in the same sheath, while such vessels as the brachial, radial, ulnar, etc., have two veins each, called *venæ comites*. The superficial veins run between the layers of the superficial fascia, terminating in the deep

veins, and are not usually accompanied by arteries. All veins freely anastomose, and even those dignified with special names have very irregular origins and distributions.

What are sinuses?

Venous channels, found only within the skull, formed by a separation of the layers of the dura mater, lined with endothelium continuous with that of the veins.

How are the veins classed?

As belonging to the *pulmonary, systemic, or portal systems*, the latter an appendage of the systemic.

Name the principal veins which have no valves.

The venæ cavæ, hepatic, portal, renal, uterine, ovarian, cerebral, spinal, and pulmonary.

Name the veins of the head and neck.

(1) Those of the exterior :

Facial,	Internal maxillary,	Posterior auricular,
Temporal,	Temporo-maxillary,	Occipital.

(2) Those which return the blood from head and face :

External jugular,	Anterior jugular,
Posterior external jugular,	Internal jugular,
	Vertebral.

(3) Veins of diploë and cranium :

Veins of diploë,	Cerebral,
Cerebellar,	Ventricular, or venæ galenæ.

Name the cerebral sinuses.

Superior longitudinal,	Straight sinus,
Inferior longitudinal,	Lateral sinuses (2),
Occipital (2),	Cavernous (2),
Circular,	Transverse,
Superior petrosal,	Inferior petrosal.

How is the internal jugular^r (Fig. 76) formed?

By the junction of the lateral and inferior petrosal sinuses just outside jugular foramen; at base of neck the internal jugular unites with subclavian vein to form the innominate vein—at, or

above the junction is a pair of valves; into the jugular empty the facial, lingual, pharyngeal, superior and middle thyroid, and sometimes occipital veins.

Where do the following veins empty?

The *external jugular*^s; into subclavian vein external to internal jugular; the *posterior external jugular*, into internal jugular; the *anterior jugular*, into termination of external jugular or the subclavian vein; the *vertebral*, descends through vertebral foramina in transverse processes of cervical vertebræ to empty into back of innominate vein, valves guarding the orifice.

Describe the veins of the upper extremity.

They consist of superficial and deep, the latter being the *venæ comites* of the arteries; commencing as *digitals* these empty into the *interossei*, these into *palmar* until the *deep radial* and *ulnar* are formed, which, uniting, form the so-called *brachial vein*, really consisting of two *venæ comites* with transverse anastomoses. The superficial veins running in the superficial fascia are called

Radial	}	<i>Median cephalic</i>	}	<i>Cephalic</i>	}	<i>Axillary.</i>
Median						
<i>Anterior and Posterior ulnar</i>	}	<i>Basilic</i>	}	<i>Brachial</i>		

Describe the axillary vein.

It is a continuation of brachial and basilic, receiving veins of corresponding names with the arteries of the axilla, and is continued beneath the clavicle under the name of the *subclavian vein*⁹; it has valves opposite lower border of subscapular muscle, also at mouths of cephalic and subscapular veins.

Describe the subclavian vein⁹.

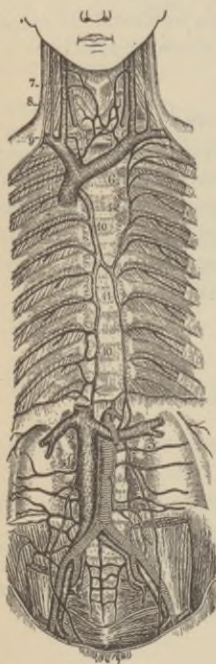It extends from lower border of first rib to back of sternoclavicular joint, there uniting with internal jugular to form the vena innominata—the subclavian vein lies in *front* of the artery with the anterior scalene muscle interposed at its second part; its branches are, the external and anterior jugular and branch of cephalic; on right side the *right lymphatic duct* empties at the

junction of the axillary and internal jugular veins, and at the same point on the left side the *thoracic duct*.

How are the *venæ innominatæ*^{5, 6} formed?

Each by the subclavian and internal jugular, which unite just below the first costal cartilage to form the superior vena cava⁴; the *right innominate* is about one and a half inches long, receiving blood by right vertebral, internal mammary, inferior thyroid, and superior intercostal veins; the *left vein* is larger and about three inches long; the left vertebral, internal mammary, inferior thyroid, superior intercostal, and occasionally some thymic and pericardiac veins empty into it.

Fig. 76.



Describe the superior vena cava⁴.

It measures from two and a half to three inches and is formed by the union of the two innominate veins^{5, 6}, is half covered by the pericardium and enters upper part of right auricle; it returns the blood of the upper half of body and receives the vena azygos major and small mediastinal and pericardiac veins.

Describe the azygos veins.

They connect the superior and inferior *venæ cavæ*, taking the place of those vessels in that part of the chest occupied by the heart.

The *right azygos*¹⁰ commences opposite first and second lumbar vertebræ by a branch from right lumbar or renal vein, or from inferior vena cava, enters thorax by aortic opening, arches over root of right lung to empty into superior cava, receiving in its course the nine or ten right lower intercostal veins, the vena azygos minor, œsophageal, medias-

tinal, vertebral, and right bronchial veins, also at times it is connected with right superior intercostal vein.

The *left lower azygos*¹¹ (vena azygos minor) commences by a branch from left lumbar or renal vein, enters thorax through left crus of diaphragm, passes across from the left side of vertebral column at sixth or seventh dorsal vertebra to enter the right azygos vein, receiving veins from four or five lower intercostal spaces; also mediastinal and œsophageal branches.

The *left upper azygos*¹² is formed by veins, usually two to three, from the intercostal spaces between left superior intercostal and highest branch of left lower azygos, and empties into right azygos or left lower azygos; it is sometimes absent, its place being taken by left superior intercostal.

Name the other principal veins of base of the neck and of the thorax.

Internal mammary,
Inferior thyroid,
Intercostals,

Mediastinal,
Pericardiac,
Bronchial.

Briefly describe the spinal veins.

They are the *dorsi-spinal* on the exterior of the spinal column, forming plexuses around vertebral spines, laminæ, and processes, emptying into intercostal, lumbar, and sacral veins respectively.

The *meningo-rachidian*, lying between vertebræ and theca spinalis forming plexuses, one running along the posterior surfaces of vertebral bodies forming the *anterior longitudinal veins* receiving the *venæ basis vertebrarum*, the other on the inner surface of the laminæ, the *posterior longitudinal veins*, both extending the whole length of the spinal canal; the posterior emptying into dorsi-spinal, the anterior into vertebral, intercostal, and sacral veins, respectively.

The *venæ basis vertebrarum*, in vertebral bodies, empty into anterior longitudinal.

The *medulli-spinal*, those of the cord itself, forming a minute plexus over cord between the pia mater and arachnoid, near base of skull converging to form two or three trunks terminating in the inferior cerebellar veins or petrosal sinuses.

Describe the chief veins of the lower extremity.

They are deep and superficial, the former commence as venæ comites of *digitals*, which form the *interossei*, these the *anterior* and *posterior tibial* and *peroneal* accompanying same named arteries, which uniting, form the *popliteal*, in the thigh to be called the *femoral*, being joined by *profunda femoris* and *internal saphenous veins*, which again changes its name to *external iliac* above Poupart's ligament; into external iliac empty the epigastric and circumflex iliac veins.

The superficial veins are the

Internal or long saphenous, commencing on inner side of dorsum of foot, running up on inside of leg and thigh to enter femoral vein after passing through the saphenous opening of fascia lata; its branches are

<i>Cutaneous,</i>	<i>Superficial circumflex iliac,</i>
<i>Superficial epigastric,</i>	<i>Communicating,</i>
	<i>Pudic.</i>

External or short saphenous, commences at outer side of dorsum of foot, passes behind the external malleolus, up the middle of leg posteriorly to empty into popliteal vein between heads of gastrocnemius.

Describe the internal iliac vein.

It is formed by the venæ comites of all branches of external iliac artery except the umbilical, and unites opposite sacro-iliac articulation with external iliac vein to form the common iliac vein; it receives the following veins,

<i>Gluteal,</i>	<i>Internal pudic,</i>	<i>Hemorrhoidal,</i>	<i>Uterine and vaginal,</i>
<i>Sciatic,</i>	<i>Obturator,</i>	<i>Vesico-prostatic</i>	<i>Plexuses, in female,</i>
		<i>Plexuses, in male,</i>	
		<i>Dorsal vein of penis.</i>	

Describe the common iliac veins.

Formed by the junction of the external and internal iliac veins, and receiving the ilio-lumbar, occasionally the lateral sacral, and the *left iliac* the middle sacral vein, they unite at an angle upon the intervertebral substance between the fourth and fifth lumbar vertebræ to form the inferior vena cava.

Describe the inferior vena cava¹.

It runs upward from junction of the two common iliacs, along the right side of the aorta, pierces the central tendon of diaphragm, and terminates at back of right auricle, being partially covered by serous layer of the pericardium; it returns the blood from all parts below the diaphragm, and receives the following branches,

<i>Lumbar,</i>	<i>Suprarenal,</i>	sometimes <i>Middle sacral,</i>
<i>Right spermatic,</i>	<i>Phrenic,</i>	
<i>Renal^{2, 3},</i>	<i>Hepatic.</i>	

Describe the portal system of veins.

Formed by the union behind the head of the pancreas of the *superior and inferior mesenteric, splenic, and gastric veins*, collecting the blood from the viscera of digestion, the resulting *portal vein* divides in the transverse fissure of the liver into a branch each for the right and left lobe, which ramify to form a *venous plexus* in the liver tissue; the hepatic artery sends branches within the liver to the portal vein, and external to the organ the vein receives the smaller gastric and the cystic vein; the portal blood is returned to the inferior vena cava by the *hepatic veins*.

What veins return the blood from the substance of the heart?

<i>Great cardiac vein,</i>	<i>Anterior cardiac veins,</i>
<i>Middle cardiac vein,</i>	<i>Right or small cardiac vein,</i>
<i>Posterior cardiac veins,</i>	<i>Venæ Thebesii.</i>

What is the coronary sinus?

A dilatation of about one inch of the great cardiac vein in posterior part of left auriculo-ventricular groove, covered by the muscular tissue of the left auricle and receiving the posterior cardiac veins, and an oblique vein from back of left auricle; its orifice is guarded by the coronary valve.

Describe the pulmonary veins.

Commencing in the lung capillaries they form a main vein for each lobule, which unite into two trunks for each lung, opening separately into the left auricle; at times there are three veins on the right side, or the two left terminate by a common opening.

The Lymphatics.

What are lymphatics ?

Delicate vessels with transparent walls formed of same three coats as arteries and found in all parts of the body probably, except the nails, cuticle, hair, and cartilage; they have numerous valves producing their characteristic beaded appearance; they are supplied with nutrient arteries but not with nerves.

What are the lacteals ?

The lymphatics of the small intestine, conveying *chyle during digestion*, lymph at other times.

Describe the lymphatic glands.

They are small solid, round, or ovoid glandular bodies, situated in the course of the absorbent vessels which previous to entering a gland break up into several *afferent vessels*, form a plexus within, and emerge by several *efferent vessels* which soon unite to form a single trunk; each gland is surrounded by a fibrous capsule which sends partitions inward, forming alveoli in which lies the gland-pulp or *lymphoid tissue* consisting of a rete whose meshes are filled with lymph-cells. The glands are chiefly found in the mesentery, along great vessels, in the mediastinum, axilla, neck, at front of elbow, groin, and popliteal space, being usually named from their locality, as axillary, etc.

Describe the thoracic duct.

This conveys the bulk of the lymph and chyle into the blood, being the common lymph-trunk, except for right upper extremity, right side of head, neck, and thorax, right lung, same side of heart, and convexity of liver. It commences by the triangular *receptaculum chyli*, on the front of body of second lumbar vertebra, enters the thorax by aortic opening, and opposite the upper border of seventh cervical vertebra it curves downward to empty at the junction of the left internal jugular and subclavian veins.

Describe the right lymphatic duct.

It is about one inch long, receiving lymph from those parts *excepted* in the account of the thoracic duct, and empties at the junc-

tion of the right internal jugular and subclavian veins; both ducts have double semilunar valves at their orifices, preventing regurgitation of blood.

Nervous System.

What are the two divisions of the nervous system?

The *cerebro-spinal* or that presiding over animal life, and the *sympathetic*, that regulating organic life.

Describe the structure of the nervous tissue.

It is composed chiefly of two structures, the *gray or vesicular* originating impulses and receiving impressions; and *white or fibrous*, conducting impressions; in the sympathetic system is found a third structure, *gelatinous nerve-tissue*; seventy-five per cent. of nerve-tissues is composed of water, the remainder being albumen, phosphorized-fat, and salts.

Describe the microscopic structure of the white nerve-tissue.

It is formed of tubular fibres each consisting of a central *axis-cylinder*, surrounded by the *white substance of Schwann*, the whole enclosed by the *tubular membrane or primitive sheath*. A bundle of these fibres invested by a fibro-areolar membrane, the *perineurium* (neurilemma), constitutes a *nerve*, receiving a special blood-supply by the *vasa nervorum*; the *gelatinous* variety consists of finely granular fibrillæ enclosed in a sheath—by some these are not considered to be nerves.

Describe the gray or vesicular nerve-tissue.

This consists of large granular cells containing nuclei and nucleoli, ovoid, or with one or many processes (*unipolar, multipolar*), some of which become continuous with an axis-cylinder.

How do nerves terminate?

Peripherally sensory nerves end in minute plexuses, end-bulbs, tactile corpuscles, and Pacinian corpuscles; in the special organs they end in cells and in other not well ascertained ways; motor nerves end peripherally in plexuses or by "*motorial end plates*." The central terminations are not well understood.

What organs compose the cerebro-spinal system?

The brain, spinal ganglia, and the cranial and spinal nerves.

Name the membranes of the brain.

The dura mater, the arachnoid, and pia mater.

Describe the cerebral dura mater with its processes.

It is a dense fibrous membrane lining the interior of skull, constituting the internal periosteum, is continuous with that of spinal cord, and is prolonged to outer surface of the skull through the various foramina; by separation of its layers the cerebral sinuses are formed; its smooth under surface is covered with endothelial cells; its processes are the,

Falx cerebri, a sickle-shaped layer occupying the longitudinal fissure of the brain; along the upper and lower border respectively run the superior and inferior longitudinal sinuses.

Tentorium cerebelli, covering the upper surface of the cerebellum; it supports the weight of the posterior lobes of the cerebrum; it is attached to the horizontal arms of the occipital cross, enclosing the lateral sinuses, to the upper margin of the petrous bone, including the superior petrosal sinuses, whence it extends to anterior and posterior clinoid processes; to the mid-line, above, the falx cerebri is attached antero-posteriorly, and below medianly the base of the

Falx cerebelli, a small triangular process passing between cerebellar lobes behind.

What are the Pacchionian bodies?

Numerous aggregations of small whitish granulations of unknown function formed upon outer surface of dura mater near superior longitudinal sinus, lying in depressions in the bone, in the superior longitudinal sinus, on the inner surface of the dura mater, and on the pia mater; unknown in infancy, rare before third year; they are usually found after tenth year.

Describe the arachnoid.

It is a delicate membrane lying between the pia mater and dura mater, being separated from the latter by the *subdural space*; it bridges over the convolutions, forming *part of subarachnoidean space*, and at the base, by being stretched between the middle lobes,

the *anterior subarachnoidean space* is left; while between the cerebellar hemispheres and medulla oblongata lies the *posterior subarachnoidean space*, the two communicating across the crura cerebelli, and by an opening in its lower boundary with the fourth ventricle; these spaces contain the cerebro-spinal fluid, forming an elastic water-cushion for the encephalon: it consists of interwoven bundles of fibrous and yellow elastic tissue covered with a layer of endothelium.

What is the pia mater?

It consists of a minute plexus of bloodvessels derived from the internal carotid and vertebral arteries, held together by fine areolar tissue; it dips between the convolutions, forms the velum interpositum and choroid plexuses of the fourth ventricle, and contains nerves and lymphatics.

What are the divisions of the brain called?

The cerebrum, cerebellum, pons Varolii, and medulla oblongata.

What is the weight of the brain?

Forty-nine and a half ounces, on the average, in males, and forty-four ounces in females; heaviest male brain recorded sixty-eight and three-eighths ounces, lightest thirty-four ounces; female brain, heaviest fifty-six ounces, lightest thirty-one ounces; idiots' brains seldom weigh more than twenty-three ounces.

Name the fissures and lobes of the cerebrum.

Each half, or *hemisphere*, has its external surface subdivided into five lobes by the

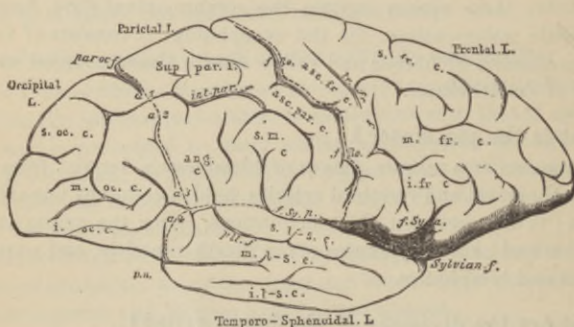
Fissure of Sylvius, *f. Sy. p.*, beginning at anterior perforated space, it passes to external surface of hemisphere and subdivides, one arm (*f. Sy. a.*) ascends toward longitudinal fissure, one passes nearly horizontally backward.

The *fissure of Rolando*, *f. Ro.*, commences at or near middle of the longitudinal fissure, running downward and forward to a little above the horizontal branch of the Sylvian fissure.

Parieto-occipital fissure, *par. oc. f.*, commences about midway between posterior extremity of brain and fissure of Rolando, running downward and forward for a variable distance.

The *frontal lobe* lies in front of the fissure of Rolando, and above the horizontal part of the Sylvian fissure; its under surface is called the *orbital lobe*.

FIG. 77.



Convolutions of outer surface of brain.

The *parietal lobe* is bounded in front by fissure of Rolando, behind by parieto-occipital fissure, and below by horizontal limb of Sylvian fissure.

The *occipital lobe* lies behind parieto-occipital fissure.

The *temporo-sphenoidal lobe* occupies middle cerebral fossa of skull, and is limited above and in front by Sylvian fissure.

The *central lobe*, or island of Reil, lies in the fissure of Sylvius at the base of brain.

The inner or median surface of each hemisphere presents five fissures :

The *calloso-marginal fissure*, *c. m. f.* (Fig. 78), separating the marginal convolution from the gyrus fornicatus, *g. f.*

The *parieto-occipital fissure*, *par. oc. f.*, a continuation of that of same name on outer surface of hemisphere.

The *calcarine fissure*, *calc. f.*, runs from back of hemisphere horizontally forward to posterior inferior extremity of gyrus fornicatus, *g. f.*; it is joined by the parieto-occipital fissure.

The *collateral fissure*, *coll. f.*, runs below and nearly parallel to preceding, separated by the uncinatè gyrus.

The *dentate fissure*, *d. f.*, commences below posterior extremity of corpus callosum, running forward to end at recurved part of uncinate gyrus.

The *transverse fissure*, between the middle lobe and crus cerebri, admitting pia mater into the lateral ventricles.

Mention the principal convolutions of the brain.

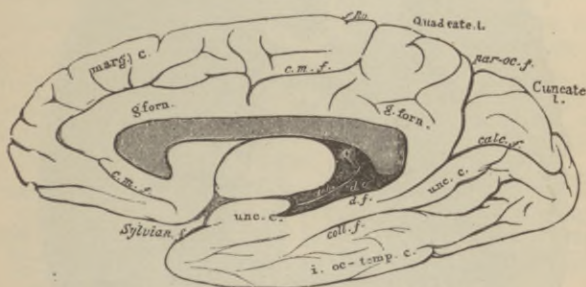
The convolutions, or *gyri*, are elevated ridges covered with gray matter, separated by deep furrows, or *sulci*, thus securing a great extent of gray matter; while not uniform in all brains, nor symmetrical, certain principal convolutions are constant, such as

The *gyrus fornicatus*, *g. forn.*, that lying over corpus callosum.

The *marginal*, *marg. c.*, forming anterior superior margin of the great longitudinal fissure.

The *ascending frontal*, *asc. fr. c.* (Fig. 77), forming anterior boundary of fissure of Rolando.

FIG. 78.



Convolutions of outer surface of brain.

The *ascending parietal*, *asc. par. c.*, the posterior boundary of same fissure.

Angular gyrus, *ang. c.*, lying between back of horizontal limb of Sylvian fissure, and a short fissure running upward from it.

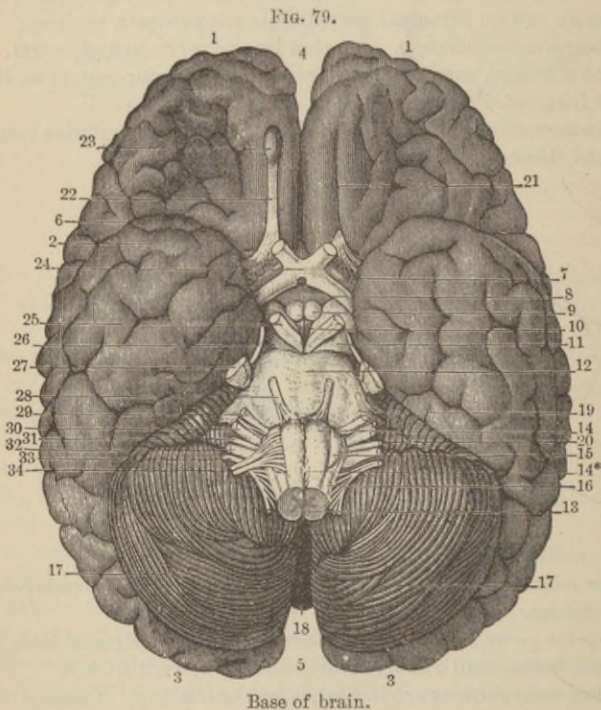
Other convolutions are indicated by contractions of names on the diagrams, so that with the preceding explanations of points of reference no further details are requisite.

What is the quadrate lobe (Fig. 78), and what is the cuneus (Fig. 78)?

The former is the marginal convolution between the callosomarginal fissure in front and the parieto-occipital behind; the latter lies between the parieto-occipital and calcarine fissures.

Mention the various objects seen on the under surface of cerebrum, naming them from before backward.

*Longitudinal fissure*⁴ (Fig. 79), antero-posterior.



Corpus callosum, the transverse commissure, connecting cerebral hemispheres.

Lamina cinerea, a thin layer of gray substance, extending from end of corpus callosum back to tuber cinereum above optic tracts.

*Fissure of Sylvius*⁶, separating by its horizontal limb the frontal and parietal lobes from temporo-sphenoidal; (*old nomenclature*) separates anterior and middle lobes chiefly by the ascending or pre-central limb.

*Anterior perforated spaces*⁷, between roots of olfactory nerve on each side for passage of vessels into corpus striatum.

*Optic commissure*²⁴, union of optic tracts.

Tuber cinereum, an eminence of gray matter, part of floor of third ventricle.

*Infundibulum*⁸, a hollow conical process of gray matter projecting from middle of under surface of tuber cinereum, communicating with third ventricle.

Pituitary body, a vascular, two-lobed body projecting from apex of infundibulum into sella turcica of sphenoid.

*Corpora albicantia*⁹, the two small rounded, infolded terminations of the anterior crura of fornix.

*Posterior perforated space*¹⁰, between corpora albicantia in front, pons Varolii behind, and cerebral crura on either side, forms part of floor of third ventricle, and gives passage for vessels to optic thalami.

*Crura cerebri*¹¹ (*peduncles of cerebrum*) connect the cerebrum with cerebellum, medulla oblongata, and spinal cord.

*Pons Varolii*¹² (see page 195).

Name the five great ganglia of the brain, other than the gray matter of the cerebral and cerebellar hemispheres and medulla oblongata.

Olfactory bulbs ²³ ,	Optic thalami,	Pons Varolii ¹² ,
Corpora striata,	Tubercula quadrigemina.	

Describe these ganglia.

*Olfactory bulbs*²³, the ganglia of the sense of smell, lie in olfactory grooves of cribriform plate of the ethmoid, and arise by two white roots, one crossing Sylvian fissure from a nucleus of gray matter in middle lobe, the other from inner back part of frontal (*orbital*) lobe, and a gray root from under surface of same lobe.

Corpora striata, chief part of motor tract, lying in lateral ventricles, the intra-ventricular gray portion called *caudate nucleus*, the extra-ventricular, the *lenticular nucleus*, the *internal capsule* dividing the two.

Optic thalami, they are white externally, the ganglia of general sensation, forming the lateral boundaries of the third ventricle, each presenting an anterior tubercle in lateral ventricle, and posteriorly two small *internal* and *external geniculate bodies*.

Corpora quadrigemina (optic lobes) are four rounded eminences situated behind third ventricle and posterior commissure; the anterior pair are the *nates*, the posterior pair the *testes*; they are the centre of vision.

The *pons Varolii*, containing much gray matter and one special mass called the *superior olivary* body, might be considered a fifth ganglion.

What are the commissures?

Connecting bands of white or gray matter.

Enumerate them.

Those pursuing an antero-posterior course, are

<i>Olfactory tracts,</i>	<i>Fornix,</i>
<i>Tænia semicircularis,</i>	<i>Gyrus fornicatus,</i>
<i>Crura cerebri,</i>	<i>Fasciculus unciformis,</i>
<i>Peduncles of pineal gland,</i>	<i>Processus e cerebello ad testes.</i>
<i>Striæ longitudinales.</i>	

Those passing transversely, are

<i>Anterior,</i>	<i>Pons Varolii,</i>
<i>Middle,</i>	<i>Fornix (also a longitudinal</i>
<i>Posterior,</i>	<i>commissure),</i>
<i>Corpus callosum,</i>	<i>Posterior medullary velum,</i>
<i>Optic chiasm,</i>	<i>Valve of Vieussens.</i>

What are the ventricles of the brain?

Five serous cavities in the brain, four of which intercommunicate; they are *two lateral*, a *third*, a *fourth*, and a *fifth*.

Describe the lateral ventricles.

The *corpus callosum* roofs them in; each has an *anterior cornu*, curving outward and forward into the anterior lobe, a *middle cornu*

descending into the middle lobe downward and backward, then turning downward and forward, containing the curved *hippocampus major*, and a *posterior cornu* curving downward and inward into the posterior lobe, containing the hippocampus minor; the floor from before backward is formed by the *corpus striatum*, *tænia semicircularis*, *optic thalamus*, *choroid plexus*, *corpus fimbriatum*, and *fornix*; the septum lucidum forms the inner wall.

Describe the following parts :

The *corpus callosum*; it is a thick arched layer of transverse fibres at the bottom of the longitudinal fissure, anteriorly curving upon itself, giving off two peduncles to the entrance of the Sylvian fissure, posteriorly it becomes continuous with the fornix; a median linear depression on its upper surface is called the *raphé*, parallel to which on each side run two or more elevated longitudinal bands, the *stricæ longitudinales* or *nerves of Lancisi*.

The *tænia semicircularis*; lies in a depression between corpus striatum and optic thalamus and is a commissure between these bodies.

Choroid plexus; the vascular margin of the velum interpositum, communicating with that of opposite side just behind anterior pillars of fornix, through the oval *foramen of Monro*; posteriorly, it descends into the middle horn, becoming there continuous with pia mater through transverse fissure.

The *corpus fimbriatum* (*tænia hippocampi*); the lateral edge of the posterior pillar of the fornix, forming a white band just behind choroid plexus.

The *fornix*; continuous with corpus callosum behind, consisting of a triangular body with apex forward, two *anterior crura*, curving downward to base of brain, there to form the *corpora albicantia* and terminate in the optic thalami, and two *posterior crura*, running down the middle cornua of the lateral ventricles, as the *hippocampi majores*; on the back under surface, between posterior crura, certain transverse longitudinal and oblique lines have been termed the *lyra*.

The *septum lucidum*; is a vertical septum, attached above to under surface of corpus callosum, below to anterior part of fornix and prolonged portion of corpus callosum; it is triangular in form,

and consists of two lamina of white nerve matter lined internally with gray matter, the space between forming the *fifth ventricle*, not communicating with other ventricles.

What is the pes hippocampi ?

The rounded elevations of lower extremity of hippocampus major.

What is the pes accessorius ?

A white projection at the junction of the two hippocampi.

What is the fascia dentata ?

The gray substance of the dentate convolution, seen by raising the edge of corpus fimbriatum.

What is the internal capsule ?

A large tract of white matter belonging to pyramidal tract, consisting of two limbs, the *anterior* lying between anterior part of lenticular nucleus and caudate nucleus, the *posterior* between posterior part of lenticular nucleus and thalamus, which, by their junction, form a projection inward, the *knee* or *genus*.

What is the external capsule ?

A small tract of white matter lying between the outer part of the lenticular nucleus and cerebral cortex.

Describe the third ventricle.

Narrow and oblong, the lateral walls being the optic thalami and peduncles of pineal gland; above the under surface of the velum interpositum roofs it in, containing the choroid plexuses of this ventricle; the lamina cinerea, tuber cinereum, infundibulum, corpora albicantia, and posterior perforated space form its floor; it is limited in front by the anterior crura of the fornix and part of anterior commissure; behind, by the posterior commissure, beneath which opens the *iter e tertio ad quartum ventriculum*; while in front by the foramen of Monro it communicates with the lateral ventricles; the cavity is crossed by an anterior and posterior *white commissure* and a middle *gray one*.

Describe the fourth ventricle.

It is the space between posterior surface of the medulla oblongata and pons in front, and the cerebellum behind. Its *roof* is the valve of Vieussens and that portion of the cerebellum called the *nodulus, uvula, and amygdalæ*; the *lateral boundaries* on each side are the *processus e cerebello ad testes*, and posterior pyramids and restiform bodies of the medulla oblongata; the *floor* consists of the posterior surface of the medulla oblongata and the pons, upon the former of which will be seen the posterior median fissure obliterated above, terminating below in front of *calamus scriptorius* at the orifice of a short blind canal, the remains of the fœtal central canal of cord; on each side of median fissure are two convex longitudinal eminences, the *fasciculi teretes*; external to these, opposite *crus cerebri* on each side, is the *locus cœruleus*—a ganglionic mass; a thin streak of this embedded gray matter continued to top of ventricle is called the *tænia violaceæ*, and certain white lines, the *lineæ transversæ*: this cavity communicates with that of the third by *iter e tertio*, etc., and with the subarachnoid space, through an opening in the pia mater extending between the medulla oblongata and cerebellum.

The *fifth ventricle* has been described with *septum lucidum*, p. 194.

Describe the pons Varolii.

It is the bond of union between the different segments of the encephalon: bridging the medulla oblongata is a broad transverse band forming the *middle peduncles* or *crura cerebelli*: longitudinal fibres pass up from the medulla oblongata to form the *two crura cerebri*, which become connected with the *corpora striata* and *optic thalami*, through which they pass to reach the gray matter of the hemispheres forming the *corona radiata*: the *locus niger*, a mass of gray matter, is found in the substance of each *crus*; the third nerve emerges from inner side of each *crus*, the fourth nerve around the outer side from above, while the optic tract is adherent by its upper border.

Describe the corpora quadrigemina.

These are four rounded projections placed just behind third ventricle beneath posterior border of *corpus callosum*: they are

the centre of vision. Two white bands on each side connect them with optic thalamus and optic tracts, those passing from the anterior pair, or *nates*, to thalamus are the *brachia anteriora*, those running from the posterior pair, the *testes*, to the thalamus are the *brachia posteriora*; passing from the testes to the cerebellum on each side is the *processus e cerebello ad testes* or *inferior cerebellar peduncle*.

What is the valve of Vieussens ?

A thin lamina of nerve tissue, stretching from the vermiform process of cerebellum from one *processus e cerebello ad testes* to the other, forming the roof of the *iter e tertio*, etc.: a little ridge descending upon the upper part from the *corpora quadrigemina* is the *frænulum*, and on either side are the transverse fibres connecting the fourth nerves.

What is the pineal gland ?

A reddish conical body lying beneath the *nates*, connected by its base by two *peduncles* to the anterior crura of fornix: the gland has a small cavity—said by some to open into that of the third ventricle—containing a viscid fluid and a sandy substance, the *acervulus cerebri*, composed of calcium carbonate and phosphate, magnesium and ammonium phosphate, with some animal matter.

Describe the medulla oblongata.

It is the upper enlarged part of spinal cord, extending from upper border of atlas to lower border of pons Varolii; its posterior surface forms the floor of the fourth ventricle, its anterior rests on the basilar groove of the occiput. It contains the vaso-motor, cardiac, and respiratory centres, also those of deglutition, mastication, etc. Divided into lateral halves by the *anterior (d, Fig. 80)* and,

Posterior median fissures, it presents on each side of anterior fissure,

The *anterior pyramid (p, a, Fig. 80)* formed by antero-lateral columns of the cord, these latter fibres *decussating* above *d* (crossing from one pyramid to that of the other) at the lower part; behind the pyramid is the *olivary body* containing in its interior a capsule of gray matter, the *corpus dentatum*; behind the olivary body is,

The *lateral tract* continuous with lateral tract of the cord; back of this is the *restiform body*, continuous with posterior columns of cord below, above passing into corresponding hemisphere of cerebellum forming ²ts *inferior peduncle*; running along the posterior median fissure on either side are the

Posterior pyramids continuous with posterior median columns of cord; diverging above, they form the lateral boundaries of the *calamus scriptorius*.

Describe the cerebellum.

It is that portion of the encephalon contained in the inferior occipital fossæ composed of *laminæ* covered with gray matter; on the upper surface the two *hemispheres* are seen connected by a median elevated lobe, the *superior vermiform process*, while they are separated in front and behind by notches respectively called the *incisuræ cerebelli anterior and posterior*; the superior vermiform process consists of a *lobulus centralis* in incisura anterior, the *monticulus cerebelli* the central projecting portion, and the *commissura simplex*, near the incisura posterior.

Describe the under surface of the cerebellum.

It is divided by a central longitudinal depression, the *valley*, into two hemispheres. Projecting from the bottom of the valley is the *inferior vermiform process*, consisting of the *commissura brevis* in the posterior notch, in front of the conical *pyramid*, more anteriorly, the *uvula*, lying between two rounded lobes the *amygdalæ* or *tonsils*, and which projects into fourth ventricle, and finally in front of uvula the *nodule*; attached to each side of nodule and also to flocculus, is a thin white layer which together form the *posterior medullary velum*.

Name the lobes of the cerebellum.

Below, from before backward, they are, on each side,

The *flocculus*, or *pneumogastric lobule*, a prominent tuft below and behind middle peduncle.

The *amygdala*, just described.

The *digastric*, on outside of tonsils, partially connected with pyramid.

The *slender*, behind former, connected with commissura brevis and back of pyramid.

The *inferior posterior*, joining the commissura brevis in the valley.

Only one *fissure*—the *great horizontal*—pertains to the cerebellum, commencing in front at pons, and passing horizontally round free margin of each hemisphere to median line; from this numerous secondary fissures proceed, marking out lobes, as two on the upper cerebellar surface on each side, viz., the *anterior*, or *square globe*, extending back to posterior edge of vermiform process, and the *posterior*, or *semilunar*, passing from preceding to great horizontal fissure.

How many peduncles has the cerebellum ?

Three; the transverse fibres of pons Varolii, or *middle peduncle*; on each side the restiform bodies of medulla oblongata, or *inferior peduncles*; and the processus e cerebello ad testis, forming the *superior peduncles*.

Describe the arrangement of the gray matter of the cerebellum.

A vertical section reveals a central stem of white matter containing a capsule of gray matter, the *corpus dentatum*. From the central white stem ten or twelve plates, or *laminæ*, spring, giving origin to smaller secondary and tertiary laminæ, covered externally by a layer of gray matter, so that the cut surface presents the foliated appearance giving origin to the name *arbor vitæ*.

The Spinal Cord.

What is the spinal cord ?

The elongated cylindrical part of the cerebro-spinal axis contained in the vertebral canal, measuring about seventeen inches in length, extending from upper border of atlas to lower border of body of first lumbar vertebra, presenting a *cervical enlargement* from third cervical to first or second dorsal vertebra, and a *lumbar enlargement* opposite last two or three dorsal vertebræ; it terminates by a slender filament of gray substance, the *filum terminale*. The

white matter is disposed externally, the gray internally in the form of two crescents joined by a transverse commissure, the anterior thicker extremities, forming the *anterior cornua*, or *horns*, the posterior the *posterior cornua*.

How many membranes has the cord ?

Three; the *dura mater*, continuous with that of brain, but separated from bony walls by loose areolar tissue, containing a plexus of veins; the *arachnoid*, continuous with cerebral arachnoid, also having a *subdural* and *subarachnoidean* space, the latter communicating with general ventricular cavity of brain by the *foramen of Magendie*, an aperture in pia mater of fourth ventricle—this space contains an abundant serous secretion, the *cerebro-spinal fluid*; and the *pia mater*, sending processes down into anterior and posterior median fissures, having medianly in front a fibrous band, the *linea splendens*, and on each side another, the *ligamentum denticulatum*, whose outer border presents about twenty serrations, the apices of each attached to inner surface of *dura mater*, serving to support the cord.

Describe the fissures.

They are the *anterior and posterior median*, dividing cord into two lateral halves, joined medianly by a white *commissure*; on each side of anterior fissure is a series of foramina for the exit of anterior roots of nerves; this line of openings is called the *antero-lateral fissure*; two *postero-lateral fissures* run parallel to posterior median fissure, giving exit to posterior roots; finally, a delicate groove on each side between the postero-lateral and posterior median fissures exists, marking off the *posterior pyramids*.

Name the columns of the cord marked off by these fissures.

On each side the *anterior*, continuous with the anterior pyramid of medulla oblongata.

The *lateral*, continuous with lateral tract of medulla oblongata.

The *posterior*, continuous with restiform body of medulla oblongata.

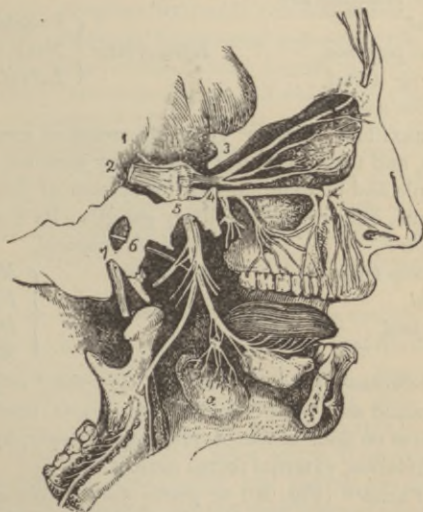
The *posterior median*, continuous with posterior pyramid of medulla oblongata.

fibres; a third, anterior, connecting the two retinae—*inter-retinal fibres*; a fourth and fifth, lateral, *cerebro-retinal*, connecting the hemisphere of one side with retina of eye of same side; and a sixth, posterior—*inter-cerebral*—connecting one optic tract with the other; *distribution*, retina.

Thirdⁱⁱⁱ, Motor oculi; *superficial origin*, inner surface of crus cerebri; *deep origin*, a nucleus for each in floor of iter e tertio ad quartum ventriculum; *escapes*, by sphenoidal fissure; *distribution*, to all eye muscles including iris, except external rectus and superior oblique.

Fourth^{iv} (Fig. 80), Patheticus, motor, *superficial origin*, outer side crus cerebri; *deep origin*, floor of aqueduct of Sylvius; *escapes* through sphenoidal fissure; *distribution* to superior oblique of eye.

FIG. 81.



Fifth^v (Fig. 80), Trigeminus or Trifacial, nerve of general sensation, motion, and taste; *superficial origin*, by a motor and a sensory root from side of pons Varolii; *deep origin*, sensory root from upper expanded posterior gray horns of medulla at junction with resti-

form body—the *Gasserian ganglion* formed on this root lies on apex of petrous portion of temporal bone; the motor root arises from a mass of gray cells to inner side of nucleus of sensory root; *escapes*, ophthalmic³ (Fig. 81) by sphenoidal fissure, superior maxillary⁴ (Fig. 81) by foramen rotundum, inferior maxillary⁵ (Fig. 81) by foramen ovale.

Ophthalmic division³ (Fig. 81), purely sensory, supplies eyeball, ciliary muscle, iris, lachrymal gland, nasal and ocular mucous membrane, skin and muscles of eyebrow, forehead and nose, and ciliary ganglion; its branches are

Frontal, *Lachrymal,* *Nasal.*

Superior maxillary division⁴ (Fig. 81), sensory, is distributed to temple, cheek, lower eyelid, nose, upper lip, and teeth, and, by Meckel's ganglion connected with this nerve, the palate and pharynx; its branches are

<i>Orbital,</i>	} <i>Infra-orbital</i> {	<i>Palpebral,</i>
<i>Spheno-palatine,</i>		<i>Nasal</i> (Fig. 81),
<i>Posterior dental,</i>		<i>Labial.</i>
<i>Anterior dental.</i>		

Inferior maxillary division⁵ (Fig. 81), nerve of common sensation, motion, and taste; supplies masticatory muscles, teeth, gums, skin of temple and of external ear, lower part of face and lower lip, the tongue, otic and submaxillary ganglia; its branches are

<i>Masseteric,</i>	} <i>Inferior dental</i> {	<i>Mylo-hyoid,</i>
<i>Two deep temporal,</i>		<i>Incisor,</i>
<i>Buccal,</i>		<i>Dental,</i>
<i>Pterygoid,</i>		<i>Mental.</i>

Sixth, Abducens^{vi} (Fig. 80), motor; *superficial origin*, between anterior pyramid and pons Varolii; *deep origin*, from nucleus of fasciculus teres on floor of fourth ventricle; *escapes*, by sphenoidal fissure; *distribution*, external rectus muscle.

Seventh, Facial^{vii} (Fig. 80) or *portio dura of the seventh nerve*, the motor nerve of the muscles of expression, of platysma, buccinator, two muscles of external ear, posterior belly of digastric, stylo-hyoid, stapedius, through chorda tympani, the lingualis, through otic ganglion, the tensor tympani, through Vidian, the levator palati and azygos uvulæ muscles; *superficial origin*, medulla

oblongata, from groove between olivary and restiform bodies; *deep origin*, from nucleus of fasciculus teres in floor of fourth ventricle and nucleus of motor root of fifth nerve; *escapes*, by internal auditory meatus to aquæductus Fallopii; and thence by stylo-mastoid foramen; *distribution*, to muscles already mentioned; its branches are

<i>Tympanic,</i>	Temporo-facial	{	<i>Temporal,</i>
<i>Chorda tympani,</i>			<i>Malar,</i>
<i>Posterior auricular,</i>			<i>Infra-orbital,</i>
<i>Digastric,</i>	Cervico-facial	{	<i>Buccal,</i>
<i>Stylo-hyoid,</i>			<i>Supra-maxillary,</i>
			<i>Infra-maxillary.</i>

The communications of the facial are

With auditory nerve; with Meckel's ganglion by large petrosal nerve; with otic ganglion by small petrosal nerve; with sympathetic on middle meningeal by external petrosal nerve; with pneumogastric, glosso-pharyngeal, carotid plexus, auricularis magnus, auriculo-temporal and with the three divisions of fifth nerve.

Eighth, Auditory^{viii b} (Fig. 80), or *portio mollis of the seventh nerve*, nerve of hearing; *superficial origin*, from medulla oblongata in groove between olivary and restiform bodies at lower border of pons; *deep origin*, superior vermiform process of cerebellum, gray substance of posterior pyramid and restiform body; *escapes*, by internal auditory meatus; *distribution*, to internal ear; its branches are,

Vestibular, to the vestibule, *Cochlear*, to the cochlea (see p. 320).

Ninth, Glosso-pharyngeal^{viii a} (Fig. 80) or first division of eighth nerve, nerve of general sensation and taste; *superficial origin*, medulla oblongata just behind olivary body; *deep origin*, gray nucleus at lower part of floor of fourth ventricle; *escapes*, at central part of jugular foramen, after which it presents two gangliform enlargements, the *jugular and petrous ganglia*; *distribution*, to muscles of pharynx, mucous membrane of pharynx, fauces, tonsil, and tongue, and the middle ear; its branches are

<i>Tympanic</i> (Jacobson's),	<i>Pharyngeal,</i>	<i>Tonsillar,</i>
<i>Carotid,</i>	<i>Muscular,</i>	<i>Lingual.</i>

Tenth, Pneumogastric^x (Fig. 80) or *par vagum of the eighth nerve*; both motor and sensory; *superficial origin*, from lateral tract of medulla oblongata behind olivary body and below the glosso-pharyngeal; *deep origin*, gray nucleus lower part of floor of fourth ventricle—the motor filaments probably come from spinal accessory; *escapes*, by jugular foramen presenting a gangliform enlargement, *ganglion of the root*, and lower another, *ganglion of the trunk*; *distribution*, to organs of voice and respiration, the pharynx, œsophagus, stomach, and heart; the branches are

<i>Auricular,</i>	<i>Anterior pulmonary,</i>
<i>Pharyngeal,</i>	<i>Posterior pulmonary,</i>
<i>Superior laryngeal,</i>	<i>Œsophageal,</i>
<i>Recurrent laryngeal,</i>	<i>Gastric,</i>
<i>Cervical cardiac,</i>	<i>Hepatic (to hepatic sympathetic</i>
<i>Thoracic cardiac,</i>	<i>plexus).</i>

Eleventh, Spinal accessory^{xi} (Fig. 80), or *third division of the eighth nerve*, a motor nerve; *superficial origin*, lateral tracts of medulla oblongata below roots of vagus, and from same part of spinal cord as low as sixth cervical vertebra; *deep origin*, gray matter below nucleus of vagus and anterior horn of gray matter of cord; it sends filaments to ganglion of root of vagus and pharyngeal and superior laryngeal branches of same nerve; *escapes*, by jugular foramen, the spinal portion first entering skull through foramen magnum; *distribution*, to sterno-cleido-mastoid and trapezius muscles, communicating with second, third, and fourth cervical nerves.

Twelfth, Hypoglossal^{xii} (Fig. 80), or ninth nerve, motor nerve of tongue; *superficial origin*, groove between pyramidal and olivary bodies by numerous filaments; *deep origin*, special nucleus at lowest point of fourth ventricle; *escapes*, by anterior condyloid foramen; *distribution*, to thyro-hyoid, genio-hyoid, stylo-glossus, hyo-glossus, genio-hyo-glossus, and by descendens noni to sterno-hyoid, sterno-thyroid, and omo-hyoid muscles; it communicates with the pneumogastric, gustatory of fifth, sympathetic, and first and second cervical nerves; its branches are

Descendens noni, Muscular, Thyro-hyoid, Meningeal.

The Spinal Nerves.

How many pairs of spinal nerves are there ?

Eight cervical, twelve dorsal, five lumbar, five sacral, and one coccygeal—thirty-one in all.

Describe their origin.

Each nerve arises by an anterior *motor* root, emerging from the antero-lateral fissure, and a posterior *sensory*, having a ganglion on it, springing from postero-lateral fissure; these unite to pass out through the intervertebral foramina—except first cervical, which emerges between the atlas and occiput—after which they break up into an *anterior* and *posterior division*, the latter, the smaller, supplying the spine, dorsal muscles, and integument, while the anterior larger divisions form plexuses whence the remainder of the trunk and limbs receive their nerve-supply.

Describe the cervical plexus with its branches.

It is formed by the anterior divisions of the four upper cervical nerves lying upon the levator anguli scapulæ and scalenus medius muscles; its branches are,

<i>Superficialis colli,</i>	<i>Communicating,</i>
<i>Auricularis magnus,</i>	<i>Muscular,</i>
<i>Occipitalis minor,</i>	<i>Communicans noni,</i>
<i>Sternal,</i>	<i>Phrenic.</i>
<i>Clavicular,</i>	
<i>Acromial,</i>	

Describe the phrenic nerve (internal respiratory nerve of Bell).

It *arises* from third and fourth nerves with a branch from fifth, runs obliquely over scalenus anticus muscle, passes across subclavian artery, enters chest across root of internal mammary artery, to be *distributed* to pericardium, pleura, and under surface of diaphragm and phrenic plexus; it is joined by filaments from sympathetic, fifth and sixth cervical, the nerve to subclavius muscle, and one from union of descendens noni with the spinal nerves.

Describe the brachial plexus with its branches.

The anterior divisions of the fifth and sixth, with a branch of the seventh cervical nerves form the *outer cord*, the eighth cervical and first dorsal form the *inner cord*, a branch from the latter and one from the united fifth and sixth join the seventh nerve to form the *posterior cord*; this is the usual, but not *invariable* arrangement; its branches are,

Communicating, above clavicle to phrenic.

Muscular, to longus colli, scaleni, rhomboidei, and subclavius muscles.

Posterior or long thoracic (external respiratory nerve of Bell), from fifth, sixth, and seventh nerves, to serratus magnus muscle.

Suprascapular, from outer cord; to supra- and infra-spinatus muscles and shoulder-joint.

External anterior and internal anterior thoracic, the former from outer cord, the latter from inner cord; both to pectoral muscles.

The *three scapular*, the upper from communicating branch from outer to posterior cord, the other two from posterior cord; to subscapular, teres major, and latissimus dorsi muscles.

Circumflex, from posterior cord with musculo-spiral; to deltoid and teres minor muscles, the shoulder-joint, and skin of lower deltoid region.

Musculo-cutaneous (external cutaneous), from outer cord and pierces the coraco-brachial muscle; to coraco-brachial, biceps, brachialis anticus muscles, elbow-joint, and skin of outer half of front of forearm.

Internal cutaneous, from inner cord with ulnar and inner head of median; to skin over biceps and that of inner half of forearm in front and behind.

Lesser internal cutaneous (nerve of Wrisberg), from inner cord alone, or a branch from this joined with intercosto-humeral (the lateral cutaneous branch of second intercostal nerve, piercing external intercostal muscle to supply skin of upper half of inside of arm), or, again, the intercosto-humeral may entirely replace it; to skin of inner side of arm.

Median, from outer and inner cords by two roots which embrace the axillary artery uniting in front or to its outer side, first lying external to brachial artery, then crossing to its inner side, passing between heads of pronator radii teres muscle to run between deep

and superficial flexor of fingers to within two inches of wrist, when it becomes superficial; its branches are,

Muscular, to all anterior superficial forearm muscles except flexor carpi ulnaris.

Anterior interosseous, to deep forearm muscles except inner half of flexor profundus digitorum.

Palmar cutaneous, piercing fascia above wrist; to skin of palm to radial side.

Muscular, to abductor, opponens, and outer head of flexor brevis pollicis.

Five digitals, supplying both sides of thumb, index, middle, and radial side of ring fingers.

Ulnar, from inner cord runs behind inner condyle, thence passing into forearm between heads of flexor carpi ulnaris to run some distance from ulnar artery at upper third, but close to it for rest of its extent; it partially supplies elbow and wrist-joints, both sides of little and ulnar side of ring finger and skin of forearm and hand; its branches are,

Articular.

Muscular, to flexor carpi ulnaris, inner half of flexor profundus digitorum, the little finger muscles, the interossei and lumbricals, palmaris brevis, adductor, and inner head of flexor brevis pollicis.

Cutaneous,

Superficial palmar.

Dorsal cutaneous,

Deep palmar (muscular).

Musculo spiral, from posterior cord and branch of inner cord, running in same-named groove with superior profunda vessels to divide in front of condyle into the *radial* and *posterior interosseus*; its branches are,

Radial,

Muscular,

Cutaneous,

Posterior interosseous.

Radial, to skin of ball and outer side of thumb, and that on back of index, middle, and part of ring fingers;

Posterior interosseous, supplying wrist-joint and all muscles on back of forearm except anconeus, supinator longus, and extensor carpi radialis longior.

Muscular, to triceps, anconeus, supinator longus, extensor carpi radialis longior, and brachialis anticus.

Cutaneous, to skin of lower, outer, and back part of arm, forearm, and hand.

Dorsal Nerves.

Describe them.

Twelve in number on each side, the first escapes between first and second dorsal vertebræ, the last between the last dorsal and first lumbar; they divide into an *anterior* and *posterior* division, the latter supplying spine, extensor muscles of back and dorsal integument; the former (anterior) are,

The *intercostal nerves*, each connected by one or two filaments with the adjacent sympathetic ganglia: the anterior division of the *first* nerve aids in the formation of the brachial plexus, its intercostal branch is small and gives off no lateral cutaneous branch: the lateral branch of the *second* nerve is the intercosto-humeral (see p. 206): the remaining nerves give off *lateral cutaneous* branches supplying skin of front of thorax and abdomen, while they give *muscular branches* to the intercostal and abdominal muscles.

Describe the lumbar nerves.

The posterior branches resemble in origin and arrangement those of the dorsal region, while their anterior branches form the lumbar and part of the sacral plexuses.

Describe the lumbar plexus and branches.

It is formed by loops of communication between the anterior divisions of the four upper lumbar nerves *in the substance* of the psoas muscle, thus,

The first nerve gives off,

Ilio-hypogastric, to skin of gluteal and hypogastric regions.

Ilio-inguinal, to internal oblique muscle and skin of scrotum (labium in female), and upper inner part of thigh, and

A *communicating loop*, to second lumbar nerve, from which arises, in conjunction with a branch from the third nerve, the

External cutaneous, to skin of antero-external and posterior surfaces of thigh: from the second nerve and loop from first nerve comes, the

Genito-crural, to cremaster muscle and skin of front of upper part of thigh; and a

Communicating loop, to third lumbar nerve. By a branch of the third and fourth nerves with fibres from the second is formed the

Obturator, to obturator externus and adductor muscles, hip- and knee-joints, also sometimes to skin of thigh and leg.

The *accessory obturator*, either from obturator or formed by two filaments from third and fourth nerves, to pectineus muscle and hip-joint.

Communicating loop, between third and fourth nerves.

Communicating loop, between fourth and fifth nerves.

Anterior crural, from third and fourth, with communicating branch from second lumbar nerve. It descends beneath Poupart's ligament external to artery between the psoas and iliacus muscles after emerging from former, and divides into an anterior and posterior division: its branches are, within the pelvis,

Muscular to iliacus internus, to *femoral artery*; external to pelvis,

Middle cutaneous,

Internal cutaneous,

Long saphenous,

Articular (hip and knee),

Muscular.

It supplies all the anterior thigh-muscles except tensor vaginae femoris, and skin of front and inner side of thigh, leg, and foot.

Describe the sacral plexus.

It is formed by the lumbo-sacral cord (the anterior division of fifth nerve with a branch of the fourth), and anterior divisions of three upper sacral nerves and part of that of fourth: it rests upon the anterior surface of the pyriformis muscle, giving off the

Superior gluteal, from lumbo-sacral cord passing out through great sacro-sciatic foramen, to gluteus medius and minimus and tensor vaginae femoris muscles.

Muscular branches, to pyriformis, obturator internus, gemelli, and quadratus femoris.

Pudic passes out of pelvis by greater sacro-sciatic foramen to reënter it by lesser sacro-sciatic foramen: its branches are,

Inferior hemorrhoidal, *Perineal*, *Dorsal of penis*.

Muscular, to transversus peronei, accelerator urinæ, erector penis and compressor urethræ muscles: the preceding branches supply analogous muscles and parts in female.

Small sciatic, escapes by greater sacro-sciatic foramen, to skin of scrotum, back of leg and thigh, and gluteus maximus muscle.

Great sciatic, is a continuation of lower part of sacral plexus,

forming the largest nerve in the body. Escaping by the greater sacro-sciatic foramen below pyriformis muscle, it gives off these branches,

Articular (to hip).

Muscular, to biceps, semi-tendinous, semi-membranous and adductor magnus, and divides into the *internal* and *external popliteal nerves*.

Give the branches of the internal popliteal nerve.

Articular (to knee).

Muscular to gastrocnemius, plantaris, soleus, and popliteus.

External or short saphenous, a cutaneous branch communicating with external popliteal, musculo-cutaneous, and small sciatic nerves.

Describe the posterior tibial nerve.

It is a continuation of former, runs down middle of back of leg beneath the calf muscles to divide between the inner malleolus and the heel into the internal and external plantar: its branches are,

Muscular, to tibialis posticus, flexor longus digitorum and pollicis muscles.

Plantar cutaneous, to skin of heel and inner side of sole of foot.

Internal plantar, supplying skin of sole, tarsal, and metatarsal articulations, the two inner lumbricals, abductor pollicis, and flexor brevis digitorum, with four *digital* branches which supply both sides of first, second, and third toes and inner half of fourth.

External plantar, smaller than preceding, supplying flexor accessorius, abductor minimi digiti, flexor brevis minimi digiti, all the interossei, two outer lumbricales, adductor pollicis, transversus pedis muscles, and skin of little toe and adjoining side of fourth toe.

Describe the external popliteal nerve.

It descends obliquely along outer side of popliteal space close to tendon of biceps, giving off,

Two *articular branches* to knee; *cutaneous branches* to skin of postero-external surface of leg, and a branch, the *communicans peronei*, joining external saphenous nerve: it divides into the

Anterior tibial, about one inch below head of fibula, giving *mus-*

ular branches to tibialis anticus, extensor longus digitorum, peroneus tertius, extensor proprius pollicis, and extensor brevis digitorum, *articular* to tarsal and metatarsal joints, and *cutaneous* to skin of adjacent sides of great and second toes;

Musculo-cutaneous, giving off *muscular branches*, to peroneus longus and brevis, and *cutaneous*, to skin of lower part of leg, and dorsum of foot and toes, except outer side of little and adjoining sides of great and second toes.

Describe the sacral and coccygeal nerves.

They are five in number, their long roots forming the *cauda equina* in the spinal canal; each divides into an *anterior* (see page 209) and *posterior division*, the latter escaping by the posterior sacral foramina, except the fifth, which emerges between sacrum and coccyx, and supplies multifidus spinæ muscle and skin of posterior gluteal region; a branch goes from third nerve to bladder; the two lower nerves join with coccygeal, forming loops, which supply skin over coccygeal region and coccygeus, levator, and sphincter ani muscles.

The Sympathetic Nerve.

What is the sympathetic nerve or system?

It consists of a series of ganglia with intervening commissural bands, forming two cords on either side of spinal column connected above by *ganglion of Ribes* on the anterior cerebral communicating artery, and below by *ganglion impar*, in front of coccyx; they also communicate with the spinal system of nerves.

Locate and briefly describe the connections of the cranial and facial ganglia.

Ganglion of Ribes, on anterior communicating artery, *connected* with cavernous and carotid plexuses.

Carotid ganglion (Laumonier's) on under surface of vessel.

Gasserian, on fifth nerve (infra).

Ciliary or *ophthalmic*, in orbit (infra).

Spheno-palatine (Meckel's), in spheno-maxillary fossa (infra).

Otic (Arnold's), on inner side of inferior maxillary nerve below foramen ovale (infra).

Ganglia are occasionally found on middle meningeal, lingual,

temporal, and pharyngeal arteries, receiving the name of their discoverer, as Bidder, Cloquet, etc.

Ganglion of Bochdalek is situated at point of junction of one of the nasal branches of Meckel's ganglion and anterior dental nerve.

Submaxillary lies above deep portion of submaxillary gland (infra).

Describe the ciliary ganglion.

Situated in the orbit between the optic nerve and external rectus muscle, its roots are, *sensory*, from nasal branch of ophthalmic (fifth pair); *motor*, third nerve; *sympathetic*, cavernous plexus; its branches are,

Short ciliary to ciliary muscle and iris.

Describe the spheno-palatine ganglion.

Deeply placed in spheno-maxillary fossa, its roots are, *sensory*, from superior maxillary; *motor*, facial, through Vidian; *sympathetic*, from carotid plexus; its branches are,

<i>Ascending,</i>	<i>Middle palatine,</i>	<i>Vidian,</i>
<i>Anterior palatine,</i>	<i>Superior nasal,</i>	<i>Pharyngeal, or</i>
<i>Posterior palatine,</i>	<i>Naso-palatine,</i>	<i>Pterygo-palatine.</i>

Describe the otic ganglion.

It lies immediately beneath foramen ovale on the inner surface of inferior maxillary nerve; its roots are, *sensory*, from auriculo-temporal; *motor*, internal pterygoid branch of inferior maxillary, also facial and glosso-pharyngeal through continuation of small petrosal nerve; *sympathetic*, from middle meningeal plexus; its branches supply tensor tympani and tensor palati muscles.

Describe the submaxillary ganglion.

Situated above deep portion of submaxillary gland, its roots are, *sensory*, from gustatory branch of inferior maxillary; *motor*, facial, through chorda tympani; *sympathetic*, from facial plexus; its branches go to mucous membrane of mouth, to submaxillary gland and to its duct.

Describe the petrosal nerves.

The *great petrosal* (large superficial petrosal) is usually described as a branch of the spheno-palatine ganglion passing through the

Vidian canal, distributing twigs to mucous membrane of back part of nose, septum, and end of Eustachian tube, entering skull through foramen lacerum medium, where it divides into the *large superficial petrosal*, which enters hiatus Fallopii, receives a twig from Jacobson's nerve, and terminates in the geniculate ganglion of facial nerve, and the *carotid (large deep petrosal)* joining the carotid plexus.

Small petrosal (small superficial petrosal) connects geniculate ganglion of seventh nerve with otic ganglion.

External petrosal (external superficial petrosal) passes between geniculate ganglion of seventh nerve to middle meningeal plexus.

More correctly, the great petrosal and carotid branches may be said to *form* the Vidian nerve, which runs forward through the same named canal to join the sphenopalatine ganglion, supplying it with motor and sympathetic fibres. According to this description, the twigs said to be given off by the Vidian nerve to the nasal mucous membrane must be considered branches of the *ganglion* running back in the same sheath.

Describe the cervical ganglia.

There are three on either side, viz., the

Superior cervical ganglion. It is placed opposite second and third cervical vertebræ behind carotid sheath, and gives off a

Superior branch, to internal carotid artery, forming by its division the cavernous plexuses and carotid plexus (with its subdivisions);

Descending branch, connecting superior with middle ganglion;

External branches to cranial and spinal nerves, and *anterior branches* forming plexuses on external carotid and its branches;

Pharyngeal, forming with branches from pneumogastric, glosso-pharyngeal, and external laryngeal nerves, the *pharyngeal plexus*;

Laryngeal, uniting with superior laryngeal nerve and its branches;

Superior cardiac, connected with other branches of sympathetic, and with some of pneumogastric, passes to back of aorta, the right joining the *deep*, and the left (usually) the *superficial* cardiac plexus.

Middle cervical ganglion is placed opposite fifth cervical vertebra; by its

Superior and inferior branches it communicates respectively with superior and inferior cervical ganglia; the *external* filaments join

fifth and sixth spinal nerves, the internal are the *thyroid* to inferior thyroid artery and gland, and the *middle* or *great cardiac nerve*, communicating with other sympathetic branches and recurrent laryngeal, to terminate in the deep cardiac plexus.

Inferior cervical ganglion is placed between base of transverse process of seventh cervical vertebra and neck of first rib on inner side of superior intercostal artery; its *superior* and *inferior branches* connect it respectively with middle cervical, and first thoracic ganglia; the *external branches* join the spinal nerves, others form a plexus or vertebral artery; its chief branch is the

Inferior cardiac nerve, communicating with recurrent laryngeal and middle cardiac nerves, terminating in the deep cardiac plexus.

What is the carotid plexus?

It is a plexus situated on the outer side of the internal carotid artery communicating with the Gasserian and spheno-palatine ganglia, the sixth nerve, and tympanic branch of glosso-pharyngeal; it supplies the carotid artery and dura mater

What is the cavernous plexus?

It is one situated below and internal to that part of the internal carotid artery running alongside of the sella turcica, in the cavernous sinus; it communicates with third, fourth, fifth, and sixth nerves, and ophthalmic ganglion, and supplying carotid, it, with the carotid plexus, forms plexuses embracing the cerebral and ophthalmic arteries.

What are the other ganglia of the sympathetic system?

Usually twelve thoracic, four lumbar, four or five sacral, one coccygeal (ganglion impar), and numerous ganglia connected with the various viscera, whence plexuses are formed named from their locality, or the organ.

What are the branches of the thoracic portion?

Communicating, with one another and the dorsal spinous nerves, filaments to aorta and its divisions and to posterior pulmonary plexus, and

The *Great Splanchnic nerve*, formed by internal branches from thoracic ganglia between sixth and tenth, with filaments from

upper six; it perforates crus of diaphragm to terminate in semi-lunar ganglion, sending branches to renal plexus and suprarenal capsule.

The *Lesser Splanchnic*, springing from tenth and eleventh ganglia and cord between and communicating with great splanchnic, it pierces diaphragm with preceding, to join the cœliac plexus.

Smallest, or *Renal Splanchnic*, arises from last ganglion, occasionally communicates with preceding, pierces diaphragm, and terminates in renal and lower part of cœliac plexus.

Describe the solar plexus.

It supplies all the abdominal viscera, consisting of a network of nerves and ganglia lying in front of the aorta and crura of diaphragm, surrounding the cœliac axis and root of the superior mesenteric artery, extending below to the pancreas, laterally to the suprarenal capsules. The great and part of lesser splanchnic nerves of both sides and termination of the right pneumogastric form this plexus, in conjunction with the two semi-lunar ganglia, these latter being large, irregular gangliform masses, composed of smaller ganglia with interspaces between, placed by side of cœliac axis and superior mesenteric artery, close to suprarenal capsules, that on the right lying beneath the vena cava. From this are derived the following plexuses accompanying the same-named arteries to the various organs:

<i>Phrenic</i> , or <i>diaphragmatic</i> ,	<i>Suprarenal</i> ,
<i>Cœliac</i> ,	<i>Renal</i> ,
<i>Gastric</i> ,	<i>Superior mesenteric</i> ,
<i>Hepatic</i> ,	<i>Spermatic</i> ,
<i>Splenic</i> ,	<i>Inferior mesenteric</i> .
<i>Aortic</i> ,	

Name some of the more important.

Tympanic (see p. 316).

Great, or *deep, cardiac* is placed in front of bifurcation of trachea, and above that of pulmonary artery, behind aortic arch, and is formed by all sympathetic cardiac nerves (except left superior), and cardiac branches of recurrent laryngeal and pneumogastric (except left superior cardiac and left inferior cardiac of pneumogastric).

Superficial cardiac lies beneath aortic arch in front of right pul-

monary artery, and is formed by left superior cardiac, left inferior cardiac of pneumogastric, and branches from deep cardiac plexus.

Coronary, the *posterior*, chiefly from deep, the *anterior* from superficial cardiac plexus.

Aortic, on sides and front of vessel between roots of superior and inferior mesenteric arteries.

Hypogastric, lying in front of sacrum, between common iliac arteries, it supplies the pelvic viscera, and is formed by filaments from aortic plexus, and from lumbar and first two sacral ganglia, contains no ganglia, and divides into two lateral portions, forming the inferior hypogastric or pelvic plexuses.

Inferior hypogastric plexuses. These lie upon each side of rectum and bladder (rectum, vagina, and bladder, in females), and each is formed by a continuation of the hypogastric plexus and branches from second, third, and fourth sacral nerves, and a few filaments from sacral ganglia; the branches accompany those of internal iliac artery, and are distributed to all the pelvic viscera; their branches are

Inferior hemorrhoidal plexus.

Vesical plexus.

Prostatic plexus

} *Small and large
cavernous nerves
to penis.*

Vaginal plexus.

Uterine nerves.

VISCERAL ANATOMY.

The Digestive Organs.

What is a viscus?

Any of the internal organs with their appendages, contained within the cranial, thoracic, or abdominal cavities.

Of what does the digestive apparatus consist?

Of the alimentary canal, a musculo-membranous tube, lined with mucous membrane, about thirty feet long, and extending from the mouth to the anus, and certain accessory organs.

Name the subdivisions of the alimentary canal.

Mouth, pharynx, œsophagus, stomach, small intestine (duodenum, jejunum, ilium), large intestine (cæcum, colon, rectum).

What are the accessory organs ?

The teeth, salivary glands (parotid, submaxillary, sublingual), liver, pancreas, and spleen.

The Teeth.**What is their function ?**

To reduce the food to fragments, thus enabling the digestive fluids to act to best advantage.

Into what classes are they divided ?

Into

Temporary, or milk teeth, ten in each jaw, viz., four incisors, two canines, and four molars ;

Permanent teeth, sixteen in each jaw, viz., four incisors, two canines, four bicuspid or premolars, six molars.

Of what parts does every tooth consist ?

Of a

Crown or body (Fig. 82), that part projecting above the gum.

Neck, the constricted portion between crown and fang.

⁴*Fang, or root*, that part occupying the alveolus, held there by the periodontium (periosteum), lining the socket; in addition, the teeth are steadied by the *gums*, composed of dense fibrous tissue covered with mucous membrane.

³*Pulp-cavity*, an interior cavity filled with the tooth-pulp, a vascular connective tissue with numerous nerves, both arteries and nerves reaching the pulp by a canal opening at apex of fang.

Describe the characteristics of each of the four varieties of teeth.

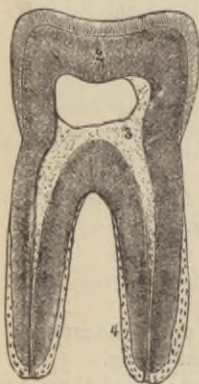Incisor or cutting teeth. The crown is wedge-shaped, convex in front, bevelled and slightly concave behind; the fang is single, long, conical, and transversely flattened.

Canines. Crown is large, conical, convex in front, rises above level of other teeth; fang long, conical, compressed laterally; upper pair are called in common parlance "eye-teeth," the lower "stomach-teeth."

Bicuspid. Crown has two projecting cusps, fang generally is single, laterally grooved with bifid apex; they are also called *pre-molars*.

Molar (grinders). Crown nearly cubical, with four cusps in upper, and five in lower molars; fangs, usually three for first two upper, and two for first two lower molars; the third molar is called the "wisdom tooth" (*dens sapientiae*), from its late appearance, and usually has but one fang with grooves indicating a tendency to formation of three fangs in upper, two in lower jaw.

FIG. 82.



The *second temporary molar* is the largest milk tooth, and is succeeded by the second permanent bicuspid.

Describe the structure of a tooth.

Each is formed chiefly of

Dentine, or *ivory*², composed of minute, wavy, branching tubes, called *dental tubuli*, embedded in a hard, homogeneous substance, the *intertubular tissue*. The tubules are about $\frac{1}{1500}$ th of an inch in diameter, dividing dichotomously, giving the wavy appearance of the cut surface, and open into the pulp cavity. Chemically dentine consists of twenty-eight parts of animal, and seventy-two of earthy matter.

*Enamel*¹ forms a thin crust over crown, is the densest of all animal tissues, containing only 3.5 per cent. of animal matter, and is composed of minute parallel hexagonal rods, about $\frac{1}{3500}$ th of an inch in diameter, pursuing a wavy course.

Cement, or *crusta petrosa*⁴, is a layer of true bone commencing at the neck and becoming thicker toward apex of fang.

Pulp, filling the pulp-cavity³, consisting of soft, very vascular connective tissue, with numerous nerves and cells, the latter being

of two kinds, columnar, called *odontoblasts*—arranged in a layer lining pulp-cavity—and fusiform cells wedged in between these or permeating the pulp, both having fine processes, said to be prolonged into the dentinal tubules.

Whence do the teeth obtain their blood and nerve supply?

From the alveolar and infraorbital branches of internal maxillary, and from inferior dental artery; the nerves come from the anterior and posterior dental branches of the superior maxillary, and from the inferior maxillary division of the fifth nerve

When do the temporary teeth appear?

The time is variable, but, according to the latest authority, they erupt as follows, expressed in *months*:

	Molar.	Molar.	Canine.	Incisor.	Incisor.	Incisor.	Incisor.	Canine.	Molar,	Molar.
Upper. . . .	20-30	12-15	18-24	8-10	8-10	8-10	8-10	18-24	12-15	20-30
Lower	20-30	12-15	18-24	12-15	4-7	4-7	12-15	18-24	12-15	20-30

The order of their appearance is first, lower central incisors; then upper central incisors, closely followed by laterals; then lower laterals; next upper anterior molars followed by lower; then upper canines followed by lower; finally, lower back molars, followed by upper.

Describe the order of appearance of the permanent teeth.

The first to appear are first molars at end of sixth year, the lower teeth usually preceding the upper; thus, expressed in *years*, these teeth erupt as follows:

	Wisdom.	Molar.	Molar.	Bicuspid.	Bicuspid.	Canine.	Incisor.	Incisor.	Incisor.	Incisor.	Canine.	Bicuspid	Bicuspid.	Molar.	Molar.	Wisdom.
Upper	17-21	12-13	6½	10	9	11-12	8	7	7	8	11-12	9	10	6½	12-13	17-21
Lower	17-21	12-13	6½	10	9	11-12	8	7	7	8	11-12	9	10	6½	12-13	17-21

Describe the development of the teeth.

About the seventh foetal week appears a depression in each jaw, the *primitive dental groove*, from the bottom of which is developed a ridge which, atrophying at intervals, leaves a row of projecting papillæ, containing *odontoblasts*, which become capped with epithelial masses developed from the margins and sides of the groove, the *enamel organ*. Now the groove becomes converted into *follicles*, each containing a papilla, by contraction and projection of its margins and the ingrowth of membranous septæ.

About the thirteenth week the papillæ grow rapidly, the follicles deepen and become closed in by the coalescence of from two to five small membranous outgrowths springing from their margins, called *opercula*. The lips of the dental groove advance and fuse, completing the *saccular stage* about the end of the fifteenth week. The more superficial portion of the groove remains open, leaving the *secondary dental groove*, in which ten lunated depressions appear behind each of the sacs of the milk teeth, for the ten anterior permanent teeth; the secondary groove closes in like the primary one, the follicles becoming *cavities of reserve*, into which papillæ grow to be closed in as for the temporary teeth; the remaining teeth arise from successive expansions backward of the primitive dental groove. The dentine forms from without inward capped with enamel, and by the gradual growth of the fang the crown produces absorption by pressure upon the overlying bone and mucous membrane, when *eruption* occurs; the *cementum* is formed by the periodontal membrane last of all, increasing up to old age.

The Mouth.

What is the mouth?

It is an ovoid cavity in which food is masticated, bounded by lips in front, by cheeks and alveolar processes of both jaws with their contained teeth at sides, by hard and soft palate above, by tongue and floor of mouth below, and terminates at the anterior pillars of the fauces where it opens into pharynx by fauces, and is lined by mucous membrane covered by scaly stratified epithelium containing numerous racemose glands, continuous with external skin; it presents for examination

The *hard palate*, formed by palatal processes of superior maxillary and palate bones covered by the intimately adherent periosteum and mucous membrane.

Soft palate, consisting of a fold of mucous membrane depending from posterior border of hard palate, enclosing muscular tissue, an aponeurosis, adenoid tissue, mucous glands, etc.; the muscles on each side being the levator and tensor palati, palato-glossus, palato-pharyngeus, and azygos uvulæ—the latter with fellow forming the median projecting conical *uvula*.

Anterior and posterior pillars of the fauces, the former containing within a fold of mucous membrane the palato-glossus muscle on each side, arching downward and forward from palate to base of tongue; the latter, the palato-pharyngei muscles, passing backward and downward to sides of pharynx.

Isthmus faucium, bounded by pillars of fauces, base of tongue, and free margin of soft palate.

Tonsils (Fig. 83), situated between anterior and posterior pillars on each side, consisting of glandular tissue containing twelve to fifteen openings leading into crypts lined with mucous membrane, external to which is a layer of closed capsules analogous to those of Peyer's glands; the tonsil is only separated from the internal carotid artery by superior constrictor muscle.

Openings of ducts of Steno, opposite second upper molar tooth on each side, delivering the secretion of parotid glands.

Openings of ducts of Wharton, one on either side of frænum of tongue, delivering secretion of submaxillary glands.

Openings of ducts of sublingual gland (ducts of Rivinus), from eight to twenty in number, they open on an elevated crest of mucous membrane on each side of frænum linguæ, one or more joining in a tube opening into Wharton's duct called the *duct of Bartholine*.

What are the salivary glands?

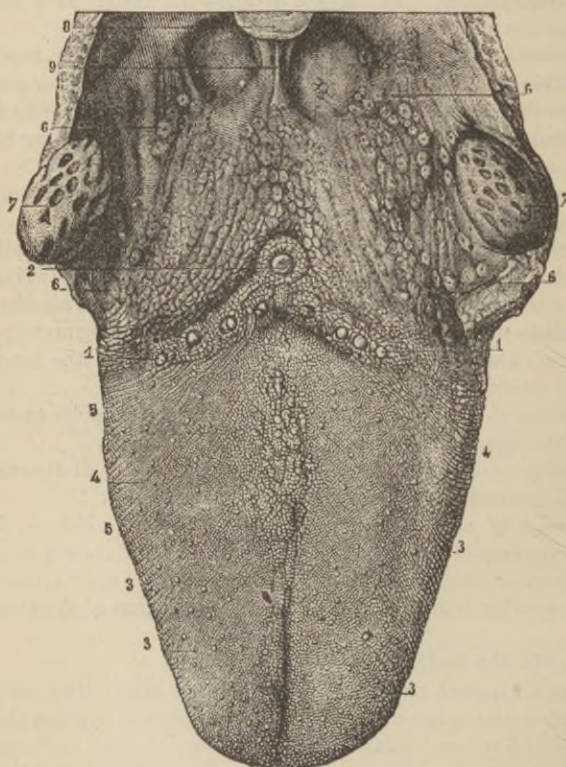
Three compound racemose glands on each side. The *parotid*, the largest, lies below and in front of ear between zygoma above, mastoid behind, and ramus of jaw in front—its duct is *Stenson's*; the *submaxillary* lies below jaw in anterior part of submaxillary triangle—its duct is *Wharton's*; the *sublingual* lies beneath mucous

membrane of floor of mouth against jaw, close to symphysis—its ducts are those of *Rivinus*.

Describe the tongue.

Its base is attached to hyoid bone by muscles, to epiglottis by the two lateral and one median⁹ glosso-epiglottidean fold of

FIG 83.



mucous membrane, and to soft palate by anterior pillars; its tip, sides, dorsum, and part of under surface are free; a median raphé

and fibrous septum divide the organ into halves; its mucous membrane reflected over floor of mouth to gums forms in front an antero-posterior fold, the *frænum linguae*; the tongue is formed by certain *intrinsic muscular fibres*, viz., those of *lingualis*, and by *extrinsic muscles*, the *stylo-glossus*, *hyo-glossus*, *genio-hyo-glossus*, and *palato-glossus* (see p. 121). The mucous membrane of tongue presents the

Circumvallate papillæ, numbering eight to ten, arranged on back part of dorsum in two lines converging behind like a letter V, presenting at their junction a deep mucous follicle, the *foramen cæcum*².

*Fungiform papillæ*³, scattered over dorsum, but chiefly found at sides and apex.

*Filiform papillæ*⁴, with secondary papillæ projecting from apices, arranged in lines, cover the anterior two-thirds of dorsum of tongue.

*Racemose glands*⁵, situated along sides beneath tip, but chiefly over posterior third of dorsum.

Lymphoid tissue, collected into masses or *follicles*, some resembling crypts of tonsil.

Describe the blood supply.

This is from,

Lingual	{	<i>Dorsalis linguae</i> ,	Facial, by submental branch anastomosing with sublingual.
		<i>Sublingual</i> ,	
		<i>Ranine</i> ,	
<i>Ascending pharyngeal</i> .			

Describe the nerve supply.

The gustatory branch of fifth is distributed to papillæ at front and sides, which endows these parts with general sensibility; and also by its connection with the *chorda tympani* becomes the nerve of taste.

Lingual branch of the glosso-pharyngeal, supplying mucous membrane of base and sides and circumvallate papillæ; it is the nerve of taste for these parts.

Hypoglossal, to muscles; the motor nerve.

Superior laryngeal, sends a few filaments to base from its internal branch.

What two anatomical points of surgical interest does the palate present in the neighborhood of the last molar tooth ?

Just behind this tooth the *hamular process and internal pterygoid plate* can be felt, the point for division of tensor palati aponeurosis in the operation for cleft palate, and in front of this to inner side of last molar tooth is the *posterior palatine artery* as it emerges from the canal, sometimes requiring plugging after a cleft-palate operation.

The Pharynx.

What is the pharynx ?

A conical musculo-membranous sac, about four and a half inches long, extending from under surface of base of skull to a point corresponding to the cricoid cartilage in front, and the fifth cervical vertebra behind. It is widest opposite cornua of hyoid bone, narrowest below, where it terminates in the œsophagus; it is bounded above by basilar process of occiput, is connected *posteriorly* with the cervical vertebræ and longus colli and recti capitis antici muscles; *anteriorly* it is incomplete, opening into the mouth, being attached to internal pterygoid process, pterygo-maxillary ligament, lower jaw, tongue, hyoid bone and larynx; *laterally*, it is attached to styloid processes and muscles arising from them, while the common and internal carotid arteries, the internal jugular veins, and eighth, ninth, and sympathetic nerves here lie in contact with it.

How many openings communicate with it ?

Seven: the two posterior nares, two Eustachian tubes, mouth, larynx, and œsophagus.

Of how many coats does it consist ?

Three: an internal *mucous*, continuous with lining of mouth, etc., covered with ciliated epithelium down to the level of floor of nares, below by squamous epithelium, containing racemose glands most plentiful around orifices of Eustachian tubes, and much lymphoid tissue surrounding crypts like those of tonsil; a middle

fibrous coat (pharyngeal aponeurosis), thick above, where the muscular fibres are wanting; and an external *muscular coat* composed of the superior, middle, and inferior constrictors, stylo-pharyngeus, and palato-pharyngeus muscles.

Describe the pharyngeal muscles.

*Inferior constrictor*⁸: *origin*, side of cricoid and thyroid cartilages; *insertion*, posterior median raphé; *action*, constricts pharynx during swallowing; *nerves*, pharyngeal plexus, glosso-pharyngeal, external laryngeal, recurrent laryngeal.

*Middle constrictor*⁹: *origin*, greater and lesser cornua of hyoid bone and stylo-hyoid ligament; *insertion*, posterior median raphé; *action*, same as superior constrictor; *nerves*, glosso-pharyngeal, pharyngeal plexus.

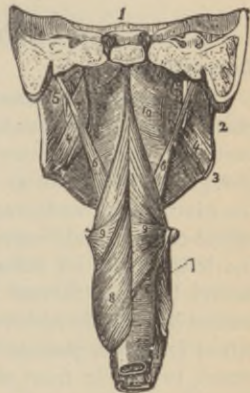*Superior constrictor*¹⁰: *origin*, lower third of margin of internal pterygoid plate and hamular process, contiguous surface of palate bone, reflected tendon of tensor palati muscle, pterygo-maxillary ligament, alveolar process above posterior end of mylo-hyoid ridge and side of tongue; *insertion*, posterior median raphé and pharyngeal spine of occipital bone; *action*, same as other constrictors; *nerves*, glosso-pharyngeal plexus.

*Stylo-pharyngeus*⁶: *origin*, inner side of base of styloid process; *insertion*, blends with constrictor muscles, and is inserted into the posterior border of thyroid cartilage; *action*, draws sides of pharynx upward and outward; *nerves*, glosso-pharyngeal, pharyngeal plexus, the former running on outer side, and crossing muscle to reach tongue.

What is the pharyngeal tonsil?

A considerable mass of lymphoid tissue extending across back of pharynx, between the orifices of the Eustachian tubes.

FIG. 84.



What arteries supply the pharynx?

<i>Superior thyroid,</i>	<i>Pterygo-palatine,</i>
<i>Ascending pharyngeal,</i>	<i>Descending palatine, to</i> <i>epiglottis, etc.</i>

What are its nerves?

Branches from pharyngeal plexus, formed by pharyngeal branches of glosso-pharyngeal, pneumogastric, superior laryngeal, and sympathetic nerves.

The Œsophagus.**Describe it.**

It is a muscular canal, about nine inches long, joining the pharynx and the stomach, commencing at lower border of cricoid cartilage, passing through the œsophageal opening of the diaphragm, to terminate at cardiac orifice of the stomach, opposite the ninth dorsal vertebra; in the *neck* it lies between trachea and spinal column and longus colli muscle, at lower part inclining to the left, having on either side the common carotid artery, with lateral lobes of thyroid gland—the recurrent laryngeal nerves ascend between it and trachea; in the *thorax*, while a little to the left at first, after passing behind aortic arch, it runs to right of the vessel, to pass in front and to the left again before piercing the diaphragm.

What coats has it?

It has three: an internal *mucous*, when empty thrown into longitudinal folds, containing numerous racemose glands, its surface is studded with small papillæ, and it is covered by a thick layer of squamous epithelium; a middle *cellular*, loosely connecting the mucous and the succeeding coat; a *muscular*, composed of an external longitudinal and internal circular layer, the fibres *above* consisting chiefly of the striated, but *below* almost entirely of the unstriped involuntary variety.

Name its arteries and nerves.

Arteries, chiefly from thoracic aorta.

Veins, are drained by vena azygos minor.

Nerves, from œsophageal plexus, formed by pneumogastrics with some sympathetic filaments.

The Stomach.

Describe it.

The stomach is irregularly conical, curved upon itself, presenting a round base turned to left side. Moderately distended, it measures about twelve inches in its longest, and four inches in its vertical diameter. It lies in left hypochondriac, epigastric, and part of right hypochondriac regions, immediately behind anterior wall of abdomen below the liver and diaphragm, and above the colon; it presents for examination the

Greater or splenic end, or *fundus*, situated to the left, being attached to the spleen by gastro-splenic omentum, and to diaphragm by gastro-phrenic ligament.

The *lesser*, or *pyloric end*, is in contact with abdominal wall and under surface of liver near end of cartilage of eighth rib.

The *œsophageal*, or *cardiac orifice*, is the highest point of the stomach, is funnel-shaped, and communicates with œsophagus.

The *pyloric orifice* communicates with duodenum, the opening being guarded by a reduplication of the mucous lining containing numerous circular muscular fibres, forming a thick ring—this is called the *pyloric valve*.

The *lesser curvature* extends along the upper border of organ between the cardiac and pyloric orifices, is concave, and is connected with under surface of liver by the lesser omentum.

The *greater curvature* is convex, extends along lower border between the two orifices, and gives attachment to great omentum.

How many coats has the stomach?

Four, as follows: a

Serous, derived from peritoneum covering all parts except along greater and lesser curvatures, where the omenta leave a triangular space, along which pass the vessels and nerves; a

Muscular, consisting of three sets of fibres: *longitudinal*, continuous with the longitudinal coat of œsophagus and small intestine, more distinct along the curvatures; the *circular fibres* form a continuous layer beneath the former set, most abundant at pyloric

end, forming valve (supra); the *oblique fibres*, some passing obliquely from left to right, others *vice versâ*, around the cardiac orifice, to which part they are chiefly limited; a

Mucous, covered with columnar epithelium, and thrown into longitudinal folds or *rugæ* when stomach is empty, covered by small shallow polygonal-shaped alveoli from $\frac{1}{100}$ th to $\frac{1}{350}$ th of an inch in diameter, into which the gastric follicles open.

Describe the gastric glands.

They are of three kinds, the

Peptic follicles, lined throughout with columnar epithelium, consisting of a duct into which open several cæcal tubes, in which, beneath the epithelium, lie large spheroidal, coarsely granular *peptic cells*; these glands are found in all parts of the stomach.

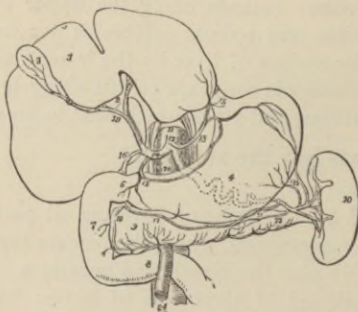
Mucous glands, found in greatest numbers at pyloric end, and resemble the preceding, but are *without* the large peptic cells, and the cæcal tubes are longer.

Lenticular, or *simple solitary*, found especially in early life, consisting of masses of lymphoid tissue.

Give the blood and nerve supply.

The *arteries* are, *gastric*¹³, *pyloric* and *right gastro-epiploic*¹⁷ branches of the *hepatic artery*¹⁴.

FIG. 85.



Left gastro-epiploic²¹, } Branches of
 Vasa brevia²³, } Splenic artery²⁰.

The *veins* empty into splenic and portal veins.

The *nerves* are terminal branches of both pneumogastrics and numerous branches from sympathetic.

The Small Intestine.

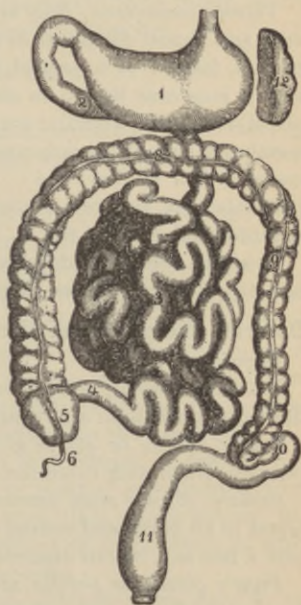
Describe it.

It is the narrowest part of the digestive tract, is a convoluted tube some twenty feet long, occupying the central and lower parts of the abdominal and pelvic cavities, and is suspended from the spine by a fold of peritoneum called the *mesentery*; its three divisions are the

*Duodenum*² (Fig. 86), as long as the breadth of twelve fingers, *i. e.*, eight to ten inches, passing upward and backward to the right to under surface of liver, near gall-bladder—*ascending portion*—then descending in front of right kidney—*descending portion*—thence running transversely across spine to end in the jejunum on left side of second lumbar vertebra—*transverse portion*—the junction being crossed by superior mesenteric artery; it is only partially covered by peritoneum, has no mesentery, and surrounds the head of the pancreas; into the descending portion, to the inner side, pass obliquely the common bile and pancreatic ducts.

*Jejunum*³, so-called because usually empty after death, includes upper two-fifths of remainder of small intestine, and lies chiefly in the umbilical region.

FIG. 86.



*Ileum*⁴, includes remainder (three-fifths) of small intestine, is named from its numerous coils, occupies chiefly umbilical, hypogastric, right iliac, and occasionally pelvic regions, and opens into the inner side of the commencement of the large intestine in the right iliac fossa; the orifice is guarded by a two-leaved valve (see page 231).

What coats has the small intestine?

The same as stomach.

The *mucous membrane* is covered with columnar epithelium, and forms transverse folds encircling the tube for one-half to two-thirds its circumference, forming the

Valvulae conniventes; they are absent in first two inches of duodenum and almost disappear in lower part of ileum; *villi* cover the surface, formed of a central lacteal vessel accompanied by unstriped muscular tissue, an encircling plexus of capillaries, lymphoid tissue and granular corpuscles, all enclosed by a basement membrane supporting columnar epithelium: their number is estimated at four million; the

Cellular coat connects mucous with muscular coat, and contains the intestinal vessels; the

Muscular coat, externally is composed of longitudinal and internally of circular fibres, these not forming complete rings.

Describe the glands of the small intestine.

They are,

Brunner's glands, resembling pancreas in structure, and are limited to duodenum and commencement of jejunum.

Simple follicles or *glands of Lieberkühn*, are minute tubular depressions lined with columnar epithelium.

Solitary glands, most numerous in lower part of ileum, but found in all parts, and consist of masses of lymphoid tissue about half a line to a line in diameter.

Peyer's glands or *patches* are twenty to thirty ovoidal patches composed of numerous solitary glands (hence named *agminated glands*), situated opposite to mesenteric attachment, their long axis lengthwise, and are largest and most numerous in ileum, although occasionally seen in duodenum; the *valvulae conniventes* cease at their margins.

Name bloodvessels and nerves.

The *arteries* are from gastro-duodenal of hepatic and superior mesenteric arteries; the *veins* chiefly empty into portal vein; *nerves* are, from superior mesenteric plexus of sympathetic.

The Large Intestine.**Describe it^{5, 7, 8, 9}.**

It extends from ileum to anus, is about five feet long, is large and sacculated, has the same coats as small intestine, the mucus destitute of villi, but thrown into crescentic folds by the longitudinal muscular fibres which are disposed in three bands, shorter than the other coats, so forming them into pouches.

Describe the subdivisions of the colon.

They are,

The *cæcum*⁵ or *caput coli*, the dilated commencement of the large bowel situated in the right iliac fossa, and usually wholly covered by peritoneum.

The *appendix vermiformis*⁶, a narrow, blind-ended, worm-like tube, from three to six inches long, springing from lower back part of cæcum, held, coiled upon itself, by a peritoneal fold.

The *ileo-cæcal valve* (or Bauhin's) is formed by two horizontal semilunar folds of mucous membrane at the termination of ileum in cæcum, opening toward large intestine and guarding against reflux *from large into small bowel*; the mucous folds are reinforced by circular muscular fibres, and the surfaces toward the ileum are covered with villi, while these are absent on the cæcal side.

The *ascending colon*⁷ extends up from cæcum in front of right kidney, to under surface of liver to right of gall-bladder, where abruptly bending to the left, it forms the *hepatic flexure*; it is almost—sometimes entirely—enveloped in peritoneum, in which latter event it has an *ascending meso-colon*.

The *transverse colon*⁸ traverses the abdomen from right to left, just below liver, stomach, and spleen, to left hypochondriac region, where it curves downward beneath lower end of spleen, forming the *splenic flexure*; it has a wide transverse *meso-colon*, attaching it to the spine.

The *descending colon*⁹ passes down in front of left kidney to left iliac fossa and is only partially covered with peritoneum, its posterior surface usually being free.

The *sigmoid flexure*¹⁰, the narrowest part, lies in left iliac fossa extending from descending colon at crest of ilium to left sacro-iliac symphysis; it is curved like an S, and is held in place by a loose peritoneal fold, the *sigmoid meso-colon*.

The *rectum*¹¹ extends from left sacro-iliac symphysis to anus, is from six to eight inches long, curves slightly to right and then adapts itself to sacral curve, and near top of coccyx inclines backward to anus; it is non-sacculated, but just above anus presents a considerable dilatation; it is only covered with peritoneum at its anterior portion—except above—while its lower inch and a half is destitute of any such covering; the longitudinal muscular fibres form a continuous layer around the rectum.

What are the appendices epiploicæ ?

They are little peritoneal pouches filled with fat placed along colon and upper part of rectum.

What guards the anal orifice ?

The sphincter ani and internal sphincter; a third has been described as some three inches up the bowel (see page 331)

What are the folds of Houston ?

Three semilunar folds of mucous membrane, one at upper right side of rectum, one at left middle portion, and one projecting from front of rectum opposite bladder.

Name the glands of the large intestine.

Follicles of Lieberkühn and solitary glands.

Give the blood- and nerve-supply of the large intestine and rectum.

The *arteries* are branches of the *superior* and *inferior mesenteric*, the *middle hemorrhoidal* from the internal iliac, and the *inferior hemorrhoidal* from internal pudic.

The *nerves* come from sympathetic plexuses around mesenteric arteries, and, in case of rectum, the fourth anterior sacral nerve supplies the sphincter muscle.

The Liver.

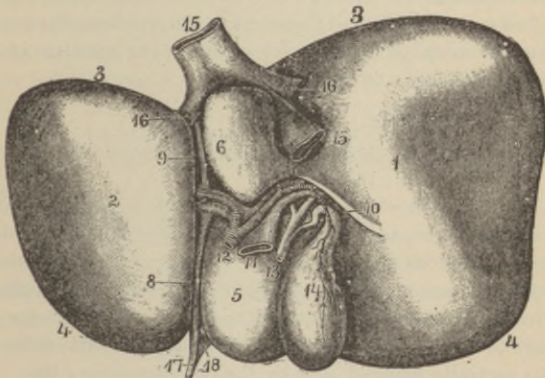
Describe it.

It occupies the right hypochondriac region extending across the epigastrium into the left hypochondriac. It is the largest gland in the body, weighing from three to four pounds, its transverse diameter is from ten to twelve inches, its antero-posterior six to seven, its thickest part behind three inches. Covered by peritoneum, except at attachments of ligaments and bottom of fissures, it possesses a *fibrous coat*, covering the whole organ continuous with the *capsule of Glisson* at transverse fissure; there are five fissures, five lobes, five ligaments, and five sets of vessels; the

Upper surface is convex, smooth, lying in contact with diaphragm above, and below with a small portion of abdominal wall; it is divided into two unequal lobes by a peritoneal fold, the suspensory ligament; the

Under surface is concave, is in relation with stomach, duodenum,

FIG. 87.



hepatic flexure of colon, right kidney, and suprarenal capsule, and is divided by a *longitudinal fissure*^{8,9}, into a right and left lobe; the

*Anterior border*⁴ is thin, sharp, and deeply notched at site of

round ligament; it corresponds usually with margins of ribs in males, projecting a little lower in women and children; the

*Posterior border*³ is rounded and grooved, or even perforated, by inferior vena cava.

Describe the ligaments.

They are five in number, four being composed of folds of peritoneum, the fifth is the obliterated umbilical vein; the

*Suspensory or broad ligament*¹⁸ (falciform) is a falciform antero-posterior peritoneal fold, with apex backward, attached to liver from notch on anterior border to posterior border,—its anterior free edge enveloping the round ligament—and to diaphragm and sheath of right rectus muscle as low as umbilicus; the

Coronary ligaments consist of two layers reflected from diaphragm on upper and lower margins of posterior border of organ, between which firm areolar tissue binds the liver to diaphragm; the

Lateral ligaments, right and left, triangular, are formed of two layers of peritoneum extending from sides of diaphragm to adjacent margins of posterior border of liver; the

*Round ligament*¹⁷, a fibrous cord, ascends from umbilicus in anterior free margin of broad ligament to longitudinal fissure, traceable back to vena cava, the back portion, the remains of ductus venosus, the anterior of umbilical vein.

Describe the fissures.

They are five in number, dividing the under surface of the organ into five lobes; the

Longitudinal fissure^{8, 9}, extends from notch on anterior border to posterior border, separating right and left lobes, and is joined by the *transverse fissure*¹⁰ at posterior third; the anterior two-thirds of the longitudinal fissure is called the *umbilical fissure* from lodging foetal umbilical vein, the posterior third the *fissure of the ductus venosus* lodging the obliterated foetal vessel; the anterior part of the former is often partially bridged over by the *pons hepaticus*; the

*Transverse fissure*¹⁰ is about two inches long, passing transversely across under surface of right lobe from junction of posterior and middle thirds of longitudinal fissure; here enter the portal vein, hepatic artery, and nerves, and the bile ducts and lymphatics emerge; the

*Fissure of the gall-bladder*¹⁴ lies parallel and to right of longitudinal fissure reaching back nearly to transverse fissure; the

Fissure for vena cava is short and deep, sometimes converted into a canal, extending obliquely upward from a little behind right extremity of transverse fissure to posterior border of liver, there joining the fissure of ductus venosus; the hepatic veins here empty into vena cava.

Describe the lobes of the liver.

They are five in number; the

*Right lobe*¹, the largest, of a quadrilateral form, its under surface marked by three fissures: viz., transverse, for gall-bladder, and for inferior cava, and by an anterior depression for colon, a posterior one for right kidney; the longitudinal fissure forms the division between this and the

*Left lobe*², smaller and flattened, resting by its anterior concave surface on stomach; the

*Lobus quadratus*³ is marked off from under surface of right lobe by transverse fissure behind, by that for the gall bladder on the right, and anterior part of longitudinal fissure on left; the

*Lobus Spigelii*⁶ projects from back under surface of right lobe, bounded in front by transverse fissure, on right by that for cava, and on left by posterior third of longitudinal fissure; the

*Lobus caudatus*⁷ is a small elevation running obliquely outward from base of lobus Spigelii to under surface of right lobe; it intervenes between right end of transverse fissure and commencement of that for vena cava.

Describe the vessels of the liver.

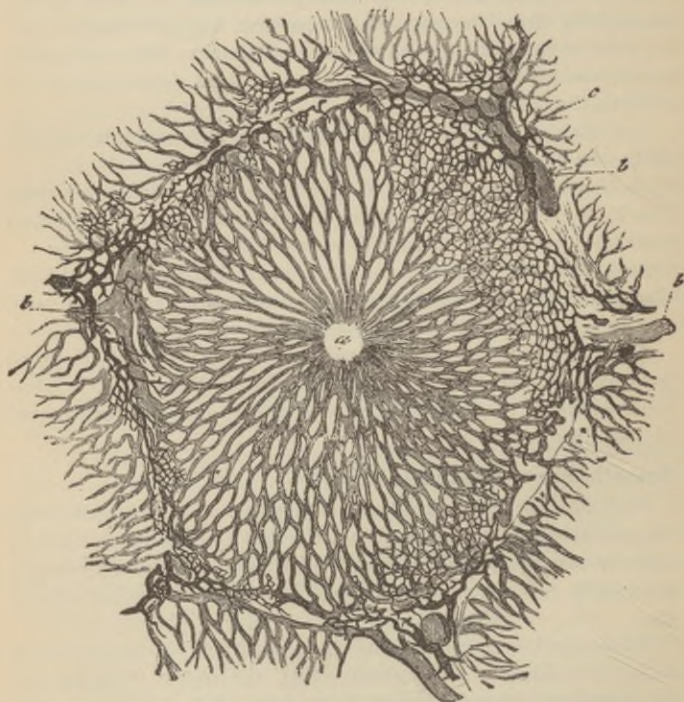
They number five, viz., hepatic artery, portal vein, hepatic vein, hepatic duct, and the lymphatics; the first three are enveloped in loose areolar tissue called *capsule of Glisson*, which accompanies the vessels through the *portal canals* in the interior of the organ; the

*Portal vein*¹¹, about four inches long, is formed by the junction of superior mesenteric and splenic veins, the latter receiving the blood returned by inferior mesenteric vein, while the gastric veins empty into the portal vein itself. Entering the transverse fissure it divides into branches for right and left lobe, which receive the

vaginal and *capsular* veins, and subdividing form *interlobular veins*^b (Fig. 88), which send branches to interior of each lobule forming a plexus converging to empty into the central *intra-lobular vein*^a running at right angles to other vessels; the intra-lobular vein empties into a *sublobular vein*, a radicle of hepatic vein; the

*Hepatic veins*¹⁶ (Fig. 87) commence in sublobular veins as just described, which unite to form three large and several smaller branches terminating in inferior vena cava in fissure for that vessel; the

FIG. 88.



*Hepatic artery*¹² springs from coeliac axis, enters transverse fissure, and divides into branches which ramify in the capsule of

Glisson—*vaginal*, supplying nutriment to vessels, ducts, etc., *capsular* to terminate in external fibrous coat—and ends in a plexus on outer surface of each lobule formed by ultimate branches of portal vein, the *interlobular plexus* above described; the

Hepatic duct ^{above 13} is formed by the union of two trunks of nearly equal size which emerge from the transverse fissure, one from the right and other from left lobe; it passes downward to the right for one inch and a half to be joined by the *cystic duct* from the gall-bladder, to form the ductus communis choledochus (see p. 238); the

Lymphatics accompany bloodvessels, and consist of a deep and superficial set.

Whence do the nerves of the liver come?

From the hepatic plexus of the sympathetic, from the pneumogastric nerves, especially the left, and right phrenic.

Describe the liver structure.

It is composed of numerous lobules from one-twentieth to one-tenth of an inch in diameter, of irregular form in human liver, polygonal in pigs, their bases clustered round the sublobular vein, to which each is connected by its intralobular vein; the lobules are bound together by loose areolar tissue; each lobule is formed of *hepatic cells*, spheroidal or many-sided nucleolo-nucleated cells, measuring from one-one thousandth to one-two thousandths of an inch, containing granular yellow coloring matter and globules, which cells lie in the meshes of the dense capillary network occupying its interior, spaces between the cells forming *intercellular biliary passages*, the radicles of the bile ducts.

What is the capsule of Glisson?

The areolar tissue entering the transverse fissure, surrounding the hepatic vessels to their ultimate ramifications, and continuous with fibrous coat of organ.

How may the portal be distinguished from the hepatic veins in a liver section?

The portal veins are collapsed, being surrounded by the capsule of Glisson, while the hepatic are patulous, being closely connected with liver substance.

Describe the gall-bladder¹⁴.

It is a pear-shaped, fibro-muscular receptacle for the bile; its fundus and under surface of body and neck covered by peritoneum, while its interior is lined with a cylindrical-celled, epithelial-coated mucous membrane, presenting a honeycombed appearance from the confluence of numerous minute rugæ; its length is from three to four inches, its capacity from eight to twelve fluidrachms, and it lies in a fissure on the under surface of liver, its *fundus*—most dilated portion—projecting slightly beyond the anterior border, touching abdominal wall just below ninth costal cartilage; the narrow *neck* curves upon itself like an italic *f*, to terminate in the *cystic duct*, which is about one inch long, and is lined by mucous membrane so disposed in a series of crescentic folds as to present the appearance of a *spiral valve*; it joins the hepatic duct to form the common bile-duct.

Describe the ductus communis choledochus¹³ (Fig. 87).

It is about three inches long, three-sixteenths of an inch in diameter, and is formed by the junction of the hepatic and cystic ducts; it opens usually by a common orifice with the pancreatic duct, a little below the middle of inner side of descending portion of duodenum; its walls are composed of fibrous with a little muscular tissue, its mucous membrane is covered with columnar epithelium, and it runs between the layers of gastro-hepatic process of the peritoneum.

The Pancreas.

Describe the pancreas⁹ (Fig. 85).

It is a compound racemose gland, from six to eight inches long, by one and one-half inches at its widest part, lying behind the stomach and in front of the first lumbar vertebra. It is composed of lobules connected by areolar tissue, each lobule consisting of an ultimate branch of the duct lined with columnar epithelium, terminating in caecal pouches or acini, also lined with cylindrical epithelium, outside of which is a fine capillary network. The *Pancreatic duct* (*canal of Wirsung*) extends the whole length of

gland and opens into middle of descending part of duodenum, to the inner side, with common bile-duct; its

Head or right extremity is embraced by the concavity of the duodenum, the common bile-duct lying behind, the pancreatico-duodenal artery in front; the

Tail or left extremity reaches spleen above left kidney and suprarenal body; the

Body is covered by the ascending layer of transverse meso-colon and posterior surface of stomach; posteriorly, the superior mesenteric artery and vein, the portal vein, the vena cava, and the aorta separate it from the first lumbar vertebra.

The *arteries*¹⁸ (Fig. 85) are derived from the splenic, pancreatico-duodenal branch of hepatic and superior mesenteric arteries.

The *veins* empty into splenic and superior mesenteric veins.

The *nerves* come from the splenic plexus of the sympathetic.

What is the lesser pancreas?

A lobular fold, passing transversely to the left behind the superior mesenteric vessels, which is sometimes detached from the gland when it may open into duodenum by a separate duct an inch or more above the pancreatic duct.

The Ductless Glands.

What are the ductless glands?

The spleen, suprarenal capsules, thyroid and thymus glands, bodies whose functions are uncertain and which have no ducts.

The spleen and suprarenal capsules lie in the abdominal cavity, but the others will be for convenience described after them.

The Spleen¹⁰ (Fig. 85).

Describe it.

It is a soft, brittle, very vascular, oblong, flattened organ embracing the cardiac end of the stomach, to which it is attached by the gastro-splenic fold of peritoneum, which latter membrane completely invests the spleen, except where the gastro-splenic

omentum and suspensory ligament are attached; the organ lies deeply in the left hypochondriac region; the

Outer surface is convex, smooth, lying in contact with diaphragm, which separates it from the ninth, tenth, and eleventh ribs; the

Inner surface is concave, lies in contact with stomach, and presents the

Hilum, a vertical fissure pierced at various points by bloodvessels, lymphatics, and nerves; the

Anterior border is often notched, and the

Posterior border is rounded and in relation with left kidney; the

Suspensory ligament, a peritoneal fold, connects it with the under surface of diaphragm; the

Fibro-elastic coat, beneath the serous (see above) which intimately adheres to it, forms the framework of the spleen, passing inward at the hilum with the vessels as sheaths, from which, and the inner surface of capsule, numerous bands or *trabeculae* pass, uniting to form numerous small spaces or *areolae* filled with the splenic pulp.

Describe the spleen-pulp.

It is of a dark reddish-brown color, and under the microscope is seen to consist of a network of branched connective-tissue cells, containing pigment granules (broken-down blood corpuscles), granular matter, nucleated cells, free nuclei, and red blood-cells in all stages of disintegration; the

*Splenic artery*²⁰ (Fig. 85) is large, tortuous, and divides at hilum into five or six branches which do not anastomose to any extent, each branch breaking up again and again into smaller ones, until they terminate in bundles of straight vessels which open into the interstices of the reticulum formed by the branched connective-tissue cells.

What are the Malpighian bodies?

Small, rounded, expanded masses of the lymphoid tissue of the external coat of the small splenic arteries, from one-one hundredth to one twenty-fifth of an inch in diameter, usually surrounding the vessel, but sometimes projecting from one side; they are composed of a delicate reticulum packed with lymph corpuscles and pervaded by capillaries; the

Splenic vein arises from the *lacunar* spaces in the pulp, and empties into the portal vein; the

Nerves are derived from the right pneumogastric nerve and the right and left semilunar ganglia.

The Thyroid Gland.

Describe it.

It consists of two lateral lobes situated at the sides of the upper portion of the trachea, connected about their lower thirds by a narrow transverse portion, the *isthmus*, which is occasionally absent. A third lobe, the *pyramid*, sometimes springs from the left upper side of isthmus, or the left lobe, and extends to hyoid bone; it is at times detached; occasionally a slender muscular band—the *levator glandulæ thyroideæ*—extends from hyoid bone to isthmus or the pyramid. Structurally, the gland consists of a connective-tissue capsule, sending in septa subdividing the organ into lobes, each of which is formed of numerous closed vesicles filled with a viscid yellowish fluid embedded in connective tissue containing a dense vascular plexus surrounding the vesicles.

What arteries supply this gland?

The *superior* and *inferior thyroid* branches respectively of external carotid and thyroid axis, and at times the *middle thyroid*, or *thyroideæ ima*, springing either from the innominate artery or aortic arch, itself to pass up on the front of the trachea. These vessels are remarkable for their size and frequent anastomoses. (For description of those vessels, see pages 159 and 161.)

Describe the veins of the thyroid gland

They form a plexus on the surface of the gland, whence arise the

<i>Superior thyroid vein,</i>	} Emptying into internal jugular vein.
<i>Middle thyroid vein,</i>	
<i>Inferior thyroid vein</i> opening into innominate vein.	

Name the nerves.

Branches of the pneumogastric nerves and of middle and inferior cervical ganglia.

The Thymus Gland.

Describe it.

This is a temporary organ of unknown function, reaching its full development at the end of the second year, after which it gradually atrophies, having nearly disappeared at puberty. When fully developed it extends from fourth costal cartilage to lower border of thyroid gland, consisting of two lateral lobes in close contact along the middle line, while sometimes an intermediate lobe exists; the sternum and origins of the sterno-hyoid and sterno-thyroid muscles cover it, as it lies in the neck behind these muscles upon front and sides of trachea; it rests, in the mediastinum, upon the pericardium, the thoracic fascia separating it from the aortic arch and great vessels. Its dimensions are: length, two inches, breadth, one and a half inches, thickness, three to four lines; at birth it weighs about half an ounce.

Describe its structure.

It is formed of numerous lobules bound together by delicate areolar tissue, all being inclosed by a fibrous capsule; the lobules are composed of a *cortical* lymphoid tissue, and a *medullary* portion containing a few lymphoid cells, but toward the centre granular cells and concentric corpuscles exist. Each follicle is surrounded with a capillary plexus.

Describe the arterial and nerve supply.

The *arteries* are derived from internal mammary, and superior and inferior thyroid.

The *veins* empty into thyroid and left innominate veins.

The *lymphatics* arise in the substance of the gland, and are said to empty into internal jugular vein.

The *nerves* are very minute, coming from pneumogastric and sympathetic.

The Suprarenal Capsules.

What are they ?

Two triangular or semilunar flattened bodies, situated behind peritoneum, immediately in front of upper part of each kidney.

They consist of a thin, closely adherent *fibrous capsule*, which sends numerous communicating partitions inward, a *cortical* and *medullary portion*, the former containing groups of finely granular polyhedral cells, with a channel between them and the fibrous portions, believed to be a lymph sinus; the *medullary portion* is formed of stout connective-tissue bundles, between which lie coarsely granular columnar and branched cells, which have been thought to communicate with the nerve fibres of the very fine plexus found in the medulla.

What parts do these organs lie in contact with ?

The lower concave border rests upon upper end of kidney; their anterior surfaces touch respectively the under surface of liver, pancreas, and spleen; their posterior surfaces lie upon crura of diaphragm, opposite tenth dorsal vertebra, and their inner margin is related to the great splanchnic nerves and semilunar ganglia, on the right side touching vena cava, on left aorta.

Name its vessels and nerves.

The *arteries* are the suprarenal and branches of inferior phrenic and renal arteries forming a dense capillary network in its interior; the

Veins return blood from the medullary venous plexus by suprarenal veins into inferior vena cava on right side, and on left into renal vein; the

Nerves are very numerous, chiefly distributed to medulla, and are derived from solar and renal plexuses and phrenic and pneumogastric nerves, having developed upon them numerous small ganglia, whence the opinion held by some that these bodies belong to the sympathetic nervous system.

The Abdominal Cavity.

What is the abdomen ?

An ovoidal cavity, limited above by the thorax, below by the brim of pelvis; in front and at sides, by lower ribs, abdominal muscles, and venter illi; behind, by spine, psoas, and quadratus lumborum muscles; it is lined with peritoneum—a serous mem-

brane—which is reflected to form partial or complete investments for the contained organs or *viscera*.

Name the abdominal viscera.

Stomach,	Intestines,
Liver,	Gall-bladder,
Spleen,	Pancreas,
Kidneys,	Suprarenal capsules,
Bladder (when full),	Abdominal aorta,
Uterus (during pregnancy),	Inferior vena cava,
Receptaculum chyli,	Thoracic duct.

Describe the openings in its walls.

They are the

Umbilical, for *fœtal* umbilical vessels, obliterated after birth, leaving a depression, the *umbilicus*.

Opening for inferior vena cava, in diaphragm.

Aortic opening, behind diaphragm between *crura*, for aorta, vena *azygos major*, thoracic duct, and sometimes left sympathetic nerve.

Œsophageal opening, in diaphragm for *œsophagus* and pneumogastric nerves.

Internal abdominal ring, on each side, for spermatic cord in male, round ligament in female.

Femoral, or *crural ring*, on each side, below Poupart's ligament, for femoral vessels.

Into what regions is the abdomen artificially divided ?

Into nine, by two imaginary parallel lines encircling the body on a level with ninth costal cartilages and summits of iliac crests, and two other parallel lines drawn from the cartilage of the eighth rib on each side to the centre of Poupart's ligament.

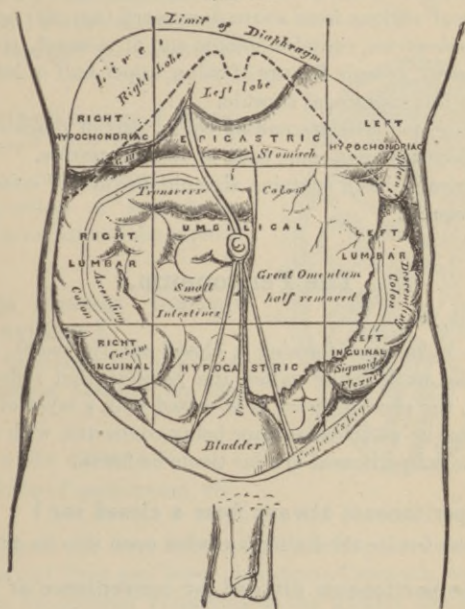
What are these regions named, and what does each contain ?

The right lateral are, from above downward (see cut), the

Right hypochondriac, which contains right lobe of liver, gall-bladder, hepatic flexure of colon, upper part of right kidney, and part of right suprarenal capsule.

Right lumbar, contains ascending colon, lower part of right kidney, and some coils of small intestine.

FIG. 89.



Right inguinal (iliac), contains cæcum and appendix vermiformis, ureter, spermatic vessels.

The median regions are, from above downward (see cut); the

Epigastric, contains middle and pyloric end of stomach, left lobe of liver, lobulus Spigelii, pancreas, duodenum, parts of kidneys and suprarenal capsules, aorta and branches, vena cava, semilunar ganglia, thoracic duct.

Umbilical, contains transverse colon, part of great omentum and mesentery, transverse portion of duodenum, and some coils of jejunum and ileum, part of both kidneys, and the receptaculum chyli.

Hypogastric, contains coils of small intestine, the bladder in children, or when distended in adults, and the uterus during latter six months of pregnancy, often cæcum, appendix vermiformis, and sigmoid flexure of colon.

Left lateral regions from above downward (see cut) are,

Left hypochondriac, contains splenic end of stomach, spleen, and tail of pancreas, splenic flexure of colon, upper half of left kidney, and part of left suprarenal capsule.

Left lumbar, contains descending colon, part of omentum, lower part of left kidney, and some coils of small intestine.

Left inguinal (iliac), contains sigmoid flexure of colon, ureter, spermatic vessels.

The Peritoneum.

Describe it.

A serous membrane forming a closed sac (in *male*), the layer covering the walls being called the *parietal*, that reflected over the viscera, the *visceral* layer; it is coated with a layer of flattened endothelium, its attached surface being connected with subjacent parts by the subperitoneal areolar tissue or fascia.

Does the peritoneum always form a closed sac?

No; in the female the Fallopian tubes open into its cavity.

How is the peritoneum divided for convenience of description?

Into the *greater sac*¹⁵, or that covering upper anterior portion of liver⁵, the stomach⁶ behind and above, descending to ileum forming the anterior layer of great omentum¹⁶, the under surface of mesocolon²⁰, the mesentery²¹, and reflections²³ upon and between the rectum¹¹, uterus in female²², and bladder¹³, then lining the antero-lateral abdominal walls to reach, from the under surface of diaphragm¹⁷, the upper surface of liver, the starting-point of this description (see Fig. 90).

The *lesser sac*, or *cavity of the great omentum*¹⁶, starting from diaphragm behind, this layer passes over back of liver¹⁸, then

covers back and under side of stomach⁶, forms the inner layer of great omentum¹⁶, passes over colón⁷ completing meso-colon²⁰, and thence passes over duodenum⁹ and pancreas¹⁰ to line the posterior abdominal wall, reaching the point started from; the two cavities communicate through the foramen of Winslow.

Describe the foramen of Winslow¹⁸ (Fig. 90).

It is an opening at the constricted portion of peritoneum where it curves around the hepatic vessels.

Does this foramen transmit anything?

No; it is merely the orifice of communication between the two sacs.

What are the omenta?

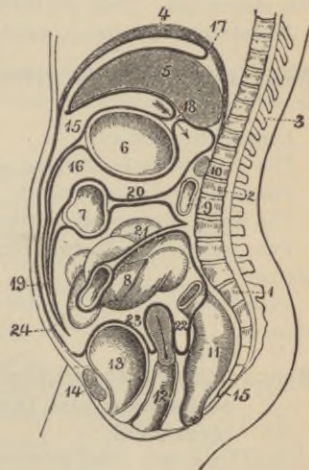
Three folds of peritoneum, viz., the

Gastro-hepatic, or lesser omentum¹⁸, extending between the transverse fissure of liver and lesser curvature of stomach, consisting of two layers, the anterior pertaining to the greater, the posterior to the lesser sac, which enfold at the right free border the *hepatic artery, common bile-duct, portal vein, lymphatics, and hepatic nerve plexus*.

The *great, or gastro-colic omentum¹⁹*, is formed of four layers, two descending, one from the anterior, the other from posterior wall of stomach, and uniting below to pass as low as pelvis, when they ascend to transverse colon, separate and embrace this part of the bowel; the

Gastro-splenic omentum is the fold connecting spleen with stomach, contains the splenic vessels and vasa brevia, and is continuous below with the great omentum.

FIG. 90.



What are the mesenteries ?

Double layers of peritoneum embracing various portions of intestinal tube (except duodenum), which they suspend from posterior abdominal walls; between the folds run the vessels of the part suspended. They are called, the

*Mesentery*²¹, *meso-cæcum*, *meso-colon*²⁰, *meso-rectum*.

What other name is given to suspensory folds of peritoneum ?

Ligaments, such as,

The *gastro-phrenic*, slinging stomach from diaphragm.

The *longitudinal*, *two lateral*¹⁷, and *coronary* ligaments of liver.

The *vesical*, five so-called false ligaments.

Two *vesico-uterine*²³, two *recto-uterine*²², two *broad ligaments* of uterus.

Suspensory ligament of spleen connecting this organ with diaphragm.

Mention the viscera wholly⁽¹⁾ and partially⁽²⁾ covered with peritoneum and those totally deficient⁽³⁾ in such investment.

(1) The *spleen*, *small intestine*⁸, *cæcum*, *transverse colon*⁷, *sigmoid flexure*, *ovaries*, *uterus*, *stomach*⁶ and *liver*⁵ practically, *duodenum* (first part), *rectum*¹¹ (upper third).

(2) *Duodenum*⁹ (descending and transverse),
Ascending colon,
Descending colon,

Rectum (middle third¹¹),
*Vagina*¹² (upper part),
*Bladder*¹³ (posterior surface).

(3) *Rectum*¹¹ (lower third),
*Bladder*¹³ (base, anterior surface),
Vagina (lower portion).

*Pancreas*¹⁰,
Kidneys,
Suprarenal capsules,

ORGANS OF VOICE AND RESPIRATION.

The Larynx.

What is the larynx¹ (Fig. 92)?

The voice-organ, formed of cartilages united by ligaments, the segments enjoying movement upon one another, which is effected by numerous muscles.

Mention the component cartilages.

They are nine in number, being the

*Thyroid cartilage*¹,

Two arytenoid cartilages,¹

*Cricoid cartilage*⁵,

Two cuneiform cartilages,

Epiglottis,

Two cornicula laryngis.

Describe the thyroid (shield-like) cartilage.

It consists of two *alæ*², or lamellæ, united at an acute angle in front, forming a vertical ridge¹, whose more prominent upper portion is called the *pomum Adami*³, or Adam's apple; the

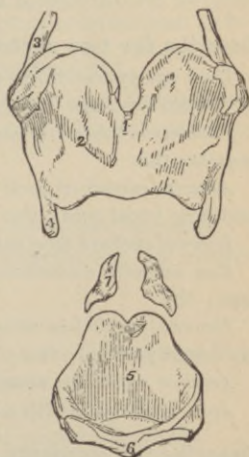
Inner surfaces of the *alæ* are smooth, giving attachment in front, at the receding angle formed by their junction, to epiglottis, true and false vocal cords, thyro-arytenoid and thyro-epiglottidean muscles.

The *outer surface* affords attachment along an oblique ridge to sterno-thyroid and thyro-hyoid muscles, below and behind to inferior constrictor muscle.

The *upper border* presents a deep, medium notch¹, and is slightly concave on either side.

The *lower border* is connected medianly with cricoid cartilage by crico-thyroid membrane, and on each side by crico-thyroid muscle.

FIG. 91.



The *posterior* borders are thick, rounded, and terminate above and below on each side in *cornua*, the two *superior*³ having attached to their apices the thyro-hyoid ligament, while the *inferior*⁴ articulate internally by an oval facet with cricoid cartilage; to this border are also attached the stylo-pharyngeus and palato-pharyngeus muscles.

Describe the cricoid (ring-like) cartilage.

It is placed with its narrow portion⁶ in front, and has on each side two articular facets, one on upper margin behind for arytenoid cartilages, one externally, near lower margin for inferior cornu of thyroid cartilage.

The *upper border* gives attachment in front and at sides to crico-thyroid membrane, at sides to lateral crico-arytenoid muscles.

The *lower border* is connected with first tracheal ring by a fibrous membrane.

The *posterior surface* presents a median vertical *ridge* for attachment of longitudinal fibres of œsophagus, and on either side the posterior crico-arytenoid muscles are attached.

Describe the two arytenoid (pitcher-like) cartilages⁷.

They are pyramidal in form, and are placed at the upper border of cricoid cartilage at back of larynx; the

Posterior surface of each affords attachment to arytenoideus muscle; the

Anterior surface of each has attached the thyro-arytenoid muscle and false vocal cord; the

Internal surfaces face each other; the

Base presents a concave, smooth, articular facet for cricoid cartilage; the

External angle has attached to it the posterior and lateral crico-arytenoid muscles; the

Anterior angle has attached to it true vocal cord; the

Apex articulates with a corniculum laryngis.

Describe the cornicula laryngis.

They are two small conical cartilaginous nodules surmounting the apices of arytenoid cartilages affording attachment to aryteno-epiglottidean folds.

Describe the two cuneiform cartilages.

They are elongated cartilages contained in free borders of aryteno-epiglottidean folds.

Describe the epiglottis.

It is a thin, leaf-shaped lamella of *fibro-cartilage*, attached by apex to reëntering angle of thyroid cartilage just below median notch; it lies at base of tongue, in front of upper opening of larynx, and during deglutition shuts like a lid over laryngeal orifice. Its

Base is free, rounded, curving forward toward base of tongue; the

Apex is attached to receding angle of thyroid by thyro-epiglottic ligament; the

Anterior surface is covered with mucous membrane reflected on to sides and base of tongue, forming the three glosso-epiglottidean ligaments; the

Posterior surface shuts down over laryngeal opening during deglutition; the

Lateral margins give attachment to aryteno-epiglottidean folds.

How are the ligaments of the larynx divided?

Into *extrinsic*, or those connecting thyroid cartilage and epiglottis with hyoid bone; and *intrinsic*, those binding the various cartilages together.

Name the extrinsic ligaments.

Thyro-hyoid membrane, *Two lateral thyro-hyoid ligaments*, containing a small cartilaginous or bony nodule, the *cartilago triticea*; *Hyo-epiglottic*.

Name the intrinsic ligaments.

<i>Crico-thyroid membrane</i> ,	<i>Two inferior thyro-arytenoid ligaments</i> ,
<i>Two crico-thyroid capsular ligaments</i> ,	<i>Hyo-epiglottic ligament</i> ,
<i>Two crico-arytenoid ligaments</i> ,	<i>Thyro-epiglottic ligament</i> ,
<i>Two crico-arytenoid capsular ligaments</i> ,	<i>Three glosso-epiglottic folds</i> ,
	<i>Two superior thyro-arytenoid ligaments</i> .

What are the vocal cords?

The *superior* or *false vocal cords*, on each side, are two folds of mucous membrane enclosing the superior thyro-arytenoid ligaments composed of elastic tissue, stretching between angle of thyroid cartilage below epiglottis and anterior surfaces of arytenoid cartilages; the lower margin forms the upper free crescentic margin of ventricle of larynx.

The *true*, or *inferior vocal cords*, are two strong, yellow elastic fibrous tissue bands, the inferior thyro-arytenoid ligaments, covered by thin, tightly adherent mucous membrane, which pass from the receding angle of the thyroid to anterior angles of arytenoid cartilages, the upper border forming the lower margin of ventricle of larynx, the lower continuous with lateral portion of crico-thyroid membrane; each has the thyro-arytenoid muscle lying parallel externally; these cords or membranes produce sound by their vibrations, the false cords do not, although indirectly influencing vocalization.

What is the glottis (rima glottidis)?

It is the narrow triangular interval between the true vocal cords; it measures, in males, somewhat less than an inch, by from one-third to one-half inch at its base *behind*, when dilated.

Describe the ventricle of the larynx.

It consists of an oval depression or *sinus* on each side, between the true and false vocal cords leading upward, external to superior cord, into a cæcal pouch, the *sacculus laryngis*.

Describe the sacculus laryngis.

It is a slightly curved conical membranous sac, situated between the inner surface of thyroid cartilage and false vocal cords on each side; internally lined with mucous membrane, perforated by orifices of ducts of sixty to seventy follicular glands lying in the submucous tissue; it is strengthened externally by a fibrous capsule continuous below with superior thyro-arytenoid ligament, and has its inner (laryngeal) surface covered by the inferior thyro-arytenoideus, and its external by thyro-epiglottideus muscles, which compress the sacculus, discharging the mucus upon, and for the lubrication of the vocal cords.

What kind of epithelium has the mucous membrane?

Above the false vocal cords squamous epithelium is found, except in front, which is covered by ciliated columnar cells as high as middle of epiglottis; below the false cords, only ciliated columnar epithelium is found.

Describe the muscles of the larynx and epiglottis.

*Crico-thyroid*² (2) (Fig. 92): *origin*, triangular from antero-lateral surface of cricoid cartilage; *insertion*, lower border of thyroid and anterior border of lower cornu; *action*, increases tension of vocal cords by tilting thyroid cartilage forward; *nerve*, superior laryngeal.

Crico-arytenoideus posticus (2): *origin*, lateral half of posterior surface of cricoid; *insertion*, outer angle of base of arytenoid cartilage; *action*, by rotating arytenoid cartilages outward it opens glottis and tightens cords; *nerve*, recurrent laryngeal.

Crico-arytenoideus lateralis (2): *origin*, upper border of side of cricoid; *insertion*, outer angle of base of arytenoid; *action*, by rotating arytenoids inward closes glottis; *nerve*, recurrent laryngeal.

Thyro-arytenoideus (2): *origin*, lower half of receding angle of thyroid and crico-thyroid membrane; *insertion*, base and front surface of arytenoid cartilage; *action*, advances arytenoid and cricoid cartilages thus relaxing vocal cords, also compresses sacculus laryngis; *nerve*, recurrent laryngeal.

Arytenoideus (1): *origin*, back surface and outer border of one arytenoid to be *inserted* at same part of other cartilage; *action*, approximates arytenoids closing back of glottis; *nerves*, superior and recurrent laryngeal.

Kerato-cricoideus: a small muscular bundle; *origin*, from near lower border of cricoid cartilage; *insertion*, inferior cornu of thyroid cartilage; *action*, possibly steadies one cartilage upon the other, only occasionally found, and usually on one side.

Triticeo-glossus: *origin*, cartilage of same name in lateral thyrohyoid ligament; *insertion*, tongue with hyo-glossus muscle; occurs on one or both sides; *action*, unknown.

Describe the muscles of the epiglottis.

Thyro-epiglottideus: *origin*, inner surface of thyroid cartilage; *insertion*, aryteno-epiglottidean fold, margin of epiglottis, outer sur-

face of sacculus laryngis; *action*, depresses epiglottis; *nerve*, recurrent laryngeal.

Aryteno-epiglottideus superior: *origin*, apex of arytenoid cartilage; *insertion*, aryteno-epiglottidean folds; *action*, narrows upper laryngeal orifice; *nerve*, recurrent laryngeal.

Aryteno-epiglottideus inferior: *origin*, arytenoid cartilage above superior vocal cord; *insertion*, inner upper part of epiglottis; *action*, compresses sacculus laryngis; *nerve*, recurrent laryngeal.

Mention the arteries and veins of the larynx.

The *arteries*, are laryngeal branches of superior and inferior thyroid arteries, which inosculate freely; the

Veins, empty into superior, middle, and inferior thyroid veins.

What nerves supply the larynx?

The *superior*, and *inferior* or *recurrent laryngeal*, branches of pneumogastric, the former receiving branches from spinal accessory and superior cardiac sympathetic nerves; the

Superior laryngeal is chiefly a nerve of sensation, supplying laryngeal mucous membrane and arytenoid muscles by its *internal laryngeal* branch, after piercing the thyro-hyoid membrane; and the *crico-thyroid muscle* by its *external laryngeal* branch; the

Recurrent laryngeal is the motor nerve supplying all the laryngeal muscles except *crico-thyroid*; the right nerve descends the neck to pass from before backward around the subclavian artery, the left winds in the same direction around the aortic arch, and both nerves ascend in groove between trachea and œsophagus to their distribution, giving off in their course cardiac, œsophageal, tracheal, and pharyngeal branches, and anastomosing with superior laryngeal nerves.

The Trachea and Bronchi.

What is the trachea^s (Fig. 92)?

It is a membranous, cylindrical air-tube, flattened posteriorly, of a transverse diameter of three-quarters to one inch, extending from lower part of larynx (corresponding to sixth cervical vertebra), to opposite fourth or fifth dorsal vertebra, where it bifurcates to form the

Right and left bronchus; it is composed of sixteen to twenty imperfect cartilaginous rings surrounding two-thirds of the cylinder, enclosed in a double elastic fibrous membrane connecting the rings with one another, while the space behind has, in addition to the membrane—there forming a single layer—a layer of longitudinal and another of transverse unstriped muscular fibres, the transverse lying beneath the fibrous membrane called the *trachealis muscle*; the last ring, by a triangular hooked-process curving backward between the bronchi, forms two imperfect rings on either side for right and left bronchus; the lining mucous membrane contains much lymphoid tissue and numerous glands, and is covered by several layers of epithelium, the most superficial columnar ciliated.

Give the relations of the trachea in the neck.

It is covered in *front* from above downward by

Anastomosing branches	<i>Posteriorly, it lies upon</i>
between jugular veins,	Œsophagus,
Isthmus of thyroid gland	<i>Laterally, lie</i>
Inferior thyroid veins,	The common carotid
Arteria thyroidea ima	arteries ¹³ ,
(when present),	Lobes of thyroid gland,
Sterno-hyoid muscle,	Inferior thyroid arteries,
Stero-thyroid muscle,	Recurrent laryngeal nerves.

Describe its relations in the thorax.

It is *covered* from before backward by

Manubrium of sternum,	<i>Posteriorly, lies the</i>
Remains of thymus gland,	Œsophagus,
Left innominate vein,	<i>Laterally, on each side, the</i>
Arch of aorta,	Pneumogastric nerves,
Innominate artery,	
Left carotid artery ¹² ,	
Deep cardiac plexus.	

What are the bronchi?

Two tubes, structurally like trachea, extending from its bifurcation into the lungs, dividing and subdividing to form the bronchial tubes, in whose walls only scattered cartilaginous plates exist until the diameter of one-fourth of a line is reached, when

they become wholly membranous, while the muscular coat and elastic fibrous coat then form a continuous circular layer around the smallest tubes; the mucous membrane is covered with ciliated columnar epithelium; the

Right bronchus is wider, shorter (about one inch long), and more horizontal than left; the

Left bronchus is smaller, more oblique, and longer (nearly two inches).

Describe the relations of each bronchus.

The *right*, beginning opposite fourth dorsal, enters lung opposite fifth dorsal vertebra, lying behind superior vena cava and right auricle of heart, having the right pulmonary artery at first below, then anterior to it, and the vena azygos major arching over it from behind.

The *left bronchus*, commencing at same point as right, passes in front of œsophagus, thoracic duct, and descending aorta beneath the aortic arch, the left pulmonary artery lying at first above, then in front of it to enter lung opposite sixth dorsal vertebra.

What vessels and nerves supply trachea and bronchi?

The *arteries* are tracheal branches of inferior thyroid arteries and bronchials from aorta; the

Veins empty into thyroid plexus and bronchial veins; the

Lymphatics empty into mediastinal glands; the

Nerves are branches from pneumogastric, recurrent laryngeal branch of same, and sympathetic nerve.

The Lungs.

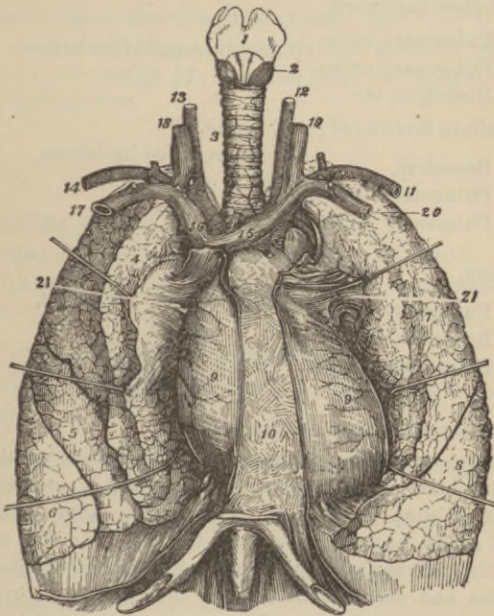
Describe them.

They are the two organs of respiration, occupying the greater part of the thoracic cavity, separated by the heart and other contents of the mediastinum, covered by the pleuræ, of a specific gravity of 0.345 to 0.746, weighing together about forty-two ounces, the right being the heavier by two ounces. They are pinkish-white at birth, but irregularly marked by slate-colored patches as age advances from the deposit of carbonaceous matter, or perhaps altered blood-pigment, in the lung tissue; they are divided into

lobes, the right lung having three^{4,5,6}, the left only two^{7,8}; each lung has an

Apex, extending into root of neck beneath and above first rib, about one to one and a half inches, where it is in contact with first and second part of subclavian artery; the

FIG. 92.



Base is broad and concave, resting upon diaphragm, its thin margins extending lower down externally and behind than in front; the

External surface is smooth, convex, marked by the interlobular fissures, and conforms to the shape of the thorax; the

Inner surface is concave, and the left lung presents a depression in front for heart; behind, each has a deep fissure, the *hilum pulmonis*, the point of attachment of root of lung; the

*Root*²¹ is the point of entrance of bronchus, pulmonary and bronchial arteries, and of exit of the pulmonary and bronchial veins and lymphatics; in front of each lies the phrenic nerve and anterior pulmonary plexus, behind, the pneumogastric and posterior pulmonary plexus.

In what order are these various structures arranged?

From before backward,

Pulmonary veins,	} may be recalled by letters,
Pulmonary artery,	
Bronchus, etc.	
	V, A, B.

From above downward; right lung,

Bronchus,	} to be recalled by letters,
Pulmonary artery,	
Pulmonary veins.	
	B,
	A,
	V.

Left lung,

Pulmonary artery,	} to be recalled by letters,
Bronchus, etc.,	
Pulmonary veins.	
	A,
	B,
	V.

Describe the structure of the lung.

They have externally a serous coat, a subserous areolar tissue penetrating between the lobules, and their bulk is composed of the pulmonary substance or parenchyma, which is formed of an aggregation of *lobules*, each composed of a terminal bronchial tube with its air cells, and ramifications of pulmonary and bronchial vessels, lymphatics, and nerves, thus forming a miniature of lung; they are pyramidal and large upon the surface, smaller and irregular in the interior; the *alveoli*, or *air-cells*, are small polyhedral alveolar recesses measuring about one-two-hundredths to one-seventieth of an inch, opening into the sides and ends of the intercellular passages—*i. e.*, the irregular terminations of the bronchioles—separated from one another by delicate membranous septa, between the layers of which lies the plexus formed by the pulmonary artery, thus exposing the blood to air *on two surfaces*; they are lined with a layer of squamous epithelium.

What are the vessels and nerves of the lungs ?

They receive blood by bronchial arteries for their own nutrition, and venous blood by pulmonary artery for aëration, *i. e.*, absorption of oxygen and emission of carbonic dioxide; the vessels are

Bronchial arteries, branches of aorta. *Pulmonary arteries*, from right side of heart. The *bronchial veins* empty on right side into the vena azygos, on the left, into superior intercostal vein; the

Lymphatics empty into bronchial glands; the

Nerves are derived from the anterior and posterior pulmonary plexuses, formed chiefly by branches from the sympathetic and pneumogastric nerves.

The Pleuræ.**What are the pleuræ ?**

Two closed delicate serous sacs, consisting of a portion investing each lung and another lining, respectively, the right and left halves of thorax.

Are the pleuræ in contact internally ?

No, except at one point in front, leaving a space between them elsewhere.

What is the visceral layer (that covering lung) of each pleura called ?

The *pleura pulmonalis*, investing the lung as far as its root.

What is that called which lines the thorax ?

Pleura costalis, or *parietal layer*.

What is the ligamentum latum pulmonis ?

This *broad ligament of the lung* is a triangular fold of the pleura passing downward from lower border of root of lung to diaphragm, retaining lower part of lung in position.

Do the pleural cavities differ from each other ?

Yes, the right is shorter, wider, and extends higher in neck.

What is the mediastinum ?

The median space left between the two pleural sacs, extending from sternum to vertebral column, containing all the thoracic viscera but lungs.

Mention its subdivision, and the contents of each.

The *anterior mediastinum*, bounded in front by sternum, on each side by pleuræ, and behind by pericardium; its contents are

Origins of sterno-hyoid and sterno-thyroid muscles,

Origin of triangularis sterni muscle,

Left internal mammary vessels,

Remains of thymus gland,

Loose areolar tissue containing lymphatics.

The *middle mediastinum* is the broadest portion of interpleural space; its contents are the

Heart enclosed in the pericardium, *Pulmonary artery,*

Ascending aorta, *Pulmonary vein,*

Superior vena cava, *Phrenic nerves.*

Bifurcation of trachea,

The *posterior mediastinum*, bounded in front by pericardium and roots of lungs, behind by spinal column, and laterally by the pleuræ; its contents are the

Descending aorta, *Pneumogastric nerves,*

The greater azygos vein, *Splanchnic nerves,*

The lesser azygos vein, *Œsophagus,*

Left superior intercostal vein, *Thoracic duct,*

Lymphatic glands.

The Urinary Organs.**Where are the kidneys situated ?**

In the lumbar regions, one on each side of the vertebral column each kidney reaching from the eleventh rib nearly to the iliac crest, but the right a little lower than the left; they lie embedded in a mass of fat behind the peritoneum, which retains them in place with the aid of their bloodvessels.

What are their size and weight?

Each measures about four inches in length, two in breadth, and one inch in thickness; they weigh, in the male, from four and a half to six ounces; in the female, four to five and a half ounces.

Describe their relations.

The *Anterior surface of right kidney* is in relation with the right lobe of liver, descending portion of duodenum, and ascending colon.

The *Anterior surface of left kidney*, with great end of stomach, lower end of spleen, tail of pancreas, and descending colon.

The *Posterior surface of each* rests upon crus of diaphragm, the anterior lamellæ of transversalis aponeurosis separating it from quadratus lumborum and psoas magnus.

The *Superior extremity* is embraced by the suprarenal capsule.

What is the hilum of the kidney?

A notch or fissure one inch long at central portion of internal border, opening into a cavity, the *sinus*; through it pass the *lymphatics*; the *renal vein* is in front; the *renal artery*^Δ next, and *ureter*[∪], or excretory duct, behind and below.

Describe the naked-eye appearances of a vertical section of a kidney.

The kidney proper consists of a

*Cortical structure*¹, composed of convoluted and straight uriniferous tubules, bloodvessels, nerves, lymphatics, connective tissue, and Malpighian bodies, and is prolonged down between the pyramids, forming the *columns of Bertin*; a fibrous *capsule* envelops the organ, passes into the sinus which it lines, blending with the sheaths of vessels, nerves, and the calices; the

*Medullary substance*² consists chiefly of straight tubuli uriniferi, "looped tubes of Henle", bloodvessels, etc., arranged in eight to eighteen

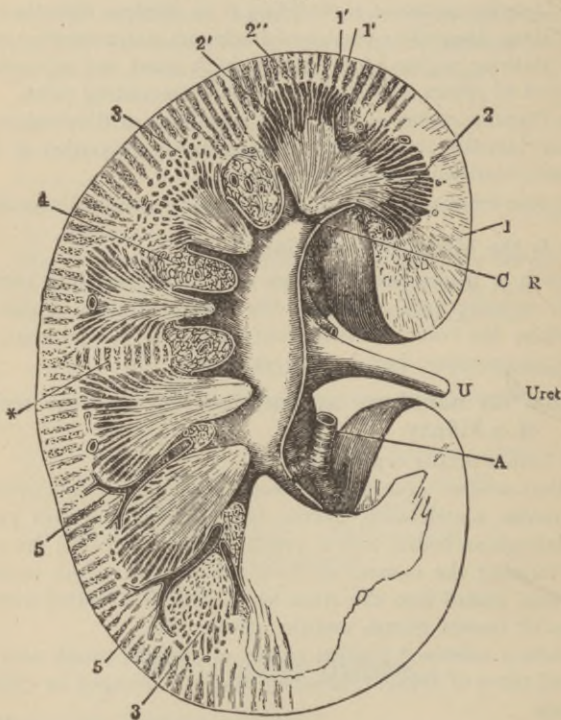
*Pyramids of Malpighi*², whose apices are embraced by the calices of the pelvis; the

Pelvis consists of from seven to eighteen *calices*^c, cup-like tubes, embracing the apices of one or more Malpighian pyramids, converging to form three *infundibula*, these again joining to form the *pelvis*^c, which gradually contracts into the *ureter*[∪] or *excretory duct*.

Describe the tubuli uriniferi¹⁵ (Fig. 94).

They commence in a dilated caecal extremity, the *Malpighian capsule* and terminate by opening on the free surface of the *papillæ*¹⁵. They are called, in various portions of their course, the

FIG. 93.



*Proximal convoluted tube*³, the much convoluted portion after leaving the Malpighian capsule and situated in the cortical portion.

The *spiral tube of Schachow*⁴, next succeeding, where the tube approaches the medullary portion in a spiral manner; now entering the medullary portion, the tubes suddenly become smaller,

quite straight, dipping down into the pyramids to ascend, suddenly enlarge, and again become spiral, and reënter the cortical structure, constituting the descending

*Loop of Henle*⁵, this ascends^{7,8} in an irregular angular manner through the cortex, and terminates in the

Distal convoluted tube^{10,11}, which terminates in a narrow

*Curved tube*¹², continuous with a

Straight, or collecting tube^{13,14}, terminating on summit of one of the papillæ.

Describe these straight tubes^{13,14}.

Traced into pyramids from the papillæ, they run from apex to base, dividing dichotomously, receiving the curved tubes, to enter the cortex much increased in number, where they form conical masses with their bases toward the medullary portion.

What are these conical masses called ?

The pyramids of Ferrein.

Describe the epithelium of the uriniferous tubules.

It varies in different portions, being flattened polyhedral, angular, and columnar.

Describe the Malpighian bodies (tufts, or vascular glomeruli).

Each is formed by a *renal afferent*^a (Fig. 95) *arteriole*, which, after piercing the capsule—a pouch-like commencement of a tubulus uriniferus lined with flattened epithelium^k—breaks up into a tuft of vessels forming a plexus^c, from which arises the *efferent*^e *vessel* emerging from capsule near point of entrance of afferent arteriole.

Describe the renal circulation.

The

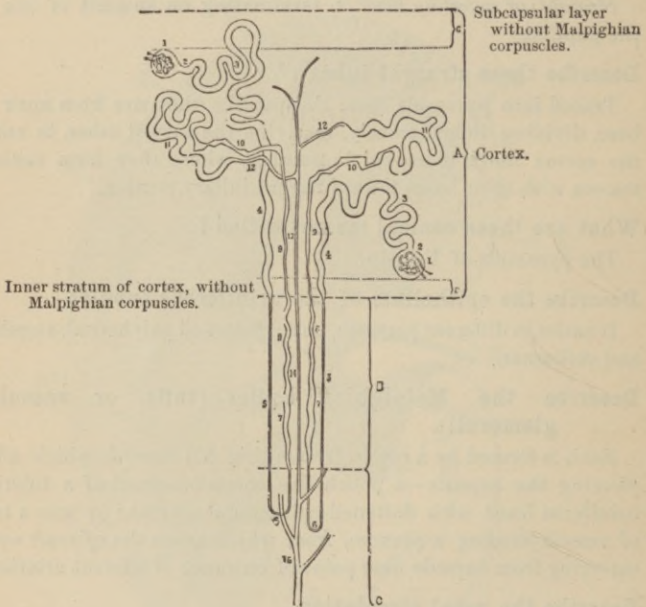
Renal artery, from aorta, divides just external to hilum, into four or five

Primary branches, which divide and subdivide to form

Arteriæ propriæ renales, two of which run along the sides of each Malpighian pyramid, giving off afferent branches to Malpighian bodies in columns, and, bending between bases of pyramids and cortex, send off the (1) interlobular, and (2) arteriolæ rectæ;

(1) *Interlobular arteries*, passing outward between the pyramids of Ferrein to capsule, terminating in stellate plexuses beneath it (*stars of Verheyen*), and also supplying afferent arterioles to Malpighian bodies of cortex, whence issue efferent vessels forming a dense *venous plexus* around adjacent uriniferous tubules; and the

FIG. 94.



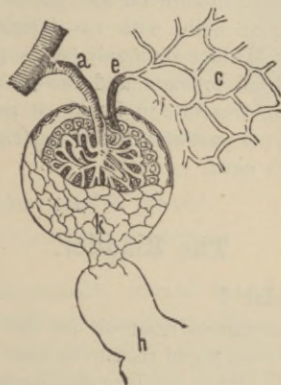
(2) *Arteriolæ rectæ*, or *descending branches*, passing from bases to apices of pyramids, there to terminate in the venous plexuses.

The blood is collected by the *stellate venous plexuses* beneath the capsule, forming *venæ interlobulares*, which pass between pyramids of Ferrein, are joined by branches emptying the plexuses around convoluted tubes of cortex, and join the *venæ rectæ* at bases of Malpighian bodies; these *venæ rectæ* being branches from *plexuses* at apices of medullary pyramids formed by *arteriolæ rectæ*. The

junction of the *venæ rectæ* and *venæ interlobulares* form the *venæ propriæ renales*, accompanying the arteries of the same name, which receive venous twigs from Malpighian bodies of medulla and unite in the sinus to form the

Renal, or *emulgent vein*, which passes out of hilum to empty into inferior vena cava, the right vein being the shorter.

FIG. 95.



Describe the nerves of the kidney.

They are small, fifteen in number, have ganglia developed upon them, and come from the solar plexus, lower and outer part of semilunar ganglia, and from lesser and smallest splanchnic nerves forming the *renal plexus*, communicating with spermatic plexus.

The Ureters.

What is the ureter ?

It is the tubular, cylindrical, excretory duct of the kidney, of the size of a goose-quill, sixteen to eighteen inches long, extending from the pelvis of kidney to base of bladder, into which it opens by a constricted orifice, after having passed obliquely for nearly an inch between its muscular and mucous coats: it has a *fibrous coat* continuous with capsule of kidney and fibrous tissue

of bladder, a *muscular* composed of longitudinal and circular fibres, a *mucous* covered with several layers of many shaped epithelial cells.

Describe its course and relations.

It passes obliquely downward along posterior abdominal wall beneath the peritoneum, over the iliac arteries, behind ilium on *right side*, and sigmoid flexure on *left*, enters the posterior false ligament of bladder in male, with vas deferens between it and bladder, and enters bladder obliquely (see supra) about one and one-half inches behind prostate, and two inches from its fellow, at posterior angle of trigone; in female it passes along sides of cervix uteri and upper part of vagina; the right ureter lies close to outer side of vena cava.

The Bladder.

What is the bladder¹?

The musculo-membranous reservoir for the urine, situated behind the pubes, between it and rectum in male, between the pubes and uterus in female; when moderately distended its dimensions are, length five inches, breadth three inches, capacity about one pint; in the child it is an abdominal organ, and also in adults *when distended*. It presents for examination, the

*Summit*¹⁰ (Fig. 98), connected with umbilicus by a fibro-muscular cord, the *urachus*, and by two fibrous cords placed on either side, the obliterated fetal hypogastric arteries; the

Body lies against posterior surface of pubes, triangular ligament, internal obturator muscles, and—when distended—abdominal walls, its posterior surface being covered by peritoneum, having some coils of small intestine interposed between it and rectum, and uterus in female; the obliterated hypogastric arteries cross its sides obliquely from below, upward and forward, all below them being uncovered with peritoneum; the vas deferens curves from before backward along each side to reach the base of bladder passing across the obliterated hypogastric vessels and along inner side of ureter; the

Fundus, or *base*¹¹ (Fig. 98), is directed downward and backward, resting in the male upon the second portion of rectum, in the female upon lower part of cervix uteri, being adherent to upper part of vagina, but separated from cervix by a fold of peritoneum which is reflected so as to cover a small portion of base; in male the peritoneum passes from rectum to same portion of base; the

Neck, or *cervix*¹² (Fig. 98), is the constricted portion continuous with urethra, surrounded in male by prostate gland, and is directed downward and forward.

How is the bladder held in place?

By *true* and *false ligaments*; the true, being the

Anterior, or *pubo-prostatic*, formed by two folds of the rectovesical fascia extending from either side of pubic symphysis to front of cervix over upper surface of prostate gland; the

Lateral, of same tissue, passing between lateral surfaces of prostate gland on each side, and sides of base of bladder; the

*Urachus*²² (Fig. 98), a fibro-muscular cord covered with peritoneum, stretching between apex of bladder and umbilicus.

The false ligaments are,

Two Posterior, folds of peritoneum passing, in male from sides of rectum, in female from sides of uterus, to postero-lateral aspect of bladder, and contain the obliterated hypogastric arteries, the ureters, vessels, and nerves.

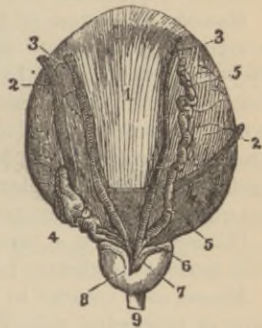
Two lateral, peritoneal folds passing from iliac fossa to sides of bladder.

*Superior*²³ (Fig. 98), a peritoneal fold passing over urachus and obliterated hypogastric arteries from apex of bladder to umbilicus.

What is the urachus²² (Fig. 98)?

The remains of a tubular canal connecting bladder with allantois in *fœtus*.

FIG. 96.



Describe the structure of the bladder.

It has four coats, viz., a

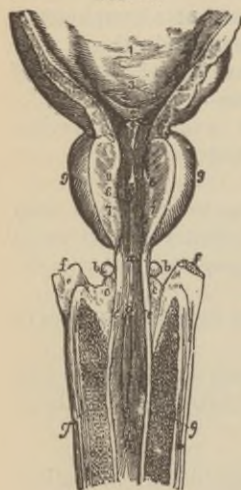Peritoneal^{23, 24} (Fig. 98), covering posterior surface from entrance of ureters at base to its summit, passing on to sides whence it is reflected to abdominal and pelvic walls: a

Muscular, consisting of fibres spirally arranged forming figure of eight loops, the more superficial being nearly *longitudinal*, the deeper nearly *circular*, corresponding to same-named layers of older authors; these form seven more or less distinctly marked layers, the loops directed toward, and embracing the urachus and urethra respectively, the aggregation of these loops around the neck forming the sphincter and the fibres passing in all directions are continued into prostatic urethra (Pettigrew): a

Cellular, which is a layer of areolar tissue intimately blended with mucous membranes binding it to the muscular coat; a

Mucous coat, covered by transitional epithelium, the superficial layer of polyhedral cells, below club-shaped and smaller spindle-celled: it contains a few mucous follicles and numerous racemose glands lined with columnar epithelium near the neck; it is thrown into folds or *rugæ* when bladder is empty.

FIG. 97.

**What are the muscles of the ureters?**

Two oblique bands rising behind the orifices of the ureters which converge, to be inserted by a fibrous process into the middle lobe of prostate gland.

What is the trigonum vesicæ or trigone vesical² (Fig. 97)?

A triangular smooth surface at base of bladder, with apex forward, of a paler color than remainder of mucous membrane, which is intimately adherent to subjacent tissues: the

Lateral boundaries are two slightly marked ridges on each side passing backward and outward from

the apex formed by urethral opening to orifices of ureters³, corresponding to the muscles of these ducts, the openings being placed about two inches from one another and one and a half inches behind urethral opening, a line connecting the two forming the *base of the trigone*.

What is the uvula vesicæ⁴ (Fig. 97)?

A slight elevation of the mucous membrane projecting from lower anterior portion of floor of bladder into orifice of urethra.

Mention the arteries supplying the bladder.

Superior, middle and inferior vesical, and small twigs from *obturator and sciatic arteries* in male, with additional branches from *uterine and vaginal*, in female: the *veins* form intricate plexuses around neck, sides, and base, emptying into internal iliac vein; the *lymphatics* accompany the vessels.

Give the nerve-supply of the bladder.

Branches from hypogastric plexus of sympathetic supply upper part, and the third and fourth sacral nerves the base and neck.

The Male Urethra.

Describe this canal.

It extends from neck of bladder⁴ to meatus urinarius, measuring from eight to nine inches, presenting a double curve when penis is flaccid, but a single one with convexity downward during erection.

Name and describe each of its divisions.

They are the prostatic^{7,8}, membranous, and spongy.

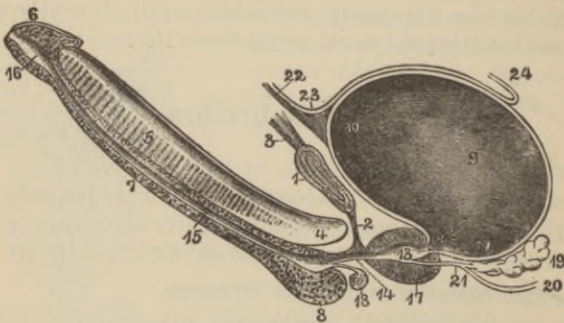
The *prostatic portion*^{7,8} (Fig. 97) is that portion passing from base to apex of prostate gland, running nearer the upper surface, measuring one and a quarter inches long, is the widest and most dilatable section of urethra and is spindle-shaped; upon the median aspect of the floor is a narrow longitudinal ridge eight to nine lines long, the *verumontanum* or *caput gallinaginis*⁵ (Fig. 97) containing muscular and erectile tissue: on either side is a slight fossa, its floor presenting the numerous openings of the prostatic ducts, called the *prostatic sinus*.

The *sinus pocularis*, or *uterus masculinus*⁶ (Fig. 97), is a depression extending about a quarter of an inch upward and backward beneath middle lobe of prostate in the median line at fore part of verumontanum, upon or within whose margins are the slit-like orifices of the *seminal or ejaculatory ducts*⁸ (Fig. 97).

The *membranous portion*^a (Fig. 97) is that portion, three-quarters of an inch long, extending between apex of prostate and bulb of corpus spongiosum, which is included between the layers of the triangular ligament about one inch beneath the pubic arch; it is surrounded by the compressor urethræ muscle, and is the narrowest portion of urethra, except meatus.

The *spongy portion*^{d, h} (Fig. 97) is the longest measuring about six inches, is so called from being contained in the corpus spongiosum, extends from membranous portion to meatus urinarius, and presents a posterior dilatation, that of the bulb⁸ (Fig. 98), and one

FIG. 98.



anterior, the *fossa navicularis*¹⁶ (Fig. 98), the former having opening into it the ducts of Cowper's glands, the latter fossa being situated within the glans penis, having an opening directed forward in its roof, the

Lacunus magnus, the orifice of a large mucous crypt; there are also here numerous other scattered openings of glands similarly directed.

What is the meatus urinarius?

The anterior orifice of the urethra, a vertical slit about three

lines long bounded on each side by a small labium, and is the narrowest portion of the canal.

Describe the structure of the urethra.

It possesses three coats, viz., a mucous, forming a part of the genito-urinary membrane internally and continuous with the skin externally, having numerous mucous glands imbedded in its sub-mucous tissue, which open on its free surface, and is covered with columnar epithelium except near meatus where it is squamous.

The *muscular coat* consists of longitudinal fibres externally, circular within, the latter lying beneath urethral mucous membrane for its whole length, the former leaving the circular fibres at the bulb to envelop the spongy body beneath its fibrous coat, again rejoining the circular fibres at the meatus urinarius; both muscular layers are in direct continuity with those of bladder. (For voluntary urethral muscles see p. 331.)

Erectile, this is a thin layer of erectile tissue surrounding the membranous and prostatic portions, anteriorly becoming continuous with that of corpus spongiosum.

Female Urethra.

Describe this canal.

It is about one and one-half inches long, extends from bladder to meatus urinarius above anterior vaginal wall, pierces the triangular ligament, and is embraced by compressor urethræ muscle as in male: its structure is similar to that of male urethra, it is lined by laminated squamous epithelium merging into spheroidal near bladder, is a quarter of an inch in diameter, but is capable of much greater dilatation; and its anterior opening (meatus) is situated near anterior margin of vagina, about one inch below clitoris, surrounded by a prominence of mucous membrane.

The Male Generative Organs.

Where is the prostate gland situated⁹ (Fig. 97)?

It surrounds neck of bladder and commencement of urethra, lying in pelvic cavity posterior to deep perineal fascia, behind and

below symphysis pubis upon the rectum: through it pass the urethra and seminal ducts.

Describe its form and size.

It resembles a horse-chestnut in form, measures one and a half inches transversely, one inch antero-posteriorly, three-quarters of an inch in depth, and weighs about six drachms: the base is directed backward toward bladder: it consists of two equal-sized lateral lobes and a middle lobe, a small transverse band or rounded triangular eminence placed between lateral lobes immediately beneath neck of bladder behind commencement of urethra.

Describe its structure?

It is composed of numerous follicular pouched glands opening into elongated canals which join to form twelve to twenty excretory ducts imbedded in the interstices of a stroma formed of interlacing bundles of unstriped muscle, the whole being inclosed in a fibrous capsule.

What retains the gland in place?

The pubo-prostatic ligaments of bladder, posterior layer of deep perineal fascia, and anterior portion of levator ani muscle.

Describe the situation and structure of Cowper's glands?

They are two small lobulated glands of the size of peas, lying between the two layers of the deep perineal fascia in front, close behind bulb of urethra, surrounded by compressor urethræ muscle and opening, by ducts one inch long which pass obliquely forward beneath mucous membrane, on the floor of bulbous portion of urethra.

The Penis.

Describe the penis?

It has a root, body⁵ (Fig. 98), and extremity or glans penis⁶, and consists of three elongated cylindrical masses of erectile tissue, composed of a fibrous sheath which sends inward numerous interlacing bands (trabeculæ) forming numerous meshes in which lie the bloodvessels. The upper two cylindrical bodies lying side by

side, like a double-barrel gun, are called the corpora cavernosa⁵; the third, much smaller, lying in median line beneath, like the ramrod of a gun, is the corpus spongiosum⁷.

Describe the corpora cavernosa.

Situated as just described, they are intimately connected in their anterior three-fourths where they are in contact, presenting a median dorsal groove for vessels and nerves, an inferior median one for corpus spongiosum, while their posterior fourth diverges, forming the *crura*⁴, which are attached to the rami of pubes and ischium anterior to the tuberosity; near their point of junction with one another they become slightly enlarged, forming, on either side, the *bulb of the corpus cavernosum*.

What other structure besides the crura secures the root of the penis to symphysis pubis?

The *suspensory ligament*, a fibrous membrane.

What is the septum pectiniforme⁵?

The anterior portion of the vertical fibrous septum which is incomplete, the fibrous bands resembling in their arrangement the teeth of a comb; the septum and fibrous sheath contain numerous elastic and muscular fibres in addition to the white fibrous tissue.

Describe the corpus spongiosum.

It incloses the urethra¹⁵, lying medianly below at junction of corpora cavernosa, commencing behind in front of deep perineal fascia between the crura of the corpora cavernosa as a rounded enlargement, the *bulb*⁸, which is surrounded by the accelerator urinæ muscle. Anteriorly it forms a conical enlargement, flattening from above downward, which caps the blunted end formed by the corpora cavernosa, the *glans penis*⁶, the margin of whose base is called the *corona glandis*, the constriction behind the *cervix*.

What other parts of importance does the penis present?

The *meatus urinarius*, the external orifice of urethra opening at summit of glans penis.

The *prepuce*, a portion of skin of penis prolonged forward so as either completely or partially to cover glans penis, lined internally by a tissue resembling mucous membrane.

The *frænum præputii*, a fold of mucous membrane passing from behind meatus to bottom of a depressed raphé to become continuous with under margin of prepuce.

Glandulæ Tysonii odoriferæ, numerous small lenticular sebaceous glands upon corona and cervix of glans, secreting sebaceous matter with a peculiar odor.

What is meant by erectile tissue ?

An intricate venous plexus formed by the interspaces between the fibrous trabeculæ, the blood being delivered in the following ways: (1) by arteries terminating in ordinary capillaries—this is the arrangement in the corpus spongiosum and glans—(2) fine convoluted arterial twigs opening directly into venous network by funnel-shaped extremities.

What are the helicene arteries ?

Convoluted, tendril-like arterial branches opening directly into venous plexus (supra), as just explained, most abundant in back parts of spongy and cavernous bodies.

Name the arteries, veins, and lymphatics of the penis.

The arteries are all branches of internal pudic, viz.,

Artery of bulb, to corpus spongiosum.

Arteries of corpora cavernosa, to these bodies.

Dorsal arteries of penis, to corpora cavernosa, glans, prepuce, and skin; the

Veins return blood by dorsal vein, prostatic plexus, and pudental veins.

Lymphatics, the superficial end in inguinal glands, the deep join deep pelvic lymphatics; the

Nerves are branches of internal pudic and hypogastric plexus of sympathetic.

The Testes and their Coverings.

What are the testes or testicles (Fig. 99) ?

They are the procreating glands, those which secrete the seminal fluid, are of ovoid form compressed laterally, and are each obliquely suspended in the scrotum by their own spermatic cord.

They measure from one and a half to two inches long, one inch in breadth, and one and a quarter inches antero-posteriorly, weighing from six to eight drachms, the left being slightly larger.

What is the scrotum ?

A cutaneous pouch containing the testicles and part of spermatic cords, formed of integument externally and beneath this of a reddish contractile layer, the *dartos*, continuous with contiguous superficial fascia and sending inward a partition, the *septum scroti*, dividing the scrotum into two compartments.

Describe the coats of the testis.

They are, the

Tunica vaginalis testis, a serous coat originally derived from peritoneum, consisting of a portion investing the testis, the visceral layer, or *tunica vaginalis propria*, and a parietal layer, or *tunica vaginalis reflexa*; the

Tunica albuginea is formed of white fibrous tissue surrounding the gland and reflected into its interior at its postero-superior border to form an incomplete vertical partition, the *mediastinum testis*, or *corpus Highmorianum*, from which fibrous septa pass, separating the glandular lobules; the

Tunica vasculosa, or *pia mater testis*, consists of a plexus of blood-vessels bound together by areolar tissue, which invests the *inner surface* of the tunica albuginea and sends off processes between the lobules.

What is meant by the coverings of the testis ?

The structures with which the testes become invested in their passage, previous to birth, from the abdomen along the inguinal canals into the scrotum.

Name these coverings.

Skin, } scrotum, closely adhering to each other.
Dartos, }

Intercolumnar, or *external spermatic fascia*, derived from margins of external abdominal ring.

Cremaster muscle, derived from lower border of internal oblique muscle (some authors deny this).

Infundibuliform, or *fascia propria*, a downward continuation of infundibuliform process of transversalis fascia.

Tunica vaginalis, derived from peritoneum (supra).

Describe the structure of the testis.

It consists of some hundreds of *seminiferous* tubules, one-one-hundred and fiftieth to one-two-hundredths of an inch in diameter, convoluted so as to form three hundred conical *lobules*, with apices toward mediastinum; the tubes then unite to form twenty or thirty larger ducts, one-one-fiftieth of an inch in diameter, called *vasa recta*^e, which, passing upward and into the mediastinum, form a close network of anastomosing tubules, the *rete testis*; these, at the upper end of the mediastinum, terminate into twelve to twenty *vasa efferentia*^e, perforate the tunica albuginea, and become enlarged and convoluted, forming *coni vasculosi* †, which aggregated compose the *globus major* of epididymis; the tubules consist of a membrana propria lined with a layer of polyhedral cells, with two or more inner layers of spheroidal cells, which divide into epithelial cells ultimately to become converted into spermatozoids; the vasa recta and tubes of rete testis have thin walls lined by one layer of squamous cells; the vasa efferentia and epididymis have thicker walls, containing muscular tissue and are lined with columnar epithelium.

What is the epididymis?

A convoluted tube, some twenty feet long, lying along posterior border of testis, commencing on testicle side by convergence of tubes of *coni vasculosi*, and ending in the single vas deferens beyond.

Describe its various parts.

The *globus major*^e is formed by the *coni vasculosi*, or *efferent ducts*, which open at intervals into the single duct forming epididymis; the

Body^s is the central portion formed by the convolutions of the tube bound together by delicate areolar tissue; the

Globus minor^e is the lower enlarged portion, composed as body is, and connected to testis by fibrous bands and areolar tissue; the

*Vas aberrans*ⁱ is a narrow tube extending up into cord for two or three inches, ending in a blind extremity, occasionally con-

nected with lower part of tube of epididymis, or commencement of vas deferens; the

Hydatids of Morgagni are small bodies attached to epididymis or upper portion of testicle by pedicles; one of these is probably the remains of the *duct of Müller*.

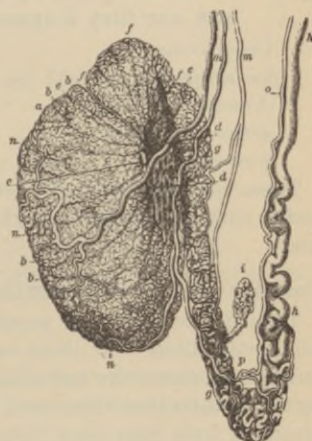Describe the vas deferens^h.

It is the excretory duct of testis, and a continuation of epididymis, commencing at *globus minor*^g to ascend along posterior side of testis and epididymis, back of spermatic cord, through the inguinal canal to internal abdominal ring, whence, passing into pelvis, it crosses external iliac, curves around epigastric artery to reach side, then by a curve downward and backward, the base of bladder internal to the ureter² (Fig. 96); here it lies between the bladder and rectum, coursing along inner border of seminal vesicle⁵ (Fig. 96) on each side, becoming enlarged and sacculated, but narrowing at base of prostate where, joined by duct of *vesiculæ seminales*⁶ (Fig. 96), it forms the ejaculatory duct⁷ (Fig. 96). It measures about two feet long, is about one and a quarter lines in diameter, its lumen measuring but one-third line, and has thick, rigid walls, presenting a hard, cord-like sensation when rubbed between the fingers.

What are the arteries of the testis and its coverings?

The gland itself is supplied by the *spermatic artery*^m (Fig. 99), the coverings receive blood from *superficial external pudic* and *deep external pudic* from femoral, *superficial perineal* from internal pudic, *cremasteric* from epigastric, and *artery of vas deferens* from superior vesical.

FIG. 99.



The *veins* leave back of testicle forming the *pampiniform plexus*, which ends in a single trunk emptying on right side into ascending vena cava, on left into left renal vein.

Veins of the same name as arteries supplying coverings, return blood to femoral, external and internal iliac veins.

What nerves go to each testicle and its coverings?

Branches from spermatic plexus of sympathetic to testicle itself, to coverings and cord the *ilio-inguinal*, *ilio-hypogastric*, *superficial perineal*, *inferior pudendal*, and *genital branch of genito-crural nerve*.

What are the component parts of the spermatic cord, and how are they disposed?

<i>Vas deferens,</i>	<i>Spermatic nerve-plexus,</i>
<i>Spermatic artery,</i>	<i>Branch of ilio-inguinal nerve,</i>
<i>Cremasteric artery,</i>	<i>Branch of genito-crural nerve,</i>
<i>Artery of vas deferens,</i>	<i>Vas aberrans (when present),</i>
<i>Spermatic veins,</i>	<i>Lymphatics.</i>

These form a cord bound together by connective tissue about four inches long, extending from globus minor to internal abdominal ring.

Describe the vesiculæ seminales.

They are two lobulated membranous receptacles for the semen, which they dilute with their own secretion. They are pyramidal in form, are about two and a half inches long by five lines broad, by two to three lines thick, and lie in contact with base of bladder, diverging from each other from base of prostate to near entrance of ureters; they join by their anterior pointed extremities with vas deferens, forming on each side the *ejaculatory ducts*⁷ (Fig. 96), terminating in prostatic urethra by slit-like orifices on each side of the *sinus*⁵ (Fig. 97) at front of verumontanum.

Describe the descent of the testes.

During early foetal life the testes lie at back part of abdomen, behind the peritoneum, just below and in front of kidneys; attached to lower end of epididymis, and attaining its full development from fifth to sixth foetal month is the *gubernaculum testes*, which contains muscular tissue; this divides below into three portions,

passing to Poupart's ligament, to os pubis and rectus muscle, and to dartos at bottom of scrotum; the gubernaculum is supposed to contract and so cause descent of testicle, but this is a moot point. Between the fifth and sixth month each testis reaches the iliac fossa, by seventh it enters internal abdominal ring, by eighth month it has reached the scrotum, carrying before it the peritoneal sac, the upper part of which usually becomes obliterated just before birth, the lower portion then forming the *tunica vaginalis testis* completely cut off from abdominal cavity; the other structures in front of the testis are likewise carried onward, forming its covering, as already described (see page 275).

Female Organs of Generation.

What is the vulva ?

The term includes the following organs :

<i>Labia minora</i> ¹³ ,	<i>Vaginal orifice</i> ¹⁵ ,
<i>Mons veneris</i> ⁴ ,	<i>Clitoris</i> ⁶ ,
<i>Labia majora</i> ⁵ ,	<i>Meatus urinarius</i> ¹⁴ ,

These parts are also called the *puendum* and *external organs of generation*.

Describe the mons veneris⁴.

It is a rounded eminence surmounting vulva in front of pubes, formed by a collection of fatty tissue, and at puberty becomes covered with hair.

Describe the labia majora⁵ and minora¹³.

The *Labia majora*⁵ are two prominent longitudinal cutaneous folds passing downward from mons veneris to anterior part of perineum enclosing the common *urino-sexual opening*. Each labium is formed externally of hair-covered skin, internally, of mucous membrane enclosing between these *layers* fatty areolar tissue and a structure resembling the dartos; the junction of the labia in front constitutes the *anterior commissure*, that behind, the *posterior commissure*; the

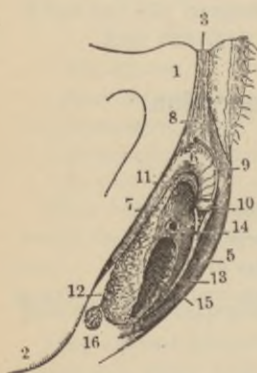
Labia minora, or *Nymphæ*¹³, are two thin folds of mucous mem-

brane, containing numerous sebaceous glands, inside the labia majora, running from clitoris⁶,—above which they form a hood-like prepuce,—obliquely downward for about one and a half inches on each side of vaginal orifice, to be lost in the labia majora.

Describe the remaining structures forming the vulva.

The *clitoris*⁶ is a small penis with root, body, and glans, composed of two corpora cavernosa formed of erectile tissue attached to rami of pubes and ischium by two crura⁷; it has a suspensory ligament and two erectors clitoridis muscles; the

FIG. 100.



Vestibule is the triangular smooth surface below clitoris, bounded on each side by labia minora; the

*Meatus urinarius*¹⁴ is placed at back part of vestibule, about one inch below clitoris, near vaginal margin, surrounded by a prominence of mucous membrane; the

*Vaginal orifice*¹⁵ is of an elliptical form, usually more or less closed in the virgin by hymen, and is surrounded by sphincter vaginae muscle, the analogue of male accelerator urinae muscle; the

Hymen is a thin fold of mucous membrane, variously shaped, but usually semilunar, with concavity upward, stretched across lower part of vaginal orifice; it may occasionally form a complete occluding membrane, the condition being then known as *imperforate hymen*; it may be practically absent in the virgin, and again, may persist after copulation, but at that time is usually ruptured, giving rise to small, rounded elevations surrounding vaginal outlet, called *carunculae myrtiformes*; the

*Glands of Bartholine*¹⁶ are small, oblong, reddish-yellow bodies, lying on each side of commencement of vagina, each opening by a long single duct external to hymen on inner side of each labium majorum; the

*Bulbi vestibuli*¹² are two oblong masses—a venous plexus enclosed

in a fibrous envelope—extending from clitoris along each side of vestibule, a little behind labia majora; the

*Pars intermedia*¹¹ is another small venous plexus immediately in front of preceding, with which it is continuous as well as with glans clitoridis; the

Fourchette is a small transverse mucous fold, just within posterior commissure; the

Fossa navicularis is the space between fourchette and posterior commissure.

The Vagina.

Describe it.

It is a cylindrical membranous canal flattened from before backward, lying between rectum and bladder, extending from vulva to uterus, curved forward and downward conforming to axis of pelvis and of outlet. Narrow at its orifice it is larger above, its anterior wall measuring about four inches, its posterior six, being attached higher up on os uteri *behind* than in *front*.

Describe its structure.

It is formed of an external layer of erectile tissue, a muscular coat, and a lining mucous membrane with a *median anterior* and *posterior raphé* or *columns of the vagina*; it contains mucous glands; the epithelium is of the squamous variety.

Give the relations of the vagina.

Its *anterior surface* is in relation with base of bladder and urethra;

The *posterior surface* is connected with lower three-fourths of rectum, the upper fourth being separated from bowel by recto-uterine fold of peritoneum forming *Douglas's cul-de-sac* or *pouch*;

Laterally, above it gives attachment to broad ligaments of uterus, below to levatores ani muscles and recto-vesical fascia.

The Uterus and its Appendages.

Describe the position and parts of uterus.

It is the organ of gestation, situated in pelvic cavity between rectum and bladder, opening below into vagina, which is attached

around its cervix. It is pear-shaped, flattened from before backward, is about three inches long, two inches in breadth at upper part, and one inch thick, weighing from one to one and a half ounces; it presents for examination the

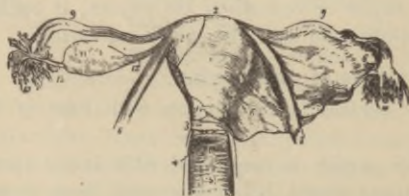
*Fundus*², which is convex, covered with peritoneum, and placed below level of brim of pelvis; the

*Body*¹ gradually narrows from fundus to neck, with anterior flattened surface covered with peritoneum for its upper three-fourths, and a posterior peritoneum-covered convex surface, while each lateral margin is concave, affording attachment to Fallopian⁹ tube above, to round ligament in front and below this, and to ovarian ligament below and behind both; the

*Cervix*³ is the lower, rounded, constricted portion of uterus projecting into upper portion of vagina, which is attached further up behind than in front; the

Cavity of the Body is small, triangular, flattened from before backward, its upper extended lateral angles forming funnel-shaped cavities at the bottom of each of which opens, by a minute orifice, the Fallopian tube; at the inferior angle is the small opening into the cavity of the cervix called *os internum* or *internal os uteri*; the

FIG. 101.



Cavity of the cervix is spindle-shaped, flattened antero-posteriorly, and opens into cavity of uterus above by *internal os uteri*, and below into vagina by the *external os uteri*; a median longitudinal crest of mucous membrane on back and front walls from which proceed obliquely other smaller ones, forms the *arbor vitæ*, hardly noticeable after the first labor; the

Os externum or *external os uteri* (also *os tinctæ*)⁴ is a transversely ovoidal opening from cervix into vagina which presents an *anterior* and *posterior lip*.

Describe ligaments of uterus.

Six are peritoneal folds, viz.,

Anterior or vesico-uterine, two crescentic folds passing between uterine neck and back of bladder; the

Posterior or recto-uterine, passing between sides of uterus and rectum; the peritoneal pouch thus formed between rectum and uterus being called *Douglas's cul-de-sac* or *recto-vaginal pouch*; the

*Two lateral or broad ligaments*¹ (Fig. 101), stretched between sides of uterus and lateral walls of pelvis, dividing this cavity into two portions, and containing between their folds the Fallopian² tubes and the round ligaments³.

Describe the round ligaments of the uterus³.

They are two rounded cords, four or five inches long, commencing at superior angles of uterus to pass forward and outward through internal abdominal ring into inguinal canal to become lost, after dividing into three fasciculi, in the fatty tissue of mons veneris; they consist of dense fibrous tissue and unstriped muscle, enclosed, in the fœtal state, by a process of peritoneum extending a short distance into inguinal canal, the so-called *canal of Nuck*, usually obliterated in adult, but sometimes pervious throughout life.

Describe the structure of uterus.

The womb has three coats, viz., a

Serous, derived from peritoneum covering fundus of organ and its posterior surface, but only the superior three-fourths of its anterior surface; a

Muscular, forming bulk of uterus, composed of bundles of unstriped muscular tissue interspersed with areolar tissue, blood-vessels, lymphatics, and nerves. The fibres are disposed in three layers, viz., transverse, in front and behind fundus; middle layers, passing longitudinally, obliquely, and transversely; and circular, arranged in two hollow cones whose apices surround the orifices of the Fallopian tubes, whose bases fuse in middle of uterine body; at cervix these fibres pass transversely; a

Mucous, thin, smooth, and closely adherent to subjacent parts,

covered with columnar ciliated epithelium, and containing numerous tubular follicles, most numerous in the cervix; when their ducts become obliterated their secretion is retained, forming small vesicular elevations within os and cervix uteri called *Ovula of Naboth*.

Name the uterine vessels and nerves.

The

Arteries are the *uterine*, from internal iliac, and *ovarian*, from aorta, which pursue a very torturous course and freely anastomose.

The *veins* accompany arteries and terminate in uterine plexuses; during pregnancy they are called *uterine sinuses*, consisting of the lining membrane of the vein adhering to the walls of canals channelled through uterine substance; the

Lymphatics, terminate in pelvic and lumbar glands; the

Nerves, are branches of inferior hypogastric, and spermatic plexuses, and of third and fourth sacral nerves.

What are the Fallopian tubes?

They are the *oviducts*, two tubes about four inches long, extending between layers of broad ligament on each side from superior angle of uterus to sides of pelvis; the canal of each tube is very minute at its commencement the *ostium internum* at the superior angle of the uterine cavity, continuing so for inner half, when it gradually widens into the trumpet-shaped *ostium abdominale*¹⁰, called from the fringe-like *fimbriae*¹⁰ which surround the opening—one of which is attached to ovary—the *fimbriated extremity*¹⁰. Their walls are formed of a serous or peritoneal coat, a muscular, formed of longitudinal and circular fibres, and a mucous coat covered with ciliated columnar epithelium, continuous on one side with uterine lining, on other with peritoneum.

Describe the ovaries¹¹.

They are two flattened, ovoid bodies suspended by their anterior margins from back of broad ligaments⁷, behind and below Fallopian tubes, upon either side of uterus; they are attached by their inner extremities to uterus by the ovarian ligaments and by their outer ends to one of fimbriae of Fallopian tube; their dimensions are, *length*, one and one-half inches; *width*, three-quarters of an inch; *thickness*, one-third of an inch.

Describe the structure of the ovaries.

They consist of numerous *Graafian vesicles* imbedded in a fibrous stroma, covered externally by modified peritoneum, having columnar instead of squamous cells.

The *stroma* consists of numerous spindle-cells with connective tissue and abundant bloodvessels; the condensed peripheral layer surrounding the organ was formerly described as the *tunica albuginea*.

What are the Graafian vesicles ?

Ovisacs, minute vesicles from one-one-hundredth of an inch in diameter, to even one-one-twentieth of an inch after puberty; microscopically, they are seen to consist of an *external fibro-vascular coat* connected with stroma by a vascular network, an internal coat, or *ovicapsule* lined by a layer of nucleated cells, the *membrana granulosa*, which are heaped up around ovum at that part of *Graafian vesicle* nearest the ovarian surface, forming the *discus proligerus*; it contains also a transparent, albuminous fluid, suspending the ovum in the immature vesicles.

Describe the human ovum.

It is a spherical mass of protoplasm, one-one-hundred and twenty-fifth of an inch in diameter, and consists of the

Vitelline membrane, or *zona pellucida*, a transparent sac surrounding the

Vitellus, or *yolk*, a fluid containing granules, among which is found the

Germinal vesicle, containing a smaller body, the

Germinal spot, one-thirty-six hundredths of an inch in diameter.

What is the corpus luteum ?

An irregular yellow spot in ovary at site of a ruptured Graafian vesicle, which differs in appearance according as it is a *true* or *false corpus luteum*.

Describe the differences between these two kinds of corpora lutea.

The *true corpus luteum* is that of pregnancy which increases up to a certain point, reaching sometimes the size of a mulberry, and usually does not entirely disappear until full term.

The *false corpus luteum* is that following ordinary menstruation, is much smaller, and disappears in about three months.

Name the ovarian arteries, veins, and nerves.

The *arteries* are the ovarian, from aorta, anastomosing with uterine artery; these vessels also supply Fallopian tubes; the

Veins follow arteries and form a plexus near ovary, called the *Pampiniform plexus*; the *nerves* are derived from inferior hypogastric or pelvic plexus, from ovarian plexus, and the Fallopian tubes receive branches from one of the uterine nerves.

What is the parovarium?

It is also called the *organ of Rosenmüller*, is the remains of a fetal structure, and in the adult consists of a few closed epithelial-lined, convoluted tubes, one commonly ending in a bulbous hydatid-like swelling; at its uterine end the parovarium is connected with the remains of the Wolffian duct—the *duct of Gaertner*.

The Mammary Glands.

Describe the mammæ.

They exist in both sexes, being in male only rudimentary, but in female are two large hemispherical eminences situated toward lateral aspect of pectoral region on each side, reaching from axilla to sternum, and from third to sixth or seventh ribs; just below the centre projects a small, dark-colored conical prominence, the *nipple*, surrounded by a lighter colored *areola*, in which are numerous prominent sebaceous glands, which enlarge during pregnancy; the color of both nipple and areola darken during pregnancy, and the latter also extends its area.

Describe the structure of the mammary glands.

They are composed of gland-tissue, of fibrous tissue connecting the lobes, and fatty tissue in intervals between lobules; the lobes consist of lobules formed of a number of rounded vesicles grouped about a small lactiferous tube into which their ducts open, which, by their union, finally form fifteen or twenty excretory ducts, or *tubuli lactiferi*, which converge toward the areolæ, dilating beneath it into the *ampullæ* at base of nipple, when they contract into

straight tubes perforating the summit of the nipple; the lobules are surrounded by a dense capillary network during lactation, as is also the nipple, which becomes erected when irritated, partly from fulness of blood, partly from contraction of its muscular tissue.

Name the vessels and nerves of the mammæ.

The *arteries* are derived from thoracic branches of axillary, intercostal, and internal mammary arteries; the

Veins form an anastomotic circle around the base of the nipple, called the *circulus venosus*, from which large vessels radiate to terminate in axillary and internal mammary veins; the

Lymphatics chiefly run along lower border of pectoralis major to axillary glands, a few pass through intercostal spaces to anterior mediastinal glands; the *nerves* come from anterior and lateral thoracic cutaneous.

THE ORGANS OF SENSE.

The Skin and its Appendages.

Of what parts does the skin consist?

<i>Epidermis</i> , or <i>cuticle</i> , formed of	} <i>superficial epithelial layers</i> and the <i>rete mucosum</i> , or <i>deep epithelial layers</i> , which contain the pigment.
<i>Derma</i> , <i>cutis vera</i> , or <i>true skin</i> , formed of	
	} <i>papillary layer</i> , upon which lies <i>rete</i> with an interposed basement membrane; <i>corium</i> .

Enumerate the accessory structures contained in the skin.

The *tactile corpuscles*, in papillæ of sensitive parts.

Ducts of sweat-glands,
Hair-follicles, into which open } passing through all the layers
sebaceous glands, } of the skin.

Where do sweat- and sebaceous-glands with the hair follicles lie?

Chiefly in the subcutaneous fatty tissue, but sometimes in the deepest layers of the corium.

Describe the epidermis.

It is composed solely of epithelial cells, the deepest layer being columnar, more rounded in the middle portions, and flat, scaly, and horny on free surface; the deepest, softest layer is accurately moulded upon the papillary layer of the derma, and contains the skin pigment; it is called the *rete mucosum*.

Describe the derma.

Is a tough, flexible, and highly elastic tissue, protecting subjacent parts, and is the chief organ of the sense of touch; excretion is effected by its various glands, and absorption also takes place from its surface. The derma consists of the

Papillary layer, situated upon its free surface, presenting innumerable, minute, vascular conical eminences, averaging in length one-one-hundredth of an inch by one-two-hundred and fiftieth of an inch in diameter at their bases, scattered irregularly in slightly sensitive parts, but arranged in parallel curved lines, forming ridges, in highly sensitive regions; each papilla contains one or more capillary loops, and one or more nerve fibres, some terminating in oval-shaped bodies, the

Tactile corpuscles, where touch is most highly developed.

The *corium* is composed of interlacing bands of white fibrous tissue, with some yellow elastic fibres, unstriped muscular fibres wherever hair exists, lymphatics, bloodvessels, and nerve-plexuses.

What are the nails?

Flattened, horny structures of modified epithelium, covering the dorsal aspects of derma of distal phalanges of fingers and toes. They are convex externally, and have a *root*, imbedded in a groove of skin, whence the growth in length comes; a *matrix*, that portion of derma beneath, by which the nail grows in thickness; the *lunula*, the white crescentic portion next to root, its color owing to diminution in size, number, and vascularity of the papillæ, which are disposed in longitudinal rows elsewhere in the matrix.

What are the hairs?

They are also modified epidermis, found everywhere in skin, except palms of hands and soles of feet, but varying in size. They each have a

Root, bulbous in form, springing from a vascular papilla at the bottom of an involution of the epidermis and corium, called a hair-follicle, which sometimes extends into subcutaneous cellular tissue; into the hair-follicle open one or more sebaceous glands; the

Shaft consists of a *central* or *medullary portion*, a *fibrous portion*, and a *cortical* of thin flattened scales; the medulla is commonly absent in fine hairs; the

Point is formed only of the fibrous and cortical portions.

Describe the sebaceous glands.

Most abundant in scalp, face, arm-pits, around nasal and oral apertures, and in external auditory canal; the largest are the Meibomian glands of eyelids; they are small sacculated glands, lodged in the corium or subcutaneous tissue of nearly every part, except palmar and plantar surfaces; the ducts usually open into hair follicles, but sometimes on general surface of skin.

Describe the sweat glands.

They are each formed of a single convoluted tube, situated either in deepest portion of corium, or more usually in subcutaneous cellular tissue, and opening on free surface by a spiral duct; the tubes are formed of an external fibro-cellular coat, continuous with superficial layer of corium, and a lining of epithelial cells continuous with epidermis.

What is their estimated number and area?

Nearly two and a half millions, forming an evaporating area of about eight square inches.

Organs of Taste.

Where does the sense of taste reside?

In the mucous membrane of dorsum of tongue, upper portion of pharynx, soft palate, and fauces.

Are there any special taste-organs?

Yes, the *taste-goblets*, flask-like bodies with their bases resting on corium, and a neck opening between epithelial cells. They consist

of spindle-shaped, flattened cells externally, with central spindle-cells, whose inner fine terminations are continuous with a terminal nerve fibril; these bodies are found in the circumvallate and some of the fungiform papillæ, and at the side of base of tongue.

What are the special nerves of taste?

For its anterior two-thirds, *chorda tympani of facial*, recognizing acid, saline, and styptic qualities (according to Flint).

For posterior third, *lingual branch of the glosso-pharyngeal*, for perception of alkaline, metallic, sweet, and bitter tastes (Flint).

Organs of Smell.

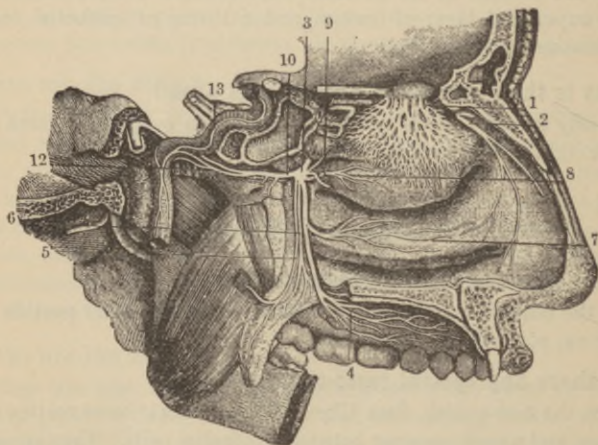
Where does the sense of smell reside?

In the mucous membrane lining upper portion of nasal fossæ, where the *olfactory nerve filaments* are distributed.

Describe the nasal mucous membrane.

It is also called the *Schneiderian*, or *pituitary* membrane, and is continuous with that of pharynx, Eustachian tube, tympanum,

FIG. 102.



and mastoid cells, and with that of the accessory nasal cavities, the frontal, ethmoidal, and sphenoidal sinuses and antrum, also through lachrymo-nasal duct, with conjunctiva. Its epithelium is ciliated columnar below, and simple columnar above; it contains numerous mucous glands, and in the deeper portions of epithelial layer certain nucleated bodies are found, the *olfactory cells of Schultze* with two processes, one running between epithelial cells to free surface, the other inward, to connect with a terminal nerve fibre.

What vessels supply the exterior of the nose?

Lateralis nasi, from facial to alæ of nose; the

Artery of septum, from superior coronary to septum; the

Nasal branches of ophthalmic and infraorbital to dorsum and sides of nose; the *veins* terminate in the facial and ophthalmic.

What are the vessels of the nasal fossæ?

Anterior and posterior ethmoidal from ophthalmic to ethmoidal cells, frontal sinuses, and roof; the

Spheno-palatine and twig from *small meningeal*, from internal maxillary to membrane over spongy bones, meatuses, and septum; the

Alveolar, from internal maxillary to antrum; the

Veins usually accompany the arteries, terminating in facial, ophthalmic, and other trunks.

What are the nerves of the nose?

Branches of *facial*, *infraorbital*, *infratrochlear*, and *nasal branch of ophthalmic*.

Describe the nerve-supply to the nasal fossæ.

The *olfactory*¹ is distributed to mucous membrane over upper third of septum, and superior and middle spongy bones; the

*Nasal branch of ophthalmic*² supplies upper anterior part of septum and outer wall; the

Anterior dental branch of superior maxillary supplies inferior turbinated bone and inferior meatus; the

*Spheno-palatine*⁶, by *naso-palatine* branch⁷, supplies middle of septum, by *anterior palatine*, the middle and inferior spongy bones.

The *Vidian*¹⁰ supplies the upper back part of septum and superior spongy bones, parts to which are also distributed the upper anterior nasal branches of *spheno-palatine ganglion*⁷.

(For bones forming nasal fossæ, see p. 58.)

The Eye.

Describe the eyeball.

It is a spherical organ, with the segment of a smaller transparent sphere, the cornea, forming its anterior portion, lying in the orbit in a cushion of fat, and held in position by the ocular muscles, the optic nerve, conjunctiva, and eyelids. The following points should be studied, the

Diameters, antero-posterior in adult about ninety-five hundredths of an inch, transverse ninety-two hundredths of an inch, vertical ninety hundredths of an inch.

Anterior and posterior poles, the centres respectively of the cornea and fundus oculi.

Axes of eyeballs, or ocular axes which pass through the poles of each eye and are nearly parallel, *not corresponding to axes of orbits*, which diverge.

Visual axis passes from the yellow spot through the centre of curvature of the refracting media, so that *these axes converge*.

Nodal point, the centre of curvature of refracting media.

Equatorial plane, that passing through centre of eyeball at right angles to the axis, dividing the globe into two segments, an anterior and a posterior hemisphere.

Equator, the line where the just-mentioned plane cuts the surface of eyeball.

Meridional planes, planes coinciding with ocular axis.

Meridians, the lines where meridional planes cut surface of eyeball.

What is the capsule of Tenon ?

The *tunica vaginalis oculi*, and consists of a thin membranous sac isolating the eyeball and allowing free movement, arising from optic foramen behind to become lost upon sclerotic in front, having a visceral layer investing posterior portion of globe, and a parietal layer lining the fatty cushion in which eye rests, both layers being lined by flattened endothelial cells: the lymphatic vessels of the sclerotic open into it, the cavity being a lymph space also communicating with the lymph-spaces of the optic nerve sheath; the

ocular muscles pierce this capsule: that portion of the capsule behind the point of passage of the tendons is sometimes called the

Capsule of Bonnet, while to that in front the name of

Capsule of Tenon has been restricted; this is an unnecessary refinement.

What are the tunics or coats of the eye?

The *sclerotic*² and *cornea*², the most external, protective tunic.

Choroid, *iris*, and *ciliary processes*, the middle or vascular tunic.

Retina, the innermost, nervous tunic.

What are the humors of the eye?

The refracting media, three in number, viz., the

*Aqueous*³, filling anterior chamber.

*Crystalline*⁴, or crystalline lens.

*Vitreous*⁵, filling posterior four-fifths of the globe.

Sclerotic and Cornea.

Describe the sclerotic.

It is a firm, unyielding fibrous membrane maintaining the form of the posterior five-sixths of the globe, thicker behind than in front, with smooth white external surface except where tendons are attached, covered in front by conjunctival membrane, and having an inner brown-stained surface grooved for ciliary nerves. Posteriorly to the nasal side it is pierced by the optic nerve with whose sheath it is continuous, the sclerotic at this point forming a thin

Lamina cribrosa through whose openings the nerve filaments pass, the most central orifice, called the *porus opticus*, transmitting the *arteria centralis retinae*. Surrounding the cribriform lamella are numerous small openings for the ciliary vessels and nerves; the *venae vorticosae* emerge midway between margin of cornea and entrance of optic nerve, and the anterior ciliary vessels around the corneal border. The sclerotic is formed of white fibrous tissue, mingled with fine elastic fibres and fusiform nucleated cells. The following points should be noted; the

Thickness, about one-twenty-fifth of an inch posteriorly, one-sixtieth of an inch anteriorly;

Lamina fusca, the fine cellular tissue connecting sclerotic with choroid; the

Subconjunctival tissue, loose areolar tissue binding conjunctiva to sclerotic; the

Arteries are few, come from *ciliary*, and form a coarse network; the

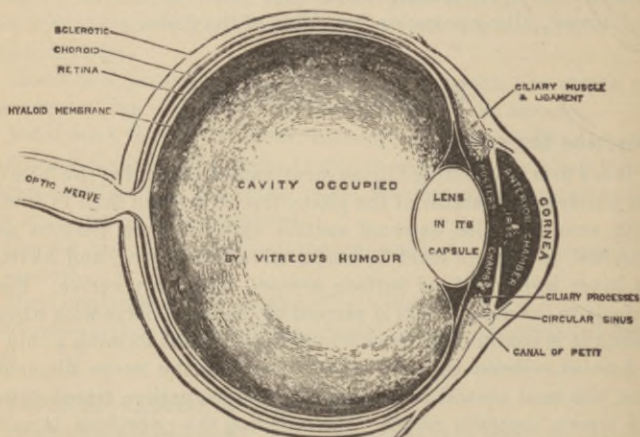
Anterior vascular zone, surrounding cornea, formed by subconjunctival branches of anterior ciliary vessels; the

Nerves, whose existence is very doubtful.

Describe the cornea.

It is the transparent, projecting, anterior sixth of the external tunic. It is not quite circular, being a little broader in the transverse than the vertical diameter, and is set in sclerotic somewhat

FIG. 103.



Section of eyeball.

like a watch-crystal in its case: its thickness, one twenty-second of an inch to one thirty-second of an inch, is nearly same throughout except toward outer margin where it is thinner: it is *non-vascular*, the capillary vessels forming loops at its circumference: the *nerves* are numerous, estimated at from twenty-four to forty-five, and are derived from the ciliary nerves.

Describe the structure of the cornea.

It consists from without inward, of the following layers :

Layer of conjunctival epithelium, the deepest columnar, next polyhedral, most superficial three or four layers of scaly cells ; the

Anterior elastic lamina or membrane of Bowman, one two-thousandth to one-twelve-hundredths of an inch thick, forming a thin, firm, elastic layer consisting of extremely closely interwoven fibrils similar to those of corneal tissue proper, but with no corneal corpuscles ; the

True corneal tissue is fibrous, tough, unyielding, continuous with sclerotic and composed of sixty, superimposed, flattened lamellæ made up of fibrillar connective-tissue continuous with fibres of sclerotic : the layers are held together by a cement substance in which are *corneal spaces*, stellate in form, communicating with adjacent spaces by processes, each space containing a similarly shaped but smaller *corneal corpuscle* which does not entirely fill it ; the

Posterior elastic lamina (membrane of Descemet or Demours) is a structureless, elastic, brittle, extremely thin membrane, not rendered opaque by water, alcohol, or acids : its chief peculiarity is the tendency to roll upon itself with the attached surface innermost, when separated from cornea proper : at its circumference it breaks up into bundles of fibres joining the *ligamentum pectinatum iridis* ; the

Posterior epithelial layer is a single layer of polygonal transparent nucleated cells.

Describe the choroid.

It is a thin, dark-brown, vascular membrane investing the posterior five-sixths of globe terminating in front at ciliary ligament, there bending inward to form the ciliary processes : it is connected externally with sclerotic by the *lamina fusca*, and consists of two layers, the

External layer is formed of the larger branches of the ciliary arteries and the *venæ vorticosæ*, interspersed with stellate pigment cells by the union of whose processes a delicate network is formed ; externally the choroid is covered by a layer of elastic fibres, the *membrana suprachoroidea*, coated externally with endothelial cells ; the

Internal layer or membrana Ruyschiana consists of a fine capillary plexus formed by the short ciliary vessels, which is separated from pigmentary layers of retina by the

Vitreous membrane, a thin, structureless layer.

The arteries of the choroid are the short, posterior ciliary, and recurrent branches from the long posterior and anterior ciliary; the

Veins, form four to five *venæ vorticosæ*^f (Fig. 104), which pierce the sclerotic midway between corneal margin and optic nerve; the

Nerves are the long and short ciliary nerves.

What are the ciliary processes ?

Sixty to eighty folds formed by plaiting and folding inward of choroid at its anterior margin, which are received between corresponding folds of the suspensory ligament of the lens; they consist of large and small processes, irregularly alternating, the former about one-tenth of an inch long.

What is the ciliary body ?

It is that portion of the middle tunic between the choroid and iris formed of the ciliary muscle and ciliary processes.

Describe the ciliary muscle^b.

A grayish circular band of unstriped muscular fibre about one-eighth of an inch broad, thickest in front, thinnest behind, consisting of radiating and circular fibres, the former, the more numerous, arising from junction of cornea and sclerotic to pass backward to choroid opposite the ciliary processes; the latter are internal, and pursue a circular course around the insertion of the iris; they are called the "*ring-muscle*" of Müller and were formerly described as the *ciliary ligament*.

Describe the circulus arteriosus major and minor.

The former is an anastomotic ring formed by long ciliary arteries in the ciliary muscle; the latter, a second anastomotic circle formed by transverse offsets from the converging branches passing forward from the circulus major.

Describe the iris^c (Fig. 104).

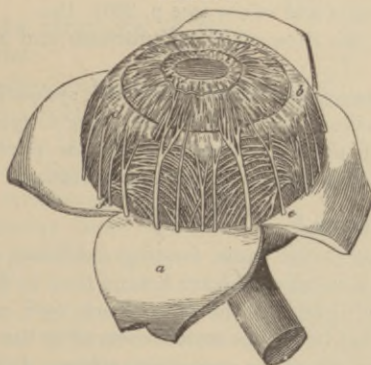
It is a thin, circular, perforated contractile curtain, suspended behind the cornea in the aqueous humor in front of the crystalline

lens, forming the anterior portion of the middle ocular tunic, and is formed of radiating and circular muscular fibres, and of a fibrous stroma. Anteriorly it is covered by a layer of polyhedral cells resting on a fine basement membrane, being continuous with the membrane of Descemet. It presents for examination the

Pupil, the nearly central opening in iris placed a little to nasal side of centre; the

Ligamentum pectinatum iridis, a reticular tissue, connecting iris with cornea, derived from membrane of Descemet which sends fibrous prolongations to iris and sclero-corneal junction; the

FIG. 104.



Spaces of Fontana, the intervals between the reticulated fibres of the ligamentum pectinatum at outer angle of anterior chamber, which communicate with a larger space in the sclerotic close to sclero-corneal junction; the

Canal of Schlemm or Sinus circularis iridis, lined with endothelium, a venous sinus, containing two or three plexiform veins receiving blood from the sclerotic and ciliary plexuses and communicating with anterior ciliary veins; the

Uvea, a layer of purplish-hued pigment-cells on posterior surface of iris continuous with pigment layer of ciliary processes; the

Sphincter pupillæ, the narrow band of circular muscular fibres surrounding pupil on its posterior surface, about one-thirtieth of

an inch wide, supplied by third nerve through ophthalmic ganglion; the

Dilator pupillæ, consisting of the radiating muscular fibres converging from circumference of iris toward pupillary margin, where they blend with the circular fibres; it is supplied by sympathetic fibres from ophthalmic ganglion; the

Membrana pupillaris, a delicate, transparent, vascular membrane which occluded the pupil in the fœtus, usually disappearing about eighth fetal month, but occasionally persisting; it is nourished by many small vessels continued from margin of iris to those on front part of lens capsule; the

Arteries, are branches of long and anterior ciliary forming the *circulus iridis major* and *minor* (see p. 296); the

Veins, empty into those of ciliary processes and anterior ciliary veins; the

Nerves, are branches of third, fifth, and sympathetic, through long and short ciliary nerves, the third going to sphincter pupillæ (circular fibres), the sympathetic to dilator pupillæ (radiating fibres), and the fifth supplying common sensation.

What is the retina ?

The innermost ocular tunic, forming a delicate, grayish, transparent nervous membrane, thicker behind than in front, terminating nearly as far forward as the ciliary body by a ragged margin, the *ora serrata*, but its fibrous stroma covered by the pigment layer passes forward to iris as the *pars ciliaris retinæ*. It presents the

Macula lutea or yellow spot of *Sömmering*, a round elevated spot exactly in centre of retina posteriorly, which corresponds to axis of eye; here vision is most perfect, the retina being thin, crowded with nerve elements, but destitute of rods and the nerve-fibre layer; the

Fovea centralis is a minute central depression at summit of yellow spot; the

Optic papilla or *disk* is the point of entrance of optic nerve, centrally pierced by *arteria centralis retinæ*, lying about one-tenth of an inch to inner side of yellow spot; it is the only portion of retina where the sense of vision is wanting, and is therefore called the *blind spot*; the

Pars ciliaris retinae consists of the fibrous and pigmented portions of retina, destitute of nerve elements, continued over ciliary processes to iris; the

Arteries of retina spring from *arteria centralis retinae*, a branch of the ophthalmic, which after piercing the optic nerve divides into four or five branches which soon enter the nervous layer of retina to form a fine capillary plexus not extending beyond inner nuclear layer; no vessels exist in the fovea centralis and very few in the macula lutea.

Describe the structure of the retina.

It is exceedingly complex, being composed from within outward of the following ten layers,

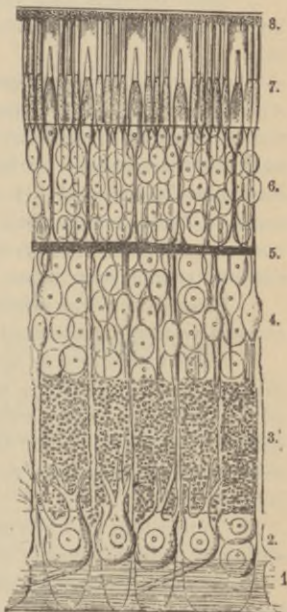
1. *Membrana limitans interna*, a transparent membrane formed of retinal connective tissue, lying in contact with hyaloid membrane of vitreous humor.

2. *Fibrous layer*, composed of continuations of optic nerve fibres deprived of their medullary sheaths, forming radiating bundles or plexuses.

3. *Vesicular layer*, a single layer of large ganglion cells, except at macula lutea where there are several layers; they have one process prolonged into the fibrous layer becoming continuous with a nerve fibril, and one or more extending into inner molecular layer or, according to some, passing through it to terminate in inner nuclear layer.

4. *Inner molecular layer*, made up of a dense reticulum of minute fibrils, mingled with processes of ganglion cells and those of next layer, containing in the interstices minute clear granules.

FIG. 105.



5. *Inner nuclear layer*, containing (1) oval nuclei with two processes, one passing inward to inner molecular layer, believed to become continuous with processes of ganglion cells, and another passing into outer molecular layer, these bifurcating and (according to some) communicating with rod and cone fibres; (2) nucleated cells without branches; (3) cells connected with fibres of Müller.

6. *Outer molecular layer*, is thinner, resembles the inner molecular layer, but contains branched stellate cells—probably ganglion cells.

7. *Outer nuclear layer*, consists of (1) *rod-granules*, transversely striated cells, with an external fine process connected with a single rod of Jacobs's membrane, and an internal prolongation which enlarges, then breaks up into minute fibrils entering the outer molecular layer; and (2) *cone-granules*, closely connected with cones of Jacobs's membrane, with a thick process passing inward, becoming bulbous and terminating by numerous fibrillæ, which enter outer molecular layer.

8. *External limiting membrane*, a membrane formed of retinal connective tissue, perforated by numerous openings.

9. *Jacobs's membrane or rods and cones*, composed of *rods* arranged perpendicularly to surface, each composed of an outer and inner portion joined by cement substance; and *cones*, with apices directed toward choroid, formed of two portions and like rods their outer segments are transversely striated; this is probably the perceptive layer of retina.

10. *Pigmentary layer*, formerly considered part of choroid, consisting of a single layer of hexagonal, pigmented epithelial cells.

The connective tissue is modified to form a fenestrated, sponge-like structure the *membrane of Müller*.

The Humors.

What is the aqueous humor?

A small amount of clear alkaline fluid composed of water 96.7, albumen 0.1, sodium chloride and extractive 3.2, filling anterior and posterior chambers of the eye.

What are the anterior and posterior chambers of the eye?

The anterior chamber is a space filled with aqueous humor bounded in front by cornea, behind by front of iris, and communicating through pupil with the

Posterior chamber, also filled with aqueous humor, which is now thought to be only a narrow chink between peripheral portion of iris, the suspensory ligament, and ciliary processes.

Describe the vitreous humor.

This forms about four-fifths of entire globe, is transparent, of the consistence of thin jelly, and is composed of an albuminous saline fluid enclosed, except where hollowed out for crystalline lens, in a delicate *hyaloid membrane*, beneath which are small, granular, nucleated cells; it possesses neither vessels nor nerves, and is hollowed out in front where the crystalline lens reposes. Running from entrance of optic nerve to posterior surface of crystalline lens is the *canal of Stilling or hyaloid canal*, filled with fluid and lined with a process of the hyaloid membrane.

Describe the crystalline lens with its ligaments, etc.

It is a transparent double convex body, more convex posteriorly than in front, enclosed in a *capsule*, and is lodged in a depression of the vitreous humor, where it is retained by its suspensory ligament. It lies immediately behind the pupil surrounded and slightly overlapped by the ciliary processes, measuring about one-third of an inch transversely by one-fourth of an inch antero-posteriorly, and is composed of water 60, soluble albuminous matter 35, insoluble albuminous matter 2.5, fat and cholesterine 2 per cent.; its

Capsule, is transparent, very elastic, and brittle, measuring one-two thousandth of inch in front, one-six thousandth of an inch behind, and is attached anteriorly to lens by a single layer of polygonal nucleated cells, which absorb fluid post-mortem, and breaking down from the *liquor Morgagni*; the

Suspensory ligament or zonula of Zinn, is a thin transparent membrane, containing longitudinal elastic fibres, connecting anterior margin of vitreous with anterior surface of lens near its cir-

cumference, presenting upon its outer surface a number of folds between which fit the similar projections of the ciliary processes ; the

Canal of Petit is about one-tenth of an inch wide, passing around circumference of lens, bounded in front by suspensory ligament, behind by vitreous humor, its base being formed by capsule of lens ; when inflated it becomes sacculated.

What is the structure of the crystalline lens ?

It is formed of numerous laminae, composed of hexagonal fibres one-five thousandth of an inch broad, with serrated margins, those of contiguous fibres accurately fitting one another ; the lens is also divisible after boiling or immersion in alcohol into three triangular segments with their bases outward. The central harder portion is called the *nucleus*, the peripheral portions the *cortex* ; it possesses neither vessels nor nerves.

Describe the muscles of the eyeball.

*Rectus superior*⁴ : *origin*, upper margin of optic foramen and sheath of the optic nerve ; *insertion*, sclerotic coat three to four lines from cornea ; *action*, turns eyeball upward ; *nerve*, third cranial.

*Rectus inferior*⁵ : *origin*, ligament of Zinn ; *insertion*, sclerotic three to four lines from cornea ; *action*, turns eye downward ; *nerve*, third cranial.

Rectus internus : *origin*, ligament of Zinn ; *insertion*, sclerotic three to four lines from cornea ; *action*, turns eye inward ; *nerve*, third cranial.

*Rectus externus*⁶ : *origin*, by two heads, the upper⁸ from the outer margin of optic foramen, the lower⁷ from ligament of Zinn, and a pointed bony process at the lower margin of the sphenoidal fissure ; *insertion*, sclerotic, as other recti ; *action*, turns eye outward ; *nerve*, sixth cranial (abducens) : between the two heads pass the ophthalmic vein, the third, nasal branch of the fifth, and the sixth cranial nerves.

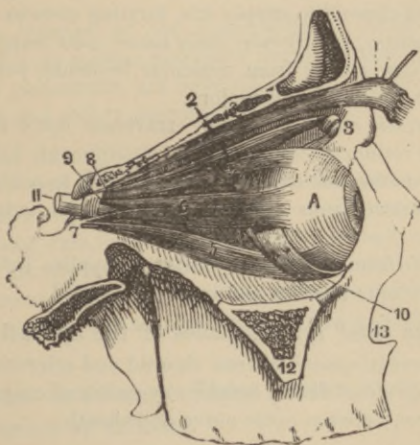
*Obliquus superior*² : *origin*, one line above the inner margin of the optic foramen, terminating in a rounded tendon which plays through a fibro-cartilaginous ring or pulley³ beneath the internal angular process of the frontal bone, whence it passes beneath the superior rectus ; *insertion*, sclerotic between superior and external

recti, midway between the cornea and entrance of the optic nerve; *action*, rotates eye on its antero-posterior axis; *nerve*, fourth cranial (patheticus).

*Obliquus inferior*¹⁰: *origin*, orbital plate of superior maxillary; *insertion*, sclerotic between superior and external recti; *action*, rotates eyeball on antero-posterior axis; *nerve*, third cranial.

(For muscles of lids see pp. 116, 117.)

FIG. 106.



Recapitulate the nerve supply of the ocular muscles.

Third cranial, or motor oculi, supplies superior, internal and inferior recti, and inferior oblique muscles.

Fourth cranial or patheticus, supplies superior oblique muscle.

Sixth cranial or abducens, supplies external rectus muscle.

Describe the vascular supply of the eyeball and its appendages.

(All branches of the vessels not supplying these parts *will be omitted*, having been already described on page 161.)

Ophthalmic, arising from cavernous portion of internal carotid, entering orbit by optic foramen, giving off the

Lachrymal to lachrymal gland, conjunctiva, and upper eyelid, inosculating with palpebral arteries.

Supra-orbital, supplies levator palpebræ and superior rectus muscles.

Superior and inferior palpebral, supply eyelids.

Nasal, supplies lachrymal sac.

Short ciliary, twelve to fifteen in number, penetrate sclerotic around optic nerve entrance to supply choroid and ciliary processes.

Long ciliary, two in number, penetrate sclerotic, pass forward between it and choroid to supply iris, forming *circulus iridis major* near ciliary margin, and *circulus iridis minor*, near margin of pupil.

Anterior ciliary, spring from muscular branches, perforate sclerotic, and join *circulus iridis major*.

Arteria centralis retinae, obliquely traverses optic nerve to be distributed to retina.

Muscular branches, one superior, one inferior, to ocular muscles.

Anterior cerebral, from internal carotid, gives twigs to optic nerve.

Infra-orbital, from internal maxillary, supplies inferior rectus and inferior oblique muscles and lachrymal gland.

What are the chief lymph-spaces of the eyeball?

The *perichoroidal space*, between choroid and sclerotic.

Cavity of capsule of Tenon, between eyeball and capsule.

Vaginal space, between optic nerve and sheath.

What veins return the blood from the eye?

The *superior and inferior ophthalmic* emptying into the cavernous sinus; they also freely anastomose with the facial veins.

Name the nerves of the eye.

Optic or second cranial, nerve of special sense: motor nerves, the *third, fourth, sixth*, and *sympathetic filaments*.

The *Ophthalmic division of fifth*, supplies general sensation by

Lachrymal, to same-named gland, conjunctiva, and skin of upper eyelid; also the following branches:

Frontal	{	<i>Supra-trochlear</i>	; and Nasal	{	<i>Ganglionic.</i>
		<i>Infra-orbital</i>			<i>Long ciliary.</i>
					<i>Infra-trochlear.</i>

The *sympathetic* arises from cavernous and carotid plexus receiving communicating filaments indirectly from spinal nerves, and sending branches to third, fourth, fifth, and sixth nerves; the dilator fibres (radiating) of iris, ciliary ganglion, muscles of orbit and lids, with walls of arteries, receive their sympathetic nerve supply from this source; the

Short ciliary, numbering about ten, arise from ciliary (ophthalmic) ganglion, and pierce the sclerotic posteriorly, to ramify in sheath of optic nerve, choroid, ciliary muscle, iris, and cornea; the

Ascending branches of the sphenopalatine (Meckel's) ganglion, reaching orbit by sphenomaxillary fissure, usually considered to supply only periosteum, are believed by some to go to optic and sixth nerves and ciliary ganglion.

Give a brief description of optic tracts.

The deep origin of the nerve fibres of these tracts are the optic thalami, corpora geniculata, and nates of corpora quadrigemina, which, forming two flattened bands, wind around crus cerebri, to which they are slightly attached, as well as to lamina cinerea and tuber cinereum, and joining in front of latter they form the *optic commissure* (see page 200 for illustration and more elaborate description).

What course do the nerve fibres pursue in the optic commissure or chiasm?

The most numerous, the *decussating* fibres, connect the right hemisphere with the left retina, and the left hemisphere with the right retina, occupying the centre of the commissure.

Other fibres (*longitudinal, cerebro-retinal*) connect each hemisphere with the retina of its own side.

Others (*inter-cerebral*) pass posteriorly, connecting the two optic tracts.

Others (*inter-retinal*) pass anteriorly, connecting the two retinae.

What are the origin and course of the optic nerves?

They arise on either side from the optic commissure, each passes into the orbit through optic foramen with central artery of retina, which pierces it, and enter eyeball through lamina cribrosa one-

tenth inch to nasal side of globe, to aid in forming retina; these nerves are surrounded with a sheath derived from the dura mater between which and nerve is a lymph space communicating with subarachnoid space.

APPENDAGES OF EYE.

(Tutamina Oculi.)

Name these.

<i>Eyebrows, or supercilia,</i>	<i>Lachrymal gland¹ and ducts²,</i>
<i>Eyelids, or palpebræ,</i>	<i>Lachrymal sac,</i>
<i>Conjunctiva^a, a mucous membrane,</i>	<i>Lachrymo-nasal duct.</i>

What are the eyebrows?

The arched eminences of skin surmounting upper margins of orbits on each side, from which grow several rows of short, obliquely placed hairs; by the attached muscles the eyebrows can partially shut off light from eyes.

What are the eyelids?

Two movable curtains protecting by their closure the eyes from injury; the upper lid is the larger and more movable, having its own elevator muscle; the

Palpebral fissure is the elliptical space between the margins of lids when opened, the internal and external angles being called, respectively, the *internal* and *external canthus*, the former being prolonged inward, leaving a triangular space between the lids, the *lacus lachrymalis*, at the commencement of which is a small elevation on each lid, the *lachrymal papilla³*, whose summit is pierced by a minute opening, the *punctum lachrymale³*, the commencement of the lachrymal canal.

What structures form the eyelids?

Externally the skin, beneath which is much loose areolar tissue, separating it from the fibres of the *orbicularis palpebrarum muscle*. The lids retain their shape by means of the so-called *tarsal carti-*

lages—in reality dense connective tissue *without* cartilage cells—that for the upper lid being semilunar and the larger, that for lower lid elliptical; these structures are connected at their orbital margins with the circumference of the orbit by a fibrous membrane, the *tarsal ligaments*, while in addition a rounded fibrous cord, the *tendo-oculi*, passes between the inner angle of each and the nasal process of superior maxillary bone.

Imbedded in the cartilages are numerous sebaceous glands, the *Meibomian glands*, discharging their secretion upon the free edge of lids, preventing their adhesion; they number thirty or forty in the upper lid, fewer in the lower lid.

Attached to the free margins of lids is a double or triple row of stiff hairs, curved in each lid so that their convexities meet, preventing interlacing, these are the *cilia*, or *eyelashes*; the inner surfaces of lids are lined by a mucous membrane, the *conjunctiva*.

Their *vascular supply* is from the *palpebral* branches of ophthalmic artery anastomosing with contiguous branches of facial.

The *nerves* are the third, seventh, and sympathetic to muscles, the ophthalmic branch of fifth to skin and conjunctiva.

Describe the conjunctiva.

It is a mucous membrane lining the inner surfaces of the eyelids and reflected thence upon anterior segment of sclerotic, its epithelial layer passing over cornea; the

Palpebral conjunctiva is thick, opaque, vascular, and covered with papillæ, containing numerous glands; at the inner angle of the eye it forms a semilunar fold, the *plica semilunaris*⁴ (Fig. 108). The folds formed by the passage of the conjunctiva from lids to eyeball are called the *superior* and *inferior palpebral folds*, the former being the deeper; they contain numerous convoluted mucous glands; the

Ocular conjunctiva is thin, transparent, possesses few vessels in health, and is loosely attached to globe by the subconjunctival areolar tissue.

What is the caruncula lachrymalis⁵ (Fig. 108)?

It is a small, conical, reddish body, at inner canthus, occupying the space called the lacus lachrymalis, and is formed of a group of follicles, resembling the Meibomian glands, covered with conjunctiva; from the caruncle project a few slender hairs.

Describe the lachrymal apparatus.

It consists of the lachrymal gland with its ducts, the canaliculi, the lachrymal sac, and the nasal duct. The

*Lachrymal gland*¹ (Fig. 107) is an oval, compound racemose gland of the size and shape of an almond, lodged in a depression at upper, outer portion of orbit, its concave under surface resting upon the globe of eye, the conjunctiva, superior and external recti muscles intervening; it is held in contact with orbital periosteum by a few fibrous bands. It has six or seven

FIG. 107.

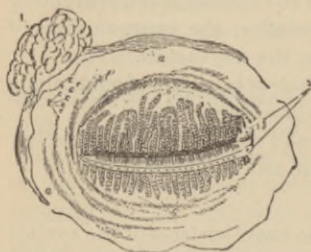
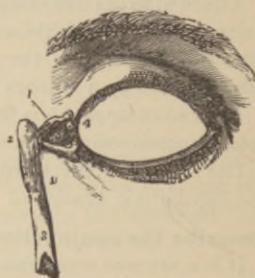
FIG. 108.



*Ducts*² (Fig. 107), opening by minute orifices on upper outer half of palpebral conjunctiva near superior retro-tarsal fold. The secretion, or the

Tears, are taken up by the puncta, thence passing through canaliculi into lachrymal sac and nasal duct, thus reaching inferior meatus of nose.

Describe the canaliculi.

They are two minute canals¹ about one-half a line in diameter, commencing at the puncta, the superior passing upward, then bending acutely to pass inward to lachrymal sac, the inferior passing downward, then upward and inward; they are lined with mucous membrane continuous with conjunctiva, and are one-third of an inch long.

What is the lachrymal sac² (Fig. 108) ?

It is the flattened, ovoidal, sacciform dilatation of upper part of nasal duct, lodged in the groove formed by lachrymal bone and nasal process of superior maxillary; its walls are formed of fibrous elastic tissue covered in by tensor tarsi muscle and a fibrous expansion from tendo-oculi attached to ridge of lachrymal bone, while internally it is lined with mucous membrane.

Describe the nasal duct³.

It is a membranous canal about three-fourths of an inch long extending from the termination of lachrymal sac through osseous nasal duct to inferior meatus of nose, passing in a direction downward, backward, and slightly outward, its lumen being narrowest about the midpoint; externally, it is composed of fibro-areolar tissue; internally, of mucous membrane continuous with that of nose and lachrymal sac, the epithelial coating of both being of ciliated epithelium, that of the canaliculi of scaly cells.

What is the valve of Hasner ?

An imperfect valve of mucous membrane guarding the somewhat expanded terminal opening of the duct into the inferior meatus of nose.

The Ear.**Where is the auditory apparatus lodged ?**

In the petrous and mastoid portions of the temporal bone.

Enumerate the divisions.

The <i>External ear</i> , comprising the	{	<i>Auricle</i> , or <i>pinna</i> ,
		<i>External auditory canal</i> .
<i>Middle ear</i> , or <i>tympanum</i> , comprising	{	<i>Membrana tympani</i> ,
		<i>Cavity of tympanum</i> ,
		<i>Mastoid cells</i> ,
		<i>Eustachian tube</i> ,
<i>Internal ear</i> , or <i>labyrinth</i> , comprising	{	<i>Vestibule</i> ,
		<i>Semicircular canals</i> ,
		<i>Cochlea</i> ,
		<i>Auditory nerve</i> .

The External Ear.

What is the auricle ?

Its foundation is an expanded layer of fibro-cartilage, so disposed in ridges as to concentrate and direct the waves of sound into the external auditory canal, to which it is attached ; the cartilage is deficient at certain points where it is connected by fibrous tissue ; it is covered with perichondrium, outside of which is thin, firmly adherent skin, containing sweat and sebaceous glands, and provided with short downy hairs. The various ridges and depressions are as follows : the

Concha, the deep cavity leading into meatus ; the

Tragus, the pointed prominence in front of concha projecting back over meatus, bearing on its under surface tufts of hairs ; the

Antitragus, a small tubercle opposite tragus, separated by a deep notch, the *incisura intertragica* ; the

Helix, the external prominent margin of auricle ; the

Antihelix, a parallel prominence anterior to former, bifurcating above to form the

Fossa of the antihelix ; the

Fossa of helix, the narrow, curved depression between the helix and antihelix.

What is the lobe or lobule of the ear ?

The inferior, soft pendulous portion, formed of fat and connective tissue enclosed by integument.

Describe the muscles of the external ear.

The *attolens aurem*, *attractans aurem*, and *retractans aurem*, have been described on page 116.

The muscles of the auricle, but slightly developed in man, are the

Helicis major : a narrow, vertical band on anterior border of helix ;

Helicis minor : an oblique band at root of helix ;

Tragicus. a short, vertical band on outer surface of tragus ;

Antitragicus : stretching from outer part of antitragus to lower part of helix ;

Transversus auriculæ : radiating from posterior surface of convexity of concha to prominence caused by groove of helix ;

Obliquus auris : a few fibres passing from upper back part of concha to convexity immediately above.

Give the vascular and nervous supply to the auricle.

The arteries are *Posterior auricular*, from external carotid.

Anterior auricular, branch of temporal.

Auricular, branch of occipital.

The *veins* accompany the corresponding arteries.

The nerves are, *Auricularis magnus*, from cervical plexus.

Posterior auricular, from facial.

Auricular branch (Arnold's) of pneumogastric.

Auriculo-temporal, from inferior maxillary division of fifth nerve.

Occipitalis major and *minor*.

What is the external auditory canal ?

It is an osseo-cartilaginous, oval, cylindrical canal, with greatest diameter vertical at external orifice, but reversed at tympanic end; it is narrowest at middle. About one and a quarter inches long, it is directed obliquely forward and inward, and slightly curved with convexity upward, and is lined by thin adherent skin, containing hair follicles, sebaceous and ceruminous glands in its cartilaginous portion. A narrow groove at the tympanic extremity, for insertion of *membrana tympani*, is sometimes called the *sulcus tympanicus*, interrupted above by the *notch of Rivinus*.

What are the arteries and nerves ?

The *arteries* are branches of posterior auricular, internal maxillary and temporal.

The *nerves* come chiefly from auriculo-temporal branch of superior maxillary division of fifth nerve.

The Middle Ear or Tympanum.

Describe the *membrana tympani*.

It forms the outer wall of the tympanum, and is an oval, translucent membrane placed obliquely at the bottom of external audi-

tory meatus, with its anterior, shallow funnel-shaped surface facing downward, forward, and outward; at its upper anterior border is a white, pointed *tubercle*, formed by the short process of the malleus, while a yellowish-white stripe passing from this downward and backward toward the centre, indicates the handle of the malleus. During life, when illuminated, the membrana tympani presents a triangular *light spot* or "*cone of light*," having its apex at end of malleus handle, whence it spreads downward and forward, and a darker central portion, the *umbo*, or shadow. The upper anterior part bridging a small notch in the bony ring to which the membrane is attached (the notch of Rivinus), is laxer, consisting of loose connective tissue, vessels, and nerves, covered with skin and mucous membrane, and has received the name of the *membrana flaccida*, or *Shrapnell's membrane*.

Of what tissues is the membrana tympani composed?

Of the skin, which is derived from the lining of the meatus; of a fibrous layer, some of whose fibres radiate from near the centre to the circumference, others form a dense ring around the attached margin; and of mucous membrane, derived from that lining the tympanum. The handle of the malleus passes between the inner and middle layers—according to von Tröltsch, it is received *between* the circular and radiating fibres of the middle coat; an *anterior* and a *posterior pouch* have also been described upon the posterior surface by von Tröltsch, opening downward, formed by a "duplication of the membrana tympani extending from its border forward to the manubrium."

Describe the arterial supply of the membrana tympani.

The *deep auricular* branch of internal maxillary supplies the external layers forming a plexus, which communicates at the periphery with one in the mucous membrane formed from

Tympanic branches of internal maxillary and internal carotid arteries, and by the

Vidian, from internal maxillary, and

Stylo-mastoid, from posterior auricular.

Mention the nerves supplying the membrana tympani.

To the external layer run filaments from the *superficial temporal* branch of the fifth, while the mucous layer is supplied by the *tympanic plexus*.

The Tympanum.

Describe it.

It is an irregular cavity, measuring about one-half of an inch antero-posteriorly, one-third of an inch vertically, and one-fifth of an inch transversely, situated in the petrous bone, compressed from without inward, being placed above the jugular fossa, having the carotid canal in front, the mastoid cells behind, the external meatus externally, and the labyrinth internally; it communicates with the pharynx by the Eustachian tube, and presents for examination the following points; the

Roof, a very thin plate of bone, indicated on cranial surface by a depression on posterior surface of petrous portion of temporal bone; the

Floor, narrow, corresponding to jugular fossa, and presenting near inner wall a small *foramen for Jacobson's nerve*; the

Outer wall, the membrana tympani and bony ring to which it is attached, presenting three small orifices, the

Iter chordæ posterius, opening in angle of junction between posterior and external walls, just behind membrana tympani on a level with its centre, for entrance of chorda tympani nerve; the

Glaserian fissure, just above and in front of bony ring giving origin to membrana tympani, for passage of laxator tympani muscle and some tympanic vessels, and the lodgement of the long process of malleus; the

Iter chordæ anterioris or *canal of Huguier*, opening just above preceding, for escape of chorda tympani nerve; the

Inner wall is vertical, looking directly outward, and presents the

Fenestra ovalis or *oval window*, a kidney-shaped opening leading into vestibule, closed by base of stapes with its ligament; the

Fenestra rotunda or *round window*, below, at bottom of a funnel-shaped depression, opening into scala tympani of cochlea, closed by the *membrana tympani secundaria*; the

Promontory, a rounded hollow eminence—the first turn of the cochlea—situated between oval and round windows, and presenting three grooves lodging branches of tympanic plexus; the

Eminence of the aquæductus Fallopii, passes above oval window,

along inner tympanic wall, to curve behind that opening nearly vertically downward along posterior wall; the

Pyramid, a hollow conical projection, behind the oval window and in front of vertical portion of aquæductus Fallopii, containing the stapedius muscle whose tendon escapes from its summit; a minute canal communicates with the aquæductus Fallopii transmitting the nerve to stapedius muscle; the

Posterior wall, presenting the

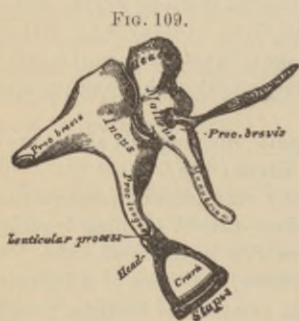
Openings of the mastoid cells, one large and several smaller openings. The anterior wall, is wider above than below, corresponding with carotid canal, the thin bony partition being perforated by tympanic branch of carotid; it presents the

Orifice of the canal for the tensor tympani muscle, which is situated above, close to aquæductus Fallopii, on the summit of a small conical eminence, *the anterior pyramid*; the

Opening of Eustachian tube, is immediately below preceding, separated by a thin horizontal bony plate, the *processus cochleariformis*.

What are the ossicles of the tympanum?

Three bones forming a movable chain, passing between membrana tympani and oval window, called the



Malleus or *hammer*, consisting of an oval *head* articulating with incus, a *neck*, a *manubrium* or handle, affording attachment near its root to tensor tympani muscle, a *short process* coming in contact with membrana tympani, and a *processus gracilis* or long process, lodged in the Glaserian fissure, and giving attachment to so-called laxator tympani muscle; the

Incus or *anvil*, having a body articulating with malleus, a *long process* terminating in a rounded end, the *os orbiculare*, which articulates with head of stapes, and a *short process* attached to margin of opening into mastoid cells; the

Stapes or stirrup, consists of a *head* articulating with os orbiculare, a *neck* receiving insertion of stapedius muscle, two branches or *crura* joining the oval *base*, which latter is connected with margins of oval window by ligamentous fibres.

Describe the ligaments of the ossicles.

The *suspensory ligament of the malleus*, passing between tympanic roof and head of malleus: the

Posterior ligament of malleus, or laxator tympani minor muscle of Sömmering, passing from upper back part of external meatus to handle of malleus and processus brevis; the

Posterior ligament of the incus, passing between posterior tympanic wall near margin of opening into mastoid cells and end of short process of incus; the

Suspensory ligament of the incus, descending from tympanic roof to incus, near its articulation with malleus; the

Annular ligament of stapes, connecting circumference of its base to margins of oval window; the

Capsular ligaments, around articulations between incus and malleus, and incus and stapes, these joints having their surfaces coated with cartilage, and being provided with a synovial membrane.

Other ligaments have been described under special names, as the anterior and external ligaments of the malleus, and the *obturator ligament* of the stapes, this latter being a membrane filling up opening between crura of stapes.

Describe the muscles of the tympanum.

Tensor tympani: *origin*, under surface of petrous bone, cartilaginous Eustachian tube, its own osseous canal; *insertion*, handle of malleus near root; *action*, draws membrana tympani inward—*i. e.*, increases *tension*; *nerve*, from otic ganglion.

Laxator tympani major: *origin*, spinous process sphenoid bone, and cartilaginous Eustachian tube; *insertion*, neck of malleus above processus gracilis; *action*, relaxes membrana tympani; *nerve*, tympanic branch of facial. (Now called *ant. ligament of malleus*.)

Laxator tympani minor: *origin*, upper back part external meatus; *insertion*, handle of malleus and processus brevis; *action*, relaxes membrana tympani. (Now called *posterior ligament of malleus*.)

Stapedius: *origin*, from interior of pyramid; *insertion*, neck of stapes; *action*, compresses contents of vestibule; *nerve*, filament of facial.

Describe arterial supply of the tympanum.

The *tympanic branch* of the internal maxillary enters by Glaserian fissure and is distributed to membrana tympani (tympanic branch of carotid also supplies this), anastomosing with *Vidian* and

Stylo-mastoid, from posterior auricular to back part of tympanum and mastoid cells.

Petrosal, from middle meningeal, entering through hiatus Fallopii.

Tympanic, from internal carotid.

Vidian, from internal maxillary.

Branch, from ascending pharyngeal passing up Eustachian tube.

What nerves supply the tympanum ?

The *Tympanic branch of the glosso-pharyngeal* (Jacobson's nerve), which pierces floor of tympanum to supply fenestræ and mucous membrane, and aids in forming *tympanic plexus*; the

Tympanic branch of facial, supplying stapedius muscle; the

Branch from otic ganglion, supplying tensor tympani muscle.

(The *chorda tympani from facial*, passing into tympanum by iter chordæ posterius, emerging by iter chordæ anterius, arching across cavity between handle of malleus and long process of incus; it is covered by mucous membrane and gives off no branches.)

Describe the formation of the tympanic plexus.

The tympanic branch of glosso-pharyngeal, or Jacobson's nerve, divides into three branches, lying in grooves on the promontory, one passes forward and downward to join *carotid plexus*, another passes upward to join *greater superficial petrosal nerve* in hiatus Fallopii, the third passes upward and forward through petrous bone close to ganglionic enlargement of *facial*, from which it receives a filament, and becomes the *lesser superficial petrosal nerve*; the tympanic mucous membrane is supplied by branches from this plexus.

Describe the Eustachian tube.

It is about one and one-half inches long, passing downward, forward, and inward, the passage by which the air in the middle ear freely communicates with that in the pharynx, thus permitting free vibration, as the hole in the side of a drum does. It consists of about one-third bone, and two-thirds fibro-cartilage and fibrous tissue; the tympanic orifice measures about one and one-half inch, the oval pharyngeal opening one-third inch.

The *osseous portion*, is one-half inch long, commencing at lower part of anterior tympanic wall, gradually narrowing to terminate at angle of junction of petrous and squamous portions of temporal bone; the

Cartilaginous portion is about one inch long, formed by a triangular plate of elastic fibro-cartilage curved upon itself into a partial tube, but inferiorly the margins are not in contact, the defect being filled by fibrous tissue; the

Mucous membrane is continuous with that of pharynx, and is covered by ciliated epithelium.

Where is the pharyngeal orifice situated ?

At upper lateral portion of pharynx behind posterior part of inferior meatus, just above the level of nasal floor.

Has this tube any special muscles ?

Yes, the following have been described :

Spheno-salpingo-staphylinis: *origin*, sphenoid bone and cartilaginous tube; *insertion*, convex external border of cartilage; *nerve*, internal pterygoid; *action*, abductor or dilator of tube.

Salpingo-pharyngeus: a thin layer beneath mucous membrane, probably really a fascia.

(The *Levator palati*: *origin*, temporal bone and cartilaginous tube; *nerve*, pneumogastric; *insertion*, osseous tube, cartilage, and mucous membrane; *action*, dilates tube transversely.)

Give the arterial supply of the Eustachian tube ?

The *ascending pharyngeal*, from external carotid.

Branches of middle meningeal, from internal maxillary.

Branch, from *stylo-mastoid artery*.

The *nerves* are, in addition to those supplying muscles of tube (supra), from the *fifth* and *seventh* pairs and *glosso-pharyngeal*.

The Internal Ear or Labyrinth.

Name its divisions.

The <i>osseous labyrinth</i> , consisting of	{	<i>Vestibule</i> ³ (Fig. 110), <i>Semicircular canals</i> ^{5, 6, 7} , <i>Cochlea</i> ⁸ .
<i>Membranous labyrinth</i> , consisting of	{	<i>Utricl</i> e, <i>Membranous semicircular</i> <i>canals</i> , <i>Saccule</i> , <i>Membranous cochlea</i> .

Internal auditory canal, at bottom of which the auditory nerve enters.

Auditory nerve (eighth cranial, or portio mollis of seventh), with the

Organ of Corti, what the retina is to the eye, viz., the terminal and receptive auditory apparatus.

Describe the internal ear.

It is formed by a series of cavities excavated in the petrous bone, communicating externally with middle ear by the round and oval windows, internally, with internal auditory meatus: within the osseous labyrinth, surrounded by the

Perilymph, is the *membranous labyrinth*—filled with endolymph—upon which the auditory nerve filaments are distributed.

Describe the various subdivisions of the osseous labyrinth.

The *vestibule* is the common central cavity with which all parts of the internal ear communicate, placed behind cochlea in front of semicircular canals, at inner side of tympanum; it is ovoid, measuring about one-fifth of an inch from before backward, as well as from above downward, and presents the

Fenestra ovalis, or *oval window*, on its outer wall, closed in the fresh state by base of stapes and its ligament; the

*Fovea hemispherica*², a small, circular depression on its inner wall, perforated antero-inferiorly by several minute foramina for branches of auditory nerve, the perforated plate, called the *macula cribrosa*; the

Pyramidal eminence, a vertical ridge behind *macula cribrosa*; the

Aqueductus vestibuli, at back of inner wall, transmitting a small vein, and, according to some, containing a tubular prolongation of lining membrane of vestibule, ending in a blind end in cranial cavity between layers of dura mater; the

*Fovea semi-elliptica*¹, a transversely-oval depression on roof, separated by pyramidal eminence from *fovea hemispherica*; the

*Orifices of semicircular canals*³, these are five in number, opening behind; the

Apertura scalæ vestibuli cochleæ, a large oval opening, is situated anteriorly.

Describe the semicircular canals^{5, 6, 7}.

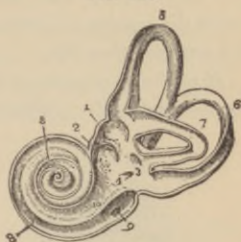They are three curved bony tubes, each describing the greater part of a circle, of unequal length, of a diameter of about one-twentieth of an inch, each lying at a right angle to the other two, and presenting at one end a dilatation, or *ampulla*, more than double the diameter of the tube; the

*Superior semicircular canal*⁵ is vertical, describes about two-thirds of a circle, passes at right angles to posterior surface of petrous bone, and forms a projection upon its anterior surface; its outer end is its *ampulla*, opening separately into vestibule; its inner undilated extremity joins with that of the

*Posterior semicircular canal*⁶, opening by a common orifice at back of vestibule; this canal is also vertical, is nearly parallel to posterior surface of petrous bone, is the longest, the dilated extremity opening at lower back part of vestibule; the

*External, or horizontal semicircular canal*⁷, is the shortest, is directed outward and backward, is ampullated, and opens into vestibule just above oval window, its other extremity by a separate orifice at upper back part of vestibule.

FIG. 110.



The *cochlea*^s is conical, somewhat resembles a snail-shell, forms the anterior part of the labyrinth, is placed almost horizontally in front of the vestibule, its apex directed toward the upper front part of tympanic wall, and its base corresponding to anterior perforated depression at bottom of internal auditory meatus; it presents for examination the

Modiolus, a central, conical axis, perforated by numerous canals for filaments of cochlear branch of auditory nerve, its apex terminating in a delicate expanded

lamella, like a funnel divided longitudinally, called the *infundibulum*; extending from base to apex is a canal, the *canalis centralis modioli*, for a small nerve and artery; making two and one-half spiral turns around the modiolus is the

Spiral canal^s, about one-tenth of an inch in diameter, and one and a half inches long, narrowing from base to apex, there forming the

cupola, where the *scala tympani* and *scala vestibuli*, formed by the *lamina spiralis*, communicate by the *helicotrema*.

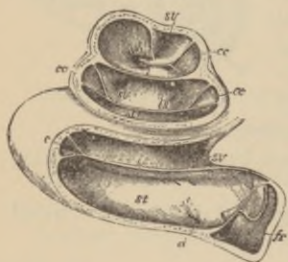
The *cochlea* presents three openings, viz., the round window, communicating with tympanum, the oval one opening into vestibule, and that of the *aquæductus cochleæ*⁹; projecting from the modiolus is the

Lamina spiralis osseal^s, a process formed of two bony lamellæ, between which are numerous canals for nerve fibres, defective in last half turn of cochlea leaving an aperture, the *helicotrema*, and terminating by the hook-like *hamular process*^h; winding around the modiolus at the point of attachment of the *lamina spiralis* is the *canalis spiralis modioli*, lodging the enlargement of the cochlear nerve containing ganglion cells, called the *ganglion spirale*, whence come the nerve branches to the organ of Corti.

What is the *scala vestibuli*^{s. v.} (Fig. 111)?

It is that portion of the canal of the cochlea above the *lamina spiralis* and membrane of Reissner, communicating with vestibule

FIG. 111.



below and scala tympani above, by the helicotrema; it is filled with perilymph.

Describe the scala tympani^{s. t.}.

It is that portion of the spiral canal below the lamina spiralis^{l. s.} and membranous cochlea, terminating below inferiorly at the round window—which is closed by membrane, the *membrana tympani secundaria*—and communicating above with scala vestibuli at helicotrema; it is filled with perilymph.

What is the aquæductus cochleæ^{d?}

A small canal transmitting a vein from cochlea to jugular vein, commencing at lower wall of scala tympani, and ending to inner side of carotid canal close to posterior surface of petrous bone.

Describe and name the subdivisions of the membranous labyrinth.

It consists of a series of closed membranous sacs containing *endolymph*; its various parts are called

The *vestibule*, consisting of the $\left\{ \begin{array}{l} \text{Utricule,} \\ \text{Saccule,} \end{array} \right\}$ two membranous sacs, with the former of which communicate three

Membranous semicircular canals.

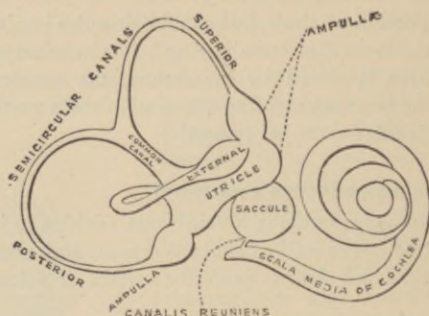
The utricle and saccule are separate, but are indirectly connected by a minute canal passing from saccule to the similar one from utricle, passing along aquæductus vestibuli to end by a blind pouch near posterior surface of petrous bone; the saccule communicates with scala media (or membranous cochlea) by the *canalis reuniens*. The endolymph in all parts is thus seen to communicate freely.

Describe the utricle.

It is an oblong, laterally compressed sac, filled with endolymph, placed in upper back part of vestibule in fovea semielliptica, communicating behind with semicircular canals by five openings, and has distributed, chiefly at one part of its walls, numerous branches of the auditory nerve, at which point is a round mass of minute crystals of calcium carbonate, bound together by delicate fibrous tissue forming the *otoliths*, *otoconia*, or *ear-stones*; the thickening of

the wall both of utricle and saccule, where the nerves penetrate, is sometimes called the *macula acustica*.

FIG. 112.

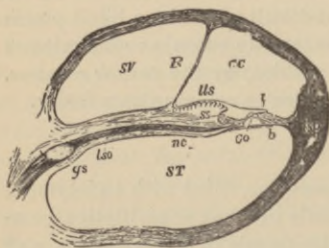


What are the membranous semicircular canals?

They are three canals of the same shape but smaller than the containing osseous canals, to which they are fastened by numerous fibrous bands, conveying the auditory nerve filaments to the ampullæ; like the osseous canals they have five orifices which open into the utricle.

Describe the saccule.

FIG. 113.



It is a globular sac, smaller than utricle, to which it is attached at one point, and lies in fovea hemispherica; it is surrounded with perilymph, and indirectly communicates by a short canal with utricle by means of the blind canal passing along aquæductus vestibuli to terminate near posterior surface of petrous bone; and with membranous cochlea or *scala*

media by *canalis reuniens*, a small passage connecting the two cavities.

What is the membranous cochlea^{cc} (Fig. 113).

More usually called *scala media* or *ductus cochlearis* (Fig. 113)

it begins by a blind extremity at lower anterior portion of vestibule, enters cochlea, where it forms in cross section a triangular canal, its base being outer bony walls of cochlea, its lower wall the *membrana basilaris*^b, its upper the *membrane of Reissner*^r; it is filled with endolymph and contains the *organ of Corti*^{co}, covered by the delicate *membrana tectoria*^t parallel with basilar membrane^b. The periosteum on upper surface of osseous spiral lamina forms an elevation, the

Limbus laminae spiralis^{ls}, which presents an upper and lower margin called respectively the *labium vestibulare* and *labium tympanicum*, the groove formed between these being termed the *sulcus spiralis*^s.

What is the membrane of Reissner^r?

A delicate membrane stretched between outer wall of cochlea and periosteum of vestibular surface of osseous spiral lamina near commencement of *limbus laminae spiralis*^{ls}, forming the upper wall of membranous cochlea.

What is the membrana basilaris^b?

A thin membrane passing from *labium tympanicum* to bony wall of cochlea, where it expands into the triangular *ligamentum spirale*^{sp}. It forms the lower wall of membranous cochlea, supporting on its upper surface the organ of Corti^{co}.

Describe the membrana tectoria or membrane of Corti^t.

A delicate membrane passing from between *labium vestibulare* and attachment of the membrane of Reissner^r to outer wall of cochlea, running nearly parallel with basilar membrane^b; some contend that it is free, resting upon the organ of Corti^{co}, and in its fresh pulpy condition serves as a damper of vibrations.

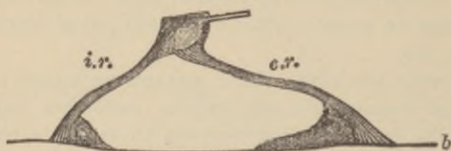Describe the organ of Corti^{co}.

It consists of a complex body formed by a series of some three thousand arches roofing over a space called the *zona arcuata*, formed of rods and epithelial hair cells, lying upon the *membrana basilaris*^b and covered by the *membrana tectoria*^t; the

Rods of Corti are disposed in two rows, the *inner*^{ir} and *outer*^{or} rods, each rod with its swollen base resting upon the basilar membrane^{bb}, and its expanded upper end inclined toward and in contact with the opposite one, forming an arched canal filled with

endolymph; according to Waldeyer there are about six thousand rods in the inner row, and four thousand five hundred in the outer; a nucleated mass of protoplasm occupies the angle between the base of each rod and the basilar membrane; the

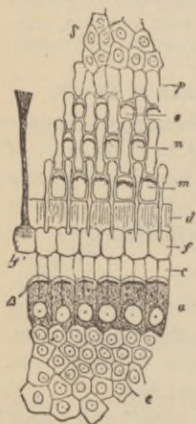
FIG. 114.



Hair cells^a (Fig. 115) are epithelial cells with stiff hair-like cilia^β disposed in three or four rows upon the superior surfaces of the outer rods^m to the number of about eighteen thousand, and in a single row upon inner rods^{cd} numbering about thirty-three hundred; the

Lamina reticularis (Fig. 115) is formed of several rows of small fiddle-shaped cuticular structures called *phalanges*, connected together and to heads of outer rods, forming rings^{mno}, through which project the hairs of the outer hair cells.

FIG. 115.



Where does the auditory nerve arise and to what parts of the ear is it distributed?

Its *superficial origin* is from groove between olivary and restiform bodies at lower border of pons; its *deep origin* is threefold (1) from superior vermiformis process of cerebellum, and from (2) inner and (3) outer auditory nuclei formed chiefly by gray substance of posterior pyramid and restiform body, from which latter it receives fibres as it winds around it. Entering with facial nerve the internal auditory canal, at its bottom it divides into the *cochlear* and *vestibular branches*,

both of which contain numerous ganglion cells; the

Vestibular division divides into three branches, the superior

splitting into many filaments which pass through upper back part of bottom of meatus, enter the vestibule through macula cribrosa to be distributed to utricle and ampulla of external and superior semicircular canals; the middle branch passes through the openings of the fovea hemispherica to supply the saccule; the inferior passes to ampulla of posterior semicircular canal; the

Cochlear nerve divides into numerous filaments at base of modiolus which enter its canals, pass between the two plates forming the lamina spiralis, forming a plexus which contains ganglion cells, and sends branches, it is thought, to communicate with the hair cells; the

Intumescencia ganglioniformis Scarpæ is the gangliform swelling on the vestibular branch in the internal auditory canal; the

Ganglion spirale is the gangliform enlargement on the cochlear nerve as it occupies the *canalis spiralis modioli*.

Give the arterial supply of the labyrinth ?

The *internal auditory*, a branch of basilar artery, enters with nerve the internal auditory canal, there to divide into a *vestibular* and *cochlear branch*; the

Stylo-mastoid, from posterior auricular; occasionally

Branches from occipital.

What is the internal auditory canal ?

A canal about one-third of an inch long, passing outward from posterior surface of petrous portion of temporal bone to end in a cribriform partition perforated with numerous foramina, some of them arranged in a spiral-shaped depression, the

Tractus spiralis foraminulentus, others in three groups in as many depressions; at the upper part is the commencement of the aquæductus Fallopii for the seventh or portio dura nerve.

Anatomy of Inguinal Hernia.

What is the inguinal canal ?

The canal passing downward and inward for one and a half inches which lodges the spermatic cord in the male, the round ligament in the female, pursuing a course parallel to Poupart's

ligament through or between the abdominal muscles, commencing at internal abdominal ring and terminating at the external abdominal ring.⁸

Describe the internal abdominal ring.

It is an ovoidal opening in the transversalis fascia¹³ midway between anterior superior iliac spine and spine of pubes, and about half an inch above Poupart's ligament⁶. It is bounded above and externally by arched fibres of transversalis muscle¹⁰, below and internally by epigastric vessels¹³; from its circumference passes the *infundibuliform fascia* on to the spermatic cord or round ligament.

What is the external abdominal ring⁸?

An obliquely triangular opening in the aponeurosis² of external oblique muscle¹, just above and to outer side of crest of pubes; from base to apex it averages one inch by half an inch transversely. It is bounded below by the crest of pubes, above by the curved aponeurotic *intercolumnar fibres*⁷, and on each side by the free borders of the aponeurosis called the *internal*⁵ and *external columns*⁶ of the ring; from the margins of the ring passes on to the cord or round ligament, the *intercolumnar fascia*.

Give the boundaries of the inguinal canal.

Anteriorly, the skin, superficial fascia, aponeurosis of external oblique, and outer third of internal oblique muscles.

Posteriorly, the triangular ligament, conjoined tendon¹¹ of internal oblique and transversalis muscles, transversalis fascia¹³, subperitoneal fat, and peritoneum.

Superiorly, the arched fibres of internal oblique¹⁰ and transversalis muscles.

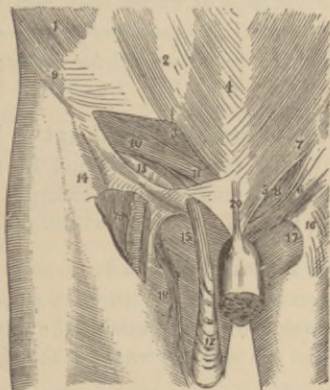
Inferiorly, the union of the transversalis fascia¹³ and Poupart's ligament⁶.

What is Poupart's ligament⁶?

The infolded, thickened margin of aponeurosis of external oblique muscle, extending from anterior iliac space⁹ to spine of pubes, from which it is reflected a short distance along the pectineal line, forming *Gimbernat's ligament*, while a triangular band of tendinous fibres attached by its apex to the reflected portion of Poupart's

ligament along the pectineal line, passing inward beneath spermatic cord behind the inner pillar in front of the conjoined tendon, and interlacing with its fellow at the linea alba, is called the *triangular ligament*: the lower part of Poupart's ligament forms the external pillar of the external abdominal ring⁶.

FIG. 116.



Describe the relations of the epigastric artery and the internal abdominal ring.

It passes between the transversalis fascia and the peritoneum along the lower inner margin of internal ring beneath the spermatic cord.

What is the cremasteric fascia?

A series of muscular loops connected by areolar tissue investing the spermatic cord, supposed to have been derived from the internal oblique muscle during the descent of the testicle, and, of course, absent in the female.

What is Hesselbach's triangle?

A triangular space at lower part of inner surface of abdominal wall, bounded externally by the epigastric artery, internally by margin of rectus muscle, and below by Poupart's ligament: the conjoined tendon stretches across the inner two-thirds of this space, the remainder being filled in by the transversalis fascia.

What is an oblique inguinal hernia ?

A protrusion of bowel, omentum, or both, following the course of the spermatic cord in the inguinal canal through both internal and external rings (*when complete*), the neck of the sac being to *outer* side of epigastric artery.

What are the coverings of an oblique inguinal hernia ?

*Skin; superficial fascia; intercolumnar fascia; cremaster muscle*¹²; *infundibuliform fascia; subserous cellular tissue; and peritoneum forming sac.*

Where is the seat of stricture most apt to be ?

(1) At internal ring, (2) inguinal canal by fibres of internal oblique or transversalis muscles, (3) at external ring, provided it is not at thickened neck of sac, the most usual site in *old herniæ*.

What is a direct inguinal hernia ?

One where the protrusion passes through some part of Hesselbach's triangle, passing directly through the external abdominal ring, the neck of the sac being *internal* to the epigastric vessels.

What coverings has a direct hernia ?

The same as an oblique, except that the *transversalis fascia* take the place of the *infundibuliform fascia*, and the *conjoined tendon* is substituted for the cremasteric fascia, but this latter covering is probably a *theoretical*, not an actual one.

Femoral Hernia.**Describe the femoral or crural canal.**

It lies beneath Poupart's ligament⁶, to inner side of femoral vein¹⁹, extending from *femoral ring* above to *saphenous opening*¹⁷ below: it is about half an inch long, closed above by the *septum crurale*, formed of condensed areolar tissue, and below by the *cribriform fascia*, a portion of the deep layer of the superficial fascia covering the saphenous opening: the

Femoral or crural ring is an oval space between femoral vein and Gimbernat's ligament, half an inch in diameter, larger in female

than in male, situated below and external to internal abdominal ring: it is closed by the septum crurale and a lymphatic gland; the

*Saphenous opening*¹⁷ is an ovoidal opening one and a half inches long by half an inch wide, below inner portion of Poupart's ligament⁶, formed by the pubic portion¹⁷ of fascia lata passing behind the saphenous vein leaving a margin concave outward, while continuous with it is a strong falciform process, the iliac portion of the fascia lata, the *falciform process of Burns*¹⁶, passing in front of the vein, its narrow pubic portion blending with the attachment of Poupart's and Gimbernat's ligaments; this is called *Hey's ligament*¹⁶: the opening is covered in by the *cribriform fascia*.

Bound the femoral canal.

Anteriorly, lie the transversalis fascia¹³, Poupart's ligament⁶, and falciform process of fascia lata¹⁶;

Posteriorly, iliac fascia, covering pubic portion of fascia lata;

Externally, the fibrous septum separating it from femoral vein;

Internally, the junction of the processes of the transversalis and iliac fasciæ forming femoral sheath lying against outer edge of Gimbernat's ligament.

Describe the position of parts around the ring.

The *Spermatic cord* in male, the *round ligament* in female, lie just above anterior margin; the

*Femoral vein*¹⁹ lies upon its outer side; the

Epigastric artery crosses upper outer angle of ring; the

Obturator artery once in three and a half cases arises in common with epigastric, when it closely skirts around the upper and inner margins of the ring.

Describe the septum crurale.

It is a layer of condensed cellular tissue upon which lies a small lymphatic gland, closing the femoral ring.

What is the crural sheath?

It is a continuation downward of the fascia transversalis in front, and of the iliac fascia behind the femoral vessels forming their sheath, divided by septa into separate compartments for femoral artery externally, femoral vein next, and leaving a third internally, the femoral canal.

Describe the deep crural arch.

When present, for it is not infrequently absent, it is a band of fibres derived from transversalis fascia, crossing the front of, and adherent to the crural sheath, passing from the centre of Poupart's ligament to the pectineal line behind the conjoined tendon.

Where is the seat of stricture most apt to be?

At (1) junction of Hey's and Gimbernat's ligaments, (2) margin of saphenous opening, (3) neck of hernial sac.

What are the coverings of a femoral hernia?

They are *Skin, Superficial fascia, Cribriform fascia, Crural sheath, Septum crurale, Subserous areolar tissue, Peritoneum forming sac.*

Perineum and Ischio-rectal Regions.**What is the ischio-rectal region?**

That portion of the outlet of the pelvis immediately behind the perineum containing the rectum, upon either side of which is a deep fossa filled with fat, the

Ischio-rectal fossa^b, of a triangular shape, between the end of rectum^x and tuberosity of the ischium^c on each side; its base corresponds to the skin, and apex to point of division of obturator fascia and origin of anal fascia; its base measures about one inch, its depth two inches, being deepest behind, and is bounded *internally*, by sphincter ani^x, levator ani^b, and coccygeus⁶ muscles; *externally*, by tuberosity of ischium^c and obturator fascia; *in front*, by line of junction of superficial and deep perineal fascia; and *behind*, by margin of gluteus maximus muscle¹¹ and great sacro-sciatic ligament; the

Internal pudic artery and nerve run about one and a half inches above margin of ischiatic tuberosity, becoming more superficial as they pass forward along inner margin of pubic arch; the

Inferior hemorrhoidal vessels, occasionally large enough to give trouble after lithotomy, traverse the centre of each fossa.

What is the perineum ?

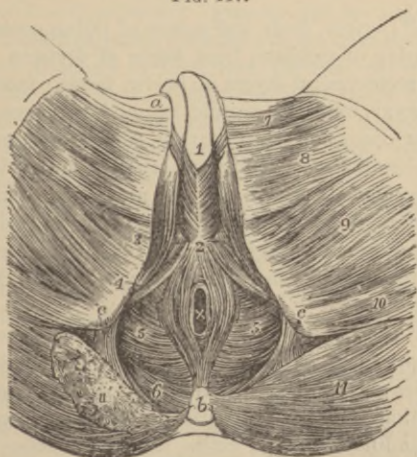
It is the anterior portion of the pelvic outlet, in front of ischio-rectal fossæ, is of a triangular form, bounded, deeply, by rami of pubes and ischia, forming, superiorly, the pubic arch, and behind, by an imaginary line drawn between ischiatic tuberosities; the lateral boundaries, in adult, vary from three to three and one-half inches.

Describe the muscles of the perineum.

External sphincter ani^x: *origin*, tip of coccyx^b and superficial fascia in front of bone; *insertion*, tendinous centre of perineum²: *action*, closes anus; *nerve*, fourth sacral.

Internal sphincter ani: consists of an aggregation of the involuntary circular fibres of intestine, forming a muscular ring two lines thick and one inch broad.

FIG. 117.



Sphincter tertius (Hyrtl): *origin*, sacrum, encircling rectum four inches above anus (not described by many anatomists).

*Accelerator urinæ*¹: consists of two symmetrical halves with median tendinous raphé; *origin*, central tendon of perineum² and median

raphé in front; *insertion*, fibres spread over front of triangular ligament, encircle the bulb and corpus spongiosum, spread over sides of corpora cavernosa, to which they are partly attached and partly terminate in a tendinous expansion covering dorsal vessels of penis; *action*, empties urethra after bladder ceases to contract, perhaps aids in erection of penis; *nerve*, perineal branch of pudic.

*Erector penis*³: *origin*, inner surface of each tuberosity of ischium, surface of crus penis and adjacent portion of pubic ramus (*Erector clitoridis* in female arises from ischial tuberosity; *inserted* on side of crus clitoridis); *insertion*, by an aponeurosis into sides and under surface of each crus penis; *action*, maintains erection; *nerve*, perineal.

*Transversus perinei*⁴: *origin*, inner front side of tuberosity of ischium; *insertion*, tendinous centre of perineum (in female, side of sphincter vaginae); *action*, steadies perineal centre; *nerve*, perineal.

*Levator ani*⁵: *origin*, body and ramus of pubes posteriorly, inner surface of spine of ischium, from angle of division between obturator and recto-vesical layers of pelvic fascia; *insertion*, sides of apex of coccyx^b, opposite muscle by median fibrous raphé, extending from coccyx to anal margin, side of rectum (and vagina in female) blending with sphincter muscles, and side of prostate gland, uniting beneath it with opposite muscle mingling with external sphincter and transversus peronei muscles at perineal centre²; *action*, supports rectum, vagina, and pelvic viscera, with its fellow helps form the floor of the pelvis; *nerves*, inferior hemorrhoidal and fourth sacral.

Compressor urethræ: *origin*, aponeurotic, from three-fourths of an inch of upper part of pubic ramus on each side; *insertion*, each muscle divides surrounding urethra from prostate gland to bulb of urethra, uniting with the opposite muscle above and below this tube by a tendinous raphé; *action*, shut-off muscle; *nerves*, perineal.

*Coccygeus*⁶: *origin*, by apex from spine of ischium and lesser sacro-sciatic ligament; *insertion*, by base into margin of coccyx and side of lowest segment of sacrum; *action*, raises coccyx; completes pelvic floor behind; *nerve*, anterior division fifth sacral.

Sphincter vaginæ: (in female) surrounds vaginal orifice, is homologous with accelerator urinæ in male—*origin*, central tendon of perineum; *insertion*, corpora cavernosa of clitoris.

Erector clitoridis, in female replaces the erector penis muscle.

Describe the perineal fasciæ.

The *superficial layer of the superficial fascia*, is thick, loose, loaded with fat and continuous with the fasciæ of ischio-rectal and crural regions; the

Deep layer of the superficial fascia is a thin, moderately strong, aponeurotic layer, continuous in front with dartos layer of scrotum, is firmly attached to the margins of the rami of ischium and pubes external to crura of penis as far back as ischial tuberosity, and passes down behind the transversus perinei muscles to blend with lower margin of the deep perineal fascia; the

Anterior layer of the deep perineal fascia is attached above and laterally to pubic arch, subpubic ligament and rami of ischium and pubes beneath crura of penis, forming a dense membranous lamina, extending and attached to tendinous perineal centre, becoming continuous with deep layer of the superficial fascia behind transverse perineal muscles: it embraces and is continued forward on anterior extremity of membranous urethra, which passes through it one inch below symphysis pubis; the

Posterior layer of the deep perineal fascia is attached like preceding, but more posteriorly, embraces back portion of membranous urethra and is continued backward over outer surface of prostate gland, the two layers forming the *triangular ligament*: the portion of urethra embraced between these layers is the *membranous urethra*; the

Obturator fascia is a continuation of transversalis and iliac fasciæ below a white band at level of a line passing from lower part of symphysis pubis to spine of ischium: it covers the internal obturator muscle and is continuous with posterior layer of triangular ligament; the

Recto-vesical fascia, or *visceral layer of pelvic fascia*, descends into pelvis upon upper surface of levator ani muscle, investing prostate, bladder, and rectum.

Describe Buck's fascia.

It is a moderately dense fascia investing the penis as far as glans, being a prolongation forward of deep layer of superficial fascia, blending with dartos layer of scrotum : it directs the urine forward into scrotum, penis, and upon abdomen when the urethra is ruptured.

What layers of fascia form the triangular ligament ?

The superficial and deep layers of the *deep perineal fascia* according to the description of most authorities.

What structures lie between the layers of the deep perineal fascia ?

<i>Membranous urethra,</i>	<i>Cowper's glands and ducts.</i>
<i>Compressor urethræ muscle,</i>	<i>Pudic vessels,</i>
<i>Subpubic ligament,</i>	<i>Pudic nerves,</i>
<i>Dorsal vein of penis,</i>	<i>Arteries and nerves of bulb,</i>
	<i>Venous plexus.</i>

What structures are exposed by the removal of the deep layer of the superficial fascia ?

The erector penis muscles covering the crura of penis.
The accelerator urinæ muscle covering corpus spongiosum and bulb.
Transversus perinei muscles.
Transversus perinei arteries.
Superficial perineal vessels.

What parts are divided in lateral lithotomy ?

Skin.
Superficial fascia.
Inferior hemorrhoidal vessels and nerves.
Posterior fibres of accelerator urinæ muscle.
Transversus perinei muscle and vessels.
Superficial perineal vessels and nerves, (probably) deep perineal fascia.
Anterior fibres of levator ani.
Part of compressor urethræ.
Membranous and prostatic portions of urethra.
Part of prostate gland (neck of bladder, according to Gross).

What structures must be avoided in this operation?

In front, the bulb and its artery.

Externally, pudic artery.

Toward median line and posteriorly, the rectum.

At neck of bladder, the entire division of lateral lobe and, therefore, the *capsule* of prostate gland and venous plexus.

Briefly describe the special points of interest connected with the female perineum.

The *perineal body* is the point of junction of all the muscular and aponeurotic structures of perineum, forming a pyramidal mass of tissue extending for some distance up between rectum and vagina, upon the integrity of which depends the proper support afforded to the pelvic viscera by the *floor of the pelvis*.

The length of the female perineum is only about one inch, extending from posterior commissure to verge of anus: the *accelerator urinæ muscle* is replaced by the *sphincter vaginae* encircling the vaginal outlet: the triangular ligament, formed essentially as in male, and perforated by the urethra, is much smaller.

INTRODUCTION

TO

PLATES ON OSTEOLOGY

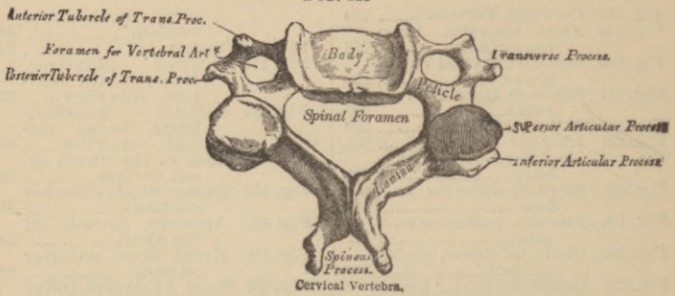
The following illustrations, taken from GRAY, are added with the idea of making this work a complete guide to the Student in his practical work. In the majority of our schools a careful study of osteology precedes dissection, the Student being given each bone for examination, and being required to master its anatomical details before receiving another one. The assistance offered by a complete set of plates needs no comment. Supplemented, as these illustrations are, by an admirably clear and condensed text, the Student has, in this work, a most efficient aid in that portion of his anatomical studies which is usually considered most dull and uninteresting.

THE PUBLISHER.

INDEX OF OSTEOLOGICAL PLATES.

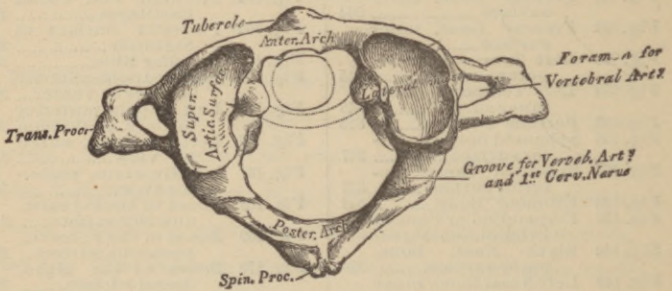
Fig. 118	Cervical Vertebra.....	338			
Fig. 119	First Cervical Verte- tra or Atlas.....	338			
Fig. 120	Second Cervical Verte- bra or Axis.....	338			
Fig. 121	Seventh Cervical Ver- tebra.....	339			
Fig. 122	A Dorsal Vertebra.....	339			
Fig. 123	Lumbar Vertebra.....	339			
Fig. 124	Peculiar Dorsal Verte- bra.....	340			
Fig. 125	Sacrum, anterior sur- face.....	341			
Fig. 126	Sacrum, posterior sur- face.....	341			
Fig. 127	Occipital Bone, outer surface.....	342			
Fig. 128	Occipital Bone, inner surface.....	342			
Fig. 129	Left Parietal Bone, ex- ternal surface.....	343			
Fig. 130	Left Parietal Bone, in- ternal surface.....	343			
Fig. 131	Frontal Bone, outer surface.....	344			
Fig. 132	Frontal Bone, inner surface.....	344			
Fig. 133	Left Temporal Bone, outer surface.....	345			
Fig. 134	Left Temporal Bone, inner surface.....	345			
Fig. 135	Petrous Portion.....	346			
Fig. 136	Sphenoid Bones, super- ior surface.....	347			
Fig. 137	Sphenoid Bones, an- terior surface.....	347			
Fig. 138	Ethmoid Bone.....	348			
Fig. 139	Perpendicular Plate of Ethmoid (enlarged)	348			
Fig. 140	Right Nasal Bone, outer surface.....	349			
Fig. 141	Left Nasal Bone, inner surface.....	349			
Fig. 142	Left Superior Maxill- ary Bone, outer surface.....	349			
Fig. 143	Left Superior Maxill- ary Bone, inner surface.....	350			
Fig. 144	Left Malar Bone, outer surface.....	350			
Fig. 145	Left Malar Bone, inner surface.....	350			
Fig. 146	Palate and Alveolar Arch.....	351			
Fig. 147	Left Palate Bone, in- ternal view.....	351			
Fig. 148	Left Palate Bone, pos- terior view.....	352			
Fig. 149	Left Lachrymal Bone, external surface...	352			
Fig. 150	Right Inferior Turbu- rated Bone, inter- nal surface.....	352			
Fig. 151	Right Inferior Turbu- rated Bone, outer surface.....	352			
Fig. 152	Vomer.....	352			
Fig. 153	Inferior Maxillary Bone, outer sur- face, side view.....	353			
Fig. 154	Inferior Maxillary Bone, inner sur- face, side view.....	353			
Fig. 155	Base of the Skull, in- ner surface.....	354			
Fig. 156	Base of Skull, external surface.....	355			
Fig. 157	Anterior Region of the Skull.....	356			
Fig. 158	Hyoid Bone, anterior surface.....	356			
Fig. 159	Roof, Floor and Outer Wall of Nasal Fossa	357			
Fig. 160	Left Clavicle, anterior surface.....	357			
Fig. 161	Left Clavicle, in- ferior surface....	357			
Fig. 162	Sternum and Costal Cartilages.....	358			
Fig. 162*	Posterior Surface of Sternum.....	358			
Fig. 163	Peculiar Ribs.....	359			
Fig. 164	Left Scapula, anterior surface or venter...	360			
Fig. 165	Left Scapula, posterior surface or dorsum	361			
Fig. 166	Left Humerus, anter- ior view.....	362			
Fig. 167	Left Humerus, poster- ior view.....	362			
Fig. 168	Bones of the Forearm, anterior surface....	363			
Fig. 169	Bones of the Forearm, posterior surface..	364			
Fig. 170	Bones of the Hand, dorsal surface.....	365			
Fig. 171	Bones of the Hand, palmar surface.....	365			
Fig. 172	Right Os Innomina- tum, external sur- face.....	367			
Fig. 173	Right Os Innomina- tum, internal sur- face.....	368			
Fig. 174	Right Patella, anterior and posterior sur- face.....	368			
Fig. 175	Right Femur, anter- ior surface.....	369			
Fig. 176	Right Femur, poster- ior surface.....	369			
Fig. 177	Bones of the Leg, anterior surface....	370			
Fig. 178	Bones of the Leg, posterior surface....	370			
Fig. 179	Bones of the Foot, dorsal surface....	371			
Fig. 180	Bones of the Foot, plantar surface.....	372			

FIG. 118



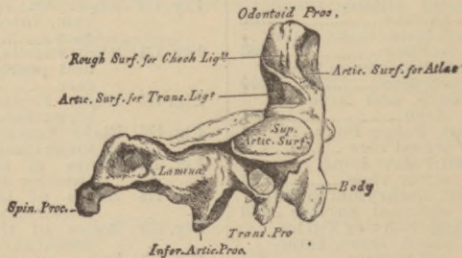
CERVICAL VERTEBRA.

FIG. 119.



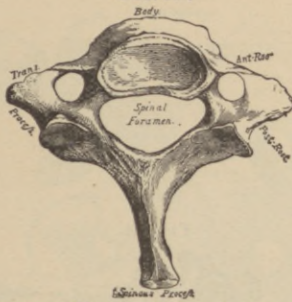
FIRST CERVICAL VERTEBRA OR ATLAS.

FIG. 120.



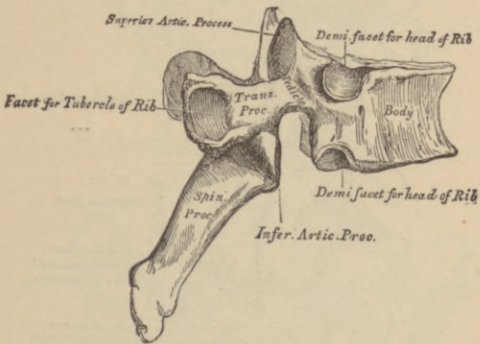
SECOND CERVICAL VERTEBRA OR AXIS.

FIG. 121.



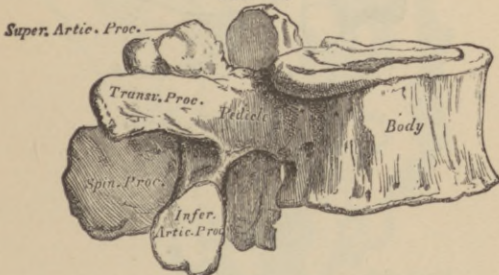
SEVENTH CERVICAL VERTEBRA OR VERTEBRA PROMINENS.

FIG. 122.



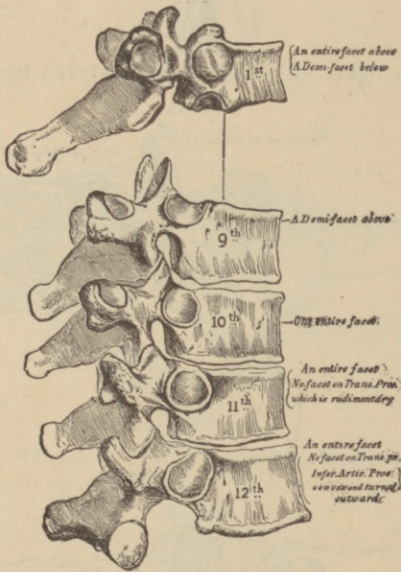
A DORSAL VERTEBRA.

FIG. 123.



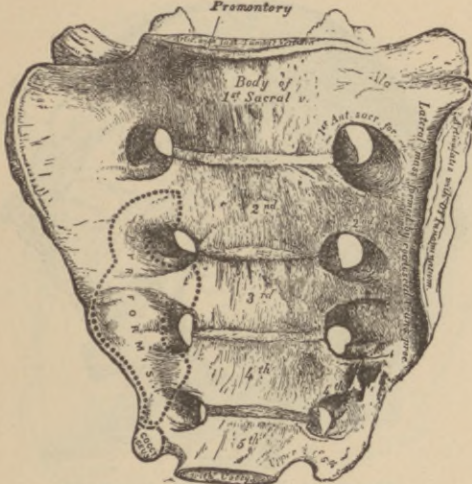
LUMBAR VERTEBRA.

FIG. 124.



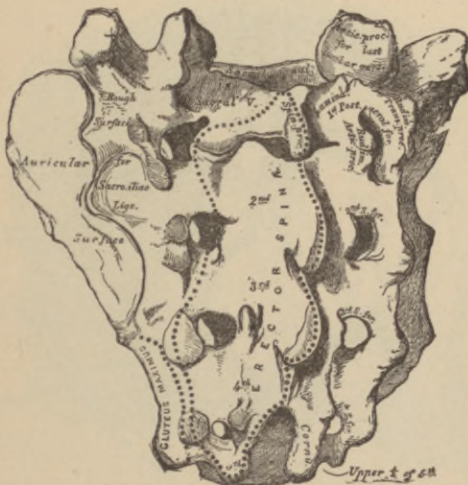
PECULIAR DORSAL VERTEBRÆ.

FIG. 125.
Promontory



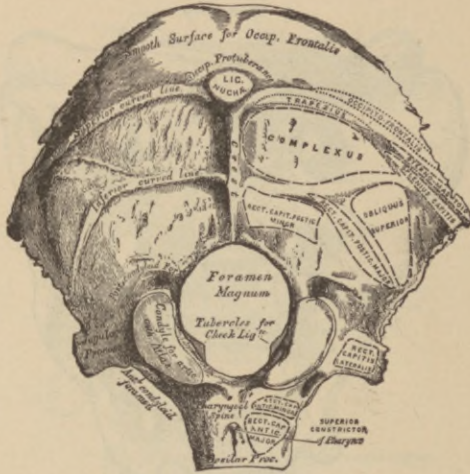
SACRUM, ANTERIOR SURFACE.

FIG. 126.



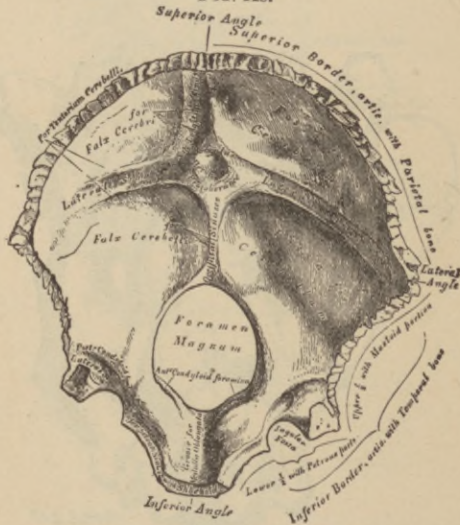
SACRUM, POSTERIOR SURFACE.

FIG. 127.



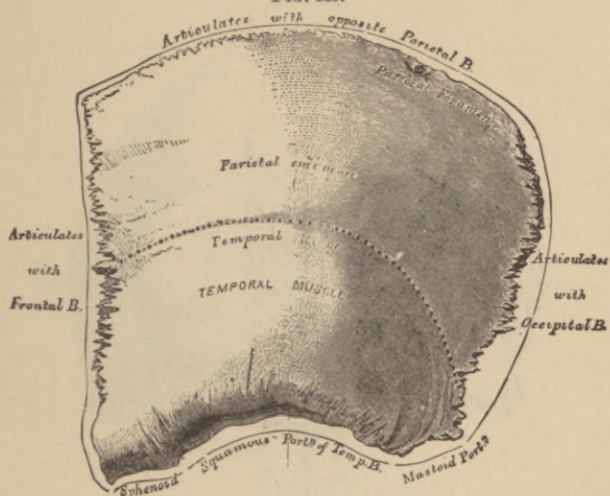
OCCIPITAL BONE, OUTER SURFACE.

FIG. 128.



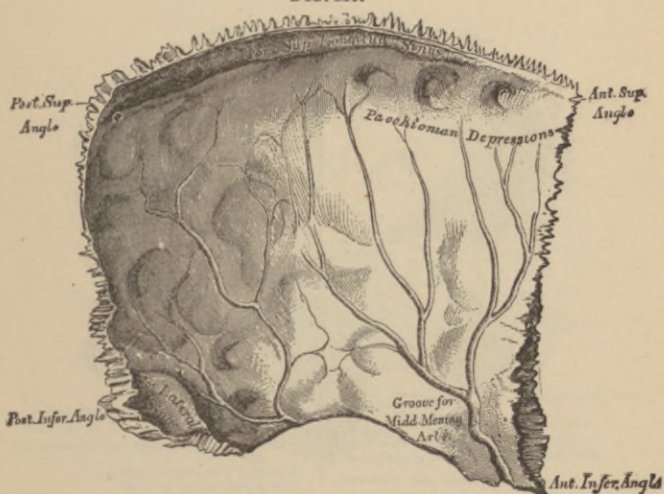
OCCIPITAL BONE, INNER SURFACE.

FIG. 129.



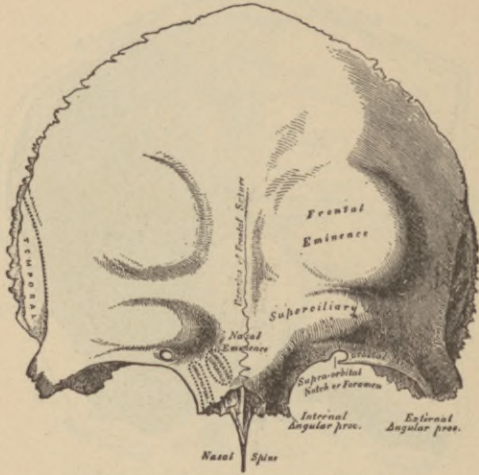
LEFT PARIETAL BONE, EXTERNAL SURFACE.

FIG. 130.



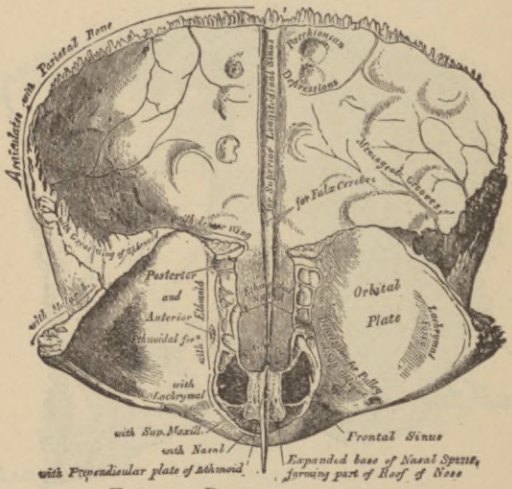
LEFT PARIETAL BONE, INTERNAL SURFACE.

FIG. 131.



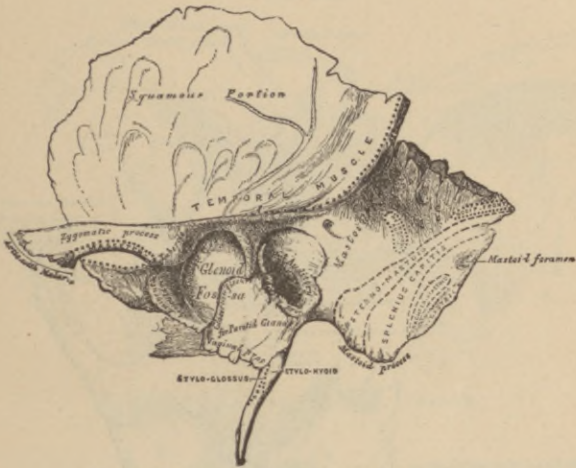
FRONTAL BONE, OUTER SURFACE.

FIG. 132.



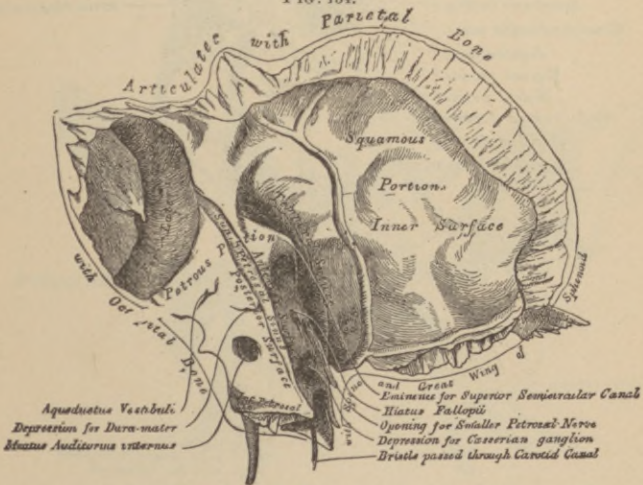
FRONTAL BONE, INNER SURFACE.

FIG. 133.



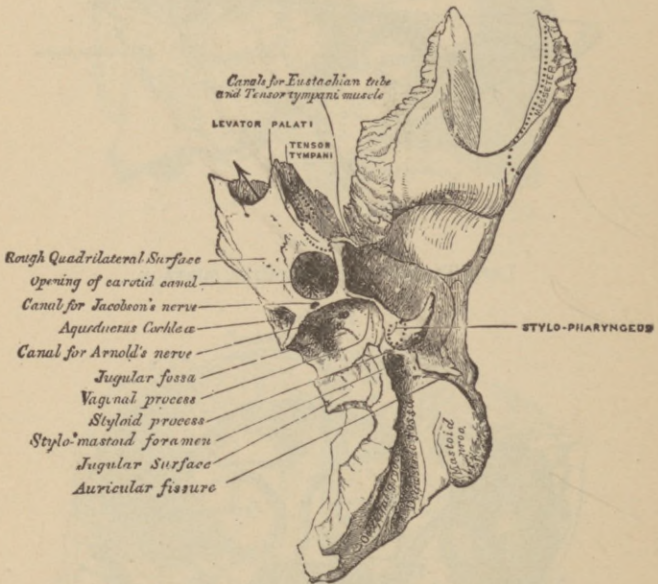
LEFT TEMPORAL BONE, OUTER SURFACE.

FIG. 134.



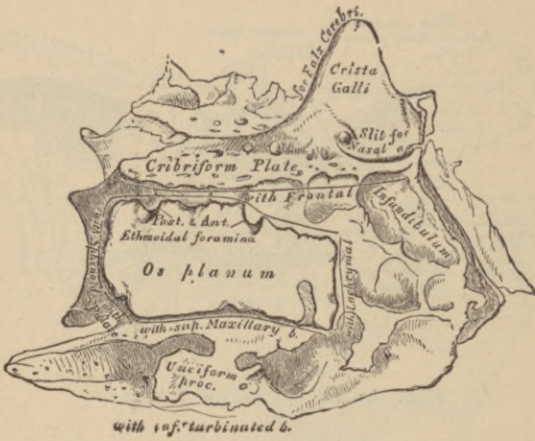LEFT TEMPORAL BONE, INNER SURFACE.

FIG. 135.



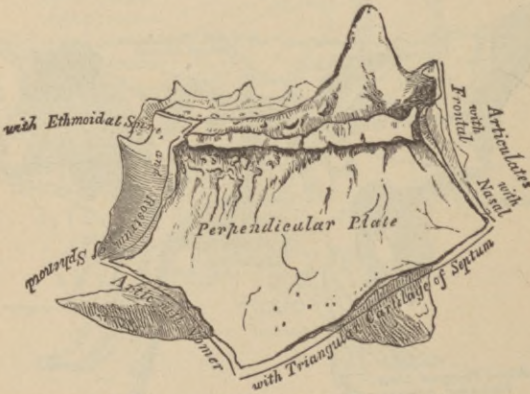
PETROUS PORTION, INFERIOR SURFACE.

FIG. 138.



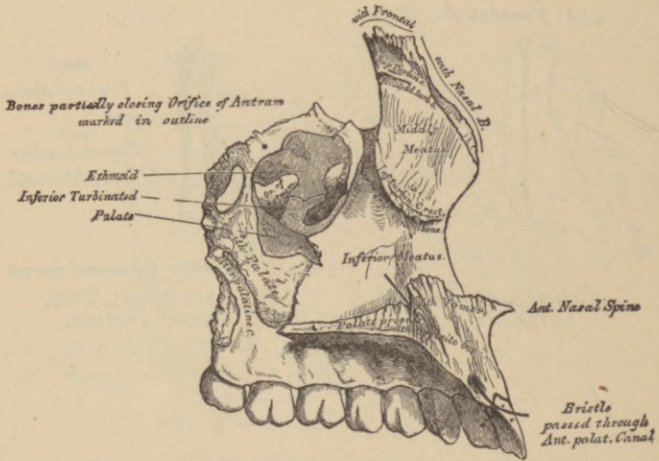
ETHMOID BONE, OUTER SURFACE OF RIGHT LATERAL MASS, (ENLARGED).

FIG. 139.



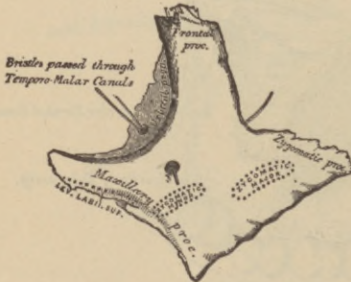
PERPENDICULAR PLATE OF ETHMOID (ENLARGED), SHOWN BY REMOVING THE RIGHT LATERAL MASS.

FIG. 143.



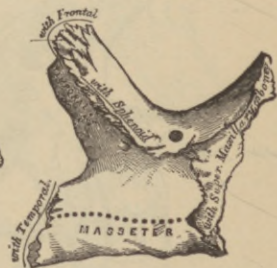
LEFT SUPERIOR MAXILLARY BONE, INNER SURFACE.

FIG. 144.



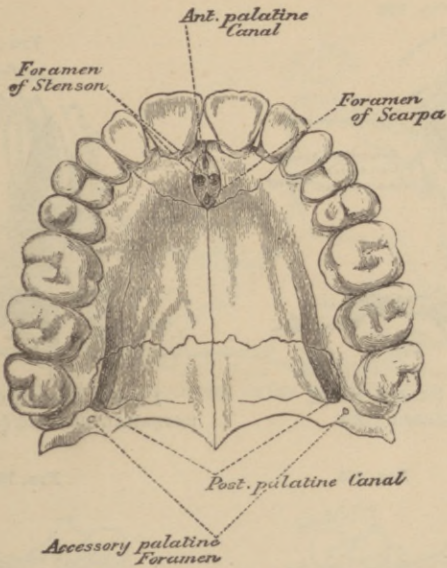
LEFT MALAR BONE, OUTER SURFACE.

FIG. 145.



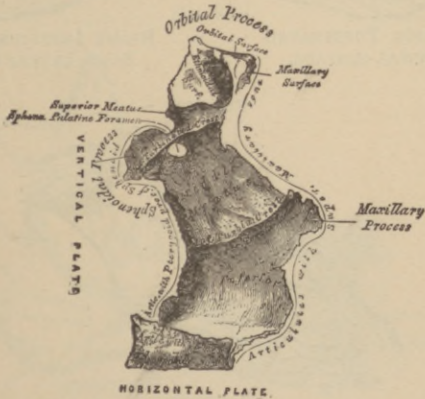
LEFT MALAR BONE, INNER SURFACE.

FIG. 146.



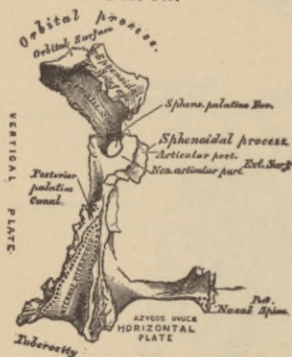
THE PALATE AND ALVEOLAR ARCH.

FIG. 147.



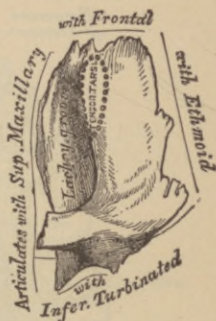
LEFT PALATE BONE, INTERNAL VIEW.

FIG. 148.



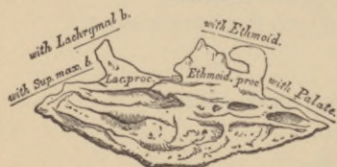LEFT PALATE BONE,
POSTERIOR VIEW.

FIG. 149.



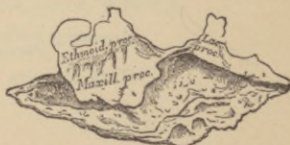LEFT LACHRYMAL BONE,
EXTERNAL SURFACE (ENLARGED).

FIG. 150.



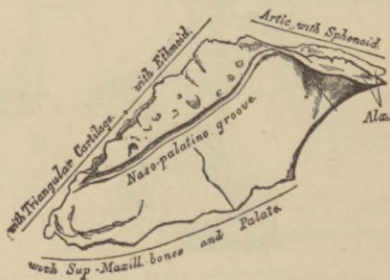
RIGHT INFERIOR TURBINATED
BONE, INTERNAL SURFACE.

FIG. 151.



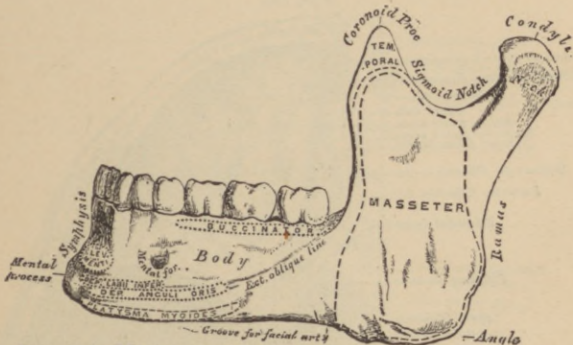
RIGHT INFERIOR TURBINATED
BONE, EXTERNAL SURFACE.

FIG. 152.



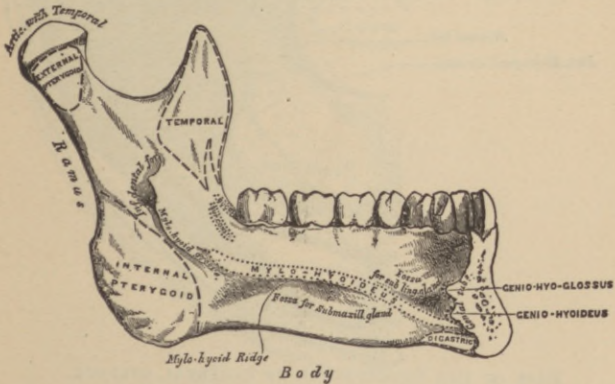
VOMER.

FIG. 153.



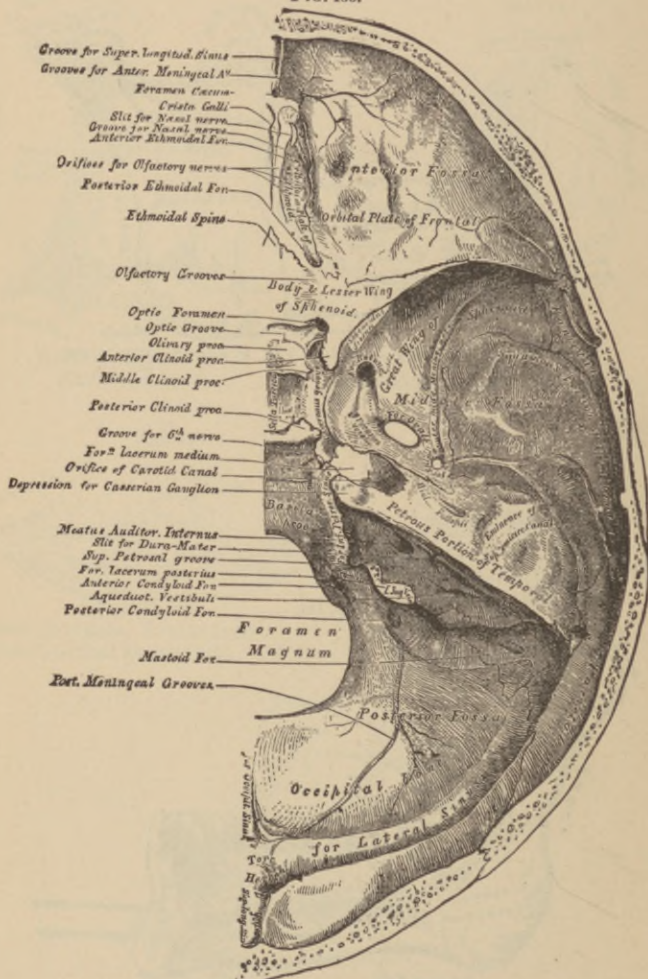
INFERIOR MAXILLARY BONE, OUTER SURFACE, SIDE VIEW.

FIG. 154.



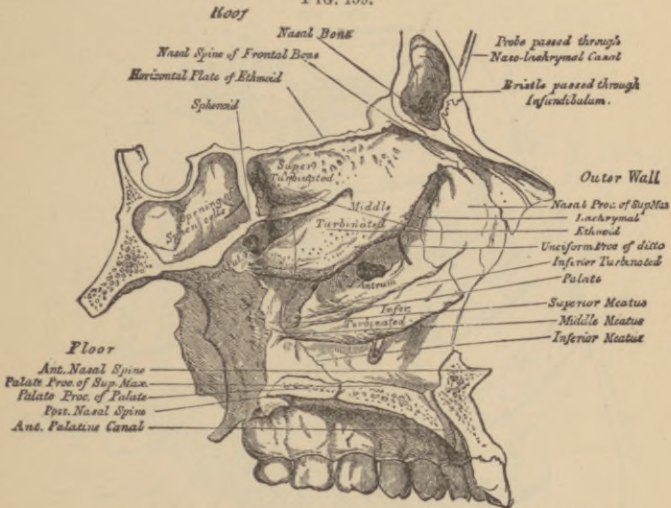
INFERIOR MAXILLARY BONE, INNER SURFACE, SIDE VIEW.

FIG. 155.



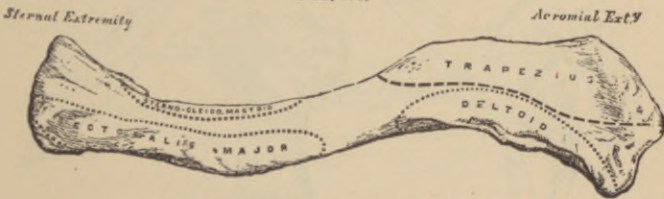
BASE OF THE SKULL, INNER OR CEREBRAL SURFACE.

FIG. 159.



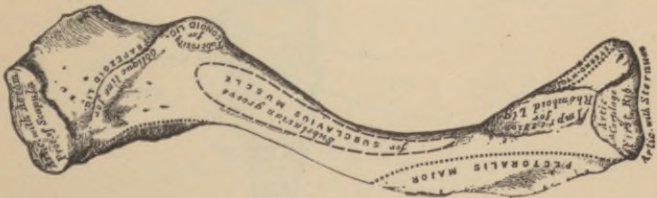ROOF FLOOR, AND OUTER WALL OF LEFT NASAL FOSSA.

FIG. 160.



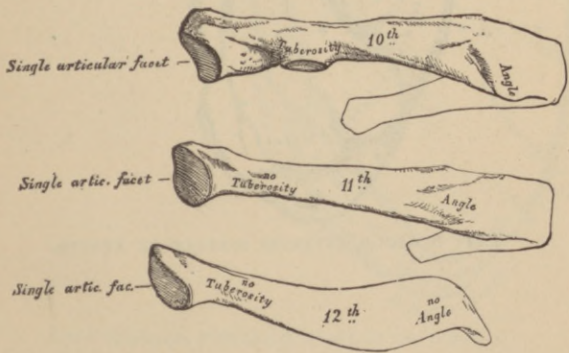
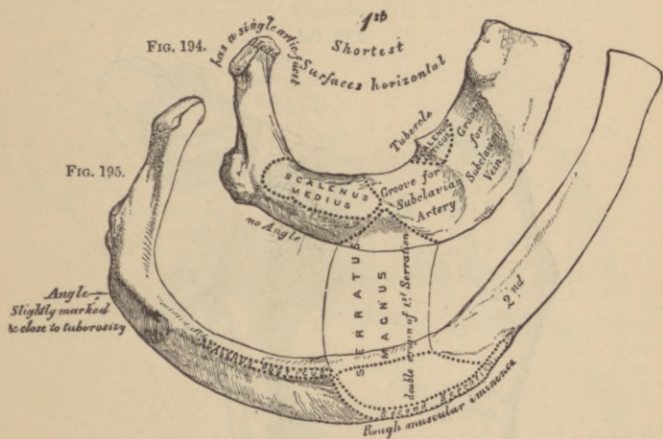
LEFT CLAVICLE, ANTERIOR SURFACE.

FIG. 161.



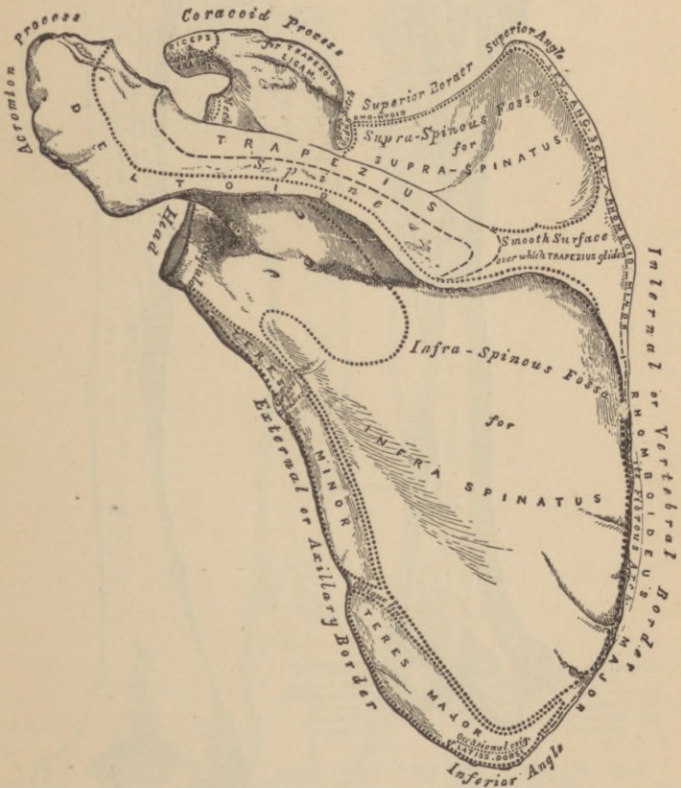
LEFT CLAVICLE, INFERIOR SURFACE.

FIG. 163.



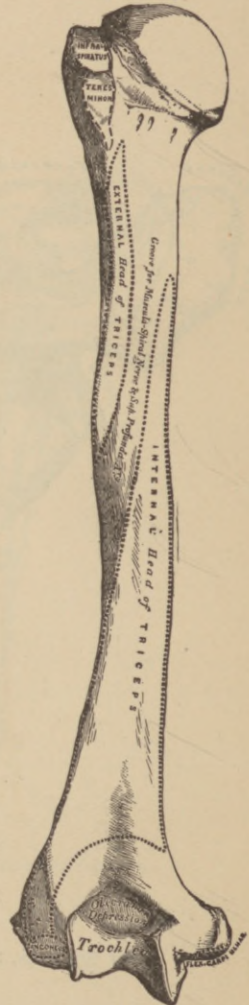
PECULIAR RIBS.

FIG. 165.



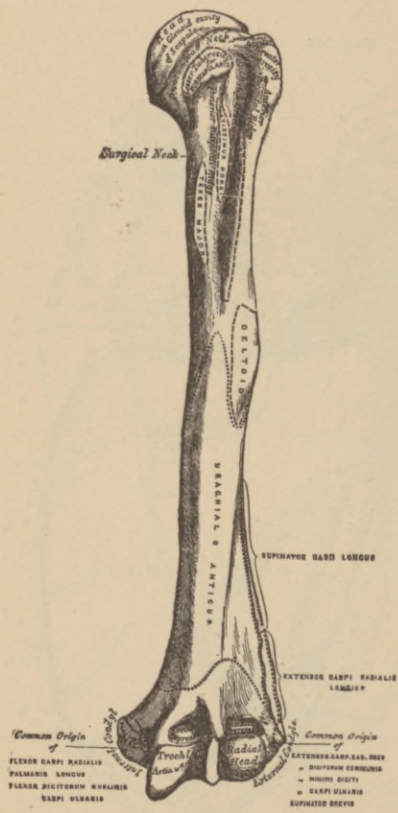
LEFT SCAPULA, POSTERIOR SURFACE OR DORSUM.

FIG. 167.



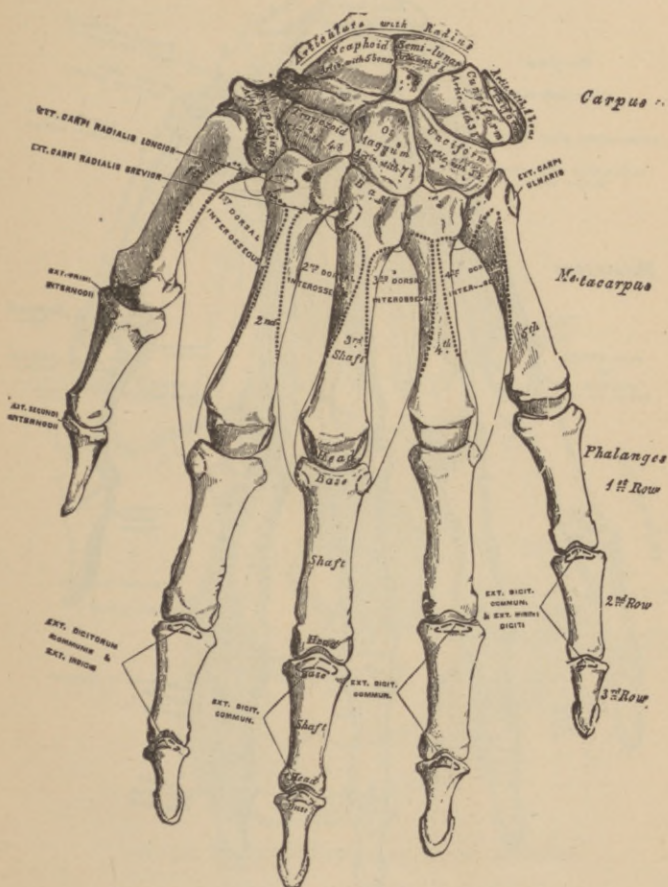
LEFT HUMERUS,
POSTERIOR SURFACE.

FIG. 166.



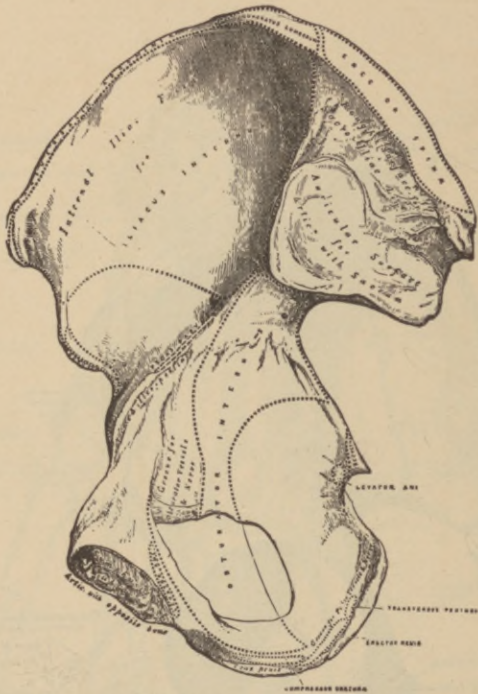
LEFT HUMERUS, ANTERIOR VIEW.

FIG. 170.



BONES OF THE LEFT HAND, DORSAL SURFACE.

FIG. 173.



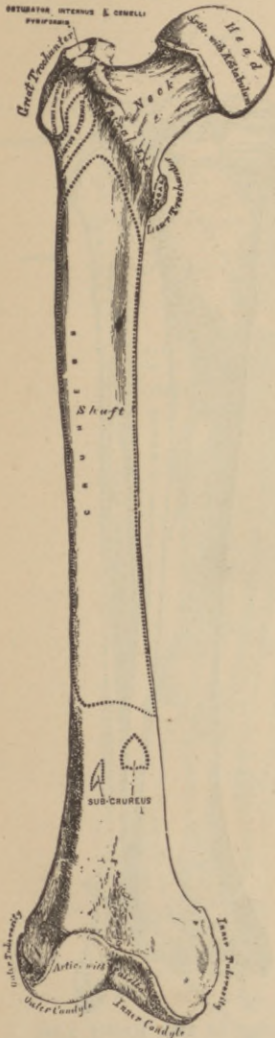
RIGHT OS INNOMINATUM, INTERNAL SURFACE.

FIG. 174.



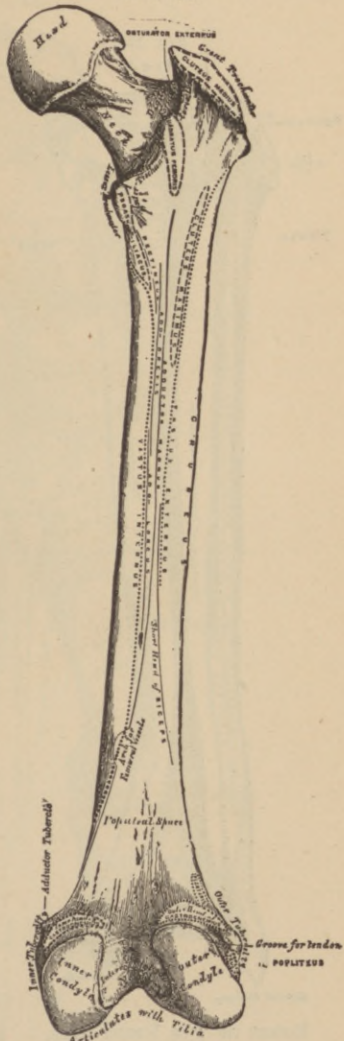
RIGHT PATELIA, ANTERIOR SURFACE. POSTERIOR SURFACE.

FIG. 175.



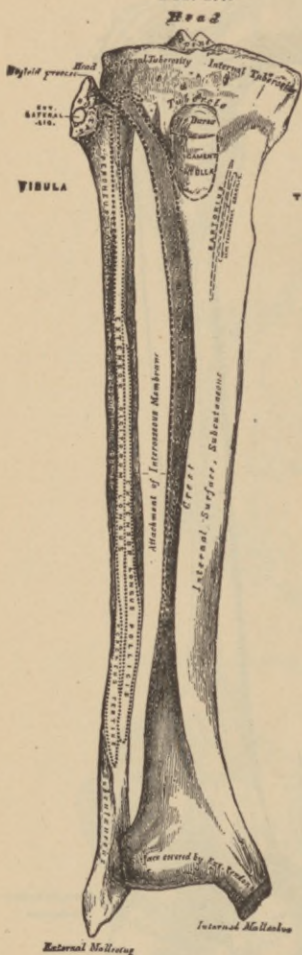
RIGHT FEMUR,
ANTERIOR SURFACE.

FIG. 176.



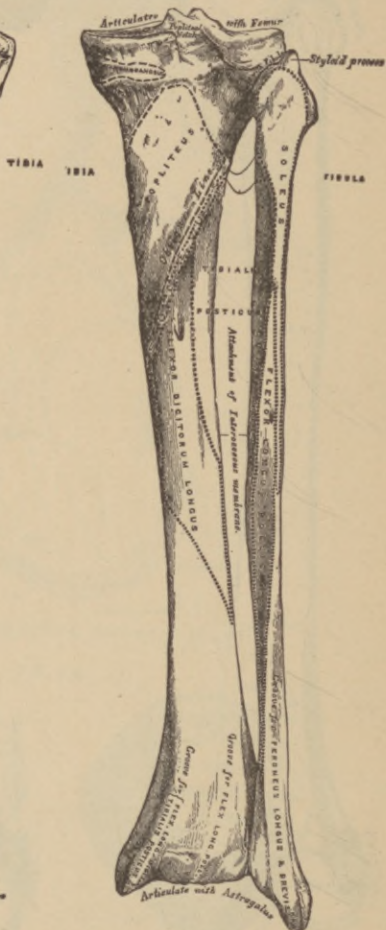
RIGHT FEMUR,
POSTERIOR SURFACE.

FIG. 177.



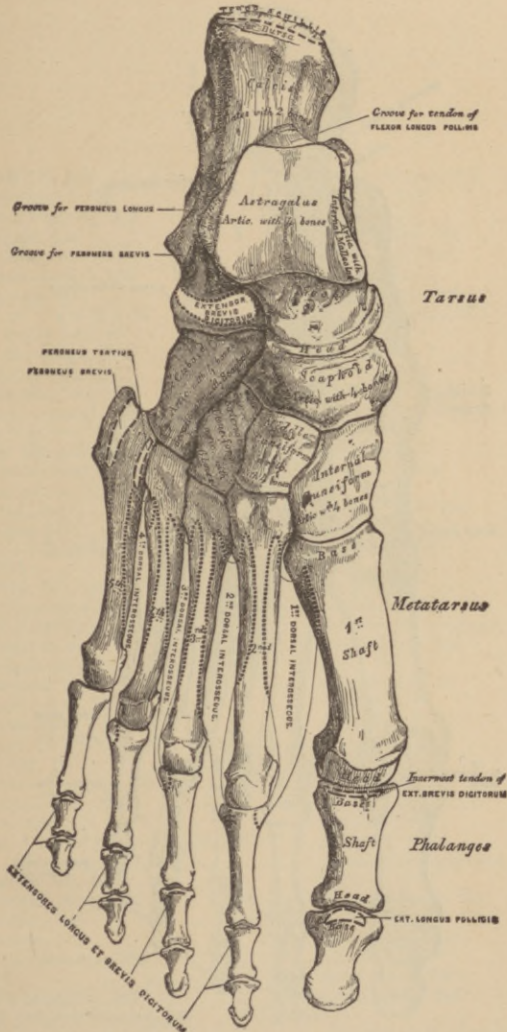
BONES OF THE RIGHT LEG,
ANTERIOR SURFACE.

FIG. 178.



BONES OF THE RIGHT LEG,
POSTERIOR SURFACE.

FIG. 179.



BONES OF THE RIGHT FOOT, DORSAL SURFACE.

I N D E X.

ABDOMEN, 243
 muscles of, 129
 Abdominal cavity, 243
 regions, 245
 Absorbents, 184
 Acervulus cerebri, 196
 Acetabulum, 68
 Alveoli of lower jaw, 50
 of upper jaw, 43
 of the lungs, 258
 Amphiarthrosis, 92
 Anastomoses, 157, 175
 Anatomy, general, 17
 descriptive, 17
 Angle of the jaw, 51
 of subscapular fossa, 76
 Annulus ovalis, 154
 Antihelix, 310
 Antitragus, 310
 Antrum of Highmore, 40
 Anus, 232
 Aorta, 158, 167, 168
 Appendices epiploicæ, 232
 Appendix auriculæ, 154, 155
 ensiform, 65
 vermiformis, 231
 Aponeuroses, 115
 pharyngeal, 225
 Apophysis, 21
 Aqueduct of Sylvius (iter e tertio,
 etc.), 194, 195
 Aquæductus cochleæ, 36
 Fallopîi, 36, 203
 vestibuli, 319
 Arachnoid membrane of brain, 186
 of spinal cord, 199
 Arbor vitæ, 198, 282
 Arch, crural, deep, 330
 palmar, 166
 plantar, 175
 Areola of mammæ, 286
 Arm, 78
 Arnold's ganglion, 202
 Arteriæ propriæ renales, 263
 Arterial anastomoses, 175

Arteries, helicine, 274
 hepatic, 168
 lingual, 161
 pharyngeal, 161
 sublingual, 161
 Arteries of the—
 ankle-joint, 112
 auditory canal, 311
 auricle, 311
 bone, 19
 choroid, 298
 elbow-joint, 104
 Eustachian tube, 317
 eye, 304
 eye-lids, 304
 hip-joint, 108
 iris, 296
 kidney, 263, 264
 knee-joint, 110
 labyrinth, 325
 larynx, 254
 lung, 259
 mammæ, 287
 membrana tympani, 312
 nasal fossæ, 291
 nose, 291
 œsophagus, 226
 ovaries, 286
 pancreas, 239
 penis, 274
 pharynx, 226
 retina, 299
 shoulder-joint, 103
 spleen, 240
 stomach, 000
 supra-renal capsules, 243
 testicle, 277
 thymus gland, 242
 thyroid gland, 241
 tympanum, 316
 uterus, 284
 wrist-joint, 105
 Arteriolæ rectæ, 264
 Artery—
 anastomotica magna, 173

Artery—

- aorta, 158, 167, 168
- arteria receptaculi, 162
- auricular, 161
- axillary, 165
- basilar, 164
- brachial, 165
- carotid (external), 161
- (internal), 162
- cerebral, anterior, 163
- middle, 163
- posterior, 163
- choroid, anterior, 166
- communicating, anterior, 163
- posterior, 163
- coronary, 159
- digital, 167, 175
- dorsalis hallucis, 174
- pedis, 174
- epigastric, deep, 171
- superficial, 171
- facial, 161
- femoral, 171
- gastric, 168
- gluteal, 170
- hemorrhoidal, 170
- hepatic, 168
- iliac, circumflex, 171
- external, 171
- internal, 169
- ilio-lumbar, 170
- infra-orbital, 162
- innominate, 159
- intercostal, 167
- lingual, 161
- lumbar, 169
- mammary, internal, 164
- maxillary, internal, 161
- meningeal, anterior, 162
- mesenteric, superior, 168
- inferior, 168
- obturator, 170
- occipital, 161
- ophthalmic, 162
- palmar arches, 166
- peroneal, 174
- pharyngeal, ascending, 161
- phrenic, 168
- plantar, external, 174
- internal, 174
- popliteal, 173
- profunda femoris, 173
- inferior, 165
- superior, 165

Artery—

- pubic, deep external, 173
 - superficial external, 173
 - internal, 170
 - pulmonary, 175
 - radial, 166
 - renal, 169
 - sacral, lateral, 170
 - middle, 169
 - sciatic, 170
 - spermatic, 169
 - splenic, 168
 - subclavian, 163
 - subscapular, 165
 - suprarenal, 169
 - suprascapular, 164
 - temporal, 161, 162
 - thoracic, acromial, 165
 - superior, 165
 - thoracica alaris, 165
 - longa, 165
 - thyroid, superior, 161
 - inferior, 164
 - thyroidea ima, 159
 - tibial, anterior, 173
 - posterior, 174
 - transversalis colli, 164
 - tympanic, 162
 - ulnar, 166
 - uterine, 170
 - vaginal, 170
 - vertebral, 164
 - vesical, 169, 170
- Arthrodial joints, 93
- Articulations, 92
- atlo-axoidean, 95
 - carpal, 105
 - carpo-metacarpal, 106
 - costo-sternal, 98
 - costo-transverse, 98
 - costo-vertebral, 97
 - metacarpo-metacarpal, 106
 - metatarso-metatarsal, 113
 - occipito-atloid, 94
 - occipito-axoidean, 96
 - phalangeal, of foot, 114
 - of hand, 107
 - radio-ulnar, 104
 - sacro-coccygeal, 100
 - sacro-iliac, 99
 - sacro-ischiatic, 100
 - sacro-vertebral, 99
 - scapulo-clavicular, 101
 - scapulo-humeral, 102

Artery—

- sterno-clavicular, 101
- tarsal, 112
- tarso-metatarsal, 113
- temporo-maxillary, 96
- tibio-fibular, 110
- vertebral, 94

Arytenoid cartilages, 250

Atlas, 63

Auricle, 310

Axis, 63

- coeliac, 168
- optic, 292
- thyroid, 164
- visual, 292

Azygos veins, 180

uvulæ, 122

BARTHOLIN, duct of, 221
glands of, 280

Bauhin, valve of, 231

Bell, external nerve of, 206

internal nerve of, 205

Bladder, 266

Bodies, Malpighian, 263

Pacchionian, 186

Body, ciliary, 296

- olivary, 196
- perineal, 335
- pituitary, 191
- restiform, 197

Bone, astragalus, 90

calcaneum, 90

clavicle, 75

coccyx, 72

cuboid, 90

cuneiform, 91

ethmoid, 38

femur, 85

fibula, 89

frontal, 23

humerus, 78

hyoid, 65

ilium, 69

incus, 314

innominate, 68

ischium, 70

lachrymal, 44

malar, 44

malleus, 314

maxillary, inferior, 49

superior, 40

nasal, 40

Bone—

occipital, 27

os calcis, 90

os magnum, 84

palate, 45

parietal, 25

pectineal, 70

peroneal, 89

phalanges of foot, 92

of hand, 85

pisiform, 84

pubic, 70

sacral, 71

scaphoid, 83

scapula, 76

semilunar, 83-

sphenoid, 30

stapes, 315

sternum, 65

structure, microscopic, 18

temporal, 34

tibia, 88

trapezium, 84

trapezoid, 84

turbinated, inferior, 47

middle, 39

superior, 39

ulna, 80

unciform, 84

vomer, 48

Bones of the body, 20

of the carpus, 83

of the foot, 90

of the hand, 82

of the leg, 88

of the lower extremity, 85

of the metacarpus, 84

of the metatarsus, 91

of the tarsus, 90

of the trunk, 61

of the upper extremity, 74

Wormian, 20

Bonnet, capsule of, 293

Bowman's membrane, 295

Brain, commissures of, 192

divisions of, 187

points on base, 190

on surface, 187-190

ventricles, 192

weights, average, 187

Bronchi, 255

Brunner's gland, 230

Bulb of corpus cavernosum, 273

of corpus spongiosum, 273

- Bulbi vestibuli, 280
 Bulbs, olfactory, 191
 Burns, ligament of, 329
 Bursa of ankle, 149
 of hip, 108
 of knee, 110
 of shoulder, 102
 of wrist, 139
- CÆCUM**, 231
 Calamus scriptorius, 197
 Calices of kidney, 261
 Canal, alimentary, 224
 auditory, external, 311
 internal, 36
 carotid, 36
 central, of the cord, 200
 crural, 329
 dental, 41, 50
 femoral, 328
 Hunter's, 144, 171
 hyaloid, 301
 infraorbital, 41
 inguinal, 326
 of the modiolus, 320
 nutrient, 19
 palatine, 46
 sacral, 72
 spiral, of the cochlea, 320
 for tensor tympani, 37
 Vidian, 33
 Canal of—
 Huguier, 35
 Nuck, 383
 Petit, 302
 Schlemm, 297
 Stilling, 301
 Canaliculi, 308
 Canalis reuniens, 322
 Canals, semicircular, 319
 membranous, 322
 Canthus, 306
 Capillaries, 158
 Capsule, internal, 194
 of Bonnet, 293
 of Glisson, 237
 of the lens, 301
 of Tenon, 293
 Capsules, suprarenal, 242
 Caput *ceci*, 231
 gallinaginis, 269
 Carpus, 83
 Cartilages of the larynx, 249
 of Santorini, 250
 of tarsal, 306
 of Wrisberg, 251
 Cartilago triticea, 251
 Caruncula lachrymalis, 307
 myrtiformes, 280
 Cauda equina, 211
 Cavity, cotyloid, 68
 glenoid, of scapula, 78
 of the omentum, 246
 orbital, 55
 of reserve, 220
 sigmoid, greater, 80
 lesser, 80
 of radius, 82
 Cells, auditory, 324
 ethmoid, 39
 hepatic, 237
 mastoid, 35, 314
 olfactory, of Schultze, 291
 Cement, 218
 Cerebellum, 197
 Cerebro-spinal system, 185
 Cerebrum, 187
 convolutions of, 189
 fissures of, 187
 lobes of, 188
 Cervix of penis, 273
 of uterus, 282
 Chordæ tendineæ, 155
 Choroid tunic, 295
 plexus, 193
 Cilia, 307
 Circle of Willis, 163
 Circulus arteriosus iridis major,
 296
 iridis minor, 296
 venosus, 287
 Clavicle, 75
 Clinoid processes, 30, 33
 Clitoris, 280
 Coccyx, 72
 Cochlea, membranous, 322
 osseous, 320
 Cœliac axis, 168
 Collar-bone, 75
 Colon, 231
 flexures of, 231
 Columnæ carneæ, 155, 157
 papillares, 155
 Columns of Bertin, 261
 of spinal cord, 199
 Commissure, optic, 200
 Concha, 310

Condyles, of femur, 86
 Condyles of humerus, 79
 Coni-vasculosi, 276
 Conjunctiva, 307
 Conus arteriosus, 154
 Convolution of cerebrum, 189
 Coracoid process, 77
 Corium, 288
 Cornea, 294
 Cornicula laryngis, 250
 Cornua of thyroid cartilage, 250
 of the ventricles, 192
 Corona glandis, 273
 radiata, 195
 Coronoid process, 49, 81
 Corpora albicantia, 191
 cavernosa, 273
 quadrigemina, 192, 195
 striata, 192
 Corpus Arantii, 155
 callosum, 193
 dentatum of cerebellum,
 198
 of olivary body, 196
 fimbriatum, 193
 highmorianum, 275
 luteum, 285
 spongiosum, 273
 Corpuscles, Malpighian, 240
 tactile, 288
 Corti, organ of, 323
 Cortical substance of kidney,
 261
 Cotyloid cavity, 68
 Coverings of the testicle, 275
 of hernia, 328, 330
 Cowper's glands, 272
 Crest of the ilium, 69
 lachrymal, 44
 nasal, 43, 47
 of the pubes, 71
 of the tibia, 88
 turbinate, 42, 46
 Cricoid cartilage, 250
 Crista galli, 38
 Crura cerebri, 191
 of clitoris, 280
 of penis, 273
 Crusta petrosa, 218
 Crypts of Lieberkühn, 230
 Cuneiform cartilages, 251
 Cuneus, 190
 Cupola of cochlea, 320
 Cuticle, 287, 288

DARTOS, 276
 Dentine, 218
 Derma, 288
 Descemet, membrane of, 295
 Diaphragm, 133
 Diarthrosis, 93
 Digestion, organs of, 216
 Disk, optic, 298
 Discus proligerus, 285
 Dorsum of scapula, 76
 Douglas's cul-de-sac, 281, 283
 Duct, cystic, 238
 hepatic, 237
 lymphatic, 184
 nasal, 309
 pancreatic, 238
 of Bartholin, 221
 of Gärtner, 286
 of Müller, 277
 of Rivinus, 221
 of Steno, 221
 of Wharton, 221
 of Wirsung, 238
 thoracic, 184
 Ducts, biliary, 237
 ejaculatory, 278
 Ductus cochlearis, 322
 communis choledochus, 238
 Duodenum, 229
 Dura mater of cerebrum, 186
 of spinal cord, 199

EAR, 310
 internal, 318
 Earstones, 321
 Eminence, hypothear, 141
 thear, 141
 Eminentia collateralis (pes accessorius), 194
 Enamel, 218
 Enarthrosis, 93
 Endocardium, 157
 Endolymph, 318
 Endosteum, 19
 Epidermis, 288
 Epididymis, 276
 Epigastric region, 245
 Epiglottis, 251
 Epiphysis, 22
 Equator of eyeball, 292
 Eustachian tube, 317
 Eye, 292
 its appendages, 306

- Eyebrows, 306
 Eyelashes, 307
 Eyelids, 306-
- FALLOPIAN** tubes, 284
 Fallopius, aqueduct of, 313
 hiatus of, 36
- Falx cerebelli, 186
 cerebri, 186
- Fascia, anal, 333
 Buck's, 334
 cremasteric, 327
 cribriform, 329
 dentata, 194
 intercolumnar, 326
 ischio-rectal, 333
 lata, 142
 lumbar, 131
 obturator, 333
 palmar, 138
 perineal, 333
 plantar, 150
 recto-vesical, 333
- Fasciæ, 114
 of the perineum, 334
- Fauces, 221
- Femur, 85
- Fenestra ovalis, 313
 rotunda, 313
- Ferrein, pyramids of, 263
- Fibro-cartilage, 94, 97, 102, 107, 110,
 307, 310
- Fibula, 89
- Fimbriæ, 284
- Fimbriated extremity, 284
- Fissure, auricular, 37
 calcarine, 188
 calloso-marginal, 188
 collateral, 188
 dentate, 189
 Glaserian, 35
 palpebral, 306
 parieto-occipital, 187
 pterygo-maxillary, 60
 of Rolando, 187
 of Sylvius, 187
 precentral, 187
 spheno-maxillary, 60
 sphenoidal, 53
 transverse, 189
- Fissures of cerebellum, 198
 of cerebrum, 187
 of liver, 234
- Fissures of spinal cord, 199
- Folds, palpebral, 307
- Fontana, spaces of, 297
- Fontanelles, 52
- Foot, 90
- Foramen for Arnold's nerve, 37
 cæcum, 24
 condyloid, 28
 ethmoidal, 25
 for Jacobson's nerve, 37
 infra-orbital, 41
 inter-vertebral, 62
 lacerum anterius, 33, 53
 magnum, 27, 54
 mastoid, 35
 medium, 54
 mental, 49
 nutrient, 19
 obturator, 68
 of Monro, 193
 of Scarpa, 43
 of Stenson, 43
 of Winslow, 247
 olfactory, 38
 ovale, 31
 optic, 33
 orbital, 32
 palatine, 43
 petrosal, 36
 posterior, 54
 pterygo-palatine, 47
 rotundum, 31
 sacral, 71
 spheno-palatine, 46
 spinal, 63
 spinosum, 32
 stylo-mastoid, 37
 supra-orbital, 24
 supra-scapular, 77
 thyroid, 68
 Vesalii, 32
- Foramina at the base of the skull, 54
 olfactory, 38
 orbital, 32
 spheno-maxillary, 60
 Thebesii, 154
- Forearm, 80
- Fornix, 193
- Fossa, canine, 40
 coronoid, 80
 digastric, 35
 digital, 86
 glenoid, 78
 hyaloid, 301

Fossa, incisive, 40
 infra-spinous, 77
 ischio-rectal, 330
 jugular, 29
 lachrymal, 25
 navicularis of vulva, 281
 of penis, 270
 olecranon, 80
 ovalis, 154
 pterygoid, 33
 scaphoid, 33
 spheno-maxillary, 61
 sublingual, 50
 submaxillary, 50
 subscapular, 76
 supraspinous, 77
 temporal, 59
 zygomatic, 60
 Fossæ, nasal, 58
 of the skull, 53
 Fourchette, 281
 Fovea centralis, 298
 hemispherica, 319
 semi-elliptica, 319
 Frænulum, 196
 Frænulum preputii, 274

GERTNER, duct of, 286

Gall-bladder, 238
 Ganglia, basic, 191
 cervical, 213
 of fifth nerve, 202
 of the sympathetic, 211-214
 Ganglion, Arnold's, 211, 212
 Gasserian, 202
 impar, 211
 Meckel's, 212
 of ribs, 211
 spheno-palatine, 212
 spirale, 320, 325
 Gasser, ganglion of, 202
 Gimbernat's ligament, 326
 Ginglymus, 93
 Gladiolus, 65
 Gland, lachrymal, 308
 mammary, 286
 pineal, 196
 prostate, 271
 thymus, 242
 thyroid, 241
 Glands, Brunner's, 230
 Cowper's, 272
 ductless, 239

Glands, gastric, 228
 intestinal, 230
 lachrymal, 308
 lymphatic, 184
 Meibomian, 307
 of Bartholin, 280
 of Tyson, 274
 sebaceous, 289
 solitary, 230
 sweat, 289
 Glans clitoridis, 280
 penis, 273
 Glenoid, 78
 Glisson's capsule, 235
 Globus major, 276
 minor, 276
 Glottis, 252
 Gomphosis, 93
 Graafian vesicle, 285
 Groove, bicipital, 79
 infraorbital, 41
 musculo-spiral, 79
 mylo-hyoid, 51
 naso-palatine, 49
 optic, 30
 pterygo-palatine, 47
 Gubernaculum testis, 278
 Gums, 217
 Gyrus, angular, 189
 fornicatus, 189

HAIRS, 288

Hamstrings, 146
 Hamular process, 33
 Hand, 82
 Haversian canals, 18
 system, 18
 Head of the humerus, 79
 of the ulna, 81
 Heart, 153
 Helicotrema, 320
 Helix, 310
 Henle, tubes of, 261, 263
 Hernia femoral, 328
 inguinal, 325
 Hey, ligament of, 329
 Hiatus Fallopii, 36
 Hilum of kidney, 261
 Hippocampus major, 193
 minor, 193
 Horner's muscle, 117
 Houston, folds of, 232
 Huguier, canal of, 35

- Humerus, 78
 Humor, aqueous, 300
 vitreous, 301
 Humors of the eyeball, 300
 Hunter's canal, 144
 Hydatids of Morgagni, 277
 Hymen, 280
 Hypochondrium, 244, 246
 Hypogastrium, 246
- I**LEUM, 69, 230
 Ilium, 69
 Incisura intertragica, 310
 Infundibula of kidney, 261
 Infundibulum of brain, 191
 Inguinal regions, 245, 246
 Intestine, large, 231
 small, 229
 Internal capsule, 194
 Intumescencia ganglioniformis Scar-
 pæ of seventh nerve, 325
 Iris, 296
 Ischium, 70
 Iter chordæ anterioris, 313
 posterioris, 313
 e tertio ad quartum ventriculum,
 194
 Ivory, 218
- J**ACOB'S membrane, 299
 Jacobson's nerve, 203
 Jejunum, 229
 Joint, ankle-, 111
 elbow-, 103
 hip-, 107
 rotators of the, 144-146
 knee-, 108
 shoulder-, 102
 wrist-, 105
 Joints, motion in, 93
 structures of, 93
- K**IDNEYS, 260
- L**ABIA majora, 279
 L minora, 279
 Labium tympanicum, 323
 Labium vestibulare, 323
 Labyrinth, membranous, 321
 osseous, 318
 Lacteals, 184
 Lacunus magnus, 270
 Lacunæ, 18
 Lacus lachrymalis, 306
 Lamellæ, 18
 Lamina cinerea, 191
 cribrosa (of sclerotic), 293
 fusca, 294
 reticularis, 324
 spiralis, 320
 Laminae of cornea, 295
 Lancisi, nerves of, 193
 Larynx, 249
 Layer, dermoid, 288
 ganglionic, 299
 molecular, 299, 300
 Leg, 88
 Lens, crystalline, 301
 Lieberkühn, crypts or follicles of, 230
 Ligament, annular, of foot, 149
 annular of hand, 139
 conoid, 102
 coronary, 110
 costo-xiphoid, 98
 cotyloid, 107
 crucial, of knee-joint, 110
 deltoid, 112
 falciiform, 329
 Gimbernat's, 326
 glenoid, 102
 ilio-femoral or Y, 107
 of Burns, 329
 of Hey, 326
 of Zinn, 301
 orbicular, 104
 Poupart's, 129, 326
 rhomboid, 101
 round, of the liver, 234
 round, of the uterus, 283
 sacro-sciatic, 100
 stellate, 97
 stylo-maxillary, 97
 suspensory, of lens, 301
 of liver, 234
 of penis, 273
 of spleen, 240
 transverse, of hip-joint, 107
 trapezoid, 102
 triangular, of perineum, 334
 Ligaments of the bladder, 267
 broad, of uterus, 283

- Ligaments, check, 96
 of the knee-joint, 108
 of the larynx, 251
 of the liver, 234
 of the ossicles, 315
 of the ovaries, 284
 of the scapula, 102
 of the sternum, 99
 of the uterus, 283
 peritoneal, 248
 tarsal, 307
- Ligamentum latum pulmonis, 259
 mucosum, 110
 nuchæ, 124
 patellæ, 108
 pectinatum iridis, 297
 suspensorium, 96
 teres, 107
 Winslowii, 109
- Limbus laminae spiralis, 323
- Line, inter-trochanteric, 86
- Linea aspera, 86
 ilio-pectinea, 70
 quadrati, 86
- Liquor Morgagni, 301
- Lithotomy, structures affected, 334
- Liver, fissures of, 234
 lobes of, 235
 structure of, 237
 vessels of, 235
- Lobe of the ear, 310
- Lobes of the cerebellum, 197
 of the cerebrum, 187
 of the liver, 235
 optic, 192
- Lobule of the ear, 310
- Lobules of the liver, 237
 of the lung, 258
- Lobulus caudatus, 235
 quadratus, 235
 Spigelii, 235
- Lower, tubercle of, 154
- Lumbar regions, 245, 246
- Lung, broad ligament of, 259
- Lungs, 256
- Lunula, 288
- Lymphatics, 184
 hepatic, 237
 of lung, 259
 of penis, 274
 of thymus gland, 242
 of trachea and bronchi, 256
 of uterus, 284
- Lymph-spaces of eyeball, 304
- Lyra, 193
- M**ACULA acoustica, 322
 lutea, 298
- Maculae cribrosæ, 325
- Malleolus, 88, 89
- Malpighi, bodies of, 240
 pyramids of, 261
- Malpighian corpuscles, 263
 tuft, 263
- Mammæ, 286
- Manubrium of the malleus, 314
 of the sternum, 65
- Marrow of bone, 19
- Masses, lateral, of ethmoid, 39
- Mastoid process, 85
- Meatus auditorius externus, 36
 internus, 36
 nasi, 59
 urinarius, 273, 280
- Meckel's ganglion, 212
- Mediastinum, 260
 testis, 275
- Medulla oblongata, 196
- Medullary substance, 261
- Membrana basilaris, 323
 granulosa, 285
 pupillaris, 298
 Ruyschiana, 296
 sacciformis, 104
 tectoria, 323
 tympani, 311
 secundaria, 321
- Membrane, hyaloid, 301
 interosseous, 104, 111
 Jacob's, 300
 limiting, 299, 300
 of Bowman, 295
 of Descemet, 295
 of Reissner, 323
 pituitary, 290
 Schneiderian, 290
 Shrapnell's, 312
 vitelline, 285
- Membranes of brain, 186
 of the spinal cord, 199
 synovial, 93
 tarsal synovial, 114
 wrist synovial, 105
- Meridians of eyeball, 292
- Mesenteries, 248
- Meso-cephalon (pons Varolii), 195

- Metacarpus, 84
 Metatarsus, 91
 Modiolus, 320
 Monro, foramen of, 193
 Mons veneris, 279
 Morgagni, hydatids of, 277
 Mouth, 220
 Müller, duct of, 277
 muscle of, 296
 Muscle of Bowman (ciliary), 296
 ciliary, 296
 cremaster, 327
 dilator pupillæ, 298
 Horner's, 117
 kerato-cricoides, 253
 levator glandulæ thyroideæ, 241
 of Müller, 296
 sphincter pupillæ, 297
 triticæo-glossus, 253
 of the arm, 134
 of the auricle, 310
 of the back, 123
 Muscles, double-bellied, 116
 of the abdomen, 129
 of the ear (external), 116
 of the epiglottis, 253
 of the Eustachian tube, 317
 of the eyeball, 302
 of the face, 117, 118, 119
 of the forearm, 136
 of the foot, 150
 of the hand, 140
 of the head, 111
 of the hip, 144, 145
 of the larynx, 253
 of the leg, 147
 of the neck, 120
 of the palate, 122
 of the perineum, 331
 of the pharynx, 225
 of the shoulder, 134
 of the stomach, 227
 of the thigh, 142
 of the thorax, 132
 of the tympanum, 315
 Muscular fibre, 114
 Musculi pectinati, 154
- N**ABOTH, ovules of, 284
 Nails, 288
 Nates of cerebrum, 196
 Neck of humerus, 79
 Nerve tissue, 185
- Nerve, abducens, 202
 Arnold's, 37, 204
 auditory, 203
 Bell's external respiratory,
 206
 internal respiratory, 205
 chorda tympani, 202, 313, 316
 circumflex, 206
 cochlear, 203, 320
 crural anterior, 209
 facial, 202
 genito-crural, 208
 glosso-pharyngeal, 203
 hypoglossal, 204
 ilio-hypogastric, 208
 ilio-inguinal, 208
 intercosto-humeral, 206, 208
 interosseous, 208
 Jacobson's, 37, 203, 316
 laryngeal, 204, 254
 maxillary, inferior, 202
 superior, 202
 median, 206
 motor oculi, 201
 musculo-spiral, 207
 nonus or ninth pair, 204
 obturator, 209
 of Wrisberg, 206
 olfactory, 200
 ophthalmic division of fifth,
 202
 optic, 200
 par vagum, 204
 patheticus, 201
 phrenic, 205
 pneumogastric, 204
 portio dura, 202
 portio mollis, 203
 pudic, 209
 radial, 207
 spinal accessory, 204
 sympathetic, 211
 thoracic, 206
 trigeminus, 201
 tympanic, 203
 ulnar, 207
 vestibular, 203, 324
 Vidian, 213
 Nerve-fibres, optic, 200, 305
 Nerves of ankle-joint, 112
 of auditory canal, 311
 of auricle, 311
 of bladder, 269
 of choroid, 296

Nerves, cranial, 200
 hepatic, 237
 of Eustachian tube, 318
 of elbow-joint, 104
 of eye, 304
 of eyelids, 304
 of eye-muscles, 303
 of hip-joint, 107
 of iris, 298
 of kidney, 265
 of knee-joint, 110
 of Lancisi, 193
 of larynx, 204, 254
 of lung, 259
 of membrana tympani, 312
 of nasal fossæ, 291
 of nose, 291
 of œsophagus, 227
 of ovaries, 286
 of pancreas, 239
 of penis, 274
 of pharynx, 226
 of shoulder-joint, 102
 of spleen, 241
 of stomach, 229
 of supra-renal capsules, 243
 of taste, 222, 290
 of testicles, 278
 of thymus gland, 242
 of tongue, 222
 of trachea and bronchi, 256
 of tympanum, 316
 of uterus, 284
 of wrist-joint, 105
 petrosal, 213
 popliteal, 210
 sciatic, 209
 spinal, 205
 splanchnics, 214
 thyroid, 241

Nervous system, 185

Neurilemma, 185

Nipple, 286

Nose, 290

Notch, cotyloid, 68
 inter-clavicular, 65
 inter-condyloid, 87
 popliteal, 88
 sacro-sciatic, 70
 sigmoid, 49
 supra-orbital, 24
 supra-scapular, 77

Nuck, canal of, 283

Nymphæ, 279

ODONTOBLASTS, 220
 Odontoid ligaments, 95, 96
 process, 63

œsophagus, 226

Omentum, 247

Opening, saphenous, 329

Opercula, 220

Optic thalami, 192

Ora serrata, 298

Orbital cavities, 55

Organ of Corti, 323
 of hearing, 310
 of Rosenmüller, 286
 of sight, 292
 of smell, 290

Organs of generation, female, 279
 male, 271
 of sense, 287
 of taste, 289
 of voice and respiration, 249
 urinary, 260

Os calcis, 90
 orbiculare, 314
 planum (orbital of ethmoid), 39
 tincæ, 282
 uteri, 282

Ossa innominata, 68
 triquetra, 20

Osteology, 17

Ossification, 20

Ossicles of tympanum, 314

Otoliths, 321

Ovaries, 284

Oviducts, 284

Ovisacs, 285

Ovules of Naboth, 284

Ovum, 285

PACCHIONIAN bodies, 186
 Palate, 221

Palpebræ, 306

Pampiniiform plexus, 278, 286

Pancreas, 238
 lesser, 239

Papilla, lachrymal, 306
 optic, 298

Papillæ of skin, 288

Parovarium, 286

Pars ciliaris retinæ, 299
 intermedia, of vulva, 281

Peduncles of cerebellum, 195, 196,
 197

Pelvis, 73

- Pelvis of the kidney, 261
 Penis, 272
 Pericardium, 152
 Perilymph, 318
 Perineum, 331
 female, 335
 Periosteum, 19
 Peritoneum, 246
 Peronei muscles, 147, 149
 Pes accessorius, 194
 hippocampi, 194
 Petit, canal of, 302
 Peyer's patches, 230
 Phalanges of ear, 324
 of foot, 92
 of hand, 85
 Pharynx, 224
 Pia mater of brain, 187
 of spinal cord, 199
 of the testes, 275
 Pinna, or auricle, 310
 Plane, equatorial, 292
 meridional, 292
 Plantar arch, 175
 Plate, cribriform, 38
 orbital, 39, 41, 44
 perpendicular, 38
 Pleuræ, 259
 Plexus, brachial, 206
 carotid, 214
 cavernous, 214
 cervical, 205
 choroid, 193
 gastric, 215
 lumbar, 208
 pampiniform, 278, 286
 sacral, 209
 solar, 215
 splenic, 215
 tympenic, 316
 Plexuses of the sympathetic, 214,
 215, 216
 Pli courbe (angular gyrus), 252
 Plica semilunaris, 307
 Point, nodal, 292
 Poles of the eyeball, 292
 Pomum Adami, 249
 Pons Varolii, 195
 Portal system, 178, 235
 Porus opticus, 293
 Pouches of membrana tympani, 312
 Poupart's ligament, 129, 326
 Prepuce of clitoris, 280
 of penis, 273
 Process, acromion, 77
 alveolar, 43, 50
 articular, 21
 auditory, 36
 basilar, 28
 clinoid, 30, 33
 condyloid, 28, 49, 79, 85, 86
 coracoid, 77
 coronoid, 50, 81
 ethmoidal, 48
 falciform, 329
 hamular, of cochlea, 320
 of pterygoid plate of sphenoid; 33
 lachrymal, 48
 malar, 42
 mastoid, 35
 maxillary, 48
 mental, 49
 nasal, 42
 odontoid, 63
 olecranon, 80
 olivary, 30
 orbital, 39, 41, 45, 46
 palatine, 43
 pterygoid, 33
 sphenoidal, 46
 spinous, 32, 43, 47, 63, 70, 71
 styloid, 37
 transverse, 63
 turbinate, 39
 unciform, 39
 vaginal, 37
 vermiform, 197
 zygomatic, 34
 Processes, ciliary, 296
 clinoid, 30, 33
 of Ingrassias 32
 Processus cochleariformis, 37
 cerebello ad medullam (inferior peduncles), 197
 ad pontem (middle peduncles), 195
 ad testes, 196
 gracilis, 314
 Promontory of sacrum, 71
 of tympanum, 313
 Prostate gland, 271
 Prostatic urethra, 269
 sinus, 269
 Pterygoid processes, 33
 Pubes, 70
 Punctum lachrymale, 306
 Pupil, 297

- Pylorus, 227
 Pyramid, anterior, 196
 posterior, 197
 of tympanum, 314
 Pyramids of Ferrein, 263
 of Malpighi, 261
- RADIUS, 81**
 Rami of inferior maxillary, 50
 Ramus of ischium, 70
 of the pubes, 70
 Receptaculum chyli, 184
 Rectum, 232
 Regions of abdomen, 244
 Reil, island of, 188
 Reissner, membrane of, 323
 Renal vessels, 263
 Rete mucosum, 288
 Rete testis, 276
 Retina, 298
 Ribes, ganglion of, 211
 Ribs, 66
 Ridge, mylo-hyoid, 51
 pterygoid, 32
 Rima glottidis, 252
 Ring, abdominal, 326
 crural, 328
 femoral, 328
 Rings and phalanges, 324
 Rivinus, duct of, 221, 222
 notch of, 311
 Rods and cones (Jacob's), 300
 of Corti, 323
 Rolando, fissure of, 187
 Rosenmüller, organ of, 286
 Rostrum of the sphenoid, 31
- SAC, lachrymal, 309**
 Saccule, 322
 Sacculus laryngis, 252
 Sacs of the peritoneum, 246
 Sacrum, 71
 Santorini, cartilages of (cornicula laryngis), 250
 Scala media, 322
 tympani, 321
 vestibuli, 320
 Scapula, 76
 Scarpa, foramen of, 43
 intumescencia ganglioniformis, 325
 Schindelysis, 93
- Schlemm, canal of, 297
 Schultze, olfactory cells of, 291
 Schwann, substance of, 185
 Sclerotic, 293
 Scrotum, 275
 Sella turcica, 30
 Septum crurale, 329
 lucidum, 193
 nasi, 58
 pectiniforme, 273
 Sheath, crural, 329
 Shin, 88
 Shoulder-joint, 102
 -blade, 76
 Shrapnell's membrane, 312
 Sight, organs of, 292
 Sigmoid flexure, 232
 Sylvius, aqueduct of, 36, 203, 313
 fissure of, 187
 Sinus aortici or sinus of Valsalva, 156
 circularis iridis, 297
 of the kidney, 261
 of Morgagni (sacculus laryngis), 252
 pocularis, 270
 Sinuses, 23
 sphenoidal, 31
 of Valsalva, 155, 156
 Skin, 287
 Slit, nasal, 38, 58
 Smell, organ of, 290
 Space, anterior perforated, 191
 posterior perforated, 191
 Spaces, Fontana's, 297
 Spermatic cord, 278
 Sphincter vesicæ, 268
 Spinal cord, 198
 Spine, ethmoidal, 30
 of the ischium, 70
 nasal anterior, 43, 58
 posterior, 47
 of the pubes, 71
 of the scapula, 76
 of the sphenoid, 32
 of the tibia, 88
 Spines of the ilium, 69
 Spinous processes, 21
 Spleen, 239
 Spot, blind, 298
 germinal, 285
 light, 312
 yellow, 298
 Squamous, 22


- Stars of Verheyen, 264
 Steno's ducts, 221
 Stenson's foramina, 43
 Sternum, 65
 Stilling, canal of, 301
 Styloid, 22
 Stomach, 227
 Substance of Schwann, 185
 Sulei, 189
 Sulcus spiralis, 323
 typanicus, 311
 Surface, auricular, 70
 trochlear, 79
 Sustentaculum tali, 90
 Sutura, 92
 Suture, baso-sphenoidal, 52
 coronal, 52
 lachrymo-ethmo-frontal, 52
 lambdoidal, 52
 masto-occipital, 52
 masto-parietal, 52
 petro-occipital, 52
 petro-sphenoidal, 52
 sagittal, 52
 spheno-parietal, 52
 squamo-parietal, 52
 squamo-sphenoidal, 52
 Sutures, facial, 52
 of the orbit, 56, 57
 of the skull, 51
 Sympathetic system, 211
 Symphysis, 92
 of inferior maxillary, 49
 Synarthrosis, 92
 Synchondrosis, 92
 Synovial membranes, 93
- TARSUS**, 90
 Taste, nerves of, 290
 Taste-goblets, 289
 Tænia hippocampi, 193
 semicircularis, 193
 Teeth, 217
 Tendo-oculi, 307
 Tendons, 115
 Tenon, capsule of, 292
 Tentorium cerebelli, 186
 Testes, 274
 of the cerebrum, 196
 descent of, 278
 Thebesius, foramina of, 154
 Thigh, 85
 Thorax, 64
- Thyroid axis, 164
 cartilage, 249
 Tongue, 222
 Tonsils, 221
 Trachea, 254
 Tract, lateral, 197
 optic, 305
 uveal, 297
 Tracts, olfactory, 200
 Tractus spiralis foraminulentus, 325
 Tragus, 310
 Trigonum vesicæ, 268
 Trochanters of femur, 85
 Trochlea, 22
 Tube, Eustachian, 317
 Tuber annulare (pons Varolii), 195
 cinereum, 191
 Tubercle, 21
 genial, 50
 of Lower, 154
 Tuberosities, 21
 of femur, 87
 of humerus, 79
 of ischium, 70
 maxillary, 40
 Tubes of Henle (convoluted tubes), 261
 spiral, of Schachowa, 262
 Tubuli lactiferi, 286
 seminiferi, 276
 uriniferi, 262
 Tuft, Malpighian, 263
 Tunica albuginea, 275
 vaginalis, 275
 vasculosa, 275
 Tunics of eyeball, 293
 Tutamina oculi, 306
 Tympanum, 313
 Tyson, glands of, 274
- ULNA**, 80
 Umbilical region, 245
 Umbilicus, 244
 Umbo, 312
 Urachus, 267
 Ureters, 265
 Urethra, 271
 bulb of, 270
 Uterus, 281
 masculinus, 270
 Utricle, 321

- Uvea, 297
 Uvula, 221
 vesicæ, 269
- VAGINA**, 281
 Vaginal, 22
- Valley of cerebellum, 197
- Valsalva, sinuses of, 155, 156
- Valve, Eustachian, 154
 ilio-cæcal, 231
 mitral, 156
 tricuspid, 155
 of Bauhin, 231
 of Vieussens, 196
- Valves of Kirkring (valvulæ conniventes), 230
 semilunar, 155
- Valvulæ conniventes, 230
- Vas aberrrens, 276
 deferens, 277
- Vasa efferentia, 276
 recta, 276
 vasorum, 158
- Vein, axillary, 179
 basilic, 179
 cephalic, 179
 jugular, 178
 femoral, 182
 iliac, 182
 median, 179
 popliteal, 182
 portal, 183
 radial, 179
 splenic, 183
 subclavian, 179
 supra-renal, 183
 ulnar, 179
 vena cava, 180, 183
 vertebral, 181
- Veins, 177
 azygos, 180
 cardiac, 183
 choroid, 296
 hepatic, 183
 iliac, 182
 innominate, 180
 interlobular, 264
 jugular, 178
 of bone, 19
 of head and neck, 178
 of lower extremities, 182
 of œsophagus, 226
 of supra-renal capsules, 243
- Veins of thymus, 242
 of trachea and bronchi, 256
 of the eye, 296, 298
 of the kidney, 265
 of the larynx, 254
 of the lung, 259
 of the pancreas, 239
 of the penis, 274
 of the stomach, 229
 of the thorax, 181
 pulmonary, 183
 saphenous, 182
 spinal, 181
 thyroid, 241
 uterine, 284
 without valves, 178
- Velum interpositum, 187, 193, 194
- Venæ comites, 177
 propriæ renales, 265
 rectæ, 264
 vorticossæ, 296
- Venter of the ilium, 70
 of the scapula, 76
- Ventricle of the cord, 200
 fifth, 194
 fourth, 195
 of the larynx, 252
 third, 194
- Ventricles, lateral, 192
- Verheyen, stars of, 264
- Vertebra prominens, 64
- Vertebræ, 61
- Verumontanum, 269
- Vesaluis, foramen of, 32
- Vesicle, germinal, 285
 Graafian, 285
- Vesiculæ seminales, 278
- Vestibule, 280
 of the ear, 318
- Vidian canal, 33
 nerve, 213
 Vieussens, valve of, 196
- Villi, 230
- Viscus, 216
- Viscera, covered by peritoneum, 216
 partially, 248
 wholly, 248
- Vitellus, 285
- Vocal cords, 252
- Vomer, 48
- Vortex of heart, 157
- Vulva, 279

WALLS of the tympanum, 313
Wharton's ducts, 221
Whorl of heart, 157
Willis, circle of, 163
Wings of the sphenoid, 31, 32
Winslow, foramen of, 247
ligament of, 109
Wirsung, duct of, 238
Wormian bones, 20
Wrisberg, cartilages of, 251
nerve of, 206

YELK, 285

ZINN, zonula of, 301
Zona pellucida, 285
Zone, anterior vascular, 294
Zonula of Zinn, 301
Zygoma, 34, 60





REYNOLDS
BINDERY, INC.
DEC1972

NATIONAL LIBRARY OF MEDICINE



NLM 00104884 1