

SENN (E. J.)

al

Tenorrhaphy by Means of the Suture á
Distance of Catgut, with Report
of Case.

Read before the Chicago Pathological Society, April 9, 1894.

BY EMANUEL J. SENN, M.D.


CHICAGO.

INSTRUCTOR IN SURGICAL PATHOLOGY, RUSH MEDICAL COLLEGE; HOUSE-
SURGEON, ST. JOSEPH'S HOSPITAL; MEMBER OF THE
CHICAGO MEDICAL SOCIETY.



REPRINTED FROM
THE JOURNAL OF THE AMERICAN MEDICAL ASSOCIATION
APRIL 28, 1894.

CHICAGO:
PRINTED AT THE OFFICE OF THE JOURNAL OF THE ASSOCIATION
1894.



Tenorrhaphy by Means of the Suture à Distance of Catgut, with Report of Case.

Read before the Chicago Pathological Society, April 9, 1894.

BY EMANUEL J. SENN, M.D.

CHICAGO.

INSTRUCTOR IN SURGICAL PATHOLOGY, RUSH MEDICAL COLLEGE; HOUSE-
SURGEON, ST. JOSEPH'S HOSPITAL; MEMBER OF THE
CHICAGO MEDICAL SOCIETY.

REPRINTED FROM
THE JOURNAL OF THE AMERICAN MEDICAL ASSOCIATION
APRIL 28, 1894.

CHICAGO:

PRINTED AT THE OFFICE OF THE JOURNAL OF THE ASSOCIATION.
1894.



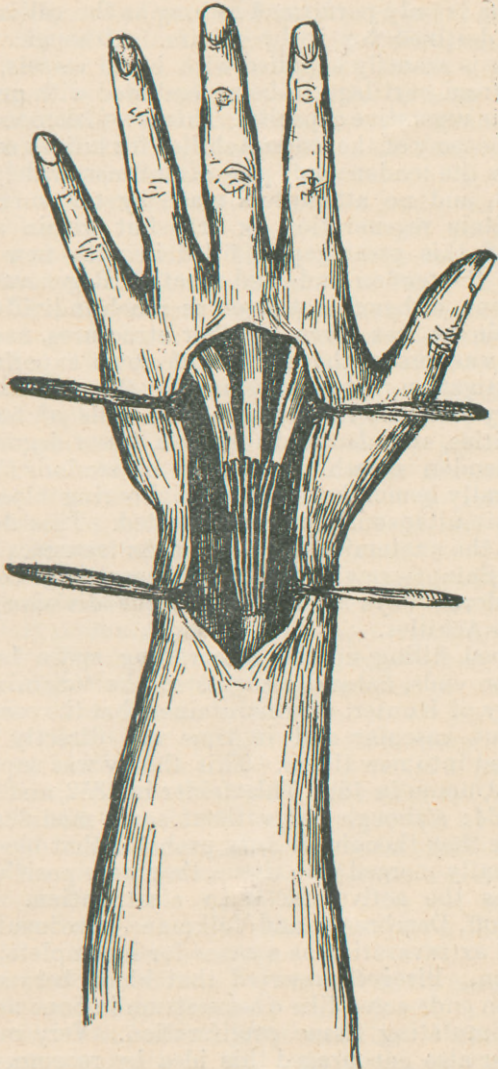
TENORRHAPHY BY MEANS OF THE SUTURE
À DISTANCE OF CATGUT, WITH
REPORT OF CASE.

Injuries to tendons and their sheaths is of frequent occurrence, and a perfect knowledge of anatomy and method of repair of these structures for the requisite surgical treatment is of great importance to the practical surgeon. In studying our text-books of surgery, one is struck by the liberal space allotted to fractures; while the subjects of laceration of tendons and treatment are superficially dealt with in a few lines. Although injuries to tendons occur both in hospital and private practice far less often than fractures, this subject should receive comparatively more consideration from authors, both from a pathological and surgical standpoint. It is not in recent cases where tendons are simply divided that surgeons meet with difficulties; but it is in old cases as in ancient fractures, where pathological conditions have manifested themselves and produce the many complications which call for difficult surgical intervention. Therefore, before considering the treatment by means of the *suture à distance*, I will comment lightly on the pathology and regeneration of divided tendons. Tendons are composed histologically of connective tissue. The cells are not round, but elongated into fibrils which are firmly bound together and give the appearance of white fibrous cords. They do not possess the quality of elasticity, and the vascular supply is very limited.

Tendons in performing their physiological function, glide backward and forward; and like other parts of the body which are subject to motion are provided with a means intended to place friction at a mini-

mum, that is, protection and lubrication. The tendon sheath answers these two purposes well. In complete rupture of tendons there is a loss of function and a consequent atrophy; followed later by a degeneration of the extremities to a limited extent. It is a law of nature that where a tissue irrespective of histological structure or vascular supply, and which has performed a customary amount of work is suddenly put to rest, either through trauma or otherwise, there is always more or less involution of its cells.

However, ruptured tendons differ from nerves in that the two ends only degenerate for about half an inch; while the medulla of the distal portion of a nerve degenerates into a granular mass, devoid of cellular organization. The sheath of Schwann which is composed of connective tissue, alone remaining intact. This difference is most probably due to the different functions performed by the two structures and also to their difference in histology. The one composed of connective tissue whose function is entirely mechanical, namely, that of moving the bone to which it is attached, through the contraction of its muscle; while nerve cells are of a far more highly organized structure, and have vital properties for the transmission of peripheral and central stimuli. The cells of an injured tendon are surrounded by cells of their own kind, as connective tissue is omnipresent in the body and they accommodate themselves according to circumstances by union with surrounding structures; so that no matter how far the tendon ends may have retracted, there will likely be some function performed through contraction of neighboring muscles. On the other hand, the distal end of a nerve, provided collateral anastomosis is not established, degenerates in the course of several weeks. This deterioration of nerve cells does not take place by reason of a deficient vascular supply, but as a result of loss of function. Cell life, either animal or vegetable, is only maintained when metabolism is in progress; and metal



bolism is only performed as long as the cell acts the rôle destined for it by nature. Although tendon tissue is scantily supplied with blood vessels, it differs from cartilage in being endowed with great intrinsic vegetative capacity. This is well demonstrated in tenotomy of the tendo-Achilles for talipes equinus, where the tendon ends are oftentimes widely separated, and no attempt is made by the surgeon to facilitate regeneration by art; but within a short period this great gap is filled in with new tissue from the tendon ends and sheath. Regeneration of tendons, although not given as much individual attention as was given to other structures, nevertheless was made the subject of some experimental investigation. It takes place by the production of embryonal cells from the mature cells of both extremities, and also probably to a lesser degree from the tendon sheath. In injury of tendons there is generally hemorrhage from neighboring blood vessels simultaneously cut or lacerated. This depends upon the anatomical location of the trauma.

M. Saint Germain speaks of a hemorrhage continuing eleven days after subcutaneous division of the tendo-Achilles.

Blood filling up the intervening space between tendon ends, naturally suggested the "organization" theory of Hunter, who maintained that the coagulum became vascular and in time was directly transformed into new tissue. This theory was supported by d'Ammon in 1837, Thierfelder in 1852, and Jobert in 1864; although not without some modifications. While they thought it very probable that blood was gradually merged into tissue, they were positive that it was the active factor in cicatrization. Later Pirogoff, Dembrosky and Volkmann gave insufficient blood extravasation as a cause for incomplete regeneration. Pirogoff asserted that blood between the tendon ends acted like a sequestrum in bone necrosis by stimulating tissue proliferation. Very recently Walter also encouraged this idea by recommending

in tenotomy, non-ligature of vessels, in order to produce a clot as devised by Schede in the treatment of bone cavities. The inter-tendinous bloody effusion disappears by absorption about the fifth or sixth day according to observations of Lebert. Bouvier in 1837 insisted that regeneration was affected by the cellular sheath, which through a process of corrugation and thickening, developed into a tendinous cord.

The blastema theory for a time found many adherents, championed by Henle in Germany, Robin in France and Brodhurst, Adams and Paget in England. This hypothesis was founded on the supposition that protoplasm was spontaneously developed into cells. This reasoning rested on a weak foundation when it came to practical demonstration and was soon exploded. Bizzozero in 1868 already looked upon the principle of this theory in the light of a second rôle. Cohnheim made a step in advance toward the true law of regeneration when he affirmed that leucocytes which had emigrated from the blood vessels surrounding the interval between the two tendon extremities were changed into granulation tissue through their own innate powers. The cellular theory is the last promulgated and has been faithfully defended by Türcher, Donders, Virchow, Remak, Kölliker, Cornil and Ranvier. Regeneration of connective tissue is analogous to regeneration of any other tissue, in that it can only generate from mature cells of its own kind. The blood clot acts in a passive manner by forming a temporary matrix for the immature cells and also in the capacity of an irritant; thus provoking a hyperæmia which is favorable to the production of new tissue. The iodoform gauze tampon accomplishes the same effect; only one is artificially produced, while the other is nature's effort to accomplish the same purpose.

After injury there is always more or less para-vascular extravasation of blood; which is not essential for regeneration, but is a great auxiliary. Karyokinetic figures are seen in the cells of the tendon ex-

tremities and also in the tendon sheath within forty-eight hours after the trauma, followed by the production of bud-like processes which extend into the blood clot. These are embryonal cells and being of connective tissue origin, are called fibro-blasts. They are round or angular in shape, multi-nucleated and are composed of the elementary matter of all animal and vegetable life, protoplasm. All proliferation is followed by vascularization, that is extension of blood vessels from the neighboring mature tissue into the mass of granulation tissue. Cicatrization next becomes manifest. The embryonal cells after having supported themselves through metabolism for a certain length of time, by their own natural inherent quality evolutionize into mature cells or fixed permanent tissue. The large round or angular cells gradually merge into fibrils. In this metamorphosis each cell draws its neighbor into closer relation; thereby producing cicatricial or scar contraction. In this instance nature again centers her efforts to a good purpose; for by the mechanism of contraction the two tendon extremities are brought nearer toward each other.

The *suture á distance* as a means of establishing communication between ruptured tendons was inaugurated by Gluck in 1884. He operated successfully upon a case where the extensor tendon of the index finger was separated eight centimeters. This mode of suture was studied experimentally by Forgin, Assaki, Jeannel and Van Haecke. Where the divided ends are not too far apart, a plastic operation should always be resorted to; that is the procedure devised by Czerny, of splitting the tendon upon one side for some distance, and turning the divided flap over to its fellow of the opposite side and suture. If the flap does not reach, the other tendon should be treated in the same manner and both flaps united end to end. In cases where approximation can not be secured, the *suture á distance* is the most useful, in fact it is the only operation which can be resorted to

under the circumstances. An absorbable suturing material, such as sterilized catgut or kangaroo tendon should be used. The tendon ends are united *à distance* by several sutures in order to make a firm bridge-work. Catgut becomes entirely absorbed by phagocytosis in a short time. The operation meets several important indications, namely: 1, it prevents the tendon ends from retracting through elasticity of the muscle; 2, it forms a passage way for tissue proliferation; 3, it establishes a barrier, by which the embryonal cells secure protection from atrophy, caused by pressure of surrounding parts; 4, the suture being a foreign body, acts as a stimulant to the mature cells.

The following case is of interest, as there was extensive loss of substance of the extensor tendons of the hand, and this was entirely remedied by the absorbable *suture à distance*.

Mr. G. H., young man, English, miner by occupation; residence Northern Michigan. Entered St. Joseph's Hospital Jan. 6, 1894. Three months previously while at work in a mine, he accidentally thrust his wrist against a jagged, sharp rock, making a complete transverse incision of the extensor communis digitorum tendon at its junction with the muscle just below the middle of the fore-arm. The extensor indicis tendon was also severed. After the accident the integument was stitched and the wound bandaged. According to the patient's statement no attention was given to the deeper structures. The dressings were removed several days later and the wound found healed; but the three fingers supplied by the extensor communis digitorum were absolutely useless as far as extension was concerned. The patient waited three months in the hope of again recovering the use of his disabled hand, but to no avail.

Operation: Incision of three inches in the area of the old scar, parallel with the tendons. After carefully dissecting away the scar tissue, the proxi-

mal end was found. It did not consist of connective tissue, but was true muscular structure. Then came a tedious search for the four distal extremities, the three tendons of the extensor communis digitorum and the extensor indicis. After searching for some time without success, I carried the incision further in the distal direction and found the tendon ends about two inches above the metacarpo-phalangeal line. The perplexing problem of securing union between the distal ends and the proximal end now presented itself, as the intervening space was four inches in length. Splicing after the method of Czerny could not possibly be practiced here, and under the circumstances, I resorted to multiple *sutures á distance*, as the means of indirect approximation. Medium sized catgut, sterilized according to Bergmann's method was used. I made eight sutures, connecting the extensor communis digitorum and the extensor indicis tendons to the extensor communis digitorum muscle. The external wound was closed with an interrupted row of silkworm sutures and a continued row of catgut. No provision was made for drainage, as hemostasis had been well effected by ligature and hot water irrigation. The hand was dressed in an extended position upon an anterior splint. The dressing was removed upon the fourth day and the wound presented a favorable appearance, except for a small suppurating focus around one stitch. This suture was removed and after thorough disinfection with a solution of bromin and insertion of a small iodoform gauze tampon, the dressing was re-applied. The wound was irrigated the subsequent three days and I succeeded in aborting a diffuse suppuration, the wound healing intact. The sutures were removed upon the ninth day. On the twelfth day the patient could extend the three fingers upon the splint with slight effort. He speedily recovered the use of his fingers and at the end of a month was discharged from the hospital with function

entirely restored. Patient could lift a glass of water to his mouth and even write with perfect ease.

Remarks:—Although I did not have the opportunity of making an examination *in vivo* of the regenerative process which took place, I am satisfied that there was new tendon tissue produced to the extent of over four inches. When the patient made extension, by placing a finger at the muscle extremity, the impulse was perceptible along the whole route of the tendons, showing that there was direct communication. The new fibrous cords when in action would bulge and become prominent to such an extent as to become visible through the skin. These tests were convincing proofs. This case is also of pathological interest by reason of the sutures uniting muscle with tendon. Muscle cells are endowed with very limited intrinsic vegetative capacity, and do not extend further than an inch from the ruptured end; so that in this case proliferation from the distal extremity was the prime factor in effecting reposition, as connective tissue is the most prolific of all tissues. I wish also to dwell on the importance of making as many sutures as possible in order to construct a canal, thereby securing a line of least resistance for the embryonal cells. If I had secured each tendon with but one suture, I am certain that there would have been very probably an obliteration of the canal by neighboring tissues, and consequent failure of the operation. An interval of four inches is an unusual occurrence. It is seldom that tendons become separated for more than one or two inches at the most; and when united by this method, the operation will yield encouraging results.

