

Vaughan (George T.) *Supplement of the water*

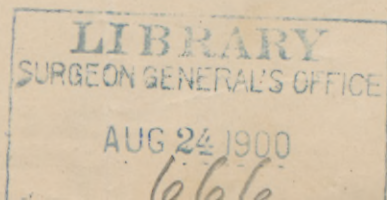
[Reprinted from THE MEDICAL NEWS, Jan. 8, 1898.]

**EXCISION OF THE RIGHT CLAVICLE FOR
OSTEOSARCOMA.**

BY GEORGE TULLY VAUGHAN, M.D.,
OF WASHINGTON, D. C.;
PASSED-ASSISTANT SURGEON, U. S. M. H. S.; PROFESSOR OF PRIN-
CIPLES AND PRACTICE OF SURGERY IN GEORGE-
TOWN UNIVERSITY.

W. S., American, aged twenty-eight years, was admitted to the marine ward of the German Hospital, Philadelphia, October 15, 1895. His family history was negative, and he denied all venereal diseases and rheumatism. During March, seven months before admission, he began to complain of pain situated in the right clavicle. Shortly afterward enlargement of the bone became apparent. The pain was of a dull aching character, often radiating to the chest and mastoid process on the right side, and was aggravated by use of the arm. On examination, the inner two-thirds of the clavicle was found to consist of a hard, spindle-shaped tumor, extending to within $2\frac{1}{2}$ cm. of the joint. The right external jugular vein was distended.

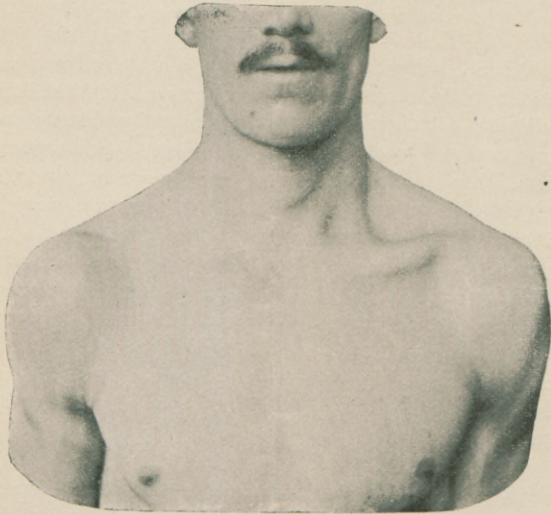
October 22d, under ether anesthesia, the entire right clavicle, with the tumor, was removed by an incision extending along the bone from one end to the other, disjoining the acromial end first, dissecting the tumor loose from the surrounding parts, and last, disarticulating at the sternoclavicular articulation. The tumor was broken through while using the bone as a lever in separating its sternal attachments. To control the hemorrhage, it was necessary to apply over twenty ligatures. To prevent dropping of the shoulder, the detached portions of the trapezius and sternocleidomastoid muscles above were carefully sutured to corresponding portions of the deltoid and pectoralis major muscles below. The wound was



closed with catgut sutures, leaving an opening in the middle for a gauze drain, and the dressing was applied, with the arm in the Velpeau position.

Subsequent to the operation, the highest temperature was 102.2° F., which continued for one day only.

FIG. 1.



Showing site of operation and resulting deformity after excision of the clavicle.

Fourteen days after the operation the patient was out of bed. The wound healed by primary union, except at two points, one in the middle and one at the outer end, which healed by granulation. Forty-one days after the operation the patient was discharged. There was no deformity and no interference with the function of the arm. The tumor measured 11.25 c.cm. in circumference, and, on microscopic examination, was pronounced a mixed-cell

sarcoma. The accompanying illustration shows the condition of the parts one year subsequent to the operation, and it will be seen that there is absolutely no deformity except the absence of the clavicular prominence on the right side. During the interval he had been performing his accustomed work as fireman on a steamboat, and stated that he felt no inconvenience from the loss of the clavicle, his arm being free from pain and as strong as ever. With his clothes on there was no evidence of dropping of the shoulder, and after stripping it was barely perceptible—not more than one centimeter—which is no more than is often observed in the normal individual.

Excision of the entire clavicle seems to be a rare operation, though partial excision is comparatively common. Professor Ashhurst up to 1893, had been able to collect but 36 cases of the complete operation at one sitting, following which there were 7 deaths, a mortality of nearly 20 per cent. It seems that Dr. Charles McCreary did the first complete excision in 1813, removing the right clavicle from a boy of fourteen, with scrofulous caries; that of Remmer in 1732, given by Gross as the first operation, having been, according to Ashhurst, a partial excision. The same author gives the mortality from partial excision, or excision *a deux temps*, in 76 cases as a little over 14 per cent. The celebrated operation of Dr. Mott,¹ performed during 1828, for sarcoma of the left clavicle, which required nearly four hours for its performance, and in which forty ligatures were employed, was a case of partial excision, though from the size of the tumor and the part of the clavicle removed—the inner end—was really a more formidable operation than the majority of cases of complete excision. Dr. Mott referred to it as his “Waterloo operation,” and said that it was without a precedent, and far surpassed in tediousness, difficulty, and danger anything he had ever witnessed or performed.

¹ *American Journal of the Medical Sciences*, January, 1883.

Faint, illegible text, possibly bleed-through from the reverse side of the page. The text is arranged in approximately 20 horizontal lines across the page. A prominent brown stain is visible in the upper right corner.