

SHANDS (A. R.)

W. ... ; Compliments
of the Author.

TREATMENT OF CLUB-FOOT
BY WOLFF'S METHOD.

BY A. R. SHANDS, M. D., OF WASHINGTON, D. C.

Recent House Surgeon to Hospital for Ruptured and Crippled, New
York, N. Y. ; Professor of Orthopædic Surgery, Medical
Department of the Columbian University.

Reprinted from the VIRGINIA MEDICAL MONTHLY, September, 1894.



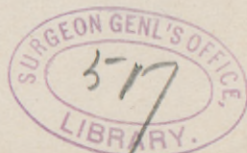TREATMENT OF CLUB-FOOT BY WOLFF'S METHOD.*

By A. R. SHANDS, M. D., of Washington, D. C.,

Recent House Surgeon to Hospital for Ruptured and Crippled, New York, N. Y. ;
Professor of Orthopædic Surgery, Medical Department of the
Columbian University.

In presenting to you, this evening, this report on the treatment of club-foot, it is not intended that any new method shall be advanced on this subject, about which so much has been written, nor to discuss any of the numerous theories described in all of the text-books; but simply to give a practical illustration of the method and the results of a treatment by means of plaster-of-Paris that is practiced by Prof. Julius Wolff, of Berlin. Various means have been and are being used for the correction of this deformity, such as plaster-of-Paris, splints, orthopædic appliances of various kinds, as well as various operative measures, such as tenotomies, fasciotomy, tarsectomies, etc., all giving, in the hands of the competent surgeon, good results. No rule can be established as to which is the best treatment, for in this, as in everything else, the method that the surgeon best knows is apt to give the best result. All admit that nothing in the whole range of orthopædic practice requires more persever-

* Read, by invitation, before the Orthopædic Section of the New York Academy of Medicine, October 20th, 1893.



ance and closer attention to the minute details of the means used than the treatment of an extremely deformed club-foot.

It was early in the spring of the present year that Dr. Gibney, Surgeon-in-Chief to the Hospital for Ruptured and Crippled, called my attention to the Wolff method of application of plaster-of-Paris in the treatment of club-foot, and it was at his suggestion that this treatment was begun in these cases that I have the honor of presenting to you this evening. Only in the non-use of any anæsthetic has the treatment differed essentially from that of Wolff, as described in a paper read before the "Association of American Physicians," in Berlin, by Dr. Freiberg, of Cincinnati, and published in this country in the *Medical News*, October 29th, 1892.

In the paper above referred to, Wolff is said to first anæsthetize his patient, except in cases of very young children and in slight degrees of club-foot, and then, by manual force, he brings the foot into its proper position, or as nearly so as he can at one sitting without use of too much force. Then, while an assistant holds the foot in this corrected position, he applies strips of rubber adhesive plaster spirally around the foot, extending them well up above the ankle. This is done with a view of aiding to hold the foot in its new position until the plaster-of-Paris is applied. As no attempt has been made in these cases to reduce any of the deformity at the first sitting, there has been no need of either an anæsthetic or the adhesive plaster. No difficulty has been found in these cases to apply the dressing with the assistance of an ordinary nurse, after which the patient has been allowed to remain undisturbed for at least twenty-four hours before beginning the redressment. This gives ample time for the plaster to set, and, at same time, serves to restore confidence on the part of the child. At the first two or three sittings, an attempt has been made to correct but very little of the deformity, for the pain will be much greater at first than it is later on. It will be found to be best to regu-

late the amount of twisting all through the course of treatment by the amount of pain it gives.

The method of applying the plaster and the treatment is as follows: First, apply a piece of cotton felt to both the outer and inner borders of the foot, extending it over the malleoli. This is done as an extra precaution for the protection of the bony prominences, being needed especially over the metacarpo-phalangeal joint of the great toe, and over the cuboid bone—the latter being usually very prominent. Then apply snugly at least two thicknesses of a canton flannel bandage to the foot and leg, extending it up as far as the tuberosity of the tibia. Now, having the foot and leg well protected, the plaster is applied, extending it also up to the tuberosity of the tibia; this will prevent the leg from moving in the plaster case and give a better leverage when the redressment is begun. Two ordinary sized plaster bandages will be found quite sufficient for a foot and leg of a child six or eight years old. Care should be taken to have the toes held in their natural relation to each other; otherwise you will have an uneven pressure, and, as a result, swelling and pain. The plaster should extend well over the toes, leaving their ends exposed; then grasp the leg with one hand, holding it steady on the table, and with the other make pressure on the plantar surface of the foot with a small piece of board. This serves the purpose of overcoming some of the deformity, and, at the same time, will give an even surface upon which the child can walk. On the following day, begin the redressment by cutting out a wedge shaped piece of the plaster on the outer border of the foot, selecting the point most prominent in the deformity, for there is where the pressure is most needed, then connect the upper and lower angle of this cut by cutting a line through the plaster only around the foot. Care should be taken not to have this linear cut around the foot near enough to the heel to allow the foot to slip in the dressing when it is twisted, and thereby defeat the object in view. The plaster case is now in two parts, each firmly fixed to the foot; now, by grasping the leg with one hand

and the end of the foot with the other, it takes but little force with this leverage to bring the opposite sides of the wedge-shaped incision into apposition, and thereby overcome a certain amount of the deformity. While an assistant holds the parts in their new relation to each other, they are fixed there with another wet plaster bandage applied around the foot and ankle in a figure of eight, care being taken to fill well the gap made by the linear incision on the inner side of the foot. This third bandage being applied on a dry surface, it can be easily peeled off at the next sitting; then make the wedge-shaped incision larger, and repeat the redressment as before. This can be repeated three or four times, when it will become necessary to apply an entirely new dressing. Great care should be taken lest you get compressed, between the edges of the plaster when forced together, a fold of loose skin, in which case a bad excoriation will result. This was learned by experience, for, in one of these cases, not only the operation had to be suspended, but the excoriation becoming infected, quite an extensive cellulitis followed which gave some trouble to heal.

Cutting plaster dressing is no easy job; quite a simple and easy way of doing it in these cases is to use a small, fine-tooth hand-saw, and by dipping it in warm water every few seconds it goes through quite easily. The foot being well protected with cotton felt and bandages, there is little or no danger of its being cut. The number of sittings will have to be regulated by circumstances, pain, etc. In these cases it has been done in two four times a week, and in the others two and three times a week. The condition of varus should be corrected first, after which the equinus can be corrected by making the wedge incision on the dorsum of the foot, and the linear incision over the heel, so as to allow the tendo-achilles to be stretched. If much pain is complained of, which is likely to occur only at some of the bony prominences, it can be readily relieved by cutting out a fenestrum and thereby relieve the painful pressure.

The treatment should be continued until the foot is some-

what over-corrected, and then Wolff advises that it be held there by means of a plaster case protected with silicate of soda, and, incorporated in the plaster, a piece of light steel extending from the ball of the foot above the heel. A piece of steel one-half inch wide and as thick as the blade of a case knife, will be found quite sufficient. Then fit a shoe over this case, which is allowed to remain for at least six months.

CASE I.—Louis S., age eight years. Diagnosis: Left congenital equino-varus. *November 8, 1892.*—Astragalus removed.

January 10 and February 20, 1893.—Under ether, foot twisted with Thomas' wrench.

March 14.—Wolff treatment begun; has 35 or 40 degrees of varus remaining.

April 15.—Deformity corrected; had redressment bi-weekly.

CASE II.—Charlie B., age eight years. Diagnosis: Double equino varus. Left foot has 35 degrees of varus; right, 45 degrees. *March 21.*—Etherized; has left achillotomy, plantar fasciotomy, and twisted with Thomas' wrench. Right foot has Wolff method begun.

April 10.—Left foot again twisted with Thomas' wrench, and put in plaster.

April 20.—Both feet over-corrected. Right foot has had Wolff method bi-weekly.

CASE III.—Willie S., age six years. Diagnosis: Left equino-varus. Has 45 degrees of inversion. *March 25.*—Wolff method begun.

June 1.—Deformity overcome entirely. Has had redressment bi-weekly. Discharged from hospital with foot in plaster and silicate of soda case.

CASE IV.—Willie C., age eight years. Diagnosis: Left equino-varus. Had Phelps' operation at Bellevue in 1891. *September 10, 1892.*—Stands with external border of foot on floor and in extreme inversion.

March 24, 1893.—Has had ether five times since admission, and foot twisted with Thomas' wrench and plaster applied at each sitting. Has about 25 degrees of varus remaining. Wolff treatment begun to-day.

May 15.—Has had redressment once a week for the past seven weeks. Condition of varus entirely overcome.

CASE V.—Robt. C., age nine. Diagnosis; Right equino-

varus, with well marked pes cavus. *March 17.*—Had achillotomy, fasciotomy, and twisting with Thomas' wrench.

April 1.—Foot partially corrected as to both cavus and varus, about 30 degrees of varus remaining.

July 20.—Condition of varus corrected; some cavus still present. Has had redressment bi-weekly for six weeks altogether; had to discontinue treatment for six weeks on account of an excoriation.

CASE VI.—Norman McG., age four and a half years. Diagnosis: Double equino-varus. Stands on outer border of left foot, with about 45 degrees of inversion; right, about 25 degrees of inversion. *July 15.*—Has achillotomy, plantar fasciotomy, and twisting with Thomas' wrench of both feet.

August 26.—Has 35 degrees of inversion of right, and 15 or 20 of left. Wolff method begun to-day.

September 9.—Deformity of right corrected at four sittings.

September 15.—Left corrected at eight sittings. (See photograph before and after treatment.)



CASE VI.—Before Treatment



After Treatment.

CASE VII.—Roland B., age four and a half years. Diagnosis: Right equino varus. Has had no treatment.

August 30.—Foot rests on outer border; over cuboid bone is a callous, size of a silver quarter. Toes point directly across to inner border of opposite foot. Wolff treatment begun to-day.

October 1.—Inversion of foot corrected; has had redressment tri-weekly, thirteen sittings. (See photograph before and after treatment.)



CASE VII.—Before Treatment.



After Treatment.

CASE VIII.—Chas. P., age eight and a half years. Diagnosis: Double equino-varus. Had double achillotomy when three years old; was treated at Roosevelt Hospital for one year when three years old. June 13.—Walks on outer border of feet, with toes pointing across to opposite foot; feet are inverted to a right angle. Has astragalotomy of left foot, and an open incision on inner side of foot. Right foot has achillotomy, fasciotomy, and twisting with Thomas' wrench.

August 9.—About 45 degrees of inversion of each foot remains. Wolff method begun to-day, taking right foot first.

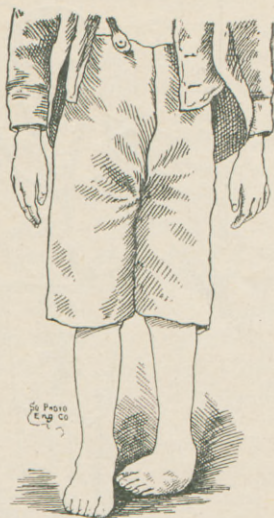
September 20.—Deformity of right foot corrected at eight sittings.

October 15.—Deformity of left foot corrected at nine sittings.

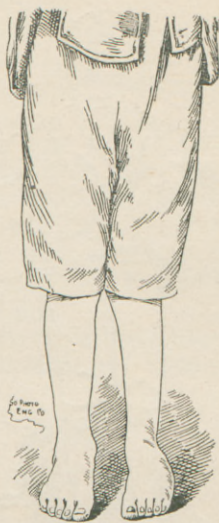CASE IX.—Andrew T., age nine years. Diagnosis: Left congenital equino-varus. Has never had any treatment. Stands on outer border of foot, with foot inverted at right angle at medio-tarsal joint. (See photograph.)

September 13.—Wolf treatment begun.

October 16.—Deformity of foot corrected. (See photograph.) Has had redressment three times a week for past four weeks.



CASE IX.—Before Treatment.



After Treatment.

The treatment of these cases has necessitated a great deal of patience, perseverance and labor; but, when such results as have been shown can be obtained in so short a length of time, without the use of either an anæsthetic or the knife—consequently, with no risk of an operation—one should surely feel well repaid.

As it is well known that these deformities all have a tendency to a rapid recurrence when left unprotected, the importance of an over-correction, before discontinuing the treatment, cannot be too strongly urged. Convert the equino-varus into a slight degree of calcaneo-valgus, and then hold it there sufficiently long for the new position to become permanent. Surely there can be no more effectual way of doing this than is recommended above. The cheapness of this method as to apparatus is another great recommendation in its favor.

1305 H Street, N. W.

