

MED
HISF

SENN (N.)

Reprinted from
ANNALS OF SURGERY,
August, 1893.

A New Method of Direct Fixation of the Fragments in
Compound and Ununited Fractures.

By NICHOLAS SENN, M.D., Ph.D., LL.D.,

OF CHICAGO.

PROFESSOR OF PRACTICE OF SURGERY AND OF CLINICAL SURGERY IN RUSH
MEDICAL COLLEGE; PROFESSOR OF SURGERY IN CHICAGO POLYCLINIC;
ATTENDING SURGEON PRESBYTERIAN HOSPITAL; SURGEON IN
CHARGE ST. JOSEPH'S HOSPITAL.

presented by the author

SURGEON GEN. ...
498
LIBRARY

A NEW METHOD OF DIRECT FIXATION OF THE
FRAGMENTS IN COMPOUND AND
UNUNITED FRACTURES.¹

BY NICHOLAS SENN, M.D., PH.D., LL.D.,

OF CHICAGO,

PROFESSOR OF PRACTICE OF SURGERY AND OF CLINICAL SURGERY IN RUSH
MEDICAL COLLEGE; PROFESSOR OF SURGERY IN CHICAGO POLYCLINIC;
ATTENDING SURGEON PRESBYTERIAN HOSPITAL; SURGEON IN
CHARGE ST. JOSEPH'S HOSPITAL.

THE treatment of compound and ununited fractures has always been a fruitful field of research and observation for the surgeon. Notwithstanding that this subject has been the special study of many able surgeons, it has not reached the stage of perfection its importance demands. It is true that the adoption of rigid antiseptic precautions in the treatment of compound fractures has reduced the mortality from 50 to 70 per cent. almost to *nil*, and the same has rendered operations for ununited fractures nearly devoid of danger. On the other hand, it must be admitted that the mechanical treatment of both these classes of fractures has undergone but little improvement during the last decade, which has witnessed such marvelous improvements in other departments of surgery. No systematic attempts have been made to utilize the wound in compound fractures for the purpose of securing accurate reduction and perfect retention. For many years the operative treatment of ununited fractures has undergone no material change. The principal object of this address is to make an earnest plea in favor of a more frequent recourse to direct means of fixation in the treatment of compound and ununited fractures. It appears to me that the time is at hand when a compound fracture should be treated upon the same prin-

¹ President's Address, delivered at the meeting of the American Surgical Association, May 30, 1893.



ciples as a wound of the soft parts, viz., to bring into apposition and hold in contact by direct temporary mechanical measures the different anatomical constituents of the wound until the process of repair is completed. As soon as this method of treatment is perfected and more generally adopted, we shall hear less frequently of the many unsatisfactory remote results of these injuries, such as delayed and non-union paralysis, impairment of general health from long confinement to bed, shortening, angular deformity, displacement by rotation, exuberant callus, and permanent injury to adjacent joints from long-continued permanent extension. In very oblique fractures, compound as well as simple, interposition of soft tissues takes place more frequently than is generally supposed, and this condition not infrequently is the sole cause of non-union. In oblique fractures of the femur it is generally conceded that continued extension and external fixation do not succeed in preventing more or less shortening and angular deformity. It is a well-known fact that long-continued extension is usually followed by temporary and often by permanent injury to the adjacent joints. Over-riding of fragments is often productive of harmful pressure upon important vessels and nerves. Displacement of fragments and imperfect immobilization are the most potent factors in the production of exuberant callus which so often impairs the functional result and so frequently causes remote painful affections. Displacement of detached fragments in comminuted compound fractures is often not recognized, and much less frequently corrected without direct intervention.

Thorough disinfection is frequently out of question without enlarging the external wound and free exposure of the seat of fracture.

Long-continued confinement in bed incident to treatment of fractures of the lower extremities is detrimental to the general health of the patient, and is often the indirect cause of many fatal intercurrent affections. These evils attending the treatment of compound fractures heretofore in vogue can be avoided in a measure by resorting to direct fixation of the fragments. Direct treatment of the fracture does not add to but diminishes the danger of traumatic infection, provided the operation is done under strict

antiseptic precautions. It not only enables the surgeon to bring the fragments into accurate apposition and secure permanent retention, but it also makes it possible for him to disinfect every part of the wound, and to arrest the hæmorrhage, important elements in the prevention of traumatic infection. Such treatment thoroughly and conscientiously carried out imparts a sense of security regarding the usual immediate and remote complications which is foreign to the ordinary routine treatment.

HISTORY OF DIRECT IMMOBILIZATION OF FRAGMENTS.

The same means which have been resorted to in holding the fragments together in the operative treatment of ununited fractures have been employed occasionally in immobilizing compound fractures. The objects to be obtained in both forms of fracture were the same, viz., to bring the fractured or vivified surfaces in contact and secure perfect retention during the process of repair.

Suturing.—Perhaps the oldest method of accomplishing direct fixation is suturing. Different kinds of metallic wire, silk, silkworm gut and absorbable sutures have been employed for this purpose. Silver wire is the material most frequently used. Before antiseptic surgery was practiced the ends of the wire were brought out of the wound with the intention of removing the suture, as soon as the object for which it was employed had been realized. Since it has been ascertained by experiments and clinical observations that small antiseptic substances can be safely left in aseptic wounds, the wire was cut short to the twist with the expectation that the suture would become encysted and remain indefinitely in the tissues without causing any disturbance. In oblique fractures with a tendency to shortening, the tension on the suture is great, and undoubtedly has often seriously impaired the nutrition of the part of the fragments included in the suture. For good reasons the bone suture has often been charged with causing necrosis. The old method of suturing fragments is very defective, as the suture was made only to include one side of the broken bone.

The technique of bone suture has recently been materially improved. Wille (*Eine Verbesserung der Technik der Knochen-sutur. Centralblatt f. Chirurgie, 1892, No. 46*), has recently modified the old method in so far that the wire is made to

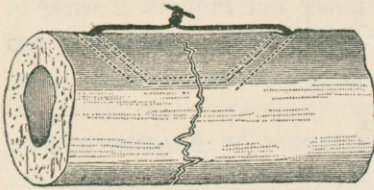

FIG. 1.—Old method of bone suture.

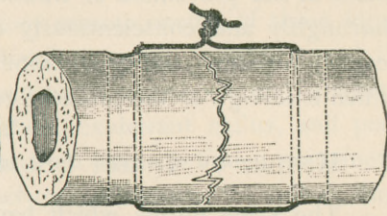


FIG. 2.—Improved bone suture. Transverse fracture, wire suture including entire thickness of both fragments.

include the entire thickness of both fragments in wiring transverse and slightly oblique fractures.

The same author has also shown that in suturing oblique fractures by this method the suture does not prevent lateral and longitudinal displacement, as can be seen from the two illustrations represented by Figs. 3 and 4.

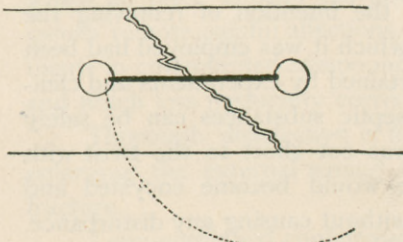


FIG. 3.—Oblique fracture sutured, showing curve in which fragment will become displaced.

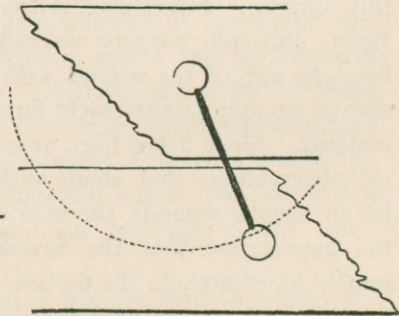


FIG. 4.—Extent of lateral and longitudinal displacement that may occur.

The further the drill openings are apart the greater will be the tendency to displacement. In very oblique fractures Wille advises to cut two grooves with a file or saw in the fragments, the direction of the groove being at a right angle to the fractured

surfaces, and the tying of the fragments firmly together with silver wire.

If the seat of fracture is sufficiently accessible so that the drill can be applied vertically to the fractured surfaces, he drills

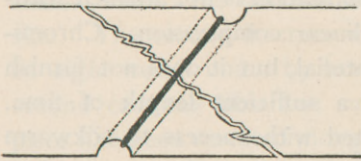


FIG. 5.—Peripheral groove for wire.

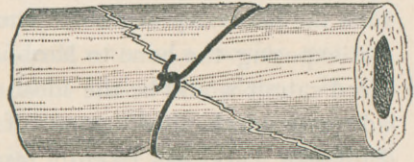


FIG. 6.—Lateral groove for wire.

through both fragments, and with a hook of his own device pulls a silver wire through the perforation, cuts the wire in the centre, and twists each half separately.

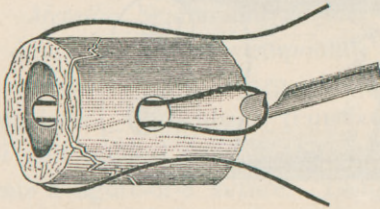


FIG. 7.—Wire drawn through the perforation.

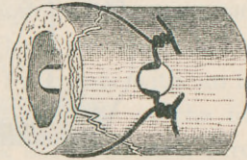


FIG. 8.—Wire cut in the centre and each half twisted separately.

It appears to me that in operating by this method it would be much better not to cut the wire, but pass both ends through the loop and twist them in the same manner as in tying the

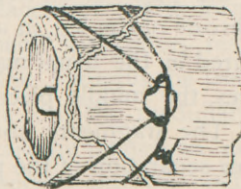


FIG. 9.—Author's modification of twisting the wire, Staffordshire knot.

Staffordshire knot. These modifications of suturing the fragments are a great improvement upon the old method, but do

not set aside all of the objections to the silver wire suture. The drilling of the fragments, the passing of the silver wire through the perforation made with the drill, the twisting of the wire, are details which often require a great deal of time and are attended by many and frequently insurmountable difficulties; at the same time the necessary degree of immobilization is not attained without exposing the bone to harmful linear compression. Chromicized catgut would be the ideal material, but it does not furnish adequate mechanical support for a sufficient length of time. Professor Park has recently resorted with success to silkworm gut as a substitute for silver wire in the direct treatment of an ununited fracture.¹ While such means of direct fixation may frequently answer a useful purpose in the treatment of ununited fractures, they are not applicable in maintaining retention in very

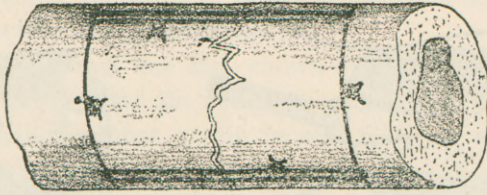


FIG. 10.—Dollinger's bone ligature as a substitute for bone suture.

oblique recent fractures, owing to the strong muscular contractions invariably present in such cases.

Dollinger² describes a new method of bone suture, or rather bone ligature, which he has made use of in two cases where perforation of the bone could not easily be carried out. In one case, pseudarthrosis of the leg, in a man forty-three years old, the tibia was sutured in the usual manner. The fibula was fractured in two places, the middle piece, about four inches in length, lying loose. The fragments could not be perforated without causing further separation of the periosteum. A ring of silver wire was placed around the lower part of the upper frag-

¹ American Journal of the Medical Sciences, April, 1890.

² Knochennaht ohne Durchbohrung des Knochens, Centralblatt für Chirurgie, 1893, No. 2.

ment a little above the seat of fracture, and a similar ring around the upper part of the middle fragment. A piece of wire was then placed on each side of the fragments, parallel to the long axis of the bone and within the two rings encircling the bone. The rings were then tightened up and fixed, and then the longitudinal wires were doubled over and their ends united on each side. The second fracture was dealt with in a similar manner. In eight weeks union by bony callus had taken place. In the second case the tibia was sutured in a similar manner, after a piece had been resected along with a tumor which had developed in the part. The resected ends were hard and ivory-like and could not be readily sutured in the ordinary way. While this method of suturing may guard effectively against diastasis of the fragments, it certainly could not prevent lateral displacement and shortening in oblique fractures.

Metallic Spikes and Screws.—Among the older methods of direct fixation of compound and ununited fractures must be mentioned the sharp metallic spikes recommended by Malgaigne. Dieffenbach transfixed the fragments with an iron nail and applied over it and including one side of the fragments a figure-of-8 suture. Langenbeck used two steel screws which were driven into the fragments, and which were then connected by an iron bar, which effected immobilization of the fragments.

Ivory Cylinders and Clamps.—Volkman and Heine inserted an ivory cylinder into the medullary cavity of the fragments across the line of fracture with a view of preventing lateral and longitudinal displacement. The former applied this treatment in three cases with satisfactory results. In two cases of ununited fracture of the humerus he used an ivory nail, which reached some distance into the medullary cavity of each fragment. In the third case he treated an ununited fracture of the femur in a child by inserting into the medullary canal a piece of fresh bone taken from an amputated limb. In all of these cases the foreign substance healed in and was undoubtedly eventually removed by absorption. This method of treatment has been

more fully described by Bircher,¹ to whom it has generally been accredited. Bircher uses a solid ivory cylinder. Its method of insertion and relative position to the fragments are shown in Fig. 11.

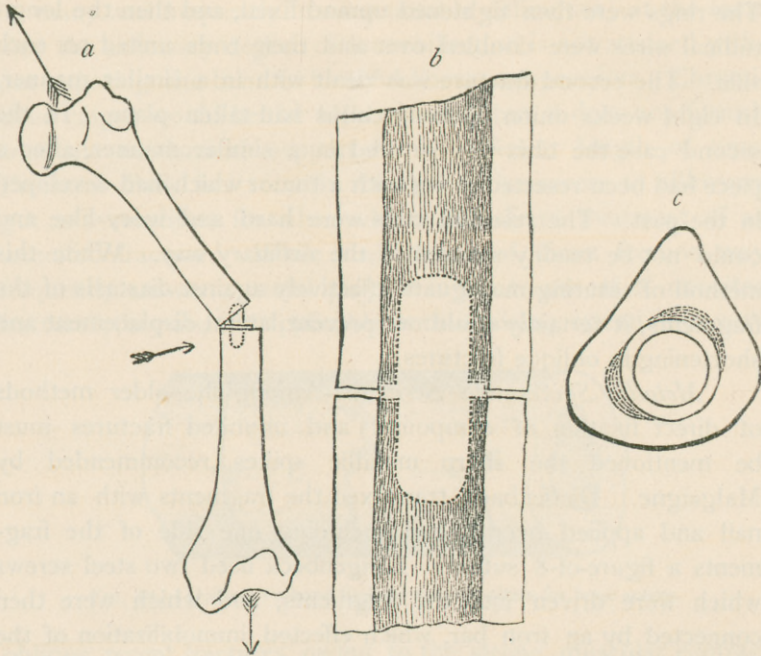


FIG. 11.—Bircher's method of retention with ivory cylinder.

- a* { Direction of pressure.
 { Traction upon leg.
b { United fracture place.
 { Longitudinal section. Natural size.
c { Transverse section showing ivory cylinder in the interior of the
 { medullary canal.

To prevent slipping of the ivory cylinder upward or downward he makes a shoulder or projection at the centre on one side of the cylinder, which rests in a depression made with a chisel in one side of the medullary canal, as is shown in Fig 12, or in a bone defect at the seat of fracture, as in Fig. 13.

The ivory clamp which he uses in uniting fractures of parts

¹ Eine neue Methode unmittelbarer Retention bei Fracturen der Röhrenknochen. Archiv. f. klinische Chirurgie, Band xxxiv, S. 410.

of bones devoid of a medullary cavity resembles the capital letter H, one bar of which rests in the channels cut on each side in the bone, while the other bar rests on the surface of the fragments.

Bircher treated by these methods of fixation five cases, four compound fractures, and one subcutaneous fracture (femur) com-

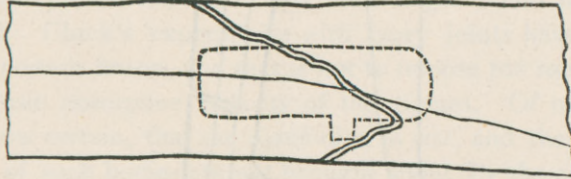


FIG. 12.—Shoulder of ivory cylinder fixed in depression of wall made with chisel.

plicated by a large hæmatoma. In all of the cases more or less suppuration followed, and the foreign body was removed as soon as firm consolidation had taken place. In every instance bony union in good position with very little shortening was secured, and the functional results were excellent. In the com-

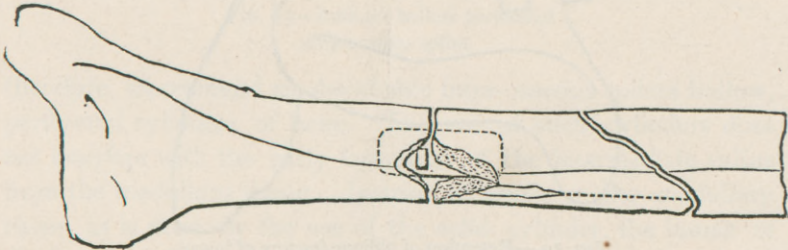


FIG. 13.—Projection of ivory cylinder resting in defect at seat of fracture.

pound fractures infection had taken place before the treatment was commenced.

Socin¹ has given this treatment quite an extensive trial, and is pleased with the results. He has applied it in pseudarthrosis caused by defective reposition or interposition of soft parts, and in many cases of compound fracture. He does not resort to

¹ Die Behandlung gewisser Knochenbrüche mittelst Einlegen von Elfenbeinstiften, in die Markhöhle.—Correspondenzblatt f. Schweizerärzte, 1887, No. 12.

the operative removal of the ivory cylinder. The method has yielded such encouraging results in his hands that he intends to extend it to the treatment of subcutaneous fractures, with a strong tendency to displacement of the fragments, as in very oblique fractures of the lower third of the tibia.

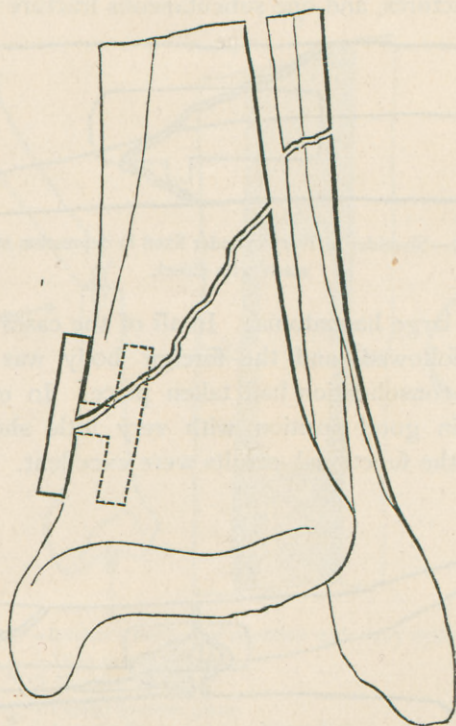


FIG. 14.—Retention of oblique fracture of lower end of tibia by ivory clamp.

ABSORPTION OF ASEPTIC IVORY AND BONE IN THE LIVING TISSUES.

The insertion of a solid ivory cylinder into the medullary cavity of the shaft of the long bones as a means of direct fixation is not applicable in the treatment of very oblique fractures, as immobilization and retention cannot be thus secured. Again, the introduction of such a large and solid foreign substance overtaxes the absorptive capacity of the tissues, and either removal by operative treatment becomes necessary, or spon-

taneous elimination is sure to take place sooner or later. There is a limit to the absorption of aseptic absorbable bodies. While an aseptic ivory or bone nail driven into bone for the purpose of exciting callus production, or to serve as a temporary means of fixation, will be removed by absorption in the course of time, if their immediate vicinity remains aseptic, a similar disposal of a solid ivory cylinder the size of the little finger could hardly be expected. Gluck's experiments with ivory joints have taught us an important lesson, and that is not to impose too much upon the intrinsic absorptive capacity of the tissues. Of one thing we are now certain, that the diminution in size, and the ultimate removal of such bodies are not brought about by the corroding action of pus, as has been claimed by many, but by the action of living tissues. The mechanical effect is the same whether a solid or hollow cylinder of ivory or bone is used. I would,

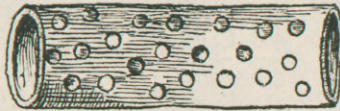


FIG. 15—Author's hollow perforated intra-osseous splint.

therefore, recommend as absorbable intra-osseous splints hollow, perforated cylinders of bone. The use of such cylinders does not interfere with the early formation of the intermediate callus from the medullary tissue. Instead of crushing the medullary tissue, as is done by the use of the solid cylinder, the lumen of the hollow cylinder is filled at once with this valuable bone-producing material, and the product of tissue proliferation, and the new bloodvessels later fill the perforations, and establish communication between the process of repair within and outside of the cylinder. The surface for absorption of the foreign substance is also immensely increased, and thereby the probability of its spontaneous removal greatly increased. Such cylinders should be made of the shaft of the long bones of young animals, such as chickens, turkeys, or rabbits. The medullary cavity can be increased in size by the use of a small round file, and the per-

forations made with a drill. The length of this intra-osseous splint will vary, according to the size of the bone and the obliquity of the fracture, from one to three inches. Displacement of the splint upward or downward need not be feared if additional immobilization is secured by an appropriate external support. Experimental research and clinical experience have demonstrated that pieces of aseptic ivory or bone of moderate size are removed by absorption in aseptic tissues. These substances, must, therefore, be included among the absorbable means of direct fixation of compound or ununited fractures. The encapsulation of unabsorbable material, used for the same purpose, is always an uncertain process, and it is a well-known clinical fact that even encapsulated foreign substances may give rise to disturbances at any

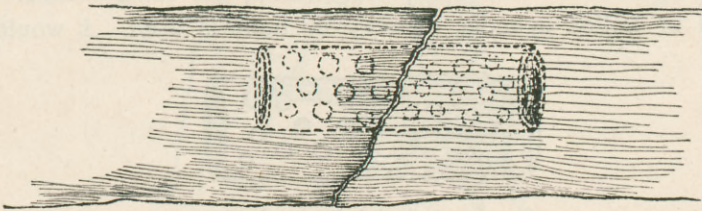


FIG. 16.—Intra-osseous splint *in situ*.

time. Trendelenburg¹ reports a somewhat unusual fate of an ivory nail which was used in the fixation of an ununited fracture of the lower end of the femur. The patient died two and a half years after the operation. Post-mortem examination showed that the fracture had united firmly by bony callus. The ivory nail had been driven into the bone in such a manner that it projected into the knee joint. That part of the nail in the bone remained unchanged, while the part which projected into the joint had become detached, and was found as a sequestrum in a small cyst which had formed in the capsule of the joint. The ends of this fragment were rounded off, and the surface was covered with giant cells. This observation would tend to prove that ivory may remain intact in aseptic bone tissue, while absorption

¹ Mittheilungen aus der chirurgischen Klinik zu Rostock, 1881.

takes place at a point where the foreign substance perforates the periosteum, that is, on the surface of the bone.

Riedinger¹ made experiments on animals in reference to the fate of ivory nails and fragments of bone and other material implanted into living bone. Wood, rubber, etc., produced in every instance suppuration, and was invariably eliminated. Ivory and fragments of bone, even if taken from another species of animals, produced no such result, and were gradually reduced in size, and finally disappeared. He made the observation that the speed with which the material disappeared by absorption depended on the vascularity of the bone. In one experiment a fragment of bone which was driven into a perforation of the shaft of a long bone did not undergo absorption except that part which projected into the medullary cavity. He ascertained, also, by his experiments that ivory or bone pegs driven into the shaft of a long bone brought about elongation of the bone. Two ivory pegs inserted into the left tibia of a dog increased the length of the bone 4 mm.

Aufrecht² observed that in a case of pseudarthrosis treated by transfixion with ivory pegs, that the surface of the pegs became rougher the longer they remained in the bone. Their surface was covered with giant cells. His investigations concerning the absorption of ivory in bone led him to the following conclusions :

- (1) Giant cells originate by confluence of cells as described by Ziegler.
- (2) Giant cells appear in places where an obstacle is found to the transformation of fibroblasts into connective tissue, or where in the cells themselves the capacity for the formation of connective tissue is reduced.
- (3) The giant cell can bring about resorption of bone, probably in so far as on its existence depends the accumulation of carbonic acid.

¹ Ueber Pseudarthrosen am Vorderarm mit Bemerkungen über das Schicksal implantirter Elfenbein und Knochenstifte. *Archiv für klinische Chirurgie.* Bd. 26, S. 985.

² Ueber Riesenzellen in Elfenbeinstiften, welche zur Heilung einer Pseudarthrose eingeklebt waren. *Centralblatt f. die Med. Wissenschaft,* 1877.

(4) The club-shaped closed ends of new bloodvessels can be easily mistaken for giant cells when the places of their connections with vessels are obscured by the tissues.

These experiments and observations prove that bone or ivory used in the direct fixation of a fracture can be safely left in the tissues with the expectation that the material will become encysted and remain harmless, and that in the course of time it will be removed by absorption. They also teach that these substances are more rapidly removed by absorption when inserted into the medullary cavity, or when placed around instead of into the bone. My own experience has satisfied me that bone is absorbed more readily and in a shorter time than ivory, and on this account I prefer it to the latter material in the direct treatment of fractures. I am convinced that a hollow cylinder of bone inserted into the medullary cavity of a bone is removed completely by absorption in a comparatively short time. The same fate awaits a thin ring of bone embracing and holding in mutual uninterrupted contact two or more fragments in the treatment of compound and ununited fractures by direct fixation.

RETENTION OF COMPOUND AND UNUNITED FRACTURES BY DIRECT FIXATION WITH BONE FERRULE.

The most efficient way to prevent lateral and longitudinal displacement in oblique fractures of the shaft of the long bones is to bring the fractured surfaces in accurate contact, and hold them in this position by an efficient absorbable circular support. The use of silver wire and other unabsorbable suture material for this purpose is objectionable, because the linear pressure caused by the support must affect in a detrimental manner the fragments, and the circular splint, even if it becomes encysted, remains as a foreign substance liable at any time to become a source of disturbance. Catgut and other absorbable ligatures are not sufficiently durable to hold the parts in contact for a sufficient length of time. It has occurred to me that such fractures could be retained almost to perfection after

reduction by engaging the ends of the fragments in a ferrule, or ring of bone or ivory. The rough, and often denticulated, fractured surfaces, held in contact by the circular splint, will bring about interlocking of the fragments, the best safeguard against undue shortening. If the fractured surfaces are smooth, and interlocking of the fragments cannot be thus secured, shortening and lateral displacement are effectually prevented by the ring, the broken ends grasped by the ring acting like two inclined planes gliding in opposite directions, which will permit sliding of one fragment over the other only till each fragment impinges firmly against the respective side of the ring, after which further over-riding is a mechanical impossibility. Angular deformity and rotation can be readily prevented by an appropriate external support. The application of such a ferrule requires less time, is attended by less disturbance of the soft parts, and is a much easier procedure than suturing of the bone.

The results which have attended this treatment in my hands so far have been exceedingly satisfactory, and have induced me to present them on this occasion with the hope of becoming the subject of a thorough discussion on the advisability and technique of direct fixation of compound and ununited fractures.

Preparation of Bone Ferrules.—The ferrules are made of different sizes from fresh bone obtained from the slaughter-house or butcher-shop. For the humerus and femur of the adult the femur of an ox should be selected; for children, the same bone of a smaller animal will answer the purpose. For the tibia the corresponding bone of the animal is chosen. With a sharp saw the shaft of the bone is cut transversely, the length of the sections corresponding with the desired width of the ferrule, which will vary from a quarter of an inch to an inch. With a round file the medullary canal is enlarged until the thickness of the bone does not exceed one-sixth of an inch; in some instances a much thinner ring will furnish the necessary lateral support. If the ferrule is longer than an inch it should be perforated at a number of points in order to furnish so many avenues through which the products of tissue proliferation and the new blood-vessels can reach the tissues outside of the ferrule, and *vice versa*,

and also with the intention of facilitating the absorption of bone after the fracture has become consolidated. Ferrules made of the tibia should retain the shape of the bone in order to adapt their lumen to the treatment of fractures of the tibia. Sterilization is effected by boiling for an hour or more, after which the rings are kept immersed in sublimate alcohol, 1:1000, ready for use.

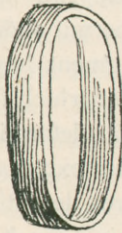

FIG. 17.—Circular bone ferrule for humerus or femur.

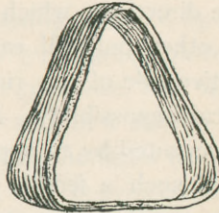


FIG. 18.—triangular bone ferrule made of ox tibia.

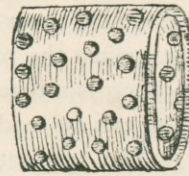


FIG. 19.—Wide perforated bone ferrule.

Future experience may show that partial decalcification of the bone ferrule is an advantage. Should further clinical experience show that the bone is not sufficiently absorbable, such ferrules could be made of chromicized catgut.

Application of Bone Ferrule.—In the treatment of compound fractures the observance of the strictest antiseptic precautions, and in the operative treatment of ununited fractures by this method, rigid aseptic measures must precede and accompany the direct treatment of the fracture. The seat of fracture must be exposed in such a way that both fragments are readily accessible. The ferrule must be large enough so that it can be slipped over the fragments without danger of breaking it. In the majority of cases the use of an anæsthetic is indispensable for the purpose of securing complete muscular relaxation and the necessary immobility of the limb not only until reduction is effected and the ferrule is in place, but until the whole dressing is applied and complete immobility at the seat of fracture has been assured. After the seat of fracture has been freely exposed, the most accessible fragment is isolated from the surrounding

tissues with as little disturbance of the periosteum as possible, when the ferrule is slipped over the fragment and is pushed away from the line of fracture far enough to clear the other fragment. After reduction has been accomplished, the second fragment is engaged in the ring, which is then pushed back sufficiently far to grasp both fragments securely.

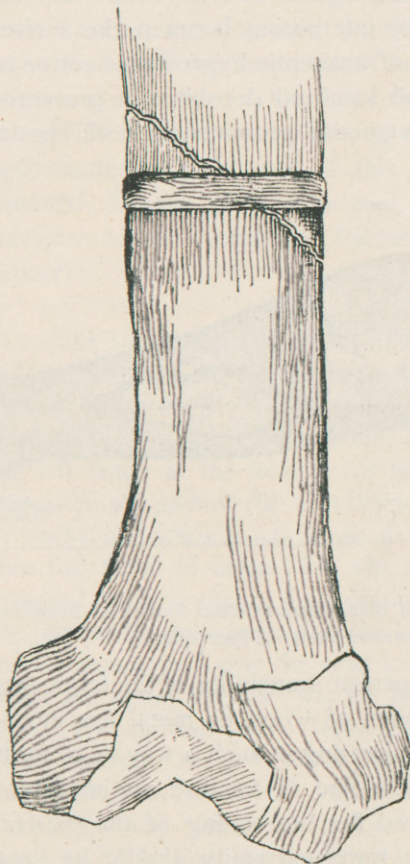


FIG. 20.—Oblique fracture of femur united by bone ferrule.

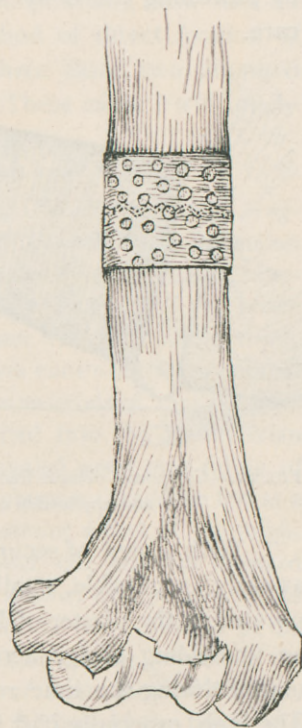


FIG 21.—Transverse fracture of humerus immobilized by a wide perforated bone ferrule.

A reliable assistant should hold the limb in proper position, as bending at the seat of fracture might break the ring. Hæmor-

rhage is to be carefully arrested, and if the wound is aseptic the different tissues are separately united by buried sutures. In case of infected fractures, and in fractures accompanied by troublesome oozing, free drainage must be established. Bending at the seat of fracture is prevented and absolute immobilization secured by a circular plaster-of-Paris splint, which can be fenestrated at a point opposite to the wound, if the wound has been drained. Harmful pressure is avoided by interposing between the surface of the limb and splint a layer of antiseptic hygroscopic cotton at least an inch in thickness, and localized decubitus is prevented by protecting all bony subcutaneous prominences with special care.

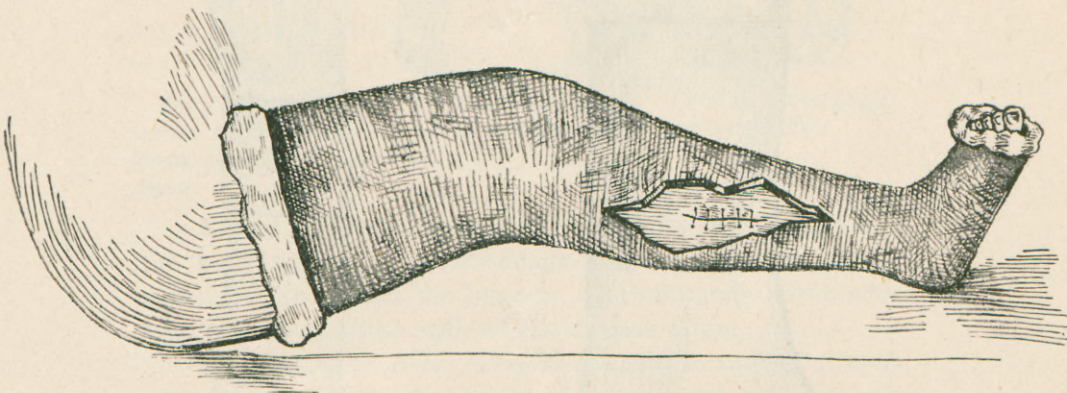


FIG. 22.—Compound oblique fracture of tibia treated by direct fixation of fragments and application of fenestrated plaster-of-Paris splint.

With a view of securing perfect immobility of the fragments as early as possible, small splints of wood or metal are incorporated in the plaster-of-Paris dressing in such a way as to form an unyielding bridge across the line of fracture, an important matter during the time required for the setting of the plaster. The limb, especially if it is the lower extremity, should be kept suspended in an elevated position for a number of days in order to prevent, as far as possible, the occurrence of œdema at and below the seat of fracture. If the wound has not been drained, and no indications for a change of dressing present themselves,

the first dressing should not be disturbed until union between the fragments is sufficiently firm to prevent displacement during the second dressing. In wounds that require drainage the dressing is changed after two to five days without interrupting the fixation splint. Should suppuration set in, the bone ferrule should not be removed until direct fixation has become unnecessary, when the sinus is enlarged, the ring cut on one side with bone forceps, and fractured on the opposite side by bending, when each half can be extracted separately. Loose fragments of bone are removed at the same time.

Clinical Experience.—During the short time I have had an opportunity to make use of this method of direct fixation of fractures, I have given it a trial in three cases, two ununited fractures and one compound fracture. These cases I will briefly report:

CASE I—*Ununited Fracture of Femur; Direct Fixation of Fragments; Union with Fragments in Good Position.*—A Bohemian laborer, thirty-seven years of age, in apparently good health, nineteen months ago attempted to mount a railroad engine, fell and broke the left femur at the junction of the lower with the middle third. Extension was applied the next day and was continued for a number of weeks, and when it was removed it was ascertained that the fracture had failed to unite. He was admitted into the Presbyterian Hospital April 7, 1893. Examination revealed great over-riding of the fragments; the upper end of the lower fragment could be felt as a marked prominence over the outer and posterior aspect of the thigh, while the upper fragment was on the inner side and was directed toward the popliteal space. Measurement showed nearly three inches of shortening. No provisional callus could be felt. Motion at the seat of fracture quite free. Patient was unable to walk without the aid of crutches. Operation in the clinic of Rush Medical College, April 13. The limb was constricted near the base of the thigh, and the seat of fracture exposed by a long incision through the intermuscular septum between the flexor and extensor muscles on the outer side of the thigh. A spur of new bone was found projecting at a right angle from the outer side of the upper fragment at a point corresponding with the upper end of the lower fragment. The apex of

this triangular mass of bone was connected with the lower fragment by a strong band of connective tissue. This prominence was removed with the chisel, and the lower fragment isolated from the surrounding mass of connective tissue. The fracture was originally a very oblique one, but the sharp point of each fragment had become rounded off and was covered by cicatricial tissue without a trace of callus formation. The isolation of the upper fragment proved a tedious and difficult part of the operation. No amount of extension succeeded in materially diminishing the over-riding. The fragments were vivified with a chisel in an oblique direction, but before the surfaces could be brought in contact each fragment was shortened in order to do away with the over-riding, and to enable me to resort to direct fixation with a bone ferrule. The first two rings were too small and were broken in the attempt to engage both fragments. The third ring was large enough, but was cracked on one side when by the weight of the limb a slight bend was produced at the seat of fracture. It retained its place and was strengthened by tying around it a very strong chromicized catgut ligature. The wound was united throughout by buried and superficial sutures, and the limb immobilized in a circular plaster-of-Paris splint. On the second day the temperature reached nearly 100° F., consequently the dressing was removed through a fenestrum cut in the splint, and one of the superficial sutures was removed. About an ounce of bloody serum escaped. At this point a slight suppuration followed, and the wound was drained down to the seat of fracture, and was washed out daily with peroxide of hydrogen and a weak solution of corrosive sublimate. The temperature soon fell to normal, and at the present time, five weeks after the operation, suppuration has nearly ceased, the entire wound has healed with the exception of a small fistulous tract which leads down to the bone ring. A very large callus has formed, fragments are in good position, and the shortening does not exceed two inches. The bone ring was removed in the manner described, as the union was firm enough to hold the fragments in place. The same plaster-of-Paris dressing will remain until consolidation is sufficiently firm to dispense with an external support. Owing to the existence of suppuration the bone ferrule had not undergone any appreciable changes.

CASE II—*Ununited Fracture of Humerus Resulting from Extensive Loss of Bone; Paralysis of Musculo-spiral Nerve; Direct Fixation of Fragments by Artificial Impaction and Bone Ferrule, Aided by Catgut Sutures; Secondary Nerve Suture.*—This patient was a

single lady, twenty-four years old, an American by birth, and school teacher by profession. Family history good and general health fair. Three years ago she suffered from an attack of acute suppurative osteomyelitis of the lower part of the left humerus. An abscess formed at the lower part and outer aspect of the arm, which was incised two weeks after the beginning of the first symptoms. She made a good recovery, and the abscess healed promptly with the exception of a fistulous opening which led down to the bone. At the

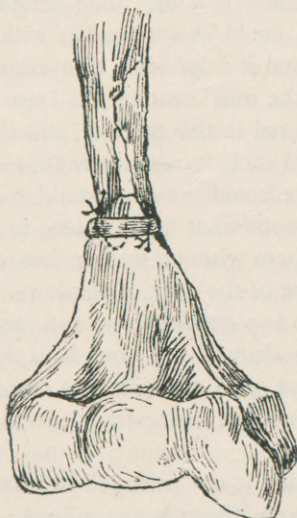


FIG. 23.—Ununited fracture of lower end of humerus treated by splitting upper fragment and impacting fragment corresponding with shaft of bone into the lower; immobilization by bone ferrule, two catgut sutures and plaster-of-Paris splint.

expiration of a year an operation was performed for this condition, and as it appears a resection of the entire diameter of the humerus to the extent of at least four inches was made. Since the operation the patient has been unable to extend the hand, showing that the musculo-spiral nerve was severed during the operation. The resection wound healed quickly, but there has been no attempt at union by bony callus. The patient was admitted into the Presbyterian Hospital April 1, 1893. The whole limb was atrophied. Arm very much shortened. Resected ends separated about three inches and connected by a band of cicatricial tissue. Paralysis of musculo-spiral

nerve complete. The proximal bulbous end of the nerve could be readily located in the scar, and was exceedingly painful on pressure. The operation was performed in the clinic of the Rush Medical College, April 6, 1893.

Esmarch's constriction of the limb. Line of incision through the old scar. Both ends of the musculo-spiral nerve were found and isolated. Both fragments conical. The scar tissue interposed between them was excised. The lower fragment very short; the base of the bone expanding into the condyles. The atrophy of this fragment was extreme; the bone could be cut readily with the knife. Upper fragment firmer. I found it impossible to overlap and unite by fixation the fragments in the usual manner, as I was satisfied that bony union could not be secured in this manner, and the shortening of the arm would have reached such an extent that even if bony consolidation could have been effected the arm would have been useless. I determined to pursue a somewhat novel course in securing apposition of extensive bone surfaces without further loss of bone. I made a perforation in the centre of the apex of the lower fragment, and split the upper fragment into two equal halves, and impacted the fragment corresponding with the shaft of the bone into the opening made in the lower fragment, and used the partially detached fragment as a bridge which overlapped the lower fragment to the extent of the impaction.

All the surfaces which it was intended to bring into contact were freely vivified, but no bone tissue was sacrificed. From the perforation in the lower fragment liquid fat escaped, which proved to what extent atrophy had advanced. Before the impaction was made a bone ferrule, with a number of perforations, was slipped over the upper fragment, and after impaction it was pushed downward far enough to grasp all of the three fragments. For the purpose of maintaining the impaction the upper and lower fragments were anchored to the bone ring by heavy chromicized catgut sutures. The nerve ends were resected and united by direct and paraneural sutures of catgut. The external incision had to be sutured transversely, owing to the increased shortening of the arm. No drainage. The arm and forearm were supported by a posterior angular felt splint, over which was applied a plaster-of-Paris dressing, which included also the shoulder.

The first dressing was not removed until the end of the third week, when the wound was found united throughout by primary intention. Later, a small fistulous opening formed in the centre of

the scar. At the end of seven weeks the bone ferrule was removed. It had become greatly diminished in size by absorption, which was especially well marked on the inner side of the ring. A large mass of callus was found firmly uniting the three fragments.

CASE III—*Compound Comminuted Fracture of Leg; Fixation of Tibia with Bone Ferrule; Fenestrated Plaster-of-Paris Splint; Suppuration; Efforts at Repair.*—Italian boy, twelve years of age, sustained a compound fracture of the left leg by falling from a gravel train. The bystanders asserted that a car wheel passed over the leg. The physician who was called to attend him applied a temporary dressing. He was admitted into St. Joseph's Hospital April 28, 1893, two days after the accident. A lacerated wound, three inches in length, was found over the inner and anterior aspect of the leg at the junction of the middle with the lower third. On the fibular side the skin was contused and detached from the tissues underneath over an area as large as the palm of the hand, with a torn wound in the centre. The tibia was comminuted; two large fragments completely detached were removed, as the wound was infected. Chloroform was administered, and the opening was enlarged and the wound thoroughly disinfected. The fragments overlapped each other, the upper being directed forward and the lower backward. The fibula was fractured a little higher up. On making extension the fracture could be reduced perfectly, but as soon as traction was suspended the displacement reappeared. Owing to the extent of the injury of the soft tissues, retention of the fracture by extension or external fixation was out of question, and I resorted to direct fixation. A bone ferrule with a $\frac{3}{4}$ -inch lumen and $\frac{5}{8}$ inch wide was slipped over the upper fragment, extension was made, complete reduction effected, when the bone ring was pushed downward sufficiently far to grasp both fragments firmly. It held the fragments in perfect apposition without extension. The wounds were packed with iodoform gauze, and after applying the external dressing the limb was immobilized in a fenestrated plaster-of-Paris splint which extended from the toes to the middle of the thigh. For about a week suppuration was quite profuse, and the temperature ranged from 99° to 103° F. During this time the wounds were irrigated twice a day with a saturated solution of acetate of aluminum, and hot compresses wrung out of the same solution were applied. The contused undermined skin sloughed, leaving a large granulating wound on the fibular side. At the end of the first week the temperature became normal and suppuration

diminished. During this time I could satisfy myself that the ring held the fragments in perfect apposition by direct inspection and touch through the wound. The fragments became covered with granulation, and at the end of four weeks union was sufficiently firm to warrant the removal of the ring. The same fixation splint was allowed to remain until the completion of the bony consolidation.

REMARKS.

In all of these cases the bone ferrule served an admirable purpose in maintaining complete retention of the fracture during the time required in the formation of a union sufficiently firm to render direct fixation superfluous. In the two cases in which suppuration set in soon after the treatment was initiated, the bone ferrule did not undergo any appreciable changes, while in Case 2, in which suppuration did not occur until the end of four weeks, and then only over a small space in the centre of the thin scar, a considerable portion of the ring had disappeared by absorption, and I have no doubt if it had been allowed to remain it would have been disposed of in this way. The most important requirement in carrying out this treatment successfully is to assist direct fixation in securing retention of the fracture by an immovable external circular splint of plaster-of-Paris, which should immobilize the limb uninterruptedly from the time the bone ferrule is applied until the process of repair is completed. Access to the seat of fracture should be secured through a fenestrum. It is better to use the ring a little too large than too small, as in the former case loose spaces can be packed with chips of decalcified bone, while in the latter there is great danger of breaking the ring during the application of the plaster-of-Paris splint.

EXPERIMENTAL INVESTIGATIONS.

Before the bone ferrule was used in the direct fixation of the fractures in the cases reported in this paper, I tested the feasibility, safety and utility of this treatment on the lower animals. Two dogs were selected for this purpose. The first experiment was made on a large black dog. The

right leg was shaved and disinfected. An incision was made down upon the femur at its middle through the intermuscular septum on the outer side of the bone. The bone was divided transversely with a chisel. A round bone ferrule about three-fourths of an inch wide and with a lumen a little larger than the shaft of the bone was applied in such a manner that it grasped both fragments equally. The wound was closed throughout by buried and superficial sutures, and sealed with an iodoform collodion dressing. The entire limb was encased in a plaster-of-Paris splint. Wire gauze was applied over the splint. The animal did not seem to suffer much from the injury; commenced to eat and walk the second day after the operation. In three weeks the splint was so much injured by the animal that it was removed. Wound healed throughout. Limb in good position, very little if any mobility at the seat of fracture. The place of fracture could be felt as a firm spindle-shaped swelling. The dog commenced to use the leg, and about a week later it would have been difficult to tell from his walking and running that the thigh had been fractured. As nothing has been seen or heard of the bone ring so far, it is safe to assume that it has become absorbed.

The second experiment was made on a much smaller dog. Through the same incision the radius and ulna were divided obliquely with a chisel, the fracture of the radius being near the elbow joint, that of the ulna about an inch lower down. The fracture of the ulna was treated by direct fixation in the same manner as in the preceding experiment, only that the ring was much narrower. The limb was immobilized in the same manner. At the end of a week it was ascertained that the wound was suppurating, and the sutures were removed. Two weeks later the splint was removed. Some motion at the seat of fracture. An abundant provisional callus rendered the further use of a splint unnecessary. During the fourth week the dog ran away, and has not been heard from since. I have no doubt that both fractures united in a satisfactory manner, but the bone ring will be eliminated sooner or later.

CONCLUSIONS.

I trust I have said enough on the importance of direct fixation in the treatment of compound and ununited fractures to induce others to give the new treatment which I have outlined a trial. Finally, I beg leave to submit for your further consideration and discussion the following conclusions :

1. Direct fixation of the fragments is indicated in all compound fractures in which perfect retention cannot be secured by simpler measures, and in the treatment of ununited fractures requiring operative interference.

2. This method is also justifiable in the treatment of certain forms of subcutaneous fractures, in which reduction and retention cannot be accomplished without it.

3. Free exposure of the fragments in compound fractures secures the most favorable condition for thorough disinfection.

4. Perfect reduction and direct fixation of the fragments are the most reliable prophylactic measures against delayed non-union and deformity.

5. A compound fracture should be regarded in the same light as an injury of the soft tissues, and should be treated upon the same principles, viz., accurate coaptation of the different anatomical structures, and perfect retention by direct means of fixation, aided by an efficient external support.

6. Bone suture, metallic, bone and ivory nails do not furnish the necessary degree of support and immobilization in the direct treatment of fractures characterized by a strong tendency to displacement.

7. The solid intra-osseous splint of ivory or bone as advised by Heine, Langenbeck and Bircher is objectionable, because it interferes with the ideal production of the intermediate callus and its spontaneous removal, is beyond the absorptive capacity of the tissues.

8. The hollow, perforated ivory or bone cylinder, devised by the author, answers the same mechanical purpose without the objections which have been charged against the solid cylinder.

9. The safest and most efficient means of direct fixation of

oblique fractures is by a bone ferrule, which must be applied in such a manner that it surrounds both fragments.

10. Such a circular absorbable direct splint prevents to perfection lateral and longitudinal displacement.

11. Rotation of the limb below and angularity at the seat of fracture must be prevented by a carefully applied circular plaster-of-Paris splint.

12. For fractures not requiring drainage the entire wound should be closed by buried and superficial sutures, as the bone ferrule is removed by absorption.

13. In suppurating wounds the bone ferrule should not be removed until direct fixation has become superfluous by the formation of a sufficiently firm union between the fragments.

14. The external splint should be applied in such a manner that it does not require a change throughout the entire treatment, permitting at the same time access to the wound, should this become necessary.

15. Direct fixation of a fracture combined with perfect immobilization brings the different anatomical structures of the broken bone permanently into their former normal relations, preparing the way for the early initiation and speedy consummation of an ideal process of repair and the realization of a perfect functional result.

16. Should future experience demonstrate that bone is not sufficiently absorbable, the same kind of ferrules can be made of partially decalcified bone or chromicized catgut.

