

Roe (J.O.)

STRICTURE OF THE ŒSOPHAGUS
FROM INTERSTITIAL THICKENING
OF ITS WALLS


A FIBROID HYPERTROPHY

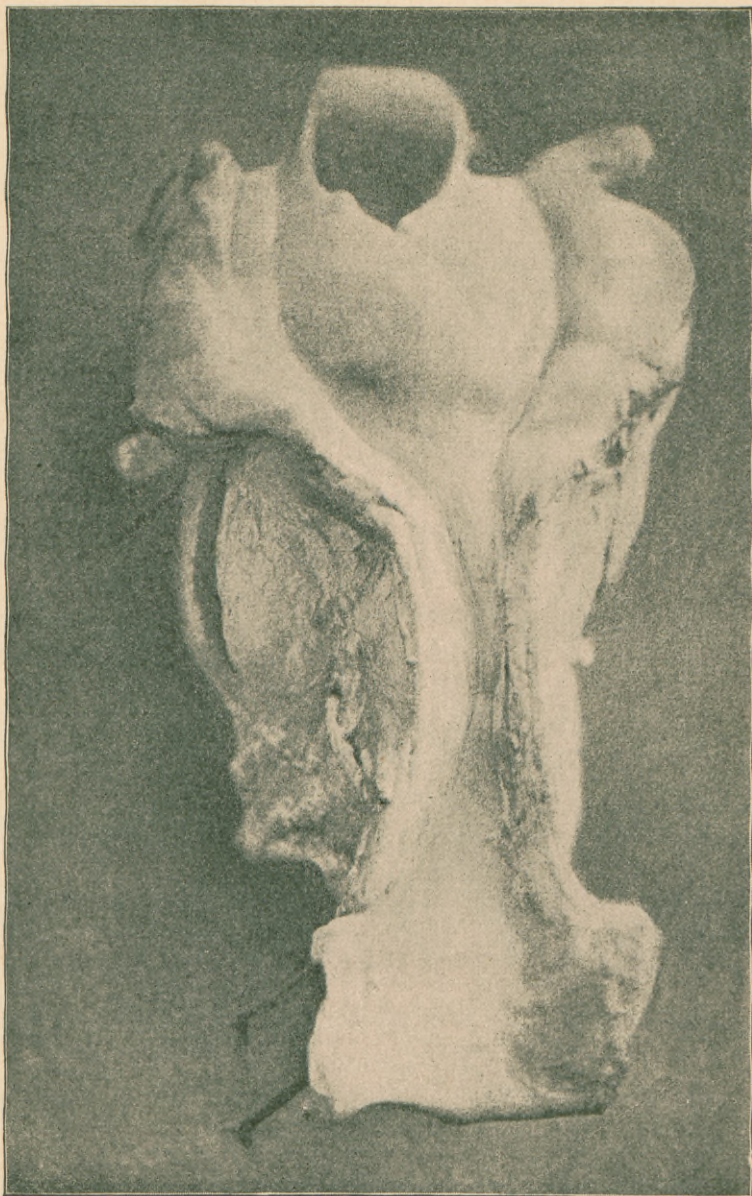
BY
JOHN O. ROE, M.D.
ROCHESTER, N. Y.

REPRINTED FROM
THE NEW YORK MEDICAL JOURNAL
OF MARCH 14, 1891



NEW YORK
D. APPLETON AND COMPANY
1891





This illustration is from a photograph taken directly from the specimen.

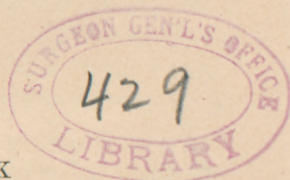STRICTURE OF THE ŒSOPHAGUS
FROM INTERSTITIAL THICKENING
OF ITS WALLS

A FIBROID HYPERTROPHY

BY
JOHN O. ROE, M. D.
ROCHESTER, N. Y.

REPRINTED FROM
THE NEW YORK MEDICAL JOURNAL
OF MARCH 14, 1891

NEW YORK
D. APPLETON AND COMPANY
1891



COPYRIGHT, 1891.
By D. APPLETON AND COMPANY.

STRICTURE OF THE ŒSOPHAGUS
FROM INTERSTITIAL THICKENING OF ITS WALLS;

*A FIBROID HYPERTROPHY.**

By JOHN O. ROE, M.D.

ROCHESTER, N. Y.

AMONG the numerous pathological causes that produce contraction or stricture of the œsophagus, interstitial thickening of its walls is of the rarest occurrence.

So rare is it, that by many observers its occurrence is doubted. Fibrous growths have been found in the walls of the œsophagus like those that are found in the uterus or other parts of the body; but I have been unable to find reported a case of interstitial thickening of the walls of the œsophagus where the diagnosis was confirmed by a thorough microscopic examination. Cases are reported where the constrictions of the œsophagus were believed to be due to connective-tissue thickening, but the absence of a microscopic examination renders these observations valueless. The following case, which is in every respect a typical one, can not, therefore, fail to be of special interest. ■

Mrs. M. A., fifty-eight years of age, was referred to me April 14, 1887, on account of a great difficulty in deglutition from

* Read before the American Laryngological Association at its twelfth annual congress.

which she had suffered for three months. During the first week in January she began to have much difficulty in swallowing. This difficulty increased slowly until, by the last week in March, it had become impossible for her to swallow any substance whatever. She was at first unable to swallow liquid and solid substances, but moistened semisolid substances she could swallow quite readily. She began about this time to have considerable pain in the back and sides of her neck, and the cervical lymphatics became enlarged and painful. She also expectorated a considerable amount of muco purulent material.

In the early part of March she was treated by a physician for this obstruction to deglutition with gum-elastic bougies. There was some improvement in swallowing directly after the use of the bougies, but the obstruction soon became as great as before, which necessitated daily dilatation of the œsophagus in order that she might take sufficient nutriment to sustain her. In a short time dilatation of the œsophagus was discontinued, and she was sustained by rectal alimentation. Shortly after this she passed into the hands of another physician, the one who referred her to me.

On examining her throat, there was nothing abnormal to be seen about the pharynx, but in the larynx there was a chronic laryngitis, rigidity of the arytænoïd articulations, and almost complete immovability of the vocal bands, which were separated about three millimetres from each other, and afforded sufficient breathing space only when she remained perfectly quiet. The slightest exertion would cause great dyspnœa. On attempting to swallow, substances would drop into her larynx and cause more or less strangling. This was due to the rigidity of the larynx and its inability to close during deglutition.

On examining the œsophagus, the largest instrument I was able to pass was a flexible, conical-shaped bougie, No. 13, American scale. With a small olive-pointed, demi-bulbous bougie I determined that the contraction was cylindrical in shape and projected equally on all sides. It began about two inches below the entrance of the œsophagus and extended for a distance of about two inches, being narrowest in the middle portion.

Dilatation gave some slight improvement in deglutition, but not sufficient to enable her to take enough nutriment to sustain her. She had at this time become so weak that she was unable to walk alone. The nutritive enemata were no longer sufficient to sustain her, as they had ceased to be retained. In order, therefore, to administer sufficient sustenance, a small gum-elastic catheter was introduced twice daily, and about a quart of beef tea, eggs, and cream mixed together were injected into the stomach. Oil inunctions were also employed. Notwithstanding this, her debility increased, and on May 1st she died. Her death was evidently due to asthenia.

On post-mortem examination, there was found the condition of rigidity of the aryænaoid articulations already described, and a general thickening of the tissues throughout the larynx. There was, however, no swelling of the aryænaoids indicative of tubercle.

On examination of the œsophagus, the constrictions of the tube, both in extent and location, were found as already described. The opening through the stricture was sufficient only to permit the passage of an ordinary small-sized lead-pencil by using a little force. The circumference of the outer walls of the œsophagus was also found much smaller at this point than at any other portion of the tube, showing that the stricture was not confined to the contraction of the interior of the tube, although the outer contour of the tube was not contracted to the same relative extent as that of the interior of the tube.

On opening the œsophagus by making a longitudinal section through its posterior wall, it was found to be very greatly thickened in the region of the stricture. At the most contracted portion the wall of the œsophagus was from five to six millimetres in diameter, being three times its normal thickness, and gradually becoming thinner toward either end of the stricture. (*Vide* illustration.) On making a section of this tissue, it was so firm to the cut of the knife that I was led to think that it was a scirrhus formation; but, on microscopic examination of this tissue, it was found that the muscular fibrillæ had become degenerated and replaced by a connective-tissue formation.

It was therefore a pseudo-hypertrophy of the muscular wall, or a real hypertrophy of the connective tissue. This tissue formation, however, had been thrown out far in excess of the amount of the muscular tissue that it had replaced.

There was, in addition to this disease of the œsophagus, a moderate enlargement of the thyreoid gland, the left lobe being larger than the right, and involving the recurrent laryngeal nerve on that side, but not pressing upon the œsophagus. Microscopic examination of the gland tissue showed the enlargement to be a chronic interstitial thickening of the connective tissue similar to the condition found in the œsophagus.

In an extended search through medical literature I have been unable to find any case of stricture of the œsophagus reported in which a thorough examination revealed a condition exactly like this one just reported. The nearest approach to it is the report of those cases of stricture of the œsophagus caused by hyperplasia of the muscular wall. Two of those cases are reported by Poncet,* and one by Ruppert.† The two cases of Poncet occurred in men fifty-nine and fifty-five years old, respectively. Neither was alcoholic or syphilitic, and to no assignable cause could the stricture be attributed. The first patient had, however, suffered an attack of acute articular rheumatism seven months before the commencement of the difficulty in deglutition.

In both cases gastrotomy was performed. The second patient died eight days after the operation, while the first lived four months and died of suppurative parotiditis.

In the first case the post-mortem examination showed the canal of the œsophagus, just above the cardia, to be almost completely obliterated, only admitting a very

* Sur les rétrécissements de l'œsophage par hyperplasie musculaire. *Bull. méd.*, Paris, 1888, ii, 451.

† Hypertrophy of Muscular Coat, the Result of Chronic Catarrh of the Mucous Membrane. *Gaz. Lek.*, Warszawa, 1884, 2 S., iv, 315.

fine probe ; but there was no lesion of the mucous membrane.

The muscular layers appeared to the unassisted eye very much thickened. The constricted portion, examined microscopically, showed some muscular fibers, irregular and quite generally parallel to the direction of the canal, and spreading out into the surrounding connective tissue. At certain points the muscular cells were disposed in small, circular fasciculi, and assumed a very yellow tint.

The peri-oesophageal tissue was found normal. In the second case a post-mortem examination revealed, a short distance above the cardia, a constriction, forming a ring through which could be admitted an ordinary pen-holder. This ring, which was situated under the mucous membrane, appeared red, hard, and fibrous. On making a section, the strictured portion presented a dense surface, homogeneous and similar to that of the preceding case. The microscopic examination of this case was, unhappily, very imperfect. It showed only the absence of all epithelial lesions, and that the nature of the tissue, where the cuts were made, was largely connective tissue.

The case reported by Ruppert was that of a valet who was admitted to the Hospital of the Infant Jesus, Warsaw, Poland, October 24, 1883. In May, 1883, the patient began to have difficulty in swallowing, which had been preceded a short time before by vomiting blood. This greatly increased, although at times he could swallow much more readily than at other times, owing, it was believed, to an exacerbation of a catarrhal inflammation of the mucous membrane of the oesophagus. For six years before the appearance of this trouble he had been addicted to the excessive use of alcohol, which was, without doubt, the exciting cause of this catarrhal inflammation. After admission to the hospital, dilatation of the stricture was undertaken and continued with some improvement in swallowing, but the obstruction finally increased to such an extent that he

gradually failed and died from inanition on November 27th of the same year.

The œsophagus presented a fusiform dilatation which began two centimetres below the tracheal bifurcation, and ended two centimetres above the cardia with a considerable stricture. The longitude of the dilatation was seven centimetres, and the longitude of the stricture two centimetres. The lumen of the œsophagus in the constricted portion was between two and three centimetres in diameter. The thickness of the walls in the dilated portion was two millimetres, and, in the constricted, seven millimetres. The constricted portion of the œsophagus, when cut, appeared as a thick, compact, unpliant tissue, which had the distinct appearance of being chiefly hyperplasia of the muscular strata. On microscopic examination, the epithelium was absent, and only here and there remnants of the mucous membrane were found in the form of fibrous tissue, with abundant infiltrations of small cells. The submucous membrane appears as a compact connective tissue, which is hyperplastic, abundantly vascular, and has many elastic fibers. There was marked hyperplasia of the muscular coat, especially the muscularis externa, and equally in the circular as well as in the longitudinal fibers. The examination proved the existence of ulceration in the mucous membrane of the œsophagus in the constricted as well as in the dilated portion, and an almost complete destruction of the mucous membrane, while a very considerable hyperplasia of the muscular strata and of the submucous tissue could readily be detected.

Ruppert, however, does not state whether the hypertrophy is that of the muscular fibers, that is, a real hypertrophy, or hypertrophy of the connective tissue, that is, a pseudo-hypertrophy, as in the case that I have reported.

Albers * refers, in his work, to cases of this form of contraction of the œsophagus which were observed by Rokitan-sky and Baillie, where the hypertrophied valves of the

* *Atlas der pathologischen Anatomie*, Bd. ii, S. 236.

œsophagus formed a ring which constricted the lumen at its lower part. Zenker and von Ziemssen,* however, believe, from the superficial description of the cases, that they were only undiagnosed carcinoma with hyperplasia of the muscular tissue.

The question of ætiology in these cases is an interesting one. It is difficult to believe that muscular hyperplasia, or a thickening of the connective tissue, is a spontaneous formation; but in these cases, in which we have no history of an irritation, we have no indication as to the exact cause of the formation.

In the case of the man addicted to the use of alcohol, whose case is reported by Ruppert, we have a direct relation of cause and effect between the catarrhal inflammation of the mucous membrane of the œsophagus and the muscular hyperplasia.

The cause of the stricture in the case which I have reported is obscure. This connective-tissue formation is the result, in every instance, of a chronic inflammatory process, and it is analogous to the same formation that takes place in the lung tissue in fibrous phthisis. In this case the chronic inflammatory trouble which caused the difficulty is inexplicable. There was no history of any chronic œsophageal trouble previous to the time when this difficulty in deglutition commenced. There was no ulceration of the interior of the œsophagus at this point, and there was no evidence of chronic inflammation in any other portion of the œsophagus. There was no cicatricial tissue in the stricture, and the mucous membrane was entirely intact. The contraction, therefore, could not have been the result of the action of corrosive substances, and there is no evidence that a foreign body lodged there, causing chronic œsophagitis.

* *Handbuch der speciellen Pathologie u. Therapie*, Bd. viii, S. 32.

It was not a simple stenosis of the gullet, for in that case there would have been no morbid changes in any of its component tissue; and a simple stenosis of the gullet is usually a congenital abnormality. There is a possibility, however, that this stricture might have originated from a congenital narrowing of the tube, and the chronic inflammation might have resulted from the continued irritation of the substances forced through it.



REASONS WHY

Physicians Should Subscribe

FOR

The New York Medical Journal,

EDITED BY FRANK P. FOSTER, M. D.,¹

Published by D. APPLETON & CO., 1, 3, & 5 Bond St.

1. **BECAUSE** : It is the *LEADING JOURNAL* of America, and contains more reading-matter than any other journal of its class.
2. **BECAUSE** : It is the exponent of the most advanced scientific medical thought.
3. **BECAUSE** : Its contributors are among the most learned medical men of this country.
4. **BECAUSE** : Its "Original Articles" are the results of scientific observation and research, and are of infinite practical value to the general practitioner.
5. **BECAUSE** : The "Reports on the Progress of Medicine," which are published from time to time, contain the most recent discoveries in the various departments of medicine, and are written by practitioners especially qualified for the purpose.
6. **BECAUSE** : The column devoted in each number to "Therapeutical Notes" contains a *résumé* of the practical application of the most recent therapeutic novelties.
7. **BECAUSE** : The Society Proceedings, of which each number contains one or more, are reports of the practical experience of prominent physicians who thus give to the profession the results of certain modes of treatment in given cases.
8. **BECAUSE** : The Editorial Columns are controlled only by the desire to promote the welfare, honor, and advancement of the science of medicine, as viewed from a standpoint looking to the best interests of the profession.
9. **BECAUSE** : Nothing is admitted to its columns that has not some bearing on medicine, or is not possessed of some practical value.
10. **BECAUSE** : It is published solely in the interests of medicine, and for the upholding of the elevated position occupied by the profession of America.

Subscription Price, \$5.00 per Annum. Volumes begin in January and July.

