

Dup.

ROE, (J. O.)

Dup.
I. H.

The Correction of Nasal Deformities by Subcutaneous Operations.

OR

✓

BY

JOHN O. ROE, M. D.

ROCHESTER, N. Y.

17741

LIBRARY
SURGEON GENERAL'S OFFICE
JUN 7 1905
763

REPRINTED FROM
THE AMERICAN MEDICAL QUARTERLY,
JUNE, 1899.

THE
LIBRARY OF THE
MUSEUM OF COMPARATIVE ZOOLOGY
AND ANATOMY
HARVARD UNIVERSITY
CAMBRIDGE, MASS.

The Correction of Nasal Deformities by Subcutaneous Operations

BY

JOHN O. ROE, M. D.

ROCHESTER, N. Y.

EX-PRESIDENT OF THE MEDICAL SOCIETY OF THE STATE OF NEW YORK; EX-PRESIDENT OF THE AMERICAN LARYNGOLOGICAL ASSOCIATION; CORRESPONDING MEMBER OF THE SOCIÉTÉ FRANÇAISE D'OTOLOGIE, DE LARYNGOLOGIE ET DE RHINOLOGIE; MEMBER OF THE BRITISH MEDICAL ASSOCIATION; OF THE AMERICAN MEDICAL ASSOCIATION; OF THE AMERICAN CLIMATOLOGICAL ASSOCIATION; OF THE AMERICAN LARYNGOLOGICAL, RHINOLOGICAL AND OTOLOGICAL SOCIETY; OF THE NEW YORK ACADEMY OF MEDICINE; OF THE CENTRAL NEW YORK MEDICAL ASSOCIATION; OF THE MONROE COUNTY MEDICAL SOCIETY, ETC.; LARYNGOLOGIST TO THE ROCHESTER CITY HOSPITAL. *f*

Mrs Luches brother rec

Yard!
LIBRARY
SURGEON GENERAL'S OFFICE

JUN-7--1905

REPRINTED FROM

THE AMERICAN MEDICAL QUARTERLY,

JUNE, 1899.

7631

THE CORRECTION OF NASAL DEFORMITIES BY SUBCUTANEOUS OPERATIONS.¹

BY JOHN O. ROE, M. D.,
ROCHESTER, N. Y.

THE method of performing operations subcutaneously is by no means new, for it is a century since Delacroix and Anel demonstrated the advantages of evacuating cavities containing pus and blood by this method; and since Abernethy adopted the plan of opening abscesses and diseased joints by valvular incisions so as to exclude the air. The practical advantages of this method were more fully demonstrated in 1816, by Delpech, who performed the operation of tenotomy in a subcutaneous manner, in order to avoid the subsequent inflammation which attended the operation when performed by the old method of exposing the tendon before it is divided.

The object of performing operations subcutaneously, at that time, was chiefly for the purpose of excluding the air, for it was even then observed that when air is excluded from a wound no inflammation follows. But, with the recent adoption of antiseptic methods, it may be said that the only advantage which now remains, of performing operations subcutaneously, is the avoidance of wounding the skin on any of the exposed portions of the body. As

¹A portion of this paper was read before the Sixty-fifth Annual Meeting of the British Medical Association.

the nose is the most prominent feature of the face, the facial expression depends to a great extent upon its appearance, and as deformities of the nose are especially unsightly, it is not only important that they should be corrected, but that the operation should be performed in a manner that will leave as few traces as possible of the previous disfigurement.

Previous to the time that the writer demonstrated the methods by which nasal deformities could be corrected by subcutaneous operations, all attempts that had been made to correct such deformities, so far as he is aware, involved the laying open of the skin in order to reach the deformed part and usually resulted in exchanging a deformity for an unsightly blemish. The unsightly scars left behind, therefore, had the effect of discouraging such operations, and, unless the deformity was excessively hideous, the person generally preferred to bear the ill he then had rather than fly to others he knew not of.

The importance of correcting nasal deformities, as well as other deformities of an unsightly nature, is evident from the conscious effect of such deformities in influencing the habits and thoughts of the person. On account of this distinguishing mark many are deterred from participating in the enjoyments of social life by the consciousness of the disadvantages under which they are continually laboring. So universally recognized are the disadvantages of a deformed and unsightly nose, that, even in ancient times, much attention was given to the shape and appearance of this important feature. It is said that among the ancient Persians no man who had a crooked or deformed nose was allowed to sit upon the throne; and children of royal blood were accustomed to have their noses moulded into perfect shape by the eunuchs who had charge of the royal offspring.

CLASSIFICATION.

Nasal deformities are usually divided into two main classes: (1), Idiopathic or congenital, and (2), traumatic

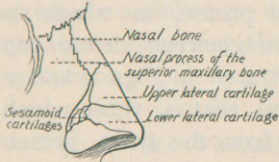


Fig. 1.



Fig. 2.

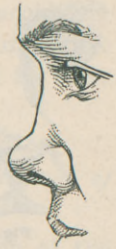

Fig. 3.

or acquired. Congenital deformities are frequently regarded as mere accentuations of certain racial types, but, as no special deformity is characteristic of any particular race, no class of deformities can be said to be governed merely by racial influences. Traumatic or acquired deformities sus-



Fig. 4.



Fig. 5.

tain but little or no relation to the natural conformation of the nose, so they may assume any form in which accident or disease happens to leave them.



Fig. 6.

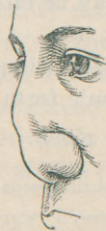

Fig. 7.

But, from a surgical point of view, nasal deformities may more properly be divided into (1), the deformities which affect the bony portion of the nose, and (2), the deformities which affect the cartilaginous portion.

This division can be clearly understood by

reference to Fig. 1, which illustrates the anatomical conformation of the different parts of the nose. *Deformities of the bony portion* may be sub-divided into



Fig. 8.

(a), vertical, that is, those which distort the dorsal profile, in which the dorsal line is too convex, or too concave, as illustrated in Figs. 2 and 3; and (b), lateral, that is, those which, when viewed from the front, present unusual deviation from the normal contour, whereby the bony portion may be either spatulated, Fig. 4, or deflected, Fig. 5.

Deformities of the cartilaginous portion may be confined to the tip of the nose, to the shield cartilages, or wings of the nose. They may therefore be sub-divided into (a), those which affect the tip of the nose, whether excessive Fig. 6, or defective, Fig. 7, in the amount of tissue, or distorted from its normal direction, Fig. 8; and (b), those which affect the wings of the nose, which may be either collapsed, Fig. 9, or abnormally expanded, Fig. 10.

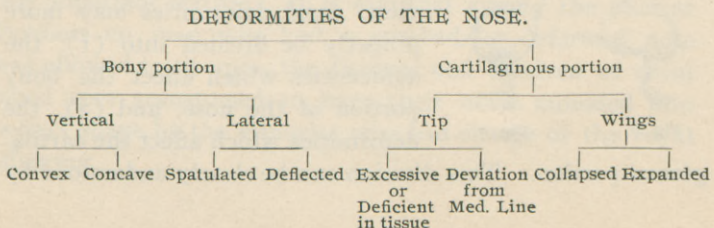


Fig. 9.



Fig. 10.

For convenient reference, this classification can be more clearly shown in the following diagrammatic form:



This classification applies to ordinary nasal deformities only and does not include those extraordinary deformities which result from extensive destruction of the hard or soft parts by syphilis, lupus, or other diseases, or by accidents, in which metallic or other artificial supports or plastic operations involving the integument are required for their correction.

ETIOLOGY.

(1). *Convex Vertical Deformity of the Bony Portion of the Nose.*

This deformity consists of an undue projection of the anterior process of the nasal bones giving to the nose an angular appearance and is sometimes termed, according to its different modifications of the nose, angular deformity of the nose, *nez en bec de corbin*, *rabe Nase*, *nez a promontaire*, *nez a chanfrein*. This deformity frequently causes the patient much annoyance not only on account of its unsightly appearance but also on account of the sensitiveness of the nose itself. In consequence of this sensitive condition the nose is easily and frequently irritated by contact with different objects, such as towels, handkerchiefs, etc. This sensitive condition is usually produced by one nasal bone overriding the other, the former presenting a sharp edge and in some cases nearly penetrating the skin.

This deformity may be congenital, or it may be caused by a fracture of the nasal bones, the fragments being thrown forward and allowed to remain in that position; or it may be produced by any injury to the nasal bones exciting a periostitis and causing an excessive amount of ossific deposit at this point.

(2). *Concave Vertical Deformity of the Bony Portion of the Nose.*

This deformity, sometimes termed saddle-back nose, con-

sists in a lowering or flattening of the bridge of the nose, and may be either idiopathic or traumatic. The idiopathic variety may be due to lack of development of this portion of the nose, associated with a general lack of systemic development, or, it may be the result of local organic conditions. During the development of the face, the central portion, comprising the nose, the ethmoid and sphenoid bones and parts adjacent, is not only late in developing, but is also the last portion of the face to undergo ossification. At birth the nose, at its base and central portion, is flat and nearly level with the face, but later this depressed line is replaced by a more prominent one as the nose becomes developed. From this it will readily be seen that anything, which interferes with the proper development of these parts, so as to cause them to remain in their infantile condition, while the end of the nose undergoes due development, will give the nose an unsightly shape, on account of the relative depression of the central portion.

The development of this portion of the nose may also be interfered with by local organic conditions. The most important of these is nasal obstruction. This may operate to produce imperfect development (1), by disturbance of the circulation in the part, caused by intranasal pressure resulting from hypertrophy of the tissues; (2), by the suction-force produced in the interior of the nasal chamber during each act of respiration and deglutition. This suction-force, exerted on the inner side of the yielding nasal tissues, tends to draw them inward, and to prevent their normal expansion and development. In some cases the concave vertical deformity may exist in appearance, but not in reality, for the reason that an abnormal development of the end of the nose might make a normal dorsum appear to be depressed and undeveloped.

Of the traumatic causes, those injuries to the bridge of

the nose which are sufficient to cause fracture and dislocation of the nasal bones are the most frequent. These injuries are the result of falls, or blows, or fistic encounters, and the injury may vary from a simple dislocation, to a compound comminuted fracture, with extensive laceration of the parts and complete destruction of the bony framework resulting in complete flattening of this portion of the nose. Very often this depressed condition of the nose is the result of fractures and dislocations, that have not been properly treated, or it may be associated with depression of the cartilaginous part, the result of abscesses of the septum, or specific disease, causing destruction or dropping inward of the nasal bones.

(3). *Spatulated Deformity of the Bony Portion of the Nose.*

This deformity may consist in a spatulated condition, *i. e.*, a flattening of the dorsum and bulging outward of the nasal bones, or in a deflection of this portion of the nose to one or the other side. The spatulated deformity of the nasal bones consists in an undue bulging outward, and is usually associated with the concave vertical deformity already described. This bulging of the bones may be unilateral or bilateral, and gives to the dorsum a flattened appearance. When of idiopathic origin, it generally results from the same conditions of intranasal pressure, that give rise to the concave vertical deformity, causing the bones to bulge outward. This effect in many cases I have observed to result from, or to be associated with, an excessive hypertrophy of the middle turbinated bone. When of traumatic origin, it ordinarily results from blows on the nose, which, when coming from directly in front, may result in an outward dislocation of both of the nasal bones. Injuries to one nasal bone may cause an exostosis on that side alone, in which case the deformity will be unilateral.

(4). *Deflection of the Bony Portion of the Nose.*

Deflections of the bony portion of the nose may be due to an unequal growth of the two sides of the nose, or to injuries causing dislocations of the nasal bones, which, at the time of the injury, were not properly reduced. In the case of injuries, the distortion may result from a fracture, or inward dislocation and consequent depression of the nasal bone on one side, alone, or there also may be an outward discoloration and corresponding bulging of the bone on the opposite side of the nose, giving it the appearance of what is termed by blacksmiths an offset.

(5). *Excessive Development of the Tip of the Nose.*

The abnormal enlargement of the tip or anterior portion of the end of the nose may be due to an excessive development of the tissues of this region, consisting of a redundant amount of cartilaginous tissue, or to an excessive amount of fatty tissue, or to both combined. This enlarged condition of the end of the nose is what is commonly known by the term "*snub*" or "*pug nose*," and is frequently associated with the concave vertical deformity of the bony portion.

In some cases, excessive development of the end of the nose may be confined to the upper portion of the tip, not broadening the end of the nose but giving it an upward tilt, so that the dorsal line describes a curve. This form of nose is termed by the French "*le nez retroussé*," and is sometimes termed the "*Celestial nose*," which gently curves upward from the root to the tip. This condition may be purely idiopathic, a family peculiarity, but is more often associated with defective development of the bridge of the nose and the result of the same local causes—namely, obstructions of the nasal passage and intranasal

pressure. This condition, too, causes a chronic engorgement of the end of the nose by interfering with the return circulation and also by the sympathetic irritation reflected from the interior of the nose, which, by lessening the inhibitory resistance of the peripheral vessels, accounts for the fact of its being accentuated in "alcoholics."

For these reasons, chronic engorgement and undue redness of the end of the nose is almost invariably indicative of chronic irritation in the interior of the nose, and the influence of these chronic conditions, in affecting the growth and development of the parts, as already pointed out, emphasizes the importance of giving attention to the condition of the nasal passages in children.

(6). *Defective Development of the End of the Nose.*

When the tissue of the lower portion of the nose is deficient in amount, we have a corresponding flattening of the end, termed "*nez camus*," "*floche nose*," and "*frog nose*." In extreme cases the end of the nose is completely flattened upon the face.

Flattening of the end of the nose may be due either to lack of development of the cartilaginous portion of the septum and the columnar cartilage, or to destruction of this portion by diseased conditions. It may also result from deflection or wrinkling of the triangular cartilage, which may have been congenital, but is generally the result of injuries. In many cases which have come under my notice, the flattening of the end of the nose resulted from abscesses of the anterior portion of the nasal septum. In one case, the flattening of the end of the nose resulted from an injury inflicted upon the nose by the obstetric forceps at birth.

Destruction of the upper shield cartilages, located in the dorsum of the nose, and which fill the gap between the

lower shield cartilages and the nasal bones, sometimes takes place, giving to this portion of the nose an indented appearance as if the nose had been struck with a small round body, a poker for instance, as shown in Fig. 11.

The destruction of these cartilages is usually caused by abscesses of the septum (Fig. 12), following the hematomata so often resulting from external injuries, and frequently due to failure to recognize the abscess, before the destruction of these tissues has taken place. In other cases, these cartilages may become dislocated by external injuries, giving to the nose at this point the same indented appearance as shown in Fig. 11.

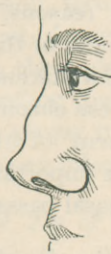

Fig. 11.

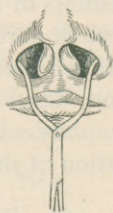

Fig. 12.

(7). *Deviation of the Cartilaginous Portion of the Nose.*

Deviation of the cartilaginous portion of the nose may be due to the unequal vertical growth of the alæ, forcing the nose over to one side, or there may be unequal development in the thickness of the two wings, distorting the nose, and giving it the appearance of being deflected. The most frequent distortion of the end of the nose results from injuries, inflicted on the nose by falls or blows during childhood, dislocating the triangular cartilage and causing deviation of the nasal septum, as shown in Fig. 13. The deformity at first may be so slight as to be almost unnoticeable, but later, as development takes place, the nose becomes increasingly distorted.

Frequently pressure against one side of the nose may slowly cause bending to the opposite side, as is sometimes the case with persons who habitually use their handkerchief

with one particular hand. This is especially the case when one nostril is obstructed, for, when blowing the nose, pressure on the open side is avoided, in order to give ample room for the expulsion of the discharge. In other cases, deflection of the cartilaginous portion may be associated with deflection of the osseous portion toward the same side, so that the whole nose, though straight along the dorsal line, may be deviated to one side, often at a considerable angle from the medium line (vide Fig. 36). This condition may result from injury, or it may be an anatomical peculiarity.

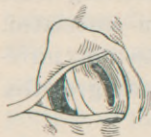

Fig. 13.

(8). *Collapse or Flattening of the Wings of the Nose.*

In the collapsed condition we have an undue flattening of the sides of the nose, interfering seriously with the nasal respiration. (Vide Fig. 34.) This may be due to defective or distorted development of the alæ, or to paralysis of the dilatores naris muscles. In other cases cicatricial contraction of the interior of the nose, the result of specific ulceration, lupus, burns, etc., may cause contraction of the nasal opening and consequent distortion of the alæ on one or both sides. In other cases it may result from injuries causing dislocation or fracture of the alæ and the consequent distortion.

(9). *Expansion or Spreading of the Wings of the Nose.*

This deformity is usually of congenital origin and consists of a marked distension or bulging outward of the lower shield cartilages, giving the end of the nose a very broad, prominent, and inordinately flat appearance. On examination, however, it will be found that there is but little thickening of the tissues, the concavity of the interior being proportionate to the extreme bulging.

This bulging outward of the wings is oftentimes in-

creased by the habit of inserting the finger into the nostrils to remove the crusts and dried discharges, resulting from intranasal disease, with which it is very often associated. Marked expansion and distortion of the alæ not infrequently takes place from the pressure of intranasal growths.

TREATMENT.

As I have pointed out in previous articles on the Correction of Nasal Deformities,¹ the beauty of the nose depends almost entirely upon its symmetry, if the disproportionate relation between the size of the nose and the size of the face is not too great.

In correcting deformities of the nose, then, we have to study the symmetrical relations of the different portions of the nose to one another rather than its proportionate relation to the face. A nose which is originally proportionate to the face will, if deformed by loss or displacement of tissue of any portion, appear very unsightly, while the same nose, made one or two sizes smaller, will, if its different parts are made perfectly symmetrical, have a more or less handsome appearance. Therefore, in correcting deformities of the nose, it is symmetry and not size that is to be considered.

In this way it will readily be seen that the causes and conditions of the different deformities of the nose are so various, that the operations required for the correction of these deformities must be equally varied, and no two cases will be found exactly alike, requiring the same operation.

There are, however, general underlying principles governing the different operations which must be observed

¹"The Deformity Termed Pug-Nose and Its Correction by a Simple Operation," *Medical Record*, N. Y., June 4, 1887. "The Correction of Angular Deformities of the Nose by a Subcutaneous Operation," *Medical Record*, N. Y., July 18, 1891. "The Correction of Deformities of the Nose Resulting from Abscess of the Nasal Septum," *New York Medical Journal*, March 25, 1893. "The Correction of Depressed and Saddleback Deformities of the Nose by Operations Performed Subcutaneously, Without the Aid of Metallic or Other Artificial Supports," *Medical Record*, N. Y., June 5, 1897.

in order to secure the desired result. Thus, in the convex vertical deformity of the bony portion of the nose and excessive development of the tissues of the tip of the nose, the excessive or redundant tissue must be removed; whereas, in the concave vertical deformity of the bony portion of the nose or of defective development of the tip of the nose, the low portions must be filled in. Usually this can be done with tissue taken from the elevated portions, so as to make the nose symmetrical, or when this cannot be accomplished by the transfer of tissue from the elevated to the low portion, the latter can be filled in by tissue taken from some other portion of the nose, where it can be spared, and the elevated portions lowered so as to make the nose symmetrical.

In many forms of distortion of the nose, especially those resulting from injury, there is almost invariably a displacement rather than a destruction of tissues, which require only to be replaced to their original position. It is important, however, that all these operations be performed subcutaneously in order to avoid the wounding of the skin and the consequent disfigurement. In some instances fracture of the nasal bones and of the septum, too, may also be necessary in order to restore the parts to a normal condition.

To particularise further, I will briefly describe, as near as I can, the steps taken in the different operations for the correction of these deformities. As already observed, however, it is rare for one variety of deformity to exist alone, and to require but one form of operation for its correction.

Convex Vertical Deformity of the Bony Portion of the Nose.

This deformity is the one most often found uncomplicated, and the operation for its correction is in the main performed as follows :

The skin is first raised from the projecting portion by incising the wall of the nose from the inside of the nostrils through to the under side of the skin, great care being exercised not to wound the skin. The opening is then enlarged sufficiently to admit the instrument required, which may consist of bone scissors, rongier forceps, a slender saw, or such other instrument as may be necessary according to the conditions present.

In removing the projecting portion, great care must be exercised not to remove too much of the redundant tissue, lest a depression be left in the top of the nose which may be more unsightly than the original deformity. This mistake more readily happens in those cases in which the upper portion of the nasal passage extends all the way up into this projecting portion. In these cases the nasal passage is very easily opened on removing the projecting angular portion.

By way of example, I will briefly cite from my records one or two typical cases, illustrating each of the different varieties of nasal deformities, together with illustrations of the appearance of the patient both before and after the operation.

Mrs. C., age thirty, was referred to me by her family physician on account of an unsightly angular convexity of the nasal bones, as shown in Fig. 14. The natural conformation of her nose was angular, but about five years before, she met with a slight accident, striking her nose against a table, which rendered it exceedingly sensitive; so much so that she scarcely could use a towel or a handkerchief without pain.

The operation for the removal of this deformity was performed according to the plan already described. After the skin was elevated from the deformed portion, the projecting portion of the nasal bone was sawed off, and the edges trimmed smoothly with a pair of slender bone-clipping forceps, so as to give the nose the exact contour desired. After the parts were thoroughly cleansed and rendered aseptic, the skin was replaced, and a gentle compress was placed over the dorsum of

the nose to hold the skin closely coapted against the bony framework.

The parts speedily healed, but, before the healing was complete, she accidentally dropped onto her nose a small hand mirror, with which she was inspecting it, while lying in bed. This injury brought about



Fig. 14.



Fig. 15.

a highly inflamed condition and a slight abscess at the seat of injury. This was evacuated antiseptically and subcutaneously as soon as the pus was manifest, antiphlogistic measures adopted. The disturbance, however, soon subsided, and the nose became perfectly well and symmetrical in every way, as shown in Fig. 15, much to the delight of the patient.

Miss D., Buffalo, N. Y., twenty-one, was referred to me on account of a convex vertical deformity of the bony portion of the nose, associated with a deflection of the whole nose to the right, both of the osseous and cartilaginous portions, together with a deviation of the septum to the same side.

This deformity of the nose followed an injury from falling on the ice when she was a child twelve years of age. Previous to this time her nose was perfectly straight, but since that time the deformity had been slowly but steadily increasing.

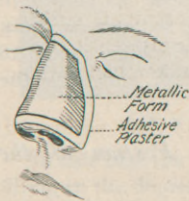

Fig. 16.

In correcting this deformity, the operation for removing the angular projection was performed in a manner very similar to the one just described. In this case, however, the septum also required straightening and the whole

nose resetting to the median line. This was done at the same time that the septum was straightened, by refracturing both nasal bones so as to elevate one and depress the other, while bringing the nose over to the median line.



Fig. 17.



Fig. 18.

This was accomplished by a method devised by myself, that obviated all danger of injuring the skin. It consisted in raising the skin from the nasal bones so as to apply the forceps to the bone from underneath the skin. After the nasal bone and septum were fractured, the nose was put in place, irrigated with a bichloride solution and made thoroughly antiseptic, and a dressing applied to the interior of each nostril in the form of a splint wound with cotton, so as to maintain the bone in an elevated position, and at the same time to hold the fractured septum in a vertical position until healed. The form employed by the writer for treating fractures of the nose, as shown in Fig. 16, was also applied to the exterior of the nose, so as to maintain symmetry throughout until healing had taken place. Figs. 17 and 18 illustrate the appearance of the patient both before and after the operation.

Concave Vertical Deformity of the Bony Portion of the Nose.

The operations for the correction of this deformity are entirely different from the last, and consist in filling in the depressed portions with flaps of tissue taken from the

unduly prominent portion, subcutaneously, thereby lowering that portion at the same time.

The methods by which this is done cannot be more clearly shown than by citing an illustrative case :

Mr. E——, aged nineteen, was referred to me for the correction of a marked saddle-back deformity of his nose, which had resulted from being struck with a base-ball club, four years before. On examination it was found that the nasal bones had been fractured, and the upper portion of the alæ of the nose and the shield cartilages were driven upward and inward, causing the sides of the nose to bulge somewhat outward, giving to the center of the nose a depressed and spatulated appearance. A large, perpendicular ridge, on the right side of the septum, at the osseo-cartilaginous junction, was also produced by the injury. This flattened condition of the center of the nose gave to its end the appearance of being unduly prominent, as seen in Fig. 19. None of the tissues, however, had been destroyed, but simply displaced from their normal position by the external force.

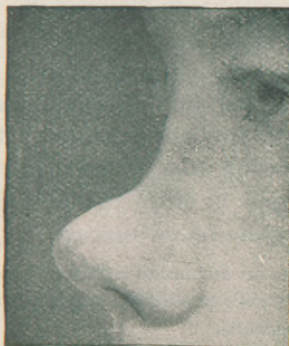

Fig. 19.

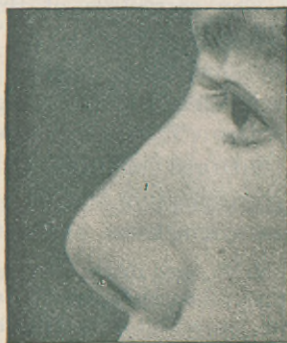

Fig. 20.

In this case the indications were to use the displaced tissues for filling in the depressed portion. The displaced tissues found on the sides of the nose were restored to the top, by raising the skin from the dorsum, through an incision made from the interior of the nostril, and turning the flaps, made of this displaced tissue, upward, to fill in the depression in the center of the nose. A portion of this displaced

tissue consisted of bone, which was sawed loose with a sharp, slender saw. When this was completed, a flap was made of the redundant cartilaginous tissue, constituting the ridge on the right side of the septum. In order to get this latter flap to the desired place on the dorsum, it was necessary to turn the flap twice to reach the spot. This was done by cutting the lower part loose and turning it up, allowing the upturned end to become attached sufficiently to supply it with nutriment, when the other end was cut away and again turned upward. When the further end had again become firmly attached, the lower end was cut away and turned into place, which completed the filling of the top of the nose very nicely. The end of the nose still projected slightly above the line of the dorsum. This was lowered by removing sufficient tissue to bring it down to the line of the dorsum, making the nose perfectly symmetrical, as shown in Fig. 20. The nose was then held in place for a considerable period, by an external dressing, until the parts were thoroughly healed, and the nose showed no tendency to become distorted.

Spatulated Deformity of the Bony Portion of the Nose.

The correction of this deformity usually consists in sawing off portions of the bulging nasal bones, and placing these bone flaps, together with the attached soft tissues, in the median line in such a position as will fill in the depressed portion. This deformity is almost always associated with an enlarged condition of the end of the nose, which requires a corresponding amount of reduction in order to make the nose symmetrical, as illustrated by the following case :

Mr. B., aged thirty, was referred to me on account of a flattened condition of the central portion of the nose, which caused him much annoyance, on account of its disfiguring appearance.

This condition was attributed to an abscess in the nose, occurring when he was a lad, the cause of which, however, was unknown, that resulted in the lack of development of this portion of the nose, as shown in Fig. 21.

On examination, the dorsum of the nose was found to be much flattened, and the nasal bones bulged outward. The end of the nose was not hypertrophied, but the shield cartilages were very much dilated or expanded, giving to the nose a markedly pugged appearance.

In the examination of the interior of the nose, the middle turbinated bodies were found very greatly hypertrophied, which doubtless had much to do with the outward bulging of the nasal bones.



Fig. 21.




Fig. 22.

The operation in this case consisted, first, in removing the hypertrophy of the middle turbinated bones. Bone flaps were then made from the bulging portion of the nasal bones, subcutaneously, and placed on the dorsum, which gave that portion of the nose normal contour. The expanded portions were then reduced by subcutaneous incisions through the cartilage. They were, however, so much expanded that it was necessary to resect a portion of the shield cartilage, in order to reduce the end to a size proportionate to the dorsum of the nose. The parts were then held in place until firmly fixed in position, as shown in Fig. 22.

Deflection of the Bony Portion of the Nose.

This deformity may be corrected by two different methods. First, by refracturing the bones and holding them in the desired position until firmly fixed. Second, by a subcutaneous osteo-plastic operation, which consists in elevating the skin from the dorsum, sawing off with a slender saw the projecting portion and placing it in the depression on the other side of the nose.

The first method has been illustrated in the second case cited of angular deformity of the bony portion of the nose.

The second method is illustrated by the following case :

Miss B., of New York, was, by her medical adviser, referred to me for the correction of a deformity of the nose, which resulted from being thrown from a carriage and striking on the nose and fracturing it, ten years before. She was so ill for a short time after, that cerebral complications were feared and, in consequence, the nose was allowed to go uncared for. As a result of the fracture, the right nasal bone was depressed and the left one displaced outward, making the nose very crooked and producing the condition which would be termed by a blacksmith "an offset" in the middle of the nose, as shown in Fig. 23.



Fig. 23.

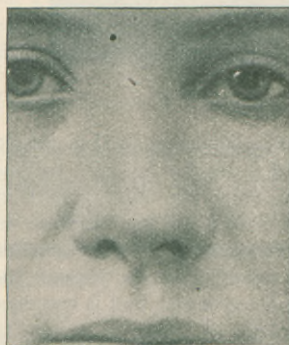

Fig. 24.

The condition of the nose was such that refracturing of the nasal bones so as to elevate the right nasal bone and depress the left one was not advisable. The only resource left, therefore, was an osteoplastic operation. The skin from the dorsum was accordingly raised and the bulging portion of the left nasal bone was carefully sawed off, leaving as much of the soft parts attached to it as possible. It was then carried over the bridge of the nose and placed in position in the depression on the right side, completely filling it. Union of this flap with the bone was encouraged by denuding the bone of the periosteum at this point before the flap was placed in position. It was carefully held in position until united and thoroughly fixed. The two sides of

the upper portion of the nose were then perfectly symmetrical. The lower portion of the nose was distorted to the left by a deviation of the cartilaginous portion of the septum. This deformity of the septum was corrected, making the nose perfectly straight. A third operation was found necessary to remove a redundancy of the alæ on the left side. The nose was then carefully held in position by a dressing adapted to it until it had become thoroughly fixed in the desired shape, leaving the nose perfectly symmetrical, as shown in Fig. 24.

Excessive development of the tip of the nose.

The so-called pug, or snub nose, is corrected by removing the redundant tissue from the end of the nose subcutaneously. The operation is performed from the interior of the nostrils as illustrated by the following case:

Miss F., age twenty-three, was referred to me for the correction of a deformity of the nose due to excessive development of the tissues at the end of the nose, giving it a very pronounced pug, as shown in Fig. 25. This condition had existed since childhood and was steadily becoming more pronounced.



Fig. 25.



Fig. 26.

The mucous membrane is first turned back from the anterior surface of the interior of the nostrils, and the superfluous tissue removed, after which the mucous membrane was replaced. Bulging of the

wings was also present in this case and the operation for reducing them was performed by very carefully incising the cartilage through to the skin in several places, so as to remove all elasticity without wounding the skin. The nose was held in place by an external dressing until healed in the desired position, as shown in Fig. 26. In some cases it is necessary to supplement the main operation by minor ones until the desired degree of perfection is attained.

Defective Development of the End of the Nose.

This deformity is corrected by filling in the deficiency with tissue from adjacent parts, by plastic operations, performed subcutaneously, varied according to the requirements of the case. The method by which this defect can be rectified is demonstrated by the following two typical and interesting cases:

Case I.—A young man, aged eighteen years, was referred to me by his family physician for the correction of a deformity and flattened condition of the end of the nose, which was congenital, or at any rate



Fig. 27.



Fig. 28.

had existed from infancy. This deformity was so conspicuous that people on the street and elsewhere would frequently turn to observe him. This was so annoying to him that he rarely mingled in society, and shunned people as much as possible. In this case the anterior and superior portion of the triangular cartilage was missing,

and the flattening of the end of the nose and the consequent lateral bulging of the alæ gave it the appearance of a frog-shaped nose, as shown in Fig. 27. Besides this, the frenum of the nose was attached so low down on the lip as to cause the end of the nose to slant backward, and the nostrils to stand prominently open, which was accentuated by the upward tilt of the end of the nose.

To correct this deformity, it was necessary to adopt a special plan of operation for raising the end, instead of depressing it, as in the operation for pug-nose just described. In order to reduce the width of the nose and at the same time to raise the end and take away the very flattened appearance, sufficient tissue was taken from the interior of the alæ on each side to form a flap, which was carried upward and held in place under the skin, which had previously been raised at the tip of the nose. It required two operations at different times to accomplish this. In order still further to raise the point of the nose, the frenum was lengthened and its attachment to the upper lip set higher up. This was done by cutting through the anterior column of the frenum on a line with the upper lip, then carrying the incision upward about half the length of the frenum and then backward, forming a stair, and then upward to a distance equal to the length of the first horizontal incision through the frenum, so that the lower end of the frenum would fit into the second stair, so to speak. The lower end of the frenum was then set into the second stair, and carefully stitched there. The skin on each side of the lower end of the frenum from which the anterior column had been removed was then raised and the edges drawn together in front of this denuded surface, so that on healing no perceptible scar was left. Two or three minor operations were required to complete the work, as shown in Fig. 28. So symmetrical and perfect is the nose that those unacquainted with the young man would not suspect that his nose had been at any time deformed.

Case II.—A girl sixteen years old had had from infancy an extremely flattened condition of the nose, the result either of an unrecognized abscess of the septum or a congenital defect, there being no history of inherited specific disease or evidence of tuberculosis taint. Examination showed that the nasal bones were normal, but the triangular cartilage of the septum was entirely absent. The soft parts were present in their normal proportions, but so flattened upon the face, from lack of central support, as to give the girl a very unsightly appearance, as shown in Fig. 29. The difficulty in this case

was to find enough material to render the septum sufficiently firm to hold up the end of the nose. There was, as is usual in these cases, a marked widening and thickening of the dorsum of the nose proportionate to the amount of flattening. This thickened ridge of tissue was incised through to the under side of the skin on both sides a short



Fig. 29.



Fig. 30.

distance from the septum, at a point where it thinned into the alæ of the nose. The skin was then raised from the dorsum of the nose, and the flaps were turned upward and held in place by small ivory splints, having holes through which sutures were passed from one to the other through the flaps and tied so as to hold them firmly in place without strangulating the parts. This relieved the flattened condition of the nose, and also gave the dorsum a sharper appearance. The end of the nose was, however, altogether too low.

Owing to the entire absence of the triangular cartilage, there was not sufficient central support to hold the nose up. In order to do this,

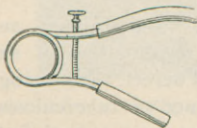


Fig. 31.

and to increase the solidity of the septum, I first scarified each side of the lower portion of the septum and the floor of the nose, and divided the anterior portion of the septum, leaving the front portion of the skin intact. I then cut wide, thick flaps from the floor of the nostril opposite the portion of the septum which I wished to render more rigid. The end of the nose was then raised and the flaps turned up and held together with clamps in a manner similar to the upper flaps, and their upper ends connected to

the under end of the cut portion of the septum with fine sutures. The result was most excellent; for the flaps, when united, were found sufficient to support it and to give the nose a very presentable appearance—so much so that it would not be suspected that the previous very flattened condition ever existed, as shown in Fig. 30. In order to maintain the nose in position until the parts became thoroughly healed, I placed in each nostril small spiral springs (Fig. 31), the upper arm being bent to the proper contour, so as to lie along under the dorsum, the other arm lying along the floor of the nose. The tension was regulated by turning the small screw in the stern. These springs were worn until the tissues had become firmly fixed and self-supporting and their further use unnecessary, the nose having then assumed a symmetrical appearance.

Deviation of the Cartilaginous Portion of the Nose.

The correction of this deformity consists in loosening the nose by subcutaneous incisions so that it can be placed in its normal position in the median line of the face, and held there until firmly fixed, as illustrated by the following case:

Mr. C., aged forty, was thrown from his wheel, striking the end of his nose against a curb, causing some contusion of the nose, followed by a considerable swelling and inflammation. When this had



Fig. 32.

Fig. 33.

subsided, the end of the nose was found to be deflected markedly to the right. This condition was allowed to go uncared for, and at the time when I saw him, two years later, the end of the nose was set over to the right side, and there was, at the same time, a marked bulging of the left nasal bone, giving the nose a very distorted appearance, as shown in Fig. 32. There was also a marked depression in the center of the nose at the junction of the upper shield cartilage with the nasal bone.

An examination showed that the triangular cartilage had been dislocated, to the right, and the left nasal bone fractured, and thrown outward. The operation in this case consisted, first, in cutting loose, subcutaneously, the cartilaginous portion along its base, and also at its junction with the vomer, and setting it in the median line. The bulging portion of the left nasal bone was sawed off and placed in the depression in the dorsum, which filled the gap completely. The nose was then held in place until the parts were entirely healed in their normal position, as shown in Fig. 35.

Collapse or Flattening of the Wings of the Nose.

The operation in these cases consists in incising the lower shield cartilage, and in some cases the upper shield cartilage also, sufficiently to overcome their elasticity, and then to hold them in the desired position until fixation of the tissues has taken place, as illustrated by the following case :

Miss B., aged twenty-three, had had difficulty in breathing through the nose for several years. On examination, the wings of the nose were found flattened and collapsed against the septum, giving very



Fig. 34.



Fig. 35.

little space for respiration. To overcome this contracted condition, the interior of the nose had previously been cauterized, in order to increase the patency of the nostrils, but which had had the effect to contract, rather than to increase, their capacity.

The nostrils were not only collapsed against the septum, as shown in Fig. 34, but the lateral shield cartilages were set so close to the septum as to give little opportunity for expanding the nostrils. In order to overcome this condition, the base of the lateral shield cartilages were cut loose, subcutaneously, and the outerlying tissues dissected up sufficiently to allow each one to be set out a sufficient distance to give ample room for the nasal passage. This was done subcutaneously, so as to prevent any cicatricial contraction of the interior of the nostril on healing. The elasticity of the lateral cartilage was overcome by subcutaneous incisions with a very slender knife. The nostrils were then held in the desired position by an internal support, consisting of a hollow tube of celluloid, formed in the desired shape. This support was maintained until the parts were firmly fixed in position, as shown in Fig 35.

Expansion or Spreading of the Wings of the Nose.

The operation for the correction of this condition consists in overcoming the elasticity of the wings by incisions through the shield cartilages subcutaneously with a slender knife in several places, and then holding them in place by an external form until they are firmly fixed in the desired position. In some instances the cartilage is so redundant that a portion of it must be excised.

It is unnecessary to cite cases to illustrate this condition, for the method of correcting this deformity has been illustrated in two or three of the cases already cited.

Deflection of the Whole Nose.



Fig. 36.

Fig. 36 illustrates a case of deviation of the whole nose, which was evidently of congenital formation, as there was no history of any accident that might have caused the condition. Usually, however, this condition is the result of accident.

The operation for correcting this deformity consisted in fracturing the nasal bones on both sides in the manner already de-

scribed, and liberating the septum along its base. The nose was then placed in the center of the face, and held there, in the manner described in the report of the second case of angular deformity of the bony portion of the nose, until fixed in its normal position.¹

As I have stated in the previous papers already referred to, no two cases of nasal deformity are exactly alike or require exactly the same operation, for, no matter how much they appear alike externally, the conditions will be sufficiently varied to require a special study of each case before any operative procedures should be undertaken, as briefly illustrated in the few cases I have selected for demonstration.

There are three conditions which must be observed in order to ensure success in these operations. In the first place, although unnecessary to state, the utmost antiseptic and aseptic precautions must be adopted, for, if suppuration in the wound should take place, engrafted tissues would be destroyed, and not only would the object of the operation be defeated, but the deformity of the nose would be increased thereby. In the next place, the plan of the operation must be carefully studied in order that the tissues at our disposal may be utilized to the best advantage. In the third place, and not less important than the operation itself, the greatest care and the most vigilant attention are required, for no matter how well directed the operation may be, the object cannot be attained unless scrupulous attention is paid to the healing process.

These operations on the nose, therefore, are not attended with the immediately brilliant results possible in many opera-

¹Three of the cases cited have been used for the illustration of previous articles. They are, however, typical and, to save the necessity of making other similar cuts, I have reproduced them here.

tions performed on other parts of the body, which can be completed at one time, the wound requiring only to be maintained aseptic until the cure is complete. On the contrary, these operations on the nose require frequent and most careful attention. The parts must not only be held in place by retentive appliances, but the shape of these appliances and the dressing must often be changed from day to day as the swelling subsides and the union of the parts takes place. It may be necessary to add a little internal or external pressure here and remove a little there until the fixation of the tissue is complete.

Without this careful attention to detail by the surgeon, and the most faithful compliance on the part of the patient with regard to all instructions, failure and disappointment will be the almost inevitable result, for, in no part of the body is the tendency of the tissues to revert to their former condition and position so strong as in the nose.

Frequently the principal or main operation must be supplemented by minor operations for the correction of slight defects. An unduly prominent portion may require lowering, a depressed portion may require raising, and so on until the work is completed. To paraphrase, we might say in these cases that eternal vigilance is the price of a perfect nose.

When considering the vast change made in the appearance of the nose by a slight alteration or departure from its symmetry and the wondrous changes made in the facial appearance and physiognomy of the person by its disfigurement, it is readily seen why the nose is regarded as one of the most distinguishing of racial characteristics.

