

Mears (J. E.)

CLOSURE OF THE JAWS

AND

ITS TREATMENT,

WITH THE

REPORT OF A CASE IN WHICH COMPLETE OCCLUSION FOLLOWED
A GUNSHOT WOUND OF THE LEFT SUPERIOR MAXILLA,
RECEIVED AT TWO-AND-A-HALF YEARS OF AGE,

AND WHICH WAS

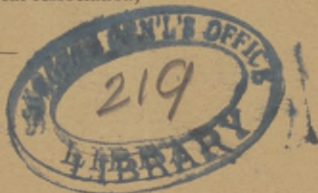RELIEVED EIGHTEEN YEARS SUBSEQUENTLY BY OPERATION
ACCORDING TO A NEW METHOD.

BY

J. EWING MEARS, M.D.,

PROFESSOR OF ANATOMY AND CLINICAL SURGERY IN THE PENNSYLVANIA
COLLEGE OF DENTAL SURGERY, DEMONSTRATOR OF SURGERY IN
JEFFERSON MEDICAL COLLEGE, ETC.

Extracted from the
Transactions of the American Surgical Association,
Vol. I. 1883.



PHILADELPHIA:
COLLINS, PRINTER, 705 JAYNE STREET.
1883.

CLOSURE OF THE JAWS

AND

ITS TREATMENT,

WITH THE

REPORT OF A CASE IN WHICH COMPLETE OCCLUSION FOLLOWED
A GUNSHOT WOUND OF THE LEFT SUPERIOR MAXILLA,
RECEIVED AT TWO-AND-A-HALF YEARS OF AGE,

AND WHICH WAS

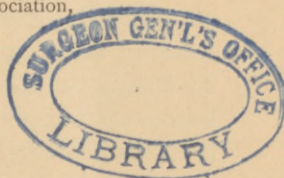RELIEVED EIGHTEEN YEARS SUBSEQUENTLY BY OPERATION
ACCORDING TO A NEW METHOD.

BY

J. EWING MEARS, M.D.,

PROFESSOR OF ANATOMY AND CLINICAL SURGERY IN THE PENNSYLVANIA
COLLEGE OF DENTAL SURGERY, DEMONSTRATOR OF SURGERY IN
JEFFERSON MEDICAL COLLEGE, ETC.

Extracted from the
Transactions of the American Surgical Association,
Vol. I. 1883.



PHILADELPHIA:
COLLINS, PRINTER, 705 JAYNE STREET.
1883.

CLOSURE OF THE JAWS AND ITS TREATMENT,

WITH THE REPORT OF A CASE IN WHICH COMPLETE OCCLUSION
FOLLOWED A GUNSHOT WOUND OF THE LEFT SUPERIOR
MAXILLA, RECEIVED AT TWO-AND-A-HALF YEARS OF
AGE, AND WHICH WAS RELIEVED EIGHTEEN
YEARS SUBSEQUENTLY BY OPERATION
ACCORDING TO A NEW METHOD.

CLOSURE of the jaws exists, as is well known, under two forms—the spasmodic or temporary, and the chronic or permanent. The former occurs usually in connection with some condition which produces irritation in the motor filaments of the third division of the fifth nerve, causing spasmodic contraction, notably of the masseter and internal pterygoid muscles. Among the causes may be enumerated delayed or difficult eruption of the third molar or wisdom teeth of the lower jaw, the development of tumors from the external surface of the ramus and body of the lower jaw, alveolar abscess in connection with the posterior teeth, necrosis, suppurative tonsillitis, and finally I have observed it to follow operations upon the lower jaw when performed in the molar region.

For the relief of these conditions the treatment consists in the removal of the causes. When dependent upon the impeded eruption of the wisdom tooth, the mouth should be opened by levers under the influence of an anæsthetic agent, and the second molar tooth should be extracted so as to afford space for the third molar, or, if the latter is found to be an imperfectly developed tooth, as sometimes happens, the offending organ should be removed. For purposes of mastication, the third is regarded as of less value than the second, and it would seem, therefore, to be

better practice to remove it in all cases. Where tumors, necrosis, and alveolar abscesses exist as causes, the treatment is obvious. After operations in the molar region of the lower jaw, antispasmodic remedies should be administered, and water, as hot as it can be borne, should be held in the mouth in contact with the parts so as to allay irritation.

In permanent closure of the jaws we have quite different conditions to deal with. The contraction is not due, in this form, to the perverted function of pre-existing structures, but to the formation of adventitious tissues, which firmly and permanently lock the jaws, and in some forms defy successful removal. Although not a very unusual occurrence, it would appear, from an examination of surgical text-books, that the description and treatment of this truly distressing condition have not, until a recent period, claimed the attention their importance deserves.

In volume iii. of the third American edition of Velpeau's Surgery, edited by Dr. Valentine Mott, of New York, the latter, under the caption of Concluding Remarks, records sixteen cases which came under his care from 1812 to 1843, and in which he operated with great success, accomplishing *perfect cures* in all instances save one. He enumerated three causes upon which "immobility of the lower jaw" depended. The first and most frequent cause was the formation of unyielding cicatrices, resembling, as it were, *adventitious ligaments*. A preternatural rigidity or dynamic contraction of the muscles was stated as the second, and the formation of an osseous plate of bone connecting the upper and lower jaws was given as the third cause. His process of surgical treatment consisted in the use of an instrument constructed upon the screw and lever principle with which the jaws were forcibly separated. The instrument employed was devised by Scultetus, and is depicted in his *Armamentarium Chirurgicum*. In one case (in 1831) all efforts to separate the jaws were ineffectual, and he regretted myotomy was not known at the time the operation was performed, for he was persuaded that subcutaneous division of the masseter muscle would have liberated the jaws, and resulted in rendering complete his list of perfect cures. With the expression of high respect for the

opinions and statements of this distinguished surgeon, I cannot think that he was afforded the opportunity of examining, at the expiration of a sufficient period of time, the results of his method of operation in the cases recorded.

In the Jacksonian Prize Essay of 1867, Mr. Christopher Heath, of London, recorded cases in which he had performed operations for relief of permanent closure of the jaws, and in a chapter devoted to the subject collated the work of others up to that date. According to Mr. Heath's statements, English text-books on surgery were remarkably barren of any information upon the subject. He alludes to a reference of Mr. Cooper, in his Surgical Dictionary, to a case treated by Dr. Valentine Mott, in 1831, in which an operation was performed for closure of an opening in the cheek caused by sloughing and accompanied by closure of the jaws. In the edition of Cooper's Dictionary, issued in 1861, closure of the jaws is described as occurring after "sloughing of the cheeks and gums from profuse salivation, the cicatricial bands being so rigid as scarcely to allow of the separation of the teeth, but they became more pliant in time." The latter part of this statement, Mr. Heath very justly says, is not borne out by general experience. Due credit is given to our distinguished President, Prof. S. D. Gross, for giving "by far the most complete account of the affection in his large work on Surgery."

Prof. Gross, in the first edition of his Surgery, states, as the most common cause, according to his observation, "profuse ptyalism followed by gangrene of the cheeks, lips, and jaw, and the formation of firm, dense, unyielding inodular tissue, by which the lower jaw is closely and tightly pressed against the upper. In the worst cases there is always extensive perforation of the cheeks permitting a constant escape of the saliva and inducing the most disgusting disfigurement. A second cause is given as ankylosis of the temporo-maxillary joints, consequent upon injury or arthritic inflammation. The formation of an osseous bridge, uniting the jaws or extending from the lower jaw to the temporal bone, is assigned as the third cause. The effect of the closure is stated to be a serious interference with mastication and articulation, and if it occur early in life it is often followed by a stunted development of the jaw.

With regard to treatment, Prof. Gross states that ankylosis of the temporo-maxillary articulation may be relieved by forcibly depressing the lower jaw with wedges or levers, an anæsthetic agent having been administered. In order to prevent re-formation of the adhesions, the lever is to be used daily for many months or years. When the immobility depends upon the presence of inodular tissue, the proper remedy is excision of the offending substance—an operation which is both tedious, painful, and bloody, and unfortunately not often followed by any but the most transient relief owing to the tendency in the parts to reproduce the adhesions, however carefully and thoroughly they may have been removed. After the excision is effected, the patient must make constant use of the wedge, wearing it for months and years so as to counteract the tendency to reclosure. In a large experience, Prof. Gross found that but few patients were permanently relieved by operations of this kind. Where immobility of the jaw is caused by the formation of an osseous bridge it may be remedied by the removal of the adventitious substance by means of the saw and pliers. Sometimes, however, such a procedure is rendered inexpedient on account of the long duration and excessive firmness of the ankylosis and the large quantity of the new osseous tissue.

In cases of long standing it is recommended to divide the masseter muscle subcutaneously and with great care, lest important vessels be divided. Plastic operations may be performed to close the gap in the cheek which may follow salivation.

I have made these liberal quotations from Prof. Gross's work in order to show how little confidence was reposed in the methods of operation then in vogue in this country at least, and how unsatisfactory the results were which followed their employment.

In 1855, Dr. Friedrich Esmarch, Professor of Surgery in the University of Kiel, read an essay at the Congress at Göttingen on the "Treatment of Closure of the Jaws from Cicatrices."¹ In this essay he gave an elaborate description of the anatomical

¹ Die Behandlung der narbigen Kieferklemme durch Bildung eines künstlichen Gelenkes um Unterkieferkiel, 1860.

relations and histological characters of the mucous membrane of the cavity of the mouth, as well as of the pathological conditions which occur in cicatricial formations in this membrane. He described the outer space, or buccal cavity as it is termed, between the alveoli and teeth and cheek and lips as an elastic dilatable sac, and showed that as soon as this sac shrinks together, loses its elasticity, or is replaced by a rigid substance, the mobility of the jaw must either be impaired or entirely cease. After ulceration or sloughing of the mucous membrane, cicatricial contraction ensues, which the depressors of the jaw cannot overcome. If the cicatricial tissue is entirely excised, re-formation of a cicatrix, possessed, if anything, of greater powers of contraction, takes place. Mechanical appliances, it is true, such as the metal shields of Mr. Clendon, of London, dentist, may retard and limit, to a certain extent, this formation, but it requires their constant use for long periods of time, and under very painful and trying conditions to the patient. In order to supply the place of the destroyed mucous membrane, Dieffenbach suggested, after division and separation of the cicatrix from the bones, the covering of the raw surfaces with sound mucous membrane transplanted from an adjacent part. In the most favorable cases this is almost impossible, owing to an absence of sufficient healthy mucous membrane near by. Jaesche, in 1858, recommended the use of a flap of skin instead of mucous membrane, which may be also difficult to obtain from a favorable point. Esmarch, however, would not hesitate to take a flap of skin from so remote a part as the arm. In view, therefore, of the pathological conditions which exist in these cases, and of the great difficulties presented in overcoming them, as well as the failures which followed efforts made, Esmarch recommended the formation of an artificial joint in front of the contraction, in order to give the other half of the jaw some, although a limited motion. This joint was to be formed by the excision of a segment of bone of such size as to prevent union of the divided ends, and the operation was performed by an external incision along the base of the jaw.

Although this operation was suggested by Prof. Esmarch in

1855, the method was not employed until 1858, and then by Dr. Wilms, of Berlin.

In 1857, shortly after the suggestion of Esmarch had been made, Prof. Rizzoli, of Bologna, operated for permanent contraction of the jaws by a simple division of the lower jaw in front of the cicatrix, using for that purpose powerful forceps applied within the mouth. In order to prevent union he inserted a piece of gutta-percha between the cut surfaces of bone, which procedure, it is stated, was accomplished successfully. Satisfactory results have been achieved by English and Continental surgeons by the employment of both of these methods. Many years before, Dieffenbach had endeavored to relieve the closure of the jaws by the division of the ramus of the jaw, and in this manner obtain the formation of an artificial joint. This method of operation was not followed by complete success.

In cases where closure results from ankylosis of the temporo-maxillary articulation, Mr. Heath recommended either division of the bone or resection of the joint, giving preference to the former on account of the ease with which it could be performed from within the mouth "by dissecting up the mucous membrane and masseter muscle so as to introduce a narrow saw or strong bone-forceps and dividing the ramus as high up as convenient," and thus establishing a false joint as originally proposed by Dieffenbach for cicatricial contractions.

He also quotes from Sédillot the case of true ankylosis in which M. Grube, in 1863, divided the ramus of the jaw from within the mouth with a straight chisel, and in this way formed a false joint. The masseter muscle was subsequently divided subcutaneously, and the cure was permanent.

In the last edition of his work on Surgery, Prof. Gross refers to the two methods suggested by Mr. Heath, neither of which he characterizes as very promising nor easy of execution. He reports a case of complete synostosis of the lower jaw on the left side, the result of rheumatism, in a girl seven years of age, in whom, in 1874, he exsected the condyle along with a portion of the neck of the bone, and succeeded in establishing excellent motion. The parts were exposed by a curvilinear incision in front of the ear with hardly any loss of blood, and the condyle

was prized out of its socket by means of an elevator which combined the principles of a lever and a knife.

Under the date of December 6, 1845, Dr. John M. Carnochan, of New York, in a communication addressed to Dr. Townsend, translator of Velpeau's Surgery, called attention to the fact that he was the first to put into practice the division of the masseter muscle, and the first to propose simultaneous division of the masseter and temporal muscles of one or both sides, and the formation of an artificial joint on the inferior maxillary, either by simple division of the bone or by exsection of a portion of it as a remedy for immobility of the jaw. In this communication he reports at length a case upon which he operated in 1840. After dividing the adhesions and applying the screw lever, he failed to separate the jaws; he then divided the masseter muscle subcutaneously with a narrow tenotome, and again applied the lever. Again the efforts were without avail, and before resorting to division of the temporal muscle, as was his intention, he re-applied the lever, and under the force employed the jaw was fractured in its body. The patient could now open the mouth to the extent of an inch and a half. The result following this accident, and the successful attempt of Dr. John Rhea Barton, of Philadelphia, to form an artificial joint in the femur, suggested the application of this principle to the lower jaw. With the intention of putting this plan into execution at a future day, the union of the fractured bone was permitted to take place, and the jaw became again immovable, with a slightly increased space between the teeth. So far as I am able to ascertain, the operation suggested was never performed. The inference he drew from the results in the case was that mere fracture or section of the inferior maxilla, even accompanied by repeated and free motion, would be insufficient to produce an artificial joint, and that to fulfil this indication the entire exsection of a portion of that bone (towards the angle or at some other locality which the nature of the individual case might suggest) would be necessary. It will be seen from this statement of Dr. Carnochan that the operations described as that of Esmarch and of Rizzoli were, in fact, suggested by him some fifteen years previous to the presentation of the essay of Esmarch at the Congress at Göttingen.

A *résumé* of the methods of operation which have been suggested for the relief and cure of permanent closure of the jaws shows that they have been as follows:—

1st. Excision, more or less complete of the cicatricial bands or osseous formations, and the subsequent employment, for a long period of time, of wedges and levers to retain the separation of the jaws. Transplantation of mucous membrane to cover the surface of the wound as suggested by Dieffenbach, or transplantation of skin as practised by Jaesche.

2d. Division of the cicatricial tissues, and the adaptation of metal shields, not only to prevent re-contraction, but to re-establish the sulcus of mucous membrane at the base of the alveolus.

3d. Dieffenbach's method of simple division of the ramus of the jaw—and a formation of a false joint *behind* the point of contraction.

4th. The formation of a false joint as originally suggested by Carnochan. Esmarch's suggestion that it be formed in front of the contraction, and that a segment of bone be removed for this purpose—by external incision.

5th. The formation of a false joint *in front* of the contraction by simple division of the bone, made by forceps applied within the mouth—Rizzoli's method.

In closure due to ankylosis of the temporo-maxillary articulation, the methods practised are:—

1st. Division of the ramus of the jaw from within the mouth, either by saw, forceps, or chisel, and the formation of a false joint.

2d. Exsection of the condyle with a portion of the neck, the incision being external.

A patient having presented herself to me for relief from permanent closure of jaws of long standing, due to cicatricial contraction, I had occasion to study the various methods of operation which had been proposed for this form, and became impressed, as the result of this investigation, with the fact that, objections more or less valid, could be urged against each, and that it was possible to carry into execution successfully a method with the

hope of securing better results. Moreover, in two cases I had failed by the plan of excision, and the use of levers to accomplish satisfactory results, and I had witnessed similar failures in others. The objections in cases of cicatricial contraction against the methods of operation above enumerated may be stated as follows:—

1st. Excision.—The re-formation of the cicatrix and the great pain to which the patient is subjected in the use of wedges, levers, and screws—the difficulties of securing flaps of mucous membrane and skin from adjacent parts and their successful transplantation. The almost universal failures.

2d. Division and Use of Shields.—The pain and inconvenience experienced by the patient in the use of the shields, and difficulty of obtaining the full coöperation of the patient in carrying out the necessary manipulations within the mouth.

3d. Division of the Ramus *behind* the Contraction.—Dieffenbach's Method.—The difficulty of obtaining a permanent false joint after simple section of the bone, and without division also of the overlying masseter muscle.

4th. Carnochan's Method as practised by Esmarch.—The loss of one-half of the jaw for the purposes of mastication, where excision is made in front of the contraction. Its inapplicability when both sides are affected, and the deformity which results.

5th. Carnochan's Method as practised by Rizzoli.—The difficulty in accomplishing the formation of a false joint by simple division of the bone—the tendency to reunion being much greater than when a segment is removed.

Considering these objections I decided to operate upon my patient in the following manner: By division of the ramus of the jaw, about its middle, exsection of the condyle and division of the insertion of the temporal muscle, thus releasing the coronoid process and effecting its removal with the condyle—division of the masseter muscle at its points of origin—non-interference with the cicatricial band. By this plan I hoped to secure sufficient space for free movements of the remaining portion of the ramus, and I proposed to utilize the cicatricial band as a *quasi* ligament, and obtain movement of the bone between this band

and the internal pterygoid muscle. By division of the masseter at its point of origin, I proposed to relieve the tension of this muscle and more effectually prevent union of the divided fibres.

CASE.—The patient consulted me in January of this year (1883), and gave the following history of her case: She is now twenty years of age. Eighteen years ago, when two years and a half old, and then residing on the banks of the Brazos River in Texas, she received a gunshot wound of the left superior maxilla, the charge, medium sized bird shot, entering just below the inferior margin of the orbit.

At the time of the receipt of the injury she was engaged in play on the porch of her dwelling, and the gun was discharged by a lad thirteen years of age, whose height compelled him to hold the weapon at an angle in taking direct aim at her head. This was done in play, the gun being presumed to be unloaded. The father, who was soon at her side, made efforts to check the hemorrhage which ensued, and sent immediately for the nearest physician, living some thirty-two miles distant. Late in the evening he arrived, "tired and cross," and declined to do anything, as he did not like to cause unnecessary pain, and as the child was sure to die. After a night's rest he returned home.

On examination it was found that the charge had entered just below the left orbit, comminuting the upper and fracturing the lower jaw as well, passed through the mouth and emerged below the left ear. The father, in the hope of saving his child's life, continued his efforts to ward off fever and allay swelling by the administration of simple remedies, and the application of lint saturated in arnica. At the same time the mouth was forced open to cleanse it, but so great was the pain caused by the effort, that it was discontinued. The patient was, after a short time, unable to open the mouth for the purpose of taking nourishment, and finally all efforts were abandoned to effect the separation of the jaws, and soon they became firmly locked. At the expiration of a week following the accident, another physician was summoned, who removed some wadding, shot, and pieces of bone, and gave a very unfavorable prognosis as to the recovery of the child.

At the time of the accident the globe of the eye did not appear to be seriously injured, but the inflammation which attacked the parts and the cicatricial contraction which ensued in the closure of the

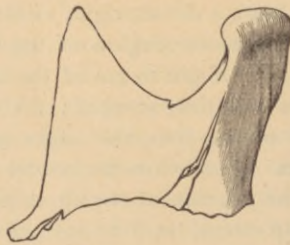wound, destroyed vision, and drew down the ball to such an extent as to expose but a line of the iris, and produced a marked condition of ectropion. Soon the patient became accustomed to eat only soft food, which she learned to force between the teeth. The pressure exerted upon the teeth caused them to break, and the posterior teeth, which could not be erupted, became carious and gave pain.

A careful examination of the parts involved showed firm and complete occlusion of the jaws, absence of the two central and right lateral incisor teeth of the upper jaw, which had been worn away by the pressure made in rubbing pieces of food over them. Slight lateral movement could be obtained, showing absence of temporo-maxillary ankylosis. On passing the finger into the buccal cavity of the left side, a dense, rigid, cicatricial band could be felt extending from the molar region of the upper, to the molar region of the lower jaw. Eight to ten of the anterior teeth of the upper and lower jaws had fully erupted; the remaining were imbedded in the alveoli of the jaws, the edges of the crowns being seen in some instances. Just below the border of the orbit, on the left side, occupying the position of the upper portion of the canine fossa, there was a deep sulcus, lined by integument which had been drawn into it, and with it the lower eyelid; complete eversion of the lid having been produced, and the lower segment of the globe being constantly uncovered. This sulcus was caused by the entrance of the charge of shot. There was marked flattening of the entire left side of the face produced by the injury inflicted upon the structures, and the absence of subsequent full development. On the left side of the neck, on the upper portion, a few shot could be felt lying beneath the integument, and one was also felt beneath the mucous membrane overlying the left side of the lower jaw. Articulation was somewhat impaired.

On the 26th of January, 1883, I operated upon the patient in the manner above indicated, and with a view of relieving, by the one operation, the condition of ectropion. To accomplish this, I began the incision to the nasal side of the sulcus, carried the knife through it, and continued the incision along the lower border of the zygomatic arch to the tubercle at its base. I then dissected up the tissues from the bottom of the sulcus, and also from the anterior portion of the floor of the orbit, in order to release them completely, and thus replace the lower lid. Owing to the contraction which had ensued, it was found necessary to divide this flap of tissue trans-

versely, bring it into proper position, and secure the edges by a hare-lip pin. Continuing the dissection, I divided the fibres of the masseter muscle separating the entire origin, and then depressed it with the superjacent structures, thus very easily and completely exposing the coronoid process, the articulation and outer surface of the ramus to one-half its extent. With strong bone forceps I divided the ramus, severed the ligaments of the articulation with the probe-pointed bistoury, then twisted out the articular head, and finally detached the insertion of the temporal muscle, removing the piece of the ramus with the processes which I exhibit (Fig. 1).

Fig. 1.

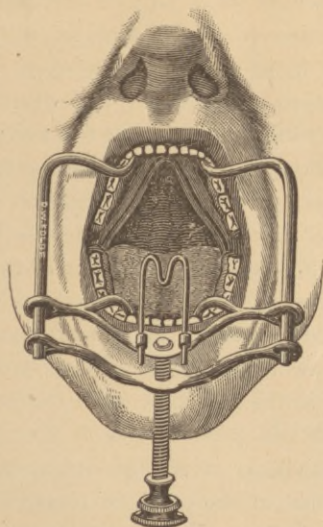


Efforts were now made with wedges of wood to separate the jaws, but without success. On passing a probe between the jaws I found a strong osseous band which firmly united them; this I divided with the Adams saw, passing it between the imperfectly erupted teeth, and sawing from before backward. The wedges were again used, and the jaws separated to the extent of one inch between the processes at the position of the incisor teeth. The divided portions of the osseous band were then cut away with pliers and knife, and found to consist of a thin plate of bone.

On recovery from ether, the patient found no difficulty in opening the mouth, although it was accompanied by slight pain. In a few days the pain disappeared, and the mouth could be readily opened. Within three weeks after the operation twenty-one roots and partially erupted teeth were extracted, so as to fit the processes for the adaptation of artificial dentures. The incision was closed by four interrupted silver sutures, and dressed with lint saturated with carbolized oil. In order to assist in the exercise of separating the jaws, I employed daily for two weeks a mouth gag, which I devised some years since, and which works with a strong screw.

(Fig. 2.) In using it the patient complained of pain on the sound side, the structures of which had become somewhat rigid owing to long disuse.

Fig. 2.



At this time the patient is wearing a set of artificial dentures, which are retained readily in place, and which serve the purpose of mastication excellently well. The ectropion is relieved so that the globe is covered by the eyelids. Articulation is much improved. No tendency to re-contraction is observed. On the contrary, the patient states that her ability to open the mouth increases each day, and that she can separate the jaws to a greater extent than was done at the operation, and without pain. Exact measurement gives the distance between jaws, when separated, as one-and-a-half inches at the position of the incisor teeth.

Whilst, in the present case, the incision was made so as to relieve the ectropion as well as to uncover the joint and ramus, I should modify it but slightly in other instances, as it completely exposes the parts, and does not involve either large branches of the facial artery or nerve, thus avoiding excessive hemorrhage or subsequent facial paralysis. It should begin at the middle of

the lower border of the malar bone, and be carried outward in contact with this border and the inferior border of the zygomatic arch, to a point over the tubercle at its base; it is desirable to keep near the border of the zygoma in order to avoid wounding the duct of Steno, which lies a finger's breadth below.

If there is objection to the disfigurement produced by the cicatrix, when the incision above described is employed, the ramus can be exposed and divided, and disarticulation accomplished by an incision beginning about the middle of its posterior border and carried along the angle and base of the body of the jaw to such an extent as to permit easy elevation of the flap. The position of the facial artery is to be remembered, and section of this vessel avoided if possible. Branches of the facial nerve will be divided, and more or less facial paralysis will follow. The parotid gland should be pushed up so as to escape injury.

So far as I am aware, the plan of operation suggested and practised is novel, in the fact that it includes removal of both coronoid and condyloid processes with the upper half of the ramus, as well as division of the masseter, external pterygoid, and temporal muscles, at the point of origin of the former, and the insertion of the latter. The advantages claimed over other methods are:—

First. Its application to all forms of permanent closure, that due to temporo-maxillary ankylosis, as well as to cicatricial formations.

Second. The utilization of the entire body of the jaw in opening the mouth, not only affording in this way greater advantage in mastication and articulation, but serving to prevent deformity.

Third. The formation of a more perfect artificial joint in the removal of both processes, thus overcoming the resistance of the more or less fixed upper segment, when the joint is made either in the body or the ramus of the bone.



