

Jarvis (W. C.)

ali

Catarrhal Affections of the
Nasal Passages as a Cause
of Pulmonary Phthisis,
with Special Reference
to the Question of
Heredity.

BY

WILLIAM C. JARVIS, M. D.,

CLINICAL PROFESSOR OF LARYNGOLOGY AND DISEASES
OF THE NOSE AND THROAT IN THE NEW YORK
UNIVERSITY MEDICAL COLLEGE.

REPRINTED FROM

The New York Medical Journal
for September 5 and 12, 1885.



CATARRHAL
AFFECTIONS OF THE NASAL PASSAGES
AS A CAUSE OF
PULMONARY PHTHISIS

*WITH SPECIAL REFERENCE TO THE QUESTION OF
HEREDITY.*

BY

WILLIAM CHAPMAN JARVIS, M. D.,
CLINICAL PROFESSOR OF LARYNGOLOGY AND DISEASES OF THE NOSE AND
THROAT IN THE NEW YORK UNIVERSITY MEDICAL COLLEGE.

*REPRINTED FROM
THE NEW YORK MEDICAL JOURNAL
FOR SEPTEMBER 5 AND 12, 1885.*



NEW YORK:
D. APPLETON AND COMPANY,
1, 3, AND 5 BOND STREET.
1885.

CATARRHAL AFFECTIONS OF THE NASAL PASSAGES

AS A CAUSE OF

PULMONARY PHTHISIS,

WITH SPECIAL REFERENCE TO THE QUESTION OF
HEREDITY.*

THE ætiology of pulmonary tuberculosis, a subject always replete with interest to the clinical investigator, has naturally received a deeper significance since the discovery of the *Bacillus tuberculosis*. Despite, however, the positive character of Koch's results, there remains, according to his own admission, much yet to be learned concerning the præ-tubercular conditions which determine the development of the tubercle bacillus.† These conditions, variously and oft-times vaguely referred to by such terms as tubercular disposition, predisposition, heredity, environment, etc., it would appear, are the principal avenues through which this momentous question, affecting the lives of so many thousands in our crowded city and elsewhere, is to be approached.

Several years ago, while studying the cause and compli-

* Read before the American Climatological Association, May 27, 1885.

† "Mittheilungen aus dem kaiserlichen Gesundheitsamte."

cations of nasal diseases, my attention was attracted to the co-existence of bronchial with nasal catarrh, and somewhat later to the association of nasal disease with pulmonary phthisis.

These earlier impressions did not assume the shape of convictions until the reliable evidence I am about to present for your serious consideration was forthcoming.

In view of the light already thrown upon the question of the ætiology of tuberculosis through Koch's bacillary investigations, I have deemed it profitable to review some of the evidence he has offered us concerning the disposition and predisposition to phthisis.

As regards the question of the physical conditions favorable for the development of bacilli, we are informed by Koch that pent-up secretions, removal of the protective epithelia of the bronchi, abrasions, etc., are to be considered the proper soil—the "*geeignete Boden*"—for the lodgment and growth of the deadly tubercular plant. Now, these conditions will be recognized as the common results of catarrhal inflammation of the upper and lower air-passages. One or more of them are frequently observed in nasal catarrh, and may be also associated with catarrhal phthisis when taken in the popular sense of the term as taught to us by Dr. Alfred L. Loomis.

In certain cases we find pulmonary tuberculosis rapidly following in the train of a catarrhal bronchitis, while others will, apparently, resist the inroads of the bacillus for many years.

In treating my subject I shall begin with the nares and endeavor to distinctly trace the effects of nasal catarrh upon the larynx, and then in turn explain the relation of the resultant laryngeal disease to bronchial catarrh, catarrhal phthisis, and, finally, pulmonary tuberculosis.

The relations of the nostrils to the lungs is so intimate

that we are not surprised to find Koch involuntarily addressing his attention to the nose for a partial solution at least of the question of the ætiological relations of the bacillus to pulmonary tuberculosis, with the remark, "Air inhaled through the nose is deprived of disease-germs, and nasal respiration, therefore, constitutes a positive protection against infection by reason of the retention of the infectious material by the nasal mucous membrane." Conspicuous among the complications traceable to nasal catarrh, and bearing upon the question of the causation of pulmonary phthisis, is *chronic irritative hyperæmia of the larynx*. I can not at present enter into a description of this affection, or fully explain how it is brought about by the entrance of nasal mucus into the larynx. I called especial attention to this condition in a paper read before the American Laryngological Association, session of 1881, to which I must refer you.*

This affection is usually observed as a peculiar red discoloration of the normally pearly white vocal cords, and, when found, constitutes an excellent guide for the determination of the amount of congestion of the general laryngeal mucous membrane. Chronic hyperæmia of the larynx frequently develops attacks of acute catarrhal laryngitis, and this affection in turn often involves the tracheal and bronchial mucous membrane by inflammatory extension. In other words, recognizing the larynx, with certain modifications, as the upper portion of the lungs, catarrhal inflammation of this organ clearly constitutes a menace to the integrity of the entire pulmonary tract. The laryngoscopic study of the pathological processes concerned in the production of laryngeal hyperæmia and its common sequela—laryngitis—is, therefore, required to throw light upon the pulmonary diseases following in its wake.

* "Archives of Laryngology," vol. iii, p. 148.

Nasal stenosis and defective nasal drainage are the two most important indirect agents concerned in the production of this affection. The manner in which these intra-nasal disturbances lead to laryngeal and lung complications is principally by habitual mouth-breathing, the irritating action of nasal mucus in the larynx, and inflammatory extension from the posterior nares.

The part played by nasal mucus as an ætiological factor in the production of laryngeal and pulmonary disease is well pronounced and very important. The constancy with which chronic irritative hyperæmia of the larynx occurs as a result of chronic nasal catarrh encouraged me to make the statement that the simple discovery of this peculiar congestion was, as a rule, sufficient evidence of the existence of a chronic nasal catarrh.

The manner in which chronic hyperæmia of the larynx is induced through defective nasal drainage is exceedingly simple, and is best understood by carefully studying the direction of the several anatomical planes of the upper air-passages. I will refer you to a paper read by me before the New York Academy of Medicine, in which is given a detailed description of this system of drainage.*

I may simply state in passing that the disturbances to nasal drainage originating from a nasal catarrh prevent the natural disposition of nasal mucus, and, consequently, permit it to enter the larynx. Now, nasal mucus in the larynx is a foreign body, and as such invariably gives rise, by prolonged irritation, to a familiar train of signs and symptoms. Foremost among the signs stands, as I have already pointed out, chronic irritative hyperæmia of the larynx. The larynx naturally resents the invasion of its territory by irritating nasal discharges, and we have, as one of a number of *well-marked symptoms*, a constant inclination to "clear the

* "Medical Record," March 14, 1885.

throat." This act in itself may constitute an additional irritant by the rasping effect of the effort upon the vocal cords. The part played by habitual mouth-breathing as an excitant of laryngeal disease is simply that resulting from the absence of those conditions so essential for the purification and preparation of the respired air, and attributable to prolonged nasal stenosis.

Having briefly presented the most conspicuous causes which serve to account for catarrhal disease in the larynx, the next step would naturally be to study the nasal complications responsible for the existence of the laryngeal affection.

Among these may be mentioned deviation of the nasal septum, turbinated hypertrophies, polypi, adenomata of the vault of the pharynx, etc. The proper consideration of either one of these conditions, taken alone, would cover many pages. I shall, therefore, be compelled to entirely omit the consideration of some, and only briefly accentuate those most commonly concerned in the production of laryngeal and pulmonary disease.

Hypertrophy of the turbinated tissues is an almost invariable concomitant of the moist forms of nasal catarrh. It may stand either alone or, as is commonly the case, exist as the result of a deviated septum. The co-existing mouth-breathing, hypersecretion, and disturbed nasal drainage will, of course, be governed by the location and amount of the turbinated hypertrophy. Passing promptly to the consideration of the second condition, the deviated septum, we are at once confronted by the most active and common agent concerned in the production of pulmonary and laryngeal disease. This condition differs from turbinated hypertrophy in being both a cause and result of catarrhal inflammation. Its existence, furthermore, implies the co-existence of a turbinated hypertrophy, barring, of course, recent trau-

matic deviations and extra-nasal distortions of the septum.* I have already had occasion to explain how a deviated septum, through *pressure irritation*, excites catarrhal inflammation.† Its action may be, to employ a homely example, compared to that of a shoe-button impacted in the nostril. The deviated cartilaginous spur, like this familiar foreign body, presses against the exceedingly sensitive surfaces of the turbinated tissues, invariably exciting and keeping up a certain amount of inflammatory action.

Thus we have a system of reciprocal irritation provoking and prolonging a nasal catarrh. For want of a better expression, I have called this *pressure irritation*, and I trust the term may recall to your mind the pathological process it indicates when employed in this paper.

The rôle played by the turbinated tissues and septum in the production of rhinitis hypertrophica was noted by me in a paper read before the American Laryngological Association, session of 1880; and the ætiological relation of the nasal septum to diseased turbinated bodies was also satisfactorily demonstrated by Dr. Harrison Allen, though in a way differing from my own, in the same year.

Having determined the ætiological significance of the deviated septum in nasal catarrh, for a more detailed description of which I must refer you to my earlier papers on this subject. Another factor, which serves in turn to account for the deviated septum, requires a brief consideration—namely, heredity.

The term heredity, usually furnishing much material for uncertain speculation and little opportunity for satisfactory demonstration, has, in this connection, assumed a more definite meaning by reason of much corroborative testimony always at hand.

* See "Archives of Laryngology," 1882, vol. iii, p. 300.

† *Ibid.*, vol. ii, p. 147.

This evidence has convinced me that the deviated septum is frequently transmitted from parent to child.

In 1882, while engaged relieving the sufferings of a young woman, brought on by a congenital occlusion of the nares, my attention was attracted to an abnormal contraction of the superior maxillæ. In reporting the case I laid great stress upon the possibility of the chronic coryza and turbinated hypertrophies being associated with this condition as cause and effect.* Since that time, by careful investigation and comparison, I have been enabled to supply the necessary links in a chain of evidence which has demonstrated that one of the most common causes of catarrh is discoverable in the conformation of the hard palate. This peculiar malformation I find to be transmitted from parent to child with remarkable regularity, and its intelligent recognition and proper appreciation enables one to most satisfactorily account for a large number of catarrhal disturbances in the upper air-passages.

In these cases we find that the superior maxillary bones are not only contracted, but are likewise elevated, abnormally increasing the depth and diminishing the diameter of the roof of the mouth. The vertical measurement of the osseous nares is naturally more or less affected by the encroachment of the elevated hard palate, and the nasal septum, as a consequence, is bent laterally, as exemplified in the diagram, Fig. 1, A representing the normal septum and maxillary arch, and B the abnormal.

These plaster impressions, kindly presented to me by Dr. Eddy, nicely illustrate this peculiar palatine formation. They were selected from among thirty other plaster casts as the only two in which I could positively pronounce the existence of a chronic nasal catarrh. The doctor, on referring to the name of the subject, found that both belonged

* See "Archives of Laryngology," 1882, vol. iii, p. 108.

to the same individual—a patient he had referred to me several years before for a severe chronic coryza, and the

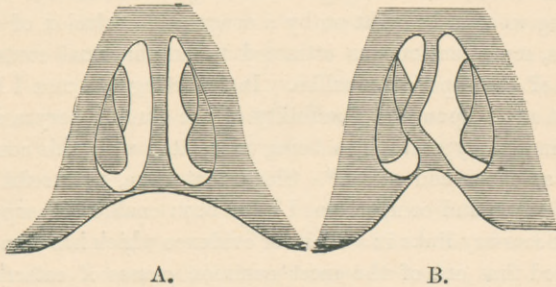


FIG. 1.

only one out of the whole number of casts. On comparing this plaster impression, Fig. 2, with the normal palatine arch, you will discern certain well-defined differences. The dis-

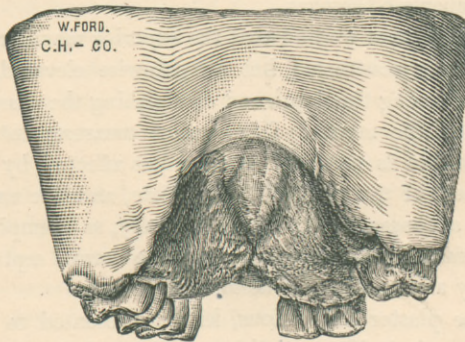


FIG. 2.

tance between the alveolar ridges is much greater in the normal specimen. The transverse diameter of the abnormal specimen is not only smaller, but its surface is markedly irregular. The maxillary arch may be considerably higher

than this normal specimen, and yet not constitute a pathological condition. No two maxillary arches are exactly alike, and some exhibit an elevation easily mistaken for a deformity. The important distinction to bear in mind is the abrupt elevation along the line of the median raphé. When such a condition is observed, we may at once look for, and, in my experience, invariably discover, a corresponding deviation of the septum. This condition, furthermore, is found associated with a chronic coryza. Indeed, I hold it to be possible in certain cases to diagnosticate the existence of a chronic nasal catarrh by the simple examination of the roof of the mouth, or, what amounts to the same thing, by inspecting an impression in wax or plaster, from any part of the world. After having ascertained the congenital character of this nasal abnormality, the next step was an endeavor to account for its existence. In tracing this peculiar formation to its hereditary origin, I was greatly assisted by instituting a comparative study of the external nose, and particularly the persistence of certain types in the same family.* By employing a similar method of reasoning to the internal configuration of the nares, I have been able to trace the peculiar conformation back to a common parental origin. This condition occurs as an hereditary manifestation with great constancy. Once the peculiar nasal type of the parents is recognized, its modifications in the children are easily determined.

It would appear that abnormal contraction of the nares is likely to be associated with intellectual enlargement of the skull in certain families, a fact which may serve to account for the tendency to phthisis attributed by some observers to severely studious or sedentary habits.

* "It is said by Ribot that, of all the features, the nose is the one which heredity preserves best."—"Hereditary Traits," Richard A. Proctor.

It is well known that a marked increase in the dimensions of the cranial dome is apt to be accompanied by a contraction of the osseous frame-work of the face. If it were convenient I might cite a number of interesting examples, carefully collected by me, to prove the correctness of this view.

Through Dr. L. J. B., referred to me by Dr. P. A. Morrow, my interest in the elevated arch and the septum of heredity received a fresh impulse.

Fig. 3 is a reproduction of the doctor's palatine profile. He creditably appreciated the significance of the high-pitched arch, and directed my attention to the peculiar formation of his own. The co-existing deviation of the septum was very well marked, and there were several other interesting features connected with this physician's condition.

I might mention, for instance, the unique occurrence, as far as I know, of a periodical perspiration over a circumscribed area, above the left malar prominence, and around the neighboring portion of the cheek.

There was an extensive *general* deviation of the septum to the left, and it was fair to presume that this peculiar respiratory anomaly was due to prolonged intra-nasal pressure exerted by the deflected structure.

The prompt disappearance of this annoying symptom after removal of the offending tissues confirmed the correctness of this view. The doctor, although a life-long sufferer with nasal catarrh, was so much benefited by surgical treatment as to pronounce himself, in certain respects, a different man. Free nasal respiration through the left nostril was, for the first time in his life, made possible.

The following extract from his family history is of interest as regards the question of heredity: His father, a physician now deceased, was all his life-time annoyed by a persistent coryza and throat trouble. On comparing the

doctor's photograph with an oil-painting of his father, a resemblance in respect to the shape of the nose and forehead

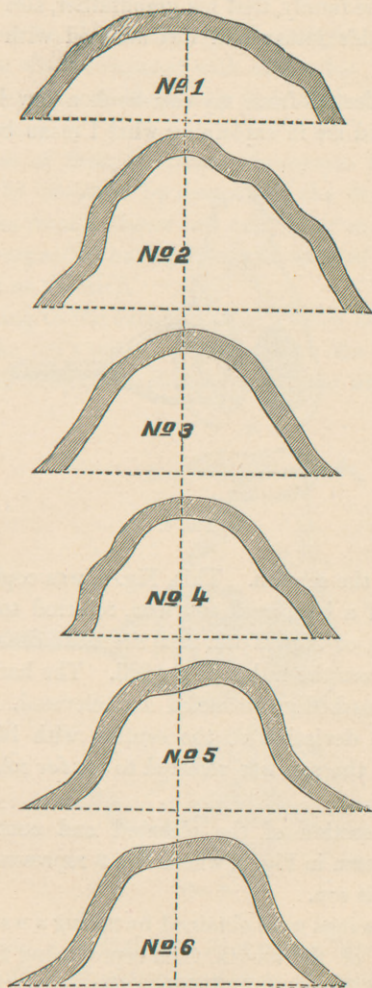


FIG. 3.

is sufficiently well marked to challenge the attention of even a casual observer. Furthermore, I ascertained, from a member of the family, that his grandfather, also a physician, looked like his father and was afflicted with a catarrhal affection.

I have selected from my case-book a few life-sketches, which will aid me in explaining what I mean by hereditary

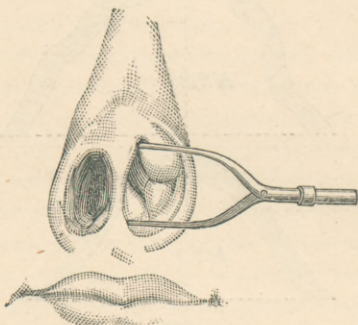


FIG. 4.

deviation of the septum. This, Fig. 4, was copied from the life-sketch of a boy, aged fourteen, referred to me by Dr. A. W. Berle, of New York, and the next drawing, Fig. 5, was taken from the father of the lad. The hard palates of both were markedly contracted and elevated. The father had bilateral deviation of the septum with life-long nasal catarrh, and the son was referred to me for relief from the same trouble.

A cross-section of the elevated and contracted hard palates is shown in Fig. 3, where No. 3 represents the father and No. 4 his son.

These tracings were obtained by taking a wax impression of the roof of the mouth, then reproducing the deformity in plaster of Paris, and dividing the casts thus obtained

with a fine saw, in a transverse direction. The divided fragments were then simply laid upon a piece of paper and outlined.

You may be able to distinguish a slight resemblance in their shape, when compared with each other, this similarity being rendered more distinct by their dissimilarity with the other arches.

An idea of their abnormal divergence from the true type may be obtained by comparing the two arches with No. 1, taken from a plaster cast exhibiting an unusually flattened and expanded hard palate, and selected as an extreme illustration of the kind.

Returning to the sketches (Fig. 4) you observe the cartilage of the son's septum is deviated to the left as a localized nodular projection, almost on a level with the floor of the nose.

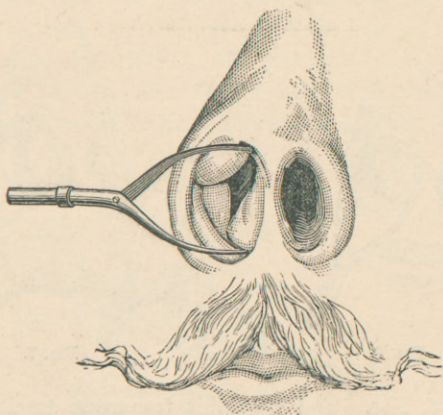


FIG. 5.

The father's septum (Fig. 5) was also thrown to the left, but, in the form of general deviation, situated superiorly in

the nostril, the inferior-anterior edge of the septum being deflected into the right nostril in a manner similar to the son's.

It may be worth noting that when the lad was first brought to me I sought the hereditary origin of his deviated septum in the mother's nose, with a negative result; and yet, unwilling to be adjudged guilty of an erroneous conjecture, I persuaded the mother to induce her husband to visit me, and proved the correctness of my inferences as just described. The removal of the deviated cartilage from the boy's nostril was followed by an excellent result. This drawing (Fig. 6) shows the nose of a son aged twenty-two, and next to it (Fig. 7) that of the father. They are copied from life-sketches. You observe that both septa are *generally* deviated in the same direction. Both were severely afflicted with a life-long coryza.

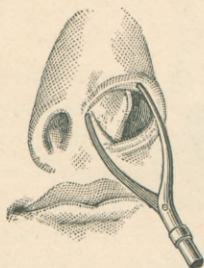


FIG. 6.

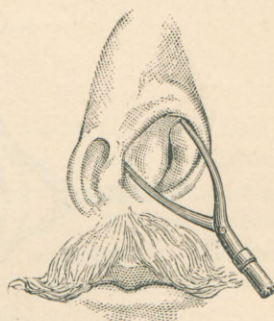


FIG. 7.

Fig. 3, Nos. 5 and 6, exhibit transverse tracings of the father's and son's hard palates in the order mentioned. The point of highest elevation, it will be observed, is toward the nostrils into which the septa were deflected. The father, an old man, had become reconciled to his lot in life, although

the extremely harassing character of his complaint made me marvel at this decision.

His bitter experience had the happy effect of making him alive to his son's life-interests. Directing our attention again to the sketches (Figs. 6 and 7), you observe the cartilage of the septum is conspicuously inclined to the left in both father and son. The father's septum (Fig. 7) exhibits, however, a greater degree of deflection, the respiratory space being reduced to a useless slit.

You may be able to distinguish a similarity in the shape of the external nose. The father, although a sufferer for many years with bronchitis and asthma, might be considered, under the circumstances, tolerably well developed and preserved. The son, on the contrary, also complaining of lung trouble, was stunted in stature, emaciated in appearance, with a haggard face and an unhealthy skin.

I operated upon the young man, removing two antero-inferior turbinated hypertrophies, and shaving off the septum for the whole length of the triangular cartilage, excising also a small portion of the anterior border of the vomer. Fig. 8, taken from a life-sketch, exhibits the left

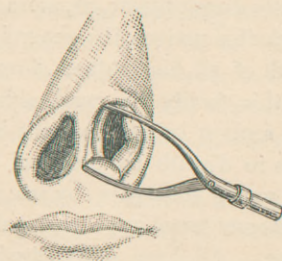


FIG. 8.

nostril after excision of the deviated structures. I employed my transfixion needles and *écraseur* for the removal

of the redundant turbinated tissues, using my fenestrated cartilage forceps, tubular-spring forceps, and rongeur bone scissors for leveling the septum.

The subject of this illustration (Fig. 9) was afflicted with, and cured by me of, an extensive osseo-cartilaginous deviation of the septum. The drawing was taken from a



FIG. 9.

life-sketch, and the history of this individual throws much light upon the origin and growth of the septum of heredity. You may catch my meaning when I inform you that I was enabled to correctly diagnosticate, or, more accurately speaking, infer, through this patient, the general condition of the nostrils and health of all his brothers, four in number, and his father. In this family the nasal asymmetry was very well marked, the septum in one instance being deviated to such an extent as to disturb the external symmetry of the nostril. All the young men seen by me, three in number, possessed the paternal nasal type and palatine arch in an exaggerated form. All have suffered with nasal catarrh dating far back in the memory of the family, and I am informed that the absent son, not yet examined by me, is severely afflicted with the same complaint. The patient, an

engineer by profession and a very intelligent individual, referred to me by Dr. J. L. Corning, stated that a physician informed him that his condition was due to a scrofulous taint, probably inherited from his father. I failed to discover the slightest trace of scrofula in any of these individuals.

The cases I have just cited are not to be considered, as regards their immediate condition, phthysical in character; they have simply been submitted as excellent examples of the influence of heredity as a determining factor in the production of nasal disease, and as such must assist us in interpreting the same conditions when found in phthisis.

The testimony which I have just submitted, re-enforced by much more which I could, but can not now conveniently, offer, affords, to my manner of thinking, excellent proof of the intimate association of a high-pitched hard palate with a deviated septum, and their transmission from parent to child.

The relation of *traumatic deviation of the septum* to nasal catarrh and catarrhal phthisis is not so important as that of the hereditary variety; still it possesses many points of interest did time permit their consideration. Traumatic deviations of the septum, especially in those not predisposed to phthisis, are not likely to be followed by pulmonary tuberculosis. It should be borne in mind that the two conditions may be associated. The differentiation, however, as I shall have occasion to explain, is, as a rule, easily accomplished.

Although the cases of induced coryza just cited by me were of the hypertrophic variety, it should not be inferred that rhinitis atrophica may not be developed by the deviated septum.

Deviations determining the existence of atrophic coryza are *general* in character, and the dryness is evidently due to

the excessive drain upon the mucous follicles resulting from the prolonged passage of air through a single nostril.

As an example of pulmonary phthisis following in the train of a rhinitis atrophica, I may be permitted, in an effort to make my meaning clearer, to precede my report of cases with a brief reference to a patient, aged thirty, treated by me at the University College Dispensary in the winter of 1882.* I found the nasal septum in this individual most extensively deflected, the deviation being osseo-cartilaginous in character. An atrophic rhinitis existed as a result of the nasal disease, both nasal chambers being inordinately enlarged through long-standing atrophic processes. Large and firm masses of muco-purulent matter clung to their smooth walls. These dry crusts were constantly detached and precipitated into the throat, irritating and inflaming the larynx. The patient was harassed and enfeebled by the unremitting efforts required to free his throat and larynx from these suffocating crusts. The atrophic processes had reached the pharynx, where, in the form of a pharyngitis sicca, it presented a dry patch, which obstructed the downward flow of the scanty nasal mucus, collecting it in the shape of sticky incrustations just behind the velum.

A laryngoscopic examination showed the true cords to be deeply injected and the contiguous structures inflamed by reason of the constant irritative action of the nasal incrustations which had found lodgment there.

The patient was extremely emaciated, weak, and miserable through the constant efforts required to free the throat from inspissated irritating discharges. There were night-sweats and the usual symptoms of advanced phthisis. An examination of his lungs, conducted by Dr. Moore, assistant to the Department of Medicine at the University Dispensary, and myself, revealed the existence of advanced

* See also No. I of illustrative cases.

destructive processes, as evidenced by the presence of cavities, a profusion of fine crepitant râles, and other familiar signs of the last stage of a rapidly progressing pulmonary phthisis. It was clear that the patient had reached a point where fatal prostration was imminent, and for an important reason we considered it best to advise him of his hopeless condition. Hoping to delay the fatal issue as much as possible, the patient found it convenient to accept the invitation of relatives in Florida, and so passed from under my observation.

The points of interest to us as regards this case, briefly summed up, are the history of a long-standing nasal catarrh and the manner in which it developed a pulmonary phthisis. That the nasal catarrh preceded the tubercular disease is proved by two features of the affection—namely, a deviated septum, osseo-cartilaginous in character, not associated with external nasal disfigurement, and therefore non-traumatic but hereditary, and a rhinitis atrophica.

Either of these pathological conditions would indicate the chronicity and persistency of the nasal catarrh, and therefore prove that they must have preceded the pulmonary disease; and in this, and in similar cases, we are afforded excellent evidence of the occurrence of the pulmonary lesion as a secondary complication to the catarrhal processes.

I will now direct your attention to the color of the mucous membrane of the upper air-passages as an indication of incipient or developed pulmonary phthisis. The color I refer to is a peculiar anæmic, pink hue, resembling that sometimes observed in hypertrophy of the tonsils. This pallor is by no means confined to the atrophic form of rhinitis, where, as far as the nostril is concerned, it invariably occurs, but exactly opposite to what we might expect is discoverable in rhinitis hypertrophica, where its presence

should naturally lead one to suspect and find the anæmia of pulmonary phthisis. In two of the reported cases appended to this paper the condition was found in connection with a rhinitis hypertrophica; and in another, likewise phthisically inclined, it was associated with an hypertrophic and atrophic process in the same individual. I still favor the view advanced by me several years since, in an article on laryngeal phthisis,* that anæmia of the upper respiratory mucous membranes influences the character of reparative changes, as exhibited, for instance, in the conversion of accidental abrasions in the larynx into phthisical ulcerations. It would seem to indicate diminished vitality or a lowered power of resistance. As an example, I might mention that my experience in operations upon the septum leads me to expect an exceedingly slow reparative process, and one usually requiring assistance in patients presenting marked anæmia of the septal mucous membrane.

In this class of cases, as we might naturally expect, the slight vascularity of the mucous membrane favors the action of the cocaine salts, and they are, in my experience, the only ones in which we can positively promise freedom from pain before operating.

I have selected a few histories from my case-book as good illustrations of the ætiological relations of nasal catarrh to pulmonary phthisis.

CASE I.—Mr. —, engineer, aged thirty, came to me for treatment in October, 1884. His complaint was a long-standing catarrh. The right nostril (Fig. 9) for respiratory purposes was practically useless, and had been so as far back as he could remember. Nasal respiration was, and had always been, carried on through the left nostril. Despite, however, the ease with which air was inspired through

* "Archives of Laryngology," vol. iv, p. 187.

the free nostril, he had never been comfortable, on account of the respiratory obstruction referred to the narrow nostril, and eagerly utilized the smallest amount of space afforded at intervals by the temporary subsidence of the congested turbinated tissues. In addition to the respiratory discomfort, he was annoyed by the accumulation of inspissated mucus in the larger naris, and was wearied by the constant though ineffectual efforts employed to remove the ropy muco-purulent matter and offensive crusts. He was also tormented with the usual throat and laryngeal symptoms which occur as a result of the disturbances to nasal respiration and drainage. The slightest exposure was likely to be followed by obliteration of the insignificant respiratory aperture in the right naris, producing a disagreeable sense of tension in that nostril, evidently arising from the turbinated turgescence. The same exposure sometimes resulted in attacks of lung trouble, occasionally confining him to the house. In appearance he was thin and anæmic, his emaciation carrying with it more the impression of a peculiar build than an unusual or rapid loss of flesh. His appetite, though usually excellent, was capricious, and even at its best was not followed by any noticeable increase in weight.

Examination.—An examination of the nares anteriorly with my nasal speculum revealed the presence of just those conditions which would serve to account for the symptoms complained of. The vomer, ethmoid, and triangular cartilage projected to the right in the form of a *general* and easy incline from above downward. Anteriorly, however, the columna was displaced laterally to the right as an irregular knuckle of cartilage (see Fig. 10). No evidence of disfigurement of the external naris could be observed on ordinary inspection (another indication of the hereditary character of the complaint). An interesting feature observed upon the septum in the left nostril was a vertical elevation near

the ethmo-vomerine suture, caused by the abrupt interruption of the perpendicular plate of the septum at this point. Behind this vertical ridge quantities of glairy or inspissated mucus would collect, and, by reason of the excessive breadth of the inner naris at this point, they would effectually elude the action of the respiratory pressure exerted by the patient to remove them. The turbinated structures and perturbinated mucous membrane was markedly atrophic in the larger or left nostril, but the inferior turbinated tissue in the right or narrow nostril was slightly hypertrophied. Just here we note an instructive example of cause and effect, for, as we might have expected, the life-long inspiration of air through a single nostril—unable, through secretory disturbances, to furnish the necessary amount of moisture—is naturally followed by desiccation and atrophy of the pituitary membrane. The right nostril, on the contrary, being almost completely stenosed, is always bathed in the nasal fluids. In other words, with certain modifications, it is a case of unequal distribution of respiratory labor with the natural consequence, a rhinitis atrophica and hypertrophica occurring in the same individual. The pharynx, larynx, and trachea presented the anæmia of phthisis. The patient's lungs were carefully examined by Dr. W. H. Katzenbach, of the Chest Department of Bellevue Hospital, and myself, and our suspicion was confirmed by the detection of the very early signs of pulmonary phthisis.

An interesting point in the patient's family history related to his brother, a physician, who, several years since, was threatened with a pulmonary phthisis and only escaped with his life by abandoning his labors and by careful treatment and systematic change of climate. It is easy to foresee the probable fate of the subject of this history under unfavorable circumstances, for there is every reason to believe that we have here an individual afflicted from child-

hood with a nasal disease due to a malformed septum, doubtless hereditary in character. I infer the hereditary character of the complaint from the peculiar form of the deviated septum already pointed out, from the fact that the brother and several ancestors of the patient were afflicted with pulmonary phthisis, and for other reasons already given.

Treatment.—Measures were at once employed to relieve the patient of the discomfort occasioned by the accumulation of muco-purulent matter and crusts in the ample interior of the right nostril. This was readily accomplished by thoroughly cleansing the nostril with warm detergent washes, and by the assiduous employment of the cotton probe. The naris, once renovated and relieved of all offending substances, was kept constantly clean by the daily employment of a convenient post-nasal douche, in the use of which the patient acquired much manual dexterity.

To prevent the adherence of nasal crusts to the sinuosities of the nostrils, the membrane was bathed at convenient intervals in a fine spray of vaseline. The douche became part of the patient's daily toilet, and he soon ceased to feel any discomfort except in the right nostril. A sense of oppression from his inability to breathe through this side increased his desire to obtain any relief offered by a surgical remedial measure. I therefore operated with this intent, leveling the deviated structure. This included a portion of the vomer as well as the deflected triangular cartilage. I employed my tubular forceps, fenestrated cartilage forceps, and rongeur or bone forceps. There were two sittings of about an hour each. The use of cocaine upon the patient was particularly satisfactory. A ten-per-cent. solution was applied in the form of a spray, and the parts in two or three minutes were so completely benumbed that bone and carti-

lage were crushed at short intervals without the slightest manifestation of pain. I have noticed a singular obtuseness to pain in other cases in which cocaine has been applied to an anæmic mucous membrane.

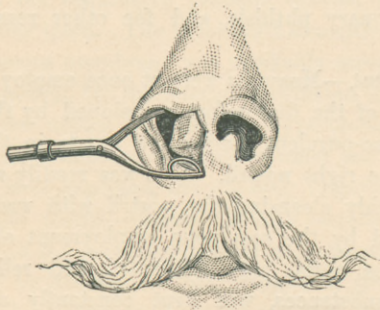


FIG. 10.

Fig. 10, taken from a life-sketch, shows the deviated septum anteriorly, and Fig. 11 the same after operating. Nasal

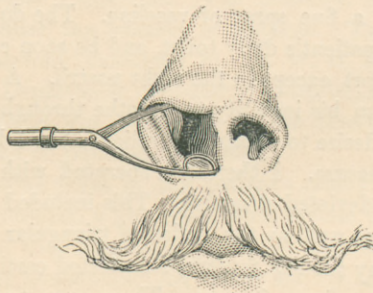

FIG. 11.

respiration was completely re-established through the stenosed nostril, and this and the relief from other catarrhal

complications left the patient in a most excellent condition—almost, in fact, unconscious of his trouble.

He embraced a good opportunity, and is now traveling abroad; on his return he will arrange to spend the winter farther south than New York. Under the favorable conditions afforded by physical ease and a suitable climate the chances of this individual escaping the ravages of tubercular phthisis appear most excellent.

CASE II.—Mr. —, merchant, aged thirty-one, from Owego, N. Y., consulted me in January, 1884. The patient distinctly recollects having suffered with a nasal catarrh seven years ago. Although the affection at that time proved troublesome, still the excellent state of his general health induced him to consider the malady as trifling and transient in character. Small quantities of phlegm were constantly hawked up from behind the palate. There was a disposition to clear the windpipe of particles of viscid matter. At that time and for several years subsequently he plowed the fields as a farmer.

The catarrhal symptoms, instead of disappearing, as he had hoped and expected, became more pronounced and troublesome, and, his stomach becoming incidentally involved, dyspepsia was added to his misery. The prolonged physical and mental discomfort resulting from the persistent catarrhal disturbances ultimately sapped his energy and strength, rendering him unfit to pursue his usual occupations.

Clammy night-sweats commenced last summer, and have continued with varying frequency and severity since then. Becoming alarmed about himself, he was easily induced to seek medical advice.

Prominent among the symptoms given me at the first interview was a cough, which had, however, commenced only about a year ago. Phlegm was expectorated with the

cough, particularly on rising in the morning. The cough, though annoying, was not painful. Six months ago only a pellicle of mucus was raised in coughing. There is now a disposition to draw flakes of mucus from behind the soft palate.

Examination.—General thickening of the nasal mucous membrane, post-inferior turbinated hypertrophy (dextra). The usual inflammatory redness of chronic hypertrophic coryza is replaced by the pale, anæmic hue peculiar to atrophic catarrh. The same pallor occurs upon the mucous membrane of the throat, larynx, and trachea. A livid, circumscribed, inflammatory process is visible upon the edge of the left true vocal cord.

Percussion furnished pronounced dullness over a large extent of the chest. The resonance on the right side was higher pitched than on the left. Auscultation demonstrated the presence of numerous fine crepitant râles diffused throughout the right lung and commencing in the left; also cog-wheel respiration, etc.

The patient, though feeble, was able to exercise in the open air and to visit my office. This, however, was in accordance with his own wish. Indeed, he seemed to dread nothing so much as confinement to the house—a natural feeling for one who has largely led an out-of-door life. The unusually cold and inclement February weather severely tried the patient's feeble powers of endurance, and with the decrease in his appetite and strength there was an increase in the copiousness and frequency of the night-sweats. I foresaw the patient's rapid decline under these unfavorable surroundings. He followed my advice and went South to escape the harsh wintry weather, and possibly to prolong his life a little. On the advent of the warm weather he returned, passing through New York on his way home. I then examined his chest and found that the fine râles had become

generally diffused throughout both lungs. The patient safely reached home and died, near the middle of the summer, surrounded by his family.

Remarks.—The important and instructive features of this case are, first, *the history of a long-standing catarrhal affection* (of at least seven years' duration) *preceding any symptom referable to the lungs.* Although not holding myself in abeyance to the history of patients as given by themselves, still the exceptional intelligence displayed by this individual in relating his symptoms, and their agreement with the local findings, induces me to believe that *the nasal catarrh preceded the pulmonary disease.* In other words, in the combined constitutional depression and pulmonary irritation, resulting from the mental and physical wear and tear, respiratory disturbances, dyspepsia, etc., following in the train of a long-neglected nasal catarrh, we recognize the precursors of a fatal pulmonary tuberculosis. The peculiar blanching of the intra-nasal mucous membrane, and also of the pharynx and larynx, afforded additional evidence of the existence of a pulmonary phthisis secondary to a hypertrophic rhinitis. Such an appearance is just the opposite to what we might expect to find in this affection, and therefore indicates the anæmia of phthisis, for, although the catarrhal hyperæmia had entirely disappeared, its pre-existence is presumable from the presence of the more persistent products, namely, the intra-nasal hypertrophies.

The circumscribed congested area upon the right vocal cord probably resulted from the rasping character of the efforts constantly employed to clear the larynx of irritating mucus. Its very existence constituted an additional source of irritation, and, although not to be designated as an ulcer, it is highly probable that this abraded surface would have eventually proved to be the starting-point of a phthisical

process, in accordance with a pathological process already described by me.*

CASE III.—Mr. —, aged fifty-three, from Ohio, came to me, through the recommendation of his son, a patient referred to me by Dr. M. J. Roberts, of New York, in quest of relief from an annoying nasal catarrh. The malady had existed for many years. Much discomfort was caused by the constant efforts required to remove a constant accumulation of thick, tenacious nasal mucus. Examination of the nostril revealed, among other signs of a rhinitis hypertrophica, the presence of an irregularly shaped posterior turbinated hypertrophy, occupying the right post-nasal fossa. The hypertrophy exhibited no signs of active congestion, but was dark-blue in color, evidently indicating much passive engorgement of the turbinated venous sinuses. The nasal mucous membrane, throughout almost its entire extent, presented the pallid hue of phthisical anæmia. Exploration of the chest demonstrated the existence of catarrhal phthisis, most markedly developed at the apex of the right lung.

Believing the posterior hypertrophy to be responsible for much of the patient's discomfort, I concluded it best to remove this source of irritation. I employed my nasal *écraseur*, easily encircling the hypertrophied tissue with a loop of No. 5 piano-wire. As might naturally be anticipated from the blanched appearance of the pituitary membrane, the operation was a bloodless one. The patient pronounced himself much benefited by the operation and after-treatment, and returned to his home well satisfied. This was in January, 1881. In July, 1882, I was informed that he had caught cold and was carried off by an attack of pneumonia, thus confirming my suspicions that his pulmonary phthisis would eventually lead to his death.

* "Archives of Laryngology," vol. iv, p. 187.

The son of the deceased, a man about thirty years of age, had, as I have already indicated, consulted me for relief from a chronic coryza. The coryza, I discovered, was due to an hereditary malformation of the septum and nasal chamber. I succeeded in rendering him comparatively free from his complaint by removing the offending deviation of the septum. He has enjoyed excellent health ever since. It was interesting and instructive to note the close resemblance between the forehead and face of the father and son. The frontal prominences of both projected so far forward as to place the forehead almost on a vertical plane with the face. The face beneath the overhanging forehead appeared unnaturally narrow, affording an example of Blumenbach's observation of the marked retrocession and contraction of the bones of the face in individuals exhibiting great cranial development.

The father was an intelligent man, and his son, utilizing excellent educational opportunities, developed unusual literary ability as the editor of a journal. The youngest, and only other son of the family, about whom I was consulted but never saw, I am informed possessed a rare degree of intelligence, and have a right to suspect that he possessed the cranial conformation of his father and brother.

A few days ago I was informed that this son had just fallen a victim to consumption. Despite the discouraging family history of the surviving son, I feel confident that *timely* treatment and care have sufficiently removed the impress of his unfortunate inheritance to enable him to live out his natural life.

Here, then, we have the mournful picture of a father, afflicted with a life-long catarrhal malady, eventually perishing with pulmonary tuberculosis, his eldest son harassed by a nasal catarrh traceable to a deviated septum, and an-

other son, a young man, dying two years after the father with the same disease.

I might add other illustrations to the foregoing cases did not the typical character of those just reported make this unnecessary.

Treatment.—The treatment of these and similar cases is essentially one aimed at the direct cause of the disease—namely, the deviated septum and co-existing turbinated hypertrophies. It largely consists in the restoration of nasal symmetry by methods which facilitate the excision of bone and cartilage, and the removal of intra-nasal redundancies. A variety of instruments are therefore required, their character being determined by the density and situation of the offending structures. My regular office operating-set consists of my wire-snare nasal écraseur, and transfixion-needles for removing soft redundancies; a fenestrated cartilage forceps, tubular-spring forceps, beaked scissors, and trimming scissors for excising cartilage; and my rongeur forceps for cutting through bone. Nearly all the operations indicated by these instruments are, through the benumbing influence of cocaine and rhigolene anæsthesia, rendered bloodless and painless. Most of you are acquainted with my methods of operating, and, inasmuch as more than a mere reference to them would exceed the limits and not accord with the purpose of this paper, I must refer those ignorant of these procedures to my earlier publications.

Appropriate treatment should also be instituted to heal and contract the raw surfaces, to remove and prevent the reformation of nasal crusts in the atrophic forms of the disease, and to check excessive discharges of nasal mucus. In other words, to borrow an expression from Niemeyer, "Where there is the slightest suspicion of a predisposition to consumption, every catarrh, no matter how slight, is to

be treated with the utmost care, which is not to be relaxed until the catarrh is entirely well."

Conclusions.—Briefly reviewing the subject-matter I have just presented, you will observe that, in determining the relations of nasal catarrh to pulmonary phthisis, I have, in the order of its origin and sequence, commenced by observing and interpreting the catarrhal manifestations as they occur in the nares, and have traced the gradual extension of the nasal disease to the larynx.

Within the larynx we discovered the catarrhal impress in the form of a chronic irritative hyperæmia of the larynx, brought about by the combined action of nasal discharges, habitual mouth-breathing, and inflammatory changes, chronic catarrhal hyperæmia of the larynx; to go a step further, oftentimes merges into an acute laryngitis, and this in turn may develop bronchitis. We recognize the deviated septum as a most common cause of nasal catarrh, producing this disease by pressure irritation, interference with nasal drainage, and unequal distribution of the nasal respiratory function. We have seen the importance of heredity as a factor responsible for the existence of certain forms of deviated septa, and noted the conditions indicating the hereditary character of these abnormalities.

Viewing the larynx as really the upper portion of the lung, although divorced from it on artificial anatomical grounds, we are often enabled to determine approximately, by the appearance of the laryngeal and tracheal mucous membrane, what conditions may exist beyond the line of laryngoscopic vision, and thus complete our pathological picture, beginning in the nares and ending in the lungs.

It is hardly necessary for me to insist upon the value of the lessons to be derived from the early recognition of the clinical facts I have just presented. They at least offer something tangible as regards prophylaxis against phthisis

or tuberculosis, for their successful treatment falls in the positive domain of surgery. The results are for the most part favorable and speak for themselves, provided the methods which I have proposed and published for removing redundancies or the remedying of defects are not commenced too late.

It is hardly necessary for me to add that great care should be exercised to properly discriminate between cases in which pulmonary phthisis or tuberculosis precedes or exists with nasal catarrh, and are, therefore, not related to the last mentioned affection as cause and effect, and those developed by a catarrhal affection. Being mindful of this, I have felt the necessity of sometimes giving details which were indispensable but which may have been wearisome. It must also be borne in mind that errors are likely to creep in from difficulty or carelessness in differentiating distortions of the septum resulting from injury from those dependent upon heredity. My experience, however, encourages me to state that, different from what you might probably imagine, in most instances, such a distinction, when properly made, constitutes a simple question of differential diagnosis. I have already referred to some of the rules which facilitate the recognition of the septum of heredity; and, were it advisable just here, I could mention other criteria of equal value. It is obvious that, in treating a subject of this kind, many questions present themselves, the proper interpretation of which must, for the present at least, baffle scientific investigation — such, for instance, as the proneness of some families with malformed septa to phthisis or tuberculosis, while others, on the contrary, are afflicted with annoying sthenic but, as far as the life of the individual is concerned, harmless pulmonary maladies. These, among similar speculations, though perhaps partly explainable by ingenious hypothetical methods, must, nevertheless,

for want of sufficient demonstrative and experimental evidence, prove for the most part unintelligible. But even in the contemplation of such obscure problems the earnest investigator may derive encouragement from Prof. Huxley's remark, that "whatever may be men's speculative doctrines, it is quite certain that the order of nature is constant, and that the chain of natural causation is never broken."

25 EAST THIRTY-FIRST STREET, N. Y.



The New York Medical Journal,

A WEEKLY REVIEW OF MEDICINE.

PUBLISHED BY
D. Appleton & Co.



EDITED BY
Frank P. Foster,
M. D.

THE NEW YORK MEDICAL JOURNAL, now in the twenty-first year of its publication, is published every Saturday, each number containing twenty-eight large, double-columned pages of reading-matter. By reason of the condensed form in which the matter is arranged, it contains more reading-matter than any other journal of its class in the United States. It is also more freely illustrated, and its illustrations are generally better executed, than is the case with other weekly journals.

It has a large circulation in all parts of the country, and it is largely on this account that it is enabled to obtain a high class of contributed articles, for authors know that through its columns they address the better part of the profession; a consideration which has not escaped the notice of advertisers, as shown by its increasing advertising patronage.

The special departments of the JOURNAL are as follows:

- LECTURES.**—The frequent publication of material of this sort is a prominent feature, and pains are taken to choose such as will prove valuable to the reader.
- ORIGINAL COMMUNICATIONS.**—In accepting articles of that class, regard is had more particularly to the wants of the general practitioner, and all the special branches of medicine are duly represented.
- BOOK NOTICES.**—Current publications are noticed in a spirit of fairness, and with the sole view of giving information to the reader.
- CLINICAL REPORTS** are also a regular feature of the Journal, embracing clinical records from the various hospitals and clinics, not only of New York, but of various other cities, together with clinical contributions from private practice.
- EDITORIAL ARTICLES** are numerous and carefully written, and we are able to give timely consideration to passing events.
- MINOR PARAGRAPHS.**—Under this heading are given short comments and notes on passing events.
- NEWS ITEMS** contain the latest news of interest to the profession.
- OBITUARY NOTES** announce the deaths which occur in the ranks of the profession, with a brief history of each individual when practicable.
- SOCIETY PROCEEDINGS** are given promptly, and those of a great number of societies figure. At the same time we select for publication only such as we think profitable to our readers.
- REPORTS ON THE PROGRESS OF MEDICINE** constitute a feature of the Journal which we have reason to think is highly valued by our readers.
- MISCELLANY** includes matter of general interest, and space is also given for **NEW INVENTIONS** and **LETTERS TO THE EDITOR**.

As a whole, we are warranted in saying that the NEW YORK MEDICAL JOURNAL is regarded with the highest favor by its readers and by its contemporaries.

Subscription price, \$5.00 per annum.

