

GARDNER (W.)

A YEAR'S WORK

IN



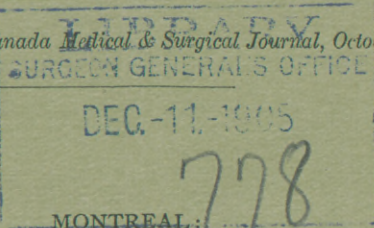
ABDOMINAL SURGERY.

BY

WILLIAM GARDNER, M.D.,

PROFESSOR OF GYNÆCOLOGY, MCGILL UNIVERSITY; GYNÆCOLOGIST TO THE
MONTREAL GENERAL HOSPITAL; ONE OF THE VICE-PRESIDENTS OF THE
BRITISH GYNÆCOLOGICAL SOCIETY.

Reprinted from the Canada Medical & Surgical Journal, October, 1887.



GAZETTE PRINTING COMPANY.

1887.

A YEAR'S WORK IN ABDOMINAL SURGERY.*

BY WILLIAM GARDNER, M.D.,

Professor of Gynæcology, McGill University; Gynæcologist to the Montreal General Hospital; one of the Vice-Presidents of the British Gynæcological Society.

Mr. President and Gentlemen—During the last working year I have opened the peritoneal cavity 38 times. Of these 35 were abdominal sections, the others were total vaginal extirpations of the uterus, and I have included them in the list because the important element of peritoneal section obtains equally in them with the abdominal cases proper. The list I submit includes an unusual variety of cases and conditions, and I venture to think that its recital may be of some interest and furnish material for a useful discussion. Every operation was done in a private hospital, with the most scrupulous attention to cleanliness of the hands of operator, assistants and nurses; and of instruments, sponges and ligatures, but without the use of any antiseptic whatever except to the field of operation—abdominal wall or cavity of the vagina,—where a 1-1000 sublimate solution was always freely used after thorough scrubbing of the part with soap and water. The after-treatment was entirely under my own watching and control, a circumstance to which I attribute great importance in determining the results obtained. The following is a brief classification of the cases with results:

		<i>Recoveries.</i>	<i>Deaths.</i>
Ovariectomies	16	16	—
Hysterectomies	2	2	—
Removals of Uterine Appendages	11	10	1
Abdominal section for opening Pelvic Abscess	2	2	—
Puerperal Peritonitis	2	—	2
Abdominal section for			
Retro-Peritoneal Cyst.....	1	1	—
Exploratory Operations.....	3	2	1
Total Vaginal Extirpation of Uterus	3	3	—

Of the ovariectomies several were of exceptional interest. In

* Read in abstract before the annual meeting of the Canadian Medical Association, at Hamilton, Sept. 1st, 1887.

two there was twisting of the pedicle, giving rise in both to violent pain, and in one of them to severe peritonitis. In the latter case, a patient of my friend Dr. Molson, the pedicle was twisted three times; the walls of the cyst, a dermoid, were almost black; adhesions were universal; the second ovary being enlarged and cystic, was also removed; the cavity was washed out and a drainage-tube employed for five days. The uterus was found to be somewhat enlarged, soft and vascular. A suspicion of possible pregnancy flashed across my mind, but the idea was not seriously entertained at the time of the operation. The patient recovered without a bad symptom. Three months afterwards I had an opportunity of examining her, and found her undoubtedly pregnant to about five months, gestation persisting in spite of the rotation of the tumor, with strangulation and consequent severe peritonitis, a double ovariectomy with washing out and drainage, the glass drainage-tube lying behind the uterus and in contact with its posterior wall for five days. This is my second ovariectomy during pregnancy; the first also recovered without a symptom worthy of note. The patient was delivered at full term just six months after the operation. Both mother and child are alive and well to-day.*

The other twisted pedicle case was sent to me by Dr. Vaux of Brockville, and was that of an unmarried woman of 25. She had for several weeks suffered severe pain, unrelieved by morphia in full doses. The twisted pedicle was enormously thickened from œdema the result of obstructed circulation, and the cyst wall much discolored; there were papillomatous growths from its interior, and hemorrhage into its cavity. Recovery was rapid and complete.

In both cases the tumors were small, as is usual in axial rotation, and they are good examples of the many untoward accidents to which all ovarian tumors are liable, and furnish strong arguments in favor of the plea for early ovariectomy.

Another of the series was in a hale old lady of 68, whose recovery from the conditions incidental to the operation was absolutely without any event worthy of note, except slight cys-

* See Canada Lancet, February, 1887.

titis, but who on the second day developed pleurisy, which soon became double, with most alarming symptoms. The pulse rose to 180, and was irregular and unequal. She ultimately made a perfect recovery.

In two of the cases the tumors were sarcoma, one being sarcomatous degeneration of a dermoid cyst. In both there were adhesions to intestine and every other structure within reach. In both, washing out and drainage were resorted to. They were desperately severe operations, but both recovered. In one the curious symptom of polyuria developed in the third week, and for several days six to seven pints of urine were secreted. There was great thirst and enormous appetite. These symptoms had completely disappeared before the patient was discharged.

In one case—an enormous tumor—the patient had a successful pregnancy and uneventful delivery at full term, after the tumor had attained considerable size, and she had been tapped four times, once at the interval of a fortnight before her confinement.

In nine of the sixteen cases the condition of the second ovary was such as in my opinion to demand its removal. Such conditions were marked enlargement and cystic disease. The question of the necessity of removing the second ovary under these circumstances has given me some anxiety in young subjects, as it seems to me it must to every conscientious surgeon. So far as I know there is no known method by which to diagnose on the operating-table a condition comparatively harmless, and which may not prevent successful ovulation and conception from one which is the commencement of a disease that must ultimately demand operation. It is quite certain that all slightly enlarged and cystic ovaries are not commencing ovarian tumors. In a woman who has already attained or is nearing the menopause, the second ovary when in such a condition, or, according to some surgeons, even when apparently perfectly healthy, must always be removed, knowing as we do its proneness to the disease which has required operation for the first. But it is far otherwise in the young woman, married or not, from whom by a double ovariectomy, it may be, needless, all possibility of realiza-

tion of the much cherished hope of maternity is for ever removed. I confess that for myself the question is as yet unsolved. All recently published experience is quite in accord with my own that the double operation does not in the least add to the dangers. It may be remembered that Sir Spencer Wells' statistics seemed to indicate an opposite conclusion.

The operation of removal of the appendages is one, now-a-days, of even more interest than ovariectomy, because more recent and inasmuch as it involves certain questions not yet quite solved to the satisfaction of everybody. I can honestly say that some of my cases have given me more satisfaction than anything else in my work during this last, as in former years of my work. The list comprises examples of almost all the conditions for which the operation is ever necessary. Such were pyosalpinx, hæmato-salpinx, pelvic hæmatocele, enlarged and cystic ovaries, and cirrhotic very small ovaries, with and without adhesions from previous pelvic peritonitis. Some have been restored in a few weeks from a life of more or less complete invalidism to health, activity and usefulness. Others have been slow in recovering from the operation, because of secondary inflammation about the pedicle. In others still, nothing could have been more favorable than the after course *quoad* the operation, but the morbid condition of nerve centres which is in some the result of long-continued suffering and habits of invalidism continued for several months to manifest itself in the persistence of pain in the regions whence the diseased appendages were removed, or in some distant reflex symptom, most commonly headache. The single death of the series was from hemorrhage, and it is the only death in the list of which I have any reason to be ashamed, as it might have been prevented if I had been called to the patient in time. As it was, I reached her bedside nine hours after the operation, when she was moribund. The peritoneum was found full of blood, but the ligatures held fast. The exact source of the blood flow was not found, but it was doubtless either a rent of some part of the broad ligaments or one of the suture needle punctures. The operation was a perfectly simple one for cystic ovaries without any adhesions whatever. Some of the operations were the most difficult I have ever had to

encounter, by far more difficult than any but the most difficult ovariectomies, and I think that without washing out and the drainage-tube some of them had scarcely a chance of recovery. It is in such cases, perhaps, more than in any other in the whole range of abdominal surgery that the value of experience becomes apparent in the separation of adhesions and recognition by touch of the educated finger of the parts which must be removed. This all important part of the operation must be done solely by the sense of touch, and in some of my cases the whole operation was done through an inch-and-a-half incision.

Of the miscellaneous cases, the following one of exploratory incision is of exceptional interest: A tumor-like mass of doubtful nature remained after the symptoms of a severe attack of peritonitis in a delicate girl of 30, had subsided. The patient continued to vomit and suffer from great pain and difficulty in defecation. She was much emaciated. On opening the abdomen the peritoneum was found studded in numerous places with tubercle. This was verified by microscopic examination of a portion removed. The mass described was found to consist of the small intestine densely matted together in its own coils and adherent to everything around. The mass was somewhat separated from its surroundings, returned, and the abdominal opening closed, with a drainage-tube in the pelvis. She recovered easily and rapidly from the operation, and for a time was much relieved of her symptoms. For a few weeks she was able to dispense with morphia, which she had taken daily up to the time of operation, and the bowels acted spontaneously and without pain. She survived the operation six weeks, dying of exhaustion. This is my second case of tubercular peritonitis simulating ovarian tumor. The other case will be found recorded in the CANADA MEDICAL AND SURGICAL JOURNAL for June 1885.

In the two puerperal cases the patients were almost *in extremis* and the operations were done as a last resort, but without avail in influencing the symptoms. In both the abdominal cavity was opened, washed out, and a drainage-tube inserted. The conditions found were those of intense general peritonitis, with copious exudations of lymph and pus, and infiltration of ovaries,

tubes and cellular tissue with inflammatory exudation. In neither was there any encysted collection of the products of inflammatory action or evidence of disease in or about the appendages from which the general peritonitis might have started. In one of the cases there had been persistent right iliac pain during the pregnancy, and the symptoms of the fatal illness began by an aggravation of this pain. These facts justified Dr. George Ross and myself in opening the peritoneum in the hope that some condition within the power of surgery to relieve might be found. Puerperal fever was, however, prevailing, and the result of the exploration confirmed the idea that these cases were of septic character. Both patients died within twelve hours of the time of operation, but in neither was death in the least hastened by the operation, so far as an opinion could be formed from the symptoms present when the operation was undertaken, and in one the agonizing pain was at once relieved, an effect which morphia had failed to produce.

The results of exploratory abdominal section for peritonitis, a very recent development, have already proved beyond doubt that many lives may be saved by an operation which in competent hands does not in the least lessen the patient's chances. That peritonitis in the lying-in woman not rarely is of a character and has such an origin that we can occasionally thus save a life has already been amply demonstrated by the experience of Lawson Tait and John W. Taylor of Birmingham, and others. One of Mr. Tait's successful cases I had the good fortune to see and assist at during my stay with him last summer. The kind of case in which we have the best reasons to anticipate success are those of previously existing, perhaps latent disease of ovaries or tubes, such as abscess of the ovary or pyosalpingitis, roused to activity by the process of parturition, and leading, it may be, to general peritonitis. That such conditions not rarely exist was shown by Dr. Grigg, of the Queen Charlotte Lying-in Hospital, in a paper read before the British Gynæcological Society, based on the conditions found in certain autopsies. Other conditions in which the operation is indicated are encysted collections of the products of inflammation in the peritoneum or pelvic cellular tissue. I

believe the time has come when it may with perfect justice be said that in a suitable case of puerperal, pelvic or peritoneal inflammation in which life is threatened, the practitioner is bound to do the operation or have it done for him, and so will save the valuable life of many a wife and mother.

The two hysterectomies recovered, both without any bad symptom. In both I adopted, as in all my previous hysterectomies, the extra-peritoneal method of dealing with the pedicle, clamping it with Koeberle's serre-nœud. It is possible, and much to be desired, that "a more excellent way" (as Keith has it) may yet be devised, but that it has not yet been attained is amply proved by a comparison of the experience of Keith, Bantock and Tait by the extra-peritoneal method, with the published results of Schröder and Martin in Germany by the intra-peritoneal method. If ever induced to try the latter method, I shall certainly combine it with drainage of the Douglas' pouch through the vagina after Martin's method.

In 19 of the 35 abdominal sections the drainage-tube was used. It was employed in all cases where adhesions were extensive and oozing surfaces remained, and when washing out was resorted to. In the latter case much sponging to remove the water used was thereby saved, as it was sucked out through the drainage-tube. Of all improvements in the technique of abdominal surgery next to the intra-peritoneal ligature, none has so much conduced to success as the use of the drainage-tube. By its employment operations may often be much shortened and the peritoneum saved much labor in the absorption of effused blood, and the patient's chances of recovery correspondingly increased.

Experience in the use of the drainage-tube is an important factor in the amount of good to be gained by it. In the experience of other surgeons I had learnt much as to the kind of case in which to use a drainage-tube, but not much as to the length of time it must be allowed to remain in the wound. I had never seen any definite rules on this point laid down till I read the remarks of my friend Dr. Bantock in his paper on "A Hundred Cases of Abdominal Section" published in the London *Lancet* a few months ago. It is possible to remove the drainage-tube much too soon, and I am sure I have seen ill results in my own

practice from this. Since reading Dr. Bantock's paper I have followed his instructions on this point, and with, I believe, signal advantage. These are, in the main, to the effect that the drainage-tube ought not to be removed till the whole amount of secretion that can be removed from it in twenty-four hours does not exceed one drachm of amber-colored serum.

Next to improvements in the technique of abdominal surgery the after-treatment of cases is of prime importance as affecting the patient's prospects. When in Europe last year I found that Mr. Lawson Tait and Dr. Bantock held very strong opinions on certain questions connected with the management of such cases after operation. One of the principal points on which they agreed is the advantage of the avoidance of opium entirely. During the last twelve months I have uniformly followed this example with the exception of one or two instances, and a comparison with my previous experience has thoroughly convinced me that they are right. As a rule, the pain after an abdominal section is mainly at the needle punctures of the abdominal wall, and almost invariably ceases in twelve hours. A dose of opium or morphia will, it is true, relieve the pain, but it dries the secretions, makes the patient clamorous for drink which it is so important that she should avoid for thirty-six hours, it quiets the bowels and so favors accumulation of flatus, and distension, whereas it is all-important that the peristaltic action of the intestines should be kept up, not only to carry off flatus, but to prevent adhesion of coils of intestine to the pedicle, to raw surfaces whence adhesions have been separated, or to the inner aspect of the abdominal wound, which may lead to obstruction. It is more than probable that most of the deaths after abdominal section attributed to peritonitis in recent years have been due to obstruction.

In my work during the year I have given no opium, and invariably, immediately on the appearance of distension, pain or vomiting, I have given enemata and purgatives with the most signal advantage. I am convinced that in my own experience I have thus seen lives saved, besides a vast diminution of the trouble and difficulty in managing the cases afterwards.

I append the following table of the ovariectomies included in the series :—

OVARIOTOMIES.

NAME, &c.	ORDINARY ATTENDANT.	HISTORY AND SYMPTOMS.	LOCAL CONDITIONS.	OPERATION.	RECOVERED OR DIED.	SUBSEQUENT HISTORY.
E. T., aged 31, unmarried.	Dr. Bingham, Williston, Vt., U.S.A.	Menses began at 14; always regular. General health good. First noticed enlargement $3\frac{1}{2}$ years before operation.	General abdominal enlargement; wave fluctuation, bulging in flanks, flat in front; bowel note not distinct in flanks; girth 36 in.; uterus retroverted, prolapsed, and slightly mobile.	Two and a-half inch incision; no adhesions; parovarian cyst right side, limpid fluid, favorable pedicle; ovary and tube spread out over cyst wall; operation complete in 25 minutes.	Recovered.	Perfect health.
M. B., aged 60, married.	Dr. Hill, Ottawa.	Mother of several children. Menopause many years ago. General health perfect. No symptoms, but tumor first noticed $1\frac{1}{2}$ years ago.	Fluctuation in areas; great enlargement; no tenderness; uterus pushed forward, lying behind pubes.	Multilocular ovarian cystoma; few slight anterior adhesions; tumor is of right side. Severe attack of double pleurisy with rapid pulse, reaching 180, rapidly reduced by digitalis; rapid recovery.	Recovered.	Slight cystitis for a few weeks; two months after operation, a smooth, tender swelling in region of pedicle slowly disappeared. Otherwise well.
M. C., aged 51, married.	Referred by Dr. R. P. Howard, Montreal.	Menses began at 17; married 30 years; one child 25 years ago; menses ceased eight months ago. Pain in left lumbar region and first signs of tumor one year ago, rapid growth; three months before operation measured 42 inches. Was tapped, 24 gallons removed, in Burlington, Vt.	Fluctuating tumor; clear note in flanks; no firm areas; 35 $\frac{1}{2}$ in.; uterus retroverted; movable $3\frac{1}{2}$ inches by sound.	Unilocular cyst of left ovary; no adhesions; very broad pedicle; ligatured in sections; a small dermoid cyst attached to base of large tumor.	Recovered.	Perfectly well.

OVARIOTOMIES—(Continued.)

NAME, &C.	ORDINARY ATTENDANT.	HISTORY AND SYMPTOMS.	LOCAL CONDITIONS.	OPERATION.	RECOVERED OR DIED.	SUBSEQUENT HISTORY.
C. M., aged 53, unmarried.	Dr. James Bell, Montreal.	Menses began at 12; ceased four years ago. Never pregnant. Is much emaciated and sallow; severe abdominal pain, rectal tenesmus and pain. Six months ago first noticed lump in left iliac region. Steady increase of size, with pain. Full doses of morphia for six weeks.	Nodulated, firm tumor springing from left side, extending from pubes to within 2 inches of lower ribs; in parts elastic feel; uterus moveable; marked induration in posterior vaginal septum; girth of abdomen 34 inches.	No adhesions; favorable pedicle; multilocular cyst of left ovary, jelly-like contents. In Douglas' pouch the induration felt, evidently malignant disease of the rectum.	Recovered.	Recovery from operation rapid and perfect; great relief from pain; no morphia needed for some weeks. Died three months after from cancer of rectum.
M. B., aged 29, married.	Dr. M. C. McGannon, Brockville, Ont.	Menses began at 11; always regular, profuse. Married three years; one child 22 months ago. First noticed tumor in left iliac region 12 months ago, steadily increasing; dysuria last 18 months.	Abdomen enlarged, 32½ inches; uneven fluctuating areas; uterus retroverted, prolapsed and moveable.	Multilocular cystoma of left ovary; omental adhesions, grumous contents; favorable pedicle. Three ligatures to omentum; right ovary size of hen's egg and cystic, also removed.	Recovered.	Perfect health.
M. I., aged 39, married.	W. G.	Menses began at 15. Married 14 years; five pregnancies, last 11 months ago. Menses now regular. First noticed tumor Sept. 1884, on left side. Tapped four times, once during last pregnancy two weeks before labor.	Abdomen very large, 45½ inches, uneven, fluctuating over large areas; edema of hypogastrium; uterus retroverted, prolapsed, and moveable.	Large quantity peritoneal fluid; multilocular cystoma left ovary; omental adhesions; favorable pedicle; right ovary cystic and enlarged, also removed.	Recovered.	Perfect health.
H. S., aged 30, married.	Dr. Beckstead, Lisbon Centre, N. Y.	Menses began at 16; at first scanty, of late profuse and protracted leucorrhœa; pain in hips. Never pregnant. In Jan. '85, diagnosed a pelvic ovarian tumor. No abdominal enlargement till Jan. '87. Rapid enlargement.	Elastic, uneven condition of abdomen, 35 in., fluctuates in areas. Uterus retroverted; sensitive, moveable; body felt in Douglas' pouch; tapped two months before operation.	Multilocular cystoma left ovary; no adhesions; favorable pedicle; right ovary size of pullet's egg and cystic, also removed.	Recovered.	Perfect health.

<p>J. B., aged 18, married.</p>	<p>Dr. Ball, Stanstead, P. Q.</p>	<p>Menses began at 11; always regular. Married two years, never pregnant. Noticed enlargement four months after marriage. A good deal of pain during last year. Twice tapped during last three months.</p>	<p>Uniform enlargement; general fluctuation; distinct wave. Uterus retroverted, prolapsed. Tumor distinct in pelvis; girth 4½ inches.</p>	<p>Multilocular cystoma of left ovary; universal anterior parietal adhesions. Three ligatures to bleeding points; drainage-tube.</p>	<p>Recovered. Perfect health.</p>
<p>M. C., aged 25, unmarried.</p>	<p>Dr. Yanx, Brockville.</p>	<p>Menses began at 17; is quite regular. Good health till two years ago, then began to have occasional attacks of severe pain in right iliac region; this pain almost constant last five months; three months ago tumor first noticed in right iliac region; pain at times very severe, not relieved by morphia; girth 25½ inches.</p>	<p>Tumor is tense, elastic, insensitive, moveable, entirely below umbilicus; uterus ante-flexed, pressed down in front of tumor.</p>	<p>No adhesions; cyst wall dark colored; pedicle twisted very thick and cedematous, size of adult's head; contents chocolate-colored fluid; papillomatous growths from interior of cyst, which is unilocular, and of right ovary; left ovary a mass of cysts and of size of pullet's egg, also removed; oozing from pelvis; drainage-tube.</p>	<p>Recovered. Perfect health.</p>
<p>M. D., aged 20, married.</p>	<p>Dr. James Bell, Montreal.</p>	<p>Menses began at 13. One child 1 year old; suckled ten months. Menses returned at six months; regular till seven weeks before operation. First noticed a lump in right iliac region 8½ months ago; steady growth; much pain, irritation of bladder, constipation, pain and difficulty in defecation; great wasting, weakness; pulse 90-100; in bed for 2 months.</p>	<p>Irregular, nodular, sensitive tumor extending up right side of abdomen from pelvis to hypochondrium, very slightly moveable; in places elastic, semi-fluctuating; floor of pelvis indurated; os uteri pushed forwards and to right side; portio-vaginalis obliterated by collar-like induration around it.</p>	<p>Desperately severe operation; adhesions to intestines, omentum and to whole of pelvis; lower part of tumor a friable mass, in which neither ovary nor fundus of the uterus is distinguishable. After enucleation of tumor, the operation finished by clamping cervix uteri and bringing it out at lower angle of abdominal incision. The tumor, a sarcoma with dermoid elements. Washing out and drainage.</p>	<p>Recovered. Recovery was fairly rapid, interrupted by septic fever for a few days. In third week polyuria, 6 to 7 pints urine daily; great thirst; enormous appetite. Returned home 6 weeks after operation; general conditions excellent; 2 months later signs of recurrence; a month later much emaciated, sinking fast; recurrence of growth, fecal fistula at lower end of abdominal incision; is dying.</p>

OVARIOTOMIES—(Continued.)

NAME, &c.	ORDINARY ATTENDANT.	HISTORY AND SYMPTOMS.	LOCAL CONDITIONS.	OPERATION.	RECOVERED OR DIED.	SUBSEQUENT HISTORY.
Mrs. S., aged 31, married.	Dr. Molson, Montreal.	Began to menstruate at 19. Married eight years; four pregnancies to full term, last 14 months ago, suckled 10 months; menses returned after weaning; four months ago first noticed a lump in left iliac region; three weeks ago, after a walk, sudden severe pain, vomiting, fever, retention of urine, constipation; full doses of morphia up till time of operation.	A thin-walled, fluctuating cyst size of a child's head, quite tender; uterus fixed, retroverted, quite tender.	Parietal, pelvic and omentum adhesions; a dermoid cyst of left ovary; long, slender pedicle, twisted three times round its axis; contents creamy, coagulate solid; cyst wall dark-colored; cyst wall teeth, hair and bone, hair almost black; right ovary enlarged; cyste, also removed; wash out, drainage; uterus somewhat enlarged, soft, and of dark-red color.	Recovered.	Three and a half months later, seen and examined; is undoubtedly pregnant; 26th Aug., 1887, daily expecting confinement at full term.
M. G., aged 38, married.	Dr. Molson, Montreal.	Married 13 years; before marriage menses irregular, last three years profuse, especially last six months.	Anæmic, fat, weak person; flowing continuously; pains in hips, left leg and thigh. The veins of left leg and thigh distended, varicose; during last six months moderate enlargement of abdomen; feels solid thro' the thick rigid parietes; uterus fixed.	Abdominal wall thick, 1½ inches fat; right omentum adherent to lower parts of parietes; a cyst on either side, with broad attachment, containing clear amber-colored fluid with cholesteroline crystals. Cysts freely opened but not removed on account of broad attachment and nature of contents; ovaries not distinguishable; washing out, drainage.	Recovered.	Recovery was tedious, but seemed to be complete, when (slowly and with severe pain) an abscess developed in right iliac region. Opened by abdominal section. Complete recovery.

M. V., aged 33, married.	Dr. Geo. Ross, Montreal.	<p>Began to menstruate at 11; married 9 years; five pregnancies, last 20 months ago; suckled 15 months. Menses regular last five months; noticed enlargement four months ago; rapid increase for one month, then very slow; slight abdominal pain; losing flesh.</p>	<p>Uniform, fluctuating enlargement, 38$\frac{1}{2}$ in.; firm areas and trabeculae; uterus retroverted, fixed.</p>	<p>Multilocular cystoma of left ovary; anterior adhesions; adhesion of rectum to pedicle, pedicle broad; ligatured in sections; right ovary enlarged and cystic, removed; wash out and drain.</p>	Recovered. Perfect health.
N. C., aged 22, unmarried.	Dr. J. Stephenson, Iroquois, Ont.	<p>Menses regular, profuse; began at 16. Noticed enlargement 10 months ago; rapid increase. General health perfect.</p>	<p>Uneven enlargement of abdomen; fluctuation in areas; uterus retroverted, lies on floor of pelvis.</p>	<p>Multilocular cystoma of left ovary; no adhesions, favorable pedicle; right ovary cystic, enlarged; size hen's egg, removed; bleeding from rent in right broad ligament; after ligature, oozing; drainage-tube.</p>	<p>Recovered. On removal of drainage-tube abscess formed, with pain and fever; discharged freely for a few months; silk ligatures came away; complete recovery after some months.</p>
A. S., aged 43, unmarried.	Dr. A. D. Blackader, Montreal.	<p>Menses ceased 4 years ago; healthy till 3 years ago, when began to have pelvic pain. Two years ago a small pelvic tumor in right iliac region. Severe pain last few months. Steady increase of size.</p>	<p>A rounded, firm, tender tumor size of a child's head; uterus not very moveable, retroverted.</p>	<p>Desperately severe operation; tumor solid, very friable, broke down during removal; adhesions to parietes, omentum, intestines and pelvic structures proceeding from right ovary and involving tube; clamping of right corner of uterus; wash out and drain; microscopic examination showed sarcoma.</p>	<p>Recovered. Recovered from operation, but recurrence and death eleven weeks after operation.</p>
M. A., aged 57, married.	W. G.	<p>Menses ceased five years ago. A few months later a constant thin, pinkish discharge, which has never ceased.</p>	<p>Uterus enlarged and retroverted; cervix healthy.</p>	<p>Uterus extirpated by vagina. After its removal a cyst of the size of an orange also removed; found to be dermoid.</p>	Recovered. Good health.

