

FRIEDENWALD (H.) *Author of the work*

*Cranial Deformity and Optic-Nerve
Atrophy.*

BY

HARRY FRIEDENWALD, A.B., M.D.,
OF BALTIMORE, MD.



FROM
THE AMERICAN JOURNAL OF THE MEDICAL SCIENCES,
MAY, 1893.

H. W. M. 3117

CRANIAL DEFORMITY AND OPTIC-NERVE ATROPHY.

BY HARRY FRIEDENWALD, A.B., M.D.,
OF BALTIMORE, MD.

THERE are three classes of congenitally abnormal crania: 1, The enlarged skulls of hydrocephalus; 2, the very small skulls or microcephali; and 3, the variously deformed skulls.

The last named, to which I wish to draw attention in this paper, are produced by the too early union or synostosis of the bones that make up the cranium, and the peculiar deformity depends upon which sutures are prematurely closed. If it be the frontal suture, then the deformity will consist in a very narrow forehead and very wide head behind, and is known as trigonocephalus. When the synostosis is along the sagittal suture it gives rise to the long scaphocephalus or boat-shaped head, with the depression across the middle.

The general rule is that if there is any interference with the early growth or extension of the cranial cavity in one part there will be compensatory development in other parts; the deficiency of one portion together with the excessive development of the others constitute the peculiar deformities under consideration. It would be impossible for me to name all the deformities that have been described. I wish to mention but one in addition to those named above, the *Thurmschaedel* or steeple-shaped skull, known as oxycephalus, which is due to premature "synostosis of the parietal with the occipital and temporal bones, with compensatory development in the region of the bregma."

These many varieties of cranial deformity form a subject of great interest to the neurologist and alienist on account of their relation to epilepsy, idiocy, insanity, and crime. While it is of less importance, it is certainly not of less interest to the physician to study their relation to optic-nerve disease and to blindness.

To illustrate this I shall report the following case:

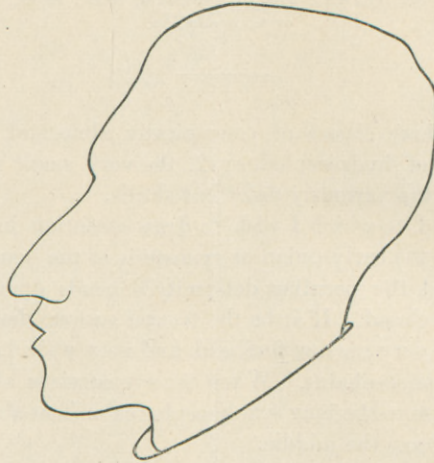
The patient is an intelligent salesman, aged twenty-six years. There was no blood relationship between his parents, who were both healthy, as are likewise his brothers and sisters. There is no mental trouble in the family. His head, deformed since birth, presents a typical example of steeple-shaped skull, as is seen in the sketch of his profile and by the appended craniometrical figures.¹ At school he found that his sight was

¹ The cranial measurements were made according to Peterson, *New York Medical Record*.



defective, the left eye being the worse. Since his school days his sight has not changed appreciably. He suffered from severe headaches until his sixteenth or seventeenth year, but since then they have been rare and mild. The eyeballs are bulged slightly forward.

FIG. 1.



1. Circumference (50.5 cm., from which deduct 6 per cent. for skin and hair, making) 47.5 cm. (Average in men, 52 cm.)
2. Naso-occipital arc (34.5 minus 6 per cent. leaving) 32.4 cm. (Average 32 cm.)
3. Naso-bregmatic arc, 15 cm. (Average 12.5 cm.)
4. Bregmato-lambdoid arc, 11 cm. (Average 12.5 cm.)
5. Binauricular arc (35.5 cm., from which deduct 6 per cent.) 34.2 cm. (Average 32 cm.)
6. Antero-posterior diameter, 16.4 cm. (Average 17.7 cm.)
7. Greatest transverse diameter, 14.7 cm. (Average 14.6 cm.)
8. Binauricular diameter, 11.9 cm. (Average 12.4 cm.)
9. Distance of bregma from point in median plane midway between meatus, 13 cm. (Average 12.4 cm.)
10. Facial length, 13.3 cm. (Average 12.37 cm.)
11. Empirical greatest height, 14.5 cm. (Average in men, 13.3 cm.)

The peculiar deformity is prominently shown when measurements 1 and 11 are compared.

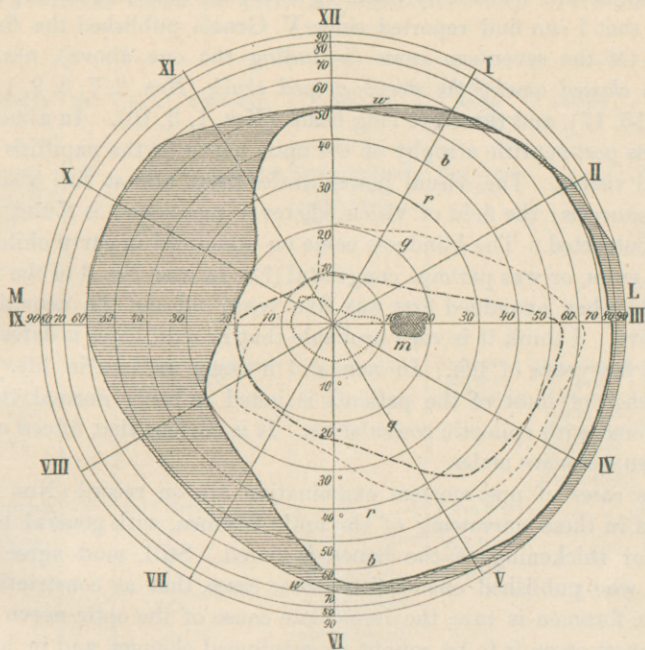
The ophthalmoscopic examination made November 21, 1891, revealed atrophic papillæ which were grayish-white and not transparent, so that the lamina cribrosa was not visible; the papillary edges were slightly blurred and irregular. The arteries and veins presented no abnormality. (They were not tortuous.) It was evident that this is a case of post-neuritic atrophy.

The vision of the right eye is 8/xxiii, 8/xii partly, that of the left eye 8/xviii. The vision cannot be improved by glasses. The fields of vision of both eyes are very much contracted on the nasal sides. (See Fig. 2.)

The history as well as the cranial and ophthalmoscopic appearances of hitherto recorded cases (see table) are in the main like the one just

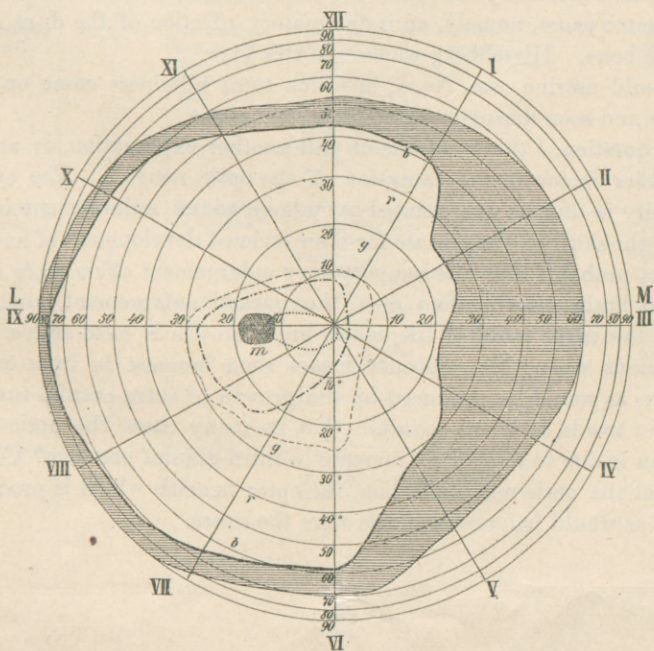
FIG. 2.

COD



White ———
Blue - - - - -
Red - · - · -
Green ·····

COS



presented, as will be seen by referring to the list classified below, which are all that I can find reported since V. Graefe published the first in 1866. Of the seventeen cases (including the one above), *nine are properly classed among the steeple-shaped skulls* (Nos. 2, 7, 8, 9, 11, 12, 13, 14, 15, 17), and three are long heads (Nos. 1, 3, 10). In almost all there was post-neuritic atrophy of the optic nerve, or the papillitis itself was still visible. The visual power varies from almost full vision to total amaurosis; the field of vision wherever mentioned is found to be much contracted. The blindness came on unnoticed in early childhood in most cases, or was perhaps congenital (?). In case No. 3 of the table, the child when examined first was five years old and the neuritis was still active. I think it is very probable that in most cases it dates from the first few years of life. In none did it come on late in life. The intelligence of most of the patients is noted as being normal, though two suffered with epileptic convulsions. It is curious that fifteen of the seventeen cases are males.

Three cases of post-mortem examination are on record (Nos. 2, 15, 16), and in these narrowing of the optic foramen, with general hyperostosis or thickening of the bones, is noted. Still, most agree with Michel, who published one of these three cases, that as constriction of the optic foramen is rare, the immediate cause of the optic-nerve affection in most cases is to be sought in meningeal changes and in hydrocephalic conditions of the brain. At the same time stenosis of the optic foramen must be looked upon as a very important factor.

Virchow, who examined a number of Hirschberg's cases, believes that the cranial deformity and also the blindness are often to be referred to the same cause, namely, an inflammatory affection of the dura mater and the bone. Hirschberg concurs in this view.

I should ascribe case No. 1, in which total blindness came on very rapidly and soon disappeared, to hydrocephalus.

The question, I think, admits of still another explanation, or at least of another factor in the causation of the optic neuritis. The cranial deformity is due, as was pointed out above, to an enlargement of one part of the skull to compensate for the restricted development of another. Is it not probable that this compensatory enlargement offers more resistance to brain growth than does the normal enlargement, and that, during the early years of life, when brain growth is most active, there are periods when this resistance means such increase in intra-cranial pressure as would be produced by the growth of intra-cranial tumors? In other words, is it not possible that in many cases the optic-nerve affection is due to temporary increase in intra-cranial pressure? Certain it is that the optic-nerve affection, the optic neuritis which is produced, is such as would be present if this were the cause.

TABULATED CASES OF CRANIAL DEFORMITY AND OPTIC-NERVE ATROPHY.

Reported by	Sex.	Age.	Deformity.	Vision.	Ophthalmoscopic appearance.	Autopsy.	Remarks.
1. v. Graefe, Arch. f. Oph., Bd. xii. No. 2, p. 133.	M.	8	Long, narrow skull.	Complete blindness, which came on suddenly.	Papillo-retinitis.	Pupils widely dilated; patient cured; mother epileptic, father drunkard and suicide; other children died young.
2. Michel, Archiv. d. Heilk., xiv. p. 39; also, Handb. d. Kinderkr.	M.	15	Steeple-shaped skull.	Neuritis followed by atrophy	Hyperostosis of skull; foramina optica narrow; pachymeningeal thickening over cortex.	Probably hereditary syphilis.
3. Hirschberg, Centralbl. f. Augenheilk, Jan., 1883.	M.	5-14	Scaphocephalus (Virchow).	R. = $\frac{15}{cc}$ L. = 0 Field of vision concentrically narrowed to about 20° all around; blindness came on gradually and unnoticed. L. divergent.	When first examined, optic neuritis, later atrophy.	Had convulsions; eyes prominent.
4. Hirschberg, loc. cit.	F.	3	Great bulging of temporal region especially on the right side (Virchow).	Slight visual power; reduced gradually.	Neuritic atrophy.	
5. Hirschberg, loc. cit.	M.	15	Synostosis of sagittal suture with very broad forehead (Virchow).	Vision defective since early youth. R. = $\frac{15}{cc}$ L. almost blind and divergent. Right field reduced about 10 or 20°.	Neuritic atrophy.	Had convulsions; intelligence fair.
6. Hirschberg, loc. cit.	M.	4½	Leptocephalus (Virchow).	Gradual blindness during first year; after that time complete.	Neuritic atrophy.	Peculiar cranial deformity noticed when born.
7. Hirschberg, loc. cit.	M.	20	Skull narrow and high.	R. = $\frac{15}{xx}$; field of vision normal. L. counts fingers at 5' (eccentric). L. divergent.	Neuritic atrophy.	Deformity noticed when born; intelligence good.
8. Hirschberg, loc. cit.	M.	7	Steeple-shaped skull.	R. = $\frac{15}{xx}$; field of vision fair. L. = 0.	Papillæ atrophic (light greenish-white color.	

Reported by	Sex.	Age.	Deformity.	Vision.	Ophthalmoscopic appearance.	Autopsy.	Remarks.
9. Hirschberg, loc. cit.	M.	9½	Steeple-shaped skull.	R. = $\frac{15}{xx}$; field of vision very narrow, about 20° in every direction. L. = 0 divergent.	Atrophy.	Maternal grandfather had same cranial deformity; intelligence good.
10. Vossius, Klin. Monat. Zehender, 1884, p. 172.	M.	7½	Long skull, temples very wide, glabella broad, forehead low, and rises very slantingly.	R.=0. L. counts fingers at 8'. Divergence.	Atrophy, blurred papillary edges (probably neuritic, H.F.)	Intelligence normal.
11. Stood, Zehender's klin. Monat., 1884, p. 241.	M.	33	Occipital portion undeveloped; steeple-shaped? (H. F.)	Blind since childhood. R. = $\frac{1}{o}$ L. = $\frac{1}{oo}$ Divergence; nystagmus.	Frequent convulsions (epileptic?) intelligence normal.
12. Mauz, Bericht der Oph. Gesells., Heidelberg, 1887.	M.	50-60	Steeple-shaped skull.	Had some vision as child, but gradually lost it almost entirely.	Post-neuritic atrophy.		
13. Manz, loc. cit.	M.	40	Steeple-shaped skull.	Had slight amount of vision, but lost it almost entirely after variola. R.=0, L. counts fingers.	Post-neuritic atrophy.		
14. Manz, loc. cit.	M.	young man	Steeple-shaped skull.	Blind since early childhood; slight perception of light in left eye.	Post-neuritic atrophy.		
15. Manz, loc. cit.	M.	40	Asymmetrical steeple-shaped skull.	R.=0, L. about one-half examined, due to papillitis. Vision became normal, leaving a permanent defect in the field of vision.	R. old atrophy. L. fresh papillitis (due to intra-cranial tumor).	Cause of death: osteosarcoma on inner surface of right parietal and temporal bones. Base of skull very irregular. Foramina large and edges sharp, but optic foramina narrow.	Died at age of 40. The deformity of the skull was old, the tumor recent.
16. Ponfik, original not accessible, quoted by Manz.	Deformed skull.	Stenosis of optic foramina.	Details not accessible.
17. H. Friedenwald.	M.	28	Steeple shaped	R. = $\frac{8}{xviii}$ L. = $\frac{8}{xviii}$	Post-neuritic atrophy.	Intelligence very good.

I make this suggestion not simply for its theoretical interest, but because it may give us the solution of the treatment of this otherwise incurable affection. The last few years have shown that brain and skull surgery has great possibilities. In epilepsy and idiocy from impeded cranial growth we have reason to hope for many cures, if the cranial vault is trephined and weakened, and thus allowed to expand. I believe that optic neuritis in children when due to cranial deformity should be put down similarly as a possible indication for trephining. Case No. 3 in the table might thus come under this head. If in such a patient we would be able to find any other signs of increased intra-cranial pressure, I do not think that the operation would be out of place.

In microcephaly blindness is rare, as we would expect *à priori*, at least if we accept the view of Broca, that commonly this condition is primarily due to impaired development of the brain, and not to interference offered to its growth by the cranial bones. Still there may be cases where this last explanation holds, and in some of these we may expect optic neuritis.

The consideration of the relation of hydrocephalus to blindness is beyond the province of this paper.

BIBLIOGRAPHY.

- V. Graefe: Arch. f. Ophth., xii., No. 2, p. 133.
Michel: Arch. d. Heilkunde, xiv., p. 39.
Hirschberg: Centralbl. f. Augenheilk., 1883 (which includes cases published previously by himself and Schüller).
Leber: Graefe and Saemisch, v., p. 805.
Michel: Handb. d. Kinderkrankh.—Gerhardt, Bd. v. Abth. ii., p. 515.
Manz: Berichte d. Ophthal. Gesellsch., Heidelberg, 1887, p. 18.
Gowers: Manual of Ophthalmoscopy. Third Amer. ed., p. 180.
Stood: Klin. Monats. f. Augenheik., 1884, p. 241.
Vossius: Klin. Monats. f. Augenheik., 1884, p. 172.
Ponfick: Bresl. ärztl. Zeitschr., No. 21, 1886.

The American Journal OF THE MEDICAL SCIENCES.

MONTHLY, \$4.00 PER ANNUM.

WITH 1893 THE AMERICAN JOURNAL OF THE MEDICAL SCIENCES enters upon its seventy-fourth year, still the leader of American medical magazines. In its long career it has developed to perfection the features of usefulness in its department of literature, and presents them in unrivalled attractiveness. It is the medium chosen by the leading minds of the profession on both sides of the Atlantic for the presentation of elaborate Original Articles; its Reviews are noted for discernment and absolute candor, and its Classified Summaries of Progress each month present an epitome of medical advances gleaned by specialists in the various departments. According to unquestionable authority, "It contains many original papers of the highest value; nearly all the real criticisms and reviews which we possess, and such carefully prepared summaries of the progress of medical science and notices of foreign works that from this file alone, were all other publications of the press for the last fifty years destroyed, it would be possible to reproduce the great majority of the real contributions of the world to medical science during that period."

The Medical News.

WEEKLY, \$4.00 PER ANNUM.

BY KEEPING closely in touch with the needs of the active practitioner, THE NEWS has achieved a reputation for utility so extensive as to render practicable its reduction in price from five to **Four Dollars** per annum. It is now by far the cheapest as well as the best large weekly medical journal published in America. Employing all the recognized resources of modern journalism, such as the cable, telegraph, resident correspondents, special reporters, etc., THE NEWS furnishes in the 28 quarto pages of each issue the latest and best information on subjects of importance and value to practitioners in all branches of medicine. Its numerous departments are designed to subdivide and present its material in the most attractive and convenient manner.

In a word THE MEDICAL NEWS is a crisp, fresh, weekly newspaper, and as such occupies a well-marked sphere of usefulness, distinct and complementary to the ideal monthly magazine, THE AMERICAN JOURNAL OF THE MEDICAL SCIENCES.

The Year-Book of Treatment for 1893

Gives a classified summary and review of the real advances in treatment made during 1892 in all departments of the science of medicine. Price, \$1.50; or in combination with either or both the above journals, 75 cents.

The Medical News Visiting List for 1893

Published in four styles: Weekly, dated, for 30 patients; Monthly, undated, for 120 patients per month; Perpetual, undated, for 30 patients weekly per year; Perpetual, for 60 patients weekly per year. The first three styles contain 32 pages of important data and 176 pages of assorted blanks; the 60-patient perpetual consists of 256 pages of blanks. Price, each, \$1.25. In combination with either or both above periodicals, 75 cents. Or, JOURNAL, NEWS, VISITING LIST and YEAR-BOOK, \$8.50. Thumb-letter index for VISITING LIST, 25 cents extra.

LEA BROTHERS & CO., PUBLISHERS, PHILADELPHIA, 706 & 708 SANSOM STREET.