

FORDYCE (J. A.)

ADENO-CARCINOMA OF THE SKIN
ORIGINATING IN THE COIL GLANDS

BY

J. A. FORDYCE, M. D.

Professor of Dermatology and Syphilology, Bellevue Hospital Medical College; Visiting Surgeon
to the City Hospital, etc.

[Reprinted from the JOURNAL OF CUTANEOUS AND GENITO-URINARY DISEASES
for February, 1895]



NEW YORK
D. APPLETON AND COMPANY
72 FIFTH AVENUE
LONDON: CAXTON HOUSE, PATERNOSTER SQUARE

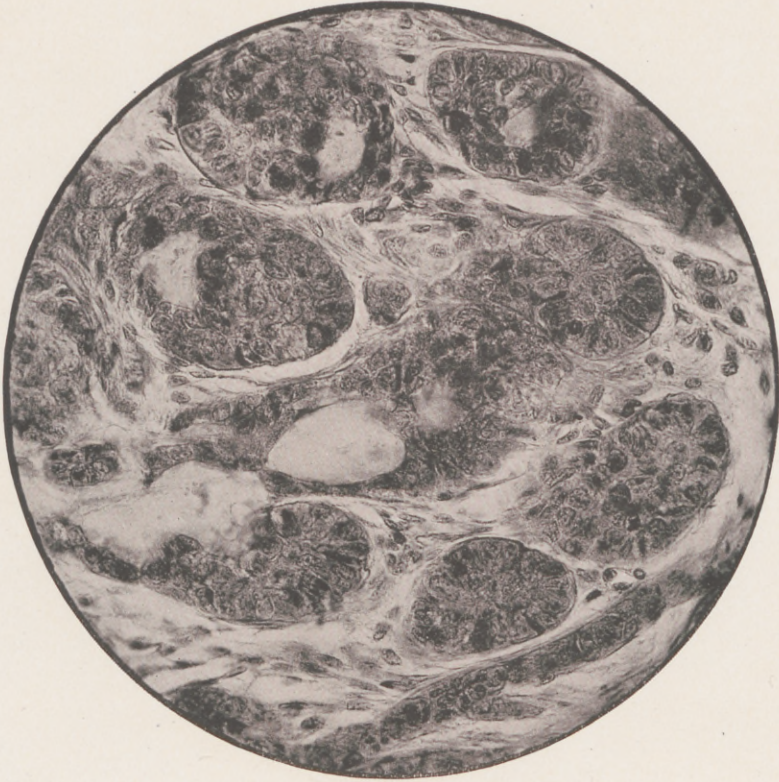


FIG. 4.—Spencer $\frac{1}{4}$ in., $\times 400$.

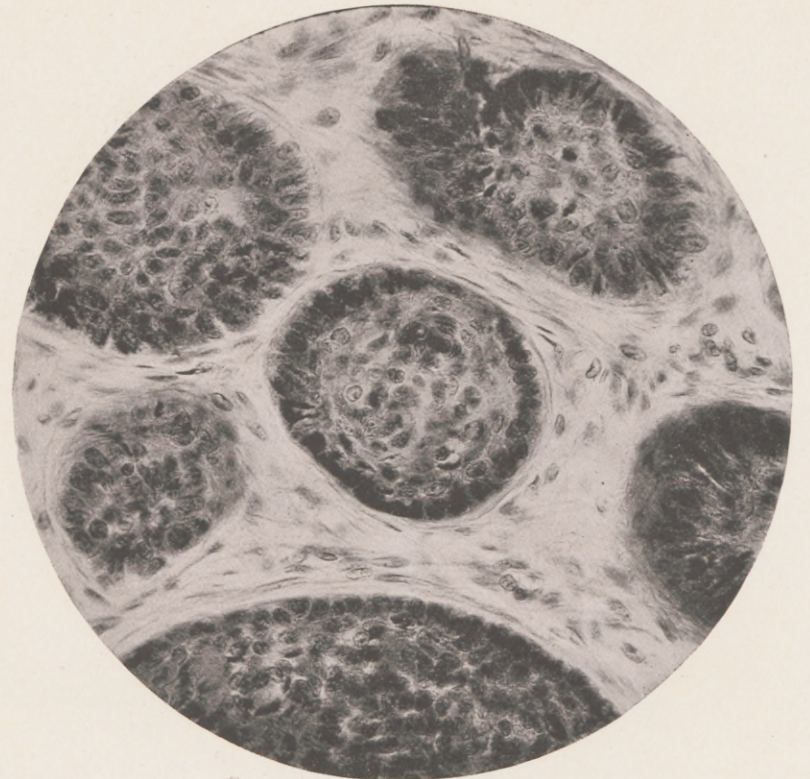


FIG. 5.—Spencer $\frac{1}{4}$ in., $\times 400$.

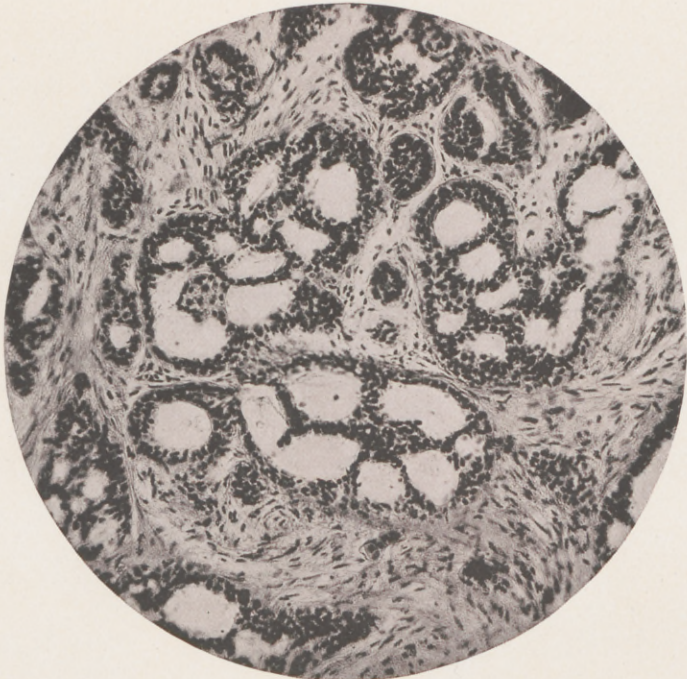


FIG. 6.—Spencer $\frac{1}{2}$ in., $\times 150$.

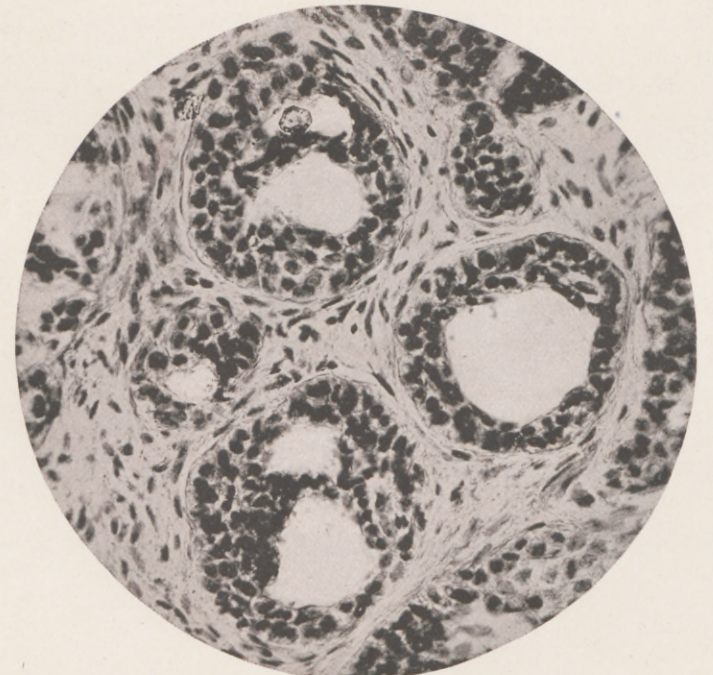


FIG. 7.—Spencer $\frac{1}{4}$ in., $\times 400$.

ILLUSTRATING DR. FORDYCE'S ARTICLE ON ADENO-CARCINOMA OF THE COIL GLANDS.

(Photomicrographs by the Author.)

ADENO-CARCINOMA OF THE SKIN ORIGINATING IN THE COIL GLANDS.*

By J. A. FORDYCE, M. D.,

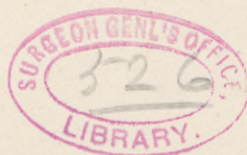Professor of Dermatology and Syphilology, Bellevue Hospital Medical College; Visiting Surgeon to the City Hospital, etc.

CANCERS of internal organs are generally the result of an abnormal proliferation of the glandular epithelium of the part affected. In the skin, on the contrary, the epidermis is the structure which is most frequently first involved. The squamous-celled epithelioma, or the lobulated variety of the French writers, undoubtedly starts in those cells of the epidermis which are destined to form the stratum corneum. Certain varieties of skin cancer which have their point of departure in the epidermis are made up entirely of small epithelial cells which preserve the character of the cells in the lowermost rete layer. These cells extend throughout the cutis and subcutaneous tissue in the form of tubular processes, showing no disposition to form epidermic "globes" or horny tissue. It is difficult to explain why the epithelium in one variety of these malignant growths should always produce, although in an abnormal manner, the form of cell in which it in a physiological manner ends its existence, while another variety preserves its embryonic or original character.

We may suppose that certain epidermic cells have in themselves the power to develop into horny tissue, while others do not possess such power, or are destined for another purpose, such as the formation of the glandular appendages.

In that rare variety of malignant cancerous new growth in which pigment-bearing cells predominate, it is possible that yet another variety of epithelial cell is first involved.

* Read at the Eighteenth Annual Meeting of the American Dermatological Association, Washington, D. C., May, 1894.



The tubular variety of skin cancer, to which type the so-called rodent ulcer belongs, may originate from the epidermis, from the outer root sheath of the hairs, or possibly from the glands of the skin.

Although many attempts have been made to show that it has a uniform pathology, such efforts have been unsuccessful, as in specimens removed from epitheliomata, which are clinically of the same class, various points of origin, either alone or combined, have been noted.

From whatsoever structure epitheliomata arise, after a certain duration the original arrangement of the cells may be lost in the tendency which they show to arrange themselves in alveola which bear a close resemblance to those met with in mammary or other glandular carcinomata. I have, during some recent investigations of cutaneous new growths, excised a number of small pearly tumors which are seen with more or less frequency on the faces of middle-aged individuals. Such small tumors not infrequently exist for many years without ulceration or any change to indicate a malignant tendency. After excision, partial or complete, the wound heals kindly, and no sign has afterward been observed which would point to a recurrence of the growths.

Microscopic examination has shown such tumors to consist of epithelial downgrowths from the epidermis, which in many cases had undergone a partial or complete degeneration of a hyaline nature. With this degeneration of the cell the power of proliferation which it originally possessed is lost and the new growth comes to a standstill.

In other instances, however, the center of the tumor will slowly ulcerate while extension at the margin takes place, giving rise to an open epitheliomatous ulcer whose peripheral cells readily take the microscopic stains and show active cell division. These pearly tumors have many points of resemblance, both in their clinical features and pathological anatomy, to the affection which has been described under the various names of *hydradénomes éruptifs*, *adénomes sudoripares*, syringo-cystadenom, adenoma of the sweat glands, benign cystic epithelioma, etc.

This curious affection, at first considered to be a benign epithelioma having a sweat-gland origin, has been shown to originate in the epidermis and to be independent of the coil glands. Its benign nature, too, has been questioned, as in the case lately reported by Dr. White, open epitheliomatous ulcers resulted from a number of the supposed benign tumors. As the predilection of cancer in general for the glandular structures is so strongly marked, the temptation has been strong among many pathologists to attribute to certain cutaneous epitheliomata such an origin without sufficient proof that such was the case. An examination of many of the usual forms of cancer situated

at a distance from the mucous membranes will show a structure made up of tubules of small epithelial cells, which suggest in a striking manner overgrown and abnormally proliferated sweat ducts or glands. This is the case in the so-called benign epithelioma and in other varieties of skin cancer.

Although a wide difference of opinion exists among pathologists regarding the rôle played by the sweat glands in tumor formation, there are few well-authenticated examples of adenomata which can be directly traced to these organs. Virchow (*Die krankhaften Geschwülste*, Bd. iii) had never seen a single example of such a tumor.

Rindfleisch (*Lehrbuch der patholog. Gewebelehre*) found a flat, warty-like elevation of the skin to be on section a tumor originating in the coil glands. Peterson (*Archiv für Dermat. und Syph.*, 1892, p. 919) reported a case of *nævus verrucosus unius lateris*, which proved on microscopic examination to be an adenoma of the sweat glands. He expressed the view that the tumor originated not from the fully developed gland, but from some disturbance in its embryonal development. In a later article (*Beiträge zur Kenntniss der Schweissdrüsen-Erkrankungen*, *Archiv für Dermat. und Syph.*, 1893, p. 445) he concludes, from a further examination of the same case, that the tumor started from the ducts of the fully developed glands.

Elliot (*Journal of Cutaneous and Genito-Urinary Diseases*, 1893, p. 168) found a similar pathological condition of the coil glands occurring in a *nævus unius lateris* of the shoulder, which had existed since childhood. Elliot preferred to give the name adeno-cystoma to the pathological condition which he found, there being no new formation of glandular tissue. He further believed the process to be secondary, and developed in consequence of the irritation to which the *nævus* had been subjected.

While it is not improbable that adenomata of the sweat glands may remain in a quiescent state for a long time before giving rise to malignant epitheliomata, there is very little proof, either in the clinical course or pathological anatomy of such malignant growths, to show which ones had such a beginning.

Thiersch and Waldeyer have described primary cancer of the sweat glands, but the attempts which have been made by Cornil and Ranvier, Thin, and others to prove that all tubular epitheliomata of the skin have such an origin have not been successful. Neither the shape, size, nor arrangement of the cells are sufficient criteria on which to base the diagnosis of sweat-gland epitheliomata.

Darier (*Contributions à l'étude de l'épithéliome des glands sudoripares*, *Archives de méd. expérimentale et d'anat. pathol.*, 1889,

pp. 115 and 267) has reported a peculiar case occurring in the service of Besnier, in which multiple, deep-seated, and painful tumors developed with great rapidity on the trunk of a man aged seventy-one. Darier's examination showed that each tumor started with a proliferation of the sweat-gland epithelium, which filled the lumen of the canal, broke through the membrana propria, and infiltrated the connective tissue. He gave to his case the name "diffuse multiple epithelioma of the sudoriparous glands," and believes it to be unique in the number, the rapid evolution, and the structure of the tumors. The author was able in medical literature to find but two analogous cases, one of which was reported by Malherbe, the other by Creighton. In the latter case a dog was the subject of the affection.

Darier (*loc. cit.*) has quoted a number of cases collected from literature in which a sweat-gland origin of the tumors in question was probable. These cases are briefly as follows:

Henocque and Souchon (*Gaz. hebdom.*, 1866, p. 310) observed a tumor on the back of a man aged thirty-four which had existed for eight years. At first its growth was slow, later it became more rapid. The authors concluded from its microscopic structure that it was an adenoma of the sudoriparous glands.

Cristol (*Gaz. hebdom.*, 1886, p. 364) observed a tumor with a similar structure on the back of a woman aged thirty-three. The growth was stationary during many years, but finally ulcerated deeply, and was believed, on microscopic examination, to have had a sweat-gland origin.

Chandelux (*Arch. de physiol.*, t, xiv, 1882) published a report of a painful subcutaneous tumor the size of a pea which had existed six years on the forearm of a woman aged forty-three. The author was able to determine a proliferation of the epithelium lining the sweat glands, which he believed to be the starting point of this growth.

Liénaux (*Ann. de méd. vétérinaire*, avril, 1888) examined a tumor the size of an egg which affected the skin of a dog. His examination showed pretty conclusively that the glands under consideration gave rise to the new growth.

Cornil and Ranvier (*Jour. de l'anat. et de la phys.*, 1865, pp. 256 and 466) were able to demonstrate the development of a cancer of the leg from the coil glands. The careful study of this case by the authors leaves little doubt regarding the structure first involved, which is admitted by Darier to be incontestably an epithelioma of the sweat glands.

Equally good pathologists differ regarding the part played by the sweat glands in the production of tubular epithelioma. While it is admitted by many that their epithelium may proliferate in many

forms of skin cancer, it seems difficult to determine in what class of cases this proliferation is primary. The slow clinical course and non-implication of the lymph glands were supposed, among other symptoms, to indicate a growth which took place at the expense of the sudoriparous glands. When in a growth of this character epithelial processes recalling the shape of the sweat ducts were encountered, the conclusion was reached that these glands were their original point of departure. It is an error to suppose that any universal law can be formulated from either the clinical course or histological structure of such growths; their location on the skin away from the mucous orifices, where there is less irritation and less vascularity and lymphatic supply, as has been observed by Besnier, Hutchinson, and others, seems to have more to do with their benign course than a fixed origin or structure. I have examined many cases of such epitheliomata from the face, presenting typical tubular prolongations of epithelium, with no tendency to the formation of horny epithelium, and very frequently could trace their origin to the interpapillary processes of the rete or to the hair follicles, both the sweat and sebaceous glands being unaltered. While it is not denied that either or both of these glands may give rise to the tubular epithelioma, the proof that such is the case is difficult to obtain, as the ulcerative process so soon destroys the tissues which may be first involved.

It is probable that rodent ulcer and tubular epithelioma are pathologically identical. Thin (*On Cancerous Affections of the Skin*, London, 1886) has expressed this view, and has endeavored to associate it with a sweat-gland origin. He does not believe it to be identical with an epithelioma starting from the rete Malpighii, though admitting that the clinical diagnosis is not easy to make. Walker (*British Journal of Dermatology*, September, 1893) is the most recent advocate of the glandular origin of rodent ulcer. His argument is that in its structure it corresponds to glandular cancer, and that when carcinoma of the breast secondarily attacks the skin it is almost identical with rodent ulcer.

In most of his cases he was able to trace an origin to the sweat glands. The slow course of the ulceration is to be attributed, according to this author, to the normal slow growth of the glandular epithelium, the rete cells having a rapid growth.

The case which forms the subject of this report differed in its clinical features from the usual type of cutaneous cancer in which a sweat-gland origin has been claimed. Unfortunately, the duration of the tumor before the stage of ulceration was not noted. It may be said to have some clinical resemblance to the cases reported by Henocque and

Souchon and by Cristol. It would have been a matter of some interest to have determined whether it began as a deep or surface affection.

Dr. Bronson, in whose service at the City Hospital the case occurred, excised the tumor from the anterior surface of the leg of a

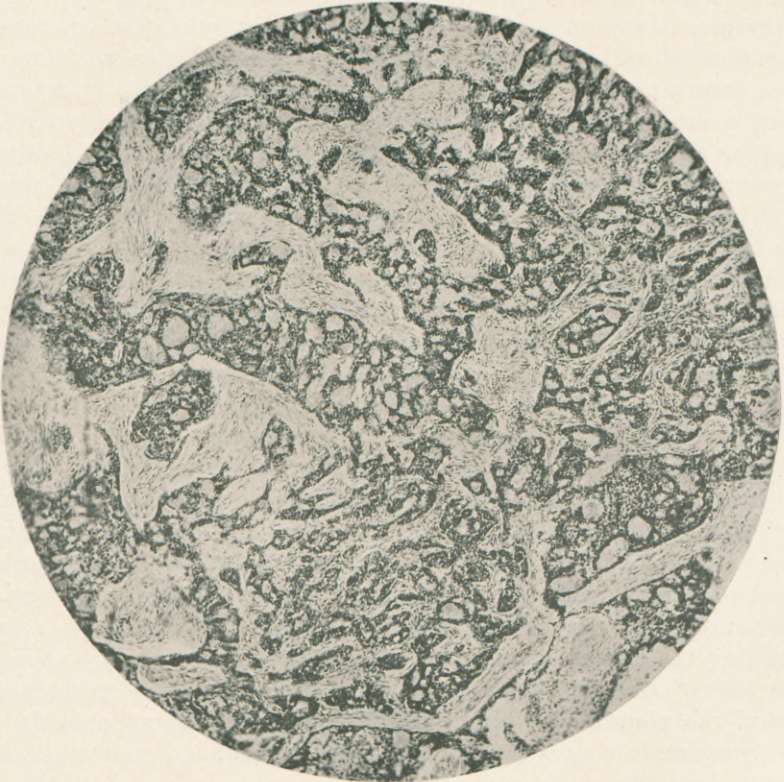


FIG. 1.—(Spencer 1 in. \times 60.) Showing the distribution of the epithelial tissue and its adenomatous structure.

man thirty-five years old, and kindly gave it to me for examination.

It is interesting to note that the cancerous nature of the new growth was not suspected prior to a microscopic examination made before the operation of excision.

The growth was composed of distinct lobules, separated by the ingrowth of connective tissue; it was soft to the feel, about half the

size of a small egg, and defined from the surrounding tissue without being distinctly encapsulated. It extended about one inch below the skin, and measured an inch and a half in its long diameter. An open ulcer, somewhat larger than a silver dime, was present over the tumor. Portions of the growth were fixed in Flemming's solution, Foa's solution, and in absolute alcohol. Sections were stained in hæmatoxylon, safranine, Biondi's mixture, and in other ways.

Under a low power (Spencer one inch, Fig. 1) the derma is seen to be occupied by bands, masses, and glandlike arrangements of small epithelial cells which stain imperfectly in places. The cell masses and bands extend from just below the epidermis, which is unchanged ex-

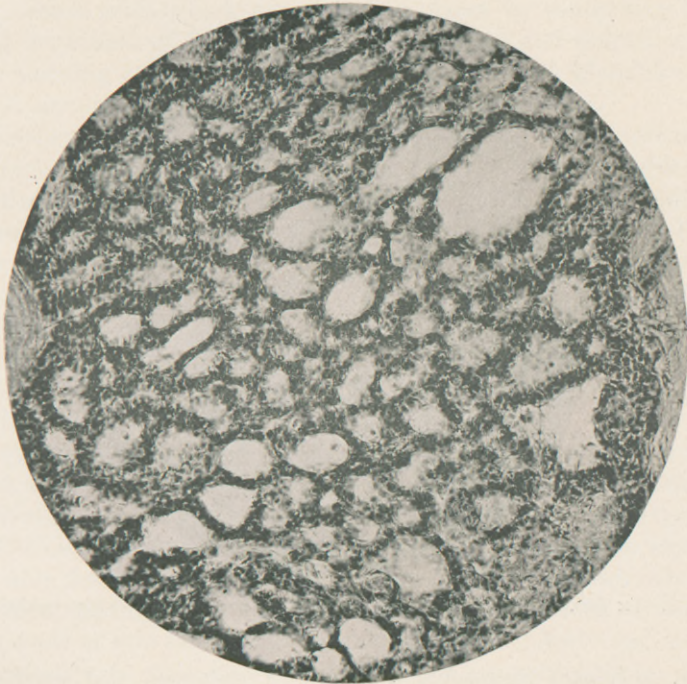


FIG. 2.—(Spencer $\frac{1}{2}$ in. \times 150.) More highly magnified field of a portion of Fig. 1.

cept at the location of the ulceration previously mentioned, to the subcutaneous connective tissue which is penetrated by them.

They differ in their arrangement from that met with in other varieties of skin cancer, suggesting to the observer at the first glance an attempted reproduction of glandular tissue, which becomes still more noticeable when higher amplification is employed (Fig. 2).

Here a highly complicated network has been formed by the interlacement of bands of epithelial tissue, inclosing cavities which are partially or completely filled with degenerated cells or with a homogeneous substance allied to colloid matter.

Cystlike cavities are seen in other parts of the microscopic field which are lined by a single layer of columnar epithelial cells which present a striking resemblance to overgrown sweat ducts.

In other instances the cell layer is double and quite regular in arrangement; while, again, the overgrown ducts or glands are completely filled with cells or show a localized overgrowth at one or more points. In Fig. 3 an overgrowth of columnar epithelium is shown which probably represents an early stage of the malignant process.

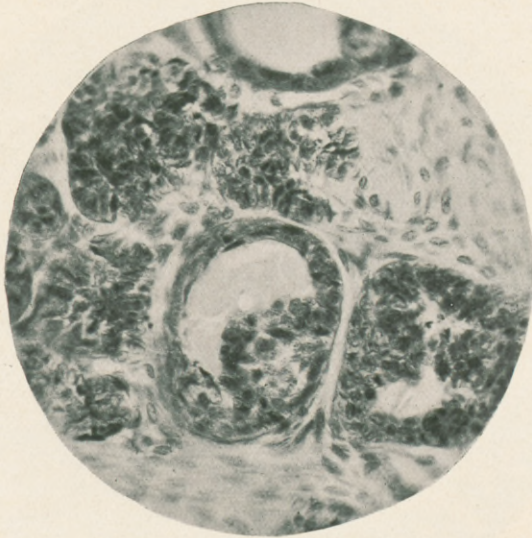


FIG. 3.—($\times 300$.) Showing the beginning proliferation of the glandular epithelium.

Fig. 4 (plate) represents a group of enlarged and proliferating sweat ducts cut transversely. The columnar shape and regular arrangement of the peripherally located cells are well shown. These cells are situated upon a basement membrane, and are an almost exact reproduction of those normally met with in the sweat glands, although here very much hypertrophied. The lumen of the tubules is completely filled by the growing and multiplying cells, and in places the basement membrane is penetrated and the surrounding connective tissue infected by them. This photomicrograph is made from a section taken

from a portion of the tumor fixed in Flemming's solution. Consequently the cells are much less deeply stained.

In Fig. 5 (plate), where the same amplification is employed, the tubules are larger, of irregular size, and their caliber completely occupied by the newly formed cells, which are also seen in places breaking through the *membrana propria* and infiltrating the connective-tissue stroma. This infection of the surrounding connective tissue may be accepted as positive evidence of the malignant character of the new growth.

Figs. 6 and 7 (plate) represent in a striking manner the adenoma-like structure of the new growth, together with the intracanalicular proliferation of the basement cells. The cavities are lined by a double row of cubical cells, which are united in places by connecting bands, dividing the lumen of the tubes into various sized and shaped cavities.

The outlying portions of the tumor have lost their glandlike structure, and assume the appearance of an alveolar carcinoma.

The other anatomical structures of the skin were not implicated in the cancerous process, neither was there any evidence of a tendency to cell-nesting or the formation of epidermic "globes." The epithelial processes met with in the small-celled cancer of the skin, starting in the *rete Malpighii*, resemble at times some of the cell arrangements in the case under consideration. In the epidermic cancer, however, the cells are larger, and do not rest upon a distinct basement membrane, as in this case. Furthermore, the epithelial bands or tubules starting from the *rete* have no distinct caliber, and do not reproduce so perfectly the glandular structure.

Frequently, when a new growth has reached the size of this one, its point of departure has been destroyed by ulceration or in some way obliterated, so that it is not possible to determine from what structure the epithelial proliferation was primary. The adenomatous character of the new tissue is so apparent here, and differs so radically from those cases starting from the other anatomical divisions of the skin, that an error of this kind could scarcely be made. Active cell division (*karyokinesis*) was well shown in the Flemming preparations, stained with safranine, denoting a rapid growth of the new tissue.

The intracellular bodies (so-called parasites of cancer) will not be considered at this time, as I desire on some future occasion to discuss their relationship to the cancerous process.

While believing that the manifestations of the malignant disease can best be explained by the parasitic theory, I am not prepared to admit that its cause is found in these bodies.

Prognosis.—Unfortunately, the case here presented has not been

seen since the tumor was excised, so that the question of recurrence of the growth can not be considered.

Such cases are too rare to permit any expression of opinion regarding their malignancy as compared to other cutaneous cancers.*

66 Park Avenue.

* The photomicrographs used in illustrating the article were taken with the lenses made by the Spencer & Smith Optical Co., of Buffalo, N. Y., especially corrected for photography with yellow or yellowish-green light as suggested by Dr. H. G. Piffard, of this city. They are reproduced by the half-tone process, and necessarily lose some of the details seen in the originals.

