

FENGER (C.)

al

BENIGNANT TUMORS OF THE ILEUM.

BY

CHRISTIAN FENGER, M. D.,

---

Opening Address of the Session of 1894-5 at Northwestern University  
Medical School, Sept. 25, 1894.

---

Reprinted from  
THE CHICAGO CLINICAL REVIEW,  
December, 1894.









## BENIGNANT TUMORS OF THE ILEUM.\*

BY CHRISTIAN FENGER, M. D., CHICAGO.

Benignant tumors of the intestinal tract are not uncommon, but they rarely develop; to such a size or in such a location as to cause danger to life. While both benignant and malignant tumors are relatively common in certain portions of the intestinal tract, the small intestine is usually exempt, with the exception of the portion where the bile and pancreatic ducts enter the duodenum, in which localities carcinomas are quite common.

From the connective tissue and muscularis, tumors of the connective tissue type develop; the sarcomas of the small intestine have been recently described by M. Baltzer<sup>1</sup>, who could find only fourteen cases in the literature.

Benignant tumors—myomas, fibromas, lipomas, angio-myomas—are more common, but have attracted less attention, as they only exceptionally give rise to obstruction as such, more often to invagination. They consequently play only a secondary part in the causation of the grave symptoms attendant upon invagination.

Leichtenstern<sup>2</sup> distinguishes between—1. Fibromas, which originate in the submucosa and protrude in the lumen of the bowel as fibroid polypi, and which may cause obstruction or invagination.

2. Myomas, originating in the muscularis mucosa, or intes-

\*Opening address of the session of 1894-5 at Northwestern University Medical School, September 25, 1894.





testinal muscularis, in some cases rich in vessels, (angio-myomas) in other cases more fibrous; these latter protrude into the intestines as polypi, and give rise to the same disturbances as the first variety.

3. Submucous lipomas, which protrude as pedunculated polypi, often multiple, but which seldom attain such a size as to cause obstruction.

4. Mucous polypi, papillomatous or with a smooth surface.

As to the frequency of polypi of all the different varieties in the entire intestinal tract, Leichtenstern gives the following table:

Rectum.....	(estimate too low)	75
Colon.....		10
Cæcum,.....		4
Ileo-cæcal valve.....		2
Lower portion of the ileum (usually found by causing invagination).....		30
Jejunum.....		5
Duodenum.....		2

He states that they often give only indistinct symptoms, until in some cases, obstruction is caused either by congestive swelling and rapid growth, or more commonly, when situated in the lower ileum, by invagination. As the tumors are never large enough to be discovered by palpation, they are not diagnosed, with the exception of the polypi of the rectum, which are found on rectal examination.

Rokitansky<sup>10</sup> in speaking about connective tissue tumors of the intestine, states that such tumors may develop from the subperitoneal tissue or the muscularis, may become pendulous toward the peritoneal cavity and, by traction on the intestinal wall, form a pocket communicating with the lumen of the intestine. They may also in rare instances, extend into the lumen of the intestine, and cause disturbance by reason of their size. Thus they may cause obstruction or intussusception, or if they press upon the bile duct or pancreatic duct may cause retention of the respective secretions.

Förster<sup>4</sup> states that fibroid tumors in the intestinal tract are commonly myomas which develop in the submucous tissue and protrude into the lumen of the intestine. Such a tumor, in the case of a man of seventy, developed



from the muscular coat of the intestine, he has described as follows: The tumor was round, six to seven lines in diameter, originated from the muscularis of the ileum, the muscular fibres extending continuously into the tumor. The tumor protruded toward the peritoneal surface with its whole mass so that the lumen of the intestine was not narrowed. Microscopical examination showed the tumor to consist of organic muscle fibres interwoven with a sparse stroma of connective tissue, and a normal development of blood-vessels. The muscle-cells in the tumor were two or three times as large as those in the wall of the intestine, and the nuclei were correspondingly larger than those in normal muscle fibre.

He remarks that such tumors might be of practical importance if they should develop to more considerable size or protrude into the lumen of the bowel, but neither in the literature nor in his experience had he found a single instance of this kind.

Virchow<sup>11</sup> states that myomas are rare, and, if we exclude uncertain observations, develop only into small tumors. He has found these tumors only in the small intestine. He describes a specimen from the Berlin Museum, of a tumor in the transverse portion of the duodenum, the size of a cherry stone, clad with mucous membrane, which protruded into the lumen of the intestine, and which had undergone calcareous degeneration. Microscopical examination showed that the tumor was composed of connective tissue and muscle-fibres, and that it was connected with the muscularis of the intestine.

He also states that sub-mucous lipomas are found in the stomach, jejunum and colon. They may become pedunculated, and the large polypi of the jejunum are usually pedunculated lipomas which push the mucosa before them, and which often extend for an inch into the intestine. Innocent in themselves, they may give rise to intussusception, but Virchow does not state that they have ever caused occlusion by their size alone.

Huss<sup>5</sup> reports a case of lipomas in the mucous membrane of the small intestine. The patient, a man forty-four years of age, had a dysentery a year before, followed by chronic diarrhoea, cachexia and death, but had no symptoms



of ileus. In the small intestine twelve polypi the size of a hazel-nut, were found protruding into the gut; chronic dysenteric ulcers were also found in the rectum and large intestine. The lipomas were not caused by the dysentery, nor did they cause any symptoms.

Klebs<sup>6</sup> considers intestinal myomas rare, and states that their muscle fibres are much larger than normal.

Böttcher<sup>3</sup> has described a myomatous polypus of the ileum from the Dorpat Pathological Museum. The specimen consisted of a piece of intestine which showed an angular flexure with stenosis. In the angle was a tumor  $5\frac{1}{2}$  cm. long and 3 cm. in diameter, which protruded into and almost filled the lumen of the dilated intestine. The polypus was covered with normal mucous membrane. On transverse section, three layers of the tumor could be distinguished; first, a whitish layer  $\frac{1}{2}$  cm. thick, consisting of thickened mucous membrane and containing dilated vessels in firm fibrous tissue. Next to this was seen a wavy band 1 to  $1\frac{1}{2}$  mm. in diameter, extending into the muscular coat and representing a thickened layer of intestinal muscularis. The main mass of the tumor consisted also of muscular fibre with a sparse amount of connective tissue, but a large number of vessels.

Böttcher believes that this myoma had grown into the lumen of the intestine in the following manner: By reason of its weight it pulled the peritoneal surface of the intestine inward, causing a funnel-shaped depression on the outside, and consequent agglutination of the peritoneal surfaces thus brought in contact with each other.

Wesener<sup>1,2</sup> thinks it likely that the myoma, as such, may be developed toward the mucous side of the intestine.

Perls<sup>9</sup> states that leiomyomas are not very rare in the intestinal tract, but that they usually remain small, from the size of a cherry to that of a plum. Larger myomas are found only in the fundus of the stomach.

Birch-Hirschfeld<sup>2</sup> states that submucous pedunculated lipomas have been known to reach the size of an apple. If developed to this extent, they might cause stenosis directly or might be caught by the peristaltic movements of the intestine and cause invagination. Mucous polypi originate by chronic catarrhal inflammation, are often multiple and



may attain a large size. They are most commonly found in the lower part of the ileum, colon and rectum.

Wesener,<sup>12</sup> to whom we are indebted for a careful and exhaustive review of the literature of the subject, found in the Pathological Museum of Giessen, a round tumor of the duodenum, the size of an apple. It was located in the posterior wall of the duodenum, 5 cm. above the entrance of the bile duct; but the large mass of the tumor extended into the peritoneal cavity and protruded only slightly into the lumen of the intestine. Behind the tumor were the pancreatic and bile ducts which, however, were not compressed. On microscopical examination this tumor was found to be a myoma.

Wesener also found a myoma of the duodenum in the following case; A man fifty-five years of age had suffered from gonorrhoeal cystitis and chronic polyarthritis, and toward the end of his life presented indistinct symptoms of intestinal disturbance, constipation alternating with diarrhoea, and occasional attacks of copious vomiting which persisted for two or three days and then disappeared, to recur after a short time. The increasing emaciation for the last few months before the patient died caused the diagnosis of carcinoma of the stomach to be made, though neither tumor nor coffee-ground vomiting was observed. The autopsy showed a dilated stomach, together with dilatation of the pylorus and the upper portion of the duodenum, but no carcinoma. Fifteen centimeters below the pylorus, a nodular tumor the size of a plum protruded into the intestine. On its apex was a depression with loss of substance, where the mucous membrane was wanting. The tumor in the duodenum was part of a larger tumor, the size of a fist, situated outside of the intestine between the duodenum and the transverse colon, lying on the atrophied pancreas, to the head of which it was adherent. Microscopical examination showed the tumor to be a myoma which had originated in the circular fibres of the muscularis of the intestine without causing absolute obstruction. The tumor had evidently caused a certain degree of stenosis, as was shown by the dilatation of the duodenum and stomach above.

Pelizzari<sup>8</sup> reports the case of a young girl in whom a



large round tumor presented in the ileo-cæcal region. This tumor was supposed to be ovarian. It caused no symptoms at first, but later on pain, vomiting, constipation, and finally symptoms of ileus occurred. Sixteen days later a myoma, one pound in weight, was passed by the rectum, and the symptoms disappeared.

I am not aware that any benignant tumors of the small intestine have been operated upon, with the exception of polypi in cases of invagination, where they play only a secondary part in the obstruction.

I desire to report the following case as an instance in which the myoma itself caused obstruction, and in which the tumor was successfully removed by operation:—

*CASE. Synopsis. Chronic intestinal obstruction, with intermittent attacks of fecal vomiting, accompanied by paroxysmal pain and visible peristaltic contraction of isolated coils of intestine. No tumor felt. Exploratory abdominal incision in the interval between attacks. Sessile tumor of ileum. Longitudinal incision of intestine. Excision of tumor. Suture of intestinal wound. Recovery.*

R. M., male, seventy-five years of age, consulted me May 16, 1893. Family history negative. General health always good until a year before, when he had occasional attacks of constipation unattended with vomiting. During the last five or six weeks bowels have moved but slightly and the stomach has refused food, or after eating he would feel a sensation of heaviness and become nauseated; in an hour or two after eating there was occasional vomiting of fecal matter. During the last two weeks he has vomited almost every day, first the stomach contents, then the contents of the bowels. Paroxysmal pain in the abdomen, the paroxysms becoming more frequent. No pus or blood in the feces.

*Examination.* Patient in bed, old, pale, decrepit, emaciated. Abdomen not tympanitic, but when a paroxysm of pain occurred, I found that it was accompanied by peristaltic contraction of coils of intestine, which was plainly visible through the thin abdominal wall. The paroxysm lasted a few minutes. No tumor could be felt anywhere on the abdomen; no hernia existed. Rectal examination negative.



*Diagnosis.* Chronic intestinal obstruction from carcinoma probably in large intestine, high up in the sigmoid flexure, or in the left or right flexure of the colon.

The patient was advised to go to the hospital for operation. I proposed to make an exploratory median laparotomy. If an inoperable carcinoma of the colon was found, to make the Maydl colotomy in two stages; if operable, to perform the radical operation.

*Operation.* On May 19, at the Emergency Hospital, in the presence of doctors from the Polyclinic, and assisted by Drs. Waters, Bernauer and Livingston, I operated in the following manner:

During the two days preceding operation the patient had not vomited. On palpation in narcosis no tumor was felt. During the preparation of the field of operation, a copious evacuation of the bowels occurred, due probably to the relaxation of the intestine in narcosis.

An incision three inches in length was made in the median line below the umbilicus, and the peritoneum sutured to the skin. The loops of small intestine which came into view were neither injected nor dilated. Examination with the hand in the abdominal cavity revealed nothing abnormal in the rectum or colon. This made me think that perhaps a false diagnosis had been made and that the patient's condition was merely due to chronic senile constipation.

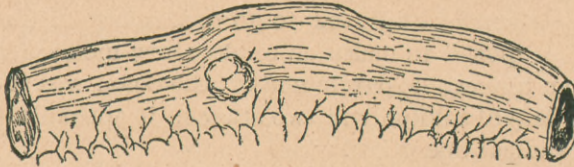Upon examination of the small intestine, I now discovered a small round tumor, which felt like an intussusception, and pulled the loop in which it was contained out of the abdominal wound. The tumor was the size of a walnut; the intestinal wall over it was somewhat thickened and movable, but the tumor could not be dislodged. Attempts at dislodgement caused traction upon the base of the tumor, which was seen to be  $1\frac{1}{2}$  cm. in diameter, covered with serosa, not the smooth muscularis, but a slightly depressed, slightly lobulated surface. It was situated on the side of the loop, midway between the convex border and the mesenteric attachment; half an inch from the latter (Figure 1.).

The loop was now emptied to a distance of five inches on each side of the tumor, and a strip of iodoform gauze



FENGER: BENIGNANT TUMORS OF THE ILEUM.

pushed through the mesentery and tied, to prevent feces from getting into the loop.



A longitudinal incision an inch and a half long was now made over the tumor, in the middle line of the convex border of the loop, whereupon the tumor came out. (Figure 2)

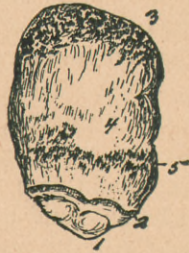

FIGURE 2—TUMOR.

Cylindrical tumor 45 mm. long; 28 mm. in diameter, clad with mucosa. 1. Base, proximal end, of tumor in wall of ileum as seen in Figure 1. 2. Border of mucous membrane covering tumor. 3. Distal end of tumor, dark, discolored, mucosa yellow from imbibition of bile coloring matter from feces, signifying necrosis of mucosa. 4. Mucosa: Light red, ecchymosis at "5."

It was smooth, cylindrical, rounded, 45 mm. long and 28 mm. in diameter, clad with mucosa, dark at the rounded end, and yellowish from imbibition of bile coloring matter from feces. As the base or pedicle of the tumor, which was  $1\frac{1}{2}$  cm. in diameter, extended beyond the line of incision, the latter was prolonged to the base which was excised leaving a transverse incision one inch in diameter.

The T-shaped intestinal wound was now united by step sutures, first a continuous silk suture from the distal end of the longitudinal to the transverse wound, and the transverse wound united by interrupted sutures passed through the mucosa only. Interrupted Lembert sutures were then introduced through the serosa and muscularis to bury the mucosa sutures, especial care being taken at the angles of the wound.

Examination of the intestine as to its permeability for feces and gases now revealed an indentation on the side of



the intestine opposite to the base of the incision, indicating that one of the mucosa sutures had caught the mucosa on the opposite side of the intestine. The sutures of the transverse wound were therefore loosened and the opposite wall of the intestine freed by division of the offending suture. The transverse wound was then reunited by mucosa and sero-muscular sutures as before, and the loop flushed with sterilized water.

The iodoform gauze strips which compressed the loop above and below were removed, and the permeability of the intestine as to feces and gases again tested. It was found that the intestine was entirely permeable at the place of operation and that at the line of sutures the intestine was air tight. The intestine was now flushed again with sterilized water.

An omental flap was then made by pulling down the omentum, which was followed by the transverse colon. The omentum was not quite long enough to go around the loop without some compression, but it was brought around and sutured to both sides of the mesentery.

The loop in the field of operation and the omental flap were now anchored by sutures to the parietal peritoneum at the lower border of the wound and an iodoform gauze drain laid down to the base of the loop. The remainder of the abdominal wound was then united in the usual manner.

The operation occupied about an hour and a half. At its close the patient was in good condition; pulse 110, and strong. He made a good and uneventful recovery and is at this time, sixteen months later, well.

#### MACROSCOPICAL EXAMINATION OF THE TUMOR.

The tumor is 45 mm. long, 28 mm. broad, cylindrical, smooth. At its distal end it is dark brown with spots of yellow from imbibition of bile coloring matter from the feces. The surface here is clad with mucosa necrosed as in typhoid ulcers, with red stripes from injection and ecchymosis. Over the remainder of the tumor the mucosa is normal. The base of the tumor, which is  $1\frac{1}{2}$  centimeters in diameter, is situated in the muscularis from which it probably originated.

The cut surface of the tumor (Figure 3) is smooth gray, tough, moist, a fibro-myoma. At the apex which corres-



ponds to the necrotic mucosa, it is dark red brown from imbibition with blood or hæmatin.

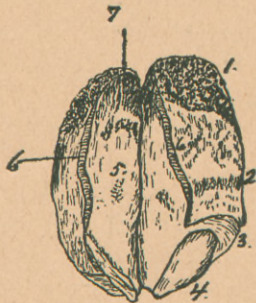


FIGURE 3—TUMOR LAID OPEN.

1. Distal end. 2. Normal mucosa on surface of tumor. 3. Divided mucosa and muscularis at base of tumor. 4. Tumor tissue at base covered with peritoneum. 5. Cut surface of tumor, smooth, homogeneous, grayish-white, perfectly uniform, tough. 6. Divided mucosa, immovable on tumor (no submucosa). 7. Cut surface of distal end of tumor, dark brown from imbibition of blood (hæmatin.)

#### MICROSCOPICAL EXAMINATION OF THE TUMOR.

Sections from the base at the place of the divided mucous membrane show:—

1. The mucous membrane is of normal thickness and structure, with perfect tubular glands and a normal layer of lymphoid cells between them.

2. The muscularis mucosa also extends over the whole surface of the tumor and forms a layer of bundles of organic muscular fibres half as thick as the mucosa proper, consequently considerably hypertrophied; there is a sharp line of definition between this muscularis and the tumor tissue and the elements of the one are not interwoven with those of the other.

3. The deep or circular layer of muscular fibres presents at the base of the tumor the following conditions: At the free end of the base (Fig. 3) it is of normal thickness and covered with a normal layer of the longitudinal muscularis. But at the corner where the tumor commences, the fibres spread out in bundles separated by fibrous tissue, the tissue of the tumor. These bundles of the muscularis can be followed as long radiating tracts deep into the tumor; they spread out like a fan and their branches become gradually more slender until bundles of 4 to 10 mus-



cular fibres form bands that finally are lost in the tissue of the tumor.

4. The longitudinal or outer layer of muscular fibres is present in normal condition as a continuous covering outside of the circular layers, and is covered with a normal layer of peritoneum.

The tissue of the tumor proper is a dense connective tissue with small connective tissue cells, and has many vessels; the latter are empty and not dilated, almost all small subcapillaries; neither larger veins nor arteries are seen. In many places, as well between the bundles of the circular muscle fibres above mentioned, as in the tumor inside of them, are tracts of myxoma tissue with branched cells and fine fibrillated—rarely homogeneous inter-cellular substance.

The anatomical character of the tumor would thus be designated as a mixed form of the connective tissue type—a myo-myxo-fibroma.

The tissue from which the tumor originated is the muscular coat of the intestine, not the external layer of longitudinal muscle fibres, but the inner layer of circular muscle fibres exclusively.

269 La Salle Avenue.

#### BIBLIOGRAPHY.

1. Baltzer, M. Archiv für klinische Chirurgie. Band xlv, heft 4, page 717.
2. Birch-Hirschfeld, F. V. Lehrbuch der pathologischen Anatomie. Band ii, 2nd half, page 585.
3. Böttcher. Archiv der Heilkunde. Band xi, page 125.
- 4; Förster. Virchow's Archiv. Band xiii, 1858, page 270.
5. Huss. Schmidt's Jahrbücher. Band li, page 171.
6. Klebs. Handbuch der pathologischen Anatomie. Band i, Abtheilung 1, page 266.
7. Leichtenstern. v. Ziemssen's Handbuch der Speciellen Pathologie und Therapie. Lieferung 19, page 542.
8. Pellizari. Centralblatt für Chirurgie. No. 14, 1875, page 222.
9. Perls. Lehrbuch der pathologischen Anatomie und Pathogenese. 1877, Theil i, page 425.
10. Rokitansky. Lehrbuch der pathologischen Anatomie. Band iii, page 231.
11. Virchow, R. Die Krankhaften Geschwülste. Band i, page 382.
12. Wesener. Virchow's Archiv. Band xciii, page 377.











