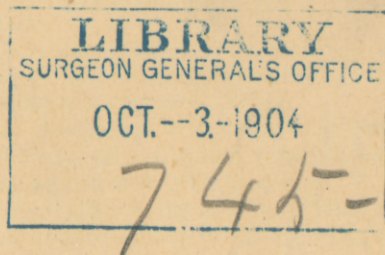


FENGER (C.)

Retention from Displacement, Bending and Valve-
Formation (Oblique Insertion) in the
Biliary Tract.

BY
CHRISTIAN FENGER, M. D.,
CHICAGO.



REPRINTED FROM
THE MEDICAL STANDARD, CHICAGO,
NOVEMBER AND DECEMBER, 1896,
AND JANUARY, 1897.

LIBRARY
SURGEON GENERAL'S OFFICE

OCT.--3-1904

745-

RETENTION FROM DISPLACEMENT, BENDING AND VALVE-FORMATION
(OBLIQUE INSERTION) IN THE BILIARY TRACT.*

BY CHRISTIAN FENGER, M. D., CHICAGO.

In the following paper I wish to call attention to a form of obstruction of the biliary passages which has as yet received comparatively little attention, partly because it is not very common, and partly because a minute study of the anatomical conditions is required to make us see the real character of the obstruction—namely, bending and valve-formation in the biliary passages.

Schueppel, in his encyclopedic article on the "Extra-Hepatic Bile-Ducts," states that the hepatic duct originates from a right and left main branch 5 mm. in diameter, which take up three or four smaller branches coming in from the longitudinal grooves in the hilus of the liver. The hepatic duct is 3 cm. long and 6 to 7 mm. in diameter.

The gall-bladder contains on an average 50 cc. of bile; its fundus is in a line with the anterior border and in contact with the hypochondrium corresponding with the cartilage of the eighth rib, at the place where the right parasternal line crosses the arch of the ribs.

The cystic duct is 4.8 cm. long, 4.5 mm. in diameter. At its place of origin, from the neck of the gall-bladder, it makes a considerable—almost an abrupt—bend. The shape of its lumen is peculiar and distinct from that of the other biliary passages in that when it is distended with fluid, the duct does not present a uniform smooth tube, but globular protuberances with furrows between, having a shape similar to a miniature colon; corresponding to the furrows there are found on the inner side of the wall semi-lunar valves, folds of the mucous membrane, the so-called Heister's valves, alternating on one and then on the other side of the canal at variable distances.

The axis of the canal of the cystic duct will thus be a rather curved or wavy line. It is evident that this condition will not only predispose to the arrest of gall-stones on their passage through the duct, but is also apt to favor occlusion by bending and valve-formation, as this condition is here so to speak, pre-existing.

The common duct is 7 cm. long, 6 or 7 mm. in diameter. In the hepatico-duodenal ligament, it has the hepatic artery on its right, and the vena porta on its inferior and posterior

surface down to the cavity of the duodenum. Its relations to the head of the pancreas are as follows: (a). It is located in a groove on the posterior surface of the head of the pancreas in fifteen out of twenty-two bodies (O. Wyss.); or, (b) it perforates the head of the pancreas; that is, it is surrounded by the tissue of the pancreas on all sides in seven out of twenty-two cases. This anatomical condition is important inasmuch as a swelling of the pancreas will in the first case push the common duct out of the way without compressing it, and only very considerable enlargement of the pancreas can cause stenosis by pushing or bending of the duct; while in the second case, compression leading to occlusion may easily take place where the duct passes through the head of the pancreas.

The intestinal portion of the common duct is 2.4 cm. long, 2 mm. in diameter, perforates the wall of the duodenum obliquely, first passing through the muscularis, then running for a while in the sub-mucosa before it passes through the mucous membrane, which here forms the so-called caruncula duodenalis major, through which it enters the duodenum. While running in the sub-mucosa of the duodenum, it takes up the pancreatic duct at an acute angle, 8 or 10 mm. before it enters the duodenal caruncle. The opening or canal through the latter is called the porus biliaris. This main trunk, 8 to 10 mm. in length, is the so-called Vater's diverticulum.

When we examine into the mechanism of occlusion of the bile passages as given by Schueppel, we find it arranged as follows:

1. Obstruction from within. (a) Bodies that fill the lumen, gall-stones, parasites, echinococcus, ascaris, dystomum hepaticum. (b) Cicatricial strictures following local inflammations of the mucosa, causing or leading to either complete occlusion, that is, obliteration, or stricture formation. (c) Tumors within the bile ducts—benignant or malignant.

2. Obstruction from without. Compression from masses of cicatricial tissue or adhesions, the result of chronic inflammation, peritonitis or perihepatitis.

3. Finally, as has been especially stated by Niemeyer, deviations of the bile-ducts in the

* Read before the American Surgical Association, 1896.

hilus from displacement caused by peritonitic adhesions between the hilus of the liver and the neighboring organs, colon, omentum, duodenum, stomach, abdominal wall. Virchow has pointed to similar conditions due to pregnancy and other causes.

I shall call attention at this time only to the last group. Virchow was probably the first to definitely call attention to retention from bending of the bile-ducts. He states that in women with corset-liver-lobe and with considerable atrophy of the liver tissue in a line with the pressure from the ribs, he has seen, during pregnancy, that the lobe has been folded over against the right lobe of the liver, and when the line of atrophy is located high up near the hilus, the gall-bladder has followed it, and this bending of the gall-bladder has caused traction on the bile-ducts, displacement of their shape and icterus.

Virchow saw a fatal case of severe icterus where the corset-liver-lobe was turned upward in a patient who was not pregnant, but because of adhesions between the gall-bladder and the colon which came up on the anterior surface of the liver, pulling the bile-ducts with it.

Courvoisier mentions bending of the cystic duct at its origin as a cause of obstruction of the gall-bladder. He further mentions that the permanency of a biliary fistula following cholecystostomy with normal bile-ducts may be due to traction on the gall-bladder and cystic duct in an abnormal direction (for instance, downward), causing a bend at the upper end of the ductus choledochus, so that the hepatic duct is in line with the cystic duct, resulting in all or most of the bile passing out through the fistula and little or none through the common duct.

Bending of the duodenal portion of the common duct followed by unilateral dilatation above and valve-formation, the same as in the urinary passages, has been observed and rightly interpreted by Konitzky. Seyffert, in a similar case of dilated common duct, speaks briefly of "Ventilartige Verschluss," valve-like occlusion, but does not enter into any detailed consideration of the subject.

My views on the question, from what I have seen in the cases to be mentioned below, are the following:

Bending is most likely to take place at the beginning of the cystic duct and at the beginning of the duodenal portion of the common duct, because these are the places where there is a sudden change in the diameter of the passages. The bending may be caused either by elongation of the ducts or by traction from adhesions. The obstruction caused by the bending is here, as in the urinary passages, at the beginning incomplete, resulting in intermittent retention and consequently in intermittent

attacks of the symptoms. The obstruction will be followed by retention and increased pressure above resulting in dilatation or hypertrophy. Hypertrophy without dilatation I have seen in the gall-bladder; dilatation sometimes with and sometimes without hypertrophy, in the ducts.

Obstruction caused by valve formation will give rise to the same symptoms as obstructions from other causes, namely, recurrent attacks of biliary colic, without icterus, if the obstruction is above the common duct; with icterus if the passage of the bile into the intestine is prevented.

Case 1. Bending of the Cystic Duct.

Synopsis. Recurrent attacks of pain in region of gall-bladder for twenty years—no icterus. Tumor to be felt in region of gall-bladder. Cholecystectomy. Hypertrophied gall-bladder occluded by bend of cystic duct at its origin. Cystic duct otherwise normal. Extensive and firm adhesions between the entire biliary tract and surrounding organs. Recovery from operation. Four months later, relapse of attacks of pain.

Mrs. M. L., thirty-eight years of age, was admitted to Mercy hospital in my service January 8, 1896. The patient's family history was good. She had had the ordinary diseases of childhood. She is married and has two children, aged respectively fifteen and thirteen. Twenty years ago the patient began to complain of severe pain in the umbilical region, occurring in attacks at intervals of one or two months, and the attacks lasting four or five days. Occasionally the attacks terminated with vomiting. The patient was never jaundiced and never to her knowledge had clay-colored stools. Early in November, 1895, the attacks became more severe and without free intervals between the attacks, constant soreness being present. The appetite failed and the patient lost ten pounds in weight. About this time she noticed a tumor in the abdomen just above and to the right of the umbilicus. The tumor moved with respiratory movements, and after palpation it almost disappeared. The urine was normal, but there was impaction of feces.

The diagnosis lay between carcinoma of the ventricle or transverse colon, inflammation in and around the gall-bladder, peritoneal tuberculosis and fecal accumulation. Dr. Billings made the diagnosis of right movable kidney and in addition a tumor, probably of the gall-bladder.

Operation.—On January 17, 1896, I operated in the following manner: The patient was anesthetized with ether. An incision was made along the outer border of the right rectus muscle. The gall-bladder presented in the wound one inch below the border of the liver. It was hard on the sides, but there was fluctuation over the fundus. It was adherent to the transverse colon and pylorus, and the lesser curvature and anterior wall of the stomach. The adhesions were so firm that it was necessary to peel off a layer of the wall of the gall-bladder in order to loosen the organ. From the feeling of the gall-bladder I suspected carcinoma, but no carcinomatous nodules could be found anywhere in the surrounding organs. The introduction of a hypodermic needle brought out no fluid because the

gall-bladder was afterwards found to contain only a little bloody gelatinous mucus, and a number of small, irregular pigment concretions. I could detect no grating of the needle on stone, but Dr. Morgan noticed a grating which was probably produced by contact of the needle with one of the pigment concretions.

The gall-bladder was loosened, peeled off from the liver, the hæmorrhage stopped by the Paquelin cautery. The cystic duct was then isolated, ligated, disinfected with crude carbolic acid and cut off. The wound was packed with sterile gauze, which was brought out of the wound. The patient made a good recovery and was discharged from the hospital on Feb. 17. On the fifth day after the operation the packing was removed from the wound and the edges of the wound approximated.

As shown by the figure (Figure 1), there is a very considerable hypertrophy of the non-dilated gall-bladder and the cavity is smaller than usual, and is partitioned off in three wide spaces with narrow necks between. It contained about a teaspoonful of reddish gelatinous mucus, not bile-colored, in which was found a few irregular concretions of inspissated bile pigment masses, not gall stones.

Microscopic examination of the wall shows no distinct hypertrophy of the muscularis, but the wall consists of a mass of wavy connective tissue, sparsely provided with vessels. In the para-vascular spaces and lymph spaces are granulation tissue cells, here and there in larger groups, showing a chronic lymphangitis and periphlebitis, similar to the condition I have so often found in the chronic inflammations of the appendix, giving rise to attacks of remittent appendicitis. Near the surface of the gall-bladder in the place of the serosa, the accumulation of leucocytes is more dense. The inner wall is covered with a layer of mucous membrane, in which are a number of tubular glands, on the surface of which is cuboid and cylindrical epithelium.

On the outer wall of the gall-bladder, near the cystic duct, is a swollen lymph-gland the size of a hazel-nut. The cystic duct goes off at a right, or rather at an acute angle; its wall is normal, not thickened. Its lumen is 15 mm. wide and is consequently, if anything, smaller than normal. A probe passes from the cystic duct easily into the gall-bladder and at the entrance, at the angle of the bend, the wall forms a valve which has caused the occlusion.

On May 16 I received a letter from the patient in which she said she had been gaining steadily until a week previous, when she began to feel very much as she did before the operation. It therefore seems probable that a second operation will be necessary in this case.

Remarks.—The choice of operation in this case between leaving and removing the gall-bladder was easy, as the gall-bladder was evidently useless and was the seat of inflammation of long standing. The density of the adhesions of the surrounding organs to the whole tract of bile-ducts made any further loosening of the adhesions inexpedient, so much the more as I

thought I had the right to expect that the symptoms would be relieved by division at this point as the cystic duct was normal. The return of symptoms as shown by the letter from the patient, seems to prove that it belongs to the same class as the eighteen cases operated upon by Riedel, where the pain was caused by adhesions between otherwise normal bile passages and the surrounding organs, and in this case it would seem as if separation of the adhesions from the remainder of the bile-ducts would be necessary in order to cause permanent cessation of the symptoms.

Riedel remarks: "But even when the stones have been passed by the bowel, the patient is not even then sure to be free from attacks of pain and digestive disturbance, as

these symptoms can be caused by adhesions between neighboring organs and the gall-bladder which may contain bile, but is oftentimes pulled into manifold shapes." He also states that in addition to one hundred and twenty cases of gall-stones operated upon in his surgical clinic, there were eighteen patients who were operated upon on account of attacks of pain caused by adhesions alone. As long as these adhesions do not cause retention, as in the eighteen cases mentioned, the patients retain their weight and strength, because there is no cholæmia and no sepsis. If infection from reten-

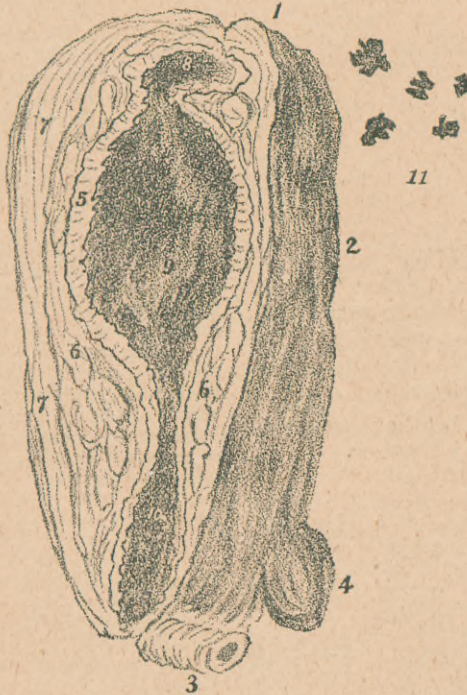

FIGURE 1.—GALL-BLADDER.

1. Fundus. 2. Corpus. 3. Cystic Duct. 4. Lymph-Gland.
5. Mucosa, thickened and velvety, 1 to 2 mm. thick.
6. Sub-Mucosa, 3, 5, 7 mm. thick. 7. Muscularis, 3 to 5 mm. thick. 8. Small Cavity in Fundus, 15 mm. wide, 5 mm. high, caused by constriction, separated from 9. Large Cavity in Corpus, 25 mm. wide, 33 mm. long, separated by a stricture 15 mm. long from 10. Cavity 15 mm. long, 15 mm. wide, Entrance to Cystic Duct, whose opening is 1.5 mm. wide. 11. Hard, irregular bile pigment concretions.

tion in the gall-bladder has been the cause of the pericystitis, we may expect to find the remaining adhesions less dense and easier to separate.

The reason why, in this case, the symptoms should persist, while the remaining adhesions after the apparent removal of the cause should yet cause recurrent attacks of pain, is as yet

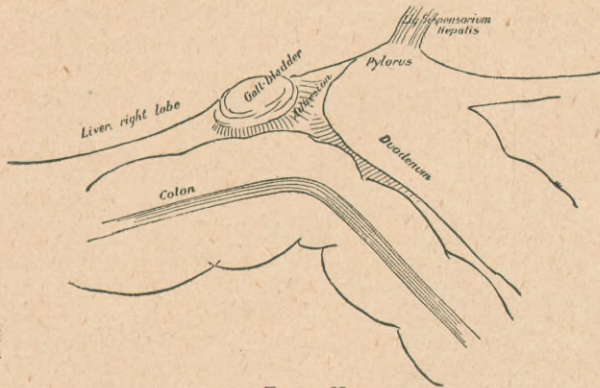


FIGURE II.

unknown to us. As Riedel remarks: "Why is it that thousands of patients walk around with their adhesions without ever dreaming of their existence, and a few only have to suffer all the time from identical adhesions?"

Case II. Bending of the Duodenal Portion of the Common Duct Without

Dilatation Above.

Synopsis. Intermittent attacks of pain in right hypochondriac region with vomiting and jaundice for eight years. Three or four months previous to the operation a gall-stone passed by the bowels. Since that time, increasing frequency of attacks. Operation between attacks. Icterus present. No gall-stones in biliary passages. Gall-bladder slightly thickened but otherwise normal. Dilatation of cystic duct. Common duct not dilated. Extensive adhesions between duodenum and common duct and between descending and ascending portions of duodenum. Loosening of all adhesions. Cholecystostomy. Free passage of a flexible sound from gall-bladder down into duodenum. Recovery.

Mrs. A., 28 years of age, was admitted into Mercy Hospital in my service, April 20, 1896. The patient's family history was good, she had had the ordinary diseases of childhood, but until 1888 was very healthy. At this time, however, she began to have severe paroxysms of pain in the right hypochondriac region radiating toward the right scapula, accompanied by nausea and vomiting and followed by jaundice, which would last for about a week. The stools were clay-colored, and there was great tenderness at the right costal arch. The first attack lasted for a few hours only and she felt well until three months later, when she had a similar attack. These attacks have since recurred at

irregular intervals, which diminished gradually from three months until now they recur every two to four days.

Although the patient had carefully examined the stools for several years, she found a gall-stone for the first time in December or January last. She has lost rapidly in weight and strength since the attacks have recurred so frequently. Her appetite is good; the bowels are obstinately constipated, but the bowel-movements are normal in appearance and color. During the attacks the patient gets relief only by assuming the knee-chest position.

Examination.—The patient's skin was slightly icteric, the conjunctivæ very slightly if at all abnormal; the abdomen was lax, as the patient had borne children; the border of the liver could be felt in normal position right below the costal arch at the outer border of the rectus. An indistinct hardness could be felt at the border of the liver. There was slight tenderness over the gall-bladder and over the entire right half of the epigastric region.

Diagnosis.—Cholelithiasis. Obstruction from stones in the duct, one having passed four months ago. The symptoms were apparently typical; many slight attacks, two or three per week, the stone passed four months ago which presented round surfaces and no facets, and the inflammation of the gall-bladder, which was retracted but thickened with adhesions.

I advised cholelithotomy and on April 24, after the usual preparations, I operated in the following manner: The patient was prepared as usual. Dr. Letourneau administered the ether and Drs. Morgan and Rankin assisted.

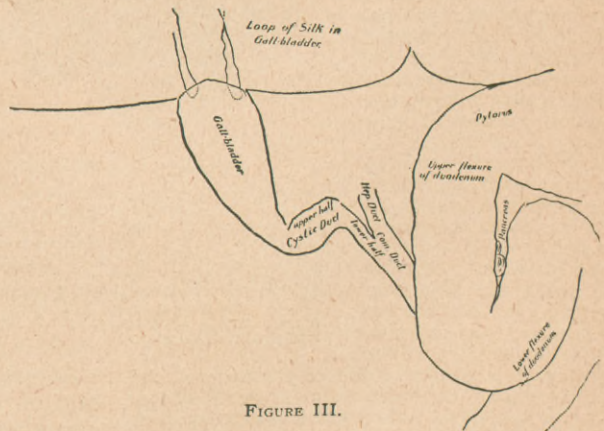


FIGURE III.

A lateral longitudinal incision was made from the ribs to the umbilicus, the peritoneum stitched to the skin, and eighteen flat gauze sponges inserted. Upon palpation the fundus of the gall-bladder was found free on line with the border of the liver. The transverse colon was adherent to the body of the gall-bladder close to the fundus (Figure II). The pyloric portion of the duodenum was adherent to the gall-bladder and the transverse colon. The adhesions were loosened partly by cutting between the ligatures and partly by blunt dissection with the end of the finger and Kocher's

sound, and the gall-bladder freed up to the neck. Below the neck could be seen a transverse swelling, the upper half of the cystic duct, which went off at a right angle, was one cm. broad and two to three cm. long, and on palpation was found to be empty—that is, it contained no stones. (See Figure III.)

The gall-bladder was empty, the wall slightly thickened. The duodenum was found to be pushed over so as to cover the hepatico-duodenal ligament, and was loosened by blunt dissection and pushing with the ends of the fingers so as to expose the territory of the common duct. When this had been laid bare for an inch and a half or two inches, the finger passed up through the foramen of Winslow could feel no stone, but the pancreas was so swollen and nodular that I suspected cancer.

Upon palpation of the duodenal (anterior) surface of the pancreas through the duodenal wall, neither stone nor movable polypus could be felt, but only the enlarged hard lobes of the pancreas. Along the common duct, on its free border, were two lymph-glands the size of a half hazel-nut.

By stretching the common duct I could see it shining through the anterior wall of the ligament as a whitish band, 7 to 10 mm. broad, little if any dilated. I could also see the lower half of the cystic duct shining through, beginning at the bend, dilated, horizontal, upper half of the duct and going down to the common duct at a right angle with the upper portion and in line with the common duct.

So far, the examination gave no explanation of the symptoms. Stenosis from the bend in the dilated and thickened cystic duct might cause pain in the region of the gall-bladder by reason of retention, but would not cause icterus, and besides this the gall-bladder was empty. I thought of carcinoma in the head of the pancreas, but the pancreas felt exactly as the inflamed pancreas feels in cases of gall-stone. I sought for stone in Vater's diverticulum, but could detect no hard, movable body through the duodenal wall.

The pancreas was not freely palpable on both sides of the duodenum because the left side of the pancreas near the head was covered with a loop of the duodenum—that is, the ascending portion.

The ascending portion of the duodenum was now loosened from the descending portion; the adhesions were soft and elastic, like spider's web, and an inch or more below, the nodular left border of the head of the pancreas was encountered.

I thought perhaps the traction on the duodenum from adhesions might cause pain and possibly icterus and that by loosening the adhesions and freeing the ascending from the descending portion of the duodenum, the attacks of pain might cease. When this had been done I could grasp the head of the pancreas and the duodenum over it with the left index finger and thumb, the index finger being in the foramen of Winslow, and lift the head of the pancreas and the duodenum a little forward, and could palpate the entire duodenal surface of the head of the pancreas with the fingers of the right hand. I could detect no stone, but felt some harder, nodular portions, especially one shown in Figure III, between the two portions of the duodenum.

I then passed a long fine sewing needle through the side of the pancreas and the hard nodule into the head of the pancreas and its

duodenal portion in the endeavor to discover a stone in Vater's diverticulum. The fine needle could do no harm even if it went through the duodenum. However, after pushing the needle in different directions from a single point of insertion, I could not detect any stone.

I concluded that no stone could be present except perhaps a small one in Vater's diverticulum, and that there was no carcinoma. The question as to the cause of the icterus and the measures to be taken to relieve the condition then arose.

I did not want to open either the duodenum or the common duct simply for exploration; I therefore resolved to open the gall-bladder, to attempt to explore the common duct from this point, and to relieve the icterus and cholæmia for the time being by the establishment of a biliary fistula.

Sponges were packed entirely around the hilus of the liver and two loops of heavy silk, half an inch apart, were inserted in the gall-bladder. The wall of the latter was thickened. The gall-bladder was now incised between the loops. Upon incision, neither bile, pus nor other fluid escaped, but after a few minutes a little blood came out, from which cultures were taken with negative results. Upon exploration with the little finger no stones were found in the gall-bladder, whose walls were smooth and velvety.

The common duct was now explored through the gall-bladder. A flexible, olive-pointed bougie was inserted in the wound in the gall-bladder, but was stopped at the bend in the cystic duct, which it could not pass. By lifting the liver and making traction upon the gall-bladder, the bent upper half of the cystic duct could be straightened, and by manipulating the cystic duct with the index finger (exactly as a finger in the rectum on the prostate gland can guide a catheter into the bladder) the end of the bougie was passed through the cystic into the common duct, and, by manipulating the duodenum and head of the pancreas, was finally passed down into the duodenum.

Digital exploration along the bougie in the gall-bladder, the cystic duct, the common duct, and for three or four inches in the duodenum where it met the lower bend of the duodenum failed to detect any stone.

I therefore concluded that no stone was present, that the bile-passages and the common duct were patent and that the icterus had been due to bending or oblique insertion of the intestinal portion of the common duct, which was pulled to one side by the adhesions between the ascending and descending portions of the duodenum.

The cholecystostomy was completed by uniting the gall-bladder to the parietal peritoneum, but not to the skin, by eight sutures, and packing the wound in the wall outside of the opening in the gall-bladder, in which a rubber drainage tube was inserted. A gauze drain was also passed down on the common duct and the duodenum. The operation required about two hours.

The patient's progress was uneventful; May 1, the dressings were soaked with bile. The packing below the gall-bladder was removed and the stitches tightened. The wound was clean. May 4, the stitches were removed, the wound had united perfectly. The dressings were saturated with bile. The packing around the tube was removed and new packing

inserted. May 6, very little bile in the dressings. May 8, no bile in dressings, and icterus disappearing. May 11, tube removed. Dressings slightly stained with bile. Light packing inserted and the stitch tightened. May 13, dressings stained with bile and wound closing. May 17, the patient has been out of bed for six days, has had no pain since operation, can walk around, is up all day and can eat anything. The stools are normal. The dressings are slightly tinged with bile and serum. The skin and sclerotics are normal in color. Two weeks later biliary fistula finally closed.

Remarks.—Could the stone which had passed four months prior to the operation and had caused adhesions—that is, local plastic peritonitis on the surface of the biliary passages and the pancreas—have left adhesions uniting the ascending and descending portions of the duodenum over the head of the pancreas, producing a displacement sufficient to cause pain? This was possible. Could this condition also have caused recurrent retention of bile and icterus by deviation or displacement of the direction of the duodenal portion of the common duct or the papilla, or must there of necessity be a small stone in Vater's diverticulum to account for the icterus?

testine that no permanent dilatation of this duct resulted. During its passage through the common duct, the usual plastic peritonitis, which extended to the pancreas, caused the free surfaces of the ascending and descending portions of the duodenum to become adherent to each other for one inch in the transverse diameter of the intestine. This adhesion in the exact line where the duodenal portion of the common duct is situated, caused displacement (*Verlegung*), and the consequent continuance of the attacks of pain and icterus after the disappearance of the stone or stones.

Leichtenstern reports a similar case of frequently recurrent attacks of colic without passage of stones by the bowels, with chronic icterus. At the operation the gall-bladder was found to be totally atrophied. It was universally adherent to the surrounding organs and contained a thimbleful of mucus. No stones were found here or in the cystic or common duct, after thorough separation of the adhesions. The icterus disappeared immediately after the operation and perfect recovery followed. Leichtenstern remarks: "The pain



FIGURE IV. FLEXIBLE METALLIC SOUND.

The plastic peritonitis on the left half of the head of the pancreas caused the here otherwise movable descending portion of the duodenum to adhere to its surface and become still more firmly fixed by additional adhesions to the ascending portion of the duodenum.

Could the immobilization of the duodenum have caused the difficult passage of ingesta and the duodenitis? Duodenitis would not give rise to such frequent attacks of pain. A mechanical cause for the frequent attacks would be much more likely, but in a former observation, (Case V, "Stones in the Common Duct,") a small stone in Vater's diverticulum did not cause obstruction, but did cause the frequent attacks of pain, not by inflammation of the wall of the duct but by some mechanical action.

The course of the disease in this case seems to be as follows: When the symptoms began eight years ago, with biliary colic and icterus, a stone or stones, perhaps the one passed four months previous to the operation, became impacted in the cystic duct, causing dilatation and bending as found during the operation and shown in Figure III. The inflammatory swelling around this dilated cystic duct caused compression of the hepatic duct or inflammation of the ducts sufficient to occasion icterus. The stone passed down into the common duct so short a time before its removal through the in-

and periodic attacks of colic as well as the icterus must have been caused by pulling and constriction from the adhesions."

The anxiety I experienced in this case in order to make sure that no stone existed anywhere in the biliary tract, was not relieved by the passage of a flexible sound from the gall-bladder down into the duodenum, because a small stone, half hidden in a diverticulum, might escape notice, notwithstanding palpation along the sound.

As the rubber sound does not permit of feeling the click of a stone, I have had made a flexible metallic sound (see Figure IV). I first had made a flexible metallic sound 33 cm. long, olive pointed at both ends, and made of a steel spiral. In searching for stones in the cystic duct, through the gall-bladder, I found that the click of a gall-stone could be easily felt, at any distance, but I also found that the flexibility of the sound would not allow it to pass the angles of a bent cystic duct. I therefore made the following modification: Through the hollow flexible metal sound I passed a soft metal (copper) stylet. This permits of giving the sound any shape or bend desired, which is retained as long as the stylet is in. I am thus enabled to pass the sound over the angle or bend, and by removal of the stylet the flexible sound can then be passed further on. I can thus feel the click of a stone low down in the com-

mon duct or in Vater's diverticulum, even of a small stone that would escape notice upon palpation along the sound through the wall of the duodenum.

I have recently had an opportunity to demonstrate the usefulness of this sound at a post-mortem examination on a patient upon whom I had made an exploratory laparotomy which had failed to detect any gall-stones, and who died a month later with symptoms of duodenal obstruction. A biliary calculus the size of a cherry stone was found in the duodenal portion of the duct. The sound passed down from the gall-bladder, passed by the stone and entered the duodenum without difficulty. On moving the sound up and down I could easily feel the grating of the stone against the side of the spiral sound.

Case III.—Oblique Insertion of the Duodenal Portion of the Common Duct with Dilatation Above.

Synopsis.—Recurrent attacks of pain of varying intensity and at irregular intervals in the region of the liver for twenty-five years, sometimes followed by icterus, most severe in the spring and autumn. Probable diagnosis, stones in the common duct with probable cholecystitis. Operation during severe attack in January, 1896. No stones found, but chronic cholecystitis and extensive adhesions between the cystic and common ducts and surrounding organs. Extreme dilatation of the common duct, which presented a sac the size of a hen's egg. Cholecystotomy, no stones in the gall-bladder. Duodenum opened to explore diverticulum of Vater, no stones found, wound closed. Opening of common duct revealed no stones, but enormous cystic dilatation. Closure of wound in common duct. Opening in gall-bladder united to skin. Death after twenty-four hours. Autopsy: No bile in peritoneal cavity, no peritonitis. Duodenal portion of common duct of normal size and patent; at its upper portion bending and oblique insertion into the dilated common duct, dilatation of cystic and hepatic ducts.

Miss X., a teacher, 33 years of age, was sent to me for operation by Dr. Windrow, Jan. 24, 1896. She was never well as a child, but was always dull, hypochondriac and morbidly retiring. She had an extremely violent temper, which, as she came to adult life, she was careful to keep under control. She had the first attack of pain in the region of the liver at the age of 7 or 8. The attacks which were sometimes followed by icterus, recurred and she began early to use morphine to relieve the pain. During the more severe attacks she became intensely cold, and was obliged to use hot baths to overcome the cold and pain. She had consulted prominent medical men in Europe, but without relief. One physician diagnosed gall-stones, and advised operation. During all this time she was treated with internal medicine, massage and electricity, but did not improve.

Change of climate and work was advised for her, and she came to the United States in 1889. During her stay in the east she felt better at first, but, later on, the seacoast did not seem to agree with her, and so in 1892 she came to Chicago. She seemed on the whole better after this, but had severe attacks in the spring and

autumn. The attacks would last for ten days with one exacerbation daily, which usually occurred one hour later each day. The attacks would be brought on by mental excitement, anger, or irregularities in diet, such as too heavy a meal, or too much wine or coffee. As she was aware of this she put herself upon a well-regulated diet, and lived a quiet life, but still had difficulty in filling her position as a teacher.

Menstruation commenced at the age of 12. It was always painless and lasted three days. She had no leucorrhœa. She was habitually constipated, and sometimes her bowels would not move for several days. She used rhubarb as a laxative, and after it operated the movements were apparently normal. Occasionally the stools were clay-colored. The urine was often dark after the attacks, was passed slowly and in small quantities. She was subject to severe headache, and became very nervous after work or when exhausted.

The attacks often commenced with sudden and violent pain, which forced her to lie down, undress and apply hot compresses over the liver, and also required the hypodermic use of morphine. Icterus was sometimes present during the attacks, with yellowish-green skin and yellow conjunctivæ.

During 1892 and 1893 she drank a good deal of Vichy water, and applied cold water compresses over the liver at night, which seemed to help her for a time. During the summer of 1895 she was ill most of the time and had very frequent attacks. With the advent of 1896 she became worse. Her last attack occurred on January 13; it was attended with violent pain, which was not relieved by morphine; icterus, temperature 103 degrees, extreme tenderness over the liver and obstinate constipation. When the latter condition had been overcome by large doses of rhubarb, the stools were clay-colored. The patient was confined to her bed for two weeks, at the time of this last attack, in the hospital where I was called to see her.

Upon examination, the patient was not emaciated, was deeply icteric, the skin was dark greenish-yellow and conjunctivæ icteric; temperature 102 degrees; pulse 110. She had constant pain in the region of the gall-bladder, and the feces were clay-colored. Examination of the abdomen showed that the hot fomentations for the pain had so burned the skin of the right half of the abdomen that several granulating surfaces were present. The liver was somewhat enlarged, extending one and one-half inches below the costal arch. There was indistinct resistance in the region of the gall-bladder and tenderness on pressure.

The frequently recurrent attacks of pain and icterus, with comparatively short duration of the latter, made the diagnosis likely to be gall-stones in the common duct, together with probable stones in the gall-bladder causing inflammation of the same. The patient was removed to the Passavant Memorial Hospital for operation.

Operation.—On January 26, I operated in the following manner: Ether, preceded by morphine, was administered by Dr. Waters. The abdomen was disinfected, the granulating skin surfaces scraped with a sharp spoon, and a piece of gauze sewed to the margin of the skin incision.

I now made a lateral longitudinal incision from the ribs to below the umbilicus. Considerable hæmorrhage ensued from the vessels in the abdominal wall. The fat was an inch in

thickness and the posterior sheath of the rectus muscle tense. The peritoneum was sewed to the skin wound. The border of the liver and the gall-bladder presented in the wound. The gall-bladder was of the same color as the liver, and, on a plane with its free border, felt like a mass of flesh or liver, had the shape of a bent finger, and no fluctuation could be detected. There were no adhesions at the top of the gall-bladder, but the corpus was adherent to the pylorus, duodenum and transverse colon. The adhesions between the gall-bladder and the pylorus, greater curvature of the stomach and duodenum, which was covered by the fundus of the stomach, were separated to a depth of two or three inches, partially by division between ligatures and partially by blunt dissection. The pylorus and duodenum were thus loosened from the body of the gall-bladder and the adhesions between the latter and the transverse colon separated by division between ligatures and blunt dissection. The duodenum could not be recognized until the

body of the gall-bladder. The walls were smooth and velvety and no stones could be felt. No sound or probe, either metal or elastic, could be passed down into the cystic duct. The introduction of Murphy's button was impossible on account of the thickness of the wall, which was 1 cm. thick. Consequently cholecystenterostomy by this method was out of the question. In continuance of the search for stones in the duodenal portion of the duct, I now opened the duodenum over the diverticulum of Vater. An assistant made digital compression of the duodenum above and below the point of incision. I made a longitudinal incision one-half an inch long in the duodenum over the head of the pancreas, which was followed by the escape of air bubbles, bile and mucus. Upon introduction of the finger in the incision, no stone could be felt nor could the opening of the bile duct be discovered.

The next step in the operation was the opening and exploration of the common duct. With the finger in the foramen of Winslow an incision

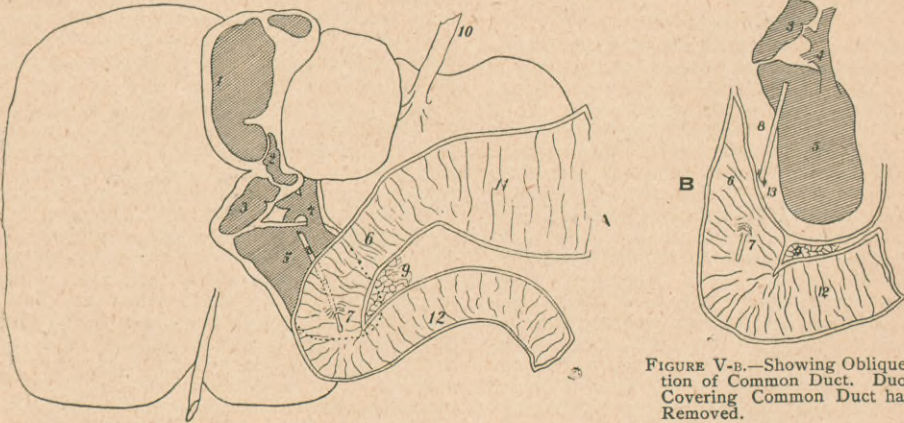


FIGURE V. (One-third natural size.)

Bile-Ducts filled with Paraffin. 1. Gall-Bladder. 2. Upper Half of Cystic Duct. 3. Lower Half of Cystic Duct. 4. Hepatic Duct, somewhat dilated. 5. Common Duct dilated to a large sac extending downward and to the left behind the descending portion of the duodenum, and even a little behind the ascending portion of the duodenum. 6. Descending Portion of Duodenum. 7. Biliary Papilla. 8. Probe passed through Duodenal Portion of Common Duct. 9. Pancreas. 10. Suspensory Ligament of the Liver. 11. Stomach. 12. Ascending Portion of the Duct. 13. Point at which Non-Dilated Portion of Common Duct Enters Dilated Portion of the Duct.

FIGURE V-B.—Showing Oblique Insertion of Common Duct. Duodenum Covering Common Duct has been Removed.

ventriculum of the stomach had been separated from its anterior surface. Finally I found the foramen of Winslow and on introducing the finger into the lesser omental sac, I found an elastic tumor the size of the small intestine between the duodenum and the hilus of the liver; this was the common duct dilated to a tumor two inches in diameter, with the duodenum adherent to and partially covering it. I could detect no stones; no enlargement of the pancreas could be felt, nor could any tumor be felt through the duodenum.

With a view to exploring the bile ducts for gall-stones from within, the gall-bladder was opened at the fundus by an incision three-fourths of an inch long. The wall was 1 cm. thick, soft and bleeding, and mucus escaped followed by bile. Upon digital exploration after incision, I found the supposed tumor to be a thick partition wall encroaching upon the lumen of the gall-bladder from the knee like bend (Fig. V-A, 1), dividing off the smooth upper portion. The exploring finger entered the cavity in the fundus, below which was a narrow isthmus and below this a larger cavity in

three-fourths of an inch long was made in the common duct, through which bile escaped. Digital exploration revealed a cavity the size of a hen's egg, with smooth walls, and which contained no stone. In the upper right portion of this cavity I could feel two openings, the anterior being the entrance to the cystic duct and the posterior the entrance to the hepatic duct. I could feel the division or place where the hepatic and cystic ducts united to form the common duct. The openings were 1 cm. or more in diameter at the upper right end of the cavity of the dilated common duct. The wall of the duct was white and firm, 2 mm. in diameter, slightly thickened and the duct was considerably dilated. The probe or sound could not be passed down into the duodenum, nor could any stone be felt. The duodenum was so immovable that it was impossible to bring it into apposition with the common duct for choledochoduodenostomy. I therefore closed the wound in the duodenum with Czerny-Lembert sutures.

As the operation had already lasted a considerable time—about two hours and a half—and as the patient was becoming weak, it was

not deemed advisable to unite the common duct to the small intestine, and I therefore concluded to close the wound in the common duct and make a gall-bladder fistula to the skin to relieve the icterus. The wound in the common duct was now closed with a double row of sutures, and the opening in the gall-bladder sutured to the skin. A drainage tube was inserted in the gall-bladder, with gauze above and below the gall-bladder, down to the wound in the common duct. Another drainage tube was inserted down to the wound in the common duct, with gauze packing below it. The wound was then closed and dressed in the usual way. At the close of the operation the patient was weak; pulse 120.

She never recovered from the collapse; in the course of a few hours her temperature began to rise, the pulse grew weaker, and she died twenty-four hours after the operation.

Autopsy.—The condition of the peritoneum was normal, the intestines little, if any, distended; the ovaries, uterus, appendix, lungs, heart and liver normal. The incision wound of the duodenum was agglutinated, and the gauze packing adherent to it. The wound in the common duct was firmly agglutinated, the duct greatly distended and its walls very much thickened. The gall-bladder was enlarged and its walls thickened. The gauze was universally adherent to the field of operation. No stone could be found. The kidneys were not examined, but the pancreas, spleen, and stomach were normal; the latter was filled with a brownish fluid.

The body was markedly jaundiced and quite well nourished. The dressings and gauze were saturated with greenish-yellow bile. After removal of the gauze around the drain to the common duct, no bile, pus, or serous fluid could be found; the surfaces were perfectly dry; there was no fluid of any kind in the peritoneal cavity, and the parietal and visceral peritoneum was glistening, smooth and perfectly normal.

The following injection experiments were made to show the patency of the biliary tract:

1. Water was injected into the gall-bladder through the opening in the apex by a four-ounce hard rubber syringe. The water filled the gall-bladder, but was stopped at the neck and did not enter the cystic duct. Fluid could pass up into the gall-bladder, but, by reason of the valve-like formation, nothing could pass down.

2. The nozzle of the syringe was now inserted into the common duct through a small opening made on its anterior surface above the sutured incision made during the operation. The common duct now became distended until it formed a large round tumor, the size of a hen's egg, or larger, extending downward and to the left behind the duodenum and upward to the hilus of the liver. As this sac became more tense the water entered the gall-bladder and flowed out through the opening in its apex, but even when this was held closed and more water was injected, not a drop passed from the common duct into the duodenum, showing complete obstruction when the common duct was distended.

After reopening the wound in the duodenum, the opening in the diverticulum of Vater could easily be found, and the probe passed up through the duodenal portion into the common

duct. Small quantities of water passed down along the probe into the duodenum.

As no stone could be found in the common duct or gall-bladder it was evident that the obstruction to the flow of liquid was caused by valve-formation or bending or oblique insertion, between the gall-bladder and the cystic duct and between the common duct and its duodenal portion.

These obstructions were still further studied and illustrated by filling or injecting the biliary passages with paraffin, for the careful accomplishment of which I am indebted to Dr. Haiselden, my house surgeon in the German Hospital of Chicago.

Remarks.—No stone was present, the gall-bladder was hypertrophied by reason of a valve in the cystic duct; the common duct was dilated on account of valve-formation near the diverticulum of Vater. The operative indications under these circumstances were to open the duodenum and make a communication-opening between the duodenum and the common duct. This can be done when the common duct is found to be dilated, by first opening the common duct and making digital exploration, and then opening the duodenum, sewing the wall of the common duct to the wall of the duodenum, and closing the openings in the duodenum and common duct. In this case, as the patient had been two and a half or three hours under operation, I was unable to carry the operation beyond this point. If the duodenum is sufficiently movable to allow the openings to be brought together, choledochoduodenostomy could be made by suture or by the Murphy button.

Konitzky reports the case of a girl twenty-one years of age who was admitted to the Gynecological Clinic at Marburg, October 24, 1887. She was healthy as a child, menstruated at sixteen. Menstruation was regular for a year, then ceased for two years and was irregular thereafter. She last menstruated June, 1887. At the age of fifteen she had general weakness, nose-bleed and was ordinarily subject to headaches. In July, 1887, the headache increased, with loss of appetite, gradually increasing icterus, increasing weakness and enlargement of the abdomen in the region of the liver. On examination, strongly marked icterus was observed and a tumor which included almost the entire right half of the abdomen and extended 10 cm. over on the left side. The tumor extended from the liver to the ilium. It was fluctuating and had no connection with the pelvic organs; the stools were clay-colored and the urine contained bile. The diagnosis was made of echinococcus cyst of the liver, causing pressure on the bile ducts. He operated on November 6, 1887. A longitudinal lateral incision was made, whereupon the cyst presented in the opening. Before the cyst was opened it was sutured to the parietal peritoneum. Upon

incision the cyst wall was found to be 2 mm. thick. A large amount of thin, greenish fluid was evacuated. The inner wall of the cyst was dark green. After evacuation the cyst wall was united to the skin, and the usual dressings applied. Microscopic examination of the cyst wall showed it to be connective tissue, and no traces of glands, epithelium or muscles could be found. The condition of the patient was satisfactory immediately after operation. On the third day cough set in with bloody sputum; on the sixth day she passed 510 grams of urine, and vomiting commenced. On the seventh day the pulse was 100 and weak with severe vomiting and beginning collapse, and she died on the eighth day. The autopsy showed no peritonitis. The gall-bladder was atrophic and the bile ducts in the liver dilated. After opening the duodenum, the duodenal papilla was found low down, and permitted the passage of a sound from the papilla into the cyst. The duodenal portion of the common duct was $2\frac{1}{2}$ cm. long, not dilated, but rather narrower than normal, but perfectly patent; was located on and entered the cyst on its lower left aspect or wall. It passed through the wall obliquely from behind forward. At the upper end of the cyst, (the dilated common duct) was a dilated hepatic duct. The gall-bladder was contracted and narrow, the cystic duct, or at least its lower half, dilated and about 2 cm. in diameter, and entered the cyst about 5 cm. away from the hepatic duct. The cyst then was a common duct dilated in its whole extent, down to the duodenal portion. The pancreas was normal. The pancreatic duct did not unite with the duodenal end of the common duct, but passed into the duodenum separately and opened into the latter 4 cm. above the papilla for the common duct.

The author thinks it possible that gall stones may have been the primary cause of the dilatation, but after their passage other causes must have come into play. As the autopsy showed a bend of the common duct at the point where it enters the wall of the intestine, he believes that this bend caused a valve-like occlusion, and calls attention to the analogous condition of valve-formation in the upper end of the ureter, where it originates from the pelvis of the kidney. As the valve-formation in the ureter is often incomplete at first, causing intermittent hydronephrosis and gradual dilatation commencing at the place of obstruction, so he thinks that a gradually increasing dilatation of the common duct above the duodenal portion took place in this case above the valve or bend.

He cites a similar case reported by Douglas in 1852, who found the following condition at the autopsy of a girl, seventeen years old,

who had presented the symptoms of icterus, fever and a painful tumor in the right hypochondrium: The common duct was dilated to a large sac containing half a gallon of fetid bile. The walls of the sac were thickened and the openings of the hepatic and cystic ducts dilated so as to permit the passage of a finger. The gall-bladder and the portion of the cystic duct nearest the gall-bladder were not dilated, but there was considerable dilatation of the hepatic and bile ducts. At the lower edge of the large sac, towards the duodenum, there was a small opening leading into a normal, undilated duodenal portion of the common duct, at the upper end of which a sort of valve was found.

Seyffert reports the case of a woman, 23 years of age, who had been married three years. One year later, after child-birth, icterus set in, which was permanent, with an interruption of three months. Six months later she had swelling of the abdomen and tenderness on pressure, and nine months later a sudden and violent attack of hepatic colic, which lasted a day and a half and was accompanied by hæmatemesis, vaginal hæmorrhage, and some gastric disturbances; the urine was dark; she had pain in the lumbar and sacral regions, which was relieved by flexing the thighs upon the abdomen. An ovarian tumor was suspected. Examination showed tenderness over the liver and in narcosis, a normal sized, somewhat hardened gall-bladder was found in the normal location.

Below and close to the right lobe of the liver was a large round tumor the size of a child's head, soft, fluctuating, and extending from the border of the liver to two inches above the symphysis pubis. The fluctuation was indistinct and there was clear percussion over the tumor. It was not connected with the genital organs. The urine contained a small amount of bile coloring matter.

Diagnosis.—Cyst of the pancreas.

Operation.—On May 28, 1888 an incision 10 cm. long was made in the linea alba above the umbilicus, and the peritoneum sutured to the skin. The cyst was punctured and a portion of its contents, which consisted of dark green,ropy bile, evacuated; a piece of the wall of the cyst which was about 5 mm. thick, was excised, and the cyst wall sutured to the skin with mattress suture. The cyst was now emptied and showed a smooth inner surface with no gall-stones or concretions. A drainage tube was inserted and dry dressings applied.

For several days after the operation the dressings were soaked with bloody bile; the stools were yellowish-brown and covered with bile. The patient got on well until four weeks after the operation, when more blood appeared

in the dressings, mixed with bile, and suddenly obstinate vomiting with abdominal pain, dizziness and increasing weakness set in, and she died two days later, apparently without much pain, with symptoms of anæmia.

Post-Operative Diagnosis.—Cystic tumor in the right hypochondriac region containing bile.

The autopsy revealed a small, retracted, empty gall-bladder, which did not extend beyond the border of the right lobe of the liver; the liver was large, smooth, and grayish-green. The liver, stomach, pancreas and duodenum were taken out together; the biliary papilla in the duodenum was found to be swollen and no bile passed on pressure. The probe could be passed in for 5 cm.. The duodenal portion of the common duct was cut open from the biliary papilla, and from this point up, the duodenal portion of the common duct was normal, patent and opened freely into the large cavity. A sound could be passed from the gall-bladder into the cystic duct which was somewhat dilated and $2\frac{1}{2}$ cm. long, and from here into the cystic cavity. The hepatic duct also opened into the cystic cavity, consequently the latter was formed by the enormously dilated common duct, the cystic and hepatic ducts partaking in the dilatation. The cyst, when opened, presented a cavity the size of the fist; up toward the liver the surface was of a grayish-red color, the inner surface showing even to the naked eye the appearance of a dilated bile duct. On microscopic examination, the inner wall of the sac was found to be covered with typical cylindrical epithelium. In the neighborhood of the cystic duct, the sac was of a greenish color; the lower portion of the sac, near the duodenal third of the common duct, was ulcerated, uneven, with necrotic strings and masses, and was covered with a soft, fresh coagulum the size of a walnut.

Post-Mortem Diagnosis.—Large cyst of the common duct; laparotomy; ulcerative destruction of the inner wall of the cyst with hæmorrhage; universal anæmia.

Remarks.—The autopsy showed neither stones, strictures, valves nor tumors in or outside the common duct. The ulcerated territory was probably caused by gall-stones that had disappeared, but no gall-stone could be found in the body or the feces. The lumen of the duodenal portion of the common duct was normal, patent, and passage was impeded only by swelling of the mucous membrane. The violent attacks of gall-stone colic, as given in the history, would speak for a pre-existing stone, but the anamnesis is imperfect, as the patient was in the clinic only two days before the operation and the diagnosis of pancreatic cyst was made. The icterus, having persisted for almost

a year and a half, was probably caused at first by catarrhal duodenitis. The attacks of pain, which lasted a day and a half, were thus probably caused by incarcerated gall-stones. The feces were ordinarily not clay-colored, consequently the occlusion of the bile ducts was not complete; the history also stated that feces were mostly normal. Subsequent to the operation the feces were always bile-colored; there was consequently incomplete retention, as both urine and feces contained bile, and the author concludes that the valve-like occlusion of the common duct must have permitted the passage of some bile after the emptying of the cyst. (The valve mechanism is not described or further mentioned by the author.—F.)

Why did the patient die, as the bile passed down into the duodenum after the operation, and as at first all the other grave symptoms disappeared? This was due to the necrotic inflammation of the sac and hæmorrhage and subsequent fatty heart.

From the above cases it will be seen that bending and valve-formation at the beginning of the duodenal portion of the common duct are followed by considerable, even enormous, dilatation of the latter. When the dilatation reaches an extreme degree, a cystic tumor is found below the liver.

Diagnosis has never yet been made before the operation or before the autopsy. The prognosis is apparently grave, as all the patients operated upon have died. As to the plan of operation, we can conclude what to do only when it is possible to make a diagnosis during the operation. The choice of procedure will be between choledochoduodenostomy or choledochenterostomy on the one hand, and choledoch-abdominal fistula on the other. If the common duct is dilated to a large cavity, which presents like a cyst against the abdominal wall, choledochostomy might be preferred for temporary relief, and possible spontaneous disappearance of the pain when the sac is retracted. If the passage of bile into the intestines is not re-established spontaneously, choledochenterostomy might be attempted later on. In lesser degrees of dilatation of the common duct, primary choledochenterostomy might be made, preferably into the duodenum.

In all cases of this kind it is impossible to make an exact diagnosis beforehand. There is no difference in the symptoms between obstruction from stone and obstruction from other causes, with the exception of malignant tumors. As calculous obstructions are by far the most commonly encountered, we naturally at first expect to find a stone, and it is not until during the operation that we are disappointed in this respect, and find that we have to look out for

other conditions. It is natural, therefore, that this is the class of cases which causes the operator a great deal of mental anxiety during the operation in regard to making the choice of the different procedures at his disposal. How to relieve the patient from the symptoms must be decided then and there.

269 La Salle Avenue.

BIBLIOGRAPHY.

Courvoisier, L. G. Casuistisch-statistische Beitrage zur Pathologie und Chirurgie der Gallenwege. Leipzig, 1890.

Douglas. Cited from Konitzky.

Fenger. Stones in the Common Duct and Their Surgical Treatment. American Journal of the Medical Sciences. February and March, 1896.

Konitzky, G. Ein Fall von hochgradiger cystischer Erweiterung des Ductus Choledochus. Inaugural Dissertation, Marburg, 1888.

Leichtenstern, O. Behandlung der Erkrankungen der Gallenwege innere Behandlungs-

weisen. Handbuch der speciellen Therapie innerer Krankheiten. Band 4, Abth. 6, b.

Niemeyer, F. Lehrbuch der speciellen Pathologie und Therapie. Berlin, 1863. Band 1, page 671.

Riedel, B. Chirurgische Behandlung der Gallensteinkrankheit. Band 4, Abth. 6, b., page 80.

Schueppel, O. Die Krankheiten der Gallenwege und Pfortader. V. Ziemssen's Handbuch der speciellen Pathologie und Therapie. Lief. 22, page 4.

Seyffert, R. Zur Pathologie der Gallengaenge. Cyste der Ductus Choledochus operativ-behandelt. Inaugural dissertation. Greifswald, 1888.

Virchow, R. Die Krankhaften Geschwulste. Band 1, page 276.

Virchow R. Gesammelte Abhandlungen. Page 756.

Idem, page 777.

Wyss, O. Zur Aetiologie des Stauungs-Icterus. Virchow's Archiv. Band 36, page 454.

