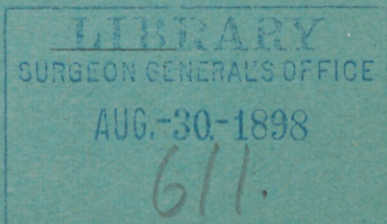
 Duhring (L. A.)

A CASE OF LEPRO MACULOSA
ET TUBEROSA.

BY

LOUIS A. DUHRING, M.D.,

PROFESSOR OF SKIN DISEASES IN THE UNIVERSITY OF PENNSYLVANIA.



FROM

THE MEDICAL NEWS,

December 27, 1890.

Reprinted from *THE MEDICAL NEWS*, December 27, 1890.

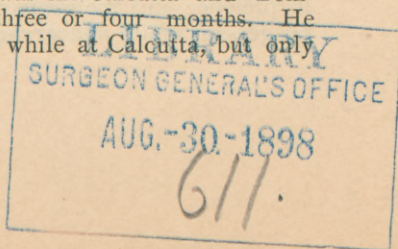
A CASE OF LEPROSY MACULOSA ET TUBEROSA.

By LOUIS A. DUHRING, M.D.,
PROFESSOR OF SKIN DISEASES IN THE UNIVERSITY OF PENNSYLVANIA.

RECENTLY a case of leprosy, illustrating the macular variety, came to my notice in this city. The man presented himself for treatment, and at the time was entirely unaware of the nature of the disease. He had been under the care of a number of physicians, and had been treated for supposed syphilis and other affections, but no one had even intimated to him that the disease was or might prove to be leprosy. When told of the disease from which he was suffering he expressed great surprise, and even doubt as to the correctness of the diagnosis, for the reason that he had not for many years been in a leprosy country or district, and even then only as a traveller; and, moreover, because none of the other physicians who had treated him from time to time had so regarded the disease.

The notes of the case are briefly as follows:

J. A., aged forty-one years, and born in Sweden. There is no family history of interest. He was in Peru and Chili in 1868, and was in the merchant-marine service as a sailor from 1871 to 1888. In 1878, he was in Calcutta and Bombay for a period of three or four months. He frequently went ashore while at Calcutta, but only

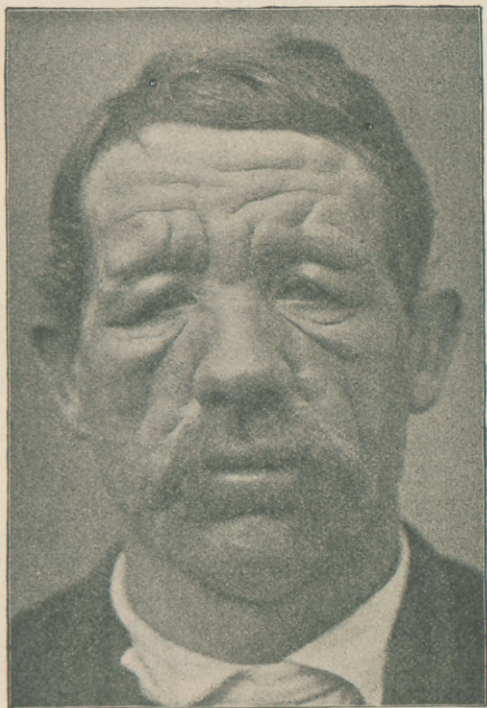


once while at Bombay. He has never visited other leprosy countries, and during the past eighteen months has lived in a city near Philadelphia, working in shipyards and printworks. He has no idea concerning the origin of the disease, which made its appearance, he states, two and a half years ago, upon the left brow and on the posterior surface of the right thigh, in the same form as it now exists. At first the spots were so faintly discolored and thickened as to be barely noticeable, and they have gradually become more and more pronounced, and have greatly multiplied. At present the disease involves the entire face, the trunk, and extremities, and exists in the form of numerous rounded and ovoidal, coin-sized, dull-yellowish, and dusky-orange, smoky, coppery, and brownish-yellow macules, and tuberoso and flat patches of infiltration. The latter are flat or elevated, and in some places even lumpy or nodular, as on the face. The disease is most marked on the face and back. (See cuts.) The face shows the peculiar heavy-looking, severe, leonine expression so characteristic of this disease, due to the tuberoso infiltration and swelling of the cutaneous tissues, and the consequent sinking-in of the normal lines and creases of the skin. The eyelids are much thickened, and droop, as shown in Fig. 1.

There are no circumscribed tubercles present, either on the face or on other regions, the infiltrations, as stated, being in the form of diffuse or spread-out tuberoso or flat lesions, such as occur in late syphilitic infiltrations and gummata. The macules and patches are distinctly anæsthetic—some more so, some less—the sticking of a needle into the skin causing no pain. The disease gives rise to no subjective symptoms, nor inconvenience beyond its presence and the consequent disfigurement, and his general health and strength remain good.

The disease portrays mainly the macular manifestation in an advanced stage. The lesions are numerous and extensive, and the entire force of the

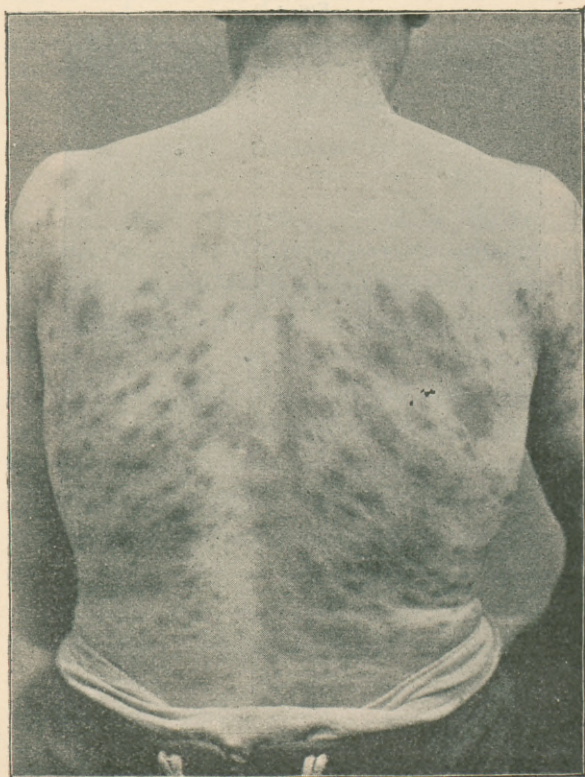
FIG. I.



infective process seems to have expended itself on the skin. Some of the lesions on the trunk well illustrate the so-called morphoea of leprosy, as de-

scribed by Erasmus Wilson and others of the older authors, and the resemblance to the ordinary mor-

FIG. 2.



phœa simplex is so marked as to suggest that both diseases have a common starting-point in nerve

complication, although, of course, of an entirely different nature. This I feel convinced of, and I have long held this view. Both kinds of cutaneous lesions are due to impaired or altered nerve-supply, the one—lepra—to a known and definite cause, the other—morphœa simplex—to obscure and non-specific causes. Both are neuritic.

A piece of infiltrated skin was excised and prepared for the microscope. The examination was made by Dr. M. B. Hartzell, to whom I am indebted, with the following results: The lesion from which sections were made for microscopical examination was situated upon the posterior surface of the upper part of the right thigh, and was one of the earliest signs noticed by the patient, and was therefore one of the oldest. No pathological changes of any kind were found in the epidermis. In the corium an abundant diffuse infiltration of small round cells existed, with here and there slender tracts of unaltered connective tissue. This cellular infiltration was seen to be uniformly distributed throughout all parts of the corium, except that immediately beneath the papillary portion, where it was completely absent. In this part of the corium, beyond a few dilated lymph spaces, no change was noticed. No so-called lepra cells were anywhere found. Numerous sections, stained according to the methods of Weigert and Ziehl, were carefully examined for bacilli, but none were seen.

The man was seen only once, having subsequently failed to return for advice and suggestions as to treatment. The case is interesting from several points of view. First, as to the date and origin of the disease, and as to the mode of infection, upon which questions nothing positive can be stated. The natural supposition would be that the disease

was contracted in India, and the only point which renders this doubtful is the long period—ten years—between the time of exposure and the first manifestations. But, it is entirely possible, and even probable, that the disease manifested itself insidiously, perhaps for several years before the attention of the patient was called to it. I think this highly probable, more especially as the man is by no means intelligent or observing. There is no history of contact with other lepers. The patient was amazed when informed of the true nature of the disease, which he had never suspected, and appeared to be anxious to place himself under treatment.

The second point of interest relates to the diagnosis. As stated, he had been seen by many physicians, none of whom informed him as to the nature of the disease, nor instituted or suggested any systematic course of treatment. The disease is undoubtedly lepra, but could be, I can well see, confounded with several affections, notably with granuloma fungoides (mycosis fungoides) in its early stage, to which it bears resemblance, also the infiltrated form of tubercular syphilis; but the wide distribution and the numerous areas of disease, and the bronzed tint of the skin, ought to be sufficient to exclude the latter disease. On the other hand, the dusky-yellowish color is not unlike that seen in granuloma fungoides; but the variegated colors as well as the inflammatory symptoms common to that disease are wanting.

THE MEDICAL NEWS.

A National Weekly Medical Periodical, containing 24-28 Double-Columned Quarto Pages of Reading Matter in Each Issue. \$4.00 per annum, post-paid.

THE year 1890 witnesses important changes in THE MEDICAL NEWS resulting from a careful study of the needs of the profession. Its price has been reduced, and its bulk also, though in less proportion. The mass of information, on the other hand, has been increased by condensing to the limit of clearness everything admitted to its columns. Three new departments have been added to its contents—viz.: *Clinical Memoranda*, being very short signed original articles, *Therapeutical Notes*, presenting suggestive practical information, and regular *Correspondence* from medical centres. *Hospital Notes* will detail the latest methods and results of leading hospital physicians and surgeons. Special articles will be obtained from those best qualified to write on subjects of timely importance. Every avenue of information appropriate to a weekly medical newspaper will be made to contribute its due information to the readers of THE NEWS.

The American Journal of the Medical Sciences.

Published monthly. Each number contains 112 octavo pages, illustrated. \$4.00 per annum, post-paid.

IN his contribution to *A Century of American Medicine*, published in 1876, Dr. John S. Billings, U. S. A., Librarian of the National Medical Library, Washington, thus graphically outlines the character and services of THE AMERICAN JOURNAL: "The ninety-seven volumes of this Journal need no eulogy. They contain many original papers of the highest value; nearly all the real criticisms and reviews which we possess; and such carefully prepared summaries of the progress of medical science, and abstracts and notices of foreign works, that from this file alone, were all other productions of the press for the last fifty years destroyed, it would be possible to reproduce the great majority of the real contributions of the world to medical science during that period."

COMMUTATION RATE.—Postage paid.

THE MEDICAL NEWS, published every Saturday,	} in advance, \$7.50.
THE AMERICAN JOURNAL OF THE MEDICAL SCIENCES, monthly,	

LEA BROTHERS & CO., 706 and 708 Sansom St., Phila.