

Cohen (S.S.)

al

A CASE OF AKROME GALY.

BY

SOLOMON SOLIS-COHEN, M.D.,


PROFESSOR OF CLINICAL MEDICINE AND APPLIED THERAPEUTICS IN THE PHILADELPHIA POLYCLINIC; ONE OF THE PHYSICIANS TO THE PHILADELPHIA HOSPITAL, ETC.


*presented by the author.*

FROM

THE MEDICAL NEWS,

November 5, 1892.





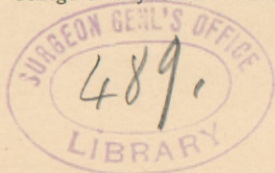[Reprinted from THE MEDICAL NEWS, November 5, 1892.]

### A CASE OF AKROMEGALY.<sup>1</sup>

BY SOLOMON SOLIS-COHEN, M.D.,  
PROFESSOR OF CLINICAL MEDICINE AND APPLIED THERAPEUTICS IN THE  
PHILADELPHIA POLYCLINIC; ONE OF THE PHYSICIANS  
TO THE PHILADELPHIA HOSPITAL, ETC.

THE case of akromegaly herewith reported I met with accidentally. The subject is not aware that he has any disease, and while he has kindly given me permission to publish his measurements and photograph, he has stipulated that the face should be rendered unrecognizable. This has been skilfully accomplished by retouching the photographs prior to reproduction. Untouched photographs are presented for the information of the Fellows of the College. I saw the man attempting to engage in athletic sport, and was amused by the way in which the big, burly fellow was literally played with by a much smaller man. He is a native American, and born of native-American parents, of English stock. He is six feet two and a half inches in height, and apparently of great muscular development. At the age of sixteen years he weighed one hundred and eighty pounds. His present weight, at the age of twenty-five years, is two hundred and thirty-eight pounds. Up to four years ago he was a blacksmith, and was then able to wield a thirty-pound sledge. Now he cannot lift much weight, and cannot vie with smaller men in athletic exercises of any kind. He is clumsy and sluggish in

<sup>1</sup> Read before the College of Physicians of Philadelphia, October 5, 1892.





movement, and although he can run long distances (four miles) without becoming "winded," he is quite slow. He has not spontaneous or intense headache, though headache may be brought on by close study; occasionally he has confusion of ideas. He claims to have a remarkable memory for facts in history and literary quotations, but he finds difficulty with mathematics or other studies requiring deep thought. This is not necessarily abnormal. He has periods of drowsiness. His appetite is exaggerated. He has not noticed excessive thirst or polyuria. A single examination of the urine failed to disclose the presence of albumin, sugar, or tube-casts.

The thickening and dumpiness of the fingers are quite characteristic. The hands (Fig. 1) are enlarged laterally rather than longitudinally, having a characteristic spade-shape. The skin is thick and tough, and the fine lines almost obliterated, while the main furrows are coarse and deep. The segmentation of the fingers is thus quite marked in the photograph. The nails are short and broad, not striated. The grasp is not strong. I was able to endure without wincing his greatest pressure upon my own hand.

His feet are broad, flat, large and fleshy, and he has had to increase the size of his shoes, more particularly in breadth, within two years.

In two years the size of his hat-band has twice been increased, from six and three-quarters to seven, and now to seven and a half. His nose and ears have been large since boyhood, but his nose has lately much increased in size. Three years ago he first noticed the increase in the size of other features and a changed expression of his face, and at his last vacation his family noticed that in the nine months of his absence from home his physiognomy had altered considerably. At the age of sixteen years he thinks that he was as tall as he is at present.

FIG. 1.

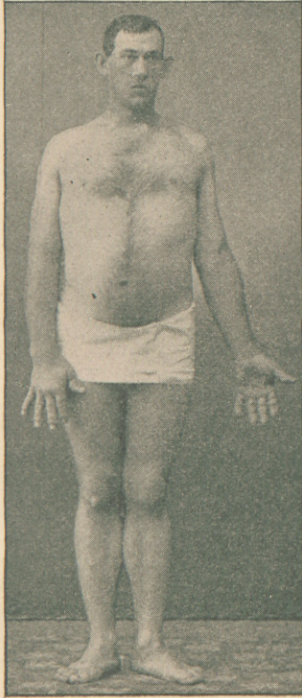


FIG. 2.

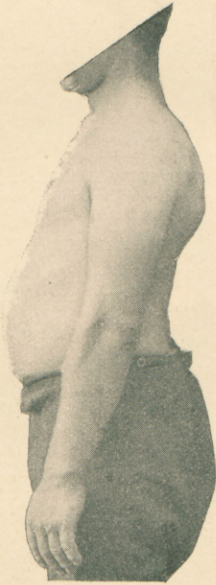
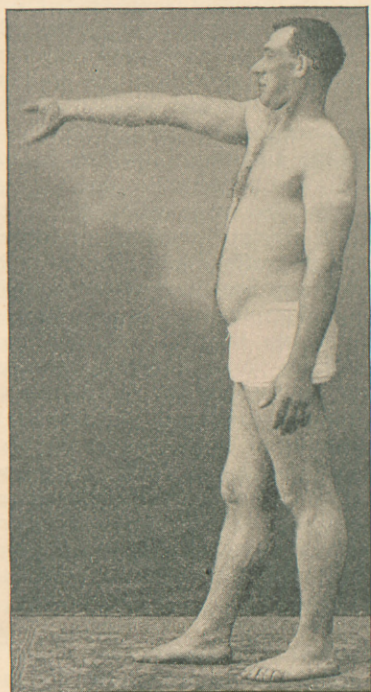




FIG. 3.



His father and brothers are tall men, but their noses and hands, the man distinctly states, are unlike his. They do not stoop. Very noticeable in his attitude is his stoop forward—the cervico-dorsal kyphosis, with a tendency to forward thrust of the head (Fig. 2). This is likewise shown negatively in a photograph (Fig. 3) by the manner in which he has thrown the trunk backward from the waist in order to get the head into a vertical position. The varicose condition of the veins of his legs also attracted attention. There is a slight paunching of the abdomen. The nose is large, thick, characteristic. The patient states that it is "growing." The superciliary ridges are prominent, the frontal sinuses much enlarged, giving a characteristic forehead, as is well shown in the profile (Fig. 3); the malar bones are enlarged, projecting laterally, so that the outline of the face is the typical lengthened ellipse of akromegaly.

The ears are large, standing out at right angles with the head, and the cartilages are thickened almost to rigidity. The lips are thick and the lower lip overhangs the chin. The tongue is broad, thick, deeply furrowed. The lower teeth do not project beyond the plane of the upper, although the chin is much enlarged vertically. The scapulæ are enormous, and the acromion and coracoid processes can be easily demonstrated, while the distance between them seems to be quite great. The sternal extremities of the clavicles stand out prominently as knobs. The sternum is unusually long, and the xiphoid process is apparently ossified.

The thyroid cartilage is large, thick, and gristly; the cricoid is apparently ossified; internally the larynx is large, but presents no abnormality. Although the external nose is immense, the nasal chambers do not appear to quite correspond in size, but I did not make accurate measurements. The thyroid gland was not demonstrable, although careful search was made for it by Dr. Franklin H. Hooper, of Boston, and myself.



Dulness on percussion over the upper portion of the sternum gives some color to the theory that there is a persistent thymus in some of these cases.

The thoracic and pulmonary development is remarkable. The man has an expansion of more than six inches, and the chest-sounds are perfect both on percussion and on auscultation. The heart is apparently proportionate in size to the frame. No lesion was detected.

One feature present that I have not seen mentioned in connection with these cases is a peculiarity of the olecranon and olecranon fossa. The former is comparatively small, the latter apparently much deeper than normal. Hyper-extension of the arm could be readily produced. The photographs show this, and also a similar phenomenon at the knees. (Fig. 3.) The patellæ readily slip out of place, and the man has been laid up three times on account of luxation of the patella.

The rough examination that I was able to make detected no lesion of the eye. I did not have an opportunity to have an ophthalmoscopic examination made.

The photographs do not adequately represent the case, but they are, I think, sufficient to verify my descriptions. The case is interesting in demonstrating that akromegaly is not so rare as one might be inclined to imagine. The man is young, and may be expected to develop other symptoms, while the present conditions will probably become more marked.







*The Medical News.*

*Established in 1843.*

A WEEKLY MEDICAL NEWSPAPER.

*Subscription, \$4.00 per Annum.*

---

*The American Journal*

OF THE

*Medical Sciences.*

*Established in 1820*

A MONTHLY MEDICAL MAGAZINE.

*Subscription, \$4.00 per Annum.*

---

COMMUTATION RATE, \$7.50 PER ANNUM.

---

LEA BROTHERS & CO.

PHILADELPHIA.